



YT → Top 10 mnem
5pm
↓
Anatomy ✓

ANESTHESIA AIIMS PYQ

• fast five mcqs
↓
1.4.

Medsynapse by Dr. Nikita



Which of these is most commonly used as pre-anesthetic medication ?

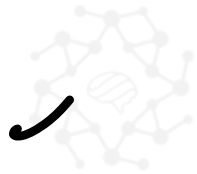Cholinergi → contractⁿ
↑ Secretions

a. Atropine ✓

b. Scopolamine

c. Promethazine

✓ Glycopyrrolate



MEDSYNAPSE
Where Concepts Meet Mnemonics

→ anticholinergic - ↓ secretions
atropine
• CNS.



Which of the following combinations can be used for day care surgery?

- a. Ramifentanil, midazolam, propofol → PONV ↓ ✓
- b. Fentanyl, midazolam, thiopentone sodium
- c. Morphine, midazolam, propofol
- d. Morphine, diazepam, ketamine



Which anesthetic agent can cause pain on IV administration?

egg allergy
↓
NOT C/I

a. Ketamine

b. Propofol

c. Thiopentone

d. Midazolam



oil based inj.

MEDSYNAPSE
Where Concepts Meet Mnemonics



Muscle relaxant that can be used in a patient with high serum bilirubin of 6.0 and serum creatinine of 4.5 mg/dL?

Cisatracurium → No histamine release

- a. Atracurium → Hofmann elimination (plasma)
Does not require kidney/liver.
- b. Vecuronium
- c. Pancuronium
- d. Mivacurium



A pregnant woman with placenta previa started to bleed as she went into labor. Her blood pressure was 80/50 mm Hg. A lower segment caesarean section was planned in view of acute shock. What type of anesthesia will you plan for this patient?

- control better
- ✓ a) General anesthesia with IV induction by ketamine
 - b) Spinal anesthesia up to L4 level
 - c) General anesthesia with IV induction by propofol followed by maintenance with fluranes
 - d) Sedation and epidural analgesia

Sympathetic
↑BP
∴ in shock
• NMDA
• Dissociative
anest
• emerg delirium



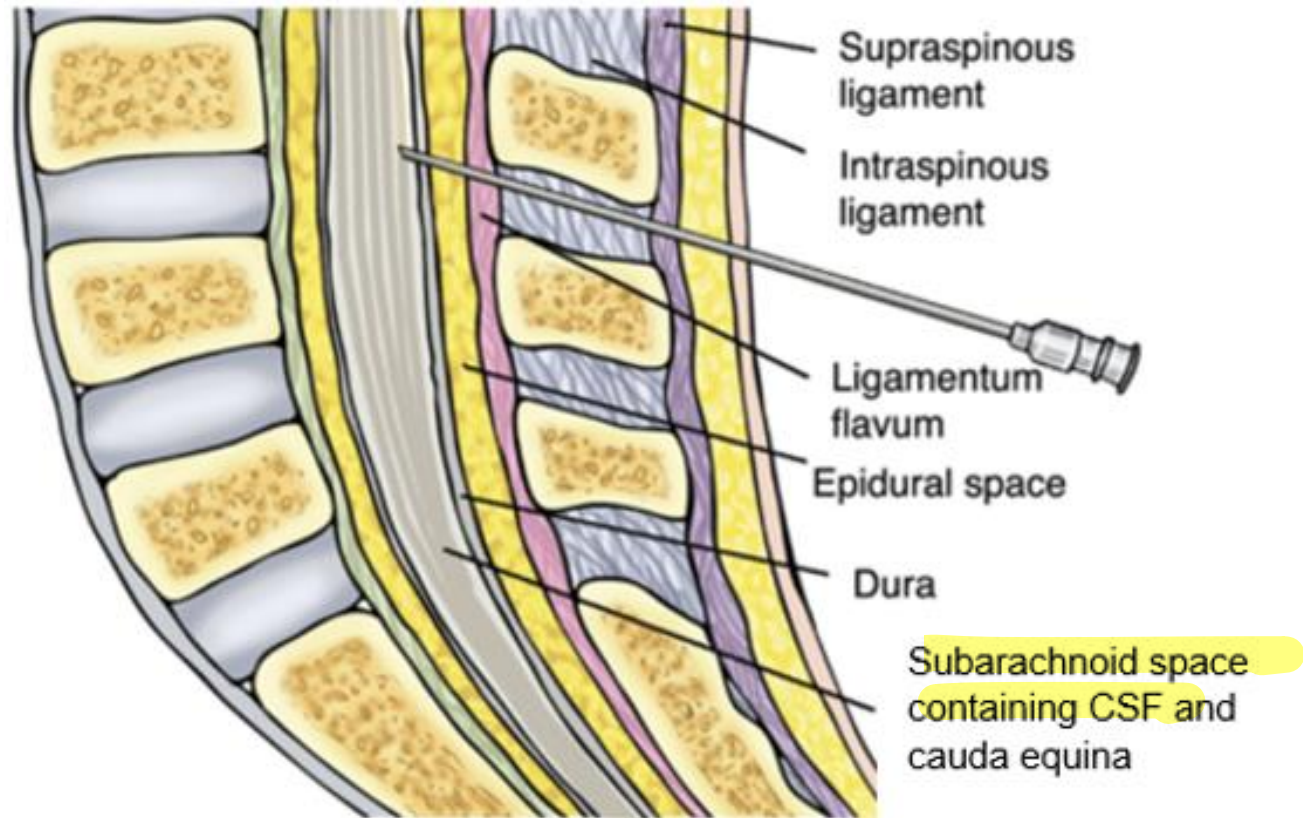
While performing a lumbar puncture, a snap is felt just before entering into the epidural space. This is due to piercing of which structure?

→ subarachnoid space
CSF

- a. Ligamentum flavum
- b. Supraspinous ligament
- c. Duramater
- d. Posterior longitudinal ligament

last layer →
arachnoid

vs epidural →
Lig flavum.



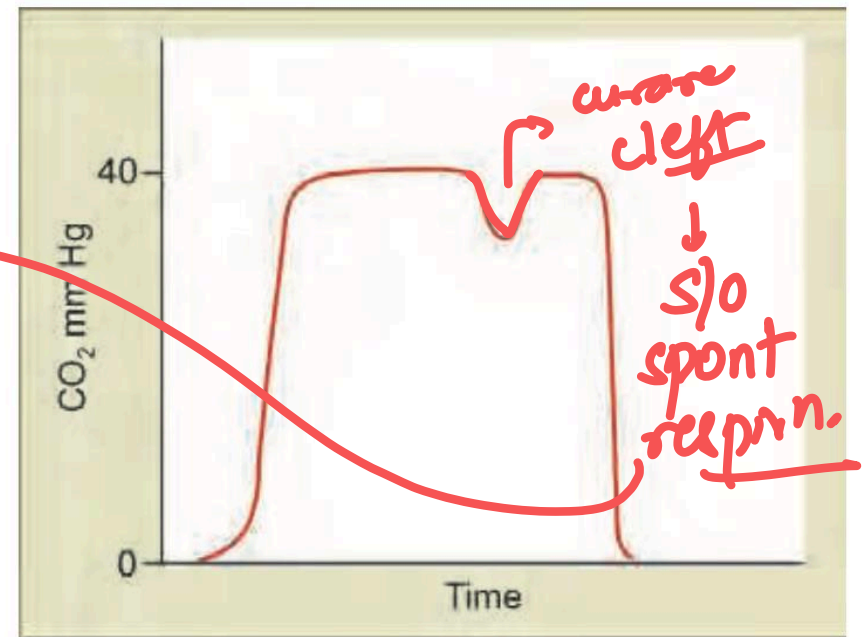skin
sc
supraspinous
interspinous
LF → epid.
dura
arachnoid



A patient was in surgery when suddenly a resident noticed the following plot on the capnograph monitor. What should be the immediate next step in management of the patient?


Capno → main videos

- a) Increase muscle relaxant
- b) Increase the depth of anesthesia
- c) Check tubes for any blockage
- d) Change soda-lime



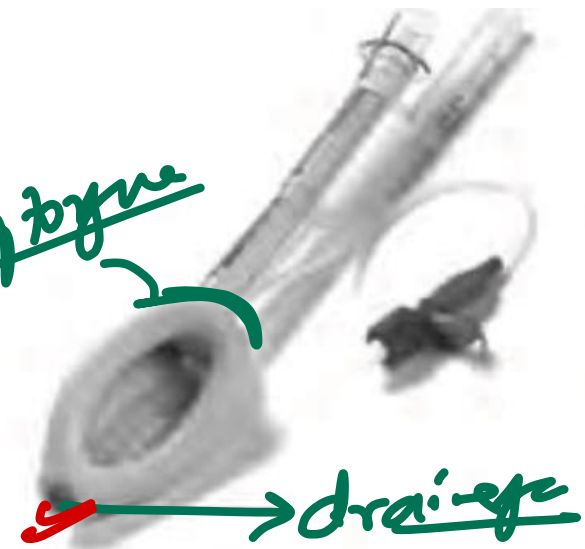

The diagram of a correctly positioned **proseal-type Laryngeal Mask Airway** is provided below. Above what site is the arrow marked area of the airway positioned?



LMA

bx 9 type



- a. Carina
- b. b. Upper end of trachea
- c. Vocal cords
- d. Above esophagus

for drainage



What is color of medical oxygen cylinder?

- a. Black body with grey shoulder
- b. Grey body with black and white shoulder
- c. Black body with white shoulder → Black
① O_2 → Black
② air → Grey
③ entonox → Blue
- d. Grey body with black shoulder

• orange → cyclopropane
• Brown → Helium



MEDSYNAPSE
Concepts Meet Mnemonics



What is the most commonly used site to measure core temperature during general anesthesia?

- a. Pulmonary artery → gold std
- ✓ b. Distal esophagus → easier, m/c
- c. Rectum - prostate
- d. Tympanic membrane → CNS sx



What is the most commonly used site to measure core temperature during general anesthesia?

- a. **Pulmonary artery**
- b. **Distal esophagus**
- c. **Rectum**
- d. **Tympanic membrane**





What is the most commonly used site to measure core temperature during general anesthesia?

- a. Pulmonary artery**
- b. Distal esophagus**
- c. Rectum**
- d. Tympanic membrane**

