



ENT INICET PYQ

Medsynapse by Dr. Nikita

Topical treatment for recurrent respiratory papillomatosis includes (AIIMS MAY 2015):



- a. Acyclovir
- b. b. Cidofovir
- c. c. Ranitidine
- d. d. Zinc



MEDSYNAPSE
Where Concepts Meet Mnemonics

Kashima operation is done for (AIIMS MAY 2015): :



- a) Recurrent cholesteatoma
- b) Bilateral vocal cord palsy
- c) Atrophic rhinitis
- d) Choanal atresia



Medsynapse by Dr. Nikita

Eustachian tube function is best assessed by (AIIMS MAY 2015): :



- a) Tympanometry
- b) VEMP
- c) Rhinomanometry
- d) Politzer test

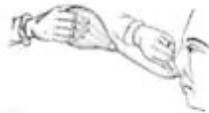

Medsynapse by Dr. Nikita

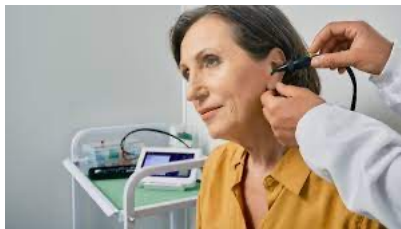

POLITZER TEST

- This test is done in children who are unable to perform Valsalva.
- In this test politzer's bag is introduced into the patient's one nostril and other is closed.
- Given a sip of water to the patient and asked to swallow and big is squeezed simultaneously.
- Patient feel air reaching in his ear or hissing sound is heard if ET is patent .



YNAPSE
s Meet Mnemonics



- Sonotubometry,
- Impedance
- Tubo-tympano-aerography (TTAG)
- Tubomanometry (TMM)

Medsynapse by Dr. Nikita

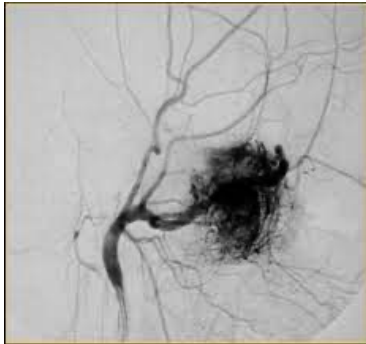
The main vessel involved in bleeding from Juvenile nasopharyngeal angiofibroma (AIIMS MAY 2015): :



- a. Facial artery
- b. Ascending pharyngeal artery
- c. Internal maxillary artery
- d. Anterior ethmoidal artery

YNAPSE
s Meet Mnemonics

Medsynapse by Dr. Nikita



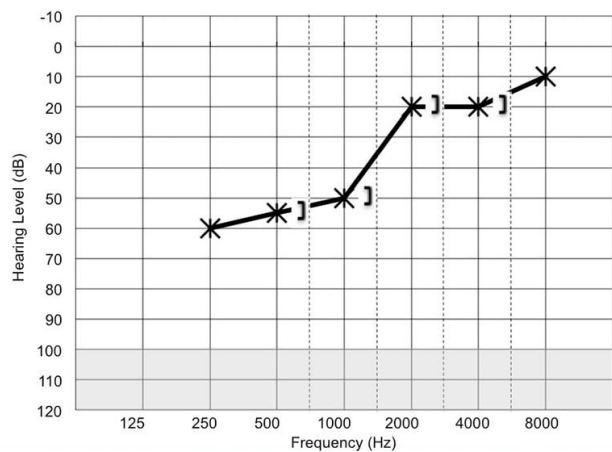
MEDSYNAPSE
Where Concepts Meet Mnemonics

Medsynapse by Dr. Nikita

This audiogram is seen in



- a) Otosclerosis
- b) Meniere's disease
- c) Presbycusis
- d) Congenital hearing loss



Medsynapse by Dr. Nikita

Which of the following tests is recommended for neonatal screening of hearing?



- a. Automated auditory brainstem response
- b. Spontaneous OAE
- c. Evoked OAE
- d. Distorted product OAE

MEDSYNAPSE
Where Concepts Meet Mnemonics

Medsynapse by Dr. Nikita

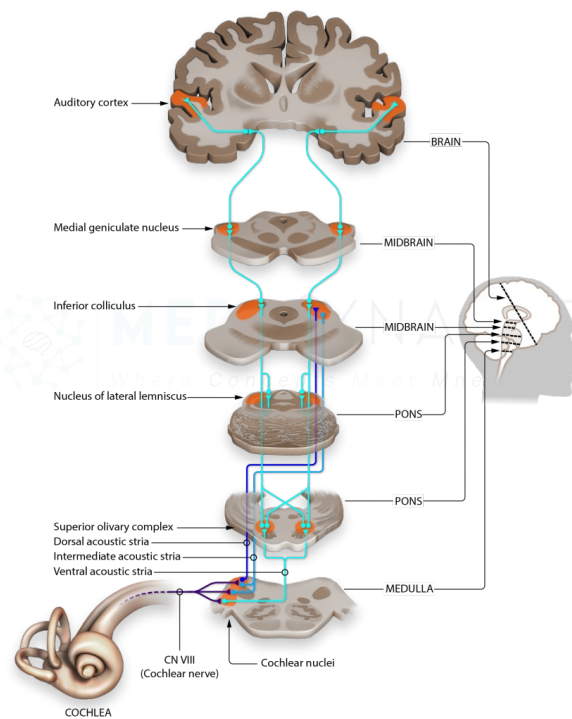
Which of the following is a part of auditory pathway



- a) Inferior colliculus
- b) Lateral geniculate body
- c) Lateral lemniscus
- d) Superior olivary nucleus

MEDSYNAPSE
Where Concepts Meet Mnemonics

Medsynapse by Dr. Nikita



Medsynapse by Dr. Nikita

A patient presents with vertigo associated with horizontal nystagmus. The slow component is towards the right. What is the most likely diagnosis?



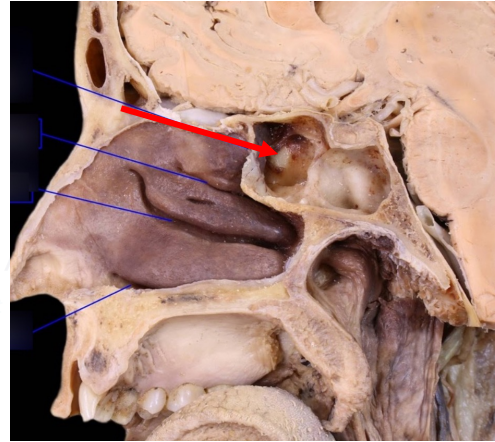
- a) Posterior canal BPPV
- b) Right hypoactive labyrinth
- c) Superior canal BPPV
- d) Left hypoactive labyrinth

Medsynapse by Dr. Nikita

Site of drainage of marked structure is



- a) Middle meatus
- b) Superior meatus
- c) Sphenoethmoidal recess
- d) Inferior meatus

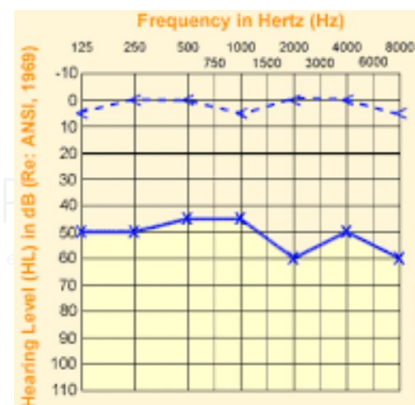


Medsynapse by Dr. Nikita

Tuning fork test results in given patient would be



	Rinne	Weber
A	Left Rinne positive	Lateralised to right ear
B	Left Rinne positive	Lateralised to left ear
C	Left Rinne negative	Lateralised to left ear
D	Left Rinne negative	Lateralised to right ear



Medsynapse by Dr. Nikita