



ORTHOPEDICS AIIMS PYQ

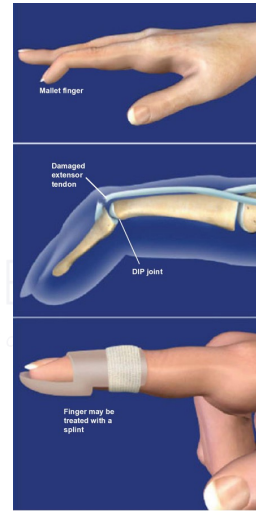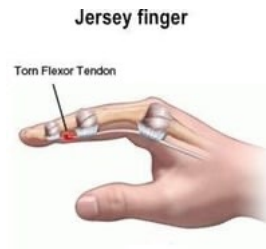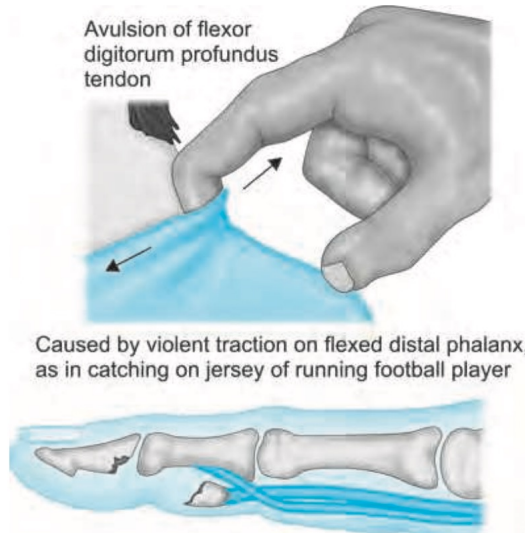
Medsynapse by Dr. Nikita

Jersey finger is caused by rupture of:



- a) Flexor digitorum superficialis**
b) Flexor digitorum profundus
c) Extensor digiti minimi
d) Extensor indicis proprius

Medsynapse by Dr. Nikita

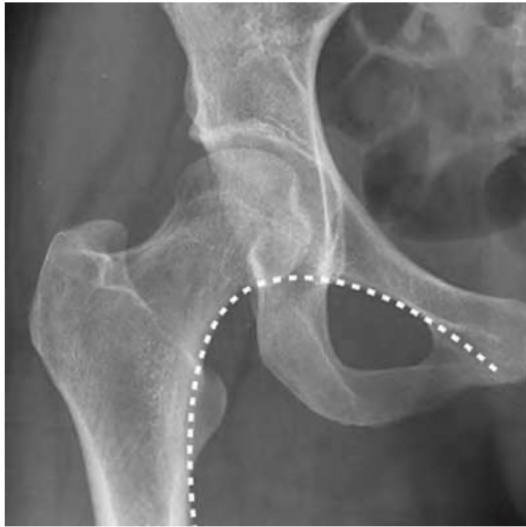

Medsynapse by Dr. Nikita

Shenton line is seen in X-ray of:

- a) Shoulder
- b) Elbow
- c) Knee
- d) Hip

Medsynapse by Dr. Nikita



- _____ Border of _____ ramus
- _____ border of obturator foramen
- _____ border of neck of femur

Medsynapse by Dr. Nikita

Which of the following tractions is not used in lower limb?

- a. Gallows
- b. Bryant
- c. Dunlop
- d. Perkin



Medsynapse by Dr. Nikita

In Osteoporosis which of these is seen?



- MEDSYNAPSE**
Where Concepts Meet Mnemonics
- a) Normal calcium, normal ALP
 - b) Decreased calcium, increased ALP
 - c) Decreased calcium, decreased ALP
 - d) Normal calcium, decreased ALP

Medsynapse by Dr. Nikita

Judet view of X-ray is for:



- MEDSYNAPSE**
Where Concepts Meet Mnemonics
- a. Calcaneum
 - b. Scaphoid
 - c. Shoulder
 - d. Pelvis

Medsynapse by Dr. Nikita

Investigation of choice in stress fracture:



- a) CT scan
- b) MRI
- c) X-ray
- d) Bone scan

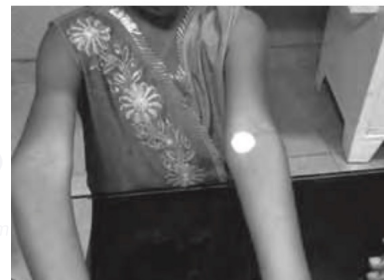

Medsynapse by Dr. Nikita

A 9-year-old child presents to your clinic with the following deformity. Which is the most likely fracture leading to such a defect?



- a) Colle's fracture
- b) Lateral epicondyle fracture
- c) Medial epicondyle fracture
- d) Supracondylar fracture

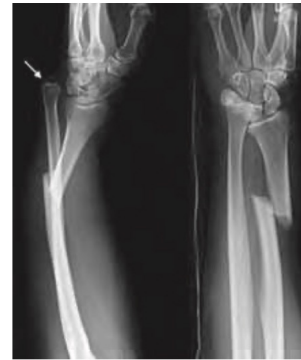

Medsynapse by Dr. Nikita

A child presented with pain in the forearm following a trauma. An AP and lateral X-ray of the forearm reveal the findings as shown. What is the most likely diagnosis?



- a. Colle's fracture**
b. b. Smith fracture
c. c. Monteggia fracture
d. d. Galeazzi's fracture



Medsynapse by Dr. Nikita

All the following can lead to damage of the axillary nerve except:



- a. Fracture of surgical neck of humerus**
b. Intramuscular injection
c. Improper use of crutches
d. Shoulder dislocation

Medsynapse by Dr. Nikita

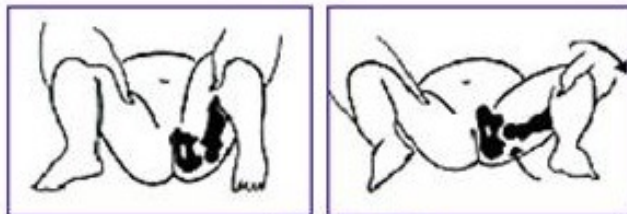
The following pelvic X-ray was seen in a patient. All the following signs will be present except:



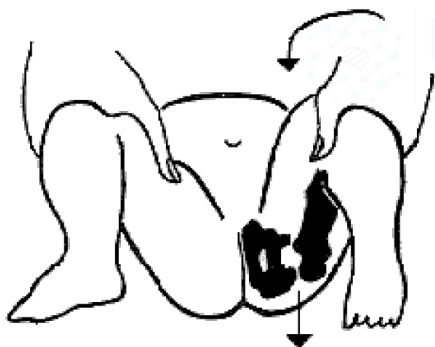
- a. **Narath**
- b. **Barlow**
- c. **Ortolani**
- d. **Gaenslen's**



Medsynapse by Dr. Nikita



Ortolani Test



Medsynapse by Dr. Nikita

Positive Galeazzi Sign

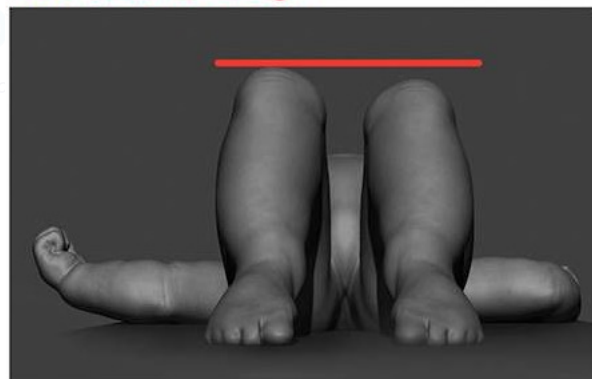


Illustration by Walt Shumway.

