



ANESTHESIA AIIMS PYQ

Medsynapse by Dr. Nikita

Which of these is most commonly used as pre-anesthetic medication ?



- a. Atropine
- b. Scopolamine
- c. Promethazine
- d. Glycopyrrolate



MEDSYNAPSE
Where Concepts Meet Mnemonics

Which of the following combinations can be used for day care surgery?



- MEDSYNAPSE**
Where Concepts Meet Mnemonics
- a. Ramifentanil, midazolam, propofol
 - b. Fentanyl, midazolam, thiopentone sodium
 - c. Morphine, midazolam, propofol
 - d. Morphine, diazepam, ketamine

Medsynapse by Dr. Nikita

Which anesthetic agent can cause pain on IV administration?



- MEDSYNAPSE**
Where Concepts Meet Mnemonics
- a. Ketamine
 - b. Propofol
 - c. Thiopentone
 - d. Midazolam

Medsynapse by Dr. Nikita

Muscle relaxant that can be used in a patient with high serum bilirubin of 6.0 and serum creatinine of 4.5 mg/ dL?



- a. Atracurium
- b. Vecuronium
- c. Pancuronium
- d. Mivacurium



MEDSYNAPSE
Where Concepts Meet Mnemonics

Medsynapse by Dr. Nikita

A pregnant woman with placenta previa started to bleed as she went into labor. Her blood pressure was 80/50 mm Hg. A lower segment caesarean section was planned in view of acute shock. What type of anesthesia will you plan for this patient?



- a) General anesthesia with IV induction by ketamine
- b) Spinal anesthesia up to L4 level
- c) General anesthesia with IV induction by propofol followed by maintenance with fluranes
- d) Sedation and epidural analgesia



MEDSYNAPSE
Where Concepts Meet Mnemonics

Medsynapse by Dr. Nikita

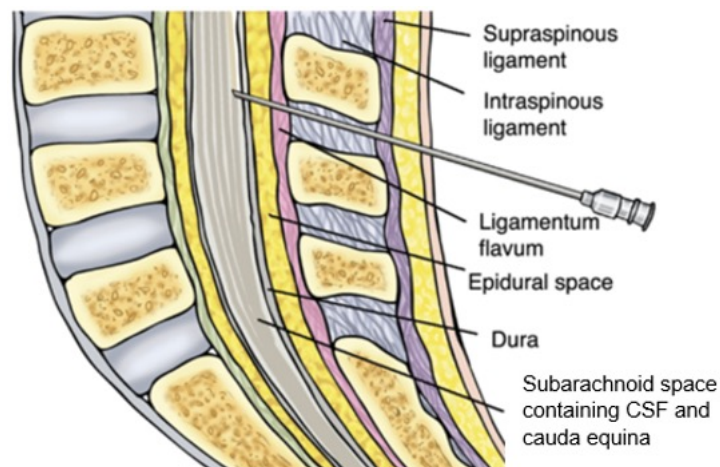


While performing a lumbar puncture, a snap is felt just before entering into the epidural space. This is due to piercing of which structure?

- a. Ligamentum flavum
- b. Supraspinous ligament
- c. Duramater
- d. Posterior longitudinal ligament

MEDSYNAPSE
Concepts Meet Mnemonics

Medsynapse by Dr. Nikita

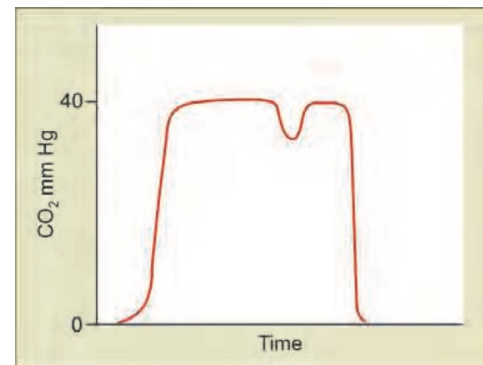


Medsynapse by Dr. Nikita

A patient was in surgery when suddenly a resident noticed the following plot on the capnograph monitor. What should be the immediate next step in management of the patient?



- a) Increase muscle relaxant**
b) Increase the depth of anesthesia
c) Check tubes for any blockage
d) Change soda-lime

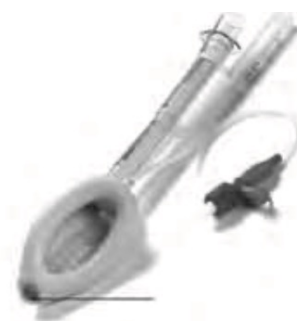

Medsynapse by Dr. Nikita

The diagram of a correctly positioned proseal-type Laryngeal Mask Airway is provided below. Above what site is the arrow marked area of the airway positioned?



- a. Carina**
b. Upper end of trachea
c. Vocal cords
d. Above esophagus



Medsynapse by Dr. Nikita

What is color of medical oxygen cylinder?



- a. Black body with grey shoulder
- b. Grey body with black and white shoulder
- c. Black body with white shoulder
- d. Grey body with black shoulder

Medsynapse by Dr. Nikita



Medsynapse by Dr. Nikita

What is the most commonly used site to measure core temperature during general anesthesia?



- a. Pulmonary artery**
- b. Distal esophagus**
- c. Rectum**
- d. Tympanic membrane**

Medsynapse by Dr. Nikita