



# DERMATOLOGY AIIMS PYQ

Medsynapse by Dr. Nikita

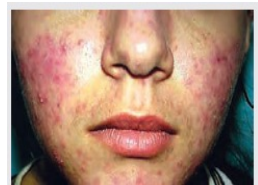A 25-year-old girl presented with erythematous papules on the face as seen in the figure. The lesions were exacerbated on excessive sweating, sun exposure and emotional disturbance. What is the diagnosis?



- a) SLE
- b) Acne vulgaris
- c) Acne rosacea
- d) Photodermatitis



MEDSYNAPSE  
Where Concepts Meet Mnemonics



Medsynapse by Dr. Nikita

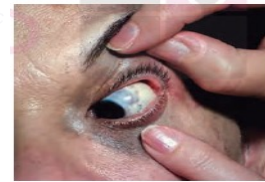A lady came with complaints of a bluish lesion over left side of forehead and left eye. An irregular bluish lesion in left superior conjunctive and forehead is seen. What is the diagnosis?



- a) Nevus of Ota
- b) Nevus of Ito
- c) Becker's nevus
- d) Mongolian spot



MEDSYNAPSE  
Where Concepts Meet Mnemonic



Medsynapse by Dr. Nikita

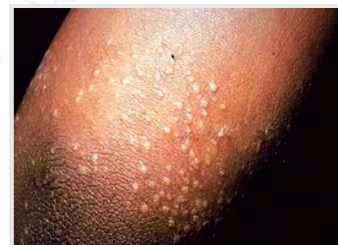A child came with similar lesions as shown in the picture over elbows and shaft of penis. What is the diagnosis?



- a. Lichen planus
- b. Scabies
- c. Lichen nitidus
- d. Lichen scrofulosorum



MEDSYNAPSE  
Where Concepts Meet Mnem

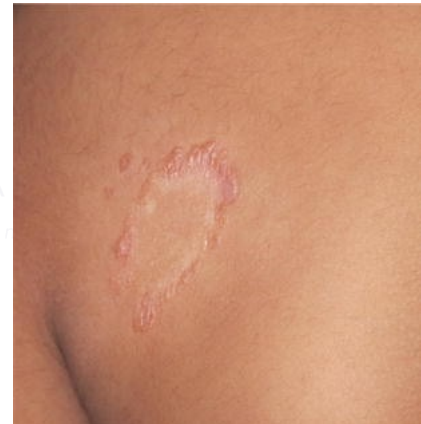

Medsynapse by Dr. Nikita

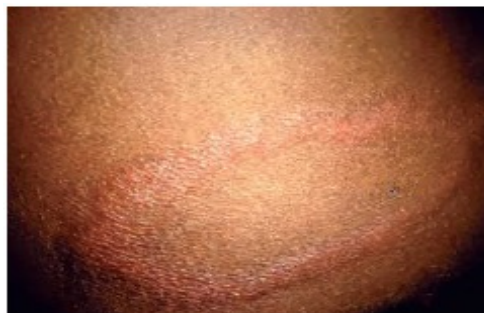A man with Leprosy came with the following lesion on the shin. What is the correct classification?



- a) LL
- b) BT
- c) BL
- d) BB



Medsynapse by Dr. Nikita

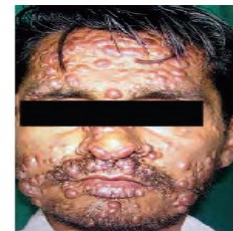

Medsynapse by Dr. Nikita

A 26-year-old man from Bihar comes with juicy looking papules over his face and back of neck, which were hypopigmented and normoaesthetic. History revealed an episode of prolonged fever in childhood. Diagnosis:



- a. Tuberculoid leprosy**  
**b. Lepromatous leprosy**  
**c. Post Kala Azar dermal leishmaniasis**  
**d. Histoid Hansen's**

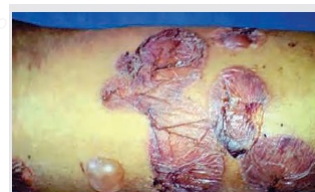

Medsynapse by Dr. Nikita

A patient came with itchy tense blisters on normal skin as well as over urticarial plaques, as shown in the image. What is the diagnosis?



- a) Pemphigus vulgaris**  
**b) Bullous pemphigoid**  
**c) Linear IgA disease**  
**d) Dermatitis herpetiformis**

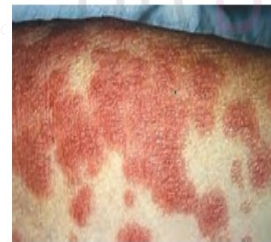

Medsynapse by Dr. Nikita

The patient came with history of bullae involving >30 % body surface area along with erosions of the lips and other mucosae for the past 7 days. What is the most probable underlying etiology?



- a) Bacterial infection
- b) Viral infection
- c) Drugs
- d) Malignancy

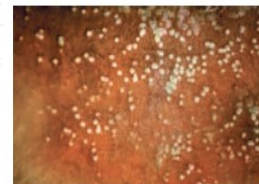

Medsynapse by Dr. Nikita

A 7 months pregnant lady with diabetes mellitus comes with the following lesions all over the body, mainly on the trunk. Which of these drugs can be appropriately used in the treatment?



- a) Azathioprine
- b) Cyclosporine
- c) Retinoids
- d) Methotrexate

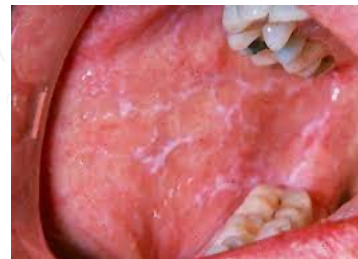

Medsynapse by Dr. Nikita

A lady presents with history burning sensation on eating spicy food. On examination bilateral white lacy streaks are present in buccal mucosa. There is no history tobacco abuse but amalgamated third molar is present. What is the diagnosis?



- a. Leukoplakia
- b. Candidiasis
- c. Lichen planus
- d. Aphthous stomatitis

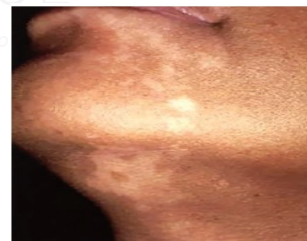

Medsynapse by Dr. Nikita

A lady came with unilateral white skin lesions with leukotrichia as shown in the picture. What is likely diagnosis?



- a) Piebaldism
- b) Segmental vitiligo
- c) Focal vitiligo
- d) Waardenburg syndrome



Medsynapse by Dr. Nikita

A patient presented with a vesicle on shin.  
Microscopy of Tzanck smear showed giant cells.  
Causative agent is:

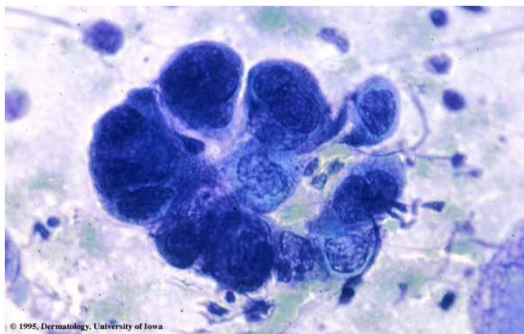


- a) Vaccinia virus
- b) Varicella zoster
- c) Mycobacterium
- d) Molluscum contagiosum



Medsynapse by Dr. Nikita

Tzanck Smear for Herpes Viruses



© 1996, Dermatology, University of Iowa

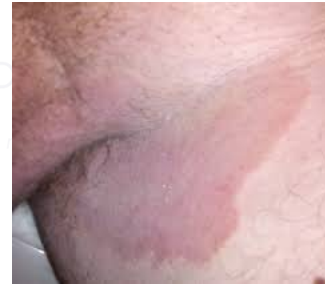

Medsynapse by Dr. Nikita

A young male presents with the following itchy lesion for one month. All of the following genera can cause this kind of lesion except:



- a. Aspergillus
- b. Microsporum
- c. Trichophyton
- d. Epidermophyton



Medsynapse by Dr. Nikita