



OBGY AIIMS PYQ

Medsynapse by Dr. Nikita



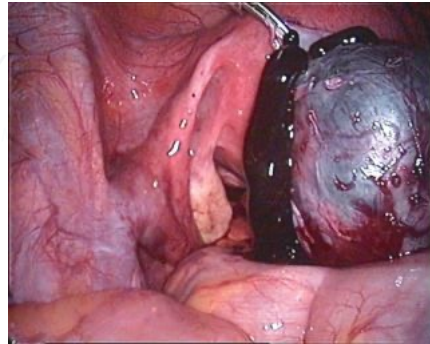Scan me for Medsynapse app

Medsynapse by Dr. Nikita

A 28-year-old female patient presented with lower abdominal pain along with dysmenorrhea. The following finding was seen on laparoscopic examination. What is the likely diagnosis?



- a) Krukenberg tumor
- b) Endometriosis
- c) Polycystic ovaries
- d) Cystadenoma of ovary

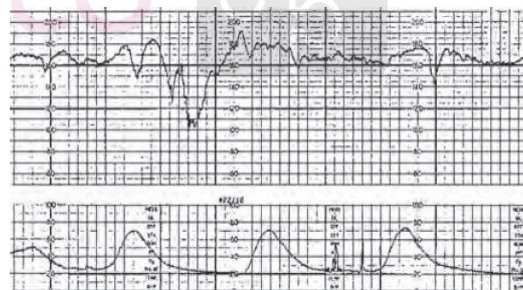


Medsynapse by Dr. Nikita

Following fetal tocographic finding was seen in a 30-year-old female patient in labor. What does it suggest?



- a) Early cord compression
- b) Fetal distress
- c) Head compression
- d) Fetal anemia

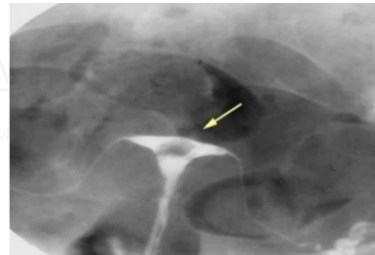

Medsynapse by Dr. Nikita

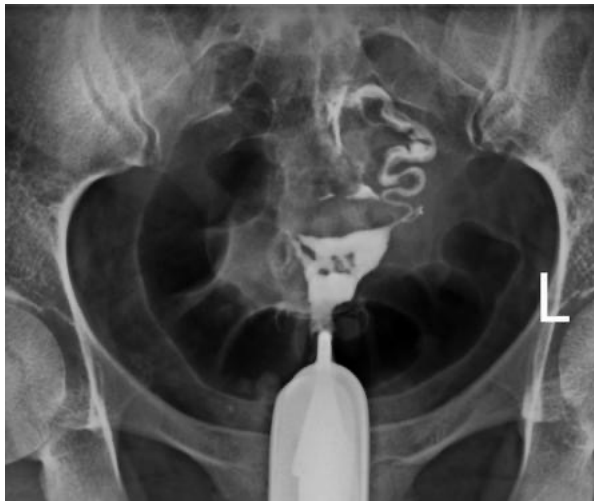HSG image below shows:



- a) Endometrial polyp
- b) Fibroid uterus
- c) Genital TB
- d) Asherman syndrome



Medsynapse by Dr. Nikita



Medsynapse by Dr. Nikita

Which of the following statements is true about Swyer syndrome?



- a) Can be fertile with surrogacy**
- b) Can be fertile with ovum donation
- c) Presents with primary infertility
- d) Gonadectomy is indicated for all patients

Medsynapse by Dr. Nikita

Which of these is seen in Asherman syndrome?



- a. Oligomenorrhea**
- b. Hypomenorrhea
- c. Metromenorrhagia
- d. Polymenorrhea

Medsynapse by Dr. Nikita

What is the most likely cause for beaded appearance of fallopian tubes with clubbed ends of fimbriae on HSG?



MEDSYNAPSE
The Concepts Meet Mnemonics

- a) Genital tuberculosis
- b) Chlamydia
- c) Neisseria gonorrhoea
- d) Endometriosis

Medsynapse by Dr. Nikita

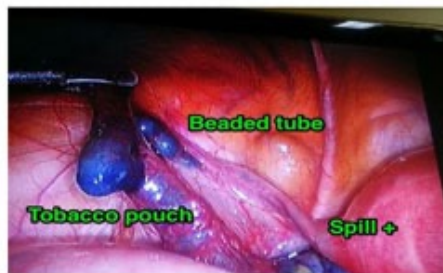
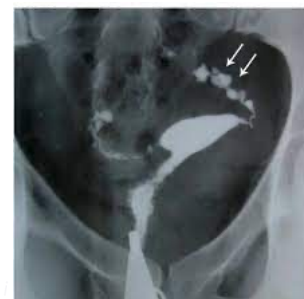
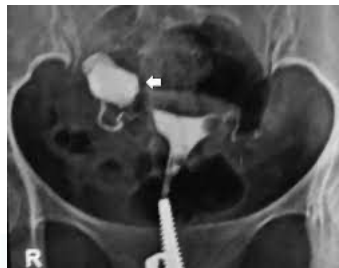
Figure 1: Laparoscopic finding suggestive of GTB: beaded tube, tobacco pouch (*although spill is present, tubes are clearly damaged).



Medsynapse by Dr. Nikita

Which of these is diagnostic of menopause?



- 
- a) Serum FSH > 30
 - b) Serum LH > 20
 - c) Serum FSH < 40
 - d) Serum estradiol < 30

Medsynapse by Dr. Nikita

What is the first sign of puberty in a girl?



- 
- a) Thelarche
 - b) Menarche
 - c) Adrenarche
 - d) Pubarche

Medsynapse by Dr. Nikita

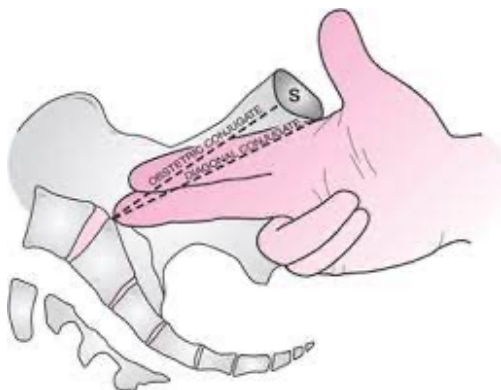
In the pelvic inlet, which is the shortest anteroposterior diameter?



- a) True conjugate
- b) Obstetric conjugate
- c) Anatomical conjugate
- d) Bispinous diameter

MEDSYNAPSE
Where Concepts Meet Mnemonics

Medsynapse by Dr. Nikita



D.S. YNAPSE
Concepts Meet Mnemonics

Medsynapse by Dr. Nikita



Estrogen and progesterone in the first 2 months of pregnancy are produced by:



- a) Fetal ovaries
- b) Fetal adrenal
- c) Placenta
- d) Corpus luteum



MEDSYNAPSE
Where Concepts Meet Mnemonics

Medsynapse by Dr. Nikita

Drug of choice for pregnancy-induced hypertension is:



- a) Atenolol
- b) Enalapril
- c) Nitroprusside
- d) Alpha-methyldopa



MEDSYNAPSE
Where Concepts Meet Mnemonics

Medsynapse by Dr. Nikita

Modified BPP consists of:



- a) NST with AFI
- b) NST with fetal breathing
- c) NST with fetal movement
- d) NST with fetal tone



Medsynapse by Dr. Nikita

All of these can be used for post-coital contraception except:




- a) Desogestrel
- b) Copper-T
- c) Levonorgestrel
- d) OCP



Medsynapse by Dr. Nikita

Drug – Emergency contraception
Levonorgestrel
Ethinyl estradiol 50 µg + Norgestrel 0.25 mg
Conjugated estrogen
Ethinyl estradiol
Mifepristone
Copper IUDs
Centchroman
Ulipristal



Medsynapse by Dr. Nikita

What is the approved dose of misoprostol in emergent management of postpartum hemorrhage?



- a) 200 mcg
- b) 600 mcg
- c) 400 mcg
- d) 1000 mcg



Medsynapse by Dr. Nikita

What is the best time to give anti-D to a pregnant patient?



- a) 12 weeks
- b) 36 weeks
- c) 28 weeks
- d) After delivery



MEDSYNAPSE
Where Concepts Meet Mnemonics

Medsynapse by Dr. Nikita