

*These are recall questions by students and it is based on a survey done among 1000 students

Ophthalmology

Q1:A child came in due to complaints of diminished vision in dim light along with dry eyes and rough corneal surface. Which deficiency is associated?

(Ophthalmology, clinical, easy)

- A. Iron
- B. Protein
- C. Niacin
- D. Retinoic acid

Q2:A boy came with thin built, lens subluxation and long fingers, shows deficiency of cystathione synthase. Which AA should be supplemented?

(Ophthalmology, clinical, moderate)

- A. Serine
- B. Tyrosine
- C. Methionine
- D. Cysteine

Q3:Acute red eye in a young male with morning stiffness. X-ray spine shown:

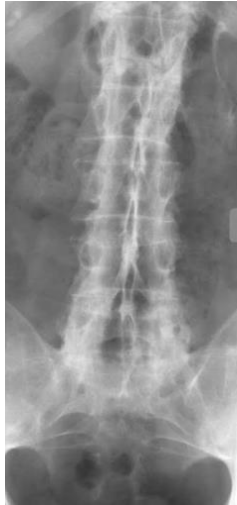(Ophthalmology + radiology+medicine *clinical, easy)

• Join our Telegram group -

MBBS Books Library India



Estd. 1996



- A. Ankylosing spondylitis
- B. RA
- C. Psoriatic arthritis
- D. Sjogren syndrome



.Q4:A 15 year old girl non compliant for myopic glasses, what can be prescribed (OPHTHALMOLOGY , Clinical , easy) Estd. 1996

- A.Lasik
- B.Femto lasik
- C.ICI
- D.Spherical alternative correction

Q5:A 33 yr female with complaints of diminishing vision on right halves of both eyes. Probably diagnosis? (OPHTHALMOLOGY, medicine , clinical , easy)

- A.Left optic tract
- B.R occipital lobe
- C.Optic chiasma
- D.R optic nerve

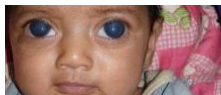Q6:. Corneal transparency is decided by (OPHTHALMOLOGY + biochemistry, clinical , easy)

- A.CHONDROITIN SULPHATE
- B.HYALURONIC ACID
- C.KERATIN SULPHATE
- D.HEPARIN SULPHATE

Q7: A child with whitish pupillary reflex has undergone enucleation & shows Flexner winter Steiner rosette. Diagnosis is? (OPHTHALMOLOGY+ pathology , clinical, moderate)

- A.Retinoblastoma
- B.Rhabdomyosarcoma
- C.Medulloblastoma
- D.Astrocytoma

Q8:A one month baby comes with watering & megalocornea, diagnosis is:- (OPHTHALMOLOGY , clinical , moderate)

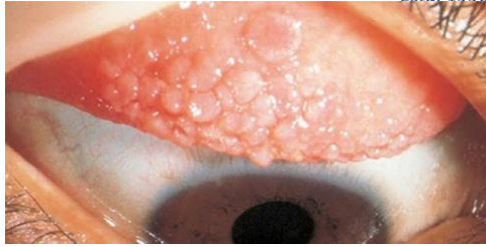


- A.Buphthalmos
- B.Cataract
- C.MPS
- D.hurler syndrome

Q9. A female comes with H/O contact lens use comes with following. Diagnosis is:(OPHTHALMOLOGY , clinical , moderate)



Estd. 1996



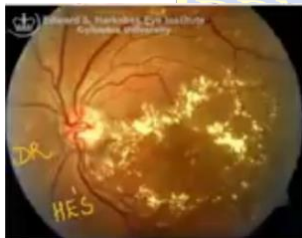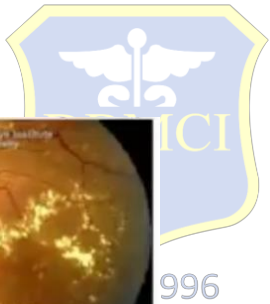A. Trachoma

B. GPC

C. Spring Cataract

D. Acute follicular conjunctivitis

Q10: A elderly female with gradual painless DOV fundus image :- (OPHTHALMOLOGY , clinical , difficult)



A. Hard exudates in DR

B. Flame Hemorrhages in HTN

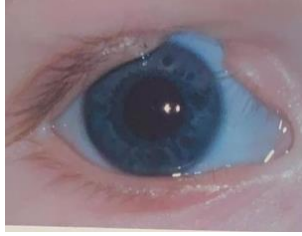C. Soft exudates in HTN

D. CRVO

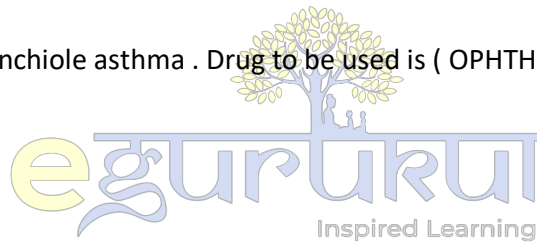

• Join our Telegram group -

MBBS Books Library India

Q11:Upper lid coloboma IBIS most likely complication? (OPHTHALMOLOGY, clinical , moderate)



- A.Cataract
- B.Exposure keratitis
- C.Difficulty in eye movement
- D.Glaucoma



Q12:A patient of POAG is known case of bronchiol asthma . Drug to be used is (OPHTHALMOLOGY+ PHARMACOLOGY, clinical, moderate)

- A.) Latanoprost
- B)gemeprost
- C) carboprost
- D)alpostadil

Q13: there is H/O trauma with chisel and hammer . Which of the investigation will be detrimental?
(Ophthalmology+ radiology, clinical, moderate)

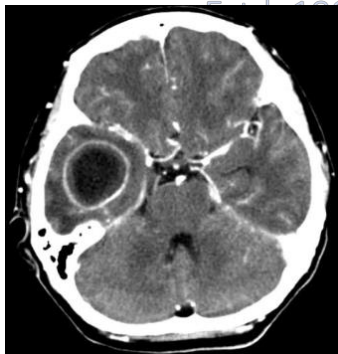
- A)MRI orbit
- B)X ray orbit
- C)CT scan
- D)B scan

ENT

Q14: A woman presented to ENT OPD with complaints of nasal obstruction . O/E , greenish black crust seen in nasal cavity covering turbinate and septum . She also had merciful anosmia is also present .what other sign will you find in this case on examination (ENT , clinical , difficult)

- A.) Roomy nose
- B)nasal polyp
- C) foreign body
- E) Inferior turbinate hypertrophy

Q15.Patient with history of chronic middle ear infection now present with neurological manifestation , headache and vomiting . Ct brain is shown . Probable diagnosis is (ENT ,radiology, clinical , moderate)



- A)extra Dural abscess
- B) cerebral abscess
- C) temporal lobe abscess
- D) meningitis

Q16: A 35 year old male presents with epistaxis. Conservative management was done to stop the bleeding but it failed which will be next step of management .

(ENT , clinical , moderate)

- A.) endoscopic sphenopalatine artery ligation
- B) maxillary artery
- C) ICA
- D) ECA

Q17: A patient if thyroidectomy was being extubated . The anesthesiologist realised that when he removes the tube the patient beings to have recurrent cyanotic spells. Which of the following could be the cause:

(ENT , clinical , moderate)

- A) B/L RLN palsy
- B) B/L SLN palsy
- C) edema
- D) hemorrhage



Q18: which of the following is the topical use of the medicine shown in the image

(ENT+pharmacology , one liner , easy)



- A) subglottic stenosis
- B) inlay type I myringoplasty
- C) post -adenoidectomy to control bleeding
- D) rhino-cerebral mucormycosis

Q19:A post tonsillectomy child was lying in the ward. He started bleeding in the ward. Which of the following should be done:


(ENT , clinical , easy)

- A.) Take to OT , remove the clot and re-ligation
- B) take to OT and pressure packing
- C) cautery
- D) conservative management

Q20:A patient has undergone submandibular gland excision and the Whartons duct was ligated in thr process . Which of the following nerves is most likely to be damaged?

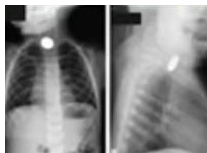(ENT , clinical , easy)

- A) Inferior alveolar nerve
- B) Hypoglossal nerve
- C) Lingual nerve
- D) Nerve to myelehoid



Q21:. A child was brought by mother with H/O dysphagia, she informed that the child was playing alone and gives H/O foreign body . X ray was done and images are given ..most likely site of FB:

(ENT + radiology , clinical , moderate)



- A) trachea
- B) larynx
- C) esophagus
- D) bronchus

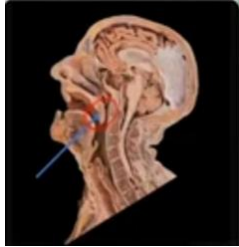

Estd. 1996



Q22: A patient was admitted with skull base trauma . The doctor was testing the marked structure . Which of the following nerve is being tested:

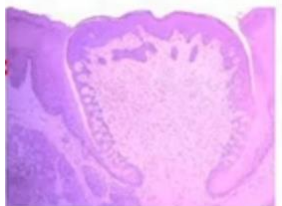
(ENT+anatomy , clinical , easy)



- A) vagus
- B) facial
- C) glossopharyngeal
- D) trigeminal

Q23. Given is a microscopic image of papillae of tongue . Identify the papillae:

(ENT+anatomy , one liner , easy)



- A) Circumvalate
- B) Fungiform
- C) Filiform
- D) Foliate

Dermatology

Q24: One question on hair perforation test (Dermatology , one liner , moderate)

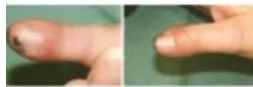A.T. Mentagrophytes

B.M. Audoni

C.M. Gypseum

D.Epidermophyton

Q25:. Finger with Paronychia & extensive wheal like infection pattern (linear) on upper limb.
Suitable antibiotic for Rx?(Dermatology ,+pharmacology clinical , moderate)



A.Amoxiclave

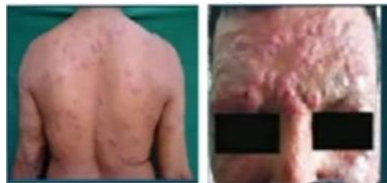B.Amikacin

C.Norfloxacin

D.Metronidazole



Q26:. A patient is on MBMDT Therapy and presented with inflammation over pre existing lesions and also nerve involvement . Treatment approach will be? (Dermatology+ pharmacology .clinical , difficult)



A.Stop ALT and start steroids

B.Stop ALT and give thalidomide

C.Continue ALT and start steroids

D.Continue ALT and give thalidomide

Q27: A truck driver came with complains of painless genital ulcer after Unsafe intercourse, motility of the causative organism can be best checked by which type of microscope?(Dermatology , clinical , difficult)

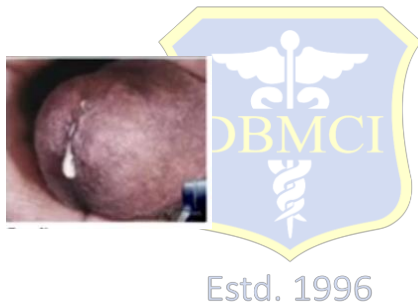A.Dark field microscope

B.Electron microscope

C.Florescent microscope

D.Light microscope

Q28: Migrant labourer came with complains of urethral discharge after 1 week of unprotected sexual intercourse. What is the causative agent...?(Dermatology , clinical , difficult)



A. E coli

B. Gonorrhoea

C. Ureaplasma urealyticum

D. Trichomonas

Q29: A pt of 30 years came with Flaccid bullae on her skin which are easy to rupture. Biopsy revealed Suprabasal split. Diagnosis?(Dermatology , clinical , difficult)

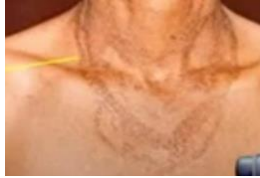A.Pemphigus vegetans

B.P. vulgaris

C.P. foliaceus

D.Erythema multiforme

Q30:. What are the associated features of this deficiency disorder?(Dermatology , one liner, easy)



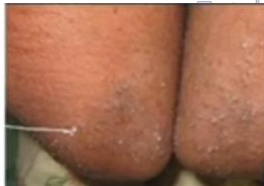A.History of diarrhea and dementia or cognitive impairment

B.?

C.?

D.?

Q31:Girl child was presenting with rough lesions over her elbows, knees (extensor surface), also had problem in night vision.(Dermatology. Clinical , moderate)



A.Keratosis pilaris

B.Phyrnoderma

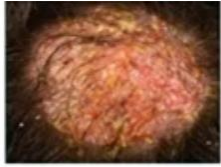C.?

D.?

Q32:. Male child c/o mild painful Boggy swelling in the scalp for 3 months. Pet animals are there in home. Diagnosis?(Dermatology)I , clinical , moderate)



Estd. 1996




- A. Folliculitis
- B. Abscess
- C. Kerion
- D. epidermal cyst

Biochemistry

Q33: A five-year-old male patient k innieented with Anemia, hone pain, hepatosplenomegaly.
(Biochemistry , clinical , moderate)

Image



Estd. 1996



- A. Glucocereberoside
- B. Hexosamindase A
- C. u-Galactosidase
- D. B-Galactosidase

Q34:: Glucose transporter?

(Biochemistry +Physiology, clinical , moderate)

Image

- A. SGLT1
- B. SGLT2
- C. GIUT4
- D. GLUT2

Q35: In an experiment conducted by a student on ETC, when pyruvate and one inhibitor is added, it resulted in inhibition of oxidative phosphorylation. Which inhibitor most likely used by the student.

(Biochemistry, theory based, difficult)

- A. Oligomycin
- B. 2,4-DNP
- C. Antimycin
- D. Rotinonc

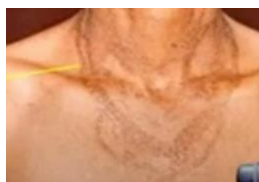Q36: A patient complains of knee pain. Routine investigations are unremarkable and still, the patient is unsatisfied. Urine turns black on standing, what is the enzyme involved?

(Biochemistry, clinical, moderate)

- A. Homogentisate oxidase
- B. Xanthine oxidase
- C. Tyrosine transaminase
- D. 4- fumarylacetoacetase

Q37: Which vitamin deficiency causes this scenario?

(Biochemistry, clinical, easy)



- A. Niacin
- B. Zinc
- C. Thiamine
- D. Pyridoxine

Q38: Patient: Cystathionine Synthase B deficiency .Which vitamin is deficient (or supplementation necessary)

(Biochemistry , clinical , easy)

- A. Tyrosine
- B. Methionine
- C. Homocysteine
- D. Niacin

39: Clinical Question with picture. Child with bitot spots, ui y night blindness. The demarcated ic findings is

(Biochemistry+dermatology , clinical , difficult)

Image

- A) Phrynoderma
- B) Icthyosis
- C) Eczema
- D) Keratosis Pilaris Rubra



Q40: Anycar old boy with del clopmental delay, recurrent chest infection and worsening bone pain/

Scrum PTH = normal Phosphate = low

The patient was not responsive to Vitamin D supplementation. The patient is most likely to be suffering from which type of rickets? (Biochemistry +medicine+ orthopedic ,clinical , moderate)

- A) Nutritional Rickets
- B) X-linked hypophosphatamic rickets
- C) Vitamin D dependent rickets Type I
- D) Vitamin D dependent rickets Type II

Q41: A person has a meal at 8 pm at night and records blood glucose at 7 am on the next day which cante to 180mg/d1. What's the source of this glucose(biochemistry , clinical, easy)

- A. Dietary Glucose

B. Hepatic Gluconeogenesis

C. Hepatic Glycogenolysis

D. Muscle glycogenolysis

Q42: What type of defect is seen in HNPCC? (Biochemistry+pathology , one liner , easy)

A. Base-excision repair

B. Nucleotide-excision repair

C. Mismatch repair

D. Non-homologous end joining repair

Q43: patient with tendon xanthoma

Elevated serum cholesterol (398)

Elevated LDL (220)

Treated with statins

Probable disorders?

(Biochemistry , clinical, moderate)

A.) Familial hyperchylomicronemia

B) familial hypercholesterolemia

C) familial dysbetalipoproteinemia

D) familial combined hyperlipidemia

Q44: female on maize as a staple diet . History of diarrhoea and lesions in the neck region . It is due to deficiency niacin. Which of the following symptom can be seen in patient?

(Biochemistry.clinical.moderate)

A) dementia and diarrhoea

B) memory loss

C)

D)

Radiology

Q45: An industrial worker was admitted to hospital after injury to eye following his work with hammer and chisel. Foreign body was suspected to be impacted in his eye. Which among the following investigations done would be detrimental?

(Radiology +medicine+ pathology, clinical , moderate)

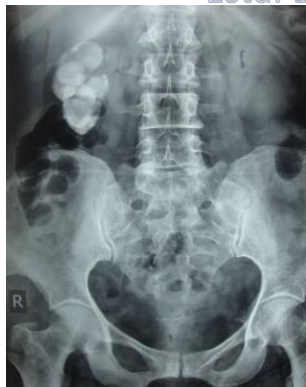A.)CT Scan

B.)MRI

C)X Ray

D)B mode scan

Q46: a 35 year old patient with abdominal pain and sterile pyuria.? diagnosis? (Radiology , clinical , difficult)



A)Putty kidney

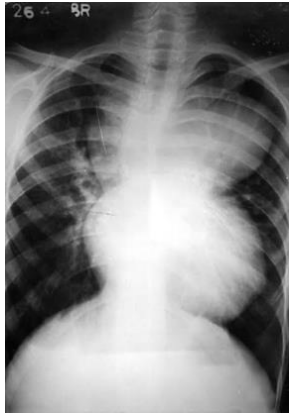B)Nephrocalcinosis

C)Calcified psoas abscess

D)Staghorn calculi

Q47 :A 12 year old kid was taken to hospital with fever and fatigue . Image shows?

(Radiology +medicine+pediatrics, clinical , difficult)



A) Snowman heart – TAPVC

B) Boot shaped – TOF

C) Egg on string- TGA

D) Box shaped Heart Ebsteins Anamoly

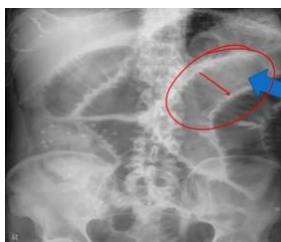


Estd. 1996



Q48:which part of the intestine is dilated on this abdominal radiograph:

(Radiology+SURGERY , one liner , easy)



A) Transverse colon

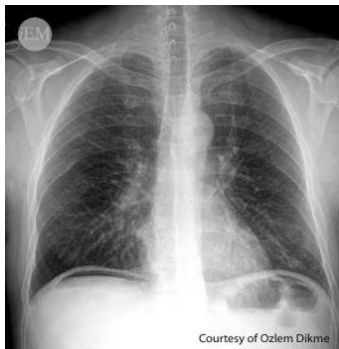B) Ileum

C) Jejunum

D) Duodenum

Q49: patient present with distended abdomen and pain in the abdomen for past 4 days .
Radiograph are given below . What is the most likely diagnosis?

(Radiology , clinical , moderate)



- A) hollow viscus perforation
- B) liver abscess
- C) thoracic empyema
- D) gastric volvulus

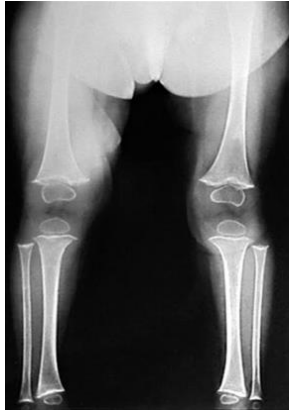Q50:A patient met with a road traffic accident. In the casualty , he had a feeble pulse with pulse rate 110 BPM. There is reduced air entry on left side of thorax . Systolic BP is 70 . There is bruising in left hypochondrium with ecchymosis . What is next best step?

(Radiology, clinical, moderate)

- A.) Abdominal paracentesis
- B)X ray abdomen
- C)FAST

D) CECT abdomen

Q51: A 10 year old child presented with limb pain with normal bone mineralization. Radiograph is show below . what is the most likely diagnosis?(radiology+orthopedic , clinical , moderate)



A . Rickets

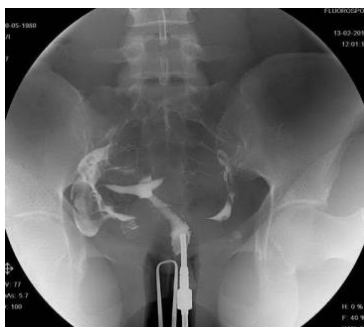B.scurvy

C.metaphyseal dysplasia

D.pyknodystosis

Q52: what is the name of the investigation shows below done in a female who presented with recurrent miscarriage?

(Radiology, clinical , moderate)



- A)genitogram
- B)saline infusion sonography
- C)CT Hysterosalpinography
- D)hysterosalpingogram

Q53: A patient presented with loss of vision of the lateral side . MRI image shows an aneurysm compressing the optic chiasma . What is the most likely vessel if origin?(radiology , clinical , moderate)

- A) ACOM
- B) ACA
- C) MCA
- D) ICA

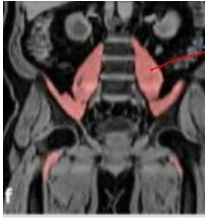

Q54: A child is suffering from acute lymphoblastic leukemia . He has undergone prophylactic cranial irradiation fir the same while waiting for bone marrow transplant. Which of the following will be least likely to be affected by radiation exposure?

(Radiology ,medicine, clinical, moderate)

- A) neurones in brain
- B)spermatogonia
- C)bone marrow
- D) intestinal mucosa

Q55: A child was brought to the hospital by his father with complaint of fever . Low backache and persistent flexion of the hip joint . He had a history of spine TB in the past . On examination child has? Inguinal swelling . Indetify the marked muscle responsible to be involved .(radiology,+ anatomy , clinical, easy)



A.psoas muscle

B.

C

D

Q56: A 55 year old chronic smoker presented with pain in the thigh and angiography was done and shown below . What is the most likely management of this case?

(Surgery + radiology , clinical , Difficult)

A.aorto-iliac bypass

B.axillofemoral bypass

C.percutaneous transluminal angioplasty

D.ileo femoral bypass

Q57: A 63 year old hypertensive patient presented with chest pain and diaphoresis . On examination he has unequal pulses in both arms . Which of the following is the most useful imaging investigation in emergency in this case?(Radiology +medicine , clinical, difficult)

A) cardiac enzymes

B)TEE

C)TTE

D)D dimer



Medicine

Q58:Pheochromocytoma. All correct except: (Medicine , clinical , moderate)

A.Urinary VMA and catecholamines

B.Present with headache only and sometimes abdominal pain and vomiting

(Medicine , one liner , moderate)

C.Propnolol is given initially for hypertension

Treatment of choice is surgical


Q59. A patient came to the opd with chief complaints of fatigue and difficulty in breathing which got aggravated on work. The patient is a known cause of hypertension, hypercholesterolemia and is on metoprolol, aspirin etc. what is the next step in management of this patient.(Medicine,clinical, moderate)

A.Increase the dose of metoprolol

B.Add clopidogrel

C.Increase the dose of aspirin

D.Surgical intervention



Q60. A patient presented with fever and chills.he also had cough with yellow colored purulent discharge. What is the next step in management of the patient.(Medicine , clinical , moderate)

A.Positive pressure ventilation

B.Give antibiotics

C.Treat accordingly in icu.

D.Manage conservatively at home.



Q61: SIADH history:

Plasma 245 mosmol

Urine 1000mosmol

Finding seen (Medicine , clinical , easy)

A.Hyponatremia

B.Hyponatremia

C.Hyperkalemia

D.Hypokalemia

Q62:. A patient on digoxin therapy was receiving several other drugs and the ECG shows presence of tall peaked T waves. Which of the following drug is unlikely to be responsible for these ECG changes? (Medicine, clinical , moderate) ko

A.Triamterene,

B.Atenolol

C.Clarithromycin

D.KCl



Q63:. What is the acid base mechanism in chronic kidney disease?(Medicine +physiology, direct question , easy)

A.Met alkalosis

B.Met acidosis

C.Respiratory acidosis

D.Respiratory alkalosis

Q64: a female patient feels numb on the fingertip. Her facial skin was tightened . ANA was found to be positive . Immunofluorescence showed nucleolar pattern

(Medicine , clinical, moderate)

- A) systemic sclerosis
- B) sjogren's syndrome
- C) SLE
- D) rheumatoid arthritis

Q65: patient with vomiting was treated with anti emetics. Patient was relieved of symptoms , but then later develop abdominal movements. What is the drug to be prescribed to reduce the movements?

(Medicine , pharmacology , clinical , moderate).

- A)scopolamine/hyoscine
- B)methyldopa
- C)benzhexol
- D) cyproheptadine



Q66: all are side effects of cocaine toxicity except?

(Medicine , one liner, easy)

- A) hyperthermia
- B) bradycardia
- C) myocardial infraction
- D) agitation

Q67: CKD patient undergoing pyeloplasty. What is the best suited post op. Analgesic ?

(Medicine+pharmacology , clinical, easy)

- A.diclofenac

B.naproxen

C.indomethacin

D.acetaminophen

Q68: A 54 old male patients from chhattisgarh having progressive motor paresis symptoms and leg stiffness . What history will you enquiry for making a diagnosis?(medicine +forensic medicine ,clinical ,moderate)

A)diet history

B) vaccination history

C) history of fever

D)past history of similar illness

Q69: 20 year old boy Presented with fever of 1 month ,hum bleeding and easy bruisability . Examination showed petechial rashes . On evaluation ,Hb=3 %g Total count 1500 , platelet count 15000/mm³ and peripheral smear showed macrocytes . Bone marrow examination showed fatty streaks absent megakaryocytes and no immature cells what is your diagnosis ?

(Medicine , clinical , difficult)

A) disseminated TB involving Marrow

B)PNH

C) acquired aplasia

D)myelodysplasia

Q70: 35 year old female presented with claudication in forearm transient , loss of vision and abdominal pain .she also had weak femoral pulsesn.fumdus also showed retinal Hemorrhage . diagnosis?(Medicine +pathology, clinical , difficult)

A)takayasu arteritis

B)PAN

C)microscopic polyangiitis


D)thromboangiitis obliterans

Q71: person on construction site fainted .skin turgor decreased , temperature was 105 deg F.
Which is least likely to be seen in this ?(Medicine + forensic medicine , clinical , easy)

- A)red hot skin
- B)tachypnea
- C) bradycardia
- D) sweating

Q72: patient presents with fever , nocturnal cough , mess breathlessness and wheezing for four weeks . Absolute eosinophil count >5000 . X ray shows military pattern .. diagnosis ?

(Medicine , clinical , moderate)

- 
- A.bronchial asthma
 - B.miliary tuberculosis
 - C.tropical pulmonary eosinophilia
 - D.hypersensitivity pneumonitis

Q73: patient with end stage renal disease , not having urine output and peripheral edema. Which antihypertensive is safe?

(Medicine +pharmacology, clinical , moderate)

- A.)aliskiren
- B) Amlodipine
- C)chlorthalidone
- D)prazosin



Q74: a hypertensive female become pregnant. Which of the drug has to be changed? (Medicine +OBG , clinical , moderate)

- A.)alpha methyl dopa
- B) calcium channel blocker
- C)ACE inhibitor
- D)labetalol

Q75: in a patient on maize diet with diarrhea , dermatitis and dementia .which of the following vitamin is deficient?

(Medicine+biochemistry , clinical , easy)

- A)B1
- B)B2
- C)B3
- D)B12



Q76: a menopausal lady , with severe back pain and history of colles fractures and dexta score -2.5 . Which of the following is wrong about her management?

(Medicine +pharmacology , clinical , moderate)

- A)teriparatide can be given before bisphosphonats
- B) bisphosphonats can be used for 1 yr only
- C)oral vit D3 can be given with calcium
- D) calcium req is 1200mg

Q77: metronidazole should not be used with

(Medicine , one liner , easy)

- A) alcohol
- B) grapefruit juice

C) benzodiazepines

D) MAO inhibitors

Q78: A 56 year patient with history of recurrent retrosternal chest pain , each episode lasting 3-5 min and subsiding with sublingual nitrate . Now he presented to emergency with excruciating chest pain .he also has HTN , DM , hypercholesterolemia . On lovastatin aspirin atenolol and metformin .ecg shows LVH with ST with T wave flattening trop I is what is next step in management:

(Medicine +pharmacology , clinical , difficult)

A) IV NTG infusion

B) injection enoxaparin

C) add clopidogrel

D) increase the dose of



Q79: a female patient complains of headache for two years for which she took analgesic regularly m there is no history of nausea and vomiting or blurred vision or photophobia . However from past 6 month the headache was not relieved by NSAIDs and was worsening . Stopping the analgesic the headache have improved . Likely diagnosis is?

(Medicine , clinical , moderate)

A) chronic migraine

B) medication overuse headache

C) tension headache

D) new onset persistent headache

Q80: 68 yr male with cough ,sputum.auscultation showed bronchial breath sounds and crackles . No confusion . RR= 20/min, urea 44mg/L .BP 110/70 next step in management?

(Medicine , clinical , moderate)

A) home treatment with antibiotics

B) admit in ICU manage without invasive mechanical ventilation



C) admit in ICU and manage with invasive mechanical ventilation

D) consider hospital admission in non ICU setting.

Q81: A 24 year female with Presented with arthritis , palpable purpura abdominal pain and hematuria . Likely diagnosis is (medicine + pediatrics clinical moderate)

A)HSP

B)SLE

C)takayasu

D) rheumatoid arthritis

Q82: all are increased in iron deficiency anemia except

(Medicine , one liner , easy)

A)TIBC

B) soluble transferrin receptor

C) transferrin saturation

D)free erythrocyte protoporphyrin



Q83: A 12 year old child is suffering from myoclonic jerks throughout the day since 1 month . Teacher reports irritability , loss of concentration . Parents give no significant history other than fever with rash that the child had at 1 year of age which resolved spontaneously in some days , EEG showed periodic bursts of sharp slow waves . What investigation will lead you to the diagnosis?(Medicine +pediatrics , clinical , difficult)

A)anti gq1 ab in CSF

B)anti measles igG in CSF

C)

Q84: A 24 year software engineer presents with fatigue since 1 month . She is having a sedentary lifestyle , mostly sitting in front of computer for 12 -14 hours , she usually orders junk food and is not eating vegetables and fruits . Her Hb 9 and MCV 120 fl.what is the most likely etiology?(Medicine + Physiology + pathology, clinical , easy)

- A) B12 deficiency
- B) folate deficiency**
- C) sideroblastic anemia
- D) chronic blood loss

Q85: a 30 yr old male weighing 70kg had serum sodium of 120 meq /L. What is the total sodium deficit?

(Medicine + physiology, clinical , moderate)

- A) 280meq
- B) 480meq
- C) 840meq**
- D) 1400meq

Q86: a 12 yr old with h/o repeated resp infection. Bulky greasy stools with high stools with high fat >10g. Which of the following is correct about complications expected in this patient.

(Medicine + physiology , clinical, moderate)

- A. serum shows hypernatremia
- B. patient generally having protein losing enteropathy
- C. patient has distal intestinal intussusception at this age.**
- D. rectal prolapse can occur after treatment

Q87: an AIDS patient presented with fever cough and yellowish sputum production . examination showed bronchial breath sounds and crackles in right infra scapular area . X ray showed right lower lobe consolidation. CD4 count is 55. What is the most common cause of this condition. (medicine+microbiology, clinical moderate)

- A. streptococcus pneumoniae**
- B. streptococcus aureus
- C. mycoplasma
- D. pneumocystis jirovecii

Q88: a 50 year old male Presented with fatiguability for one year . Evaluation showed mild anemia massive splenomegaly hb 10gm% . Eosinophi 6%. Lymphocyte15%. Also seen myeloblast , myelocytes , metamyelocytes and bands. M-E ratio is 18:1 . What is most sensitive investigation?

(Medicine +pathology , clinical , difficult)

- A.) FISH and PCR
- B)leucocyte alkaline phosphatase
- C)immunophenotyping
- D)whole body PET CT

Q89: patient k/c/o cirrhosis present with distended abdomen and jaundice . He now comes with decreased urine output that does not respond to fluids

BP normal. USG shows cirrhosis with ascites .BUN 42 and creatinine 18 . Which of the following is used in treatment

(Medicine , clinical, difficult)

- A)torsemide
- B) albumin with ostreotide
- C)liberal saline infusion
- D)IV dobutamine

Q90: A patient presented with tendon xanthoma and has high total cholesterol and high LDL . What is diagnosis?

(Medicine , clinical , moderate)

- A.lipoprotein lipase deficiency
- B.tangier disease
- C.familial hypercholesterolemia
- D.familial hyperchylomicronemia

Q91: a patient presented with exertional fatigue with palpitations . On auscultation he had a mid diastolic murmur with prominent a waves in jvp. The likely diagnosis is

(Medicine+Physiology , clinical , moderate)

A.mitral stenosis

B.tricuspid stenosis

C.mitral regurgitation

D.tricuspid regurgitation

Q92: A 12 yr old child with generalized edema , serum cholesterol 248mg/dl. Urine protein 3+. Urine microscopy revealed fat droplets (medicine +pediatrics+pathology , clinical , moderate)

A)good Pasteur syndrome

B)urine infection

C) nephrotic syndrome

D) nephritic syndrome



Q93: A 68 year female patient presented with atrial fibrillation with mitral stenosis . Echo does not show any thrombus . Best treatment to prevent stroke is?

(Medicine +pharmacology, clinical , moderate)

A) aspirin

B) aspirin plus clopidogrel

C)dabigatran

D) warfarin



Q94: patient with giant cell arteritis presents with history of headache . Jaw claudication polymyalgia rheumatica and mononeuritis mutipl.what should be the first line treatment?

(Medicine +pharmacology +forensic , clinical , easy)

A) prednisolone

B)tocilizumab

C)opioids

Q95:a 10 yr old child presents with upper limb hypertension , lower limb pulses not palpable chest X ray showed notching of ribs . What is diagnosis?

(Medicine +pediatrics , clinical moderate)

A.atrial septal defect

B.bicuspid aortic valve

C.patent ductus arteriosus

D.coarctation of aorta



Q96: While therapy session a therapist developed unconscious and conscious feelings towards the patient . what is it called? (Psychiatry , clinical, easy)

A. Transference

B. Free association

C. Abreaction

D. Countertransference

Q97: A man sits in his balcony naked ,mostly in evening when there are lot of people in the park. What is the disorder? (Psychiatry + forensic , clinical ,

Moderate)

E. Voyeurism

F. Fetichism



G. Masochism

H. **Exhibition**

Q98 A 53 year male, who is a chronic alcoholic, tried to stop using alcohol after several requests by his family members. He started feeling uneasy and on day 3, he had clouding of consciousness , insomnia and visual hallucinations. He was agitated and started abusing everyone around. He was shaking and sweating profusely. Which is your probable diagnosis?

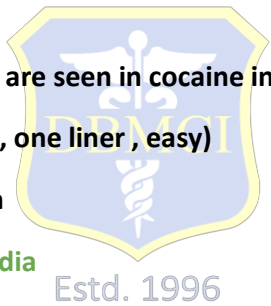
(Psychiatry , clinical , moderate)

a. Wernicke's encephalopathy

b. Delirium tremens

c. Korsakoff psychosis

d. **Anxiety disorder**



Q99:(A). All are seen in cocaine intoxication except

(Psychiatry , one liner , easy)

A. Agitation

B. **Bradycardia**

C. Hyperthermia

D. Myocardial Infarction



Q100:. A Girl of 18 years present with increased talkativeness, elevated mood,over familiarity ,pseudohallucinations, increased sexual activities, high energy, decreased sleep

(Psychiatry , clinical ,, moderate)

A. Schizomania

B. **Mania**

C. Hypomania

D. Cyclothymia

Q101: Labourer came to emergency department, with complain of dizziness and excessive fatigue while taking history by doctor he told that he was working in hot climate, temperature noted that day was 42°C , his skin showed poor turgor all of the following symptoms can be present except

(Physiology, pathology, clinical, moderate)

- A. Sweating
- B. Hypotension
- C. Tachypnea
- D. High volume pulse

Q102: A research fellow was studying of volumes and electrolyte the differences in different compartments. While experiment he took a sample and checked the electrolyte levels $\text{Na}^+ 10 \text{ mmol/L}$, $\text{Cl}^- 03 \text{ mmol/L}$, $\text{K}^+ 2.11 \text{ mmol/L}$; indicates which compartment?

(Physiology, clinical, moderate)

- A. ICF
- B. ECF
- C. Interstitium
- D. Plasma



Q103: A 58 years old man was brought to the emergency with confusion and lethargy. His temperature is 36.7°C , blood pressure is $86/58 \text{ mmHg}$, pulse is $120/\text{min}$, and respirations are $10/\text{min}$. pH is 7.59 , $\text{pCO}_2 49 \text{ mmHg}$ and $\text{pO}_2 85 \text{ mmHg}$. Which of the following condition best describe his acid base status?

(Physiology, pathology, clinical, moderate)

- A. Respiratory alkalosis
- B. Respiratory acidosis
- C. Metabolic alkalosis
- D. Metabolic acidosis

Q104: A 56 year old man with a history of Cl_2 gas for the dialysis. Before sending him for dialysis an arterial blood sample was taken for analysis. Which of the following laboratory results below indicates compensated metabolic acidosis?

(Physiology, pathology, clinical, moderate)

A. Low PCO₂, normal bicarbonate and, high pH

B. Low PCO₂, low bicarbonate, low pH

C. High PCO₂, high bicarbonate and, low pH

D. High PCO₂, low bicarbonate and High Ph

Q105: A young woman is found comatose, having taken an unknown number of sleeping pills an unknown time before. An arterial blood sample yields the following values: pH —7.10, HCO₃⁻ 32 meq/liter, PaCO₂ 68 mmHg. This patient's acid-base status is most accurately described as

(Physiology , pathology, clinical , moderate)

A. Uncompensated metabolic acidosis

B. Uncompensated respiratory acidosis

C. Respiratory alkalosis with partial renal compensation

D. Respiratory acidosis with partial renal compensation

Q106: 55 year female came with complaint of numbness, blurred vision fatigue, spasm and difficulty in walking. In investigation the resident doctor found out presence of autoimmune disease named Multiple sclerosis. Which one of the following cells are most commonly affected in such condition?

(Physiology , clinical, moderate)

A. Schwann cells

B. Oligodendrocytes

C. Astrocytes

D. Microglia

Q107: A research scholar while studying cytoskeleton, came across several strands of fibrous proteins that are wound together to form a stable structure and distribute tensile forces across cells in the tissue. Which one of the following structure is best suited?

(Physiology, pathology , one liner , easy)

- A. Intermediate filaments
- B. Microtubules
- C. Microfilaments
- D. All of the above

Q108: A 52-year-old male with Asthma presents to the emergency room in respiratory distress. The attending physician uses epinephrine to produce bronchodilation. Because epinephrine activates b-adrenergic receptors, it will relieve the symptoms. It acts through which enzyme?

(Physiology +biochemistry , clinical , moderate)

- A. Adenylate cyclase
- B. Guanylyl cyclase
- C. IP3/ DAG
- D. Tyrosine kinase

109: A child is a known case of HIV. His CD4 counts is 50. Which vaccine should be avoided?
(Pediatrics , clinical , easy)

- A. MMR
- B.
- c.
- D.

110. A baby presents with tachypnea. In the emergency he has has a carpopedal spasm. Cause is (
pediatrics , clinical , easy)

- A. Acidosis
- B. Alkalosis

111:In fetal circulation, deoxygenated blood is carried by Umbilical artery

(Pediatrics , one liner , easy)

A. Umbilical vein

B.

C.

D.

112: A 10-year old child with history of recurrent pulmonary infections now presents with bulky stools with stool fat > 10 g. Which of the following is true

(Pediatrics , clinical , moderate)

A. Serum shows hypernatremia

B. Distal intestine obstruction can be present at this age

C. Rectal prolapse may occur

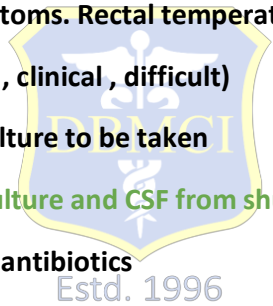
113;. A 4 year old child who has ventricular shunt for hydrocephalus got it replaced because of shunt malfunction.The child now presents with irritability and loss of appetite for 3 days and no other symptoms. Rectal temperature was 38.70C. What will be the next step in management

(pediatrics , clinical , difficult)

A. Blood culture to be taken

B. Blood culture and CSF from shunt tap

C. Start IV antibiotics



114: A question on Congenital hypertrophic pyloric stenosis

(Pediatrics , clinical , moderate)

A). Hypochlorennic Hypokalemic alkalosis

B)

C).

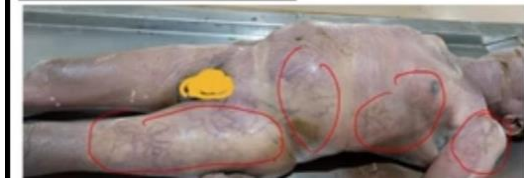D.)



Estd. 1996




Q:115: True regarding these changes? (FORENSIC MEDICINE, one liner, easy)



- A. Seen in 24 hours
- B. Due to Sulphmethemoglobin
- C. ?
- D. ?



Estd. 1996



116. The active principle of this poison? (FORENSIC MEDICINE, one liner, easy)



- A. Abrin
- B. Ricin
- C. Crotin
- D. Bhilawanol

117 A boy ate some fruit and became irritable, disoriented etc. Identify the poison with antidote. (FORENSIC MEDICINE + Pediatrics ,clinical, medium)

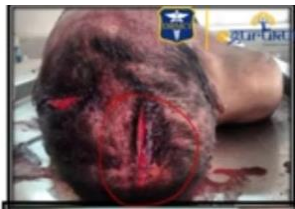A. datura, physostigmine

B.Datura, pralidoxime

C.Yellow oleander, pralidoxime

D.Yellow oleander, digoxin(something)

118:. Image of a wound shown. Identify? (FORENSIC MEDICINE, one liner, easy)



A.Incised looking lacerated

B.Lacerated looking incised

C.Incised wound

D.Contusion



119Lawyer asks the witness "did u see B killing A" witness answers yes. What is the type of examination.(FORENSIC MEDICINE, one liner, easy)

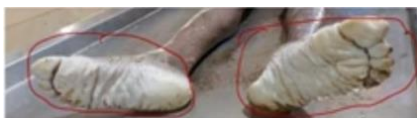A.examination in chief

B.direct examination

C.cross examination

D.?

120. The phenomenon seen in the image is due to? (FORENSIC MEDICINE, one liner, easy)



A. Torture in hot water




- B. Post- mortem hanging
- C. Immersion in water for 36 hrs
- D. Colliquative liquefaction

121: A woman gave birth to twins. The father alleged that the children does not belong to him. DNA test reveals that one of the twin child belongs to him, while the other one does not. What is the condition called: (FORENSIC MEDICINE, clinical, difficult)

- A. Superfecundation
- B. Supposititious child
- C. Atavism
- D. Posthumous child

122: Not suggestive of cocaine poisoning (FORENSIC MEDICINE, one liner, easy)

- A. Agitation
- B. Hyperthermia
- C. Bradycardia
- D. Myocardial infarction



123: Patient with gen fatigue, tiredness. Primary clinical examination is uneventful. Normal TLC and DLC. No immature cells seen. Superficial discrete lymph nodes enlarged. On biopsy showed effaced architecture, Indented nucleus, prominent nucleolus containing atypical cells. Cd10 and bc12 positive.(pathology, clinical , difficult)

- a. Follicular
- b. Burkitts
- c. Non hodgkins
- d. Mycoses fungoides.

124. Patient with mediastinal mass was diagnosed with red cell aplasia. What is the most probable cause of aplasia(pathology , clinical , easy)

- a. Bronchogenic ca
- b. Non hodgkins lymphoma

C. Thymic neoplasia

125; Pap smear with hyperchromatic nuclei pleomorphism with low maturation index involving almost all thickness. What is this called? (pathology, direct theoretical, easy)

- a. Metaplasia
- b. Dysplasia
- c. Hyperplasia
- d. Carcinoma

126: A patient presented with H/o fatigue, weight loss, infection has a history of benzene exposure. He is most likely to have which ca? (Pathology, clinical, moderate)

- a. Lung
- b. Bladder
- c. Blood
- d. bowel

127; A 34 year old woman presented with fever, migratory arthritis of lower large joints, tachycardia. Murmur is pansystolic. On echo Mitral regurgitation is present. The biopsy shows the following?

(Pathology, clinical, difficult)

Add image

- a. Aschoff body
- b. Granuloma anulare
- c. Granulomatous vasculitis
- d. Epithelioid granuloma..

128 Poor prognostic marker for multiple myeloma is?

(Pathology, one liner, easy)

- 1. S. Creatinine

2. B2- microglobulin
3. Calcium
4. Protein

129. 20 yr old boy present with gum bleeding and easy bruisibility. Fever for one month HB 3 tlc 1.5×10^3 platelet 15×10^3 Not specific general examination finding except for significant pallor and petechial rash all over the body. Ps: macrocytes corrected retic 0.5 Bone marrow fatty streak, absent megakaryocyte, no immature cells

(Pathology , clinical , difficult)

- a) Disseminated TB involving bone marrow
- b) Idiopathic acquired Aplastic anemia
- c) Paroxysmal nocturnal hemoglobinuria
- d) Myelodysplastic syndrome

130: Tocilizumab is a newer monoclonal antibody for treatment of rheumatoid arthritis. It acts against

(Pathology +pharmacology, direct theoretical , easy)

- a) 113
- b) IL12
- c) IL6
- d) IL2

131:. All are increased in IDA except?

(Pathology , one liner , easy)

- A) TIBC
- B). Soluble transferrin receptor
- C). Transferrin saturation
- D). Iron protoporphyrin

132; Digoxin toxicity is aggravated by --options have

(Pharmacology , one liner , easy)

A)Enalapril.

b).

c).

d).

133:.Drug dose to attain a stable plasma conc, if the drug is eliminated at a certain level?

(Pharmacology , direct theory based , easy)

a).

b).

c).

d).

134:.Which antihypertensive can be given to a diabetic patient with chronic renal failure. (Pharmacology , direct theory based, easy)

a)Aliskiren

b)Chlorthalidone

c)CCB

d)Beta blocker

135:Tocilizumab is effective against which type of Interleukin.(pharmacology , one liner, moderate)

a)IL-2

b)IL-12

c)IL-6

d)IL-1

136. A female patient on anti-hypertensive drugs comes for pre-conceptual counselling. Which of the following drugs will you advise to stop?

(Pharmacology, clinical, moderate)

- A. Methyl dopa
- B. Atenolol
- C. Lisinopril
- D. Nifedipine

137. Which of the following NSAID is considered safe in renal disease? (pharmacology, one liner, easy)

- A. Diclofenac
- B. Indomethacin
- C. Naproxen
- D..

138. Mechanism of action of methotrexate is (pharmacology, one liner, easy)

- A. DHFRase inhibition
- B..
- C..
- D..

139. Patient with hypertension, pedal edema, h/o of chronic renal insufficiency. Which drug is preferred?

(Pharmacology, clinical, moderate)

- A. Amlodipine
- B. Chlorthalidone
- C. Aliskiren
- D. prazosin

140: Patient was started on an anti-hypertensive following which he developed the following presentation (image of angioedema). Which drug did he take? (Pharmacology, clinical, moderate)

- A. Captopril
- B. Atenolol
- C. Amlodipine
- D. Digoxin

141: By "Indian medical practitioner" best way of prescription of alprazolam is (pharmacology, one liner, moderate)

- A. Tab alprazolam 500mcg at bedtime For 7 days
- B. Tab alprazolam 0.5mg at bedtime for 7 days
- C. Tab alprazolam 1/2mg HS for 7 days
- D. Tab alprazolam 0.5mg OD for 7 days...

142: A female taking oral contraceptives acquired tuberculosis. After prescribing anti-tubercular therapy, physician advised the patient for alternative contraception. What is the probable reason for this advice?

(Pharmacology, clinical, moderate)

- A. Rifampicin causes teratogenicity
- B. Isoniazid is teratogenic
- C. Rifampicin decreases the efficacy of oral contraceptives
- D. Oral contraceptives decrease the efficacy of antitubercular therapy

143: A patient came with a bout of vomiting. After starting an antiemetic drug, he developed dystonia. Which of the following drug is used for treatment of this motor symptom? (Pharmacology, clinical, moderate)

- A. Benzhexol
- B. Cyproheptadine
- C. L-dopa D. Hyoscine

.




144: What is the formula to calculate maintenance dose? (Pharmacology , one liner, easy)

- A. $V_d \times \text{target plasma concentration}$
- B. $CL \times \text{target plasma concentration}$
- C. $V_d / \text{target plasma concentration}$
- D. $CL / \text{target plasma concentration}$

145: Patient with stroke and irregularly irregular heart beat. Patient already on ACE inhibitors and statins. What should be added. (Pharmacology , clinical , moderate)

- A. Warfarin
- B. Dabigatran
- C..
- D..



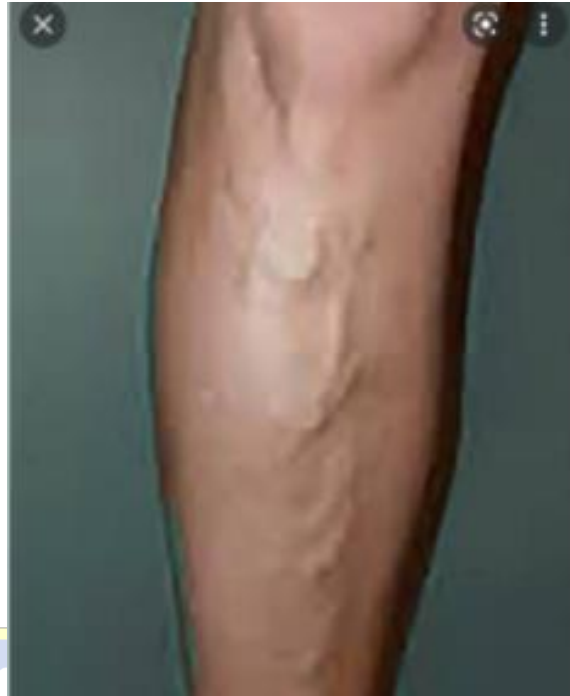146: Hypertensive patient with low urinary output symptoms. Best drug for the condition (pharmacology , clinical , easy)

- A. Prazosin
- B..
- C..
- D..

147: Periorbital edema image given. Middle aged female was recently diagnosed with hypertension and was started on therapy for the same. (2 weeks ago). Which drug could have caused this? (Pharmacology , clinical , moderate)

- A. Lisinopril
- B. CCB (Amlodipine?)
- C.
- D.

Q148: for CECP Classification (Surgery , clinical , moderate)



Options were:

- A. 3a
- B. 3b
- C. 2a
- D. 2b

Q149 Image of a women shown with left upper limb swelling. Post mastectomy Reason ?(Surgery , clinical , difficult)

- A.upper limb lymphadenopathy
- B.upper limb lymphangiosarcoma
- C.
- D.



Estd. 1996



150: RTA with absent breath sound on lt side and subcutaneous emphysema. Immediate management?(Surgery, clinical, medium)

- A.
- B.
- C.
- D.

151: A question regarding collection around pancreas

with options asking which serum levels will be

increased. serum lipase was one of the options.(Surgery, clinical , difficult)

- A.
- B.
- C.
- D.

152:A 65 year old woman presents with increased bowel sounds. Xray shows dilated bowel ,iar in biliary loop. She had hysterectomy two yrs ago . Diagnosis?

A)gall stone ileus

B) adhesion

Estd. 1996

C) mesenteric ishema

D)large bowl obstruction

153: a 40 yr old male Presented to the ER with acute abdominal pain. A fluid filled region seen in the epigastric region,which of the following investigation will be abnormal in this patient?

A)lipase

B)Ggt

C) bilirubin

D) CEA



154: Following complete thyroidectomy, anaesthetist finds it difficult to exit the pt due to repeated obstruction. Most probable cause (Surgery, clinical, difficult)


- A. U/I rln injury
- B. BI rln injury
- C. U/I sln injury
- D. haemorrhage

155: Image shown for unilateral external iliac artery blocked. Treatment asked? (Surgery, clinical, difficult)

- A. Pta and stent
- B. Ilio femoral bypass
- C. Aorto femoral bypass
- D. Axillo femoral byass

156. An xray was given.. Pt complains of abdominal pain Options were (Surgery, clinical, moderate)

- A. Gastric volvulus
- B. Hydatid cyst
- C. Perforation
- D. empyema thoracic



157. A surgeon while Operating for lung carcinoma found that the hilar lymph nodes were stained black. What can be the most probable cause? (Surgery, clinical, difficult)

- A. Melanin
- B. Anthracis
- C. Hemosiderin
- D. Foreign body.

158: Which graft in lower aorta and Iliac artery block

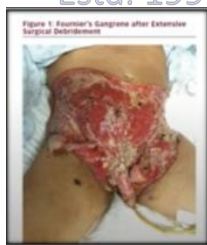(image)?(Surgery, one liner, easy)

- A. aorto femoral
- B. ileofemoral
- C. pta stenting
- D. axillofemoral graft

159: Submandibular gland excision history. Can't recall the history but they asked about the nerve injured.(Surgery, one liner, medium)

- A. Lingual
- B. Inferior alveolar
- C. nerve to myohyoid
- D. Hypoglossal

160: Which of the following is true about the following condition?(Surgery, one liner, difficult)



- A. Caused by mixed aerobes and anaerobes
- B.
- C.
- D.)

161: RTA case apparently normal, dr noticed bleeding on external urethral meatus, what should be done next?(Surgery, clinical medium)




- A. Foleys
- B. Suprapubic catheterization
- C. RGU
- D. CECT

162MOA agains Which vaccine comes under school health programme? (PSM , one liner , easy)

- A.. BCG
- B.Typhoid
- C.. tetanus
- D..

163:.Air quality index chart given and asked to identify which category.

(PSM , one liner , easy)



- A..
- B..
- C..
- D..

164:Global hunger index was asked. Which of the following is not part of it?

(PSM , one liner, easy)

- A.Infant mortality rate
- B.Child mortality rates
- C.Child undernutrition
- D.Proportional undernourishment rate

165:.Which thermometer is used to assess velocity of air and not the cooling power?(PSM , one liner , easy)

- A.Kata
- B.Globe
- C.Silvered

D.Wet globe

166. SI unit of brightness of light?

(PSM , one liner , easy)

- A. Lux
- B. Candela
- C. Lumen
- D.

167: An image of a leg with va191. Which of the following is responsible for conducting school health activities?

(PSM ,direct theory, moderate direct theory based, easy)

- A. PhC
- B. Sub center
- C. District hospital
- D. Sub divisional hospital



168. A health programme is organized and the authorities are trying to evaluate it. What part of the programme does 'clinical management' fall into? (PSM , clinical , easy)

- A. Process
- B. Outcome
- C. Input
- D. Structure

169:. In kerala,after flood, People's Complaining of fever, doxycycline prophylatically distributed,along which insecticide prefer(PSM , clinical , easy)

- A.MALATHION
- B.LINDANE
- C.PARIS GREEN
- D.ZINC PHOSPHIDE

170: Throat swab thrown in

(PSM+microbiology , one liner , easy)

- A.Yellow
- B.Red
- C.Black
- D.White

171. Which nerve is injured in medial side sensation is lost in thigh. (Anatomy , direct theory based, easy)

- A.Sural
- B.Saphenous
- C.?
- D.?



172. Neck of hernial sac medial to inf epigastric artery, which hernia is this (anatomy , clinical , moderate)

- A.Direct
- B.Indirect
- C.?
- D.?

173.. Which nerve is injured in mandibular surgery (anatomy , one liner,moderate)

- A.Lingual
- B.Hypoglossal
- C.?
- D.?

174 Which of the following prevents downward enlargement of spleen? (Anatomy , direct theory based, easy)

- A. Iliacocolic ligament
- B. phrenicocolic ligament
- C. tail of pancreas
- D. left renal artery

175. After RTA O/E base of skull fracture present. An image (a sagittal section of head of a cadaver) was shown in which the clinician is putting a probe on to the soft palate. Which nerve is being tested? (Anatomy , clinical , easy)

- A. X
- B. IX
- C. XI
- D. XII

176 Great saphenous vein (GSV) GRAFT was used in CABG. Following this operation. The patient is having loss of sensation from medial aspect of leg & foot which nerve is damaged? (Anatomy , clinical , moderate)

- A. Sural nerve
- B. Anterior tibial nerve
- C. Deep peroneal nerve
- D. Saphenous nerve

177; Patient present with vomiting next day after eating pastries the night before. Diagnosis (MICROBIOLOGY, clinical , easy)

- A. Enterotoxin- Staph Aureus
- B. Shigella
- C. Bacillus Cereus
- D. eColi

178. Obligate aerobic bacterium was isolated from a burns victim. Two images given. (MICROBIOLOGY, clinical , moderate)

- A. Pseudomonas



B.E coli

C.Klebsiella

D.Salmonella

179:Microfilaria with sheath and no nuclei in the tip of tail (MICROBIOLOGY , moderate, one liner)

A.Brugia malayi

B.Wuchereria

C.Oncocera

D.Brugia

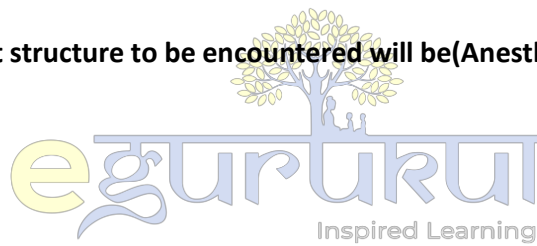

180;you are doing a lumbar puncture. Least structure to be encountered will be(Anesthesia , clinical , easy)

A.ligamentum flavum

B.dura

C.arachnoid

D.pia



181 a patient is undergoing surgery where Anesthesia is maintained on halothane . The patient developed severe hyperthermia and muscle rigidity . Which of the following agent would have contributed to this condition ?

(Anesthesia , clinical , easy)

A.)D Tuber..

B)cis

C) **suxamethonium**


Q182: a 30 year old male was intubated for surgery . The best method to confirm the position of endotracheal tube is(Anesthesia , clinical , easy)

- A)x ray chest
- B) auscultation
- C) **capnography**
- D.)chest expansion

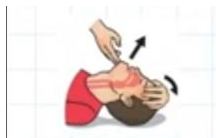183: a young male was given regional anaesthesia with 0.25% bupivacaine .the patit became unresponsive and pulse become unrecordable . The best management would have been

(Anesthesia , clinical moderate)

- A.)**CPCR with 20% intralipid**
- B.) CPCR with sodabicarb
- C) CPCR with dobutamine
- D.) CPCR with calcium



Q184:the image belt done for Airway management includes(Anesthesia , one liner , easy)



- A.)**head tilt , chin lift**
- B)in line m.stabilization
- C)jaw throat
- D.)head extension

185. Lady using ocp since 5 months.. amenorrhea since last 6 weeks..

Which is best to calculate gestational age in this case.. ...? (Obg, Clinical, Medium)

A.280 days from Imp

B.256 days from Imp

C.CRL by usg

D.Palpation of fundus

186. Both cornua obstructed by intramural fibroids, 28 yr pt comes with primary infertility.... : (Obg, One liner, Easy)

Tx

A.ART

B.Laprotomy and hysterectomy

C.Laprosopic

?



187 Second gravida in third trimester.. had twins earlier. GP..? ...(Obg, One liner, Easy)

A.G3p2

B.G1p2

C.G2p1

D.G3p1

188. Uterus didelphys Not associated with ???(Obg, One liner, Easy)

A.Transverse lie

B.Endometriosis

C.Repeated abortion

D.Premature labor...

189: A primigravida with frequent micturation during labour with Subumbilical flattening... . FHS heard on extreme of left lateral position.



What is the presentation?

(Obg, Clinical, medium)

- A. Left occipito-posterior**
- B. Face**
- C. Brow**
- D. Shoulder.....**

190 Patient with history of recurring miscarriages. Each miscarriage occurring at later stages during pregnancy. One at 12, next 14, next 24. What can be the cause? (Obg, clinical, difficult)

- A. Syphilis**
- B. APLA**
- C. ?**
- D. ?**

191: A woman in active labor has infraumbilical flattening and fhr is at lateral flanks. She has intense urge to urinate and bear down?

What lie or presentation is it?

(Obg, clinical, medium)

- A. Right Op**
- B. Transverse**
- C. Knee**
- D. Brow**

192: A woman at 36 weeks presents with painful vesicular lesions. What will be the management? (Obg, Clinical, Medium)

- A. Acyclovir with elective c sec**
- B. Acyclovir with induction of labor**
- C. Acyclovir with normal vaginal delivery**
- D. Fluid and Antibio**

193. 6 weeks of amenorrhea, left adnexal mass on usg, b hcg 2500, no fetal heart rate?What's the management (Obg, clinical, difficult)

- A.Expectant management
- B.Salpingostomy
- C.Methotrexate injection
- D.Salpingectomy

194 H/o primary infertility, two fibroids in the cornua, and both sides tubal blockage, ovulation of the women and semen analysis is normal. Rx?...(. Obg, direct theory, medium)

- A.ART
- B.Myomectomy
- C.Hysterectomy



195 PPH refractory to medical Rx ligation of devascularization in pph what all arteries can be done ?(obg, direct theory, easy)

- A.Uterine artery, pudendal artery, vaginal artery
- B.Uterine artery, internal iliac, obturator artery
- C.Uterine artery, ovarian artery, internal iliac artery
- D.Uterine artery, ovarian artery, vaginal arte

196 A 35 yr female pt. Wants to conceive ,c/o endometriosis,has bilateral fimbrial block. Her ovulation is normal.her husband semen examination is normal.how will manage?

(Obg, clinical, difficult)

- A.ART



B.Lap. Myomectomy

C.GNRH analogue

D.Clomiphene citrate

197:A male child around 20 years complains of gradual swelling around wrist for 3 months, clinical photo and x rat was given. What is the most likely diagnosis?(orthopedic, clinical , difficult)

- A. Ewings**
- B. Osteoclastoma**
- C. Pycnodysostosis**
- D. Osteosarcoma**

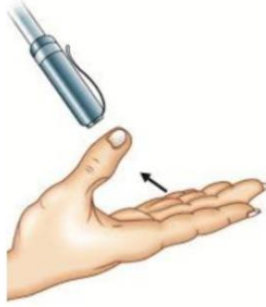


198:A patient fell down from bicycle and started having pain around hip, shortening of limb and attitude was flexion adduction, IR of HIP (ORTHOPEDECS , clinical , difficult)

- A. Ant dislocation**
- B. Transcervical fracture**
- C. Post dislocation**
- D. IT Fracture**

199Pen test with an image

Diagnosis? (Orthopedic , one liner , easy)



- a. ulnar nerve
- b. median nerve
- c. posterior interosseus nerve
- D. AIN

200:. Which is formal thought disorder?(Psychiatry , one liner , easy)

- A. Derailment
- B. Obsession
- C. Somatic delusion
- D. Thought insertion



Estd. 1996



Estd. 1996





- Join our Telegram group -
MBBS Books Library India