

# 1. Syndrome associated with posterior inferior cerebellar artery thrombosis:

a) Wallenberg syndrome

b) Medial medullary syndrome

c) Inferior alternating syndrome

d) Dejerine syndrome

Correct Answer - A

Answer A. Wallenberg syndrome

- Wallenberg syndrome is also known as lateral medullary syndrome or the posterior inferior cerebellar artery syndrome.
  - Wallenberg described the first case in 1895.
  - This neurological disorder is associated with a variety of symptoms that occur as a result of damage to the lateral segment of the medulla posterior to the inferior olivary nucleus.
  - It is the most typical posterior circulation ischemic stroke syndrome in clinical practice.
- Etiology:**
- Wallenberg syndrome is caused most commonly by atherothrombotic occlusion of the vertebral artery, followed most frequently by the posterior inferior cerebellar artery, and least often, the medullary arteries.
  - Hypertension is the commonest risk factor followed by smoking and diabetes.
  - Medial medullary syndrome, also known as inferior alternating syndrome, hypoglossal alternating hemiplegia, lower alternating hemiplegia, or Dejerine syndrome, is a type of alternating hemiplegia

characterized by a set of clinical features resulting from occlusion of the anterior spinal artery.

## 2. Space of Disse is in:

a) Spleen

b) Lymph node

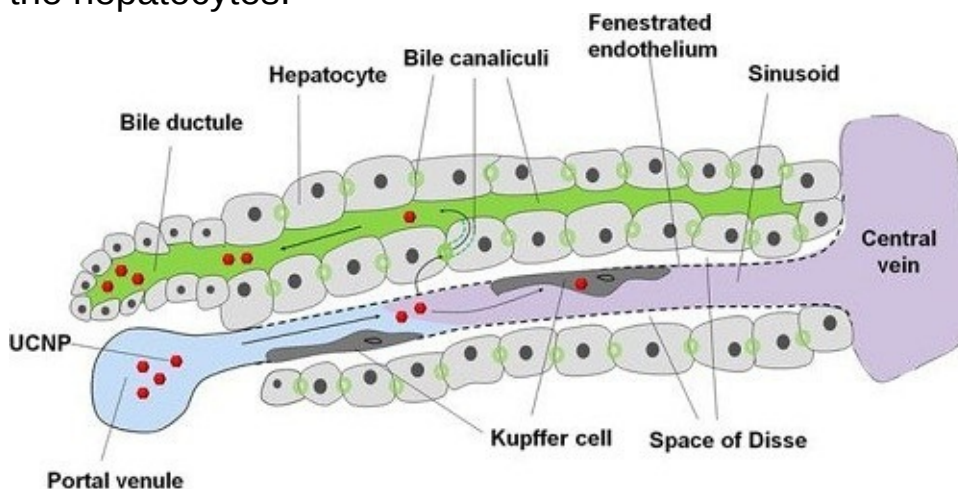
c) Liver

d) Bone

Correct Answer - C

Ans. C. Liver

- The perisinusoidal space (or space of Disse) is a location in the liver between a hepatocyte and a sinusoid.
- It contains the blood plasma.
- Microvilli of hepatocytes extend into this space, allowing proteins and other plasma components from the sinusoids to be absorbed by the hepatocytes.



### 3. What are Gitter cells:

a) Macrogia

b) Modified macrophages in CNS

c) Astrocytes

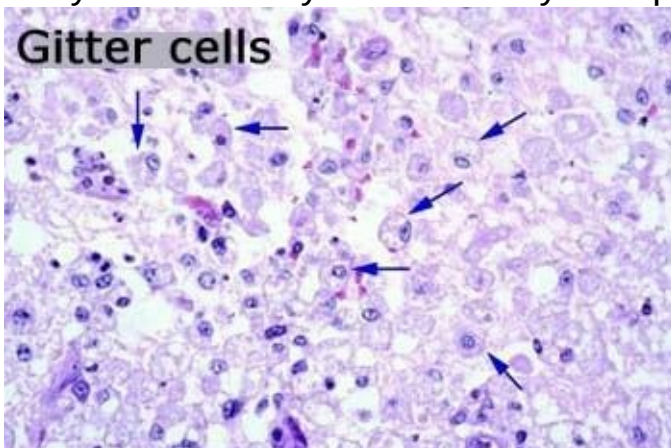
d) Oligodendrocytes

Correct Answer - B

Answer B. Modified macrophages in CNS

#### **Gitter cells:**

- These cells are macrophages and because of their appearance they are called “Gitter cells”.
- They look this way because they are lipid-laden.



- These macrophages are thought to be mainly derived from circulating blood monocytes, but some probably originate from resident microglia.
- Any time there is parenchymal damage (e.g. inflammation, infarction, parasite migration) these cells will phagocytose lipid from degenerated myelin and cellular debris.
- These lipid-laden macrophages migrate to the perivascular spaces

and leave the CNS via the blood or CSF.

#### 4. Cholecystocaval line separates:

a) Right & Left liver lobe

b) Liver with Gall Bladder

c) Right Lobe of Liver with Gall Bladder

d) Left Lobe of Liver with Gall Bladder

Correct Answer - A

Answer A. Right & Left liver lobe

Functional lobes and segments of the liver

- The functional right and left lobes of the liver are separated by an imaginary plane passing along the floor of fossa for gall bladder and the groove for inferior vena cava (cholecysto-caval line).
- On the anterosuperior surface of the liver, the plane passes little right to the attachment of falciform ligament. The functional right and left lobes of the liver are more or less of equal size.

## 5. Which of the following exocrine glandular ducts are not obstructed in cystic fibrosis:

a) Pancreas

b) Lung

c) Sweat gland

d) All of above

Correct Answer - C

Answer C. Sweat gland

Most CF patients have 3 distinct abnormal characteristics:

- The ducts of the mucus-secreting glands are obstructed due to an increase in viscosity of these secretions leading to glandular dilatation and destruction.
- CF patients are prone to chronic bacterial colonization and infections.
- The sweat glands are not obstructed in CF patients because in serous glands such as sweat glands there are abnormal concentrations of inorganic ions, rather than glandular obstruction with thick mucus.
- The quantitative pilocarpine iontophoresis sweat test is a uniformly accepted method for diagnosing CF. The sweat gland ducts must be patent for this test.
- Obstruction of airways leads to bronchiectasis and atelectasis; pancreatic duct obstruction leads to pancreatitis and malabsorption; and plugging of bile ducts leads to obstructive jaundice.

## 6. Boot shape of heart in TOF is due to:

a) Left atrial enlargement

b) Right atrial enlargement

c) Right ventricular hypertrophy

d) Biventricular hypertrophy

Correct Answer - C

Answer C. Right ventricular hypertrophy

- Boot shaped heart. A 'boot-shaped' heart ("cœur en sabot" in French) is the description given to the appearance of the heart on plain film in some cases of Tetralogy of Fallot.
- It describes the appearances of an upturned cardiac apex due to right ventricular hypertrophy and a concave pulmonary arterial segment.

## 7. Which of the following structure is not derived from external oblique muscle:

a) Inguinal ligament

b) Lacunar ligament

c) Cooper ligament

d) Linea Semilunaris

Correct Answer - D

Answer D. Linea Semilunaris

The external oblique muscle (of the abdomen) (also external abdominal oblique muscle) is the largest and the outermost of the three flat muscles of the lateral anterior abdomen.

- Inguinal ligament (Poupart's ligament) is the folded lower border of external oblique aponeurosis
- Lacunar ligament (Gimbernat ligament) is the crescent shaped expansion from the medial end of inguinal ligament attached to pectineal line of pubis.
- Pectineal ligament (Cooper's ligament) is strong fibrous band extending laterally from the lacunar ligament along pectineal line of pubis. Similar to lacunar ligament, it is made of external oblique aponeurosis.
- Reflected part of inguinal ligament extends from the lateral crus of superficial inguinal ring formed by inguinal ligament upwards to linea alba. It forms the posterior wall of inguinal canal.
- The linea semilunaris (also semilunar line or Spigelian line) is a curved tendinous intersection found on either side of the rectus abdominis muscle.

## 8. Contralateral loss of pain and temperature is due to injury to:

a) Anterior spinothalamic tract

b) Lateral spinothalamic tract

c) Fasciculus gracilis

d) Fasciculus cuneatus

Correct Answer - B

Answer B. Lateral spinothalamic tract

- Damage to lateral spinothalamic tract leads to loss of pain and temperature on the opposite side of the body below the level of lesion, since the neurons of this tract cross to the opposite side in the spinal cord.
- Anterior spinothalamic tract carries crude touch and pressure sensations. Fasciculus gracilis and fasciculus cuneatus carry conscious proprioception, fine touch, stereognosis and vibration sensations.

## 9. Duct of Bellini are present in:

a) Pancreas

b) Liver

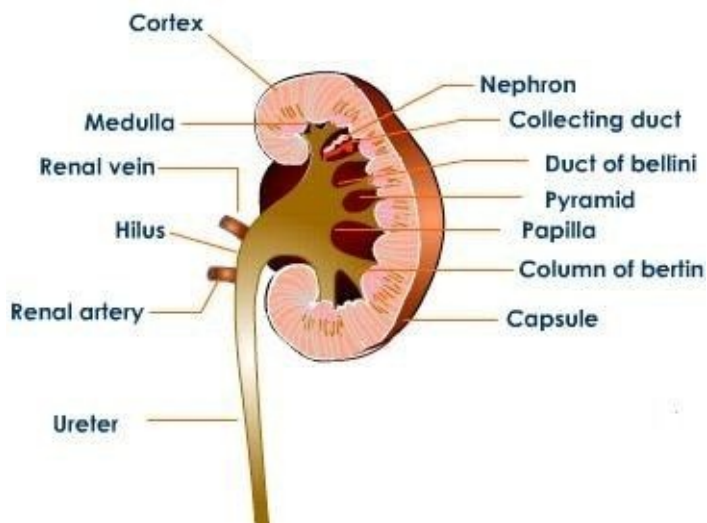
c) Kidney

d) Salivary gland

Correct Answer - C

Answer C. Kidney

- Papillary (collecting) ducts are anatomical structures of the kidneys, previously known as the ducts of Bellini.
- Papillary ducts represent the most distal portion of the collecting duct.
- They receive renal filtrate (precursor to urine) from several medullary collecting ducts and empty into a minor calyx.



## 10. Structure derived from first pharyngeal arch:

a) Levator palatini

b) Buccinator

c) Stylohyoid

d) Anterior belly of digastric

Correct Answer - D

Answer D. Anterior belly of digastric

### MESODERMAL DERIVATIVES OF PHARYNGEAL ARCHES

Pharyngeal arch	Muscular contributions	Skeletal contributions	Nerve
Ist (also called "mandibular arch")	<ul style="list-style-type: none"> <li>• Mylohyoid</li> <li>• Muscles of mastication</li> <li>• Anterior belly of digastric</li> <li>• Tensor veli palatini</li> <li>• Tensor tympani</li> <li>• Stapedius</li> <li>• Stylohyoid</li> </ul>	<ul style="list-style-type: none"> <li>• Maxilla</li> <li>• Zygomatic bone</li> <li>• Part of temporal and vomer, sphenoid, mandible</li> <li>• Meckel's cartilage:- Malleus, incus</li> <li>• Anterior ligament of malleus</li> <li>• Sphenomandibular ligament</li> <li>• Reichert's cartilage, stapes (except footplate)</li> </ul>	Mandibular division of Trigeminal Nerve (V3).

II <sup>nd</sup> (also called the "hyoid arch")	<ul style="list-style-type: none"> <li>• Posterior belly of digastric</li> <li>• Facial expression muscles</li> </ul>	<ul style="list-style-type: none"> <li>• Styloid process</li> <li>• Stylohyoid ligament</li> <li>• Smaller cornu of hyoid</li> <li>• Superior part of body of hyoid</li> </ul>	Facial
III <sup>rd</sup>	<ul style="list-style-type: none"> <li>• Stylopharyngeus</li> </ul>	<ul style="list-style-type: none"> <li>• Greater cornu of hyoid</li> <li>• Lower part of body of hyoid</li> </ul>	Glossopharyngeal
IV <sup>th</sup>	<ul style="list-style-type: none"> <li>• Pharyngeal muscles</li> <li>• Cricothyroid</li> </ul>	<ul style="list-style-type: none"> <li>• Cartilage of larynx except arytenoids</li> <li>• superior parathyroids, epiglottic cartilage</li> </ul>	Superior laryngeal branch of Vagus
VI <sup>th</sup>	<ul style="list-style-type: none"> <li>• Intrinsic muscles of larynx (except cricothyroid)</li> </ul>	<ul style="list-style-type: none"> <li>• Arytenoid cartilage of larynx</li> </ul>	Recurrent laryngeal nerve (branch of vagus)

## 11. Joint involved in movement of head from left to right.

a) Atlanto axial

b) Atlanto occipital

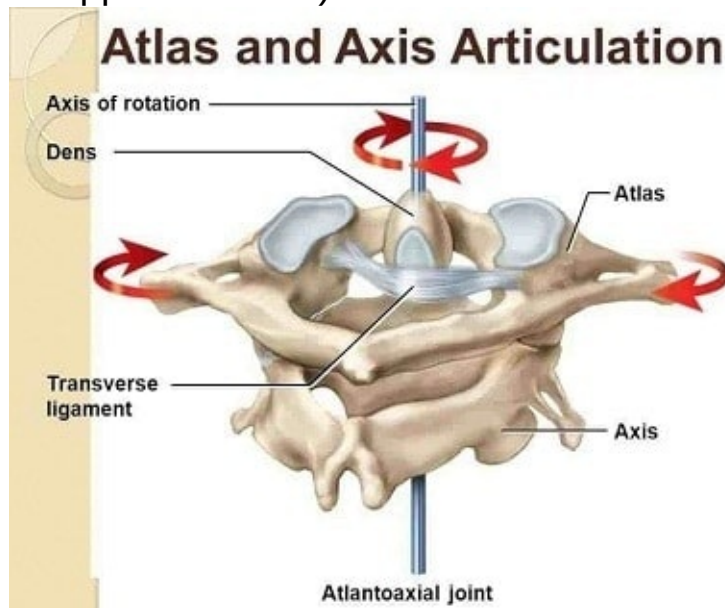
c) C2- C3 Joint

d) C3- C4 Joint

Correct Answer - A

Answer A. Atlanto axial

- Atlanto-occipital (between skull and C1) joint permits nodding of head ( as when indicating approval or YES) and Atlanto-axial joint permits the head to be turned from side to side (as indicating disapproval or NO).



## 12. What is the nerve supply of Submandibular gland:

a) Auriculotemporal nerve

b) Lingual nerve

c) Glossopharyngeal nerve

d) Inferior alveolar nerve

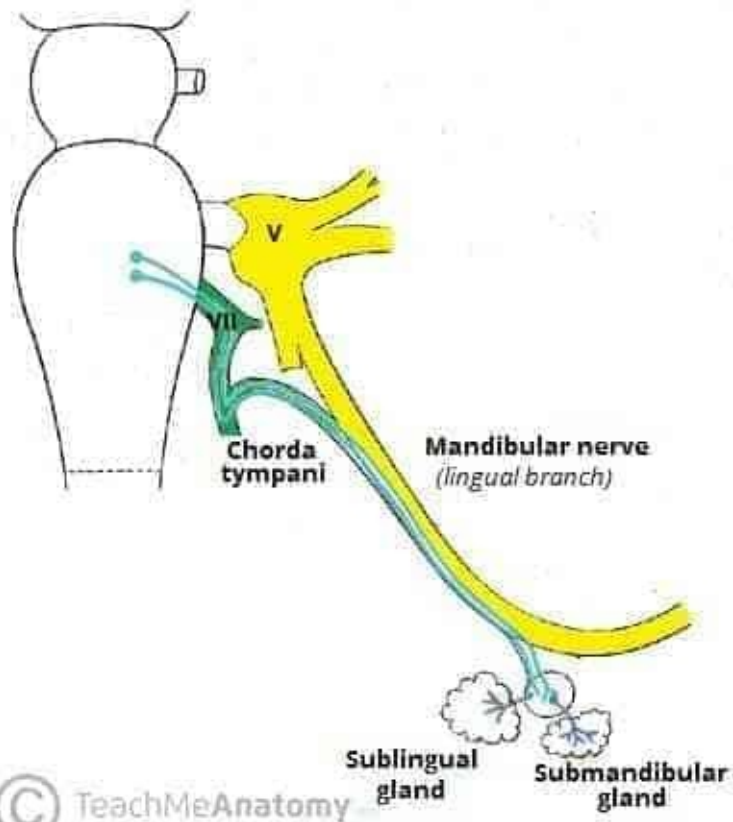
Correct Answer - B

Answer B. Lingual Nerve

- The submandibular glands receive autonomic innervation through parasympathetic and sympathetic fibres, which directly and indirectly regulate salivary secretions respectively.

### **Parasympathetic**

- Parasympathetic innervation originates from the superior salivatory nucleus through pre-synaptic fibres, which travel via the chorda tympani branch of the facial nerve (CN VII).
- The chorda tympani then unifies with the lingual branch of the mandibular nerve (CN VIII) before synapsing at the submandibular ganglion and suspending it by two nerve filaments.
- Post-ganglionic innervation consists of secretomotor fibres which directly induce the gland to produce secretions, and vasodilator fibres which accompany arteries to increase blood supply to the gland. Increased parasympathetic drive promotes saliva secretion.



### **Sympathetic**

- Sympathetic innervation originates from the superior cervical ganglion, where post-synaptic vasoconstrictive fibres travel as a plexus on the internal and external carotid arteries, facial artery and finally the submental arteries to enter each gland. Increased sympathetic drive reduces glandular blood flow through vasoconstriction and decreases the volume of salivary secretions, resulting in a more mucus and enzyme-rich saliva.

### 13. Parathyroid gland is implanted in which muscle?

a) Sartorius

b) Supinator

c) Deltoid

d) Brachioradialis

Correct Answer - D

Answer D. Brachioradialis

#### **Parathyroid surgery: Autotransplantation**

- The most common places for auto-implantation of parathyroid glands are the brachioradialis muscle and the presternal region. Other locations can also be used: the sternocleidomastoid, the subcutaneous tissue of upper limbs and abdominal fat.

## 14. Right coronary artery arises from?

a) Right Aortic Sinus

b) Left Aortic Sinus

c) Posterior coronary sinus

d) Anterior coronary sinus

Correct Answer - A

Answer A. Right Aortic Sinus

- RCA arises from anterior aortic sinus aka Right aortic sinus.
- LCA arises from left posterior aortic sinus.

## 15. Bainbridge reflex causes?

a) Bradycardia

b) Increased cardiac output

c) Decreased venous return

d) Increased heart rate

Correct Answer - D

Ans:D. Increases heart rate.

### **Bainbridge Reflex:**

- Positive feedback mechanism with compensatory increase in heart rate – Due to rise in right atrial pressure.
- Commonly referred to as “atrial reflex”.
- Resulting from increased blood pressure or increased distension of large systemic veins & right upper chamber of heart.

## 16. Golgi tendon organ responsible for?

a) Tension

b) Length

c) Pressure

d) Proprioception

Correct Answer - A

**Ans: A. Tension.**

**Difference between functions of muscle spindle & golgi tendon organ:**

**Muscle spindle:**

- Acts as “Muscle length detectors”.
- Also detects rate of change in muscle length.

**Golgi tendon organ:**

- Acts as “Muscle tension detectors”.
- Also detects rate of change in muscle tension.
- Because of location of muscle spindle & golgi tendon organ.
- Muscle spindle are parallel to muscle fibers (extrafusal fibers).
- Golgi tendon organ in series to muscle fibers (extrafusal fibers).
- Yet, Both are activated by muscle stretch.

## 17. Hormone predominately secreted after 14 day on endometrium is?

a) Progesterone

b) Estrogen

c) LH

d) FSH

Correct Answer - A

**Ans: A. Progesterone.**

**Events of ovarian cycle:**

- Bleeding continues for about 4 days.
- By 5th day, ovarian follicle is sufficiently developed.
- Secretes considerable quantities of estrogen.

**During pre-ovulatory phase:**

- Estrogen influences endometrial proliferative changes.
- Hence, "Preovulatory phase of uterine cycle" also referred "Proliferative phase".

**During post-ovulatory phase:**

- Endometrium enters secretory phase.
- Hence, "Postovulatory phase of uterine cycle" also referred "Secretory phase".
- Due to combined action of estrogen & progesterone.

**Progesterone:**

- More important & responsible for secretory changes.
- Peaks on 21st day.

**End of secretory phase:**

- Estrogen-primed endometrium.
- Degeneration of corpus luteum declines estrogen & progesterone levels.

- Results in withdrawal bleeding – Menstruation.

## 18. Peripheral chemoreceptors respond to hypoxia using which channel?

a) Calcium channel

b) Sodium channel

c) Potassium channel

d) Chloride channel

Correct Answer - C

**Ans: C. Potassium channel.**

- Carotid bodies are composed of glomus cells (also called type I), which are of neuronal phenotype and contain a variety of neurotransmitters.
- Glomus cells are in functional contact with the afferent nerve endings.
- Glomus cells are initial site(s) of sensory transduction.
- Hypoxia releases transmitter(s) from glomus cells, which in turn by depolarizing the sensory nerve ending leads to an increase in sensory discharge.
- One hypothesis assumes that a K<sup>+</sup>-channel protein is an O<sub>2</sub> sensor and that hypoxia depolarizes glomus cells by inhibiting the K<sup>+</sup> channel, leading to an increase in cytosolic Ca<sup>2+</sup>, resulting in transmitter(s) release.

## 19. With increase in age which of the following is true for lungs?

a) Pulmonary compliance increases

b) Residual volume decreases

c) Mucocillary clearance increases

d) Fibrous of interstitium dreaseses

Correct Answer - A

**Ans: A. Pulmonary compliance increases**

**Anatomical and physiological changes of respiratory system with aging:**

**Anatomical:**

- Air space size: Increased

**Compliance:**

- Chest wall compliance: Decreased
- Lung compliance: Increased to unchanged
- Total respiratory system compliance: Decreased

**Muscle strength:**

- Maximal inspiratory pressure (MIP): Decreased
- Trans diaphragmatic pressure (Pdi): Decreased
- Maximum voluntary ventilation (MVV): Decreased

**Lung function:**

- FEV1: Decreased
- FVC: Decreased
- TLC: Unchanged
- Vital capacity: Decreased
- Functional residual capacity: Increased
- Residual volume: Increased
- DLCO/VA: Decreased

**Exercise capacity:**

- VO<sub>2</sub> max: Decreased
- Dead space ventilation: Increased

**Immunology:****Bronchial fluid:**

- Neutrophils %: Increased
- Ratio of CD4+/CD8+ cells: Increased
- Epithelial lining fluid antioxidants: Decreased.

## 20. Functional residual volume is?

a) After normal inspiration

b) After normal expiration

c) After forceful expiration

d) After forceful inspiration

Correct Answer - A

**Ans:A. After normal inspiration**

- Functional Residual Capacity (FRC) is the volume of air present in the lungs at the end of passive expiration.

## 21. Polyuria is -

a) 70ml/kg

b) 60ml/kg

c) 50ml/kg

d) 40ml/kg

Correct Answer - C

**Ans: C. 50ml/kg**

- Considered polyuric if urine production is greater than 50 ml/kg/day.

## 22. Tubuloglomerular feedback control is useful for which one of the following?

a) GFR

b) Plasma sodium

c) Plasma volume

d) Determining tubular secretion

Correct Answer - A

**Ans: A. GFR.**

**Tubuloglomerular feedback – Two components:**

\* Afferent arteriole feedback mechanism  
- Usually referred as “Tubuloglomerular feedback”

\* Efferent arteriole feedback mechanism.

**Afferent arteriolar feedback mechanism:**

\* Transmitter involved – Adenosine causing  $\text{Ca}^{2+}$  channel opening.

**Efferent arteriolar feedback mechanism:**

\* Activates renin-angiotensin system generating angiotensin II → efferent arteriole constriction →  $\uparrow$ ed GFR.

\* Feedback depends on juxtaglomerular apparatus & its specialized cells.

- Macula densa – Specialized epithelium of distal tubule in close contact with afferent arteriole

## 23. Calcitonin levels increased in

a) Hyperthyroidism

b) Hyperparathyroidism

c) Hypoparathyroidism

d) Cushing Syndrome

Correct Answer - B

**Ans: B. Hyperparathyroidism**

**The serum calcitonin level is strongly increased in this type of cancer. After successful total thyroidectomy, calcitonin is no longer detectable. Increasing concentrations of calcitonin after therapy indicate relapse or metastasis. Hyperparathyroidism is present in 20-30% of patients with medullar thyroid carcinoma.**

**24. When the values of  $FEV_1=1.3$  &  $FVC=3.9$ .  
Which of the following does this signify?**

a) Normal lung function

b) Obstructive lung disease

c) Restrictive lung disease

d) Both

Correct Answer - B

**Ans: B. Obstructive lung disease**

Measurement of the bronchodilator response of forced expiratory volume in 1 second ( $FEV_1$ ) is an important method in clinical respiratory medicine.

This measurement is used to predict the response to bronchodilator treatment and is part of the diagnosis of COPD and asthma.

The bronchodilator response of forced vital capacity (FVC) has less clinical use than the bronchodilator response of  $FEV_1$  but may add important clinical physiological information

Airway obstruction was defined as  $FEV_1/FVC$  ratio below lower limit of normal (LLN) before bronchodilation, and COPD was defined as an  $FEV_1/FVC$  ratio below LLN after bronchodilation.

## 25. Antegrade peristalsis due to?

a) Ach

b) Serotonin

c) Substance P

d) VIP

Correct Answer - D

**Ans: D. VIP**

Defined as a motor pattern of the gut organ musculature that can propel content into the anal (antegrade peristalsis) or oral (retrograde peristalsis) direction.

**Impulses traveling orad activate ascending contraction:**

- Neurotransmitters here are acetylcholine, substance P, and neurokinin A.

**Impulses traveling caudad activate descending relaxation:**

- Neurotransmitters here are VIP, NO, and PACAP (pituitary adenyl cyclase activating polypeptide).

## 26. C-peptide seen in?

a) In Pre-proinsulin

b) In Proinsulin

c) As a combined entity with insulin after secretion

d) A gastrointestinal proactive molecule

Correct Answer - B

**Ans: B. In proinsulin**

**Synthesis of insulin:**

- Synthesized as larger preprohormone (Pre-proinsulin) entering ER.
- Removal of 23 amino-acid signal peptide takes place.
- Converted to "Prohormone -Proinsulin".

**Proinsulin structure:**

- Made up A & B chain, connected by C-peptide/chain.

**C-peptide –**

- Detached from granules before secretion.
- 90% – 97% insulin from B cells.
- Along with equimolar amounts of C-peptide.

## 27. In forceful expiration, which of the following neurons gets fired?

a) VRG

b) DRG

c) Pneumotaxic centre

d) Chemoreceptors

Correct Answer - A

**Ans: A. VRG**

**Medullary respiratory group:**

- Principal areas in medulla oblongata concerned with respiratory regulation.

**Includes,**

- Dorsal respiratory group (DRG).
- Ventral respiratory group (VRG).
- Pre-Botzinger complex.
- Peripheral inputs.

**Dorsal respiratory group (DRG):**

**DRG neurons –**

- Mainly concerned with inspiration.
- Descend & terminate on spinal motor neurons innervating primary inspiratory muscles.
- I.e., Diaphragm & External intercostal muscles.

**Ventral respiratory group (VRG):**

**VRG neurons –**

- Mainly concerned with forceful expiration.
- Minimal activities w.r.t inspiration.
- Contributes to both expiration & inspiration.

## 28. Slow conduction velocity is seen with which of the following nerve fibers?

a) Preganglionic autonomic nerve fibers

b) Postganglionic autonomic nerve fibers

c) Motor nerves

d) Sympathetic nerve fibers

Correct Answer - B

**Ans: B. Postganglionic autonomic nerve fibers**

**Erlanger & Gasser classification:**

**C fiber – Characteristics:**

- Diameter – 0.2-1.0
- Myelination – Unmyelinated
- Conduction – 0.2-2 (minimum)

**Functions:**

- Pain – Slow pain (“Protopathic /Second pain)
- Temperature
- Pressure
- Postganglionic autonomic fibers.
- High susceptibility to: Local anesthetics

## 29. Testosterone secreted by,

a) Leydig's cells.

b) Somatotropic cells.

c) Acidophilic cells.

d) Gonadotropic cells

Correct Answer - A

Ans:A. Leydig's cells.

- The hypothalamus sends a signal to pituitary gland to release gonadotrophic substances (follicle stimulating hormone and luteinizing hormone).
- Luteinizing hormone (LH) stimulates testosterone production.
- Testosterone is produced by gonads (by Leydig cells in testes in men & by ovaries in women).

### 30. Vasopressin acts through which channels in collecting duct?

a) Aquaporin 1

b) Aquaporin 2

c) GLUT –

d) GLUT – 4

Correct Answer - B

Ans:B. Aquaporin 2

- Principal cells of collecting duct contain a regulated system of water channels antidiuretic hormone (ADH, also called arginine vasopressin, AVP).
- ADH controls permeability of these cells to water by regulating insertion of pre-formed water channels (aquaporin-2, AQP2) into apical membrane.

### 31. True about decorticate rigidity?

a) Removal of cerebral cortex and basal ganglia

b) Flexion of lower limbs & extension of upper limbs

c) Rigidity is less pronounced than decerebrate rigidity

d) None of the above

Correct Answer - C

**Ans:C. Rigidity is less pronounced than decerebrate rigidity.**

**Decorticate rigidity:**

- Made by removing whole cerebral cortex but leaving basal ganglia intact.
- Characterized by flexion of upper extrimities at elbow & extension of lower extrimities.
- Flexion due to rubrospinal tract excitation of flexors in upper extremities & hyperextension of lower extremity.
- Decorticate animal does not have intense hypertonia as decerebrate animal.
- Due to intact basal ganglia in decorticate animal.

## 32. Zellweger syndrome is due to absence of

a) Lysosomal

b) Mitochondria

c) Peroxisome

d) Nucleus

Correct Answer - C

Answer. C. Peroxisome

- Zellweger syndrome, also called cerebrohepatorenal syndrome, is a rare congenital disorder characterized by the reduction or absence of functional peroxisomes in the cells of an individual.
- Zellweger syndrome is associated with impaired neuronal migration, neuronal positioning, and brain development.
- In addition, individuals with Zellweger syndrome can show a reduction in central nervous system (CNS) myelin (particularly cerebral), which is referred to as hypomyelination.

### 33. Urea, creatinine, nitric oxide formed by which amino acid

a) Histidine

b) Glycine

c) Cysteine

d) Arginine

Correct Answer - D

Answer: D. Arginine

- Arginine, a semiessential or conditionally essential amino acid in humans, is one of the most metabolically versatile amino acids.
- It serves as a precursor for the synthesis of urea, nitric oxide, polyamines, proline, glutamate, creatine, and agmatine.

**34. Which of the following is not the source of cytosolic NADPH ?**

a) Isocitrate dehydrogenase

b) ATP citrate lyase

c) Malic enzyme

d) G6PD

Correct Answer - B

Answer. B. ATP citrate lyase

NADPH is a cofactor used in anabolic reactions, such as lipid and nucleic acid synthesis, which require NADPH as a reducing agent.

The major source of NADPH in animals and other non-photosynthetic organisms is the pentose phosphate pathway.

The key enzymes in these processes are: NADP-linked malic enzyme, NADP-linked isocitrate dehydrogenase, NADP-linked glutamate dehydrogenase and nicotinamide nucleotide transhydrogenase.

**35. All are true regarding mitochondrial DNA, EXCEPT ?**

a) Double stranded

b) Inherited from mother

c) High mutation rate

d) All respiratory proteins are synthesized within mitochondria itself

Correct Answer - D

Answer. D. All respiratory proteins are synthesized within mitochondria itself

- Mt DNA is organized as a circular, covalently closed, double-stranded DNA.
- In sexual reproduction, mitochondria are normally inherited exclusively from the mother; the mitochondria in mammalian sperm are usually destroyed by the egg cell after fertilization.
- Mutations of mitochondrial DNA can lead to a number of illnesses including exercise intolerance and Kearns–Sayre syndrome(KSS), which causes a person to lose full function of heart, eye, and muscle movements.

### 36. Which apolipoprotein is responsible for Alzeihmers disease

a) APOE4

b) APOE3

c) APOE2

d) APOE1

Correct Answer - A

**ANSWER. A. APOE4**

Three common polymorphisms in the APOE gene, e2, e3, and e4, result in single amino changes in the ApoE protein.

The e4 allele of apolipoprotein E (APOE) is the major genetic risk factor for Alzheimer's disease (AD).

the differential effects of apoE isoforms on A $\beta$  aggregation and clearance play the major role in AD pathogenesis.

In particular, APOE e4 is associated with increased risk for AD, whereas APOEe2 is associated with decreased risk.

### 37. Hyperammonaemia inhibit TCA cycle by depleting?

a) succinate

b) a keto glutarate

c) malate

d) fumarate

Correct Answer - B

**Answer: B. a keto glutarate**

The urea cycle and the citric acid cycle are independent cycles but are linked.

To detoxify ammonia in hyperammonemia, more glutamate is required. This glutamate is formed from  $\alpha$ -ketoglutarate.

$\alpha$ -ketoglutarate  $\rightarrow$  Transamination  $\rightarrow$  glutamate +  $\text{NH}_4^+$   $\rightarrow$  glutamine.

Thus excessive  $\alpha$ -ketoglutarate is consumed leading to decrease availability of  $\alpha$ -ketoglutarate for TCA cycle

**38. which amino acid is used to synthesise Nitric oxide ?**

a) glycine

b) arginine

c) tyrosine

d) threonine

Correct Answer - B

**ANSWER: B. Arginine**

Nitric oxide is produced by a group of enzymes called nitric oxide synthases. These enzymes convert arginine into citrulline, producing NO in the process. Oxygen and NADPH are necessary co-factors. three distinct genes encode NOS isozymes: neuronal (nNOS or NOS-1), cytokine-inducible (iNOS or NOS-2) and endothelial(eNOS or NOS-3)

### 39. Menkes disease is associated with which enzyme deficiency.

a) lysyl oxidase

b) Methionine synthase

c) Glutamyl aminopeptidase

d) Lysyl hydroxylase

Correct Answer - A

**Answers: A. lysyl oxidase**

One of the enzymes, lysyl oxidase, requires copper for proper function. This enzyme cross-links tropocollagen into strong collagen fibrils.

Menkes disease (MNK), also known as Menkes syndrome, is an X-linked recessive disorder caused by mutations in genes coding for the copper-transport protein ATP7A, leading to copper deficiency. The decreased supply of copper can reduce the activity of numerous copper-containing enzymes.

These are necessary for the structure and function of bone, skin, hair, blood vessels and the nervous system such as lysyl oxidase.

## 40. LCAT deficiency increases the following

a) HDL

b) LDL

c) VLDL

d) Chylomicron

Correct Answer - A

**Answer: A. HDL**

Lecithin cholesterol acyltransferase deficiency (LCAT deficiency) is a disorder of lipoprotein metabolism.

A deficiency of LCAT causes accumulation of unesterified cholesterol in certain body tissues. Cholesterol effluxes from cells as free cholesterol and is transported in HDL as esterified cholesterol.

LCAT is the enzyme that esterifies the free cholesterol on HDL to cholesterol ester and allows the maturation of HDL.

LCAT is the enzyme that esterifies the free cholesterol on HDL to cholesterol ester and allows the maturation of HDL. LCAT deficiency does not allow for HDL maturation resulting in its rapid catabolism of circulating apoA-1 and apoA-2. The remaining form of HDL resembles nascent HDL.

**41. A 25 year old alcoholic presented with edema, hypertension, ocular disturbance, and changes in mental state was observed, diagnosis of high output cardiac failure was made with Wet Beri Beri, this is due to deficiency of?**

a) Vit B3

b) Vit B6

c) Vit B9

d) Vit B1

Correct Answer - D

**Answer: D. Vit B1**

Wet beriberi is the term used for thiamine deficiency with cardiovascular involvement.

In the first stage, peripheral vasodilation occurs, leading to a high cardiac output state. This leads to salt and water retention mediated through the renin-angiotensin-aldosterone system in the kidneys.

A more rapid form of wet beriberi is termed acute fulminant cardiovascular beriberi, or Shoshin beriberi.

The predominant injury is to the heart, and rapid deterioration follows the inability of the heart muscle to satisfy the body's demands because of its own injury.

In this case, edema may not be present. Instead, cyanosis of the hands and feet, tachycardia, distended neck veins, restlessness, and anxiety occur.

## 42. Glutamine is Increase in CSF, blood and urine, this is due to deficiency of

a) CPS-I

b) Arginase

c) OTC

d) Argininosuccinate synthetase

Correct Answer - A

**Answer: A. CPS-I**

CPS I deficiency is one of the proximal urea cycle defects and is due to a complete or partial deficiency of the mitochondrial enzyme carbamyl phosphate synthetase I (CPS I) which produces carbamyl phosphate from ammonia, ATP, and HCO<sub>3</sub>.

Carbamoyl phosphate synthetase I (CPS1 or CPSI) transfers an ammonia molecule from glutamine or glutamate to a molecule of bicarbonate that has been phosphorylated by a molecule of ATP. The resulting carbamate is then phosphorylated with another molecule of ATP. The resulting molecule of carbamoyl phosphate leaves the enzyme.

CPS-I is the rate limiting (pacemaker) enzyme this pathway.

CPS-I is active only in the presence of N-Acetyl Glutamate, an allosteric activator.

### 43. True about type 1 diabetes mellitus

- a) Decreased protein catabolism
- b) Decreased hepatic Glucose output
- c) Increased lipolysis
- d) Increase glucose uptake

Correct Answer - C

**Answer: C. Increased lipolysis**

Uncontrolled insulin-dependent diabetes mellitus (type I diabetes) involves decreased glucose utilization, with hyperglycemia, and increased fatty acid oxidation.

Increased fatty acid oxidation leads to excessive production of acetoacetic and 3-hydroxybutyric acids and of acetone, which are known as ketone bodies.

2. Acetoacetic and 3-hydroxybutyric acids dissociate at body pH and release H leading to a metabolic acidosis.

LCAT is the enzyme that esterifies the free cholesterol on HDL to cholesterol ester and allows the maturation of HDL.

LCAT deficiency does not allow for HDL maturation resulting in its rapid catabolism of circulating apoA-1 and apoA-2. The remaining form of HDL resembles nascent HDL.

#### 44. Protein which is not synthesised In liver is

a) Phase protein

b) Immunoglobulins

c) Albumin

d) Plasma hormone

Correct Answer - B

**Answer: B. Immunoglobulins**

The liver serves several metabolic functions within the body including protein synthesis and metabolism. The liver is responsible for an array of proteins.

Immunoglobulins are synthesised in plasma cells which are believed to be end products of the differentiation of cells called B-lymphocytes.

The liver plays a crucial role in the production of nearly all plasma proteins (albumin, alpha-1-acid glycoprotein, majority of coagulation cascade, and fibrinolytic pathways).

Notable exceptions include: globulins, factor III, IV, VIII.

Proteins produced by the liver: protein S, protein C, protein Z, plasminogen activator inhibitor, antithrombin III. Vitamin K dependent proteins synthesized by the liver include: Factors II, VII, IX, and X, protein S and C.

## 45. type of cholesterol present in gallstones?

a) Amorphous cholesterol monohydrate.

b) Amorphous cholesterol dihydrate.

c) Crystalline Cholesterol dihydrate.

d) Crystalline cholesterol monohydrate.

Correct Answer - D

**Answer: D. Crystalline cholesterol monohydrate.**

Gallstones are hardened deposits of digestive fluid that can form in your gallbladder.

The most common type of gallstone, called a cholesterol gallstone, often appears yellow in color. These gallstones are composed mainly of undissolved cholesterol.

Precipitation of solid cholesterol crystals from supersaturated bile has an essential role in cholesterol gallstone formation.

Gallstones are composed principally of cholesterol monohydrate crystals (cholesterol stones) or the acid salt of calcium bilirubinate (pigment stones).

When bile is concentrated in the gallbladder, it can become supersaturated with these substances, which then precipitate from the solution as microscopic crystals. The crystals are trapped in gallbladder mucus, producing gallbladder sludge.

## 46. collagen present in skin is

a) Type II

b) Type I

c) Type III

d) Type IV

Correct Answer - B

Answer: B. Type I

- Collagen is a protein that is part of cartilage, bone, and other tissues in animals and humans.
- As the main component of connective tissue, it is the most abundant protein in mammals.
- Collagen consists of amino acids wound together to form triple-helices of elongated fibrils. It is, mostly, found in fibrous tissues such as tendons, ligaments, and skin.
- So far, 28 types of collagen have been identified and described.  
**The five most common types are:**
- Type I: skin, tendon, vasculature, organs, bone (main component of the organic part of bone)
- Type II: cartilage (main collagenous component of cartilage)
- Type III: reticulate (main component of reticular fibers), commonly found alongside type I.
- Type IV: forms basal lamina, the epithelium-secreted layer of the basement membrane.
- Type V: cell surfaces, hair, and placenta

## 47. which of the following is not Ribozyme?

a) Ploy A polymerase

b) Ribonuclease

c) Transpeptidase

d) Peptidyl Transferase

Correct Answer - A

**Answer: A. Ploy A polymerase**

Polyadenylation is the addition of a poly(A) tail to a messenger RNA. The poly(A) tail consists of multiple adenosine monophosphates; in other words, it is a stretch of RNA that has only adenine bases. polyadenylation is part of the process that produces mature messenger RNA (mRNA) for translation. It, therefore, forms part of the larger process of gene expression.

## 48. Type-I hyperlipoproteinemia is characterized by

- a) Elevated LDL
- b) Elevated HDL
- c) Elevated chylomicrons
- d) Elevated lipoprotein lipase

Correct Answer - C

### **Answer C. Elevated chylomicrons**

Lipoprotein lipase deficiency (Type I hyperlipoproteinemia) results in increased level of chylomicrons.

Lipoprotein lipase deficiency is a genetic disorder in which a person has a defective gene for lipoprotein lipase, which leads to very high triglycerides, which in turn causes stomach pain and deposits of fat under the skin, and which can lead to problems with the pancreas and liver, which in turn can lead to diabetes.

The disorder only occurs if a child acquires the defective gene from both parents (it is autosomal recessive). It is managed by restricting fat in diet to less than 20 g/day.

The disease often presents in infancy with colicky pain, failure to thrive, and other symptoms and signs of the chylomicronemia syndrome.

The condition has also been called familial chylomicronemia syndrome, chylomicronemia, chylomicronemia syndrome. and hyperlipoproteinemia type Ia.

**49. In Kreb's cycle and Urea cycle the linking amino acid is**

a) Fumarate

b) Alanine

c) Arginine

d) Aspartate

Correct Answer - D

**Answer: D. Aspartate**

Aspartate helps in condensation with citrulline to form argino succinic acid.

Arginosuccinic acid undergoes a lytic reaction to form Arginine and fumarate.

oxaloacetate , the keto acid obtained from aspartate is intermediate of TCA cycle.

Hence aspartate is a common intermediate of TCA cycle through oxaloacetate and urea cycle (directly)

## 50. Vitamin A is stored in

a) Cells of Ito

b) Hepatocyte

c) Endothelial cell

d) Kupffer cell

Correct Answer - A

### **Answer A – Cells of Ito**

HSCs (hepatic stellate cells) (also called vitamin A-storing cells, lipocytes, interstitial cells, fat-storing cells or Ito cells) exist in the space between parenchymal cells and liver sinusoidal endothelial cells of the hepatic lobule and store 50-80% of vitamin A in the whole body as retinyl palmitate in lipid droplets in the cytoplasm.

## 51. Glanzmann thrombasthenia is due to

a) Decreased Gplb

b) Decreased GpIIb/IIIa

c) Anti-GpIIb/IIIa antibodies

d) Inhibition or deficiency of ADAMTS 13

Correct Answer - B

**Ans. is. b. Decreased GpIIb/IIIa**

Glanzmann thrombasthenia is an autosomal recessive disorder. There is a failure of primary platelet aggregation with ADP or collagen due to inherited deficiency of two platelets membrane glycoproteins.

It is caused due to deficiency of glycoprotein IIb- IIIa.

## 52. Apoptotic gene is-

a) Bax

b) Bcl2

c) Bclx

d) Mcl

Correct Answer - B

### **Answer-B. Bcl2**

Regulation is primarily by the Bcl-2 family of genes located on chromosome 18.

Some members of this family like bak, bid, bin, Bcl-xs (to remember, S for stimulating apoptosis) stimulate apoptosis whereas others like Bcl-2, Bcl-xl (to remember, L for lower apoptosis), etc inhibit apoptosis.

Gene families such as caspases, inhibitor of apoptosis proteins, B cell lymphoma (Bcl)-2 family of genes, tumor necrosis factor (TNF) receptor gene superfamily, or p53 gene are involved, and/or collaborate in the process of apoptosis.

### 53. Alpha one anti trypsin works by

a) inhibition of trypsin

b) inhibition of trypsinogen

c) inhibition of elastase

d) inhibition of chymotrypsin

Correct Answer - C

**Answer- C (inhibition of elastase)**

Explanation- Alpha-1 antitrypsin (A1AT) is produced in the liver, and one of its functions is to protect the lungs from neutrophil elastase, an enzyme that can disrupt connective tissue.

**54. Which one of the following is an autosomal recessive disorder?**

a) Albinism

b) Huntington's syndrome

c) Marfan's syndrome

d) Neurofibromatosis-1

Correct Answer - A

**Answer-A. Albinism**

Explanation- Albinism is caused by mutations in one of several genes, and most types are inherited in an autosomal recessive manner.

**55. Fish mouth appearance of valve in RHD is due to-**

a) Rupture of valve

b) Calcification & fibrosis

c) Hypertrophy of ventricular wall

d) None of the above

Correct Answer - B

**Answer- B. Calcification & fibrosis**

In rheumatic heart disease, an autoimmune attack on the mitral valve produces thickening of the valve leaflets. The mitral valve is often described as having a “fish-mouth” appearance.

## 56. Follicular lymphoma positivity?

a) Bcl-1

b) Bcl-6

c) Bcl- 2

d) None of the above

Correct Answer - C

### **Answer-C. Bcl-2**

A translocation between chromosome 14 and 18 results in the overexpression of the bcl-2 gene. As the bcl-2 protein is normally involved in preventing apoptosis, cells with an overexpression of this protein are basically immortal. The bcl-2 gene is normally found on chromosome 18, and the translocation moves the gene near to the site of the immunoglobulin heavy chain enhancer element on chromosome 14.

## 57. what is the histological difference between them in Ulcerative colitis & Crohn's disease?

a) Diffuse distribution of pseudopolyps

b) Mucosal edema

c) Crypt abscess

d) Lymphoid aggregates in the mucosa

Correct Answer - C

differences between ulcerative colitis and Crohn's disease are as follows:

	ulcerative colitis	Crohns disease
common site	ileocolitis with rectal sparing	procolitis, rectum
protective factor	no factors	Smoking Appendicectomy
common risk factors	antibiotic during the first year of life, turner syndrome	antibiotic during the first year of life, turner syndrome
risk factor	OCP, Smoking	$\alpha$ -Methyldopa, Wiskott–Aldrich Syndrome,
T cell involved	TH1	TH2
Earliest macroscopic finding	Aphthous Ulcer	Erythematous mucosa with a fine granular surface
Wall involved	Transmural	mucosa & submucosa
Pseudopolyp	less common	most common
type of ulcer	serpentine	Collar-button ulcers
cobblestone		

appearance	present	not present
skin lesions	seen	not seen
Creeping fat	seen	not seen
Granuloma	non-caseating granuloma seen	not seen
Fistula	classical- perinatal (enterocutaneous)	not seen
strictures	common	not common
Toxic megacolon	not seen	seen
Crypt abscess and destruction	less marked	more marked
Rose thorn appearance	seen	not seen
metaplasia	Pyloric metaplasia is a clinical marker	paneth cell metaplasia
Renal calculi	calcium oxalate uveitis, migratory polyarthritis, sacroiliitis, ankylosing spondylitis, erythema nodosum, clubbing, Primary sclerosing cholangitis	not present
Extraintestinal manifestations		Similar to Crohn disease
Named criteria to assess the severity	-----	True Love Witt's criteria-UC

## 58. What is the cause of intracorpuseular defects in hemolysis?

a) Uremic syndrome

b) PCH

c) PNH

d) Portal hypertension

Correct Answer - C

**Answer-C. PNH**

### HEMOLYTIC ANEMIA

HEMOLYSIS COULD BE:

#### 1. INTRACORPUSCULAR:

##### a. Hereditary defects

1. Defects in RBC membrane
2. Enzyme defects
3. Hemoglobinopathies
4. Thalassemia syndromes

##### b. Acquired Defects

1. PNH

#### 2. EXTRACORPUSCULAR (areas of sluggish circulation or hypo-oxygenation)

Immunhemolytic anemia, Infections, Microangiopathic, ...

## 59. Type of necrosis seen in blood vessels due to immune reactions-

a) Coagulation

b) Liquefaction

c) Fibrinoid

d) None

Correct Answer - C

### **Answer- C (Fibrinoid)**

In small vessel vasculitis, fibrin plugs frequently occur in the vessel lumen, but the term fibrinoid is usually used to refer to material outside the lumen of a vessel. Fibrinoid necrosis also occurs in the walls of arterioles in malignant hypertension.

**60. In a patient with lipoprotein lipase deficiency, which of the following is increased following a fatty meal?**

a) Chylomicron

b) LDL

c) HDL

d) Apo-A

Correct Answer - A

**Answer- A. Chylomicron**

Lipoprotein lipase deficiency (Type I hyperlipoproteinemia): is a rare, autosomal recessive disorder caused by a deficiency of lipoprotein lipase. Resulting in fasting chylomicronemia and hypertriglycerolemia. There is slow clearance of chylomicrons and VLDL. Low levels of LDL and HDL. There is no increased risk of coronary disease.

**61. In Wilson's disease, there is less urinary excretion of-**

a) Phosphorus

b) Methyl- Histidine

c) Phosphotyrosine

d) Serine

Correct Answer - B

**Answer-B. Methyl- Histidine**

**Essentials of Diagnosis & Typical Features of Wilson disease:**

- Acute or chronic liver disease
- Deteriorating neurologic status
- Kayser-Fleischer rings
- Elevated liver copper
- Abnormalities in levels of ceruloplasmin and serum and urine copper.

## 62. What is the function of IL1?

a) Enhances hematopoiesis

b) Stimulates mast cells

c) Has antiviral properties

d) Endogenous pyrogen

Correct Answer - D

### **Answer- D (Endogenous pyrogen)**

was formerly known as lymphocyte-activating factor (LAF).

augments the activity of many cell types, especially T cells.

is an endogenous pyrogen (EP).

induces an increase in acute phase reactants.

is a heat-stable and pH-stable peptide with a molecular weight of 17.5 kd.

occurs in two forms: IL-1 $\alpha$  and IL-1 $\beta$ .

### 63. CEAP score indicates-

a) Atrial disorders

b) Venous disorder

c) Neurological disorder

d) Trauma disorder

Correct Answer - B

**Answer- B. ( Venous disorder)**

Comprehensive Classification System for Chronic Venous Disorders (CEAP)

CEAP classification of chronic venous disease

Clinical classification

C3

Edema

C4a

Pigmentation or eczema

C4b

Lipodermatosclerosis or atrophie blanche

C5

Healed venous ulcer

## 64. IL- 1 activated by-

a) Capsase 1

b) Capsase 3

c) Capsase 8

d) Capsase 5

Correct Answer - A

### **Answer- A (Capsase 1)**

The two inflammatory cytokines activated by Caspase-1 are excreted from the cell to further induce the inflammatory response in neighboring cells.

## 65. Parotid mass mixed consistency

a) Pleomorphic adenoma

b) Sebaceous cyst

c) Dermoid cyst

d) All

Correct Answer - A

**Answer- A (Pleomorphic adenoma)**

It is also known as “Mixed tumor, salivary gland type”, which refers to its dual origin from epithelial and myoepithelial elements as opposed to its pleomorphic appearance.

## 66. Krabbe's disease is-

a) Deficiency of Beta- galactosylcermidase

b) Deficiency of aryl sulphatase

c) Alpha galactosidase

d) Acid lipase

Correct Answer - A

**Answer- A (Deficiency of Beta- galactosylcermidase)**

Krabbe disease is caused by mutations in the GALC gene located on chromosome 14 (14q31), which is inherited in an autosomal recessive manner. Mutations in the GALC gene cause a deficiency of an enzyme called galactosylceramidase.

**67. What is the choice of treatment for idiopathic thrombocytopenia purpura (ITP)?**

a) Blood transfusion

b) Spontaneous recovery

c) IV infusion

d) Splenectomy

Correct Answer - D

**Answer- D (Splenectomy)**

Beneficial effects of splenectomy in chronic ITP are due to both removal of the major site of platelet destruction and the major source of autoantibody synthesis.

## 68. Fluoroquinolones with maximum bioavailability is?

a) Moxifloxacin.

b) Gatifloxacin.

c) Levofloxacin

d) Ciprofloxacin

Correct Answer - C

**Ans. C. Levofloxacin.**

**Pharmacokinetics of fluoroquinolones:**

- Good oral bioavailability (except norfloxacin).
- **Levofloxacin - 100% bioavailability.**
- Multivalent cations interfere with absorption (like tetracycline).

## 69. Mechanism of action of buspirone is?

a) 5 HT1A partial agonism.

b) 5 HT1B antagonism.

c) 5 HT1B partial agonism.

d) 5 HT2C antagonism.

Correct Answer - A

Ans. A. HT1A partial agonism

### **5 HT1A:**

- \* Presynaptic autoreceptor.
- \* Modulates serotonin release.

### **Partial 5 HT1A agonists:**

- \* Buspirone, isapirone, gepirone.
- \* Useful as anti-anxiety drug.

## 70. Which statement best describes mechanism of action of azole?

a) Synthesis of ergosterol

b) Thymidylate synthase

c) Targeting Beta-1,3 – glucan

d) Disruption of cell wall.

Correct Answer - A

Ans. A. Synthesis of ergosterol

- Inhibition of 14a-lanosterol demethylase, a key enzyme in ergosterol biosynthesis ? resulting in depletion of ergosterol & accumulation of toxic 14a-methylated sterols in membranes of susceptible yeast species ? Destruction of fungus.

**71. Which is the following is orally active direct Xa inhibitor?**

a) Rivaroxaban

b) Agrataban

c) Dabigatran

d) Bilverudin

Correct Answer - A

**Ans. a. Rivaroxaban**

Rivaroxaban, apixaban & edoxaban are factor Xa inhibitors.  
Dabigatran etexilate is direct thrombin inhibitor.

**72. Which among the following is most probable reason for preference of Cisatracurium over atracurium?**

a) Decreased histamine release

b) Increased histamine release

c) Due to elimination by Hofmann elimination

d) Increased CNS toxicity

Correct Answer - A

Ans. A. Decreased histamine release

**Cisatracurium:**

\* Undergoes Hofmann elimination.

\* Does not provoke histamine release – Hence, preferred over atracurium.

\* No effect on heart rate/BP/nil autonomic effect.

\* Produces less laudanosine than atracurium – Hence, less CNS toxicity (seizures).

### 73. Which of the following drug is used in SIADH?

a) Tolvapatan

b) Desmopressin

c) Vwb factor

d) Terlipressin

Correct Answer - A

Ans. A. Tolvaptan

**Tolvaptan:**

- \* Vasopressin antagonists.
- \* Orally active nonpeptide selective V2 receptor antagonist.
- \* Metabolized by CYP3A4 – Not given to patients receiving this isoenzyme inhibitor.
- \* Given once daily.
- \*  $t_{1/2}$ : 6–8 hours.

**Actions:**

- \* Increases free water clearance by kidney (aquaretic).
- \* Corrects lower plasma  $\text{Na}^+$  levels.

**Uses:**

- \* Useful for hyponatremia treatment.
- \* Hyponatremia caused by CHF, cirrhosis of liver or syndrome of inappropriate ADH secretion (SIADH).

**Side effect:**

- \* Thirst & dry mouth (most frequent).
- \* Fever, G.I. upset & hyperglycaemia.

## 74. Drug acting on K<sup>+</sup> channels include which of the following?

a) Spironolacton

b) Amiloride.

c) Nicorandil

d) Methyldopa

Correct Answer - C

Ans. C. Nicorandil

### **Nicorandil:**

- Cardioprotective potassium channel opener.
- Causes ischemic preconditioning & coronary dilation – By activating myocardial ATP sensitive K<sup>+</sup> channels.
- Also possesses NO-releasing property.
- Useful in angina.

**75. Imipenem, a newer antibiotic with a broad antibacterial spectrum, is co administered with cilastatin. Which of the following is the best reason for the same?**

a) Combination of antibiotics is synergistic against *Pseudomonas* specie

b) Cilastatin aids gastrointestinal absorption of active moiety, imipenem

c) Cilastatin inhibits beta=lactamase enzyme destroying imipenem

d) Cilastatin inhibits an enzyme in kidney destroying imipenem

Correct Answer - D

**Ans. D. Cilastatin inhibits an enzyme in kidney destroying imipenem**

Imipenem-cilastatin 0.5 g i.v. 6 hourly (max 4 g/day).

Effective in serious hospital-acquired respiratory, urinary, abdominal, pelvic, skin & soft tissue infections including neutropenic, cancer & AIDS patients.

For *Ps. aeruginosa* infections, it should be combined with gentamicin.

## 76. DOC for smoking cessation?

a) Acamprosate

b) Varenicline

c) Thalidomide

d) Tryptophan

Correct Answer - B

Ans. B. Varenicline (If Bupropion is not an option)

### **Anti-smoking drugs:**

- Bupropion (along with Varenicline & Nicotine replacement therapy) is a USFDA approved first-line agent for pharmacotherapy in smoking cessation.

### **Varenicline:**

- Effective agents for smoking cessation.
- Synthetic drug with partial agonist action at  $\alpha_4 \beta_2$  nicotinic receptors.
- Has antagonist properties persisting due to long half-life & high receptor affinity.
- Hence, prevents stimulant effect of nicotine at presynaptic  $\alpha_4 \beta_2$  nicotinic receptors --> results in dopamine release.

## 77. DOC for Cyclosporiasis?

a) Trimethoprim sulfamethoxazole combination

b) Paromomycin

c) Metronidazole

d) Cyclosporin

Correct Answer - A

**Ans. A. Trimethoprim and sulfamethoxazole combination.**

Combination of trimethoprim with sulfamethoxazole is DOC for cyclosporiasis & Isosporiasis (Protozoal infection).

## 78. Mechanism of action of curare like drugs?

a) Blocks ACh synthesis

b) Blocks ACh receptors

c) Persistent depolarization

d) Agonistic with Ach receptors

Correct Answer - B

**Ans. B. Blocks ACh receptors**

Tubocurarine, Cisatracurium, Rocuronium: Competitive antagonist at nACh receptors mainly at NM junction.

**d-tubocurarine:**

- Obsolete clinical usage.
- Prototype NM blocker.
- Longer acting isoquinoline derivative.
- MOA: Acts predominantly at nicotinic receptor site blocking their receptors – By competing with acetylcholine (competitive antagonism).

**79. A drug with high plasma binding protein property has which of the following properties?**

a) Less GFR

b) Less drug interaction

c) Higher volume of distribution

d) Less tubular secretion

Correct Answer - A

**Ans. A. Lesser GFR**

Only free drugs can be filtered through glomerulus.

Hence, PPB decreases GFR.

Tubular secretion is an energy requiring carrier mediated active transport.

hence , PPB do not interfere with tubular secretion.

## 80. Mechanism of action of Oseltamivir?

a) Protein synthesis inhibitor

b) Thymidylate synthetase inhibitor

c) Neuraminidase inhibitor

d) Pyrimidine analogs.

Correct Answer - C

Ans. C. Neuraminidase inhibitor

### **Neuraminidase inhibitors:**

- Analogs of sialic acid.
- Interferes with release of progeny influenza A & B virus from infected host cells.
- Competitively & reversibly interact with active enzyme site → resulting in clumping of newly released influenza virions to each other & to membrane of infected cell.

## 81. True about colchicines is/are?

a) Acts by neutrophil recruitment

b) Causes metaphase arrest

c) Useful in urate-lowering therapy

d) All of the above

Correct Answer - D

Ans. D. All of the above.

**Colchicine:**

**MOA:**

- Acts by inhibiting granulocyte migration into inflamed joint.
- Depolymerization of microtubules leads to neutrophil recruitment to inflamed tissue ? Altering neutrophil motility.
- Decreases secretion of chemotactic factors & superoxide anions by activated neutrophils.
- Causes metaphase arrest.

**Most common & dose limiting toxicity:**

- Diarrhea.
- Also cause kidney damage, myopathy & bone marrow depression.

**Indications:**

- As a urate-lowering therapy (daily colchicines) suppressing attacks precipitated by abrupt serum uric acid changes.

## 82. Which of the following drug is alpha 2 agonist?

a) Apraclonidine

b) Timolol

c) PG analogues

d) Verampamil

Correct Answer - A

**Ans. A. Apraclonidine**

Apraclonidine – Selective alpha 2 agonist.

Useful in glaucoma.

Alpha agonists (Brimonidine and apraclonidine) are contraindicated in hypertensive crisis.

Dipivefrin is a prodrug which is converted into epinephrine inside the eye, so can safely be used in hypertension.

### 83. Drug to differentiate Myasthenia gravis from cholinergic crisis?

a) Pyridostigmine

b) Edrophonium

c) Methacholine

d) Clonidine

Correct Answer - B

**Ans. B. Edrophonium.**

Edrophonium – Used as a diagnostic test for myasthenia.

**Steps:**

- 2 mg dose injected intravenously.
- If no reaction occurs after 45 seconds, an additional 8 mg administered.
- If the patient has myasthenia gravis, an improvement in muscle strength lasting for about 5 minutes usually observed.

## 84. Conversion of Norepinephrine to epinephrine is mainly by?

a) S-adenosyl methionine

b) Arginine

c) Phenylalanine

d) Dehydrogenease

Correct Answer - A

**Ans. A. S-adenosyl methionine**

S-adenosyl methionine is required & enzyme is phenylethanolamine N-methyl transferase.

S-adenosylmethionine donates methyl group for conversion of NE to E in presence of Phenylethanolamine N Methyltransferase enzyme

**85. Carbapenem which has tendency to cause maximum seizures?**

a) Imipenem

b) Ertapenem

c) Doripenem

d) Meropenem

Correct Answer - A

Ans. A. Imipenem.

**Imipenem:**

- Carbapenem grp. of drugs.
- Maximum tendency to cause seizures.

## 86. DOC for diphtheria carrier state is?

a) Penicillin

b) Antitoxin

c) Penicillin Or erythromycin

d) Ciprofloxacin

Correct Answer - C

**Ans. C. Penicillin or erythromycin**

Contacts should receive antibiotics.

Benzathine penicillin G (600,000 units for persons younger than 6 years old and 1,200,000 units for those 6 years old and older)

Oral erythromycin (40 mg/kg/ day for children and 1 g/day for adults) for 7- to 10-day course.

Identified carriers in community also receive antibiotics.

Maintain close surveillance and begin antitoxin at the first signs of illness.

**87.**

## Healthy Human volunteers part of which clinical trial phase?

a) Phase 1

b) Phase 0

c) Phase 3

d) Phase 4

Correct Answer - A

**Ans: A, Phase 1.**

Phase I of clinical trial is human pharmacology and safety.

Phase I involves normal human volunteers.

**88. DOC for scorpion sting bite is?**

a) EDTA

b) Neostigmine

c) N-acetylcysteine

d) Prazosin

Correct Answer - D

**Ans: d. Prazosin**

DOC for poisoning due to sting of scorpion – Prazosin.

**Prazosin:**

- An alpha-blocker.

**Management of scorpion sting bite:**

**Depending upon the severity of Scorpion poisoning:**

- Immunotherapy - (dose depending on antivenom titer)
- Prazosin
- Midazolam
- Aspirin

## 89. MOA of Teduglutide in short bowel syndrome?

a) GLP-2 inhibitor

b) HT1a inhibitor

c) GLP-1 analogs

d) C-peptide analogs

Correct Answer - A

**Ans. A. GLP-2 inhibitor**

Glucagon-like peptide-2 (GLP-2) – Important intestinotrophic growth factor & mediator of intestinal adaptation.

FDA approved teduglutide (Gattex—NPS) to treat short bowel syndrome in adult patients requiring additional nutrition from I.V. parenteral nutrition.

Effectively improves fluid absorption.

## 90. DOC for chemotherapy induced vomiting is?

a) Granisetron

b) Prazosin

c) Clonidine

d) Dimenhydrinate

Correct Answer - A  
Ans. A. Granisetron.

**Granisetron:**

- Serotonin 5-HT<sub>3</sub> receptor antagonist.
- Used as an antiemetic treating nausea & vomiting following chemotherapy & radiotherapy.

**Main effect:**

- Reduces vagus nerve activity (Vagus N. activates vomiting center in medulla oblongata).

## 91. What is the advantage of fixed dose combination of drugs.

a) Increases efficacy of drug

b) Decreases adverse effects

c) Patient compliance improved

d) All of the above

Correct Answer - D

Ans. D. All of the above

### **Advantages of FDC:**

- Safe and effective.
- Reduces “pill burden” → Enhancing overall treatment outcome.
- Increases efficiency.
- Reduce incidence of adverse drug effects.
- Improves patient compliance.
- Offers low cost (compared to individual components of active ingredients).

## 92. DOC for digitalis is induced centro-chilar tachycardia?

a) Lidocaine

b) Reducing dosage of digoxin itself, reverses the condition

c) Verapamil

d) Beta blockers

Correct Answer - A

**Ans. A. Lidocaine**

**Digitalis toxicity:**

**Features:**

- Generally unwell & lethargy.
- Nausea & vomiting.
- Confusion.
- Yellow-green vision.
- Arrhythmias (e.g. AV block, bradycardia)
- Dizziness.

**Precipitating factors:**

- **Renal disease**
- **Hypokalaemia**
- **Hypomagnesemia**
- Hypoalbuminemia
- Hypothermia
- Hypothyroidism
- **Hypercalcemia.**
- Hyponatremia
- Acidosis.
- Myocardial ischaemia.
- **Partial AV block.**

**Drugs:**

- **Amiodarone.**
- **Quinidine.**
- **Verapamil.**
- **Spirolactone.**
- **Furosemide.**
- **Hydrochlorothiazide** - Compete with DCT secretion, hence reducing excretion.

**Management:**

- **Digibind.**
- **Correct ventricular arrhythmia by lignocaine.**
- Bradyarrhythmias by propranolol.
- Atrial tachyarrhythmias by atropine.
- Phenytoin.
- Monitor K<sup>+</sup>

**93. Antiretroviral therapy is to be given in HIV infected patients irrespective of presence of symptoms if CD4 count is less than?**

a) 100

b) 150

c) 200

d) 350

Correct Answer - C

**Ans. C. 200**

Offer ART to symptomatic patients if the CD4 count is 200–350 cells/mm<sup>3</sup>

Consider ART for asymptomatic patients with CD4 count between 200-350 cells/mm<sup>3</sup> and monitor closely for new symptoms.

If the CD4 count is 200–250 cells/mm<sup>3</sup>, physicians can consider repeating the CD4 test in 4 weeks in asymptomatic patients.

This is to rule out the possibility of a 20% margin of error in laboratory results.

Patients should start ART before the CD4 count drops below 200 cells/mm<sup>3</sup>

Ref: <http://naco.gov.in/upload/Policies%20&%20Guidelines/1.%20Antiretroviral%20therapy%20for%20HIV%20infected%20Adults%20and%20Adolescents%20Including%20Post-exposure.pdf>

**94.** Filgrastim is used in treatment of:

a) Anemia

b) Neutropenia

c) Malaria

d) Filarial

Correct Answer - B

**Ans. is. B. Neutropenia**

Filgrastim is a recombinant human granulocyte colony stimulating factor (G-CSF) which is a 175 - aminoacid glyco-protein.

It differs from the natural granulocyte stimulating factor due to its lack in glycosylation and the presence of an extra N-terminal methionine. It has proved to be effective in the treatment of severe neutropenia.

Ref: Goodman and Gilman's The Pharmacological Basis of Therapeutics, 11th Edition, Pages 1429-32; Immunopharmacology By Manzoor M. Khan, Pages 49-50

## 95. True about treatment of early breast carcinoma?

- a) Aromatase inhibitors are replacing tamoxifen in premenopausal women
- b) Post mastectomy radiation therapy is given when 4 or more lymph nodes are positive
- c) Tamoxifen is not useful in post-menopausal women
- d) In premenopausal women, multidrug chemotherapy is given in selected patients

Correct Answer - B

**Ans. B. Post mastectomy radiation therapy is given when 4 or more lymph nodes are positive**

**Tamoxifen:**

- Effective in both pre & postmenopausal women (if hormone receptor positive)
- DOC in premenopausal women

**Aromatase inhibitors:**

- Proven more beneficial than tamoxifen in postmenopausal women.

**MOA:**

- By lowering estrogen in post-menopausal women with hormone-receptor-positive breast cancer.
- In post-menopausal women, most of body's estrogen is from androgen.
- Aromatase inhibitors inhibits aromatase enzyme → blocking androgen into estrogen → lowering estrogen produced outside ovaries.

**Uses:**

- 1st line therapy in postmenopausal women, adjuvant setting or

secondary agent after 1 to 2 years of adjuvant tamoxifen therapy.

**Advantages:**

- Reduced incidence of endometrial cancer.

**Adverse effects:**

- Bone mineral density alteration-à osteoporosis & increased fractures in postmenopausal women.

**Other options:**

- In premenopausal women with any form of adjuvant systemic therapy should receive multidrug chemotherapy.

**96. A patient of RA is taking methotrexate, steroids and NSAIDs since 4 months but activity of disease progression is same. What should be the next probable step?**

a) Start monotherapy with anti TNF alpha drugs

b) Continue methotrexate and steroids

c) Stop oral methotrexate and start parenteral methotrexate

d) Add sulfasalazine

Correct Answer - D  
Ans. D. Add sulfasalazine

## 97. IV Mannitol is used for treatment of

a) Acute congestive glaucoma

b) Pulmonary edema

c) Acute renal failure

d) CHF

Correct Answer - A

**Ans. A. Acute congestive glaucoma.**

Mannitol may be used to reduce intraocular pressure when given intravenously.

**98. Variation in sensitivity of response to different doses of a drug in different individual is obtained from?**

a) Dose response curve

b) Therapeutic index

c) Bioavailability

d) Phase 1 clinical trials

Correct Answer - A

**Ans. A. Dose response curve**

The dose–response relationship, or exposure–response relationship, describes the change in effect on an organism caused by differing levels of exposure to a stressor after a certain exposure time, or to a food.

Applies to individuals, or to populations.

**99. Which one of following is functions of PGI<sub>2</sub>?**

a) Inhibits platelet aggregation

b) Is a vasodilator

c) Is pyrogenic like PGE<sub>2</sub>

d) All of the above

Correct Answer - D

Ans. D. All of the above.

**Functions of PGI<sub>2</sub>:**

- Inhibits platelet aggregation, vasodilator plus bronchodilator & pyrogenic like PGE<sub>2</sub>.

## 100. Degloving skin involves removal of?

a) skin , subcutaneous fat, fascia, muscle

b) skin, subcutaneous fat, fascia

c) skin only

d) skin subcutaneous fat

Correct Answer - D

**Answer: D. skin subcutaneous fat**

The clinical entity of degloving injury means that the skin has been lost, but the musculoskeletal unit is intact, and hence, the movements of the part have been preserved.

Degloving, also called avulsion, is a type of severe injury that happens when the top layers of your skin and tissue are ripped from the underlying muscle, connective tissue, or bone. It can affect any body part, but it's more common in the legs

Depending on the angle that the tire pulls across the extremity, the skin and subcutaneous tissue may be pulled or sheared off on leading edge of extremity.

## 101. Sexual perversions(Exhibitionism) is under section

a) Section 290

b) Section 294

c) Section 230

d) Section 291

Correct Answer - B

**Answer: B. Section 294**

EXHIBITIONISM: sexual gratification by exposing one's genitalia.

Punishable under sec 294 I.P.C.with imprisonment upto 3 months or fine

## 102. 1st affected in rigor mortis

a) Eyelids

b) Myocardium

c) Jaw

d) Neck

Correct Answer - B

### **Answer-B. Myocardium**

state of the muscles in a dead body when they become stiff or rigid with some degree of shortening.

All muscles of body are involved i.e. voluntary or involuntary.

However, it does not start in all muscles simultaneously (Nysten's rule).

Involuntary muscles (heart) are involved first than voluntary muscles.

Sequence of muscles involvement is as follows: Heart > upper eyelid > neck > jaw > face > chest > upper limb > abdomen > lower limb > finger and toes.

**103.**

## Punishment for perjury is under which section IPC ?

a) Sec 193

b) Sec 191

c) Sec 197

d) Sec 190

Correct Answer - A

### **Answer A. Sec 193**

Defines punishment for fabricating false evidence

The witness is liable to be prosecuted for perjury, and the imprisonment may extend upto seven years.

193 IPC : punishment for false evidence, (punishment for perjury) : imprisonment upto 7 years + hne

Igl IpC : (i) Giving false evidence (perjury) under oath.

192 IPC: Fabricating false evidence (perjury)

**104. Gastric lavage is not contraindicated after ingestion of which acid.**

a) HCL

b) H<sub>2</sub>SO<sub>4</sub>

c) Carbolic acid

d) Nitric acid

Correct Answer - C

**Answer-C. Carbolic Acid**

The only absolute contraindication is corrosive poisoning i.e alkalis, mineral acid, vegetable acid and organic acids (except carbolic acid).

Carbolic acid is the only corrosive in which gastric lavage can be used.

Gastric lavage must be done (except when contraindicated) irrespective of whether vomiting has occurred or not, to prevent aspiration of content.

Carbolic acid is the only corrosive in which gastric lavage is not contraindicated.

## 105. Viscera in toxicology stored in

a) Glycerine

b) Rectified spirit

c) Formalism

d) Saturated salt solution

Correct Answer - D

### **Answer-D. Saturated salt solution**

Toxicological viscera is preserved in a saturated solution of common salt (sodium chloride).

For toxicological analysis, viscera is never preserved in alcohol, formalin, or bile salt.

In fact, formalin denatures proteins and chemical toxins and would interfere with the detection of poisons during chemical analysis'

## 106. Two identical twins will not have same

a) Fingerprints

b) DNA copies

c) Iris color

d) Blood group

Correct Answer - A

**Answer: A. Fingerprints**

Identical twins have the same DNA, but their fingerprints (dactylography) are still different and they do not change.

These can be easily used to differentiate between an identical set of twins.

Identical twins have the same set of DNA, therefore DNA fingerprinting cannot differentiate them.

**107. In Alleged history of gun shot injury.there is burning, blackening, tattooing around the wound Dirt collar, the injury is**

a) Close shot entry wound

b) Close shot exit wound

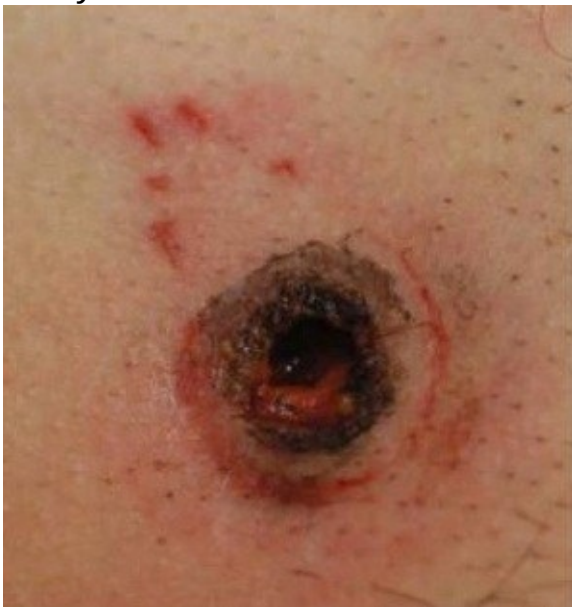c) Distant shot entry wound

d) distant shot exit wound

Correct Answer - A

Answer: A. Close shot entry wound

- Buring, blackening, tattooing around the wound are features of close shot entry.
- And may occur in contact shot when muzzle end is not pressed firmly.



- The muzzle end is not pressed firmly or is loosened by recoil, flame, gas and soot may escape sideways and soil the adjoining skin..... Parikh.
- Grease collar or dirt collar is seen at firearm entry wound. It is a black colored ring lining the entrance wound on the skin.
- It is produced by removal of substances from the bullet as it passes through the skin,

## 108. A child is having Battered baby syndrome how will you identify

a) Stab wound

b) Gunshot wound

c) Bruise of different ages

d) None of these

Correct Answer - C

### **Ans-C. Bruise of different ages**

A battered child is one who has received repetitive physical injuries as a result of non-accidental violence produced by a parent or a guardian.

multiple bruise present over body, Laceration of the oral mucosa, Parents give vague history of accident to be the cause of the injuries.

It is also called Caffey syndrome, Caffey-Kempe syndrome, maltreatment syndrome or Parent-infant traumatic stress syndrome The injuries may be caused by hand, foot, teeth, stick, belt, shoe, hot water, lighted cigarette, hot frying pan or any household article Accidental injuries typically involve bony prominences [head (forehead, occipital or parietal region), nose, chin, palm, elbows, knees and shin], match the history given by the parents and are keeping with the development of the child

**109. A patient is having gastrointestinal problems including abdominal pain and distension, bloody or mucus-filled diarrhea, and tenesmus, with rectal prolapse, A stool, ova and parasites exam reveals the presence of typical Barrel-shaped eggs, possible causative agent is?**

a) Campylobacter

b) Clostridium difficile

c) Giardia lamblia

d) Trichuris

Correct Answer - D

Answer: D. Trichuris

- whipworm can cause gastrointestinal problems, such as abdominal pain, diarrhea, mucous or bloody stools weight loss, painful urination, and weakness.
- Rectal prolapse is a hallmark, albeit rare, symptom of a heavy *T. trichiura* infection that occurs in children more frequently than adults. When rectal prolapse occurs, worms can often be identified on the edematous rectum.
- In a whipworm infection, the rectum loses its internal support because the worms bury their thin heads into the intestinal lining, loosening the elastic epithelium and weakening the surrounding muscles.



## 110. Contact isolation is done for

a) MRSA

b) Mumps

c) Diphtheria

d) Asthama

Correct Answer - C

Answer: C. Diphtheria

- A type of bacteria called *Corynebacterium diphtheriae* causes diphtheria.
- The condition is typically spread through person-to-person contact or through contact with objects that have the bacteria on them, such as a cup or used tissue.
- Even if an infected person doesn't show any signs or symptoms of diphtheria, they're still able to transmit the bacterial infection for up to six weeks after the initial infection
- The bacteria most commonly infect your nose and throat. Once you're infected, the bacteria release dangerous substances called toxins. The toxins spread through your bloodstream and often cause a thick, gray coating in nose, throat, lungs.

**111. A child is suffering from recurrent chronic infections with encapsulated bacteria is due to deficiency of subclass**

▪

a) IgG1

b) IgG2

c) IgG3

d) IgG4

Correct Answer - B

Answer: B. IgG2

- IgG2 antibodies are predominantly against the polysaccharide (complex sugar) coating (capsule) of certain disease-producing bacteria (such as, *Streptococcus pneumoniae* and *Haemophilus influenzae*).
- In young children, the ability to make IgG2 antibodies to the polysaccharide coatings of bacteria develops more slowly than the ability to make antibodies to proteins.

## 112. D.O.C for isospora

a) Penicillin G

b) Benzathine penicillin

c) Co-trimoxazole

d) Albendazole

Correct Answer - C

Answer: C. Co-trimoxazole

- The most common antibiotic that is prescribed is co-trimoxazole (trimethoprim-sulfamethoxazole), more commonly known as Bactrim, Septra, or Cotrim.
- For Immunocompetent hosts Preferred regimen: Trimethoprim-sulfamethoxazole 160 mg/800 mg PO bid for 7-10 days..

## 113. Coxsackievirus A16 causes

a) Yellow fever

b) Hand-foot-mouth disease

c) Rocky mountain spotted fever

d) Encephalomyocarditis

Correct Answer - B

Answer: B. Hand-foot-mouth disease

- Hand, Foot and Mouth Disease (HFMD) is caused by coxsackie A-16
- The viruses that cause HFMD are spread through close personal contact, through the air from coughing and the feces of an infected person.
- Coxsackievirus A16 is the most common cause, and enterovirus 71 is the second-most common cause. Other strains of coxsackievirus and enterovirus can also be responsible.
- It typically begins with a fever and feeling generally unwell. This is followed a day or two later by flat discolored spots or bumps that may blister, on the hands, feet and mouth and occasionally buttocks and groin.

## 114. Pneumocystis jirovecii is:

- a) Associated with CMV
- b) Diagnosis is by sputum microscopy
- c) Seen only in immunocompromised patients
- d) Always associated with pneumatocele

Correct Answer - B

Answer: B. Diagnosis is by sputum microscopy

- Human isolate of *Pneumocystis* which is associated with severe pneumonia in immunocompromised state particularly AIDS.
- *P. jirovecii* is an extracellular pathogen. Growth in the lung is limited to surfactant layer above alveolar epithelium.
- Serologic evidence suggest that most individuals are infected in early childhood (thus option "c" is wrong) but the pneumonia is seen only in immunocompromised state.
- Diagnosis is made by detection of organism in proper specimen
- Sputum: Quick and non invasive.
- Broncho-alveolar lavage (BAL) fluid: Mainstay of pneumocystis diagnosis.
- Transbronchial biopsy: If diagnosis cannot be made by BAL.

## 115. All are true about congenital Toxoplasmosis EXCEPT

a) Chorioretinitis

b) Conjunctivitis

c) Hydrocephalus

d) Cerebral calcification

Correct Answer - B

Answer B. Conjunctivitis

- Occurs only when mother gets primary toxoplasmosis infection whether clinical or asymptomatic during pregnancy or <6 months before conception (i.e. no risk if acquired > 6 months before conception).
- As gestational age is increased, risk of transmission to fetus increased, i.e. max. in 3rd trimester while
- severity of fetal damage is decreased, i.e. infant is usually asymptomatic if infection transmit in 3rd trimester.
- Chorioretinitis is usually treated with a combination of corticosteroids and antibiotics.
- It causes: hydrocephalous, diffuse cerebral calcification,hepatosplenomegaly,mental retardation myocarditis,lymphadenitis,microencephaly, myocarditis, chorioretinitis, multiorgan failure, Pneumonitis

## 116. true about TRIAD congenital rubella syndrome

a) PDA, cataract and deafness is seen

b) Hepatosplenomegaly, mental retardation, deafness

c) Chorioretinitis, multiorgan failure, pneumonitis

d) None of these

Correct Answer - A

Answer: A. PDA, cataract and deafness is seen

- Congenital rubella syndrome (CRS) can occur in a developing fetus of a pregnant woman who has contracted rubella, usually in the first trimester. If infection occurs 0–28 days before conception, the infant has a 43% risk of being affected.
- Infection in 2nd trimester – may be deafness only.
- >6 wks – no major abnormalities
- Diagnosis: Isolation of virus in cell cultures of throat samples, urine or other secretions.
- Detection of IgM in single serum sample shortly after birth.
- Persistence of Rubella IgG antibodies serum beyond 1 year or rising antibody titer anytime during infancy in an unvaccinated child

## 117. Disc diffusion method is also known as

a) Kirby Bauer

b) VDRL

c) Dark field microscopy

d) None of these

Correct Answer - A

Answer: A. Kirby Bauer

- The disk diffusion test, or agar diffusion test, or Kirby–Bauer test (disc-diffusion antibiotic susceptibility test, disc-diffusion antibiotic sensitivity test, KB test), is a test of the antibiotic sensitivity of bacteria.
- It uses antibiotic discs to test the extent to which bacteria are affected by those antibiotics. In this test, wafers containing antibiotics are placed on an agar plate where bacteria have been placed, and the plate is left to incubate.
- If an antibiotic stops the bacteria from growing or kills the bacteria, there will be an area around the wafer where the bacteria have not grown enough to be visible. This is called a zone of inhibition

## 118. Rubella virus belongs to which family ?

a) Rheovirus

b) Togavirus

c) Picornavirus

d) Orthomyxo

Correct Answer - B

### **And. B. Togavirus**

Rubella virus (RuV) is the pathogenic agent of the disease rubella, and is the cause of congenital rubella syndrome when infection occurs during the first weeks of pregnancy.

Rubella virus is the only member of the genus Rubivirus and belongs to the family of Togaviridae, whose members commonly have a genome of single-stranded RNA of positive polarity which is enclosed by an icosahedral capsid.

**119. Which of the following infection resembles erythroblastosis?**

a) EBV

b) CMV

c) HSV

d) STAPHYLOCOCCUS

Correct Answer - B

**ANSWER: B. CMV**

Cytomegalovirus infection is a common herpesvirus infection with a wide range of symptoms: from no symptoms to fever and fatigue (resembling infectious mononucleosis)

Infection with CMV, like that with Epstein-Barr virus (EBV, a type 4 herpesvirus), can cause a type of infectious mononucleosis in adolescents and young adults. Both CMV and EBV mononucleosis cause fever and fatigue. But EBV also causes a severe sore throat. CMV does not.

## 120. Diagnostic test for neurosyphilis

a) VDRL

b) RPR

c) TPI

d) FTA-ABS

Correct Answer - A

Answer:A. VDRL

- Examination of CSF for pleocytosis, increase protein concentration, VDRL reactivity.
- A positive CSF VDRL makes the diagnosis of neurosyphilis.
- If both test i.e. VDRL and FTA- ABS IgM (specific) test are positive in the infant then congenital syphilis should be strongly suspected and the child should be treated.
- A positive test confirms neurosyphilis but a negative result does not rule out neurosyphilis. Due to the low sensitivity of the CSF VDRL, fluorescent treponemal antibody absorption test (FTA-ABS) can be used to supplement VDRL.

## 121. Flask shaped ulcers in intestine caused by

a) Giardia lamblia

b) Entamoeba histolytica

c) Helicobacter pylori (H. pylori)

d) E. vermicularis

Correct Answer - B

### **Answer B. Entamoeba histolytica**

Disease occurs when amoeba comes in contact with the cells lining the intestine.

It then secretes the same substances it uses to digest bacteria, which include enzymes that destroy cell membranes and proteins.

This process can lead to penetration and digestion of human tissues, resulting first in flask-shaped ulcerations in the intestine.

Entamoeba histolytica ingests the destroyed cells by phagocytosis and is often seen with red blood cells (a process known as erythrophagocytosis) inside when viewed in stool samples

## 122. What type of culture media is used for Legionella?

a) (BCYE) agar media

b) MacConkey agar

c) Baird–Parker agar

d) Sabouraud's agar

Correct Answer - A

**Answer: A. (BCYE) agar media**

BCYE is selective for certain Gram-negative bacteria, especially *Legionella pneumophila*.

The organisms are nutritionally fastidious, non-spore forming, aerobic, gram-negative, slender rods.

Media containing cysteine, yeast extract,  $\alpha$ -ketoglutarate, and iron (BCYE) are required for isolation of *Legionella*.

Selective BCYE (medium containing antibiotics), is recommended for specimens likely to be contaminated with other bacteria.

### 123. Special Stain for cryptococcus :

a) ZN stain

b) Gram stain

c) Mucicarmine stain

d) Malachite green

Correct Answer - C

**Ans: C. Mucicarmine stain**

Mucicarmine stain provides specific staining of polysaccharide cell wall in *C. neoformans*.

This is limited to microorganisms with a cell wall that is composed, at least in part, of a polysaccharide component.

**124. A 36 yrs old male patient c/o cough cold fever/rusty sputum / sputum neg for tb ,h/o of travel in china & eaten crab,  
Name the infection**

a) Paragonimus westermani

b) Fasciola hepatica

c) Fasciolopsis buski

d) Entamoeba histolytica

Correct Answer - A

**Ans: A. Paragonimus westermani (lung fluke ).**

During invasion and migration of the flukes, diarrhea, abdominal pain, fever, cough, urticaria, hepatosplenomegaly, pulmonary abnormalities, and eosinophilia may develop.

Un embryonated eggs are passed in the sputum of a human.

During the chronic phase, the lungs are damaged most, but other organs may be involved.

The clinical picture resembles and is often confused with [TB](#).

Praziquantel is the treatment of choice.

## 125. Microbiological test for diagnosing leptospira infection?

a) Cold agglutination

b) Standard agglutination

c) Microscopic agglutination test (MAT)

d) None of these

Correct Answer - C

Answer: C. Microscopic agglutination test (MAT)

- Dark-field microscopy or by immunofluorescence or light microscopy after appropriate staining used
- Microscopic agglutination test [MAT](Gold Standard) also Macroscopic agglutination test
- Differential diagnosis list for leptospirosis is very large due to diverse symptoms.

## 126. Green colour of triage is for which patient ?

a) Low priority

b) Morbidity

c) Ambulatory

d) High priority

Correct Answer - C

### **Ans. C. Ambulatory Triage**

- When the quantity and severity of injuries overwhelm the operative capacity of health facilities, a different approach to medical treatment must be adopted.
- The usual principle of "first come, first treated", is not followed in mass emergencies.
- Triage consists of rapidly classifying the injured and the likelihood of their survival with prompt medical intervention.
- Higher priority is granted to victims whose immediate or long-term prognosis can be dramatically affected by simple intensive care.
- Moribund patients who require a great deal of attention, with questionable benefit have the lowest priority.
- The most common triage classification system used internationally is the four colour code system.

Red     High priority treatment or transfer

Yellow   Medium priority

Green   Ambulatory patients

Black   Dead or moribund patients

## 127. Concurrent list of Indian Constitution includes which of the following?

a) International immigration rule for quarantine

b) Prevention of extension of communicable disease from one unit to another

c) Mines and oilfield workers rules

d) Establishment and maintenance of drug standards

Correct Answer - B

Ans. B. Prevention of extension of communicable disease from one unit to another

The functions of the Union Health Ministry are set out in the seventh schedule of Article 246 of the constitution of India under three lists.

1. Union List

2. Concurrent List

3. State list

The 52 items currently on the Concurrent list are:

1. Criminal law, including all matters included in the Indian Penal Code

2. Criminal procedure, including all matters included in the Code of Criminal Procedure .

3. Preventive detention for reasons connected with the security of a State, the maintenance of public order, or the maintenance of supplies and services essential to the community; persons subjected to such detention.

4. Removal from one State to another State of prisoners, accused persons and persons subjected to preventive detention for reasons specified in Entry 3 of this list.

5. Marriage and divorce; infants and minors; adoption; wills,

intestacy and succession; joint family and partition; all matters in respect of which parties in judicial proceedings were immediately before the commencement of this Constitution subject to their personal law.

6. Transfer of property other than agricultural land; registration of deeds and documents.

7. Contracts including partnership, agency, contracts of carriage, and other special forms of contracts, but not including contracts relating to agricultural land.

8. Actionable wrongs

9. Bankruptcy and insolvency.

10. Trust and Trustees.

11. Administrators – general and official trustees.

11-A. Administration of justice; constitution and Organisation of all courts, except the Supreme Court and the High Courts.

12. Evidence and oaths; recognition of laws, public acts and records, and judicial proceedings.

13. Civil procedure, including all matters included in the Code of Civil Procedure at the commencement of this Constitution, limitation and arbitration.

14. Contempt of court, but not including contempt of the Supreme Court.

15. Vagrancy; nomadic and migratory tribes.

16. Lunacy and mental deficiency, including places for the reception or treatment of lunatics and mental deficient.

17. Prevention of cruelty to animals.

17-A. Forests.

17-B. Protection of wild animals and birds.

18. Adulteration of foodstuffs and other goods.

19. Drugs and poisons, subject to the provisions of Entry 59 of List I with respect to opium.

20. Economic and social planning.

20-A. Population control and family planning.

21. Commercial and industrial monopolies, combines and trusts.

22. Trade unions; industrial and labour disputes.

23. Social security and social insurance; employment and unemployment.

24. Welfare of labour including conditions of work, provident funds, employers' liability, workmen's compensation, invalidity and old age pensions and maternity benefits.
25. Education, including technical education, medical education and universities, subject to the provisions of Entries 63, 64, 65 and 66 of List I; vocational and technical training of labour.
26. Legal, medical and other professions.
27. Relief and rehabilitation of persons displaced from their original place of residence by reason of the setting up of the Dominions of India and Pakistan.
28. Charities and charitable institutions, charitable and religious endowments and religious institutions.
29. Prevention of the extension from one State to another of infectious or contagious diseases or pests affecting men, animals or plants.
30. Vital statistics including registration of births and deaths.
31. Ports other than those declared by or under law made by Parliament or existing law to be major ports.
32. Shipping and navigation on inland waterways as regards mechanically propelled vessels, and the rule of the road on such waterways, and the carriage of passengers and goods on inland waterways subject to the provisions of List I with respect to national waterways.
33. Trade and commerce in, and the production, supply and distribution of,-
  - (a) the products of any industry where the control of such industry by the Union is declared by Parliament by law to be expedient in the public interest, and imported goods of the same kind as such products
  - (b) foodstuffs, including edible oilseeds and oils
  - (c) cattle fodder, including oilcakes and other concentrates
  - (d) raw cotton, whether ginned or not ginned, and cotton seed; and
  - (e) raw jute.
- 33-A. Weights and measures except establishment of standards.
34. Price control.
35. Mechanically propelled vehicles including the principles on which taxes on such vehicles are to be levied.

36. Factories.
37. Boilers.
38. Electricity.
39. Newspapers, books and printing presses.
40. Archaeological sites and remains other than those declared by or under law made by Parliament to be of national importance.
41. Custody, management and disposal of property (including agricultural land) declared by law to be evacuee property.
42. Acquisition and requisitioning of property.
43. Recovery in a State of claims in respect of taxes and other public demands, including arrears of land-revenue and sums recoverable as such arrears, arising outside that State.
44. Stamp duties other than duties or fees collected by means of judicial stamps, but not including rates of stamp duty.
45. Inquiries and statistics for the purposes of any of the matters specified in List II or List III.
46. Jurisdiction and powers of all courts, except the Supreme Court, with respect to any of the matters in this List.
47. Fees in respect of any of the matters in this List, but not including fees taken in any court.

**128. Last point where reproductive and child health programme are include :**

a) Sub-centre

b) Anganwadi

c) District

d) Taluka

Correct Answer - C

Ans.C. District

The various activities of Reproductive and child Health Programme (RCH) are targeted at the district level.

“The RCH programme is based on a differential approach. Inputs in all the districts have not been kept uniform.

While the core components are the same for all districts, the weaker districts will get more support and sophisticated facilities are proposed for relatively advanced districts. On the basis of crude birth rate and female literacy rate – all the districts have been divided into three categories ‘A, B, & C’ All the districts will be covered in a phased manner over a period of three years.”

## 129. Health center in remotest area for planning and management of schemes:

a) Anganwadi

b) Block centre

c) Sub-centre

d) PHC

Correct Answer - C

Ans.C. Sub-centre

The Sub-Centre is the most peripheral and first contact point between the primary health care system and the community. Sub-Centres are assigned tasks relating to interpersonal communication in order to bring about behavioral change and provide services in relation to maternal and child health, family welfare, nutrition, immunization, diarrhoea control and control of communicable diseases programmes.

The Sub-Centres are provided with basic drugs for minor ailments needed for taking care of essential health needs of men, women and children.

### 130. Diagnostic power of a test to correctly diagnose a disease is-

a) Negative predictive value

b) Positive predictive value

c) Sensitivity

d) Specificity

Correct Answer - B

Ans.B. Positive predictive value

- Positive predictive value is the ability of a test to correctly diagnose the proportion of cases in which persons with a positive screening test result have the disease in question.
- Negative predictive value is the proportion of cases in which people with negative test result do not have the disease in question.
- Sensitivity is defined as the ability of the test to identify correctly all those who have the disease, i.e. true positive.
- Specificity is defined as the ability of the test to identify correctly those who do not have the disease, i.e. true negative.

### 131. Paradoxical carriers are-

- a) A person who acquires the microorganism due to his contact with the patient.
- b) A person who acquires the microorganism another carrier.
- c) A person who is clinically recovered from an infectious disease but still capable of transmitting the infectious agent to others.
- d) None

Correct Answer - B

Ans. B.A person who acquires the microorganism another carrier. Paradoxical carrier are defined as person who acquires the microorganism another carrier.

**132. According to IMNCI, a baby of 6 month age, criteria for fast breathing is more than \_\_\_\_\_/min**

a) 60

b) 50

c) 40

d) 30

Correct Answer - B

Ans. B. 50

As the children get older, their breathing rate slows down.

Therefore, the cut-off point for fast breathing will depend on the age of the child. o Fast breathing is present when the respiratory rate is :?

- Child less than 2 months of age : 60 breaths per minute
- Child aged 2 months upto 12 months:50 breaths per minute
- Child aged 12 months upto 5 years : 40 breaths per minute

### 133. All of the following are examples of Dietary fibre except-

a) Pectin

b) Lignin

c) Cellulose

d) Gums

Correct Answer - D

Ans. D. Gums

- Dietary fibre consists of unabsorbable cell wall and other constituents of vegetable food like cellulose, lignin, hemicellulose, gums, pectins, glycoproteins and other polysaccharides.
- Dietary fibre absorbs water in the intestine, swells, increase bulk of stool by increasing water content of faeces and soften it, decreases transit time by facilitating colonic transit.
- “The presence of fibre shortens the transit times and increases the stool bulk”

**Dietary fibre is of two types:**

1. Soluble fibres: It absorbs upto 15 times its weight in water as it moves through GIT, producing softer stools. Its good sources are oat, flaxseeds, peas, beans, apple, citrus fruits, carrots, barley and psyllium.
2. Insoluble fibre: It promotes movement of material through digestive system and increases stool bulk. It's good sources are wheat flour, wheat bran, nuts and vegetables.

**134. Cross product ratio is determined by which study ?**

a) Case control

b) Cohort

c) Cross sectional

d) RCT

Correct Answer - A

Ans.A. Case control study

Cross product ratio :

Risk in case control study is calculated by odds ratio (cross product ratio).

**135. In a normal curve what is the area that comes under 1 standard deviation-**

a) 50%

b) 68%

c) 95%

d) 100%

Correct Answer - B

Ans. B. 68%

1 SD includes → 68% of values

2 SD includes → 95% of values

3 SD includes → 99.7% of values

**136. 2 year old boy of weight 12 kg with vitamin A deficiency what is oral dose of vitamin A**

a) 50, 000 I.U

b) 1 lakh I.U.

c) 1.5 lakh I.U

d) 2 lakh I.U

Correct Answer - D

Ans.D. 2 lakh I.U

**Treatment:**

- Oral therapy: The oral regimen of vitamin A is 200,000 IU on day of presentation, next day, and 2-4 weeks later.
- Children less than 1 year of age or less than 8 kg should receive half the dose of the above dose. Repeat 200,000 IU every 6 months up to 6 years of age to prevent recurrence.
- Parenteral therapy: If the patient has severe disease, is unable to take oral feeds, or has malabsorption, the preferable dose is 100,000 IU of vitamin A given intramuscularly.
- Children with severe measles should also receive vitamin A as they are very likely to be benefited from such therapy both in terms of saving sight and reducing case fatality.
- Prevention

**Prophylaxis consists of periodic administration of Vitamin A supplements. WHO recommended schedule, which is universally recommended is as follows:**

- Infants 6–12 months old and any older children weighing less than 8 kg – 100,000 IU orally every 3–6 months

- Children over 1 year and under 6 years of age – 200,000 IU orally every 6 months
- Infants less than 6 months old, who are not being breastfed – 50,000 IU orally should be given before they attain the age of 6 months

## 137. Not a personal protective equipment

a) Goggles

b) Badges for detecting radiation

c) Gloves

d) Lab coat

Correct Answer - B

Ans. B.Badges for detecting radiation



## 138. Confounding factor is defined as

a) Factor associated with both the exposure and the disease and is distributed unequally in study and control groups.

b) Factor associated with exposure only and is distributed unequally in study and control groups.

c) Factor associated with both the exposure and the disease and is distributed equally in study and control groups

d) Factor associated with the disease and is distributed equally in study and control groups.

Correct Answer - A

Ans. A. Factor associated with both the exposure and the disease and is distributed unequally in study and control groups.

- Epidemiological studies search for the causes of diseases, based on associations with various risk factors that are measured in the study. In addition to the exposures that the study is investigating, there may be other factors that are associated with the exposure and are also risk factors for the disease. If the prevalence of these other factors differs between groups being compared, they will distort the observed association between the disease and exposure under study. Such variables may partially or completely account for any apparent association between an exposure variable and disease. These distorting factors are called confounding factors or variables.
- Thus a Confounding factor is defined as one which is associated with both the exposure and the disease and is distributed unequally in study and control groups. It is itself a risk factor for the disease.

### 139. The significance of difference between proportions can also be tested by-

a) .t' test

b) Chi square test

c) ANOVA

d) Correlation and regression

Correct Answer - B

#### **Ans. B. Chi square test**

Chi-Square test offers a method of testing the significance of difference between the proportions.

Its advantage lies in the fact that it can also be used when more than two groups are to be compared.

**By using this test, we can find out if the difference between two proportions or ratios has occurred by chance. The steps involved are-**

1. Testing the null hypothesis.
2. Applying chi-square test.
3. Calculating the degree of freedom.
4. Comparing with probability tables.

## 140. Paired T test is defined as-

- a) Test used to assess quantitative observations before and after an intervention
- b) Test that is used when the observation are in the form of proportions (for qualitative data)
- c) Test applied when separate observations are made on individuals of two separate groups, and these need to be compared
- d) None

Correct Answer - A

Ans. A. Test used to assess quantitative observations before and after an intervention

### **Paired t-tests**

- The paired t-test is used to compare the values of means from two related samples, for example in a 'before and after' scenario.
- The difference between the means of the samples is unlikely to be equal to zero (due to sampling variation) and the hypothesis test is designed to answer the question "Is the observed difference sufficiently large enough to indicate that the alternative hypothesis is true".
- The answer comes in the form of a probability – the p-value.

## 141. Best representative of incidence of disease in different timeline-

a) Histogram

b) Line diagram

c) Scattered diagram

d) Bar diagram

Correct Answer - B

Ans. B. Line diagram

- Line diagrams are used to show the trend of events with passage of time.
- It is used to show the trend of events with passage of time and shows how the frequency of a particular event or variable vary over time.

**142. For trench type of sanitary filling the amount of land required for 2 meter deep trench for 10000 population is-**

a) 1 acre

b) 2 acre

c) 3 acre

d) 4 acre

Correct Answer - A

Ans. A. 1 acre

General WHO Guidelines for Shallow Trenches is 3-5 Metre for 100 People . So About 300-500 Meter of Shallow Trenches for 10,000 People.

Also there should be a perimeter of 30 m around the trench.

Now 1 Acre = 4046 Sq Meter [200 m X 200 m ]

Hence Answer is 1 Acre.

### 143. Risk of genetic diseases in consanguineous marriage between first cousins?

a) 1-2%

b) 4-8%

c) 8-10%

d) 12-14%

Correct Answer - B

Ans. B.4-8%

Consanguinity is a marriage between relatives and has various degrees. Closely related individuals have a higher chance of carrying the same alleles than those less closely related and therefore children from consanguineous marriages are more frequently homozygous for various alleles than those from non-consanguineous unions.

Generally speaking, frequency of congenital malformations among newborns of first cousin unions is about 2 times the frequency among the general population. In other words instead of a rate of 2-3% of birth defects in the general population, the risk to first cousin couples is around 4-6%.

## 144. Which is not a epidemiological indicator?

a) ABER

b) Annual parasite index

c) Annual falciparum incidence

d) None of the Above

Correct Answer - A

Answer – A. ABER

ABER or Annual Blood Examination Rate is not an epidemiological indicator but an indicator of operational efficiency of Malaria Control Programme.

## 145. Dose of diphtheria antitoxin is-

a) 1000 to 5000 IU

b) 10000 to 100000 IU

c) 1000 to 2000 IU

d) None

Correct Answer - B

Ans. B. 10000 to 100000 IU

- DAT manufactured by Instituto Butantan is a sterile, transparent (clear) serum solution supplied in 10 mL ampoules containing 10,000 IU each.
- DAT must be stored in the refrigerator at 2 – 8°C (36 – 46°F).
- DO NOT FREEZE. Once an ampoule is opened, the DAT serum solution should be used immediately.

## 146. Vertical transmission of HIV is highest with-

a) Elective caesarean section

b) High viral RNA load

c) Breast feeding

d) Term delivery

Correct Answer - B

Ans. B. High viral RNA load

- Vaginal and emergency caesarean section deliveries, prematurity, and low CD4 cell count were most strongly associated with infant's infection status in univariate analyses .
- Children delivered vaginally or by emergency caesarean section were more likely to be infected than those delivered by elective caesarean section, with a reduction in risk of 79% associated with the latter ( $P < 0.001$ ).
- Similarly, infants delivered before 37 weeks were more than twice as likely to be infected than infants who were not premature.
- Caesarean section before onset of labour and rupture of membranes approximately halves the risk of mother-to-child transmission.

### **Transmission rate:**

- During pregnancy: 5–10%
- During labour and delivery: 10–15%
- During breastfeeding: 5–20%
- Overall without breastfeeding: 15–25%
- Overall with breastfeeding to six months: 20–35%
- Overall with breastfeeding to 18–24 months: 30–45%

## 147. The most common site of the branchial cyst is:

a) Posterior border of sternocleidomastoid

b) Anterior border of sternocleidomastoid

c) Digastric muscle

d) Omohyoid muscle

Correct Answer - B

Answer. B. Anterior border of sternocleidomastoid

- A branchial cleft cyst (BCC) commonly presents as a solitary, painless mass in the neck of a child or young adult.
- They are most commonly located along the anterior border and the upper third of the sternocleidomastoid muscle in the anterior triangle of the neck.

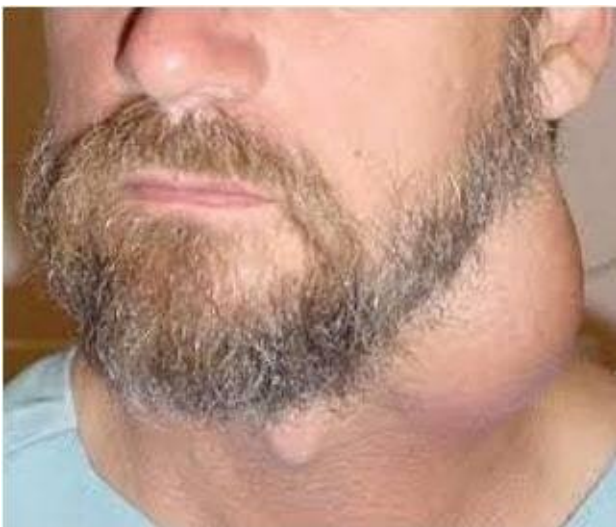

Figure 1 Branchial cleft cyst in the neck

## 148. Inspiratory stridor is found in what kind of lesions:

a) Supraglottic

b) Subglottic

c) Tracheal

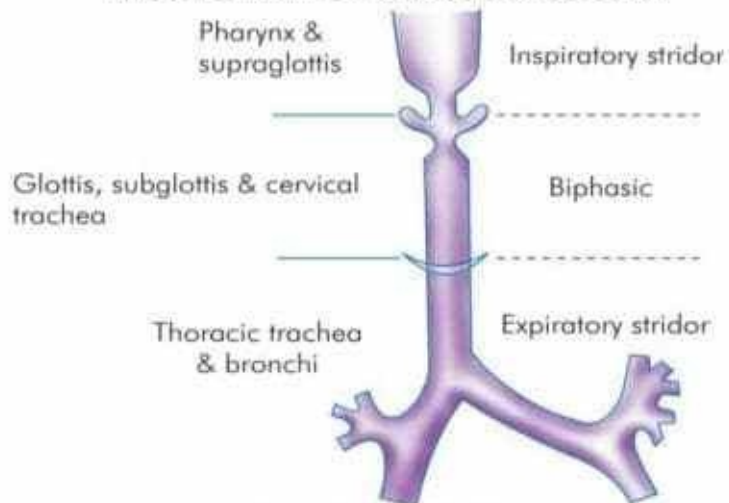
d) Bronchus

Correct Answer - A

Answer A. Supraglottic

- Generally, an inspiratory stridor suggests airway obstruction above the glottis.
- While an expiratory stridor is indicative of obstruction in the lower trachea.
- A biphasic stridor suggests a glottic or subglottic lesion.

Types Of Stridor And Probable Site of Obstruction



(Herring, Diseases of the Nose and Throat, 5th Edition, Copyright © 2010 Elsevier. All rights reserved.)

**149. In Retinitis pigmentosa decreased level of?**

a) Arachidonic

b) Trielonic

c) Thromboxane

d) Docosa hexanoic acid

Correct Answer - D  
Answer. D. Docosa hexanoic acid

## 150. What is against the rule correction in astigmatism:

a) -1.25 cyl 90

b) -2 spherical 180

c) -3 cyl 180

d) +2 cyl 180

Correct Answer - A:D

Types of regular astigmatism Depending upon the axis and the angle between the two principal meridians, regular astigmatism can be classified into the following types :

1. With-the-rule astigmatism. In this type the two principal meridians are placed at right angles to one another but the vertical meridian is more curved than the horizontal. Thus, correction of this astigmatism will require the concave cylinders at  $180^\circ \pm 20^\circ$  or convex cylindrical lens at  $90^\circ \pm 20^\circ$ . This is called 'with-the-rule' astigmatism, because similar astigmatic condition exists normally (the vertical meridian is normally rendered 0.25 D more convex than the horizontal meridian by the pressure of eyelids).

2. Against-the-rule astigmatism refers to an astigmatic condition in which the horizontal meridian is more curved than the vertical meridian. Therefore, correction of this astigmatism will require the prescription of convex cylindrical lens at  $180^\circ \pm 20^\circ$  or concave cylindrical lens at  $90^\circ \pm 20^\circ$  axis.

**\*\*\*WE HAVE TO MUG THIS UP: A plus at 90 , or minus at 180 accounts for "with the rule astigmatism"\*\*\***

## 151. Morbid fear of darkness known as:

a) Claustrophobia

b) Xenophobia

c) Mysophobia

d) Nyctophobia

Correct Answer - D

Answer. D. Nyctophobia

- **Nyctophobia** is an extreme fear of night or darkness that can cause intense symptoms of anxiety and depression.
- A fear becomes a phobia when it's excessive, irrational, or impacts your day-to-day life.
- **Claustrophobia** is a form of anxiety disorder, in which an irrational fear of having no escape or being closed-in can lead to a panic attack.
- **xenophobia**. : fear and hatred of strangers or foreigners or of anything that is strange or foreign.
- **Mysophobia**, also known as verminophobia, germophobia, germaphobia, bacillophobia and bacteriophobia, is a pathological fear of contamination and germs.

## 152. A child has ptosis and poor levator function. What surgery will you do?

a) Levator muscle resection

b) Mullerectomy

c) Fasanella Servat surgery

d) Frontalis suspension surgery

Correct Answer - D

Answer D. Frontalis suspension surgery

- Muller muscle resections are typically used for repair of minimal ptosis (2 mm) and are generally considered superior to the Fasanella-Servat procedure (tarsconjunctival mullerectomy) in maintaining eyelid contour and preserving the tarsus.
- When levator function is poor, the surgeon should consider utilizing the accessory elevators of the eyelid in ptosis repair. This type of surgery is most commonly required in congenital ptosis with poor levator function or in various forms of neurogenic ptosis with poor levator function.
- Frontalis suspension surgery performed when levator function is poor or absent, the eyelid is suspended directly from the frontalis muscle so that movement of the brow is efficiently transmitted to the eyelid. Thus, the patient is able to elevate the eyelid by using the frontalis muscle to lift the brow. Frontalis suspension can be performed transcutaneously or transconjunctivally. This surgery connects the eyelid to the brow with a sling material and utilizes the power of the frontalis muscle to elevate the poorly functioning eyelid.

**153. Which drug causes ocular hypotension with apnea in an infant?**

a) Latanoprost

b) Timolol

c) Brimonidine

d) Dorzolamide

Correct Answer - C

Answer. C. Brimonidine

- Brimonidine is a relatively selective alpha-agonist, which reduces intraocular pressure (IOP) by decreasing aqueous production and increasing uveoscleral outflow.
- Brimonidine passes through the blood-brain barrier, potentially causing central nervous system (CNS) toxicity.
- There have been reports of bradycardia, hypotension, hypothermia, hypotonia, and apnea in infants after topical brimonidine.

## 154. Chemotherapy agents for retinoblastoma:

a) vincristine ,carboplatin and etoposide

b) vinblastine, etoposide and bleomycin

c) vinblastine , vincristine and etoposide

d) vinblastine , vincristine and cisplatin

Correct Answer - A

Answer. A. Vincristine, carboplatin and etoposide

- Chemotherapy for Retinoblastoma
- Chemotherapy (chemo) is the use of anti-cancer drugs to treat cancer.
- Chemo can be given in different ways to treat retinoblastoma.  
**Some of the chemo drugs used to treat retinoblastoma include:**
  1. Carboplatin
  2. Cisplatin
  3. Vincristine
  4. Etoposide
  5. Cyclophosphamide
  6. Topotecan
  7. Doxorubicin
- Most often, 2 or 3 drugs are given at the same time.
- A standard combination is carboplatin, vincristine, and etoposide, although for very small tumors, only carboplatin and vincristine may be enough.
- Other drugs might be used if these are not effective.

**155. Drug used in acute congestive glaucoma are:**

a) Atropine

b) Pilocarpine

c) Acetazolamide

d) Both B & C

Correct Answer - D

**Answer. D. Both Pilocarpine & Acetazolamide**

**Management of angle closure glaucoma**

- Acute congestive glaucoma also is known as acute angle closure glaucoma.
- Immediate medical therapy in acute AC consists of commencing IOP-lowering eye medications such as topical  $\beta$ -blocker,  $\alpha_2$ -agonist and even prostaglandin analogues as soon as possible.
- Once the IOP is sufficiently reduced to allow iris reperfusion, pilocarpine is instilled to induce miosis in an attempt to widen the anterior chamber angles and reestablish aqueous outflow.
- Mydriatic drugs such as atropine, cyclopentolate, tropicamide and phenylephrine are precipitating factor for angle closure glaucoma, so not used (contraindicated) in its treatment.

**156. Which is the Most common ocular finding in myasthenia gravis?**

a) Ptosis

b) Lagophthalmos

c) Proptosis

d) Enophthalmos

Correct Answer - A

**Answer .A. Ptosis**

**In more than half the people who develop myasthenia gravis, their first signs and symptoms involve eye problems, such as:**

- .. Drooping of one or both eyelids (ptosis).
- ?. Double vision (diplopia), which may be horizontal or vertical, and improves or resolves when one eye is closed.

## 157. Esotropia is usually associated with:

a) Myopia

b) Hypermetropia

c) Astigmatism

d) Presbyopia

Correct Answer - B

Ans. B. Hypermetropia

- Accommodative esotropia is one of the most common types of strabismus in childhood.
- The incidence is estimated at 2% of the population.
- It is usually found in patients with moderate amounts of hyperopia.
- As the patient accommodates or focuses the eyes, the eyes converge.

**158. Which wall of heart enlargement can be seen on barium swallow in patient with mitral stenosis-**

a) Left atrium

b) Right atrium

c) Left ventricle

d) Right ventricle

Correct Answer - D

**Answer. D. Right ventricle**

Mitral stenosis is associated with right ventricular hypertrophy.

Left ventricular diastolic pressure is normal in isolated MS.

**Mitral stenosis** : Features

- left atrial pressure is increased
- pulmonary arterial pressure is increased
- Increased right ventricular afterload impedes the emptying of this chamber and Right ventricular end diastolic pressure and volume increase.
- Right ventricular hypertrophy occurs.

**159. Which of the following statements is true about the bundle of Kent?**

a) Abnormal pathway between two atria

b) It is muscular or nodal pathway between the atria and ventricle in WPW syndrome

c) It is slower than the AV nodal pathway

d) None

Correct Answer - B

**Answer. B. It is muscular or nodal pathway between the atria and ventricle in WPW syndrome**

The Wolff-Parkinson-White syndrome is defined by the combination of an atrioventricular pre-excitation (bundle of Kent) and paroxysmal supraventricular tachycardias. The diagnosis of atrioventricular pre-excitation in sinus rhythm is established on the association between a short PR interval, a wide QRS, a delta wave, a normal terminal QRS portion and frequent repolarization disorders.

## 160. Deep venous thrombosis which is incorrect –

a) Clinical assessment highly reliable

b) Mostly bilateral

c) Most common clinically presents as pain and tenderness in calf

d) Some cases may directly present as pulmonary thromboembolism

Correct Answer - B

**Answer. B. Mostly bilateral**

**Wells score or criteria: (possible score -2 to 9)**

- Active cancer (treatment within last 6 months or palliative): +1 point
- Calf swelling = 3 cm compared to asymptomatic calf (measured 10 cm below tibial tuberosity): +1 point
- Swollen unilateral superficial veins (non-varicose, in symptomatic leg): +1 point
- Unilateral pitting edema (in symptomatic leg): +1 point
- Previous documented DVT: +1 point
- Swelling of entire leg: +1 point
- Localized tenderness along the deep venous system: +1 point
- Paralysis, paresis, or recent cast immobilization of lower extremities: +1 point
- Recently bedridden = 3 days, or major surgery requiring regional or general anesthetic in the past 12 weeks: +1 point
- Alternative diagnosis at least as likely: -2 points

**161. Punched out ulcer in esophagus is seen in**

a) herpes

b) cmv

c) Oesophagitis

d) candida

Correct Answer - C

**Answer. C. Oesophagitis**

It is likely to present with a single, large shallow linear ulcer as opposed to the multiple vesicular/ "punched-out" ulcers seen in herpes esophagitis.

## 162. Type of sensation lost on same side of Brown Sequard syndrome-

a) Pain

b) Touch

c) Proprioception

d) Temperature

Correct Answer - C

### **Answer. C. Proprioception**

Damage to one half of the spinal cord, resulting in paralysis and loss of proprioception on the same (or ipsilateral) side as the injury or lesion, and loss of pain and temperature sensation on the opposite (or contralateral) side as the lesion.

**163. Achondroplasia shows which type inheritance-**

a) XLR

b) XLD

c) Autosomal recessive

d) Autosomal dominant

Correct Answer - D

**Answer. D. Autosomal dominant**

**Achondroplasia is inherited** in an autosomal dominant pattern, which means one copy of the altered gene in each cell is sufficient to cause the disorder.

## 164. MELD score includes

a) Serum creatinine

b) Transaminase

c) Albumin

d) Alkaline phosphatase

Correct Answer - A

### **Answer. A. Serum creatinine**

The Model for End-stage Liver Disease (MELD) is a prospectively developed and validated chronic liver disease severity scoring system that uses a patient's laboratory values for –

Li Serum bilirubin

Serum creatinine

The international normalized ratio (INR) for prothrombin time to predict three month survival.

Patients with cirrhosis, and increasing MELD score is associated with increasing severity of hepatic dysfunction and increased three-month mortality risk.

Given its accuracy in predicting short-term survival among patients with cirrhosis, MELD was adopted by the United network for organ sharing (UNOS) in 2002 for prioritization or patients awaiting liver transplantation in the United states.

**165. Infarcts involving which portion of the myocardium cause aneurysm as a post-MI complication-**

a) Subendocardial

b) Anterior transmural

c) Posterior transmural

d) Inferior wall

Correct Answer - D

**Answer. D. Inferior wall**

**Left ventricular aneurysm formation:**

- Left ventricular apical aneurysm formation usually occurs following antero-apical myocardial infarction, after LAD occlusion.
- This weakening of the apical wall results in an outpouching or “dyskinesis” of the apex of the heart during systole.

## 166. Risk factors for alzheimer's disease include-

a) Klinefelter syndrome

b) Low BP

c) Down's syndrome

d) None

Correct Answer - C

### **Answer. C. Down's syndrome**

People with **Down syndrome** are born with an extra copy of chromosome 21, which carries the APP gene. This gene produces a specific protein called amyloid precursor protein (APP) with age these get accumulated in the brain cell and affects the functioning of the brain leading to alzheimer's dementia.

**167. A female patient of 26 years, presents with oral ulcers, photosensitivity and skin malar rash in face sparing the nasolabial folds of both side.**

a) Sturge weber syndrome

b) SLE

c) Dermatitis

d) Psoriasis

Correct Answer - B

**Answer- B (SLE)**

Common symptoms include painful and swollen joints, fever, chest pain, hair loss, mouth ulcers, swollen lymph nodes, feeling tired, and a red rash which is most commonly on the face.

## 168. Most characteristic cardiovascular defect seen in Rubella-

a) Pulmonary artery stenosis

b) Coarctation of aorta

c) Ankylosis spondylitis

d) Rheumatic fever

Correct Answer - A

**Answer. A. Pulmonary artery stenosis**

**The classic triad for congenital rubella syndrome is:**

- Sensorineural deafness (58% of patients)
- Eye abnormalities? especially retinopathy, cataract, and microphthalmia
- Congenital heart disease? especially pulmonary artery stenosis and patent ductus arteriosus.

**169. Osborn J waves is seen in-**

a) Hypothermia

b) Hyperkalemia

c) Hypocalcemia

d) Hypokalemia

Correct Answer - A

**Answer. A. Hypothermia**

Cause people suffering from hypothermia with a temperature of less than 32°C (90°F).

## 170. Alcoholic shows which type of cardiomyopathy-

a) Hyper cardiomyopathy

b) Dilated cardiomyopathy

c) Pericarditis

d) Myocarditis

Correct Answer - B

**Answer. B. Dilated cardiomyopathy**

Alcoholic cardiomyopathy is a disease in which the chronic long-term abuse of alcohol (i.e., ethanol) leads to heart failure. Alcoholic cardiomyopathy is a type of dilated cardiomyopathy.

## 171. Which is not related to HIV

a) Primary CNS lymphoma

b) Tertiary syphilis

c) Oesophageal candidiasis

d) None

Correct Answer - B

**Answer. B. Tertiary syphilis**

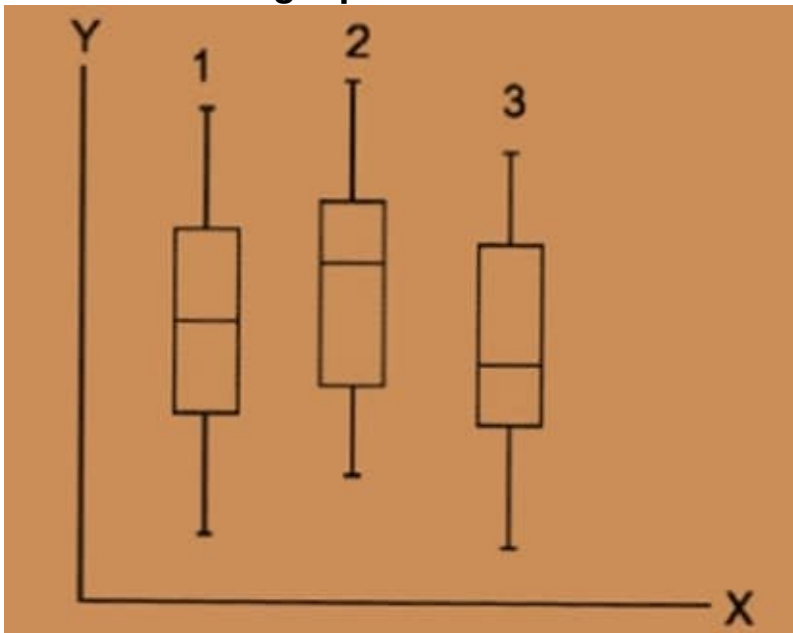
Tertiary Syphilis has no relation to HIV status and primarily based on the duration of the infection and complications of Syphilis.

## 172. Essential major blood culture criteria for infective endocarditis.

- a) Single positive culture of HACEK
- b) Single positive culture of Coxiella
- c) Single positive culture of Corynebacterium
- d) Both a & b

Correct Answer - A

**Answer. A. Single positive culture of HACEK**



### 173. Respiratory centres are stimulated by

a) Oxygen

b) Lactic acid

c) Carbon dioxide

d) Calcium

Correct Answer - C

**Answer. C. Carbon dioxide**

The body's respiratory center in the medulla is normally stimulated by an increased concentration of carbon dioxide, and to a lesser extent, by decreased levels of oxygen in arterial blood. Stimulation of the respiratory center causes an increase in the rate and depth of breathing, thus blowing off excess carbon dioxide and reducing blood acidity.

## 174. Which murmur increases on standing?

a) HOCM

b) MR

c) MS

d) VSD

Correct Answer - A

**Answer. A. HOCM**

Murmur will get softer with Valsalva or standing from squatting because less blood is being ejected through the aortic valve. Rapid squatting from a standing position forces increased venous return and would have the opposite effect of Valsalva or rapid standing.

## 175. Most common indication for liver transplant in children-

a) Biliary atresia

b) Cirrhosis

c) Hepatitis

d) Drug reactions

Correct Answer - A

Answer- A (Biliary atresia)

Indications for liver transplantation in infants and children include acute liver failure (ALF), chronic liver failure with pruritus, complications of cholestasis and failure to thrive. In young children, the most common liver disease leading to transplantation is biliary atresia

## 176. Most common type of gallstone is-

a) Mixed stones

b) Pure cholesterol stones

c) Pigment stones

d) Calcium bilirubinate

Correct Answer - A

### **Answer- A**

Mixed- Between 4% and 20% of stones are mixed.

Pigment- Between 2% and 30% of stones are bilirubin stones.

Cholesterol- Between 35% and 90% of stones are cholesterol stones.

The most common type of gallstones was mixed cholesterol type gallstones with 67.5% followed by black pigment and brown pigment types as 23.83% and 5.89%, respectively.

Mixed stones are 90% common. It contains cholesterol, calcium salts of phosphate carbonate, palmitate, proteins, and are multiple faceted.

## 177. Serpiginous ulcer distal esophagus-

a) CMV

b) Herpes

c) Pill

d) Corrosive

Correct Answer - A

Answer- A (CMV)

CMV classically causes serpiginous ulcers in the distal esophagus that may coalesce to form giant ulcers.

## 178. Omphalocele is caused by?

- a) Duplications of intestinal loops
- b) Abnormal rotation of the intestinal loop
- c) Failure of gut to return to the body cavity from its physiological herniation
- d) Reversed rotation of the intestinal loop

Correct Answer - C

Answer- C (Failure of gut to return to the body cavity from its physiological herniation)

Failure of gut to return to the body cavity from its physiological herniation. Exomphalos(omphalocele) is herniation of abdominal viscera through an enlarged umbilical ring. The viscera, which may include liver, small and large intestines, stomach, spleen, or bladder, are covered by amnion. The origin of omphalocele is a failure of the bowel to return to the body cavity from its physiological herniation during the 6th to 10th weeks.

## 179. Dohlman procedure for-

a) Meckel's diverticulum

b) Zenker's diverticulum

c) Dermatomyositis

d) Menetrier's disease

Correct Answer - B

**Answer- B (Zenker's diverticulum)**

The treatment of pharyngeal pouches (Zenker's Diverticulum) may be by either open surgical or endoscopic techniques. The endoscopic Dohlman's procedure is an ideal technique in the elderly.

**180. If a mother is donating kidney to her son is an example-**

a) Isograft

b) Allograft

c) Autograft

d) Xenograft

Correct Answer - B

Answer- B (Allograft)

Allograft – Grafting between two non-identical member of same species but not same genotypes. It includes the transplantation of heart, kidney, lung etc, from a members who donate their organs.

Anti – rejection drugs or immunosuppressant need to be taken to prevent the body from rejecting a transplanted organ.

Most human tissue and organ transplants are allografts.

**181. Uvula vesicae is produced by which prostate lobe?**

a) Anterior lobe

b) Post lobe

c) Median lobe

d) Lateral lobe

Correct Answer - C

Answer- C (median lobe)

The mucous membrane immediately behind the internal urethral orifice presents a slight elevation, the uvula of urinary bladder, caused by the median lobe of the prostate.

It is often enlarged in benign prostatic hypertrophy.

**182. True about Barrett's esophagus are all of the following except:**

a) Causes adenocarcinoma

b) Patient is usually asymptomatic

c) Histology of the lesion shows mucus secreting goblet cells

d) Chronic gastroesophageal reflux is a predisposing factor

Correct Answer - A

Answer-

Barrett esophagus is a premalignant condition that involves the distal esophagus and appears to be related to chronic gastroesophageal reflux (GORD).

There is metaplastic change in the lining mucosa of esophagus.

- Patient is usually asymptomatic in a case of Barrett's Esophagus.
- Histology of the lesion in a case of Barrett's esophagus shows mucus secreting goblet cells.
- Diagnosis of Barrett's esophagus is made by demonstration of columnar mucosa, which on histopathology shows Intestinal type of metaplasia
- Chronic reflux is a casue of Barrett's Esophagus.

**183. Parathyroid autoimplantation takes place in which of the muscle?**

a) Biceps

b) Triceps

c) Brachioradialis

d) Sartorius

Correct Answer - C

Answer- C (Brachioradialis)

- A total parathyroidectomy with a forearm autograft involves removal of all parathyroid tissue in the neck, with reimplantation of a small amount of morcellated tissue within a pocket formed in the brachioradialis muscle.

**184. Bell's palsy is associated with the lesion in which of the nerve?**

a) 11th cranial nerve

b) 7th cranial nerve

c) 9th cranial nerve

d) 3rd cranial nerve

Correct Answer - B

Answer- B (7th cranial nerve)

Bell's palsy occurs due to a malfunction of the facial nerve (VII cranial nerve), which controls the muscles of the face. Facial palsy is typified by inability to control movement in the muscles of facial expression.

## 185. Cushing ulcer is seen in case of-

a) Burns

b) Head injury

c) Cell necrosis

d) Stress

Correct Answer - B

Answer- B (Head injury)

Cushing ulcers are associated with a brain tumor or head injury and typically are single, deep ulcers that are prone to perforation.

It is a gastric ulcer associated with elevated intracranial pressure. It is also called von Rokitansky–Cushing syndrome.

The mechanism of development of Cushing ulcers is thought to be due to direct stimulation of vagal nuclei as a result of increased intracranial pressure. Brain tumors, traumatic head injury, and other intracranial processes including infections, can cause increased intracranial pressure and lead to overstimulation of the vagus nerve.

## 186. Gasless abdomen seen in-

a) Ulcerative colitis

b) Acute pancreatitis

c) Intussusception

d) Necrotising enterocolitis

Correct Answer - B

**Answer- B (acute pancreatitis)**

**Common causes include:**

- **In adult:**

- High obstruction.

- Ascites.

- Acute pancreatitis due to excess vomiting.

- Fluid filled intestine.

- Large abdominal mass.

**ACUTE PANCREATITIS - radiology signs**

renal halo sign

gasless abdomen

ground glass appearance

colon cut off sign

sentinel loop

## 187. Bidextrous grip is seen at what age?

a) 4 months

b) 5 months

c) 6 months

d) 7 months

Correct Answer - A

**Ans. A. 4 months**

### **FINE MOTOR MILESTONES:**

<b>Age</b>	<b>Milestone</b>
4 months	Bidextrous reach
6 months	Unidextrous reach
9 months	Immature pincer grasp
12 months	Mature pincer grasp
15 months	Imitates scribbling, tower of 2 blocks
18 months	Scribbles, tower of 3 blocks
2 years	Tower of 6 blocks, vertical & circular stroke
3 years	Tower of 9 blocks, copies circle
4 years	Copies cross, bridge with blocks
5 years	Copies triangle

FINE MOTOR MILESTONES

- DR.AKIF A.B



## 188. Which vaccine to be given every year ?

a) Hepatitis A

b) Hepatitis B

c) Influenza

d) Chicken pox

Correct Answer - C

**Ans. C. Influenza**

**Influenza (Flu): The flu vaccine is recommended every year for children 6 months and older:**

- Kids younger than 9 who get the flu vaccine for the first time (or who have only had one dose before July 2017) will get it in two separate doses at least a month apart.
- Those younger than 9 who have had at least two doses of flu vaccine previously (in the same or different seasons) will only need one dose.
- Kids older than 9 only need one dose.
- The vaccine is given by injection with a needle (the flu shot) or by nasal spray. The flu shot is preferred for children of all ages because it has been shown to be safe and effective. Although the nasal spray was not used in recent years, a changed version of it is now recommended (for the 2018–2019 flu season) for kids who may otherwise not get a flu shot. The nasal spray is only for healthy people ages 2 through 49. People with weakened immune systems or some health conditions (such as asthma) and pregnant women should not get the nasal spray vaccine.

## 189. APGAR score 3 at 1 minute indicates:

a) Mildly depressed

b) Further resuscitation not needed

c) Severely depressed

d) Normal

Correct Answer - C

**Ans. C. Severely depressed**

**APGAR CRITERIA:**

	Score of 0	Score of 1	Score of 2	Component of backronym
<b>Skin color</b>	blue or pale all over	blue at extremities body pink (acrocyanosis)	no cyanosis body and extremities pink	Appearance
<b>Pulse rate</b>	absent	< 100 beats per minute	> 100 beats per minute	Pulse
<b>Reflex irritability grimace</b>	no response to stimulation	grimace on suction or aggressive stimulation	cry on stimulation	Grimace
<b>Activity</b>	none	some flexion	flexed arms and legs that resist extension	Activity
<b>Respiratory effort</b>	absent	weak, irregular, gasping	strong, robust cry	Respiration

**INTERPRETATION:**

The test is generally done at 1 and 5 minutes after birth and may be repeated later if the score is and remains low.

- Scores 7 and above are generally normal
- Score 4 to 6, fairly low
- Score:3 and below are generally regarded as critically low and cause for immediate resuscitative efforts.

## 190. Severe acute malnutrition as per WHO criteria-

a) Weight for age less than median plus – 2 SD

b) Weight for height less than median plus 2 SD

c) Weight for age less than median plus 3 SD

d) Weight for height less than median minus -3SD

Correct Answer - D

**Ans. D. Weight for height less than median minus -3SD**

- Severe acute malnutrition is defined by a very low weight for height (below -3z scores of the median WHO growth standards), by visible severe wasting, or by the presence of nutritional oedema.

World Health Organization (WHO) classification of nutritional status of infants and children:

Nutritional status	Age: birth to 5 years
Obese	Weight-for-length/height or BMI-for-age >3 standard deviations (SD) of the median
Overweight	Weight-for-length/height or BMI-for-age >2 SD and ≤3 SD of the median
Moderately underweight	Weight-for-age
Severely underweight	Weight-for-age
Moderate acute malnutrition	Weight-for-length/height or BMI-for-age ≤-2 SD and ≥-3 SD of the median, or mid-upper arm circumference ≥115 mm and
Severe acute malnutrition	Weight-for-length/height or BMI-for-age

Moderately stunted

Moderately stunted (moderate chronic malnutrition)	Length/height-for-age $\leq -2$ SD and $\geq -3$ SD of the median
Severely stunted (severe chronic malnutrition)	Length/height-for-age
Moderately wasted	Weight-for-length/height $\leq -2$ SD and $\geq -3$ SD of the median
Severely wasted	Weight-for-length/height

**191. Where to look for pre-ductal O2 saturation in PDA in a 3 minute born infant?**

a) Fetal left Upper limb

b) Fetal left lower limb

c) Fetal right Upper limb

d) Fetal right lower limb

Correct Answer - C

**Ans. C. Fetal right Upper limb**

A simpler way to detect this right-to-left shunting is to use two pulse oximeters and measure **preductal** and postductal **SpO2**. In one study it was found that arterial saturation in the right arm (**preductal**) of at least 3% above the lower limb (postductal) is evidence of right-to-left ductal shunting.

## 192. True about Fragile X syndrome is-

a) Triple nucleotide CAG Sequence mutation

b) 10% Female carriers mentally retarded

c) Males have IQ 20-40

d) Gain of function mutation

Correct Answer - C

**Ans. C. Males have IQ 20-40**

### **Fragile X Syndrome**

- Fragile X syndrome is associated with a fragile site on chromosome X (Xq 29.3)
- Triple nucleotide CGG Sequence mutation
- About 20% of women who are carriers for the fragile X premutation are affected by fragile X-related primary ovarian insufficiency.
- Individuals with FXS may present anywhere on a continuum from learning disabilities in the context of a normal intelligence quotient (IQ) to severe intellectual disability, with an average IQ of 40 in males who have complete silencing of the FMR1 gene.
- Fragile sites are regions of chromosomes that show a tendency to separation breakage or attenuation under particular growth conditions.

### **Inheritance**

- Inheritance does not follow the usual Mendelian single gene patterns
- It is due to Allelic expansion.

### **Clinical Manifestations :**

**The main clinical manifestations are :**

1. Mental Retardation
- In fact it is the commonest cause of mental retardation in males.
2. Macroorchidism.

3. Characteristic facial appearance with :

- Long face
- Large prominent ears
- Prominent Jaw



## 193. Foot drop is caused by injury to which nerve involvement:

a) Femoral nerve

b) Tibial nerve

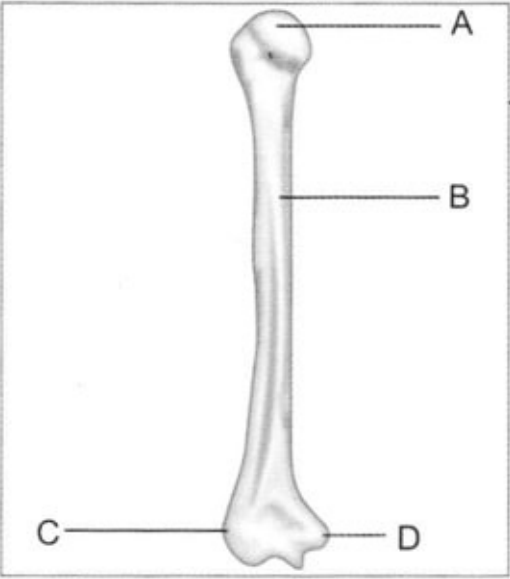
c) Common peroneal nerve

d) Sciatic nerve

Correct Answer - C

### Answer C) Common Peroneal Nerve

- **Foot drop**, sometimes called drop foot, is a general term for difficulty lifting the front part of the foot.
- Causes**
- Foot drop is caused by weakness or paralysis of the muscles involved in lifting the front part of the foot.
- Causes of foot drop might include:**
1. **Nerve injury.** The most common cause of foot drop is compression of a nerve in your leg that controls the muscles involved in lifting the foot (**peroneal nerve**). This nerve can also be injured during hip or knee replacement surgery, which may cause foot drop.
  2. A **nerve root injury** — "pinched nerve" — in the spine can also cause foot drop. People who have diabetes are more susceptible to nerve disorders, which are associated with foot drop.
  3. **Muscle or nerve disorders.** Various forms of muscular dystrophy, an inherited disease that causes progressive muscle weakness, can contribute to foot drop. So can other disorders, such as polio or Charcot-Marie-Tooth disease.
  4. **Brain and spinal cord disorders.** Disorders that affect the spinal cord or brain — such as amyotrophic lateral sclerosis (ALS), multiple sclerosis or stroke — may cause foot drop.



**194.**

## Which part of scaphoid fracture is most susceptible to avascular necrosis?

a) Distal 1/3rd

b) Middle 1/3rd

c) Proximal 1/3rd

d) Scaphoid Tubercle

Correct Answer - C

### Answer. C. Proximal 1/3rd

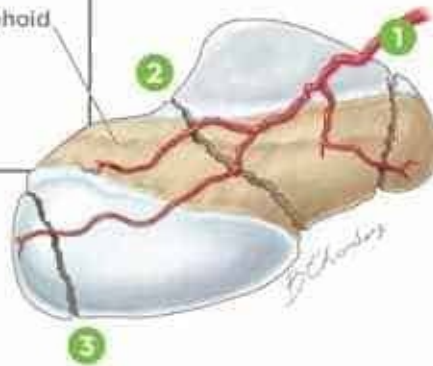
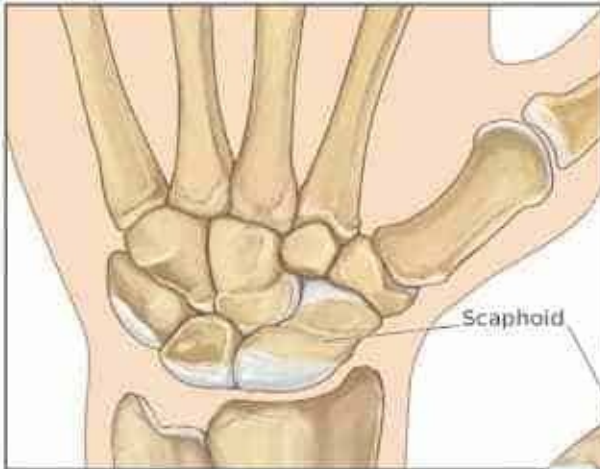- Scaphoid fractures (i.e. fractures through the [scaphoid bone](#)) are common, in some instances can be difficult to diagnose, and can result in significant functional impairment.

### Epidemiology

- Scaphoid fractures account for 70-80% of all carpal bone fractures.
- Although they occur essentially at any age, adolescents and young adults are most commonly affected.
- Older patients falling in a similar manner are more likely to sustain a [distal radial fracture](#) (usually a [Colles fracture](#)).

### Clinical Presentation

- Classically there can be pain in anatomical snuffbox which is thought to have a sensitivity of ~90% and a specificity ~40%
- Fractures can occur essentially anywhere along the scaphoid, but distribution is not even:
  - .. waist of scaphoid: 70-80%
  - ?. proximal pole: 20%
  - }. distal pole (or so-called scaphoid tubercle): 10%



### Classification of scaphoid fractures

- 1 Distal fracture
- 2 Waist fracture
- 3 Proximal fracture

Illustrations Copyright 2018 Regents of the University of Colorado.  
All rights reserved. Illustrations created by Bernson Chikody.

## 195. Pott's puffy tumor:

a) Subperiosteal abscess of frontal bone

b) Subperiosteal abscess of ethmoid bone

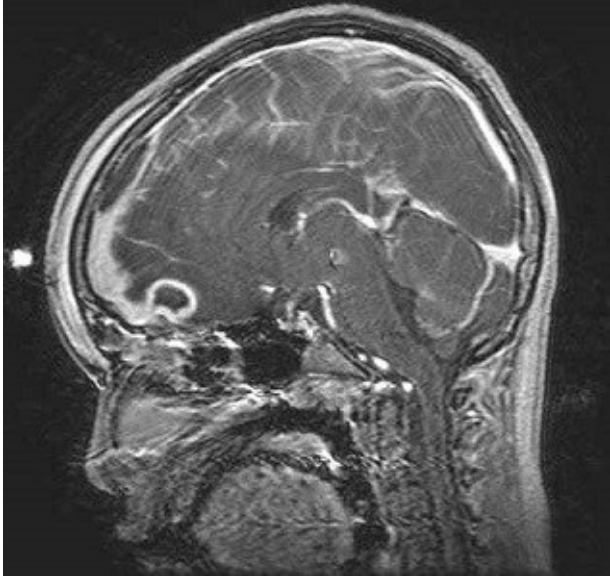c) Mucocele of frontal bone

d) Mucocele of ethmoid bone

Correct Answer - A

### **Answer. A. Subperiosteal abscess of frontal bone**

- Pott's puffy tumor, first described by Sir Percivall Pott in 1760, is a rare clinical entity characterized by **subperiosteal abscess** associated with osteomyelitis.
- It is characterized by an **osteomyelitis of the frontal bone**, either direct or through haematogenous spread.
- This results in a swelling on the forehead, hence the name.
- The infection can also spread inwards, leading to an intracranial abscess.
- Pott's puffy tumor can be associated with cortical vein thrombosis, epidural abscess, subdural empyema, and brain abscess.



**196. Scissor gait is seen in which of the following condition:**

a) Polio

b) Cerebral palsy

c) Hyperbilirubinemia

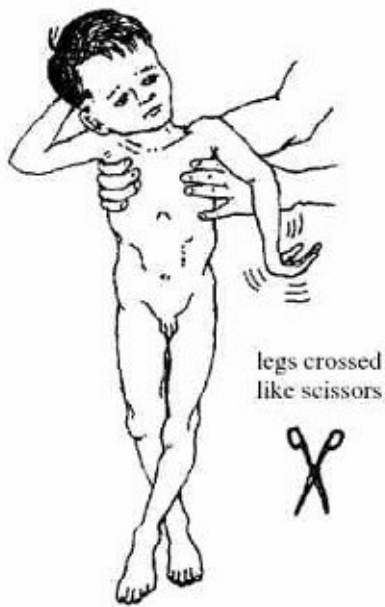
d) Hyponatremia

Correct Answer - B

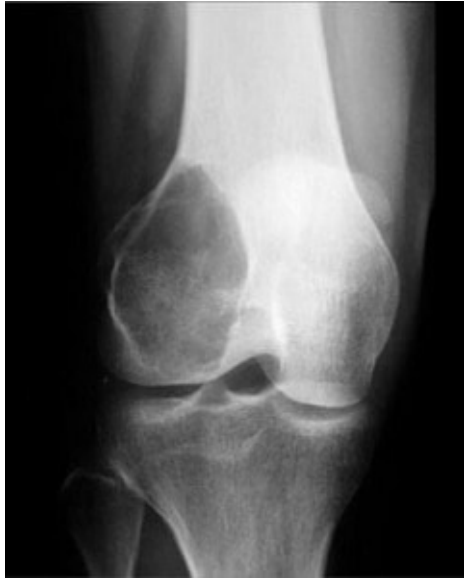**Answer. B. Cerebral palsy**

- Scissor gait is a form of gait abnormality primarily associated with spastic cerebral palsy.
- That condition and others like it are associated with an upper motor neuron lesion.

The Spastic Child (Cerebral Palsy)



**197. Which statement is incorrect about the pathology shown in the image:**



a) Tumor arise from epiphyseal to metaphyseal region

b) Tumor has distinct margin

c) Eccentric lesion

d) Chemotherapy is the treatment of choice

Correct Answer - D

**Answer. D. Chemotherapy is the treatment of choice**

**Given image is of Giant cell tumor**

- **Giant cell tumors of bone**, also known as **osteoclastomas**, are relatively common bone tumors and are usually benign.
- They typically arise from the **metaphysis of long bones**, **extend into the epiphysis adjacent to the joint surface**, and have a narrow zone of transition.

**Classic appearance**

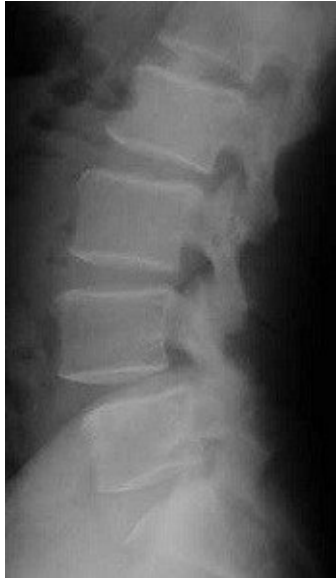There are four characteristic radiographic features when a giant cell tumor is located in a long bone:

- occurs only with a closed growth plate
- abuts articular surface: 84-99% come within 1 cm of the articular surface 1
- **well-defined with non-sclerotic margin**(though
- eccentric: if large this may be difficult to assess

#### **Treatment**

- Classically, treatment is with curettage and packing with bone chips or polymethylmethacrylate (PMMA).

**198. What should be the most likely diagnosis of this 65 year old lady presents with backache and following radiograph of the spine shown in image?**



a) Osteoporosis

b) Spondylolisthesis

c) Spondylolysis

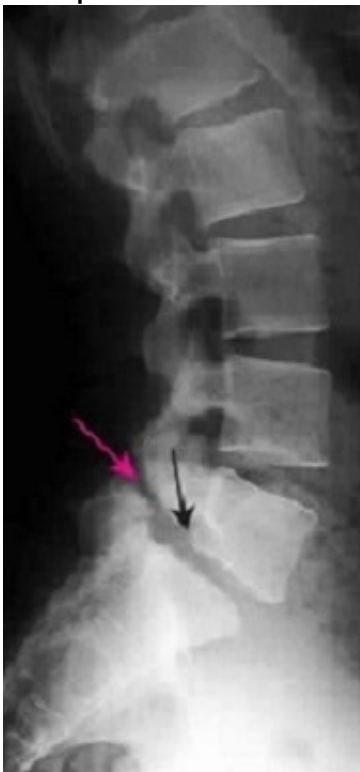d) Discitis

Correct Answer - B

**Answer. B. Spondylolisthesis**

- Spondylolisthesis is subluxation of lumbar vertebrae, usually occurring during adolescence.
- It usually results from a congenital defect in the pars interarticularis (spondylolysis).

- Spondylolisthesis is usually fixed (ie, permanent and limited in degree). It usually involves the L3-L4, L4-L5, or L5-S1 vertebrae.
- Spondylolisthesis often occurs in adolescents or young adults who are athletes and who have had only minimal trauma; the cause is a lumbar vertebra weakened by a congenital defect in the pars interarticularis (spondylolysis).
- This defect can easily lead to fractures; separation of the fracture fragments causes the subluxation. Spondylolisthesis can also occur with minimal trauma in patients who are > 60 and have osteoarthritis.
- If mild to moderate (subluxation of = 50%), spondylolisthesis, particularly in the young, may cause little or no pain.
- Spondylolisthesis can predispose to later development of spinal stenosis.
- If due to major trauma, spondylolisthesis can cause spinal cord compression or other neurologic deficits; these deficits rarely occur.



**[This x-ray shows stage 1 spondylolisthesis of L5 on S1. The black arrow shows the posterior border of L5, which subluxes anterior to S1. The red arrow points to the spondylolysis (congenital defect in the pars interarticularis).]**

Spondylolisthesis is staged according to the percentage of vertebral body length that one vertebra subluxes over the adjacent vertebra:

- Stage I: 0 to 25%
- Stage II: 25 to 50%
- Stage III: 50 to 75%
- Stage IV: 75 to 100%

Spondylolisthesis is evident on plain lumbar x-rays. The lateral view is usually used for staging. Flexion and extension views may be done to check for instability.

#### **Treatment**

- Usually symptomatic.
- Physical therapy with lumbar stabilization exercises may be helpful.

**199.** Which of the following attitude will be seen in a patient with posterior dislocation of hip?

a) Flexion, Abduction, Internal rotation

b) Flexion, Adduction, Internal rotation

c) Flexion, Abduction, External rotation

d) Flexion, Adduction, External rotation

**Correct Answer - B**

Dislocations are usually posterior, and occasionally anterior, or central through the acetabulum.

**Posterior dislocation:** Hip is flexed, adducted, and internally rotated, and leg is shortened.

**Anterior dislocation:** Hip is flexed, abducted, and externally rotated, and leg is shortened.

**Central dislocation:** Trochanter is displaced medially. One may be able to feel the head of femur rectally. There is no shortening.

## 200. True about Tenosynovitis of finger ?

- a) Fingers held in mild extension / Extension deformity at the involved fingers.
- b) Tenosynovitis of little finger will spread to thumb rather than ring finger.
- c) With involvement of little finger the infection can spread to the index finger.
- d) Treatment is conservative.

Correct Answer - B

Ans. B. Tenosynovitis of little finger will spread to thumb rather than ring finger

- Infection of the synovial sheath that surrounds the flexor tendon
- Infection from the flexor tendon sheath of the thumb can also extend along the radial bursa to the space of Parona and then into the ulnar bursa and the flexor tendon sheath of the little finger—and vice versa—leading to a “horseshoe” abscess.

**Horseshoe abscess:**

- May develop from spread pyogenic flexor tenosynovitis, of many individuals have a connection between the sheaths of the thumb and little fingers at the level of the wrist

## 201. Most common joint involved in septic arthritis:

a) Knee

b) Hip

c) Shoulder

d) Elbow

Correct Answer - A

**Answer. A. Knee**

**Septic arthritis (Acute suppurative arthritis)**

- Septic arthritis refers to pyogenic infection of a joint, i.e., infection of a joint by pyogenic organism (bacteria).
- The joint can become infected by : –
  1. Hematogenous spread from a distant site (most common route).
  2. Direct invasion through a penetrating wound, intra articular injection, arthroscopy.
  3. Direct spread from adjacent osteomyelitis especially in joints where Metaphysis is intra articular e.g., hip and shoulder.

**Clinical features**

- Disease is more common in children.
- **Knee joint is the most commonly affected joint.**
- Other joint which are affected are hip, shoulder and elbow. The child is toxic with fever, tachycardia, tachypnea.
- There is severe pain, swelling, and redness over the joint. Movements are severely restricted and the joint is held in the position of ease. Weight bearing on limb is not possible.

## 202. Painful arc syndrome pain is felt during ?

a) Mid abduction

b) Initial abduction

c) Full range of abduction

d) Overhead abduction

Correct Answer - A

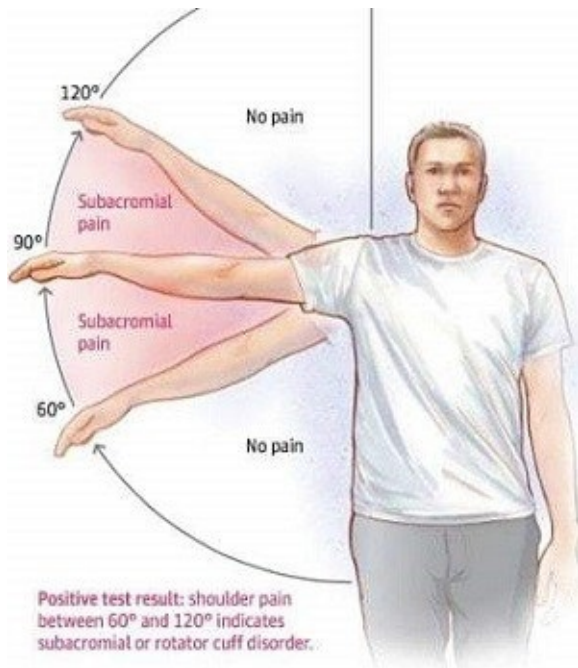
**Answer. A. Mid abduction**

**PAINFUL ARC SYNDROME**

Other Names

- **Impingement syndrome**
- **Supraspinatus syndrome**
- **Swimmer's syndrome**
- **Thrower's shoulder**

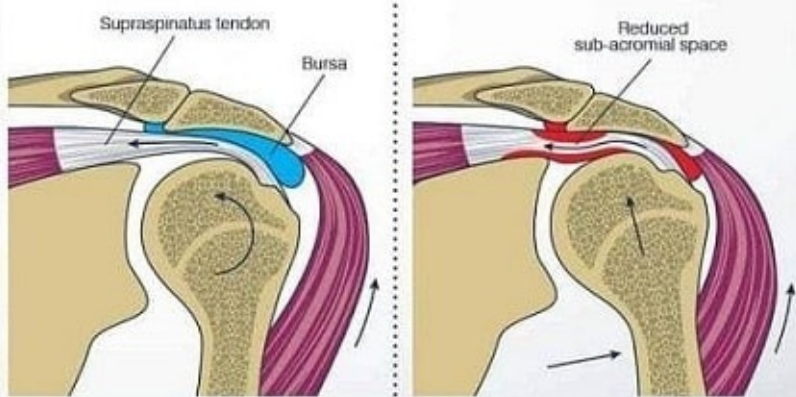
Clinical syndrome characterized by pain in the shoulder during an arc of movement between **60° and 120° of abduction.**



### **Etiology:**

1. Minor tears of the supraspinatus tendon
2. Supraspinatus tendinitis
3. Calcification of supraspinatus tendon
4. Subacromial bursitis
5. Fracture of the greater tuberosity
6. Increase in bulk of the contents in the subacromial space, seen in inflammation of the rotator cuff

### **SHOULDER IMPINGEMENT SYNDROME**



**203. Which of the following is false as physiological change in pregnancy?**

a) Increase cardiac output

b) Increase total protein

c) Increase residual volume

d) Increase GFR

Correct Answer - C

**Ans. C. Increase residual volume**

- The respiratory rate is essentially unchanged, but tidal volume and resting minute ventilation increase significantly as pregnancy advances.
- The functional residual capacity and the residual volume are decreased as a consequence of the elevated diaphragm.

**204. Overt gestational diabetes is defined as blood glucose more than\_?**

a) >200 mg/dl

b) >126 mg/dl

c) >100 mg/dl

d) >180 mg/dl

Correct Answer - B

**Ans. B. >126 mg/dl**

If fasting is 92-125 mg/dl it is diagnosed as GDM and if it is = 126 mg/dl it is designated as overt Diabetes

## 205. MgSO<sub>4</sub> have no role in prevention of-

a) Seizures in severe pre-eclampsia

b) Recurrent seizures in eclampsia

c) RDS in premature baby

d) Bradycardia

Correct Answer - C

**Ans. C. RDS in premature baby**

- Indicated to prevent seizures associated with pre-eclampsia, and for control of seizures with eclampsia.
- Magnesium sulfate (MgSO<sub>4</sub>) is commonly used as an anticonvulsant for toxemia and as a tocolytic agent for premature labor during the last half of pregnancy.
- Toxicity of I/V magnesium sulfate includes cardiac arrhythmias, muscular paralysis, respiratory depression and CNS depression in mother as well as the neonate.

**206. Green frothy vaginal discharge is produced by –**

a) Herpes simplex

b) Candida albicans

c) Trichomonas vaginalis

d) Normal vaginal flora

Correct Answer - C

**Ans. C. Trichomonas vaginalis**

**Trichomoniasis –**

- It is a sexually transmitted disease
- It is almost entirely a disease of child-bearing age
- The vaginal discharge is frothy, slightly green in colour and profuse.
- There are multiple punctate strawberry spots on the vaginal vault and portio vaginalis of cervix. Diagnosis : Culture is 98% reliable

**207. Which of the following is an absolute  
CONTRAINDICATION to OCP use:**

a) Chronic renal disease

b) DVT

c) Diabetes mellitus

d) History of amenorrhea

Correct Answer - B

**Ans. B. DVT**

**Contraindications to combined oral contraceptives**

- They are generally accepted to be contraindicated in women with pre-existing cardiovascular disease, in women who have a familial tendency to form blood clots/ thrombosis (such as familial factor V Leiden), women with severe obesity and/or hypercholesterolemia (high cholesterol level), and in smokers over age 40.
- COCP are also contraindicated for women with liver tumors, hepatic adenoma or severe cirrhosis of the liver, and for those with known or suspected breast cancer.

**208. Which of the following statement is correct about acute fatty liver of pregnancy?**

a) Occurs in 1 in 1000 pregnancy

b) Mostly seen in last trimester

c) Common if female fetus is present

d) May be associated with decreased uric acid

Correct Answer - B

**Ans. B. Mostly seen in last trimester**

- Acute fatty liver of pregnancy is usually seen in obese woman.
- It is more commonly seen in woman carrying a male foetus.
- The neonate is at risk of fatty infiltration of liver.
- It More commonly occurs in 3rd trimester.
- It May be associated with ?uric acid.

**209. Female with 41 wk gestation confirmed by radiological investigation, very sure of her LMP, no uterine contractions, no effacement and no dilatation. What should not be done?**

a) Intracervical foley's

b) PGE1 tab

c) PGE2 gel

d) PGF2alpha

Correct Answer - D

**Ans. D. PGF2alpha**

PgF2 alpha is a uterine relaxant so it can't be used in induction of labour.

## 210. Double decidua sign is seen during-

a) 1<sup>st</sup> trimester

b) 2<sup>nd</sup> early trimester

c) 2<sup>nd</sup> late trimester

d) 3<sup>rd</sup> trimester

Correct Answer - A

**Ans. A. 1<sup>st</sup> trimester**

- The double decidual sac sign (DDSS) is a useful feature on early pregnancy ultrasound to confirm an early intrauterine pregnancy (IUP) when the yolk sac or embryo is still not visualized.
- The “Double Decidual Sign”, first described by Nyberg and co-workers consists of two echogenic rings surrounding the hypoechoic gestational sac.
- The inner ring represents the chorion, embryonic disc and decidua capsularis.
- The outer ring represents the decidua parietalis.

**211. 60 year woman comes with 3rd degree uterine prolapse. What will be the management?**

a) Vaginal hysterectomy with pelvic floor repair

b) Pelvic floor repair

c) Sacrospinous fixation

d) Pessary

Correct Answer - A

**Ans. A. Vaginal hysterectomy with pelvic floor repair**

Uterine prolapse surgery is performed to remove the uterus and repair the weak tissue. Uterine prolapse frequently occurs in postmenopausal women who've had one or more vaginal deliveries.

**Sagging of the pelvic muscles which leads to uterine prolapse can occur:**

- If supportive tissues are damaged during pregnancy and delivery
- Due to estrogen loss
- As a result of straining repeatedly over the years (chronic cough, constipation etc.)
- Due to gravitational effects
- Depending on factors like age of the woman, desire for becoming pregnant and the overall state of a woman's health, the treatment plan is decided.
- Here the woman is of old age (non gestational) and have 3rd degree of prolapse. So best management of choice will be Vaginal hysterectomy with pelvic floor repair.

## 212. Day 20 of menstrual cycle falls under which phase?

a) Menstrual phase

b) Follicular phase

c) Ovulation phase

d) Luteal phase

Correct Answer - D

**Ans. D. Luteal phase**

**The entire duration of a Menstrual cycle can be divided into four main phases:**

1. Menstrual phase (From day 1 to 5)
2. Follicular phase (From day 1 to 13)
3. Ovulation phase (Day 14)
4. Luteal phase (From day 15 to 28)

## 213. Chromosome number of partial hydatidiform mole is-

a) 46 XX

b) 45 XO

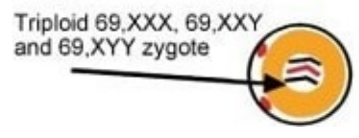
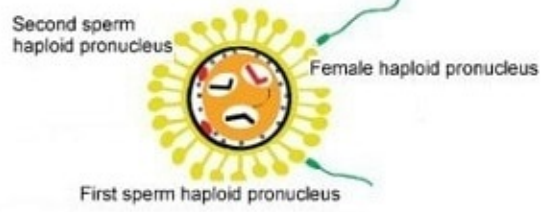
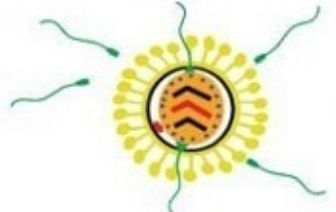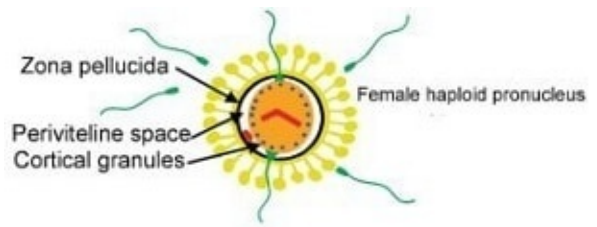
c) 46 XXY

d) 69 XXX

Correct Answer - D

**Ans. D. 69XX**

- A partial hydatidiform mole is a triploid pregnancy with 69 instead of 46 chromosomes and another strange complication of the reproductive process.
- Partial hydatidiform mole can be identified by ultrasound showing placenta tissue, some hygromatous cysts, some fetal oddities, but no clear fetus structure.
- Ultrasound is strictly an indicator. After spontaneous abortion or dilation and curettage, tissue needs to be examined by pathology and cytogenetics needs to be determined.
- If a triploid karyotype is determined as 69, XXX, 69XXY, or 69 XYY [6], then a partial mole can be confirmed.



## 214. Vulvar atrophy and itching are treated by-

a) Estrogen ointment

b) Antihistamines

c) Tamoxifen

d) None

Correct Answer - A

### **Ans. A. Estrogens ointment**

- Atrophic vaginitis, the medical term for this condition, occurs as a result of deterioration of the vaginal tissue.
- It's a common condition in postmenopausal women because as estrogen levels drop, the tissue that lines the vagina becomes thinner and more easily damaged.
- Women with atrophic vaginitis may also experience vaginal itching, burning, frequent urination, or vaginal discharge.
- Women can treat this condition topically with estrogen creams, tablets (Vagifem), or an estrogen-releasing ring placed in the vagina (Estring).
- Oral estrogen, available with a doctor's prescription, will also restore vaginal tissue.
- Vaginal lubricants offer an alternative for women wary of using estrogen.
- Moisturizers such as Replens, Astroglide, and Lubrin can reduce symptoms and make sexual intercourse more comfortable.

**215. Premature ejaculation is a part of which phase of sexual disorders?**

a) Excitement phase

b) Plateau phase

c) Orgasm phase

d) Refractory phase

Correct Answer - C

**Ans. C. Orgasm phase**

- The male sexual response is described as a sequence of phases including 4 stages: sexual desire, arousal, orgasm (ejaculation) and resolution.

**The male sexual dysfunction usually occurs in one or more of the three first stages of the sexual response cycle, including:**

- Dysfunctions of sexual desire (e.g. hypoactive sexual desire)
- Arousal (e.g. erectile dysfunction)
- Orgasm/ejaculation (e.g. premature ejaculation, retarded ejaculation or inability to ejaculate).
- Premature ejaculation occurs due to the rapid evolution of the two first stages of the sexual response cycle and is not necessarily related to strong sexual arousal or changes in erection.
- Premature Ejaculation seems to be a neurobiological problem that is related to low serotonin levels in those regions of the central nervous system that regulate ejaculation (brain and spinal cord).

**216. Nuchal translucency in USG can be detected at \_\_\_\_\_ weeks of gestation.**

a) 11-13 weeks

b) 18-20 weeks

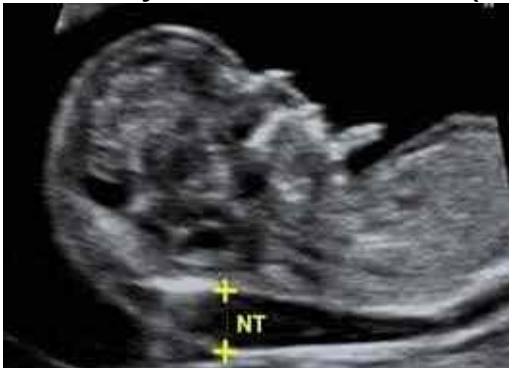c) 8-10 weeks

d) 20-22 weeks

Correct Answer - A

**Ans. A. 11-13 weeks**

Nuchal translucency is the normal fluid-filled subcutaneous space identified at the back of the fetal neck during the late first trimester and early second trimester (11.3-13.6 weeks).



## 217. First line of treatment of mastitis in a lactating mother is-

a) Dicloxacillin

b) Cefazolin

c) Ceftriaxone

d) Ampicillin

Correct Answer - A

**Ans. A. Dicloxacillin**

- The beta lactamase-resistant penicillins have been recommended in the treatment of mastitis. These include cloxacillin, dicloxacillin, or flucloxacillin.
- Because penicillins are acidic, they are poorly concentrated in human milk, which is also acid.
- Therefore, cloxacillin and its congeners tend to treat cellulitis well, but they are less effective in eradicating adenitis, the most likely precursor of breast abscess.
- When patients are allergic to penicillins, cephalixin or clindamycin may be the alternative to erythromycin.
- Combination like co-amoxiclav should be avoided because of fear of inducing MRSA

**218. Patient with recurrent abortion diagnosed to have antiphospholipid syndrome. What will be the treatment?**

a) Aspirin only

b) Aspirin + Low molecular weight Heparin

c) Aspirin + Low molecular weight Heparin + Prednisolone

d) No Treatment

Correct Answer - B

**Ans. B. Aspirin + Low molecular weight Heparin**

- The recommended treatment for women with recurrent pregnancy loss associated with antiphospholipid syndrome includes combined Aspirin and Heparin therapy.
- In pregnant SLE patients with Antiphospholipid antibodies and prior fetal loss, treatment with heparin (standard or low –molecular-weight) plus low dose aspirin has been shown in prospective controlled trials to increase significantly the proportion of live births.
- Combined aspirin and heparin therapy has proven effectiveness and is the preferred treatment for women with recurrent pregnancy loss associated with antiphospholipid syndrome.

## 219. Gestational Trophoblastic neoplasm does not include-

a) Choriocarcinoma

b) Placental site trophoblastic tumour

c) Invasive mole

d) Partial mole

Correct Answer - D

**Ans. D. Partial Mole**

**The main types of gestational trophoblastic diseases are:**

- Hydatidiform mole (complete or partial)
- Invasive mole
- Choriocarcinoma
- Placental-site trophoblastic tumor
- Epithelioid trophoblastic tumor

**Note:** In the given best option best answer can be partial as partial hydatidiform mole is not completely mentioned in it.

**220. Which vaccine is contraindicated in pregnancy:**

a) Chicken pox

b) Rabies

c) Tet toxoid

d) Hepatitis B

Correct Answer - A

**Ans. A. Chicken pox**

As a rule of thumb the vaccination with live viral or bacterial vaccine is contraindicated in pregnancy.

**The important ones are : –**

- Measles
- Mumps
- Poliomyelitis
- Rubella
- Yellow fever
- Varicella
- BCG

**221. 45 years female with 3 months menorrhagia. USG showing 2 cm submucosal fibroid. Treatment options.**

a) Ocp for 3 months

b) Progesterone for 3 months

c) Endometrial sampling

d) Hysterectomy

Correct Answer - D

**Ans. D. Hysterectomy**

**YOUNG WOMEN**

Contraception desired  
 Contraception not desirable

- Combined OCPs
- Progestogens and other hormones
- Mirena

Progestogens  
 Ethamsylate,  
 NSAIDs  
 Estrogen  
 Tranexamic for  
 3–4 months  
 GnRH 3–4  
 months

Effective  
 Minimal  
 invasive  
 Continue surgery  
 for 6–9  
 months  
 Hysterectomy  
 with  
 conservation  
 of ovaries

**OLDER WOMEN**

Rule out cancer & uterine pathology

Normal uterus (DUB)  
 Uterine pathology  
 Progestogens and others  
 ?No response  
 Hysterectomy with removal of ovaries after 50 years  
 Surgery

- Removal of an intrauterine contraceptive device if medical therapy fails.
- Myomectomy/hysterectomy for uterine fibroids.

- Wedge resection/hysterectomy for adenomyosis of the uterus.
- Dilatation and curettage with blood transfusion is the primary treatment of puberty menorrhagia with low Hb%
- Multipara, hypertensive woman with menorrhagia should be treated with MIRENA
- Hysterectomy with or without removal of the adnexa according to the age and the individual needs of the patient.

**222. In low ovarian reserve, anti mullerian hormone level will be:**

a) <1

b) 1-4

c) >7

d) >10

Correct Answer - A

**Ans. A. <1**

**AMH and ovarian reserve**

- AMH of 1.0 has very poor ovarian reserve
- The central concept for the measurement of blood levels of AMH to determine ovarian reserve is this: women with lower AMH levels have a lower ovarian reserve than women with high AMH levels. AMH is currently being used by fertility specialists to help predict women who may respond poorly to fertility medications and in general, couples who are less likely to be successful with fertility treatment.

## 223. Presenting diameter of full flexed head:

a) Suboccipito-bregmatic diameter

b) Suboccipito-frontal diameter

c) Occipito-frontal diameter

d) Occipito-posterior position

Correct Answer - A

**Ans. A. Suboccipito-bregmatic diameter**

**Suboccipito-bregmatic diameter :**

- The diameter is from suboccipital region to centre of the bregma.
- Diameter = 9.5 cm
- Fetal head circumference is smallest (32 cm )
- Head well flexed
- Flexed vertex presentation

**Suboccipito-frontal diameter :**

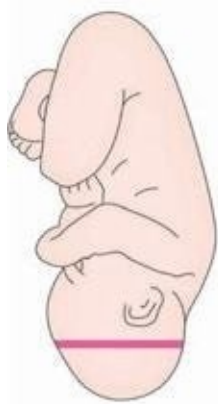- Diameter calculated from prominence at mid frontal bone to the under-surface of the occipital bone where it joins neck
- The diameter is 10.5 cm
- Vertex is partially deflexed.
- Results in occipito-posterior position.

**Occipito-frontal diameter :**

- Diameter extends from the prominent point of mid-frontal bone to the most prominent point of occipital bone
- The diameter = 11.5 cm
- Fetal head circumference ~ 34.5 cm
- Vertex is deflexed
- Associated with Direct occipito- posterior position.

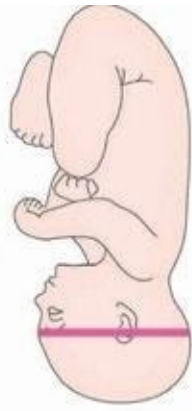**Occipito-posterior position :**

- It is a vertex presentation in which the occiput is placed posteriorly .



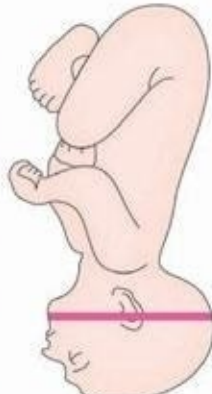Vertex

Suboccipitobregmatic



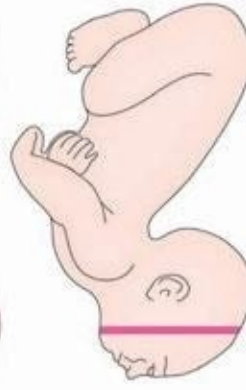Sinciput

Suboccipitofrontal



Brow

Mentovertical



Face

Submentobregmatic

## 224. What is the dose of ulipristal acetate?

a) 300mg

b) 30mg

c) 300 $\mu$ g

d) 30 $\mu$ g

Correct Answer - B

**Ans. B. 30 mg**

- Ulipristal (Ella) is a progesterone agonist/antagonist marketed for emergency contraception. It is available by prescription only. Its mechanism of action varies based on time of administration. When taken before ovulation, ulipristal delays or inhibits ovulation.
- Administration in the early luteal phase may decrease endometrial thickness and affect implantation of a fertilized egg.
- Ulipristal is labeled for use as an emergency contraceptive following unprotected sexual intercourse or contraceptive failure.
- One tablet(30-mg tablet) taken as soon as possible, within 120 hours (five days) of unprotected sexual intercourse or contraceptive failure.

**225. The major contribution of the amniotic fluid after 20 weeks of gestation :**

a) Ultrafiltrate and maternal plasma

b) Fetal urine

c) Fetal lung fluid

d) Fetal skin

Correct Answer - B

**Ans. B. Fetal urine**

- There are two primary sources of amniotic fluid: fetal urine and the lung liquid.
- After about 20 weeks, fetal urine makes up most of the fluid.

**226. PGF2 alpha maximum dose in PPH is-**

a) 2000 µg

b) 200 µg

c) 2 mg

d) 20 mg

Correct Answer - C

**Ans. C. 2mg**

**Drug doses for management of PPH:**

**15-Methyl prostaglandin F2a:**

- Dose and route:IM: 0.25 mg
- Continuing dose:0.25 mg every 15 minutes
- Maximum dose:8 doses (Total 2 mg)
- Precautions/ contraindications:Asthma

## 227. All are true about skin except:

a) Both dermis & ectoderm are derived from ectoderm

b) Skin accounts for total of 15% of body weight

c) Most of the cells in skin are keratinocytes derived from ectoderm

d) Dermis is made up of type 1 and type 3 collagen in 3:2 ratio

Correct Answer - A

Ans: A. Both dermis & ectoderm are derived from ectoderm.

- True fact: Dermis derived from mesoderm and epidermis from ectoderm.

## 228. Anaesthetic gas with maximum respiratory irritation

a) Halothane

b) Enflurane

c) Desflurane

d) Sevoflurane

Correct Answer - C

**Ans:C. Desflurane**

Desflurane and isofurane when used for induction cause respiratory irritation due to their pungent smell leading to breath holding and coughing.

Halothane and sevoflurane do not cause such effects.

**229. IV administration of which anesthetic drug is most painful among the following?**

a) Methohexital

b) Ketamine

c) Propofol

d) Etomidate

Correct Answer - C

**Ans: c. Propofol**

**Propofol preparation:**

- **Oil-based** preparation (**soybean oil, egg lecithin & glycerol**).
- Hence, **pain on injection** & rarely thrombophlebitis.

**230. Which of the following is not cardiodepressive?**

a) Propofol

b) Thiopentone

c) Ketamine

d) Etomidate

Correct Answer - D

Ans:D. Etomidate

**Major advantage of etomidate:**

- Cardiovascular stability after induction.

**Effects of etomidate induction dose:**

- Negligible increase in heart rate.
- Little decrease in blood pressure/cardiac output.
- Little effect on coronary perfusion pressure, while reducing myocardial O<sub>2</sub> consumption.

**231. Which of the following is the most common method used to know depth of anaesthesia?**

a) BIS

b) Oesophageal contractility

c) Depressed responses

d) Hypotension

Correct Answer - A

Ans:A. BIS

**Bispectral index:**

\* 1st scientifically validated & commercially available monitor to check depth of anaesthesia.

\* Utilizes many parameters (EEG signals, eye blinks) to calculate depth score.

**Adequate depth:**

\* Score of 45-60.

**Fully awake state:**

\* Score of 100

**Completely silent brain: 0.**

## 232. MRP 2 associated with which of the following?

a) Rotor syndrome

b) Dubin-Johnson syndrome

c) Crigler-Najjar syndrome

d) Gilbert syndrome

Correct Answer - B

Ans:B. Dubin-Johnson syndrome.

### **Dubin-Johnson syndrome:**

- An autosomal recessive disorder.
- Caused by gene mutation responsible for human canalicular multispecific organic anion transporter (cMOAT) protein/ also referred "multidrug resistance protein 2 (MRP2)" or ABCC2.

**233. Which of the following is water soluble contrast?**

a) Barium

b) Iodine

c) Bromium

d) Calcium

Correct Answer - B

Answer-B. Iodine

Radiocontrast agents are typically iodine, barium-sulphate or gadolinium based compounds.

## 234. Solitary lytic lesions seen in

a) Atherosclerosis

b) Multiple myeloma

c) Mitral stenosis

d) Osteoblast

Correct Answer - B

**Answer- B. Multiple myeloma**

F: fibrous dysplasia (FD) or fibrous cortical defect (FCD)

O: osteoblastoma

G: giant cell tumor (GCT)

M: metastasis(es)/myeloma

A: aneurysmal bone cyst (ABC)

C: chondroblastoma or chondromyxoid fibroma

H: hyperparathyroidism (brown tumor)

I: infection (osteomyelitis)

N: non-ossifying fibroma (NOF)

E: enchondroma or eosinophilic granuloma (EG)

S: simple (unicameral) bone cyst

**235. Not true about somnambulism among the following is?**

a) Sleep walking.

b) Patient consciousness is preserved.

c) Disorder of sleep arousal.

d) Low level motor skill/function is present

Correct Answer - D

**Ans: D. Low level motor skill/function is present.**

**Sleep walking (somnambulism):**

- The patients may carry out a range of activities for which he doesn't have any memory later on.
- It may include leaving the bed and walking about and also activities like dressing, moving around or even driving.

## 236. Confusion assessment scale used for which of the following?

a) Schizophrenia

b) Delirium

c) Dementia

d) Depression

Correct Answer - B

Ans: B. Delirium

- Confusion Assessment Method (CAM), a widely-used instrument and diagnostic algorithm for identification of delirium.

**The CAM instrument assesses the presence, severity, and fluctuation of 9 delirium features:**

- Acute onset
- Inattention
- Disorganized thinking
- Altered level of consciousness
- Disorientation
- Memory impairment
- Perceptual disturbances
- Psychomotor agitation or retardation
- Altered sleep-wake cycle.

**The CAM diagnostic algorithm is based on four cardinal features of delirium:**

- Acute onset and fluctuating course
- Inattention
- Disorganized thinking
- Altered level of consciousness.

## 237. Which of the following is the poor prognostic factor for OCD?

a) Magical thinking

b) Dirt contamination

c) Pathological doubt

d) Hoarding

Correct Answer - B

**Ans: B. Dirt contamination.**

**OCD - Clinical features & symptoms:**

- **Contamination** – Most common obsession.
- Obsession of contamination → compulsive avoiding of contaminated objects → excessive cleaning --> inability to leave their homes (due to germs fear, shame & disgust from feces, urine, dust & germs).
- **Pathological doubt** – 2nd most common.
- **Obsession of doubt** → compulsive checking → most danger of violence → forgetting to turn off the stove, or not locking the door, some patient can travel back home several times.
- **Obsession of self-doubt** → feeling guilty about issues
- **Intrusive thoughts** – 3rd most common.
- **Intrusive obsessional thoughts without compulsion** (repetitive sexual or aggressive acts, patients obsessed of their thoughts, may think that they suppose to report them to the police or to make a confession to the priest .
- Symmetry – 4th most common.
- Need for symmetry of precision → compulsion of slowness, patient can take an hour to eat a meal or shave their faces.

**238. Test based on the principle of suspect's reaction, if he witnesses an event then he behaves in a certain way is?**

a) Narcoanalysis

b) Brain mapping

c) Truth serum testing

d) Polygraph

Correct Answer - D  
Ans:D. Polygraph

**239. Intense depression & misery without any cause is?**

a) Melancholia

b) Major depressive disorder

c) Mania

d) Schizophrenia

Correct Answer - A  
Ans:A. Melancholia

**240. Which of the following is not true regarding delusional disorder?**

a) Held with absolute conviction

b) Usually false

c) Not amenable to reasoning

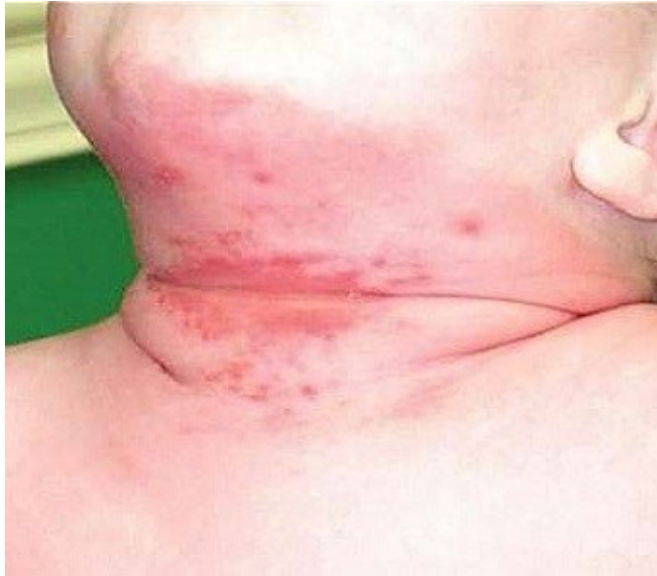d) Occurs at early age

Correct Answer - D

Ans:D. Occurs at early age.

- Delusional disorder may account for 1–2% of admissions to inpatient psychiatric hospitals.
- Age at onset ranges from 18–90 years, with a mean age of 40 years

**241. Identify the condition shown in the image below.**



a) Intertrigo

b) Heat rash

c) Eczema

d) Impetigo

Correct Answer - A

**Ans. A. Intertrigo**

Image shows Intertrigo rash on the back of a 4 month old baby's neck.

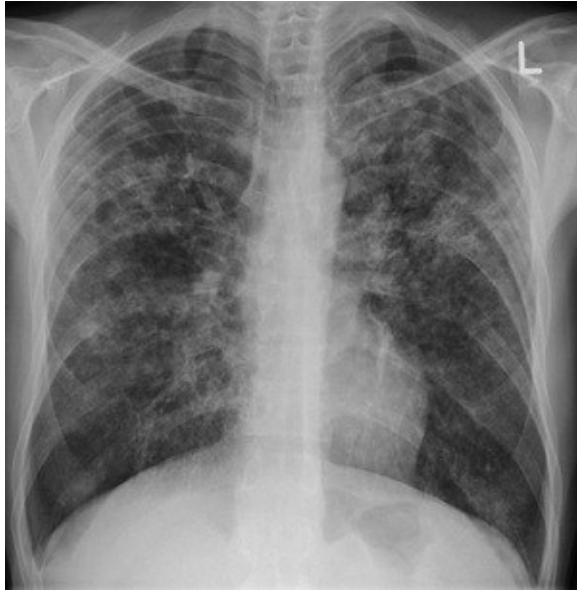Intertrigo is caused by warm moist folds of skin repeatedly rubbing together.

The affected area may become blistered or infected with bacteria or fungi.

Intertrigo is a common condition in babies and is treated with nappy

cream and keeping the affected area clean and dry.

**242. Identify the infection from the chest X-ray of a patient with low-grade fever?**



a) ILD

b) Bronchopneumonia

c) Miliary TB

d) Consolidation

Correct Answer - C

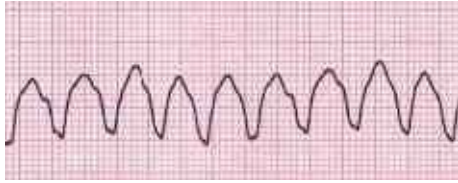
Answer-C. Military TB

- Miliary tuberculosis is due to hematogenous dissemination of tubercle bacilli.
- This is due to the hematogenous spread of infection and may be seen in both primary and post-primary disease.
- At first, the chest radiograph may be normal but then small, discrete nodules, 1-2 mm in diameter, become apparent, evenly distributed throughout both lungs. These may enlarge and coalesce but with

adequate treatment, they slowly resolve.

- Dense opacities occur with calcification and metallic dust disease

**243. Identify the condition given in the image?**



a) Atrial fibrillar

b) Atrial flutter

c) Ventricular tachycardia

d) SVT

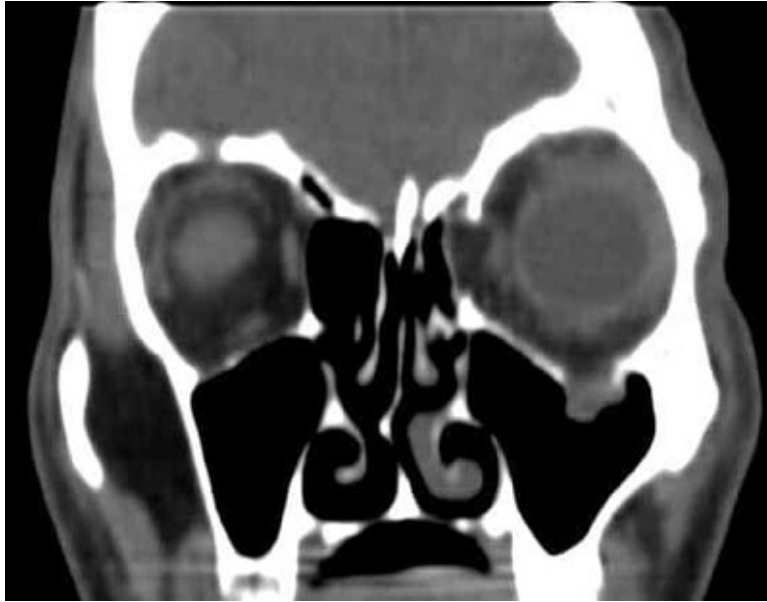Correct Answer - C

**Answer- C (Ventricular tachycardia)**

**Monomorphic VT**

- Regular rhythm.
- Originates from a single focus within the ventricles.
- Produces uniform QRS complexes within each lead — each QRS is identical (except for fusion/capture beats).

**244. A patient presented with history of diplopia and restricted eye movements. A clinical image and CT image is shown below. What will be the diagnosis?**



a) Le- fort fracture

b) Fracture maxilla

c) Fracture zygomatic

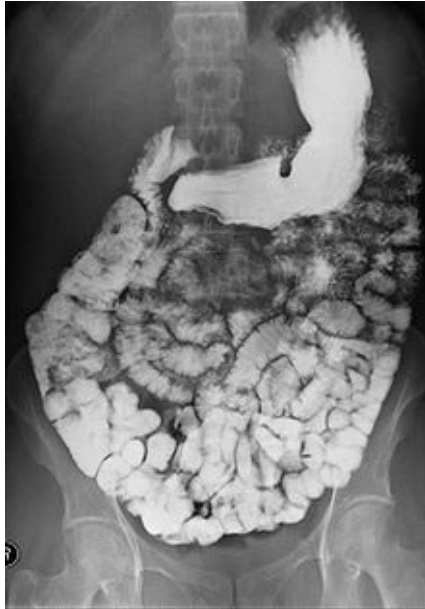d) Blow out fracture

Correct Answer - D

Answer- D (Blow out fracture)

An orbital blowout fracture is a traumatic deformity of the orbital floor or medial wall, typically resulting from impact of a blunt object larger than the orbital aperture, or eye socket.

**245. Identify the radiological procedure shown below?**



a) Barium meal follow through

b) Barium enema

c) Enteroclysis

d) Proctography

Correct Answer - A

Answer- A (Barium meal follow-through)

\* A small bowel follow-through is a single contrast study (oral contrast, either barium or water-soluble contrast).

\* It is often performed after an upper GI fluoroscopy study, as the contrast column moves from the stomach and duodenum to the small bowel.

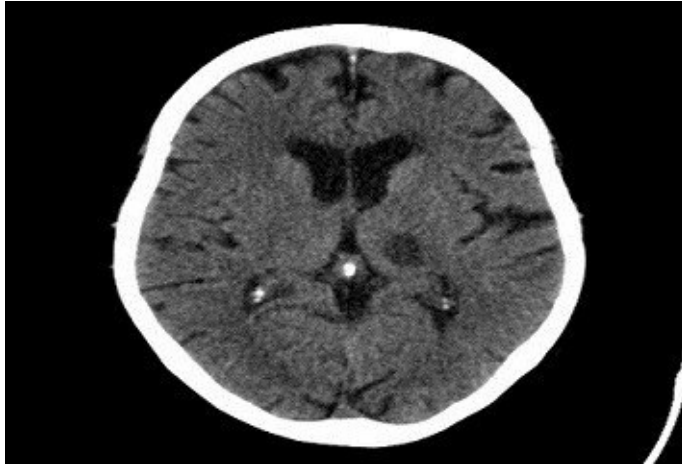
\* Most small bowel contrast examinations performed as a part of an

upper GI series- barium meal and follow-through.

\* The small bowel follow-through can be useful for evaluation of:

- strictures
- obstruction
- diverticula
- masses
- extraluminal tethering
- abnormal motility

**246. Identify the condition in the below image?**



a) Lacunar infarct

b) Embolic infarct

c) Thrombotic infarct

d) Intracerebral hemorrhage

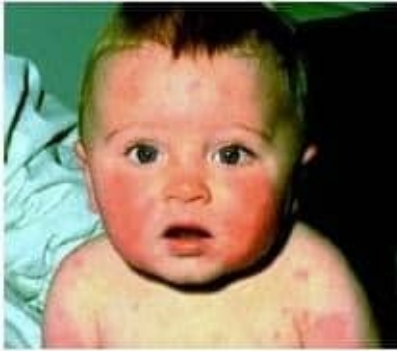Correct Answer - A

Answer-A. Lacunar infarct

- This image shows a CT scan of a lacunar infarct.
- Occlusion of a larger perforating vessel causes a lacunar infarct.
- Acutely, lacunar infarcts are often rounded with a hazy outline and may fluctuate in size in the subacute phase— most often enlarging.
- When mature, however, they become sharply delineated, shrink in size—typically less than 1.5 cm diameter—and cavity-like.
- The gliotic hyperintense rim of a mature lacune on FLAIR differentiates it from a perivascular space.
- IOC for Hyperacute Infarct → MRI[best sequence –DWI]
- Acute/hyperacute infarcts show restricted diffusion



**247. A child with history of fever, photosensitivity, rash sparing nasolabial fold presents to OP. Identify the condition?**



a) SLE

b) Polymorphous light eruption

c) Discoid lupus

d) Skin tuberculosis

Correct Answer - A

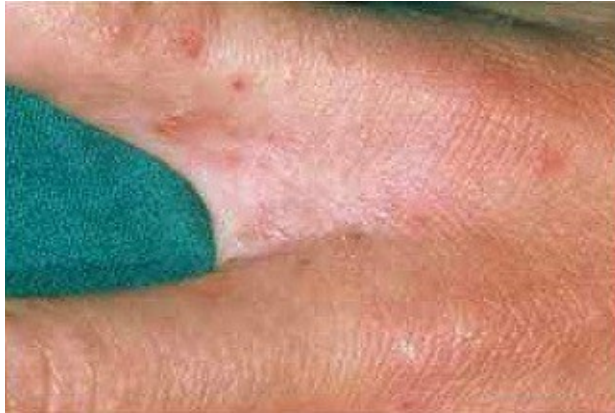**Ans:A. SLE.**

**Clinical presentation:**

- **Most common rash is photosensitive, raised erythematous malar rash.**
- **55-85% develop at some point in disease**
- **Discoid Lupus Erythematosus (DLE): 15-30% circular, scaly hyperpigmented lesions with erythematous rim, atrophic center —can be disfiguring**
- Mouth/vaginal/nasal ulcers
- Alopecia: may be diffuse or patchy. Occurs 50%.

---

**248. Patient presents with purities of inter digits of left hand as shown in the image. Identify the condition?**



a) *Sarcoptes scabiei*

b) Dermatitis herpetiformis

c) Xerotic dermatitis

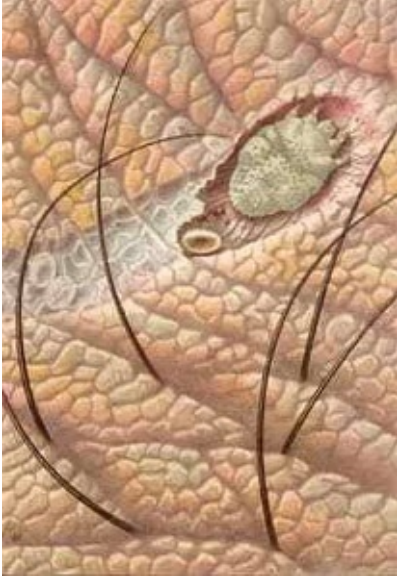
d) Erythema multiforme

Correct Answer - A

Ans:A. *Sarcoptes scabiei*

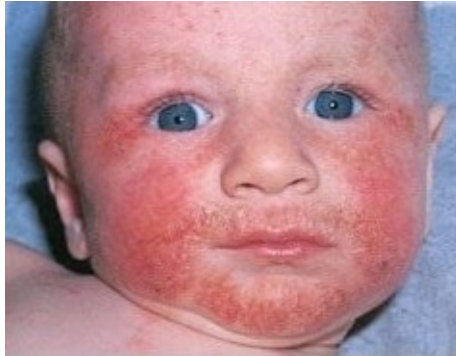- Scabies is an intensely pruritic skin condition caused by infestation with the microscopic mite *Sarcoptes scabiei*.
- *Sarcoptes scabiei* var *hominis*, and is transmitted from person to person by skin-to-skin contact.

***Sarcoptes scabiei* mite:**



- Burrowed into the epidermis, the mite, its feces and ova laid by females seem to cause the irritation that leads to itching and secondary infection from scratching.
- Scabies like warm places, such as skin folds, between the fingers, under fingernails, or around the buttock or breast creases. They can also hide under watch straps, bracelets or rings.

**249. Identify the condition. This is child with asthmatic mother.**



a) Atopic dermatitis

b) SLE

c) Erythema

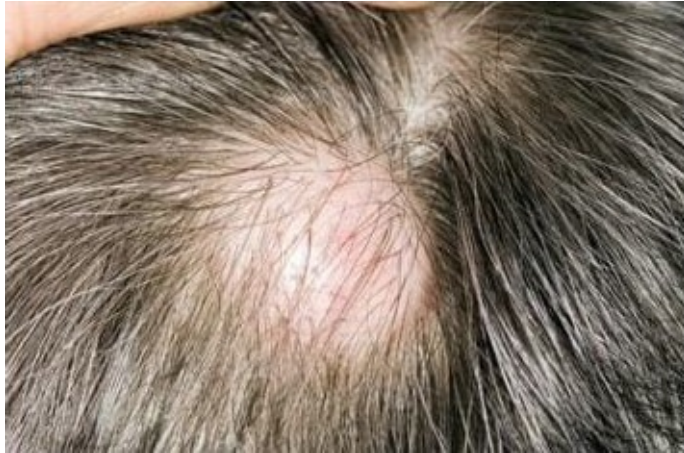d) TEN

Correct Answer - A

Ans:A. Atopic dermatitis

- Atopic dermatitis (eczema) is a type of inflammation of the skin (dermatitis) resulting in itchy, red, swollen, and cracked skin.
- Also known as “atopic eczema”.
- Long lasting (chronic) & tends to flare periodically.
- Common in children (can occur at any age).
- Usually starts in infancy or early childhood.
- Children with family history of atopic dermatitis, asthma or hay fever are more likely to develop atopic dermatitis.

**250. Identify the condition shown in the image?**



a) Sebaceous cyst

b) Alopecia areata

c) Trichotillomania

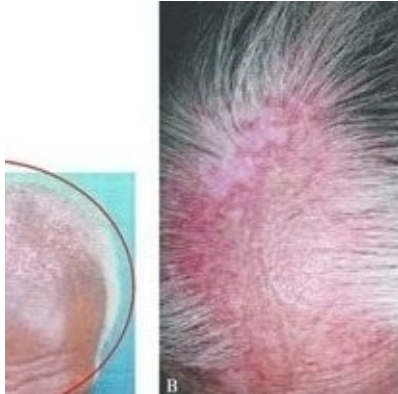d) Tinea capitis

Correct Answer - B

Ans: B. Alopecia areata

- Alopecia areata is an autoimmune disorder characterized by transient, non-scarring hair loss and preservation of the hair follicle.
- Hair loss can take many forms ranging from loss in well-defined patches to diffuse or total hair loss, which can affect all hair bearing sites.
- Patchy alopecia affecting the scalp is the most common type.

## 251. Identify the condition in the image?



a) Leukoderma

b) Piebaldism

c) Vitiligo

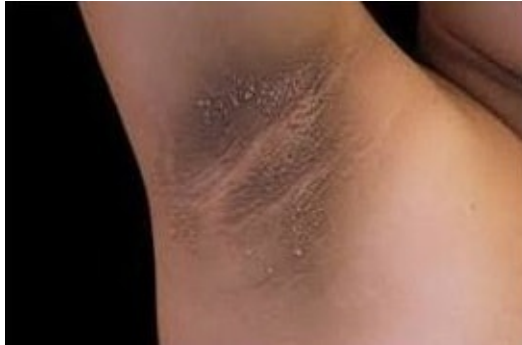d) DLE

Correct Answer - A

Ans:A. Leukoderma

- Leukoderma is a skin disease that causes loss of skin pigmentation (melanin) that leads to skin whitening.
- The white patches on the skin are termed as leukoderma.
- When the condition gets severe, the spots cover almost all parts of the body including scalp, face and the genitals.

**252. Which of the following regarding the condition depicted in the image?**



a) May be an indication of skin malignancy

b) Hypopigmentation

c) May be associated with Insulin resistant diabetes mellitus

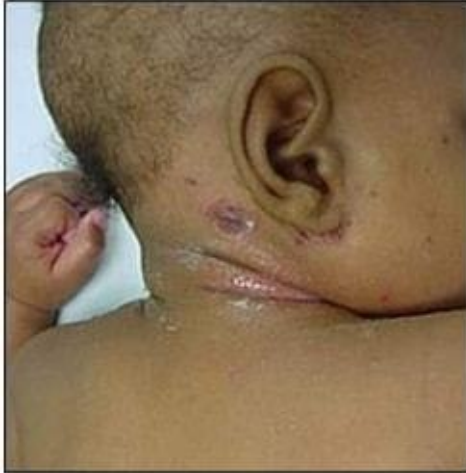d) Commonly occurs in lean and thin.

Correct Answer - C

Ans:C. May be associated with Insulin resistant diabetes mellitus

- Acanthosis nigricans is associated with obesity and insulin resistance in majority of the patients.
- Acanthosis is diffuse epidermal hyperplasia (thickening of the skin).
- Implies increased thickness of the Malpighian layer (stratum basale and stratum spinosum).
- Occurs primarily in flexural areas as velvety hyperpigmentation.
- Commonly seen in axilla.
- May be a reflection of endocrinopathy such as acromegaly, cushing's syndrome, polycystic ovarian syndrome & GIT malignancy.

**253. The causative organism for the condition depicted in image is?**



a) Staphylococci

b) Candidal infection

c) Streptococcus

d) Actinomycetes

Correct Answer - A

Ans:A. Staphylococcus.

**Impetigo:**

- Lesions of common or superficial impetigo may contain group A  $\beta$ -hemolytic streptococci, S aureus, or both.
- Most common skin infection in children.
- Highly contagious.

**Lesions in bullous (staphylococcal) impetigo:**

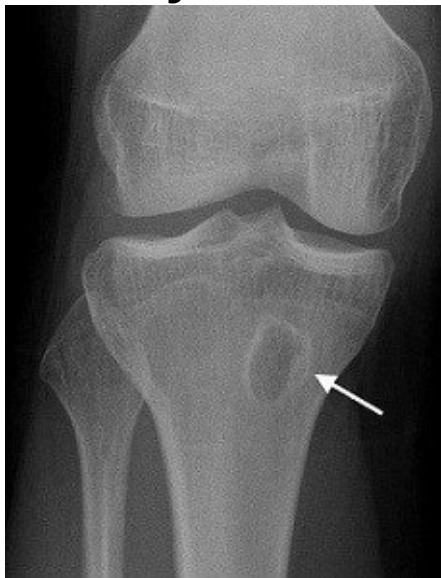- Caused by S aureus.
- Are superficial, thin-walled & bullous.
- On ruptures --> results in thin, transparent, varnish-like crust

appears.

**Distinguished from stuck-on crust of common impetigo.**

- Is distinctive appearance of bullous impetigo.
- Due to local action of epidermolytic toxin (exfoliation).

254. Identify the condition as shown:



a) Brodie abscess

b) Osteoid osteoma

c) Intracortical hemangioma

d) Chondromyxoid fibroma

Correct Answer - A

**Answer. A. Brodie abscess**

- Brodie abscess is an intraosseous **abscess** related to a focus of **subacute pyogenic osteomyelitis**.
- Unfortunately, there is no reliable way radiographically to exclude a focus of osteomyelitis.
- It has a protean radiographic appearance and can occur at any location and in a patient of any age.
- It might or might not be expansile, have a sclerotic or nonsclerotic border, or have associated **periostitis**.

## **Epidemiology**

- Typically these present in children with unfused epiphyseal plates, more frequently in boys.

## **Location**

It has a predilection for ends (metaphysis) of tubular bones:

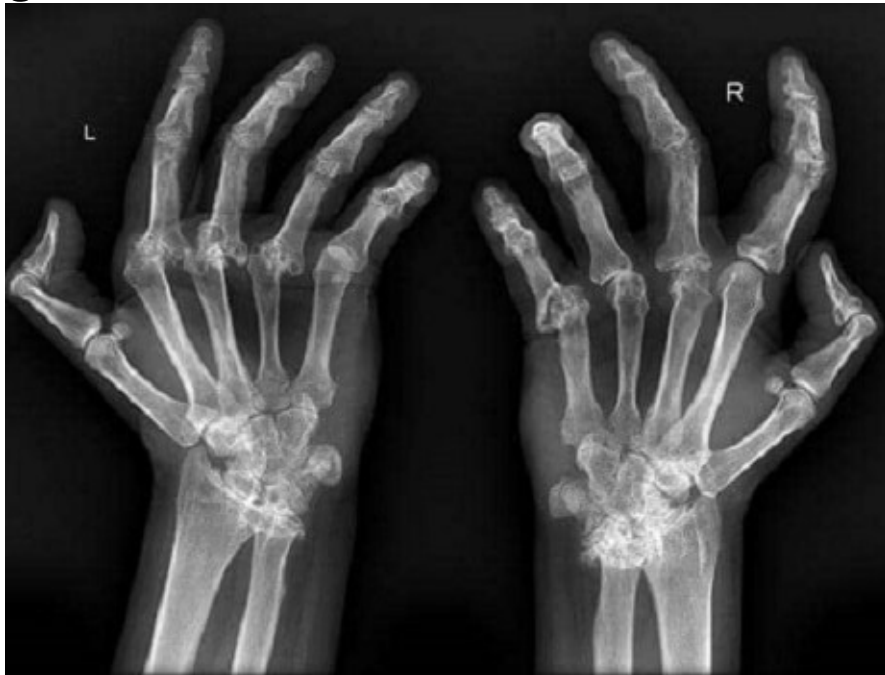1. **proximal/distal tibial metaphysis (most common)**
2. carpal and tarsal bones
3. Rarely traversing the open growth plate; epiphysis (in children and infants).

## **Radiographic features**

### **Plain radiograph**

- lytic lesion often in an oval configuration that is oriented along the long axis of the bone
- **surrounded by a thick dense rim of reactive sclerosis that fades imperceptibly into surrounding bone**
- lucent tortuous channel extending toward growth plate prior to physeal closure (pathognomonic)
- periosteal new-bone formation +/- adjacent soft-tissue swelling

**255. 14 yr old child with Naive Rheumatoid Arthritis patient as shown in image .  
What should be the correct treatment of given condition:**



a) DMARD with short course of Steroids

b) Only NSAID'S

c) DMARD after initial 3 months of NSAID'S

d) Monotherapy with TNF drugs

Correct Answer - A  
Monotherapy with TNF drugs  
Answer A. DMARD with Steroids  
Given condition is Rheumatoid Arthritis

- Rheumatoid arthritis (RA) is a chronic autoimmune multisystemic inflammatory disease which affects many organs but predominantly attacks the synovial tissues and joints.

**Clinical features:**

- It occurs between the age of 20 to 50 years.
- Women are affected about 3 times more commonly than men.

**Following presentations are common:**

**a) An acute, symmetrical polyarthritis:**

- Pain and stiffness in multiple joints (at least four)
- Symptoms of articular inflammation.
- The joints affected most commonly are the metacarpo- phalangeal joints, particularly that of the index finger.

**Other joints affected commonly are (given in Table):**

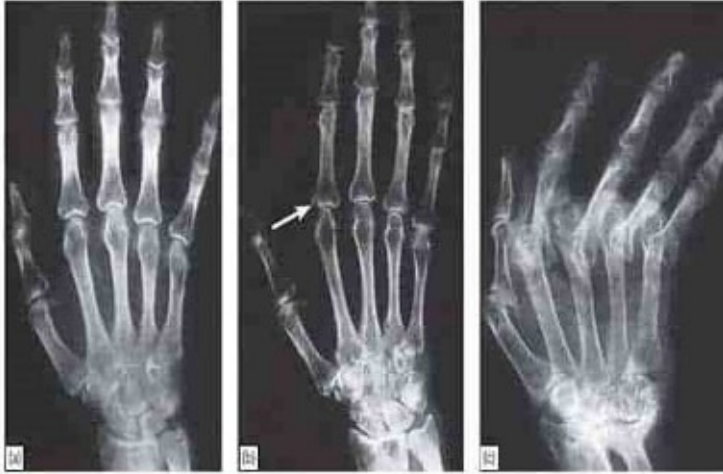Common	<ul style="list-style-type: none"> <li>• MP joints of hand</li> <li>• PIP joints of fingers</li> <li>• Wrists, knees, elbows, ankles</li> </ul>
Less common	<ul style="list-style-type: none"> <li>• Hip joint</li> <li>• Temporomandibular joint</li> </ul>
Uncommon	<ul style="list-style-type: none"> <li>• Atlantoaxial joint</li> <li>• Facet joints of cervical spine</li> </ul>

**On examination:**

- Swollen boggy joints as a result of intra-articular effusion, synovial hypertrophy and oedema of the periarticular structures.
- The joints may be deformed.

**Deformities in Rheumatoid arthritis**

Hand	<ul style="list-style-type: none"> <li>• Ulnar drift of the hand</li> <li>• Boutonniere deformity</li> <li>• Swan neck deformity</li> </ul>
Elbow	<ul style="list-style-type: none"> <li>• Flexion deformity</li> </ul>
Knee	<ul style="list-style-type: none"> <li>• Early – flexion deformity</li> <li>• Late – triple* subluxation</li> </ul>
Ankle	<ul style="list-style-type: none"> <li>• Equinus deformity</li> </ul>
Foot	<ul style="list-style-type: none"> <li>• Hallux valgus, Hammer toe, etc.</li> </ul>

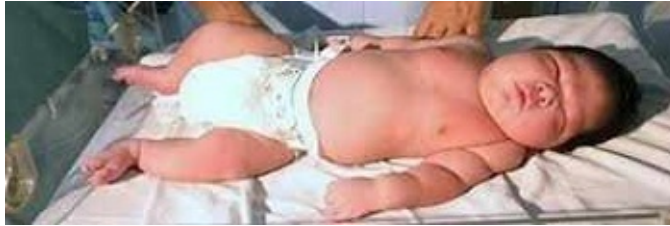

3.3 Rheumatoid arthritis – x-ray changes The progress of disease is well shown in this patient's x-rays. First there was only soft-tissue swelling and periarticular osteoporosis; later juxta-articular erosions appeared (arrow); ultimately the joints became unstable and deformed.

### **Treatment and prognosis**

- Treatment of RA is aimed at improving the symptoms and slowing disease progression.
- Therapy is with a combination of corticosteroids, non-steroidal anti-inflammatory drugs (NSAIDs), disease modifying anti-rheumatic drugs (DMARDs), and TNF antagonists (e.g. etanercept).

**256. In 34 weeks gestation the weight of baby was 3kg. The child shows following features may indicate associated condition –**



a) Anemia

b) Diabetes

c) APH

d) None

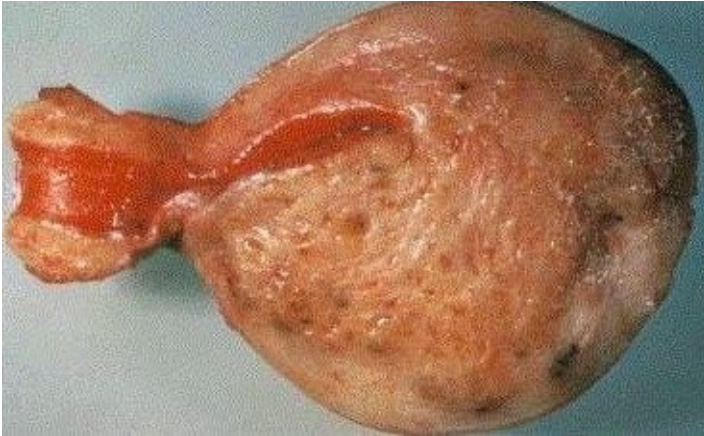
Correct Answer - B

**Ans. B. Diabetes**

- Macrosomia is the term used to describe a large fetus.
- Macrosomia is associated with Gestational diabetes and Maternal obesity
- The recommended definition is fetal (neonatal) weight exceeding two standard deviations or above 90th centile for the appropriate normal population.
- According to ACOG : birth weight of > 4500gm is called as macrosomia.
- In Indian context Birth weight of > 4000 gm is called as macrosomia.

**257.**

**30 year old woman with complaint of dysmenorrhoea, dyspareunia with chronic pelvic pain undergoes hysterectomy. From the cut section of hysterectomy specimen below identify the condition.**



a) Adenomyosis

b) Fibroids

c) Leiomyoma

d) Endometriosis

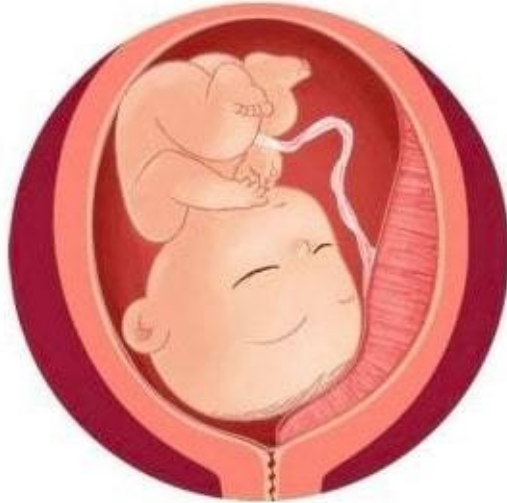Correct Answer - A

**Ans. A. Adenomyosis**

- Cross section through the wall of a hysterectomy specimen of a 30-year-old woman who reported chronic pelvic pain and abnormal uterine bleeding. The endometrial surface is at the top of the image, and the serosa is at the bottom.
- Adenomyosis is where the tissue from the lining of womb penetrates into the muscle.

- Adenomyosis can be diffuse or focal. the ultimate management of adenomyosis is hysterectomy.

**258. Identify the type of placenta praevia as shown in the picture below ?**



a) I.

b) II.

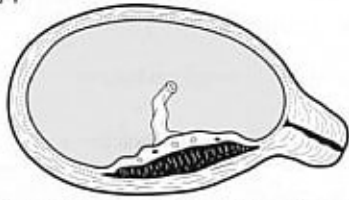
c) III.

d) IV.

Correct Answer - B

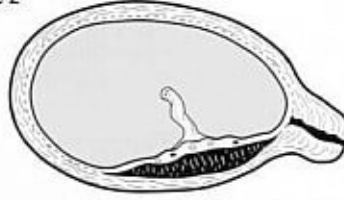
**Ans. B. II**

Type 1



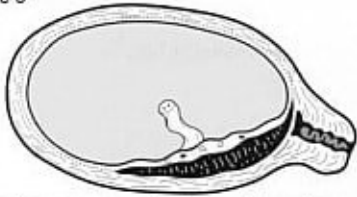
The lower margin of the placenta dips into the lower segment. ('Low implantation'.)

Type 2



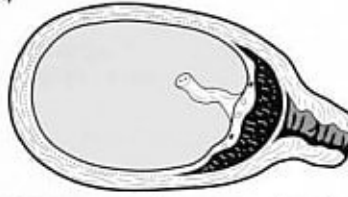
The placenta reaches the internal os when closed but does not cover it. ('Marginal'.)

Type 3



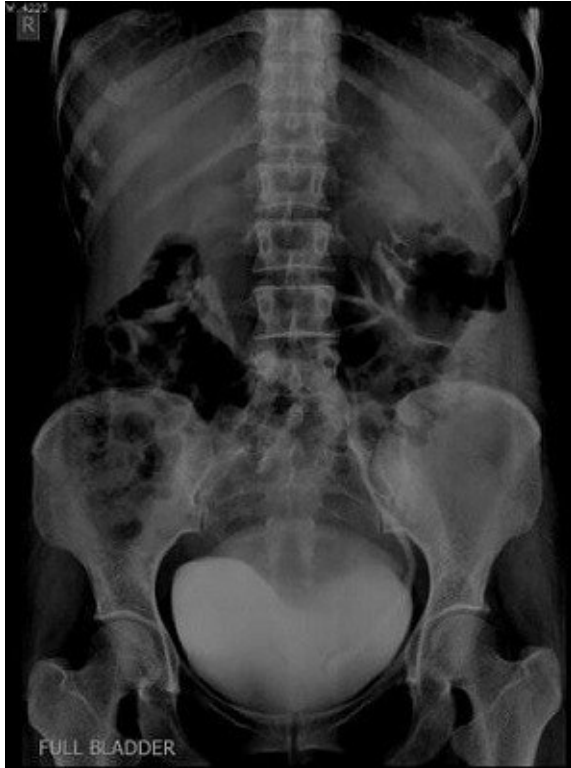The placenta covers the internal os when closed, but not when fully dilated. ('Partial' or 'Incomplete'.)

Type 4



The placenta covers the os even when the cervix is fully dilated. ('Central' or 'Complete'.)

**259. A female patient presented with recurrent Urinary tract infections. Imaging shows the following picture. What can be the most probable diagnosis?**



a) Duplication of Ureter

b) Congenital Megaureter

c) Ureterocele

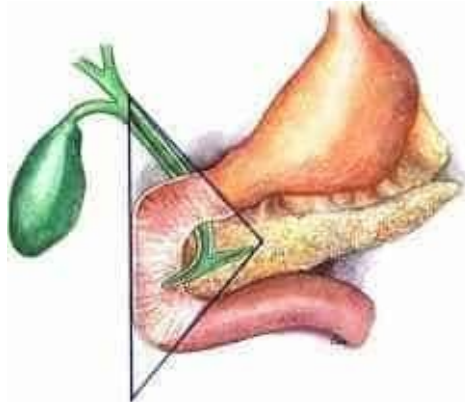
d) Urinary Stones

Correct Answer - C

**Ans. C. Ureterocele**

- Plain radiograph shows no calcification along the urinary tract. Post intravenous contrast radiograph shows dilatation of the left distal ureter showing a “cobra’s head” appearance and “radiolucent halo” effect. Findings represent intravesical Ureterocele of left ureter.
- Ureterocele represents abnormal dilatation of the distal ureteric segment. Ureterocele may be associated with either a single or a duplex ureter. Ureteric duplication is present in about 75% cases of ureteroceles. Ureterocele has a female predilection.
- Ureterocele can be further classified into simple and ectopic types.

260. Identify the triangle in the image below-



a) Koch's triangle

b) Gastrinoma triangle

c) Hesselbach's triangle

d) Sherren's triangle

Correct Answer - B

Answer- B (Gastrinoma triangle)

**Explanation-**

The gastrinoma triangle, also known as Passaro's triangle.

**The triangle is formed by joining the following three points:**

- superiorly: confluence of the cystic and common bile ducts
- inferiorly: junction of the second and third portions of the duodenum
- medially: junction of the neck and body of the pancreas

## 261. Identify the instrument-



a) Blade no. 15

b) Blade no. 10

c) Blade no. 11

d) Blade 12

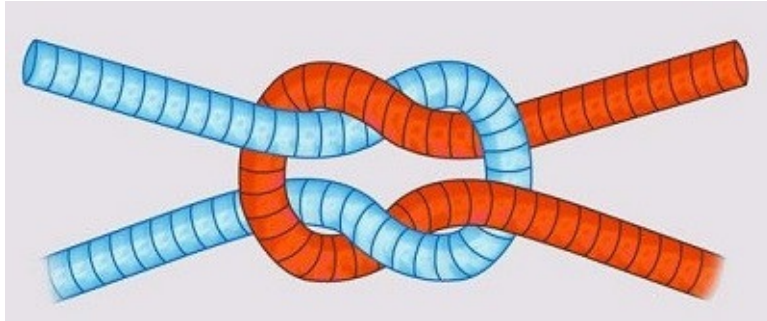
Correct Answer - C

Answer- C (Surgical blade 11)

### **Explanation-**

The No.11 is also used for other small incisions for example when inserting a laparoscopic port, vein and artery central lines ,opening the aorta and removing calcifications in the aortic or mitral valves.

262. Identify the type of knot in the image-



a) Granny knot

b) Surgeon's knot

c) Reef knot

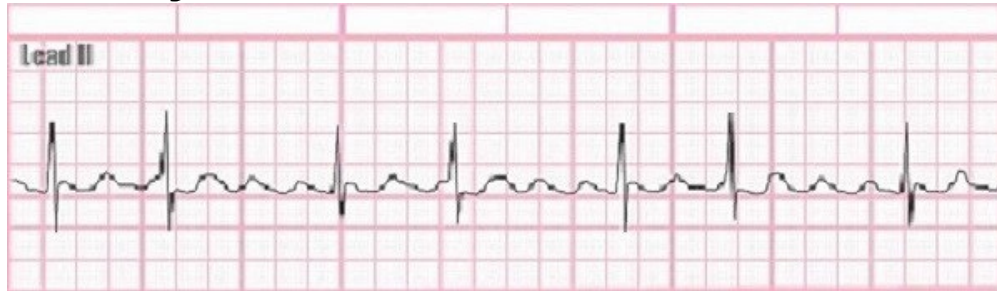d) None

Correct Answer - A

Answer- A (Granny's knot)

The granny knot is a binding knot, used to secure a rope or line around an object.

## 263. Identify the condition in the ECG?



a) Atrial fibrillation

b) Arrhythmia

c) Atrial flutter

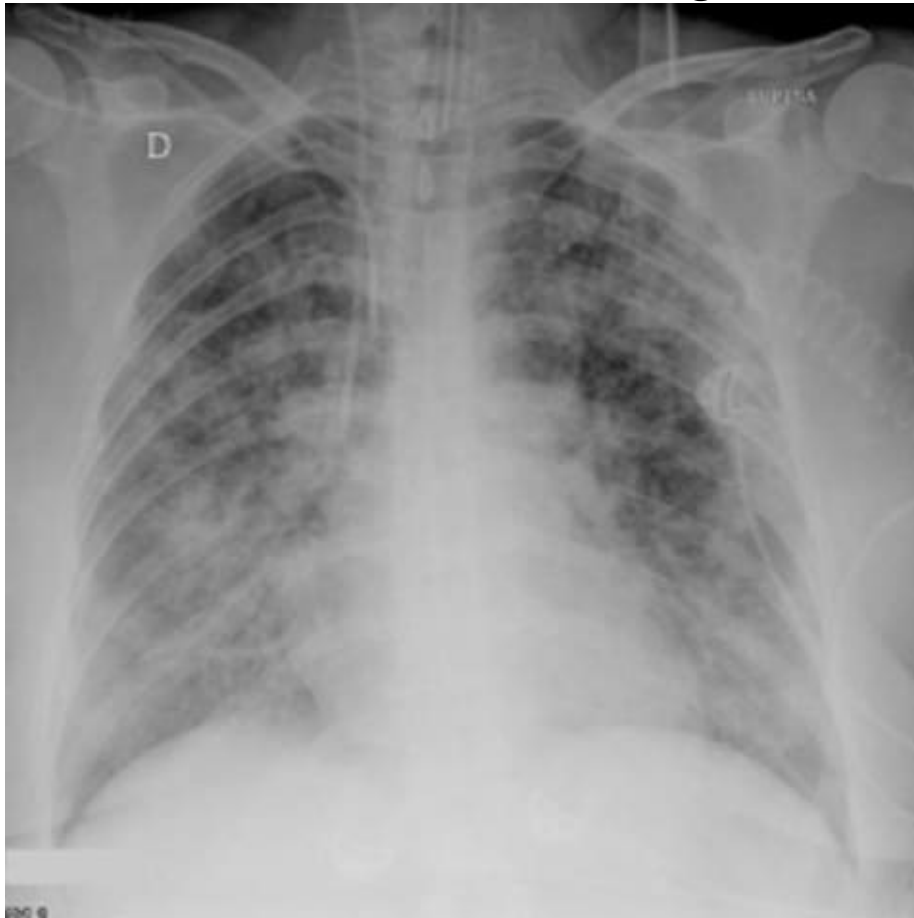d) Cardiomyopathy

Correct Answer - C

**Answer. C. Atrial flutter**

**Atrial flutter** (AFI) is a cardiac dysrhythmia characterized by rapid and regular depolarization of the atria that appears as a sawtooth pattern on the electrocardiogram (ECG) and is categorized into type I (typical) and type II (atypical) AFI.

**264. A patient is a known case of acute pancreatitis develops breathlessness, bilateral basal crepitation on day 4 and chest radiography as shown in the image below. What will be the diagnosis?**



a) Bilateral pneumonia

b) ARDS

c) Carcinogenic PE

d) Collapse

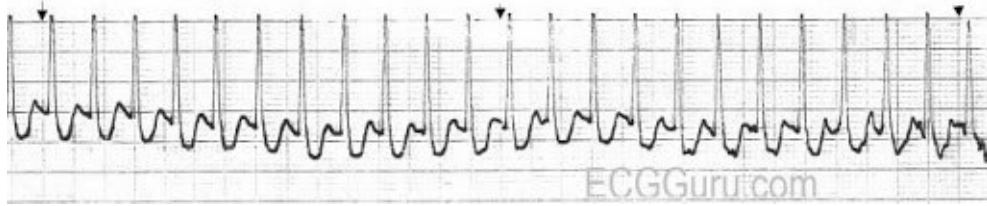
Correct Answer - B

**Answer- b. ARDS**

**Acute respiratory distress syndrome (ARDS)** is type of respiratory failure characterized by rapid onset of widespread inflammation in the lungs.

Bilateral opacities on chest imaging (chest radiograph or CT) not explained by other lung pathology (e.g. effusion, lobar/lung collapse, or nodule).

## 265. Identify the image with the diagnosis?



a) VT

b) PSVT

c) AT

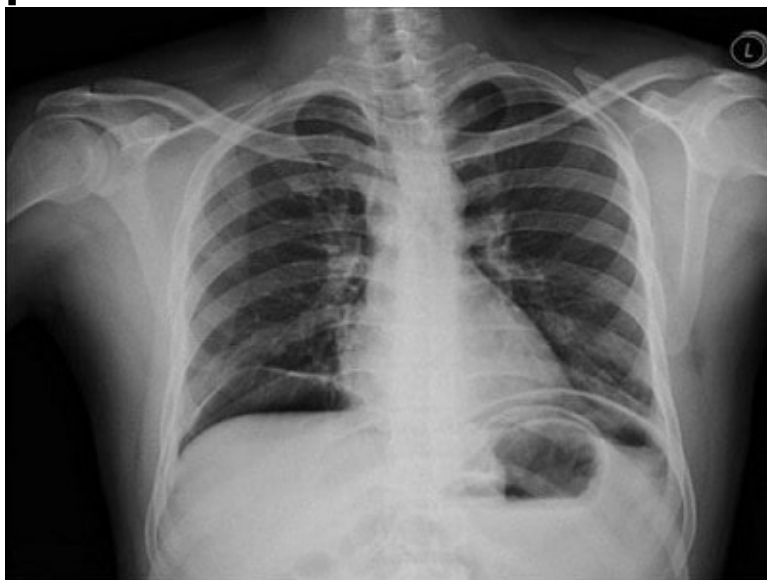
d) Ventricular fibrillation

Correct Answer - B

**Answer. B. PSVT**

**Supraventricular tachycardia (SVT).** Supraventricular tachycardia is an abnormally fast heartbeat that originates somewhere above the ventricles. It's caused by abnormal circuitry in the heart that is usually present at birth and creates a loop of overlapping signals.

**266. A patient came in emergency with severe abdominal pain pulse 112/ minute and systolic BP 80 mm/Hg with the chest X-ray shown below. What will be the next appropriate step to be taken for the patient?**



a) Exploratory laprotomy

b) Saline Wash of stomach

c) Intercostal tube drainage

d) None

Correct Answer - A

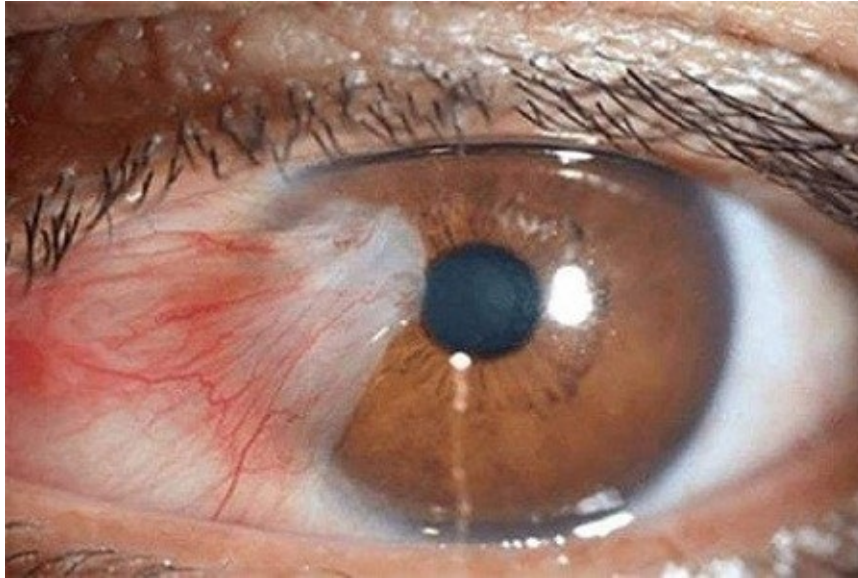
**Answer. A. Exploratory laparotomy**

- Above X-ray shows air under left diaphragm (pneumoperitoneum) which indicates hollow viscous perforation with partial intrathoracic

positioned stomach.

- This patient will require emergency exploratory laparotomy.
- This is one of the commonest surgical emergencies.

**267. True statement about given condition of eye except:**



a) Arise from any part of conjunctiva

b) Can cause Astigmatism

c) Surgery is treatment of choice

d) UV exposure is risk factor

Correct Answer - A

Answer. A. Arise from any part of conjunctiva

**Given condition is Pterygium**

- Pterygium is a non- cancerous (non-neoplastic) growth of conjunctiva.
- Characterized by a wing-shaped fold of conjunctiva upon the cornea from either side within the interpalpebral fissure.
- Pterygium is always situated in the palpebral aperture.
- Pathologically Pterygium is a degenerative & hyperplastic condition

of conjunctiva.

- The subconjunctival tissue undergoes elastotic degeneration & proliferates as vascularised granulation tissue under the epithelium, which ultimately encroaches the cornea.
- The corneal epithelium, Bowman's layer & stroma are destroyed.

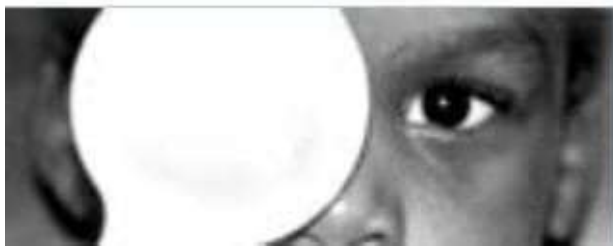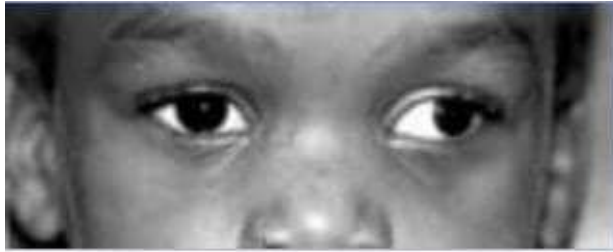### **Etiology & Clinical features**

- More common in people with excess outdoor exposure to sunlight (UV rays) dry, heat, high wind & abundance of dust.
- Clinically, presents as a triangular fold of conjunctiva encroaching the cornea in the area of palpebral aperture, usually on the nasal side.
- Other findings are stocker's line (deposition of iron).
- Pterygium is an asymptomatic condition in the early stages, except for cosmetic intolerance.
- Visual disturbance or corneal astigmatism may occur.
- Visual disturbances are due to encroachment of pterygium on pupillary area or corneal astigmatism.
- Occasionally diplopia may occur due to limitation of ocular movements.

### **Treatment**

- Asymptomatic pterygium which is not progressive is best left alone.
- Surgical excision is the only satisfactory treatment.

**268. Following test is used to diagnose which ocular condition as shown in image:**



a) Strabismus

b) Heterophoria

c) Both A & B

d) None of the above

Correct Answer - C

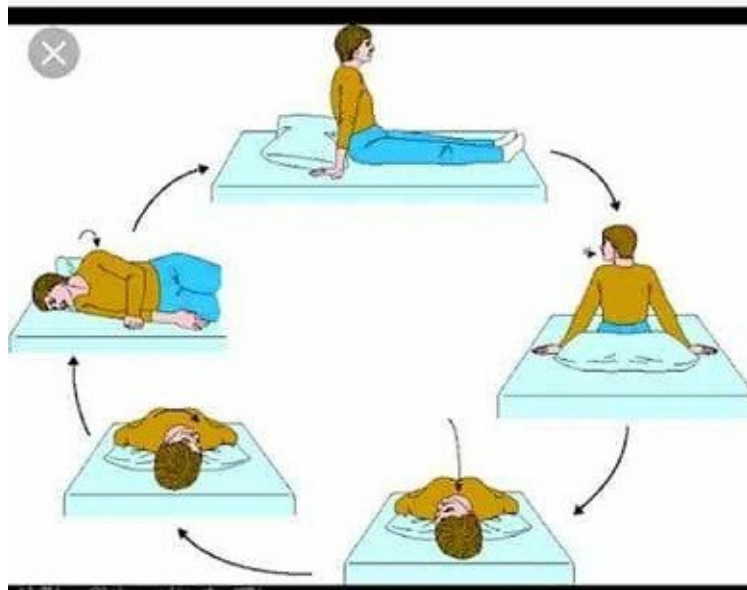
**Ans: C. Both A & B**

Given image is cover-uncover test

- The cover-uncover test to diagnose various types of tropias, which is a medical term for strabismus.
- The single cover test is a test is used to determine if there is a heterotropia or tropia, which is manifest strabismus or misalignment that is always present.
- The first eye is covered for approximately 1-2 seconds. As this eye is covered, the uncovered eye is observed for any shift in fixation.

- The cross-cover test or alternating cover test is usually employed to detect heterophoria.
- One eye is covered, and then the cover is moved immediately over to the other eye. With heterophoria, when the cover is moved to the other eye, the eye that has just been uncovered can be seen to move from a deviated point.
- The difference between heterotropia and heterophoria can be easily understood as follows.
- With heterotropia, a correcting movement of the eye can be detected already by the simple cover test; with heterophoria, such correcting movement only takes place in the cross-cover test.
- People with heterophoria can create and maintain binocular fusion through vergence, and the cross-cover test purposely breaks this fusion, making the latent misalignment visible.

269. Name the manoeuvre shown in the image:



a) Brandt daroff

b) Epley

c) Foster

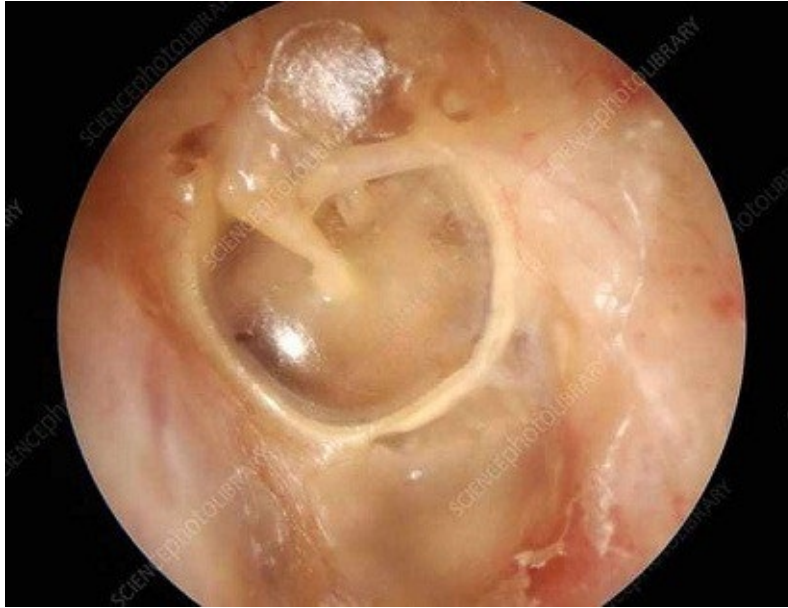d) Semont

Correct Answer - B

Answer. B. Epley

- The Epley maneuver is an exercise you can do at home to relieve dizziness caused by benign paroxysmal positional vertigo (BPPV).
- BPPV is caused by a problem with the inner ear. Calcium crystals called canaliths can end up in the semicircular canals.

**270. Identify the condition of the given image:**



a) Acquired cholesteatoma

b) Congenital cholesteatoma

c) Rupture of tympanic membrane

d) Keratosis obturans

Correct Answer - D

Answer. D. Keratosis obturans

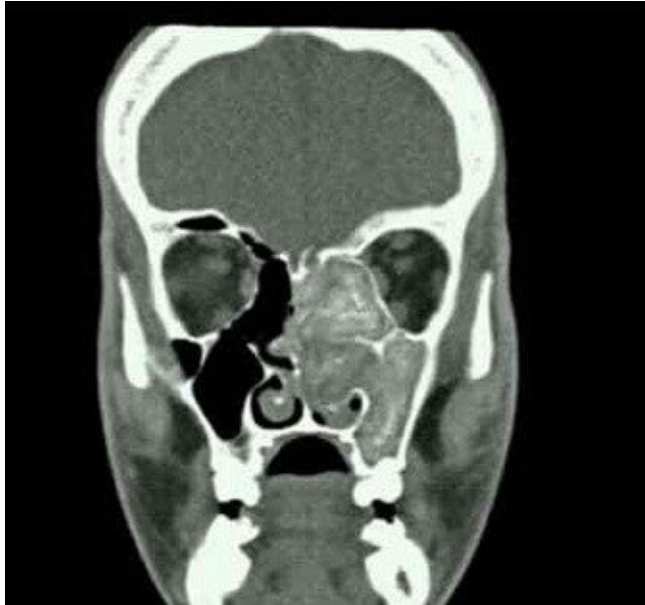Given image is Keratosis obturans, otoscope view.

- This is a rare condition of the ear canal with a generalised failure of migration of the normal canal skin.
- The skin accumulates and the underlying bone is resorbed.
- Here there is a deep widening of the ear canal with exposure of the circular annulus at the edge of the tympanic membrane (eardrum, centre).
- The jugular vein (purple) can be seen through the remaining tissue

on the floor of the ear canal.

- The eardrum is relatively unaffected here.

**271. CT image of left maxilla with history of allergic rhinitis?**



a) Ground glass appearance

b) Double densities

c) Honey comb

d) Onion Peel Appearance

Correct Answer - B

Answer: B. Double Densities

Allergic fungal sinusitis is the most common form of [fungal sinusitis](#) and is common in warm and humid climates. On imaging, it usually presents as opacification and expansion of multiple paranasal sinuses, unilaterally or bilaterally, with content that is centrally hyperdense on CT

The majority of sinuses show near complete opacification. On unenhanced CT, the sinuses are typically opacified by centrally (often serpiginous) hyperdense material with a peripheral rim of hypodense mucosa.

Approximately 40% of patients may have each of the following features 4:

- expansion of an involved sinus
- remodelling and thinning of the bone sinus walls
- erosion of the sinus wall

## 272. Identify the instrument:



a) Maddox rod

b) Maddox wing

c) Maddox glass

d) Red glasses

Correct Answer - A

### **Answer A) Maddox rod**

The **Maddox rod** test can be used to subjectively detect and measure a latent, manifest, horizontal or vertical strabismus for near and distance.

The test is based on the principle of diplopic projection

The Maddox rod is a handheld instrument composed of red parallel plano-convex cylinder lens, which refracts light rays so that a point source of light is seen as a line or streak of light.

Due to the optical properties, the streak of light is seen perpendicular to the axis of the cylinder.



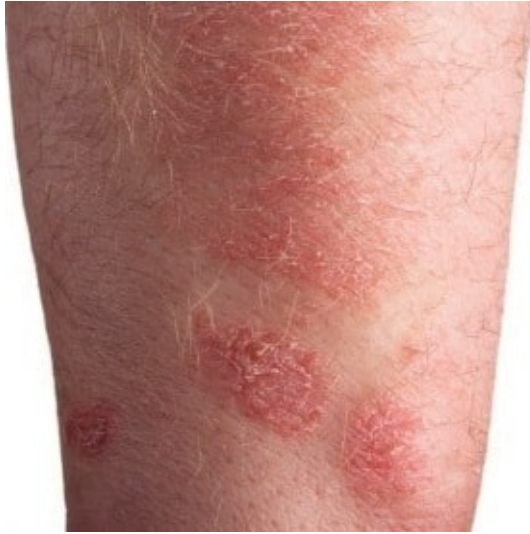**The Maddox rod test should be used in cases of:**

Small to moderate

Decompensated phorias.

Acquired strabismus (rather than congenital or early-onset)

**273. Identify the lesion of vocal cord in the image given below:**



a) Reinke's edema

b) Laryngeal Papilloma

c) Malignancy

d) Tracheomalacia

**Correct Answer - B**

-Laryngeal *papillomatosis*, or recurrent respiratory papillomatosis (RRP), is the most frequent benign tumor of the larynx.

- It is caused by the human papillomavirus (HPV) types 6 and 11. It is also the second most common cause of hoarseness in children.

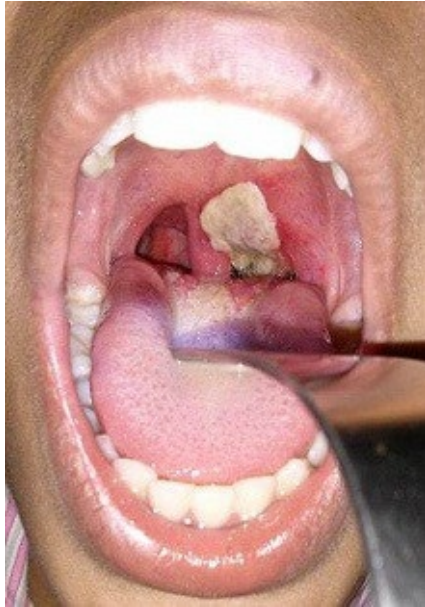-Laryngeal papillomas are located primarily in the larynx on the vocal cord margins and epiglottis.

-Tumors are benign but present obstructive problems because of their localization in the vocal cords or other sites

- **At presentation, papillomas are usually present on one or both**

**vocal cords with the anterior commissure, supraglottis, or subglottis also commonly affect**

**274. A patient gives H/o hoarseness in voice & presenting with clinical condition as shown in the image. Identify the lesion:**



a) Membranous tonsillitis

b) Follicular tonsillitis

c) Diphtheria

d) Aphthous ulcer

Correct Answer - C

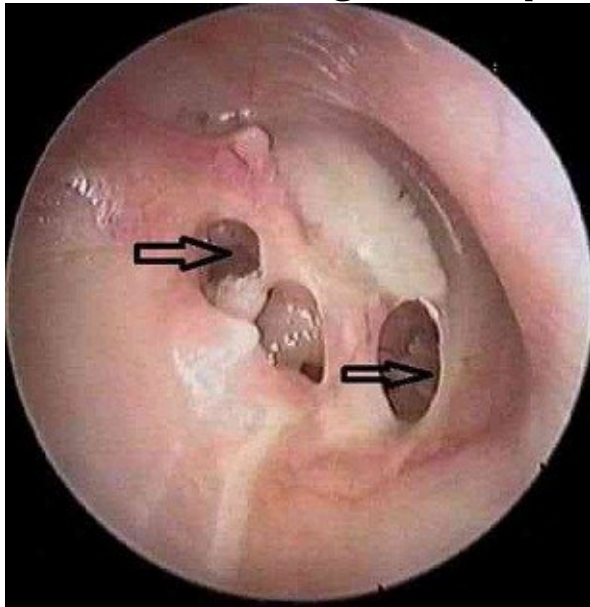-Diphtheria is a serious bacterial infection that usually affects the mucous membranes of your nose and throat.

-Diphtheria is caused by the bacterium *Corynebacterium diphtheriae*.

-Diphtheria signs and symptoms usually begin two to five days after a person becomes infected and may include:

- A thick, grey membrane covering your throat and tonsils
- sore throat and hoarseness
- Swollen glands (enlarged lymph nodes) in your neck
- Difficulty breathing or rapid breathing
- Nasal discharge
- Fever and chills
- Malaise.

**275. A patient presented with the following picture of Tympanic Membrane. Most Probable diagnosis (marked with arrow):**



a) Tubercular Otitis Media

b) Syphilitic Otitis Media

c) Pseudomonas infection

d) Fungal Otitis Media

Correct Answer - A

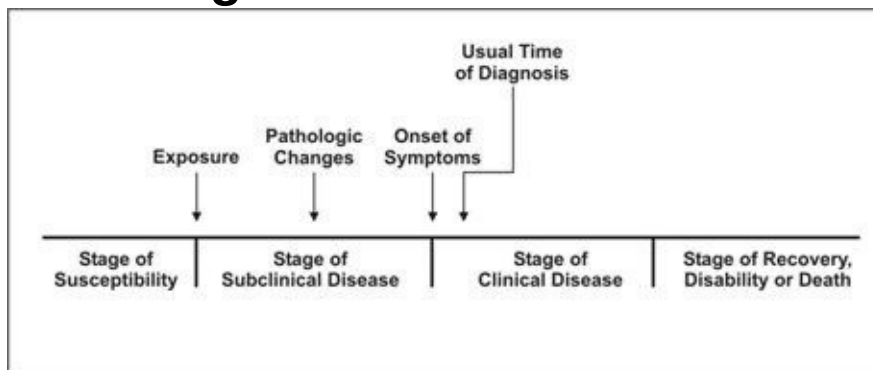
Answer. A. Tubercular Otitis Media

- Tuberculous Otitis Media Where perforations are multiple and are associated with otorrhea, a tuberculosis of the middle ear should be suspected.
- These perforations result from breaking down of tubercles.
- In the given image, Tympanic membrane showing multiple

perforations

- Infection reaches the middle ear through eustachian tube.
- The rare modes of infection are through hematogenous spread from tubercular focus in lung, tonsils, cervical lymph nodes; or due to ingestion of infected cow's milk.
- It usually affects children and young adults.

**276. Which method is used to study the following timeline?**



a) Cohort Study

b) Cross sectional study

c) Randomized Control Trials

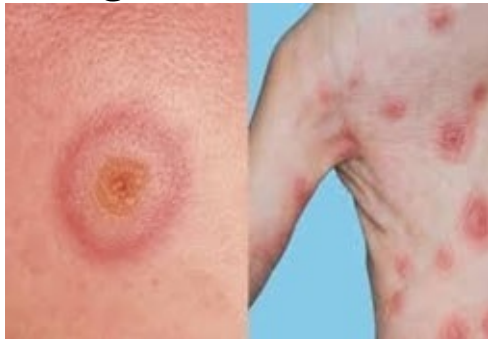d) Interventional Studies

Correct Answer - A

Ans. A.Cohort Study

- The image represents the Natural history of disease that refers to the progression of a disease process in an individual over time, in the absence of treatment.
- The timeline shows the state of susceptibility, exposure, the subclinical disease in which pathologic changes take place, the onset of symptoms, followed by the usual time of diagnosis, clinical disease, followed by recovery, disability, or death.
- Longitudinal studies are used to study the natural history of the disease.

**277. A 6 year old boy is having symptoms such as fever and chills, cough, rapid breathing, difficulty breathing, and chest pain, culture from a sample shows Gram-positive culture, Identify the image:**



a) Streptococcus pneumoniae

b) Staphylococcus

c) Propionibacterium

d) Mycobacterium

Correct Answer - A

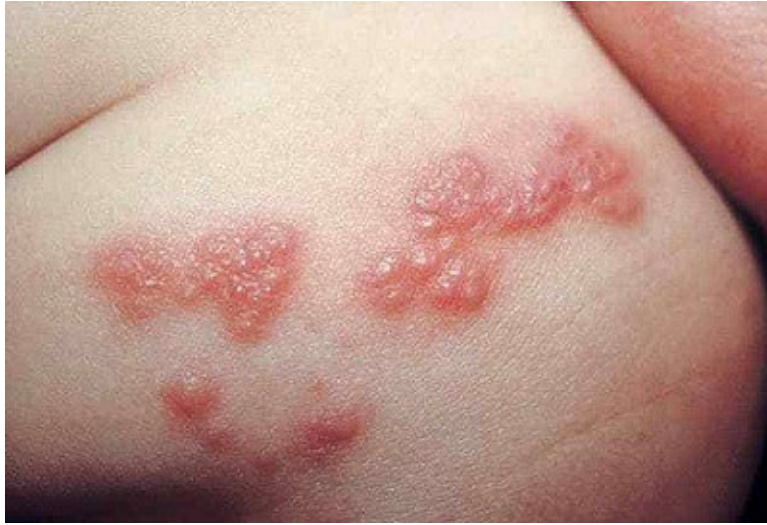Answer: A. Streptococcus pneumoniae

- Streptococcus pneumoniae (pneumococcus) is a Gram-positive bacterium that is responsible for the majority of community-acquired pneumonia
- S. pneumoniae is alpha-hemolytic, meaning that it can break down red blood cells through the production of hydrogen peroxide (H<sub>2</sub>O<sub>2</sub>).

The production of H<sub>2</sub>O<sub>2</sub> by the bacterial infection can also cause damage to DNA, and kill cells within the lungs.

- Pneumococcal pneumonia causes fever and chills, coughs, difficulty breathing, and chest pain. If the infection spreads to the brain and spinal cord, it can cause pneumococcal meningitis,

## 278. 12 Identify the picture



a) Herpes zoster pic

b) Small pox


c) Chicken pox

d) Atopic dermatitis

Correct Answer - A

Answer: A. Herpes zoster pic

- Shingles, also known as herpes zoster, is a viral disease characterized by a painful skin rash with blisters in a localized area.
- Shingles is due to a reactivation of varicella zoster virus (VZV) within a person's body.
- The disease chickenpox is caused by the initial infection with VZV.
- Once chickenpox has resolved, the virus may remain inactive in nerve cells.
- When it reactivates, it travels from the nerve body to the endings in the skin, producing blisters. Risk factors for reactivation include old age, poor immune function.



## 279. Identify the image



a) Malaria

b) Plague

c) Japanese encephalitis

d) Paragonimus

Correct Answer - C

Answer; C. Japanese encephalitis

- Japanese encephalitis (JE) is an infection of the brain caused by the Japanese encephalitis virus (JEV).
- JEV is generally spread by mosquitoes, specifically those of the Culex type. Pigs and wild birds serve as a reservoir for the virus.
- symptoms may include headache, vomiting, fever, confusion, and seizures.

## 280. What is the cause of death according to the below death certificate

Cause of death*		Time interval between onset and death
a	Direct cause of death <b>Cerebral haemorrhage</b>	<b>4 hours</b>
b	Due to <b>Metastasis of the brain</b>	<b>4 months</b>
c	Due to <b>Breast cancer</b>	<b>5 years</b>
d	Due to	

**1**  
Report disease or condition directly leading to death on line a  
Report chain of events i due to order (if applicable)  
State the underlying cause on the lowest used line

**2**  
Other significant conditions contributing to death (time intervals can be included in brackets after the condition)

**Arterial hypertension (3 years); Diabetes mellitus (10 years)**

\*This does not mean the mode of dying. e.g. heart failure, respiratory failure. It means the disease, injury, or complication that caused death.

a) Breast Cancer

b) Secondaries

c) Cerebral Hemorrhage

d) All of the Above

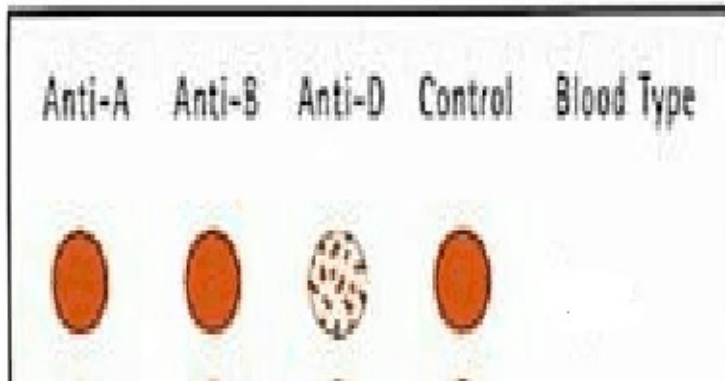
Correct Answer - D

**Ans. D. All of the Above**

All the Three are cause of death as they are in describing the sequence of events in deaths .

**281. Identify the blood grouping process done here.**

**Slide given with: AB no clumps,  
Clumping in O & No clumps in control.  
Which group does this signify?**



a) A-ve

b) B+ve

c) O+ve

d) Rh group

Correct Answer - D

Ans:D. Rh group

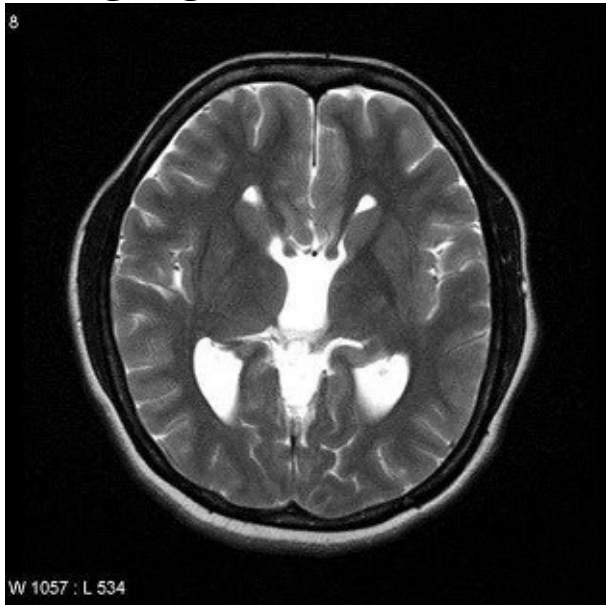
\* D antigen –

- Most important blood group antigen in routine blood banking.
- Antibodies of Rh system do not occur naturally in serum.
- Mostly as a result of antigen exposure during pregnancy or through transfusion.

\* Presence or absence of D antigen determined by testing RBC's with Anti-D.

- Agglutination indicates D positive test cells.
- No agglutination indicates D negative test cells.
- \* “Weak D” – Used to describe D antigen forms that are unagglutinated directly by anti-D reagents

**282. Identify the condition as shown in the image given below:**



a) Callosal dysgenesis

b) Dandy walker syndrome

c) Aicardi syndrome

d) Septo optic dysplasia

Correct Answer - A

Answer A. Callosal dysgenesis

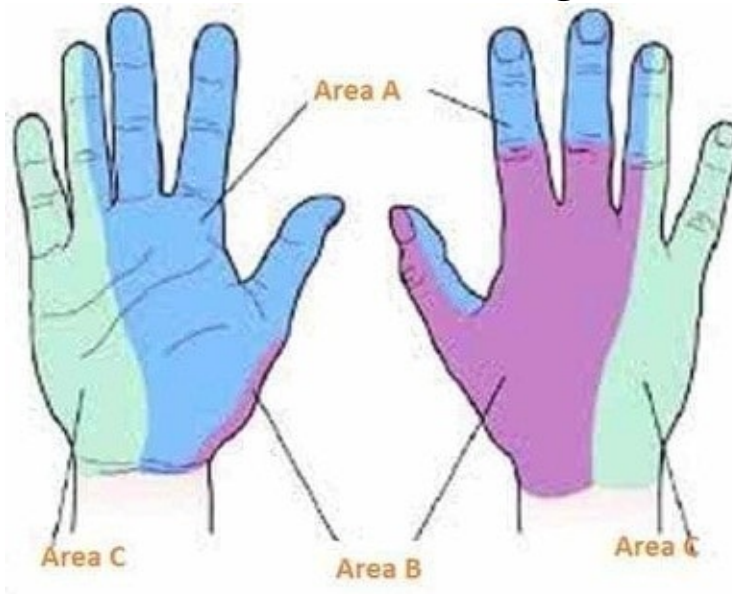
Given image is showing racing car sign

**Racing car sign (callosal dysgenesis)**

- The racing car sign refers to widely spaced lateral ventricles due to agenesis of the corpus callosum with intervening Probst bundles.
- Appearances on axial MRI or CT are reminiscent of a Formula One car seen from above, with the tyres represented by the widely-

spaced frontal horns, and the dilated trigones (colpocephaly).

**283. Which nerve supplies to the area marked as 'Area B' in the image:**



a) Ulnar nerve

b) Median nerve

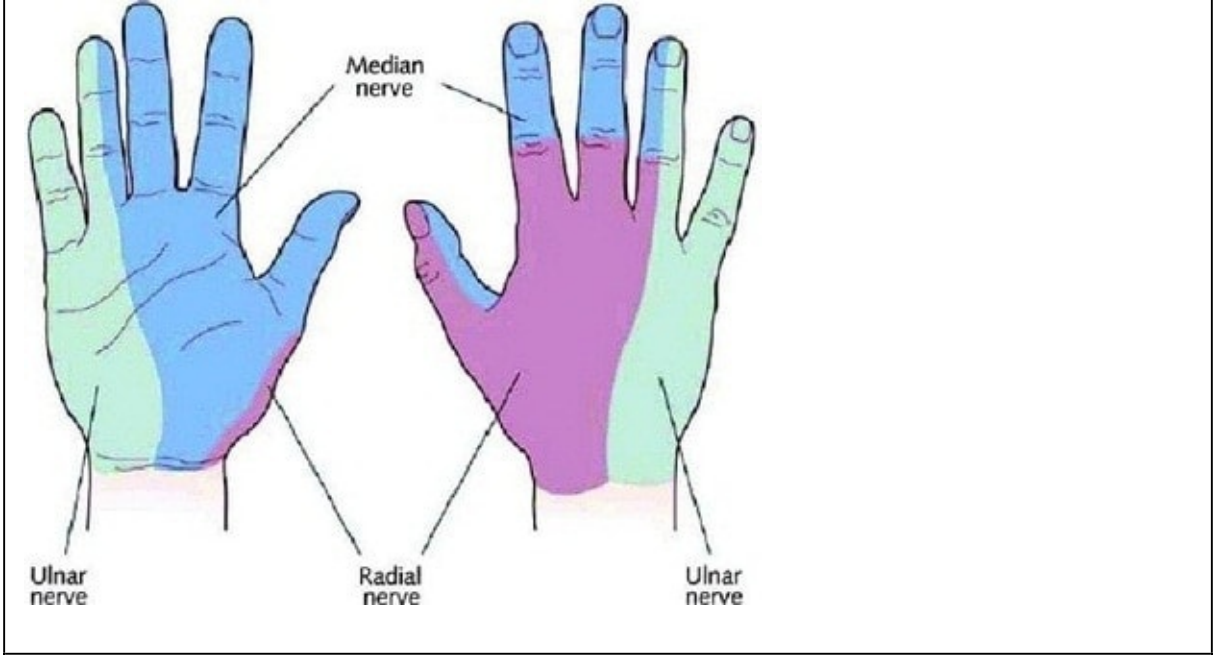
c) Radial nerve

d) Posterior interosseous nerve

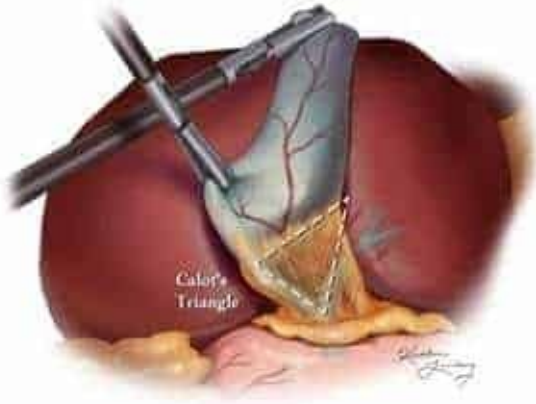
Correct Answer - C

Answer C. Radial nerve

The superficial terminal branch of the radial nerve is purely cutaneous and supplies lateral half of the dorsum of the hand, and to the proximal parts of the dorsal surfaces of the thumb, the index finger, and lateral half of the middle finger.



**284. Which of the following is not a boundary of given image:**



a) Common hepatic duct

b) Cystic duct

c) Inferior surface of the liver.

d) Gall bladder

Correct Answer - D

**Answer D. Gall bladder**

**CALOT'S TRIANGLE**

\* Calot's triangle (cystohepatic triangle) is a small anatomical space in the abdomen.

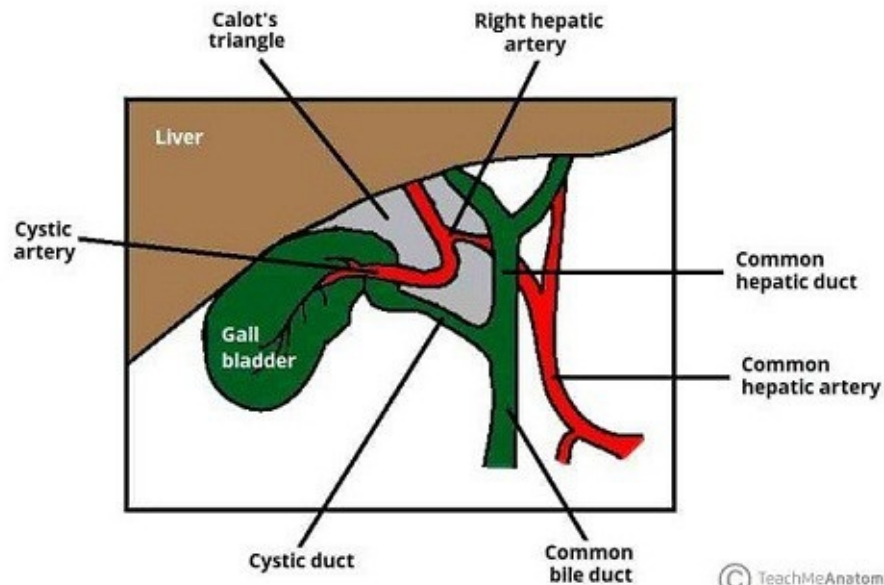
\* It is located at the porta hepatis of the liver – where the hepatic ducts and neurovascular structures enter/exit the liver.

\* The borders are as follows:

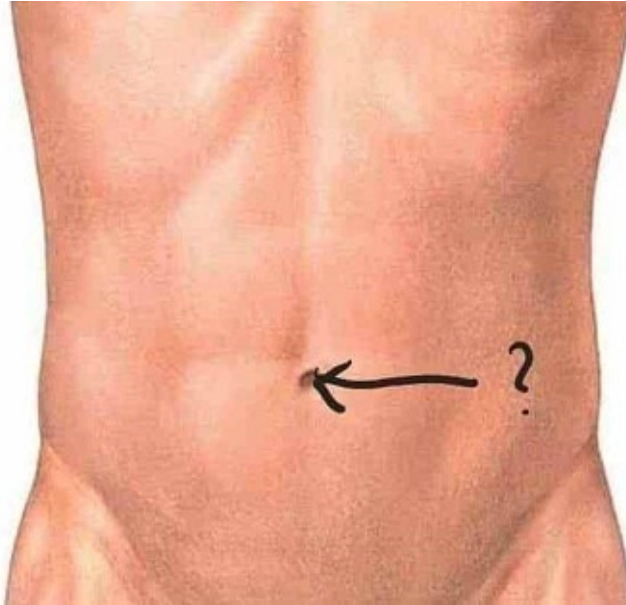
- Medial – common hepatic duct.
- Inferior – cystic duct.
- Superior – inferior surface of the liver.

\* The above differ from the original description of Calot's triangle in 1891 – where the cystic artery is given as the superior border of the triangle.

\* The modern definition gives a more consistent border (the cystic artery has considerable variation in its anatomical course and origin).



**285. Marked area in the given image is supplied by which dermatome?**



a) T8

b) T9

c) T10

d) T11

Correct Answer - C

Answer C. T10

**Important dermatome & anatomical landmarks**

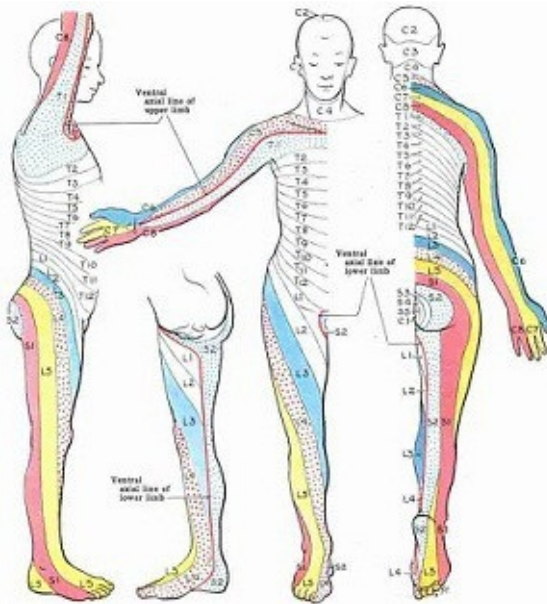
Following is a list of [spinal nerves](#) and points that are characteristically belonging to the dermatome of each nerve.

\* C2 – At least one cm lateral to the occipital protuberance at the base of the skull. Alternately, a point at least 3 cm behind the ear.

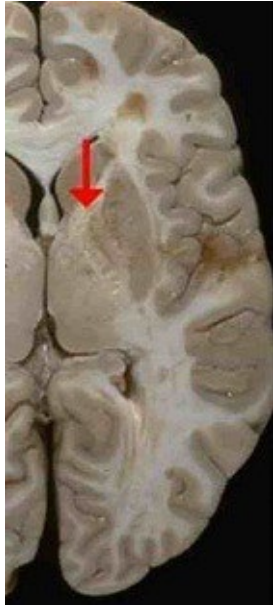
\* C3 – In the supraclavicular fossa, at the midclavicular line.

- \* C4 – Over the acromioclavicular joint.
- \* C5 – On the lateral (radial) side of the antecubital fossa, just proximally to the elbow.
- \* C6 – On the dorsal surface of the proximal phalanx of the thumb.
- \* C7 – On the dorsal surface of the proximal phalanx of the middle finger.
- \* C8 – On the dorsal surface of the proximal phalanx of the little finger.
- \* T1 – On the medial (ulnar) side of the antecubital fossa, just proximally to the medial epicondyle of the humerus.
- \* T2 – At the apex of the axilla.
- \* T3 – Intersection of the midclavicular line and the third intercostal space
- \* T4 – Intersection of the midclavicular line and the fourth intercostal space, located at the level of the nipples.
- \* T5 – Intersection of the midclavicular line and the fifth intercostal space, horizontally located midway between the level of the nipples and the level of the xiphoid process.
- \* T6 – Intersection of the midclavicular line and the horizontal level of the xiphoid process.
- \* T7 – Intersection of the midclavicular line and the horizontal level at one quarter the distance between the level of the xiphoid process and the level of the umbilicus.
- \* T8 – Intersection of the midclavicular line and the horizontal level at one half the distance between the level of the xiphoid process and the level of the umbilicus.
- \* T9 – Intersection of the midclavicular line and the horizontal level at three quarters of the distance between the level of the xiphoid process and the level of the umbilicus.
- \* T10 – Intersection of the midclavicular line, at the horizontal level of the umbilicus.
- \* T11 – Intersection of the midclavicular line, at the horizontal level midway between the level of the umbilicus and the inguinal ligament.
- \* T12 – Intersection of the midclavicular line and the midpoint of the inguinal ligament.
- \* L1 – Midway between the key sensory points for T12 and L2.

- \* L2 – On the anterior medial thigh, at the midpoint of a line connecting the midpoint of the inguinal ligament and the medial epicondyle of the femur.
- \* L3 – At the medial epicondyle of the femur.
- \* L4 – Over the medial malleolus.
- \* L5 – On the dorsum of the foot at the third metatarsophalangeal joint.
- \* S1 – On the lateral aspect of the calcaneus.
- \* S2 – At the midpoint of the popliteal fossa.
- \* S3 – Over the tuberosity of the ischium or infragluteal fold
- \* S4 and S5 – In the perianal area, less than one cm lateral to the mucocutaneous zone



**286. Identify the type of the fibre marked in the image of internal capsule:**



a) Projection fibres

b) Short association fibres

c) Long association fibres

d) Commissural fibres

Correct Answer - A

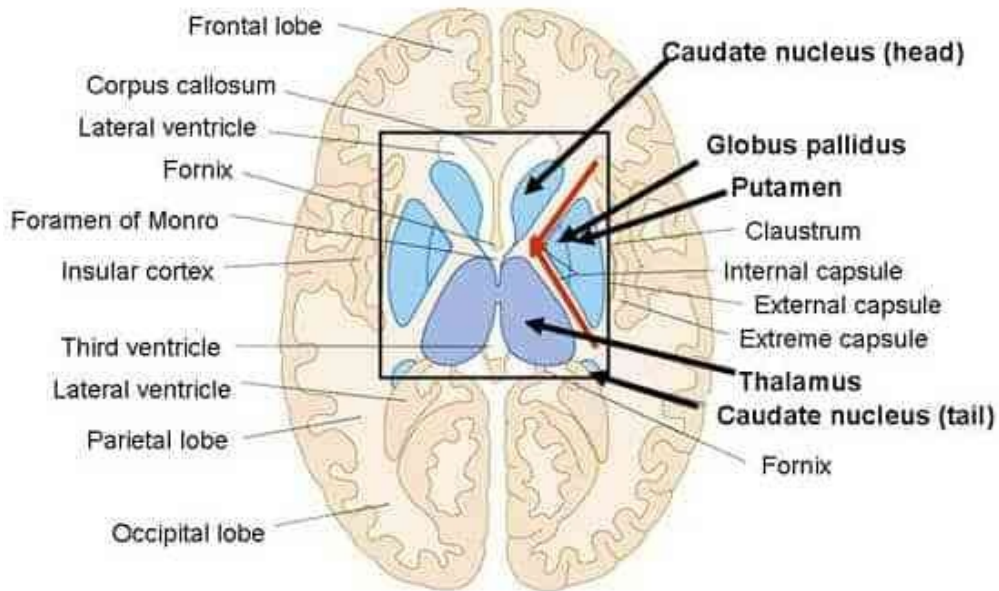
Answer A. Projection fibres

**Internal capsule**

- Area of white matter in the brain that separates the caudate nucleus and the thalamus from the putamen and the globus pallidus.
- The internal capsule contains both ascending and descending axons.
- It consists of axonal fibres that run between the cerebral cortex and

the pyramids of the medulla.

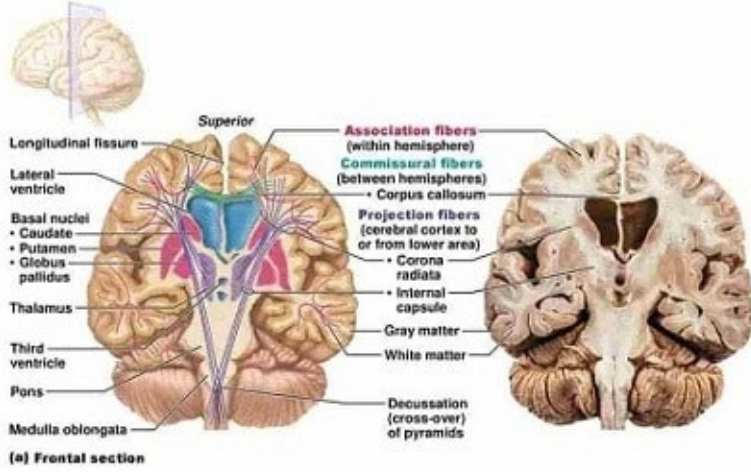
## Internal Capsule



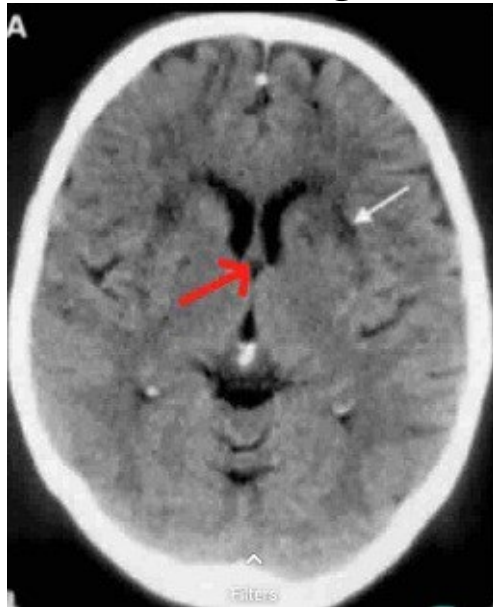
### Components

- The internal capsule is V-shaped when cut transversely (horizontally).
- When cut horizontally:
  - the bend in the V is called the genu
  - Anterior limb of the internal capsule.
  - the posterior limb or crus posterius is the part behind the genu, between the thalamus and lenticular nucleus.
  - the retrolenticular portion is caudal to the lenticular nucleus and carries optic tracts including the geniculocalcarine radiations.
  - the sublenticular portion is beneath the lenticular nucleus and are tracts involved in the auditory pathway from medial geniculate nucleus to the primary auditory cortex (Brodmann Area 41).
- Gross motor strength is impaired with ischemia of the internal capsule.

Figure 12.3a White fiber tracts of the cerebral hemispheres.



**287. Identify the structure marked by a red arrow in the given image:**



a) Great vein of galen

b) Pineal gland

c) Fornix

d) Falx cerebri

Correct Answer - C

Answer C. Fornix

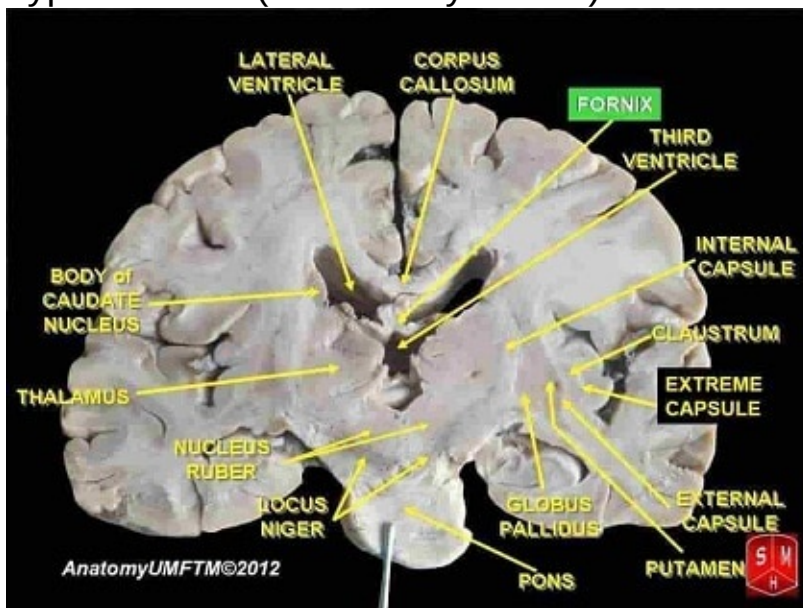
- The fornix is the main efferent system of the [hippocampus](#) and an important part of the [limbic system](#).
  - It is one of the commissural fibers connecting the [cerebral hemispheres](#).
- Gross anatomy**
- Roughly C-shaped, the fornix extends from the hippocampus to

the [mammillary bodies](#) of the [hypothalamus](#) and the anterior nuclei of the [thalamus](#).

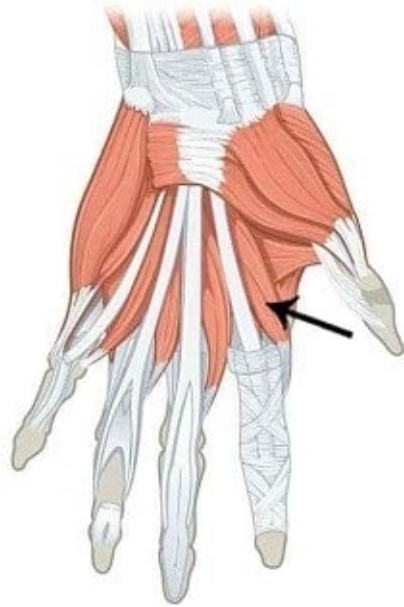
- It is a curvilinear bundle of white matter fibers that begins as a group of myelinated fibers called the alveus.
- The alveus joins to form the fimbria of the hippocampus.
- The fimbria of each hippocampus thickens and then splits off from the hippocampus to form the crus (leg) of the fornix.

**The fornix is composed of four parts:**

- crura: best seen at the splenium of the corpus callosum at the level of the superior colliculus on coronal images
- commissure: connects the crura
- body: from the merging of the crura, provides one of two major paths through which the hippocampus communicate with each other
- columns (anterior pillars): curves anteriorly and dives into the hypothalamus (mammillary bodies)



**288. What is the Nerve Supply of marked structure in the given image:**



a) Anterior interosseous nerve

b) Posterior interosseous nerve

c) Ulnar nerve

d) Median nerve

Correct Answer - D

**Answer D. Median nerve**

The structure indicated is the first lumbrical muscle of the hand.

\* The lumbricals belong to the intrinsic group of muscles which act on the hand.

\* The intrinsic muscles include the following muscles/groups:

- Thenar group (act on thumb)
- Hypothenar group (act on little finger)

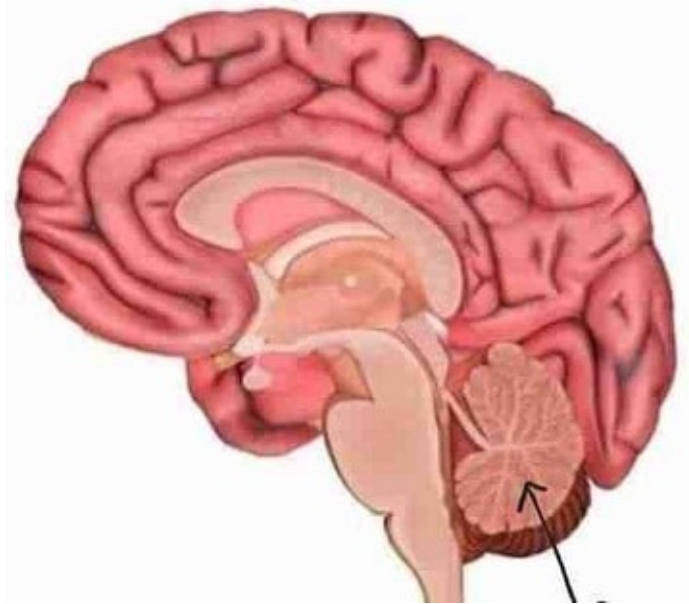
- Adductor pollicis
- Lumbricals
- Interosseous muscles
- Palmaris brevis

\* All the intrinsic muscles of the hand, except the thenar muscles and the lateral two lumbrical muscles, are innervated by the deep branch of the ulnar nerve.

\* The thenar muscles and the lateral two lumbrical muscles are innervated by the median nerve.

\* A useful mnemonic for remembering this is MEATLOAF. "MEAT" refers to the Median nerve, and LOAF refers to the muscles which it innervates: Lateral two lumbricals, Opponens pollicis, Abductor pollicis brevis, Flexor pollicis brevis

**289. Identify the marked structure in the image:**



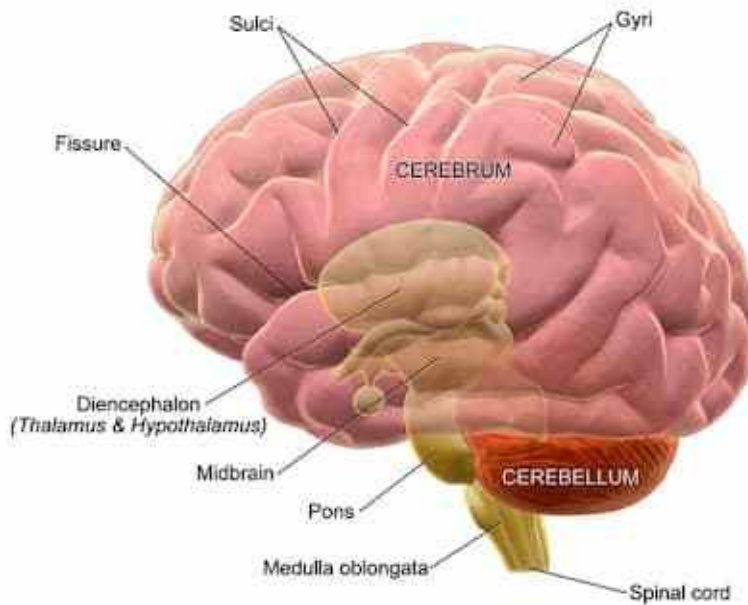
a) Cerebrum

b) Brain stem

c) Corpus callosum

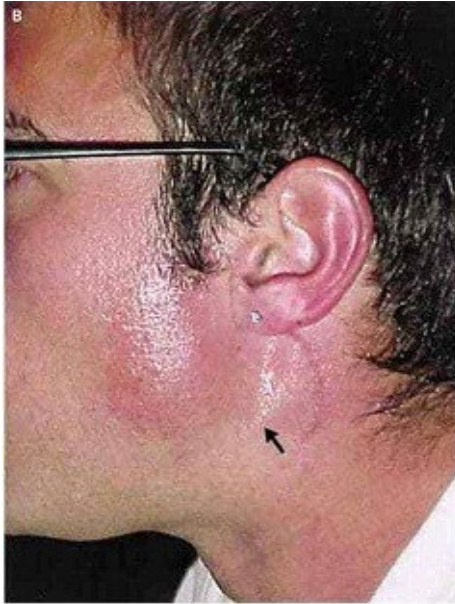d) Cerebellum

Correct Answer - D  
Answer D. Cerebellum



- The cerebellum, which stands for “little brain”, is a structure of the central nervous system. It has an important role in motor control, with cerebellar dysfunction often presenting with motor signs.
- The cerebellum is located at the back of the brain, immediately inferior to the occipital and temporallobes, and within the posterior cranial fossa.
- It is separated from these lobes by the tentorium cerebelli, a tough layer of dura mater.
- It lies at the same level of and posterior to the pons, from which it is separated by the fourth ventricle.

**290. Nerve injured in Frey's syndrome is:**



a) Auriculotemporal Nerve

b) Great auricular nerve

c) Lingual Nerve

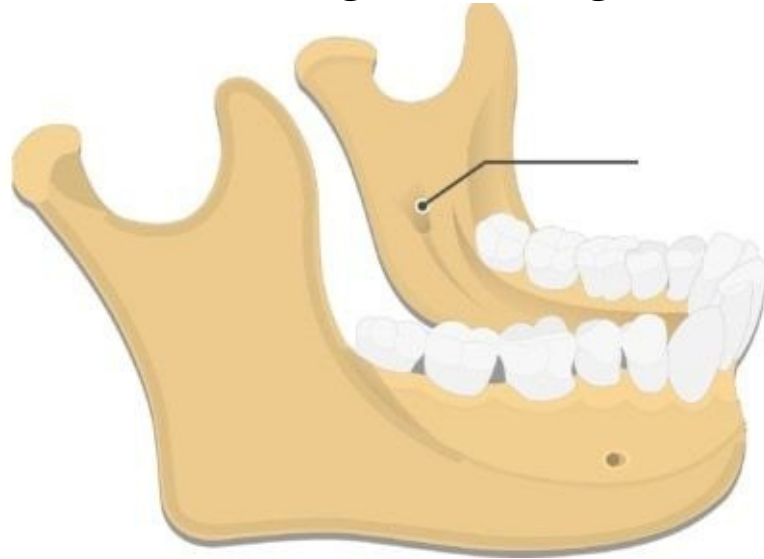
d) Inferior alveolar nerve

Correct Answer - A

Answer A. Auriculotemporal Nerve

- Frey's syndrome (also known as Baillarger syndrome, Dupuy's syndrome, auriculotemporal syndrome, or Frey-Baillarger syndrome) is a rare neurological disorder resulting from damage to or near the parotid glands responsible for making saliva, and from damage to the auriculotemporal nerve often from surgery.

**291. Which nerve passes through the marked foramen in the given image:**



a) Lingual nerve

b) Mandibular nerve

c) Chorda tympani nerve

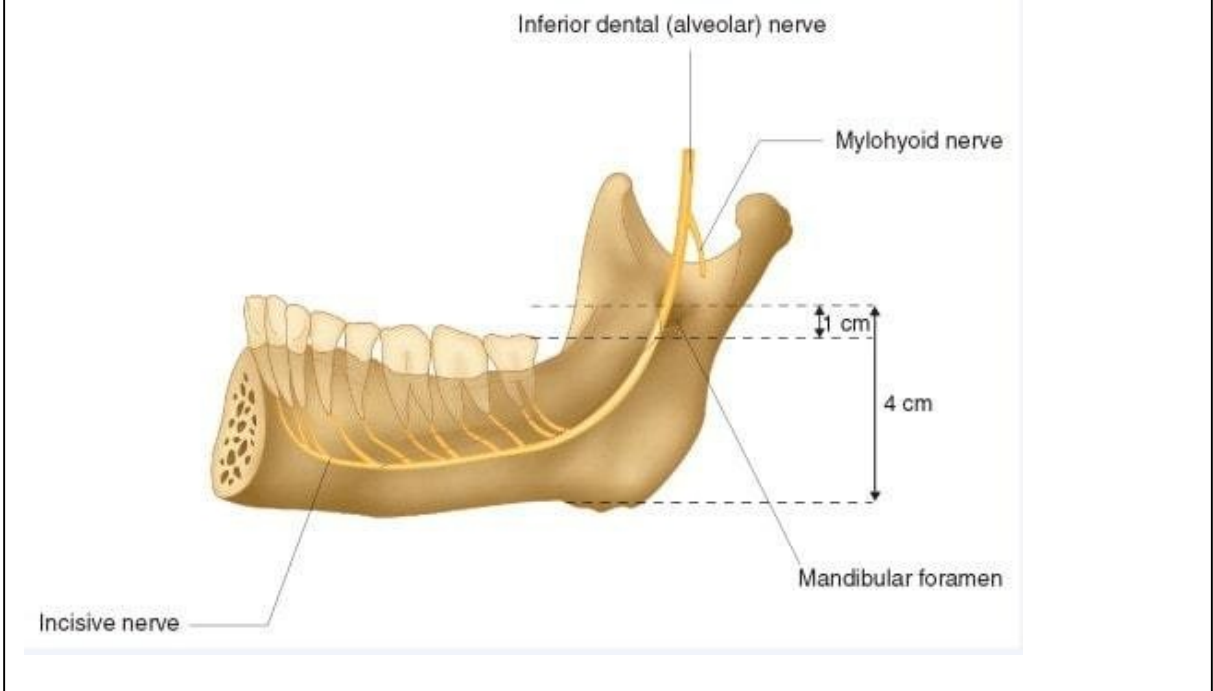
d) Inferior alveolar nerve

Correct Answer - D

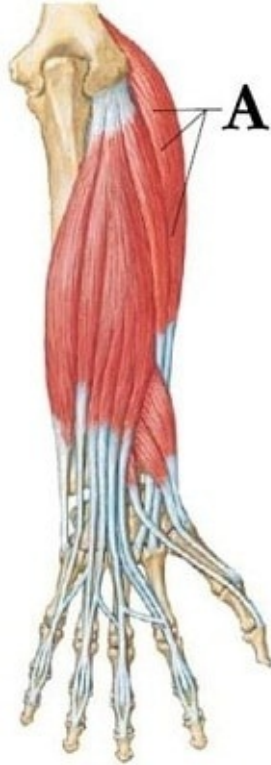
Answer D. Inferior alveolar nerve

Marked area is Mandibular foramen,

- Mandibular foramen– opening on the medial surface of the ramus; passageway for the inferior alveolar nerve and artery, which supply the lower teeth.



292. Identify the marked muscle 'A' in the diagram:



a) Brachioradialis

b) Extensor carpi radialis longus

c) Flexor carpi radialis

d) Extensor carpi ulnaris

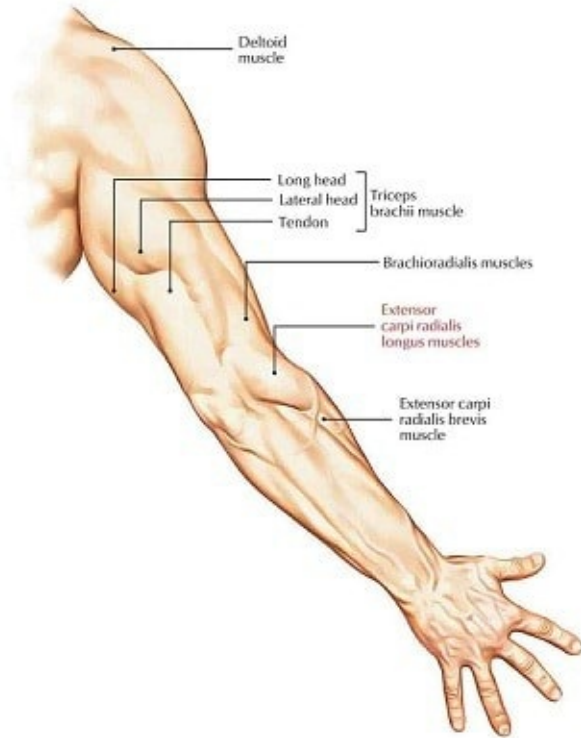
Correct Answer - B

**Answer B. Extensor carpi radialis longus**

- The extensor carpi radialis longus muscle emerges from the lateral epicondyle of the humerus and the distal part of the supraepicondylar rim; its tendon enters on the dorsal side of the

base of metacarpal II.

- In proximal areas, it is deep to the brachioradialis muscle.
- The wrist is expanded and abducted by the extensor carpi radialis longus muscle.



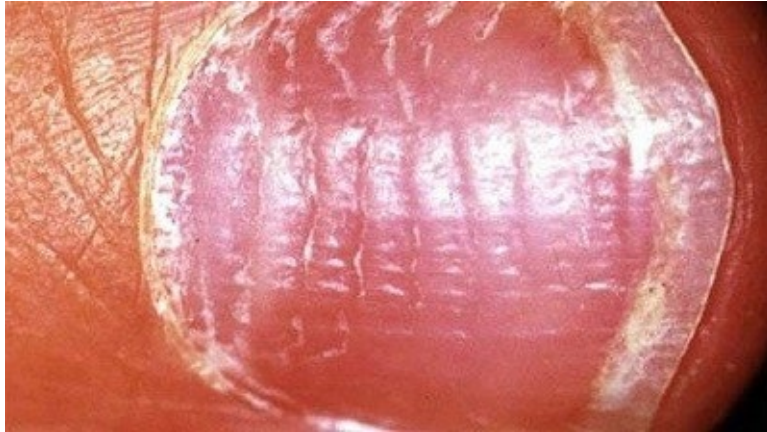### **Nerve supply**

- It is innervated by the radial nerve

### **Action**

- Extensor and abductor of hand at wrist

**293. Which of the following nail findings is seen in the condition shown below?**



a) Pterygium

b) Pigmentation

c) Pitting

d) Ridges

Correct Answer - C

**Answer. C. Pitting**

Nail pitting may show up as shallow or deep holes in your nails.

invalid question id