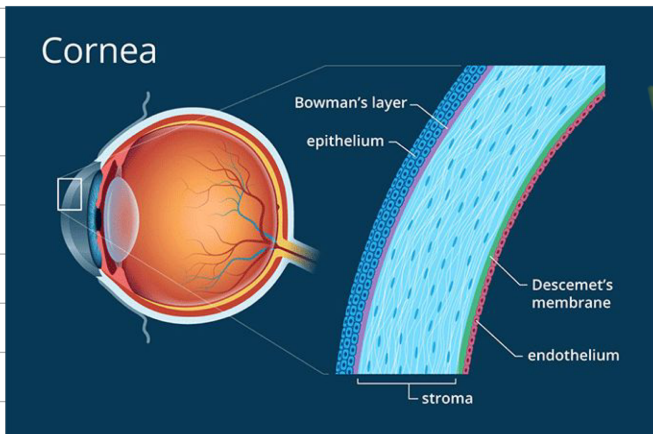

Cornea layers: From outer to inner

- mnemonic A (read as A) 1. Epithelium
 B 2. Bowman's membrane
 C (Read as S) 3. Stroma (thickest)
 D 4. Descemet membrane
 E 5. Endothelium

1. Epithelium :: Outermost layer of cornea.

- Smooth surface: due to non keratinised Squamous epithelium
- Epithelium damage → Heals completely w/out any scar.

2. Bowmen's membrane :: Acellular

↳ Not true Basement !!
 bcz → PAS -ve

- Compact layer of collagen
- Gives integrity to cornea
- Never regenerates on damage
- Scar or opacity formed (Pt can suffer from vision loss)

3. Stroma :: 90% of corneal thickness

- Bed of proteoglycan
 - ↳ Keratan sulphate
 - ↳ Dermatan sulphate

- Regularly arranged of collagen I > II
 ↳ (Provide Transparency)

- Stroma kept in relatively dehydrated state because if water absorbed by cornea it will disrupt the arrangement of collagen leading to haziness.

4. Descemet Membrane : Can regenerate

↳ its thickness can increase throughout life.

- Secreted by endothelium
- Forms basement membrane of endothelium.
- Collagen type IV (All basement membranes have type IV collagen)
- Visualized on Gonioscopy
- Only fungal infection can cross Descemet Membrane.
- Peripheral Termination is known as Schwalbe's line.

Dua's layer:

- ↳ Strongest corneal layer
- its thickness
 ↳ 7-14 μ

5. Endothelium:

- Most important layer for corneal transparency.
- Single layer of Cuboidal cells
- Visualize the endothelial layer by 1. Specular microscopy → Hexagonal pattern
 2. Confocal microscopy.

Normal endothelium count @ Birth → 3000 - 4000 cells/mm³

↓ Uses by age
 ↳ Adult: 2500 - 3000 cells/mm³
 ↳ Old: 2000 cells/mm³

VISION DISORDERS

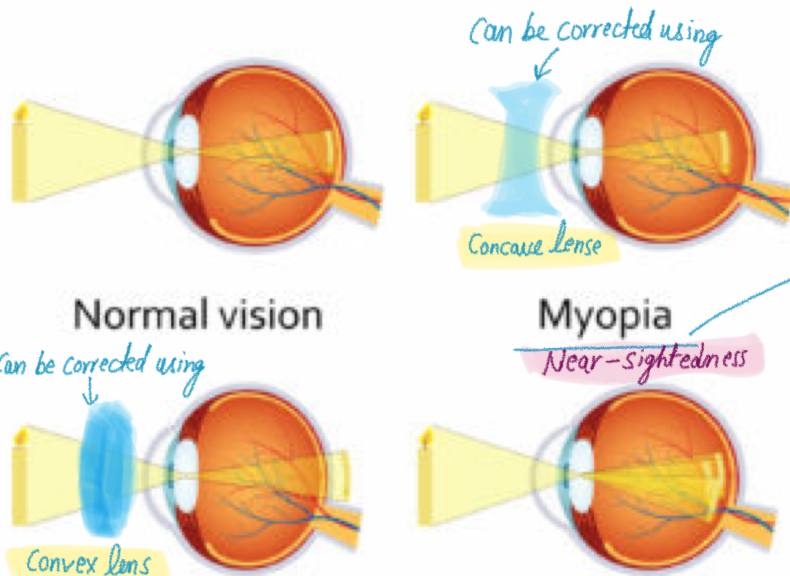


image formed in front of Retina

Near-sightedness

Can be corrected using

Convex lens

Hyperopia

Far sightedness

Image formed behind Retina

Astigmatism

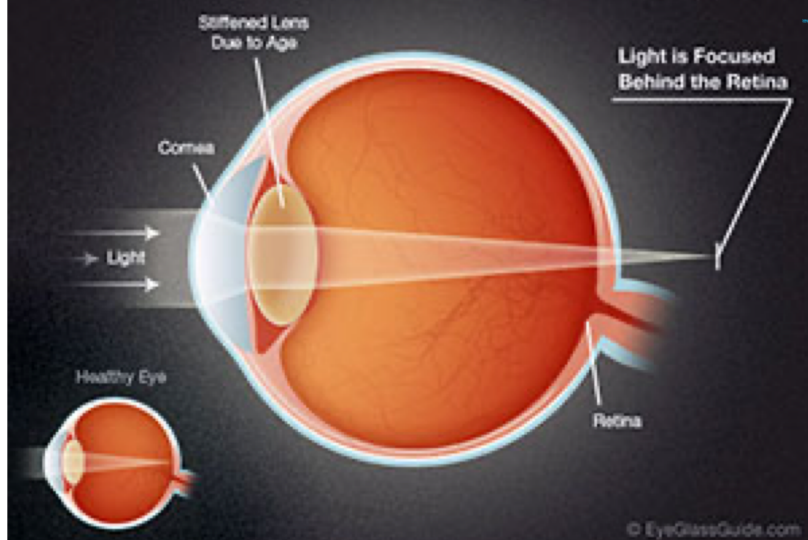
imperfection in the curvature of the eye that causes blurred vision

Objects appears blurry

faraway

Nearby

Presbyopia



Distant objects are clearly visible but nearer " are blurry

- as we age, lens reduces its ability of accommodation

Angular bacterial conjunctivitis

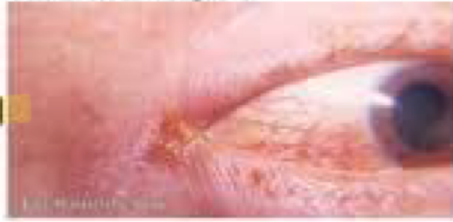- Mild chronic conjunctivitis confined to the conjunctiva & lid margins near the angles

Etiology:

- Moraxella Axenfield Bacil
- Rarely staphylococci

PATHOLOGY:

- Production of proteolytic enzyme
- Causes maceration of epithelium



Symptoms: H/o collection of dirty white foamy discharge at the angles.

- Redness in the angle of eyes
- Irritation burning sensation & feeling of discomfort in the eye.

Rx: Prophylaxis include good personal hygiene.

- Curative Rx: Oxytetracyclin 1% eye oint. 2-3 times/day for 7-14 days

Fungal Corneal Ulcer: m/c fungi: *Aspergillus*



- Patient gives History of trauma i vegetative material.
- e.g. A 52 year old farmer from Rajasthan gives history of injury with Sugar cane 5 days back.

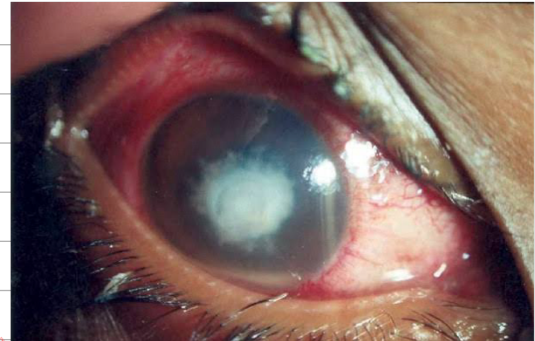Signs >>> Symptoms

Signs: • Dry Looking ulcer.

- Featherly margins of Ulcers.
- Satellite lesions.

• Wessely immune ring.

• Hypopyon: Immobile / thick pus Asterile.

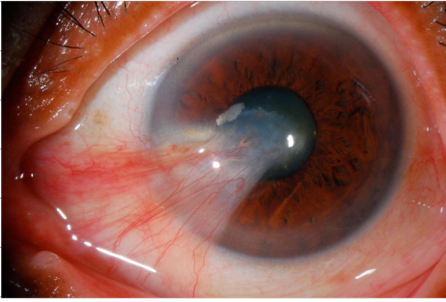


Rx: Anti-fungal - Natamycin 5% eye Drops (DOC in *Aspergillus*, *Fusarium*)
- Amphotericin B (0.15% drops) ← for candida

• Atropine: Supportive therapy.

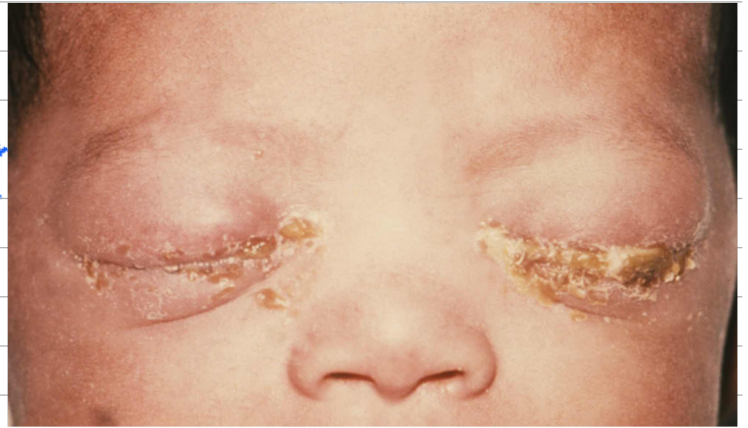• Steroids are contraindicated.

Pterygium: ocular surface lesion originating in the limbal conjunctiva within the palpebral fissure with progressive involvement of cornea.



Ophthalmia Neonatorum:

- ↓
- B/L inflammation of conjunctiva occurring in an infant, less than 1 month old.
- It is a/w catarrhal discharge.
(No tears are formed upto 4 weeks of life)
- The causes may be chemical, chlamydia, Herpes simplex, gonococcus (50%) & other bacteria.



Clinical features:

- Pain & tenderness in the eyeball
- Conjunctival discharge
- Conjunctiva may show hyperaemia & chemosis.
- May develop corneal ulceration

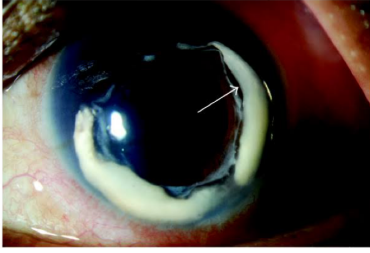
Mx: Prophylaxis needs antenatal, natal & post natal care.

- 1:1 tetracycline for gonococcal infection

- Topical erythromycin ointment &

- I/V or I/M third gen. Cephalosporin (ceftriaxone 30-50mg/kg/day IV or IM)

Cataract Sx complications:



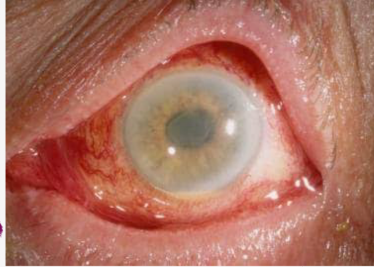- Saemmering Ring
 - Posterior capsule opacification → m/c
 - After cataract Sx.

3

Early postoperative complications

Occurs within the first few days to 4 weeks.

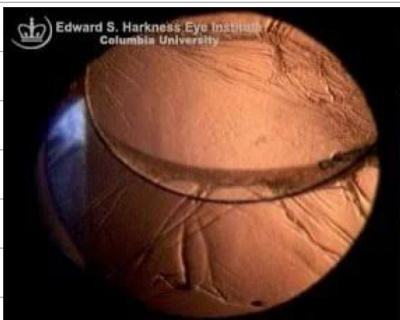- Endophthalmitis
- Retained lens matter
- Corneal edema
- Wound leak and dehiscence
- Toxic anterior segment syndrome (TASS) →



Late postoperative complications

Occurs within months to years.

- Posterior capsule opacification (most common)
- Cystoid macular edema
- Secondary glaucoma
- Retinal detachment
- Intraocular lens malpositions:
 - Windshield wiper syndrome — intraocular lens haptic rubs on the endothelium
 - Sunset syndrome — inferior subluxation
 - Sunrise syndrome — superior subluxation
 - Complete dislocation of the intraocular lens.

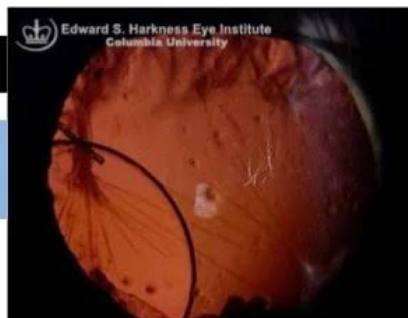

Sunrise syndrome

Misplacement of superior haptic in the ciliary sulcus, The inferior haptic being placed in the bag

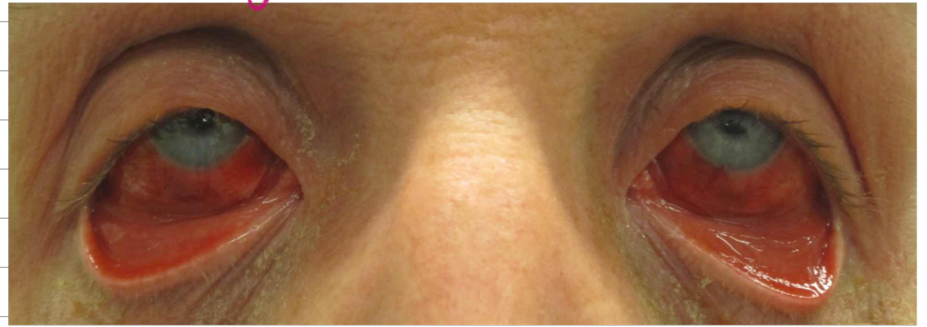
Sunset syndrome

Undetected anterior capsule rupture extending inferiorly allowing the inferior haptic to escape through the defect



Acute Hemorrhagic Conjunctivitis → known as: Pink eye.

- Apallo conjunctivitis
- Causes are ① Picornavirus ← m/c/c
 - Enterovirus type 70
 - Coxsackie A24
- ② Adenovirus type II



Keratoconus: is a form of corneal ectasia.

↳ it is non-inflammatory, progressive, ectasia and usually B/L.

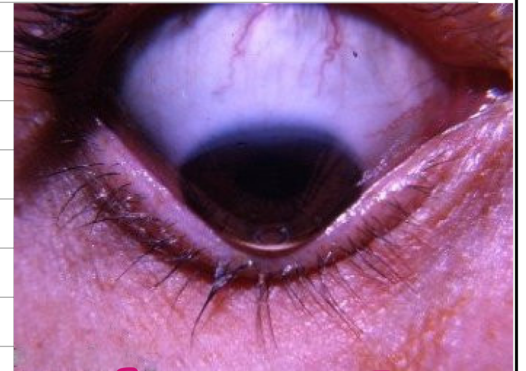
Etiology:

1. Congenital weakness.
2. A/w: Trauma
 - VKC (vernal keratoconjunctivitis)
 - Down syndrome

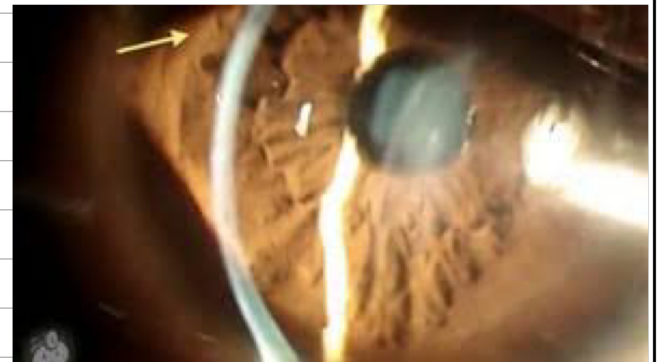- Features: Myopia astigmatism
- Hallmark — Stromal thinning (central / Paracentral)

↓
inferior to centre

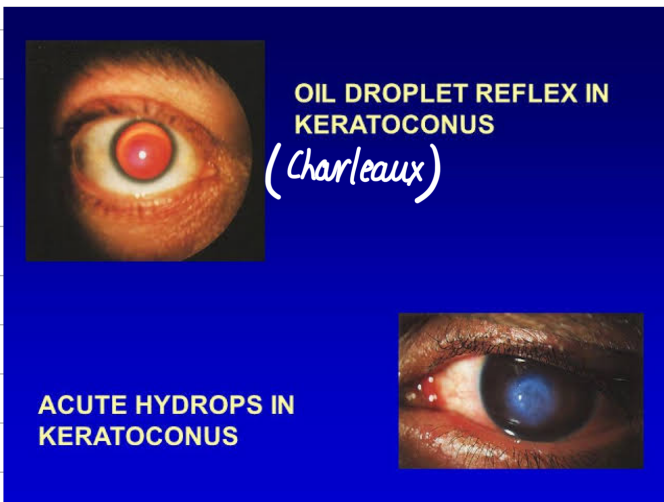
- Munson's sign: Bulging of lower eyelid on downgaze.
- Rizzuti's Sign: Arrowhead pattern of light, formed over nasal limbus when light is thrown from temporal side.
- Oil drop reflex: on ophthalmoscopy
- Scissoring reflex on retinoscopy
- VOGT's striae: Stromal stress line.



[Munson's Sign]



Rizzuti's sign



OIL DROPLET REFLEX IN KERATOCONUS (Charleaux)

ACUTE HYDROPS IN KERATOCONUS

IOC: Corneal topography

- Rx: Rigid contact lens (may lead to opacity)
- Keratoplasty
 - C3R (corneal collagen cross linking using riboflavin & UVA radiation)

Fungal keratitis:

• Causes: Filamentous: *Aspergillus* (tropical area)
Yeast: *Candida* (temperate)

• Risk factor: Agricultural material.
• Ocular surface diseases
• Steroid user, immunosuppression

• Feature: Redness
Photophobia
Pain in eye
mucopurulent discharge

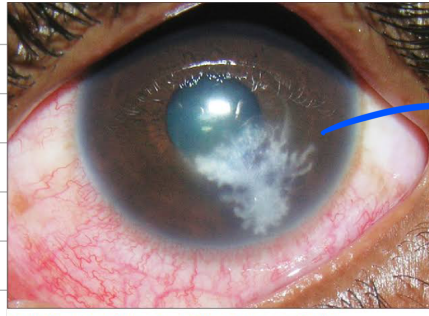
Investigation: • KOH mount

Rx: • Antifungal: • Natamycin 5% eye drops
COC for: *Aspergillus & fusarium*)

Yeast fungal keratitis → *Candida*.

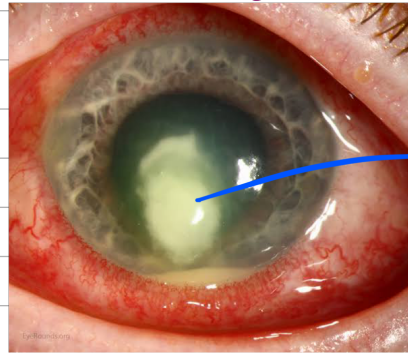
• Amphotericin B 0.15% drops (for *Candida*)
• Atropine - Supportive therapy

* Steroids are C/I



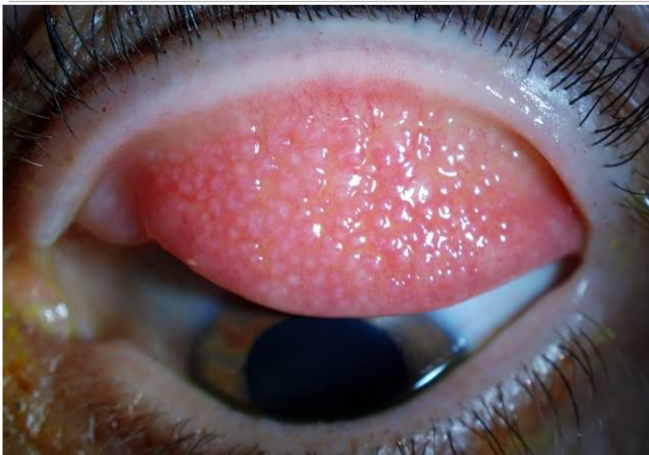Greyish white strands over cornea.

Filamentous fungal keratitis → *Aspergillus*

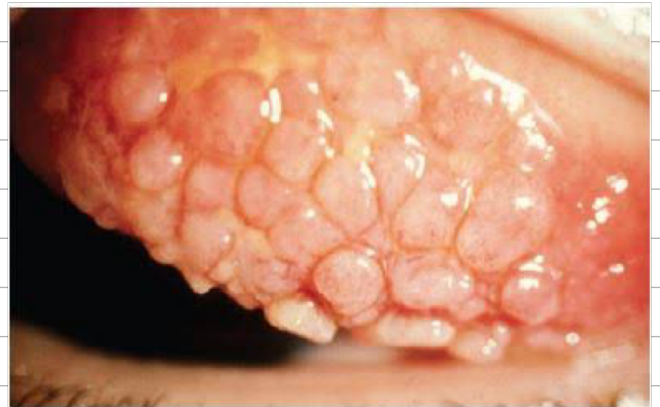

Yellowish white

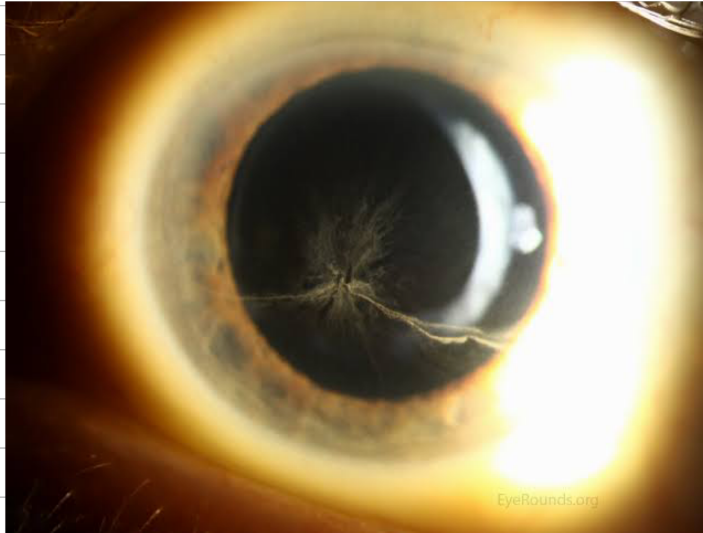Giant papillary Conjunctivitis:



vernal keratoconjunctivitis




Vortex Keratopathy : aka *Cornea Verticillata*



Vortex Keratopathy

Mnemonic - ABCDEF

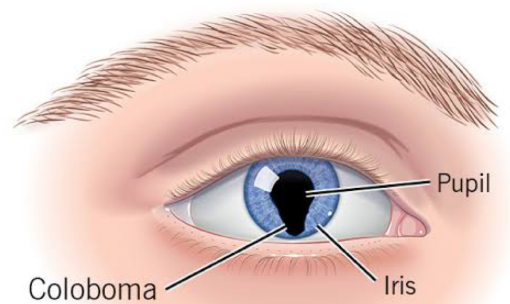
- A** Arthritis (diclofenac)
- B** Breast Cancer (Tamoxifen)
- C** Cardiac (Amiodarone)
- D** Dementia (Chlorpromazine)
- E** Enzyme deficiency
- F** Fabry's Disease



Coloboma of eye :

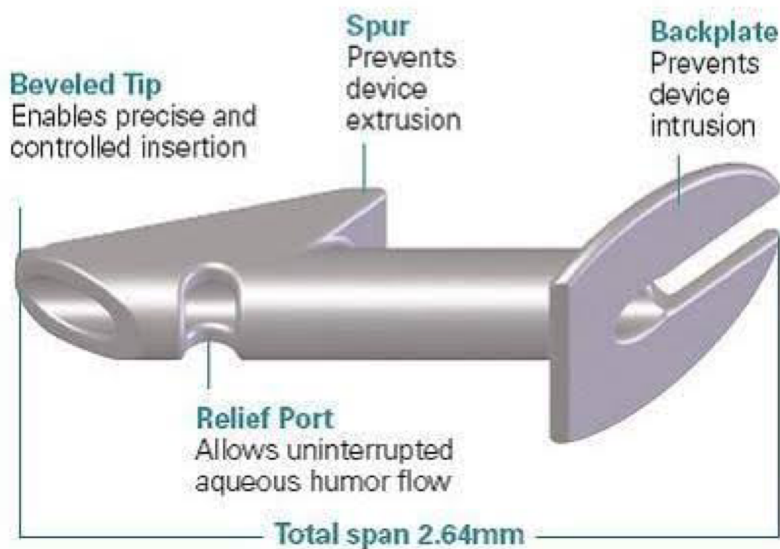
- Treacher - collins syndrome: → *Cat eye Syndrome*
↓
Caused by → *abnormality of chromosome 22q11*
- **CHARGE** association
- Trisomy 13 or 18
- Jacobsen syndrome
- Goldenhar Syndrome
- Meckel Syndrome.

Coloboma



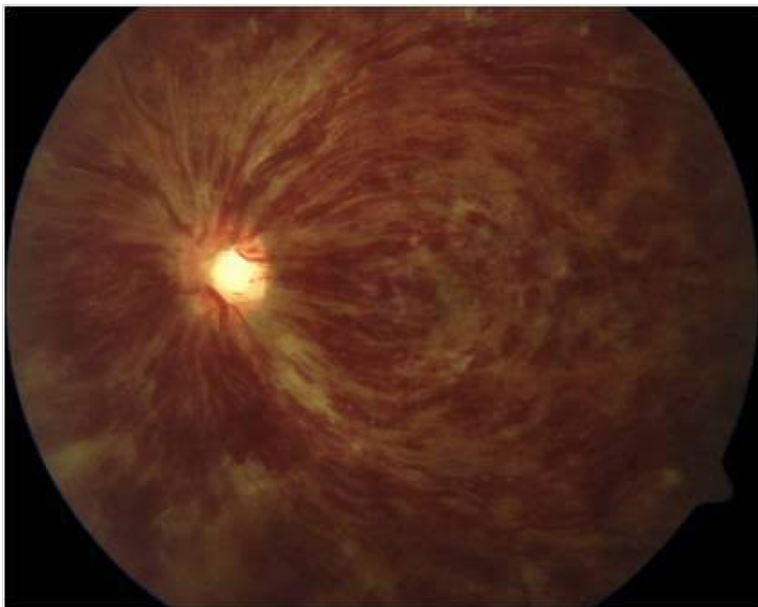©2022 Cleveland Clinic

The Ex-PRESS™ Mini Glaucoma Shunt



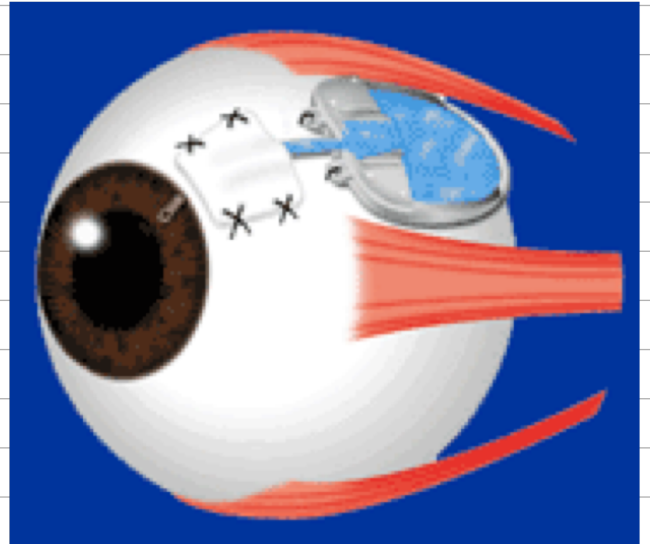
Neovascular Glaucoma : is a severe form of Secondary glaucoma characterised by proliferation of fibrovascular tissue in anterior chamber angle.

aka: 100 day Glaucoma - due to its typical development 3 months after onset of CRVO.



Seton Surgery (Glaucoma Valve)

↓
creating a new channel in sclera for fluid drainage.



Drugs in Glaucoma

↓
Drugs

S/E

- | | |
|-------------------------|---|
| - Beta-blockers | - Corneal Hypesthesia
- Systemic Side effects |
| - Sympathomimetics | - Lid Retraction
- CNS Depression and apnea in infants/children (<2yrs) |
| - Prostaglandin analogs | - Eyelash Hypertrichosis
- Macular edema
- iris pigmentation
- Periorbital fat depletion |
| - Miotics | - Retinal detachment
- Cataract |
| - Carbonic anhydrase ⊖ | - Systemic S/E
- Corneal edema |

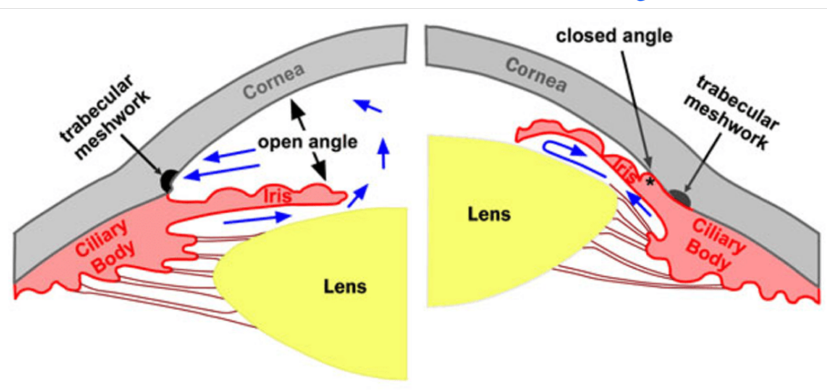
Glaucoma: Definition → 1. Progressive characteristic optic disc changes.
2. Irreversible visual field changes
3. IOP may or may not be raised.

- Raised IOP is a risk factor of Glaucoma.
- Optic disc examination done by ophthalmoscopy
- Visual field testing is done by perimetry
- IOP is measured by tonometry

Angle Closure glaucoma: Structural abnormality → iris moves forward → touches cornea in the periphery → angle closed → Angle closure glaucoma

• Pathology in iris

Rx: Iridectomy



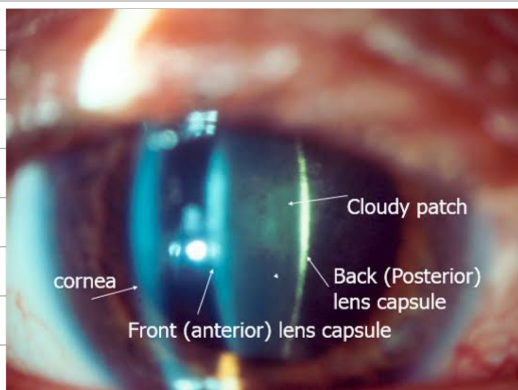
Open angle Glaucoma: Blockage of trabecular meshwork.
Pathology in Trabecular meshwork.

Rx: Trabeculectomy

Senile cataract: 50-70 years

Types (Based on the site of cataract)

- Nuclear
- Cortical
- Posterior Subcapsular
- Anterior Subcapsular

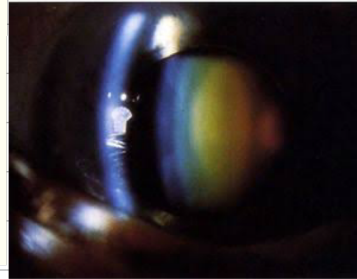
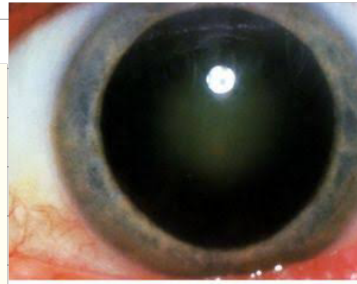


Nuclear Cataract

Due to sclerosis (\uparrow Refractive index $\rightarrow \uparrow$ Refractive power \rightarrow myopia)

Clinical features :

- Refractory error : Index myopia (loss of far vision \rightarrow Near sighted) \rightarrow
- Second sight phenomena (Improvement of near sight).
- Loss of vision is more in day (as centre of the lens is affected, & when pupil constricts bright light, there is loss of vision in daytime)
- Vision improves in dim light
- Xanthopsia : Yellow colored vision (due to the deposition of a yellow colored pigment urochrome in the lens)

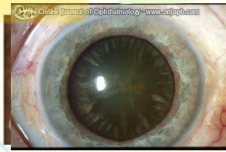

Cortical cataract

- Due to hydration of the lens
Earliest change : Formation of water clefts and vacuoles

Lamellar separation of lens fibres

Cuneiform cataract : wedge shaped opacities
(earliest site : Inferonasal)



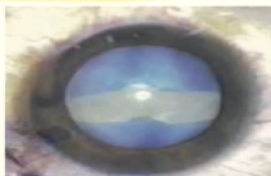
Intumescent cataract
(swollen lens)

m/c complication : Phacomorphic glaucoma
(2° angle closure glaucoma)

Argentinian flag sign :

A complication during cataract surgery

A linear break (instead of circular) of the capsule during continuous curvilinear capsulorhexis (CCC), which occurs due to high intralenticular pressure in the swollen lens.

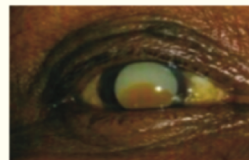


Morgagnian cataract :

Hypermature stage

Cortex liquefies and nucleus sinks down

m/c complication : Phacolytic glaucoma
(secondary open angle glaucoma due to blockage of the secondary trabecular meshwork)



Posterior Subcapsular / cupuliform cataract

Maximum visual loss is seen due to opacity at nodal point.

Loss of vision : Near > Far

Loss of vision is more in day time

Characteristic symptom : Glare

Causes → mnemonic (MNC should Repay GST)



Myotonic dystrophy

Neurofibromatosis type 2

Complicated cataract

R → X-rays

Galactosemia

Steroids

Trauma (blunt)

Steroids side effects in eye :

- PSC
- Glaucoma
- (mnemonic : GTCS)
- Glaucoma is MC with topical steroids.
- Cataract is MC with systemic steroids

Anterior Subscapular cataract



Causes Mnemonic : AACG)



A - Atopic dermatitis

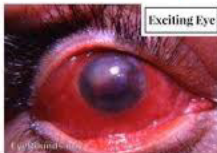A - Amiodarone

C - Chlorpromazine

G - Gold deposits

Sympathetic Ophthalmitis

- It is Bilateral granulomatous non-suppurative panuveitis, which follows a penetrating ocular trauma.
- It involves both eyes. The injured eye is called Exciting eye and the fellow normal eye which also develops uveitis is called Sympathizing Eye.



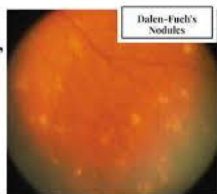Prodromal Symptoms in Sympathizing eye are:

- i) Blurring of vision due to loss of accommodation. (1st Symptom)
- ii) Photophobia.

Clinical Features:

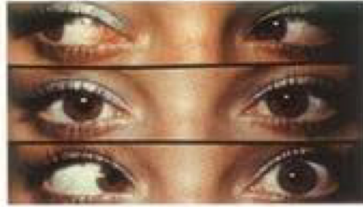
1) Anterior segment: Red and irritable eye, Retrolental flare (Earliest sign), Nodules (Koeppel's and Busacca) on iris, Mutton fat Keratic Precipitates.

2) Posterior segment: Dalen-Fuchs nodules, which are clusters of epithelioid cells containing pigment lying between the Retinal Pigment Epithelium and Bruchs membrane, are seen.



Incomitant squint

- It is a type of heterotropia in which the amount of deviation varies in different directions of gaze.
- 1. Paralytic squint
- 2. 'A' and 'V' pattern heterotropias
- 3. Restrictive squint



Squint types

Non paralytic=concomitant squint.

A-eso-deveation = esotropia= inward deviation.

- 1-Congenital.
- 2-Accommodative (refractive,non-refractive,mixed).

B-exo-deveation = exotropia =outward deviation

- 1-childhood-onset
- 2-sensory-deprivation.
- 3-convergence-insufficiency

Paralytic strabismus

3RD(Oculomotor)cranial nerve palsy(all extraocular muscles involved except the lateral rectus & the superior oblique muscle)

6th cranial nerve (Abducent)=paralysis of lateral rectus muscle .

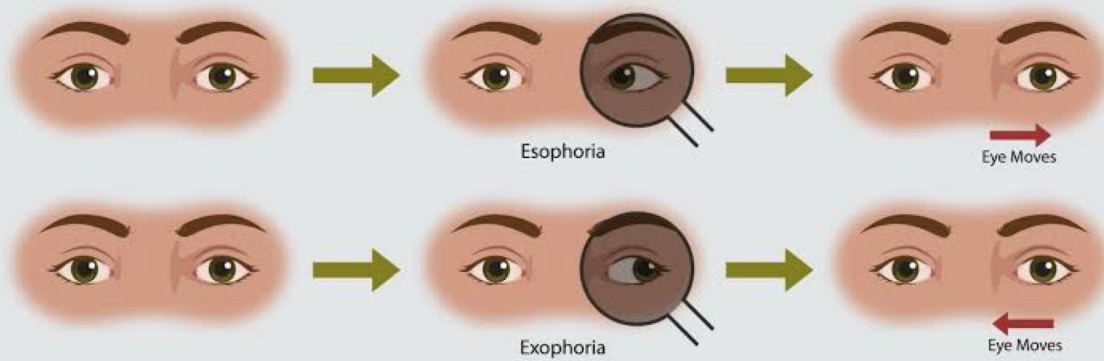
4th cranial nerve (Trochlear)=paralysis of superior oblique muscle

Maddox Rod



- Equipment - maddox rod and light source
- Will detect position of eye; eso, exo, hyper or hypo will not differentiate from a phoria or tropia
- Rods of maddox rod placed vertically will detect hyper/hypo
- Rods of maddox rod placed horizontally will detect eso/exo

Cover-uncover Test



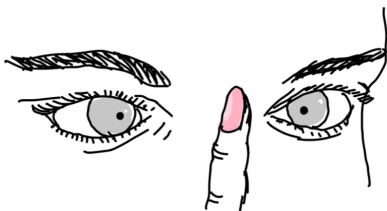
GEEKYMEDICS.COM

The cover-uncover test is useful to identify a tropia and differentiate it from a phoria. The test is done by using an opaque or translucent occluder to cover one eye. The occluder is held in front of the eye for a few seconds and then removed.

Argyll Robertson pupil features



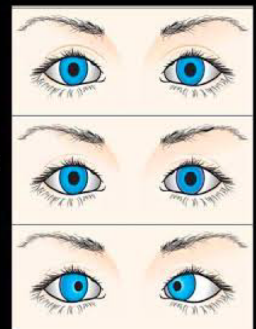
Pupils DO **NOT** constrict when exposed to bright light. ("light reflex")



Pupils DO constrict on a near object. ("accommodation reflex")

ARGYLL - ROBERTSON PUPIL

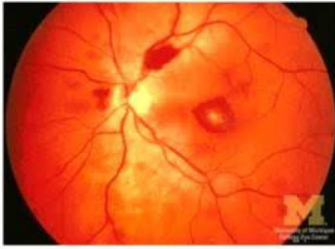
- Bilateral miotic, irregular pupils
- Caused by lesion in the pretectal area
- Light reflex is absent
- Accommodation reflex is present
- Pupils dilate very poorly with mydriatics
- Most commonly seen in tertiary neurosyphilis
- Other causes- diabetes, Wernicke's encephalopathy, midbrain tumors



PSEUDO ARGYLL ROBERTSON PUPIL

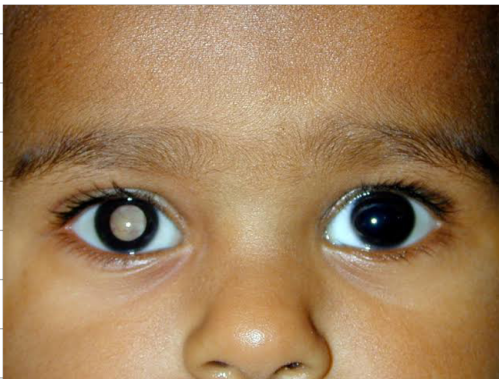- Third nerve palsy with aberrant regeneration of medial rectus innervation into sphincter pupillae.
- Near reflex present, light reflex absent

Roths spots



- Retinal hemorrhage with pale centre
- Flame shaped hemorrhage
- Coagulated fibrin, ischemia, inflammation and infection
- Infective endocarditis
- SLE, Leukemia, HIV retinopathy

Retinoblastoma



Retinoblastoma Symptoms

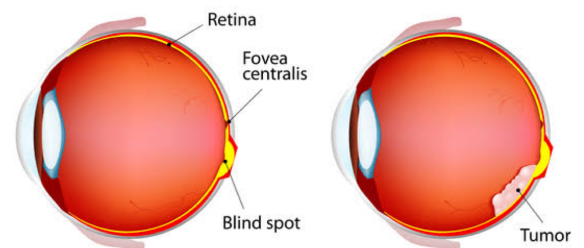
- Pupil that appears white instead of black
- Crossed eye
- Problems with vision or total loss
- Red, irritated eye
- Bulging or enlarged pupil or eyeball
- Different colored irises



- ↓
- m/c primary intraocular malignancy.
 - incidence → 1:17,000
 - RB-1 gene → Tumor suppressor gene → Located in 13q,14
 - m/c associated malignancy, Pinealoblastoma or PNET

Healthy eye

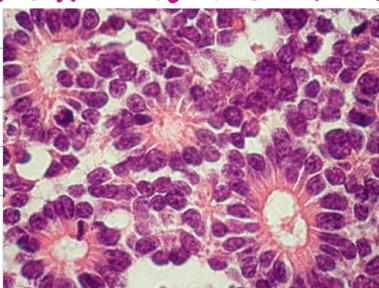
Retinoblastoma



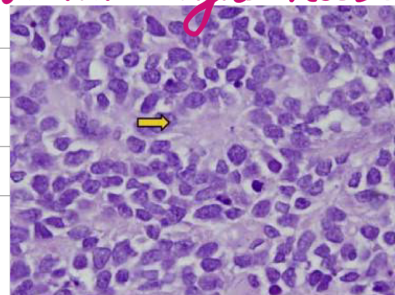
Rx: TOC → Enucleation

- Chemotherapy: C - Carboplatin
- E - Etoposide
- V - Vincristine

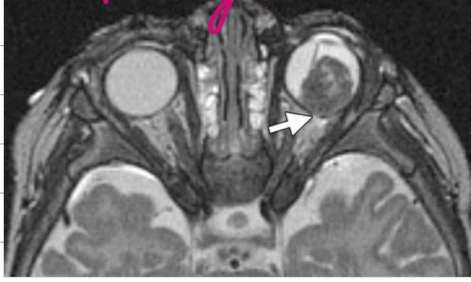Flexner - Wintersteiner rosettes



Homer Wright Rosettes

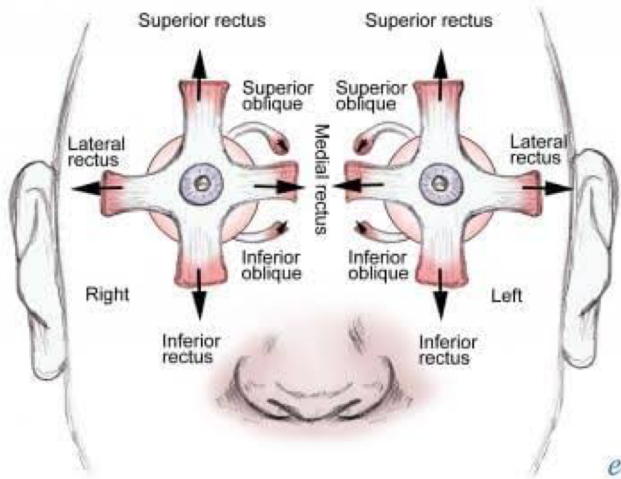


MRI showing Retinoblastoma.

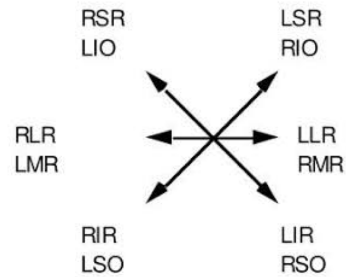


Reese Ellsworth classification for retinoblastoma

Group	Prognosis for maintenance of sight	Features
1	Very favourable	<ul style="list-style-type: none"> Solitary tumor, <4DD, at or behind equator Multiple tumors, all <4DD, all at or behind the equator
2	Favourable	<ul style="list-style-type: none"> Solitary tumor, 4–10 DD, at or behind the equator Multiple tumors, all 4–10DD all behind the equator
3	Possible	<ul style="list-style-type: none"> Any lesion anterior to equator Solitary tumor, >10DD behind equator
4	Unfavorable	<ul style="list-style-type: none"> Multiple tumors, some >10 DD Any lesion extending anteriorly to ora serrata
5	Highly unfavorable	<ul style="list-style-type: none"> Massive tumors involving more than one half of retina Vitreous seeding



Yoke muscles



Myasthenia Gravis

Myasthenia Gravis

• Fluctuating muscle weakness with muscle fatigue
worse after activity (<5% proximal limb weakness)

• Asymmetrical ptosis and diplopia (50%):

1. Ptosis: Unilateral/bilateral.

Curtain: on trying to lift the ptotic eye, the other eye goes for ptosis.

Peak sign: Can't close the eyes tightly, as eyelashes are not buried as in normal individuals.

Increased ptosis on sustained upgazed.

2. Diplopia: Binocular diplopia.

m/c muscle involved: *Medial rectus*.

Pupils sparing 3rd nerve palsy.

• Cogans lid twitch: overshoot of the lids when the patient suddenly looks up.

• Chronic progressive external ophthalmoplegia.

• Expressionless facies

• Drooped posture

• Lower limb: Typically hip muscles.

• Respiratory muscle weakness.

mnemonic: **ABCDE**

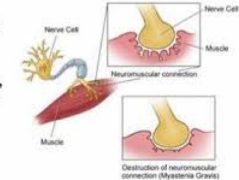
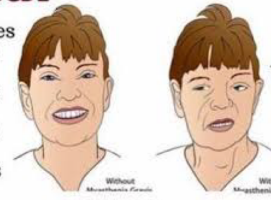A Aminoglycosides
streptomycin
macrolides
Azithromycin
Quinolones
ciprofloxacin

B Beta-Blockers & Botulinum

C Chlorquine & quinine

D D-tubocurarine, vecuronium

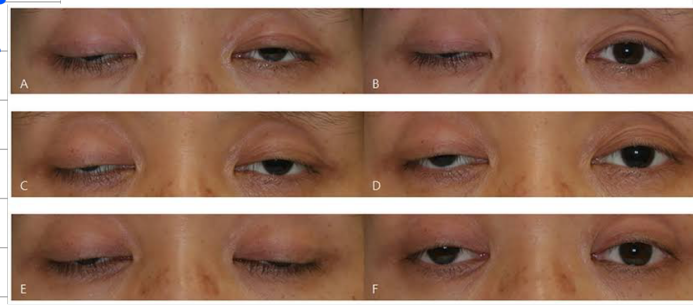E magnesium



Features:

ptosis
hypoventilation
muscle wasting,
weakness
breathing difficulty
diplopia
BF
skin/mucosa
pale cyanotic
headache
dysrhythmia

drowsiness, dizzy
food regurgitation
difficulty in chewing
dysphagia
diurnal variation
rest improves muscle strength



Macular function tests

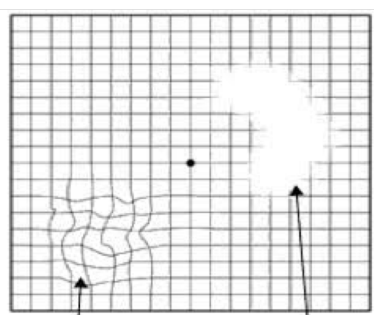
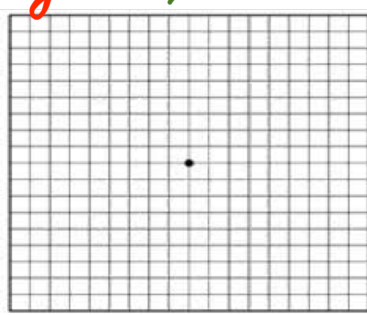
1. Clear media: Visual acuity measurement.

- FFA
- OCT

→ *Photo stress test* (shine light on retina for 10 sec record time of recovery of vision within one line of pre test vision.

if time normal: optic nerve disease, if time delayed: macular disease).

- *Amsler's grid*: m/c test (wavy lines)



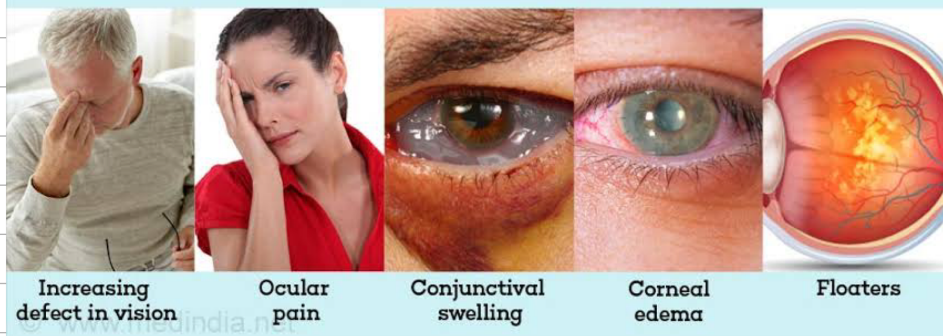METAMORPHOSIA (DISTORTION) SCOTOMA (BLIND SPOT)

2. Hazy media : • Maddox rod test.
- Multifocal ERG
 - Li (Laser interferometry)
 - PAM (Potential Acuity meter)
 - Entoptic phenomenon

Endophthalmitis :

↓
Purulent inflammation of the intraocular fluids (vitreous and aqueous) usually due to infection.

Symptoms of Endophthalmitis



Increasing defect in vision

Ocular pain

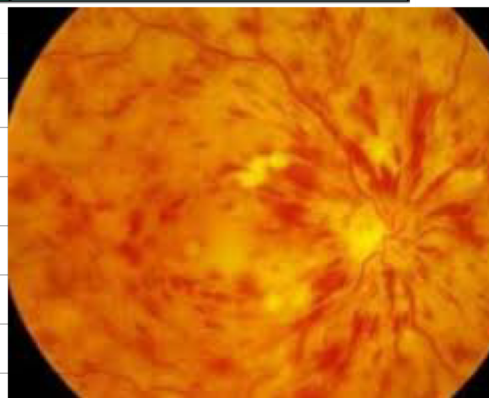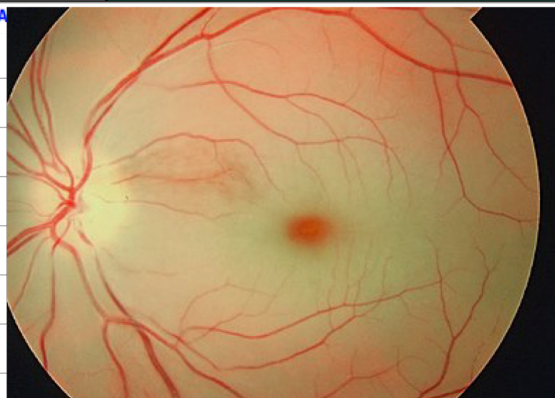Conjunctival swelling

Corneal edema

Floaters

	CRAO CENTRAL RETINAL ARTERY OCCLUSION "eye stroke"	CRVO CENTRAL RETINAL VEIN OCCLUSION "eye dvt"
CLINICAL	Sudden, profound vision loss Painless Monocular	Variable - blurred vision to sudden vision loss Painless Monocular
ETIOLOGY	Embolism Vasculitis Vasospasm Sickle Cell Trauma Glaucoma	Risk factors include: Typical stroke risk factors Hypercoagulable states Glaucoma Compression of the vein in thyroid or orbital tumors
DIAGNOSIS	Retinal pallor Macular cherry red spot +/- Afferent pupillary defect	Optic disk edema Diffuse retinal hemorrhages ("blood-and-thunder")
TREATMENT	Consult ophtho + neurology Case reports of intra-arterial TPA Limited evidence for treatment: possibly digital massage, lowering intraocular pressure	Consult ophtho + neurology No specific treatment

@FOA



Retinitis Pigmentosa

- m/c hereditary fundus dystrophy.
- m/c mode of inheritance: **Autosomal Recessive.**
- Autosomal dominant: **Best Prognosis**
- X-linked recessive: **worst prognosis.**

Symptoms: It is a **rod-cone dystrophy.**
• Initially, rods are affected and later Cones.

- mild peripheral superior scotoma.
- **Ring scotoma** or doughnut scotoma (Central vision preserved and peripheral vision loss)
- Tubular or tunnel vision.

- Signs:
1. **Arteriolar attenuation**
 2. Optic disc: **waxy, pale** (consecutive optic atrophy)
 3. **Bony spicule pigmentosa** (perivascular)
 4. **Shining reflex** at macula known as **tapetal reflex**: only in **X-linked recessive female carriers.**

Diagnosis: **IOC-ERG** (Electroretinography)

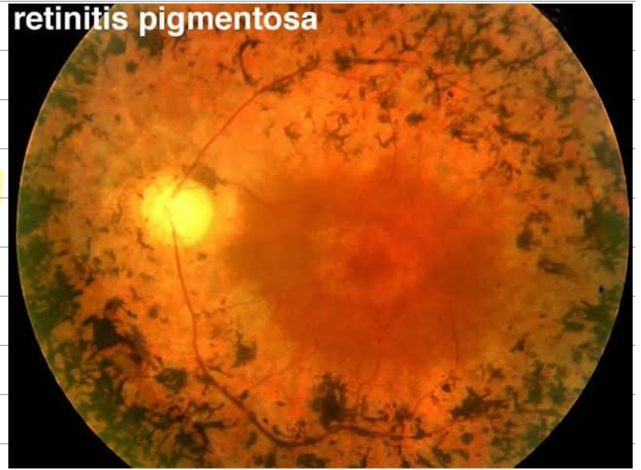
Rx: In India: No Treatment

The possible treatment: • **ARGUS II retinal prosthesis**: Restores only central 20° vision.

• **Voretigene neparvovec**: Used if there is biallelic RPE65 gene mutation.

It is adeno associated virus vector based gene therapy.

retinitis pigmentosa



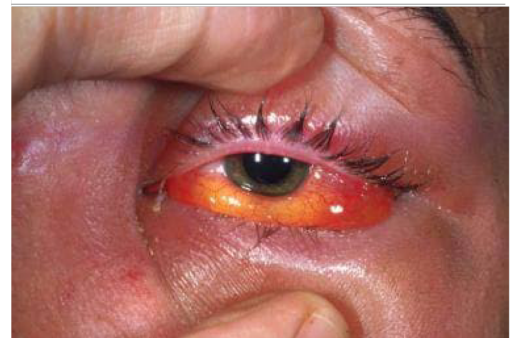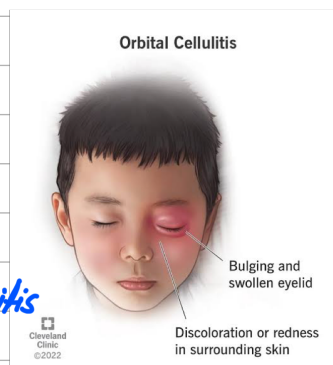
Orbital Cellulitis

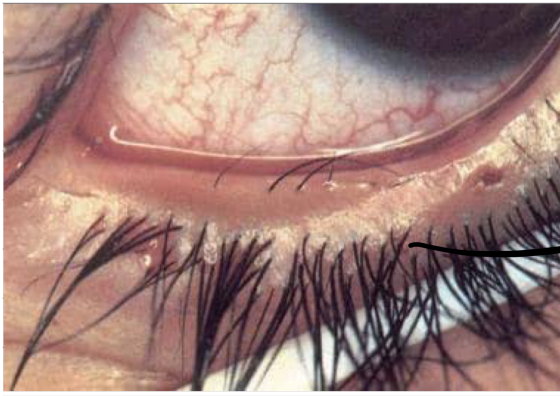
- Usually occurs as an extension from **Paranasal sinuses.**

- Predisposing cause: **Ethmoidal sinusitis**

- Unilateral

- 3rd/4th/6th Cranial nerve involved: **Complete ophthalmoplegia.**





Distichiasis

Cavernous sinus thrombosis

Flash Card

Facts

- Most cases secondary to infection located in the medial aspect of the face around the eyes and nose
- A blood clot in your cavernous sinuses.

History / PE

- Headache, low grade fever
- Bilateral periorbital edema
- Double vision (CN palsy)
- confusion
- seizures

Diagnosis

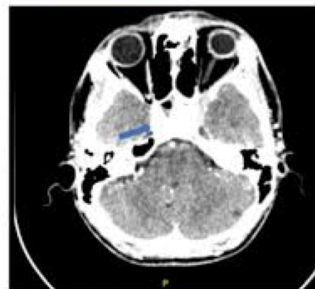
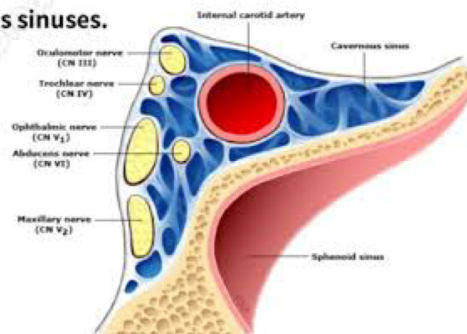
- MRI or CT of orbits with contrast

Treatment

Broad spectrum antibiotics

Differential Diagnosis

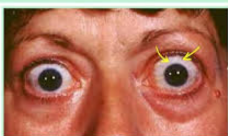- Orbital cellulitis (B/L periorbital edema and CN palsies rare)
- Acute angle-closure glaucoma
- Brain abscess (no eye symptoms)



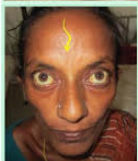@<https://medicolearning.com/>

medicolearning

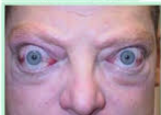Ocular signs of Thyrotoxicosis



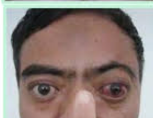Dalrymple sign: Rim of sclera is seen all around the cornea, on looking straight forward



Joffroy's sign: Lack of wrinkling of the forehead when a patient looks upward



Stellwag's sign: Staring look with infrequent blinking



Mobius sign: Lack of convergence on looking to near object

MED NAZ

