

1. Post-transplantation hypertension can be caused by: I. Rejection. II. Cyclosporine nephrotoxicity. III. Renal transplant artery stenosis (RTAS). IV. Recurrent disease in the allograft.

a) I,II,III,IV are correct

b) I,II,IV are correct.

c) I & III are correct

d) None of the above is correct.

Correct Answer - A

Both acute and chronic rejection may result in hypertension. The former causes acute fluid retention and plugging of peritubular capillaries with inflammatory cells. This may progress to intimal swelling and medial necrosis and eventuate in ischemia secondary to endothelial proliferation and obliteration of small vessels. Chronic rejection, thought to be related to protracted humoral injury, results in obliteration of capillaries via the development of intimal hyperplasia. Cyclosporine has a vasoconstrictive effect which, through activation of the renin-angiotensin system, may lead to hypertension. RTAS is responsible for hypertension in 4% to 12% of renal allograft recipients. It responds well to percutaneous angioplasty. A careful trial of angiotensin-converting enzyme inhibitors may be diagnostic of RTAS. Recurrent disease such as membranoproliferative glomerulonephritis and focal glomerular sclerosis may result in significant hypertension in renal allograft recipients.

2. Most common cause of small intestine obstruction is?

a) Intussusception

b) Idiopathic adhesions Tumors

c) Tumors

d) Postoperative adhesions

Correct Answer - D

Postoperative adhesions REF: Bailey & Love 25th edition page 1188, <http://emedicine.medscape.com/article/774140overview>
"The most common cause of small-bowel obstruction (SBO) is postsurgical adhesions"

The most common causes of intestinal obstruction in adults are:

- Intestinal adhesions — bands of fibrous tissue in the abdominal cavity that can form after abdominal or pelvic surgery
In children, the most common cause of intestinal obstruction is telescoping of the intestine (intussusception).

3. Best method to treat a large port-wine hemangioma is?

a) Radiotherapy

b) Tattooing

c) Excision with skin grafting

d) Pulsed dye Laser


Correct Answer - D

Pulsed dye Laser REF: Roxburgh's common Skin Diseases 17th edition page 194 & 205, Clinical Dermatology by John Hunter, John Savin & Mark Dahl 3rd edition page 275

"Selective Photothermolysis or Pulsed dye laser is the treatment of choice for Portwine hemangioma"

Port-wine stains are crimson blotches in which there is marked capillary dilatation compared to a capillary angioma, which is a red nodule or plaque containing proliferating endothelial cells. The latter tend to flatten and disappear at puberty. Larger ones may cause problems from bleeding and/or erosion. Cavernous haemangiomata are larger and compressible, containing large vascular spaces. Occasionally a port-wine stain of the trigeminal area is associated with a vascular malformation of the leptomeninges on the same side, which may cause epilepsy or hemiparesis (the SturgeWeber syndrome), or with glaucoma.

Excellent results have been obtained with careful and time-consuming treatment with a 585-nm flashlamp-pumped pulsed dye laser. Treatment sessions can begin in babies and anaesthesia is not always necessary. If a trial patch is satisfactory, 40-50 pulses can be delivered in a session and the procedure can be repeated at 3-monthly intervals.



4. Cock's peculiar tumor is

a) Basal cell CA

b) Squamous cell CA

c) Ulcerated sebaceous cyst

d) Cylindroma

Correct Answer - C

Ulcerated sebaceous cyst [*Ref. Love & Bailey 23/e page 173, 595; Das text book of Surgery 3/e p81*] Repeat from May 04

- Cock's peculiar tumour is a sebaceous cyst linked growth that can resemble a squamous cell carcinoma.

The proliferating cyst is usually solitary, but it often arises from a simple trichilemmal cysts in the hair follicle epithelium.

5. False about Gastric lymphoma is:

a) Stomach is the most common site

b) Associate with H. pylori infection

c) Total gastrectomy with adjuvant chemotherapy is the treatment of choice

d) 5 yr survival rate after treatment is 60%.

Correct Answer - C

Total gastrectomy with adjuvant chemotherapy is the treatment of choice [Ref: Sabiston 18/e p1269 (17/c p1312); Harrison 17/e, p 573; Schwartz 9/e p935 (8/e, p981)]

- Stomach is the most common extranodal site of lymphoma.
- It is of two types - *Primary & Secondary*
- Primary gastric lymphoma - *is lymphoma of the stomach which exhibits no evidence of liver, spleen, mediastinal lymph nodes or bone marrow involvement at the time of diagnosis (regional lymph node involvement may be present)*
- Primary gastric lymphoma is mainly (>95%) *Non-Hodgkin's lymphoma of B cell origin.*
- Most of the primary lymphomas (about 60%) arise in MALT (*mucosa associated lymphoid tissue*). MALT is usually associated with *chronic H. pylori infection*. So low-grade MALT lymphomas are thought to arise because of chronic H. pylori infection. These low grade lymphomas may later on degenerate to *high grade lymphomas*
- Immunodeficiency and H. pylori infection are risk factors for B cell lymphoma.
- Most common site of involvement (like that of adenocarcinoma) is *gastric antrum.*

- Secondary gastric lymphoma
- Stomach is the *most common extranodal site of systemic lymphoma.*
- *Almost all of them are Non-Hodgkins types*
- Treatment
- The role of gastric resection is controversial. Recent studies have shown similar disease free 5 year survival rates in patients treated with surgery+chemotherapy+radiotherapy and patients treated with chemotherapy+ radiation therapy alone. (Most patients with high grade gastric lymphomas are now treated with chemoradiation alone, without surgical resection. For disease limited to the stomach and regional nodes, radical subtotal gastrectomy may be performed, especially for bulky tumors with bleeding and/or obstruction.)
- Most common chemotherapeutic regimen is – CHOP plus *rituximab* [*CHOP stands for cyclophosphamide, doxorubicin, vincristine, & prednisone*]
- about option d i.e. (5 yr survival rate after treatment is 60%.)
Harrison 17/e writes- "Subtotal gastrectomy, usually followed by combination chemotherapy, has led to 5-year survival rates of 40-60% in patients with localized high-grade lymphomas."

6. Which one of the following preservative is used while packing catgut suture?

a) Isopropyl alcohol

b) Colloidal iodine

c) Glutaraldehyde

d) Hydrogen peroxide

Correct Answer - A

10% isopropyl alcohol is the routine packing fluid used in packing catgut sutures.

Catgut is available in glass tubes containing isopropyl alcohol and small quantity of water.

Catgut is prepared from the intestine of sheep.

Ref: Pharmaceutics By Dr. R. S. Gaud, Page 196; Veterinary Medicine/small animal clinician, Volume 72, Issues 1-6, Page 835.

7 Primary hyperparathyroidism, pheochromocytoma may be associated with which type of thyroid cancer?

a) Medullary carcinoma of the thyroid

b) Papillary carcinoma of the thyroid

c) Anaplastic carcinoma of the thyroid

d) Follicular carcinoma of the thyroid

Correct Answer - A

It is characterized clinically by medullary thyroid carcinoma (MTC), pheochromocytoma, and hyperparathyroidism. Approximately 70-95% of individuals with MEN 2A develop MTC, 50% develop pheochromocytoma, and 15-30% develop hyperparathyroidism.

Ref: Bailey and Love's Short Practice of Surgery, 24th Edition, Page 802; Harissons Internal Medicine, 18th Edition, Chapter 351.

8. The treatment of choice for squamous cell anal cancer?

a) Laser fulgaration

b) Chemoradiotherapy

c) Abdominoperennial resection

d) Platinum-based chemotherapy

Correct Answer - B

Squamous cell anal cancer is rare but associated with Human papilloma virus infection (HPV), Anal intra-epithelial neoplasia (AIN) and immunosuppression.

The current treatment of anal canal carcinoma is chemoradiotherapy (combined modality therapy).

Chemotherapy include a combination of 5-FU with mitomycin C or Cisplatin.

Ref: Bailey and Love Short Practice of Surgery, 25th Edition, Page 1269; The MD Anderson Manual of Medical Oncology, 2nd Edition, Chapter 22.

9. Meconium ileus is associated with:

a) Cystic fibrosis

b) Infant of diabetic mother

c) Hypothyroidism

d) None of the above

Correct Answer - A

Infants with cystic fibrosis have characteristic pancreatic enzyme deficiencies and abnormal chloride secretion in the intestine that result in the production of viscous, water-poor meconium.

Meconium ileus occurs when this thick, highly viscous meconium becomes impacted in the ileum and leads to high-grade intestinal obstruction.

Ref: Schwartz's principle of surgery 9th edition, chapter 39.

10. Commonest type of anal canal carcinoma is?

a) Squamous cell carcinoma

b) Adenocarcinoma

c) Adenoacanthoma

d) Papillary type

Correct Answer - A

Squamous cell carcinoma is the most common type of anal cancer. This cancer begins in the outer lining of the anal canal.

Mainly three types of malignant neoplasm are seen in anal canal

- Squamous cell carcinoma (most common)
- Basal cell carcinoma (2nd most common)
- Melanoma

Also remember:

Most common type of rectal and colon cancer **Adenocarcinoma**

Ref: S. Das textbook of surgery 3/e, Page 1078.

11. Which of the following nerve is commonly damaged during McBurney's incision?

a) Subcostal nerve

b) 10th thoracic nerve

c) 11th thoracic nerve

d) Iliohypogastric nerve

Correct Answer - D

The nerve commonly damaged during McBurney's incision is Iliohypogastric Nerve. Damage to this nerve result in the development of right inguinal hernia.

Mc Burney's incision/ grid iron incision is commonly done for appendectomy. In this an oblique incision is made in the right iliac fossa about 5cm above and medial to the anterior superior iliac spine at right angle to the spino umbilical line.

Ref: Anatomy of Abdomen and Lower Limb By Singh, Page 46.

12. Dysphagia lusoria is due to?

a) Esophageal diverticulum

b) Aneurysm of aorta

c) Esophageal web

d) Compression by aberrant blood vessel

Correct Answer - D

Dysphagia lusoria is a disorder of swallowing caused due to vascular anomalies and includes:

- A right aortic arch
- A double aortic arch
- A vascular constricting ring formed by a PDA or a ligamentum arteriosum and pulmonary artery or aortic arch
- An abnormal right subclavian artery
- An abnormal innominate artery

Diagnosis is made by lipoidal swallow or arteriography.

Ref: Bailey and Love 24/e, Page 995

13. All of the following are causes of hemobilia, EXCEPT:

a) Trauma to Abdomen

b) Malignancy

c) Rupture of hepatic artery aneurysm

d) Hepatitis

Correct Answer - D

Hemobilia presents with the triad of biliary colic, obstructive jaundice, and occult or gross intestinal bleeding.

Causes are,

- Hepatic trauma
- Ductal parasitism (*Ascaris lumbricoides*)
- Oriental cholangiohepatitis
- Hepatic neoplasms
- Rupture of a hepatic artery aneurysm
- Hepatic abscess
- Choledocholithiasis

The diagnosis may be suspected from a technetium-99m-labeled red blood cell scan, but an arteriogram is usually required for diagnosis and planning of therapy.

Ref: Doherty G.M. (2010). Chapter 25. Biliary Tract. In G.M. Doherty (Ed), *CURRENT Diagnosis & Treatment: Surgery, 13e*.

14. Linitis plastica is a type of :

a) Gastric ulcer

b) Ca stomach

c) Duodenal ulcer

d) None of the above

Correct Answer - B

Linitis plastica is a type of adenocarcinoma. Adenocarcinoma is the most common form of stomach cancer. Linitis plastica spreads to the muscles of the stomach wall and makes it thicker and more rigid.

Linitis plastica is a subtype of gastric cancer that is characterized by diffuse infiltrating adenocarcinoma without obvious carters and ulcers.

It is thought to originate from parietal cell portion of gastric mucosa.

Because of its diffuse nature ,this form of gastric cancer ususally involves the whole stomach.

Ref : Clinical Scenarios in Surgical Oncology edited by Vijay P. Khatri

15. Surgery for undescended testis is recommended at what age?

a) 6 months

b) 12 months

c) 24 months

d) 36 months

Correct Answer - A

Optimum age for surgery in case of undescended testis is 6 months.

The surgical procedure done is called orchidopexy.

Earlier intervention (Six months of age) should be considered in order to theoretically prevent the complications of cryptorchidism that may be manifested before 1 year of age.

Ref: Nursing care of the pediatric surgical patient By Nancy Tkacz Browne, Page 147-8; CPDT, 20th Edition, Page 974; Campbell's Urology, 9th Edition, Page 3775

16. A patient who has fallen over a loose manhole cover is brought to the clinic. On examination a perineal hematoma and blood in the external meatus is noted. Rupture of which of the following structure has resulted in perineal hematoma?

a) Rupture of membranous urethra

b) Rupture of bulbar urethra

c) Pelvic organ blunt trauma

d) Rupture of bladder

Correct Answer - B

The **bulbar urethra** is crushed upwards onto pubic bone, typically with significant bruising.

Cycling accidents, loose manhole cover and gymnasium accidents astride the beam account for number of cases.

CLINICAL FEATURES

The signs of a ruptured bulbar urethra are perineal bruising and haematoma, typically with a butterfly distribution. There is usually bleeding from the urethral meatus and retention of urine is also typically present.

Rupture of the membranous urethra typically occurs in association with a fractured pelvis and may be associated with an extraperitoneal rupture of the bladder.

The most common causes of pelvic fracture are road traffic accidents, severe crush injuries and falls.

The clinical features include urinary retention, blood at the urethral meatus.

There is typically marked bruising of the pubic area, scrotum and penis.

17. Commonest carcinoma that can cause splenic metastasis is which of the following?

a) Ca. Pancreas

b) Ca. Stomach

c) Ca. Ovary

d) Ca. Cervix

Correct Answer - C

Although isolated metastasis to spleen is rare, studies found the most common primary neoplasms with splenic metastasis to be gynecologic (61%), with majority being ovarian, colorectal (15%), lung (9%), and stomach (4%).

Ref: CT and MRI of the Abdomen and Pelvis: A Teaching File edited by Pablo R. Ros, Koenraad J. Morteles, 2006, Page 218.

18. Spleniculi are seen most commonly in:

a) Colon

b) Hilum

c) Liver

d) Lungs

Correct Answer - B

Spleniculi or accessory spleens are most commonly (about 80%) seen at the *hilum* of the spleen.

Also know:

Location of accessory spleen in decreasing order are:

- Splenic hilum
- Gastrocolic ligament
- Tail of pancreas
- Greater omentum
- Greater curvature of stomach
- Splenocolic ligament
- Small and large bowel mesentery
- Left broad ligament of women
- Left spermatic cord in men

Ref: Schwartz 9/e, Page 1246; Bailey & Love 25/e, Page 25/e, Page 1103

19. Which of the following stage of Breast Ca corresponds with following feature?

Breast mass of 6 x 3 cm. size
Ipsilateral supraclavicular lymph node
Distant metastasis cannot be assessed

a) T4 N3 MX

b) T4 N1 M1

c) T4 N0 M0

d) T3 N3c MX

Correct Answer - D

According to TNM staging system for breast cancer,

T3: Tumor >5 cm in greatest dimension

N3c: Metastasis in ipsilateral supraclavicular lymph node(s)

MX: Distant metastasis cannot be assessed

Ref: Hunt K.K., Newman L.A., Copeland E.M., Bland K.I. (2010). Chapter 17. The Breast. In F.C. Brunnicardi, D.K. Andersen, T.R. Billiar, D.L. Dunn, J.G. Hunter, J.B. Matthews, R.E. Pollock (Eds), *Schwartz's Principles of Surgery*, 9e.

20. Dacron vascular graft is a:

a) Textile biologic

b) Textile synthetic

c) Nontextile biologic

d) Nontextile synthetic

Correct Answer - B

Dacron graft is a type of textile synthetic graft. It is associated with increased risk of thrombosis due to low flow rates.

They are pre coated with collagen, which eliminates the need for pre-clotting.

It is now reserved for aortic and high pressure, large diameter bypass grafts or used as aortic endografts.

Ref: Diabetic Foot: Lower Extremity Arterial Disease and Limb Salvage, Anton N. Sidawy, 2006 Edition, Chapter 22, Page 234; Mastery of Vascular and Endovascular Surgery By Gerald B. Zelenock, 2006 Edition, Chapter 50, Page 414; Vascular Access: Principles and Practice By Samuel Eric Wilson, 5th Edition, Page 115; Vascular Surgery By Alun H. Davies, Page 135.

21. The MOST common type of dislocation of elbow joint is:

a) Posterior

b) Posterolateral

c) Posteromedial

d) Lateral

Correct Answer - A

In adults, the elbow is the second most frequently dislocated major joint, after the shoulder. It is the most commonly dislocated joint in children. More than 90% of all elbow dislocations are posterior dislocations.

This injury entails disengagement of the coronoid process of the ulna from the trochlea of the humerus with movement posteriorly.

The mechanism of injury is typically a fall onto an outstretched hand with the elbow in extension upon impact.

22. Which of the following gas is most commonly used in laproscopy?

a) CO₂

b) N₂O

c) O₂

d) Helium

Correct Answer - A

CO₂ is used in laproscopy because it is common to the human body and can be absorbed by tissue and removed by the respiratory system.

It is also non-flammable, which is important because electrosurgical devices are commonly used in laparoscopic procedures.

23. What is the most common position of appendix?

a) Pelvic

b) Paracolic

c) Retrocaecal

d) Retroperitoneal

Correct Answer - C

Retrocecal is the most common position of the appendix.

Positions of appendix:

- Retrocecal: 74%
- Subcecal: 1.5%
- Pelvic: 21%
- Post-ileal: 0.5%
- Pre-ileal/retro-ileal: 1%

24. Most common primary bone tumour of hand is:

a) Osteoma

b) Osteochondroma

c) Enchondroma

d) None of the above

Correct Answer - C

Enchondromas arise from cartilage and are the most common primary bone tumors of the hand. These lesions account for >90% of bone tumors seen in the hand.

Ref: Schwartz's principle of surgery 9th edition, chapter 44.

- Commonest bone malignancies (metastases) -> Secondaries
- Commonest primary malignant tumor myeloma > Multiple
- Commonest primary malignant tumor of long bones Osteosarcoma
- Commonest benign tumor of bone Osteochondroma -
(Osteochondroma is not true neoplasm since its growth stops with cessation of growth at the epiphyseal plate)
- Commonest true benign tumor of bone osteoma -> Osteoid
- Commonest benign tumor of hand - Enchondroma

25.

Which of the following Vitamin deficiency is seen in short bowel syndrome with ileal resection ?

a) Vitamin K

b) Vitamin B 12

c) Vitamin B1

d) Folic acid

Correct Answer - B

Answer- B (Vitamin B12)

Short-bowel syndrome is a disorder clinically defined by malabsorption, diarrhea, steatorrhea, fluid and electrolyte disturbances, and malnutrition.

Changes seen in Terminal Ileal Resection

- Malabsorption of bile salts and vitamin B12 (which are normally absorbed in this region)
- Vitamin B12 Malabsorption → Megaloblastic anemia
- Bile salts Malabsorption → Unabsorbed bile salts escape into the colon and stimulate fluid secretion from the colon → watery diarrhea
- Decreased bile salts in the bile → Cholesterol gall stones

26. Double bubble sign seen in :

a) Duodenal atresia

b) Duodenal stenosis

c) Volvulus

d) All

Correct Answer - D

Ans. is D

'a', 'b' & 'c' i.e. Duodenal atresia, Duodenal stenosis and Volvulus

- Double bubble sign is seen in *duodenal atresia*, duodenal web, duodenal stenosis, Ladd's band, Annular pancreas, Malrotation of gut, preduodenal vein.
- Distal gas is more often seen with midgut volvulus, duodenal stenosis and duodenal web

27. In gastrectomy following occurs except -

a) Calcium deficiency

b) Steatorrhoea

c) Fe. deficiency

d) Fluid loss

Correct Answer - D

Answer is 'd' i.e. Fluid loss

Postgastrectomy complications

Anemia as a result of vitamin B12 or iron malabsorption and osteoporosis.

Iron deficiency anemia develops because removal of the stomach often leads to a marked decrease in the production of gastric acid.

Osteoporosis develops as a result of poor calcium absorption, another problem that occurs after gastric surgery.

Dumping syndrome

Diarrhoea- may be due to different reasons. associated with dumping syndrome post-vagotomy diarrhoea associated with fat malabsorption.

Fat malabsorption leading to steatorrhoea occurs due to acid inactivation of pancreatic enzymes or poorly coordinated mixing of food & digestive juices. Fat malabsorption leads to malabsorption of fat soluble vitamins i.e. A,D,E & K.

Pushing food from your stomach to your small bowel too quickly (dumping syndrome)

Acid reflux

Chest infections, including bronchitis and pneumonia

Internal bleeding

Nausea and vomiting

Stomach acid leaking into your esophagus, causing scarring and narrowing (stricture)
Vitamin deficiencies
Weight loss

28. All of the following are features of Zollinger Ellison syndrome except

a) Intractable peptic ulcers

b) Severe diarrhoea

c) Beta cell tumors of the pancreas

d) Very high acid output.

Correct Answer - C

Ans. is 'c' i.e., Beta cell tumours of pancreas

- Gastrinoma or Zollinger Ellison syndrome is a non 13 cell neuroendocrine tumour of the pancreas It secretes gastrin
- Pathophysiology of Gastrinoma
Gastrinoma → Increase secretion of gastrin → marked gastric acid hypersecretion peptic ulcer

Pancreatic Neuroendocrine Tumors

Tumour	Biologically active peptide secreted	Tumour location	Malignant percentage	Main symptoms and signs
Gastrinoma (non 13 cell tumour)	Gastrin	<i>Duodenum</i> (70%)		• Pain (79-100%)
		Pancreas (25%) other sites (5%)	60-90%	• Diarrhoea (30-73%) • GERD (30-35%) • Peptic ulcer

<p>Insulinoma (f3 cell tumour)</p>	<p>Insulin</p>	<p><i>Pancreas > 99%</i> (Insulinomas are distributed <i>equally on head body and tail of pancrease</i>)</p>	<p>< 10</p> <ul style="list-style-type: none"> • Symptoms of hypoglycemia • Symptoms relieve on administration of glucose
<p>VIPOMA (Verner-Morrison syndrome, pancreatic cholera, WDHA)</p>	<p>Vasoactive intestinal peptide</p>	<p><i>Pancreas 90%</i></p>	<p>40-70</p> <ul style="list-style-type: none"> • Watery diarrhoea (90-100%) • Hypokalemia (80-100%) • Hypochlorhydria • Dehydration (83%) • Flushing (20%)
<p>Glucagonoma</p>	<p>Glucagon</p>	<p><i>Pancreas 100%</i> (usually occurs <i>usuall singly in pancreatic tail</i>)</p>	<p>50-80%</p> <ul style="list-style-type: none"> • <i>Dermatitis</i> (migratory necrolytic erythema) 67-90% • <i>Glucose intolerance</i> (40-90%) • Weight loss (66 to 96%) • Anemia (33-85%) • Diarrhoea (15-29%) • Thromboembolism

29. Curlings ulcer is seen in -

a) Burn patients

b) Patients with head injuries

c) Zollinger Ellison syndrome

d) Analgesic drug abuse

Correct Answer - A

Ans. is 'a' i.e., Burn patients

- Curling ulcers: *are stress ulcers associated with burns and most commonly found in the first part of duodenum.*

30. The most commonly practiced operative procedure for a perforated duodenal ulcer is -

a) Vagotomy and pyloroplasty

b) Vagotomy and antrectomy

c) Vagotomy and perforation closure

d) Graham's omentum patch repair

Correct Answer - D

Ans. is 'd' i.e., Graham's omentum patch repair

31. Prepyloric or channel ulcer in the stomach is termed as -

a) type 1

b) type 2

c) type 3

d) type 4

Correct Answer - C

Ans. is 'c' i.e., Type 3

. *Situated in prepyloric region*

. *Associated with gastric acid hypersecretion*

32. Commonest cause of pyogenic liver abscess ?

a) Stricture of CBD

b) Biliary Colic

c) Appendicitis

d) Sigmoid Diverticulitis

Correct Answer - A

Ans is 'a' ie Stricture of CBD

- Most common route of infection to liver is along the bile duct. It may be due to : -
 - i) Stone impacted in CBD.
 - ii) Benign or malignant stricture of CBD.

Most common infecting organisms are E.coli and Klebsiella pneumonia

33. All are true about amoebic liver abscess except:

a) More common in females

b) More common in left lobe of liver

c) Metronidazole is mainstay of treatment

d) a and b

Correct Answer - D

Ans is D

a i.e. More common in females & b i.e. More common in left lobe of liver

“Male preponderance of greater than 10:1 has been reported in all studies”

The right lobe of the liver is more commonly affected than the left lobe.

amebic liver abscess is 7-12 times more common in men than in women, with a predominance among men aged 18-50 years.

Metronidazole 800 mg TDS for 5–10 days

Aspiration

Repeated imaging of liver

34. False about hydatid cyst of liver:

a) Mostly asymptomatic

b) Most commonly located in right lobe of liver

c) Most common causative organism is echinococcus granulosus

d) Hepatic resection is never done

Correct Answer - D

Ans is 'd' i.e. Hepatic resection is never done

Laparoscopic aspiration, unroofing and evacuation of the hepatic hydatid cysts can be done.

35. Indications of Liver transplantation are All/Except

a) Biliary atresia

b) Sclerosing cholangitis

c) Hepatitis A

d) Cirrhosis

Correct Answer - C

Ans. is 'c' i.e. Hepatitis A

Liver transplantation is indicated for those children and adults, who in the absence of contraindications suffer from severe, irreversible liver disease for which alternative medical or surgical treatments have been exhausted or are unavailable.

- Most common indication in children _____ Biliary atresia in adults --> Cirrhosis

Harrison 17/e writes- "*Currently, chronic hepatitis C and alcoholic liver disease are the most common indications for liver transplantation, accounting for over 40% of all adult candidates who undergo the procedure.*"

Indications for
ver Transplantation

Children	Adults
Biliary atresia	Primary biliary cirrhosis
Neonatal hepatitis	Secondary biliary cirrhosis
Congenital hepatic fibrosis	Primary sclerosing cholangitis
Alagille's disease	Autoimmune hepatitis

Alagille's disease	Autoimmune hepatitis
Byler's disease	Caroli's disease
alpha-1 antitrypsin deficiency	Cryptogenic cirrhosis
Inherited disorders of metabolism	Chronic hepatitis with cirrhosis
Wilson's disease	Hepatic vein thrombosis
Tyrosinemia	Fulminant hepatitis
Glycogen storage diseases	Alcoholic cirrhosis
Lysosomal storage diseases	Chronic viral hepatitis
Protoporphyrria	Primary hepatocellular malignancies
Crigler-Najjar disease type I	Hepatic adenomas
Familial hypercholesterolemia	Nonalcoholic steatohepatitis
Primary hyperoxaluria type I	Familial amyloid polyneuropathy
Hemophilia	

Contraindications to Liver Transplantation

Absolute	Relative
Uncontrolled extrahepatic infection	Age >70
Active, untreated sepsis	Prior extensive hepatobiliary surgery
Uncorrectable, life-limiting congenital anomalies	Portal vein thrombosis
Active substance or alcohol abuse	Renal failure
Advanced cardiopulmonary disease	Previous extrahepatic malignancy (not including nonmelanoma skin cancer)

Extranepatobiliary malignancy
(not including
nonmelanoma skin cancer)

Metastatic malignancy to the
liver

Cholangiocarcinoma

AIDS

Life-threatening systemic
diseases

Severe obesity

Severe malnutrition/wasting

Medical noncompliance

HIV seropositivity

Intrahepatic sepsis

Severe hypoxemia
secondary to right-to-left
intrapulmonary shunts ($P_{O_2} <$
50 mmHg)

Severe pulmonary
hypertension (mean PA
pressure >35 mmHg)

Uncontrolled psychiatric
disorder

36. Kehr's sign seen in splenic rupture is -

a) Pain over left shoulder

b) Pain over right scapula

c) Periumbilical pain

d) Pain over renal angle

Correct Answer - A

Ans. is 'A' i.e., Pain over left shoulder

- In splenic rupture the pain may be referred to the tip of the left shoulder.
This is known as Kehr's sign.
- It occurs due to *irritation of the undersurface of the diaphragm* with blood and the pain is referred to the shoulder through the affected fibres of *phrenic nerve (C₄ and C5)*.
- Kehr's sign can be elicited by *bimaual compression* of the left upper quadrant after the patient has been in *Trendelenburg's position* for about 10 minutes prior to the manoeuvre.

37. In which condition, medical treatment of gall stone is indicated -

a) Stone is < 15 mm size

b) Radio opaque stone

c) Calcium bilirubinate stone

d) Non functioning gall bladder

Correct Answer - A

Ans is 'a' is Stone is < 15 mm size

Medical treatments for gallstones, used alone or in combination, include the following-

- Oral bile salt therapy (ursodeoxycholic acid) (particularly for x-ray-negative cholesterol gallstones in patients with normal gallbladder function)
- Extracorporeal shockwave lithotripsy (particularly for noncalcified cholesterol gallstones in patients with normal gallbladder function)
- Medical management is more effective in patients with good gallbladder function who have small stones (< 1 cm) with a high cholesterol content. Bile salt therapy may be required for more than 6 months and has a success rate of less than 50%.

38. In a patient of acute cholecystitis, referred pain to the shoulder is k/a

a) Murphy's sign

b) Gray Turner sign

c) Boas' sign

d) Cullen's sign

Correct Answer - C

Ans is 'c' i.e. Boas' sign

Boas' sign: In cases of acute cholecystitis pain radiates to the tip of the right shoulder and an area of skin below the scapula is found to be hypersensitive. This is k/a Boas' sign. Sensitivity is quite less.

Also Know:

Murphy's sign: Seen in acute cholecystitis. Murphy's sign is elicited by asking the patient to breathe out and then gently placing the hand below the costal margin on the right side at the mid-clavicular line (the approximate location of the gallbladder). The patient is then instructed to inspire (breathe in). Normally, during inspiration, the abdominal contents are pushed downward as the diaphragm moves down (and lungs expand). If the patient stops breathing in (as the gallbladder is tender and, in moving downward, comes in contact with the examiner's fingers) and winces with a 'catch' in breath, the test is considered positive. In order for the test to be considered positive, the same maneuver must not elicit pain when performed on the left side.

Grey Turner & Cullen's sign: positive in severe necrotizing pancreatitis. Grey Turner's sign is bluish discoloration seen at the flanks. Bluish discoloration around the umbilicus is known as

Cullen's sign.

39. In Patey's mastectomy the step not done is

a) Nipple and areola removed

b) Surrounding normal tissue of tumor is removed.

c) Pectoralis major removed

d) Pectoralis minor removed

Correct Answer - C

Ans. is 'c' i.e. (Pectoralis major removed)

Lets see the nomenclature of various surgeries on breast

- Simple or Total mastectomy
** it removes all breast tissue, the nipple-areola complex, and skin.*
- Extended simple mastectomy
** Simple mastectomy + removal of level I axillary lymph nodes.*
- Modified radical mastectomy
it removes all breast tissue, the nipple-areola complex, skin and the level I and level II axillary lymph nodes.
- Halstead's Radical mastectomy
removes all breast tissue and skin, the nipple areola complex, the pectoralis major and minor muscles and the level I, II and III axillary lymph nodes.
- Modified Radical Mastectomy
- Two forms of modified radical mastectomy are in use
- Auchincloss (pronounced as 'aushincloss') procedure
** Here both the pectoralis major and minor muscles are preserved with removal of level I and II axillary lymph nodes*

Patey's Procedure

here the pectoralis minor muscle is removed to allow complete dissection of level III axillary lymph nodes

- Scanlon's modification of Patey's procedure
 - * *here the pectoralis minor muscle is divided instead of removing. Division of pectoralis minor muscle allows complete removal of level III lymph nodes*
- Halstead Radical Mastectomy
- In this operation following structures are removed.
 - i) the whole breast
 - ii) the portion of skin overlying the tumor, which includes the nipple-areola complex.
 - iii) the subcutaneous fat and the deep fascia vertically from the lower border of the *clavicle* upto the upper quarter of the sheath of the *rectus abdominis* and horizontally from the *sternum* to the anterior border of *lattissimus dorsi*
 - iv) pectoralis major muscle
 - v) pectoralis minor muscle and clavipectoral fascia
 - vi) upper part of the aponeurosis of the external oblique and anterior parts of a few digitations of the serratus anterior muscle
 - vii) all fatty and loose areolar tissue along with level I, II & III axillary lymph nodes
- Structures saved are :
 - i) the axillary vein and the cephalic vein
 - ii) the long thoracic nerve of Bell (Nerve to serratus anterior).
The nerve to latissimus dorsi may be sacrificed if required.
- Also know
- Extended Radical Mastectomy - *Radical mastectomy + removal of internal mammary lymph nodes*
- Super Radical Mastectomy - *Radical mastectomy + removal of internal mammary, mediastinal and supraclavicular lymph nodes.*

40. Breast conservation surgery not indicated ?

a) Large pendular breast

b) SLE

c) Diffuse microcalcification

d) All

Correct Answer - D

Answer (a) Large pendular breast; (b) SLE ; (c) Diffuse microcalcification

41. In breast carcinoma metastasis, prognosis depends best upon -

a) Estrogen receptor status

b) Axillary lymphnode status

c) Size of tumour

d) Site of tumour

Correct Answer - A

Ans is 'a' i.e., Estrogen receptor status

- In case of metastasis, the prognosis no more depends upon the lymph node status.
- The lymph node status is the most important prognostic indicator for tumor localized to breast, as the presence of nodal metastasis implies systemic dissemination of cancer and hence a bad prognosis. But once a metastasis is discovered, the lymph node status is of little significance. Metastatic disease confers the breast tumor TNM stage IV status, with worst prognosis. Currently stage IV diseases are not curative.
- Schwartz 9/e writes - *"Treatment for stage IV breast cancer is not curative, but may prolong survival and enhance a women's quality of life. Hormonal therapies that are associated with minimal toxicity are preferred to cytotoxic chemotherapy. Appropriate candidates for initial hormonal therapy include women with hormone receptor-positive cancers; women with bone or soft tissue metastasis only; and women with limited and asymptomatic visceral metastasis.*
- About hormone receptors, CSDT 11/e, p 329 writes - *"the presence or absence of estrogen and progesterone receptors in the cytoplasm of tumor cells is of paramount importance in managing all patients with breast cancer, especially those with recurrent or metastatic*

disease. They are of proved value in determining adjuvant therapy and therapy for patients with advanced disease. Upto 60% of patients with metastatic breast cancer will respond to hormonal manipulation if their tumors contain estrogen receptors. However fewer than 5% of patients with metastatic ER-negative tumors can be successfully treated with hormonal manipulation."

42. What is true about HER2/neu overexpression in Ca breast:

a) Good prognosis

b) Responds well to taxanes

c) Responds well to monoclonal antibodies

d) Seen only in breast cancer

Correct Answer - C

Ans is 'c' i.e. Responds well to monoclonal antibodies

The **HER2** receptor (previously called HER2/neu, or ERBB-2 receptor) belongs to the epidermal growth factor receptor (EGFR) family of receptors, which are critical in the activation of subcellular signal transduction pathways controlling epithelial cell growth and differentiation and possibly angiogenesis.

Amplification of HER2 or overexpression of its protein product is observed in 18 to 20 percent of human breast cancers.

HER2 overexpression is also noted in other tumors such as esophagogastric tumors, lung, ovary & head and neck squamous cell ca. (In all of these sites, HER2 overexpression has been identified as a negative prognostic factor.)

Following points are to be noted about HER2 overexpression in breast Ca:

Prognostic value of HER2 — HER2 overexpression is a poor prognostic marker. HER2 overexpression is associated with high rates of disease recurrence and death in the absence of adjuvant systemic therapy.

Predictive value of HER2 — HER2 status predicts response to specific therapies:

- Patients with high levels of HER2 expression benefit from treatment

with agents that target HER2, such as trastuzumab (a monoclonal antibody) and lapatinib.

- HER2 status appears to predict resistance or sensitivity to different types of chemotherapeutic agents, including anthracyclines and taxanes.

Women whose tumors overexpress HER2 appear to derive greater benefit from anthracycline-based adjuvant therapy than from adjuvant therapy that is alkylating agent-based, such as CMF (cyclophosphamide, methotrexate, fluorouracil).

Relationship between HER2 overexpression and taxanes is still under study with various studies giving conflicting reports.

HER-2 positivity is associated with resistance to endocrine therapies.

Scoring of HER-2 Immunohistochemistry Assays

Score	HER-2 Status	Staining Pattern
0	Negative	No staining or membrane staining in <10% of tumor cells°
1+	Negative	<ul style="list-style-type: none"> • A faint barely perceptible membrane staining is detected in >10% of tumor cells. The cells are only stained in part of the membrane°.
2+	Equivocal	<ul style="list-style-type: none"> • Weak to moderate complete membrane staining is seen in >10% of tumor cells or <30% with strong staining^a
3+	Positive	<ul style="list-style-type: none"> • Strong complete membrane staining is seen in >30% of tumor cells°

43. Mondor's disease is ?

a) Thrombophlebitis of the Superficial veins of Breast

b) Carcinoma of the breast

c) Premalignant condition of the breast

d) Filariasis of the breast

Correct Answer - A

Ans is 'a' i.e., Thrombophlebitis of Superficial veins of Breast

- Mondor's disease
- is thrombophlebitis of the superficial veins of anterior chest wall and breast although it has also been seen in the arm.
- frequently involved veins are lateral thoracic vein, thoracoepigastric vein and superficial epigastric veins.
- aetiology is unknown
- also known as 'string phlebitis', it presents as a tender cord-like structure.
- The women may present with acute pain in the lateral aspect of breast or the anterior chest wall. A tender cord-like superficial thrombosed vein is formed and when the skin over the breast is stretched by raising the arm, a narrow shallow subcutaneous groove alongside the cord becomes apparent.
- rarely it may be bilateral.
- Management
 - it's a benign self-limited disorder
 - The differential diagnosis is lymphatic permeation from an occult carcinoma of breast
 - When the diagnosis is uncertain or a mass is present near the cord, a biopsy may be done. Treatment
- antiinflammatory drugs and warm compresses

- restricted arm movements as well as brassiere support of breast
- it usually resolves within 4 to 6 weeks. When symptoms persists or are refractory to treatment, the involved vein segment may be excised.

44. Flap commonly used in breast reconstruction is?

a) Serratus anterior

b) TRAM

c) Flap from arm

d) Delto pectoral flap

Correct Answer - B

Ans. is 'b' i.e. TRAM

(Most common) Single Pedicle Double Pedicle Free flap

Deep inferior epigastric perforator flap

45. Lateral aberrant thyroid refers to -

a) Congenital thyroid abnormality

b) Metastatic focus in lymph nodes

c) Struma ovarii

d) Lingual thyroid

Correct Answer - B

Ans is "B" i.e. Metastatic focus in lymph nodes

Lateral aberrant thyroid refers to a **metastatic focus in lymph nodes**.

Lateral aberrant thyroid is a **misnomer** and always refers to the presence of metastatic thyroid carcinoma (papillary) in cervical lymph nodes. It does not indicate the presence of ectopic thyroid tissue as the name suggests.

46. Treatment of choice for medullary carcinoma of thyroid is:

a) Total thyroidectomy

b) Partial thyroidectomy

c) ¹³¹I ablation

d) Hemithyroidectomy

Correct Answer - A

Ans. is 'a' i.e. Total thyroidectomy

Treatment of thyroid malignancies is as follows :- (Note- *this is a very important and often repeated topic in PG exams, so if time permits one must turn the pages of Schwartz Sx or any other standard book for detailed study*).

- Papillary Thyroid Carcinoma (PCT)
- High-risk tumors or bilateral tumors
 - Total thyroidectomy (or near total thyroidectomy).
- Low risk
 - The treatment is *controversial*. *Conservative approach* advocates *hemithyroidectomy* (lobectomy + isthmusectomy).
 - *More radical approach* advocates *total thyroidectomy* (or near total thyroidectomy). - *Schwartz Sx and Devita's Oncology* are in favour of radical approach.
 - (*High and Low risk decided by any one of the many classification systems*)
- If enlarged lymph nodes are found
 - *Modified radical neck dissection* is done of the affected side.
- When patients are found to have a minimal papillary thyroid carcinoma in a thyroid specimen removed for other reasons, *unilateral thyroid lobectomy and isthmusectomy* is usually

considered to be adequate treatment, unless the tumor has evidence of angioinvasion, multifocality, or positive margins.

Follicular Thyroid Carcinoma (FTC)

- FNA biopsy is unable to distinguish *benign* follicular lesions from *follicular carcinomas* therefore, *preoperative diagnosis of cancer is difficult* unless distant metastases are present.
- Patients diagnosed by *FNA biopsy* as follicular lesions should undergo *thyroid lobectomy + isthmusectomy* (because at least 80% of these patients will have benign adenomas).
The resected lobe is subjected to *histology (intraoperative frozen – section examination*, though usually not helpful should be performed in high risk cases).

47. In case of hypothyroidism which investigation is most informative and most commonly used ?

a) Serum TSH Level

b) Serum T3, T4 Level

c) Serum Calcitonin assay

d) Serum T3 level

Correct Answer - A

Ans is A ie Serum TSH Level

- *"A normal TSH Level excludes primary (but not secondary) hypothyroidism. If the TSH is elevated a free T4 level is needed to confirm the presence of clinical hypothyroidism, but free T4 is inferior to TSH when used as a screening test, as it will not detect subclinical or mild hypothyroidism. Circulating free T3 levels are normal in about 25% of the patients, reflecting adaptive response to hypothyroidism. T3 measurements are therefore not indicated." - Harrison*
- *"Among the various available serum thyroid function tests, TSH is the most useful to assess gland dysfunction." ?
Endocrine Surgery of Head & Neck, p 83.*

48. M.C. site of CA oesophagus is -

a) Middle 1/3rd

b) Upper 1/3rd

c) Lower 1/3rd

d) Lower end of esophagus

Correct Answer - A

Ans is (a) ie Middle 1/3rd

- Well, I am not quite sure of the answer.
- Esophageal Carcinoma is of two common histological types
 - i) Squamous cell Ca - the MC type in world (-95% according to Sabiston)
 - ii) Adenocarcinoma - where incidence is increasing at a rapid rate and is now the MC type in USA (Ref. Harrison, Schwartz)
- Distribution of Squamous Cell Ca.
 - Upper 1/3 10%
 - Middle 1/3 60%
 - Lower 1/3 30%
- Adenocarcinoma is mainly located in lower 1/3.
- Nowhere, I could get the MC site of esophageal carcinoma overall (including both squamous and adeno variety). [Harrison writes the MC site to be lower 1/3, but it gives incidence for US population only, not for the whole world]
- But one thing is sure - *squamous cell Ca is the MC type of esophageal cancer in world [(Ref: Bailey & Love, 25/e p1026 (24/e p1009); Robbins 8/e p772 (7/e p806); Sabiston 18/e p1090 (17/e p1118)]*
- So I presume that the overall MC site would be the MC site involved by the MC type of esophageal cancer i.e. -* Middle 1/3

So remember

- MC type of esophageal Ca in world -> Squamous Cell Ca (--95%)
MC site -> Middle 1/3

49. Which is M.C. site for iatrogenic oesophageal perforation -

a) Abdominal portion

b) Cervical portion

c) Above arch of aorta

d) Below arch of aorta

Correct Answer - B

Ans is 'b' ie Cervical portion

- Oesophageal perforation is of two types
- Iatrogenic (MC) :
 - *Common site is cervical esophagus Just above the upper sphincter.*
- Spontaneous rupture : *as seen in Boerhaaves syndrome (Rupture of esophagus after vomiting)*
 - *common in the lower 1/3 of esophagus.*

50. Corkscrew esophagus is seen in which of the following conditions ?

a) Carcinoma esophagus

b) Scleroderma

c) Achalasia cardia

d) Diffuse esophagus spasm

Correct Answer - D

Ans. is d i.e., Diffuse Esophageal spasm

- Radiological appearances of **diffuse esophageal spasm** have been described as:
curling esophagus
Corkscrew esophagus or
- pseudodiverticulosis
- Diffuse esophageal spasm is a *motor disorder* of esophagus characterized by *repetitive simultaneous non-peristaltic contractions*.
- Symptoms are *substernal chest pain* and/or *dysphagia*
- Diagnosed by *manometry*
- *Also know*
- Nutcracker esophagus
also known as 'supersqueezer' esophagus
- it is characterized by *extremely high-amplitude peristaltic contraction*
- Symptoms are *pain* and *dysphagia*
Diagnosed by *manometry study* which shows peristaltic esophageal contractions with peak amplitudes greater than two standard deviations above the normal values.

51. The most common type of Tracheo-Oesophageal Fistula is -

- a) Esophageal atresia without tracheoesophageal fistula
- b) Esophageal atresia with proximal tracheoesophageal fistula
- c) Esophageal atresia with distal tracheoesophageal fistula
- d) Esophageal atresia with proximal and distal fistula

Correct Answer - C

Ans. is 'c' i.e., Esophageal atresia with distal tracheoesophageal fistula

- TEF is classified into five types based on presence of esophageal atresia and location of fistula:
 - 1) Type A : There is *esophageal atresia without TEF*. There is no gas in abdomen. It is 2nd most common type.
 - 2) Type B : There is proximal TEF. There is no gas in abdomen.
 - 3) **Type C** : There is *proximal esophageal atresia with distal TEF*. Gas in abdomen is present. It is *most common*.
 - 4) **Type D** : Both proximal and distal fistula are present. Gas in abdomen is present. It is *least common*.
 - 5) **Type E** : Isolated TEF (H or N type) is there.

52. commonest benign tumor of the esophagus?

a) Leiomyoma

b) Papilloma

c) Adenoma

d) Hemangioma

Correct Answer - A

Ans is a. i.e. Leiomyoma

"Leiomyomas constitute more than 50% of benign esophageal tumors "-Schwartz

53. All of the following are risk factors for carcinoma gall bladder, EXCEPT -

a) Typhoid carriers

b) Adenomatous gall bladder polyps

c) Choledochal cysts

d) Oral contraceptives

Correct Answer - D

Ans. is d i.e., Oral Contraceptives

• *Risk factors for Ca Gall bladder are :*

i) Gall stones

ii) Adenomatous gall bladder polyps (*particularly polyps larger than 10 mm*)

iii) Calcified (porcelain) gall bladder

iv) Choledochal cyst

v) Estrogens

vi) Anomalous pancreaticobiliary duct junction

vii) Exposure to carcinogens (*azotoulene, nitrosamine*)

viii) Typhoid carriers

ix) Sclerosing cholangitis

54. Regarding Ca gallbladder -

a) Squamous cell ca is the most common

b) Present with jaundice

c) Good prognosis

d) All

Correct Answer - B

Answer (b) Presents with jaundice

- Biliary tract cancers tend to be slow-growing tumours that invade locally and metastasise to local lymph nodes.
- Distant metastases to the peritoneal cavity, liver and lung do occur.
- Jaundice is the most common presenting feature.
- Abdominal pain, early satiety and weight loss are also commonly seen.
- On examination, jaundice is evident, cachexia often noticeable and a palpable gall bladder is present if the obstruction is in the distal common bile duct (Courvoisier's sign).

55. The Gall stone pain is referred to the shoulder through which of the following nerves:

a) C2-C8

b) T1-T4

c) T8-T12

d) C3-05

Correct Answer - D

Ans is 'd' i.e. C3-05

Gallstone disease may refer pain to the right shoulder tip (k/a Kehr's sign). This is because, an inflamed gallbladder irritates the diaphragm which is supplied by the phrenic nerve (C3-05). These cervical nerve roots, also provide sensory supply to the right shoulder through supraclavicular nerves. Hence the gallbladder pain is referred to the right shoulder through the C3-05 nerve roots.

Kehr's sign is a classic example of referred pain: irritation of the diaphragm is signaled by the phrenic nerve as pain in the area above the collarbone. This is because the supraclavicular nerves have the same cervical nerves origin as the phrenic nerve, C3 and C4.

Boas' sign can also indicate stomach and duodenal disease. When the transverse processes of thoracic vertebrae T10-T12 are pressed or effleuraged with the bottom of the hand, pain can appear at left of spinous processes (in stomach's lesser curvature ulcer) or at right (in pyloric or duodenal ulcer).

Boas' or Boas's sign is hyperaesthesia (increased or altered sensitivity) below the right scapula can be a symptom in acute cholecystitis (inflammation of the gallbladder)

cholecystitis (inflammation of the gallbladder).

56. The best investigative modality for gall bladder stones -

a) Oral cholecystogram

b) Percutaneous transhepatic cholangiography

c) Ultrasound

d) Intravenous cholangiogram

Correct Answer - C

Ans. is 'c' i.e. Ultrasound

- *Ultrasonography*: - This is the investigation of choice for the detection of gallstones, and obstructive jaundice. USG shows echogenic focus with posterior acoustic shadowing.
- The most specific sign of a contracted, stone-filled gallbladder is a hypoechoic wall superficial to a curvilinear echo from the stones and an acoustic shadow:- WES triad (Wall, Echo, Shadow) or the "Double arc shadow sign".
- IOC for diagnosis of gallstone- acute cholecystitis, acute acalculous cholecystitis, chronic cholecystitis is Ultrasound

57. Strawberry gallbladder is seen in ?

a) Gangrene of gallbladder

b) Porcelain gall bladder

c) Adenomatosis

d) Cholesterosis

Correct Answer - D

Ans. is' i.e. Cholesterosis

Cholecystosis is the chronic inflammatory condition of the gallbladder with cholesterol deposits.

Types

- I. Aggregations of cholesterol crystals in the mucosa or submucosa —cholesterosis (Strawberry gallbladder).
- Lipoid contents are present in large foamy cells that have phagocytosed cholesterol. Here cystic duct is normal.
- The disease occurs only in gallbladder. It is a premalignant condition.
- II. Cholesterol laden polypoid projections in the mucosa — cholesterol polyposis (Gallbladder polyp).
- III. Granulomatous thickening and hyperplasia of the gallbladder — cholecystitis glandularis proliferans.
- IV. Diverticula formation in the wall of the gallbladder— diverticulosis of gallbladder.
- V. Gallbladder wall fistula.

58. VIPoma is associated with which syndrome:

a) Zollinger Ellison

b) Verner Morrison

c) Carcinoid syndrome

d) Cushing's syndrome

Correct Answer - B

Ans is 'b' i.e. Verner Morrison

VIPomas are endocrine tumors that secrete excessive amounts of *vasoactive intestinal peptide (VIP)*,

Excessive VIP causes a distinct syndrome characterized by large-volume diarrhea, hypokalemia, and dehydration. This syndrome also is called Verner-Morrison syndrome, pancreatic cholera, and WDHA syndrome for watery diarrhea, hypokalemia, and achlorhydria.

The principal symptoms are large-volume diarrhea (100%) severe enough to cause hypokalemia (80-100%), dehydration (83%), hypochlorhydria (54-76%), and flushing (20%).

In adults 80-90% of VIPomas are pancreatic in location, with the rest due to VIP-secreting pheochromocytomas,

59. All are resected in whipples operation except ?

a) Duodenum

b) Head of pancreas

c) Neck of pancreas

d) Common bile duct

Correct Answer - C

Ans is 'c'

- *Whipples operation (Pancreaticoduodenectomy)*
- is the most commonly performed operation for carcinoma of head of pancreas.
- It includes resection of:
 - *distal stomach*
 - *gall bladder*
 - *CBD*
 - *head of pancreas*
 - *duodenum*
 - *proximal jejunum*
 - *regional lymphatics*
- Restoration of gastrointestinal continuity requires -
 - *pancreaticojejunostomy*
 - *choledochojejunostomy*
 - *gastrojejunostomy*

60. Following genetic counselling in a family for Familial polyposis coli (FPC) next screening test is

a) Flexible sigmoidoscopy

b) Colonoscopy

c) Occult blood in stools

d) APC gene

Correct Answer - D

Ans. is 'd' i.e. APC gene

- *Schwartz writes - "Flexible sigmoidoscopy of first-degree relatives of FAP (Familial adenomatous polyposis) patients beginning at age 10 to 15 years has been the traditional mainstay of screening. Today following genetic counselling, APC gene testing may be used to screen family members providing an APC mutation has been identified in a family member."*
- Familial adenomatous polyposis (FAP) is a *dominantly inherited* colon cancer syndrome due to germline mutations in the *adenomatous polyposis coli (APC) tumor suppressor gene* on chromosome 5.
- Patients with this syndrome develop hundreds to thousands of *adenomas* in the colon which if left untreated will eventually develop into *colon cancer*.
- Each of the FAP adenomas has lost the normal remaining allele of APC gene but has not yet accumulated the required additional mutations to generate fully malignant cells. In due course of time many of these adenomas acquire further genetic abnormalities and develop into fully malignant cancers. APC gene is thus considered to

be a *gatekeeper* for colon tumorigenesis.

- *The detection of APC gene mutation in family members of a FAP patient helps in making a definitive diagnosis before the development of polyps.*

61. The tendency of colonic carcinoma to metastasize is best assessed by -

a) Size of tumor

b) Carcinoembryonic antigen (CEA) levels

c) Depth of penetration of bowel wall

d) Proportion of bowel circumference involved.

Correct Answer - C

Ans. is c) i.e. depth of penetration of bowel walls

- Schwartz writes

"Regional lymph node involvement is the most common form of spread of colorectal carcinoma and usually precedes distant metastasis or the development of carcinomatosis. the T stage (depth of invasion) is the single most significant predictor of lymph node spread."

- From the above given lines 'depth of penetration of bowel wall' appears to be predictor of distant metastases as well.
- CEA level is a marker for recurrence of colorectal ca after surgical resection.
- Though its preoperative levels has *some prognostic significance*, it is not a predictor for distant metastasis.
- CEA level is used to follow up post operative cases of colorectal cancer, for early detection of recurrence.

62. Following is least common about angiodysplasia of colon -

- a) Involvement of cecum
- b) Involvement of rectum in 50% of cases
- c) Affecting age group > 40 yrs.
- d) Cause of troublesome lower G.I. hemorrhage

Correct Answer - B

Ans. is 'b' i.e., Involvement of rectum in 50% cases

Site: Occur most commonly in the ascending colon and caecum; however they can also occur in rest of colon and small bowel.

Clinical features

- Anemia - most common presentation
- Hematochezia
- Melena
- There is an association with aortic stenosis (Heyd's syndrome).

63. Most common type of Intussusception is -

a) Ileocolic

b) ileoileal

c) Colo-colic

d) Caeco-colic

Correct Answer - A

Ans. is 'a' i.e., Ileocolic

- Ileo-ileo-colic (-12)
- Ileoileal (-5%)
- Colocolic (-2%)
- Multiple (1%)
- Retrograde

The **most common type of intussusception** is ileocolic (also known as ileocecal) (90%).

64. Features of intestinal obstruction : clinically/ investigation by :

a) Abdominal distension

b) Vomiting

c) Fluid level in X-ray > 4

d) a and b

Correct Answer - D

Ans. is 'a' & 'b' i.e. Abdominal distension & Vomiting

- About option 'c'

> 5 air-fluid levels in x-ray abdomen suggest intestinal obstruction
Grainger's Diagnostic radiology writes - *"3 to 5 fluid levels less than 2.5 cm in length may be seen, particularly in the right lower quadrant, without any evidence of intestinal obstruction or paralytic ileus."*

65. Commonest cause of intussusception is -

a) Submucous lipoma

b) Meckel's diverticulum

c) Hypertrophy of submucous peyer's patches

d) Polyp

Correct Answer - C

Ans. is 'c' i.e., Hypertrophy of submucosa peyer's patches

66. What is the T/t of pt with carcinoid tumor of appendix of size more than 2 cm -

a) Right hemicolectomy

b) Appendicectomy

c) Appendicectomy + abdominal CT scan

d) Appendicectomy + 24 hrs urinary HIAA

Correct Answer - A

Ans is 'a' ie. Right hemicolectomy

67. A 25 year old man presents with 3 days history of pain in the right lower abdomen and vomitings. patient's general condition is satisfactory and clinical examination reveals a tender lump in right iliac fossa. The most appropriate management in this case would be

a) Immediate appendicectomy

b) Exploratory laprotomy

c) Oschner Sherren regimen

d) External drainage

Correct Answer - C

Ans. is 'c' i.e., Oschner Sherren regimen

- The patient is presenting with typical clinical features of appendical mass.
- If an appendix mass is present and the condition of the patient is satisfactory, the standard treatment is the conservative Ochsner-Sherren regimen.
- This strategy is used as the inflammatory process is already localised and that inadvertent surgery is difficult and may be dangerous.
- It may be impossible to find the appendix and, occasionally, a faecal fistula may form.
- For these reasons, it is wise to observe a non-operative programme but to be prepared to operate should clinical deterioration

68. Which of the following is not a sign seen in acute apendicitis

a) Rovsing's

b) Rosenstein's sign

c) Boa's sign

d) Hamburger sign

Correct Answer - C

Ans. is 'C'

Accessory signs of appendicitis

- **Aure-Rozanova's sign:** Increased pain on palpation with finger in right Petit triangle (can be a positive Shchetkin-Bloomberg's).
- **Bartomier-Michelson's sign:** Increased pain on palpation at the right iliac region as the person being examined lies on his or her left side compared to when he/she lies on the back.
- **Dunphy's sign:** Increased pain in the right lower quadrant with coughing.
- **Hamburger sign:** The patient refuses to eat (anorexia is 80% specific for appendicitis)
- **Kocher's (Kosher's) sign:** From the person's medical history, the start of pain in the umbilical region with a subsequent shift to the right iliac region.
- **Massouh sign:** Developed in and popular in southwest England, the examiner performs a firm swish with his or her index and middle finger across the abdomen from the xiphoid process to the left and the right iliac fossa. A positive Massouh sign is a grimace of the person being examined upon a right sided (and not left) sweep.
- **Obturator sign:** The person being evaluated lies on her or his back with the hip and knee both flexed at ninety degrees. The examiner

holds the person's ankle with one hand and knee with the other hand. The examiner rotates the hip by moving the person's ankle away from his or her body while allowing the knee to move only inward. A positive test is pain with internal rotation of the hip.

- **Psoas sign**, also known as "Obraztsova's sign", is right lower-quadrant pain that is produced with either the passive extension of the right hip or by the active flexion of the person's right hip while supine. The pain that is elicited is due to inflammation of the peritoneum overlying the iliopsoas muscles and inflammation of the psoas muscles themselves. Straightening out the leg causes pain because it stretches these muscles, while flexing the hip activates the iliopsoas and causes pain.
- **Rovsing's sign**: Pain in the lower right abdominal quadrant with continuous deep palpation starting from the left iliac fossa upwards (counterclockwise along the colon). The thought is there will be increased pressure around the appendix by pushing bowel contents and air toward the ileocaecal valve provoking right-sided abdominal pain.
- **Sitkovskiy (Rosenstein)'s sign**: Increased pain in the right iliac region as the person is being examined lies on his/her left side

69. In carcinoma of anus distal margin of clearance of anal canal of at least

a) 2 cm

b) 5 cm

c) 4 cm

d) 7 cm

Correct Answer - A

Ans. is 'a' i.e., 2 cm

MANAGEMENT OF CARCINOMA RECTUM

Assessment of depth of penetration of perirectal nodes in rectal cancer	MRI
A punch biopsy shows carcinoma rectum with fixed mass. Chest X ray normal. Least useful investigation	Rigid proctoscope
Chemotherapy for carcinoma rectum	5 fluorouracil, folinic acid
Treatment of Choice for Ca Rectum	Surgery
Best procedure in mid rectal carcinoma	Anterior resection
Management of carcinoma near anorectal junction	Abdominoperineal resection
Pelvic exenteration	Brunshwing's operation
Management of Rectal carcinoma	Hartmann procedure
Unaffected tissue margin resected in carcinoma rectum	1 cm
Length of anal canal	4 cm
Distal clearance in surgery for ca rectum	2 cm
In carcinoma of anus, distal margin of clearance of anal canal of at least	2 cm
3.5 cm above anal verge	Abdominoperineal resection
Rectal carcinoma 5 cm from anal verge	Abdominoperineal resection
7 cm above anal verge	Anterior resection
6 cm from dentate line	Anterior resection
Treatment of Ca rectum 12 cm from anal verge	Anterior resection
APR is done in colorectal carcinoma on the basis of	Distance from anal verge

[Ref Bailey & Love 25th/e p. 1233]

70. In case of female commonest hernia is ?

a) Direct inguinal hernia

b) Indirect inguinal hernia

c) Femoral Hernia

d) Incisional hernia

Correct Answer - B

Ans is 'b' ie Indirect Inguinal hernia

- In Indirect inguinal hernia the contents of the abdomen enter the deep inguinal ring and traverse the whole length of the inguinal canal to come out through the superficial inguinal ring.
- It is the **most common** of all forms of hernia.
- It is most common in the young (*cf a direct hernia is most common in the old*)
- *Femoral hernias occur most commonly in women but lower incidence overall than inguinal hernias.*

71. Triangle of Doom is bounded by all of the following except:

a) Cooper's ligament

b) Vas deferens

c) Gonadal vessels

d) Peritoneal reflection

Correct Answer - A

Ans is a i.e. Cooper's ligament

The triangle of doom is bounded

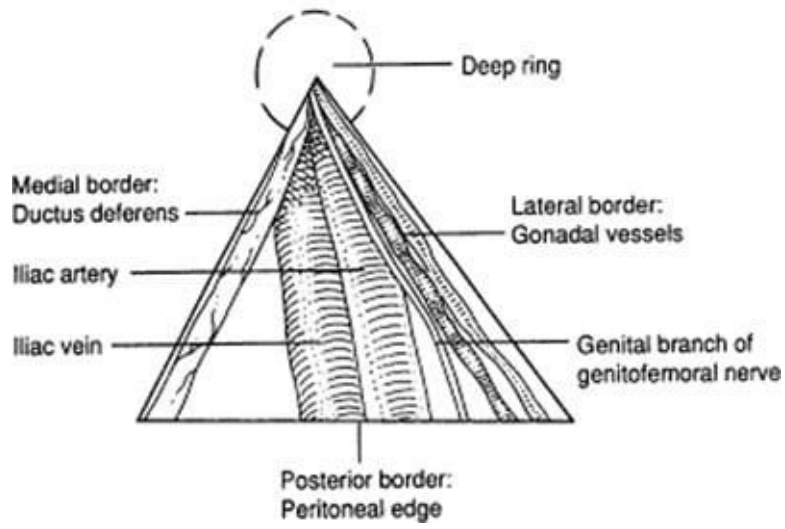
- Medially by the vas deferens
- Laterally by the vessels of the spermatic cord (gonadal vessels)
- Inferiorly by peritoneal reflection

Apex oriented superiorly at **internal ring**.

The contents of the space include

- External iliac vessels
- Deep circumflex iliac vein
- Femoral nerve
- Genital branch of the genitofemoral nerve

The Triangle of Doom



72. Regarding desmoid tumour which is not correct ?

a) Often seen below the umbilicus

b) Unencapsulated

c) More common in women

d) Highly radiosensitive

Correct Answer - D

Ans. is 'd' i.e., Highly radiosensitive

Desmoid tumour is an aggressive fibromatosis or musculoaponeurotic fibromatosis is a monoclonal fibroblastic proliferation arising in musculoaponeurotic structures.

Histologically these tumours are consist of spindle shaped cells in collagenous matrix and lack the pleomorphic, atypical or hyperchromatic nuclei of malignancy.

A minority of desmoid tumours are associated with Gardener syndrome and mutations of familial adenomatous polyposis (FAP) gene.

Most spontaneous desmoid tumours are associated with mutations of beta-catenin gene.

73. Burst abdomen most commonly occurs on the

a) 2nd day

b) 3rd day

c) 7th day

d) 9th day

Correct Answer - C

Ans. is 'c' i.e., 7th day

- *Burst abdomen occurs mostly between the 7th and 10th day after operation (but may occur anytime after surgery from 1 to more than 20 days)(ref Sabiston 18/e)*

74. False regarding hypernephroma is -

a) Radiosensitive

b) Arise from cortex usually from pre existing adenoma

c) May present with rapidly developing varicocele

d) Usually adenocarcinoma

Correct Answer - A

Ans. is 'a' i.e., Radiosensitive

RCC or hypernephroma is one of the most *radioresistant* and *chemoresistant* tumors.

In men rapidly developing varicocele is rare but impressive sign for RCC occurring most often on the left side. It occurs because left gonadal vein is obstructed where it joins the left renal vein.

As already stated RCC originates in the cortex and tends to grow out into perinephric tissue causing characteristic bulge or mass effect.

About adenomas

Adenomas are the *most common benign renal parenchymal lesions.*

- Despite the classification of adenoma as a benign tumor, *no clinical, histologic or immunohistochemical criteria can differentiate renal adenoma from renal carcinoma.*

- Smith's Urology writes about adenomas ?

- "Previously, all renal tumors less than 3 cm were considered adenomas. However, even such small tumors can metastasize and are now classified as renal cell carcinoma. Adenomas of any size should be treated as a fortuitous finding representative of an early renal cancer, and the patient should be evaluated and treated appropriately."

75. The posterior urethra is best visualized by ?

a) Static cystogram

b) Retrograde urethrogram

c) Voiding cystogram

d) CT cystogram

Correct Answer - C

Ans. is 'c' i.e., Voiding Cystogram

Voiding cystourethrography is the best method to visualize posterior urethra.

Remember,

Urethra can be imaged radiographically in two ways.

- Anterograde techniques —> *Best for visualization of posterior urethra.* (This is done along with voiding cystourethrography or with voiding following excretory urography)
- Retrograde technique —> *Best for examining the anterior (penile) urethra* (Contrast is injected through tip of urethra).

76. The Grayhack shunt is established between:

a) Corpora cavernosa and dorsal vein

b) Corpora cavernosa and saphenous vein

c) Corpora cavernosa and glans

d) Corpora cavernosa and corpora spongiosa

Correct Answer - B

Ans is 'b' i.e. Corpora cavernosa and saphenous vein

The Grayhack shunt is a surgical shunt between corpora cavernosa and the saphenous vein done for the treatment of ischemic priapism.

Priapism is an uncommon condition of prolonged erection. It is usually painful for the patient, and no sexual excitement or desire is present.

Priapism may be classified into high- and low-flow types (Nonischemic and ischemic).

Nonischemic (High flow) priapism:

- Nonischemic priapism, also termed arterial or high-flow priapism, features elevated vascular flow through the corpora cavernosa.
- It usually occurs secondary to perineal trauma, which injures the central penile arteries and results in loss of penile blood-flow regulation.
- Aspiration of penile blood for blood-gas determination demonstrates high oxygen and normal carbondioxide levels.
- Arteriography is useful to demonstrate aneurysms that will respond to embolization.
- Erectile function is usually preserved.

Ischemic (low-flow) priapism:

- Ischemic priapism, also termed veno-occlusive or low-flow priapism,

features little or absent intracorporal blood flow. It represents a true compartment syndrome involving the penis, needing emergency management.

- It is typically painful.
- The corpora cavernosa is tense with congested blood and tender to palpation. The glans penis and corpus spongiosum are soft and uninvolved in the process.
- The current theories regarding the mechanism of priapism remain in debate, but most authorities believe the major abnormality to be physiologic obstruction of the venous drainage. This obstruction causes buildup of highly viscous, poorly oxygenated blood (low O₂, high CO₂) within the corpora cavernosa.
- If the process continues for several days, interstitial edema and fibrosis of the corpora cavernosa will develop, causing impotence.

Treatment

- Ischemic priapism is a urologic emergency.
 - First-line treatment consists of aspiration of blood and irrigation of the corpora cavernosa (via a needle put in the corpora cavernosa) along with intracavernous injection of an α -adrenergic sympathomimetic agent (phenylephrine). (Sympathomimetic agents can be expected to exert contractile effects on the cavernous tissue and thus facilitate detumescence.)
 - Surgical shunting is needed when the intracavernous treatment fails.

A surgical shunt has the objective of facilitating blood drainage from the corpora cavernosa, bypassing the venoocclusive mechanism of these structures. A variety of shunt procedures may be performed. A distal cavernoglanular (corporoglanular) shunt is the first choice.

77. Which of the following urethral anomaly is the most common -

a) Hypospadias

b) Pin hole meatus

c) Epispadias

d) Stricture urethra

Correct Answer - A

Ans. is 'a' i.e., Hypospadias

- Hypospadias is a condition in which the *urethral meatus opens on the underside of penis** or the perineum (i.e. *ventral surface of penis*) proximal to the tip of the glans penis.
- Hypospadias is the *most common* congenital malformation* of the urethra. (*also know that the most common congenital malformatio of the urinary tract is Duplication of renal pelvis**)
- Occurs in 1:250 male births.

78. All the features of membranous urethral injury except

a) blood of meatus

b) Retention of urine

c) Pelvic fracture

d) Perineal butterfly hematoma

Correct Answer - D

Ans. is 'd'

1. Urethral rupture is also of two types:

- a. Bulbar urethral injury - MC
- b. Membranous urethral injury

2. Extravasation of urine (+ blood) in bulbar urethral injury

- a. It is a superficial extravasation.
- b. If the Buck's fascia remains intact, extravasation of blood and urine are confined to the penile shaft. However disruption of Buck's fascia allows extravasated contents into a space limited by colle's fascia forms a scrotal and perineal butterfly hematoma which can extend up the abdominal wall.

3. Extravasation of urine in Membranous urethral injury & Extraperitoneal bladder rupture.

- a. Extravasation is same in both
- b. It is a deep extravasation
- c. Urine extravasates in the layers of the pelvic fascia and the retroperitoneal tissues
- d. Urine collects in the perivesical space.
- e. The typical finding on cystogram is extravasation of contrast material into the pelvis around the base of the bladder.

79. Congenital hydrocele is best t/t by -

a) Eversion of sac

b) Excision of sac

c) Lords procedure

d) herniotomy

Correct Answer - D

Ans. is 'd' ie. Herniotomy

- *Bailey writes ?*

"Congenital hydrocele are a special form of indirect inguinal hernia and are treated by herniotomy."

- *Congenital hydrocele*

In this condition the processus vaginalis remain patent so there is direct communication of the tunica vaginalis with the peritoneal cavity. The communicating orifice at the deep inguinal ring is too small for the development of hernia.

- It is present since birth*.

In contradiction to assumption. congenital hydrocele is not easily reducible* due to narrowness of the deep inguinal ring but when the child lies supine, it disappears.

80. Which one of the following statement is true of undescended testis -

a) Usually descends spontaneously at puberty

b) Orchiopexy to be done if no descent by puberty

c) Has a higher incidence of malignancy

d) Maintains normal sperm production

Correct Answer - C

Ans. is 'c' i.e., Has a higher incidence of malignancy

TREATMENT-

- * Orchiopexy done before 6 months of age
- * Orchiectomy- patient with incomplete descended testis is atrophic, past puberty and normal testis
- * Orchiopexy's operation in bilateral cases
- * HCG or GnRH- cryptorchidism associated with hypogonadism and obesity
- * Approximately UDT spontaneously descend by 3 months of age
- * Secondary sexual characteristics are normal

81. What is oliguria -

a) Excretion of less than 300ml in 24 hrs

b) Excretion of less than 500ml in 24 hrs

c) Excretion of less than 300 ml. in 12 hrs

d) Excretion of less than 100 ml. in 24 hrs

Correct Answer - B

Ans. is 'b' i.e., Excretion of less than 500 ml in 24 hrs

(Note that Bailey & Love 25/e p1279 (24/e p 1300 & 23/e p 1168) write Oliguria to be less than 300 ml in 24 hrs, but we would follow Harrison & CMDT; Note that Smith's Urology 17/e p531 (16/e, p538) write it to < 400 ml/day!! what an utter confusion.)

82. Tissue suturing glue contains:

a) Cyanoacrylate

b) Ethanolamine oleate

c) Methacrylate

d) Polychloroprene

Correct Answer - A

Ans is 'a' i.e. Cyanoacrylate

Most tissue adhesives or glue are cyanoacrylate polymers, such as n-butyl-2-cyanoacrylate (eg, Histoacryl®, PeriAcryl®) or 2-octyl cyanoacrylate (eg, Dermabond®, Surgiseal).

Cyanoacrylate tissue adhesives are liquid monomers that undergo an exothermic reaction on exposure to moisture (eg, on the skin surface), changing to polymers that form a strong tissue bond. When applied to a laceration, the polymer binds the wound edges together to allow normal healing of the underlying tissue.

Compared with wounds closed with sutures, the tensile strength of wounds closed by tissue adhesives is less at the time of initial application, but equalizes by one week post-repair.

Advantages:

- Less painful application, and sometimes no need for local anesthetic injection
- More rapid application and repair time
- Cosmetically similar results at 12 months post-repair
- Waterproof barrier
- Antimicrobial properties
- Better acceptance by patients
- No need for suture removal or follow-up
- **Indications and contraindications:**

- For use of tissue adhesives the wound needs to be clean, dry with near perfect hemostasis and under no tension.
- Complex stellate lesions or crush injuries should not be closed with tissue adhesives since good wound approximation is difficult to achieve.
- Tissue adhesives are not recommended for lacerations of the hands, feet, or joints, since repetitive movements could cause the adhesive bond to break before sufficient tensile strength is achieved.
- Tissue adhesives are not recommended for the oral mucosa or other mucosal surfaces or areas of high moisture such as the axillae and perineum.
- Lacerations involving the hairline or vermilion border require more precision, and should be repaired with traditional sutures.

83. The tensile strength of wound reaches that of tissue by ?

a) 6 weeks

b) 2 months

c) 4 months

d) None

Correct Answer - D

Ans. is 'None'

It never equals the tensile strength of unwounded skin.

Robbin's writes- "How long does it take for a skin wound to achieve its maximal strength? When sutures are removed from an incisional surgical wound, usually at the end of the first week, wound strength is approximately 10% that of unwounded skin. Wound strength increases rapidly over the next 4 weeks, slows down at approximately the third month after the original incision, and reaches a plateau at about 70% to 80% of the tensile strength of unwounded skin."

84. The following statement about keloid is true ?

- a) They do not extend into normal skin
- b) Local recurrence is common after excision
- c) They often undergo malignant change
- d) They are more common in whites than in blacks

Correct Answer - B

Ans. is 'b' i.e., Local recurrence is common after excision

- A keloid scar is defined as excessive scar tissue that extends beyond the boundaries of the original incision or wound.
- Features-**
- It continues to get worse even after 1 year and up to a few years.
 - Severe itching is present
 - Margin is tender
 - Vascular, red, erythematous (immature blood vessels)
 - Extends to normal tissues, has a claw-like process. Hence the name.
- Risk factors-**
- Black race
 - Tuberculosis patients
 - Incision over the sternum, ear lobe
 - Equal in both sexes
 - Hereditary and familial
 - Vaccination sites, injection sites
- Treatment-**
- Injection of steroid preparation such as triamcinolone acetate (Kenacort) has been found to be extremely useful.

- It flattens the keloid. Intra keloidal excision and skin grafting are to be tried last.
- Recurrence is common. (Any form of excision has a high chance of recurrence)
- Care should be taken not to extend the incision on to the normal surrounding tissues.
- Silicone application
- Topical retinoids

85. The Vitamin which has inhibitory effect on wound healing is -

a) Vitamin -A

b) Vitamin - E

c) Vitamin -C

d) Vitamin B-complex

Correct Answer - B

Ans. is 'b' i.e., Vitamin-E.

- *Systemic vitamin E and glucocorticoids inhibit the inflammatory response and collagen synthesis, thereby possibly impeding the healing process.*

86. Best skin disinfectant for central line insertion is:

a) Povidone iodine

b) Alcohol

c) Cetrimide

d) Chlorhexidine

Correct Answer - D

Ans is 'd' i.e. Chlorhexidine

"Chlorhexidine is now the disinfectant recommended for all catheter placement procedures and for routine site cleansing during dressing changes."- Comprehensive Hospital Medicine: An Evidence-Based And Systems Approach By Mark V. Williams, Scott A. Flanders, p320

"Use of antiseptic solution for skin disinfection at the catheter insertion site helps prevent catheter-related infection. Chlorhexidine-based solutions appear to be superior to both aqueous and alcohol-based povidone-iodine in reducing the risk for catheter colonization and catheter-related bloodstream infection. If there is a contraindication to chlorhexidine, tincture of iodine, an iodophor or 70 percent alcohol can be used as alternatives"-uptodate.com

87. Complication of total parenteral nutrition include ?

a) Hyperglycemia

b) Hyperkalemia

c) Hyperosmolar dehydration

d) a and b

Correct Answer - D

Ans. is 'a' i.e. Hyperglycemia, 'b' i.e. Hyperkalemia

Metabolic complication

- Azotemia
- Essential fatty acid def.
- Fluid overload
- Metabolic bone ds.
- Liver dysfunction
- Glucose imbalance (Hyperglycemia, hypoglycemia)
- Trace elements & vitamin deficiency
- Electrolyte abnormalities
 - n Hyponatremia, hyponatremia
 - n Hyperkalemia, hypokalemia
 - a Hyperphosphatemia, hypophosphatemia
 - n Hypermagnesemia, hypomagnesemia
 - n Hypercalcemia, hypocalcemia
 - n High serum zinc, low serum zinc
 - n High serum copper, low serum copper

88. Content of Na' in ringer lactate is meq/1-

a) 154

b) 12

c) 130

d) 144

Correct Answer - C

Ans. is 'c' i.e., 130

1. 5% Dextrose / 10% Dx	Nil
2. N/2 saline	77 meq
3. N/5 saline	30 meq
4. 3% salime	513 meq
5. Ringer lactate	130 meq
6. Isolyte P.	26 meq

89. Actinomyces is sensitive to ?

a) Streptomycin

b) Nystatin

c) Penicillin

d) Iodoquinol

Correct Answer - C
Ans. is 'c' i.e., Penicillin

90. Liver transplantation was first done by ?

a) Starzl

b) Huggins

c) Carrel

d) Christian Benard

Correct Answer - A

Ans. is 'a' i.e., Starzl

The first human liver transplant was performed in 1963 by Dr. Thomas Starzl.

91. True about Marjolin's ulcer -

a) Develops in long standing scar

b) Sq cell Ca develops

c) Slow growing lesion

d) All

Correct Answer - D

Ans is 'a' i.e. Develops in long standing scar; 'b' i.e. sq cell Ca develops; 'c' i.e. Slow growing lesion

Baghdad sore or oriental sore or Delhi boil is caused by Leishmania Tropica.

92. Ainhum is seen in ?

a) Base of great toe

b) Base of fingers tips

c) Base of toe

d) Ankle

Correct Answer - C

Ans. is 'c' i.e., Base of Toe

- Ainhum : is a condition usually affecting Negro males (but some females) who have run barefoot in child hood.

Clinical Features : A fissure appears at interphalangeal joint of toe - usually the fifth.

This fissure becomes a fibrous band, encircles the digit and causes necrosis.

93. How much length is increased in Z plasty when it is done at 60 degrees?

a) 25%

b) 50%

c) 75%

d) 100%

Correct Answer - C

Ans is 'c' i.e. 75%

- Z-plasty is a very common interposition surgical technique utilized in plastic and reconstructive surgery to revise scars.
- In general, the greater the angle, the greater the gain in wound length.

Tissue Lengthening with Z-Plasty

Type of <u>Z-Plasty</u>	<u>Increase in Length of Central Limb (%)</u>
Simple 45-degree	50
Simple 60-degree	75
Simple 90-degree	100
Four-flap with 60-degree angles	150
Double-opposing	75
Five-flap	125

Or

Angles compared to gain in length are as follows:

30-degree angle results in a 25% gain in length

45-degree angle results in a 50% gain in length

60-degree angle results in a 75% gain in length

75-degree angle results in a 100% gain in length

90-degree angle results in a 125% gain in length

94. The procedure of choice for the evaluation of aortic aneurysm is -

a) Ultrasonography

b) Computed tomography

c) Magnetic resonance imaging

d) Arteriography

Correct Answer - B

Ans. is 'b' i.e. Computed tomography

- *"CT is the most precise test for imaging aortic aneurysm" - Sabiston*
- *'As a preoperative scanning tool, CT scan is the gold standard. Angiography has largely been replaced by contrast CT scanning" - Schwartz*

95. Pseudoclaudication is caused by

a) Femoral Artery stenosis

b) Popliteal Artery stenosis

c) Lumbar canal stenosis

d) Radial Artery stenosis

Correct Answer - C

Ans is C i.e. Lumbar Canal Stenosis

Pseudoclaudication is the term used for neurogenic claudication caused due to lumbar canal stenosis. Its symptoms mimic intermittent claudication of PVD.

Neurogenic claudication, consists of back and buttock or leg pain induced by walking or standing and relieved by sitting or changing posture. Symptoms in the legs are *usually bilateral*. Unlike vascular claudication, symptoms are often provoked by standing without walking.

Spinal stenosis can be acquired, congenital, or due to a combination of these factors. Congenital causes include achondroplasia, idiopathic. Acquired causes are degenerative diseases (spondylosis, spondylolisthesis, scoliosis), trauma, spine surgery, metabolic or endocrine disorders (epidural lipomatosis, osteoporosis, acromegaly, renal osteodystrophy, hypoparathyroidism), and Paget's disease.

Difference between Vascular and Neurogenic claudication

- Patients with vascular claudication always have pain when they walk a relatively constant distance on level ground; they do not have variable days when they can walk for considerably greater distances without pain. Patients of vascular claudication, often know exactly how far or for how long they can walk before the symptoms will

occur. This is in contrast to patients with neurogenic claudication where the symptoms occasionally occur at rest or at with highly variable walking distances. Pain in neurogenic claudication can even occur on standing.

- Pain of vascular claudication gets relieved on stopping within few minutes, and this resolution of pain occurs even if the patient simply stops and stands in place. Patients with neurogenic claudication usually have to sit down to relieve their pain. Neurogenic claudication pain gets relieved by changing posture and leaning forwards.
- Patients with neurogenic claudication often can walk further on an incline, whereas vascular claudication is marked worsened if the patient is on an incline.

96. Kaposi sarcoma is commonly seen in ?

a) Upper limbs

b) Lower limbs

c) Head and Neck

d) Trunk

Correct Answer - B

Ans. is 'b' i.e., Lower limbs

" It occurs predominantly on the skin and can involve virtually any organ, perhaps except the brain. The initially described form, now known as classic KS, predominantly involves the lower extremities of elderly men. KS is now the most common tumor seen in HIV-infected patients"- Devita's Oncology

97. All of the following are risk factors for deep vein thrombosis (DVT) except -

a) Duration of surgery more than thirty minutes

b) Obesity

c) Age less than forty years

d) Use of the oestrogen-progesterone contraceptive pills

Correct Answer - C

Ans. is 'c' i.e., Age less than 40 years

98. DVT, investigation of choice is -

a) Doppler

b) Plethysmography

c) Venography

d) X-ray

Correct Answer - A

Answer is 'a' i.e. Doppler

- Doppler USG is the first investigation of choice for DVT.

99. Surgery in varicose veins is NOT attempted in presence of -

a) Deep vein thrombosis

b) Multiple incompetent perforators

c) Varicose veins with leg ulcer

d) All of the above

Correct Answer - A

Ans. is 'a' i.e., Deep vein thrombosis

Deep vein thrombosis is a contraindication for varicose veins.

Varicose vein surgery should never be attempted in a case where deep vein thrombosis exists along with varicose veins, because in these cases superficial veins are the only valved venous pathway and excising them will only aggravate the condition.

100. Treatment of rib fracture ?

a) Immediate thoracotomy

b) IPPV

c) Analgesics

d) b and c

Correct Answer - C

Answer is 'c' i.e. Analgeic

Rib fractures are the most common injuries after blunt chest trauma.

Ribs 4 to 10 are usually fractured.

- Management of # rib
 - *Pain control with oral or i.v. analgesics or intercostal nerve blocks or epidural analgesia. (Poor pain control significantly contributes to complications such as atelectasis and pneumonia)*
 - *Chest strapping is no longer advised.*
- Management of flail chest, as mentioned in previous question, may need IPPV.

101. Trauma and Injury Severity Score (TRISS) includes:

a) GCS + BP + RR

b) RTS + ISS + Age

c) RTS + ISS + GCS

d) RTS + GCS + Age

Correct Answer - B

Ans is `b' i.e. RTS + ISS + Age

TRISS (Trauma and Injury Severity Score) :

- Injury Severity Score
- Revised Trauma Score
- Age
- Mechanism of Injury (blunt/penetrating)

102. Treatment of choice for stab injury caecum ?

a) Caecostomy

b) Ileo-transverse anastomosis

c) Transverse colostomy

d) Sigmoid colostomy

Correct Answer - B

Ans. is 'b' i.e., ileo-transverse anastomosis

Stab and low-velocity injuries to the colon with minimal contamination and hemodynamical stability can be managed by primary repair mechanisms like ileotransverse anastomosis.

103. Brain abscess in cyanotic heart disease is commonly located in

a) Cerebellar hemisphere

b) Thalamus

c) Temporal lobe

d) Parietal lobe

Correct Answer - D

Ans. is 'd' i.e. Parietal lobe

Brain abscesses in congenital cyanotic heart diseases occur due to hematogenous seeding of bloodborne bacteria. These blood borne bacteria bypass the pulmonary capillary bed d/t *right to left shunt*. They commonly infect *parietal & frontal lobes* (territory of middle cerebral artery).

Location of Brain Abscesses

Etiology	Location
Otitis media, mastoiditis	Temporal lobe > Cerebellum
Paranasal sinusitis, dental inf.	Frontal lobes
Hematogenous	Parietal lobe, post-frontal lobes (MCA territory)

**104. All are true about carcinoma palate,
except -**

a) Slow growing

b) Bilateral lymphatic spread

c) Adenocarcinoma

d) Presents with pain

Correct Answer - D
Ans. is 'd' i.e., Presents with pain

105. Epulis arises from -

a) Enamel

b) Root of teeth

c) Gingiva

d) Pulp

Correct Answer - C

Answer is 'c' i.e. Gingiva

Epulis literally means '*upon the gum*'. Thus it is a swelling situated on the gum.

It can originate from the mucous membrane, the periosteum or the bone giving rise to different varieties of Epulis.

106. Commonest site of carcinoma tongue -

a) Apical

b) Lateral borders

c) Dorsum

d) Posterior 1/3

Correct Answer - B

Ans. is 'b' i.e., Lateral borders

Most common site is middle of the lateral border or the ventral aspect of the tongue.

**107. In case of benign mixed parotid tumours
T/t of choice is -**

a) Superficial Parotidectomy

b) Total parotidectomy

c) Leave facial nerve and remove all gland

d) Radical Parotidectomy

Correct Answer - A

Ans is 'a' ie Superficial parotidectomy

Schwartz writes - "*Treatment of benign neoplasms is surgical excision of the affected gland or, in the case of the parotid, excision of the superficial lobe with facial nerve dissection and preservation.*

The minimal surgical procedure for neoplasms of the parotid is superficial parotidectomy with preservation of the facial nerve.

'Shelling out' of the tumor mass is not recommended because of the risk of incomplete excision and tumor spillage."

*Superficial **parotidectomy** is the **treatment of choice** for most **benign tumors** in the superficial lobe.*

108. True regarding cystic hygroma is -

a) Non transilluminant

b) Lined by columnar epithelium epithelium

c) Develops from jugular lymphatic sequestration

d) All

Correct Answer - C

Ans. is c i.e., Develops from jugular lymphatic sequestration

Cystic hygroma

- Cystic hygroma is a swelling usually occurring in the lower third of the neck
- It is most commonly seen in posterior triangle of the neck, but may also occur in axilla, groin & mediastinum
- It results due to sequestration of a portion of the jugular lymph sac from the lymphatic system.
- It usually manifests in the neonate or in early infancy (occasionally present at birth)
- The swelling is soft and partially compressible and invariably increases in size when the child coughs or cries.
- The characteristic that distinguishes it from all other neck swellings is that it is brilliantly translucent.
- The cysts are filled with clear lymph and are lined by endothelium.
- Mostly these are multiple cysts but occasionally they can be unilocular.
- It may show spontaneous regression.

Treatment [Ref.: Sabiston 18/e p2053; Schwartz 9/e p1415]

There are two methods of treatment: Surgical excision & Sclerotherapy

Sabiston writes- "Complete surgical excision is the preferred

treatment; however, this may be impossible because of the hygroma infiltrating within and around important neurovascular structures.

Because hygromas are not neoplastic tumors, radical resection with removal of major blood vessels and nerves is not indicated.

Injection of sclerosing agents such as bleomycin or the derivative of Streptococcus pyogenes OK-432 have also been reported to be effective in the management of cystic hygromas. Intracystic injection of sclerosants appears to be most effective for macrocystic hygromas, as opposed to the microcystic variety."

"The modern management of most cystic hygromas includes the combination of surgical excision and image-guided sclerotherapy."- Schwartz

109. The best treatment for cystic hygroma is

-

a) Surgical excision

b) Radiotherapy

c) Sclerotherapy

d) Chemotherapy

Correct Answer - A

Ans. is 'a' i.e., Surgical Excision

Definitive treatment is complete excision of the cyst at an early age.

110. Sistrunk's operation is used in

a) Parotid tumour

b) Thyroglossal fistula

c) Thyroglossal cyst

d) b and c

Correct Answer - D

Ans. Two options are correct i.e., 'b' i.e. Thyroglossal fistula & 'c' i.e. Thyroglossal cyst

Sistrunk procedure is used for excision of **thyroglossal duct cyst**

111. Adson's test is positive in -

a) Cervical rib

b) Cervical spondylosis

c) Cervical fracture

d) Cervical dislocation

Correct Answer - A

Ans. is 'a' i.e., Cervical rib

Adson's test is a provocative test for Thoracic Outlet Syndrome accompanied by compression of the Subclavian artery by a cervical rib or tightened anterior and middle scalene muscles.

112. Neuroblastomas - good prognostic factor is ?

a) N-myc amplification

b) RAS oncogene

c) Hyperdiploidy

d) Translocations

Correct Answer - C
Answer is 'c' i.e. Hyperdiploidy

113. Opsoclonus - Myoclonus is a phenomenon seen in ?

a) Wilms tumor

b) Neuroblastoma

c) Meningioma

d) Cortical tuberculoma

Correct Answer - B

Ans. is 'b' i.e., Neuroblastoma

Opsoclonus is a disorder of eye movement characterized by involuntary, chaotic saccades that occur in all directions of gaze. It is frequently associated with myoclonus and ataxia.

Opsoclonus-myoclonus may be cancer-related or idiopathic.

When the cause is paraneoplastic, the tumors involved are usually cancer of the lung and breast in adults and neuroblastoma in children.

114. In thymoma, all are seen except -

a) Hypogamma globulinemia

b) Hyperalbuminemia

c) Red cell aplasia

d) Myasthenia Gravis

Correct Answer - B

Ans is (b) i.e. hyperalbuminemia

- Thymoma is the most common Anterior mediastinal mass.
- Thymomas are seen to be associated with

Myasthenia gravis

Acquired hypogammaglobulinemia

Pure red cell aplasia Grave's ds

- *Pernicious anemia*
- *Dermatomyositis-polymyositis*
- *Cushing syndrome*

115. Intralobar sequestration of lung takes its blood supply from -

a) Internal mammary artery

b) Descending abdominal aorta

c) Pulmonary artery

d) None of the above

Correct Answer - B

Ans. is 'b' i.e., Descending abdominal aorta

- A sequestration consists of normally developed bronchioles and alveoli *supplied by systemic rather than pulmonary arteries.*
- *This blood supply is from the Aorta either above or below the diaphragm.*
- *Mostly (approx 95%) this is from the descending thoracic aorta.*
- **Other characteristic features of sequestration -**
- They occur most commonly in the lower lobes, L > R
- Lung sequestrations are of two types

116. Foreign body aspiration in supine position causes which of the following parts of the lung commonly to be affected -

a) Apical left lobe

b) Apical lobe of right lung

c) Apical part of the lower lobe

d) Posterobasal segment of left lung

Correct Answer - C

Ans. is 'c' i.e. Apical part of right lower lobe

- *Right upper lobe - posterior segment*
- *Right lower lobe - superior segment*
- *Left lower lobe - superior segment*
- *Right basilar segments (of lower lobe)*

117. IVC filter is used in following except -

a) To reduces symptoms

b) Negligible size of emboli

c) To prolong life

d) To prevent progress of native blood vessel disease

Correct Answer - B

Answer is 'b' i.e. Negligible size of emboli

118. Empyema necessitans is defined as so when ?

a) Plural empyema is under pressure

b) Pleural empyema has ruptured into bronchus

c) Pleural empyema has ruptured into the pericardium

d) Pleural empyema is showing extension to the subcutaneous tissue

Correct Answer - D

Ans. is 'd' i.e., Pleural empyema is showing extension to the subcutaneous tissue

**119. All of the following about
Gastrointestinal carcinoid tumors are
true, Except:**

a) Small intestine and appendix account for almost 60% of all gastrointestinal carcinoid

b) 5 year survival for carcinoid tumors is >60%

c) Rectum is spared

d) Appendiceal carcinoids are more common in females than males

Correct Answer - C

Ans is 'c' i.e. Rectum is spared

Rectum is not spared, but is infact a common site for carinoid tumor.

About other options:

5 year survival for carcinoid tumors is >60%

Sabiston writes-" Carcinoid tumors have the best prognosis of all small bowel tumors, whether the disease is localized or metastatic.

Resection of a carcinoid tumor localized to its primary site

approaches a 100% survival rate. Five-year survival rates are about 65% among patients with regional disease and 25% to 35% among those with distant metastasis."

Appendiceal carcinoids are more common in females than males

"Appendiceal carcinoids are more common in females. Two to three cases of appendiceal carcinoids are female."- Sleisenger and Fordtran's Gastrointestinal and Liver Disease 8/e p609

Small intestine and appendix account for almost 60% of all gastrointestinal carcinoid

Data from various books vary but as far as the question goes this

can be taken to be true as option 'c' is definitely wrong. In GIT small intestine and the appendix are the most common sites. Infact small intestine is the 2nd most common site in body after bronchus.

[Note that several textbooks including Schwartz and Sabiston, mention Appendix as the most common site of GI carcinoids, which is not true according SEER data (given in Harrison)]

120. Radiation exposure during infancy has been linked to which one of the following carcinoma -

a) Breast

b) Melanoma

c) Thyroid

d) Lung

Correct Answer - C

Ans. is 'c' i.e., Thyroid

"Differentiated thyroid carcinoma particularly papillary variety frequently follows accidental irradiation of thyroid in infancy and childhood" - Bailey

- Radiation induced cancers
- Radiation may induce some non-lethal changes in DNA sequences which may cause malignant transformation

121. Smoking may be associated with all of the following cancers, except:

a) Ca Larynx

b) Ca Nasopharynx

c) Ca Bladder

d) None

Correct Answer - D

Ans is None > Ca Nasopharynx

All the given options are mentioned by Harrison:

- *Harrison 17/e p2737 writes- "Tobacco smoking causes cancer of the lung, oral cavity, naso-, oro-, and hypopharynx, nasal cavity and paranasal sinuses, larynx, esophagus, stomach, pancreas, liver, kidney (body and pelvis), ureter, urinary bladder, and uterine cervix and also causes myeloid leukemia. There is evidence suggesting that cigarette smoking may play a role in increasing the risk of colorectal and possibly premenopausal breast cancer, but there is no association with postmenopausal breast cancer. There does not appear to be a causal link between cigarette smoking and cancer of the endometrium, and there is a lower risk of uterine cancer among postmenopausal women who smoke."*
- Thus the answer should be none, however Nasopharyngeal carcinoma is found to be least associated with smoking. Head & Neck Cancers by Enslow Jacobs 2003e p492 writes-"Association between smoking and nasopharyngeal carcinoma has been shown only by a few studies. If the association of tobacco and NPC is real, the possible mechanism of tumor induction would be the nitrosamines and its precursors in tobacco."

122. What is the treatment of choice in desmoid tumors ?

a) Irradiation

b) Wide excision

c) Local excision

d) Local excision following radiation

Correct Answer - B
Ans. is 'b' i.e., Wide excision

123. The commando operation is -

a) Abdomino-perineal resection of the rectum for carcinoma

b) Disarticulation of the hip for gas gangrene of the leg

c) Extended radical mastectomy

d) Excision of carcinoma of the tongue, the floor of the mouth, part of the jaw and lymph nodes enbloc

Correct Answer - D

Ans. is 'd' i.e., Excision of carcinoma of the tongue, the floor of the mouth, part of the jaw and lymph nodes enbloc

124. Corpora amylaciae is seen in -

a) Thymus

b) Lymph node

c) Spleen

d) Prostate

Correct Answer - D
Ans. is 'd' i.e., Prostate

125. Stereotactic radiosurgery is done for -

a) Glioblastoma multiforme

b) Medulloblastoma spinal cord

c) Ependymoma

d) AV malformation of brain

Correct Answer - D

Ans. is 'D' i.e., AV malformation of brain

It is also used for-

1. Solitary cerebral metastasis
2. Arteriovenous malformation
3. Small meningiomas
4. Schwannomas
5. Pituitary adenomas

126. In which one of the following conditions is gas under diaphragm not seen-

a) Perforated duodenal ulcer

b) Typhoid perforation

c) After laparotomy

d) Spontaneous rupture of oesophagus

Correct Answer - D

Ans. is 'd' i.e., Spontaneous rupture of oesophagus

- Chilaiditi's syndrome : Condition characterised by inter position of small or large bowel between liver and right diaphragm. Radiologically it gives gas under diaphragm.
- Iatrogenic pneumoperitoneum : Certain procedure like peritoneal dialysis, Iatrogenically air pushed before putting PD cannula to avoid injury of viscera in such case gas under diaphragm can be seen.
- All cases when intestine or viscera perforate we can get gas under diaphragm.

127. All of the following are true regarding fluid resuscitation in burn patients except:

- a) Consider intravenous resuscitation in children with burns greater than 15% TBSA
- b) Oral fluids must contain salts
- c) Most preferred fluid is Ringer's lactate
- d) Half of the calculated volume of fluid should be given in first 8 hours

Correct Answer - A

Ans. A: Consider intravenous resuscitation in children with burns greater than 15% TBSA

In children with burns over 10% TBSA and adults with 15% TBS, consider the need for intravenous fluid resuscitation.

If oral resuscitation is to be commenced, it is important that the water given is not salt free.

Preferred fluid: Lactated Ringer's Solution, because it is:

* Isotonic

* Cheap

* Easily stored

- Resuscitation formulas: Parkland formula most commonly used
- Fluid calculation: $4 \times \text{weight in kg} \times \% \text{TBSA burn}$
- Give 1/2 of that volume in the first 8 hours. Give other 1/2 in next 16 hours
- TBSA: Total burns surface area.

128. The following *is* the commonest site for venous ulcer:

March 2013 (a, e)

a) Lower third of leg and ankle

b) Instep of foot

c) Lower 2/ 3rd of leg

d) Middle 1/3rd of leg

Correct Answer - A

Ans. A i.e. Lower third of leg and ankle

- Venous ulcers usually lie just proximal to the medial or lateral malleolus.
- *Venous ulcers are accompanied by lipodermatosclerosis and hemosiderosis (if these are not present then the ulcer is probably not of venous origin).*

129. Which of the following is spared in lumbar sympathectomy:
September 2009

a) L1

b) L2

c) L3

d) L4

Correct Answer - A

Ans. A: L1

To preserve sexual functions, L1 is preserved.

130. Brodie-Trendelenburg test is positive in:

a) Deep vein thrombosis

b) Sapheno-femoral incompetence

c) Thromboangiitis obliterans

d) Below-knee perforators incompetence

Correct Answer - B

Ans. B: Sapheno-femoral Incompetence

- A test to assess the competence of the saphenofemoral junction.
- The Brodie-Trendelenburg test is used to detect venous incompetence and to differentiate between perforator and GSV incompetence.
- The Brodie-Trendelenburg test is highly sensitive for the identification of superficial and perforator reflux.
- SFJ (saphenofemoral junction) incompetence is diagnosed if the distal veins fill rapidly upon release of the tourniquet.
- Some textbooks refer to the Trendelenburg test and the tourniquet test interchangeably.

131. Cullen's sign is seen in:
March 2004

a) Acute cholecystitis

b) Acute hepatitis

c) Acute pancreatitis

d) Blunt injury abdomen

Correct Answer - C
Ans. C i.e. Acute pancreatitis

132. Acute pancreatitis causes all of the following except:

March 2005, March 2013 (g)

a) Hypercalcemia

b) Increased amylase level

c) Subcutaneous fat necrosis

d) Hyperlipidemia

Correct Answer - A

Ans. A: Hypercalcemia

Complications of acute pancreatitis:

- Intra-abdominal:

Pancreatic "collections":

- Phlegmon
- Pseudocyst
- Abscess
- Necrosis

Intestinal:

- Paralytic ileus
- Gastrointestinal haemorrhage - from stress ulceration, gastric varices due to splenic vein obstruction, or rupture of pseudoaneurysm
- Necrotising obstruction or fistulisation of colon
 - * Hepatic - obstructive jaundice due to oedematous narrowing of common bile duct
 - * Renal - hydronephrosis and hydroureter of right kidney due to peripancreatic inflammation in perirenal space
 - * Spleen - rupture or haematoma, from spread of peripancreatic

inflammation

Systemic complications range from minor pyrexia to rapidly fatal, multiple organ-system failure. They include:

- * Circulatory shock - kinin activation, haemorrhage
 - * Disseminated intravascular coagulation
 - * Respiratory insufficiency:
 - Mild e.g. hypoxaemia, atelectasis, pleural effusion
 - Severe e.g. adult respiratory distress syndrome
 - * Acute renal failure
 - * Metabolic:
 - Hypocalcaemia
 - Hyperglycaemia / diabetes mellitus
 - Hypertriglyceridaemia
 - * Pancreatic encephalopathy - confusions, delusions, coma
 - * Retinal arteriolar obstruction causing sudden blindness
- Purtscher's retinopathy**
- * Metastatic fat necrosis A serum level three to four times above normal serum amylase level, is indicative of acute pancreatitis, but a normal level does not exclude the disease.

133. Charcot's triad is defined by all of the following except:

September 2007, March 2009

a) Fever

b) Gall stones

c) Jaundice

d) Pain

Correct Answer - B

Ans. **B:** Gall stones

Cholangitis is due to partial or complete obstruction of the biliary tree with resulting bile stasis and secondary bacterial or microbial infection of the biliary tree

Causes ?

- Common bile duct stones
- Benign biliary stricture (primary sclerosing cholangitis)
- Malignancy (head of pancreas adenocarcinoma, ampulla of Vater, bile duct tumors)
- Chronic pancreatitis
- Prosthesis or stents in the common bile duct

Features:

- Charcot's triad - right upper quadrant pain, fever, jaundice
- Reynolds' pentad - right upper quadrant pain, fever, jaundice, hypotension, and mental status changes (delirium, anxiety, and coma)
- Nausea and/or vomiting
- Right upper quadrant tenderness (mild to moderate)

134. Most sensitive and specific for acute pancreatitis amongst the following is:

September 2008

a) S.amylase

b) S.Alanine transaminase

c) S.lipase

d) C-reactive protein

Correct Answer - C

Ans. C: S.lipase

Serum markers for diagnosis of acute pancreatitis:

- Alanine transaminase-Associated with gallstone pancreatitis; three fold elevation or greater in the presence of acute pancreatitis has a positive predictive value of 95 percent in diagnosing acute gallstone pancreatitis
- Amylase
- Most accurate when at least twice the upper limit of normal; amylase levels and sensitivity decrease with time from onset of symptoms
- C-reactive protein
- Late marker; high levels associated with pancreatic necrosis
- Lipase
- Increased sensitivity in alcohol-induced pancreatitis; more specific and sensitive than amylase for detecting acute pancreatitis
- Phospholipase A2
- Associated with development of pancreatic necrosis and pulmonary failure
- Procalcitonin

- Early detection of severity; high concentrations in infected necrosis
- Trypsinogen activation peptide
- Early marker for acute pancreatitis and close correlation to severity

**135. Treatment of an incidentally detected
Appendicular carcinoid measuring 2.5
cm is:
*September 2002***

a) Right hemicolectomy

b) Limited resection of the right colon

c) Total colectomy

d) Appendectomy

Correct Answer - A
Ans. A i.e. Right hemicolectomy

136. Heller's myotomy is done for:
September 2007, 2009, 2010

a) Esophageal carcinoma

b) Pyloric hypertrophy

c) Achalasia cardia

d) Inguinal hernia

Correct Answer - C

Ans. C: Achalasia cardia

Achalasia is associated with loss of ganglion cells in the esophageal myenteric plexus.

These important inhibitory neurons induce LES relaxation and coordinate proximal-to-distal peristaltic contraction of the esophagus. Achalasia is an esophageal motor disorder characterized by increased lower esophageal sphincter (LES) pressure, diminished-to-absent peristalsis in the distal portion of the esophagus composed of smooth muscle, and lack of a coordinated LES relaxation in response to swallowing.

Barium radiology may show 'bird's beak' appearance.

Esophageal (Heller) myotomy is a surgical procedure that is performed with minimally invasive techniques. The laparoscopic approach appears to be most appropriate.

**137. All of the following testicular tumours
are germ cell tumours EXCEPT:
*March 2013 (b)***

a) Seminoma

b) Teratoma

c) Choriocarcinoma

d) Sertoli cell tumour

Correct Answer - D

Ans. D i.e. Sertoli cell tumour

Testicular carcinoma

- Bilateral in 10% of cases,
- Abdominal cryptorchid testes are at higher risk as compared to inguinal cryptorchid testes
- Testicular feminization syndrome increases the risk of testicular germ cell tumour
- MC Ca of testes in young: Seminoma
- MC Ca in elderly: Lymphoma
- MC Ca in infants: Yolk sac tumour

Seminoma

- Radiosensitive,
- Corresponds to dysgerminoma of ovary &
- Treatment of choice is: Surgery

Germ Cell Tumors

- Precursor lesion
 - Intratubular germ cell neoplasm, unclassified
 - Intratubular germ cell neoplasm, specific type
- Tumors of 1 histologic type

- Seminoma
 - Variant: Seminoma with syncytiotrophoblastic cells
 - Partially regressed tumor showing seminoma with scar
- Spermatocytic seminomaEmbryonal carcinoma
 - Variant: Spermatocytic seminoma with a sarcomatous component
-
- Yolk sac tumor
- ChoriocarcinomaPlacental site trophoblastic tumor
 - Variant: "Monophasic" type
-
- Trophoblastic tumor, unclassified
- Teratoma
 - With a secondary somatic type malignant component
 - Monodermal variants
 - Carcinoid
 - Primitive neuroectodermal tumor
 - Others

138. Cobra head appearance on excretory urography is suggestive of:
March 2010

a) Horseshoe kidney

b) Duplication of renal pelvis

c) Simple cyst of kidney

d) Ureterocele

Correct Answer - D

Ans. D: Ureterocele

The term *ureterocele* denotes a cystic ballooning of the distal end of the ureter. This type of ureterocele is also termed *orthotopic*, since it arises from a ureter with a normal insertion into the trigone.

An intravesical ureterocele results from the prolapse of the mucosa of the terminal segment of the ureter through the ureterovesical orifice into the bladder.

This prolapsed ureteral mucosa carries with it a portion of the continuous sheet of the bladder mucosa around the orifice. The prolapsed segment thus has a wall that consists of a thin layer of muscle and collagen interposed between the bladder uroepithelium and the ureter uroepithelium.

Since the terminal ureteral orifice is usually narrowed and partially obstructed, and since there is no muscle support for the double mucosal walls of the prolapsed segment, it dilates. This dilated segment fills with urine and protrudes into the bladder.

On excretory urography, cobra head sign is classically seen with an intravesical ureterocele.

**139. Orchidopexy for incompletely descended testis is done after the age of:
*September 2011***

a) At birth

b) 1 year

c) 2 years

d) 5 years

Correct Answer - B

Ans. B: 1 year

Orchidopexy is usually performed after the age of 1 year to avoid the risk of operating on a tiny patient Remember:

Incomplete descent of testes may increased liability to malignant change

All types of malignant testicular tumours are more common in incompletely descended testes even if they have been brought down surgically

140. MC site for thyroglossal cyst is:

a) Beneath the foramen caecum

b) Floor of mouth

c) Above hyoid

d) Subhyoid

Correct Answer - D

Ans. D i.e. Subhyoid

Sites of thyroglossal cyst

1. Subhyoid: The most common type
2. At the level of thyroid cartilage: 2nd common site
3. Suprahyoid: Double chin appearance
4. At the foramen caecum: Rare
5. At the level of cricoid cartilage: Rare
6. In the floor of the mouth

141. True about Branchial cyst is:
March 2013 (h)

a) Cysts are more common than sinuses

b) Mostly arises from 2nd branchial system

c) Causes dysphagia and hoarseness

d) Sinus should always be operated

Correct Answer - B

Ans. B i.e. Mostly arises from 2nd branchial system

**142. All of the following are false for Gall Bladder carcinoma except:
March 2005**

a) Carries a good prognosis

b) Gallstones may be a predisposing factor

c) Commonly squamous cell carcinoma

d) Jaundice is rare

Correct Answer - B

Ans. B: Gallstones may be a predisposing factor

Primary carcinoma of the gallbladder is an uncommon, aggressive malignancy that affects women more frequently than men.

Older age groups are most often affected, and coexisting gallstones are present in the vast majority of cases.

The symptoms at presentation are vague and are most often related to adjacent organ invasion. Imaging studies may reveal a mass replacing the normal gallbladder, diffuse or focal thickening of the gallbladder wall, or a polypoid mass within the gallbladder lumen.

Adjacent organ invasion, most commonly involving the liver, is typically present at diagnosis, as is biliary obstruction. Periportal and peripancreatic lymphadenopathy, hematogenous metastases, and peritoneal metastases may also be seen. The vast majority of gallbladder carcinomas are adenocarcinomas.

Because most patients present with advanced disease, the prognosis is poor.

The radiologic differential diagnosis includes the more frequently encountered inflammatory conditions of the gallbladder, xanthogranulomatous cholecystitis, adenomyomatosis, other hepatobiliary malignancies, and metastatic disease.

hepatocellular malignancies, and metastatic disease.

The prevalence of lymphatic spread is high in gallbladder carcinoma. Lymphatic metastases progress from the gallbladder fossa through the hepatoduodenal ligament to nodal stations near the head of the pancreas.

Three pathways of lymphatic drainage have been suggested: the cholecystoretropancreatic pathway, the cholecystoceliac pathway, and the cholecystomesenteric pathway.

The cystic and pericholedochal lymph nodes are the most commonly involved at surgery and are a critical pathway to involvement of the celiac, superior mesenteric, and para-aortic lymph nodes.

143. Cryoprecipitate contains:
March 2009

a) Factor II

b) Factor V

c) Factor VIII

d) Factor IX

Correct Answer - C

Ans. C: Factor VIII

Cryoprecipitate is prepared from plasma and contains fibrinogen, von Willebrand factor, factor VIII, factor XIII and fibronectin.

Cryoprecipitate is the only adequate fibrinogen concentrate available for intravenous use.

Cryoprecipitate is indicated for bleeding or immediately prior to an invasive procedure in patients with significant hypofibrinogenemia (Cryoprecipitate should not be used for patients with von Willebrand disease or Hemophilia A (Factor VIII deficiency). It is not usually given for Factor XIII deficiency, as there are virus-inactivated concentrates of this protein available. Cryoprecipitate is sometimes useful if platelet dysfunction associated with renal failure does not respond to dialysis.

144. Adson test is positive in:
September 2007

a) Cervical spondylosis

b) Cervical rib

c) Cervical vertebra fracture

d) Superior vena cava syndrome

Correct Answer - B

Ans. B: Cervical rib

Adson's test is used to assess for the presence of Thoracic Outlet Syndrome (cervical rib) at the scalene triangle.

Process

- The patient is placed in a sitting position, hands resting on thighs.
- The examiner palpates radial pulse on side being tested
- Patient actively rotates head to ipsilateral side being tested while the examiner laterally rotates and extends the patient's shoulder
- Patient takes a deep breath and is instructed to hold it
The examiner palpates the radial pulse while moving the upper extremity in abduction, extension, and external rotation. The patient then is asked to rotate her head toward the involved side while taking a deep breath and holding it. A positive exam will result in a diminished or absent radial pulse.

145.

Drugs for paralytic ileus for bowel resection surgery are all except ?

a) Alvinopam

b) Dihydroergotamine

c) Naloxone

d) Methylnaltrexone

Correct Answer - C

Ans. is 'c' i.e., Naloxone

Pharmacologic Management of Post op paralytic ileus (P01):

- Minimizing the sympathetic inhibition of gastrointestinal motility, decreasing inflammation and stimulation of gastrointestinal μ -opioid receptors are the ultimate goals of pharmacologic management.
- A) Minimizing sympathetic inhibition**
- Both propranolol, a nonspecific β -receptor antagonist, and dihydroergotamine, an α -receptor antagonist, have been investigated for treatment of POI.
 - Neostigmine is an acetylcholinesterase inhibitor that causes an increase in cholinergic (parasympathetic) activity in the gut wall, which is believed to thereby stimulate colonic motility.
 - Use of edrophonium chloride and bethanechol chloride, which competitively inhibit acetylcholine on the binding site of acetylcholinesterase, has been reported to show improvement of POI.
 - Cisapride is a serotonin (5-HT)₄ receptor antagonist that promotes acetylcholine release from postganglionic nerve endings in the myenteric plexus and is thought to indirectly improve gastrointestinal motility.
 - Metoclopramide is suspected to enhance gastrointestinal motility

without stimulating gastric secretion, but its use has not been substantiated for POI.

B) Decreasing inflammation

- Decreasing inflammation may be indicated in patients who are about to undergo major intestinal surgery, as this is thought to be an important contributing factor to POI.
- Nonsteroidal anti-inflammatory (NSAIDs) agents can be used in conjunction with opioid analgesics for their dual effects on pain control and inflammatory inhibition.

C) Stimulation of gastrointestinal μ -opioid receptors

- Stimulation of gastrointestinal μ -opioid receptors can theoretically influence gastrointestinal motility directly; therefore, blocking the peripheral gastrointestinal effects of centrally acting opioids used for analgesia may help prevent POI.
- Two novel drugs are being investigated for this reason: alvimopan and methylnaltrexone.
- Both drugs are μ -opioid receptor antagonists, and both appear to offer promising results for preventing prolonged POI.
- Opioid therapy for postoperative or chronic pain is frequently associated with adverse effects, the most common being dose-limiting and debilitating bowel dysfunction, so alvimopan and methylnaltrexone may also be useful in the treatment of chronic opioid bowel dysfunction.
- The currently available opioid antagonists such as naloxone are of limited use because they also act at central opioid receptors to reverse analgesia and elicit opioid withdrawal.
- Alvimopan and methylnaltrexone are peripherally acting μ -opioid receptor antagonists that have been studied in patients undergoing abdominal and pelvic surgery and have been shown in several studies to significantly accelerate gastrointestinal recovery. Alvimopan received FDA approval for the treatment of POI on May 20, 2008.

D) Alternative medications

- Bisacodyl administration versus placebo twice daily starting on postoperative day 1, patients who received bisacodyl had significantly earlier bowel movements than those who received placebo (25 h v. 56 h), but further studies are needed to assess the

effect of laxatives on POI.

146. An adult hypertensive male presented with sudden onset severe headache and vomiting. On examination, there is marked neck rigidity and no focal neurological deficit was found. The symptoms are most likely due to:

a) Intracerebral parenchymal hemorrhage

b) Ischemic stroke

c) Meningitis

d) Subarachnoid hemorrhage

Correct Answer - D

Ans. d. Subarachnoid hemorrhage

The most likely diagnosis here is a **subarachnoid bleed (SAH)**.

- The most common cause is **trauma** and is managed conservatively. The second most common cause is a rupture of a berry aneurysm.
- The typical presentation of a subarachnoid hemorrhage includes a **'thunderclap' headache**.
- Meningitic features of **neck stiffness** and **photophobia** often develop over hours.
- Computed tomography (**CT**) is the investigation of choice.
- **Lumbar puncture** should be performed if the CT scan fails to establish the diagnosis of SAH; it shows a **xanthochromic** blood picture.
- Delayed ischemic neurological deficit (**DIND**) is attributed to vasospasm of the cerebral vasculature typically developing 3–10 days following ictus. It is the **main cause of a poor outcome**.

- **Endovascular treatment** ("coiling") is generally preferred over craniotomy and clipping for aneurysms amenable to this approach.

147. Gasless abdomen seen in-

a) Ulcerative colitis

b) Acute pancreatitis

c) Intussusception

d) Necrotising enterocolitis

Correct Answer - B

Answer- B (acute pancreatitis)

Common causes include:

- **In adult:**

- High obstruction.

- Ascites.

- Acute pancreatitis due to excess vomiting.

- Fluid filled intestine.

- Large abdominal mass.

ACUTE PANCREATITIS - radiology signs

renal halo sign

gasless abdomen

ground glass appearance

colon cut off sign

sentinel loop

148. Dohlman procedure for-

a) Meckel's diverticulum

b) Zenker's diverticulum

c) Dermatomyositis

d) Menetrier's disease

Correct Answer - B

Answer- B (Zenker's diverticulum)

The treatment of pharyngeal pouches (Zenker's Diverticulum) may be by either open surgical or endoscopic techniques. The endoscopic Dohlman's procedure is an ideal technique in the elderly.

149. If a mother is donating kidney to her son is an example-

a) Isograft

b) Allograft

c) Autograft

d) Xenograft

Correct Answer - B

Answer- B (Allograft)

Allograft – Grafting between two non-identical member of same species but not same genotypes. It includes the transplantation of heart, kidney, lung etc, from a members who donate their organs.

Anti – rejection drugs or immunosuppressant need to be taken to prevent the body from rejecting a transplanted organ.

Most human tissue and organ transplants are allografts.

150. Uvula vesicae is produced by which prostate lobe?

a) Anterior lobe

b) Post lobe

c) Median lobe

d) Lateral lobe

Correct Answer - C

Answer- C (median lobe)

The mucous membrane immediately behind the internal urethral orifice presents a slight elevation, the uvula of urinary bladder, caused by the median lobe of the prostate.

It is often enlarged in benign prostatic hypertrophy.

151. True about Barrett's esophagus are all of the following except:

a) Causes adenocarcinoma

b) Patient is usually asymptomatic

c) Histology of the lesion shows mucus secreting goblet cells

d) Chronic gastroesophageal reflux is a predisposing factor

Correct Answer - A

Answer-

Barrett esophagus is a premalignant condition that involves the distal esophagus and appears to be related to chronic gastroesophageal reflux (GORD).

There is metaplastic change in the lining mucosa of esophagus.

- Patient is usually asymptomatic in a case of Barrett's Esophagus.
- Histology of the lesion in a case of Barrett's esophagus shows mucus secreting goblet cells.
- Diagnosis of Barrett's esophagus is made by demonstration of columnar mucosa, which on histopathology shows Intestinal type of metaplasia
- Chronic reflux is a casue of Barrett's Esophagus.

152. Parathyroid autoimplantation takes place in which of the muscle?

a) Biceps

b) Triceps

c) Brachioradialis

d) Sartorius

Correct Answer - C

Answer- C (Brachioradialis)

- A total parathyroidectomy with a forearm autograft involves removal of all parathyroid tissue in the neck, with reimplantation of a small amount of morcellated tissue within a pocket formed in the brachioradialis muscle.

153. Bell's palsy is associated with the lesion in which of the nerve?

a) 11th cranial nerve

b) 7th cranial nerve

c) 9th cranial nerve

d) 3rd cranial nerve

Correct Answer - B

Answer- B (7th cranial nerve)

Bell's palsy occurs due to a malfunction of the facial nerve (VII cranial nerve), which controls the muscles of the face. Facial palsy is typified by inability to control movement in the muscles of facial expression.

154. Cushing ulcer is seen in case of-

a) Burns

b) Head injury

c) Cell necrosis

d) Stress

Correct Answer - B

Answer- B (Head injury)

Cushing ulcers are associated with a brain tumor or head injury and typically are single, deep ulcers that are prone to perforation.

It is a gastric ulcer associated with elevated intracranial pressure. It is also called von Rokitansky–Cushing syndrome.

The mechanism of development of Cushing ulcers is thought to be due to direct stimulation of vagal nuclei as a result of increased intracranial pressure. Brain tumors, traumatic head injury, and other intracranial processes including infections, can cause increased intracranial pressure and lead to overstimulation of the vagus nerve.

155. Most common indication for liver transplant in children-

a) Biliary atresia

b) Cirrhosis

c) Hepatitis

d) Drug reactions

Correct Answer - A

Answer- A (Biliary atresia)

Indications for liver transplantation in infants and children include acute liver failure (ALF), chronic liver failure with pruritus, complications of cholestasis and failure to thrive. In young children, the most common liver disease leading to transplantation is biliary atresia

156. Most common type of gallstone is-

a) Mixed stones

b) Pure cholesterol stones

c) Pigment stones

d) Calcium bilirubinate

Correct Answer - A

Answer- A

Mixed- Between 4% and 20% of stones are mixed.

Pigment- Between 2% and 30% of stones are bilirubin stones.

Cholesterol- Between 35% and 90% of stones are cholesterol stones.

The most common type of gallstones was mixed cholesterol type gallstones with 67.5% followed by black pigment and brown pigment types as 23.83% and 5.89%, respectively.

Mixed stones are 90% common. It contains cholesterol, calcium salts of phosphate carbonate, palmitate, proteins, and are multiple faceted.

157. Serpiginous ulcer distal esophagus-

a) CMV

b) Herpes

c) Pill

d) Corrosive

Correct Answer - A

Answer- A (CMV)

CMV classically causes serpiginous ulcers in the distal esophagus that may coalesce to form giant ulcers.

158. Omphalocele is caused by?

- a) Duplications of intestinal loops
- b) Abnormal rotation of the intestinal loop
- c) Failure of gut to return to the body cavity from its physiological herniation
- d) Reversed rotation of the intestinal loop

Correct Answer - C

Answer- C (Failure of gut to return to the body cavity from its physiological herniation)

Failure of gut to return to the body cavity from its physiological herniation. Exomphalos(omphalocele) is herniation of abdominal viscera through an enlarged umbilical ring. The viscera, which may include liver, small and large intestines, stomach, spleen, or bladder, are covered by amnion. The origin of omphalocele is a failure of the bowel to return to the body cavity from its physiological herniation during the 6th to 10th weeks.

159. Which of the following is true about coeliac plexus block?

a) Located retroperitoneally at the level of L3

b) Usually done unilaterally

c) Useful for the painful conditions of lower abdomen

d) Most common side effect is diarrhea and hypotension

Correct Answer - D

Answer- D (Most common side effect is diarrhea and hypotension)

- Celiac Plexus Block:
- Located retroperitoneally at the level of L1
- Usually done bilaterally
- Useful for the painful conditions of upper abdomen
- Most common side effect is diarrhea and hypotension

160. Most commonly performed and acceptable method of bariatric surgery is:

a) Biliopancreatic diversion

b) Biliopancreatic diversion with ilcostomy

c) Laparoscopic gastric banding

d) Roux-en-Y gastric bypass.

Correct Answer - D

Ans: D. Roux-en-Y gastric bypass.

(Ref. Sabiston 20/e p1187, 19/e p363; Schwartz 10/e p1112, 9/952; Harrison 19/p2398).

Roux-en-Y gastric bypass:

- Most commonly performed & acceptable method of bariatric surgery.

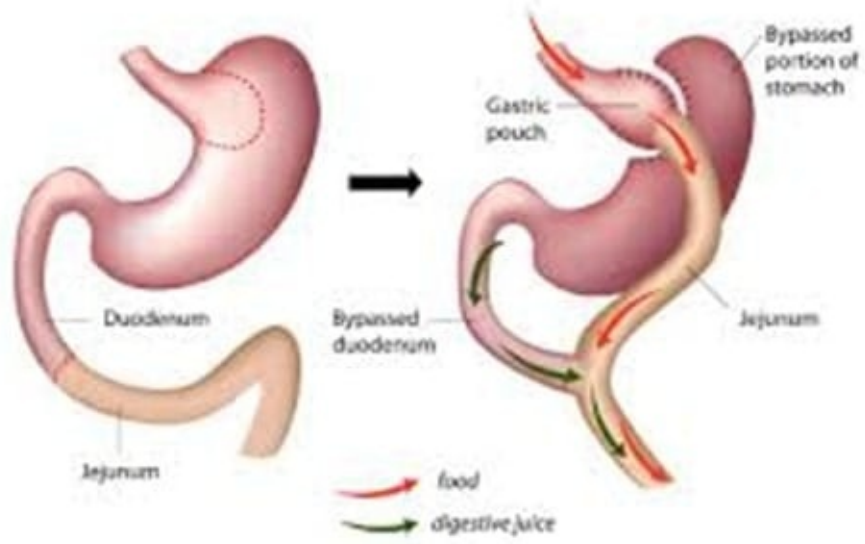
3 restrictive-malabsorptive bypass procedures:

- Combine elements of gastric restriction & selective malabsorption.
- Procedures include Roux-en-Y gastric bypass, biliopancreatic diversion & biliopancreatic diversion with duodenal switch.

Roux-en-Y:

- Most commonly undertaken & most accepted bypass procedure.
- Performed with an open incision or by laparoscopy.

Roux-en-Y Gastric Bypass (RNY)



161. A patient after road traffic accident presented with tension pneumothorax. What is the first line of management?

a) Insert wide bore needle in 2nd intercostal space

b) Immediate chest X-ray

c) CT scanEmergency thoracotomy

d) Emergency thoracotomy

Correct Answer - A

Answer- A. Insert wide bore needle in 2nd intercostal space

- First line of management in tension pneumothorax: Insert wide bore needle in 2nd intercostal space.

162. Prehn sign is positive in

a) Acute epididymo-orchitis

b) Chronic orchitis

c) Testicular torsion

d) None

Correct Answer - A

Answer- A. Acute epididymo-orchitis

On elevation of testis the-

- Pain is not relieved in torsion (test is negative)
- Pain relieved in epididymo-orchitis (test is positive)

163.

Definitive surgery is a part of which stage of damage control surgery?

a) I

b) II

c) III

d) IV

Correct Answer - D

Answer- D. IV

- Following major injury, protracted surgery in the physiologically unstable patient with the 'deadly triad' - the combination of hypothermia, acidosis and coagulopathy
- 'Damage control' or 'damage limitation surgery' is a concept that originated from naval architecture, whereby a ship was designed to have areas sealed off in the case of damage, to limit flooding.

Stages-

1. Patient selection
2. Control of haemorrhage and control of contamination
3. Resuscitation continued in the intensive care unit
4. Definitive surgery
5. Abdominal closure

164. Which of the following is not true about Boerhaave syndrome?

- a) Perforation of the esophagus due to barotrauma
- b) Most common site is left posteromedial aspect 3 - 5 cms above the gastroesophageal junction
- c) Pain is the early manifestation
- d) Most cases follow a bout of heavy eating or drinking

Correct Answer - B

Answer- B. Most common site is left posteromedial aspect 3 - 5 cms above the gastroesophageal junction

- Vomiting is thought to be the most common cause, other causes include weightlifting, defecation, epileptic seizures, abdominal trauma, compressed air injury, and childbirth, all of which can increase the pressure in the esophagus and cause a barogenic esophageal rupture.
- Two common risk factors include alcoholism and excessive indulgence in food.
- Rupture occurs most commonly in the left posterolateral wall of the distal third of the esophagus with extension into the left pleural cavity.
- Symptoms consist of vomiting, lower thoracic pain, and subcutaneous emphysema.
- Typically, the patient will present with pain at the site of perforation, usually in the neck, chest, epigastric region, or upper abdomen.

165. All of the following are indications for bariatric surgery except -

a) BMI > 40 kg/m²

b) BMI > 35 kg/m² with at least one comorbidity

c) BMI > 30 with long standing diabetes

d) Failure of other methods of weight loss

Correct Answer - C

Answer- C. BMI > 30 with long standing diabetes

Indications for bariatric surgery

- BMI > 40 kg/m²
- BMI > 35 kg/m² with at least one comorbidity
- Patient at high risk of obesity associated morbidity and mortality
- Failure of other methods of weight loss

166. Indications for emergency thoracotomy are all of the following except

a) Major tracheobronchial injuries

b) Cardiac tamponade

c) Penetrating injuries to anterior chest

d) Tension Pneumothorax

Correct Answer - D

Answer- D. Tension Pneumothorax

Emergency thoracotomy is indicated after chest trauma in following conditions :

- Cardiac arrest (resuscitative thoracotomy)
- Massive hemothorax (>1500 mL of blood through the chest tube acutely or > 200-300 ml/hr after initial drainage.
- Penetrating injuries of the anterior aspect of the chest with cardiac tamponade.
- Large open wounds of the thoracic cage.
- Major thoracic vascular injuries in the presence of hemodynamic instability

167. A female undergone surgery for left breast cancer 3 yrs back now developed blue nodule on same side

a) Lymphangiosarcoma

b) Recurrence

c) Hemangioma

d) Cellulitis

Correct Answer - A

Answer- A. Lymphangiosarcoma

- Angiosarcoma is a vascular tumor which may arise de novo in the breast or as a complication of the radiation therapy.

168. Blood loss in class III hemorrhagic shock

-

a) < 750 ml

b) 750 - 1500 ml

c) 1500-2000 ml

d) > 2000 ml

Correct Answer - C

Ans. is 'c' i.e., 1500-2000 ml

Parameters	Class I	Class II	Class III	Class IV
Blood Loss (mL)	Up to 750	750–1500	1500–2000	> 2000
Blood Loss (%BV)	Up to 15%	15–30%	30–40%	> 40%
Pulse rate (beats/min)	< 100	> 100	> 120	> 140
Blood Pressure	Normal	Minimal decrease	Decreased	Significantly decreased
Pulse Pressure	Normal	Narrowed	Narrowed	Unobtainable or very narrow
Hourly urine output	≥ 0.5 mL/kg	≥ 0.5 mL/kg	< 0.5 cc/kg	Minimal
CNS/Mental status	Slightly anxious	Mildly anxious	Anxious and confused	Confused or lethargic

169. Most common cancer in men is

a) Bladder cancer

b) Colorectal cancer

c) Prostate cancer

d) Oral cancer

Correct Answer - C

Answer- C. Prostate cancer

Cancers in males in India: Lip / oralcavity > Prostate > Colorectum > Pharynx (other than nasopharynx) > Larynx

- Lung **cancer** was the **most common cancer in men** worldwide, contributing 15.5% of the total number of new cases diagnosed in 2018.
- The top three – lung, prostate and colorectal **cancers** – contributed 44.4% of all **cancers** (excluding non-melanoma skin **cancer**).

170.

A nerve injured in radical neck dissection leads to loss of sensation in medial side of the arm, nerve injured is?

a) Long thoracic nerve

b) Thoracodorsal nerve

c) Dorsal scapular nerve

d) Medial cutaneous nerve of arm

Correct Answer - D

Answer- D. Medial cutaneous nerve of arm

- The medial cutaneous nerve of the arm is the smallest and most medial branch of the brachial plexus, and arises from the medial cord.
- It pierces the deep fascia at the midpoint of the upper arm to supply the skin over the medial aspect of the distal third of the upper arm.

171. Gold standard investigation for chronic pancreatitis?

a) MRI

b) ERCP

c) Pancreatic function tests

d) Fecal fat estimation

Correct Answer - B

Answer- B. ERCP

- ERCP has been considered the most sensitive radiologic test for the diagnosis of chronic pancreatitis, with specific ERCP findings that are highly correlative with the degree or stage of chronic disease.

172. Most accurate method for the diagnosis Gastroesophageal Reflux Disease (GERD) is

a) Histological study

b) Manometry

c) 24-hour pH recording and electrical impedance measurement

d) Barium swallow studies

e) Upper GI endoscopy

Correct Answer - C

Answer- C. 24-hour pH recording and electrical impedance measurement

- The most sensitive test for diagnosis of GERD is 24-h ambulatory pH monitoring.
- Endoscopy is indicated in patients with reflux symptoms refractory to antisecretory therapy; in those with alarming symptoms such as dysphagia, weight loss, or gastrointestinal bleeding; and in those with recurrent dyspepsia after treatment that is not clearly due to reflux on clinical grounds alone
- pH was less than 4

173. All are features of SIRS except-

a) RR > 24 & Paco₂ < 22 mm hg

b) WBC > 11 or < 4

c) Temperature < 36 and > 38

d) PR > 90

Correct Answer - A

Answer- A. RR > 24 & Paco₂ < 22 mm hg

Systemic Inflammatory Response Syndrome

Temperature > 38.3°C, or < 36°C

Heart Rate > 90 bpm

Respiratory rate > 20 breaths/min

White cell count < 4 or > 12 g/L

Blood glucose > 7.7 mmol/L not diabetic

New altered mental state

174. Which of the following primarily governs the uptake of Tc-99m MDP in body?

a) Amount of osteogenic activity

b) Amount of iodine uptake

c) Amount of calcium uptake

d) Amount of catecholamine activity

Correct Answer - A

Answer- A. Amount of osteogenic activity

Technetium 99-m is a commonly used radiopharmaceutical. Technetium 99-m methylene diphosphonate (Tc-99mMDP), desirable for the gamma camera imaging is the commonly used form.

Tc-99mMDP can be prepared from a kit containing, sodium pertechnetate (NaTcO_4) vial, MDP, stabilizers and stannous ion.

175. Technitium-99m pertechnetate labelled methylene diphosphonate is structurally similar to

a) Calcium phosphate

b) Phosphorus

c) Sodium bicarbonate

d) Magnesiumsulfate

Correct Answer - A

Answer- A. Calcium phosphate

The radionuclide administered is Technitium- 99m pertechnetate labeled methylene diphosphonate is an analog of calcium phosphate.

176. Neuroimaging features of neurocysticercosis are considered as criteria for definitive diagnosis -

a) Major

b) Minor

c) Probable

d) Absolute

Correct Answer - A

Answer- A. Major

Evidence of lesions highly suggestive of neurocysticercosis on neuroimaging studies

Positive serum immunoblot for the detection of anticysticercal antibodies

Resolution of intracranial cystic lesions after therapy with albendazole or praziquantel

Spontaneous resolution of small single enhancing lesions.

177. Laproscopic procedure patient develops shoulder pain due to

- a) Subphrenic abscess
- b) Positional pain during surgery
- c) Subdiaphragmatic migration of gas
- d) Injury to liver

Correct Answer - C

Answer- C. Subdiaphragmatic migration of gas

One type of pain that is unique to laparoscopy is the post laparoscopy shoulder pain due to the phrenic nerve irritation to the diaphragm caused by the CO₂ gas that remains in the abdomen at the end of the procedure. When the patient sits up, the gas moves upwards to the diaphragm and irritates it leading to referred pain C3-C5.

178. A patient comes with a complaint of shoulder pain after laparoscopic surgery. What should be the next step in management?

a) Oral paracetamol for 2 - 3 days

b) USG of shoulder region

c) Diagnostic shoulder arthroscopy

d) Intraarticular lignocaine injection

Correct Answer - A

Answer- A. Oral paracetamol for 2 - 3 days

Shoulder tip pain

- The patient should be warned about this preoperatively and told that the pain is referred from the diaphragm and not due to a local problem in the shoulders.
- It can be at its worst 24 hours after the operation. It usually settles within 2-3 days and is relieved by simple analgesics, such as paracetamol.

179. Which of the following should be done for an acute onset painful scrotal swelling in 12 years old male?

a) Doppler stethoscope evaluation

b) Administer analgesics

c) Advise bed rest

d) Administer antibiotics

Correct Answer - A

Answer- A. Doppler stethoscope evaluation

Acute onset painful scrotal swelling in 12 years old preadolescent male is most probably due to torsion of testis. In suspected cases of torsion of testis or testicular appendage a doppler stethoscope should be used to evaluate blood flow to the testicles.

180. Which of the following electrolyte abnormalities can be seen after brain injury?

a) Hyponatremia

b) Hyperkalemia

c) Hypomagnesemia

d) All the above

Correct Answer - A

Answer- A

Electrolyte abnormalities occur in 60% of the patients with head injury.

Patients with **brain injury** are at a high risk for the development of **electrolyte imbalance** including **hyponatremia**, hypocalcemia, hypophosphatemia as well as **hypokalemia** and (to a lesser degree) Hypomagnesemia.

So the appropriate answer will be hyponatremia.

181. Earliest hematological change following splenectomy is

a) Leukocytosis and thrombocytosis

b) Presence of Heinz bodies

c) Evidence of Howell Jolly bodies

d) Poikilocytosis

Correct Answer - A

Answer- A. Leukocytosis and thrombocytosis

In the immediate postsplenectomy period, leukocytosis (up to 25,000/4) and thrombocytosis (up to 1.106/4) develop, but within 2-3 weeks, blood cell counts and survival of each cell lineage are usually normal.

182. Percutaneous chemical lumbar sympathectomy is practised using -

a) Phenol

b) Ethanol

c) Formalin

d) Acetic acid

Correct Answer - A

Answer- A. Phenol

Chemical sympathectomy requires the injection of small quantities of dilute aqueous phenol into the lumbar sympathetic chain under radiographic control.

183. Typical of rectus sheath hematoma is -

a) Severe tenderness

b) Bluish discoloration

c) Firm painful mass

d) Ecchymosis

Correct Answer - C

Answer- C. Firm painful mass

Clinical features of rectus sheath hematoma

A) Symptoms

- Common historical features of rectus sheath hematoma (RSH) include acute abdominal pain, fever, nausea, and vomiting.

B) Signs

i) Vital signs

- A low-grade fever is common in rectus sheath hematoma. The hematoma can be large enough to compromise intravascular volume, with resultant signs of hypovolemic shock including hypotension, tachycardia, and tachypnea.

ii) Abdominal examination

- Typically, the abdominal examination reveals a palpable, painful, firm, nonpulsatile abdominal mass corresponding to the rectus sheath. The mass may be bilobar with a central groove. The mass does not move with respiration. Because the hematoma is deep to the subcutaneous tissue and rectus muscles, the mass is not always palpable, particularly in obese patients.

184. Burr hole is done for -

a) Chronic SDH

b) EDH

c) SAH

d) Contusion

Correct Answer - A

Answer- A. Chronic SDH

Liquefied SDHs are commonly treated with drainage through one or two burr holes placed over the thickest aspects of the hematoma.

Many surgeons place frontal and parietal burr holes that later can be incorporated into a frontotemporoparietal craniotomy, if needed.

185.

Following road traffic accident patient suffers polytrauma and is evaluated in the emergency section of the hospital. His pulse rate is 116, respiratory rate is 24, blood pressure of 122/78 mm of Hg and patient is mildly anxious. What is the approximate blood loss patient has following trauma?

a) <750 ml

b) 750 - 1500 ml

c) 1500 - 2000 ml

d) >2000 ml

Correct Answer - B

Answer- B. 750 - 1500 ml

Class of haemorrhagic shock				
	I	II	III	IV
Blood loss (mL)	Up to 750	750-1500	1500-2000	>2000
Blood loss (% blood volume)	Up to 15	15-30	30-40	>40
Pulse rate (per minute)	<100	100-120	120-140	>140
Blood pressure	Normal	Normal	Decreased	Decreased
Pulse pressure (mm Hg)	Normal or increased	Decreased	Decreased	Decreased
Respiratory rate (per minute)	14-20	20-30	30-40	>35
Urine output (mL)/hour	>30	20-30	5-15	Negligible
Central nervous system/ mental status	Slightly anxious	Mildly anxious	Anxious, confused	Confused, lethargic

186. Sebaceous cyst occurs occur in all the following locations in body except

a) Palms and soles

b) Axilla

c) Back

d) Pubic area

Correct Answer - A

Answer- A. Palms and soles

The scalp, scrotum, shoulders, neck, and back are the common sites, but they can occur wherever there are sebaceous glands. There are no sebaceous glands on the palms of the hands and soles of the feet, thus sebaceous cysts are not found in these locations.

187. Cortisol levels remain elevated for how many week/s following hemorrhage?

a) 1

b) 2

c) 3

d) 4

Correct Answer - A

Answer- A. 1

Burn patients have demonstrated elevated circulating cortisol levels for upto 4 weeks, while soft tissue injury and hemorrhage may sustain elevated cortisol levels for as long as 1 week.

188. A child swallowed a watch battery containing alkaline content. What next -

a) Immediate X-ray measurements

b) Remove surgically immediately

c) CT abdomen

d) Laxatives

Correct Answer - A

Answer- A. Immediate X-ray measurements

Alkaline dry cell batteries contain :

- Sodium hydroxide
- Potassium hydroxide

189. Surgical treatment of congenital hydrocele recommended if it fails to resolve by what age?

a) 1 year

b) 2 years

c) 3 years

d) 4 years

Correct Answer - B

Answer- B. 2 years

A patent processus vaginalis that is too narrow to prevent the development of an inguinal hernia may nevertheless allow peritoneal fluid to track down around the testis to form a congenital hydrocele. The majority resolve spontaneously as the processus continues to obliterate but surgical ligation is recommended in boys older than 2 years if they do not resolve spontaneously.

190. What percentage of gall stones are radio opaque?

a) 10- 20

b) 30 - 40

c) 50 - 60

d) 70 - 80

Correct Answer - A

Answer- A. 10- 20

Cholelithiasis is a common cause of epigastric or right upper quadrant pain in middle aged obese female patients.

Only 15 - 20% of the gall stones are radio-opaque.

Gallstones are the most common biliary pathology.

It is estimated that gallstones are present in 10-15% of the adult population in the USA.

191. Hemorrhage commonly seen with trivial trauma in elderly -

a) Subdural hemorrhage

b) Extradural hemorrhage

c) Subarachnoid hemorrhage

d) Intraparenchymal hemorrhage

Correct Answer - A

Answer- A. Subdural hemorrhage

Subdural hemorrhage frequently occurs in older adults, after apparently trivial trauma and is often related to a fall in which there is no direct trauma to the head.

Recurrent trivial trauma in elderly is the most common cause of subdural hemorrhage developing.

192. Which of the following provides excellent details about the chemodectomas?

a) Xray

b) CT angiography

c) MRI

d) PET SCAN

Correct Answer - C

Answer- C. MRI

MRI scanning provides excellent detail in most cases of chemodectomas.

193. Acral lentiginous type of malignant melanoma occurs in -

a) Face

b) Nape of neck

c) Mucosa

d) Sun exposed areas

Correct Answer - C

Answer- C. Mucosa

Acral lentiginous-

- Least common with worst prognosis
- MC site- sole, mucosa

194. Hoarseness of voice in lung carcinoma is due to invasion of which structure?

a) Recurrent laryngeal nerve

b) Internal laryngeal nerve

c) Glossopharyngeal nerve

d) Vagus nerve

Correct Answer - A

Answer- A. Recurrent laryngeal nerve

Hoarseness- Recurrent laryngeal nerve invasion

195. Percentage of renal stones that are radio-opaque

a) 20

b) 40

c) 60

d) 80

Correct Answer - D

Answer- D. 80

Routine use of noncontrast CT Scan has completely revolutionized to imaging evaluation of renal stone disease, nearly completely replacing plain radiographs and X urography for diagnosis of acute ureteral obstruction by renal stones.

Nephrolithiasis refers to the presence of calculi in the renal collecting system.

Nearly 10 % of the population will form a renal stone in their lifetime. Sufficient calcium oxalate and phosphate is present in 80 % of the renal calculi for them to be radio-opaque on the plain radiographs.

196. Indications of thoracotomy in blunt chest trauma include all except

- a) Initial drainage of > 500 ml of fresh blood
- b) Rupture of bronchous
- c) Continued bleeding of > 200 ml/ hr for >= 3hrs
- d) Unsuccesful attempt at drainage of cardiac tamponade

Correct Answer - A

Answer- A. Initial drainage of > 500 ml of fresh blood

Continued bleeding of > 200 ml/hr for > 3 hrs

Rupture of bronchus, aorta, esophagus or diaphragm.

Cardiac tamponade (if needle aspiration unsuccessful).

197. Visual examination is used as screening test for

a) Melanoma

b) Breast cancer

c) Thyroid cancer

d) Testicular cancer

Correct Answer - A

Answer- A. Melanoma

Visual examination is the only screening test for melanoma or skin cancer.

For lesions with suspicion of head and neck melanoma, dermatologists visual examination screening is 89 -97% sensitive with 35 - 75% positive predictive value.

198. Embolisation of tumors is done using

a) Polyvinyl alcohol

b) Autologous blood clots

c) Absolute ethanol

d) All the above

Correct Answer - D

Answer- D. All the above

The following are the embolic materials commonly used for trans-arterial embolization:

- Gelatin sponge particles
- Microspheres
- Autologous blood clots
- Polyvinyl alcohol
- n- butylcyanoacrylate glue
- Absolute ethanol

199.

Upto Level III lymph node dissection is done for which nodal status of oropharyngeal cancer?

a) N1

b) N2

c) N3

d) N4

Correct Answer - A

Answer- A. N1

Management of neck

NO Selective neck dissection

Oral Cavity at least levels I-III

Oropharynx at least levels II-IV

N1-N2a-c Selective or comprehensive neck

Level VI Subglottic laryngeal cancers

200. Breast surgery is considered under what category of cardiac risk?

a) > 10 %

b) 5 - 10 %

c) 1 - 5 %

d) <1%

Correct Answer - D

Answer- D. <1%

Low (reported cardiac risk < 1%)-

Endoscopic procedures

Superficial procedure

Cataract surgery

Breast surgery

Ambulatory surgery

201. What is the order of disorientation, which a person goes through after an event of trauma to head?

a) First time, then place followed by person

b) First place, then time followed by person

c) First person, then time followed by place

d) First time, then person followed by place

Correct Answer - A

Answer- A. First time, then place followed by person

Orientation refers to the clients recognition of person, place and time - that is knowing who and where e or she is and the correct day, date and year. This is commonly documented as "oriented X 3". Absence of correct information about person, place and time is referred to as disorientation.

202. Which of the following is the preferred route of access for total parenteral nutrition in a patient who requires the same for <14 days and there is otherwise no indication for use of central catheter?

a) Internal jugular vein

b) External jugular vein

c) Periphaeral vein

d) PICC line

Correct Answer - C

Answer- C. Periphaeral vein

Administration of parenteral nutrition via a peripheral venous catheter should be considered for patients who are likely to need short-term parenteral nutrition (less than 14 days) who have no need for central access for other reasons. Care should be taken in catheter choice, and in attention to pH, tonicity and long-term compatibility of the parenteral nutrition formulations in order to avoid administration or stability problems.

203. Which of the following is not true about use of graft in vascular surgery

- a) Autologous saphenous vein achieves superior patency rates to prosthetic materials especially in femorodistal bypass
- b) The patency of the PTFE grafts may be improved by interposition of a vein cuff at proximal anastomosis
- c) Doppler ultrasound assessment is the method of choice for quality assurance on completion of operative procedure
- d) In the absence of specific contraindications aspirin should be prescribed for all the patients of peripheral vascular disease

Correct Answer - B

Answer- B. The patency of the PTFE grafts may be improved by interposition of a vein cuff at proximal anastomosis

Autologous saphenous vein achieves superior patency rates to prosthetic materials, especially in femorodistal bypass.

In situ and reversed vein graft bypasses perform equally well and the choice of technique should be based upon anatomical considerations that are specific to individual patients.

In the absence of saphenous vein, no convincing studies exist to suggest the preferred prosthetic alternative.

The patency of PTFE grafts may be improved by interposition of a vein cuff at the distal anastomosis.

Patency rates associated with pre-cuffed PTFE, grafts are comparable to that obtained from standard PTFE grafts with an interposition vein cuff.

There is no justification for the routine use of adjuvant distal arteriovenous fistulae.

**204. For lower lip carcinoma of <1cm in size.
The treatment of choice will be-**

a) Radiation

b) Chemotherapy

c) Excision

d) Radiation and chemotherapy

Correct Answer - C

Answer- C. Excision

- Small tumors (T1 & T2) (<2cm) - If 1/3rd or less than 1/3rd lip involved- V or W-shaped excision + primary closure.
- Excision of lower lip upto 1/3rd can be sutured primarily in 3 layers – mucosa, muscle, and skin keeping vermillion border in proper apposition.

205. Preferred treatment for oral tongue carcinoma which infiltrates the local cortical bone is -

a) Subtotal glossectomy

b) Subtotal glossectomy + selective neck dissection

c) Subtotal glossectomy + selective neck dissection + mandibulectomy

d) Total glossectomy + selective neck dissection + mandibulectomy

Correct Answer - C

Answer- C. Subtotal glossectomy + selective neck dissection + mandibulectomy

- The management plan for locally advanced tongue carcinomas includes subtotal glossectomy + selective neck dissection + mandibulectomy.
- Advanced tumors (T3 and T4) often encroach upon the floor of the mouth and, occasionally, the mandible.
- In these circumstances, a resection of the tongue and floor of the mouth and mandible is required.

206. Intracranial pressure is not raised during

a) Hyperventilation

b) Status epilepticus

c) Head injury

d) Subdural hematoma

Correct Answer - A

Answer- A. Hyperventilation

Hyperventilation is used as a treatment with raised intracranial pressure.

Hyperventilation causes decreased PaCO₂ which subsequently leads to arterial vasoconstriction thus lowering cerebral blood flow (CBF), cerebral blood volume, and intracranial pressure

207. Outcome of burns depends on -

a) Extent of burns

b) Type of resuscitation fluid

c) Maintenance of airway

d) Skin grafting

Correct Answer - A

Answer- A. Extent of burns

The various factors influencing the outcome of burns are :

- Extent of burns
- Depth of burns
- Timing of first Escharectomy (removes devitalized tissue and hence source of infection)
- Age and medical comorbidities

208. Immediate physiological response to sudden decrease in blood volume is

a) Release of epinephrine

b) Shift of fluid from intracellular to interstitial compartment

c) Release of angiotensin

d) Release of thyroxine

Correct Answer - A

Answer- A. Release of epinephrine

The major hemodynamic abnormality in hypovolemic shock is decrease in preload.

The immediate physiological response of the body to the sudden decrease in volume (preload), is a release of catecholamines (epinephrine, norepinephrine).

The subsequent increase in heart rate and contractility help maintain cardiac output.

209. Cardinal rule for dressing of pressure ulcer is to -

- a) Keep ulcer tissue dry and surrounding intact tissue dry
- b) Keep ulcer tissue dry and surrounding intact tissue moist
- c) Keep ulcer tissue moist and surrounding intact tissue dry
- d) Keep the ulcer tissue moist and surrounding intact tissue moist

Correct Answer - C

Answer- C. Keep ulcer tissue moist and surrounding intact tissue dry

An ideal dressing should protect the wound, be biocompatible and provide ideal hydration.

The type of the ulcer bed and the desired dressing function determine the type of dressing needed.

The cardinal rule is to keep the ulcer tissue moist and the surrounding intact tissue dry.

210. What is the meaning of the French word "Debridement"

a) Unleash or Cut Open

b) Debulk

c) Sanitize

d) Rehydration

Correct Answer - A

Answer- A. Unleash or Cut Open

Taken from the French meaning to 'unleash or cut open', debridement has come to mean more than simply the laying open of tissues. It plays a crucial part in the management of trauma.

211. Slip sign is seen in

a) Lipoma

b) Desmoid tumor

c) Sebaceous cyst

d) Hernia

Correct Answer - A

Answer- A. Lipoma

A characteristic "slippage sign" may be elicited by gently sliding the fingers off the edge of the tumor. The tumor will be felt to slip out from under, as opposed to a sebaceous cyst or an abscess that is tethered by surrounding induration.

212. For reimplantation digits are stored in

a) Ice packs

b) Deep freeze

c) Cold saline

d) Plastic bags with ice

Correct Answer - D

Answer- D. Plastic bags with ice

The amputated part should be wrapped in moistened gauze and placed in a sealed plastic bag. This bag should then be placed in an ice water bath. Do not use dry ice and do not allow the part to contact ice directly; frostbite can occur in the amputated part, which will decrease its chance of survival after replantation. Bleeding should be controlled in the proximal stump by as minimal a means as necessary, and the stump dressed with a nonadherent gauze and bulky dressing."

213. Characteristic site for development of venous leg ulcers is

- a) Skin of gaiter region
- b) Behind lateral malleolus
- c) Shin of tibia
- d) Medial aspect of knee

Correct Answer - A

Answer- A. Skin of gaiter region

The venous ulcer of the leg characteristically develops in the skin of the gaiter region, the area between the muscles of the calf and the ankle. This is the region where many of the Cockett perforators join the posterior tibial vein to the surface vein, known as the posterior arch vein

The majority of ulcers develop on the medial side of the calf but ulcers associated with lesser saphenous incompetence often develop on the lateral side of the leg.

Ulcers can develop on any part of the calf skin in patients with post-thrombotic legs; however, venous ulcers rarely extend on to the foot or into the upper calf and, if there is ulceration at these sites, other diagnoses should be seriously considered.

214. Which of the following is true about the management of venous ulcer of lower limb?

a) Initial treatment is debridement and surgery

b) Compression dressings should ideally be applied on twice weekly basis

c) Antibiotics do not speed up the ulcer healing

d) Biological dressings do not have potential to improve healing

Correct Answer - C

Answer- C. Antibiotics do not speed up the ulcer healing

- Patients are initially treated by a compression bandaging regimen.
- Alternative to these bandaging regimens is to apply a bland absorbent leak-proof dressing beneath a graduated elastic compression stocking (class II).
- Biopsies are indicated if malignancy is suspected and it is important to remember that a Marjolin's type of ulcer (a squamous cell or basal cell carcinoma) can develop in a chronic longstanding venous ulcer.
- Consideration must be given to healing the ulcer by excision and grafting.
- Biological dressings have been developed, including fetal keratinocytes and collagen meshes
- Pinch grafts and ulcer excision with mesh grafting have been shown to provide good early healing with moderate long-term results

215. Which of the following suture has max tensile strength and minimum tissue reaction

a) Poliglecaprone

b) Polypropylene

c) Polygalctine

d) Polydioxanone

Correct Answer - B

Answer- B. Polypropylene

Polypropylene sutures are non-absorbable and provide permanent wound support.

Polypropylene sutures are blue colored for easy identification during surgery.

Polypropylene sutures have excellent tensile strength and are used for orthopaedic, plastic and micro surgeries, general closure and cardiovascular surgeries

**216. Blunt trauma exploratory laparotomy
done nonexpansile swelling found on
mesenteric border of intestine,
management**

a) Resection and anastomosis

b) Ligation

c) Excision of swelling

d) None

Correct Answer - D

Answer- D. None

Non Expansile swelling on mesenteric border of intestine is almost always due to mesenteric adenitis and it is an incidental finding, hence warranting no surgical intervention.

217. In SVC syndrome for non small cell carcinoma of lung management done

a) Radiotherapy

b) Immunotherapy

c) Chemotherapy

d) Surgery

Correct Answer - A

Answer- A. Radiotherapy

In patients with SVCS secondary to non–small-cell carcinoma of the lung, radiotherapy is the primary treatment. The likelihood of patients benefiting from such therapy is high, but the overall prognosis of these patients is poor

Small cell carcinoma of lung presenting as SVC syndrome -

Combination of chemotherapy and radiotherapy.

Non Small cell carcinoma of lung presenting as SVC syndrome-

Radiotherapy alone.

218. Hadfields operation is performed for which of the following pathology?

a) Duct ectasia

b) Fibroadenoma

c) Mondors disease

d) Inflammatory breast carcinoma

Correct Answer - A

Answer- A. Duct ectasia

TREATMENT-

- Stop smoking
- Hadfield's operation- excision of all major ducts
- Antibiotics- amoxiclav and metronidazole

219. Microdochotomy is treatment for

a) Duct ectasia

b) Breast abscess

c) Duct papilloma

d) DCIS

Correct Answer - C

Answer- C. Duct papilloma

The final diagnosis is made by excising the involved duct (Microdochotomy) and any underlying mass if present and subjecting them for a histopathological diagnosis

220. Previous radiation therapy for which disease particularly increases the risk of breast carcinoma development?

a) Hodgkins lymphoma

b) Mantle cell lymphoma

c) Nasopharyngeal carcinoma

d) Lung carcinoma

Correct Answer - A

Answer- A. Hodgkins lymphoma

A real problem in women who have been treated with mantle radiotherapy as part of the management of Hodgkin's disease, in which significant doses of radiation to the breast are received.

221. LAHSAL code is used to represent congenital malformation of -

a) Lip

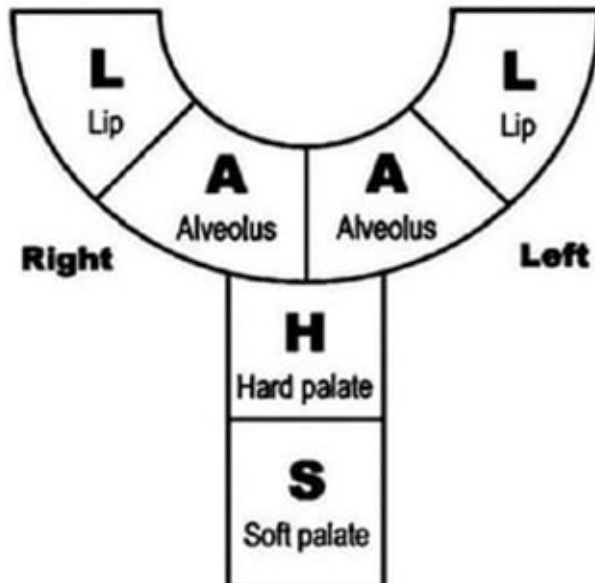
b) Alveolus

c) Hard and soft palate

d) All the above

Correct Answer - D

Answer- D. All the above



222. Which of the following histological type of breast carcinoma worst prognosis?

a) Tubular

b) Colloid

c) Papillary

d) Scirrhou

Correct Answer - D

Answer- D. Scirrhou

MC type of breast carcinoma is invasive ductal carcinoma (scirrhou).

MC form seen (60- 75%)

Hard lump, whitish yellow, non capsulated, irregular with cartilaginous consistency

Retraction of nipple

**223. Kernahen's striped 'Y' classification,
Main reference point is -**

a) Incisive foramen

b) Soft palate

c) Hard palate

d) Third molar

Correct Answer - A

Answer- A. Incisive foramen

Kernahen's striped 'Y' classification

It is used to classify cleft lip and cleft palate

The incisive foramen is taken as reference point

224. The most commonly used myocutaneous pedicle graft for pelvis surgeries contains muscle segments from -

a) Rectus abdominis muscle

b) External oblique muscle

c) Internal oblique muscle

d) Transversus abdominis muscle

Correct Answer - A

Answer- A. Rectus abdominis muscle

The most frequently used myocutaneous pedicle grafts contain, muscle segments from the rectus abdominis muscle of the anterior abdominal wall, gracialis muscle of the inner thigh, bulbocavernosus muscle of the vulva, the tensor fascia lata muscle of the lateral thigh, and gluteus maximus muscle.

225. 52 years female patient presents with 4 cm diameter diagnosed breast cancer lesion with ipsilateral axillary and contralateral supraclavicular lymphadenopathy. As per AJCC system, patient belongs to which stage of breast cancer?

a) IIa

b) None

c) IIIc

d) IV

Correct Answer - D
Answer- D. IV

AJC clinical staging of breast cancer.

Stage TIS:	<i>In situ</i> carcinoma (<i>in situ</i> lobular, intraductal, Paget's disease of the nipple without palpable lump)
Stage I:	Tumour 2 cm or less in diameter No nodal spread
Stage II:	Tumour > 2 cm and < 5 cm in diameter Regional lymph nodes involved
Stage III A:	Tumour \geq 5 cm in diameter Regional lymph nodes involved on same side
Stage III B:	Tumour \geq 5 cm in diameter Supraclavicular and infraclavicular lymph nodes involved
Stage IV:	Tumour of any size With or without regional spread but with distant metastasis

226. Revascularization and angiogenesis process after skin grafting is seen after how many days after the procedure?

a) 4

b) 5

c) 6

d) 7

Correct Answer - B

Answer- B. 5

Revascularization or angiogenesis

- After approx 5 days, revascularization occurs and the graft demonstrates both arterial inflow and venous outflow.

227. Best prognosis for carcinoma breast is seen with which of the following?

a) <1cm size, nodes -ve , ER/ PR +ve, her 2/ neu -ve

b) <1cm size, nodes -ve , ER/ PR -ve, her 2/ neu +ve

c) <2cm size, nodes -ve , ER/ PR +ve, her 2/ neu -ve

d) <2cm size, nodes -ve , ER/ PR -ve, her 2/ neu +ve

Correct Answer - A

Answer- A. <1cm size, nodes -ve , ER/ PR +ve, her 2/ neu -ve

Molecular changes in the tumor are also useful. Tumors that overexpress erbB2 (HER2/neu) or have a mutated p53 gene have a worse prognosis. Tumors that overexpress erbB2 are more likely to respond to higher doses of doxorubicin- containing regimens and predict those tumors that will respond to HER2/neu antibodies (trastuzumab) (herceptin) and HER2/ neu kinase inhibitors.

228. Favorable prognosis with > 90% 5 year survival rate for carcinoma breast is seen in which of the following?

- a) Screen detected ductal carcinoma in situ
- b) Screen detected lobular carcinoma in situ
- c) Node negative tumor with favourable histology
- d) None of the above

Correct Answer - A

Answer- A. Screen detected ductal carcinoma in situ

Intraductal carcinoma (malignant mammary ductal epithelial cells) without any invasion into basement membrane.

Group	Approximate 5-year survival rate	Features	Treatment
'Very low-risk' primary breast cancer	> 90%	special types Node negative with favourable histology	Local
'low-risk' primary breast cancer	70-90%	Node positive or unfavourable histology	Locoregional with/without systemic
'High-risk' primary breast cancer	< 70%	Large primary or inflammatory	Locoregional with systemic
'Locally advanced'	< 30%		Primary systemic
'Metastatic'			Primary systemic

229. What percentage of reduction in dying from breast cancer can be achieved with annual screening after age of 50 yrs with mammography?

a) 15- 20 %

b) 20- 25 %

c) 25- 30 %

d) 30- 35 %

Correct Answer - C

Answer- C. 25- 30 %

Meta-analysis examining outcomes from every randomized trial of mammography conclusively shows a 25-30% reduction in the chance of dying from breast cancer with annual screening after age 50 years.

230. Which of the following hormonal levels influence the development of benign breast disease?

a) Estrogen

b) Progesterone

c) Lutenizing hormone

d) Testosterone

Correct Answer - A:B

Answer- A.Estrogen & B. Progesterone

Etiology/Pathogenesis

Hormonal: Responsiveness of breast tissue to monthly changes of estrogen and progesterone play an important role in pathogenesis of benign breast disease. They may be related to excess hormonal stimulation or hypersensitivity of breast tissue.

231. Which of the following is true about breast reconstruction surgery

- a) Easiest reconstruction is done using silicon gel implant
- b) TRAM flap gives better cosmetic results than LD flap
- c) Radiotherapy in post op period does not influence the outcome after breast reconstruction
- d) Nipple reconstruction cannot be performed under local anesthesia

Correct Answer - A

Answer- A. Easiest reconstruction is done using silicon gel implant

The easiest type of reconstruction is using a silicone gel implant under the pectoralis major muscle.

This may be combined with prior tissue expansion using an expandable saline prosthesis first (or a combined device), which creates some ptosis of the new breast.

If the skin at the mastectomy site is poor (e.g. following radiotherapy) or if a larger volume of tissue is required, a musculocutaneous flap can be constructed either from the latissimusdorsi muscle (an LD flap) or using the transversusabdominis muscle (a TRAM flap as). The latter gives an excellent cosmetic result in experienced hands but is a lengthy procedure and requires careful patient selection.

It is now usually performed as a free transfer using microvascular anastomosis, although the pedicled TRAM from the contralateral side is still used.

Variations on the TRAM flap requiring less muscle harvesting, such as the DIEP flap (based on deep inferior epigastric vessels), are

increasingly being used.

Impediments to immediate reconstruction include insufficient theatre time and a lack of experienced reconstructive surgeons.

In addition, if a patient is likely to need postoperative radiotherapy then a delayed reconstruction using a flap often gives a better result.

Radiotherapy onto a prosthesis often leads to a high incidence of capsular contracture and unacceptable results.

Nipple reconstruction is a relatively simple procedure that can be performed under a local anaesthetic.

232. Treatment of large omphalocele defect can be done by

a) Primary closure

b) Staged closure using PTFE mesh

c) Painting intact sac daily with antiseptic solution

d) All the above

Correct Answer - D

Answer- D. All the above

Large defects present a more substantial problem and four techniques have been described: non-operative therapy, skin flap closure, staged closure and primary closure

233. Which of the following is not true about Pateys mastectomy

- a) It is also called modified radical mastectomy
- b) Intercosto brachial nerves are usually preserved
- c) All lymph nodes of axilla are removed
- d) Pectoralis muscle is either divided or retracted

Correct Answer - B

Answer- B. Intercosto brachial nerves are usually preserved

It is also called modified radical mastectomy and is a commonly performed procedure.

The intercostal brachial nerves are usually divided in this operation and the patient should be warned about sensation changes postoperatively.

The wound is drained using a wide-bore suction tube.

Early mobilisation of the arm is encouraged and physiotherapy helps normal function to return very quickly

234. Dermoepidermal burn is what degree of burn -

a) I

b) II

c) III

d) IV

Correct Answer - B

Answer- B. II

Dermoepidermal burns are Superficial II degree burns.

235. Macroprolactinoma ideal treatment is

a) Excision

b) Bromocriptine

c) Stereotactic radio surgery

d) Observation

Correct Answer - B

Answer- B

Bromocriptine (BEC) is generally considered to be the agent of choice in the treatment of prolactinoma because of its long track record and safety.

236. Initial treatment for most patient of growth hormone secreting pituitary adenoma is

a) Transphenoidal surgical resection

b) Somatostatin analogs

c) GH rector antagonists

d) Dopamine agonists

Correct Answer - A

Answer- A. Transphenoidal surgical resection

Transsphenoidal surgical resection by an experienced surgeon is the preferred primary treatment for both microadenomas (cure rate -70%) and macroadenomas (<50% cured).

237. Radioiodine preferred in treatment in

a) Young patients

b) Pregnancy

c) Recent onset of toxic goiter

d) Post surgery for papillary thyroid cancer

Correct Answer - C

Answer- C. Recent onset of toxic goiter

The main indications for RAI therapy include the following conditions

- 1. Hyperthyroidism due to:
 - Grave's disease
 - Toxic multinodular goitre or
 - Hyperfunctioning thyroid nodules
- 2. Non-toxic multinodular goitre
- 3. Thyroid cancer.

238. Parathyroid adenomas account for how much percentage of patients with primary hyperpara-thyroidism?

a) 50%

b) 60%

c) 70%

d) 80%

Correct Answer - D

Answer- D. 80%

Solitary adenomas, A single abnormal gland, is the cause in -80% of patients; the abnormality in the gland is usually a benign neoplasm or adenoma and rarely a parathyroid carcinoma.

239. Investigation of choice for hepatic metastasis from stomach cancer is

a) MRI

b) CECT

c) USG

d) HIDA

Correct Answer - B

Answer- B. CECT

CT is the imaging modality of choice for evaluating liver metastases. This preference is largely attributable to the effects of the dual blood supply on the enhancement characteristics of metastases, as compared with normal liver parenchyma.

240. Normal urine flow rate in healthy adults in urodynamic study is -

a) 10 ml/sec

b) 20 ml/sec

c) 25 ml/sec

d) 5 ml/sec

Correct Answer - B

Answer- B. 20 ml/sec

Ages 14 to 45 -- The average flow rate for males is 21 mL/sec. The average flow rate for females is 18 mL/sec.

Ages 46 to 65 -- The average flow rate for males is 12 mL/sec. The average flow rate for females is 18 mL/sec.

Ages 66 to 80 -- The average flow rate for males is 9 mL/sec. The average flow rate for females is 18 mL/sec.

241.

Radical nephrectomy involves resection of the following except -

- a) Gerotas fascia
- b) Ipsilateral adrenal gland
- c) Surrounding hilar lymph nodes
- d) Proximal para-aortic lymph nodes

Correct Answer - D

Answer- D. Proximal para-aortic lymph nodes

The standard management for stage I or II tumors and selected cases of stage III disease is radical nephrectomy.

This procedure involves en bloc removal of Gerota's fascia and its contents, including the kidney, the ipsilateral adrenal gland, and adjacent hilar lymph nodes.

242. Prognosis of surgery for liver secondaries is best for which cancer?

a) Colorectal

b) Neuroendocrine

c) Genitourinary

d) Esophageal

Correct Answer - C

Answer- C. Genitourinary

For noncolorectal, nonneuroendocrine tumors, metastases from genitourinary primaries have the best prognosis following hepatic metastatectomy.

243. Indications of liver transplant in PCM poisoning are all except

a) SGPT increase

b) PT/INR

c) High creatinine

d) Encephalopathy

Correct Answer - A

Answer- A. SGPT increase

Indication poor prognosis and hence necessitate a transplant in such patients-

- .. Arterial pH < 7.3 (taken by sampling of blood from an artery)
- ?. All three of an international normalized ratio (INR) of greater than 6.5, serum creatinine of greater than 300 micromoles per litre and the presence of encephalopathy (of grade III or IV). These three are markers of coagulopathy, kidney function and mental status.

244. Harder renal stone having less satisfactory results with ECWL is -

a) Oxalate stone

b) Phosphate stone

c) Urate stone

d) Cystine stone

Correct Answer - D

Answer- D. Cystine stone

Extracorporeal Shockwave Lithotripsy (ECWL):

- A urinary calculus has a crystalline structure. Bombarded with shock waves of sufficient energy it disintegrates into fragments.
- The clearance of stone from the kidney using ESWL will depend upon the consistency of the stone and its site.
- Most oxalate and phosphate stones fragment well.

245. Milan criteria is for

a) Selecting patients for Liver transplantation

b) Selecting patients for Lung transplantation

c) Selecting patients for Kidney transplantation

d) Selecting patients for heart transplantation

Correct Answer - A

Answer- A. Selecting patients for Liver transplantation

The Milan criteria state that a patient is selected for transplantation when he or she has:

1. One lesion smaller than 5 cm
2. Up to 3 lesions smaller than 3 cm
3. No extrahepatic manifestations
4. No vascular invasion

246. What should be the plan of management for a patient for whom while undergoing simple cholecystectomy T2 gall bladder carcinoma is discovered?

a) Resection of 4b-5 segment, dissection of the N1-2 nodes and excision of port sites

b) Post operative adjuvant chemotherapy

c) Radical cholecystectomy

d) Whipples procedure

Correct Answer - A

Answer- A. Resection of 4b-5 segment, dissection of the N1-2 nodes and excision of port sites

Stage I and II - simple cholecystectomy

Stage III – cholecystectomy + adjacent hepatic resection (atleast 2cm depth) + regional lymphadenectomy

Poor prognosis

247. Following are the sign/s suggestive of obstruction of urinary tract on CT Scan

a) Hyroureter

b) Perinephric stranding

c) Thickening of the lateroconal fascia

d) All the above

Correct Answer - D

Answer- D. All the above

Nonenhanced CT has been accepted as the imaging modality of choice in the radiologic evaluation of patients suspected of having urolithiasis.

CT is superior to other imaging modalities in the diagnostic accuracy and assessment of their characteristics.

The most direct sign of ureterolithiasis is the stone within the ureteral lumen, with proximal ureteral dilatation and normal distal caliber.

Other favorable secondary signs at CT are: Hydroureter, hydronephrosis, perinephric stranding, periureteral edema and unilateral renal enlargement.

248. Treatment of choice for bladder stone

a) Transurethral litholapaxy

b) Percutaneous suprapubic litholapaxy

c) Vesicotomy and stone retrieval

d) Intravenous antibiotics

Correct Answer - A

Answer- A. Transurethral litholapaxy

TREATMENT-

A transurethral cystolitholapaxy is the most common procedure used to treat adults with bladder stones.

- Small stone- Ultrasound lithotripsy
- Large stone- laser lithotripsy
- Litholapaxy- cystoscopic lithotrite
- Suprapubic cystolithotomy

249. 3cm stone in cystic duct near the ampulla of vater, The Method of removal is a

a) Transduodenal approach

b) Supraduodenal approach

c) Lithotripsy

d) Chemical dissolution

Correct Answer - A

Answer- A. Transduodenal approach

According to Maingot's "The methods of surgical drainage include transduodenal sphincterotomy, choledochoduodenotomy, and choledochojejunostomy."

250. 40 years old male complains of loin pain since 1 month. Patient's complaint of pain has severely increased over last 2 hours and pain now radiates from loin and to groin and anterior thigh and patient is writhing in bed for comfort. What is the most probable etiology?

a) Bladder calculus

b) Ureteric calculus

c) Vesico ureteric reflux

d) Hydronephrosis

Correct Answer - B

Answer- B. Ureteric calculus

There is a pattern of severe exacerbation on a background of continuing pain

Radiates to the groin, penis, scrotum or labium as the stone progresses down the ureter

The severity of pain is not related to the size of the stone

The pain is almost invariably associated with haematuria

There may be few physical signs

251. What is the main hazard of ectopic testis

-

a) Impotence

b) Carcinoma development

c) Liable to injury

d) Hernia development

Correct Answer - C

Answer- C. Liable to injury

The main hazard is liability to injury.

252. Traditionally scrotal carcinoma is associated with which of the following occupations?

a) Chimney sweeps

b) Mule spinners

c) Coal worker

d) Wood workers

Correct Answer - A

Answer- (A) Chimney sweeps

Carcinoma of the scrotum.

It is traditionally recognized as an occupational hazard for chimney sweeps and mule spinners.

It was described by Potts.

It was the first cancer linked to occupational exposure when, in 1775, Perivall Pott described it in chimney sweeps in England. Other occupations that had a preponderance of the disease included people who worked with the distillates of coal and men exposed to mineral oil.

253. Which of the following are the treatment options for cystocele?

a) Anterior colporrhaphy

b) Transvaginal tape

c) Transobturator tape

d) All the above

Correct Answer - D

Answer- D. All the above

Traditionally; an anterior vaginal wall repair (anterior colporrhaphy) was performed vaginally; now replaced by vaginally inserted tape [transvaginal tape (TVT) or transobturator tape (TOT)] or mesh slings.

254. Most common site of penile carcinoma is

-

a) Glans

b) Prepuce

c) Shaft

d) Coronal sulcus

Correct Answer - A

Answer- A. Glans

- When it occurs on the glans penis, it is known as erythroplasia of Queyrat and when it occurs on the shaft of the penis it is called Bowen's disease.
- Carcinoma of the penis is most typically a squamous cell carcinoma arising in the skin of the glans penis or the prepuce.
- MC originates from glans > sulcus > prepuce > shaft

255. Best time for surgery of hypospadias is at what age -

a) 0 - 4 months

b) 4 - 6 months

c) 6 - 10 months

d) > 2 years

Correct Answer - C

Answer- C. 6 - 10 months

Operations for hypospadias are routinely performed when the patient is between **6 and 18 months** of age.

The infant has good tolerance to surgery and anesthesia by the age of 6 months. The child is well aware of his genitalia and toilet training by the age of 18 months. So, the most suitable age for the operation of hypospadias is between 6 and 18 months.

The degree of hypospadias dictates the need for repair. If the opening is glanular or coronal (85% of patients), the penis is usually functional both for micturition and procreation and repair is done primarily for cosmetic reasons. Openings that are more proximal on the shaft require correction to allow voiding while standing, normal erection, and proper sperm deposition during intercourse.

The commonest procedure for **distal hypospadias is the 'tubularized incised plate' urethroplasty**, while techniques that utilize the foreskin are commonly used for more proximal hypospadias.

Complications of hypospadias surgery:

- **urethrocutaneous fistula (most common)**
- Recurrence of chordee
- Urethral stricture

- Meatal stenosis
- Infection

256. Commonest site of hypospadias is -

a) Just proximal to glans

b) In the meid of penis

c) Scrotum

d) Perineum

Correct Answer - A

Answer- A. Just proximal to glans

Hypospadias is a condition in which the urethral meatus opens on the underside of penis or the perineum (i.e. ventral surface of penis) proximal to the tip of the glans penis.

257. Which enzyme is of diagnostic importance in chronic pancreatitis

a) Amylase

b) Pancreatic polypeptide

c) Lipase

d) Serum Interleukin 6 levels

Correct Answer - C

Answer- C. Lipase

Elevated lipase levels are more specific to the pancreas than elevated amylase levels. Lipase levels remain high for 12 days. In patients with chronic pancreatitis (usually caused by alcohol abuse), lipase levels may be elevated in the presence of a normal serum amylase level.

258. Most common screening test for acute pancreatitis -

a) Serum amylase

b) Serum lipase

c) Urine trypsinogen

d) Insulin

Correct Answer - C

Answer- C. Urine trypsinogen

Rapid measurement of urinary trypsinogen - 2 level is useful in the emergency department as a screening test for acute pancreatitis.

259. Physiological adhesions between foreskin and glans penis persist until years of age -

a) 4

b) 5

c) 6

d) 7

Correct Answer - C

Answer- C. 6

Phimosis is a condition in which the foreskin of the penis cannot be pulled back past the glans.

The physiological adhesions between the foreskin and the glans penis may persist until 6 years of age or more, giving the false impression that the prepuce will not retract.

260. Which of the following is/ are the imaging criteria for unresectable carcinoma of pancreas?

a) Metastatic spread to vertebrae

b) Invasion in duodenal wall

c) Irregular increase in density of omental fat

d) All the above

Correct Answer - D

Answer- D. All the above

Metastatic spread outside the pancreas makes tumor unresectable.
Tumor invasion into adjacent organs signifies unresectability.

261. A 10 years old male presents a smooth swelling near superficial inguinal ring, which moves downwards when the testicle is pulled downwards. Diagnosis

-

a) Inguinal hernia

b) Congenital hydrocele

c) Encysted hydrocele of the cord

d) Varicocele

Correct Answer - C

Answer- C. Encysted hydrocele of the cord

A hydrocoele develops in a remnant of the processus vaginalis somewhere along the course of the spermatic cord. This hydrocoele also transilluminates, and is known as an encysted hydrocoele of the cord.

The swelling moves downwards and becomes less mobile if the testis is pulled gently downwards.

In females, a multicystic hydrocoele of the canal of Nuck sometimes presents as a swelling in the groin.

262. Drug of choice for palliative treatment of pancreatic carcinoma

a) Erlotinib

b) Gemcitabine

c) Paclitaxel

d) Cyclophosphamide

Correct Answer - B

Answer- B. Gemcitabine

A) Inoperable locally advanced disease-

- Gemcitabine is used as the treatment of choice for these patients.

B) Metastatic Disease

- Gemcitabine is the standard treatment with a median survival of 6 months and a 1-year survival rate of only 20%.
- Capecitabine, an oral fluoropyrimidine, has been combined with gemcitabine (GEM-CAP) in a phase III trial that showed an improvement in response rate and progression-free survival over single-agent gemcitabine, but no survival benefit.

263.

Modified-Kaush Whipple operation is devised to preserve which part of stomach?

a) Fundus

b) Body

c) Lesser curvature

d) Pyloric antrum

Correct Answer - D

Answer- D. Pyloric antrum

This procedure is also called pylorus preserving pancreaticoduodenectomy (PPPD or pp-Kaush Whipple procedure). It is the procedure of choice for most adenocarcinomas of the head of pancreas.

The original pancreato- duodenectomy as proposed by Whipple included resection of the gastric antrum.

The Whipple procedure is now reserved for situations in which the entire duodenum has to be removed (e.g. in FAP) or where the tumour encroaches on the first part of the duodenum or the distal stomach and a PPPD would not achieve a clear resection margin.

264. Which of the following causes of acute pancreatitis can cause recurrent bouts without any obvious pathology

a) Sphincter Oddi dysfunction

b) Pancreas divisum

c) Hypertriglyceridemia

d) All the above

Correct Answer - D

Answer- D. All the above

Etiology-

- Gall stones (most common)
- Alcohol abuse is the second cause of acute pancreatitis.
- Occult disease of the biliary tree or pancreatic ducts, especially microlithiasis, sludge.
- Hypertriglyceridemia
- Pancreas divisum
- Pancreatic cancer
- Sphincter of Oddi dysfunction
- Cystic fibrosis
- Drugs- Steroids, Azathioprine, Valproate, Estrogens, L-Asparaginase, 6-mercaptopurine, Sulfonamides, Tetracycline, Anti-retroviral agents, Thiazide diuretics
- Familial or genetic
- Hyperparathyroidism
- Hypercalcemia
- Post ERCP
- Most common causes in children: blunt abdominal injuries,

multisystem disease (hemolytic uremic syndrome and inflammatory bowel disease) biliary stones or microlithiasis (sludging), and drug toxicity

265. Pseudocyst pancreas is developed in how much duration following an attack of acute pancreatitis?

a) Less than 1 week

b) Less than 2 weeks

c) 3 or more weeks

d) 4 or more weeks

Correct Answer - D

Answer- D. 4 or more weeks

- Pseudocysts typically arise following an attack of mild acute pancreatitis, lie outside the pancreas, and represent an APFC that has not resolved and matured.
- Formation of a pseudocyst requires 4 weeks or more from the onset of acute pancreatitis.

266. True of umbilical hernia -

- a) Most common content is large intestine
- b) Most of the umbilical hernias disappear spontaneously
- c) Males are affected more than females
- d) Uncomplicated hernias are repaired at 1 year of age through an infraumbilical incision.

Correct Answer - B

Answer- B. Most of the umbilical hernias disappear spontaneously

Umbilical hernia develops due to either absence of umbilical fascia or incomplete closure of umbilical defect in infants.

Umbilical hernia (paraumbilical hernia) is a protusion or herniation through linea alba just above or below umbilicus.

Weakest part is umbilical cicatrix.

Contents are- greater omentum, small intestine and transverse colon.

CLINICAL FEATURES-

- Females in 5th decade
- Swelling has smooth surface, distinct edges resonant with dragging pain.
- Expansile impulse on patient coughing
- Surgical treatment is indicated if
- Hernia persists at 2 years of age or older.
- If the defect is more than 2 cm in size.
- If it is associated with complications.
- Heriorrhaphy (surgery for repair of hernia) is done through an infraumbilical incision. Defect is closed with interrupted sutures after ligating the sac.

267. Treatment of congenital hydrocephalus is -

a) Ventriculoperitoneal shunt

b) Stereotactic radio surgery

c) Diuretics

d) Radiotherapy

Correct Answer - A

Answer- A. Ventriculoperitoneal shunt

Congenital Hydrocephalus - Treatment Options

1. Ventriculoperitoneal shunt
2. Endoscopic third ventriculostomy
3. Lumbar puncture (temporary measure till a shunt is put)

268. Scrotal swelling non reducible but disappears when the child wakes up from sleep is most likely to be -

a) Congenital hydrocele

b) Varicocele

c) Indirect inguinal hernia

d) None of the above

Correct Answer - A

Answer- A. Congenital hydrocele

- In congenital hydrocele the communication with peritoneal cavity is usually too small to allow herniation of intra-abdominal contents.
- Usually hydrocele is a non reducible swelling but congenital hydrocele can passively get drained through intact tunics vaginalis due to gravity while sleeping.
- Both varicocele and indirect inguinal hernia are reducible scotal swelling.
- So the most probable answer is **Congenital hydrocele**

269. How much percentage of the blunt trauma injuries to spleen in adults are currently managed non operatively?

a) 30%

b) 50%

c) 80%

d) 90%

Correct Answer - C

Answer- C. 80%

Spleen is the intra-abdominal organ most commonly injured in a blunt trauma to the abdomen.

Up to 80% of **blunt splenic injuries** can be **managed non-operatively**.

It can be managed in 2 ways :

i) Non-operatively

- This is now the order of the day and currently > 70% of adults with blunt splenic injuries are managed non-operatively.
- But the primary requirement for it is - hemodynamic stability.

ii) Operative management

- Patients who are hemodynamically unstable or are failing non-operative management (eg. require continuing transfusion) should undergo operative treatment.

270. 40 years male presents with translucent scrotal swelling in which it is possible to get above the swelling on examination. What is the most probable diagnosis?

a) Hydrocele

b) Indirect inguinal hernia

c) Varicocele

d) Sebaceous cyst

Correct Answer - A

Answer- A. Hydrocele

Hydroceles are typically translucent and it is possible to 'get above the swelling' on examination of the scrotum.

A hydrocele is an abnormal collection of serous fluid in a part of the processus vaginalis, usually the tunica.

Encysted hydrocele of the cord is a smooth oval swelling near the spermatic cord, which is liable to be mistaken for an inguinal hernia.

The swelling moves downwards and becomes less mobile if the testis is pulled gently downwards

271. Most prevalent symptom in patients of leiomyoma of esophagus is

a) Pain

b) Pyrosis

c) Dysphagia

d) Weight loss

Correct Answer - C

Answer- C. Dysphagia

CLINICAL FEATURES-

- Asymptomatic (<5cm)
- Dysphagia, pain
- More common in males
- Location- 2/3rd of oesophagus

272. Which of the following famous personalities had hydrocele associated with hernia, which proved to be fatal?

a) Edward Gibbon

b) Thomas Edison

c) Miley Wright

d) Neil Armstrong

Correct Answer - A

Answer- A. Edward Gibbon

Edward gibbon (1737-1794), english historian had large hydrocele. The hydrocele was associated with a large scrotal hernia which probably was punctured.

273. Following is not true about traction diverticulum of esophagus -

- a) Produced due to the extraluminal forces
- b) It is not a true diverticulum
- c) The outpouching is usually small and conical
- d) May develop tracheoesophageal fistula

Correct Answer - B

Answer- B. It is not a true diverticulum

In traction diverticula extraluminal forces (like inflamed & scarred peribronchial & mediastinal lymph nodes) pull the full thickness of the esophagus out, creating a true diverticula.

Traction diverticula are much less common. They are mostly a consequence of chronic granulomatous disease affecting the tracheobronchial lymph nodes due to tuberculosis, atypical mycobacteria or histoplasmosis.

Fibrotic healing of the lymph nodes exerts traction on the oesophageal wall and produces a focal outpouching that is usually small and has a conical shape

274. Which of the following is false about zenkers diverticulum

- a) Most patients are above 50 years of age
- b) It is the most common esophageal diverticulum
- c) Mucosal outpouching through the killians triangle
- d) Cervical webs can be associated with zenkers diverticulum in 80% of the patients

Correct Answer - D

Answer- D. Cervical webs can be associated with zenkers diverticulum in 80% of the patients

Zenker diverticulum originates from the posterior wall of the esophagus in a triangular area of weakness, limited inferiorly by the cricopharyngeus muscle and superiorly by the inferior constrictor muscles (ie, the Killian triangle).

Zenker's diverticulum, also pharyngoesophageal diverticulum, also pharyngeal pouch, also hypopharyngeal diverticulum, is a diverticulum of the mucosa of the pharynx, just above the cricopharyngeal muscle (i.e. above the upper sphincter of the esophagus).

It is a pseudo diverticulum (not involving all layers of the esophageal wall).

Seen in 50years old.

275. True about esophageal carcinoma is

- a) More lethal than the colorectal cancers
- b) These show an increasing trend towards the number of squamous cell carcinomas
- c) Smaller size esophageal lesions have better survival
- d) Asymptomatic benign lesions should be excised immediately

Correct Answer - A

Answer- A. More lethal than the colorectal cancers

Etiology:

- alcohol and smoking: for squamous cell carcinoma and adenocarcinoma
- achalasia
- asbestosis
- Barrett oesophagus: for adenocarcinoma
- coeliac disease
- ionising radiation
- caustic stricture/lye stricture
- Plummer-Vinson syndrome
- Even when detected as a small lesion, esophageal cancer has poor survival because of the abundant esophageal lymphatics leading to regional lymph node metastases.

276. Patient complains of intermittent dysphagia which is equal both for solids and liquids, which of the following is the most probable diagnosis?

a) Achalasia cardia

b) Esophageal stricture

c) Carcinoma esophagus

d) Diffuse esophageal spasm

Correct Answer - D

Answer- D. Diffuse esophageal spasm

Clinical features-

- Hypertrophy of circular muscles
- Dysphagia
- Chest pain

277. Early and late suspected instrumental perforation of oesophagus should first be assessed using

a) Water soluble contrast swallow

b) CT Scan

c) Dilute barium swallow

d) MRI

Correct Answer - A

Answer- A. Water soluble contrast swallow

If this is negative, a dilute barium swallow should be considered. A CT scan can be used to replace a contrast swallow or as an adjunct to accurately delineate specific fluid collections.

278. Downhill esophagus varices develop as a result of obstruction of seen in

a) Portal vein

b) Hepatic vein

c) Superior vena cava

d) Inferior vena cava

Correct Answer - C

Answer- C. Superior vena cava

Downhill varices are produced by the obstruction of the superior vena cava, which results in collateral drainage from the head, neck and upper extremity venous systems into the veins surrounding the mid and upper thoracic esophagus and into the azygous vein. On CT varices appear as enhancing tubular regions in the periesophageal region. This density is equal to the venous blood pool.

279. Most common impacted foreign body in esophagus in children is

a) Coin

b) Food product

c) Krayon

d) Marble

Correct Answer - A

Answer- A. Coin

Coins are the most commonly impacted foreign bodies in children in esophagus and oropharynx followed by the food products

280. Pantaloon hernia is also called as -

a) Dual hernia

b) Saddle bag hernia

c) Bochdaleks hernia

d) Retrosternal hernia

Correct Answer - B

Answer- B. Saddle bag hernia

It is also called dual or saddle bag hernia.

This type of hernia consists of two sacs that straddle the inferior epigastric artery, one sac being medial and the other lateral to this vessel.

281. Rolled up omentum is seen in cases of -

a) Peritoneal tuberculosis

b) Peritoneal metastases

c) Perforation peritonitis

d) Malrotation of gut

Correct Answer - A

Answer- A. Peritoneal tuberculosis

The classic appearance of greyish white military nodules scattered over the peritoneum. In addition fibrous bands and adhesions are common.

The omentum may become thickened presenting as a transversely placed mass (rolled up omentum).

Clinically the most frequent presentation of the peritoneal disease is ascites.

282. Staging of rectal carcinoma is best done by -

a) CT Scan

b) MRI

c) TRUS

d) All the above

Correct Answer - B

Answer-B

90% of rectal growths can be felt by per-rectal examination

High-resolution phased array external MRI is the **investigation of choice** for local issues in the primary **staging of rectal cancer (best investigation for staging)** as well as for restaging after NACT-RT. It provides the highest accuracy for issues in pretreatment local **staging**

Investigation of choice – rigid sigmoidoscopy and biopsy

To assess local spread – TRUS (Endoluminal ultrasound)

For local staging and assessment of proposed circumferential resection margin – MRI (CT is not accurate in local staging)

283. Treatment of choice for low fistula in ano is -

a) Fistulotomy

b) Intravenous antibiotics

c) Staged surgical resection

d) None of the above

Correct Answer - A

Answer- A. Fistulotomy

It is divided into 2 types - high & low, according to whether their internal openings is below or above the anorectal ring.

The importance of deciding whether a fistula is a low or a high type is that a low level can be treated by fistulotomy (opening the tract) without causing damage to the sphincter.

284. Exception to Goodsals rule is considered when the anterior external opening is more situated more than cms from anal margin -

a) 2

b) 3

c) 4

d) 5

Correct Answer - B

Answer- B. 3

Goodsall's Rule

Is used to determine the location of internal opening

According to it :

- Fistulas with external opening anterior to horizontal imaginary line drawn across the mid point of anus connect to the internal opening by short straight tract.
- Fistulas with external opening posterior to the horizontal line - run a curvilinear course and open internally into the posterior midline.

285. Which of the following is not true about medical management of uncomplicated GERD?

a) PPIs are the most effective drug treatment for GORD

b) Household measure of tilting the bed is efficacious

c) Long term PPI therapy increases risk of malignant changes

d) Adequate dose of PPI for 8 weeks is the recommended treatment

Correct Answer - C

Answer- C. Long term PPI therapy increases risk of malignant changes

Treatment-

1. Lifestyle modification with avoiding or cessation of smoking, tea/ coffee, alcohol.
2. Drugs-
 - PPI- antiseecretory drugs
 - Antacids with alginate
 - Prokinetic- itopride (50mg TID) (Cisapride and mosapride not recommended as it causes cardiac arrhythmia)
 - LES sphincter is relaxed by nitrates, atropine and calcium channel blocker.
3. Mucosa protective agents- sucralfate colloidal bismuth
4. Endotherapy- plexiglass minosphere (PMMA)
5. Surgery- antireflux surgery

286. Single drug regimen for carcinoma esophagus which shows significant decrease in tumor size in 15 - 20% of patients incorporates which drug?

a) Cisplatin

b) Bleomycin

c) Doxorubicin

d) Vincristine

Correct Answer - A

Answer- A. Cisplatin

Significant reductions in the size of measurable tumor masses have been reported in 15-25% of patients given single-agent cisplatin treatment and in 30-60% of patients treated with drug combinations that include cisplatin.

287. Critical diameter of caecum when perforation is considered eminent in pseudo-obstruction is -

a) >7 cm

b) >8 cm

c) >9 cm

d) >10 cm

Correct Answer - C

Answer- C. >9 cm

It is defined as large bowel distention resulting from chronic impairment of motility.

The degree of colonic distention may be severe enough to cause caecal perforation.

Imminent perforation of caecum is considered when the caecal diameter exceeds the critical diameter of 9cm (>9cm).

288. Most common type of Hiatal hernia is

a) Sliding

b) Rolling

c) Mixed

d) None of the above

Correct Answer - A

Answer- A. Sliding

There are 4 types of hiatal hernia

Type I : Sliding hernia (most common type - 70 - 80%)

Type II : Paraesophageal or rolling hernia

Type III : Mixed

Type IV : These hernias are distinguished by the presence of other abdominal viscera within the defect i.e. omentum, transverse colon.

289. In corrosive injury of esophagus correct statement is all except

a) Alkalis are usually ingested in larger volumes

b) Alkalis cause more gastric damage than acids

c) Alkalis form fibrous scar

d) Acids form eschar

Correct Answer - B

Answer- B. Alkalis cause more gastric damage than acids

In general, alkalis are relatively odourless and tasteless, making them more likely to be ingested in large volume.

Alkalis cause liquefaction, saponification of fats, dehydration and thrombosis of blood vessels that usually leads to fibrous scarring.

Acids cause coagulative necrosis with eschar formation, and this coagulant may limit penetration to deeper layers of the oesophageal wall.

Acids also cause more gastric damage than alkalis because of the induction of intense pylorospasm with pooling in the antrum.

290. Colonoscopy is are not indicated in -

a) MEN 2B

b) FAP

c) HNPCC

d) Cornkite canada syndrome

Correct Answer - A

Answer- A. MEN 2B

MEN 2B does not predispose to colon cancer.

FAP, HNPCC, Cronkite Canada Syndrome predispose to Colon Cancer and hence screening with colonoscopy is needed

291. An individual of age 40 yrs presents with dysphagia to both solids and liquids with symptoms of regurgitation. Patient also complains of chest pain and weight loss. Which of the following is the preferred investigation for diagnosis of this pathology?

a) Barium swallow X-ray

b) Barium swallow X-ray with esophageal manometry

c) Barium swallow X-ray with esophageal manometry with endoscopy

d) None of the above

Correct Answer - B

Answer- B. Barium swallow X-ray with esophageal manometry

Barium swallow- shows cucumber oesophagus or birds beak or pencil tip deformity.

Oesophageal manometry-

- Characteristics of achalasia cardia
- Hypertensive LOS
- Aperistalsis in the body of oesophagus
- Barium swallow shows a dilated esophagus with tapering narrowing in the terminal end of esophagus, described as 'BIRD BEAK' appearance.

292. Contraindication for colostomy planning are all except -

a) Age > 60 yrs

b) Stoma near skin creases and bony prominences

c) Poorly motivated patient for elective stomy

d) Stomas through previous scars

Correct Answer - A

Answer- A. Age > 60 yrs

The patient must be explained the procedure and properly motivated for taking care of the stoma

The stoma should preferably be through rectus abdominis (to prevent prolapse and parastomal hernias)

It should be through flat surface of abdomen

It should avoid skin creases and bony prominences

It should be away from previous scars

293. Which of the following tumors most commonly presents with upper gastrointestinal bleeding?

a) Primary gastric cancer

b) Esophageal carcinoma

c) Metastases to stomach

d) Hepatic adenocarcinoma

Correct Answer - A

Answer- A. Primary gastric cancer

Tumor bleeding accounts for up to 5% of upper gastrointestinal bleeding (UGIB) cases.

294. True about small intestinal tumor is -

- a) Lymphomas are the most common small intestinal tumors
- b) Carcinoids are more common in the duodenum and jejunum
- c) Adenomatous polyps are more common in the terminal ileum
- d) Risk of developing small bowel tumor correlates positively with colorectal cancer

Correct Answer - D

Answer- D. Risk of developing small bowel tumor correlates positively with colorectal cancer

The second most common small bowel tumor is carcinoid accounting for 35% of all small bowel carcinomas, 90% of which are located in the ileum.

Lymphomas account for the third most common tumors of the small bowel.

Adenomatous polyps tend to occur in the periampullary region and proximal jejunum, close to the entrance of bile and pancreatic secretions into small intestine.

295. Simplest investigation to be performed in suspected cases of gastric cancer is -

a) Double contrast radiography

b) Plain radiography

c) CT Scan

d) Endoscopy

Correct Answer - C

Answer- C Ct scan

Investigation for diagnosis of gastric cancer:

* Ultrasound and CT scan

- To rule out secondaries in the liver.
- To look for enlarged coeliac nodes.
- Can detect ascites-guided fluid tap and cell cytology.
- To detect Krukenberg tumour (pelvic CT).
- Useful in detecting metastatic disease.

296. Which of the following is true about gastric ulcer but not the duodenal ulcer?

- a) Pain rarely occurs at night
- b) Melena is more common than hematemesis
- c) Usually occurs in 40 - 50 yrs of age
- d) Pain is relieved with ingestion of food

Correct Answer - A

Answer- A. Pain rarely occurs at night

Differential features of gastric and duodenal ulcers

Age	Usually 50 yr or older	Usually 40-50 yr
Gender	Male/Female ratio of 1.1:1	Equal male/Female ratio
Blood group	No differentiation	Most often type O
General nourishment	May be malnourished	Usually well nourished
Stomach acid production	Normal secretion or hyposecretion	Hypersecretion
Occurrence	Mucosa exposed to acid-pepsin secretion	Mucosa exposed to acid-pepsin secretion
Clinical course	Healing and recurrence	Healing and recurrence
Pain	Occurs 1/2- 1 hr after a meal; at night- rarely	Occurs 90 min-3 hr after a meal; at night : often awakens client between 1 and 2 am
	Accentuated by ingestion of food	Relieved by ingestion of food
Response to treatment	Healing with appropriate therapy	Healing with appropriate therapy
Hemorrhage	Hematemesis more common than melena	Melena more common than hematemesis
Malignant change	Perhaps in less than 10%	Rare
Recurrence	Tends to heal and recurs often in the same location	60% recur within 1 yr, 90% recur within 2 yr
Surrounding mucosa	Atrophic gastritis	No gastritis

297. Not true about highly selective vagotomy

-

a) It is also known parietal cell vagotomy

b) Nerves of Latarjet are sacrificed

c) Recurrence rates are higher than vagotomy and drainage and vagotomy and antrectomy.

d) Entire gastric reservoir capacity is preserved

Correct Answer - B

Answer- B. Nerves of Latarjet are sacrificed

In Highly selective vagotomy (also known as parietal cell vagotomy or proximal gastric vagotomy) the vagal innervation to the antrum and pylorus (nerves of Latarjet) are preserved, only the vagal supply to the proximal two-thirds of stomach (where essentially all the parietal cells are located) is cut. This preserves gastric motility.

298. Bowel punctured during laparoscopy

a) Trocar kept

b) trocar removal

c) trocar repositioned

d) None

Correct Answer - A

Answer- A. Trocar kept

To assist in identifying the precise site of injury.

299. What is not done in case of puncture wound of left colon

a) Primary suture

b) Hemicolectomy

c) Externalization

d) Resection and anastomosis

Correct Answer - B

Answer- B. Hemicolectomy

Small wound are repaired primarily by simple suturing.

More extensive wound are treated by resection and anastomosis.

Some may require colostomy (externalization)

[Ref Bailey er Love 25th/e p. 1184]

300. What is the percentage body surface area involved in head + face in burns

a) 13

b) 15

c) 17

d) 09

Correct Answer - D

Answer- D. 09

According to rule of 9 (Wallace's formula), burn surface area is calculated as :

1. 9% for the head and neck.
2. 9% for each upper limb.
3. 9% for the front of each lower limb.
4. 9% for the back of each lower limb.
5. 9% for the front of the chest.
6. 9% for the back of the chest.
7. 9% for the front of the abdomen.
8. 9% for the back of the abdomen.
9. 1% for the genitalia.

[Ref Bailey & Love 25th ed p. 381]

301. Plunging Ranula is

a) Cystic growth of sublingual gland

b) Lymph node

c) A tumor in floor of mouth

d) None

Correct Answer - A

Answer- A. Cystic growth of the sublingual gland

- Plunging ranula is a rare form of mucous retention cyst that arises from the sublingual salivary glands.
- Mucus collects below the gland and perforates through the mylohyoid muscle diaphragm to enter the neck.

302. Sialolithiasis is most commonly seen in which gland

a) Parotid

b) Sublingual

c) Submandibular

d) Minor salivary gland

Correct Answer - C

Answer- C. Submandibular

Most common site for salivary gland stone (Sialolithiasis) is submandibular gland, especially duct of submandibular gland (Wharton's duct).

303. Which structure is not preserved in modified radical mastectomy

a) Cephalic vein

b) Pectoralis minor

c) Pectoralis major

d) Branches of Intercostobrachial N.

Correct Answer - A

Answer- A

In the modified radical mastectomy, the procedure involves removal of the breast but preservation of the pectoralis major muscle. The extent of preservation of the pectoralis minor and axillary nodes varies.

Preserve thoracodorsal nerve/vessels.

304. Duputyrens and peyonies are both type of

a) Fibromatosis

b) Fibroblastic hyperplesia

c) Burn contracture

d) Myalgias

Correct Answer - B

Answer- B. Fibroblastic hyperplesia

Dupuytren contracture and Peyranie's diseases are fibroblastic hyperplasia.

Dupuytren's contracture is characterized in the established phase by flexion contracture of one or more fingers from thickening and shortening of palmar oponeurosis.

305. Mid gut Volvulus symptoms appear at

a) 1" week

b) 3rd weeks

c) 2" weeks

d) 4th weeks

Correct Answer - A

Answer- A. 1" week

Midgut volvulus can happen at any age, but most commonly occurs during the first few weeks of life. Bilious emesis is usually the first sign of volvulus.

306. Most common nerve damaged during hernia repair

a) ilioinguinal nerve

b) Iliohypogastric

c) Genitofemoral

d) None

Correct Answer - A

Answer- A. ilioinguinal nerve

- There nerves are exposed to injury during inguinal hernia repair.
 1. Ilioinguinal nerve
 2. Genitofemoral nerve
 3. Iliohypogastric nerve
- The most commonly injured nerve is ilioinguinal nerve.

307. Progressive dysphagia is seen in all except

a) CA esophagus

b) Diffuse esophageal spasm

c) Stricture

d) Achalasia cardia

Correct Answer - B

Answer- B. Diffuse esophageal spasm

Progressive dysphagia is seen in

- CA esophagus
- Stricture
- Achalasia cardia
- Dysphagia equal for both solids and liquids from onset:
 - .. Achalasia
 - ?. Diffuse esophageal spasm

308. Kher sign is seen in

a) Splenic trauma

b) Hepatic trauma

c) Renal trauma

d) Pacreatic trauma

Correct Answer - A

Answer- A. Splenic trauma

In splenic rupture the pain may be referred to the tip of the left shoulder.

This is known as Kehr's sign.

It occurs due to irritation of the undersurface of the diaphragm with blood and the pain is referred to the shoulder through the affected fibres of phrenic nerve (C4 and C5).

309. ABPI of imminent necrosis

a) < 0.3

b) 0.3

c) < 0.6

d) > 0.6

Correct Answer - A

Answer- A. < 0.3

Lower ABPI is an indication of peripheral vascular disease of lower limb.

Critical ischemia (rest pain or tissue necrosis) most commonly is associated with an ABI < 0.4 .

310. Ankle brachial pressure index is

a) 1.0

b) 10

c) 01

d) None

Correct Answer - A

Answer- A. 1.0

Ankle - brachial pressure index (ABPI) is the ratio of BP in ankle to BP in arm (upper limb).

Normal ABPI is around 1 (0.9 - 1.2).

311. In Ainhum, constriction develops usually at the level of interphalangeal joint of

a) Great toe

b) 2nd toe

c) Little toe

d) None

Correct Answer - C

Answer- C. Little toe

Ainhum is bilateral painful constriction at the base of 5th toe (little toe).

This leads to bilateral autoamputation of little toes.

312. True about carcinoma of male breast is

a) Invasive lobular Ca is most common

b) Estrogen receptor negative

c) Seen in young males

d) BRCA2 mutation is associated with increased risk

Correct Answer - D

Answer- D. BRCA2 mutation is associated with increased risk

The average age of men diagnosed with breast cancer is 68 years (old age).

Breast cancers in male have estrogen receptors and high estrogen level is a risk factor for breast carcinoma in males.

Men who inherit abnormal BRCA-1 and BRCA-2 genes have an increased risk for male breast cancer.

Most breast cancers in men are ductal carcinomas.

**313. Most common carcinoma breast in male
S**

a) Lobular carcinoma in situ

b) Ductal carcinoma in situ

c) Infiltrating ductal Ca

d) None

Correct Answer - C

Answer- C. Infiltrating ductal Ca

Most breast cancers in men are ductal carcinomas.

314. Pressure in laparoscopy is

a) 10-12 mmHg

b) 12-14 mmHg

c) 14-16 mmHg

d) 16-18 mmHg

Correct Answer - B

Answer- B. 12-14 mmHg

In laparoscopy with standard pressure pneumoperitoneum, the gas pressure is 12-14 mmHg.

315. Most common site of direct hernia

a) Hesselbach's triangle

b) Femoral gland

c) No site predilection

d) None

Correct Answer - A

Answer- A. Hesselbach's triangle

It enters the canal through inguinal triangle of Hesselbach.

Common in elderly

Always acquired

Herniation through posterior wall of the inguinal canal

Globular/round in shape; descends directly forward bulge.

Truss cannot prevent progression of Sliding type of inguinal hernia

316. Lymph drainage is increased from lower limbs by

a) Massasaging

b) Running

c) Cycling

d) Sleeping

Correct Answer - A

Answer- A. Massasaging

In the healthy limb, lymph flow is largely due to intrinsic lymphatic contractility, although this is augmented by exercise, limb movement and external compression (massaging).

Lymphatic pump/suction pump :

1. Skeletal muscle contraction (skeletal muscle pump);
2. Squeezing action of smooth muscle lining the larger lymphatics;
3. Positive intra-abdominal and negative intrathoracic pressure.
4. Therefore, compression of tissues by objects outside the body (e.g., massage of foot) increases lymph flow.

317. Nodule on thyroid with lymphadenopathy

a) Radiation

b) Chemotherapy

c) Excision of nodule

d) Total thyroidectomy + MRND

Correct Answer - D

Answer- D. Total thyroidectomy + MRND

Total Thyroidectomy is the treatment of choice for patients with MTC because of high incidence of multicentricity.

In patients with palpable cervical nodes or involved central neck nodes, ipsilateral or bilateral modified radical neck dissection is recommended.

318. Treatment of contaminated wound of leg

a) Debridement and antibiotics

b) Hyperbaric oxygen

c) Amputation

d) None

Correct Answer - A

Answer- A. Debridement and antibiotics

- After debridement, wound is reassessed and further management depends on the type of wound.
 1. If it is small and clean Primary closure can be done
 2. If it is large and clean Coverage procedure (skin graft/muscle pedicle graft) should be done.
 3. If it is still contaminated - Daily dressing and debridement is done till the wound is clean.

319. Most important diagnostic feature of congenital hypertrophic pyloric stenosis

a) Metabolic alkalosis

b) Non bilious vomiting

c) Jaundice

d) Fever

Correct Answer - B

Answer- B. Non bilious vomiting

metabolik alkalosis also occurs, non-bilious vomiting is the most important feature of CHPS.

320. Criteria for viability of muscle are all except

a) Colour

b) Intact fascia

c) Contractability

d) Bleeding when cut

Correct Answer - B

Answer- B. Intact fascia

Non viable muscle can be identified by 4cs -

- Color ? Consistency
- Contraction, and ? Circulation (bleeding on cut)

321. Gall stone impacted causing intestinal obstruction

a) Raynods pentad

b) Hepatitis

c) Gallstone ileus

d) Obstructive jaundice

Correct Answer - C

Answer- C. Gallstone ileus

Gallstone ileus refers to mechanical intestinal obstruction resulting from the passage of a large gallstone into the bowel lumen.

The stone enters the duodenum through a cholecystoenteric fistula.

The site of obstruction by the impacted Gall stones is usually the terminal end of the ileum provided that the more proximal small bowel is of normal caliber.

322. A middle aged male complains of ache and numbness and sensed of fatigus over his calf muscles that develops on exercise and is relieved on rest; this condition is not associated with

a) Smoking

b) Hypocalcemia

c) Peripheral arterial disease

d) Hypertension and diabetes

Correct Answer - B

Answer- B. Hypocalcemia

- Hyperlipidemia
- Diabetes
- Hypertension
- Cigarette smoking
- Alcohol, lipoprotein (a)
- Chlamydia pneumoniae
- Physical inactivity
- Herpes virus
- CMV infection

323. Seton used in fistula in ano is

a) Draining seton

b) Cutting seton

c) Dissolving seton

d) None

Correct Answer - B

Answer- B. Cutting seton

seton (Tight seton) : Made up of silk/prolene/monofilament nylon and used in fistula in ano

It promotes slow transection of external sphincter muscle as a result of pressure necrosis with minimum separation of ds. cut a fistula.

324. Multiple air fluid levels in X-ray of abdomen is seen in

a) Hollow viscera perforation

b) Pyoperitoneum

c) Intestinal obstruction

d) None

Correct Answer - C

Answer- C. Intestinal obstruction

The obstruction may be due to adhesion, hernia, neoplasm, foreign body etc.

A normal person has on average 4 air fluid levels. Most of them are seen in the colon.

For the diagnosis of small intestinal obstruction, we should see more than 2 air fluid levels among the dilated loops of small bowel.

325. Blunt trauma chest, first step in management after initial resuscitation is

a) CT scan

b) Angiography

c) X-ray chest

d) USG

Correct Answer - C

Answer- C. X-ray chest

First investigation of choice in any type of chest injury is chest X-ray.

326. Hemorrhage after thyroidectomy is due to

a) External carotid artery

b) Internal carotid artery

c) Superior thyroid artery

d) Inferior thyroid artery

Correct Answer - C

Answer C. Superior thyroid artery

Is usually due to slipping of ligature on the superior thyroid artery. Hematomas may cause airway compromise and must be evacuated immediately.

327. True about blind loop syndrome, all except

a) Syndrome of bacterial overgrowth

b) Steatorrhea, megaloblastic anemia & deficiency of fat soluble vitamins

c) Surgery is not indicated

d) ¹⁴C-xylose or ¹⁴C-cholyglycine breath tests are indirect tests for bacterial overgrowth

Correct Answer - C

Answer- C. Surgery is not indicated

Features

- Diarrhea
- Steatorrhea
- Megaloblastic anemia (vit. B12 deficiency)
- Weight loss
- Abdominal pain
- Fat soluble vitamin deficiency

Treatment

- Parenteral vit. B1, therapy

Broad spectrum antibiotics :

1. Tetracycline or co-amoxyclav
2. Cephalexin + metronidazole
3. Chloremphenical

328. % of malignancy in duct ectasia is

a) No risk

b) 1.5:1

c) 7:1

d) 10:1

Correct Answer - A

Answer- A. No risk

Duct ectasia

Cysts

Apocrine metaplasia

Apocrine metaplasia

Mild hyperplasia

A denosis

Fibroadenoma (without atypia)

No increased risk for cancer

329. Recurrent anal fistula, most appropriate investigation is

a) Endorectal US

b) Colonoscopy

c) MRI

d) Proctoscopy

Correct Answer - C

Answer- C. MRI

MRI is most accurate investigation for determining presence and course of recurrent anal fistulae.

330. Anal fissure diagnosed by

a) TRUS

b) Colonoscopy

c) Clinical examination

d) Ba enema

Correct Answer - C

Answer- C. Colonoscopy

Anal fissure is a linear ulcer of the lower half of the anal canal, thus can be diagnosed by visually inspecting the anal verge with gentle separation of the gluteal cleft.

The history is typical of pain and bleeding with defecation

331. 70 yr old female with bleeding from proximal colon

a) Colitis

b) Polyp

c) Diverticulitis

d) Ca colon

Correct Answer - D

Answer- D. Ca colon

Bleeding per rectum in old age suggests the diagnosis of colorectal carcinoma.

Symptoms of colorectal carcinoma are non-specific and generally develop when the cancer is locally advanced.

Symptoms vary with the anatomic location of the tumor.

Abd. pain

Anemia (microcytic hypochromic anemia indicative of iron def.)

Fatigue, palpitation and even angina pectoris

Mass in right iliac fossa

A cecal carcinoma can act as lead point in intussusception

332. A 27 year old patient presented with left sided abdominal pain 6 hours after RTA. He was hemodynamically stable and FAST positive. CT scan showed grade III splenic injury. What will be appropriate treatment

a) Splenectomy

b) Splenorrhaphy

c) Splenic artery embolization

d) Conservative management

Correct Answer - D

Answer- D. Conservative management

"In early reports, most investigators expressed extreme caution regarding nonoperative management of grades III and IV, even with hemodynamic stability. As experience has accumulated, most feel comfortable with observing stable grade III injuries, and many have begun observing grade IV and V injuries". --Sabiston

333. Retraction ball seen in

a) Burns

b) Acute pancreatitis

c) Diffuse axonal injury

d) Tracheobronchial injury

Correct Answer - C

Answer- C. Diffuse axonal injury

At the distal tip of the amputated axon there is often an enlarged ball shaped collection of cytoplasm termed a 'retraction ball'.

Axonal retraction balls- The Hallmark of Diffuse Axonal Injury.

334. Prophylactic thyroidectomy is indicated in

a) Hashimoto thyroiditis

b) MEN type 2

c) Riedel thyroiditis

d) De-Quervain's thyroiditis

Correct Answer - B

Answer- B. MEN type 2

- MEN type 2 syndrome consists of medullary carcinoma thyroid, for patients in low to high-risk groups, prophylactic thyroidectomy is recommended by age 5.
- Prophylactic thyroidectomy is indicated in **MEN 2B** syndrome.
- Medullary thyroid carcinoma (MTC) can be inherited as **familial MTC, MEN 2A** or **MEN 2B** syndromes.
- These conditions are autosomal dominant and occur due to **RET proto-oncogene mutation**.
- Individuals with RET mutation are very likely to develop MTC at a younger age. Once the mutation is confirmed, it is advised to undergo prophylactic thyroidectomy.

335. Prophylactic Thyroidectomy for MEN 2 is recommended at age of

a) 5 years

b) Before 1 year

c) When detected

d) Any time

Correct Answer - A

Answer- A. 5 years

MEN type 2 syndrome consists of medullary carcinoma thyroid, for patients in low to high risk groups, prophylactic thyroidectomy is recommended by age 5.

336. Cleft palate is ideally repaired at

a) 5 month of age

b) 1 year of age

c) Before going to school

d) 6-8 years of age

Correct Answer - B

Answer- B. 1 year of age

Timing of Repair of Cleft Palate

- According to Sabiston - before 12 months
- According to Schwartz - at 9 to 12 months of age
- According to Bailey & Love - between 6 and 18 months

337. Radiofrequency ablation is

- a) Derived from AC current
- b) Used to separate fascial planes during surgery
- c) Uses microwave
- d) Used for hemostasis

Correct Answer - A

Answer- A. Derived from AC current

Radiofrequency ablation is a medical procedure in which part of the electrical conduction system of the heart, tumor or other dysfunctional tissue is ablated using the heat generation from high frequency alternating current (in the range of 350-500 KHz).

338. Malignant melanoma false is

a) Radiosensitive

b) Surgery is the treatment of choice

c) Acral lentiginous has worst prognosis

d) Treatment is wide local excision

Correct Answer - A

Answer- A. Radiosensitive

- Melanoma are among the most radioresistant tumors.
- There are 4 common type of melanoma (these are in order of decreasing frequency)
 1. Superficial spreading type (most common)
 2. Nodular
 3. Lentigo maligna
 4. Acral lentiginous (least common)
- Wide local excision of the primary tumor is the management of choice.

[Ref Sabiston IV/Ye p. 742; Schwartz 10th/e p. 488, 490; Harrison 17th/e p. 541; Chandrasoma Taylor 3rd/e p. 895]

339. DVT not common causes

a) Prolonged immobilization

b) Extensive pelvic sx of > 30 minutes

c) Obesity

d) Age less than 40

Correct Answer - D

Answer- D. Age less than 40

A) Venous Thrombosis

- .. Inherited : Factor V Leiden (Leiden factor), antithrombin III deficiency, Protein S deficiency, Protein C deficiency.
- ?. Acquired : Old age, immobilization, prolonged bed rest, major surgery (e.g orthopaedics hip surgery), major trauma, pregnancy and puerperium, obesity, infection.

B) Both arterial and venous thrombosis

- .. Inherited : Homocystinuria/homocystinemia, dysfibrinogenemia.
- ?. Acquired : Malignancy, antiphospholipid syndrome (lupus anticoagulant), hormonal therapy (estrogen component of DCPs), polycythemia, PNH, DIC.

340. Fogarty's catheter is used for

a) Embolization

b) Embolectomy

c) Radiofrequency ablation

d) Angiography

Correct Answer - B

Answer- B. Embolectomy

- Fogarty's catheter is an embolectomy catheter indicated for the removal of fresh, soft emboli and thrombi from vessels in the arterial system.
- The Fogarty embolectomy catheter has been found useful in minimizing blood loss in large surgical procedures about the hip and pelvis. Its utility lies in the ability to achieve temporary intraluminal occlusion of the common iliac artery while the proposed surgical procedure is being carried out.

341. Choledochal cyst is dilatation of

a) Gall bladder

b) CBD

c) Hepatic duct

d) Bile duct

Correct Answer - D

Answer- D. Bile duct

A choledochal cyst is an isolated or combined congenital dilatation of the extrahepatic or intrahepatic biliary tree.

342. False about retroperitoneal fibrosis is

- a) Ureter is most commonly involved
- b) More common in females
- c) Primary idiopathic form is called ormond's disease
- d) Corticosteroids are mainstay of treatment

Correct Answer - B

Answer- B. More common in females

RETROPERITONEAL FIBROSIS (ORMOND'S DISEASE)

RPF is an uncommon inflammatory condition characterized by proliferation of fibrous tissue in the retroperitoneum.

The major structure involved are-

- 1. Ureter - Most commonly involved
- 2. Aorta
- 3. Inferior venacava
- Corticosteroids, with or without surgery, are the mainstay of medical therapy.

343. Most commonly affected in ormond's disease

a) Aorta

b) IVC

c) Ureter

d) Gonadal vessels

Correct Answer - C

Answer- C. Ureter

The major structure involved are-

1. Ureter - Most commonly involved
2. Aorta
3. Inferior venacava

344. Mucocele of gall bladder, false statement is

- a) Complication of gall stones
- b) Treatment is early cholecystectomy
- c) Obstruction at neck of gall bladder
- d) Gall bladder is never palpable

Correct Answer - D

Answer- D. Gall bladder is never palpable

It is one of the complications of Gall stones.

Caused due to obstruction of the stone at the neck of the bladder.

The t/t is early cholecystectomy.

345. Investigation of choice for 74 yr old male patient scanty bleeding per rectum irregular bowel habits

a) Sigmoidoscopy

b) Barium enema

c) Colonoscopy

d) Barium meal follow through

Correct Answer - B

Answer- B. Barium enema

The clinical features suggest diagnosis of diverticulosis.

They are mainly found in the colon (mainly the left side of colon) with sigmoid colon being the most common site.

Colonic diverticulosis is best diagnosed by Barium enema.

346. Obstruction and dilatation of large intestine in absence of any mechanical obstruction

a) Ogilvie syndrome

b) Hirschsprung disease

c) Chagas disease

d) None

Correct Answer - A

Answer- A. Ogilvie syndrome

Ogilvie syndrome, or acute colonic pseudo-obstruction (ACPO), is a clinical disorder with the signs, symptoms, and radiographic appearance of an acute large bowel obstruction with no evidence of actual physical cause of the obstruction.

347. Thyroid nodule increased radioisotope uptake IOC is

a) Biopsy

b) Thyroid scan

c) FNAC

d) None

Correct Answer - C

Answer- C. FNAC

isotope scanning a thyroid nodule can be 'hot, 'warm' or 'cold'.
FNAC is the investigation of choice for solitary thyroid nodule.

348. What is intussuscepiens

a) The entire complex of intussusception

b) The entering layer

c) The outer layer

d) The process of reducing the intussusception

Correct Answer - C

Answer- C. The outer layer

An intussusception is composed of three parts :

- The entering or inner tube - intussusceptum
- The returning or middle tube
- The sheath or outer tube - intussuscepiens

349. Gum tumor with 5 cm in dimension and contralateral lymph node enlargement of 2 cm. There is no distant metasis. The stage of tumor :

a) T3N2M0

b) T2N2M0

c) T1N2Mo

d) T3N3M0

Correct Answer - A

Answer- A. T3N2M0

TNM STAGING OF ORAL CARCINOMA

Primary tumor, as follows:

- T0 - No primary tumor
- Tis - Carcinoma in situ
- T1 - Tumor 2 cm or smaller
- T2 - Tumor 4 cm or smaller
- T3 - Tumor larger than 4 cm
- T4 - Tumor larger than 4 cm and deep invasion to muscle, bone, or deep structures (eg, antrum)

Lymphatic node involvement, as follows:

- N0: No regional lymph node metastasis
- N1: Metastasis in a single ipsilateral lymph node
- N2a: Metastasis in a single ipsilateral lymph node >3 cm but not > 6 cm
- N2b: Metastasis in multiple ipsilateral lymph nodes, none >6 cm in greatest dimension
- N2c: Metastasis in bilateral or contralateral lymph nodes, none >6

cm in greatest dimension

- N3: Metastasis in any lymph node >6 cm

Tumor metastasis(M), as follows:

- M0 - No metastasis
- M1 - Metastasis noted

Staging

Stage I : T1, N0, M0.

Stage II : T2, N0, M0.

Stage III :

- T3, N0, M0
- T1, T2, T3, N1, M0

Stage IV :

- T4, N0, M0
- Any T, N2 or N3, M0
- Any T, any N, any M

350. Most common cause of duodenal obstruction in adults

a) Lymphoma

b) Ca pancreas

c) Ca liver

d) Ca gall bladder

Correct Answer - B

Answer- B. Ca pancreas

Most common cause of duodenal obstruction (gastric outlet obstruction) in adults → Peptic ulcer disease.

Most common cause of gastric outlet obstruction → Pyloric stenosis

Most common cancer causing duodenal obstruction → Pancreatic cancer.

**351. Case of diagnosed cholecystitis
presentation acute pain sharp going to
the back diagnosis**

a) Acute pancreatitis

b) Cholecystitis

c) Appendicitis

d) Aortic aneurysm

Correct Answer - A

Answer- A. Acute pancreatitis

Clinical features-

- Acute severe, refractory, upper abdominal pain radiating to back
- Some patients may gain relief by sitting or leaning forwards
- Icterus can be caused by biliary obstruction in gallstone pancreatitis
- Grey turner's sign – bluish discolouration of the flanks
- Cullen's sign – bluish discoloration around umbilicus
- Fox sign – discoloration below inguinal ligament
- Shock, acute renal failure, ARDS, MODS
- Left sided pleural effusion

352. Man presented with acute abdomen, when man was put in knee chest position helped to relieve the pain what might be the cause.

a) Acute pancreatitis

b) Cholecystitis

c) Superior mesenteric artery ischemia

d) Renal

Correct Answer - A

Answer- A. Acute pancreatitis

Acute severe, refractory, upper abdominal pain radiating to back

Some patients may gain relief by sitting or leaning forwards

Icterus can be caused by biliary obstruction in gallstone pancreatitis

Grey turner's sign – bluish discoloration of the flanks

Cullen's sign – bluish discoloration around umbilicus

Fox sign – discoloration below inguinal ligament

Shock, acute renal failure, ARDS, MODS

Left sided pleural effusion

**353. Man gunshot wound in thorax chest tube
1900 ml blood, 200 ml of blood lost per
hr. next step**

a) Blood transfusion

b) Thoracotomy

c) PPV

d) FFP

Correct Answer - B

Answer- B. Thoracotomy

Initial drainage of more than 1500 ml blood or on going hemorrhage of more than 200 ml/hr over 3-4 hours is generally considered an indication for thoracotomy.

354. Most common cause of acute abdomen in young girl

a) Acute appendicitis

b) ovarian torsion

c) Mitzschmerz

d) Renal colic

Correct Answer - A

Answer- A. Acute appendicitis

Most common cause of acute abdomen in young women is acute appendicitis.

Other causes are intestinal obstruction, diverticulitis, adnexal torsion, ovarian cyst rupture/hemorrhage, PID, endometriosis and dysmenorrhea.

355. Decubitus ulcer is

a) Venous ulcer

b) Wet gangrene

c) Trophic ulcer

d) Post thrombotic ulcer

Correct Answer - C

Answer- C. Trophic ulcer

Trophic ulcers are neurogenic ulcers which are caused by various factors such as impairment of nutrition of the tissues, inadequate blood supply and neurological deficit.

356. Lateral border of tongue carcinoma after resection

a) Chemotherapy

b) Radiotherapy

c) Observation

d) Neck dissection

Correct Answer - D

Answer- D. Neck dissection

If regional lymphnodes are involved- Modified radical neck dissection or selective neck dissection is done.

Indications for postoperative radiation therapy include evidence of perineural or angiolymphatic spread or positive nodal disease.

357. Maximum weight reduction is by which surgery

a) BPD

b) Roux en Y gastric bypass

c) Sleeve gastrectomy

d) Gastric banding

Correct Answer - A

Answer- A. BPD

Mixed procedures

1. Gastric bypass (Roux en Y gastric bypass)
 2. Sleeve gastrectomy with duodenal snitch
 3. Implantable gastric stimulation
- In general malabsorptive procedures lead to more weight loss than restrictive procedures however morbidity risks are greater.
 - Studies have shown that it is maximum with Biliopancreatic diversion (BPD).

358. Most common organism associated with breast abscess

a) Streptococcus

b) Staphylococcus aureus

c) Klebsiella

d) None

Correct Answer - B

Answer- B. Staphylococcus aureus

- Staphylococcus aureus is the most common cause of breast abscess.
- Most are caused by S. aureus and, if hospital-acquired, are likely to be penicillin-resistant.
- Staphylococcus aureus causes the clotting of milk in the blocked duct and multiply. Duct initially gets blocked by epithelial debris or by the retracted nipple.

359. All is true about skull fracture except

a) Puppess rule gives the sequence of fracture

b) Pond fracture is a mild depressed fracture

c) Fissured fracture is most common

d) Skull fractures are due to traction

Correct Answer - B

Answer- B. Pond fracture is a mild depressed fracture

Types of Skull fracture-

1. Linear or fissured fracture: are the most common skull fractures.
2. Depressed Fracture
3. Comminuted fracture
4. Pond or indented fracture- This is a simple dent of the skull, occurring only in skull of infants, for eg. in oblique bullet wounds.
5. Gutter fractures
6. Ring or foramen fractures

Puppe's rule

- It help to assess the chronological order in which fracture were formed, since later fractures will typically stop at previously formed ones.

360. Cecum forms the posterior wall of which hernia

a) Sliding hernia

b) Rolling hernia

c) Incisional hernia

d) Hiatus hernia

Correct Answer - A

Answer- A. Sliding hernia

Sliding hernia is defined as any hernia in which part of the sac (usually the posterior) is formed by the wall of a viscus.

Cecum is involved on the right side and sigmoid colon is involved on left side.

It should be clearly understood that the caecum, appendix or part of colon wholly within a hernial sac does not constitute a sliding hernia (The viscera must form a wall of the sac to be termed as sliding hernia).

[Ref: Bailey & Love 26th/e p. 956]

361. In last decade, duodenal ulcer and its morbidity is reduced due to

a) Life style modification

b) Eradication of H pylori

c) Proton pump inhibitors

d) None

Correct Answer - C

Answer- C. Proton pump inhibitors

In last decades, with the introduction of proton pump inhibitors and increased knowledge of perforated peptic ulcer (PPU) etiology the incidence of PPU has reportedly decreased in western countries.

362. Posterior duodenal ulcer is related to

a) Gastroduodenal artery

b) Splenic artery

c) Left gastric Artery

d) Sup mesentric artery

Correct Answer - A

Answer- A. Gastroduodenal artery

Gastroduodenal artery is the most common artery involved in duodenal ulcer haemorrhage.

Also remember

Peptic ulcer is the most common cause of massive upper gastrointestinal bleed (Duodenal ulcers > Gastric ulcer)

363. Postion in surgery for pilonidal sinus

a) Sim's

b) Tredelenberg

c) Lithotomy

d) Jack knife

Correct Answer - D

Answer- D. Jack knife

For most procedures, patient is placed in prone jack knife position with slight trendelenburg.

Jack knife position

An anatomical position in which the patient is placed on the stomach with the hips flexed and the knees bent at a 90° angle and the arm outstretched in front of the patient.

364. Length of flexible sigmoidoscope

a) 30 cm

b) 40 cm

c) 60 cm

d) 70 cm

Correct Answer - C

Answer- C. 60 cm

The length of rigid sigmoidoscope is 25 cm, where as flexible sigmoidoscope are 60 cm long.

[Ref Bailey & Love 25th/e p.1221; www.medicinenet.com]

365. Hernia common in children

a) Umbilical

b) Bockdelac

c) Morgagni

d) Inguinal

Correct Answer - A

Answer- A. Umbilical

"Congenital umbilical hernias represent the most common abdominal wall defect in infant and children".

The incidence of umbilical hernias is 5-10% in white children and may be as high as 25-50% in black children.

366. Gangrene not caused by

a) Frost bite

b) Burger's disease

c) Varicose veins

d) Atherosclerosis

Correct Answer - C

Answer- C. Varicose veins

Important causes of gangrene

- Diabetes
- PVD (Buerger's disease)
- Trauma
- Obesity
- Atherosclerosis
- Raynaud's disease
- Frostbite

367. Bilateral breast carcinoma

a) Invasive lobular

b) Infiltrative ductal

c) Ductal ca in situ

d) None

Correct Answer - A

Answer- A. Invasive lobular

Lobular carcinoma (invasive) is frequently bilateral.

Histologic hallmark : pattern of single infiltrating tumor cells often only one cell in width or in loose clusters or sheets.

Signet ring cells common. Lobular carcinoma have a different pattern of metastasis compared to other breast cancers.

368. Drainage of cervical abscess is an example of -

a) Clean contaminated wound

b) Clean uncontaminated wound

c) Unclean uncontaminated wound

d) Dirty infected wound

Correct Answer - D

Answer- D. Dirty infected wound

Class IV: This class of wound is considered dirty-contaminated. These include wounds that have been exposed to fecal material. Cervical drainage abscess is an example of Class IV wound.

369. Most common location of ectopic salivary gland is -

a) Cervical lymph nodes

b) Anterior mediastinum

c) Posterior triangle

d) Parathyroid gland

Correct Answer - A

Answer- A. Cervical lymph nodes

Salivary gland heterotopia is where salivary gland acini cells are present in an abnormal location without any duct system.

The most common location is the cervical lymph nodes.

Other reported sites of heterotopic salivary gland tissue are the middle ear, parathyroid glands, thyroid gland, pituitary gland, cerebellar pontine angle, soft tissue medial to sternocleidomastoid, stomach, rectum and vulva

370. All of the following are paraneoplastic syndromes for renal cell carcinoma except -

a) Fever

b) Anaemia

c) Amyloidosis

d) Acanthosis Nigricans

Correct Answer - D

Answer- D. Acanthosis Nigricans

Hypertension

Abnormal liver function (Stauffers syndrome ie non metastatic hepatic dysfunction)

Hypercalcemia

Neuromyopathy

Amyloidosis

Increased ESR (MC paraneoplastic syndrome)

Dysfibrinogenemia

Galactorrhoea

Feminization and masculinization

371. ESWL is contraindicated in which of the following stones -

a) Cysteine stones

b) Oxalate Stones

c) Urate stones

d) Phosphate stones

Correct Answer - A

Answer- A. Cysteine stones

Contraindications for ESWL -

1. Uncorrected Bleeding disorder
2. Cysteine stones
3. Weight greater than 300 pounds
4. Pregnancy
5. Cardiac Pacemaker
6. Severe Orthopaedic deformity
7. UTI
8. Severe renal Failure

372.

Traumatic optic neuropathy due to closed head trauma commonly affects which part of optic nerve -

a) Optic canal

b) Intra ocular part

c) Intracranial part

d) Optic tract

Correct Answer - A

Answer- A. Optic canal

Indirect optic nerve injury

- Studies have shown that forces applied to the frontal bone and malar eminences are transferred and concentrated in the area near the optic canal. The tight adherence of the optic nerve's dural sheath to the periosteum within the optic canal is also thought to contribute to this segment of the nerve being extremely susceptible to the deformative stresses of the skull bones. Such injury leads to ischemic injury to the retinal ganglion cells within the optic canal.

373. All of the following are medical uses of erythropoietin except -

a) Treatment of anaemia associated with renal disease

b) Chemotherapy induced anemia

c) Anaemia Associated with Crohn's Disease

d) Megaloblastic Anaemis

Correct Answer - D

Answer- D. Megaloblastic Anaemis

Uses of erythropoetin

- Anaemia of renal failure.
- Anaemia associated with chemotherapy for diseases like myelodysplasia.
- Anaemia associated with inflammatory bowel disease.

374.

Which of the following is the most conservative neck dissection -

a) Supraomohyoid neck dissection

b) Radical neck dissection

c) Modified radical neck dissection

d) All are conservative

Correct Answer - A

Answer- A. Supraomohyoid neck dissection

Selective neck dissection - Preservation of any of the levels I through V during neck dissection is known as Selective neck dissection - The principle behind preservation of certain nodal groups is that specific primary sites preferentially drain their lymphatics in a predictable pattern. Types of SND include the supraomohyoid neck dissection, the lateral neck dissection, and the posterolateral neck dissection.

375. Which of the following is most malignant tumor?

a) Glioblastoma Multiforme

b) Meningioma

c) Osteochondroma

d) Giant cell tumor

Correct Answer - A

Answer- A. Glioblastoma Multiforme

Primary Brain Tumours

1. Gliomas (43%).

a. Astrocytomas are the commonest type. They are usually malignant.

Grade I – Cystic

Grade II – Diffuse

Grade III – Anaplastic

Grade IV – Glioblastoma multiforme (MC)

2. Meningiomas (18%)

3. Schwannoma (8%)

4. Pituitary tumors (12%)

5. Craniopharyngiomas (5%)

6. Blood vessel tumors (2%)

Other tumors

- They are pineal region tumors, pituitary adenomas, craniopharyngiomas, choroid plexus tumors, etc.

376. Most tissue reaction is seen with

a) Plain Catgut

b) Polydiaxonone

c) Silk

d) Chromic catgut

Correct Answer - C

Answer- C. Silk

Reaction to catgut depends on the stage of absorption and is mainly histocytic in type. Nonabsorbable sutures are encapsulated by a rim of connective tissue, while near the suture histocytes, giant cells and lymphocytes are found. This is most marked with silk and cotton, less so with Dacron, and least with nylon and wire.

377.

Supraomohyoid dissection is a type of -

- a) Selective neck dissection
- b) Modified radical neck dissection
- c) Radical neck dissection
- d) Posterolateral dissection

Correct Answer - A

Answer- A. Selective neck dissection

Selective neck dissection - Preservation of any of the levels I through V during neck dissection is known as Selective neck dissection - The principle behind preservation of certain nodal groups is that specific primary sites preferentially drain their lymphatics in a predictable pattern. Types of SND include the supraomohyoid neck dissection, the lateral neck dissection, and the posterolateral neck dissection.

378. Polydioxanone suture is normally absorbed in

a) 2 weeks

b) 4 weeks

c) 6 weeks

d) 6 months

Correct Answer - D

Answer- D. 6 months

Retains 70% of its original tensile strength at 2 weeks, 50% at 4 weeks, and 25% at 6 weeks.

Prolonged dermal support for at least 6 months has been associated with decreased scar spreading

379. Alagille syndrome- all of the following are true except -

a) Mutation in JAG 1 And Notch2 gene are seen

b) Can Cause Autoimmune hepatitis

c) Autosomal Recessive Disease

d) Valvular anomalies of heart seen

Correct Answer - C

Answer C. Autosomal Recessive Disease

Autosomal dominant disease

JAG 1 and NOTCH 2 mutation

Affects the liver and Heart

Heart

Pulmonary stenosis

Tetralogy of Fallot

VSD

Overriding aorta

380. Which of the following is an absorbable suture

a) Polyglactin

b) Silk

c) Polyester

d) Ethilon

Correct Answer - A

Answer- A. Polyglactin

Absorbable sutures-

1. Catgut
2. Polyglactin
3. Polyglyconate
4. Polyglycolic acid
5. Polydioxanone
6. Poliglecaprone

381. Which is the investigation of choice for staging of a lower limb sarcoma ?

a) MRI

b) CT Scan

c) PET Scan

d) PET CT

Correct Answer - A

Answer- A. MRI

MRI : Investigation of choice for soft tissue sarcomas in extremities.

CT SCAN : Investigation of choice for retroperitoneal sarcomas.

382. All of the following are true about the bare area of the liver except

- a) Infection can spread from the abdominal to thoracic cavity at this area
- b) It is not a site of portocaval anastomosis
- c) Formed by the reflections of coronary ligaments
- d) It is triangular in shape

Correct Answer - B

Answer- B. It is not a site of portocaval anastomosis

The coronary ligaments represent reflections of the visceral peritoneum covering the liver onto the diaphragm. As such, between the two layers of the coronary ligament lies the bare area of the liver, and is attached to the diaphragm by areolar tissue.

The bare area of the liver is still covered by Glisson's capsule, the fibrous capsule that sheathes the entire liver.

Bare area is a site of portocaval anastomoses

383. All of the following are premalignant conditions except -

a) Bowen's Disease

b) Senile Keratosis

c) Xeroderma Pigmentosum

d) Pyoderma Gangrenosum

Correct Answer - D

Answer- D. Pyoderma Gangrenosum

Bowen's Disease

Lupus vulgaris

Actinic Keratosis

Long standing chronic ulcer (e.g. marjolin's ulcers)

Xeroderma pigmentosum

Following burn, venous ulcer, old scar etc.

Senile Keratosis

384. Early stage of non small cell lung cancer can be treated by

a) Surgical resection

b) Surgical resection with adjuvant chemotherapy

c) Radiotherapy

d) Immunotherapy

Correct Answer - C

Answer- C. Radiotherapy

Cystoscopy is endoscopy of the urinary bladder via the urethra. It is carried out with a cystoscope.

385. Chimeric chemotherapy is being investigated for the treatment of which malignancy ?

a) Leukemia

b) Renal Cell Carcinoma

c) CA Pancreas

d) Glioblastoma Multiforme

Correct Answer - A

Answer- A. Leukemia

- Artificial T cell receptors (also known as chimeric T cell receptors, chimeric immunoreceptors, chimeric antigen receptors (CARs)) are engineered receptors, which graft an arbitrary specificity onto an immune effector cell. Typically, these receptors are used to graft the specificity of a monoclonal antibody onto a T cell.
- Two CAR-T therapies have been granted three total FDA approval for the treatment of patients with hematologic malignancies.
- The most advanced data to date concern CAR T therapies for the treatment of patients with multiple myeloma and chronic lymphocytic leukemia.
- Among the first studies investigating anti-CD19 CAR T therapeutic efficacy was a case report treating a patient with CLL.

386. Anterior Mediastinal nodes are included in which level of lymphnodes -

a) I

b) III

c) V

d) VII

Correct Answer - D

Answer- D. VII

Levels of neck lymphnodes

- Level I, submental and submandibular group
- Level II, upper jugular group
- Level III, middle jugular group
- Level IV, lower jugular group
- Level V, posterior triangle group
- Level VI, anterior compartment.
- Level VII, anterior and superior mediastinal

387. In Celiac artery compression syndrome which structure is the main cause of compression -

a) Median Arcuate Ligament

b) Rectus Sheath

c) Deep Inferior Epigastric artery

d) Lacunar Ligament

Correct Answer - A

Answer- A. Median Arcuate Ligament

Median arcuate ligament syndrome (MALS, also known as celiac artery compression syndrome, celiac axis syndrome, celiac trunk compression syndrome or Dunbar syndrome) is a condition characterized by abdominal pain attributed to compression of the celiac artery and possibly the celiac ganglia by the median arcuate ligament.

The abdominal pain may be related to meals, may be accompanied by weight loss, and may be associated with an abdominal bruit heard by a clinician. It is also called celiac artery compression syndrome.

388. The Bipolar cautery is preferred over monopolar cautery in the following surgeries except

a) Hand Surgery

b) Surgery around Penis

c) Surgery of the Hip

d) Surgery around the face

Correct Answer - C

Answer- C. Surgery of the Hip

Bipolar cautery preferred in :

- Hand surgery
- Surgery around appendages like penis
- Surgery around the face

389. All of the following are true about Nissen Fundoplication except

a) It is done for GERD

b) Reinforcement is done only in the anterior half

c) Upper part of stomach is plicated around the lower esophagus

d) It is done for paraesophageal hiatus hernia

Correct Answer - B

Answer- B. Reinforcement is done only in the anterior half

In a fundoplication, the gastric fundus (upper part) of the stomach is wrapped, or plicated, around the lower end of the esophagus and stitched in place, reinforcing the closing function of the lower esophageal sphincter. The esophageal hiatus is also narrowed down by sutures to prevent or treat concurrent hiatal hernia, in which the fundus slides up through the enlarged esophageal hiatus of the diaphragm.

In a Nissen fundoplication, also called a complete fundoplication, the fundus is wrapped all the way 360 degrees around the esophagus.

390. A 65 year old male presenting with acute pancreatitis is now having refractory hypoxia. The X RAY of chest would show

a) Bilateral infiltrates

b) Pneumatoceles

c) Ground glass appearances

d) Hilar lymphadenopathy

Correct Answer - A

Answer- A. Bilateral infiltrates

Systemic complications of pancreatitis

Hypovolemic shock

DIC

ARDS

Diabetes

391. Which Is False about stress urinary incontinence -

- a) More common in men
- b) It occurs during increased abdominal pressure
- c) It is due to weakening of pelvic floor muscles
- d) Prostate surgery may be a cause

Correct Answer - A

Answer- A. More common in men

Leaking urine upon sudden increase in abdominal pressure.

It is most common type in women.

Causes are

- Weakening of pelvic floor muscles / urethra / sphincter muscles.
- BPH, CA prostate or prostate surgery.

392. Which of the following types of shock will usually have warm peripheral extremities ?

a) Hypovolemic Shock

b) Neurogenic Shock

c) Cardiogenic Shock

d) Anaphylactic Shock

Correct Answer - B

Answer- B. Neurogenic Shock

Bradycardia

Hypothermia

Loss of sympathetic tone --> arterious & venous vasodilation

Warm and dry skin (the heart rate slows down, as well as warm, dry, and flushed skin due to venous pooling secondary to loss of vascular tone)

Others all shock have cold extremities (anaphylactic, cardiogenic and hypovolemic)

393. Antibiotic prophylaxis is best given -

a) 1 day before surgery

b) 2 hours before surgery

c) Before the time of incision

d) Only postoperatively

Correct Answer - C

Answer- C. Before the time of incision

About prophylactic antibiotics points to know are ? By definition prophylaxis is limited to the time prior to and during the operative procedure.

be most effective the prophylactic antibiotic agent should be administered intravenously before the incision is made so that the tissue levels are present at the time the wound is created and exposed to the bacterial contamination.

394. Which of the following is a feature of crush syndrome -

a) Hypokalemia

b) Hypercalcemia

c) Myoglobinuria

d) Hypophosphatemia

Correct Answer - C

Answer- C. Myoglobinuria

Features of crush syndrome :

- Hyperkalemia
- Hypocalcemia
- Hyperphosphatemia
- Hyperuricemia
- Lactic acidosis
- Myoglobinuria
- Increased BUN & creatinine.

395. A young male presents with a testicular mass on the right side. The AFP is elevated while the HCG is normal. The most appropriate next step is

a) Biopsy

b) USG

c) Orchiectomy

d) Wait and Watch

Correct Answer - B

Answer- B

A painless testicular mass is pathognomic for a testicular malignancy. USG of the testis is indicated whenever a testicular malignancy is considered and for persistent or painful testicular swelling.

396. Crush Syndrome is associated with all of the following features except -

a) Hypercalcemia

b) Hyperkalemia

c) Increased serum creatinine

d) Myoglobinuria

Correct Answer - A

Answer- A. Hypercalcemia

Features of crush syndrome :

- Hyperkalemia
- Hypocalcemia
- Hyperphosphatemia
- Hyperuricemia
- Lactic acidosis
- Myoglobinuria
- Increased BUN & creatinine.

397. A 45 year old male presenting with penile cancer extending upto the glans penis is treated with

a) Partial Penectomy with 2 cm margin

b) Circumcision

c) Partial penectomy with Inguinal nodes exploration

d) Partial penectomy with 4 cm margin

Correct Answer - A

Answer- A. Partial Penectomy with 2 cm margin

The goal of t/t in invasive penile carcinomas is complete excision with adequate margins:

- a) For lesion involving the prepuce
 - Simple circumcision is effective.
- b) For lesion of glans or distal shaft
- Partial penectomy with a 2 cm margin (less aggressive surgical resections such as Mohs micrographic surgery and local excisions directed at penile preservation can be done).
- c) For lesion involving the proximal shaft or when partial penectomy results in a penile stump of insufficient length for sexual function or directing the urinary stream
- Total penectomy with perineal urethrostomy

398. Which of the following stones are common with infection ?

a) Struvite

b) Xanthine Stones

c) Cysteine stones

d) Calcium Oxalate stones

Correct Answer - A

Answer- A. Struvite

Calcium phosphate can be combined with ammonium and magnesium to form the triple phosphate calculus ie Calcium ammonium magnesium phosphate also k/a struvite stones.

Smooth and dirty white and solitary.

Seen in alkaline urine esp with proteus infection which split urea to ammonia.

399. A 45 year old male is diagnosed with carcinoma penis. The surgeon must look out for which lymphnodes

a) Para aortic

b) External iliac

c) Internal Iliac

d) Inguinal

Correct Answer - D

Answer- D. Inguinal

More than 50% of patients present with enlarged inguinal lymph nodes (but half of these are reactive enlargement d/t sepsis).

The presence and the extent of metastasis to the inguinal region is the most important prognostic factor for survival in patients with Ca Penis.

400. High Flying prostate is a sign of -

a) Extraperitoneal Bladder rupture

b) Intraperitoneal Bladder Rupture

c) Membranous Urethral Injury

d) Bulbar Urethral Injury

Correct Answer - C

Answer- C. Membranous Urethral Injury

- The prostate is attached to pubis by puboprostatic ligament and disruption of the puboprostatic ligament with a complete rupture of the urethra can lead to a **floating prostate—Vermooten's sign (high fly prostate)**.
- Based on ascending urethrogram, posterior urethral injury is classified as (McCallum-Colapinto classification).
 1. Type I: Elongation of posterior urethra, but intact
 2. Type II: Prostate "plucked off" membranous urethra with extravasation of urine above sphincter only—**Floating prostate — Vermooten's sign**
 3. Type III: Total disruption of the urethra with extravasation of urine both above and below the sphincter.

401. Which of the following is false about undescended testis ?

- a) More common on the right side
- b) Hormonal therapy is effective
- c) Increased risk of malignancy
- d) Secondary sexual characteristics are normal

Correct Answer - B

Answer- B. Hormonal therapy is effective

- In undescended testis - the testes is arrested in some part of its path to the scrotum.
- In Ectopic testis - the testis is abnormally placed outside its path.
- Retractable testis - in infancy 80% of inapparent testis are retractile testis and require no t/t.
- Approx 70-77% of cryptorchid testes will spontaneously descend, usually by 3 months of age.
- More common in preterm, small for gestational age, LBW & twin neonates.
- More common on Rt. Side
- Secondary sexual characterstics are normal

402. RPLND and Chemotherapy may be used in management of

a) Non seminomatous Germ cell tumours of testis

b) Non germ cell tumours

c) Seminomatous Germ cell tumours

d) Lymphoma testis

Correct Answer - A

Answer- A. Non seminomatous Germ cell tumours of testis

RPLND retroperitoneal lymph node dissection

Extra gonadal Germ cell tumors Infrequently GCTs arise from an extra gonadal site. They have poor prognosis. They are treated by chemotherapy.

403. BPH involves -

a) Central zone

b) Peripheral zone

c) Transitional zone

d) Prostate capsule

Correct Answer - C

Answer- C. Transitional zone

Carcinoma of prostate arises most commonly in the peripheral zone

Benign prostatic hyperplasia originates in the transition zone

BPH typically affects the submucous group of glands in the transitional zone, forming a nodular enlargement.

Eventually, this overgrowth compresses the PZ glands into a false capsule and causes the appearance of the typical 'lateral'lobes.

Ref- Bailey and Love Volume-1/ Edition 27th

404. Which of the following is a tumour marker for bladder cancer ?

a) AFP

b) CEA

c) Bladder surface protein

d) Nuclear Matrix protein 22

Correct Answer - D

Answer- D. Nuclear Matrix protein 22

Tumour markers in CA Bladder

- Nuclear matrix protein 22
- BTA
- TRAK

405. A 45 year old lawyer presents with pain in the abdomen more so in the epigastric region that worsens with eating spicy food and is relieved by bending forward. Complications of the above mentioned condition could be all except

a) Perforation

b) Bleeding

c) Gastric Outlet Obstruction

d) Splenic Vein Thrombosis

Correct Answer - D

Ans. - D. Splenic Vein Thrombosis

- Bleeding, perforation and gastric outlet obstruction are the complications of peptic ulcer.
- Perforation: This allows stomach contents to escape into the peritoneum, causing peritonitis. It is more common in duodenal than in gastric ulcers.
- Gastric outlet obstruction: The most common cause is an ulcer near the pylorus, but occasional cases are due to antral cancer or adult hypertrophic pyloric stenosis.
- Bleeding

406. Prostate cancer that is limited to the capsule and not the urethra would be staged as -

a) Tx

b) T1

c) T2

d) T3

Correct Answer - C

Answer- C. T2

7 th AJCC (2010) TNM Staging for CA Prostate	
T: Primary tumor	N: Regional lymph nodes
Tis: Carcinoma in situ (PIN)	N0: No regional LN metastasis
T1a: ≤5% of tissue in resection for benign disease has cancer, normal DRE T1b: >5% of tissue in resection for benign disease has cancer, normal DRE T1c: Tumor identified by needle biopsy (e.g. because of elevated PSA)	N1: Metastasis in a regional LNs (obturator, internal iliac, external iliac, presacral LNs)
	M: Distant metastases
T2a: Tumor involves one half of one lobe but not both lobes T2b: Tumor involves more than one half of one lobe or less T2c: Tumor involves both lobes	M1a: Distant metastasis in non-regional lymph nodes M1b: Distant metastasis to bone M1c: Distant metastasis to other sites
T3a: Extracapsular extension on one or both sides T3b: Seminal vesicle involvement	
T4: Tumor directly extends into bladder neck, sphincter, rectum, levator muscles, or into pelvic sidewall	

407. A 65 year old male presents with CA prostate. The tumour is limited to the capsule and it is palpable on PR examination. The patient is diagnosed as stage T1b. The best treatment would be -

a) Radical prostatectomy

b) Chemotherapy

c) Palliative radiotherapy

d) Orchidectomy

Correct Answer - A

Answer- A. Radical prostatectomy

T1b T1c, T2

Radical prostatectomy or radiotherapy

External beam radiotherapy- T1 or low T2 disease

Brachytherapy- low T1 disease

408. A 55 years old male with a known history of gall stones presents with chief complaints of severe abdominal pain and elevated levels of serum lipase with periumbilical ecchymosis. All of the following are prognostic criteria to predict severity of the condition except

a) Age

b) Serum LDH

c) Base deficit

d) Serum GGT

Correct Answer - D

Answer- D. Serum GGT

Ranson Criteria for Severity of Acute Pancreatitis

At Admission

Age > 55 years
White cell count > $16.0 \times 10^9/L$
Blood glucose > 11 mmol/L
Serum lactate dehydrogenase (LDH) > 350 IU/L
Aspartate transaminase (SGOT) > 250 U/L

During Initial 48 Hours

Hematocrit decrease > 10 percentage points
Blood urea nitrogen (BUN) increase > 1.8 mmol/L as urea
 PtO_2 < 60 mm Hg
Base deficit > 4 mEq/L
Serum calcium < 2.0 mmol/L
Fluid sequestration > 6 L

409. If 90% of jejunum and ileum is removed then all of the following features will be seen except -

a) Steatorrhoea

b) Diarrhoea

c) Weight gain

d) Megaloblastic anemia

Correct Answer - C

Answer- C. Weight gain

Changes seen in Terminal ileal resection

Resection of terminal ileum results in malabsorption of bile salts and Vit. B12 which are normally absorbed in this region

Vit B12 Malabsorption : Megaloblastic anemia

Bile salts malabsorption :- Unabsorbed bile salts escape into colon where they stimulate fluid secretion from the colon, resulting in watery diarrhoea.

Reduction in bile salt pool lead to steatorrhea and malabsorption of fat soluble vitamins (due to malabsorption of fat).

Unabsorbed fatty acids bind with calcium, and thus lead to increased concentration of free oxalates (oxalates bind with calcium normally and therefore escape without intestinal absorption) Free oxalates are absorbed. Increased conc. of body oxalates lead to oxalate kidney stones.

410. Most common location of breast cancer is

a) Lower inner quadrant

b) Nipple

c) Upper inner quadrant

d) Upper outer quadrant

Correct Answer - D

Answer- D. Upper outer quadrant

Breast cancer is found most frequently in the upper outer quadrant.
Least frequently in lower inner quadrant.

411. A 22 year old woman comes with a non progressive mass in a left breast since 6 months. There are no associated symptoms. Examination shows a mobile mass not attached to the overlying skin or underlying tissue. The possible diagnosis is

a) Fibroadenoma

b) Cystasarcoma Phylloides

c) Scirrhouc Carcinoma

d) Fibroadenosis

Correct Answer - A

Answer- A. Fibroadenoma

Clinically, they present as firm masses that are easily movable. (MOUSE IN THE BREAST) They slide easily under the examining fingers and may be lobulated or smooth.

Mammography is of little help in discriminating between cysts and fibroadenomas; however, ultrasonography can readily distinguish between them because each has specific characteristics.

FNA biopsy can also be used to confirm the imaging findings

**412. Perihepatic fibrosis occurring in Fitz
Hugh Curtis Syndrome is due to -**

a) Pelvic Inflammatory Disease

b) Bile Duct Injury

c) Chronic Alcoholism

d) Viral Hepatitis

Correct Answer - A

Answer- A. Pelvic Inflammatory Disease

It is thought to result from direct intraperitoneal spread of infection towards the perihepatic region from initial pelvic inflammation/infection

Trichomonas vaginalis, Ureaplasma urealyticum and Mycoplasma hominis may also cause FHCS.

413. 45 year old female underwent modified radical mastectomy with axillary clearance for CA breast. After surgery she could not lift her arm above head. Which nerve is likely to be injured ?

a) Intercostobrachial nerve

b) Long thoracic nerve of Bell

c) Nerve to latissimus Dorsi

d) Lateral Pectoral nerve

Correct Answer - B

Answer- B. Long thoracic nerve of Bell

Overhead abduction is caused by :-

- .. Serratus anterior : supplied by long thoracic nerve.
- ?. Trapezius : supplied by spinal accessory nerve.

414. Which is the most common type of male breast cancer?

a) Infiltrating Ductal Carcinoma

b) Lobular Carcinoma

c) Mucinous Carcinoma

d) Colloid Carcinoma

Correct Answer - A

Answer- A. Infiltrating Ductal Carcinoma

- It tends to present as a lump and is most commonly an infiltrating ductal carcinoma.
- More than 90% of cases are infiltrating duct carcinoma, about 10% are ductal carcinoma in situ (DCIS).
- The known predisposing causes include gynecomastia and excess endogenous or exogenous estrogen.

415. A 25 year old male is receiving conservative management for an appendicular mass since 3 days now presents with a rising pulse rate, tachycardia and fever. The mode of management must be -

a) Ochsner sherren regimen

b) Continue conservative management

c) Proceed to laparotomy and appendicectomy

d) Intravenous antibiotics

Correct Answer - C

Answer- C. Proceed to laparotomy and appendicectomy

If an appendix mass is present and the condition of the patient is satisfactory, the standard treatment is the conservative Ochsner–Sherren regimen.

10-20% need emergency operation due to spreading infection.

416. CA Breast may locally spread to all of the following muscles except

a) Pectoralis Major

b) Pectoralis Minor

c) Latissimus Dorsi

d) Serratus Anterior

Correct Answer - C

Answer- C. Latissimus Dorsi

latissimus Dorsi is used for breast reconstruction and may rarely be involved in CA Breast local Spread'

- Muscles involved in breast cancer
- .. Pectoral muscles : Pectoralis major, Pectoralis minor.
- 2. Muscles of chest wall : Intercostal muscles, serratus anterior

417. Under what guidelines is treatment started for a patient presenting with appendicular mass on CT Scan ?

a) Ochsner Sherren Regimen

b) Conservative management and discharge

c) Immediate Laprotomy

d) Kocher's Regimen

Correct Answer - A

Answer- A. Ochsner Sherren Regimen

Ochsner Sherren regimen is the expectant management given to a patient with an appendix mass. It is expectant because it is expected that the symptoms and signs the patient presented with will improve during the course of the management and the patient may later be scheduled for elective/interval appendicectomy.

418. Which of the following is true about menetrier's disease

- a) It is premalignant condition
- b) There is increased gastric acid secretion
- c) Atrophied mucosal folds are seen
- d) Affects the stomach and small intestines

Correct Answer - A

Answer- A. It is premalignant condition

Ménétrier disease is a rare, acquired, premalignant disease of the stomach characterized by massive gastric folds, excessive mucous production with resultant protein loss, and little or no acid production. The disorder is associated with excessive secretion of transforming growth factor alpha (TGF- α).

419. A patient presents with difficulty with swallowing liquids but not solids. The best investigation to make a diagnosis is

a) Endoscopy

b) Endoscopic ultrasound

c) Manometry

d) PET CT

Correct Answer - C

Answer- C. Manometry

H/O of dysphagia with more to liquids than solids suggests achalasia cardia. In all other obstructive causes of esophagus, dysphagia for solids is seen first

Manometry is used for diagnosis.

420. Spontaneous esophageal rupture is most common in

a) Below the diaphragmatic aperture

b) Pharyngoesophageal junction

c) Above the diaphragmatic aperture

d) At the crossing of the arch of aorta

Correct Answer - C

Answer C. Above the diaphragmatic aperture

Instrumental perforation is common in the pharynx or distal esophagus.

Spontaneous rupture may occur just above the diaphragm in the posterolateral wall of the esophagus.

421. Aneurysmal dilation of the small bowel is seen in

a) Small bowel Lymphoma

b) Gall Stone Ileus

c) Duodenal Atresia

d) Sjogrens Syndrome

Correct Answer - A

Answer- A. Small bowel Lymphoma

Aneurysmal dilatation: 30%, it occurs due to replacement of muscularis by tumour or infiltration of myenteric nerve plexus
Despite the extensive involvement, small bowel obstruction is uncommon because of lack of desmoplastic reaction, and perforation is rare

422. Which is the main contraindication for a liver biopsy?

a) Thrombocytopenia

b) Hemangioma

c) Ascites

d) All

Correct Answer - D

Answer- D

Contraindications for liver biopsy include the following:

- Increased prothrombin time (PT), international normalized ratio (INR) greater than 1.6
- Thrombocytopenia, platelet count lower than 60,000/ μ L
- Ascites (transjugular route preferred) ^[10]
- Difficult body habitus (transjugular route preferred)
- Suspected hemangioma
- Suspected echinococcal infection
- Uncooperative patient

423. Treatment of choice of mucinous carcinoma of Gall Bladder confined to the lamina propria is -

a) Simple cholecystectomy

b) Extended cholecystectomy

c) Cholecystectomy with wedge resection of liver

d) Chemotherapy only

Correct Answer - A

Answer- A. Simple cholecystectomy

Treatment-

- Stage I and II - simple cholecystectomy
- Stage III – cholecystectomy + adjacent hepatic resection (atleast 2cm depth) + regional lymphadenectomy
- Poor prognosis

424. All of the following are principles of negative pressure wound therapy except

a) Stabilization of wound environment

b) Clearance of infection

c) Macrodeformation of the wound

d) Decreased edema

Correct Answer - B

Answer- B. Clearance of infection

Four primary effects of NPWT on wound healing:

- Macro-deformation - drawing the wound edges together leading to contraction.
- Stabilisation of the wound environment-ensuring it is protected from outside microorganisms in a warm and moist environment.
- Reduced oedema - with removal of soft tissue exudates.
- Micro-deformation- leading to cellular proliferation on the wound surface.

425. Most common precipitant of Raynaud's phenomenon is

a) Exposure to cold

b) Exposure to heat

c) Psychosocial triggers

d) Exertion

Correct Answer - A

Answer- A. Exposure to cold

Is ds of young women (F:M ratio is 5:1)

Commonly the upper limbs are affected specially the fingers (the thumb is generally escaped)

Exposure to cold is main trigger

426. Nigro Regimen is used for -

a) Anal Carcinoma

b) Rectal Carcinoma

c) Sigmoid Colon Carcinoma

d) Duodenal Carcinoma

Correct Answer - A

Answer- A. Anal Carcinoma

Nigro regimen refers to combined chemotherapy and radiotherapy for primary treatment of malignant tumors of the anal canal.

427. The investigation of choice for dysphagia is

a) Endoscopy

b) Manometric Study

c) Ct Scan

d) Barium Swallow

Correct Answer - A

Answer- A. Endoscopy

The investigation of choice in is endoscopy.

Barium swallow is the first investigation.

428. A 54 year old woman is diagnosed as having carcinoma of the renal pelvis of size less than 4 cm without any metastasis. The best treatment option is

a) Partial nephrectomy

b) Radical Nephrectomy

c) Chemotherapy and immunotherapy

d) Palliative Radiotherapy

Correct Answer - A

Answer- A. Partial nephrectomy

Partial nephrectomy is now being used as primary surgical therapy for patients with tumour less than 4 cm in size, earlier Radical nephrectomy was the t/t of choice for tumor of any size.

429. A 35 year old male came with jaundice, palpable mass in the right hypochondrium not associated with pain. The probable diagnosis is -

a) Carcinoma Ampulla of Vater

b) Acute cholecystitis

c) Chronic Cholecystitis

d) Chronic Pancreatitis

Correct Answer - A

Answer- A. Carcinoma Ampulla of Vater

Courvoisier's law states that in the presence of an enlarged gall bladder which is nontender and accompanied with jaundice the cause is unlikely to be gallstones. This is because gall stones are formed over a longer period of time, and this result in a shrunken, fibrotic gall bladder which does not distend easily.

430. A 60 year male presented with jaundice, pale stools, dark urine and mass in the epigastric region. Which of the following diagnosis is unlikely ?

a) Pancreatic cancer

b) Biliary Cancer

c) Periapillary Cancer

d) Chronic Cholecystitis

Correct Answer - D

Answer- D. Chronic Cholecystitis

Chronic cholecystitis is characterized by repeated attacks of pain (biliary colic) that occur when gallstones periodically block the cystic duct.

431. All of the following may lead to a gall bladder carcinoma except -

a) Gall Bladder Polyps

b) Typhoid carriers

c) Exposure to carcinogens like nitrosamine

d) Echinococcus Granulosus Infection

Correct Answer - D

Answer- D. Echinococcus Granulosus Infection

Risk factors for gall bladder

1. Gall stones
2. Adenomatous gall bladder polyps (particularly polyps larger than 10 mm)
3. Calcified (porcelain) gallbladder
4. Choledochal cyst
5. Estrogens
6. Anomalous pancreaticobiliary duct junction
7. Exposure to carcinogens (azotoulene, nitrosamine)
8. Typhoid carriers
9. Sclerosing cholangitis
10. Cholecystoenteric fistula

432. All of the following may lead to pneumatocele formation except

a) Staphylococcal pneumonia

b) Positive pressure ventilation

c) Hydrocarbon inhalation

d) ARDS

Correct Answer - D

Answer-D

- Pneumatocele formation occurs as a sequela to acute pneumonia, commonly caused by *Staphylococcus aureus*. However, pneumatocele formation also occurs with other agents, including *Streptococcus pneumoniae*, *Haemophilus influenzae*, *Escherichia coli*, group A streptococci, *Serratia marcescens*, *Klebsiella pneumoniae*, adenovirus, and tuberculosis.
- Noninfectious etiologies include hydrocarbon ingestion, trauma, and positive pressure ventilation.
- In premature infants with respiratory distress syndrome, pneumatoceles result mostly from ventilator-induced lung injury.

433. Which of the following stoma is formed in Hartman's procedure ?

a) End Colostomy

b) End Iliostomy

c) Loop Iliostomy

d) Caecostomy

Correct Answer - A

Answer- A. End Colostomy

Hartman's procedure

- This is a compromise type of resection in which the rectum and/or sigmoid colon are resected and an end colostomy done. Anastomosis and perineal dissection of the distal rectum and perineum are not done.

434. Most common site of colorectal carcinoma is -

a) Rectum

b) Sigmoid Colon

c) Ascending Colon

d) Descending Colon

Correct Answer - A

Answer- A. Rectum

Rectosigmoid region is the most common site for colorectal carcinoma. Rectum is involved in 38% of cases and sigmoid colon is involved in 21% cases.

435. Which of the following stages of lip carcinoma do not have nodal involvement ?

a) T2N1

b) T3N0

c) T1N1

d) T2N2

Correct Answer - B

Answer- B. T3N0

TNM Staging

Tx	no available information on primary tumour
T0	no evidence of primary tumour
TIS	only carcinoma <i>in-situ</i> on primary sites
T1	<2 cm
T2	2 to 4 cm
T3	>4 cm
T4	>4 cm, involvement of natrum, pterygoid muscles, base of tongue or skin

Mx	Not assessed
M0	No evidence
M1	Distant metastasis present

Nx	Cannot be assessed
N0	No clinical positive nodes
N1	Single, ipsilateral, <3 cm
N2a	Single, ipsilateral, 3-6 cm
N2b	Multiple, ipsilateral, <6 cm
N3a	Single/multiple, ilpsilateral node(s), one more than 6 cm
N3b	bilateral
N3c	contralateral

436. Which of the following is true about Mallory Weiss tear -

a) It is a mucosal tear not extending through the muscle layer

b) It is more common in women than men

c) It is common in young individuals

d) It is associated with achalasia cardia

Correct Answer - A

Answer- A. It is a mucosal tear not extending through the muscle layer

A Mallory -Weiss tear (MWT) is forceful or retching vomiting may produce a longitudinal mucosal tear immediately below squamo columnar junction at the cardia or gastroesophageal junction mainly and also in oesophagus.

Seen in males, alcoholics and pregnant females.

The mean age is more than 60 and 80% are men.

Hyperemesis gravidarum, which is severe morning sickness associated with vomiting and retching in pregnancy, is also a known cause of Mallory-Weiss tear.

437. A 40 year old male presented with a penetrating trauma to chest. He is dyspnoeic with distended neck veins with hypotension and mediastinum is shifted to opposite side. There is a sucking wound over the chest. The most appropriate management would be

a) Insertion of a large bore needle in the 2nd ICS in the mid clavicular line

b) Fluid Resuscitation

c) Starting Inotropic support

d) Endotracheal Intubation

Correct Answer - A

Answer- A. Insertion of a large bore needle in the 2nd ICS in the mid clavicular line

- This is a case of tension pneumothorax.
- Treatment consists of immediate decompression, initially by rapid insertion of a large-bore needle into the second intercostal space in the midclavicular line of the affected hemithorax, and then followed by insertion of a chest tube through the fifth intercostal space in the anterior axillary line.

438. A 40 year old male with chest trauma presents with breathlessness, decreased respiratory sounds on the right side, hyperresonance on percussion and distended neck veins. The possible diagnosis is

a) Tension Pneumothorax

b) Cardiac Tamonade

c) Flail Chest

d) Myocardial Infarction

Correct Answer - A

Answer- A. Tension Pneumothorax

- Tension pneumothorax occurs when air becomes trapped in the pleural space under pressure.
- It develops when a 'one-way valve' air leak occurs either from the lung or through the chest wall.

causes are

- Penetrating chest trauma,
- Blunt chest trauma,
- Iatrogenic lung punctures (e.g. due to subclavian central venepuncture) and
- Mechanical positive-pressure ventilation

Clinical

- Clinical signs and symptoms include dyspnea, tachypnea, hypotension, diaphoresis, and distended neck veins.

439. Which of the following is an indication for thoracotomy in case of hemothorax ?

a) Persistent drainage of 250 ml/hr

b) Total output of 1000ml of blood

c) Falling blood pressure

d) Shift of mediastinum to the opposite side

Correct Answer - A

Answer- A. Persistent drainage of 250 ml/hr

It is classified according to the amount of blood.

Minimal hemothorax 350 ml

Moderate hemothorax 350-1500 ml

Massive hemothorax 1500 ml or more

Total hemorrhagic output exceeds 1500 ml of blood

440. A 55 year old woman presented with history of recurrent episodes of right upper abdominal pain for the last one year. She presented to emergency with history of jaundice and fever for 2 days. On examination, the patient appeared toxic and had a blood pressure of 100/60 mmHg. She was started on intravenous antibiotics. Ultrasound of the abdomen showed presence of stones in the common bile duct. What would be the best treatment option for her -

a) ERCP and bile duct stone extraction

b) Laparoscopic cholecystectomy

c) Open surgery and bile duct stone extraction

d) Lithotripsy

Correct Answer - A

Answer- A. ERCP and bile duct stone extraction

Methods of biliary decompression

a. ERCP with sphincterotomy and stone extraction

- It is the procedure of choice,
- Early endoscopy allows not only diagnosis by cholangiography and direct visualization of the ampulla but also permits biliary decompression by sphincterotomy and stone extraction.

- If the stones cannot be removed, a nasobiliary catheter or stent is inserted to decompress the biliary tract.
 - b. Percutaneous transhepatic route (PTC)
- PTC is performed if
- The endoscopic procedure has failed or not available.
- If the obstruction is more proximal or perihilar.
- If there is a stricture in a biliary enteric anastomosis.
 - c. Surgical biliary decompression

441. Rigler's sign is suggestive of -

a) Pneumothorax

b) Pneumoperitoneum

c) Peritonitis

d) Hemothorax

Correct Answer - B

Answer- B. Pneumoperitoneum

Both sides of bowel become visible because of free gas on an abdominal x-ray. This is known as Rigler's Sign.

442. A 70 year old male complaining of per rectal bleeding was diagnosed of having rectal/anorectal cancer. The distal margin of the tumor was 5 cm from the anal verge the treatment of choice would be -

a) Palliative Radiotherapy

b) Abdominoperineal resection

c) Low anterior resection

d) Local Excision

Correct Answer - C

Answer- C. Low anterior resection

Surgeries

- Pre-operative neo-adjuvant radiotherapy in resectable rectal cancer reduces the incidence of local recurrence
- Adjuvant chemotherapy improves survival in node-positive cases
- Anterior(low) resection: sphincter saving procedure, mid rectum
- Proximal 2/3rd of rectum (lesions 6cms above the dentate line/2 or more cms above anal canal)
- Well differentiated tumour size tumour
- T1/T2, NO tumours
- Recto sigmoid tumors and upper third rectal tumors :High anterior resection (rectum and mesorectum are taken to a margin 5cm distal to the tumour and colorectal anastomosis is performed)
- Tumours in the middle and lower thirds of rectum: complete removal of rectum and mesorectum (TME-total mesorectal excision)

- Abdomino perineal resection(Mike's procedure)- Lower rectum
- Hartmann's procedure – for elderly and unstable patients who cannot withstand long procedure of APR
- Colonoscopy is always performed either before (for synchronous tumours) or within a few months (for metachronous tumours) of surgical resection for tumour detection

443. All of the following are true about Hirschsprung disease except -

- a) Absence of Ganglion cells in the involved segment
- b) Swenson, Duhamel and Soave are surgical procedures for this condition
- c) Mainly presents in infancy
- d) The non peristaltic affected segment is dilated

Correct Answer - D

Answer- D. The non peristaltic affected segment is dilated

In Hirschsprung's disease the absence of ganglion cells gives rise to a contracted non peristaltic segment with a dilated hypertrophied segment of normal colon above it.

Almost all cases present in infancy and childhood. Approximately half are diagnosed in the neonatal period and most of the remainder are diagnosed in early childhood.

In the newborn period, most common symptoms are abdominal distention and failure to pass meconium.

Older patients may experience chronic or intermittent constipation. Occasionally, infants may present with a dramatic complication of Hirschsprung's disease called enterocolitis.

Surgery is always required. The basic principle is removal of most or all of the aganglionic segment and anastomosing the ganglionic bowel to the rectum

444. Most common cause of goiter in India is

a) Diffuse Endemic Goitre

b) Papillary Carcinoma

c) Toxic Multinodular Goitre

d) Hashimoto's Thyroiditis

Correct Answer - A

Answer- A. Diffuse Endemic Goitre

The lack of the iodine leads to decreased synthesis of thyroid hormones and a compensatory increase in TSH, which in turn leads to follicular cell hypertrophy and hyperplasia and goitrous enlargement - Diffuse hyperplastic goiter.

Mostly patients are euthyroid.

445. All of the following are clinical features suggestive of trachea-esophagal fistula except -

a) Choking and Coughing

b) Regurgitation

c) Cyanosis

d) Fever

Correct Answer - D

Answer- D. Fever

Repeated episodes of coughing, choking and cyanosis occur on feeding with TOF.

446. In Subtotal Thyroidectomy, What is true

- a) Removal of one lobe and isthmus
- b) Removal of both lobes leaving behind 6-8 grams of tissue
- c) Removal of entire thyroid with cervical lymphnodes
- d) Removal of 1 lobe with isthmus and the second lobe partially

Correct Answer - B

Answer- B. Removal of both lobes leaving behind 6-8 grams of tissue

Subtotal thyroidectomy—Removal of majority of both lobes leaving behind 4-5 grams (equivalent to the size of a normal thyroid gland) of thyroid tissue on one or both sides—this used to be the most common operation for multinodular goitre.

447. Most important presenting feature of periampullary carcinoma is -

a) Jaundice

b) Pain

c) Weight Loss

d) Palpable Mass

Correct Answer - A

Answer- A

- Hallmark of presentation of periampullary carcinoma is obstructive Jaundice.
- Jaundice secondary to obstruction of the distal bile duct is the most common symptom that draws attention to ampullary and pancreatic head tumors.
- It is characteristically painless jaundice but may be associated with nausea and epigastric discomfort.

448. All of the following are surgical options in management of esophageal carcinoma except -

a) Ivor Lewis Approach

b) Mckeown's Approach

c) Transhiatal removal

d) Sistrunk operation

Correct Answer - D

Answer- D. Sistrunk operation

Ivor lewis operation is subtotal esophagectomy done for Ca esophagus in lower third of esophagus

In transhiatal esophagectomy (THE) Esophagus is removed through the diaphragmatic hiatus by making incisions in the abdomen and the neck.

McKeowns Surgery- 3 Incision Approach

449. A 65 year old female presents with a swelling in the neck diagnosed as a solitary thyroid nodule. The patient is investigated and a scan shows increased uptake of iodine. Serum T3 and T4 are elevated . Most probabe diagnosis is

a) Benign Colloid Nodule

b) Toxic Adenoma

c) Follicular adenoma

d) Toxic Multinodular goitre

Correct Answer - B

Answer- B. Toxic Adenoma

Elevated thyroid hormone levels with a hyperfunctioning nodule is suggestive of a toxic adenoma.

A cold nodule is more likely to be malignant than a hot nodule.

450. Chronic hemolytic anaemia is associated with which of the following -

a) Brown Pigment stone of the gall bladder

b) Black Pigment stone of the gall bladder

c) Uric acid Renal Calculus

d) Intestinal Obstruction

Correct Answer - B

Answer- B. Black Pigment stone of the gall bladder

Hemolysis causes black pigment stone of gall bladder.

Chronic hemolytic states (eg. hereditary spherocytosis, sickle cell disease).

451. All of the following is true about heart transplantation except -

a) Immunosuppression is started preoperatively

b) It is only orthotopic and not heterotopic

c) A Beating heart cadaver/donor is needed

d) High Pulmonary arterial resistance is a contra indication

Correct Answer - B

Answer- B. It is only orthotopic and not heterotopic

Types of transplant :

- Heterotopic
- Orthotopic
- A typical heart transplantation begins when a suitable donor heart is identified. The heart comes from a recently deceased or brain dead donor, also called a beating heart cadaver.

452. Thyroid nodule in a 65 year old male who is clinically euthyroid is most likely to be

a) Follicular adenoma

b) Follicular Carcinoma

c) Thyroid Cyst

d) Multinodular goiter

Correct Answer - A

Answer- A. Follicular adenoma

Most common solitary thyroid nodule is benign colloid nodule.
2nd most common cause of solitary thyroid nodule is follicular adenoma.

453. In case of polytrauma with multiple injuries to the chest, neck and abdomen, highest priority is given to

a) Stabilization of cervical spine

b) Staring of koids

c) Vasopressors

d) Assesing disability

Correct Answer - A

Answer- A. Stabilization of cervical spine

1. Primary survey - it should be done first when any polytrauma patient presents in the following order :

- 1.1 Airway maintenance with cervical spine protection
- 1.2 Breathing and ventilation
- 1.3 Circulation with hemorrhage control
- 1.4 Disability/Neurologic assessment
- 1.5 Exposure and environmental control

2. Secondary survey - complete history and examination.

454. A child presented with blunt abdominal trauma, the first investigation to be done is -

a) USG

b) CT Scan

c) Complete Hemogram

d) Abdominal Xray

Correct Answer - A

Answer- A. USG

U/S is the investigation of choice in both stable as well as unstable patients.

455. Which of the following precancerous conditions if treated would not lead to cancer

a) Cervical intraepithelial Neoplasia

b) Ductal carcinoma in situ of breast

c) Lobular Carcinoma in situ of breast

d) Vaginal intraepithelial Neoplasia

Correct Answer - A

Answer- A. Cervical intraepithelial Neoplasia

- The cancers, which have well known precancerous condition, can be diagnosed and treated at pre-cancerous stage to prevent the development of cancer : -
 - .. Cervix → GIN
 - ∴ Colon → Polyp

456. Vacuum assisted closure is contraindicated in which of the following conditions -

a) Chronic osteomyelitis

b) Large amount of necrotic tissue with eschar

c) Abdominal wound

d) Surgical wound dehiscence

Correct Answer - B

Answer- B. Large amount of necrotic tissue with eschar

Negative-pressure wound therapy (NPWT), also known as a vacuum dressing or V.A.C. dressing ("vacuum assisted closure"), is a therapeutic technique using a suction dressing to remove excess exudation and promote healing in acute or chronic wounds and second- and third-degree burns.

Contraindications for NPWT use

1. Malignancy in the wound
2. Untreated Osteomyelitis
3. Non enteric and unexplored fistulas
4. Necrotic tissue with eschar present
5. Exposed blood vessels, anastomotic sites, organs and nerves in the periwound area (must avoid direct foam contact with these structures)

457. All of the following are causes of Urothelial Carcinomas Except -

a) Smoking

b) Industrial solvents

c) Exposure to thorotrast

d) Alcohol consumption

Correct Answer - D

Answer- D. Alcohol consumption

Industrial dyes or solvents

Excessive analgesic intake,

Balkan nephropathy, and

Those exposed to Thorotrast, (a contrast agent previously used for retrograde pyelography)

458. Most common site for Cystic Hygroma is

-

a) Lower third of neck

b) Overlying the parotid gland

c) Along the Zygomatic Prominence

d) Post auricular

Correct Answer - A

Answer- A. Lower third of the neck

- Most cystic hygromas involve the lymphatic jugular sacs and present in the posterior neck region.
- The other common sites are the axillary, mediastinum, inguinal, and retroperitoneal regions, and approximately 50% of them present at birth.
- Cystic hygromas usually present as soft cystic masses that distort the surrounding anatomy, including the airway, which can result in acute airway obstruction.

459. The size beyond which the risk of rupture of an abdominal aneurysm significantly increases is greater than -

a) 5.5 cm

b) 6 cm

c) 6.5 cm

d) 7 cm

Correct Answer - A

Answer- A. 5.5 cm

High risk AAA

Endovascular aneurysmal repair (EVAR)

AAA repair- ≥ 5.5 cm/ > 5 cm females

Symptomatic aneurysm

460. True about MALToma is

a) They are secondary gastric lymphomas

b) H. Pylori infection is a risk factor

c) Commonly seen in gastric cardia

d) They are a type of T cell lymphoma

Correct Answer - B

Answer- B. H. Pylori infection is a risk factor

Stomach is the most common extranodal site of lymphoma.

It is of two types - Primary & Secondary

Most of the primary lymphomas (about 60%) arise in MALT (mucosa associated lymphoid tissue). MALT is usually associated with chronic H. pylori infection. So low-grade MALT lymphomas are thought to arise because of chronic H. pylori infection. These low grade lymphomas may later on degenerate to high grade lymphomas.

mucosa associated lymphoid tissue. It is usually primary GI lymphoma (4% of gastric lymphoma); of non-Hodgkin's B cell type.

461. A cystic mass at the base of umbilical cord in a neonate could be

a) Allantoic Cyst

b) Meckel's Diverticulum

c) Ventral mesogastrium

d) Cystic Hygroma

Correct Answer - A

Answer- A. Allantoic Cyst

Allantoic cysts are a type of true cyst of the umbilical cord.

The allantois forms from the part of the fetal yolk sac that eventually becomes the primitive hindgut (the cloaca). The cloaca divides into the hindgut posteriorly and the urogenital sinus anteriorly.

462. Chvostek sign could be seen after -

a) Gastrojejunostomy

b) Total thyroidectomy

c) Subtotal Thyroidectomy

d) Hellers Cardiomyotomy

Correct Answer - B

Answer- B. Total thyroidectomy

- Chvostek's sign refers to the contraction of the ipsilateral facial muscles on percussion of the facial nerve below the zygoma.
- It is due to hypocalcemia and one common cause of hypocalcemia is a complication during thyroidectomies.
- The parathyroid gland produces a parathyroid hormone (PTH), and resection can lead to a decrease in PTH levels.
- PTH regulates calcium levels in the body; hence, a reduction in its serum level will lead to hypocalcemia.
- So, among the most common postoperative complications following thyroid surgery is hypocalcemia.

463. An Incisional wound heals by

a) Primary Healing

b) Secondary Healing

c) Delayed primary Healing

d) Reepithelization

Correct Answer - A

Answer- A. Primary Healing

Primary Healing

- Primary wound healing or healing by first intention occurs within hours of repairing a full-thickness surgical incision. This surgical insult results in the mortality of a minimal number of cellular constituents.

464. A full thickness wound that is not sutured heals by

a) Primary Healing

b) Secondary Healing

c) Delayed primary Healing

d) Reepithelization

Correct Answer - B

Answer- B. Secondary Healing

Secondary Healing

- A third type of healing is known as secondary healing or healing by secondary intention. In this type of healing, a full-thickness wound is allowed to close and heal. Secondary healing results in an inflammatory response that is more intense than with primary wound healing. In addition, a larger quantity of granulomatous tissue is fabricated because of the need for wound closure. Secondary healing results in pronounced contraction of wounds.

465. Food can commonly get obstructed in the esophagus at all of the following locations except

a) Crossing of left bronchus

b) Crossing of arch of aorta

c) Diaphragmatic aperture

d) Crossing of the hemiazygous vein

Correct Answer - D

Answer- D. Crossing of the hemiazygous vein

Pharyngoesophageal junction -6 inches 9

466. Reactionary Hemorrhage occurs due to -

a) Dislodgement of clot

b) Infection

c) Damage to a blood vessel

d) Pressure necrosis

Correct Answer - A

Answer- A. Dislodgement of clot

Dislodgement of clot

Ligature slip

Normolisation of BP and
vasodilation

467. All of the following is true about congenital hypertrophic pyloric stenosis except

a) Ramstedt Pyloromyotomy is the treatment of choice

b) Non Bilious vomiting is seen

c) Metabolic acidosis occurs

d) More common in males

Correct Answer - C

Answer- C. Metabolic acidosis occurs

Characteristically the first born male child is affected.

The condition is most commonly seen at 4 weeks after birth ranging from the 3rd week to on rare occasion

Non-bilious vomiting, becoming increasingly projectile, occurs over several days to weeks

Infants develop a metabolic alkalosis with severe depletion of potassium and chloride ions.

Treatment- Surgery : Fredet-Ramstedt pyloromyotomy. (In it the pyloric mass is split without cutting the mucosa)

468. Which of the following is correct management of abdominal compartment syndrome

a) Antihypertensives

b) Urgent Opening of the surgical wound and application of the Bogota bag

c) Urgent Fasciotomy

d) Wait and monitor for 24 hours

Correct Answer - B

Answer- B. Urgent Opening of the surgical wound and application of the Bogota bag

Abdominal compartment syndrome is a surgical emergency and treatment includes rapid decompression of the elevated intraabdominal pressure by opening the abdominal wound and performing a temporary closure of the abdominal wall with mesh or a plastic bag. Permanent closure is done 5 to 7 days later when the condition resolves.

469. Transplanted kidney is relocated to which region in the recipient's body ?

a) Retroperitoneal region

b) Lumbar region

c) Epigastrium

d) Beside the dysfunctional Kidney

Correct Answer - A

Answer- A. Retroperitoneal region

The most common location for placing a kidney transplant is in retroperitoneal iliac fossa.

In most cases Kidney is placed retroperitoneally and the iliac arteries and veins are used for perfusion and ureter is transplanted directly into bladder.

470. Claudication due to popliteofemoral incompetence is primary seen in

a) Thigh

b) Calf

c) Buttocks

d) Feet

Correct Answer - B

Answer- B. Calf

Aorta and Common Iliac- Buttocks

Femoral Artery- Thigh

Superficial femoral artery- Calf and popliteal artery

Posterior tibial Artery- Feet

471. Balthazar scoring system is used for?

a) Acute Pancreatitis

b) Acute Appendicitis

c) Acute cholecystitis

d) Cholangitis

Correct Answer - A

Answer- A. Acute Pancreatitis

Balthazar score is used in the CT severity index (CTSI) for grading of acute pancreatitis which has two components.

Using imaging characteristics, Balthazar and associates have established the CT severity index. This index correlates CT findings with the patient's outcome

1) Grading of pancreatitis

- A: Normal pancreas → 0
- B: Enlargement of pancreas → 1
- C: Inflammatory changes → 2
- D: Ill-defined single fluid collection -4 3
- E: Two or more ill-defined fluid collections → 4

2) Pancreatic necrosis

- None → 0
- 30% → 2
- > 30 - 50% 4
- > 50% → 6

472. Triage system used for

a) Burn

b) Earthquack

c) Polytrauma

d) Floods

Correct Answer - C

Answer- C. Polytrauma

The usual principle of "first come, first treated", is not followed in mass emergencies.

Triage consists of rapidly classifying the injured and the likelihood of their survival with prompt medical intervention.

Higher priority is granted to victims whose immediate or long-term prognosis can be dramatically affected by simple intensive care.

473. Ileal obstruction due to round worm obstruction treatment is

- a) Resection with end to end anastomosis
- b) Resection with side to side anastomosis
- c) Enterotomy, removal of worms and primary closure
- d) Diversion

Correct Answer - C

Answer- C. Enterotomy, removal of worms and primary closure

Diversion is the first step in case of colonic obstruction, followed by resection and anastomosis of affected segment and then closure of diversion colostomy at a later date.

Intestinal luminal obstruction such as due to Bezoars or fecoliths of worm intestations are dealt with by enterotomy and removal followed by primary closure.

474. Surgery for perforation due to round worm is

a) Resection with end to end anastomosis

b) Resection with side to side anastomosis

c) Primary closure

d) Diversion

Correct Answer - A

Answer- A. Resection with end to end anastomosis

475. Which is a clean surgery

a) Hernia surgery

b) Gastric surgery

c) Cholecystectomy

d) Rectal surgery

Correct Answer - A

Answer- A. Hernia surgery

Clean Wound (Class I)

- Include those in which no infection is present; only skin microflora potentially contaminate the wound. No hollow viscus is entered. No inflammation
- Examples : Hernia repair, breast biopsy

476. Steroid is injurious to wound when given

a) On 1st day

b) < 2weeks

c) 2-4 weeks

d) > 4 weeks

Correct Answer - B

Answer- B. < 2weeks

Steroids used after first 3 to 4 days post injury do not affect wound healing as severely as when used in immediate post operative period. Delay in use of such drugs for about 2 weeks post injury appears to lesser the wound healing impairment.

477. In surgical patient malnutrition is best assessed by

a) Serum albumin

b) Hb level

c) Mid arm circumference

d) Tricipes skin fold thickness

Correct Answer - A

Answer- A. Serum albumin

Serum albumin is classic method to predict postoperative complications, hospital length of stay, morbidity and mortality and might to be associate to nurtitional status and disease severity.

478. Abbes flap is used for

a) Eyelid

b) Tongue

c) Lip

d) Ear

Correct Answer - C

Answer- C. Lip

Abbe flap, also called lip switch flap, is used for lip reconstruction.

479. In LAHSHAL terminology for cleft lip & cleft palate, LAHSHAL denotes

a) Bilateral cleft palate only

b) Bilateral cleft lip only

c) Bilateral cleft lip & palate

d) No cleft

Correct Answer - C

Answer- C. Bilateral cleft lip & palate

LAHSHAL classification of cleft lip and palate was proposed by Kreins 0.

It is a diagrammatic classification of cleft lip & palate. According to this classification, mouth is divided into six parts.

LAHSHAL code indicates complete cleft with and incomplete cleft with small letter.

480. Post operative abscess treatment of choice

a) Hydration

b) IV antibiotics

c) Image guided aspiration

d) Reexploration

Correct Answer - C

Answer- C. Image guided aspiration

The diagnosis and treatment of intraabdominal abscesses have improved with the advent of imaging techniques such as ultrasonography and CT. These advances have made minimally invasive drainage techniques available; such techniques complement traditional surgical drainage for patients with abdominal abscess cavities.

481. May thurner or cockett syndrome involves

a) Common iliac artery obstruction

b) Internal iliac artery obstruction

c) Internal iliac vein obstruction

d) Left iliac vein compression

Correct Answer - D

Answer- D. Left iliac vein compression

May-Thurner syndrome/cockett syndrome/ilio caval/iliac vein compression syndrome. Occurs due to compression of left iliac vein by overriding right iliac artery.

It results in left iliofemoral deep vein thrombosis.

482. Method of reduction of inguinal hernia

a) Kugel manœuvre

b) Taxis

c) Macvay procedure

d) Stopa's technique

Correct Answer - B

Answer- B. Taxis

Taxis (hernia reduction) was the treatment of choice for incarcerated hernia.

Manual reduction of hernia is known as taxis. Taxis is an archaic term used to describe an attempt at reduction of a hernia that is acutely irreducible (incarcerated).

483. Subclavian steal syndrome is

- a) Reversal of blood flow in the ipsilateral vertebral artery
- b) Reversal of blood flow in the contralateral carotid artery
- c) Reversal of blood flow in the contralateral vertebral artery
- d) B/L reversal of blood flow in vertebral arteries

Correct Answer - A

Answer- A. Reversal of blood flow in the ipsilateral vertebral artery

- Subclavian steal syndrome may occur if the first part of the subclavian artery is occluded. Arm exercise causes syncope because of reversed flow, in the vertebral artery leading to cerebral ischemia.
- It can be treated by angioplasty or surgery and is rare.
- That is the result of an ipsilateral hemodynamically significant lesion of the proximal subclavian artery.

484. Most common cause of acquired AV fistula is

a) Bacterial infection

b) Fungal infection

c) Blunt trauma

d) Penetrating trauma

Correct Answer - D

Answer- D. Penetrating trauma

"Penetrating injuries are the most common cause, but fistulas are sometimes seen after blunt trauma" – CSDT

485. Best approach in thoracic trauma is

- a) Midline sternotomy
- b) Parasternal thoracotomy
- c) Anterolateral thoracotomy
- d) Posterolateral thoracotomy

Correct Answer - C

Answer- C. Anterolateral thoracotomy

left' anterolateral thoracotomy is the best initial operative approach for unstable patients requiring resuscitation or when the location of the intrathoracic injury is unclear.

486. Venous air embolism is most common in which position in surgery

a) Sitting

b) Prone

c) Lateral

d) Lithotomy

Correct Answer - A

Answer- A. Sitting

Venous air embolism is a potential hazard whenever the operative site is above the level of patients heart.

The 'sitting' position and its modification "beach chair" positions are associated with a greater incidence of venous air embolism

487. Fatal exsanguinations occurs mostly in

- a) Closed fracture of femur shaft
- b) Open fracture of femur & tibia
- c) Partial transaction of artery
- d) Complete resection transaction of artery

Correct Answer - C

Answer- C. Partial transaction of artery

"Bleeding is more often exsanguinating after sharp injury and partial vessel transection".

488. Premalignant lesion for carcinoma rectum is

a) Familial polyposis

b) FAP

c) Juvenile polyp

d) Adenomatous polyp

Correct Answer - A

Answer- A. Familial polyposis

Pre cancerous lesions for CA rectum

1. Villous papilloma
2. Adenomas
3. Familial polyposis

489. Most common site for anal fissure is

a) 3 O'clock

b) 6 O'clock

c) 2 O'clock

d) 10 O'clock

Correct Answer - B

Answer- B. 6 O'clock

The vast majority of anal fissures occur in posterior midline.

Fissure in Ano (or Anal fissure)

- Most common site is → mid-line posteriorly
- MC symptom is -4 pain associated with defecation
- Fissure starts proximally at the dentate line

490. Alvarado score consist of

a) Leucopenia

b) Anorexia

c) Diarrhea

d) Periumbilical pain

Correct Answer - B

Answer- B. Anorexia

The most widely used is the Alvarado score. A score of 7 or more is strongly predictive of acute appendicitis.

Alvarado score

Symptoms	Score
Migration of pain	1
Anorexia	1
Nausea & vomiting	1
Signs	
Tenderness in the right lower quadrant	2
Rebound tenderness	1
Elevated temperature	1
Laboratory	
Leucocytosis	2
A shift of white blood cell count to the left	1
Total	10

491. Most common age for intussusception is

a) 0-6 Months

b) 6 Months -3yrs

c) 3-5 Yrs

d) > 5 yrs

Correct Answer - B

Answer- B. 6 Months -3yrs

Intussusception is the telescoping of one portion of the intestine into the other.

It is the most common cause of intestinal obstruction in early childhood (3 months to 6 years)

492. Retrocardiac lucency with air fluid level is seen in

a) Hiatus hernia

b) Distal end esophageal obstruction

c) Eventration of diaphragm

d) None

Correct Answer - A

Answer- A. Hiatus hernia

Hiatus hernia shows retrocardiac lucency with air or an air-fluid level above the diaphragm.

493. Most common site for carcinoid tumor is

a) Esophagus

b) Lung

c) Appendix

d) Ileum

Correct Answer - D

Answer- D

- Historically, the most common site of gastrointestinal (GI) carcinoid tumors was the appendix.
- Currently, however, the most common site of carcinoids in the GI tract is the small intestine (30%), followed by the rectum (19.6%).
- In most studies, the appendix is only the third most common site of GI carcinoids, and in some studies, it is the fourth most common.

494. Most common differential diagnosis for appendicitis in children is

a) Gastroenteritis

b) Mesentric lymphadenopathy

c) Intussusception

d) Meckel's diverticulitis

Correct Answer - B

Answer- B. Mesentric lymphadenopathy

Differential diagnosis of appendicitis in children -

1. Acute gastroenteritis
2. Intussusception
3. Meckel's diverticulitis
4. Mesentric lymphadenitis (MC)
5. Inflammatory bowel disease
6. Constipation
7. Functional pain

495. Abdominal surgery under LA, patient suddenly felt pain due to

a) Liver

b) Gut

c) Parietal peritoneum

d) Visceral peritoneum

Correct Answer - C

Answer- C. Parietal peritoneum

Embryologically parietal peritoneum is derived from the somatopleural layer of the lateral plate mesoderm. Its blood supply and nerve supply are the same as those of the overlying body wall. Because of the somatic innervation, it is pain sensitive." — BDC Anatomy

496. A 55 year male has history of dysphagia with vomiting of undigested food throughout the day, weight loss, emaciated & dehydrated. No mass palpable per abdomen. The modality of treatment is

a) IV total parenteral nutrition

b) Endoscopic dilation

c) IV normal saline

d) pH monitoring

Correct Answer - B

Answer- B. Endoscopic dilation

The symptom & sign complex indicates diagnosis of Achalasia. One of the treatment modalities for achalasia cardia is endoscopic dilation.

497. Hose pipe appearance of intestine is a feature of

a) Crohns disease

b) Malabsorption syndrome

c) Ulcerative colitis

d) Hirsprung disease

Correct Answer - A

Answer- A. Crohns disease

Crohn's disease has a hose pipe appearance.

498. In old age for rectal prolapse palliative surgery in a patient unfit for surgery is

a) Delorme's procedure

b) Well's procedure

c) Thiersch's operation

d) Low anterior resection

Correct Answer - C

Answer- C. Thiersch's operation

Tightening the anus with a variety of prosthetic materials (anal encirclement)-

Anal encirclement procedures generally have been abandoned. Anal encirclement has limited application and is reserved by most surgeons for patients of the highest surgical risk or limited life expectancy because it can be done under local anesthesia. The original Thiersch procedure involved placing a silver wire around the external sphincter within the ischioanal fat. Now synthetic mesh or silicone tubes are used instead of wire. The safety of current anesthetic techniques and the low morbidity and relative functional success of perineal proctectomy have made anal encirclement, for the most part, a procedure of the past.

499. 40 year old male complaints of GERD, on endoscopy shows dysplasia. Treatment

a) Fundoplication

b) Esophageal resection

c) PPI

d) Dietmodification

Correct Answer - B

Answer- B. Esophageal resection

If severe dysplasia or intranural carcinoma is found on mucosal biopsy, an esophageal resection should be done.

500. Renal stones which are laminated and irregular in outline are

a) Uric acid

b) Calcium oxalate

c) Struvite

d) Cystine

Correct Answer - B

Answer- B. Calcium oxalate

Calcium oxalate stones - Usually single, hard (aka Mulberry stone) -

- Dark colored d/t staining with altered blood.
- Spiky.
- On section Wavy concentric laminae.
- There may be secondary phosphate deposit on surface.
- High calcium content.

**501. In a case of perforation peritonitis, emergency lapratomy, 2nd post operative day develops oliguria.
Diagnosis**

a) Severe UTI

b) Fluid retention

c) Dehydration

d) Catheter obstruction

Correct Answer - C

Answer- C. Dehydration

Oliguria may reflect inadequate renal artery perfusion due to hypotension, hypovolemia or low QT. It can also be a sign of intrinsic renal dysfunction.

502. Etiology of bloody discharge from nipple

a) Duct papiloma

b) Breast abscess

c) Fibroadenoma

d) Cyst

Correct Answer - A

Answer- A. Duct papiloma

Table 1: Causes of nipple discharge

Physiologic

Duct abnormalities

- Intraductal papilloma
- Duct ectasia
- Periductal mastitis
- Carcinoma

Galactorrhea

- Hyperprolactinemia
- Hypothyroidism
- Medications: oral contraceptives, cimetidine, verapamil, phenothiazine, metoclopramide, alpha-methyldopa

Conditions that may mimic nipple discharge

- Eczema with drainage
- Paget's disease of the breast
- Nipple adenoma

503. Carcinoma breast is least seen in

a) Superior outer quadrant

b) Inferior outer quadrant

c) Subareolar

d) Lower inner quadrant

Correct Answer - D

Answer- D. Lower inner quadrant

Upper inner → 12 - 15%

Upper outer → = 50%

Lower inner → 3 - 5%

Lower outer → 6 - 10%

Central/areolar → 20%

[Ref Love & Bailey 25th/e p. 840, S. Das 7thie p. 607]

504. Intraoperative sentinel lymph node detection in axilla is done by using

a) Mammography

b) Isosulfan blue dye

c) MRI

d) CT

Correct Answer - B

Answer- B. Isosulfan blue dye

Lymphatic mapping is performed by using isosulfan blue dye, technetium-labelled sulfur colloid albumin or a combination of both.

505. Sentinel lymph node biopsy in carcinoma breast is done if -

a) LN palpable

b) Breast mass but no lymph node palpable

c) Breast lump with palpable axillary node

d) Metastatic CA breast

Correct Answer - B

Answer- B. Breast mass but no lymph node palpable

Axillary nodes if clinically palpable are removed by surgical dissection.

506. Indication for sentinel node biopsy is

a) Non palpable axillary lymph node

b) Palpable axillary lymph node

c) Mass > 5cm

d) Metastasis

Correct Answer - A

Answer- A. Non palpable axillary lymph node

This will be of great significance in early breast carcinomas wherein lymph nodes are not clinically palpable nor detected by investigations such as ultrasound/CT scan of the axilla. . Indication: Early breast cancer with (T1 or T2 No) clinically node negative axilla.

507. Breast conservation surgery is contraindicated in all except -

a) Tumor > 4cm

b) Multicentric tumor

c) Axillary LN involvement

d) Diffuse microcalcifications

Correct Answer - D

Answer- D

Breast conservative surgery

Indications

- Lump < 4 cm
- Clinically negative axillary nodes
- Mammographically detected lesion
- Well-differentiated tumour with low S phase
- Adequate sized breast to allow proper RT to breast
- Breast of adequate size and volume
- Feasibility of axillary dissection and radiotherapy to intact breast

Contraindications

- Tumour > 4 cm
- Positive axillary nodes > N1
- Tumour margin is not free of tumour after breast conservative surgery needs MRM
- Poorly differentiated tumour
- Multicentric tumour
- Earlier breast irradiation
- Tumour/breast size ratio is more (central tumour)
- Tumour beneath the nipple
- Extensive intraductal carcinoma

508. The following are suitable for simple mastectomy except-

a) Pagets disease

b) Fibroadenoma

c) Cystosarcoma phyllodes

d) None

Correct Answer - B

Answer- B. Fibroadenoma

Indications for simple mastectomy

A) Without an axillary procedure

1. Risk-reducing mastectomy
2. Local recurrence in a previously treated breast cancer iii) Malignant phyllodes tumor (cystosarcoma phyllodes)
- b) With concomitant axillary procedure
3. Locally advanced breast cancer (including paget disease)
4. Multifocal breast cancer
5. Extensive ductal carcinoma in situ (DCIC)
6. Patient is unsuitable for breast-conservative approach

509. Which of the following is used in the treatment of well differentiated thyroid carcinoma

a) I131

b) 99m Tc

c) 32p

d) MIBG

Correct Answer - A

Answer- A. I131

I131 is the radioisotope of choice for radiotherapy of thyroid carcinoma and hyperparathyroidism.

510. Treatment for malignant melanoma is

a) Wide excision

b) Radiotherapy

c) Excision

d) Chemotherapy

Correct Answer - A

Answer- A. Wide excision

Management of Malignant Melanoma

- Wide local excision of the primary tumor is the management of choice.
- The recommended margin of resection depends on the thickness of the tumor.

511. Moures sign is seen in

a) Carcinoma

b) Appendicitis

c) Varicose vein

d) Pancreatitis

Correct Answer - A

Answer- A. Carcinoma

"In normal persons, a click is felt when larynx is moved from side to side over vertebral column, this is called laryngeal click (post cricoid crepitus) It is absent in post cricoid carcinoma". — Moure's sign

512. Acute orchitis all are seen except

a) Increased local temperature

b) Decreased blood flow

c) Erythematous scrotum

d) Raised TLC

Correct Answer - B

Answer- B. Decreased blood flow

USG shows increased blood flow in acute stage.

Ischemic orchitis may set in, in late stages resulting in reduced blood flow on USG.

513. All are true about carcinoma penis except

a) Most common type is verrucous

b) Spreads by blood borne metastasis

c) Leads to erosion of artery

d) Slowly progressive

Correct Answer - A

Answer- A. Most common type is verrucous

MC type – SCC

ETIOLOGY-

- Premalignant lesions-
- Genital warts- Bushke- Lowenstein tumour is a giant penile condyloma (verrucous carcinoma of penis)
- Erythroplasia of Queyrat or Paget's disease of penis- precancerous lesion

SPREAD-

- Blood spread is rare
- Death may occur due to erosions of femoral vessels by inguinal LN.
- Slowly progressive

514. In testicular torsion, surgery within how much time can save viability of testis

a) 6 hr

b) 12 hr

c) 24 hr

d) 1 week

Correct Answer - A

Answer- A. 6 hr

"More than 80% testes can be salvaged if surgery is performed within 6 hours".

[Ref Schwartz 9th/e p. 1469]

515. Investigation using dye to find out stone in salivary gland

a) Sialography

b) Mammography

c) MR angiography

d) USG

Correct Answer - A

Answer- A. Sialography

Salivary duct stones & strictures

Chronic sialadenitis

Tumors of salivary glands

**516. ERCP is indicated for the following
except**

a) Distal CBD tumor

b) Hepatic porta tumor

c) Proximal cholangiocarcinoma

d) Gall stone pancreatitis

Correct Answer - C

Answer- C. Proximal cholangiocarcinoma

ERCP is not technically possible in proximal biliary obstructions.

517. Alagille syndrome is

a) Bile duct paucity

b) IHBR dilation

c) PBC

d) PSC

Correct Answer - A

Answer- A. Bile duct paucity

syndromic paucity of interlobular bile ducts (Alagille syndrome) is the most common form of familial intrahepatic cholestasis. Chronic cholestasis affects 95% of patients. Peripheral pulmonary stenosis is observed in approximately 90%. Vertebral arch defects are seen (e.g., butterfly vertebrae, hemivertebrae, and a decrease in the interpedicular distance). Ophthalmologic examination may reveal posterior embryotoxon, retinal pigmentation, and iris strands.

518. Hemorrhagic pancreatitis, bluish discoloration of flank

a) Grey turner sign

b) Cullen sign

c) Trosseue sign

d) None

Correct Answer - A

Answer- A. Grey turner sign

In acute pancreatitis :

- .. Cullen's sign : Ecchymosis (bluish-purple color) around umbilicus (periumbilical area)
- ?. Grey turner's sign : Ecchymosis (bluish-purple color) in flank

519. Complication of chronic pancreatitis include all except-

a) Renal artery thrombosis

b) Pseudocyst

c) Splenic vein thrombosis

d) Fistulae

Correct Answer - A

Answer- A. Renal artery thrombosis

Complications-

- Obstructive jaundice
- Carcinoma of pancreas
- Pseudocysts
- Pancreatic duct leak with ascites or fistula
- Thrombosis of splenic vein
- Abscess Perforation

520. During functional endoscopic sinus surgery the position of patient is

a) Trendelenberg

b) Lateral

c) Reverse trendelenberg

d) Lithotomy

Correct Answer - C

Answer- C. Reverse trendelenberg

Using the reverse trendelenburg position during functional endoscopic sinus surgery (FESS) is safe, simple, and cost-free method that has been found to reduce intraoperative blood loss.

521. Head & face burn in infant is

a) 15%

b) 18%

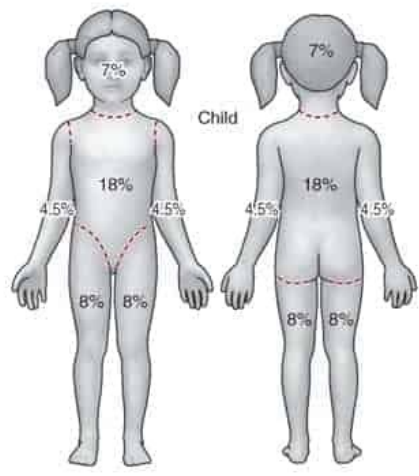
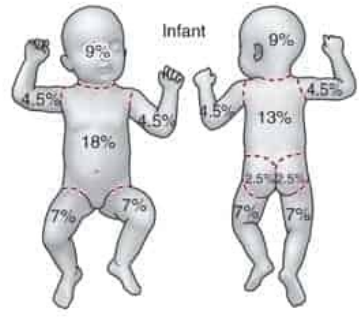
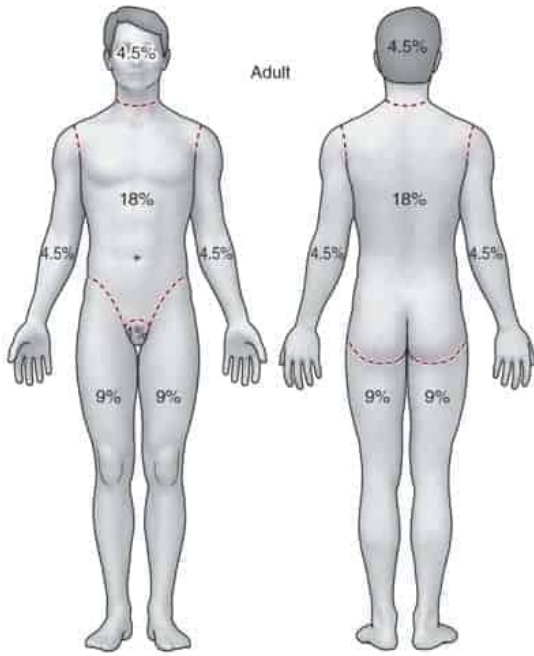
c) 12%

d) 32%

Correct Answer - B

Answer- B. 18%

"Infants have 21% of the TBSA in the head and neck" — Sabiston
Children have a relatively larger portion of the body surface area in the head and neck which is compensated for by a relatively smaller surface area in the lower extremities. Infants have 21% of TBSA in the head and neck and 13% in each leg.



522. Plasma expanders are used in

a) Endotoxic shock

b) Neurogenic shock

c) Vasovagal shock

d) Anaphylactic shock

Correct Answer - A

Answer- A. Endotoxic shock

Uses of plasma expanders 4 to correct hypovolemia, e.g. in burns, hypovolemic and endotoxic shock, severe trauma.

Contraindications - Severe anaemia, cardiac failure, pulmonary edema, renal insufficiency.

523. Whiplash injury is tear of which ligament

- a) Ligamenta flava
- b) Ant. longitudinal ligament
- c) Post. longitudinal ligament
- d) Supraspinal ligament

Correct Answer - B

Answer- B. Ant. longitudinal ligament

Hyperextension theory describes whiplash injury.

Hyperextension most commonly results in anterior cervical column injuries in the form of anterior longitudinal ligament and intervertebral disc ruptures.

524. Neurosurgery is indicated for all except

a) SDH

b) EDH

c) Intracerebral bleed

d) Diffuse axonal injury

Correct Answer - D

Answer- D. Diffuse axonal injury

Diffuse axonal injury does not have any specific treatment

Symptomatic treatment and stabilization of patient is required.

Subdural hematoma, (SDH), epidural hematoma (EDH) and intracerebral hematoma (parenchymal hemorrhage) may require surgery

525. Young male with history of trauma having left sided testis swollen & erythematous. Other side normal diagnosis

a) Torsion

b) Carcinoma

c) Hematoma

d) Hernia

Correct Answer - C

Answer- C. Hematoma

Blunt trauma to testis can cause hematoma.

There is associated tenderness, swelling and ecchymosis of the hemiscrotum.

526. Central stellate scar is seen in

a) Focal nodular hyperplasia

b) Chronic regenerative hyperplasia

c) Hepatoblastoma

d) None

Correct Answer - A

Answer- A. Focal nodular hyperplasia

- Focal nodular hyperplasia is a rare tumor-like condition predominantly found in women during to third to the fifth decade of life.
- Most commonly it is incidentally discovered as asymptomatic mass.
- The pathognomonic microscopic feature.
- A central stellate scar seen in liver imaging studies is a highly characteristic feature of focal nodular hyperplasia.
- It is also seen in Renal cell carcinoma(RCC).

527.. Z plasty ideal angle

a) 90°

b) 45°

c) 60°

d) 75°

Correct Answer - C

Answer- C. 60°

The 60 degree Z-plasty (ie, classic Z-plasty) is most commonly used because it provides the optimal balance between lengthening and ease of closure.

528. Lymphedema precox all are true except

a) U/L

b) More common in men

c) Affects the legs

d) 2-35yrs of age

Correct Answer - B

Answer- B. More common in men

Primary lymphedema with age of onset b/w ages 1 year and 35 years.

MC forms of primary lymphedema.

Female : Male - 10 : 1

Swelling involves foot and calf.

Usually unilateral

529. RTA with multiple fractures initial treatment would be -

a) Management of shock

b) Splinting of limbs

c) Airway management

d) Cervical spine protection

Correct Answer - C

Answer- C. Airway management

Management of trauma begins with primary survey.

The ATLS (Advanced Trauma Life Support) defines primary survey as assessment of the `A,B,C' i.e., Airway with cervical spine protection, Breathing and circulation.

530. With blunt trauma all over body the amount of N₂ & nitrogen end products lost/day

a) 35gm

b) 45gm

c) 55gm

d) 65gm

Correct Answer - A

Answer- A. 35gm

After injury, the initial systemic proteolysis, mediated primarily by glucocorticoides increases urinary nitrogen excretion to levels in excess of 30 gm/day.

531. Inverted Champagne bottle appearance is seen in

a) Varicose veins

b) DVT

c) Lipodermatosclerosis

d) Venous ulceration

Correct Answer - C

Answer- C. Lipodermatosclerosis

- The most commonly recognized form of lipodermatosclerosis (LDS), chronic LDS presence with induration and hyperpigmentation of the skin involving the one or both of the lower legs in a characteristic "inverted champagne bottle" appearance.
- Associated with venous insufficiency, LDS is most common in middle-aged women.

**532. 10 cm tumor on anterior surface of thigh,
what is done to know to diagnosis**

a) Incision biopsy

b) Excision biopsy

c) FNAC

d) USG

Correct Answer - A

Answer- A. Incision biopsy

Incisional biopsy is indicated when tissue samples are not obtained by FNAC or core needle biopsy as in deep tumors and for superficial soft tissue tumors > 3cm.

Excisional biopsy is indicated for easily accesible extremity or truncal lesions < 3cm.

533. Flash burn, tender, red & painful, which of the following type is the burn-

a) Scalded burn

b) First degree burn

c) Second degree burn

d) Fourth degree burn

Correct Answer - B

Answer- B. First degree burn

First degree burn (also k/a Superficial or Epidermal burn)

- These burns involve only the epidermis
- They do not blister,
- Are erythematous because of dermal vasodilation
- Blanch to touch (i.e. show capillary refilling)
- Are quite painful
- Heal without scarring in 5 to 10 days.
- They result in pain and reddening of the epidermis (outer layer of the skin).
- The clinical features are blistering and/or loss of the epidermis. The underlying dermis is pink and moist. The capillary return is clearly visible when blanched

534. In a female abdominal intestinal perforation operated has serous discharge on 5th day with wound gap. What is your diagnosis

a) Wound dehiscence

b) Enterocutaneous fistula

c) Scroma

d) Peritonitis

Correct Answer - A

Answer- A. Wound dehiscence

Dehiscence most often develops 7 to 10 days postoperatively but may occur anytime after surgery, from 1 to more than 20 days."- Sabiston

535. Peritonitis

a) Neutrophils > 250mm³

b) WBC < 100/m¹

c) Ascitis lactate level < 25 mg/dl

d) Ascitis fluid pH > 7.35

Correct Answer - A

Answer-A. Neutrophils > 250mm³

More than 250 neutrophils/cumm of ascitis fluid suggest an acute inflammatory process, the most common of which is spontaneous bacterial peritonitis.

An ascites lactate level of more than 25 mg/dl was found to be 100% sensitive and specific in predicting active spontaneous bacterial peritonitis.

536. Treatment of choice in anorectal carcinoma

a) Chemoradiation

b) APR Combined surgery and radiotherapy

c) Chemotherapy alone

d) All

Correct Answer - B

Answer-B

Abdominal-perineal resection with colostomy was the **preferred** surgical procedure for most major cancers of the **anal** canal,

537. Rectal prolapse surgery is

a) Rectal mucosal stapling

b) Mucosal resection

c) Placation/wiring

d) Rectopexy

Correct Answer - D

Answer- D. Rectopexy

Abdominal approach

1. Reduction of perineal hernia and closure of ced-de-sac (Moschowitz's operation)
2. Fixation of rectum either with a prosthetic sling (Ripstein and wells rectopexy) or by Suture Rectopexy.
3. Resection of redundant sigmoid colon \pm rectal fixation (Resection rectopexy).

538. Crohn's disease

a) Continuous involvement

b) Sinus & fistula

c) Mesenteric lymphadenitis

d) Stud ulcer

Correct Answer - B

Answer- B. Sinus & fistula

Clinical features-

- Intermittent mild diarrhea, fever, abdominal pain (MC)
- Right lower quadrant mass, weight loss, anemia
- Sometimes mimics appendicitis or bowel perforation
- Anal complaints (fissure, fistula, abscess) – frequent
- Fat/vitamin malabsorption present

539. Step ladder pattern of gas shadow is seen in

a) Duodenal obstruction

b) Intestinal obstruction

c) Gastric outlet obstruction

d) Sigmoid volvulus

Correct Answer - B

Answer- B. Intestinal obstruction

Stepladder sign represents the appearance of gas-fluid distended small bowel loops that appear to be stacked on top of each other, typically observed on erect abdominal radiographs in the setting of small bowel obstruction.

540. What is not seen in short bowel syndrome

- a) Hypergastrinemia & high gastric secretion is seen
- b) Diarrhea, dehydration and malnutrition
- c) Hirsutism
- d) Chronic TPN dependence

Correct Answer - C

Answer- C. Hirsutism

Resection of jejunum is better tolerated than resection of ileum, as the capacity for bile salt and vitamin B12 absorption is specific to the ileum

Malabsorption after massive small bowel resection is exacerbated by a characteristic hypergastrinemia-associated gastric acid hypersecretion that persists for 1 to 2 years postoperatively

Short-bowel syndrome is a disorder clinically defined by malabsorption, diarrhea, steatorrhea, fluid and electrolyte disturbances, and malnutrition.

541. Ogilvie's syndrome most commonly involves

a) Stomach

b) Colon

c) Gallbladder

d) Small intestine

Correct Answer - B

Answer- B. Colon

Ogilvie syndrome, or acute colonic pseudo-obstruction (ACPO), is a clinical disorder with the signs, symptoms, and radiographic appearance of acute large bowel obstruction with no evidence of the actual physical cause of the obstruction. The colon may become massively dilated; if not decompressed, the patient risks perforation, peritonitis, and death.

Pseudo-obstruction most commonly occurs in hospitalized patients and is associated with the use of narcotics, bed rest, and co-morbid disease.

This condition describes an obstruction, usually of the colon, that occurs in the absence of a mechanical cause or acute intra-abdominal disease.

Abdominal radiographs show evidence of colonic obstruction, with marked cecal distension being a common feature.

542. Spigelian hernia is

- a) Through linea alba
- b) Through lateral border of rectus abdominis
- c) Through medial wall of inguinal canal
- d) Through lateral wall of inguinal canal

Correct Answer - B

Answer- B. Through lateral border of rectus abdominis

Spigelian hernias can occur anywhere along the length of the spigelian line or zone — an aponeurotic band of variable width at the lateral border of the rectus abdominis. The most frequent location of these rare hernias is at or slightly above the level of the arcuate line.

Spigelian hernia occurs through the linear semilunaris which corresponds to the lateral margin of the rectus abdominis.

A spigelian hernia occurs through the spigelian fascia, which is composed of the aponeurotic layer between the rectus muscle medially and the semilunar line laterally.

543. 24 day neonate with projectile vomiting & failure to gain weight .what is the diagnosis

a) CHPS

b) NEC

c) Duodenal atresia

d) Hirschsprung's disease

Correct Answer - A

Answer- A. CHPS

Projectile vomiting in 4th week is quite suggestive of CHPS. In duodenal atresia the vomiting (usually bilious) is right from the 1st day of life. NEC and Hirschsprung's disease have different clinical presentation.

544. Not true about Barrett's esophagus

a) Metaplasia of cells

b) Predisposes to SCC

c) Precancerous condition

d) Intestinal type is the most common type

Correct Answer - B

Answer- B. Predisposes to SCC

Barrett's esophagus is premalignant condition for adenocarcinoma esophagus and not SCC.

545. Gastrotomy is

a) Open the stomach closed after tube insertion

b) Opening the stomach

c) Resecting the terminal part of stomach

d) Resecting the proximal part of stomach

Correct Answer - B

Answer- B. Opening the stomach

Gastrostomy refers to a surgical opening into the stomach.; creation of an artificial external opening into the stomach for nutritional support or gastrointestinal compression. Typically this would include an incision in the patient's epigastrium as part of a formal operation.

546. Parrot beak appearance is seen in

a) Volvulus

b) Intussuption

c) Rectal atresia

d) CA colon

Correct Answer - A

Answer- A. Volvulus

Barium/gastrograffin enema - demonstrates the point of obstruction, pathognomonic "Bird beak deformity" or parrot beak deformity.

Contrast enema is contraindicated if gangrene is suspected.

"Parrot beaked" clawing of neils is also seen in chronic cocaine abuse.

547. Raspberry tumor is seen in

a) Umbilical fistula

b) Meckel's diverticulum

c) Umbilical adenoma

d) Umbilical granuloma

Correct Answer - C

Answer- C. Umbilical adenoma

- **An umbilical adenoma** is also known as “**Raspberry tumor**”.
- It is due to a partially **unobliterated vitellointestinal duct**.
- It is seen in **infants**.
- The **prolapsing mucosa gives the raspberry appearance and bleeds on touch**.
- **Treatment:**
 - A ligature is tied around its base, and it falls off after a few days.
 - Recurrence is treated with surgery.

548. After mastectomy, breast reconstruction is done by

a) Deltopectoral

b) latissimus dorsi

c) Serratus anterior

d) Trapezius

Correct Answer - B

Answer- B. latissimus dorsi

If the skin at the mastectomy site is poor (e.g. following radiotherapy) or if a larger volume of tissue is required, a musculocutaneous flap can be constructed either from the latissimusdorsi muscle (an LD flap) or using the transversusabdominis muscle (a TRAM flap as). The latter gives an excellent cosmetic result in experienced hands but is a lengthy procedure and requires careful patient selection.

549. Peau de orange appearance of Ca breast, what is the stage

a) T4b

b) T4a

c) T3a

d) T3b

Correct Answer - A

Answer- A. T4b

Stage I : $T_1N_0M_0$

Stage IIa : $T_0N_1M_0; T_1N_1M_0; T_2N_0M_0$.

Stage IIb : $T_2N_1M_0; T_3N_0M_0$

Stage IIIa : $T_0N_2M_0; T_1N_2M_0; T_2N_2M_0; T_3N_1M_0; T_3N_2M_0$

Stage IIIb : $T_4N_0M_0; T_4N_1M_0; T_4N_2M_0$

Stage IIIc : Any TN_3M_0

Stage IV : Any T, any N, M

Early breast cancer—Stage I and **11J1N1,1-2N1;13NO Locally advanced breast cancer (LABC)**—Stage 111AI **Metastatic breast cancer**—**Stage IV**

Primary tumor (T)

TX- Primary tumor cannot be assessed

T0- No evidence of primary tumor

Tis- Carcinoma in situ

Tis (DCIS)- Ductal carcinoma in situ

Tis (Paget)- Paget disease of the nipple NOT associated with invasive carcinoma and/or carcinoma in situ (DCIS) in the underlying breast parenchyma. Carcinomas in the breast parenchyma associated with Paget disease are categorized on the basis of the size and characteristics of the parenchymal disease, although the presence of Paget disease should still be noted

T1-Tumor \leq 20 mm in greatest dimension

T1mi- Tumor \leq 1 mm in greatest dimension

T1a- Tumor $>$ 1 mm but \leq 5 mm in greatest dimension (round any measurement $>1.0-1.9$ mm to 2 mm)

T1b- Tumor $>$ 5 mm but \leq 10 mm in greatest dimension

T1c- Tumor $>$ 10 mm but \leq 20 mm in greatest dimension

T2- Tumor $>$ 20 mm but \leq 50 mm in greatest dimension

T3- Tumor $>$ 50 mm in greatest dimension

T4- Tumor of any size with direct extension to the chest wall and/or to the skin (ulceration or skin nodules), not including invasion of dermis alone

T4a- Extension to chest wall, not including only pectoralis muscle adherence/invasion

T4b- Ulceration and/or ipsilateral satellite nodules and/or edema (including peau d'orange) of the skin, which do not meet the criteria for inflammatory carcinoma

T4c- Both T4a and T4b

T4d- Inflammatory carcinoma

550. Not a component of triple test in detection of Ca breast-

a) Breast self examination

b) USG/ mammography

c) FNAC/ trucut biopsy

d) Clinical examination

Correct Answer - A

Answer- A.Breast self examination

Triple assessment includes examination by a clinician. Self examination is not a part of triple assessment.

Bailey and Love writes — "In any patient who presents with a breast lump or other symptoms suspicious of carcinoma, the diagnosis should be made by a combination of clinical assessment, radiological imaging and a tissue sample taken for either cytological or histological analysis, the so called triple assessment. The positive predictive value (PPV) of this combination should exceed 99.9%."

551. Treatment for hydroureter

a) Antibiotic prophylaxis alone

b) Immediate ureterolithotomy

c) Endoscopic ureteral stenting

d) Urinary alkalization

Correct Answer - C

Answer- C. Endoscopic ureteral stenting

Hydroureter is mainly caused by intrinsic and extrinsic obstruction of ureter. Causes are - Calculi (ureteric/VVJ) - intrinsic stricture and Retroperitoneal fibrosis - extrinsic.

552. Diversion of urine is best done at

a) Ileum

b) Jejunum

c) Caecum

d) Colon

Correct Answer - A

Answer- A. Ileum

Ileal segment is the best for urinary diversion after cystectomy.

Still better method is "Continent cutaneous diversion" method.

But the best method is "Orthotopic neobladders".

553. Ureterosigmoidostomy

a) Hyperchloremic with hypokalemic acidosis

b) Hyperkalemia

c) Metabolic alkalosis

d) Hyponatremia

Correct Answer - A

Answer- A. Hyperchloremic with hypokalemic acidosis

There is hyperchloremic metabolic acidosis with hypokalemia.

554. Injury to penis which of the following prevents extravasation of blood –

a) Bucks fascia

b) Fascia of camper

c) Fascia transversalis

d) None

Correct Answer - A

Answer- A. Bucks fascia

Superficial to tunica albuginea there is Buck's fascia (deep layer of superficial fascia of penis), a prolongation of colle's fascia (membranous layer of superficial fascia of perineum).

If Buck's fascia remains intact, hematoma is restricted to penile shaft only causing egg-plant deformity.

If Buck's fascia is disrupted, hematoma can extend to scrotum, perineum and suprapubic regions.

555. Phimosis is associated with

a) Paraphimosis

b) Meatal stenosis

c) Balanoposthitis

d) Hypospadias

Correct Answer - C

Answer- C. Balanoposthitis

Phimosis caused due to
chronic infection

Congenital

Acquired- trauma, Penis Ca and Balanitis

Pathological phimosis (as opposed to the natural non-retractability of the foreskin in childhood) is rare and the causes are varied. Some cases may arise from balanitis (inflammation of the glans penis).

Phimosis may occur after other types of chronic inflammation (such as balanoposthitis), repeated catheterization, or forcible foreskin retraction.

Phimosis may also arise in untreated diabetics

556. Circumcision is contraindicated in

a) Balanitis

b) Hypospadias

c) Paraphimosis

d) Exostrophy of bladder

Correct Answer - B

Answer- B. Hypospadias

Circumcision is not done in patients with hypospadias as the prepuce can later be used in surgical repair.

Circumcision is mostly done for cultural reasons.

The medical indications for circumcision are:

Phimosis & Paraphimosis

Recurrent balanoposthitis (i.e. inflammation of the foreskin)

Recurrent urinary tract infection

557. Which is not true about cancer of tongue

a) Adenocarcinoma most common

b) Lateral surface involved

c) Deep cervical lymph nodes not involved

d) Tobacco is the cause

Correct Answer - A

Answer- A. Adenocarcinoma most common

- SCC is the most common type of malignancy, but leiomyosarcomas and rhabdomyosarcomas are also encountered (rarely).
- Tumors on the tongue may occur on any surface but are most commonly seen on the lateral and ventral surfaces.
- The regional lymphatics of the oral cavity are to the submandibular space and the upper cervical lymph nodes.
- Risk factors- tobacco and alcohol.

558. Kasai operation

a) Biliary atresia

b) Choledochal cyst

c) Hepatocellular carcinoma

d) Primary biliary cirrhosis

Correct Answer - A

Answer- A. Biliary atresia

Kasai operation is also known as hepatoportoenterostomy.

Biliary atresia is currently MC indication for pediatric liver transplantation.

559. False about hepatic adenoma

a) Benign lesion

b) OCP use

c) Older females

d) Cold on isotope scan

Correct Answer - C

Answer- C. Older females

Hepatic adenomas are benign solid neoplasms of liver.

MC seen in younger females (20-40 years of age)

Usually solitary

Risk factor - Prior/current use of estrogens (OCP)

560. Bismuth classification in which class, hepatic duct confluence is involved

a) Type I

b) Type II

c) Type III

d) Type IV

Correct Answer - B

Answer- B. Type II

Bismuth - Corlette classification is used to classify cholangiocarcinoma

Type I - Common hepatic duct involvement.

Type II - CHD + bifurcation/confluence of hepatic ducts. Type III- a) Extension to right secondary intrahepatic duct. b) Extension to left secondary intrahepatic duct.

Type IV - Involving both right and left secondary intrahepatic ducts.

561. Parathyroid glands are removed by surgery, for recurrence investigation of choice

a) Technetium scan

b) SPECT

c) MRI

d) Neck ultrasound

Correct Answer - A

Answer-A. Technetium scan

- Preoperative localisation tests for parathyroid glands are
 1. Tc 99m labeled sestamibi scan (>80% sensitive)
 2. Single positron emission computed tomography (SPECT).
 3. CT and MRI scan.
 4. Neck ultrasound.

562. Which is not a contraindication for pancreaticoduodenectomy

- a) Metastasis
- b) Portal vein involvement
- c) Stage III CA head of pancreas
- d) Invasion of superior mesenteric vein

Correct Answer - B

Answer- B. Portal vein involvement

Tumor (T)

TX - Primary can't be assessed.

To - No evidence of primary tumor.

T1 - Ca in situ.

T1 - Limited to pancreas and 2cm.

T2 - Limited to pancreas and > 2cm.

T3 - Extends beyond pancreas but no involvement of celiac axis or superior mesenteric artery.

T4 - Involves celiac axis or Sup-mesenteric artery (unresectable primary).

Regional lymph nodes (N)

NX - Regional LN, cannot be assessed.

N1 - No regional LN metastasis.

N2 - Regional LN metastasis.

Regional lymph nodes (N)

Mx- Distant metastasis cannot be assessed.

Mo- No distant metastasis.

M1 - Distant metastasis.

563. Most common cause of chronic pancreatitis

a) Chronic alcoholism

b) Tropical pancreatitis

c) Pancreas divisium

d) Gall stone disease

Correct Answer - A

Answer- A. Chronic alcoholism

"Worldwide, alcohol consumption and abuse is associated with chronic pancreatitis in up to 70% of cases "

564. Most common cause of acute parotitis -

a) Staphylococcus Aureus

b) Streptococcus Pneumonia

c) Klebsiella

d) Streptococcus Viridans

Correct Answer - A

Answer- A. Staphylococcus Aureus

MC organism is **Staphylococcus Aureus** >> streptococcus viridans
>> pneumococcus.

Acute bacterial parotitis: is most often caused by a **bacterial** infection of Staphylococcus aureus but may be **caused** by any commensal bacteria.

Usually ascending infection Staphylococcus aureus

Ref- Manipal Manual of Surgery 5th edition

565. Pre-operative prophylaxis for pheochromocytoma

a) Alpha blockade after beta blocker

b) Beta blockade after alpha blocker

c) Alpha blocker

d) Beta blocker

Correct Answer - B

Answer- B. Beta blockade after alpha blocker

Beta blockers such as propranolol at doses of 10 to 40 mg every 6 to 8 hours are often needed in patients who have persistent tachycardia and arrhythmias. α -blockers should only be added after adequate α -blockade and rehydration.

α -adrenergic agonists may be needed in immediate post operative period to prevent post operative hypotension and cardiovascular collapse.

566. Child with polytrauma came to casualty, dose of packed cell

a) 10 ml/kg

b) 20 ml/kg

c) 30 ml/kg

d) 40 ml/kg

Correct Answer - A

Answer-A

Usual dosage of packed red cells in pediatric populations is 10-15 ml/kg, but can be increased upto 20 ml/kg in cases where higher increase in Hct is needed, as in trauma.

Colloid 10ml/kg

Crystalloid 20ml/kg

Requiring > 20 ml/Kg of PRBCs in the 1st hour of resuscitation

Pediatric MTG Pack (\leq 50 Kg)

- 4 Units of PRBCs
- 2 Units of thawed plasma
- 1 Unit of apheresis platelets

567. Polytrauma patient came to EMS, dose of crystalloid given should be

a) 500 ml RL bolus then regulated by indicators

b) 2000 ml bolus

c) 1000 ml bolus then regulated by clinical indicators

d) 250 ml bolus

Correct Answer - C

Answer- C. 1000 ml bolus then regulated by clinical indicators

Fluid resuscitation begins with 1000 ml bolus of RL for adult and 20 ml/kg for a child. Response to therapy is monitored by clinical indicators as blood pressure, skin perfusion, urinary output and mental status.

568. A polytrauma CT scan, CT brain shows a lesion with concave margin

a) EDH

b) SDH

c) Contusion

d) Diffuse axonal injury

Correct Answer - B

Answer- B. SDH

SDH - On head CT, the clot is bright or mixed density, crescent shaped (Lunate), may have a less distinct border and does not cross midline.

Contusion - The contused area appears bright on CT Scan.

569. A person inhaled peanut two days back & now unable to cough it out where is the possible location

a) Right superior lobe

b) Rt middle lobe

c) Rt lower lobe

d) Lt lower lobe

Correct Answer - C

Answer- C. Rt lower lobe

The most common anatomic location for a foreign body is the right main stem bronchus or the right lower lobe.

570. Hernia most commonly strangulates in

a) Indirect

b) Direct

c) Spigelian

d) Incisional

Correct Answer - A

Answer- A. Indirect

"Most strangulated hernias are indirect inguinal hernias, however, femoral hernias have the highest rate of strangulation (15-20%) of all hernias".

571. Van Nuys prognostic index is not based on:

a) Age

b) Microcalcification

c) Size

d) ER status

Correct Answer - D

Answer: D. ER status

DCIS may be classified using the Van Nuys system, which combines the

1. Patient's age,
2. Type of DCIS
3. Presence of microcalcification,
4. The extent of resection margin
5. The size of the disease.

Van Nuys Prognostic Index			
Parameter	Score 1	Score 2	Score 3
Van Nuys Classification	Group 1	Group 2	Group 3
	Non-high nuclear grade without necrosis	Non-High nuclear grade with necrosis	High nuclear grade with or without necrosis
Margins	≥10 mm	1–9 mm	
Size		16–40 mm	>40 mm
Age	>60	40–60	<40

572. Common cause of chronic pancreatitis

a) Chronic alcohol

b) Chronic pancreatic calculi

c) pancreas divisum

d) Gall bladder stones

Correct Answer - A

Answer: A. Chronic alcohol

"Worldwide, alcohol consumption and abuse is associated with chronic pancreatitis in up to 70% of cases "

573. The following statement about Keloid is true

- a) It contain growth factor
- b) Extended excision is the treatment of choice
- c) It do not extend beyond the wound
- d) None of the above

Correct Answer - A

Answer: A. It contain growth factor

Vaccinations, injections, insect bites, ear piercing, or may arise spontaneously.

Keloids tend to occur 3 months to years after the initial insult, and even minor injuries can result in large lesions.

They vary in size from a few millimeters to large, pedunculated lesions with a soft to rubbery or hard consistency.

Although they project above surrounding skin, they rarely extend into underlying subcutaneous tissues.

Certain body sites have a higher incidence of keloid formation, including the skin of the earlobe as well as the deltoid, presternal, and upper back regions.

They rarely occur on eyelids, genitalia, palms, soles, or across joints.

Keloids rarely involute spontaneously, whereas surgical intervention can lead to recurrence, often with a worse result.

574. Which of the following layers are cut during fasciotomy ?

a) Skin

b) Skin+subcutaneous fascia

c) Skin+subcutaneous tissue+Superficial fascia

d) Skin+subcutaneous tissue+Superficial fascia+deep fascia

Correct Answer - D

Answer: D. Skin+subcutaneous tissue+Superficial fascia+deep fascia

Fasciotomy or fasciectomy is a surgical procedure where complete opening of all fascial envelope is done to relieve tension or pressure commonly to treat the resulting loss of circulation to an area of tissue or muscle. Fasciotomy is a limb-saving procedure when used to treat acute compartment syndrome.

575. Which statement is not true regarding crohn's disease :

a) Rectum is not involved

b) Continuous lesion visualized in endoscopy

c) Non caseating granulomas

d) Cobblestone appearance

Correct Answer - B

Answer: B. Continuous lesion visualized in endoscopy

Crohn's disease is frequently associated with "skip lesions," **discontinuous areas of active disease in the colon** and small intestine with intervening segments that appear normal.

576. Which is the best investigation for carcinoma head of pancreas:

a) Guided biopsy

b) ERCP

c) Transduodenal/transperitoneal sampling

d) EUS

Correct Answer - D

Answer: D

Medical imaging techniques, such as computed tomography (CT scan) and endoscopic ultrasound (EUS) are used both to confirm the diagnosis and to help decide whether the tumor can be surgically removed

577. An abdominal mass is best demonstrated in congenital hypertrophic pyloric stenosis by:

a) In palpation over the epigastrium

b) In left hypochondriac

c) Right iliac fossa

d) During feeding

Correct Answer - D

Answer: D. During feeding

Congenital hypertrophic pyloric stenosis

Presentation

- Vomiting is the presenting symptom (child vomits milk and no bile is present)
- Immediately after vomiting the child is hungry i.e. loss of appetite does not occur.
- Weight loss is striking and rapidly the infant becomes emaciated and dehydrated.

However, greater awareness of pyloric stenosis has led to earlier identification of patients and hence with fewer incidences of chronic malnutrition and severe dehydration - Nelson 10th/1130

The diagnosis is usually made with a test feed: In this, the baby is fed with the bottle by a nurse or mother and surgeon :

- IHPS/CHPS can be diagnosed clinically. During a test feed, there is visible gastric peristalsis passing from left to right across the upper abdomen and in a relaxed baby, the pyloric 'tumor' is palpable as an 'olive' in the right upper quadrant.
- The diagnosis can be confirmed by an ultrasound, which shows

the thickened pyloric muscle.

**578. Calculate GCS of 25 year old head injury patient with following parameters
confused, opening eyes in response to
pain, localizing pain will be-**

a) 6

b) 11




c) 12

d) 7

Correct Answer - B

Answer: B. 11

Glasgow coma scale:

Behaviour	Response
 Eye Opening Response	4. Spontaneously 3. To speech 2. To pain 1. No response
 Verbal Response	5. Oriented to time, person and place 4. Confused 3. Inappropriate words 2. Incomprehensible sounds 1. No response
 Motor Response	6. Obeys command 5. Moves to localised pain 4. Flex to withdraw from pain 3. Abnormal flexion 2. Abnormal extension 1. No response

579. RET proto-oncogene is associated with the development of

a) Medullary carcinoma thyroid

b) Astrocytoma

c) Paraganglioma

d) Hurthle cell tumor thyroid

Correct Answer - A

Answer: A. Medullary carcinoma thyroid

RET proto-oncogene is a growth factor receptor (receptor tyrosine kinase)

The RET protein is a receptor for the glial cell line-derived neurotrophic factor and structurally related proteins that promote cell survival during neural development.

RET is normally expressed in the following cells

- Parafollicular C cells of the thyroid
- Adrenal medulla
- Medullary carcinoma may occur in combination with adrenal pheochromocytoma and hyperparathyroidism (HPT) (usually due to hyperplasia) in the syndrome known as multiple endocrine neoplasia type 2A (MEN-2A).
- These are tumors of the parafollicular (C cells) derived from the neural crest rather than the cells of the thyroid follicle as are other primary thyroid carcinomas
- When the familial form is associated with prominent mucosal neuromas involving the lips, tongue and inner aspect of the eyelids, with a Marfanoid habitus, the syndrome is referred to as MEN type 2B.
- RET associations: MEN 2a, MEN 2b, Familial medullary carcinoma

thyroid.

580. Cutoff for surgery in an abdominal aortic aneurysm in asymptomatic patients-

a) 5.5cm

b) 6.5cm

c) 7.5cm

d) 8.5cm

Correct Answer - A

Answer: A. 5.5cm

Operative repair of the aneurysm with the insertion of a prosthetic graft or endovascular placement of aortic stent graft is indicated for:

- Abdominal aortic aneurysms of any size that are expanding rapidly or are associated with symptoms.
- For asymptomatic aneurysms, abdominal aortic aneurysm repair is indicated if the diameter is >5.5 cm.

581. In ACLS which drug can be given following ventricular fibrillation after cardiac arrest other than epinephrine?

a) Amiodarone

b) Dopamine

c) Adenosine

d) Atropine

Correct Answer - A

Ans. A. Amiodarone

V-Fib or VF is the most common rhythm that occurs immediately after cardiac arrest. In this rhythm, the heart beats with rapid, erratic electrical impulses.

Treatment:

- Shock / Defibrillation: every 2 minutes in a single one shock, successive, shockable increments
- 200 joules - Followed by immediate CPR for 2 minutes / give and circulate a drug(s)
- 300 joules - Followed by immediate CPR for 2 minutes / give and circulate a drug(s)
- 360 joules - Followed by immediate CPR for 2 minutes / give and circulate a drug(s)

Drugs :

- Give Epinephrine 1mg of a 1:10,000 solution every 3 to 5 minutes [No Limit]

Give either:

- Amiodarone [if not contraindicated, can be given 2x]: 300mg first dose / 150mg second dose at 3 to 5 minutes increments.

- Lidocaine: First dose: 1mg/kg or 1.5 mg/kg. Can repeat it at half the original dose up to a total of 3 mg/kg [Second and remaining doses are given at either 0.5mg/kg or 0.75mg/kg depending on your starting dosage.]

**582. A 6-year-old boy experienced life threatening shock ,his CT scan showed large amount of ascites, bowel wall thickening and poor or absent enhancement of the strangulated bowel segment, showing gangrenous bowel on surgical exploration.
True about anastomosis is-**

a) Should be done by continuous layers as it takes less time

b) Should be Done with catgut

c) Should be Done by single layer seromuscular lembert sutures

d) Should be Done by Single layer taking submucosa

Correct Answer - C

Ans C. Should be Done by single layer seromuscular lembert sutures

Diagnosis is of congenital IH with strangulated small bowel with gangrenous small bowel

Transmesenteric hernia was the most common type in older children as well as in neonates .

IH results from incomplete closure of surgically created mesenteric defects, and usually acquired resulting from previous abdominal surgery especially Roux-en-Y anastomosis

Anastomosis should be done by single layer seromuscular lembert sutures

The Lambert suture generally is used in abdominal surgery. It is an inverting suture, that can be either continuous or interrupted, used to

join two segments of an intestine without entering the lumen (the inner channel through which stomach contents flow).

583. Which of the following is the best Stent for Femoropopliteal Bypass?

a) Dacron

b) Reversed saphenous

c) PTFE

d) None

Correct Answer - C

Answer: C- PTFE-covered self-expanding nitinol stents

- PTFE-covered stents are engineered with a 30–100-micron pore size to allow for the endothelial lining of the stent-graft and vessel healing.
- The two main graft types used for lower extremity bypasses are the great saphenous veins and polytetrafluoroethylene (PTFE) grafts.
- One of the most widely used stent-grafts in the treatment of chronic lower extremity ischemia is the Viabahn endoprosthesis (Gore Medical, Flagstaff, Ariz).
- It is constructed with expanded polytetrafluoroethylene (ePTFE) liner attached to an external nitinol stent.
- The inner surface is bonded with heparin.

584. Maastricht classification of donation after cardiac death. What category is stage 3 ?

- a) Awaiting cardiac arrest
- b) Brought in dead
- c) Unsuccessful resuscitation
- d) Cardiac arrest after brain-stem death

Correct Answer - A

Answer: A>Awaiting cardiac arrest

The first level of definition is simple and based on whether the situation is uncontrolled (categories I and II) or controlled (categories III, IV, and V).

Category I, the patient is declared "dead on arrival" and, Category II, there is an "unsuccessful resuscitation" whether it occurred out or in the hospital for both situations.

Category III is the most usual situation in which the treating physician and family are "awaiting cardiac arrest" to declare the death of the patient.

Category IV is always characterized by "cardiac arrest during brain death." The special situation of the Belgian law allowing the euthanasia is elaborated

Category V "euthanasia," and includes patients who grant access to medically assisted circulatory death. Organ donation after euthanasia is allowed under the scope of donation after circulatory

585. A patient arrived in ER following an RTA with hypotension, respiratory distress and subcutaneous emphysema with no entry of air on one side. What will be the best management?

a) Needle decompression in 5th intercostal space in the midaxillary line

b) Continue PPV

c) Shift to ICU and incubate

d) Secure IV line and start fluid resuscitation after insertion of the wide-bore IV line

Correct Answer - A

Ans- A. Needle decompression in 5th intercostal space in the midaxillary line

A tension pneumothorax develops when a 'one-way valve' air leak occurs either from the lung or through the chest wall.

Air is sucked into the thoracic cavity without any means of escape, completely collapsing then compressing the affected lung.

Etiology-

- The most common causes are penetrating chest trauma, blunt chest trauma with parenchymal lung injury and air leak that did not spontaneously close, iatrogenic lung injury (e.g. due to central venepuncture) and mechanical positive pressure ventilation.

C/F-

- The patient is increasingly restless with tachypnoea, dyspnoea and distended neck veins

Treatment-

- Treatment consists of immediate decompression, initially by rapid insertion of a large-bore cannula into the second intercostal space in the midclavicular line of the affected side, then followed by insertion of a chest tube through the fifth intercostal space in the anterior axillary line.

Ref- Bailey and Love, Short practice of surgery, 27th edition published in 2018 Pg 367, 920

586. Treatment of Renal cell carcinoma of less than 4 cm will be-

a) Partial nephrectomy

b) Radical nephrectomy

c) Radical nephrectomy + postoperative radiotherapy

d) Radical nephrectomy + chemotherapy

Correct Answer - A

Ans: A. Partial nephrectomy

Partial nephrectomy is now being used as primary surgical therapy for patients with a tumor less than 4 cm in size. Earlier Radical nephrectomy was the treatment of choice for tumors of any size.

- Classic radical nephrectomy consists of removal of the kidney, perirenal fat, adrenal gland, and regional lymph nodes. Most stage I and stage II tumors.
- Partial nephrectomy- is indicated for patients with a T1 tumor (according to the UICC TNM staging system) and a normal contralateral kidney.
- Intervention should be considered for growth to >3-4cm or by >0.5cm per year.

T0	No evidence of primary tumour.
T1	Tumour ≤ 7 cm in greatest dimension, limited to the kidney.
T1a	Tumour ≤ 4 cm in greatest dimension, limited to the kidney.
T1b	Tumour > 4 cm but not > 7 cm in greatest dimension, limited to the kidney.
T2	Tumour > 7 cm in greatest dimension, limited to the kidney.
T2a	Tumour > 7 cm but ≤ 10 cm in greatest dimension, limited to the kidney.
T2b	Tumour > 10 cm, limited to the kidney.
T3	Tumour extends into major veins or perinephric tissues but not into the ipsilateral adrenal gland and not beyond Gerota fascia.
T3a	Tumour grossly extends into the renal vein or its segmental (muscle containing) branches, or tumour invades perirenal and/or renal sinus fat but not beyond Gerota fascia.
T3b	Tumour grossly extends into the vena cava below the diaphragm.
T3c	Tumour grossly extends into the vena cava above the diaphragm or invades the wall of the vena cava.
T4	Tumour invades beyond Gerota's fascia (including contiguous extension into the ipsilateral adrenal gland).

AJCC: American Joint Committee on Cancer; T: primary tumour; N: regional lymph nodes; M: distant metastasis. Taken from Edge SB, American Joint Committee on Cancer.²⁴

Stage T1aN0M0

- Partial nephrectomy recommended. This can be done via open/laparoscopic/robotic procedures

Stage T1bN0M0

- PN (open/laparoscopic/robotic) in cases where technically feasible
- Laparoscopic RN should be offered if a PN is not feasible
- Open RN if laparoscopic surgery is not possible.

Stage T2N0M0

- RN – open/laparoscopic/robotic
- PN – open/laparoscopic/robotic

Stage T3

- RN – open, laparoscopic or robotic-assisted
- Resection of vascular thrombosis when applicable (usually open)
- Resection of all gross disease including hilar or retroperitoneal extension
- PN may be attempted in highly selected cases by experienced surgeons

Ref- Bailey and Love, Short practice of surgery, 27th edition published in 2018 Pg 1420

https://www.researchgate.net/publication/263933944_Surgical_ma

587. Which is not seen in Asepsis score-

a) Erythema

b) Induration

c) Serous discharge

d) Purulent exudate

Correct Answer - B

Answer- B. Induration

Criterion	Points
Additional treatment	0
Antibiotics for wound infection	10
Drainage of pus under local anaesthesia	5
Debridement of wound under general anaesthesia	10
Serous discharge	Daily 0-5
Erythema	Daily 0-5
Purulent exudate	Daily 0-10
Separation of deep tissues	Daily 0-10
Isolation of bacteria from wound	10
Stay as inpatient prolonged over 14 days as result of wound infection	5

Ref- Bailey and Love, Short practice of surgery, 27th edition published in 2018 Pg 48

588. Esophageal manometry was performed - it revealed panesophageal pressurization with distal contractile integrity as >450mm Hg pressure in the body. What will be the diagnosis?

a) Type 1 achalasia

b) Type 2 achalasia

c) Type 3 achalasia

d) Jackhammer esophagus

Correct Answer - C

Ans: C. Type 3 achalasia

Type I achalasia (classic achalasia)-

- Elevated median IRP (>15 mmHg), 100% failed peristalsis (DCI <100 mmHg.s.cm)
- Premature contractions with DCI values <450 mmHg.s.cm satisfy criteria for failed peristalsis

Type II achalasia (with esophageal compression)-

- Elevated median IRP (>15 mmHg), 100% failed peristalsis, panesophageal
- pressurisation with >20% of swallows.
- Contractions may be masked by oesophageal pressurization and DCI should not be calculated.

Type III achalasia (spastic achalasia)

- Elevated median IRP (>15 mmHg), no normal peristalsis, premature (spastic)
- contractions with DCI >450 mmHg.s.cm with >20% of swallows

- May be mixed with panesophageal pressurization
'Diffuse esophageal spasm' and jackhammer (nutcracker) esophagus-
Spastic pressures on manometry of 400-500mmHg marked hypertrophy of the circular muscle and a corkscrew esophagus on barium swallow.
Ref-Bailey and Love, Short practice of surgery, 27th edition published in 2018 Pg 1096, 1099

589. What will be the appropriate management for Abdominal aortic aneurysm-

- a) Monitor till size reaches 55mm
- b) Immediate surgery
- c) USG monitoring till >70mm asymptomatic
- d) No treatment

Correct Answer - A

Answer- A. Monitor till size reaches 55mm

An asymptomatic abdominal aortic aneurysm in an otherwise fit patient should be considered for repair if >55mm in diameter (measured by ultrasonography).

Regular ultrasonographic assessment is indicated for asymptomatic aneurysms <55 mm in diameter.

75% of aneurysms are suitable for endovascular (minimally invasive) repair, usually via the femoral arteries in the groin.

Ruptured abdominal aortic aneurysm is a surgical emergency.

Symptomatic AAA-

An operation is usually indicated in patients who are otherwise reasonably fit. Pain may be a warning sign of stretching of the aneurysm sac and imminent rupture; surgery should be performed as soon as possible (usually on the next available operating list).

Ref- Bailey and Love, Short practice of surgery, 27th edition published in 2018 Pg 961

590. What is the T stage of a 2.5cm lung carcinoma, not involving the pleura?

a) T1a

b) T2

c) T1b

d) T1c

Correct Answer - D

Ans: D. T1c

TNM 8 th - Primary tumor characteristics	
T_x	Tumor in sputum/bronchial washings but not be assessed in imaging or bronchoscopy
T₀	No evidence of tumor
T_{is}	Carcinoma in situ
T₁	≤ 3 cm surrounded by lung/visceral pleura, not involving main bronchus
T_{1a(mi)}	Minimally invasive carcinoma
T_{1a}	≤ 1 cm
T_{1b}	> 1 to ≤ 2 cm
T_{1c}	> 2 to ≤ 3 cm
T₂	> 3 to ≤ 5 cm or involvement of main bronchus without carina, regardless of distance from carina or invasion visceral pleural or atelectasis or post obstructive pneumonitis extending to hilum
T_{2a}	>3 to ≤4cm
T_{2b}	>4 to ≤5cm
T₃	>5 to ≤7cm in greatest dimension or tumor of any size that involves chest wall, pericardium, phrenic nerve or satellite nodules in the same lobe
T₄	> 7cm in greatest dimension or any tumor with invasion of mediastinum, diaphragm, heart, great vessels, recurrent laryngeal nerve, carina, trachea, oesophagus, spine or separate tumor in different lobe of ipsilateral lung
N₁	Ipsilateral peribronchial and/or hilar nodes and intrapulmonary nodes
2	Ipsilateral mediastinal and/or subcarinal nodes
3	Contralateral mediastinal or hilar; ipsilateral/contralateral scalene/supraclavicular
M₁	Distant metastasis
M_{1a}	Tumor in contralateral lung or pleural/pericardial nodule/malignant effusion
M_{1b}	Single extrathoracic metastasis, including single non-regional lymphnode
M_{1c}	Multiple extrathoracic metastases in one or more organs

Ref- Bailey and Love, Short practice of surgery, 27th edition

published in 2018 Pg 927

591. In, the primary survey which is not included-

a) CECT to look for bleeding

b) Exposure of the whole body

c) ABC

d) Recording BP

Correct Answer - A

Answer – A. CECT to look for bleeding

The primary survey aims to identify and manage the most immediately life-threatening pathologies first and follows cABCDE.

1. c- Exsanguinating external hemorrhage
2. A- airway with cervical spine control
3. B- Breathing & ventilation
4. C- Circulation & hemorrhage
5. D- Disability
6. E- Exposure

An assessment of the hemodynamic status should be made to identify shocked patients: the skin may be pale, cool and sweaty, the pulse rate raised to over 100 per minute and the blood pressure low.

Ref- Bailey and Love, Short practice of surgery, 27th edition published in 2018 Pg 323

592. MC location of gastrinoma in MEN-1 syndrome?

a) Duodenum

b) Jejunum

c) Pancreas

d) Ileum

Correct Answer - A

Answer- A. Duodenum

PETs occur in around 50-60% of MEN 1 patients.

The most common functional tumour is gastrinoma in duodenum followed by insulinoma.

Ref- Bailey and Love, Short practice of surgery, 27th edition published in 2018 Pg 856

593. Patients have precancerous lesions with abdominal swelling and inguinal nodes are seen. On examination, lymphadenopathy was found. The most probable carcinoma related to this condition will be?

a) ca penis

b) CaTestis

c) ca prostate

d) ca bladder

Correct Answer - A

Answer- A. ca penis

Cancer penis spreads to inguinal nodes.

A mass, pruritus or discharge is common. Advanced tumours may cause fecal incontinence by the invasion of the sphincters.

Anal canal tumours are palpable and irregular indurated tender ulceration. Sphincter involvement may be evident.

Ref- Bailey and Love, Short practice of surgery, 27th edition published in 2018 Pg 1371

594. A man under alcohol intoxication had fallen into a manhole and had a perineal injury with swollen scrotum and upper thigh along with blood at meatus. The patient is having difficulty passing urine as well. What will be the injury associated due to this trauma?

a) Bladder rupture

b) Penile fracture

c) Bulbar urethra

d) Membranous urethra

Correct Answer - C

Answer- C. Bulbar urethra

There is a history of a blow to the perineum, usually due to a fall astride injury. The bulbar urethra is crushed upwards onto the pubic bone, typically with significant bruising.

Cycling accidents, loose manhole covers and gymnasium accidents astride the beam account for a number of cases.*C/F*

The signs of a ruptured bulbar urethra are perineal bruising and hematoma, typically with a butterfly distribution. There is usually bleeding from the urethral meatus and retention of urine is also typically present.

Ref- Bailey and Love, Short practice of surgery, 27th edition published in 2018 Pg 1479, 1480

595. Patient with a history of carcinoma bladder presenting with dyspnoea with clinical signs of DVT and tachycardia. The risk for the patient to develop Pulmonary embolism according to WELL's score

a) High

b) Medium

c) Low

d) Cannot comment without d-dimer values

Correct Answer - B

Ans. B. Medium

Wells criteria	Score
High	> 6.0
Moderate	2.0 to 6.0
Low	< 2.0
Modified Wells criteria	Score
PE likely	> 4.0
PE unlikely	< or = 4.0

Modified Wells Criteria for DVT

Variable	Score
Lower limb trauma or surgery or immobilisation in plaster cast	1

Bedridden for >3 days or surgery in the last 4 weeks	1
Tenderness along the line of femoral or popliteal veins	1
Entire limb swollen	1
Calf >3cm larger circumference than the other side	1
10cm below the tibial tuberosity	1
Pitting edema	1
Dilated collateral superficial veins (not varicose veins)	1
Previous DVT	1
Malignancy (including treatment up to 6 months ago)	1
Intravenous drug abuse	3
Alternative diagnosis more likely than DVT	-2

**Ref- Bailey and Love, Short practice of surgery, 27th edition
published in 2018 Pg 988**

596. After 4 months of renal transplantation, a patient can likely to develop which infection-

a) EBV

b) CMV

c) Candida

d) Histoplasma

Correct Answer - B

Answer- B. CMV

Causes of allograft dysfunction

1. Early

- Primary non-function (irreversible ischaemic damage)
- Delayed function (reversible ischaemic injury)
- Hyperacute and acute rejection
- Arterial or venous thrombosis of the graft vessels
- Drug toxicity (e.g. calcineurin inhibitor toxicity)
- Infection (e.g. cytomegalovirus disease in graft)
- Mechanical obstruction (ureter/common bile duct)

2. Late

- Chronic rejection
- Arterial stenosis
- Recurrence of original disease in the graft (glomerulonephritis, hepatitis C)
- Mechanical obstruction (ureter, common bile duct)

Ref- Bailey and Love, Short practice of surgery, 27th edition published in 2018 Pg 1551

597. The patient is present with fecal peritonitis and during laparotomy, a diverticular perforation is seen. Which stage is classified according to Hinchey's stage?

a) 1

b) 2

c) 3

d) 4

Correct Answer - D

Answer- D. 4

Hinchey classification of complicated diverticulitis.

1. Grade I Mesenteric or pericolic abscess
2. Grade II Pelvic abscess
3. Grade III Purulent peritonitis
4. Grade IV Faecal peritonitis

Ref- Bailey and Love, Short practice of surgery, 27th edition published in 2018 Pg 1274

598. A young man met with a motorbike accident and had injuries to ileum and jejunum. Therefore the entire ileum and partial jejunum were resected. Which of the following would the patient suffer from

a) Vitamin B12 deficiency

b) Atrophic gastritis

c) Constipation

d) None

Correct Answer - A

Answer- A. Vitamin B12 deficiency

The ileum is the only site of absorption of vitamin B12 and bile salts. Bile salts are essential for the absorption of fats and fat-soluble vitamins.

Following resection of the ileum, the loss of bile salts increases and is not met by an increase in synthesis.

The jejunum is the principal site for digestion and absorption of fluid, electrolytes, iron, folate, fat, protein and carbohydrate, but the absorption of bile salts and vitamin B12 only occurs in the terminal ileum, where there are specific transporters.

Ref- Bailey and Love, Short practice of surgery, 27th edition published in 2018 Pg 283, 1241

599. A patient after a heavy meal comes with epigastric pain. On examination tenderness and rigidity in the upper abdomen. X-ray showing pneumomediastinum. What can be the cause-

a) Spontaneous esophageal rupture

b) Penetrating foreign body injury to esophagus

c) Perforated peptic ulcer

d) Rupture of emphysematous bulla

Correct Answer - A

Answer- A. Spontaneous esophageal rupture

This is a clinical case of spontaneous esophageal rupture/
Boerhaave's syndrome

The clinical history is usually of severe pain in the chest or upper abdomen after a meal or a bout of drinking.

Mackler's **triad**, which consists of (1) vomiting followed by (2) chest pain and (3) subcutaneous emphysema due to an esophageal rupture.

A chest radiograph is often confirmed with air in the mediastinum, pleura or peritoneum.

Investigations Chest X-ray—shows pneumomdiastinum ('V' sign of Naclerio).

MRI/CT chest.

Total count.

Ref- Bailey and Love, Short practice of surgery, 27th edition

published in 2018 Pg 1073

**Sriram Bhat M, SRB's Manual of Surgery, 4th edition published
in 2013, Pg 856**

600. Transplantation between identical twins-

a) Isograft

b) Allograft

c) Autograft

d) Xenograft

Correct Answer - A

Answer- A. Isograft

- Graft: It is the transfer of tissue from one area to another without its blood supply or nerve supply.
- Autograft: It is tissue transferred from one location to another on the same patient.
- Isograft: It is tissue transfer between two genetically identical individuals, i.e. between two identical twins.
- Allograft: It is tissue transfer between two genetically different members, e.g. kidney transplantation (Human to human) (Homograft).
- Xenograft: It is tissue transfer from a donor of one species to a recipient of another species (Heterograft).

601. Thoracscore , what is not the component

a) ASA CLASSIFICATIONS

b) SURGERY PRIORITIES

c) Performance status

d) Expected complications post-surgery

Correct Answer - B

Answer- B. SURGERY PRIORITIES

The Thoracscore is the most widely used model to assess the risk of operative mortality in thoracic patients

Parameters of thoracscore for predicting in-hospital mortality for patients requiring thoracic surgery.

Age (<55, 55-65, >65 years)

Sex

ASA classification (≤ 2 , ≥ 3)

Performance status according to Zubrod scale (≤ 2 , ≥ 3)

Severity of dyspnea according to Medical Research Council Scale (≤ 2 , ≥ 3)

Priority of surgery (elective, urgent/emergency)

Extent of resection (pneumonectomy, other)

Diagnosis (malignant, benign)

Comorbidity score

ASA, American Society of Anesthesiologists.

**Ref- Bailey and Love, Short practice of surgery, 27th edition
published in 2018 Pg 915**

602. Retrosternal goiter which is true?

- a) All patients should undergo CT chest
- b) All patients require a median sternotomy
- c) it receives blood supply from thoracic vessels
- d) Majority of retrosternal goitres should be operated immediately

Correct Answer - A

Answer- A. All patients should undergo CT chest

Retro sternal goitre tends to arise from the slow growth of a multinodular gland down into the mediastinum.

It gets its blood supply from the mediastinum itself, not from the neck.

Investigations

A chest X-ray shows a soft tissue shadow under the sternum.

A radioactive iodine study is diagnostic.

CT scan/ MRI is useful and all patients should undergo it.

Surgical removal of retrosternal thyroid is done. (TOC)

Commonly it can be removed through an incision in the neck.

Ref- Bailey and Love, Short practice of surgery, 27th edition published in 2018 Pg 810

Sriram Bhat M, SRB's Manual of Surgery, 4th edition published in 2013, Pg 498

603. True for King's Criteria with acute fulminant liver failure except-

a) Age

b) Jaundice <7days

c) Serum bilirubin >17.5 mg/dl

d) INR >3.5

Correct Answer - B

Answer- B. Jaundice <7days

King's College criteria for liver transplantation in AHF.

- APAP-associated AHF-
 - pH < 7.3
 - or
 - INR > 6.5, serum creatinine > 3.4 mg/dl, and grade III-IV encephalopathy
 - All other causes of AHF
 - INR > 6.5
- Or
- Three of the following variables:**
1. Age > 40 years
 2. The cause is nonA, nonB hepatitis or idiosyncratic drug reaction
 3. Duration of jaundice before encephalopathy > 7 days
 4. INR > 3.5
 5. Serum bilirubin > 17.5 mg/dl
- APAP, acetaminophen; INR, international normalized ratio.

604. A patient who was posted for elective inguinal hernia surgery has history MI for which he underwent CABG. What will you do in pre operative assessment?

a) History + c/e + routine labs + angiography to look for stent patency

b) History + c/e + routine labs

c) History + c/e + routine labs + stress test

d) History +c/e + routine labs + V/Q scan

Correct Answer - C

Answer- C. History + c/e + routine labs + stress test

In the given scenario the patient had undergone CABG not an angioplasty, so the first option is ruled out.

With routine lab tests, the stress test should be included to check the cardiac function as pre operative assessment

605. History of trauma with a stab injury to the right lower chest with low BP and low pulse rate. It can be improved with IV fluids and after resuscitation in the trauma center patient's BP becomes normal. A chest X-ray showed clear lung fields. What will be the next step-

a) EFAST

b) Keep immediate chest tube

c) CECT abdomen

d) CECT chest

Correct Answer - A

Answer- A. EFAST

Investigations are driven by the cardiovascular status of the patient. In torso trauma, the best and most sensitive modality is a CT scan with intravenous contrast for blunt injury if the patient is stable. Routine investigation in the emergency department of injury to the chest is based on clinical examination, supplemented by chest radiography.

Ultrasound can be used to differentiate between contusion and the actual presence of blood.

Extended focused assessment with sonar for trauma (eFAST) is becoming the most common investigation.

Ref- Bailey and Love, Short practice of surgery, 27th edition published in 2018 Pg 366, 372

606. In a patient with parathyroid adenoma, how do we confirm the removal of the correct gland after surgery?

a) 50% reduction in PTH after 10mins

b) 50% reduction in PTH after 5mins

c) 25% reduction in PTH after 10mins

d) 25% reduction in PTH after 5mins

Correct Answer - A

Answer- A. 50% reduction in PTH after 10mins

Miami criteria

The IOPTH values at baseline (pre-incision and pre excision) and at 5 and 10 minutes after parathyroidectomy were reviewed according to the Miami criterion (>50% drop from highest baseline IOPTH level at 10 minutes after excision), criterion 1 (>50% drop from pre-incision IOPTH level at 10 minutes), criterion 2 (>50% drop from the highest baseline IOPTH level at 10 minutes and final IOPTH level within the reference range), criterion 3 (>50% drop from the highest baseline IOPTH level at 10 minutes and final IOPTH level less than the pre-incision value), criterion 4 (>50% drop from the highest baseline IOPTH level at 5 minutes), and criterion 5 (>50% drop from pre excision IOPTH level at 10 minutes).

Ref- <https://www.ncbi.nlm.nih.gov/pubmed/16702520>

607. Flap commonly used in breast reconstruction is?

- a) DIEP based on deep inferior epigastric vessels
- b) TRAM based on superior gluteal vessels
- c) Gluteal flap based on thoracodorsal artery
- d) Latissimus dorsi flap based on the inferior epigastric artery

Correct Answer - A

Answer- A. DIEP based on deep inferior epigastric vessels

DIEP flap (based on deep inferior epigastric vessels)

TRAM flap based on It is either superior pedicle based on the superior epigastric vessels or inferior pedicle based on the inferior epigastric vessels.

Latissimus dorsi muscle/myocutaneous flap It is based on the thoracodorsal artery, a branch of the subscapular artery

Superior gluteal flap based on superior gluteal vessels.

Ref- Bailey and Love, Short practice of surgery, 27th edition published in 2018 Pg 879

Sriram Bhat M, SRB's Manual of Surgery, 4th edition published in 2013, Pg 350, 594

608. A 30-year-old man is presented with cramping gluteal pain after walking 500m. Which is the vessel involved during this?

a) Arterial disease with aortoiliac involvement

b) Arterial disease with femoral artery involvement

c) Femoral venous insufficiency

d) None

Correct Answer - A

Answer- A. Arterial disease with aortoiliac involvement

The muscle group affected by claudication is classically one anatomical level below the level of arterial disease and is usually felt in the calf because the superficial femoral artery is the most commonly affected artery (70% of cases).

Aorto-iliac disease (30% of cases) may cause thigh or buttock claudication. Buttock claudication in association with sexual impotence resulting from arterial insufficiency is eponymously called Leriche's syndrome. It is very rare.

Ref- Bailey and Love, Short practice of surgery, 27th edition published in 2018 Pg 943

609. Which is the most common pancreatic endocrine neoplasm?

a) Insulinoma

b) Gastrinoma

c) VIPoma

d) Glucagonoma

Correct Answer - A

Answer- A. Insulinoma

Insulinoma (70-80%) > Non functional tumours (30- 35%) > gastrinoma (20- 25%)

610. An elderly man with a long-standing mole over the face which is increasing in size and showing irregular borders. What will be the diagnosis?

a) Superficial spreading melanoma

b) Lentigo maligna

c) Acral melanoma

d) Nodular melanoma

Correct Answer - A

Answer- A. Superficial spreading melanoma

Superficial spreading melanoma

- This is the most common presentation (70%) usually arising in a pre-existent naevus after several years of slow change, followed by rapid growth in the preceding months before presentation.

Nodular melanoma (NM) Nodular melanoma accounts for 15% of all MM.

- Typically appear as blue/black papules, 1-2 cm in diameter, and because they lack the horizontal growth phase.

Lentigo maligna melanoma-

- Presents as a slow-growing, variegated brown macule on the face, neck or hands of the elderly.
- **Acral lentiginous melanoma (ALM)** ALM affects the soles of feet and palms of hands.
- It usually presents as a flat, irregular macule in later life.

Ref- Bailey and Love, Short practice of surgery, 27th edition published in 2018 Pg 610