

OneShot 4.0

# Anatomy

DBMCI · 2026



# ANATOMY

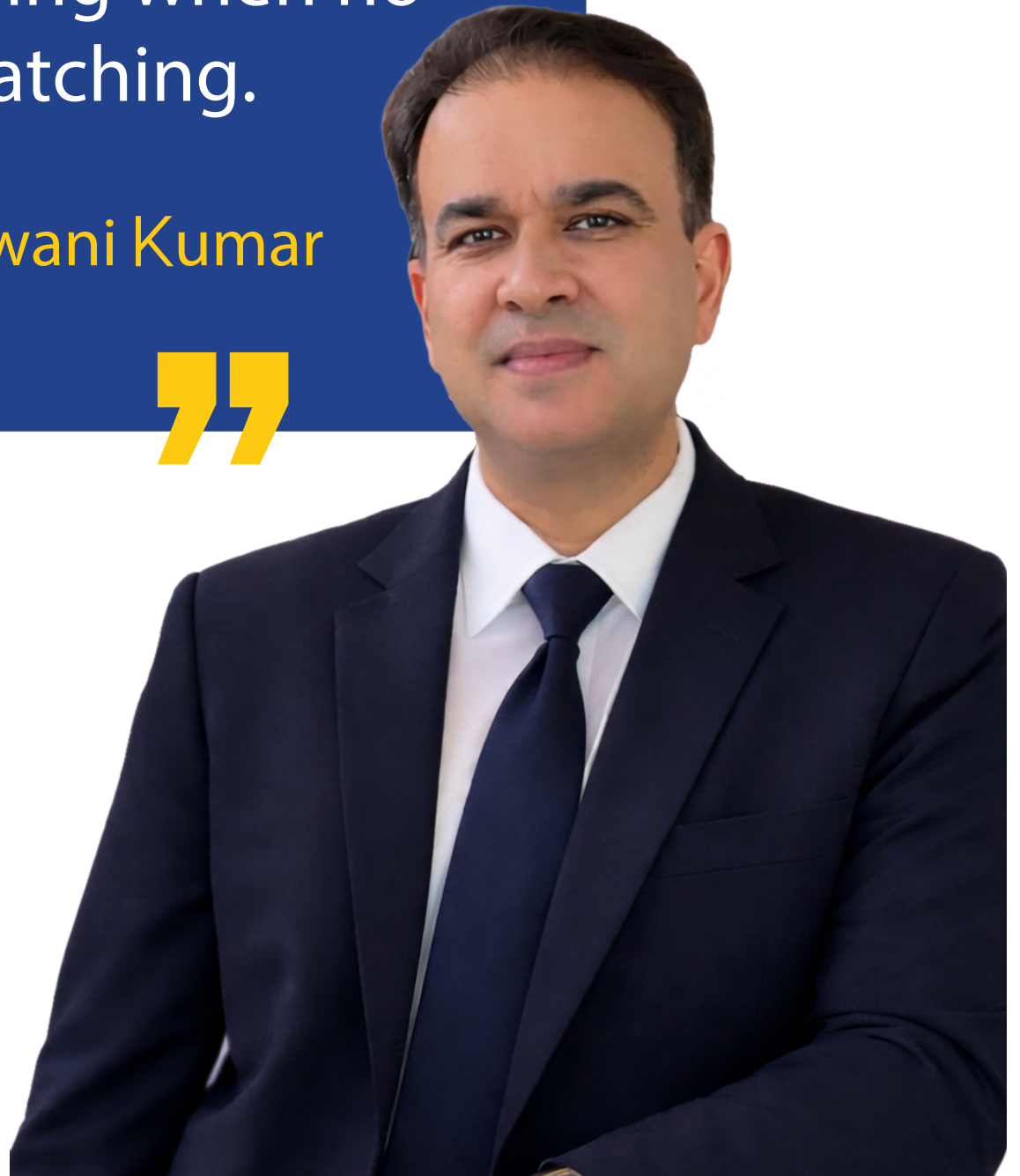Sl. No.	CHAPTER	Page No.
1.	<i>Embryology</i>	3
2.	<i>Upper Limb</i>	17
3.	<i>Lower Limb</i>	31
4.	<i>Head, Neck &amp; Face</i>	51
5.	<i>Neuroanatomy</i>	65
6.	<i>Abdomen &amp; Perineum</i>	77

“

The most powerful transformations happen not in the moments of victory, but in the quiet, unseen decisions to keep going when no one's watching.

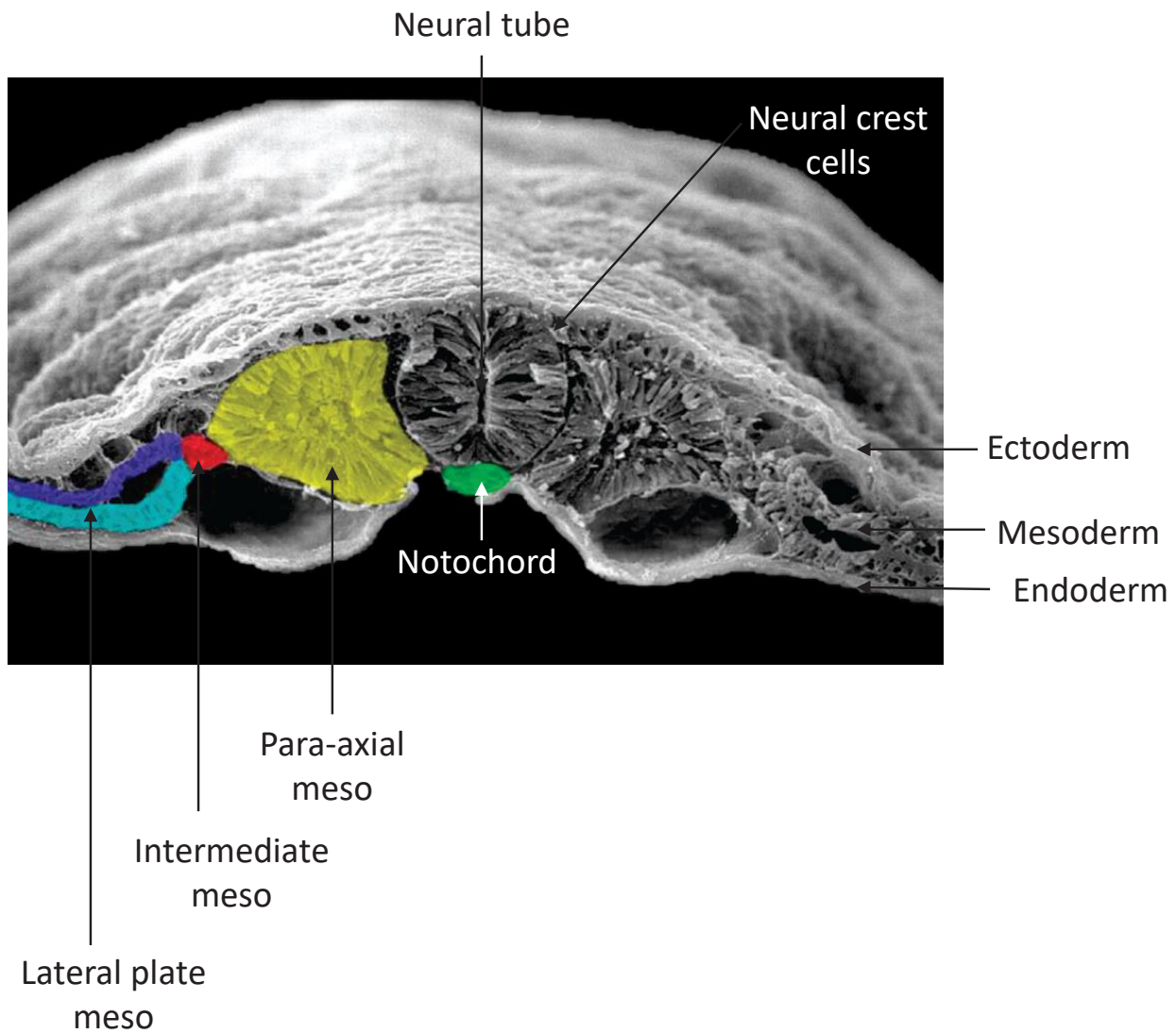
- Dr. Ashwani Kumar

”



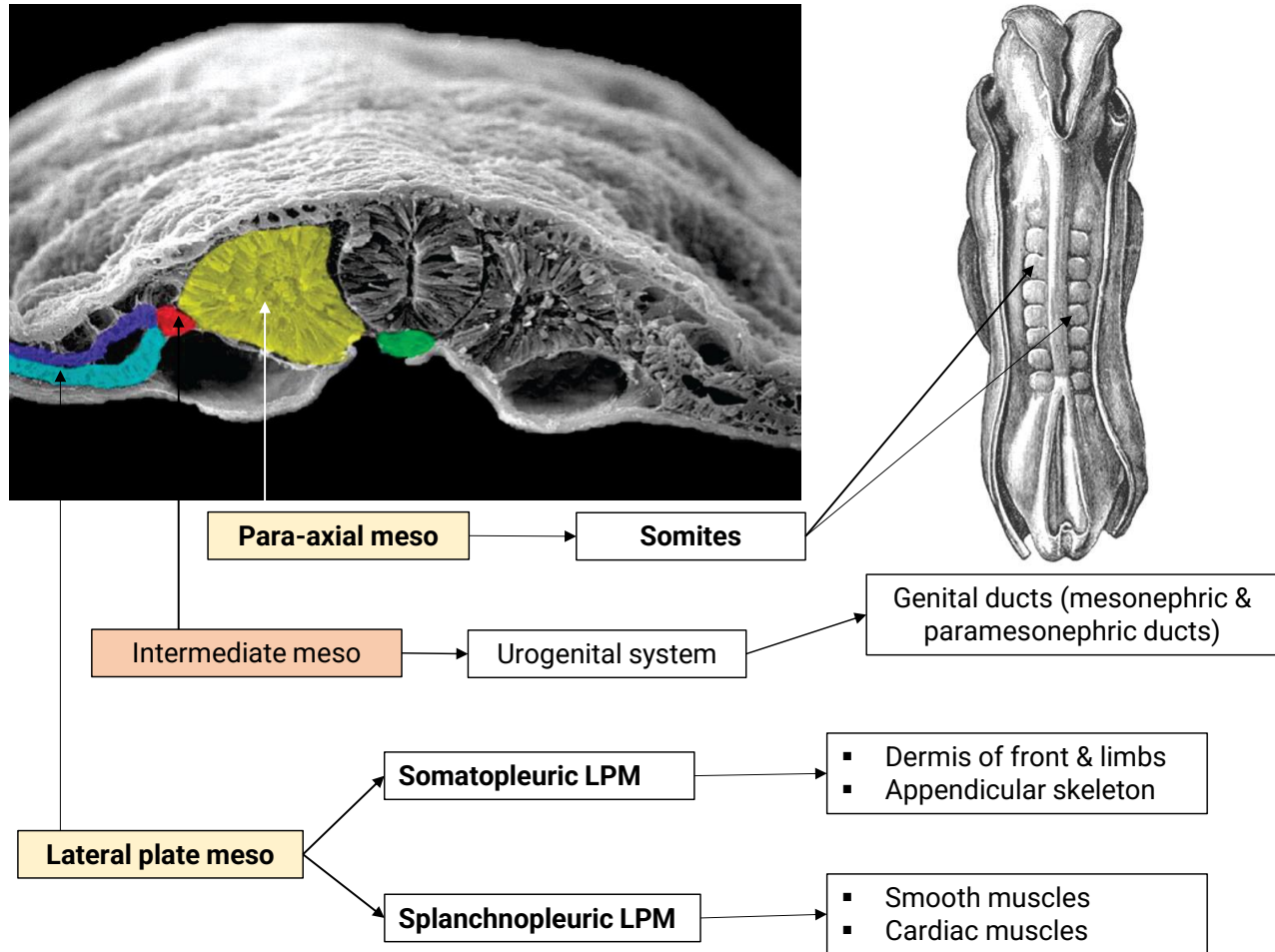
# EMBRYOLOGY

## GENERAL EMBRYOLOGY



**Somites derivatives**

- ✓ Dermis of back
- ✓ Axial skeleton
- ✓ Skeletal muscles (except pharyngeal arches)





**Neural tube**

*Key word- CNS*

- Brain & spinal cord
- Oligodendrocytes
- Astrocytes
- Ependymal cells
- Retina & pigment

**Neural crest cells**

*Key word- PNS*

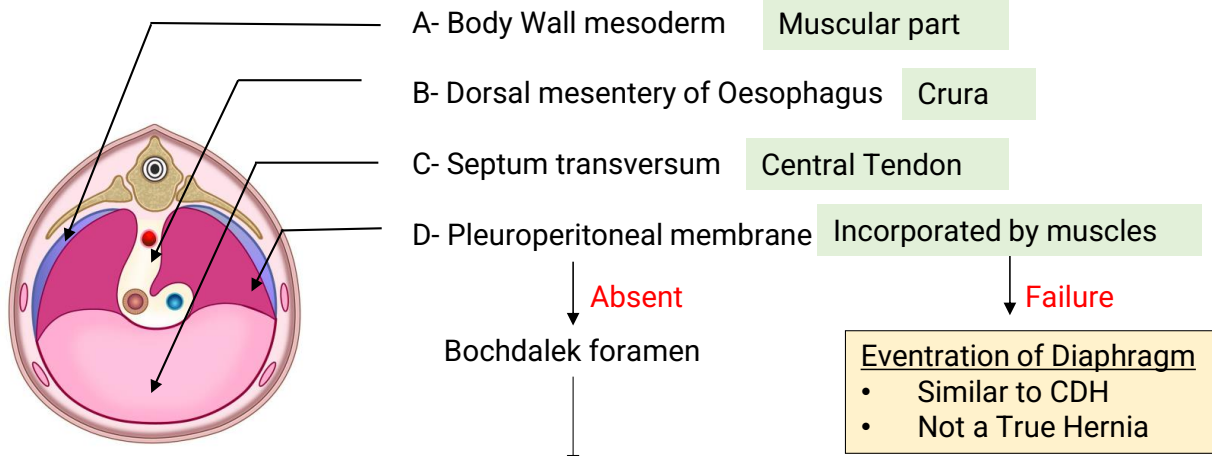
- All ganglion
- Enteric plexus
- Schwann cells
- Adrenal medulla
- Parafollicular C cells
- Melanoblast/cyte
- Skull bones (most)
- Dentine
- Pharyngeal arch cartilage
- Dermis of H&N
- Conotruncal septum

**Notochord**

Remnants

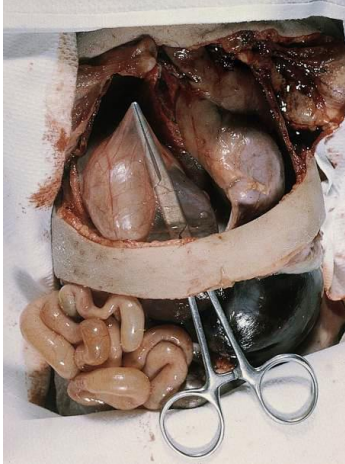
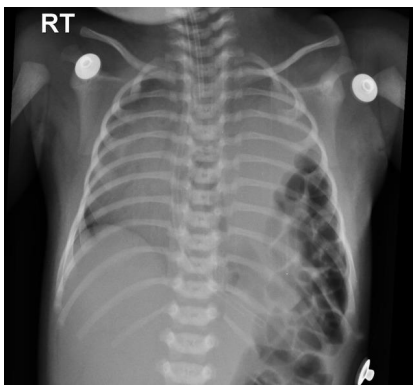
- Nucleus pulposus
- Apical ligament of dens
- Tectorial membrane

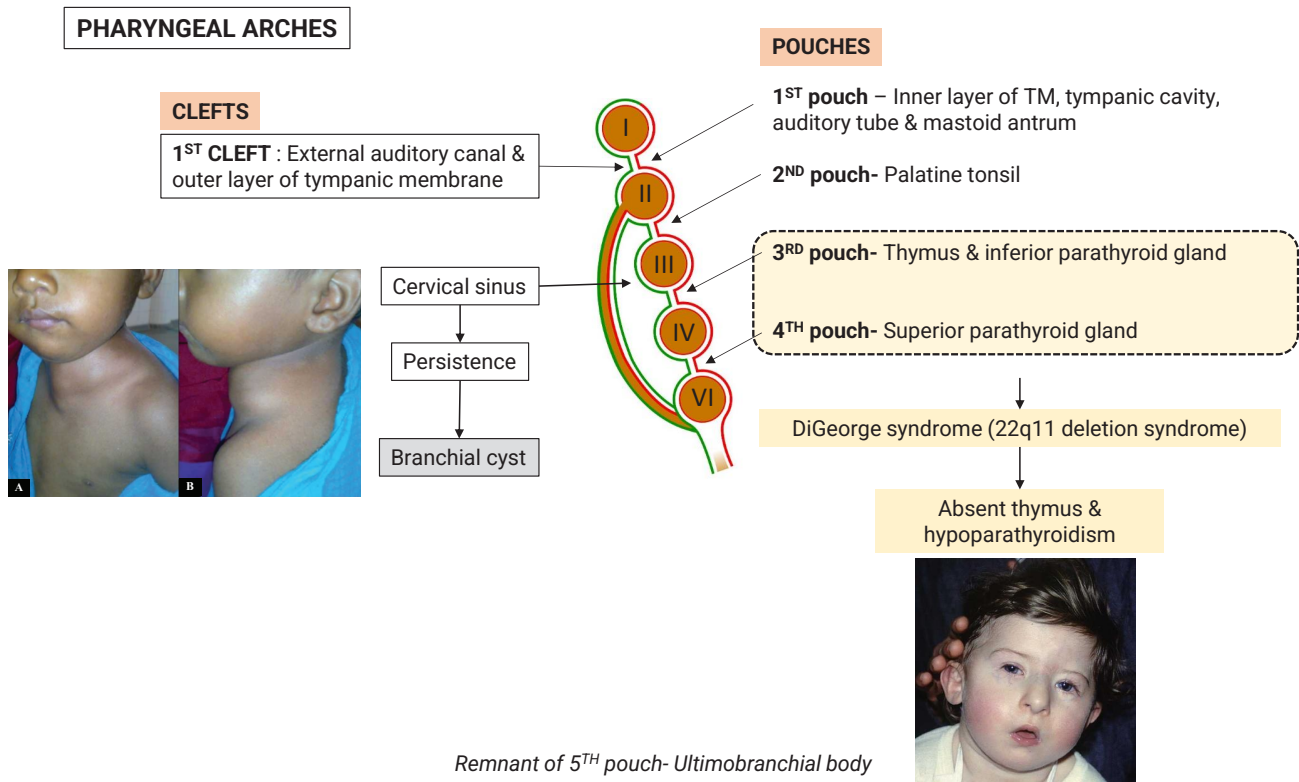
**DIAPHRAGM DEVELOPMENT**



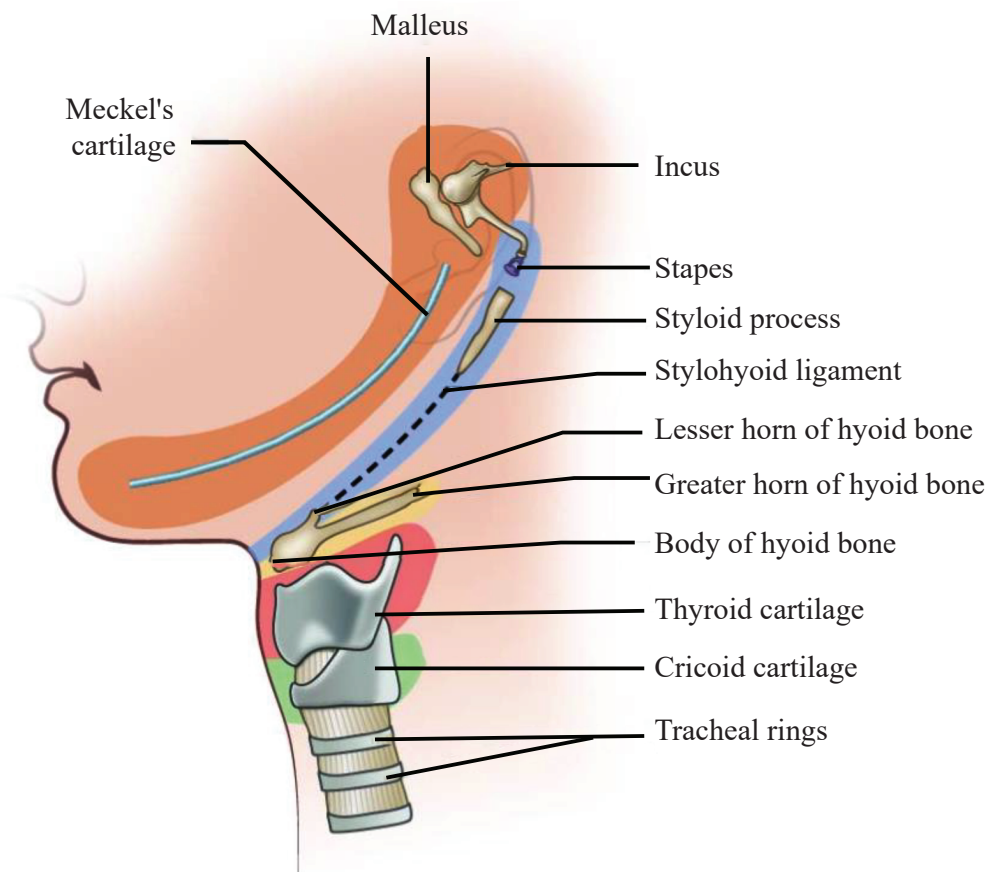
**Congenital Diaphragmatic Hernia**

- Common on left side
- Complication → left lung Hypoplasia



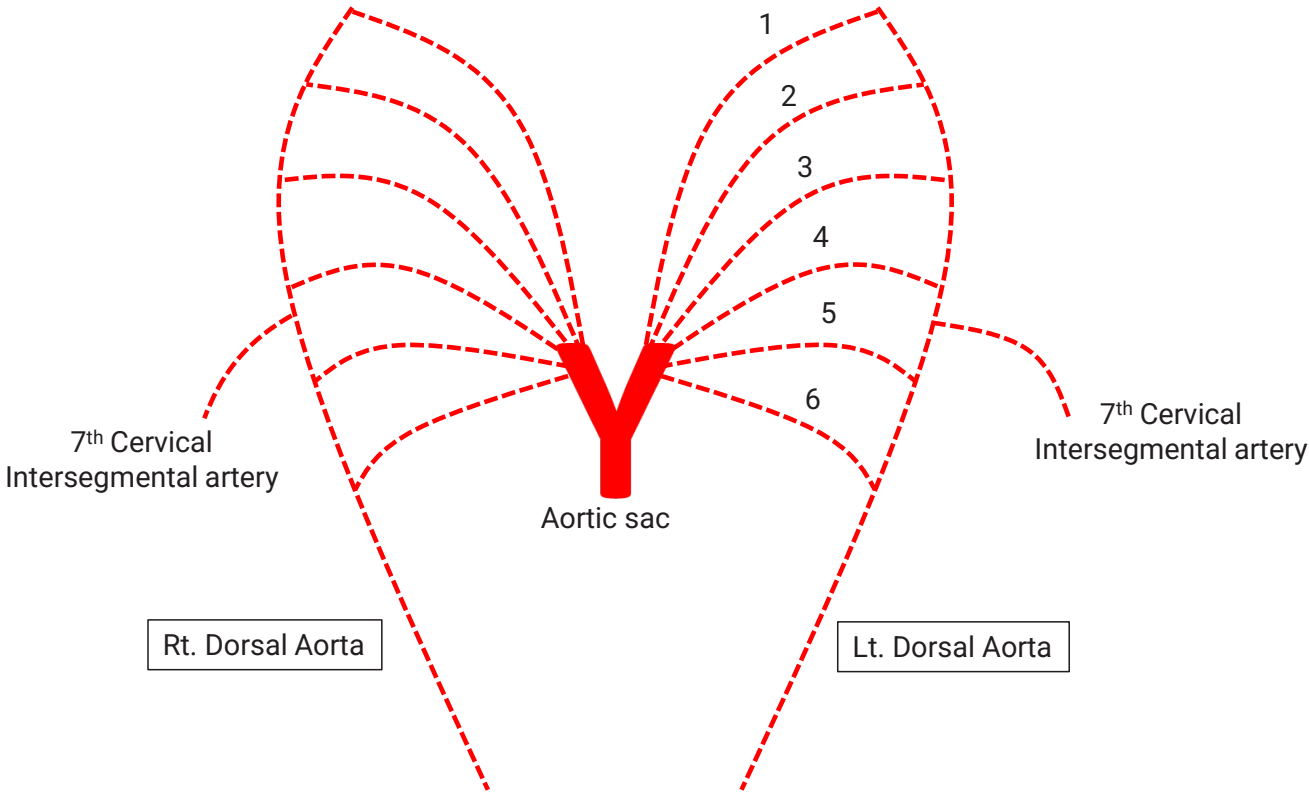


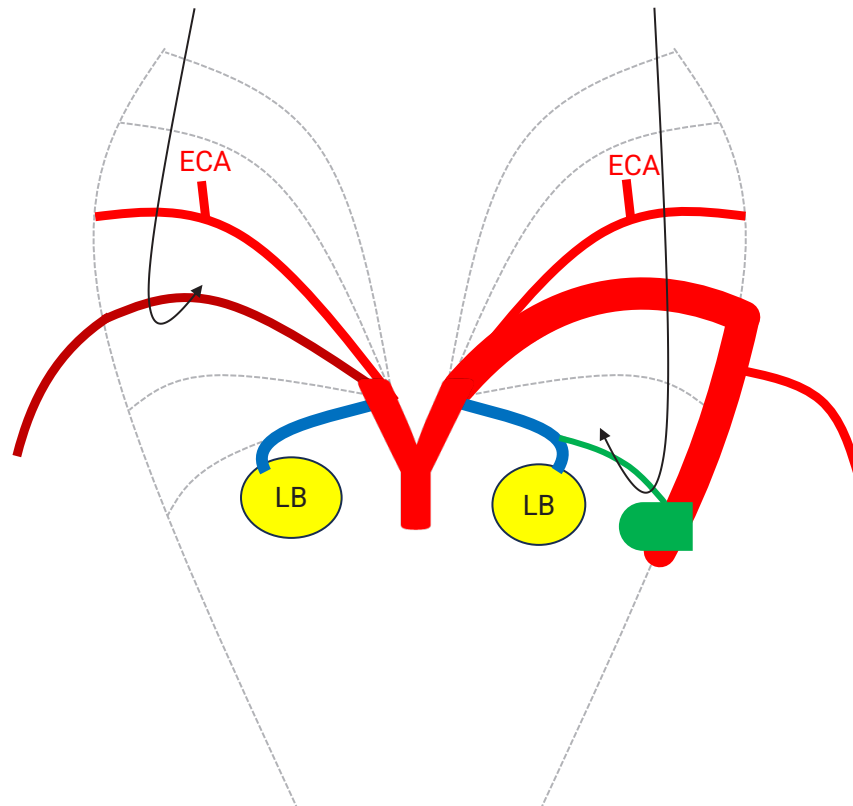
**PHARYNGEAL ARCH CARTILAGES**





**PHARYNGEAL ARCH ARTERIES**





Left RLN *hooks under the left sixth arch artery which persists in extra-uterine life* as the ductus arteriosus, a fibrous remnant. On the right side, neither the sixth nor fifth arch arteries persist.

#### Arch of Aorta

- Aortic Sac
- Left horn of AS
- Left 4<sup>th</sup> Arch artery

#### Brachiocephalic trunk

Right horn of AS

#### CCA

Proximal part of 3<sup>rd</sup> arch artery

#### ICA

Distal part of 3<sup>rd</sup> arch artery

#### Left Subclavian artery

Left 7<sup>th</sup> cervical intersegmental artery

#### Right subclavian artery

Right 4<sup>th</sup> arch artery  
Right 7<sup>th</sup> cervical intersegmental artery

#### Pulmonary artery

Proximal part of 6<sup>th</sup> arch artery

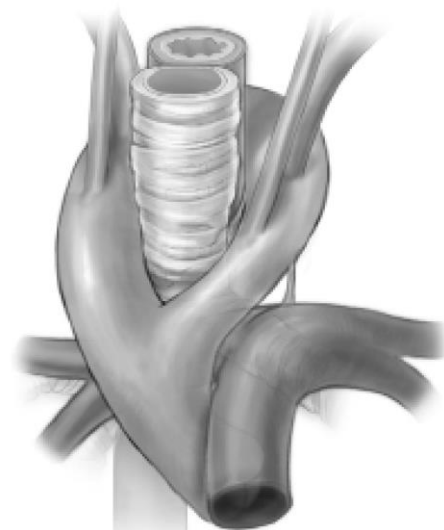
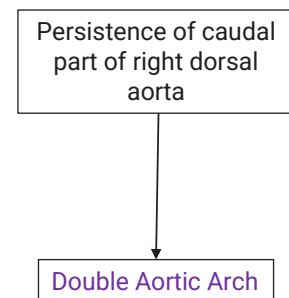
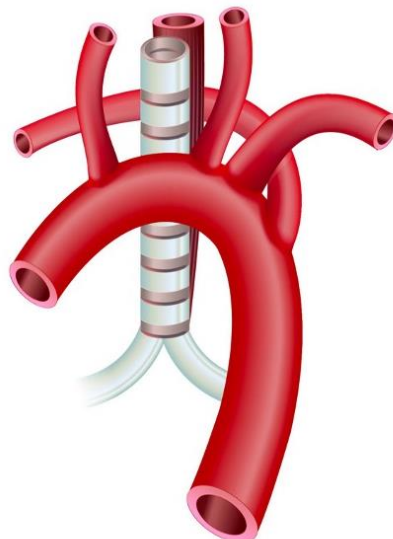
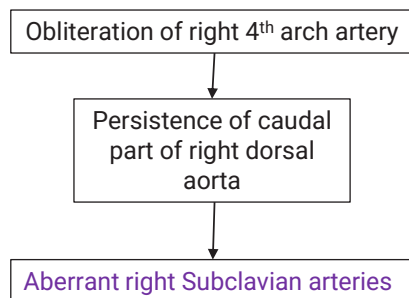
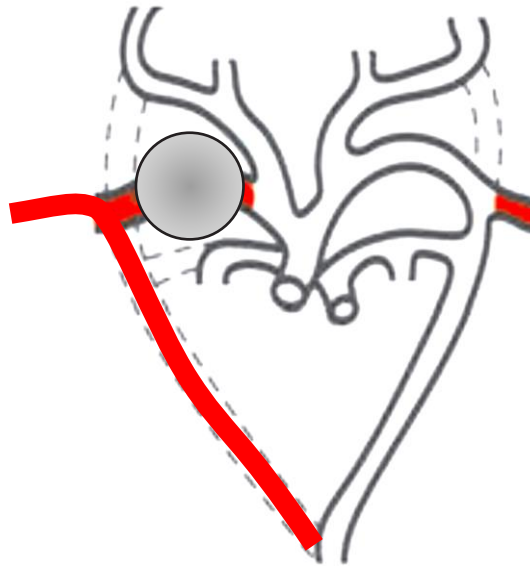
#### Ductus arteriosus

Distal part of left 6<sup>th</sup> arch artery

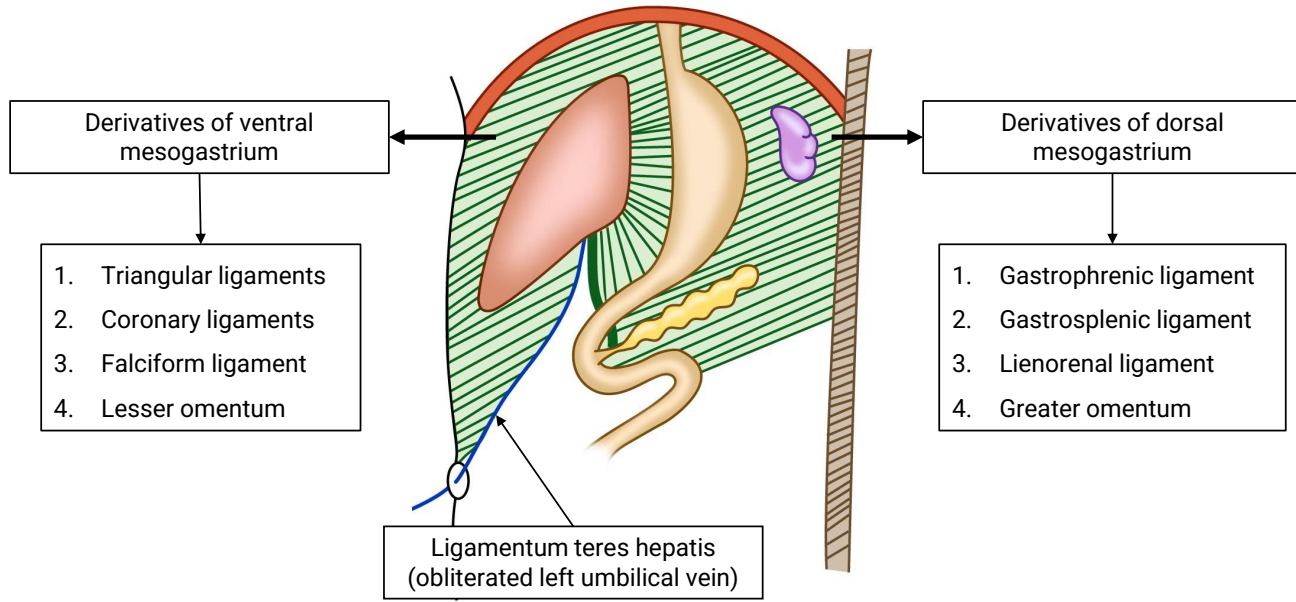
## PHARYNGEAL ARCH ARTERIES- SUMMARY

Aortic Arch	Derivatives
1 <sup>st</sup> arch	Maxillary artery (transient)
2 <sup>nd</sup> arch	Hyoid and stapedia artery (transient)
3 <sup>rd</sup> arch	Common carotid artery and proximal internal carotid artery
4 <sup>th</sup> arch	Left - Arch of aorta Right - Part of R subclavian artery
5 <sup>th</sup> arch	Degenerated
6 <sup>th</sup> arch	Left - proximal left pulmonary artery, distal ductus arteriosus Right - right pulmonary artery

## ANOMALIES :

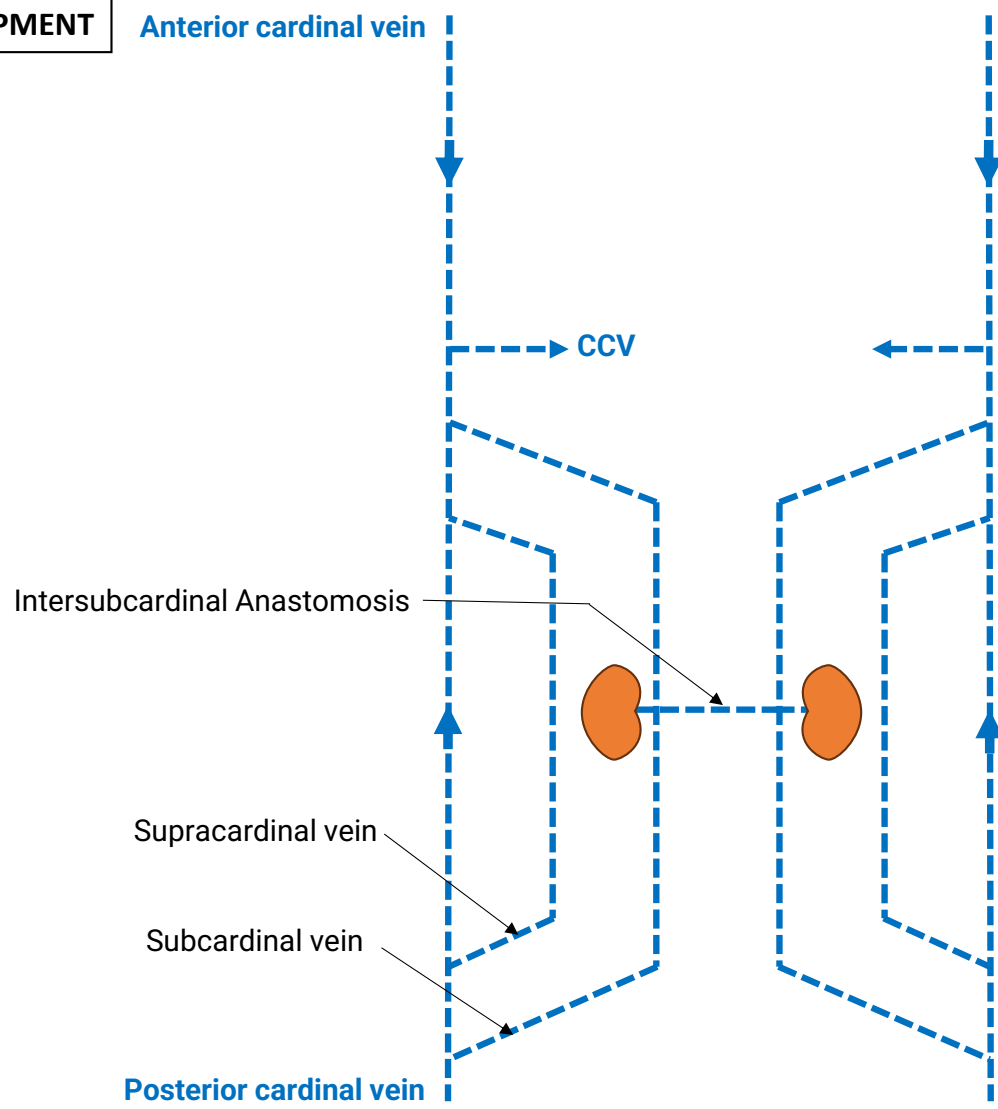


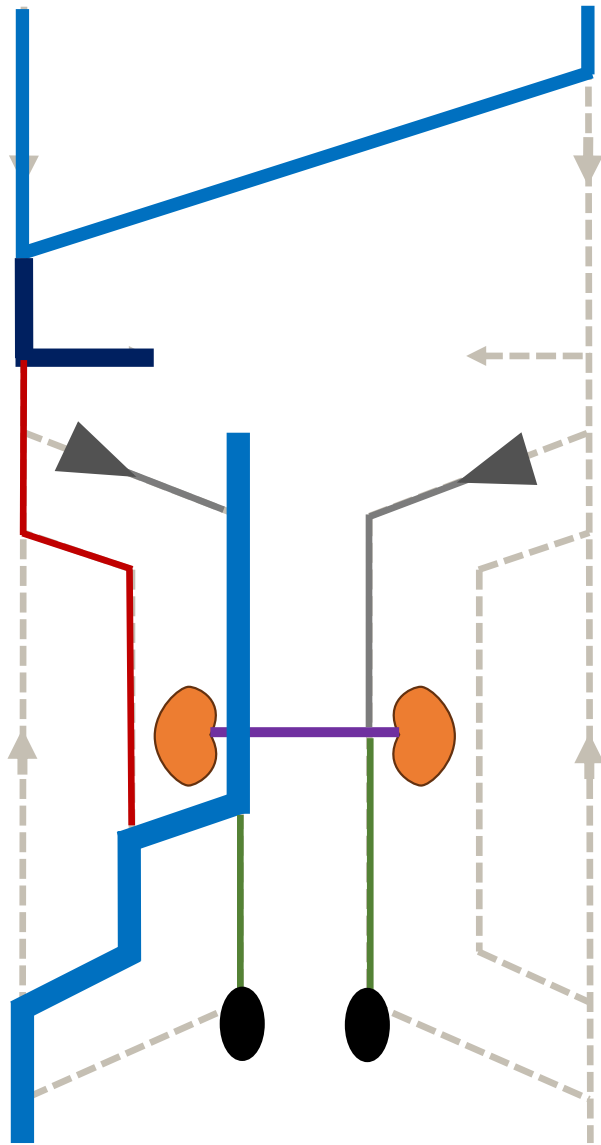
**MESOGASTRIUM & THEIR DERIVATIVES**





**VENOUS DEVELOPMENT**





**Rt. Brachiocephalic vein**  
Rt. ACV  
**Lt. Brachiocephalic vein**  
Lt. ACV + Oblique Anastomosis

**Superior Vena cava**  
Rt. ACV + Rt. CCV

**Inferior Vena Cava**  
Rt. PCV + Rt. Supracardinal vein + Rt. Subcardinal vein

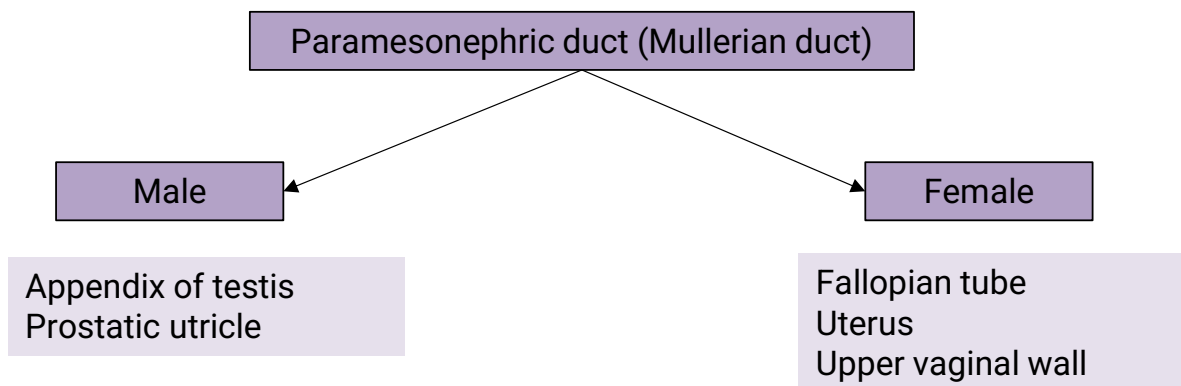
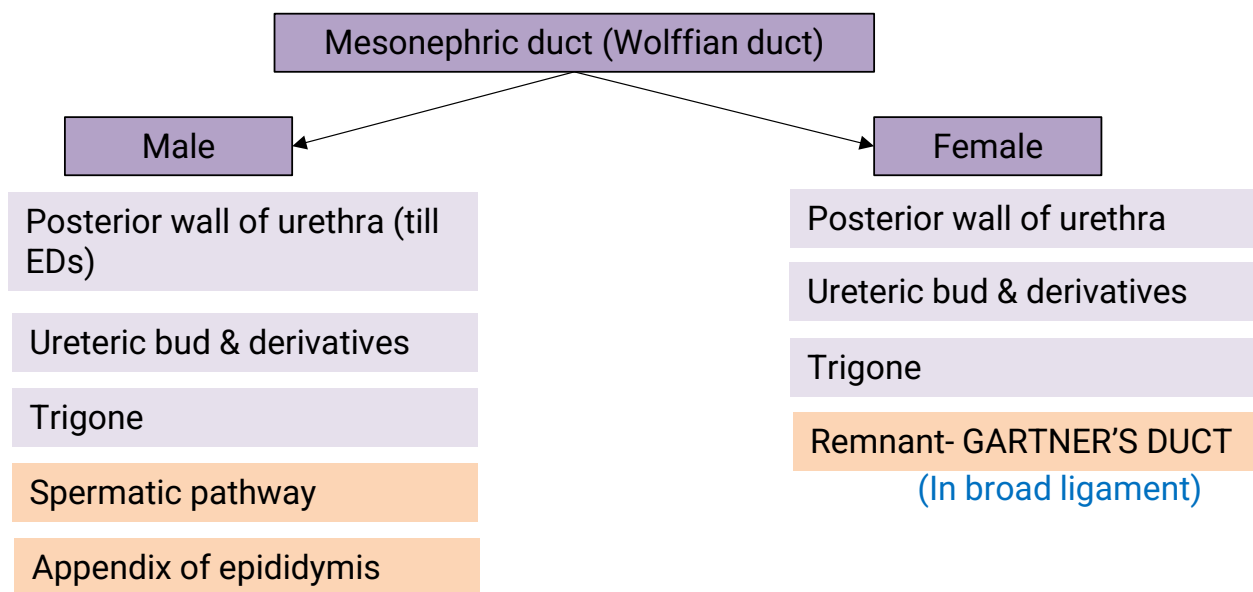
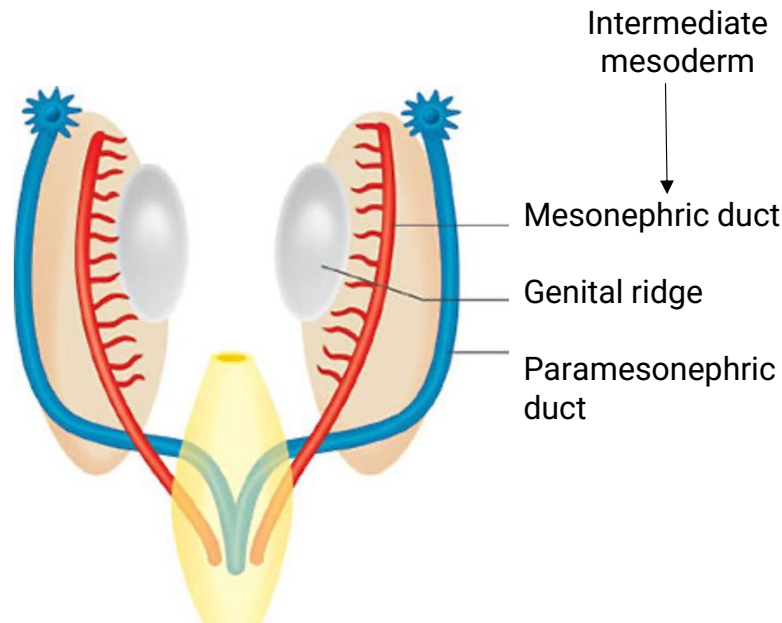
**Azygos vein**  
Rt. Supracardinal vein > Rt. PCV

**Rt. Renal vein**  
Rt. Mesonephric vein  
**Lt. Renal vein**  
Lt. Mesonephric vein + Intersubcardinal anastomosis

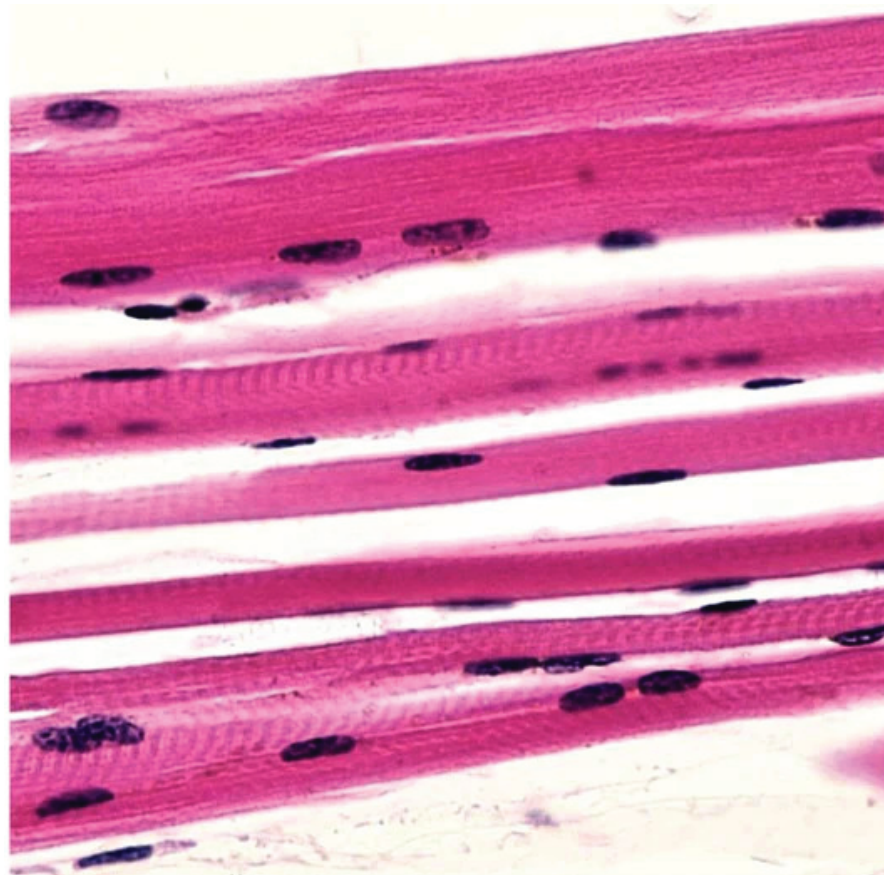
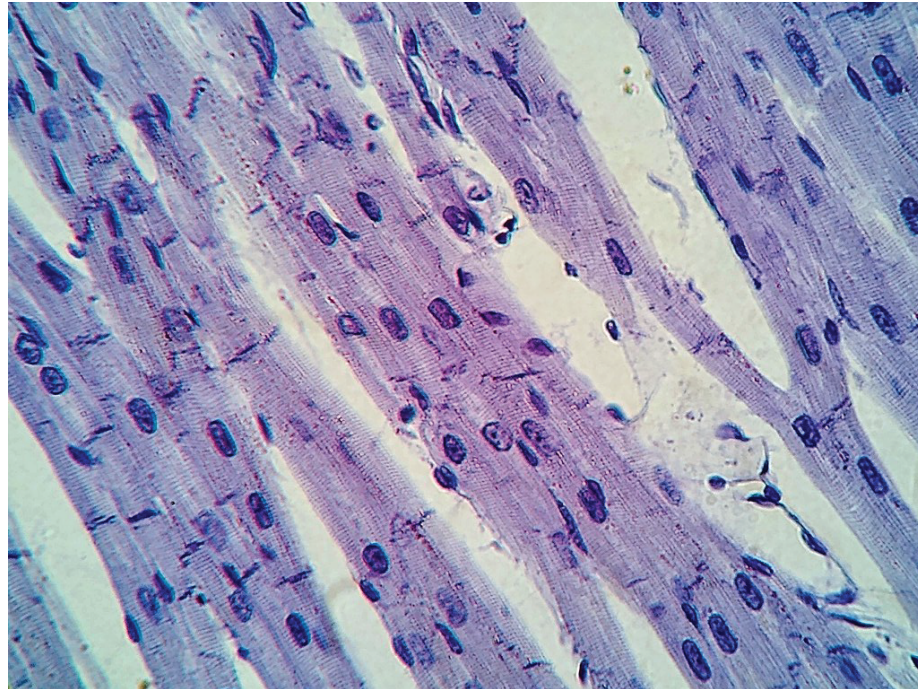
**Gonadal vein**  
Caudal part of Subcardinal vein  
**Adrenal vein**  
Cranial part of Subcardinal vein




DERIVATIVES OF THE GENITAL DUCTS



HISTOLOGY



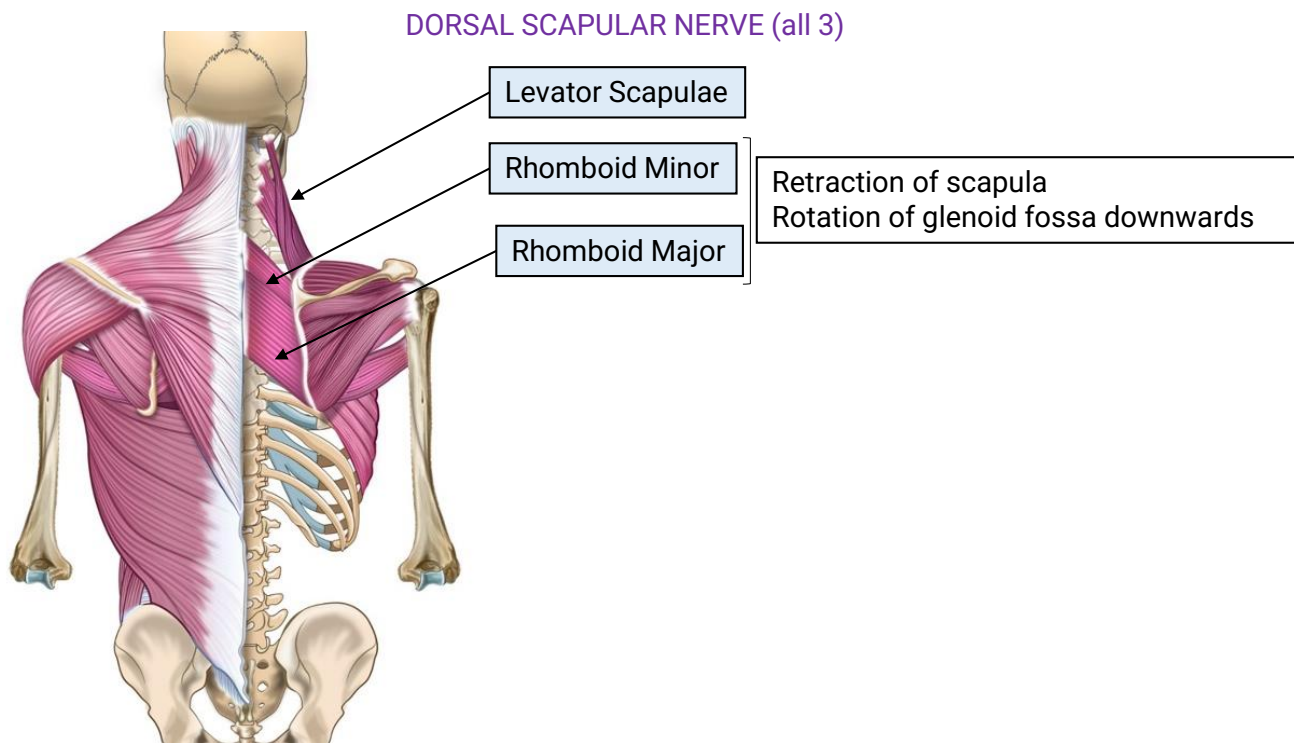




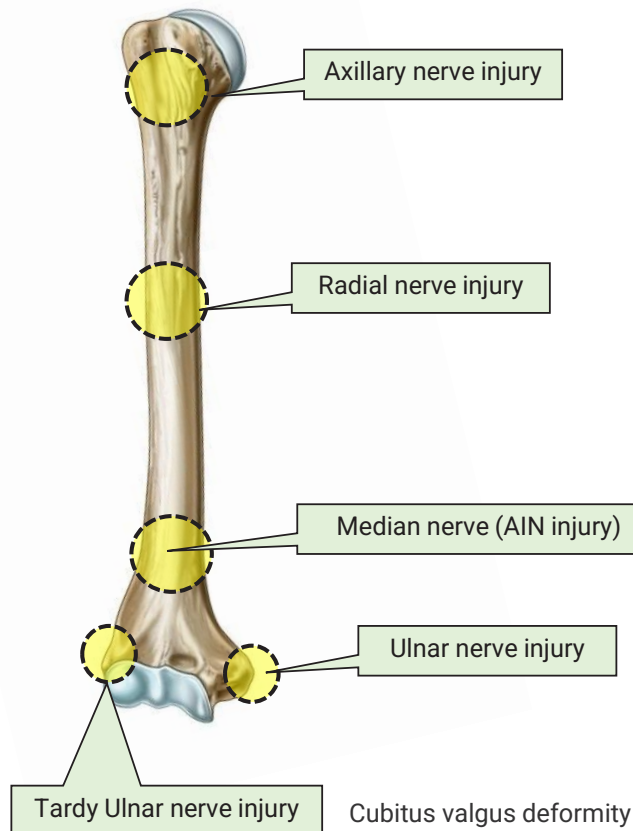
## NOTES

## UPPER LIMB

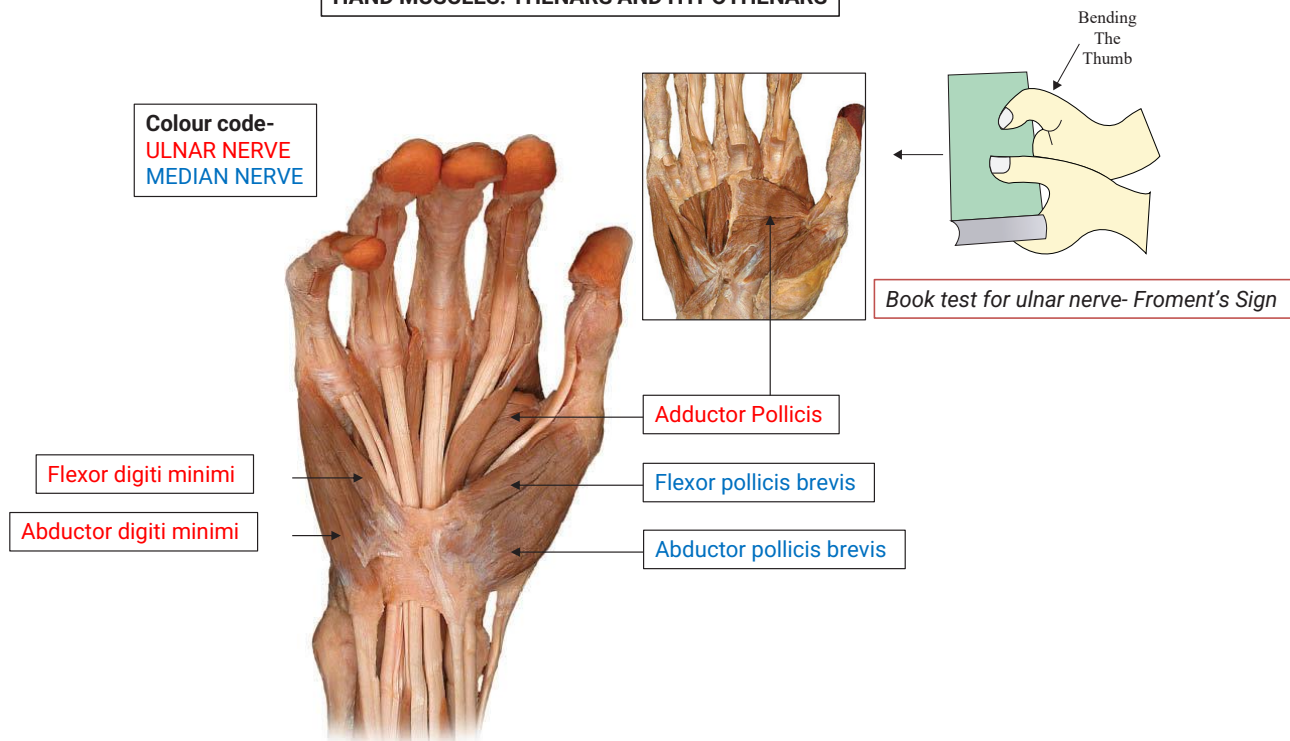
### VERTEBROSCAPULAR MUSCLES



**HUMERAL FRACTURES & NERVE INJURIES**

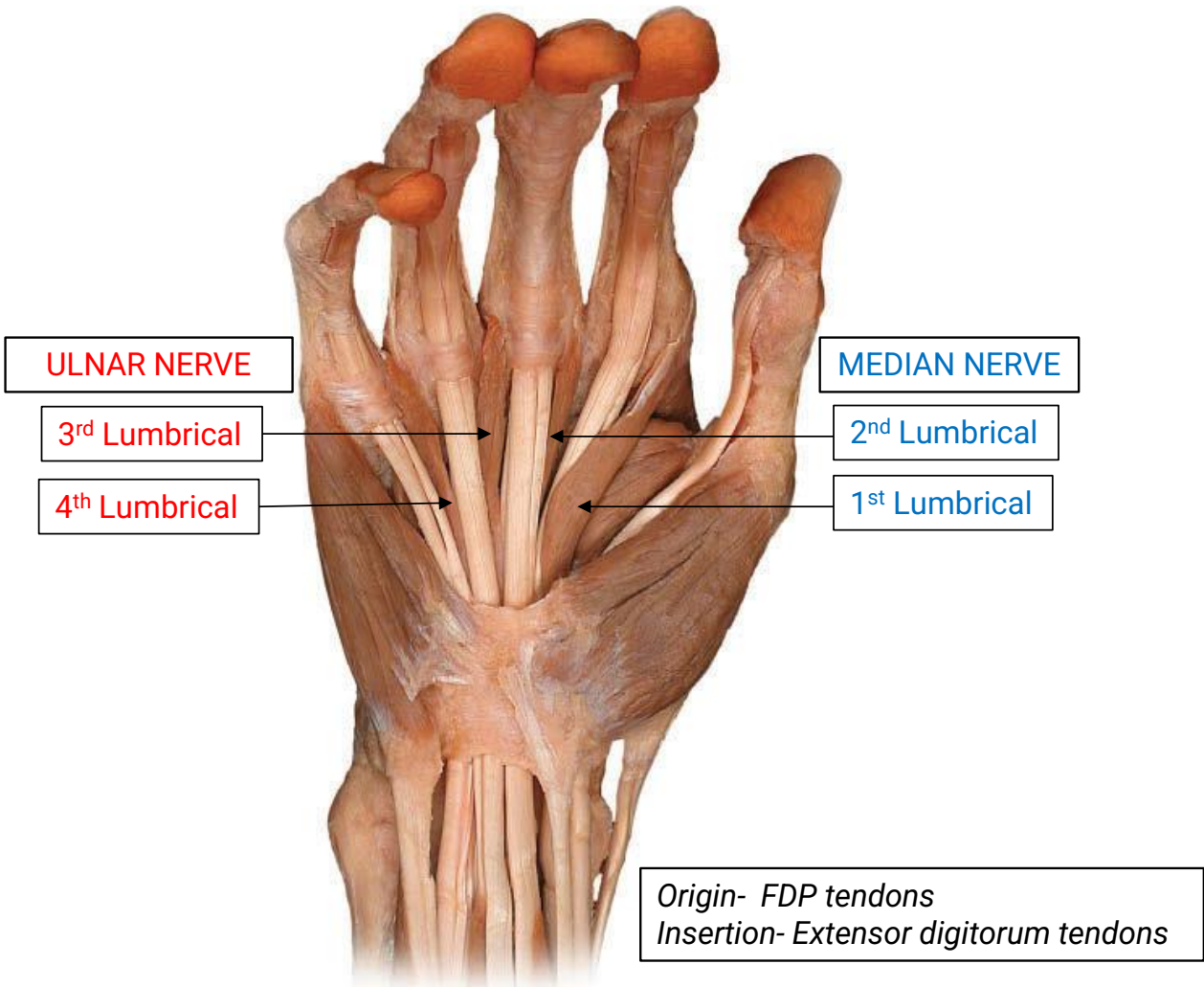


**HAND MUSCLES: THENARS AND HYPOTHENARS**



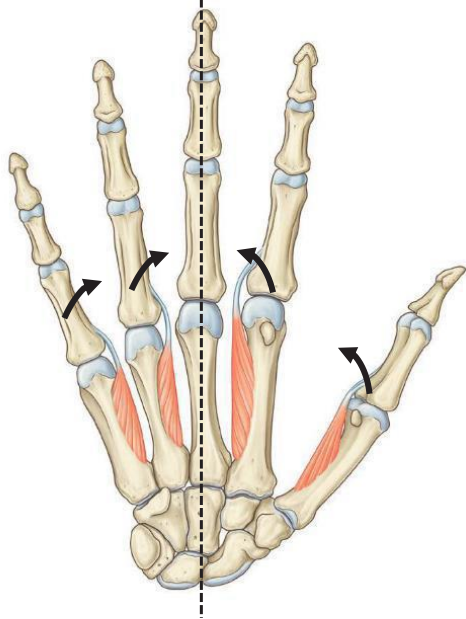


HAND MUSCLES: LUMBRICALS

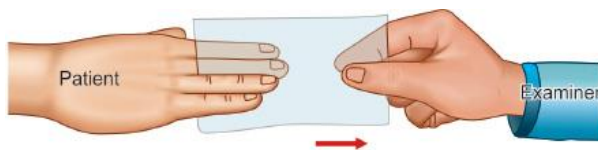


INTEROSSEI- ULNAR NERVE

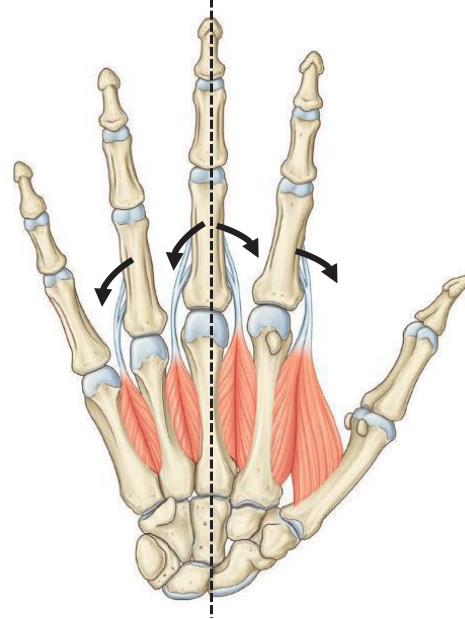
PALMAR INTEROSSEI P-AD



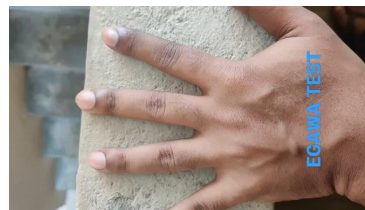- Unipennate
- Absent on middle finger
- Thumb PI may not be present
- TEST- CARD Test

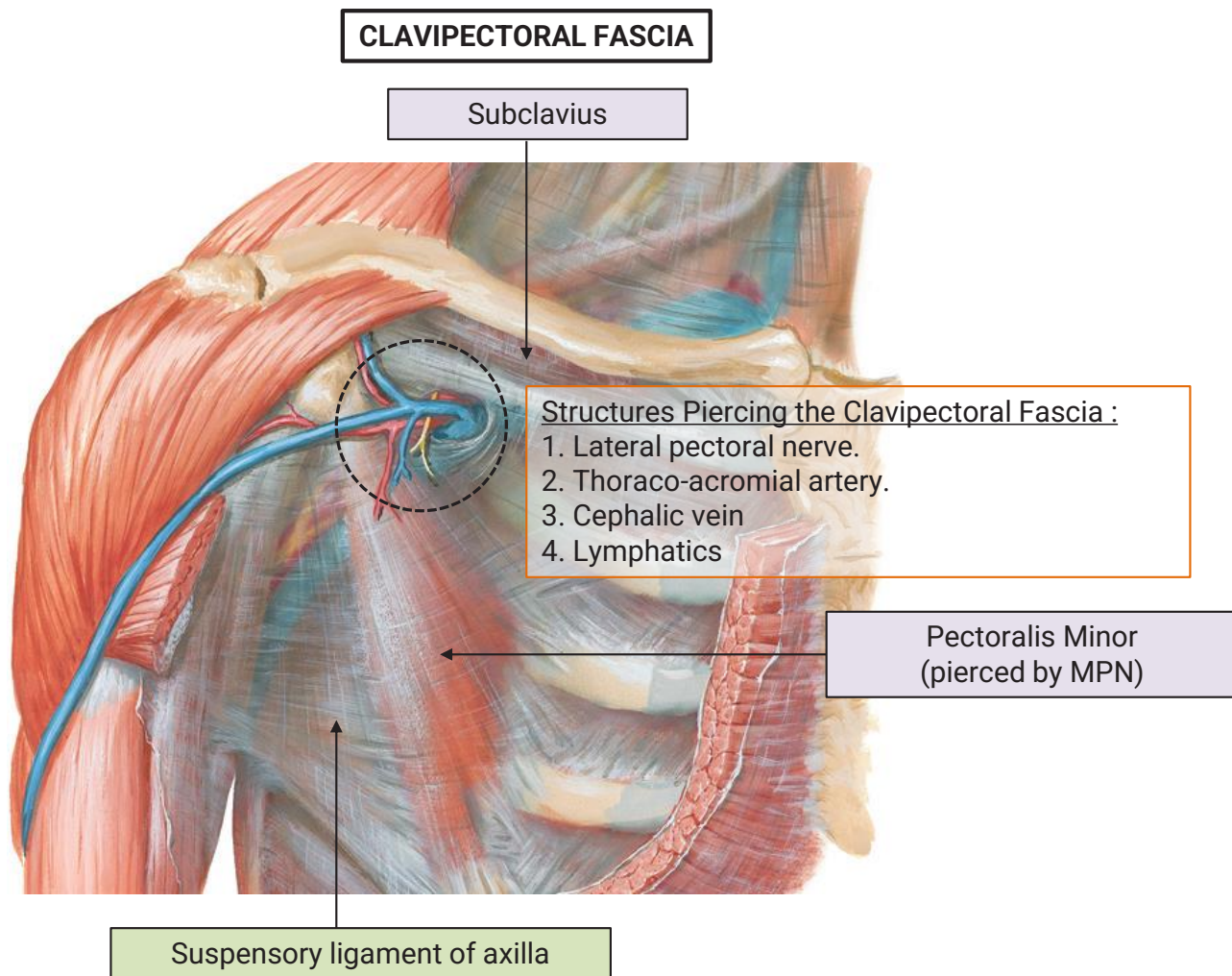


DORSAL INTEROSSEI D-AB

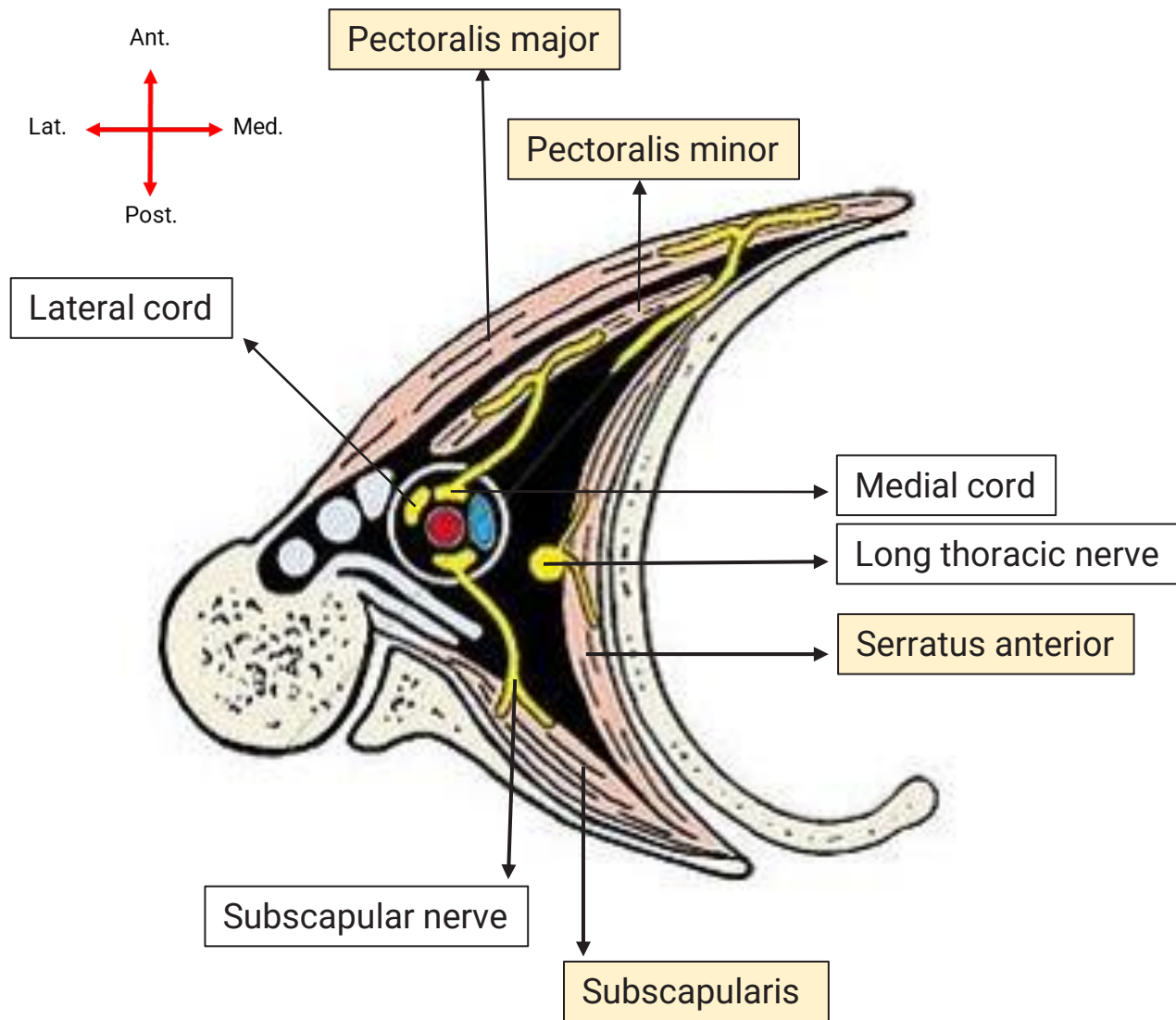


- Bipennate
- Absent on thumb & Little finger
- Middle finger- 2<sup>nd</sup> & 3<sup>rd</sup> dorsal int.
- TEST- EGAWA Test



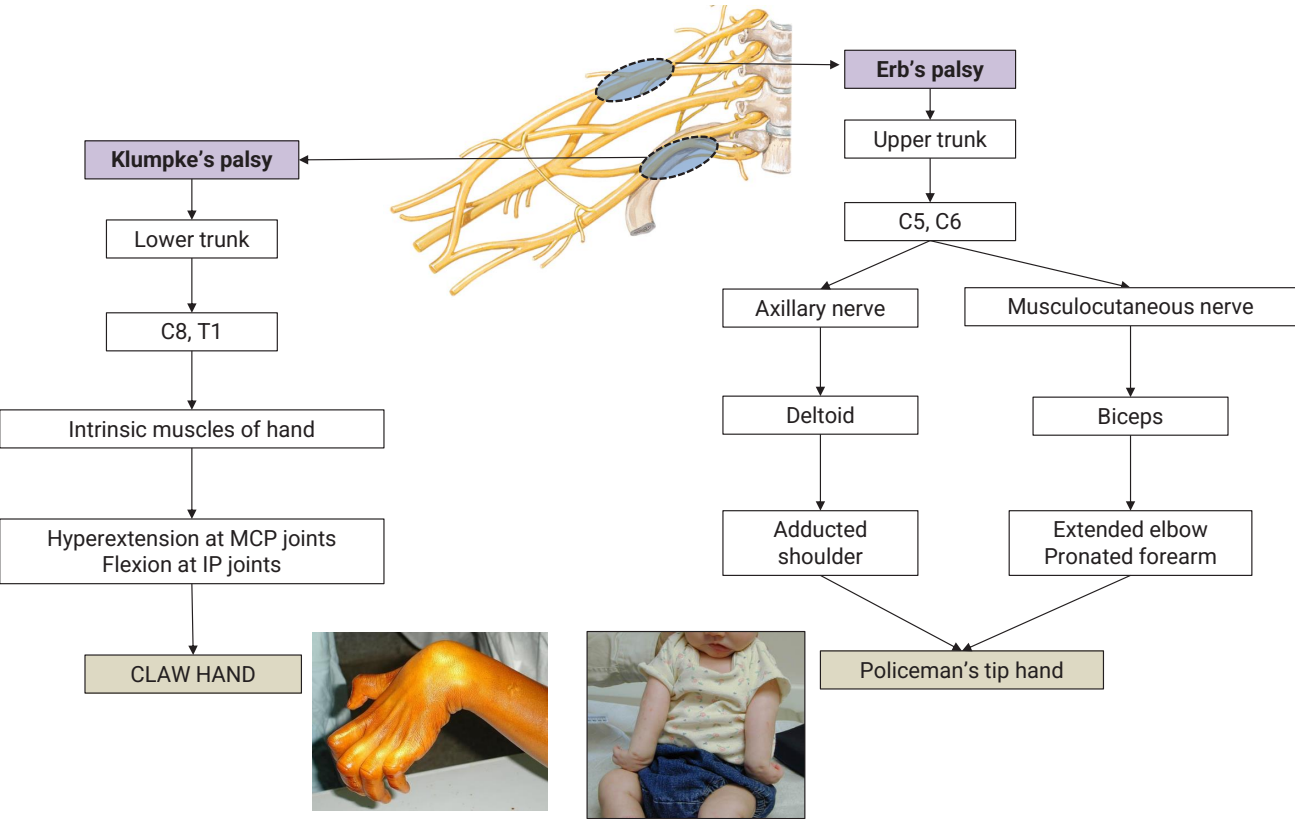
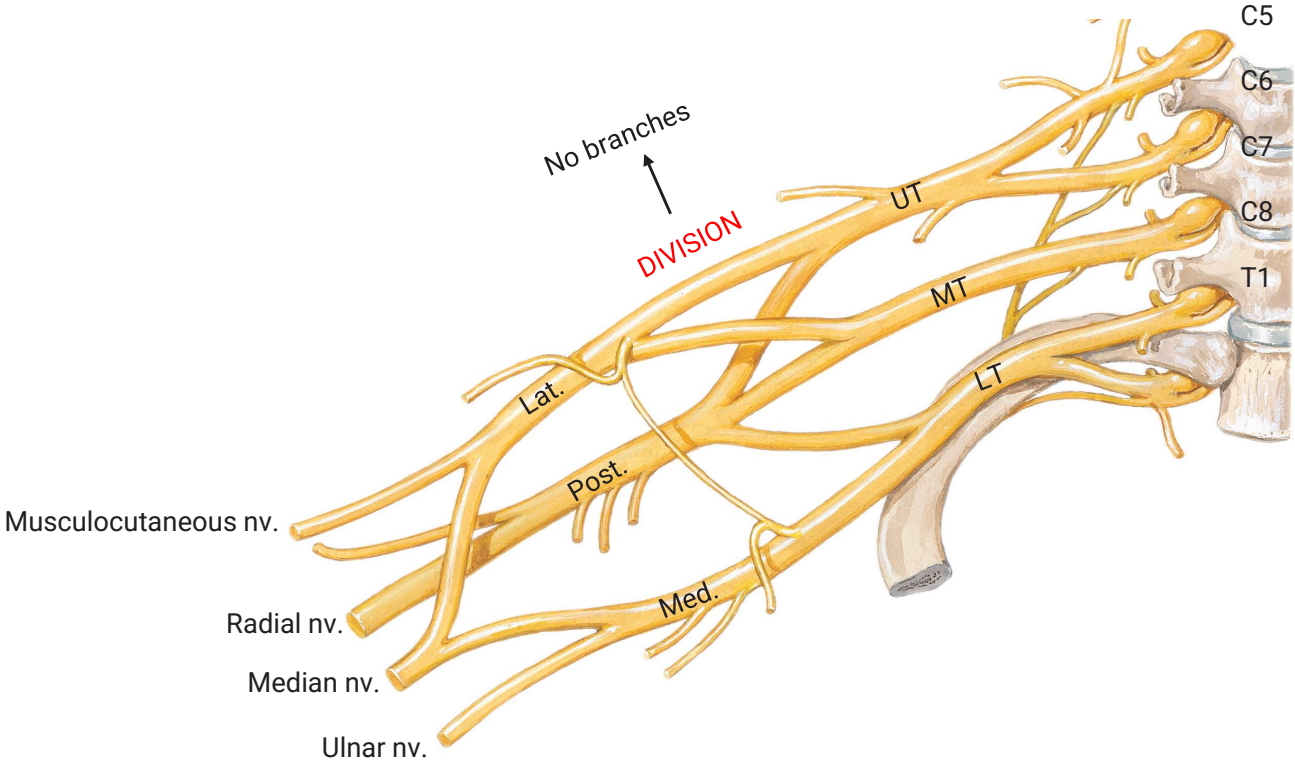


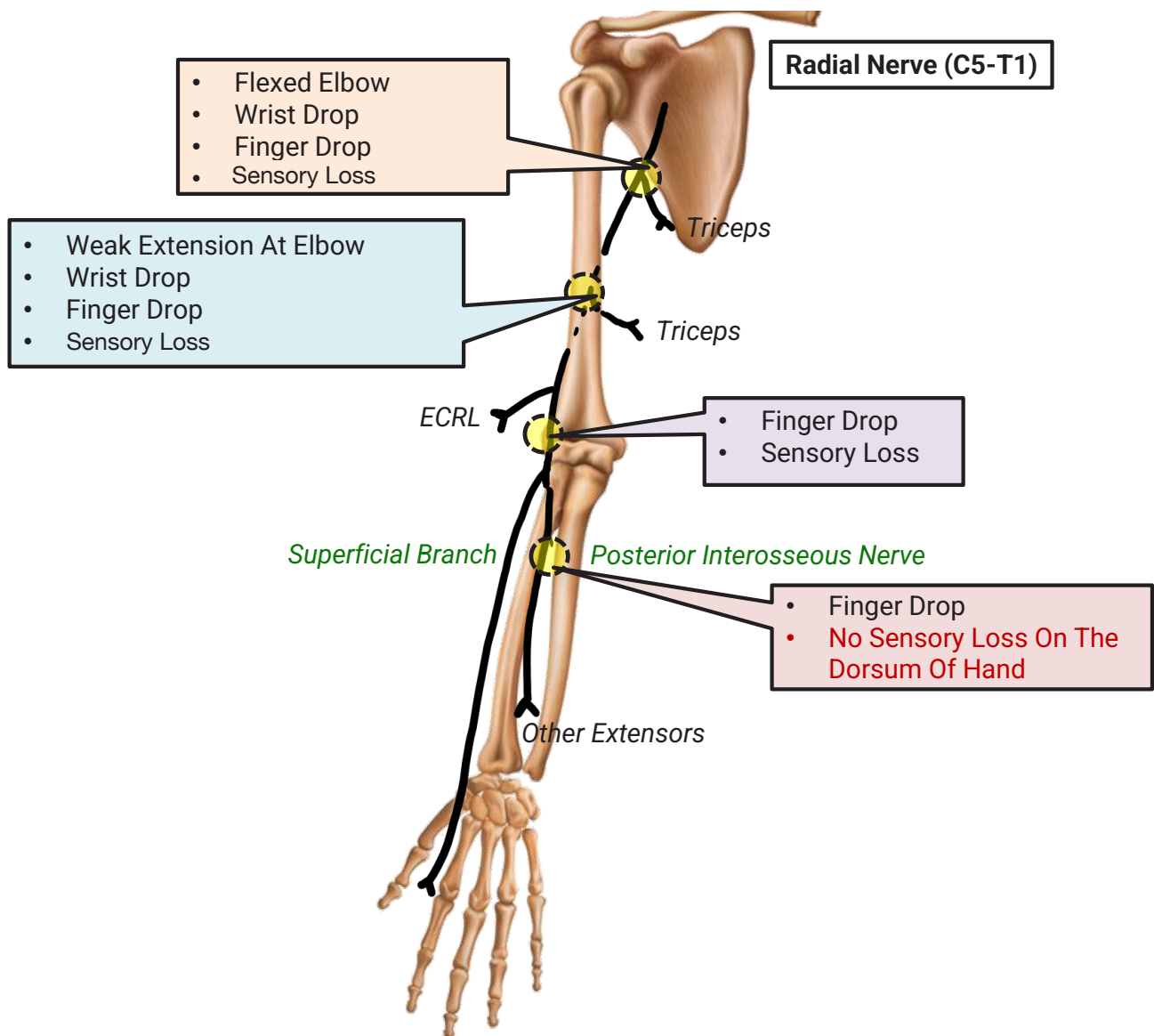
**AXILLA: T.S**

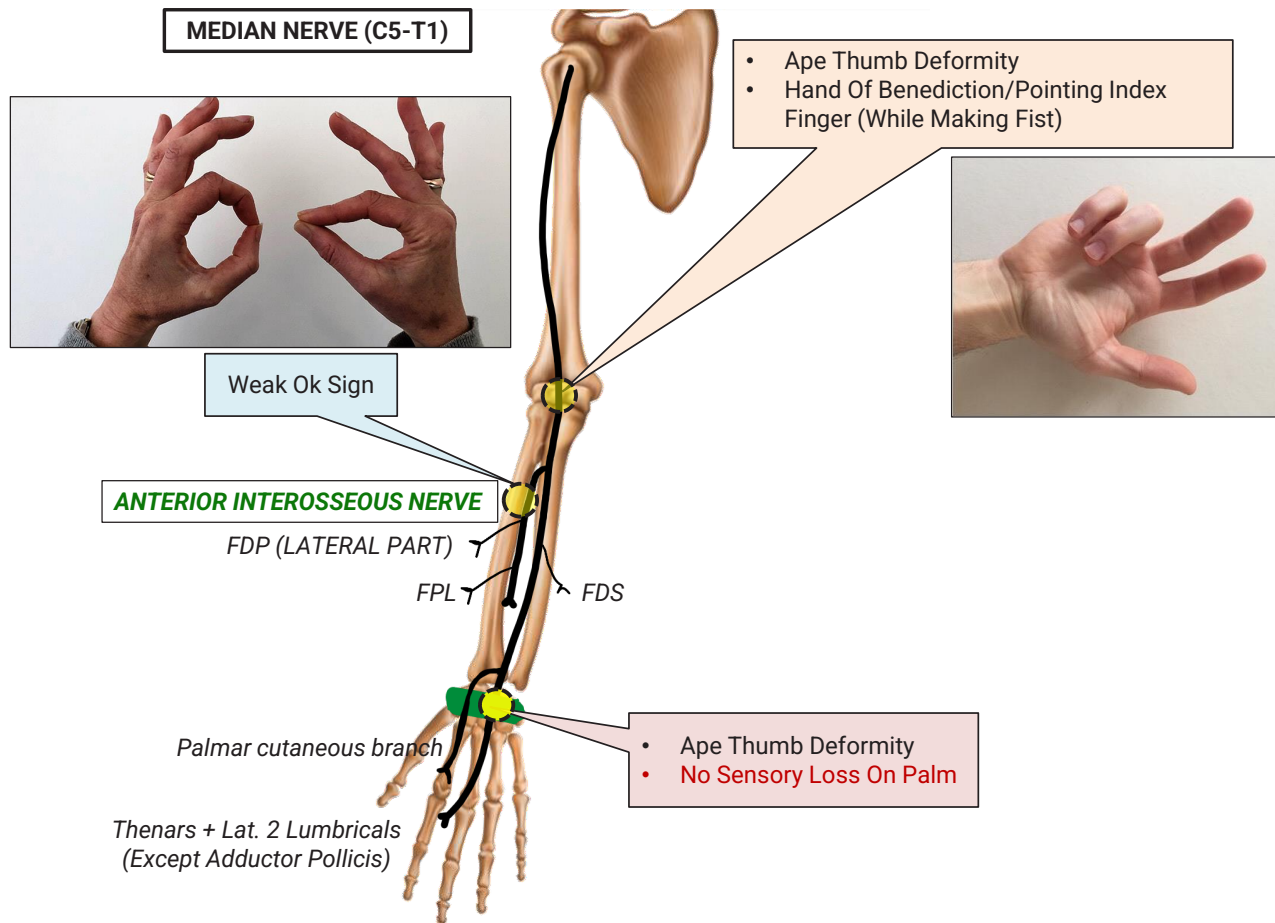




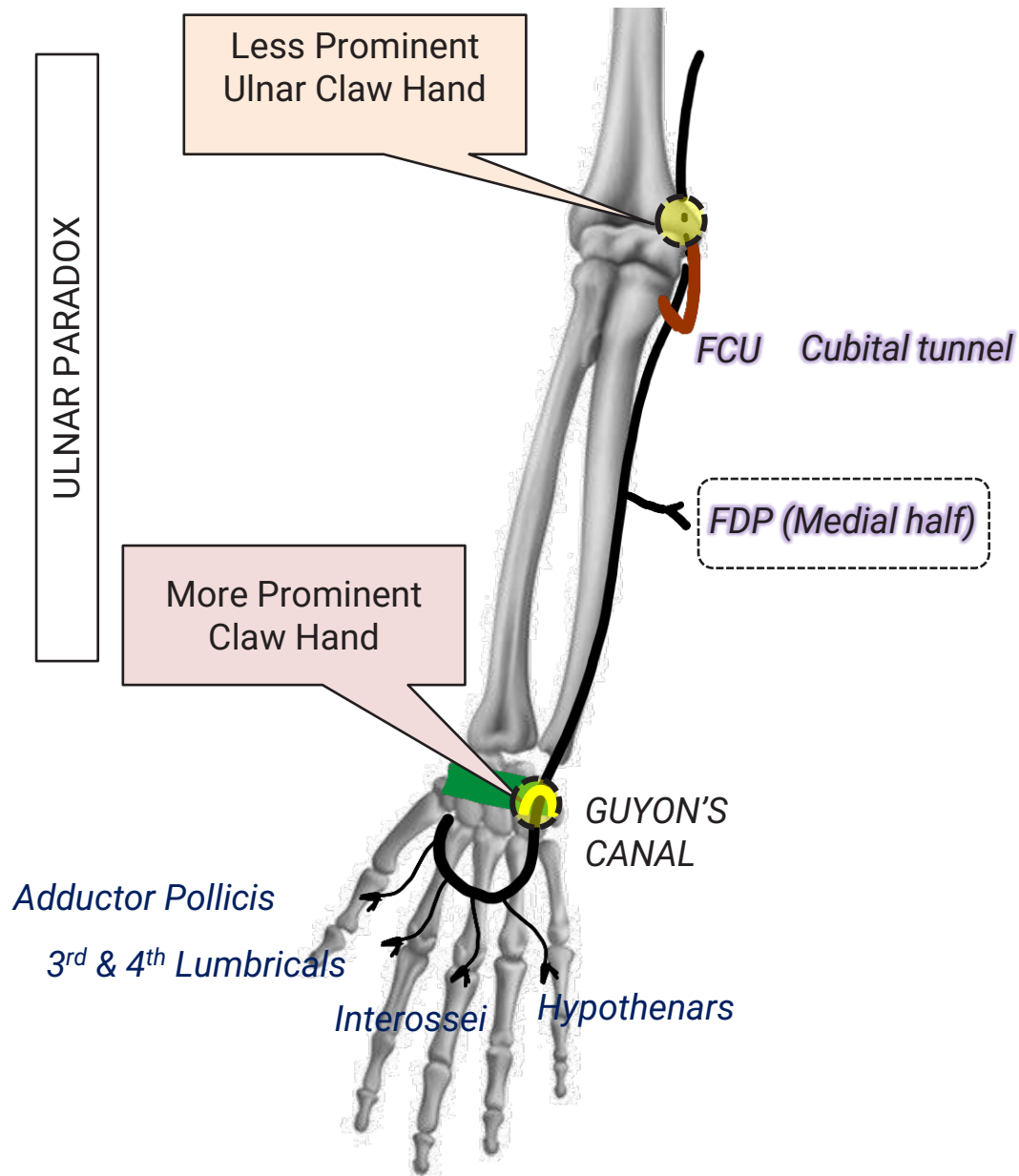
**BRACHIAL PLEXUS**

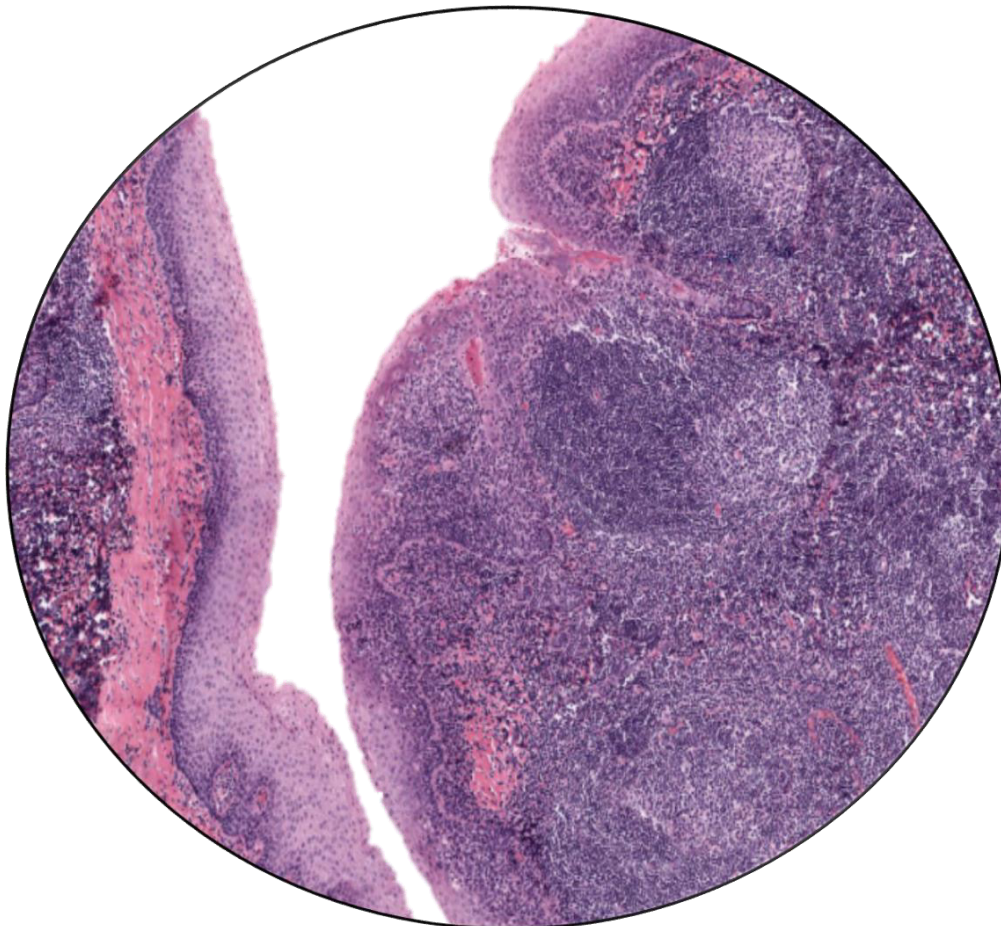
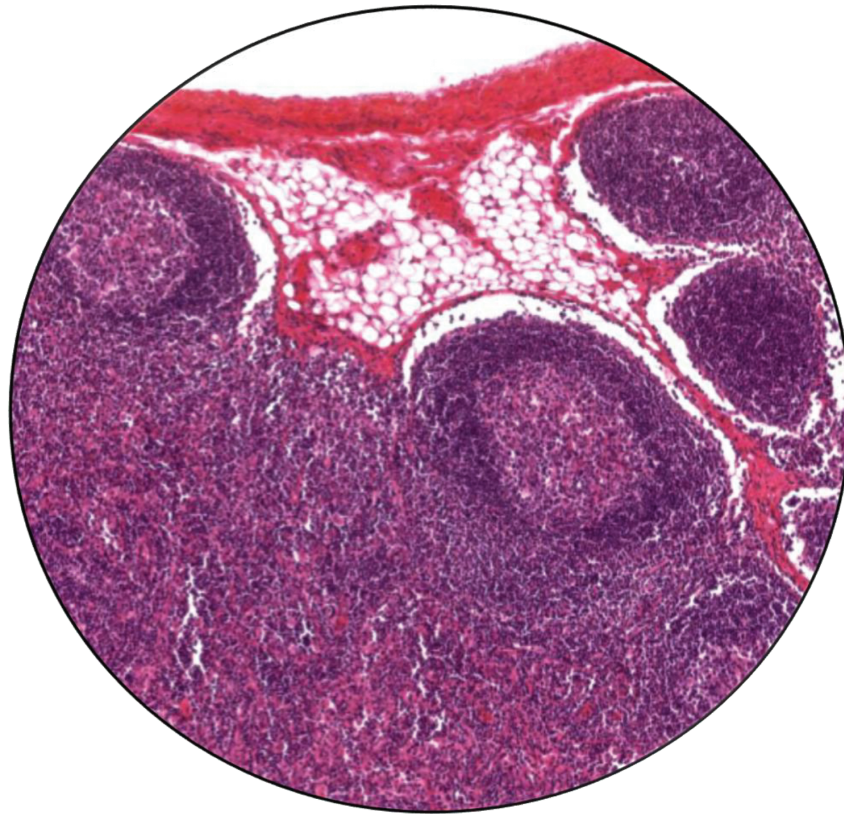


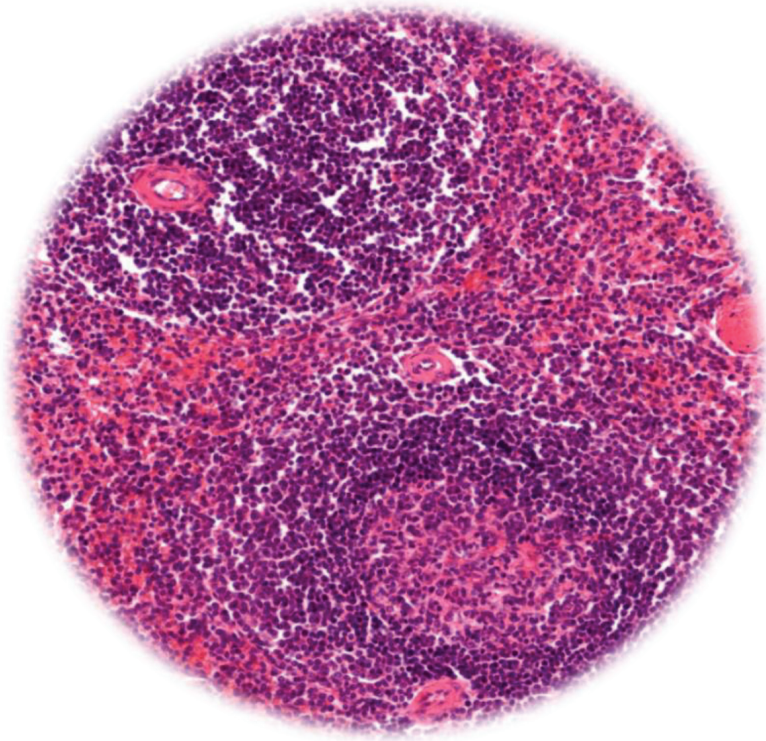
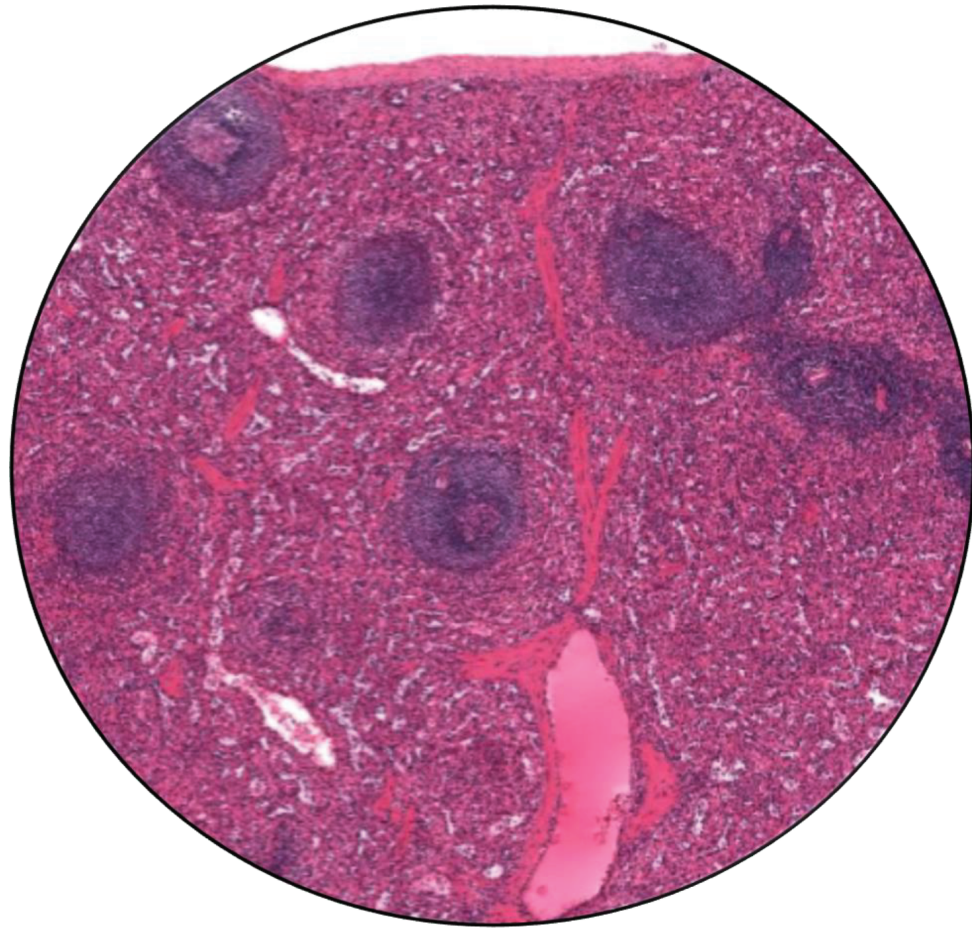


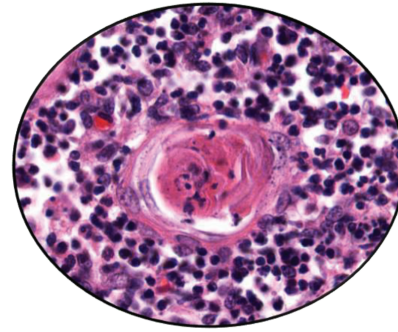
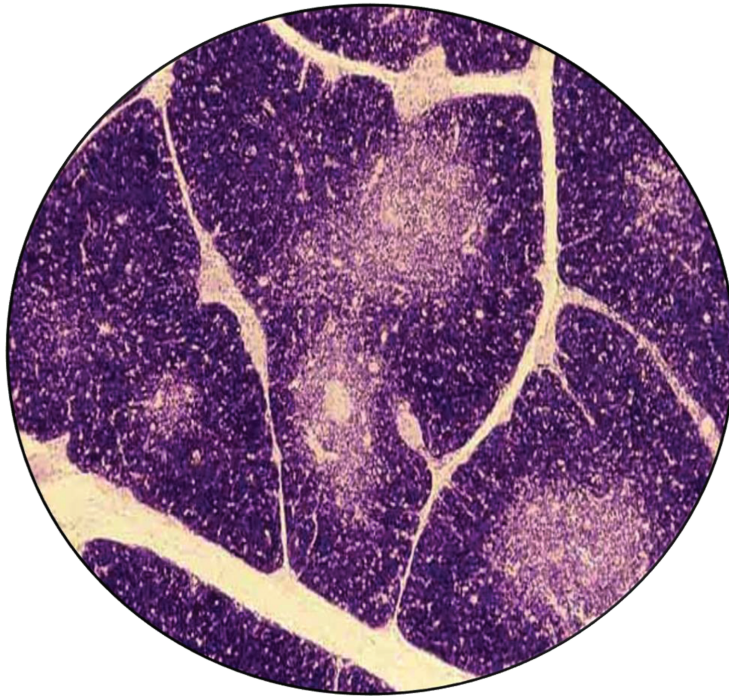


### ULNAR NERVE (C7-T1)







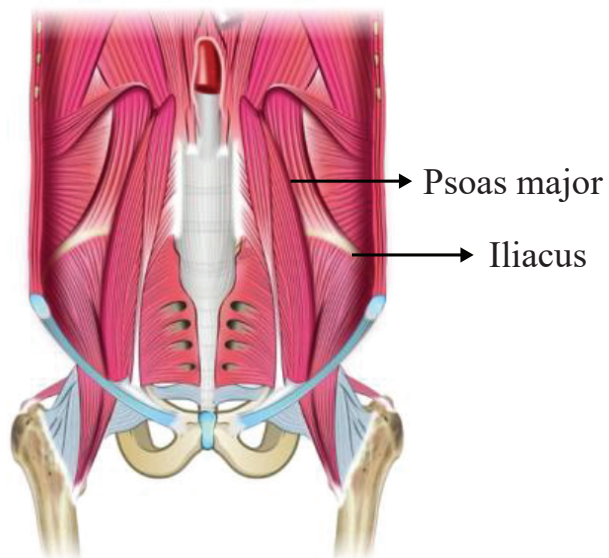
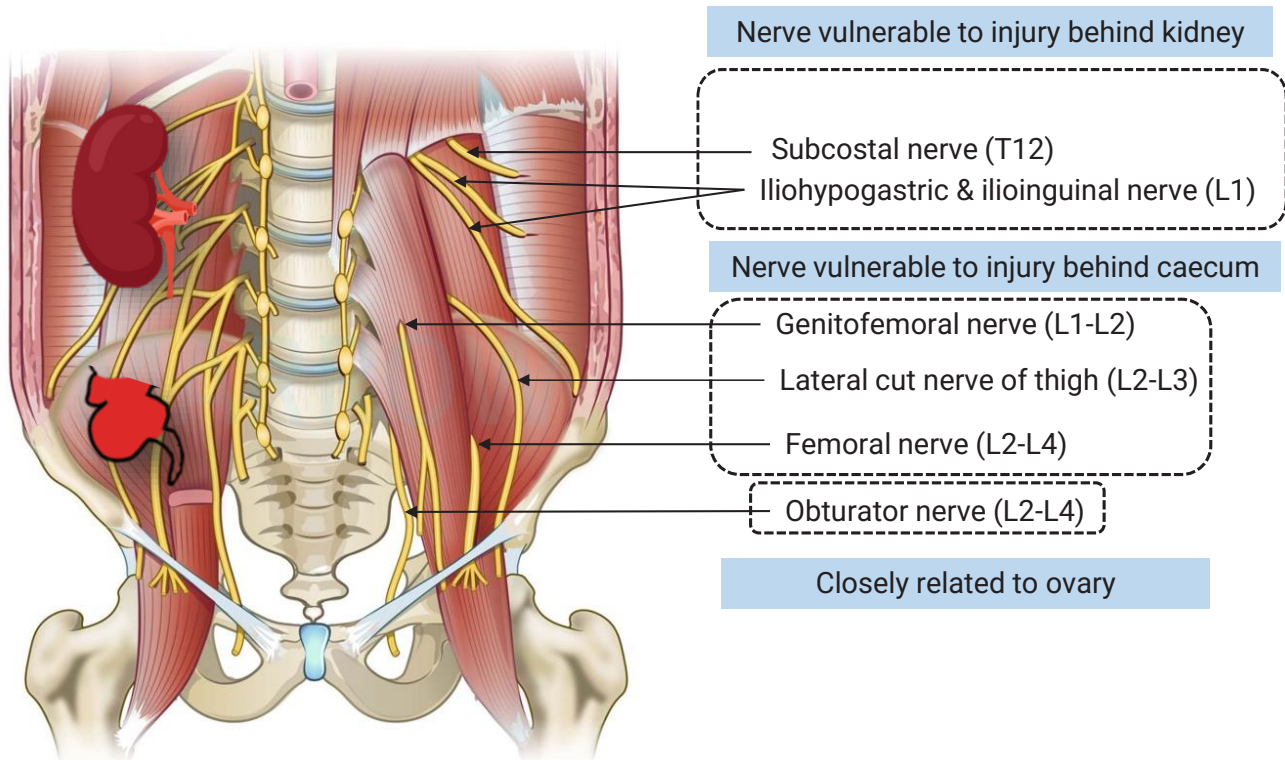


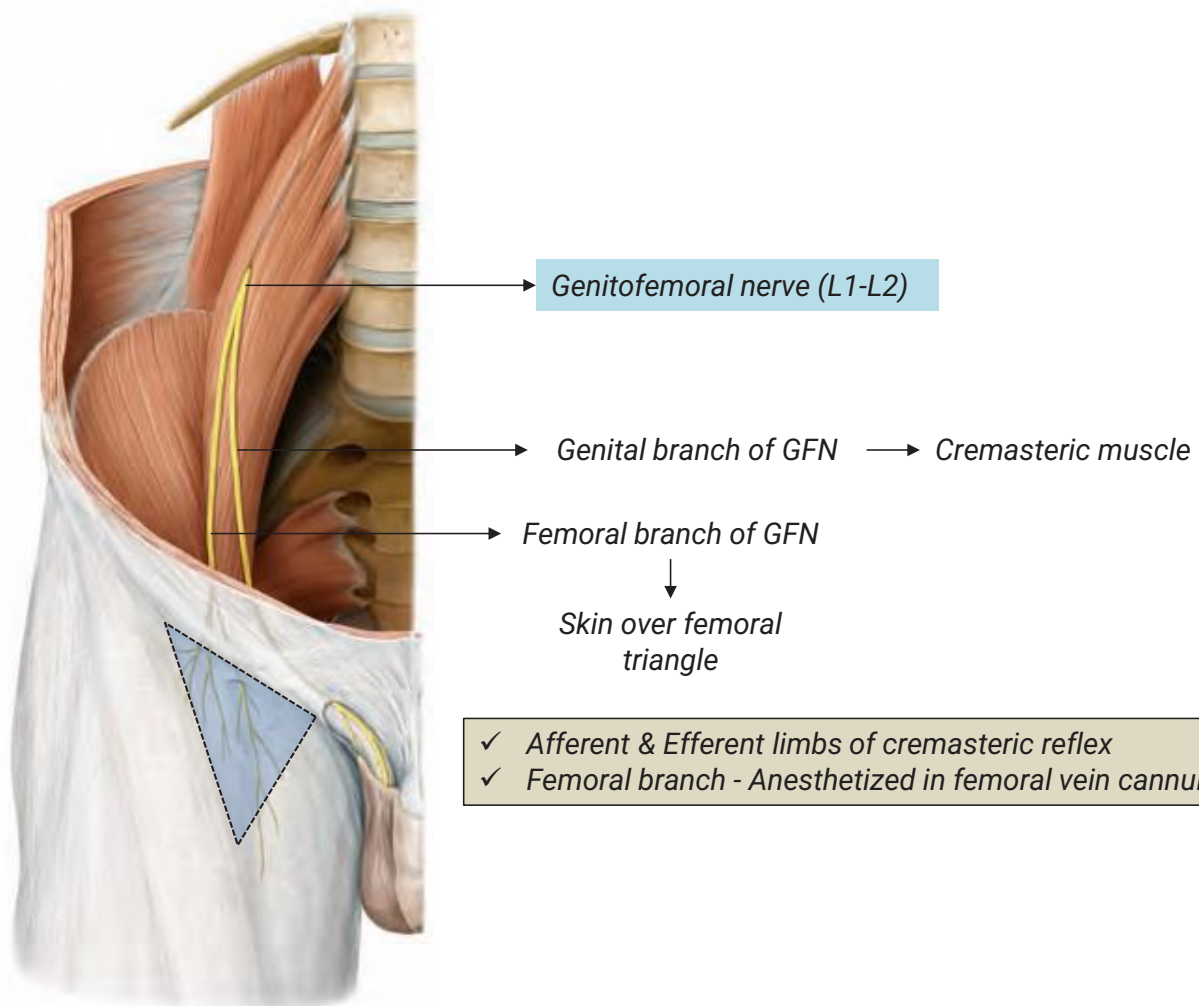
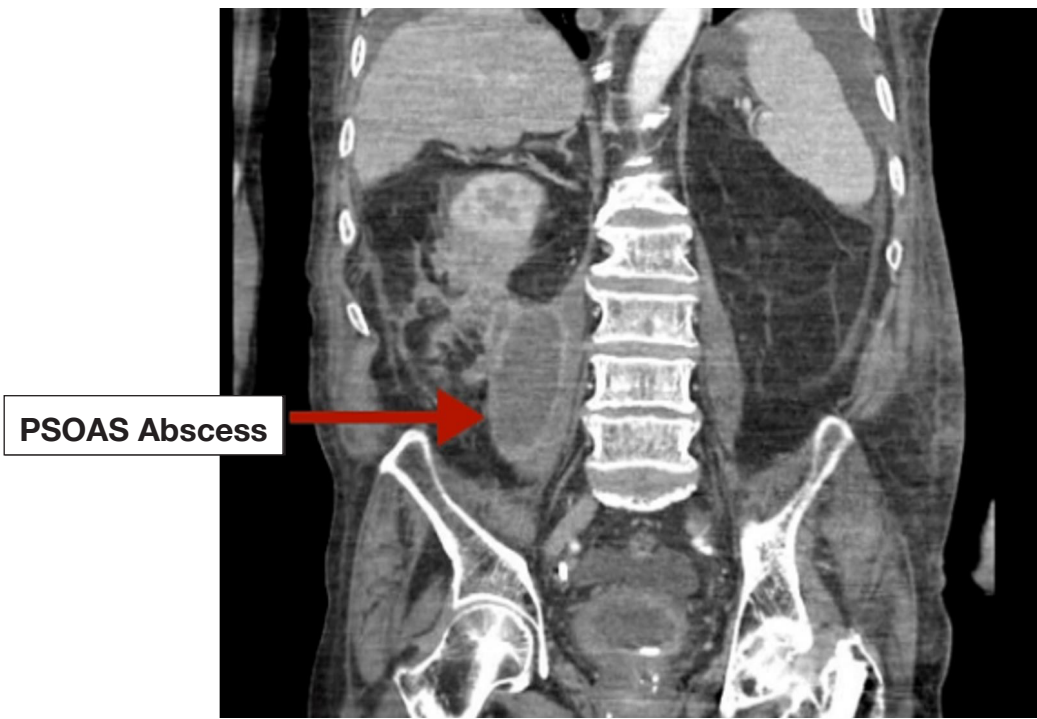


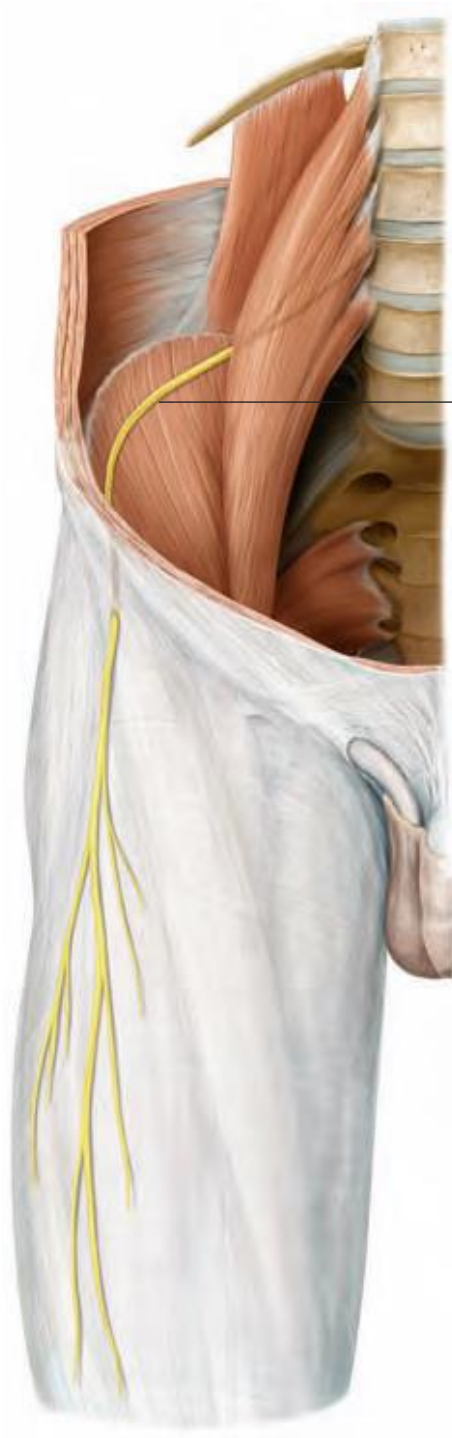## NOTES

# LOWER LIMB

## LUMBAR PLEXUS







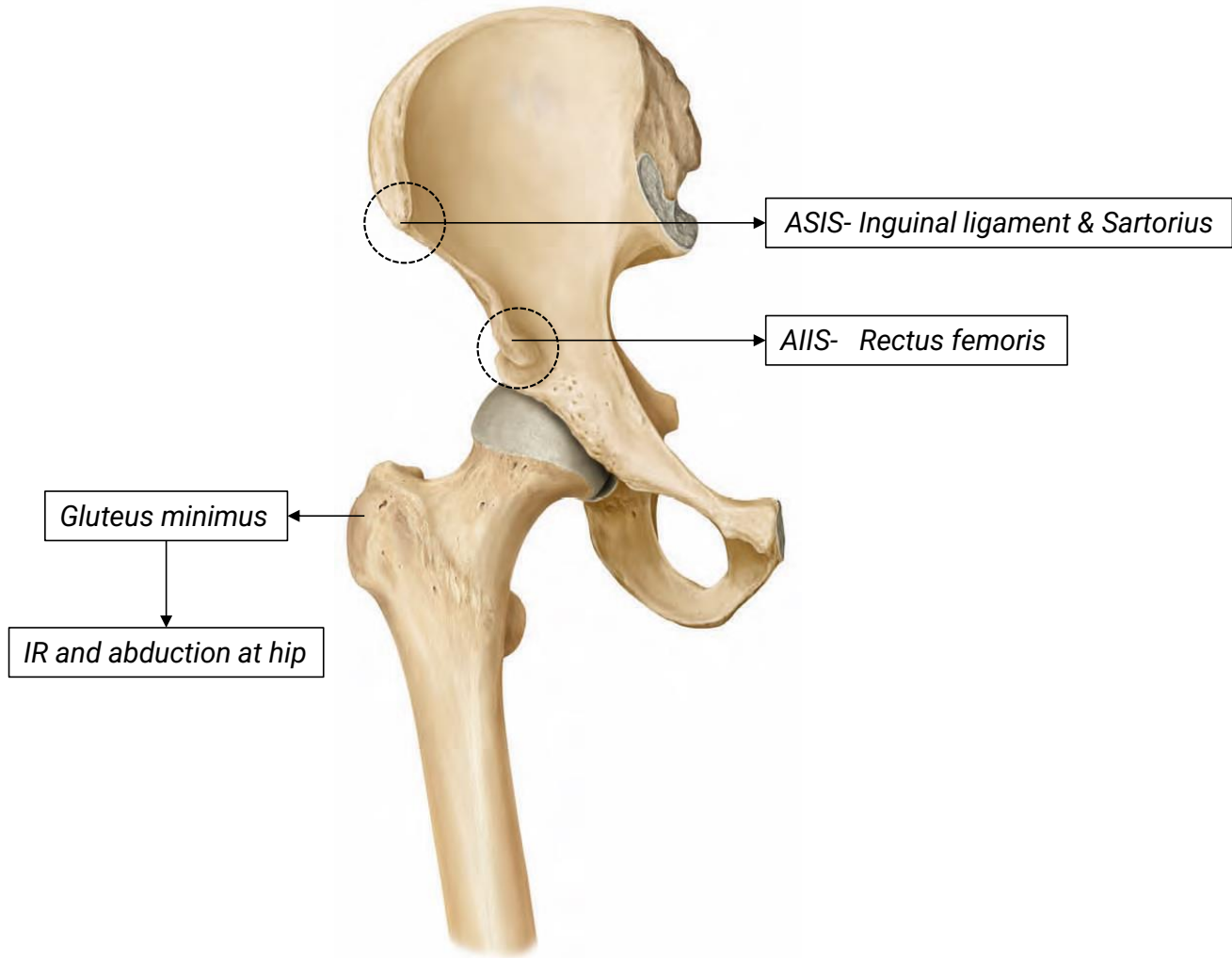
Lateral cutaneous nerve of thigh (L2-L3)

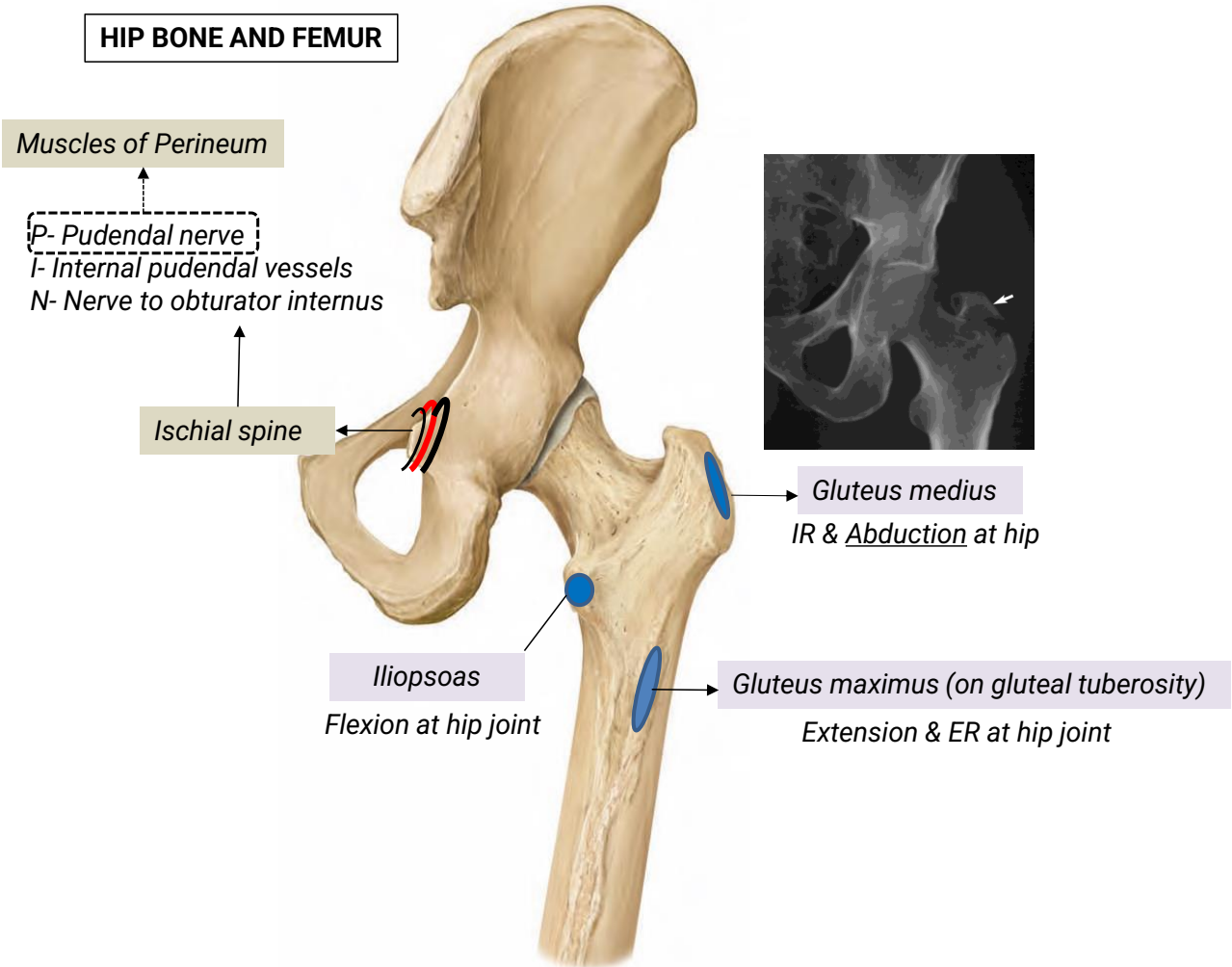
Compression deep to inguinal ligament

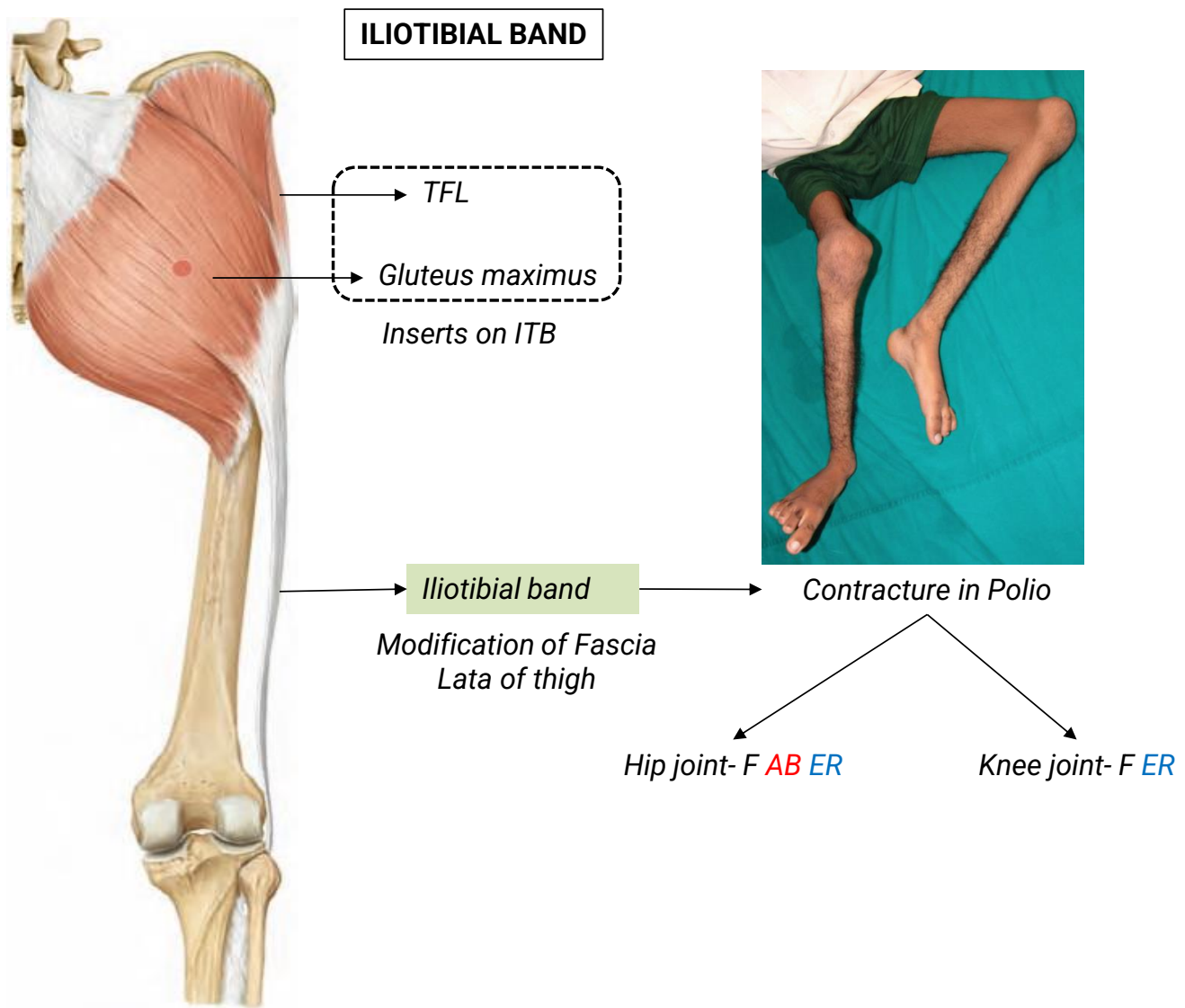
Burning stabbing in the lateral thigh area.

Meralgia paresthetica

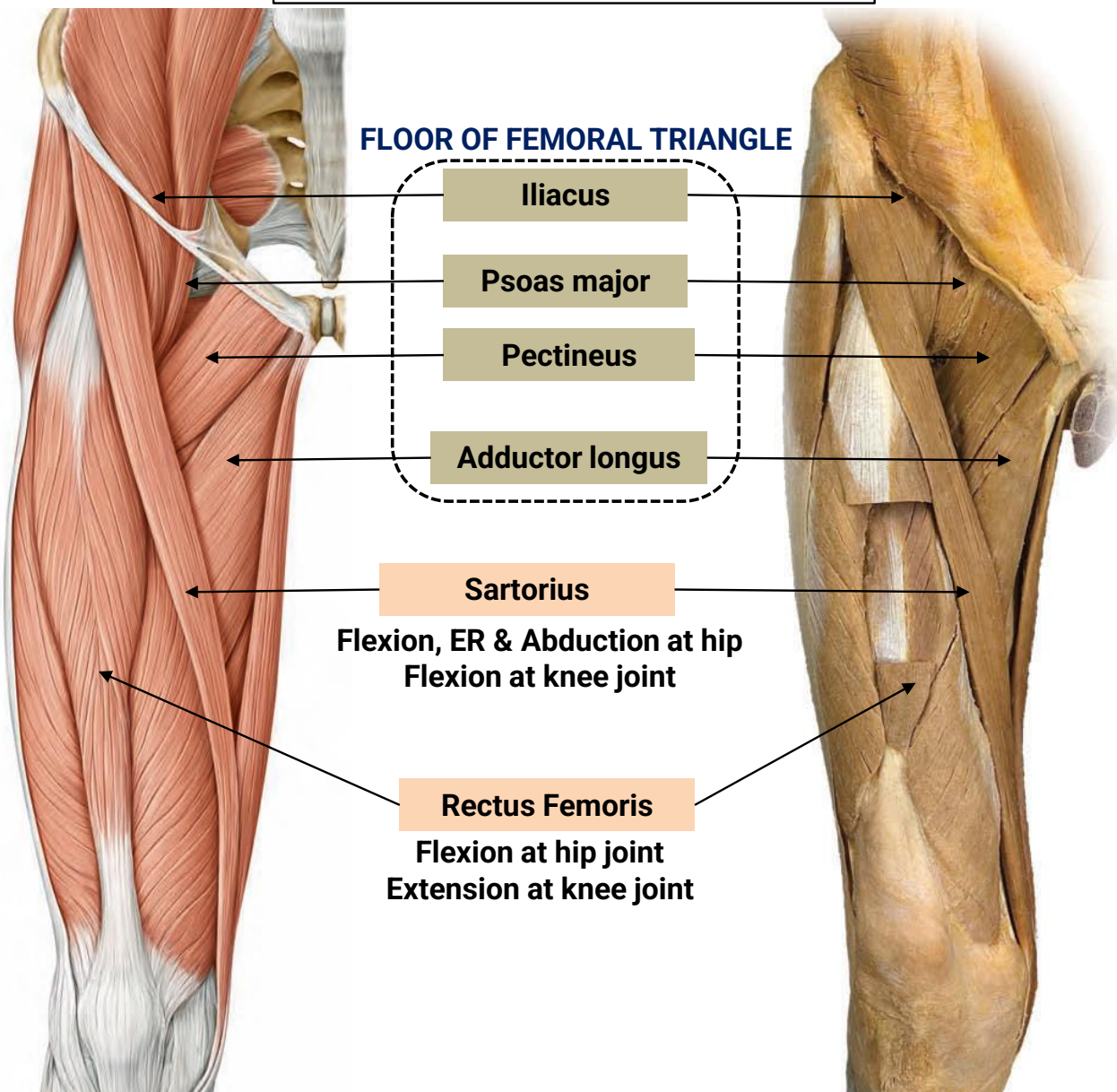
### HIP BONE AND FEMUR

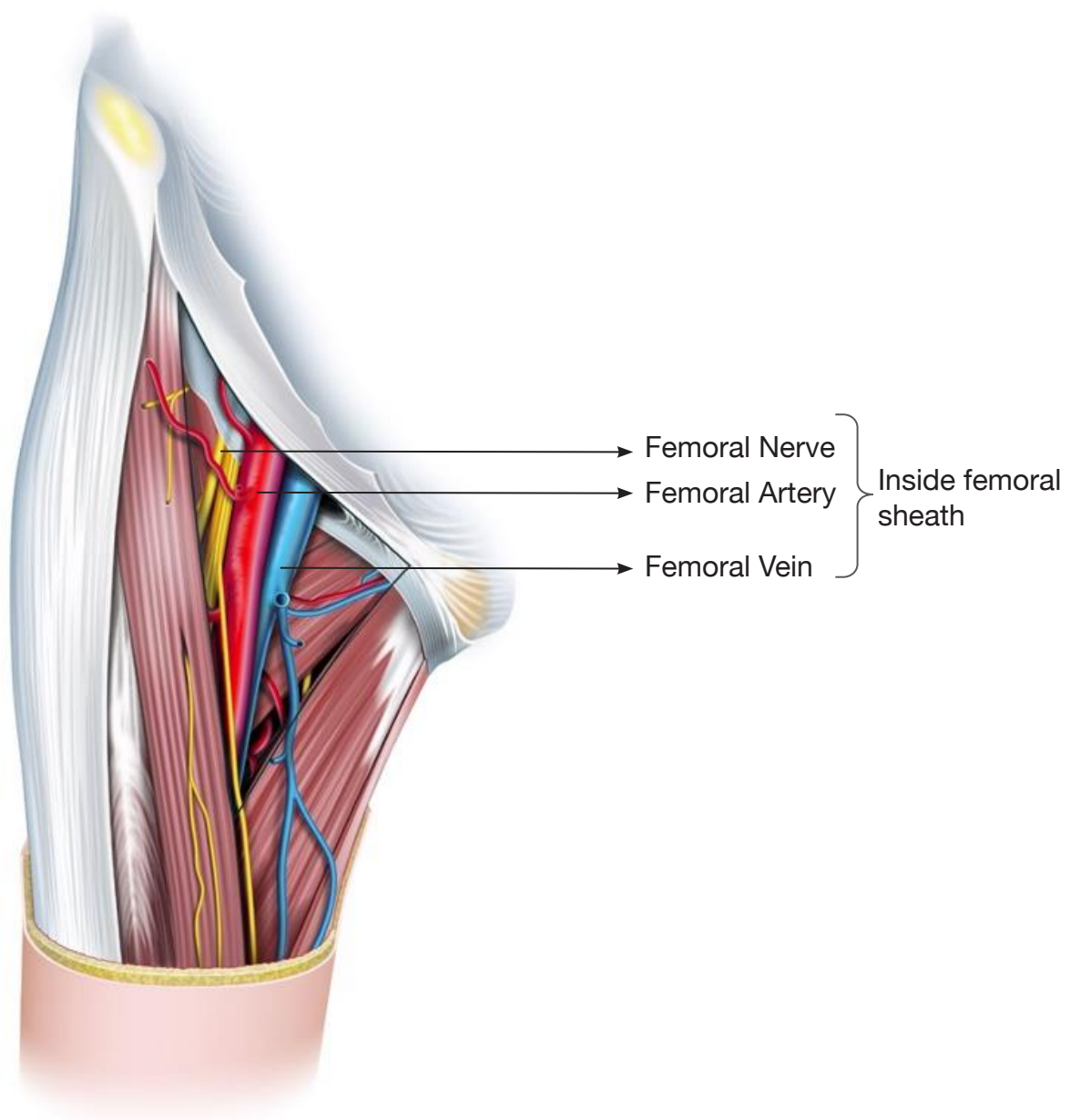






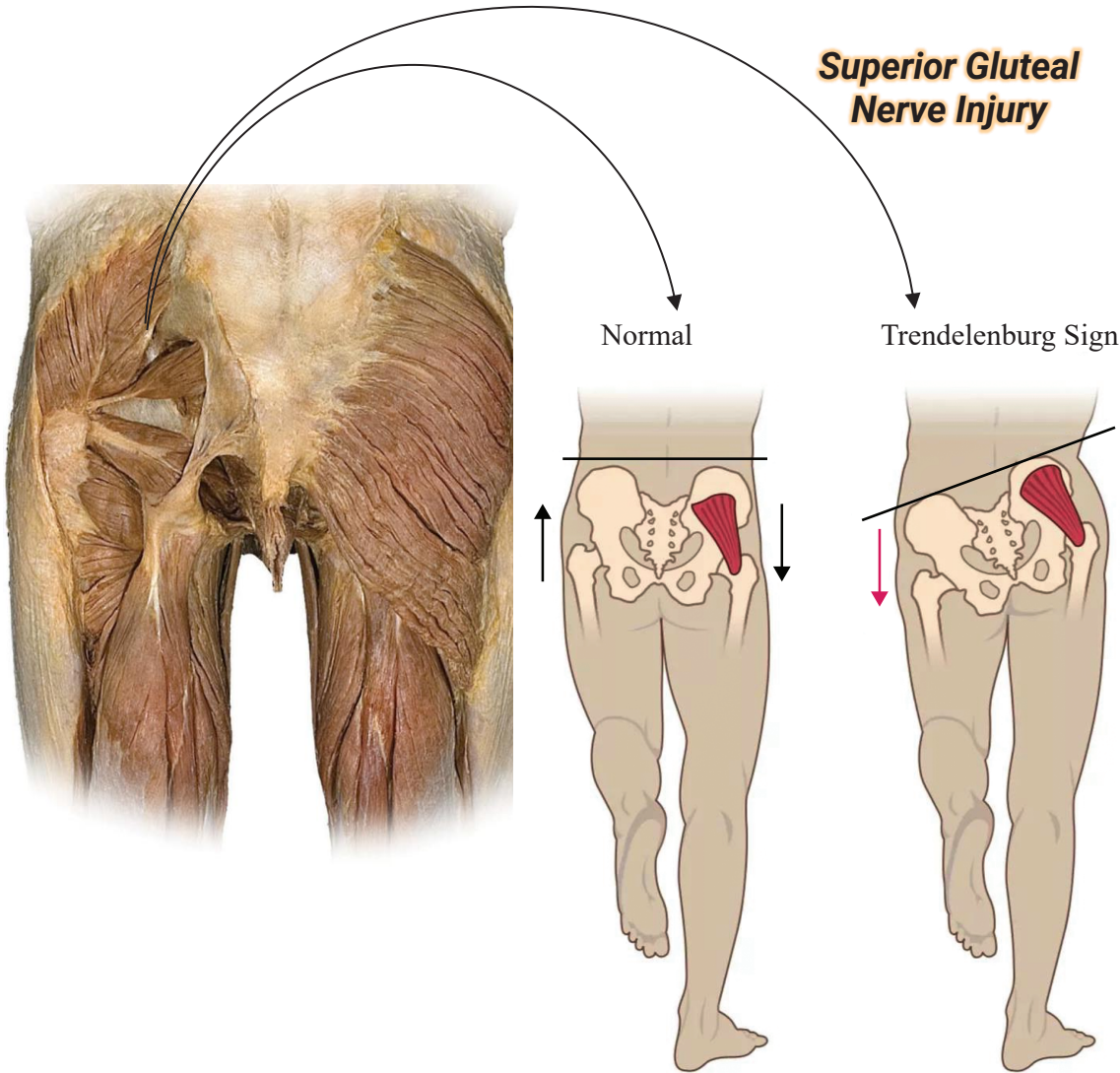
**ANTERIOR THIGH & FEMORAL TRIANGLE**



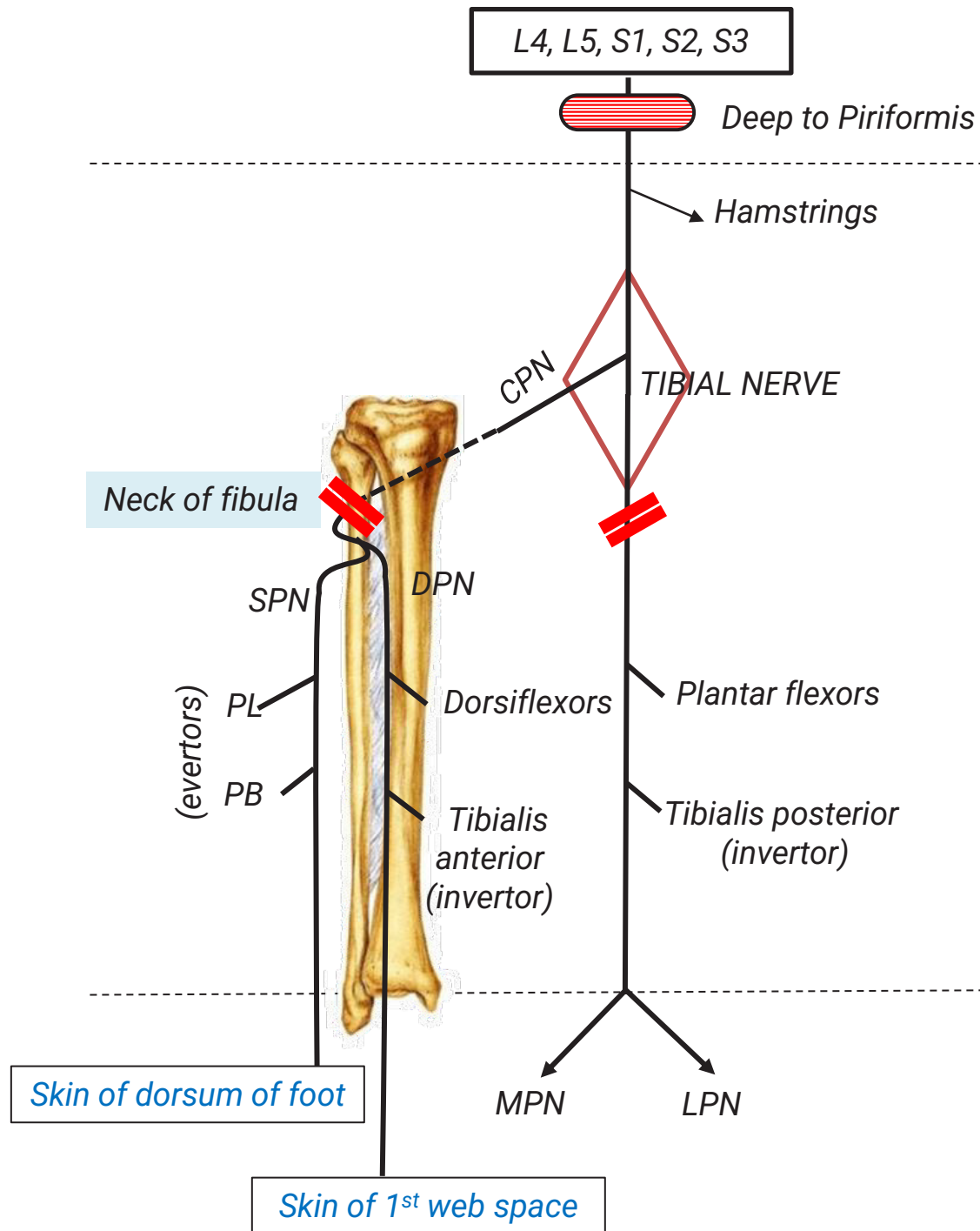


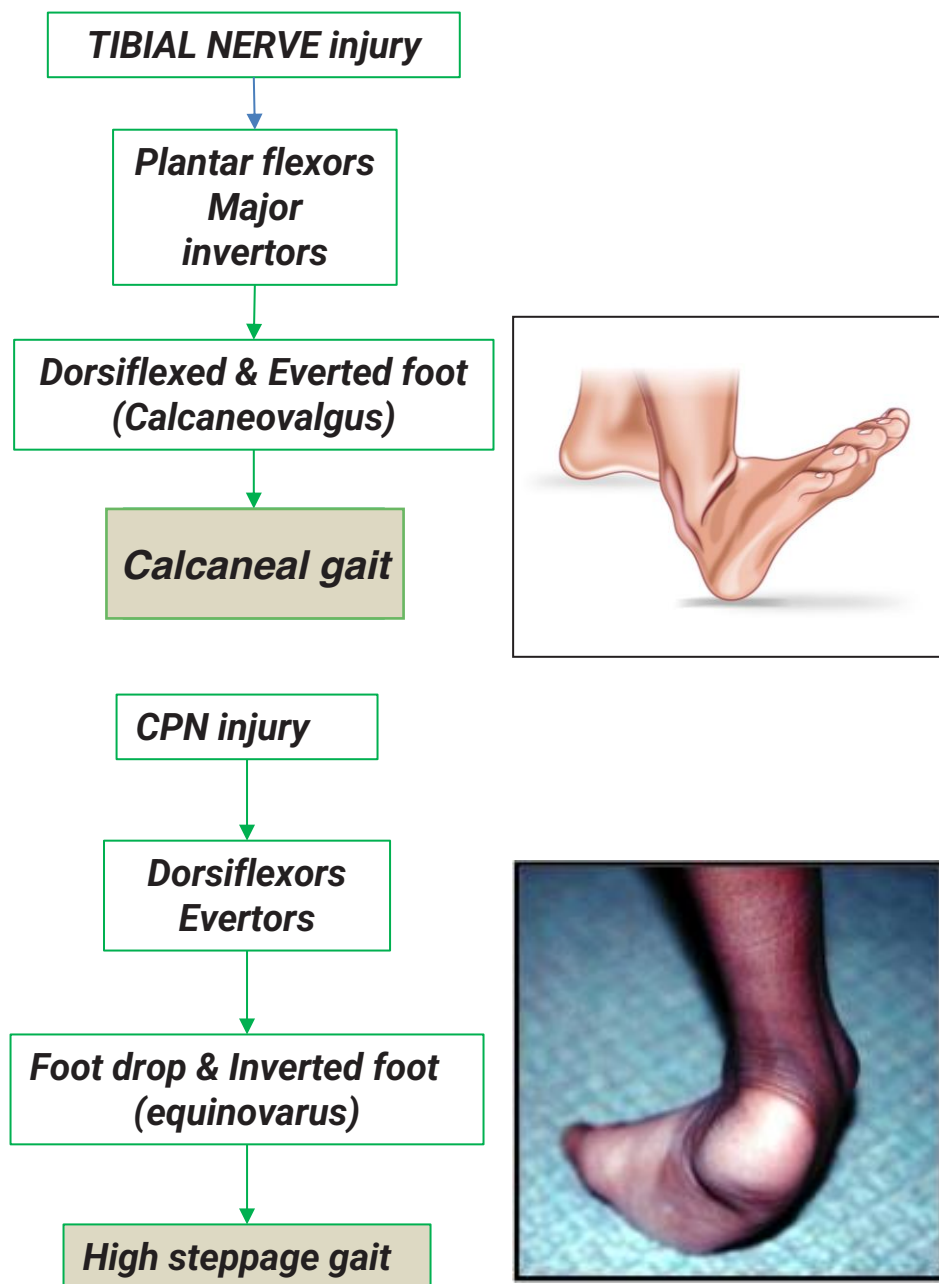


**GLUTEAL REGION**

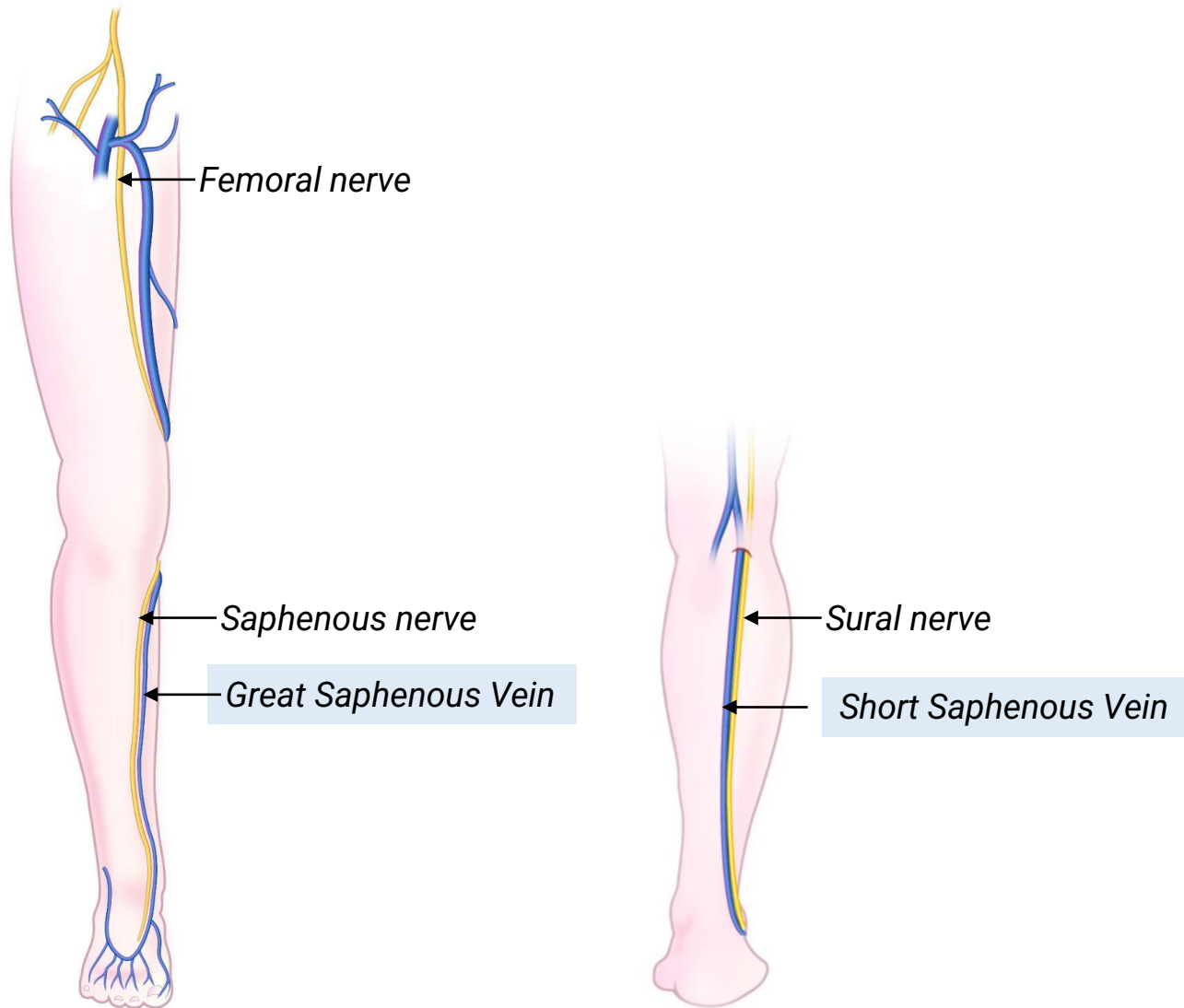


SCIATIC NERVE



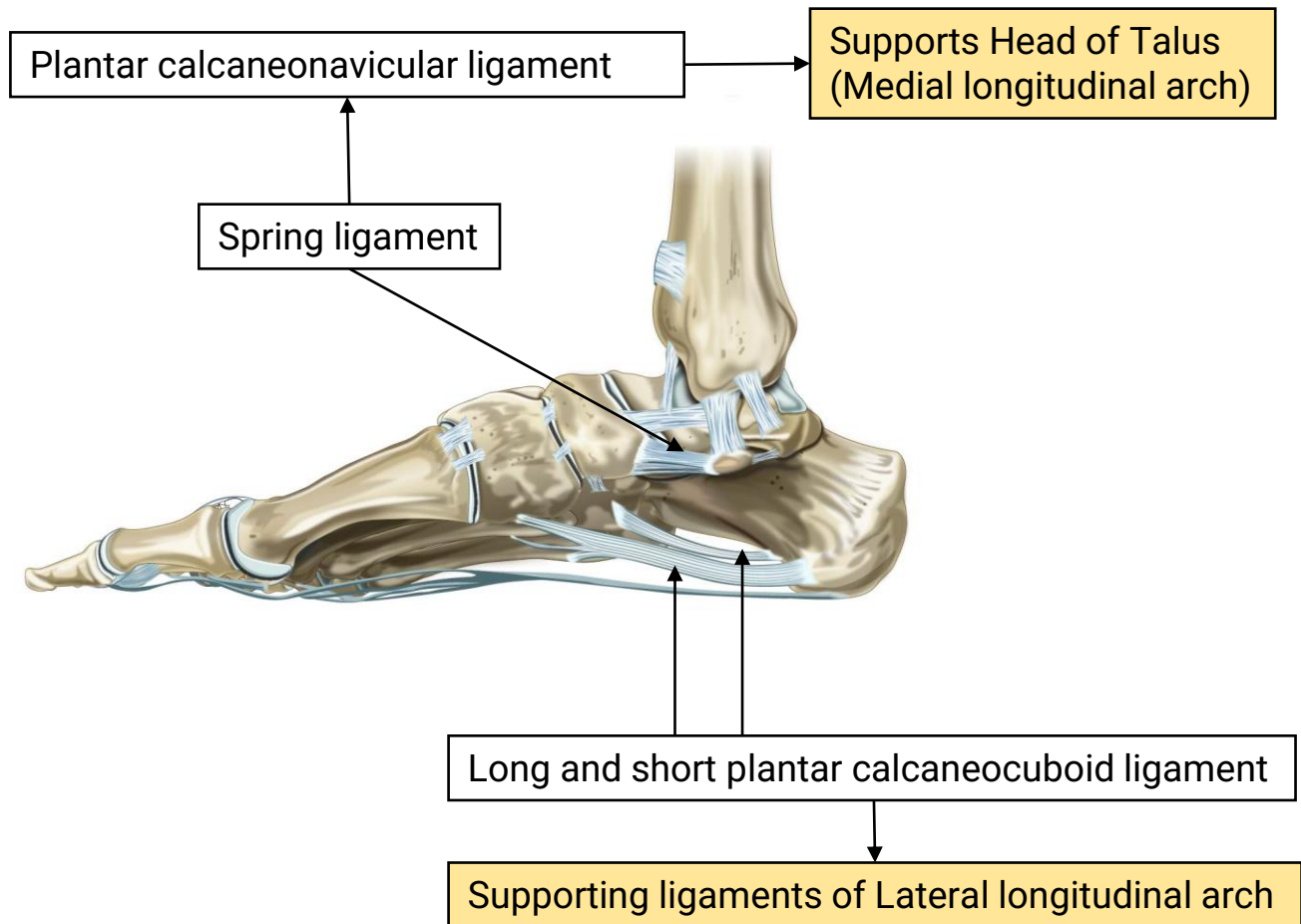


## GREAT SAPHENOUS VEIN AND SHORT SAPHENOUS VEIN

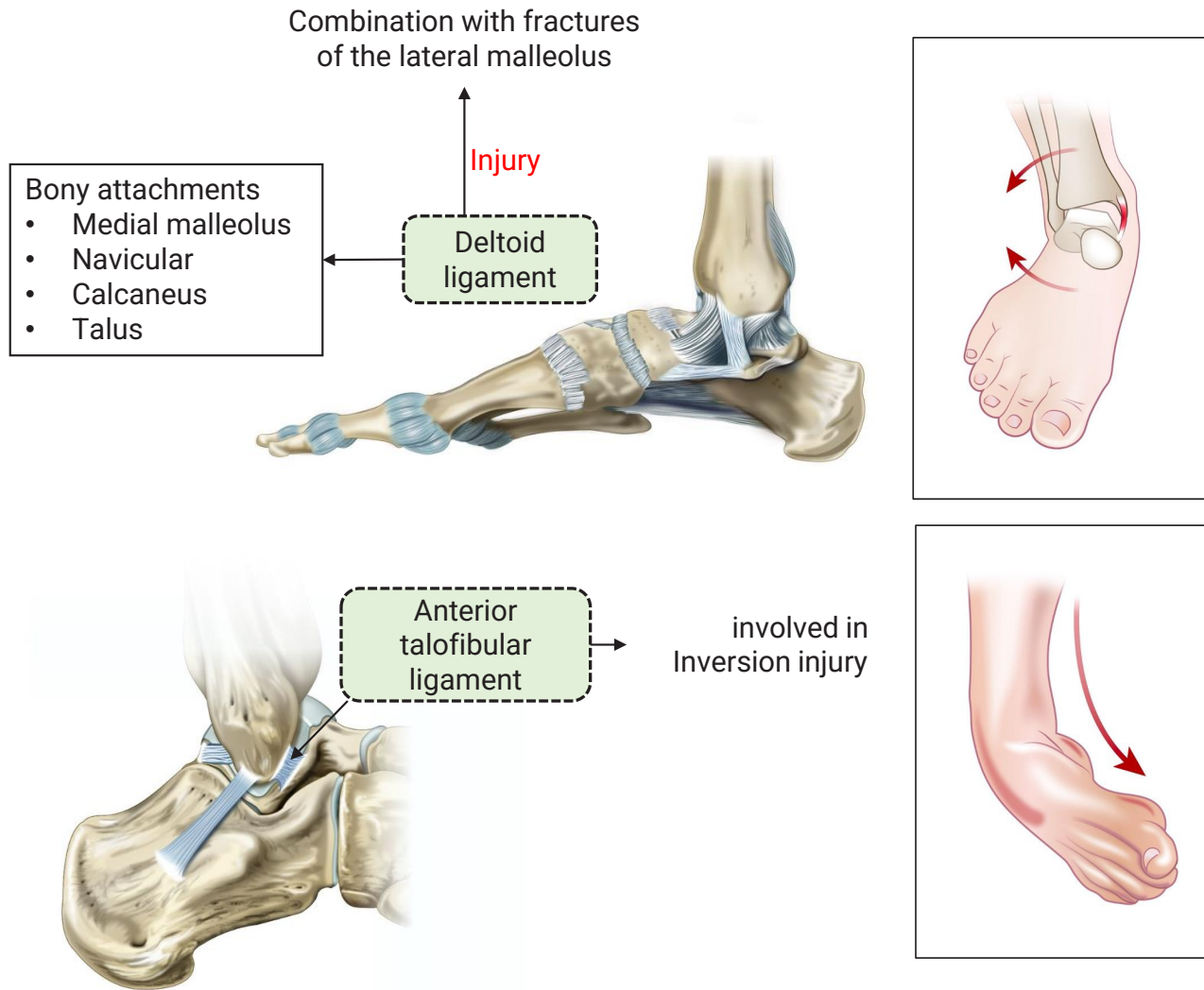




### LIGAMENTS OF FOOT AND ANKLE

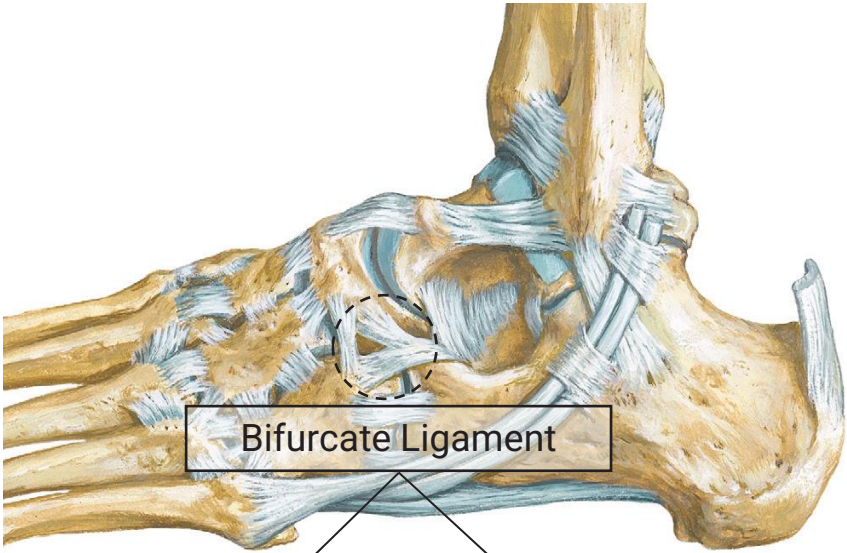


LIGAMENTS OF FOOT AND ANKLE





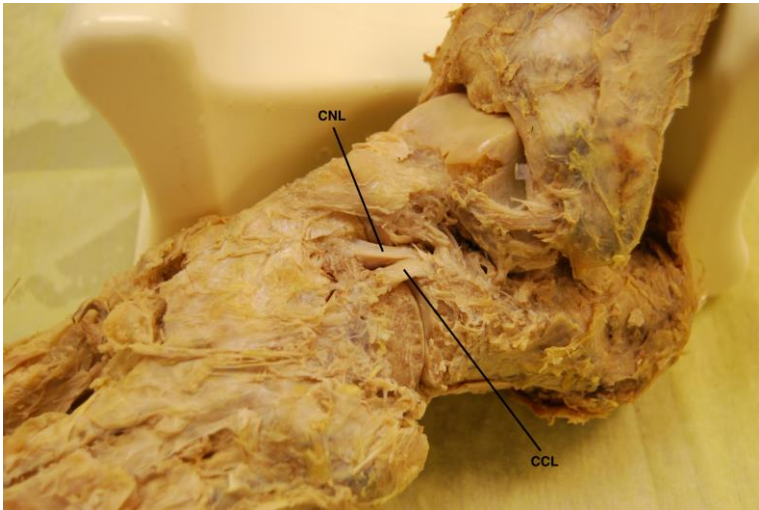
LIGAMENTS OF FOOT AND ANKLE

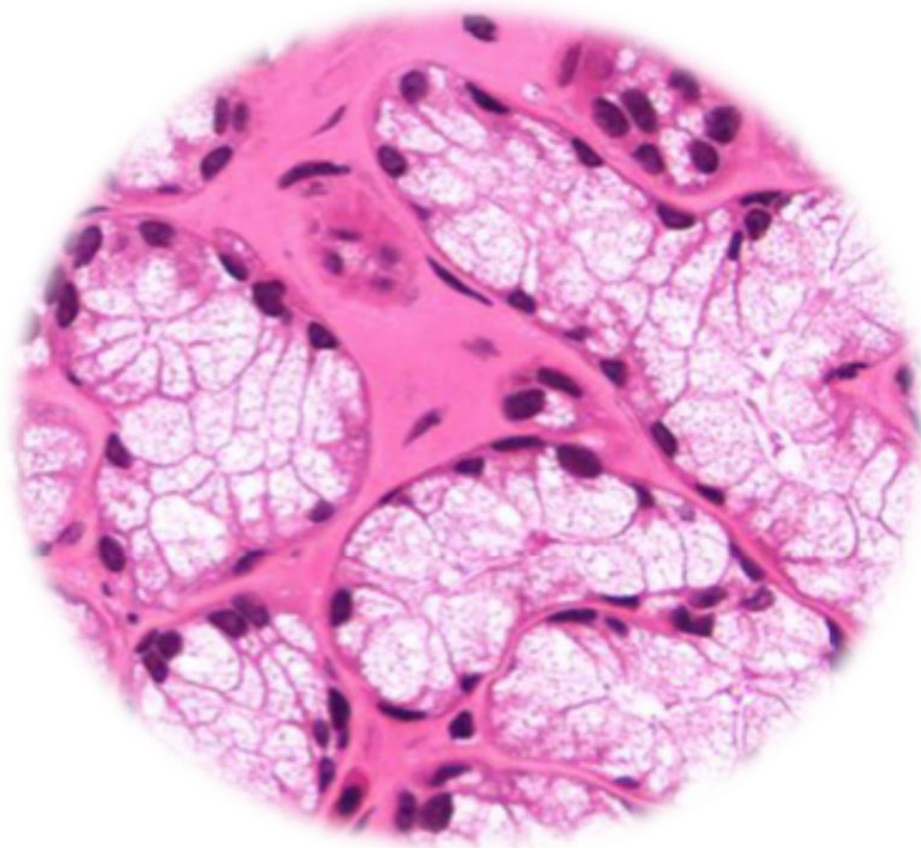
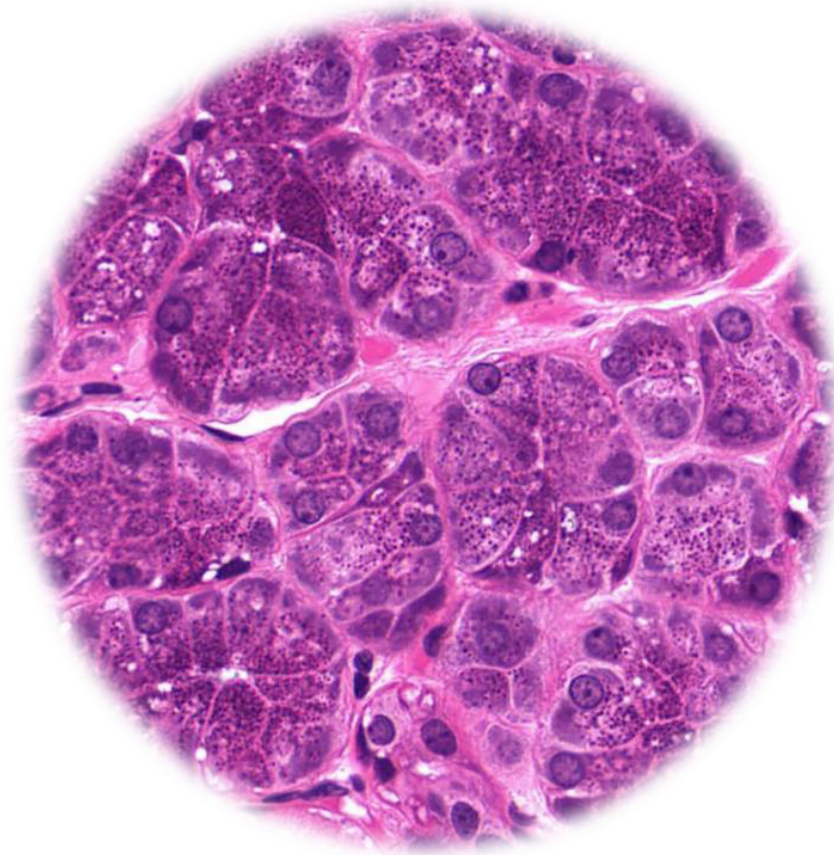


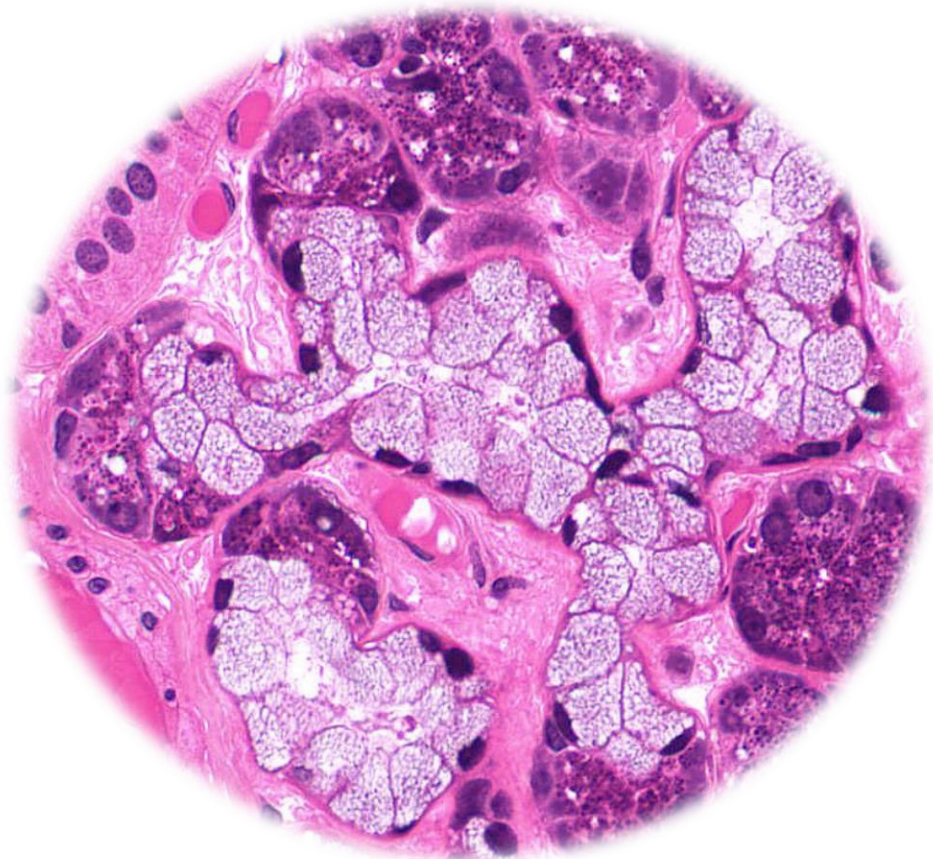
Bifurcate Ligament

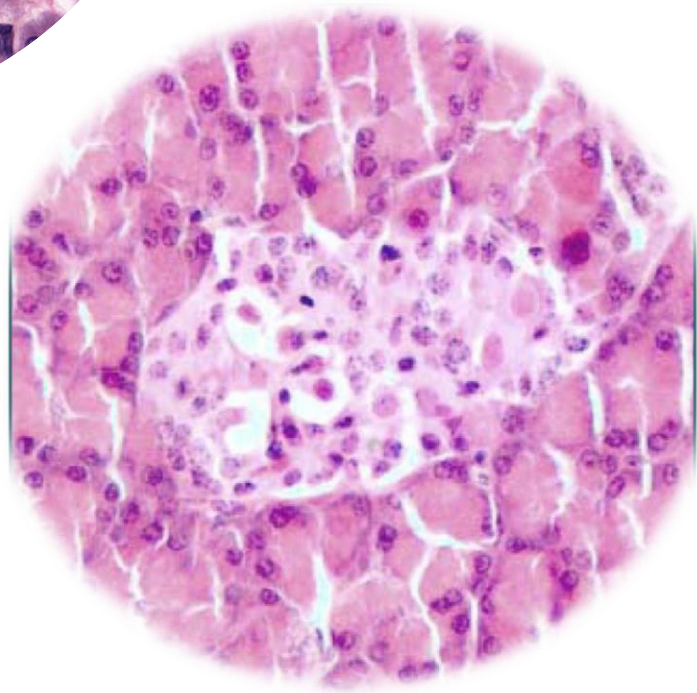
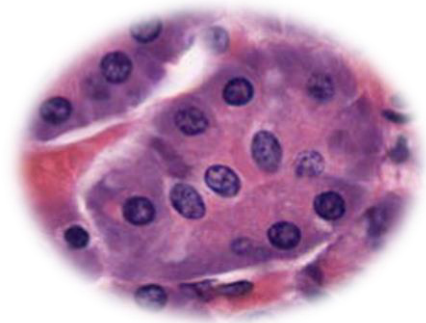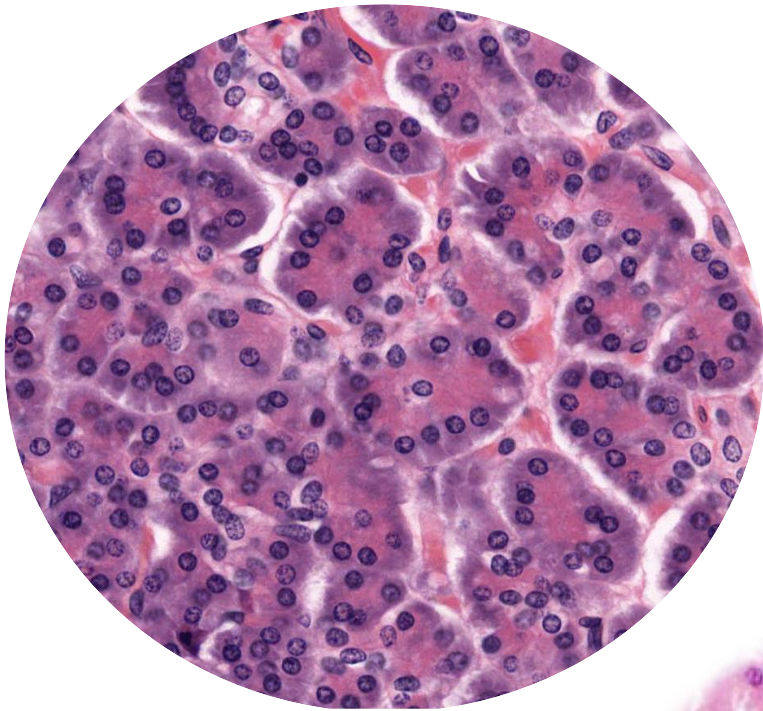
Calcaneocuboid ligament (CCL)

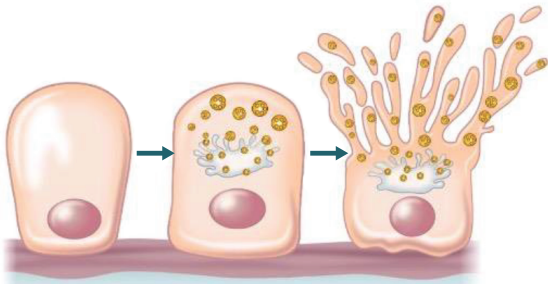
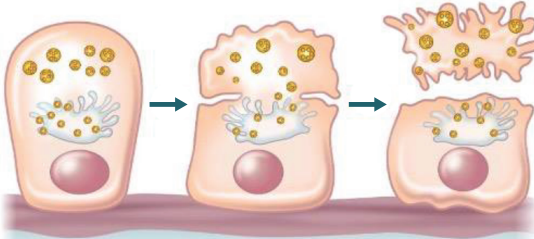
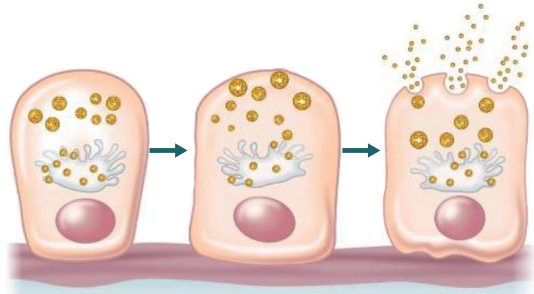
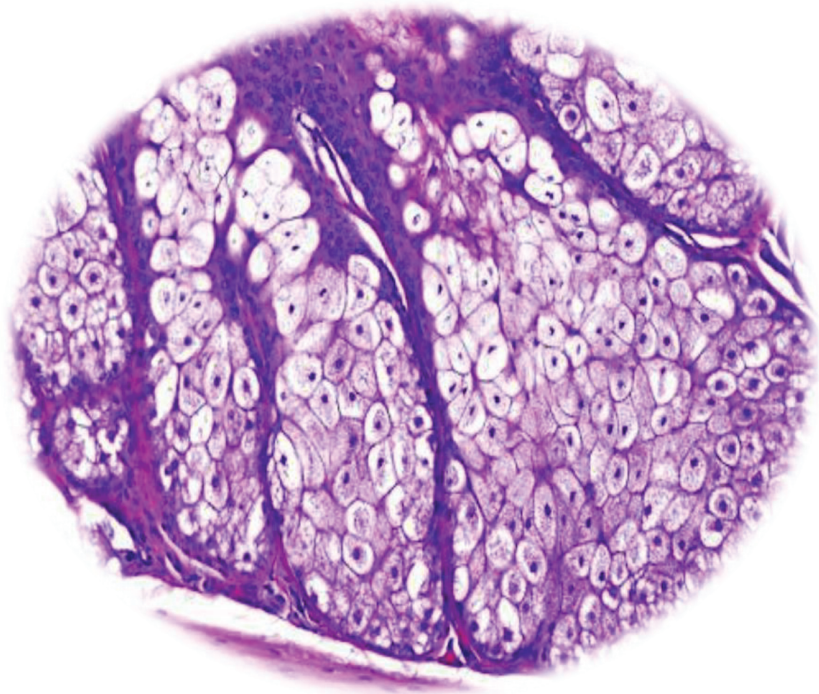
Calcaneonavicular ligament (CNL)









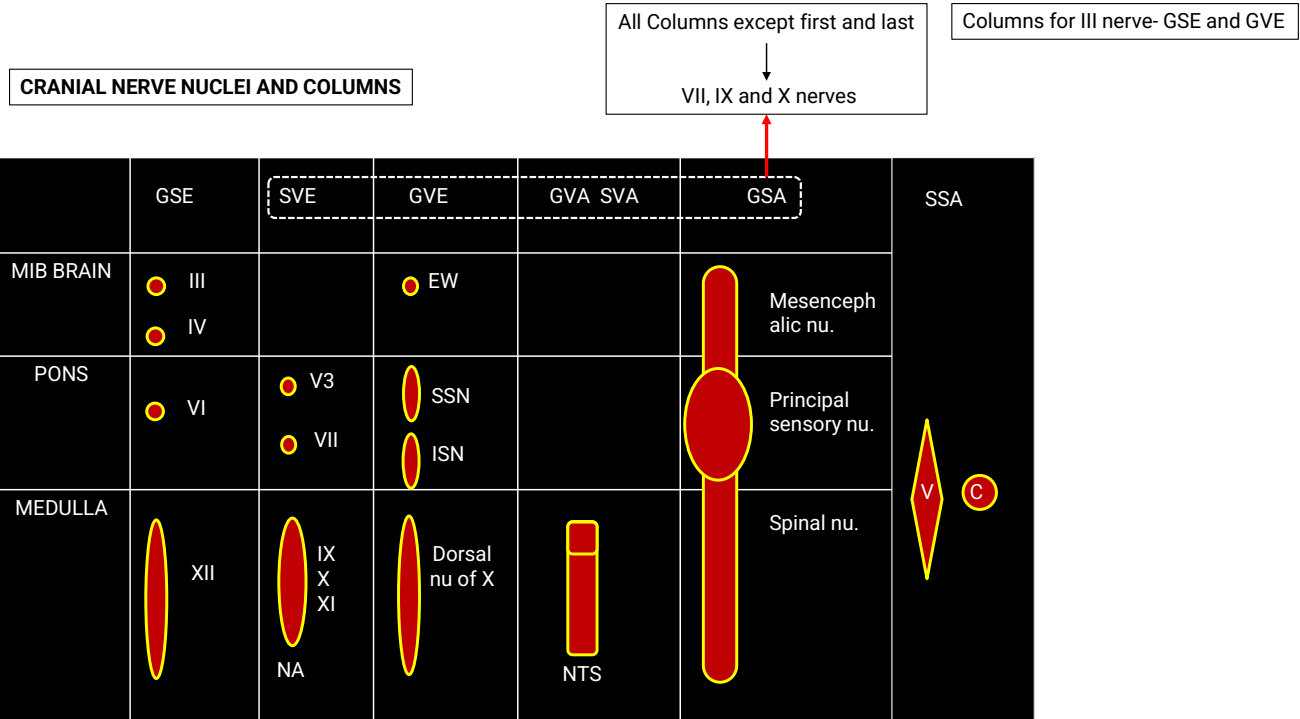


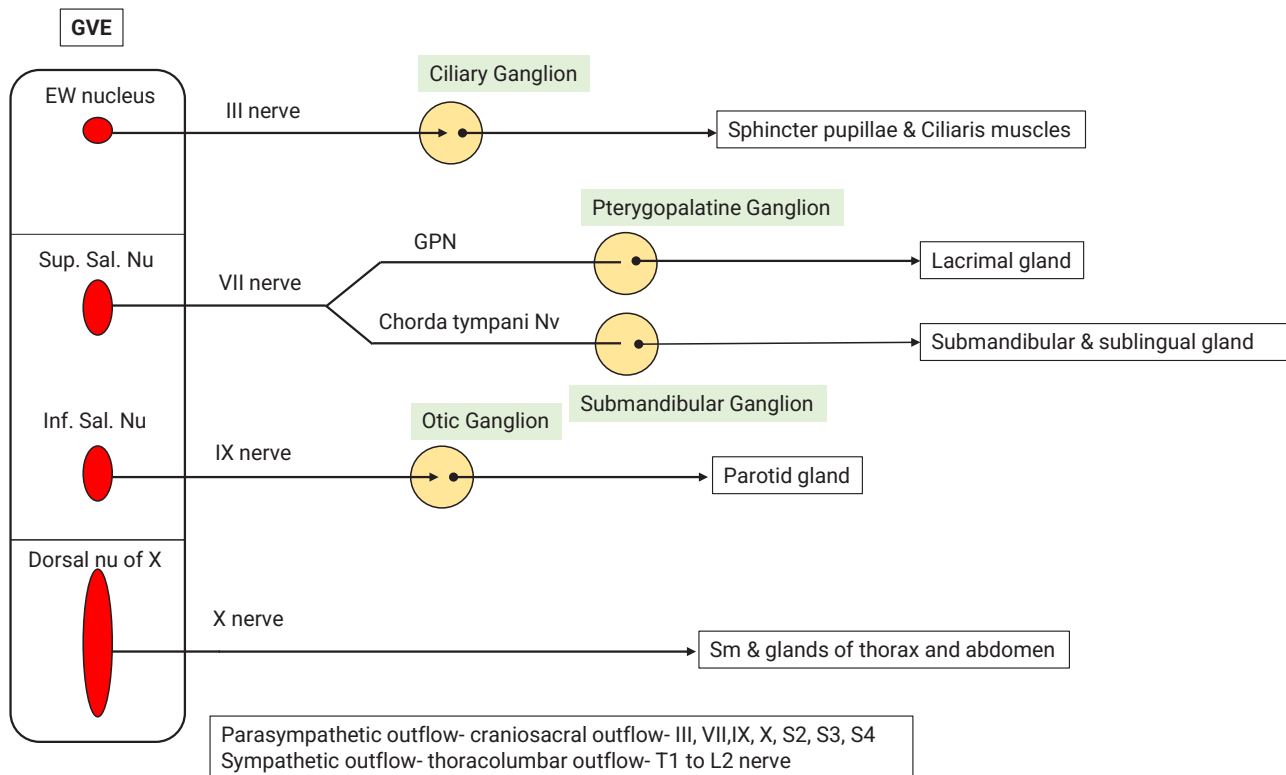
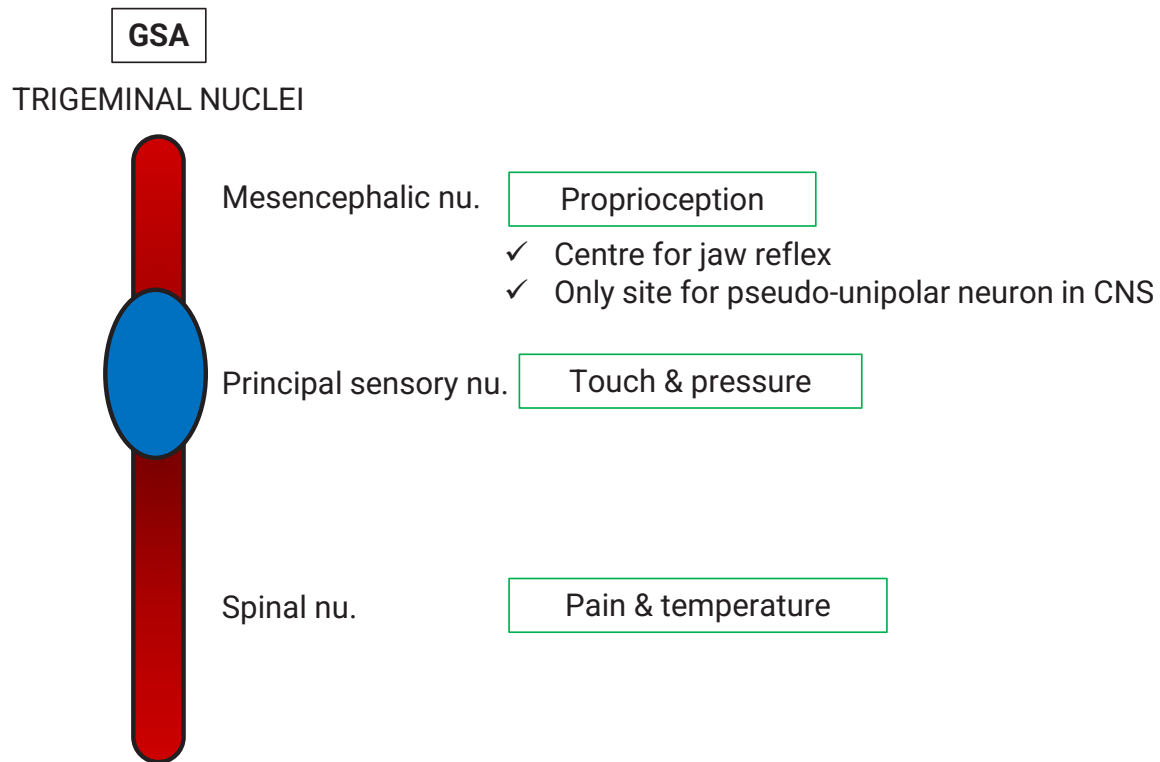


## NOTES



# HEAD, NECK & FACE



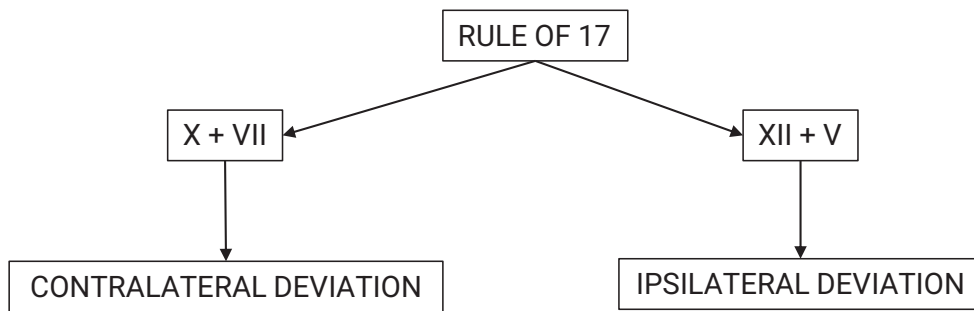




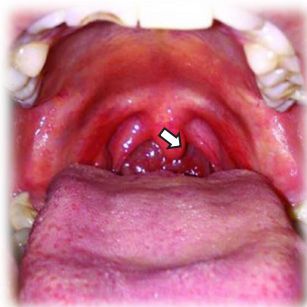**CRANIAL NUCLEI COLUMNS**

CRANIAL NERVE	GSE	SVE	GVE	GVA	SVA	GSA	SSA	
	I							
	II							
	III							
	IV							
	V							
	VI							
	VII							
	VIII							
	IX							
	X							
	XI							
	XII							

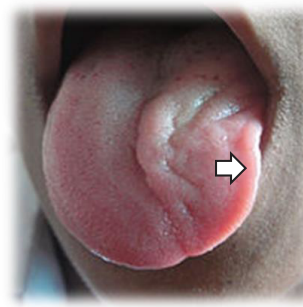**RULE OF 17**



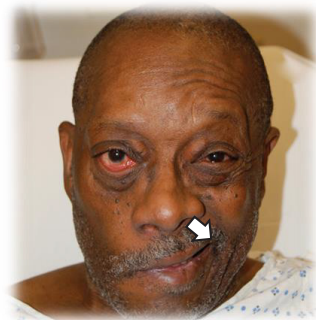
X nerve lesion



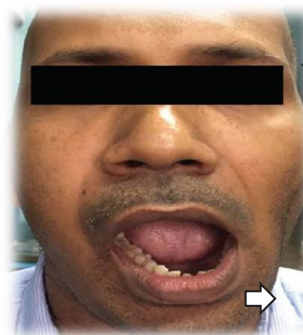XII nerve lesion



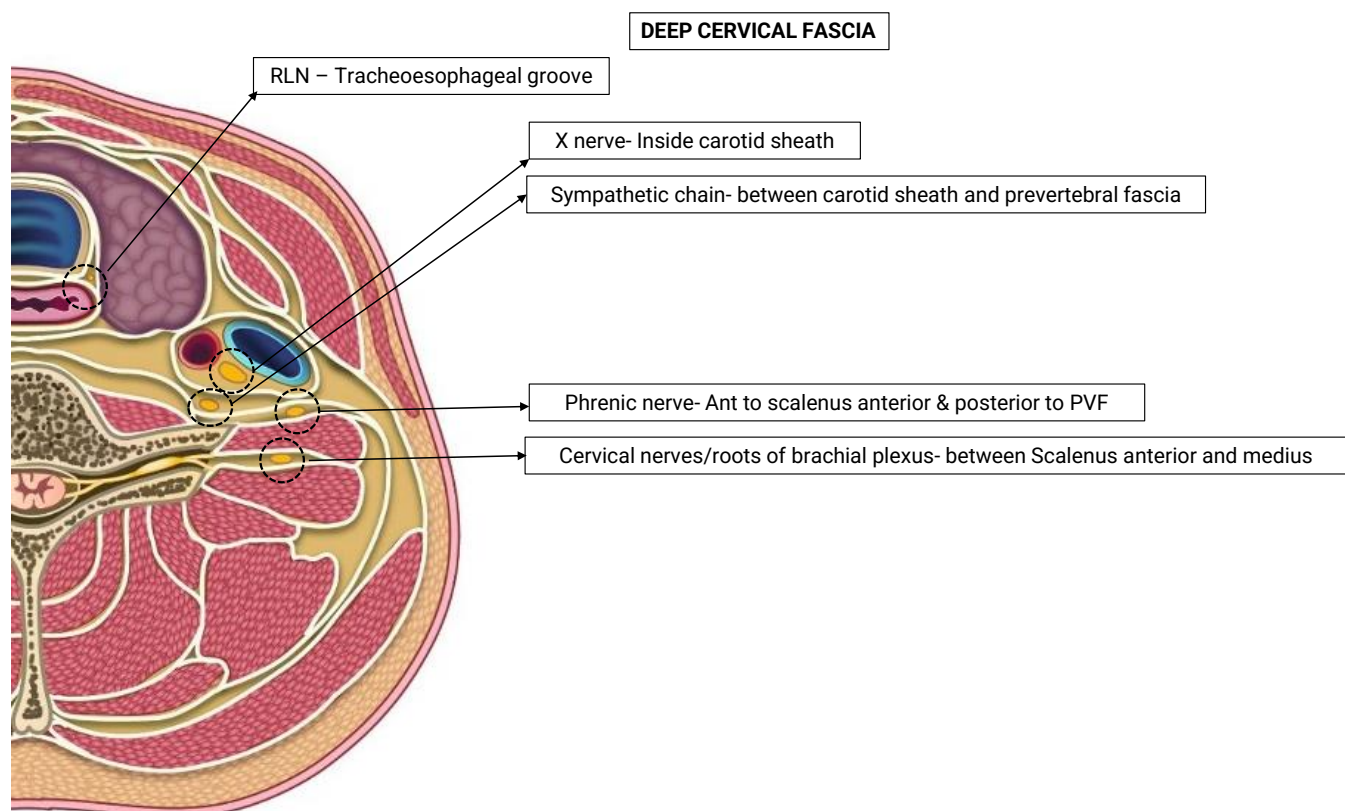
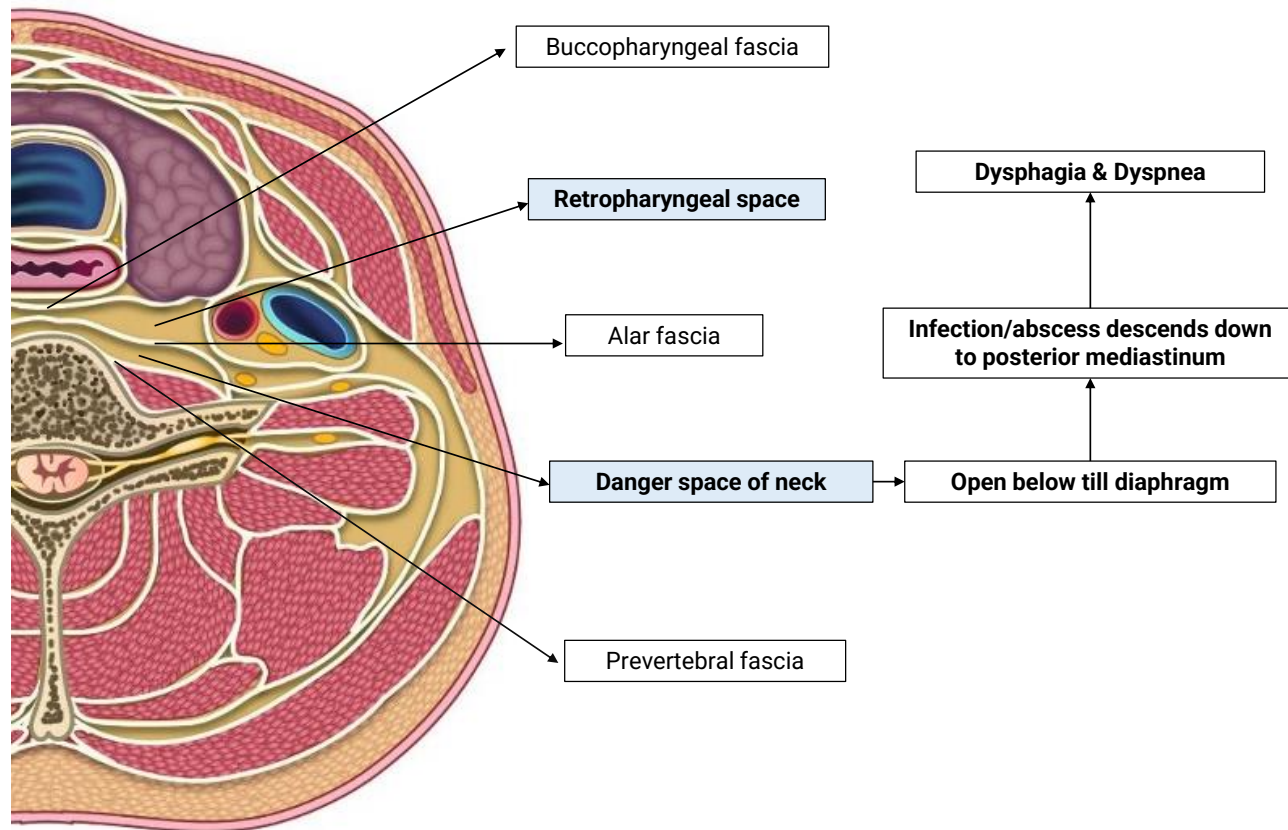
VII nerve lesion

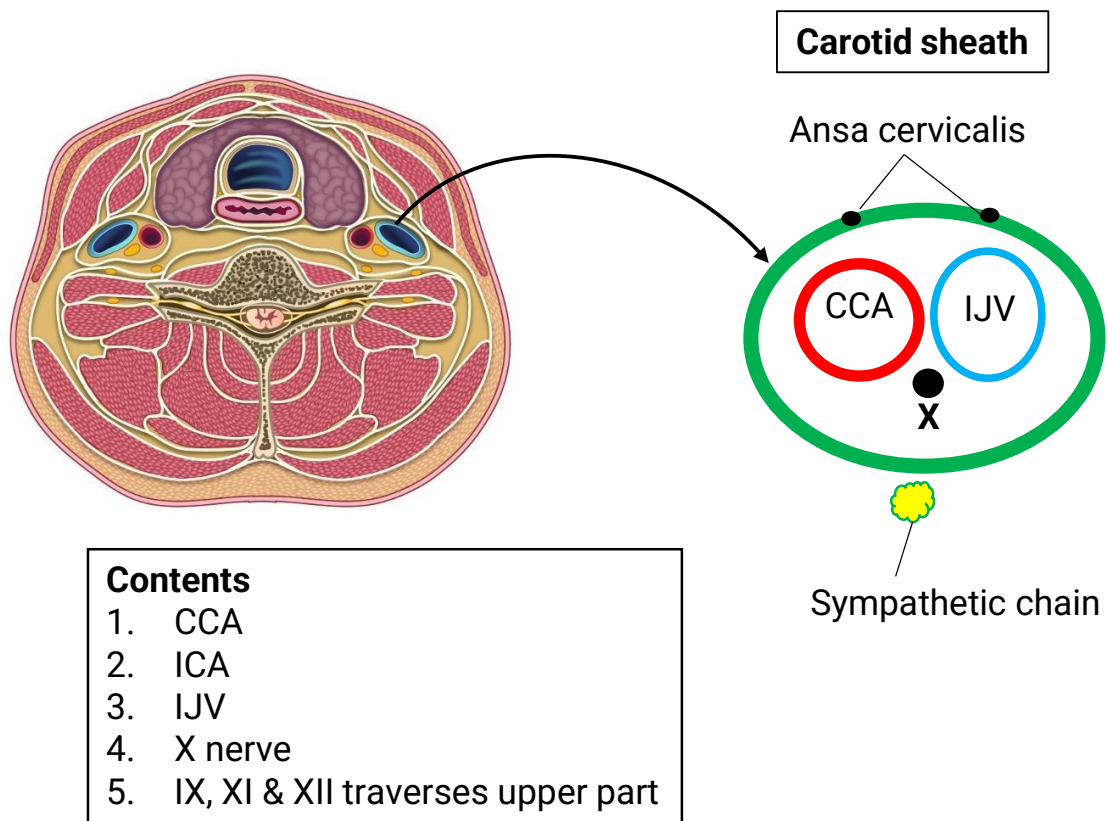


V nerve lesion



## DEEP FASCIA OF THE NECK

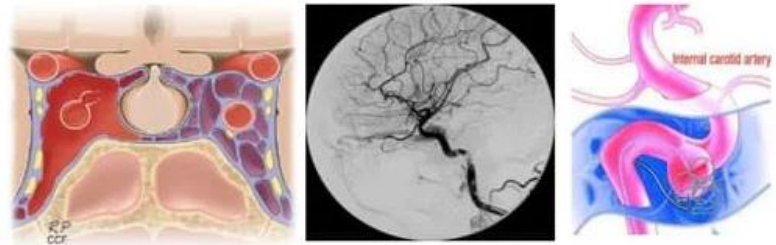
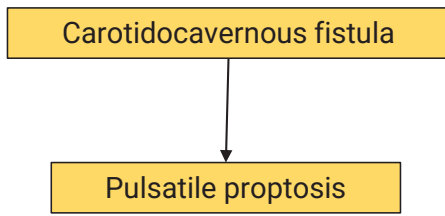
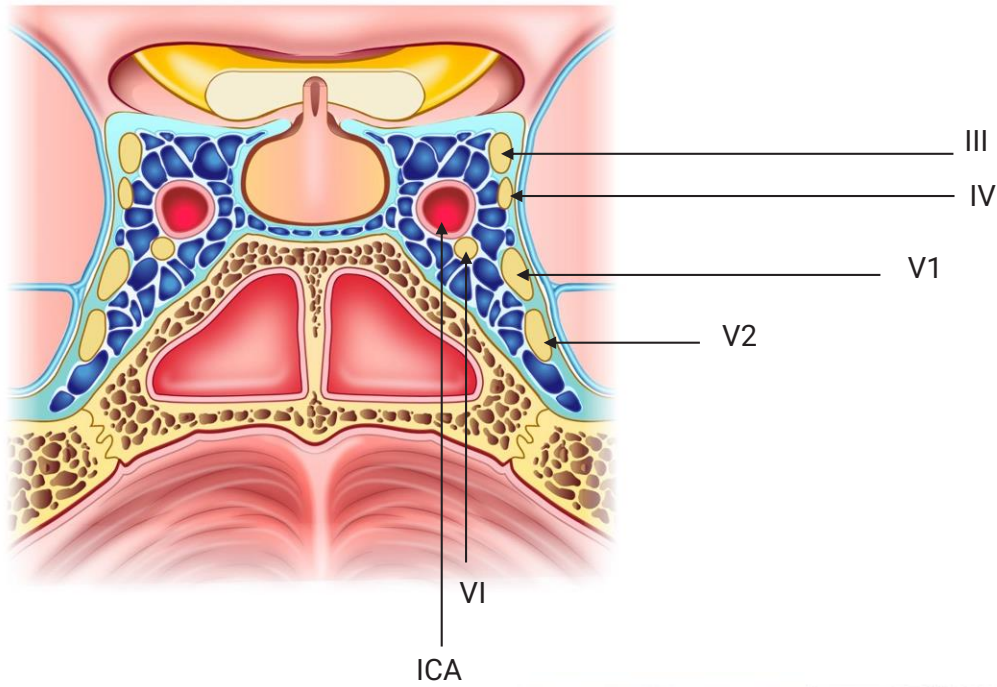




### Investing layer of Deep cervical fascia : **Rule of 2**

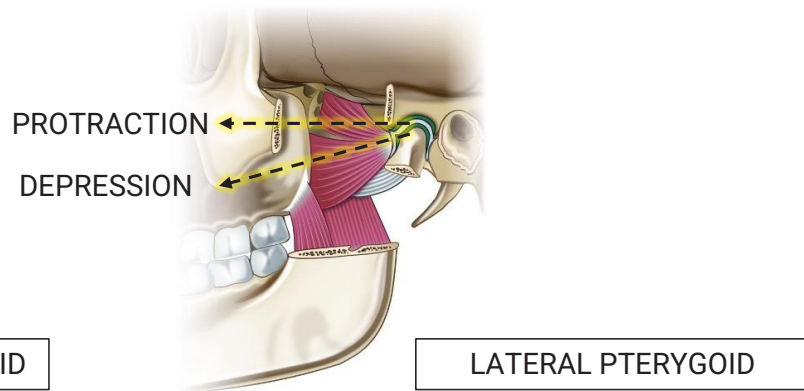
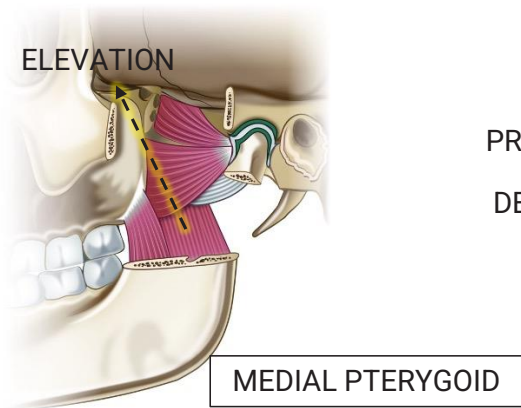
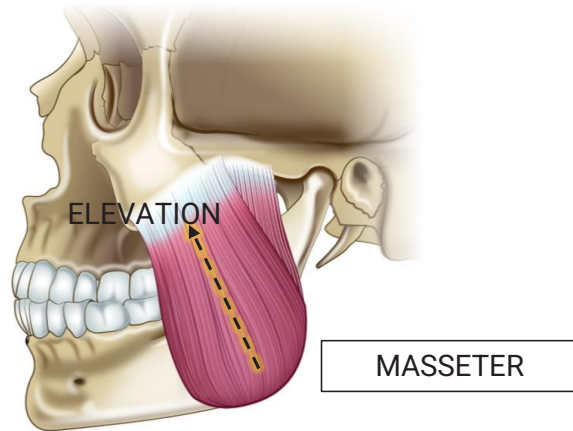
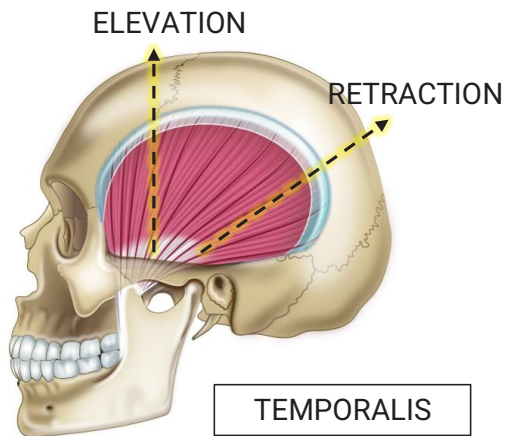
- ✓ 2 Muscles : SCM & Trapezius
- ✓ 2 Glands : Parotid & Submandibular
- ✓ 2 Ligaments : Stylomandibular & Sphenomandibular
- ✓ 2 Spaces : Suprasternal & Supraclavicular
- ✓ 2 Pulleys : Digastric and omohyoid

### CAVERNOUS SINUS RELATIONS

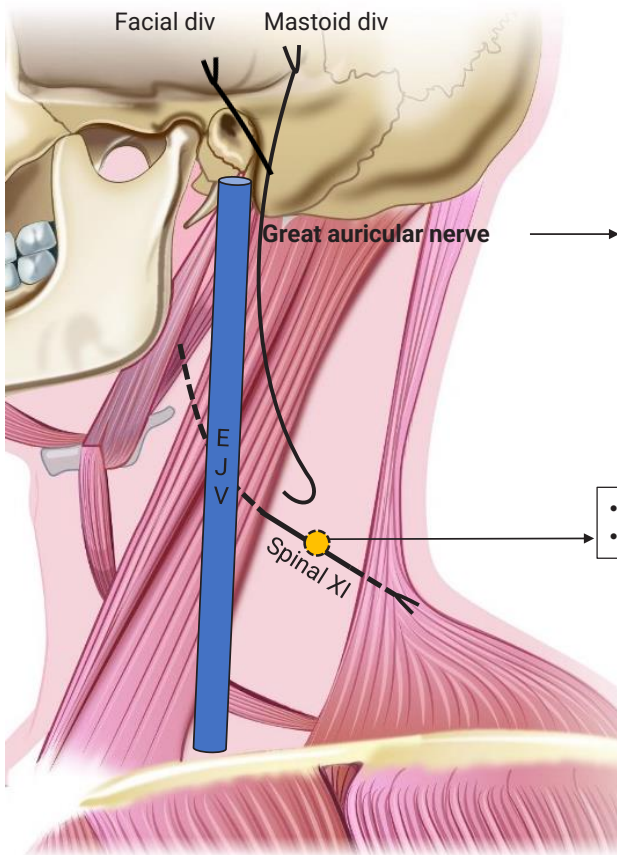




**MUSCLES OF MASTICATION**



**POSTERIOR TRIANGLE OF NECK**



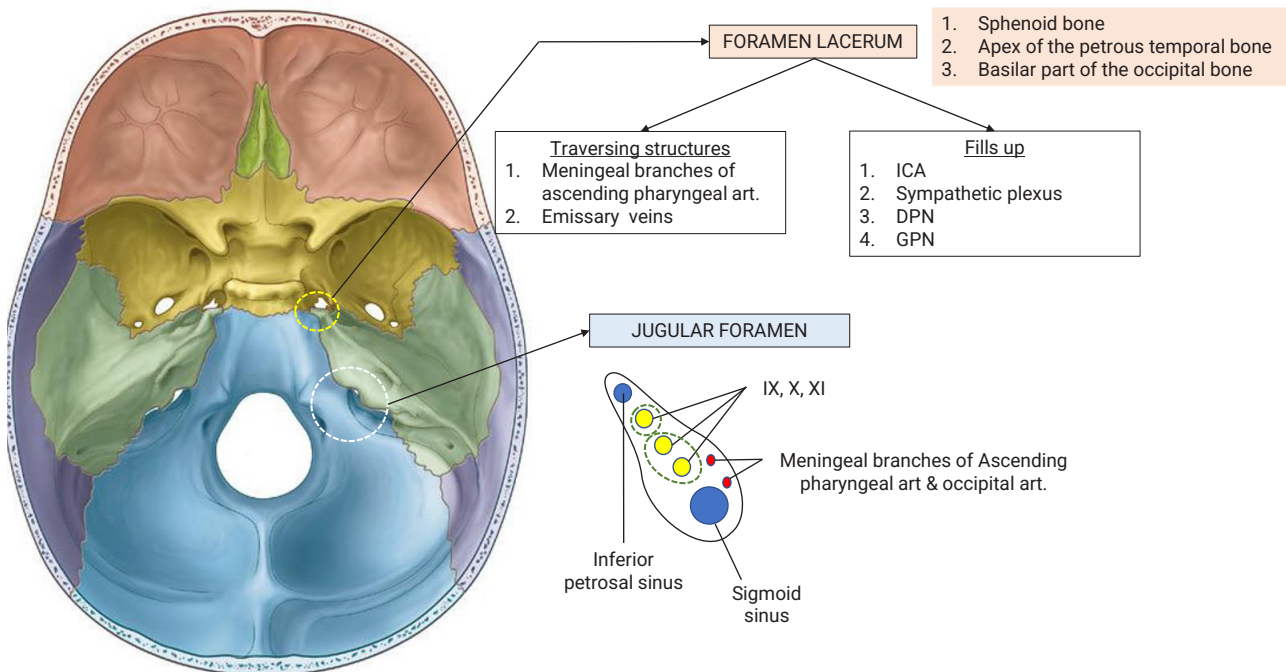
- Root value: C2-C3
- Runs with EJV
- Supplies lobule of ear
- Supplies skin at angle of mandible & parotid region
- In Frey's syndrome- ATN communicates to GAN
- Injured in parotid Sx- sensory loss in shaving area

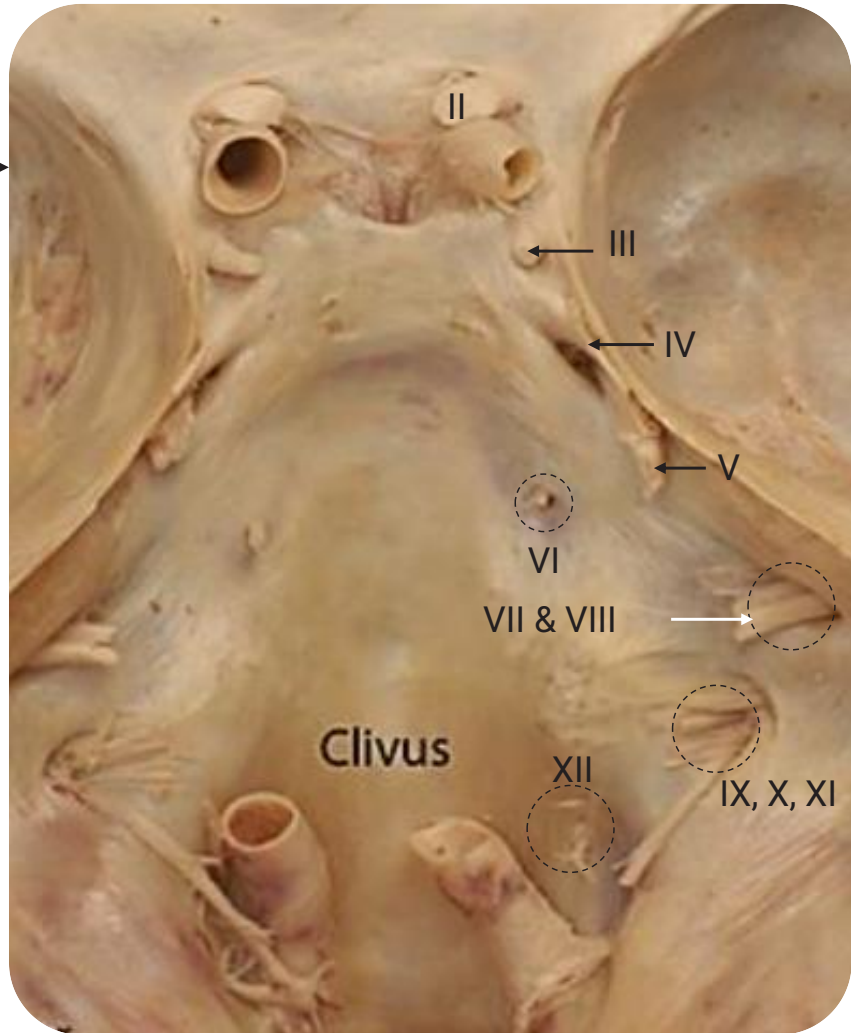
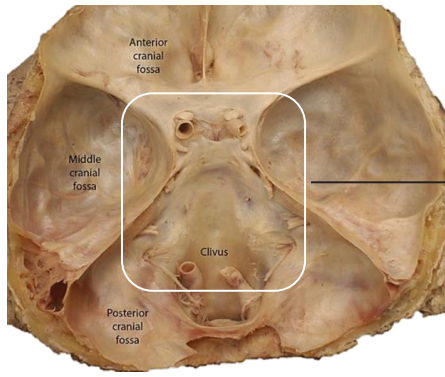
- Runs between investing layer and prevertebral layer
- Injury in posterior triangle

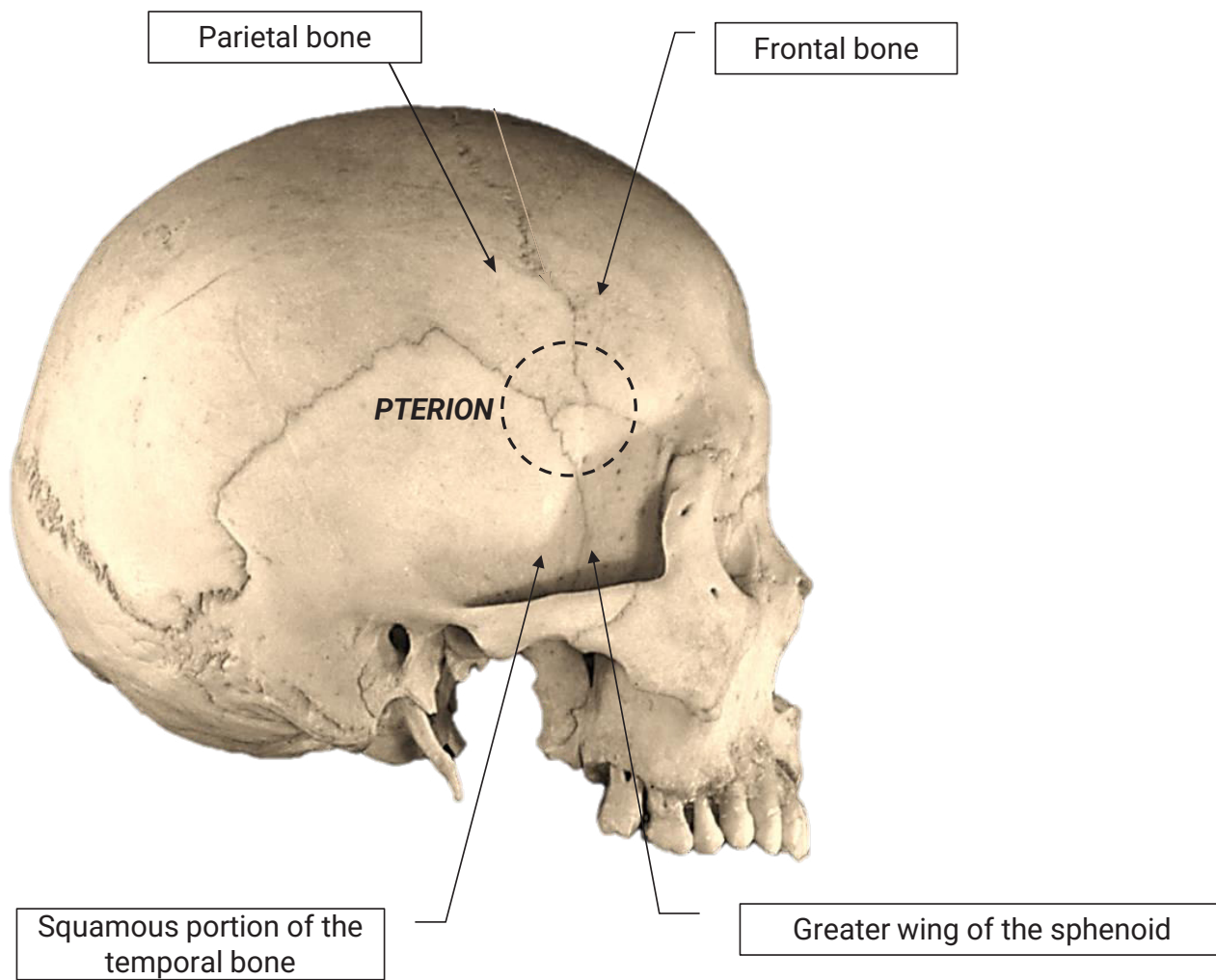
(SCM - Spared)

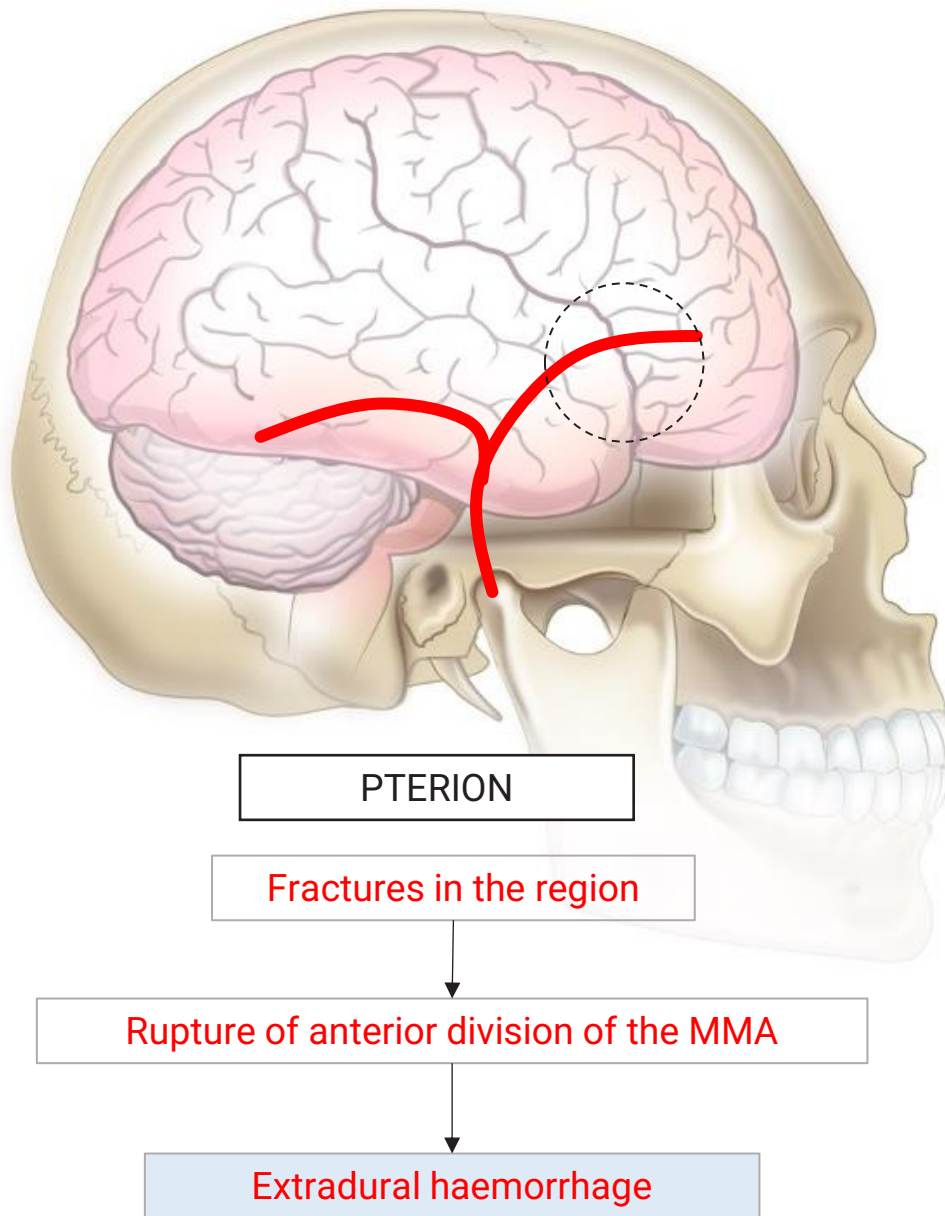
Trapezius- affected

- Difficulty in shrugging of shoulder
- Difficulty in retraction of scapula
- Difficulty in overhead abduction



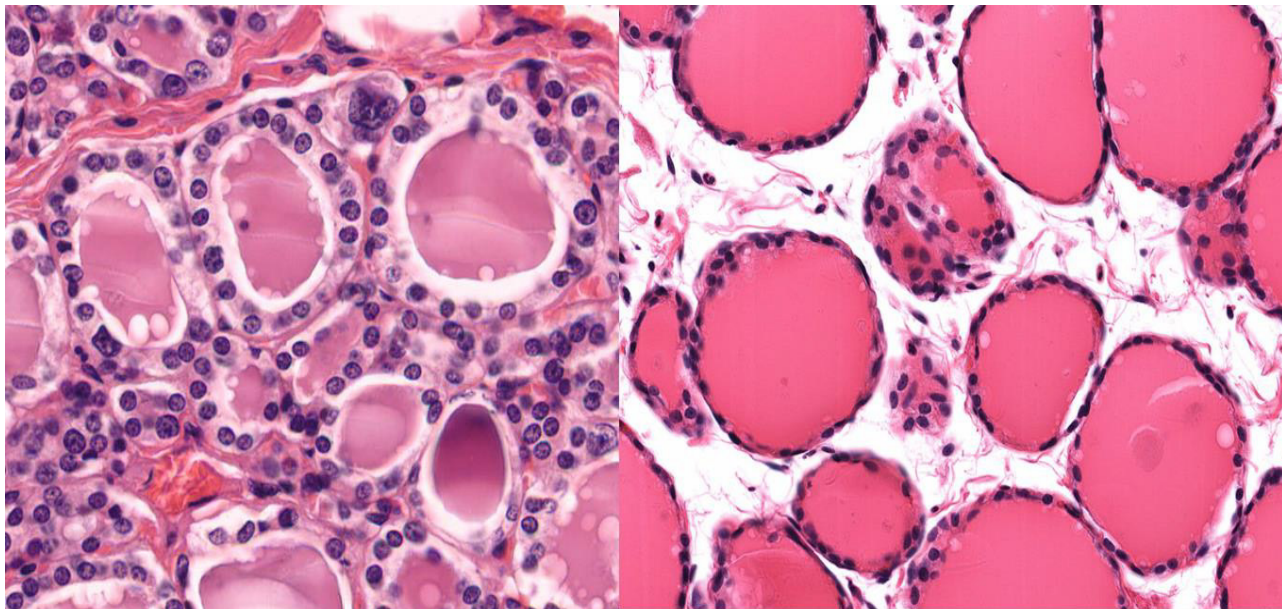
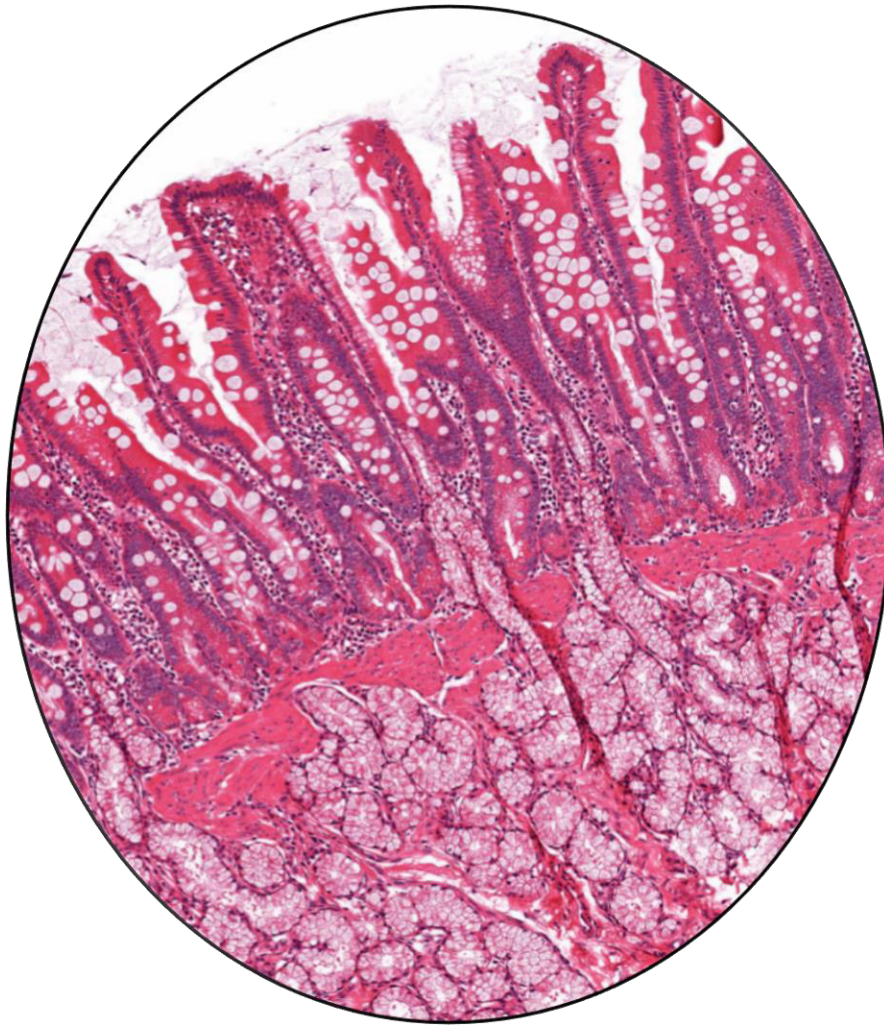


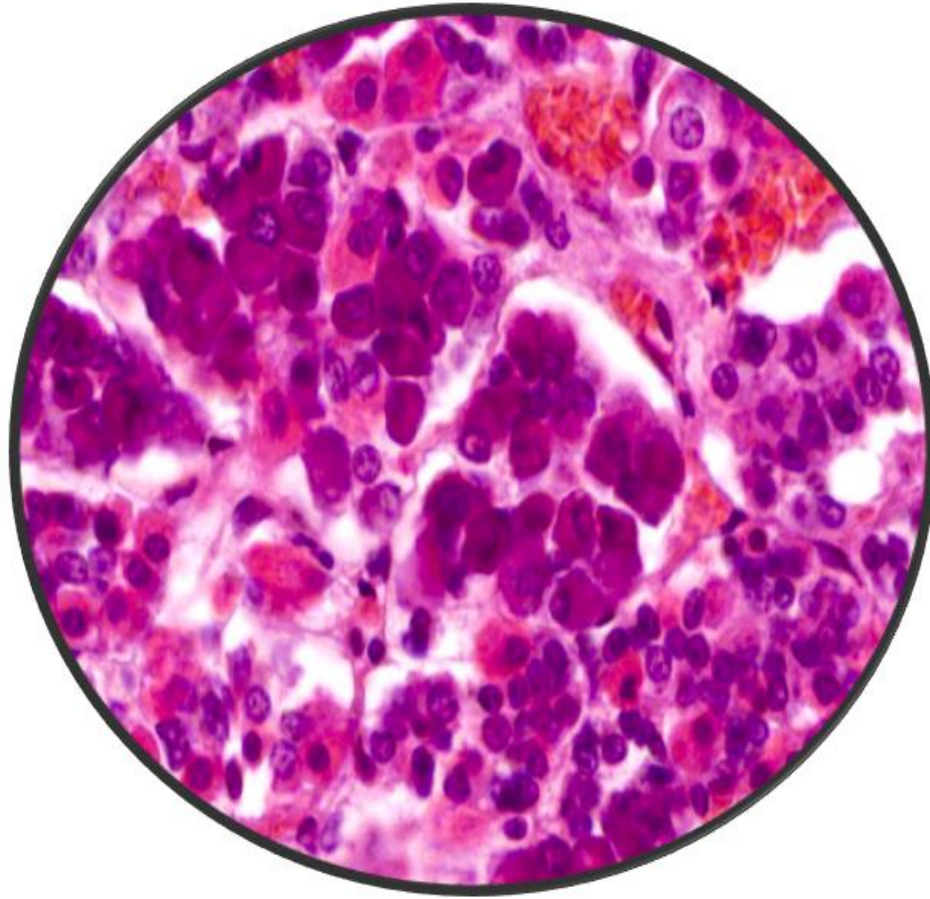




**Relations :**

- Superficial temporal vessels
- Anterior division of the middle meningeal vessels
- Middle cerebral vessels
- Sylvian fissure
- Insula
- Broca's motor speech area (on the left)
- Lesser wing of the sphenoid bone












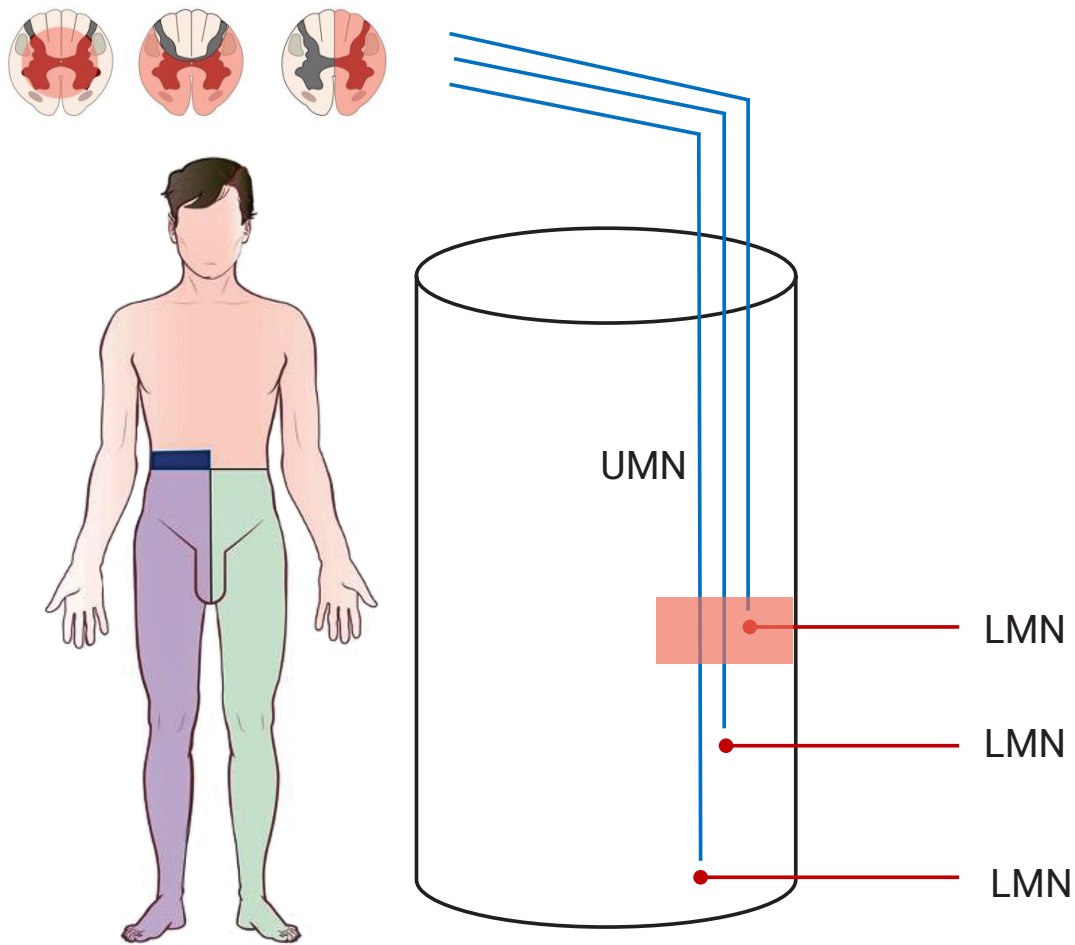
## NOTES



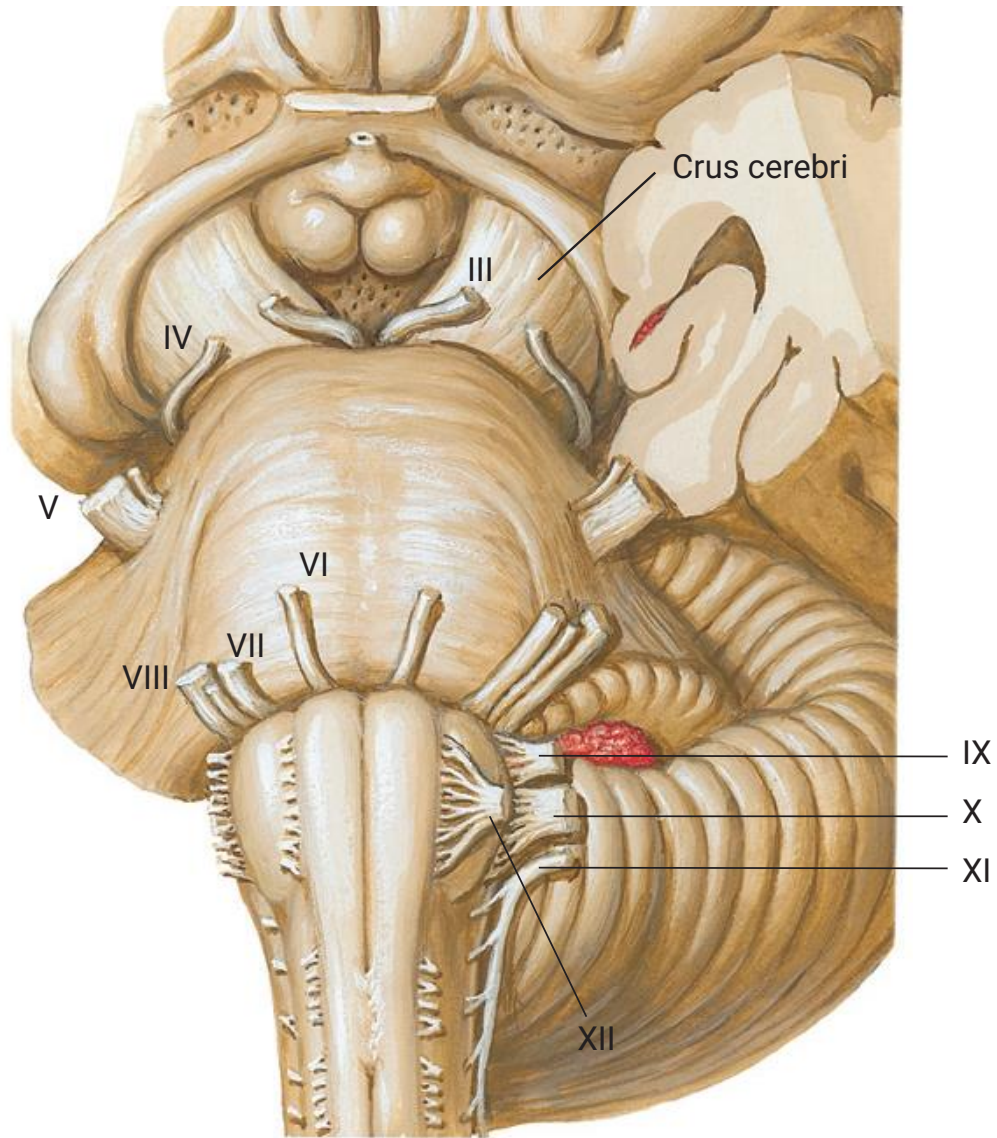
# NEUROANATOMY

## BROWN SEQUARD SYNDROME

-  Ipsilateral loss of all sensory modalities at the level of the lesion
-  Ipsilateral flaccid paralysis at the level of the lesion
-  Ipsilateral spastic paraparesis below the lesion
-  Ipsilateral loss of vibration and position sense below the lesion
-  Contralateral loss of pain and temperature below the lesion



VENTRAL ASPECT OF BRAINSTEM



**DORSAL ASPECT OF BRAINSTEM- FLOOR OF IV VENTRICLE**

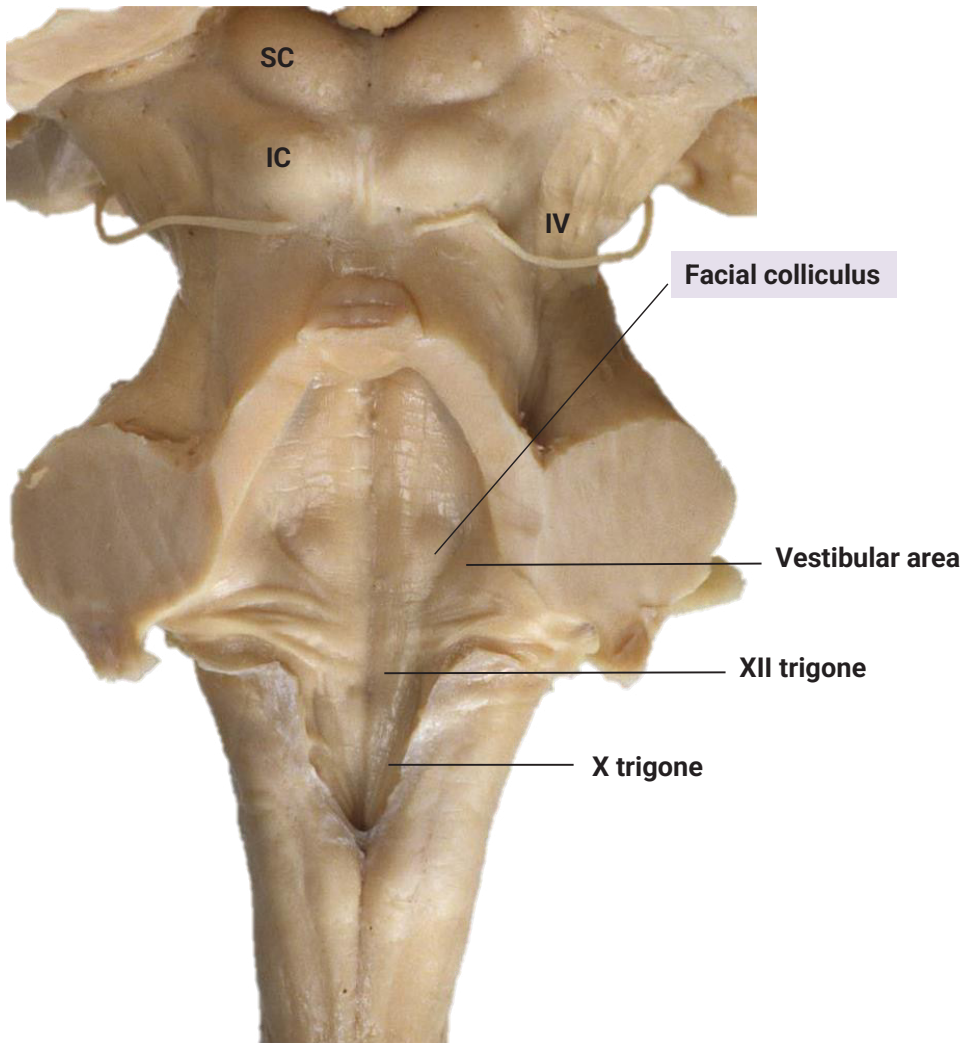
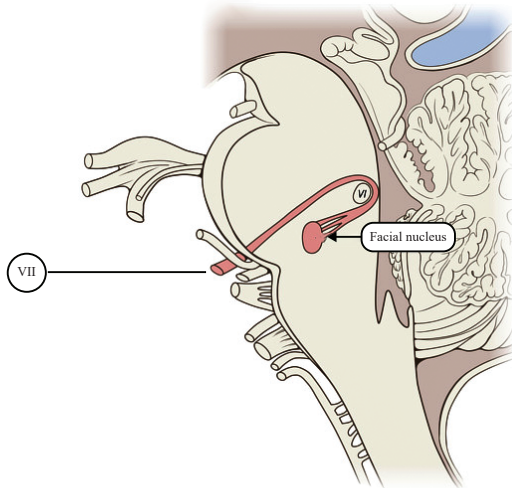
**Cranial nerve nuclei in the floor of IV ventricle  
VI, VIII, X & XII**

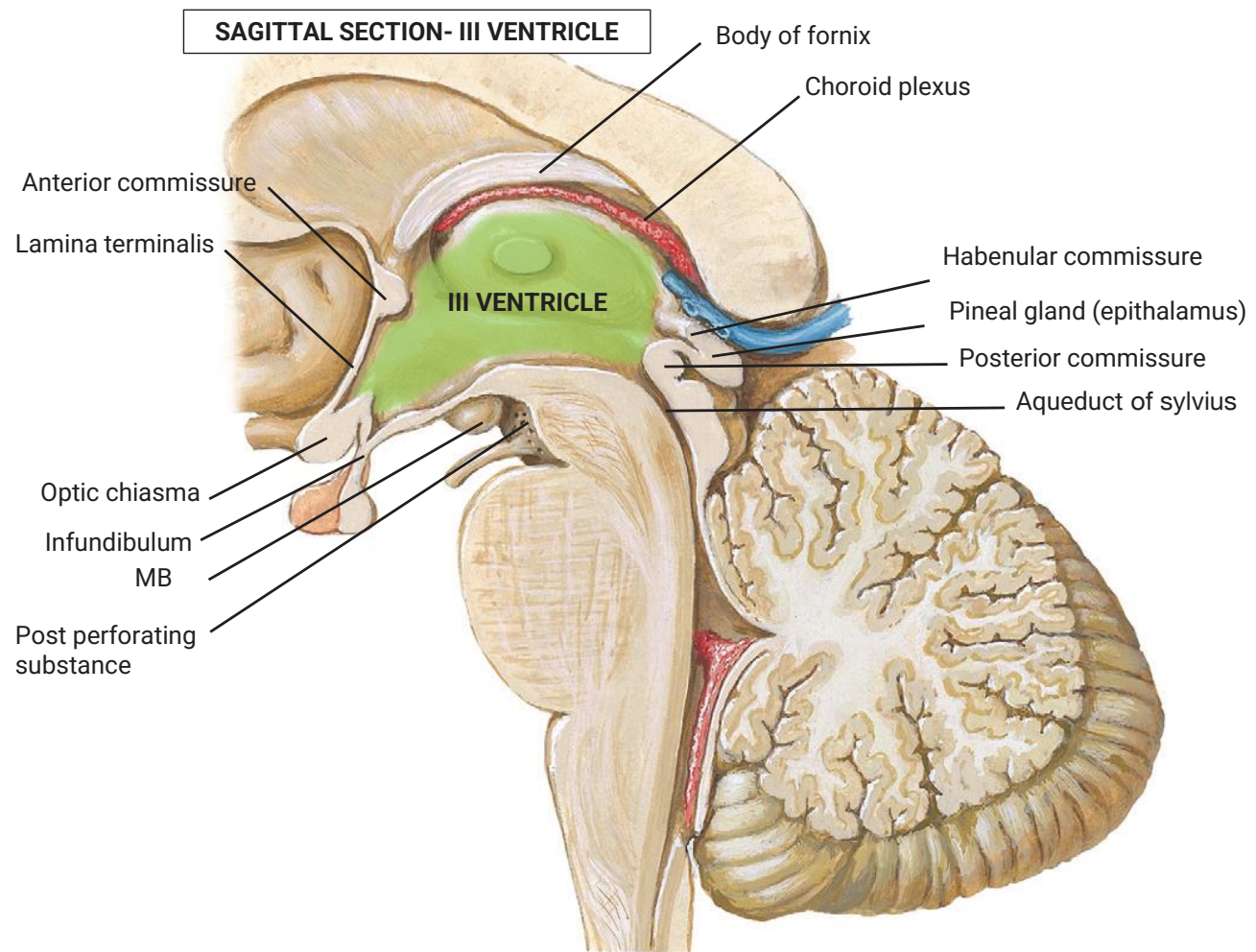
**Abducent nucleus surrounded by LMN  
of VII nerve**

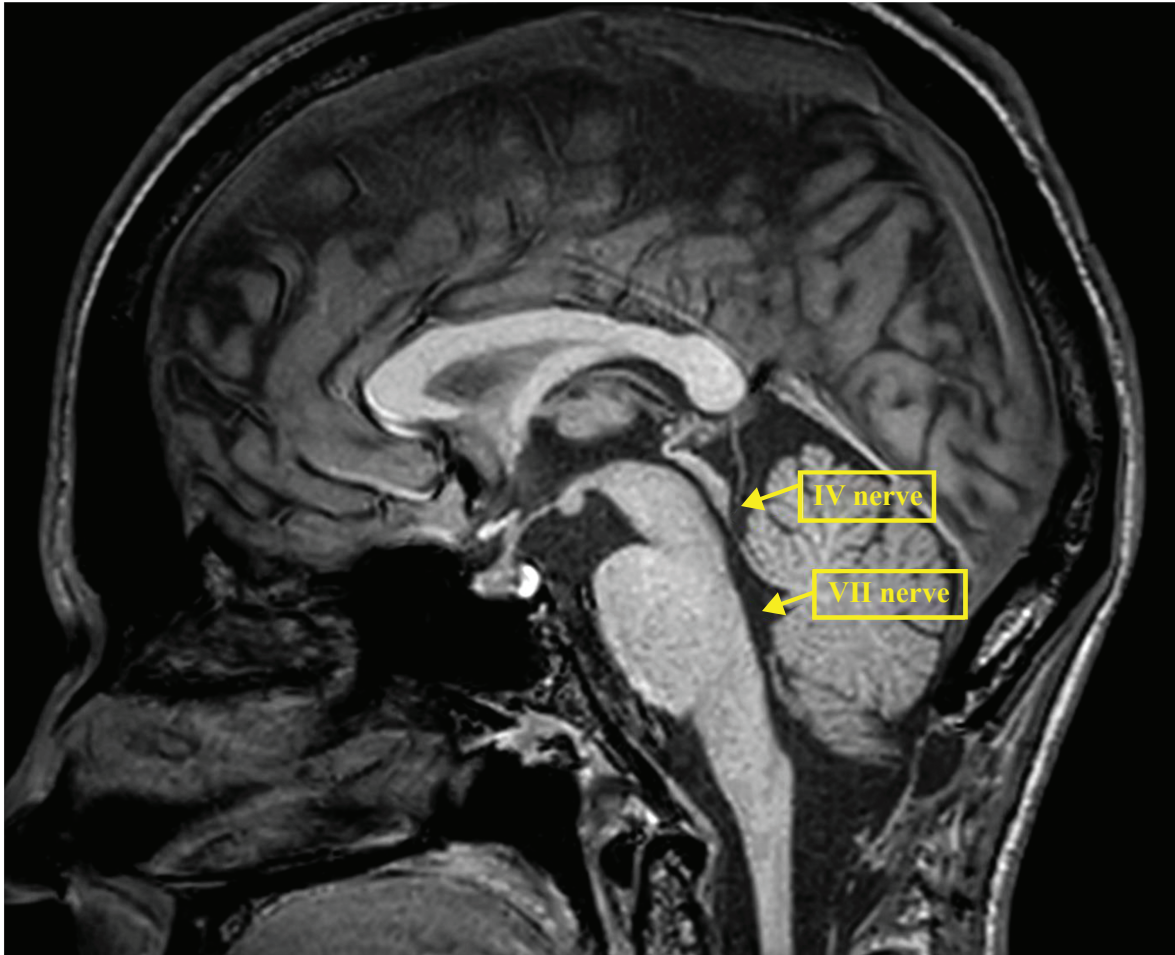
*Injury*

**LMNL of VII nerve**

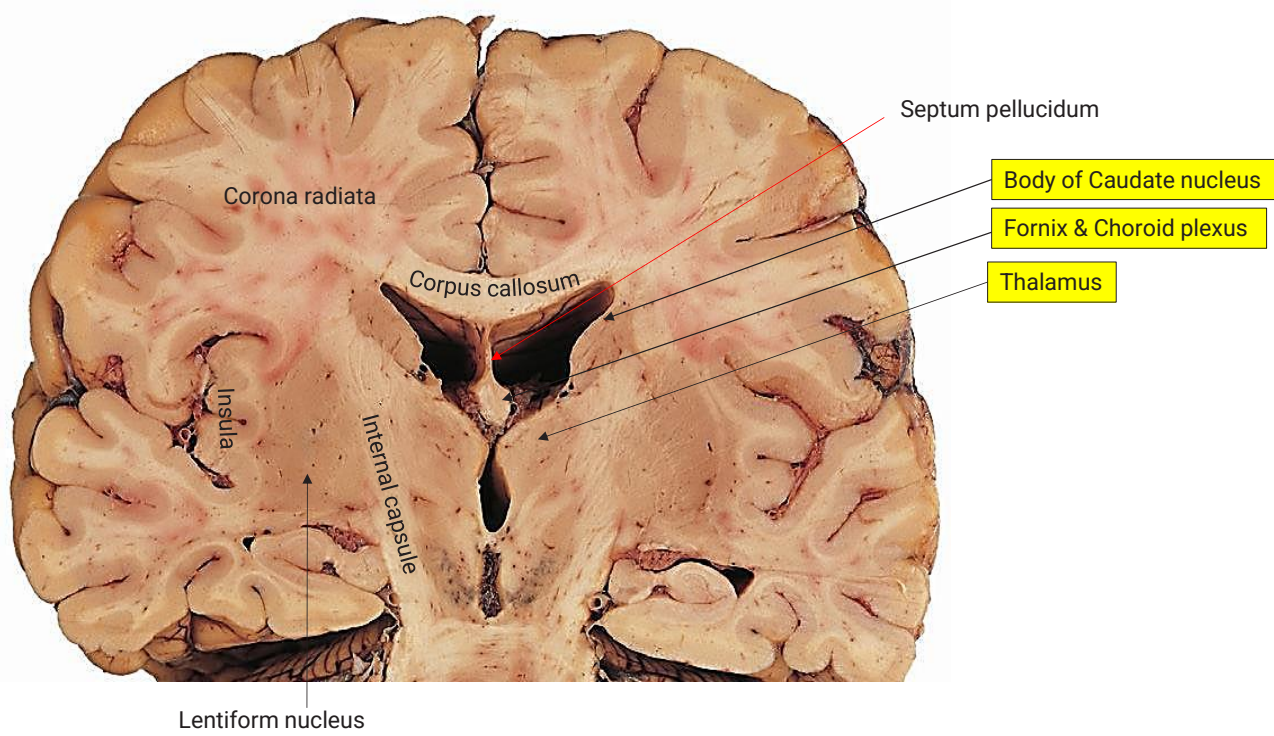
**I/L facial paralysis**

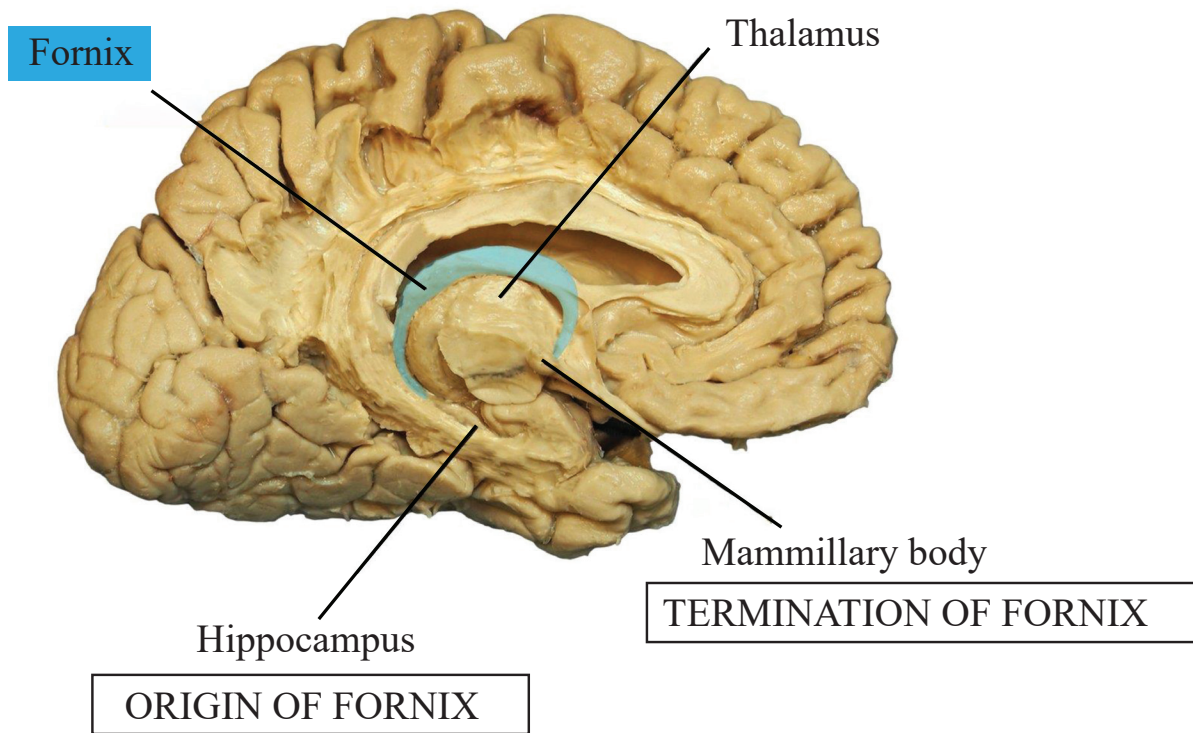




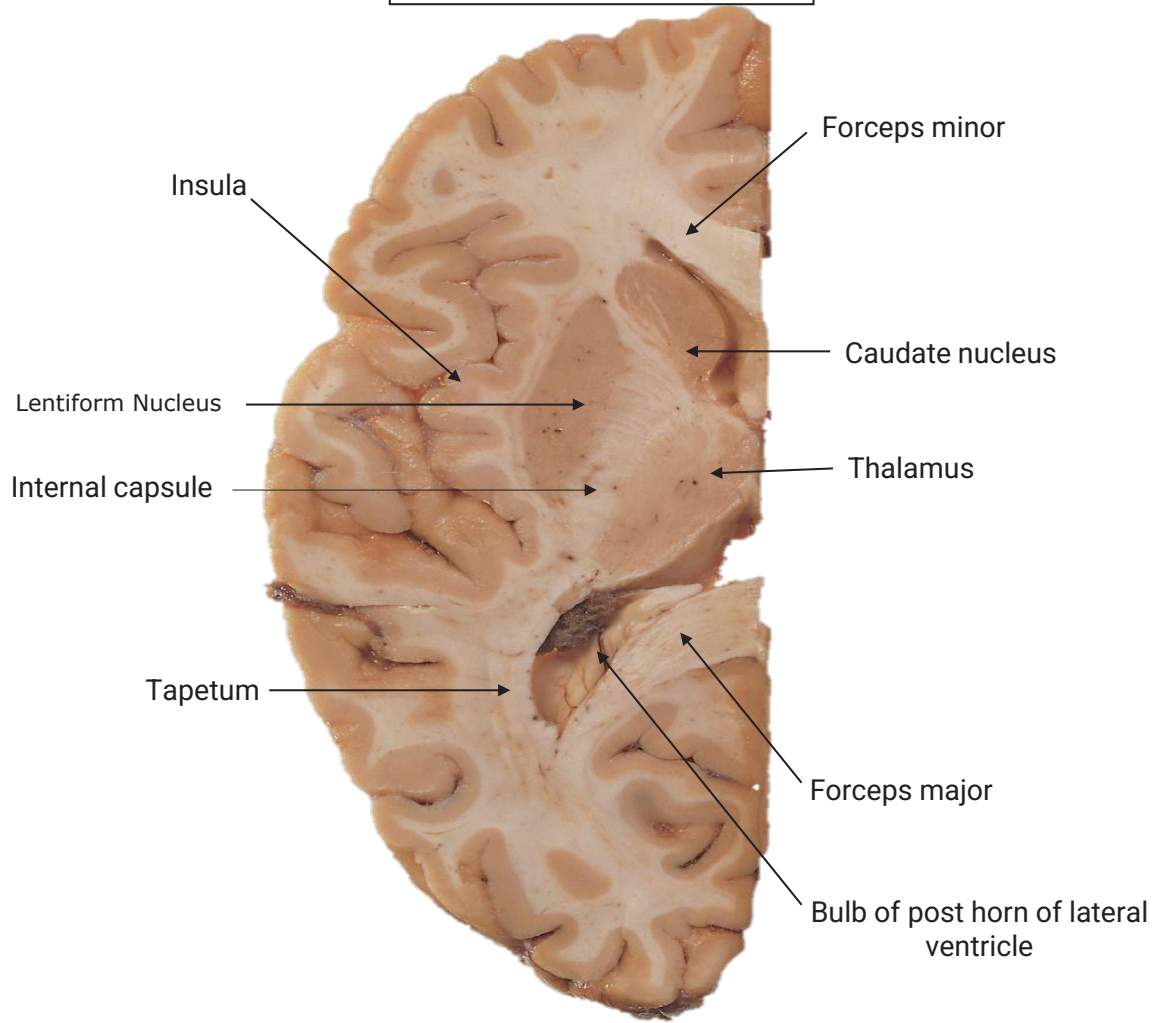


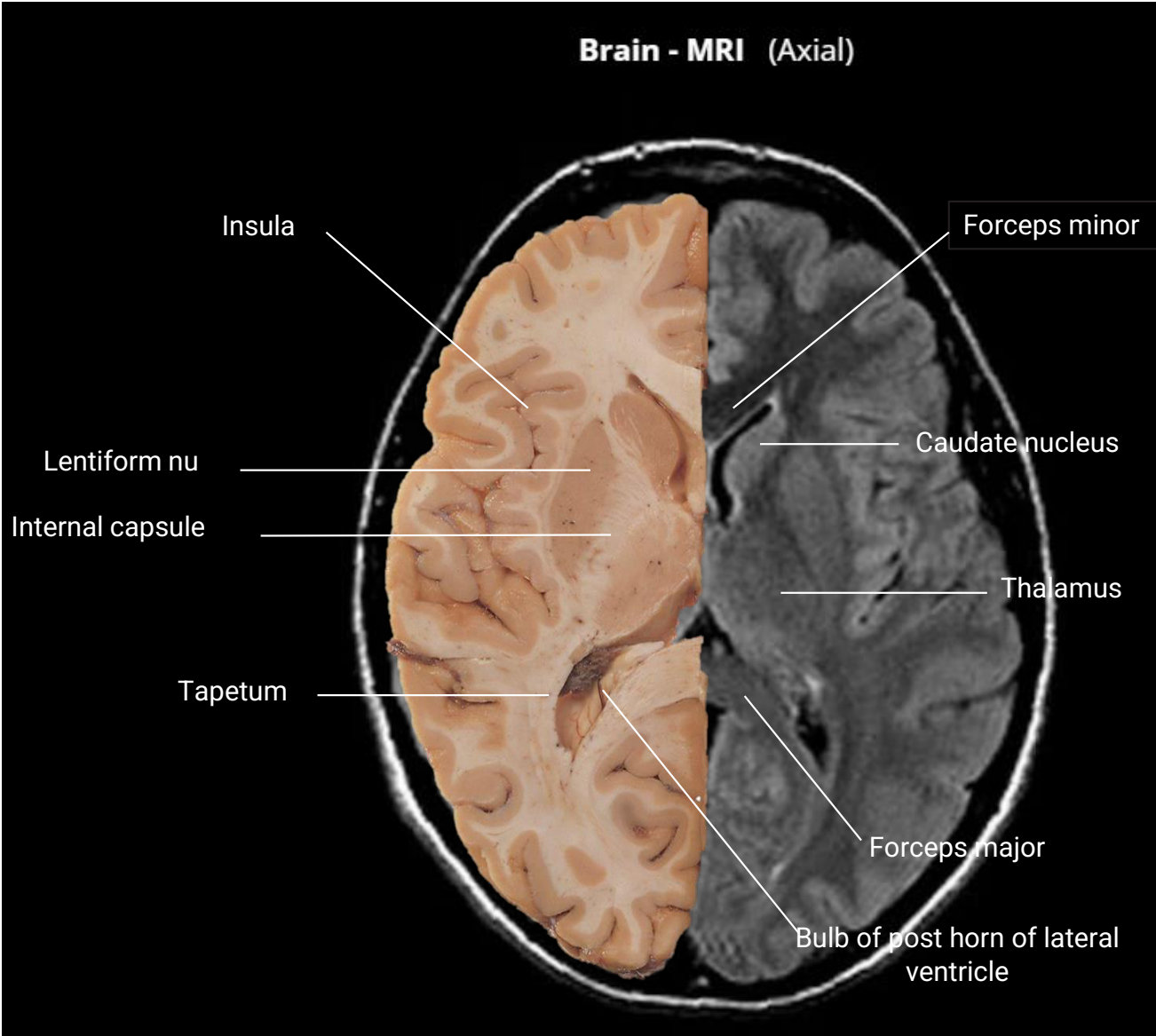
CORONAL SECTION- LATERAL VENTRICLE



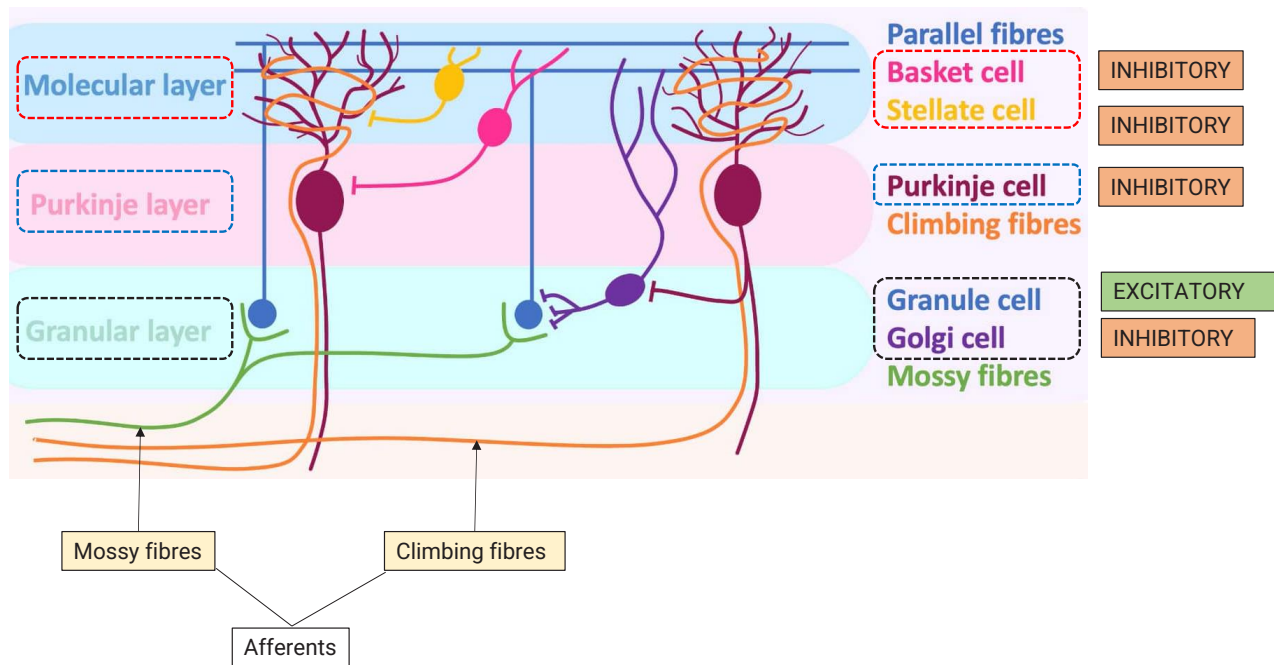


**TRANVERSE SECTION**

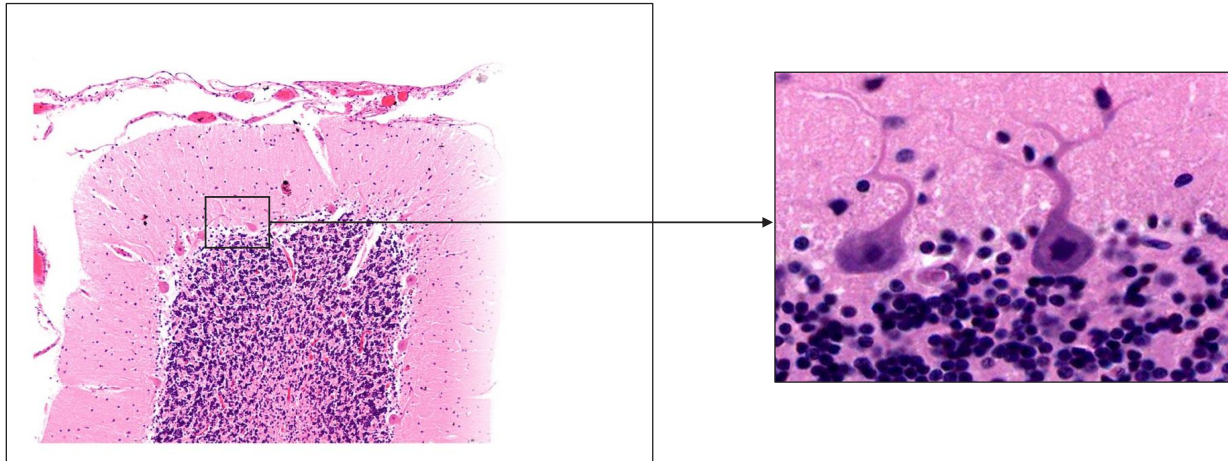




**CEREBELLAR CORTEX**



- Olivocerebellar & Para-olivocerebellar tract are CLIMBING FIBRES
- Rest all are Mossy

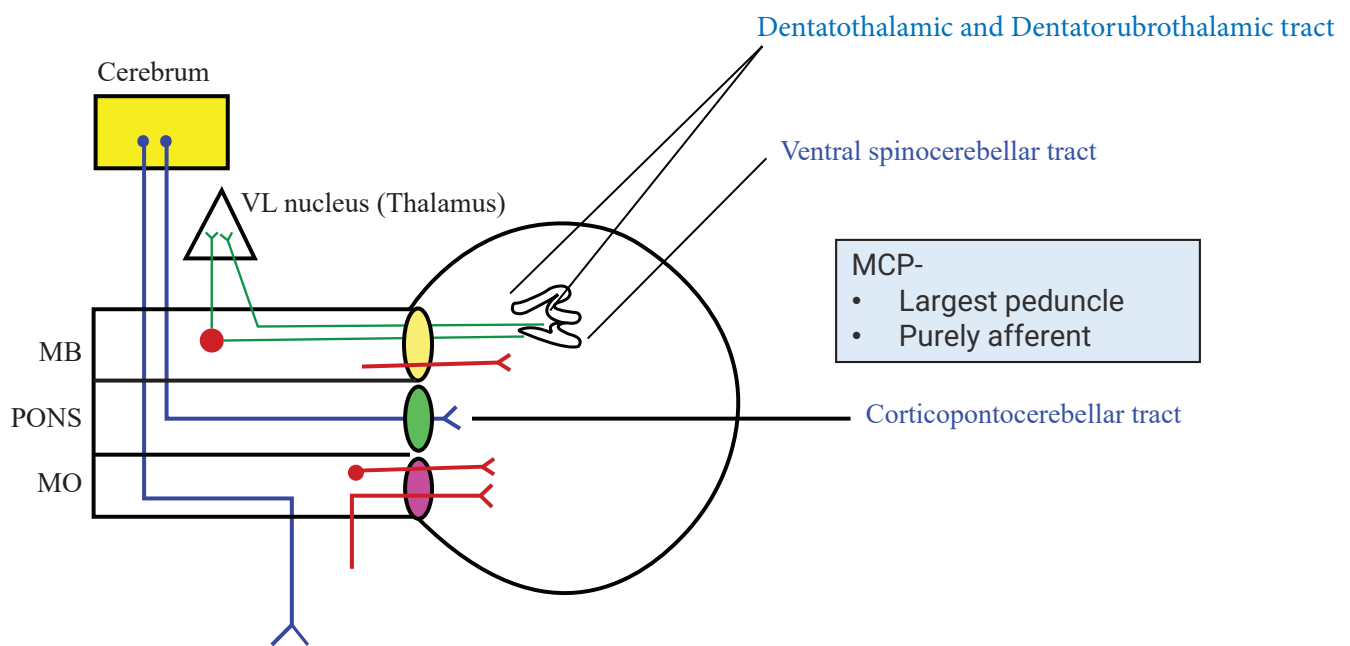


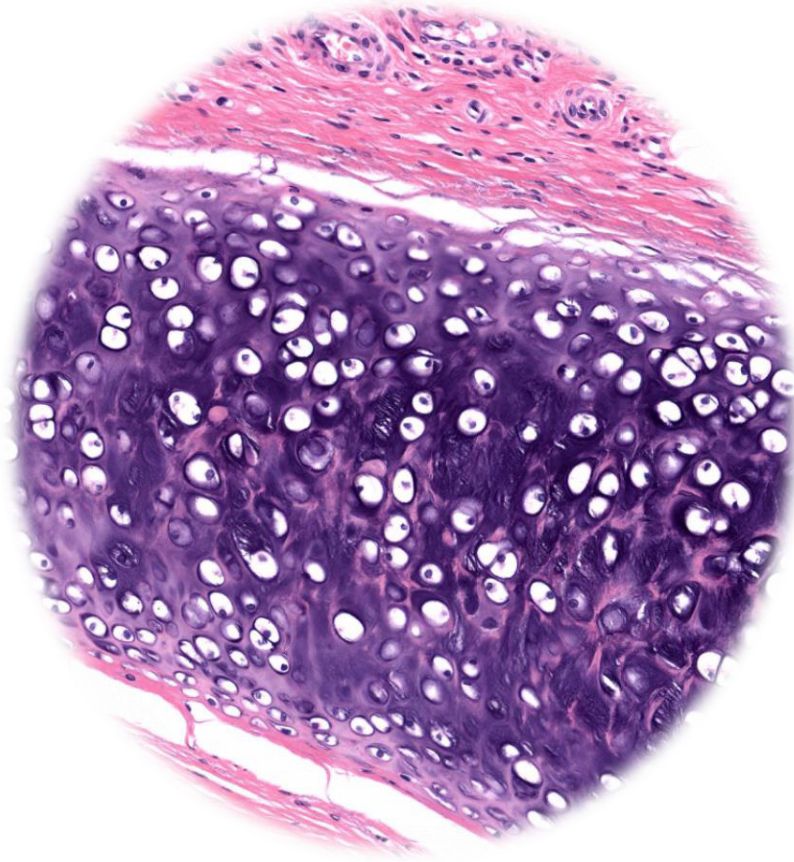
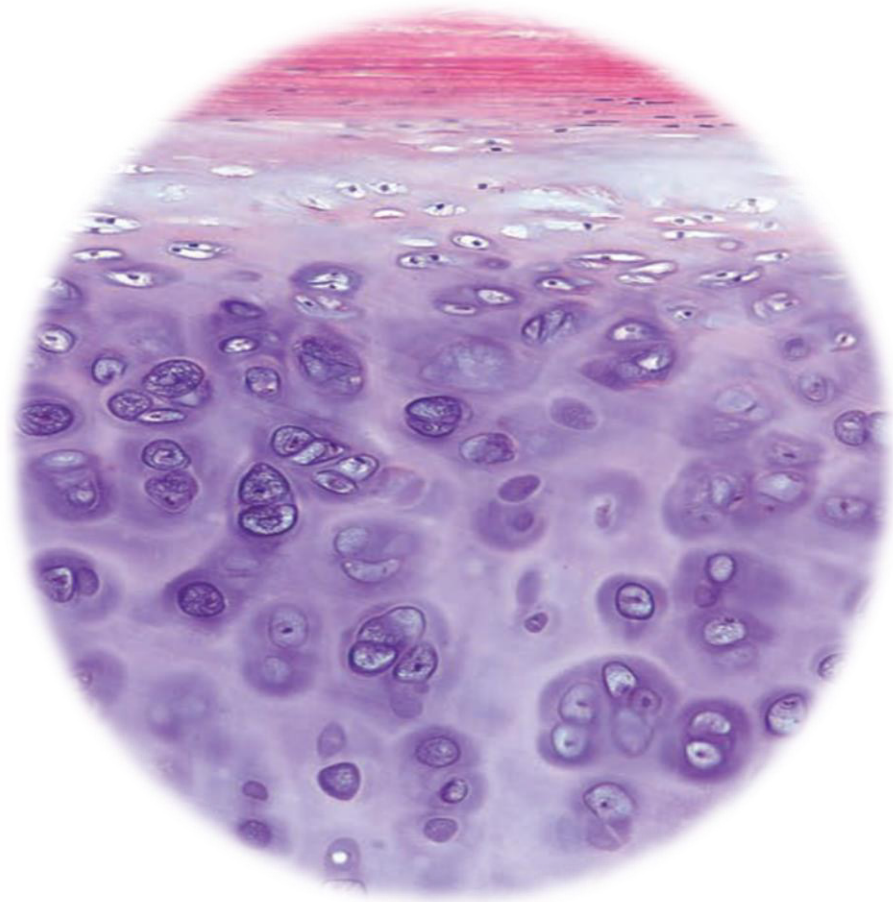
PURKINJE CELLS

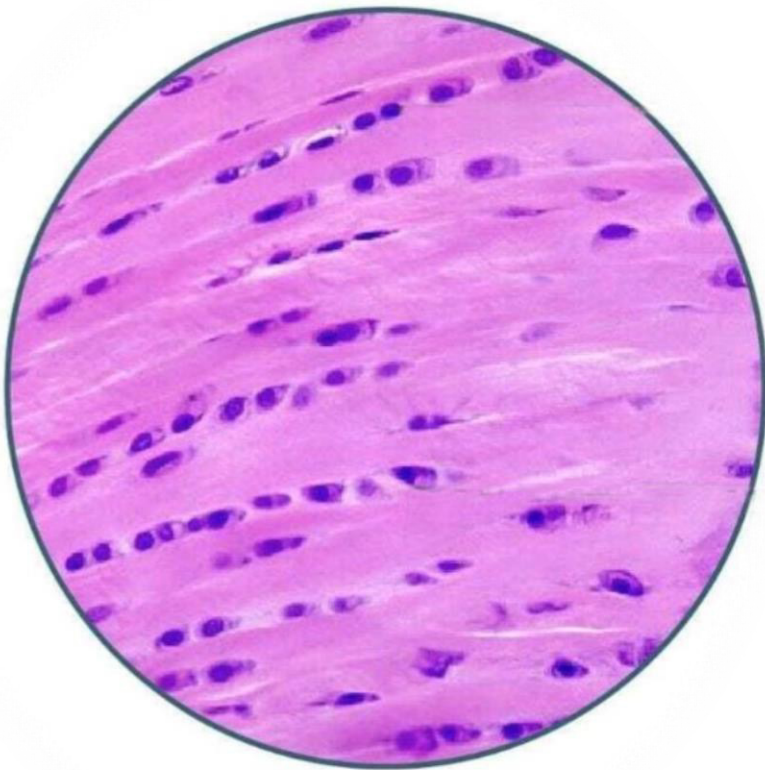ONLY EFFERENTS FROM  
CORTEX

EFFERENTS FROM  
CEREBELLUM

DEEP CEREBELLAR NUCLEI  
(mainly Dentate nucleus)





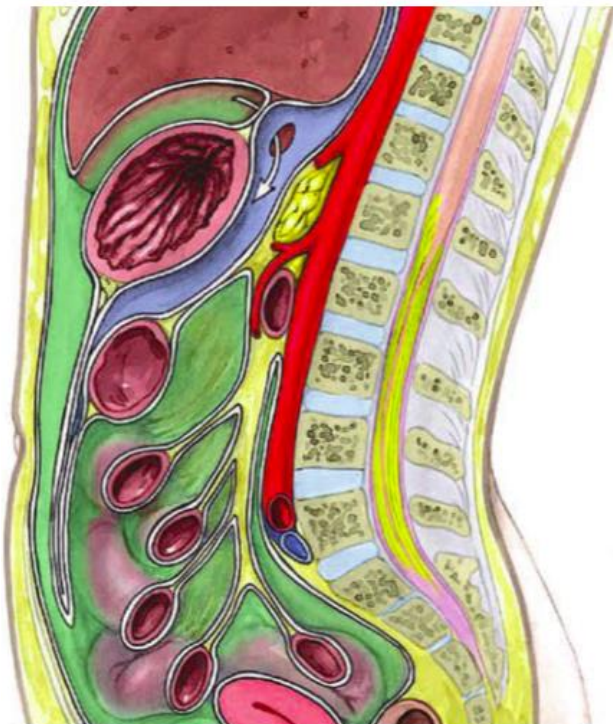
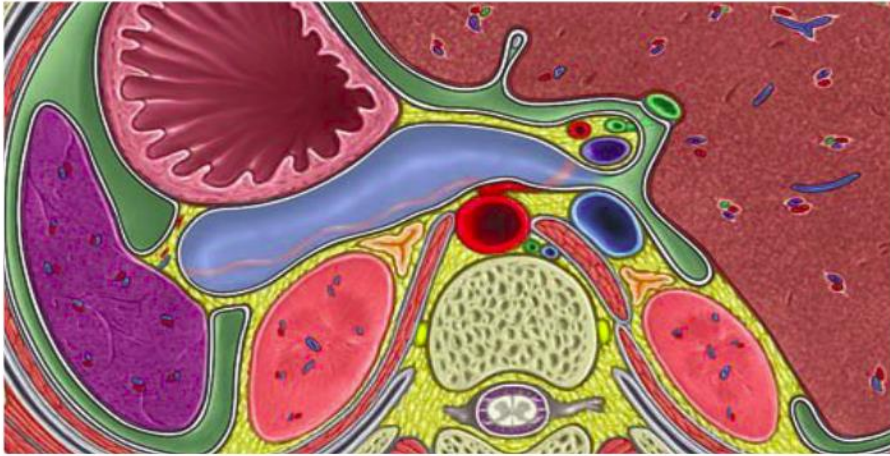




## NOTES



## ABDOMEN & PERINEUM



## Pelvic Diaphragm

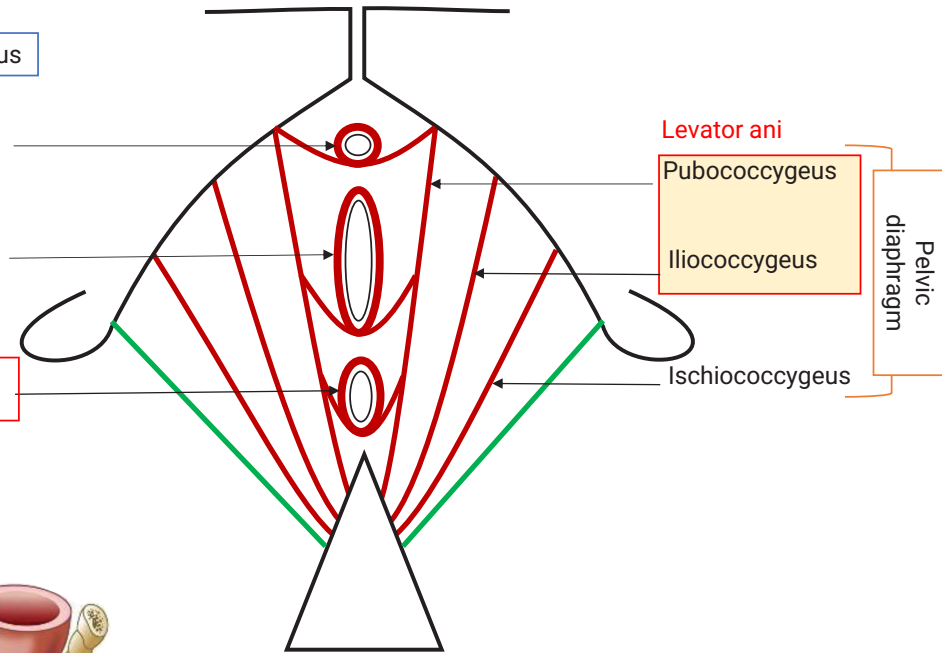
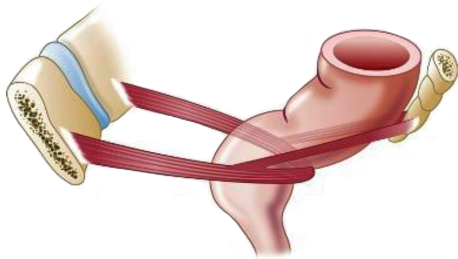
### Modifications of Pubococcygeus

1. Pubourethralis

2. Pubovaginalis

3. Puborectalis

Muscle of continence



Perineal membrane  
Inferior layer of UGD

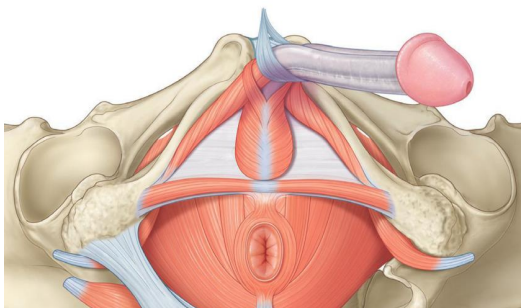
Bulb/ bulbospongiosus

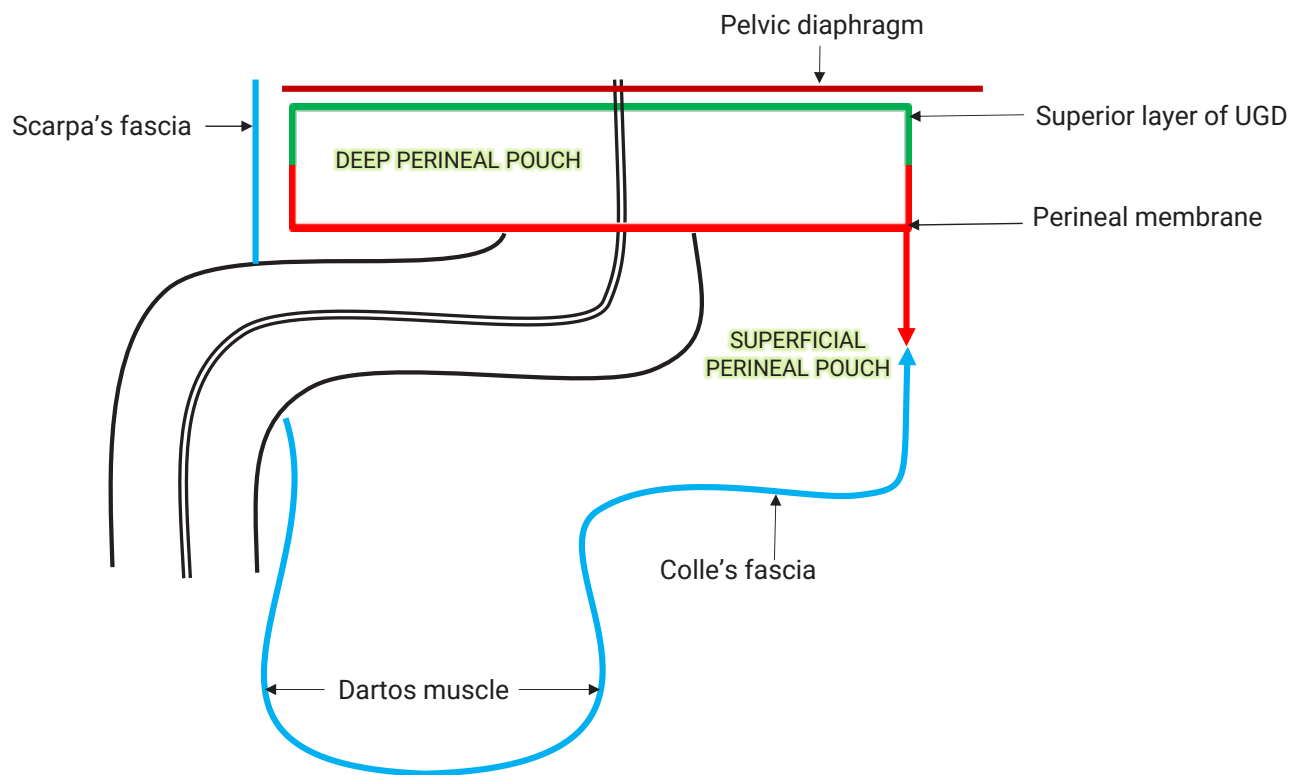
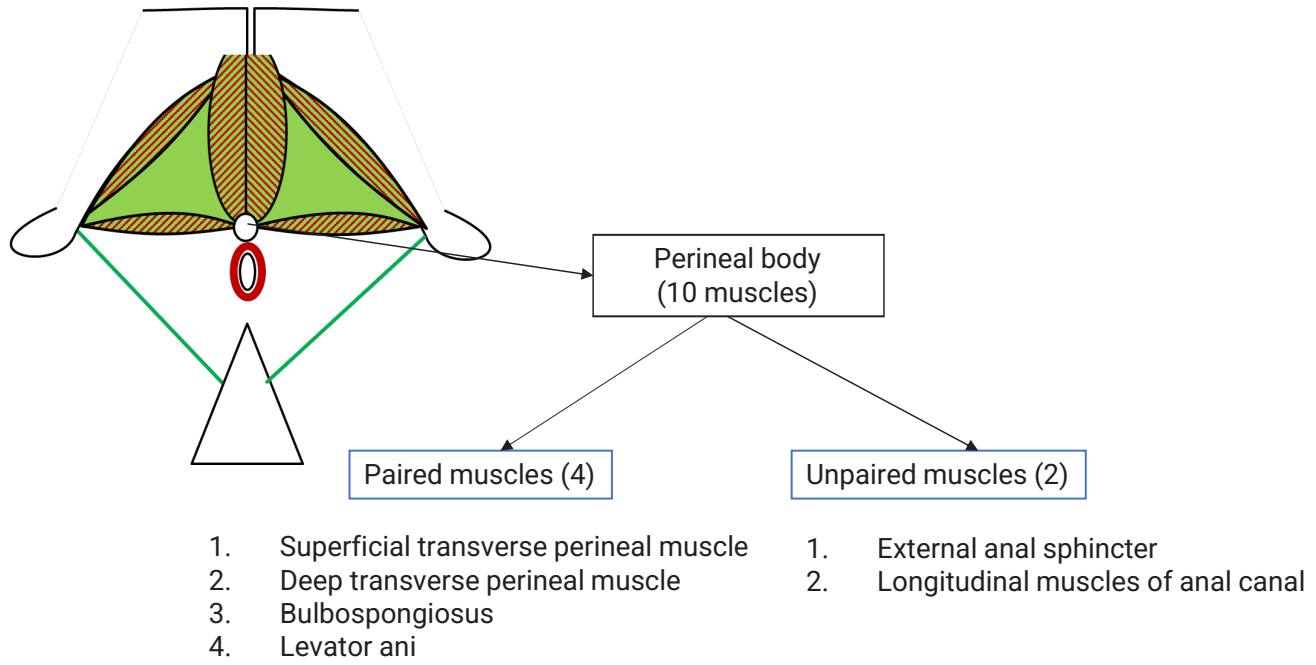
Crus/ Ischiocavernosus

Perineal body

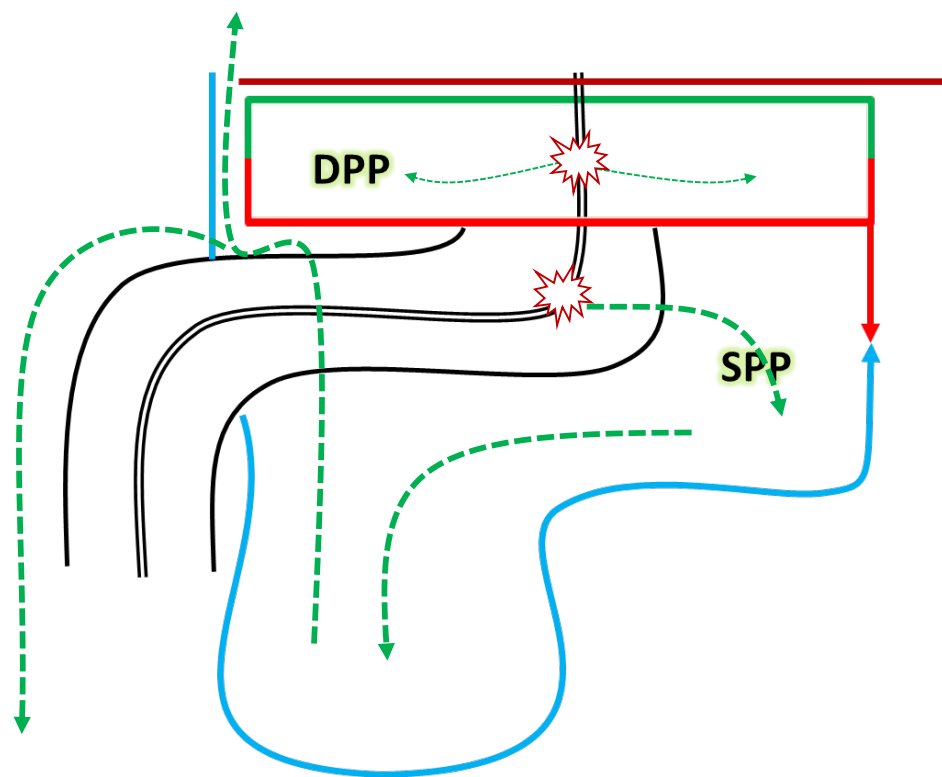
Superficial transverse perineal muscle

External anal sphincter

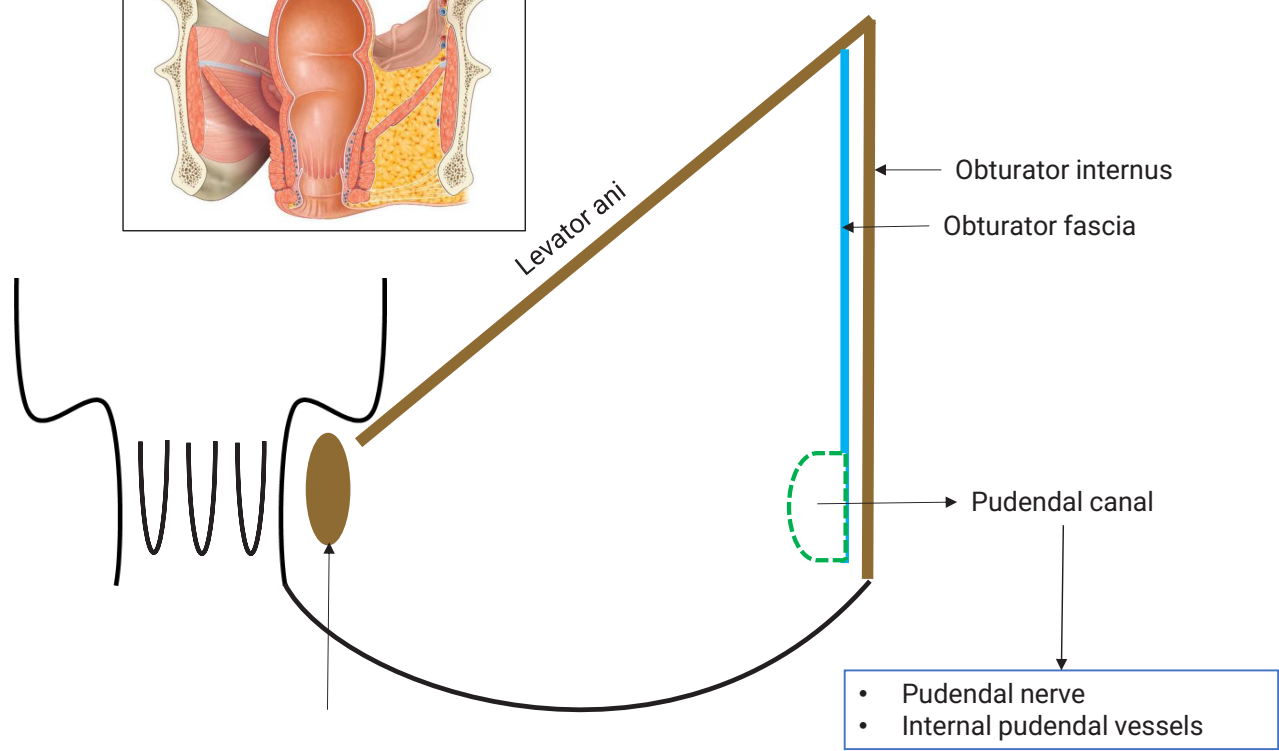
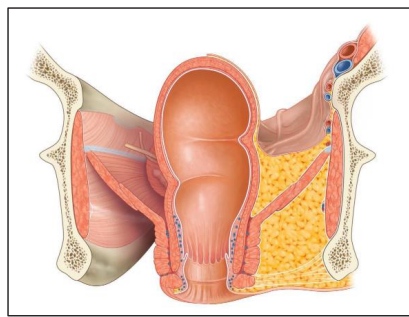




EXTRAVASATION OF URINE



ISCHIORECTAL FOSSA/ ISCHIOANAL FOSSA

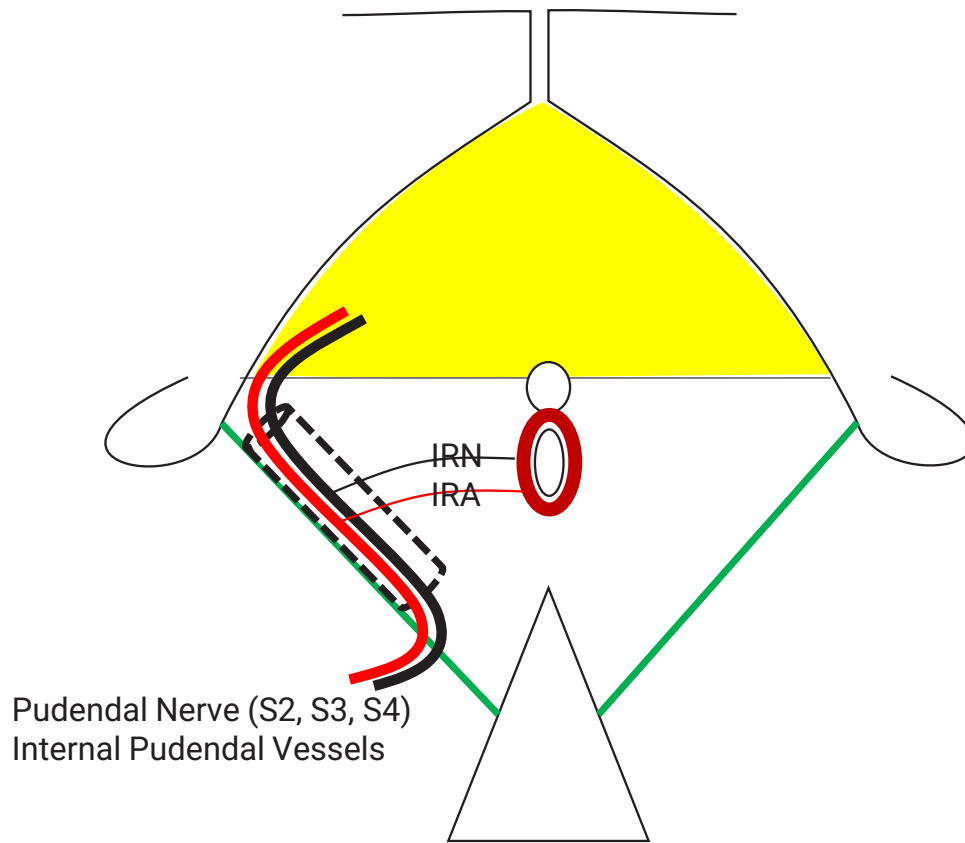


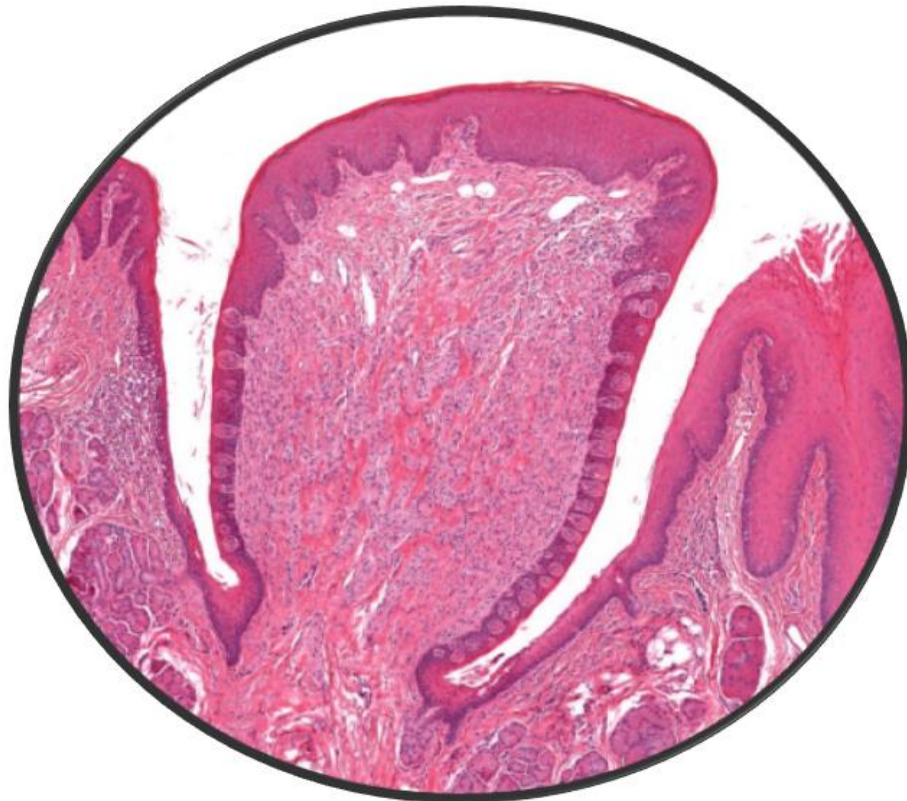
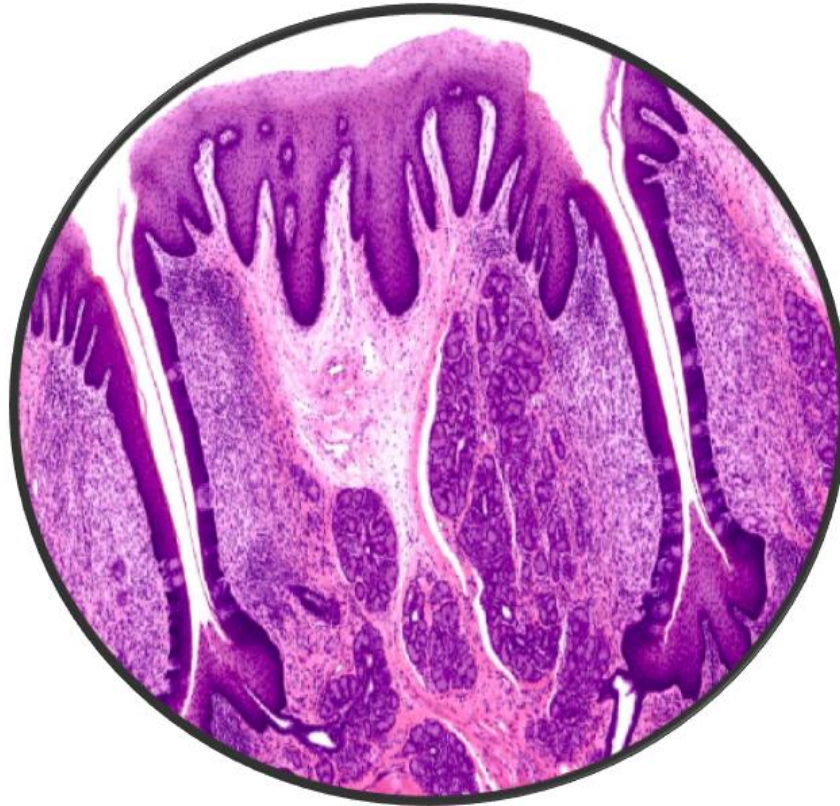

Contents of IRF

1. Fat
2. Pudendal canal and its contents
3. Inferior rectal nerves & vessels

→ Can be injured in drainage of IRF infections







NOTES



## NOTES