

1. True regarding Mondini's disease is/are?

a) Inner ear malformation

b) Predisposes to recurrent meningitis in children

c) Mostly occurs as an isolated entity

d) May be associated with Penderd and DiGeorge syndromes

e) Cochlear implants are used in treatment

Correct Answer - A:B:C:D:E

Answer- A, B, C, D, E

- It is an abnormality of the inner ear that is associated with sensorineural hearing loss.
- Mondini dysplasia can also predispose to recurrent meningitis.
- Mondini dysplasia usually occurs sporadically as an isolated abnormality but it can be associated with a variety of syndromes including Klippel Feil syndrome, Pendred syndrome, DiGeorge syndrome, Wildervanck syndrome, Fountain syndrome, Johanson-Blizzard syndrome.
- Treatment includes surgery to repair the defect to prevent recurrent meningitis, prophylactic antimicrobial therapy and conjugate - pneumococcal vaccination, hearing amplification aids & cochlear implants.

2. True regarding rhinitis medica mentosa is/are?

a) Caused by 132 - agonist sprays

b) Caused by corticosteroids spray

c) Spray itself can cause terbinate hypertrophy

d) There is inferior terbinate hypertrophy

e) Red mucosa is characteristic

Correct Answer - D

Answer- D. There is inferior terbinate hypertrophy

- It is a condition characterized by nasal congestion that is triggered by the extended use of topical decongestants and certain oral medications that constrict blood vessels in the lining of the nose: recreational use of intranasal cocaine malt also cause a similar condition.
- The classic Presentation is that the nasal mucous membranes appear "beefy-red," inflamed, and may show areas of punctate bleeding and scant mucus.
- The swelling of the nasal Passages caused by rebound congestion may eventually result in permanent turbinate hypertrophy.
- ToPical intranasal corticosteroids aPPear to have benefit in rhinitis medicamentosa to control the inflammation caused by chronic vasoconstrictor use.

3. True regarding Cald-Well-Luc surgery is/are?

a) Approach for maxillary antrum

b) Antrostomy through inferior meatus

c) Sublabial Approach leading to opening of mandibular antrum

d) Opening of maxillary antrum through gingivolabial approach

e) Opening the maxillary antrum through canine fossa

Correct Answer - A:B:D:E

Answer- A, B, D, E

- Caldwell-Luc operation is a process of opening the maxillary antrum (maxillary sinus through canine fossa by sublabial approach and dealing with the pathology inside the antrum.
- Antrum is reached through an incision in gingivolabial sulcus.
- During the surgery a naso-antral window is made (antrostomy) through the inferior meatus.

4. True regarding otosclerosis is/are?

a) More common in men

b) Involves stapes/oval window

c) Flamingo pink hue behind ear drum

d) Carhart's notch is at 4000 Hz

e) Hears better in noisy environment

Correct Answer - B:C:E

Answer- B, C, E

- In otosclerosis-50% cases have positive family history.
- Females are affected more than males.
- Bilateral conductive deafness seen in otosclerosis is not irreversible as it can be successfully treated by stapedectomy / Stapedotomy.
- Sensorineural hearing loss occurs when later in the course of time osteosclerotic focus reaches the cochlear endosteum but actually most common hearing loss seen is conductive type.
- Carharts notch is seen in bone conduction curve at 2000 Hz.

5. Clinical features of zygomatic fracture include?

a) Hypoesthesia along the distribution of infra-orbital nerve

b) Flat face

c) Malocclusion of teeth

d) Flattening of malar prominences

e) Step deformity

Correct Answer - A:D:E

Answer- A, D, E

Clinical features of zygoma fracture

- Considerable swelling over zygomatic arch is common and makes clinical diagnosis more difficult.
- Flattening of malar prominence.
- Step-deformity of infraorbital margin.
- Anaesthesia in the distribution of infraorbital nerve.
- Trismus.
- The cheek may appear flattened; compared symmetry with the opposite side.

6. True regarding the use of head mirror is/are?

a) Applied on right eye

b) Focal point should be within 6 inches

c) One eye should be closed while examining

d) Both eye should be open while focusing

e) All of the above

Correct Answer - A

Answer- A. Applied on right eye

Two types of illumination is used in otolaryngological examination:

1. Semi mobile illumination like the Bull's lamp
 2. Mobile illumination like the Clair's head light, or cold light based head bands.
- Bull's lamp: is a semi mobile source of illumination.
 - The approximate focal length of the mirror is about 10 inches.
 - The mirror is fixed over the right eye in such a way part of the mirror touches the nose.
 - The mirror is adjusted while keeping the left eye closed and the right eye is kept open to focus. Then both eyes are opened while examining.

7. Tone decay test is used for

a) Meiners disease

b) Otosclerosis

c) Cochlear deafness

d) Sensory neural deafness

e) Middle ear perforation

Correct Answer - D

Answer- D. Sensory neural deafness

- Threshold tone decay test is used for retrocochlear type of SNHL.

8. All is true about foreign body impaction in ear except-

a) Objects located medial to isthmus of canal is difficult to remove

b) Syringing is used for removal of vegetative foreign body

c) Syringing uses room temperature water

d) Blunt hook is used to remove rounded foreign body

e) GA is preferred in children to remove foreign bodies

Correct Answer - B

Answer- B. Syringing is used for removal of vegetative foreign body

- Methods of removing a foreign body include: forceps removal, syringing suction, microscopic removal with special instruments and postaural approach.
- Foreign bodies of vegetable origin such as nuts, peas and beans, are hygroscopic and should not be syringed.
- No attempts should be made to remove smooth spherical objects such as beads by forceps.
- Beads which have a diameter less than that of the isthmus can be syringed; larger ones are better removed, with a hook.

9. All are true about epistaxis except:

a) Keisselbach's plexus is source in 90% cases

b) If anterior packing is left in nose for more than 48hrs antibiotic coverage is given

c) Anterior nasal pack is easy to insert and less traumatic than balloon tamponade

d) Trotter method is first aid method

e) Cauterisation is done in refractory cases under general anaesthesia

Correct Answer - C

Answer- C. Anterior nasal pack is easy to insert and less traumatic than balloon tamponade

- Keisselbach's plexus: This plexus is the commonest site of bleeding (90% of cases)
- Anterior nasal packing- Prophylactic antibiotics should be used if pack is in place for more than 24 hours.
- A balloon tamponade may be used as an alternative to anterior nasal packing and This is less traumatic as it is best suited for epistaxis.
- Trotter's method- Patient may put in the sitting position with the head bending forwards with mouth open.
- Nasal endoscopy assisted bipolar cauterization under general anaesthesia may be done to coagulate the bleeder in case of epistaxis is refractory to conservative measures.

10. True about Secretory otitis media:

- a) Type C tympanogram may be seen in early stage of otitis media with effusion
- b) Flat tympanogram is present
- c) Leads to conductive deafness
- d) Presence of cleft palate reduces its chance
- e) Most common cause is Eustachian tube dysfunction

Correct Answer - A:B:C:E

Answer- A, B, C, E, Type C tympanogram may be seen in early stage of otitis media with effusion (B) Flat tympanogram is present (C) Leads to conductive deafness (E) Most common cause is Eustachian tube dysfunction

- This is an insidious condition characterized by accumulation of non-purulent effusion in the middle ear cleft.
- Eustachian tube (ET) dysfunction is considered the major etiological factor in the development of middle ear disease.
- Type B tympanogram: A flat or dome-shaped, graph. Seen in middle ear fluid or thick tympanic membrane.
- Type C tympanogram: Seen in Eustachian tube obstruction or early stage of otitis media with effusion.
- Hearing loss- Hearing loss is of conductive type of 20-40 dB.
- Malfunctioning of Eustachian tube(causes include palatal defects e.g cleft palate, palatal paralysis) and increased secretory activity of middle ear mucosa.

11. Which cause reddish lesion on tongue:

a) Median rhomboid glossitis

b) Hairy leukoplakia

c) Lichen planus

d) Geographic tongue

e) Fordyce's spots

Correct Answer - A:D

Answer- A, D, Median rhomboid glossitis (D) Geographic tongue

Red Lesions of Oral Cavity lesion-

- Papillomas
- Pemphigoid
- Erythroplakia
- Granular-cell tumour
- Epulides
- Hemangioma

12. True Statement regarding wax in ear-

- a) Syringing and instrumental manipulation are generally done to remove impacted wax
- b) If wax is hard and impacted, ceruminolytic substances is used to soften wax
- c) In syringing fluid is injected along the lower wall of the meatus
- d) Wax has antibacterial property
- e) None

Correct Answer - A:B:D

Answer- A, B, D, Syringing and instrumental manipulation are generally done to remove impacted wax (B) If wax is hard and impacted, ceruminolytic substances is used to soften wax

(D) Wax has antibacterial property

- Wax has acidic pH and is bacteriostatic and fungistatic.
- If wax is too hard and impacted, to be removed by syringe or instrument, it should be softened by drops of 5% sodium bicarbonate in equal parts of glycerine and water.
- Hydrogen peroxide, liquid paraffin or olive oil may also achieve
- the same result. Commercial drops containing ceruminolytic agent paradichlorobenzene 2% can also be used.
- Wax is removed either by instrumental manipulation or by syringe.
- The auricle is pulled upwards and backwards to straighten out the meatus, and the fluid is injected along the upper wall of the meatus.

13. True about antrochoanal polyp-

a) Starts as edema of maxillary sinus mucosa

b) Suppressed by steroids

c) Comes out via accessory ostium and grows in the choana and nasal cavity

d) More common in adults than children

e) Commonly presents as unilateral nasal obstruction

Correct Answer - A:C:E

Answer-A,Starts as edema of maxillary... C,Comes out via accessory ostium... E,Commonly presents as unilateral ...

- Age- Common in children
- Aetiology- Infection
- Number- Solitary
- Laterality- Unilateral
- Origin- Maxillary sinus near the ostium
- Growth- Grows backwards to the choana; may hang down behind the soft palate
- Size and shape- Trilobed with antral, nasal and choanal parts. Choanal part may protrude through the choana and fill the nasopharynx obstructing both sides
- Recurrence- Uncommon, if removed completely
- Treatment- Polypectomy; endoscopic removal or Caldwell Luc operation if recurrent.

14. Feature(s) of peritonsillar abscess:

a) Foul breath

b) Hot potato voice

c) Shifting of uvula in opposite side

d) Difficulty in swallowing even own saliva

e) Always presents as b/l severe pain in throat

Correct Answer - A:B:C:D

Answer-A,Foul breath B,Hot potato voice C,Shifting of uvula in opposite side D,Difficulty in swallowing even own saliva

Clinical features are divided into :?

- General : They are due to septicaemia and resemble any acute infection.
- They include fever (up to 104°F), chills and rigors, general malaise, body aches, headache, nausea and constipation.
- **Local :**
- Severe pain in throat. Usually unilateral.
- Odynophagia. It is so marked that the patient cannot even swallow his own saliva which dribbles from the angle of his mouth. Patient is usually dehydrated.
- Muffled and thick speech, often called "Hot potato voice".
- Foul breath due to sepsis in the oral cavity and poor hygiene.
- Ipsilateral earache. This is referred pain via CN IX which supplies both the tonsil and the ear.
- Trismus due to spasm of pterygoid muscles which are in close proximity to the superior constrictor.

15. True about spasmodic dysphonia-

a) A neurological problem

b) Mostly psychogenic in origin

c) Hyperadduction of vocal cord may be seen

d) Botulinum toxin relieves spasm

e) Speech therapy is beneficial

Correct Answer - A:C:D:E

Answer- A, C, D, E, A neurological problem (C) Hyperadduction of vocal cord may be seen (D) Botulinum toxin relieves spasm (E) Speech therapy is beneficial

- "spasmodic dysphonia is a neurological disorder affecting the voice muscles in the larynx, or voice box.
- Etiology is unknown but It is usually stress-related.
- Botulinum toxin Injection into the laryngeal muscles has been tried in the treatment of spastic dysphonia.
- Voice therapy is useful to improve voice only when combined with injection

16. Vocal cord is supplied by -

a) Internal laryngeal nerve

b) Superior laryngeal nerve

c) Recurrent laryngeal nerve

d) Vagus nerve

e) Glossopharyngeal nerve

Correct Answer - A:B:C:D

Answer- (A) Internal laryngeal nerve (B) Superior laryngeal nerve (C) Recurrent laryngeal nerve (D) Vagus nerve

- The main cranial nerve innervating the larynx is the vagus nerve via its branches; superior laryngeal nerve (SLN) and
- Recurrent laryngeal nerve (RLN).
- Above the vocal cords the sensory innervation of larynx is via internal laryngeal nerve.

17. In bilateral recurrent laryngeal nerve paralysis, which of the following is/are is seen -

a) Paramedian vocal cord

b) Dyspnea is seen

c) Stridor is seen

d) No effect on voice

e) Tracheostomy may be required

Correct Answer - A:B:C:D:E

Answer- (A) Paramedian vocal cord (B) Dyspnea is seen (C) Stridor is seen (D) No effect on voice (E) Tracheostomy may be required

Bilateral RLN paralysis (Bilateral abductor paralysis)-

- This is the most dangerous paralysis as both the cords are in median or paramedian position ,obstructing the airway.
- There is dyspnea and stridor.
- Treatment
- Tracheostomy
- Lateralization of cord
- Kashima operation

18. True about tubercular otitis media are all except?

a) Spreads through eustachian tube

b) Causes painless ear discharge

c) May cause multiple perforations

d) Usually affects both ears

e) None

Correct Answer - D

Answer- D. Usually affects both ears

- Tuberculosis of middle ear is a comparatively rare entity usually seen in association with or secondary to pulmonary tuberculosis, infection reaches the middle ear through eustachian tube.

Clinical features

- Generally, tuberculosis of middle ear is unilateral.
- It is characterized by painless otorrhoea which fails to respond to the usual antimicrobial treatment. There is painless watery otorrhea.
- Single or multiple perforation of tympanic membrane.

19. Clinical feature of facial palsy are all except -

a) Loss of forehead wrinkling

b) Difficulty in closing eye

c) Loss of taste sensation from tongue

d) Paralysis of stapedius muscle

e) Loss of Gag reflexes

Correct Answer - A:B:C:D

Answer- (A) Loss of forehead wrinkling (B) Difficulty in closing eye (C) Loss of taste sensation from tongue (D) Paralysis of stapedius muscle

Weakness of the muscle of the facial expression and eye closure

1. Absence of nasolabial fold
2. Wide palpable fissure
3. Epiphora
4. Drooping of angle of mouth
5. Loss of wrinkles of forehead
6. The face sags and is drawn across to the opposite side on smiling.
7. Voluntary eye closure may not be possible and can produce damage

20. Contraindication of cochlear implantation is/are -

a) Mondini deformity

b) Intracochlear ossification

c) Chronic suppurative otitis media

d) Agenesis of cochlear nerve

e) All

Correct Answer - C:D

Answer-(C) Chronic suppurative otitis media (D) Agenesis of cochlear nerve

Absolute

1. Active middle ear infection: ASOM, CSOM, mastoiditis
2. Agenesis of cochlea and/or Cochlear nerve
3. Mental retardation: Patient cannot cooperate with speech training

21. True about schwartz's sign -

a) Seen in otic capsule

b) Indicates active disease

c) Surgery is the Treatment

d) Causes sensory - neural deafness

e) More common in pregnancy

Correct Answer - A:B:C:D:E

Answer- (A) Seen in otic capsule (B) Indicates active disease (C) Surgery is the Treatment (D) Causes sensory - neural deafness (E) More common in pregnancy

- Schwartz's sign, also known as Flemingo's flush sign or Rising sun sign is believed to be associated with otopongiosis which is the active phase of the disease, usually in pregnancy.
- Schwartz's sign which refers to a reddish discoloration over the Promontory seen beyond the intact tympanic membrane.
- surgery remains a therapeutic option.

22. Which of the following is/are true about schwartz sign -

a) Sign of inactive disease

b) Indication for surgery

c) More common during pregnancy

d) Reddish hue over the promontory

e) Seen in the early stages of the otosclerosis

Correct Answer - B:C:D:E

Answer- (B) Indication for surgery (C) More common during pregnancy (D) Reddish hue over the promontory (E) Seen in the early stages of the otosclerosis

Schwartz sign (Flemingo's flush sign)-

- In 10% of cases flamingo - pink blush is seen through the tympanic membrane called as Schwartz sign
- It is seen in early and active stage of the disease.
- The sign is characterized by pink blush seen through the tympanic membrane caused by reddish hue over promontory due to increased vascularity of the promontory.
- This sign indicates active otosclerosis usually during Pregnancy
- It seems that the surgery remains a therapeutic option, when the active phase of the disease is stabilized even following a short course of pharmacological therapy.

23. Deformities occurring in leprosy patients is/are -

a) Facies leonina

b) Low set ear

c) Saddle nose

d) Lagophthalmos

e) Microganthia

Correct Answer - A:C:D

Answer- (A) Facies leonina (C) Saddle nose (D) Lagophthalmos
Face-

- Mask face, facies leonina, Saddle nose, sagging face, lagophthalmos, loss of eyebrows, perforated nose, depressed nose, ear deformities.

24. Which of the following is/are true about leforts fracture

a) It is fracture of zygomatic bone

b) May cause CSF rhinorrhea

c) Type 1: complete separation of facial bones from the cranial bones

d) Classified as types 1 to 5

e) None

Correct Answer - B

Answer- B. May cause CSF rhinorrhea

- Le Fort I (transverse)- crosses lower part of nasal septum, maxillary antra and the pterygoid plates.
- Le Fort II (pyramidal)- passes through the root of nose, lacrimal bone, floor of orbit, upper part of maxillary sinus and pterygoid plates
- Le Fort III (craniofacial dysjunction)- There is complete separation of facial bones from the cranial bones.

Clinical features of maxillary fracture-

- Malocclusion of teeth
- Mobility in the maxilla
- CSF rhinorrhoea.

25. True about foreign bodies of air passage in children except -

a) Vegetable foreign bodies are not common

b) Tracheal obstruction can causes sudden death

c) More common in right bronchus

d) More common in children of less than 4 yr of age

e) CT scan of chest is done in all cases

Correct Answer - A:B:E

Answer- (A) Vegetable foreign bodies are not common

(B) Tracheal obstruction can causes sudden death (C) More common in right bronchus

- The most common age group is 6 months to 4 years.
- Most common foreign body aspirated is nuts (peanuts).
- Most airway foreign bodies lodge in a bronchus (right more than left).
- The child presents with acute onset of cough- (most-common), Chocking gagging, wheezing, respiratory distress, aphonia, drooling and stridor.
- Bronchoscopy is diagnostic as well as therapeutic.

26. True about development of cochlea

a) Cochlea start developing from 3rd week of gestation

b) Semicircular canals develop after cochlea

c) Cochlea development completes by 20 week of gestation

d) Cochlea development completes at 2 year of age

e) All

Correct Answer - A:C

Answer- A,Cochlea start developing from 3rd week of gestation C,Cochlea development completes by 20 week of gestation

- Development of cochlea starts at 3 weeks and completes at 20-22 weeks of intrauterine life.
- Semicircular canal develops earlier than cochlea.

27. Which of the following is/are true about the T-stage of maxillary sinus carcinoma -

a) Stage T4a- frontal sinus involvement

b) Stage T3 - ethmoid sinus involvement

c) Stage T2- sphenoid sinus involvement

d) Stage T2- bone of the posterior wall of maxillary sinus

e) None

Correct Answer - A:B

Answer- (A) Stage T4a- frontal sinus involvement (B) Stage T3 - ethmoid sinus involvement

- T4a- Tumour invades anterior orbital contents, skin of cheek, pterygoid plates, infratemporal fossa, cribriform plates, sphenoid or frontal sinus.
- T3- Tumour invades any of the following- bone of the posterior wall of maxillary sinus, subcutaneous tissues, floor or medial wall orbit, pterygoid fossa and ethmoid sinuses.
- T2- Tumour causing bone erosion or destruction including extension into the hard palate and middle nasal meatus, except extension to posterior wall of maxillary sinus and pterygoid plates.

28. True about Reinke's oedema:

a) Usually unilateral

b) Common in smoker

c) Corticosteroid is mainstay of treatment

d) Involve whole of membranous part of the vocal cords

e) Patient has low pitch voice

Correct Answer - B:D:E

Answer- B,Common in smoker D,Involve whole of membranous part of the vocal cords E,Patient has low pitch voice

- It is bilateral symmetrical swelling of the whole of membranous part of the vocal cords.
- This is due to oedema of the subepithelial space (Reinket space) of the vocal cords.

Etiology-

- Heavy smoking,
- Chronic sinusitis &
- Laryngopharyngeal reflex

C/F-

- Patient uses false cords for voice production & this gives him a low-pitched & rough voice.

Treatment-

- Decortication of the vocal cords i.e., removal of strip of epithelium, is done first on one side & 3-4 weeks alter on the other.

29. Feature(s) of Scheibe's syndrome is/are:

a) Semicircular canal fistula

b) Abnormality in bony labyrinth

c) Dysplasia of cochlea

d) Middle ear anomaly

e) All

Correct Answer - C

Answer- C. Dysplasia of cochlea

- It is most common inner ear anomaly.
- Dysplasia is seen in the cochlea & saccule; hence also called cochleosaccular dysplasia.
- It is inherited as an autosomal recessive nonsyndromic trait.

30. True about nasopharyngeal carcinoma:

a) Level 4 cervical lymph node not involved

b) Radiotherapy is treatment of choice

c) Also c/a Guangdong tumour

d) May associated with U/L otitis media

e) Associated with EBV

Correct Answer - A:B:C:D:E

Answer- A,Level 4 cervical lymph node not involved B,Radiotherapy is treatment of choice C,Also c/a Guangdong tumour D,May associated with U/L otitis media E,Associated with EBV

- It is mostly seen in fifth to seventh decades.
- Males are three times more prone than female.
- Epstein-Barr virus is closely associated with nasopharyngeal carcinoma.
- Due to obstruction of Eustachian tube, there is conductive hearing loss, serous or suppurative otitis media.
- Radiotherapy: It is treatment of choice for nasopharyngeal carcinoma.

31. Evidence based therapy of Bell's palsy include(s):

a) Facial nerve massage

b) Facial nerve stimulation

c) Steroid

d) Acyclovir

e) All

Correct Answer - C

Answer- C. Steroid

1. Medical treatment

- Prednisolone (steroid) is the drug of choice and is started at initial visit. Initiation of therapy during first 24 hours of symptom confers a higher likelihood of recovery.
- Antiviral therapy (Acyclovir) is a newer adjunct in treating acute facial palsy of viral origin (both Bell's palsy and Ramsay hunt syndrome).
- Most surgeons these days advocate combination of steroids and antiviral drugs.

32. A person has vertigo without CNS involvement. Causes is/ are:

a) Perilymph fistula

b) Otolithiasis

c) Vestibular neuritis

d) Meniere's disease

e) Multiple sclerosis

Correct Answer - A:B:C:D

Answer- A,Perilymph fistula B,Otolithiasis C,Vestibular neuritis D,Meniere's disease

Peripheral (Lesions of end organs vestibular nerve)

- Meniere's disease
- Benign paroxysmal positional
- vertigo
- Vestibular neronitis
- Labyrinthitis
- Vestibulotoxic drugs
- Head trauma
- Perilymph fistula
- Syphilis
- Acoustic neuroma

33. Which is true about Tuning fork test in hearing loss:

a) Rinne test is negative in conductive deafness

b) Weber test- lateralized to the worst ear in sensorineural deafness

c) Lateralization of sound in Weber test with a tuning fork of 512 Hz implies a conductive loss of 15-20 dB in ipsilateral ear

d) Negative Rinne test indicates a minimum air-bone gap of 15-20 dB

e) A Rinne negative for all the three tuning forks of 256,512 & 1024 Hz indicates air-bone gap of 30-45

Correct Answer - A:C:D

Answer- (A) Rinne test is negative in conductive deafness (C) Lateralization of sound in Weber test with a tuning fork of 512 Hz implies a conductive loss of 15-20 dB in ipsilateral ear (D) Negative Rinne test indicates a minimum air-bone gap of 15-20 dB

Rinne Test

- A negative test ($BC > AC$) is seen in conductive deafness.
- Negative Rinne indicates a minimum air-bone gap of 15-20 dB.
- A prediction of air-bone gap can be made if tuning forks of 256, 512 & 1024 Hz are used
- A Rinne negative for all the three tuning forks of 256,512 & 1024 Hz indicates air-bone gap of 45-60 dB

Weber Test-

- It is lateralized to the worst ear in conductive deafness & to the

better ear in sensorineural deafness.

34. Which of the following causes lower motor neuron(LMN) type of facial nerve paralysis :

a) Bell palsy

b) Parotid tumor

c) Guillain-Barre syndrome

d) Middle cerebral artery infarct

e) Multiple sclerosis

Correct Answer - A:B:C

Answer- (A)Bell palsy (B)Parotid tumor (C)Guillain-Barre syndrome

1. Idiopathic (Bell's palsy)

- Pregnancy - 3x more common.
- Diabetes mellitus

2. Infective

- Herpesvirus
- Herpes zoster (Ramsay Hunt syndrome)
- Epstein-Barr virus

3. Neurological

- Guillain-Barre syndrome.
- Mononeuropathy- e.g. due to diabetes mellitus, sarcoidosis or amyloidosis

4. Parotid gland tumours.

35. True about tympanometry:

a) Flat in ossicular discontinuity

b) As type in otosclerosis

c) Dome shaped indicates fluid in middle ear

d) Ad type in ossicular discontinuity

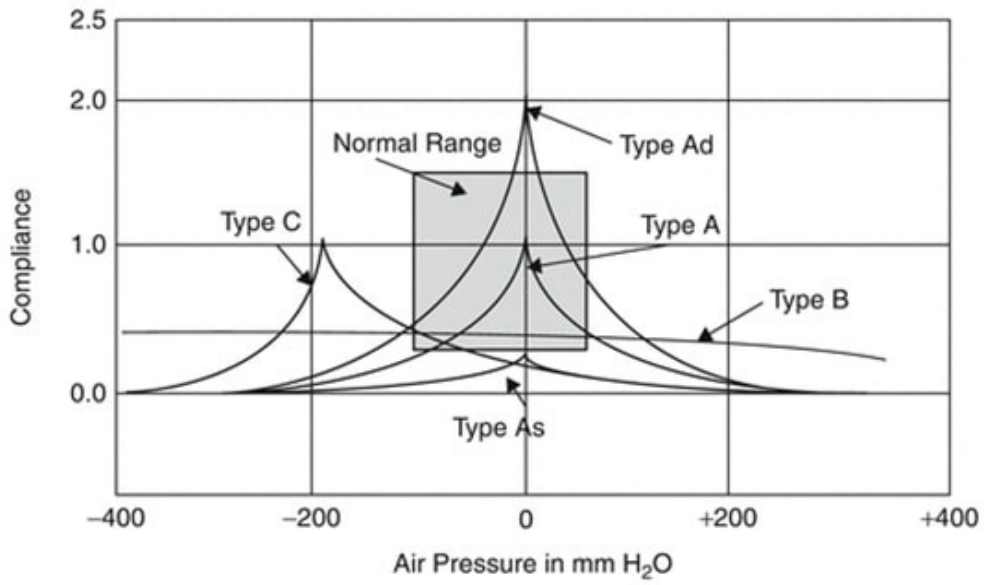
e) C type in eustachian tube obstruction

Correct Answer - B:C:D:E

Answer- (B)As type in otosclerosis (C)Dome shaped indicates fluid in middle ear (D)Ad type in ossicular discontinuity (E)C type in eustachian tube obstruction

A- Normal

- As- Reduced compliance at ambient pressure (otosclerosis).
- 's' stands for shallow tympanogram but remember for stiffness
- AD- Increased compliance at ambient pressure (ossicular discontinuity). 'd' stands for deep tympanogram.
- B- Flat or dome-shaped (fluid in middle ear).
- C- Maximum compliance at pressures more than -200 mm H₂O



36. True about bilateral abductor paralysis:

a) Voice is good

b) Stridor is present

c) Cords lie in abducted position

d) Urgent tracheostomy is needed

e) None

Correct Answer - A:B:D

Answer- A, Voice is good B, Stridor is present D, Urgent tracheostomy is needed

Trecheostomy

Transverse cordotomy

- Partial arytenoidectomy
- Reinnervation procedures
- Thyroplasty II
- Woodman's operation (External arytenoidectomy) is done in b/l abductor paralysis.
- Endoscopic laser arytenoidectomy & Isshiki type II thyroplasty is done for lateralization of coril (in bilateral abductor paralysis).

37. All are true about mandible fracture except:

a) Condylar neck is most common site

b) Malocclusion of teeth may occur

c) Anterior superior alveolar nerve is most commonly injured

d) Panorex radiographs are useful for diagnosis

e) Malunion & non-union are complications

Correct Answer - C

Answer- C. Anterior superior alveolar nerve is most commonly injured

- The condylar neck is the weakest part of the mandible and, is the most frequent site of fracture.
- Trauma to the inferior alveolar nerve leads to permanent numbness of the lower lip and teeth on the affected side.
- Fractures of the coronoid process of the mandible can result in trismus
- In fracture of condyle, displaced fragments leads to malocclusion of teeth & deviation of jaw to the opposite side on opening the mouth.
- X-rays useful in mandibular fractures are PA view of the skull (for condyle), right & left oblique view of mandible & panorexview.
- Condylar and subcondylar mandible fractures are most often treated by IMF alone.
- Delayed union and nonunion occur in approximately 3% of fractures.

38. True about chronic suppurative otitis media (CSOM):

a) Foul smelling discharge in atticoantral variety

b) Facial nerve involvement in tubotympanic variety

c) Atticoantral variety is associate with cholestetoma

d) May cause hearing loss

e) All

Correct Answer - A:C:D

Answer- (A)Foul smelling discharge in atticoantral variety (C)Atticoantral variety is associate with cholestetoma (D)May cause hearing loss

Types

Differences between atticoantral and tubotympanic type of CSOM

	Tubotympanic (safe)	atticoantral (unsafe)
Discharge	profuse mucoid	scanty purulent foul smell
Perforation	central	Marginal
Granulation	uncommon	Common
Polyp	Pale	Red, fleshy
Cholesteatoma	Absent	Present
Complications	Rare	Common
Audiogram	Mild to moderate conductive deafness	Conductive or mixed deafness

39. True about ranula:

a) Mucous retention cyst

b) Seen in floor of mouth

c) Marsupialization for large cyst

d) Parotid is most common site of origin

e) Arises from sublingual salivary gland

Correct Answer - A:B:C:E

Answer- (A)Mucous retention cyst (B)Seen in floor of mouth (C)Marsupialization for large cyst (E) Arises from sublingual salivary gland

- It is a thin walled bluish retention cyst.
- Seen in the floor of mouth on one side of the frenulum.
- It arises due to obstruction of duct of sublingual salivary gland.
- It is almost always unilateral.

Clinical Features

- Seen mostly in children and young adults.
- Only complain—swelling in the floor of mouth
- Cyst may rupture spontaneously but recurrence is common
- Treatment is complete surgical excision if small or marsupialization, if large

40. True about grommet insertion:

- a) Small plastic tube aerating middle ear
- b) Maximum duration of grommet insertion is 5 month
- c) Healing occurs more quickly after extrusion than after removal
- d) It is placed anteriorly on tympanic membrane
- e) Surgery is always needed to remove it

Correct Answer - A:C:D

Answer- (A) Small plastic tube aerating middle ear (C) Healing occurs more quickly after extrusion than after removal (D) It is placed anteriorly on tympanic membrane

If a grommet is inserted it may be placed posteriorly or anteriorly depending upon the preference of the surgeon.

The grommet is either rejected spontaneously or may be removed, preferably under an anaesthetic because this is momentarily Painful. At the second or certainly at the third myringotomy, most surgeon will insert a grommet.

Tympanosclerosis is seen much more frequently in children.

Extrusion of the tube, the majority of iatrogenic TM perforations will heal.

41. True about Vasomotor rhinitis:

a) It is a type of allergic reaction

b) Clinically simulate nasal allergy

c) Nasal mucosa generally congested & hypertrophic

d) Hypertrophy of inferior turbinate is commonly present

e) Anti-histaminics & oral nasal decongestant are used in treatment

Correct Answer - B:C:D:E

Answer- (B) Clinically simulate nasal allergy (C) Nasal mucosa generally congested & hypertrophic (D) Hypertrophy of inferior turbinate is commonly present (E) Anti-histaminics & oral nasal decongestant are used in treatment

It is nonallergic rhinitis but clinically simulating nasal allergy with symptom of nasal obstruction, rhinorrhoea (sneezing).

All the tests of nasal allergy are negative

"VMR: Swelling (or hypertrophy) of inferior turbinate is frequently seen

Clinic features-

- Paroxysmal sneezing excessive rhinorrhoea, nasal obstruction & postnasal drip
- Nasal mucosa over the turbinates is generally congested & hypertrophic

Treatment-

- anti-histaminics, oral nasal decongestant; systemic steroid Surgical treatment: Relieving of nasal obstruction & vidian neurectomy.

42.

Structures preserved in radical neck dissection -

a) Internal jugular vein

b) Carotid Artery

c) Accessory nerve

d) Brachial plexus

e) Sternocleidomastoid muscle

Correct Answer - B:D

Answer- (B) Carotid Artery (D) Brachial plexus

Cervical lymphatics and lymph node

Internal jugular vein

Accessory nerve

Submandibular gland

Sternocleidomastoid muscle

Tail of parotid

Omohyoid muscle

43. Feature of Granulomatosis with polyangiitis:

a) Nasal polyp

b) Perforated Nasal septum

c) Persistent sinus

d) Crusting of nasal mucosa

e) Collapse of nasal bridge

Correct Answer - B:C:D

Answer- (B) Perforated Nasal septum (C) Persistent sinus (D) Crusting of nasal mucosa

Granulomatosis with polyangiitis (Wegener) is a distinct clinicopathologic entity characterized by granulomatous vasculitis of the upper and lower respiratory tracts together with glomerulonephritis.

Disseminated vasculitis involving both small arteries and veins may occur.

Nasal findings include crusting granulations, septal perforation & a saddle nose

Destruction of the septum with a characteristic implosion of the nasal bridge.

44. True about vestibular schwannoma:

a) U/1 hearing loss is common presentation

b) Mostly malignant

c) Most common tumour of CP angle

d) Sensorineural deafness

e) Uncapsulated

Correct Answer - A:C:D

Answer- (A) U/1 hearing loss is common presentation (C) Most common tumour of CP angle (D) Sensorineural deafness

Benign encapsulated, extremely slow growing tumors.

80% of all Cerebello-pontine angle tumors.

Earliest symptoms -Unilateral sensorineural deafness.

The three most common presenting symptoms include insidious hearing loss, high-pitched tinnitus, and disequilibrium.

Superior division of vestibular nerve – most common site of AN.

45. Tensor of vocal cord includes:

a) Arytenoid

b) Thyroarytenoid

c) Interarytenoid

d) Posterior cricoarytenoid

e) Cricothyroid

Correct Answer - E

Answer- E. Cricothyroid

Muscle of Larynx-

- Abductor Posterior cricoarytenoid
- Adductor (3 muscle given in Dhingra): Lateral cricoarytenoid, Interarytenoid (Transverse thyroarytenoid)
- Tensor Cricothyroid & vocalis
- All muscle of larynx are supplied by Recurrent Laryngeal nerves.
- The latter receive its innervation from External Laryngeal nerve.

Sensory -

- Above vocal cords - Internal Laryngeal nerve a branch of Superior Laryngeal nerve.
- Below vocal cords - Recurrent Laryngeal nerve

46. All are true about vocal cord nodule except:

a) Caused by phonotrauma

b) Commonly occur at Junction of middle & posterior 1/3

c) Common at junction of A 1/3 with P 2/3

d) Common in teachers

e) Treatment is speech therapy

Correct Answer - B

Answer- B. Commonly occur at Junction of middle & posterior 1/3

Vocal trauma when person speaks in unnatural low tones for prolonged periods or at high intensities.

Patients complains of hoarseness.

Vocal fatigue & pain in the neck on prolonged phonation are other common symptoms.

They mostly affect teachers, actors, vendors or pop singers

Surgery is required for large nodules or nodules of long standing in adults.

Speech therapy & re-education in voice production are essential to prevent their recurrence.

They appear symmetrically on the free edge of vocal cord, at the junction of anterior one-third, with the posterior two-third.

47. True about allergic fungal sinusitis:

- a) Fungal hyphae is present in allergic mucin which is pathological hallmark
- b) Invasion of the sinus mucosa with fungus
- c) Allergic reaction to fungus
- d) Antifungal treatment lead to improvement of symptom
- e) Surgical clearance is mainstay of treatment

Correct Answer - A:C:E

Answer- (A) Fungal hyphae is present in allergic mucin which is pathological hallmark (C) Allergic reaction to fungus (E) Surgical clearance is mainstay of treatment

It is an allergic reaction to the causative fungus & presents with sinunasal polyposis & mucin.

There is no invasion of the sinus mucosa with fungus .

Usually more than one sinus are involved on one or both sides.

Features of refractory sinusitis and nasal polyposis are present.

a Gell and Coombs type I (IgE-mediated) immune response to fungal antigens. Type III and IV immune responses may also be involved.

It consist of consisting of eosinophils, Charcot-Leyden crystals, and scattered fungal hyphae.

Diagnosis

CT scan shows mucosal thickening with hyperdense areas

The diagnosis of AFS is confrmed by demonstration of allergic mucin and culture of the fungus.

Treatment-

Surgical debridement and aeration of the involved sinus followed by

the use of systemic and topical intranasal corticosteroids.

48. True about conductive hearing loss:

a) Presbycusis

b) Cholesteatoma

c) Acoustic neuroma

d) Perforation of tympanic membrane

e) Serous otitis media

Correct Answer - B:D:E

Answer- (B) Cholesteatoma (D) Perforation of tympanic membrane (E) Serous otitis media

Caused by any disease process interfering with conduction of sound from the external ear to the stapedio-vestibular joint.

Commonest cause of hearing loss in children is Chronic secretory otitis media.

Perforation of tympanic membrane.

Disruption of ossicles-trauma to ossicular chain, CSOM, cholesteatoma

Fixation of ossicles-otosclerosis, tympanosclerosis

Eustachian tube blockage

49. True about Andy Gump deformity:

- a) Occurs due defects of the anterior mandibular arch
- b) Hemimandibulectomy can cause
- c) Marginal mandibulectomy can cause
- d) Treatment is adequate reconstruction of anterior mandibular arch with plate & graft
- e) None

Correct Answer - A:B:D

Answer- (A) Occurs due defects of the anterior mandibular arch (B) Hemimandibulectomy can cause (D) Treatment is adequate reconstruction of anterior mandibular arch with plate & graft

An altered facial profile due to a missing lower jaw bone, or mandible. Resection of the anterior mandibular arch produces the "Andy Gump" deformity.

Causes

- Marginal mandibulectomy
- Segmental mandibulectomy
- Arch preserving mandibulectomy
- Hemimandibulectomy

50. Foreign body in trachea & bronchus can cause:

a) Bronchiectasis

b) Atelectasis

c) Subcutaneous emphysema

d) Pneumothorax

e) All

Correct Answer - A:B:C:D

Answer- (A) Bronchiectasis (B) Atelectasis (C) Subcutaneous emphysema (D) Pneumothorax

Trachea-

- Choking, stridor, wheeze, cough, palpatory thud, audible slap.

Bronchi-

- Cough, wheeze & diminished air entry to lung forms a triad
- Respiratory distress with swelling of foreign body
- Lung collapse, emphysema, pneumonitis, bronchiectosis or lung abscess are late feature.

51. Not self retaining hand held retractor (s) is/are:

a) Mollison's mastoid retractor

b) Jansen's mastoid retractor

c) Lempert's endaural retractor

d) Davis Retractor

e) All

Correct Answer - D

Answer- D. Davis Retractor

These retractors do not need an assistant to hold them in place.
It hold tissue apart and lock it in place.

Hand held retractor-

- Hohmann Retractor
- Lahey Retractor
- Senn Retractor
- Blair (Rollet) Retractor
- Rigid Rake
- Flexible Rake
- Ragnell Retractor
- Linde-Ragnell Retractor
- Davis Retractor

52. True about croup:

a) Caused by H.influenzae

b) X-ray PA view shows steple sign of subglottic narrowing

c) Stridor is present

d) Supraglottic edema is present

e) Commonly present in 6 month-3 year age group

Correct Answer - A:B:C:E

Answer- (A) Caused by H.influenzae (B) X-ray PA view shows steple sign of subglottic narrowing (C) Stridor is present (E) Commonly present in 6 month-3 year age group

Croup (Laryngotracheobronchitis)

Laryngotracheobronchitis is the most common infectious cause of obstruction in children usually occurring between the ages of 6 months and 3 years.

Male children (boys) are characteristically more frequently involved than females (girls)

Etiology

- It is a viral infection most frequently caused by Parainfluenza virus.

Pathology

- The most characteristic pathological feature is edema formation in the subglottic area.

Presentation

- Gradual onset with a prodrome of upper respiratory symptoms
- Hoarseness and barking cough (croupy cough)
- Stridor (initially inspiratory than biphasic)
- Fever is usually low grade (or absent) although may occasionally be high grade

- Droolings is characteristically absent and there is no dysphagia (seen in epiglottitis)
- Imaging (X ray)
- Symmetric 'steeple' or 'funnel shaped' narrowing of the subglottic region (steeple sign)
- Hypopharyngeal widening or distension
- Normal epiglottis and aryepiglottic folds

53. Which of the following statement (s) is/are true about labyrinthitis:

a) Initially quick component of nystagmus occur toward diseased ear but in later stage shift toward healthy ear

b) May occur as a complication of chronic suppurative otitis media

c) Resolve spontaneously in 1-6 wk

d) Medical treatment alone is sufficient

e) Vertigo may be present

Correct Answer - A:B:E

Answer- (A) Initially quick component of nystagmus occur toward diseased ear but in later stage shift toward healthy ear

(B) May occur as a complication of chronic suppurative otitis media (E) Vertigo may be present

This is a common complication of otitis media.

There are three typesr

- Circumscribed (fistula of labyrinth)
 - Diffuse serous &
 - Diffuse suppurative labyrinthitis
- Mild case complain of vertigo & nausea.
- Surgical treatment includes: Myringotomy

54. True about Mobius syndrome:

a) 10th CN involvement

b) 7th CN involvement

c) Abduction defect

d) Esotropia

e) 6th CN involvement

Correct Answer - B:C:D:E

**Answer- (B) 7th CN involvement (C) Abduction defect
(D) Esotropia (E) 6th CN involvement**

"It is characterized by bilateral facial weakness (i.e. VII CN), which is often associated with abducens nerve paralysis (i.e. VI CN)

Facial palsy is commonly bilateral, frequently asymmetric.

Ectropion, epiphora, and exposure keratopathy may develop.

The abduction defect may be unilateral or bilateral.

The cranial nerves V and VIII are affected.

Esotropia is common.

Surgical correction of the esotropia is indicated

55. True about Ethmoidal sinus:

a) Fully developed by 25 yr

b) Consists of 3-18 sinus on each side

c) Absent at birth

d) Lamina papyracea separate from orbit

e) Anterior ethmoidal group cells-open into superior meatus

Correct Answer - B:D

Answer- (B) Consists of 3-18 sinus on each side (D) Lamina papyracea separate from orbit

Ethmoidal cells are divided into anterior ethmoidal group which opens into the middle meatus & posterior ethmoidal group.

Present at birth

Reach adult size by 12 years

Their number varies from 3 to 18

The thin paper like lamina of bone (lamina papyracea) separating air cells from the orbit.

56. All are true about nasopharyngeal fibroma except:

a) Most common age of presentation is 20-50 yr

b) Radioresistant tumour

c) Highly vascular

d) Benign in nature

e) Surgery is treatment of choice

Correct Answer - A:B

Answer- (A) Most common age of presentation is 20-50 yr

(B) Radioresistant tumour

It is a rare tumour, though it is the commonest of all benign tumours of nasopharynx

It is locally invasive & destroys the adjoining structures

Tumour is seen almost exclusively in males in age group of 10-20 years.

Rarely, it maybe seen in older people & females

Most common presentation: profuse & recurrent epistaxis

It is made up of vascular & fibrous tissue. Mostly, the vessels are just endothelium-lined spaces with no muscle coat

Surgical excision is now the treatment of choice

Radiotherapy has been used as a primary mode of treatment

57. Complication of modified radical mastoidectomy include (s):

a) Conductive hearing loss

b) Facial nerve injury

c) Change in taste sensation

d) Sensory hearing loss

e) All

Correct Answer - E

Answer- E. All

Facial paralysis

Perichondritis of pinna

Injury to dura or sigmoid sinus

Labyrinthitis, if stapes gets disclosed

Severe conductive deafness of 50 dB or more. This is due to removal of all ossicla & tympanic membrane

Cavity problems

58. Which of the following feature (s) of rhinoscleroma is/are true except:

a) Atrophy of nasal mucosa

b) Caused by fungus

c) Treatment by antifungal drug

d) Caused by bacteria

e) Causative organism may be cultured from biopsy material

Correct Answer - B:C

Answer- (B) Caused by fungus (C) Treatment by antifungal drug

Rhinoscleroma is a rare, slowly progressing granulomatous disease of the upper respiratory tract caused by *Klebsiella rhinoscleromatis*.

Nasal disease presents with three typical stages: (1) catarrhal (2) proliferative (3) cicatrical.

Rhinoscleroma may be found in all age groups, but typically young adults 20–30 years old are most frequently affected.

Airborne transmission combined with poor hygiene, crowded living conditions, and poor nutrition contributes to its spread.

Both streptomycin & tetracycline are given together

59. Which of the following is true regarding mandibular fracture:

a) Inferior alveolar nerve damage may occur

b) Panorex radiograph is very helpful in management

c) Ramus is the most common site of fracture

d) Condylar fracture heals spontaneously & require no active intervention

e) Condylar fracture is most common site

Correct Answer - A:B:E

Answer- (A) Inferior alveolar nerve damage may occur

(B) Panorex radiograph is very helpful in management

(E) Condylar fracture is most common site

Condylar process fractures of the mandible are most common.

Clinical features

- Pain, Swelling, Deformity with trismus or malocclusion of teeth.
- Many Patients with mandibular fractures experience trauma to the inferior alveolar nerve.

Treatment:

- The fracture is reduced and fixed by:
- Closed reduction or Open reduction.

60. True about choanal atresia:

- a) Unilateral atresia should be operated within 6 month of age
- b) Occur d/t persistence of bucconasal membrane
- c) B/1 atresia usually presents with respiratory difficulties
- d) Bilateral atresia may cause cyanosis
- e) Diagnosed by failure to pass a catheter from nose to pharynx

Correct Answer - B:C:D:E

**Answer- (B) Occur d/t persistence of bucconasal membrane
(C) B/1 atresia usually presents with respiratory difficulties
(D) Bilateral atresia may cause cyanosis (E) Diagnosed by failure to pass a catheter from nose to pharynx**

Choanal atresia is an abnormality of canalization during development of the nasal passages.

It involves bone and/or soft tissue and may result in either partial (choanal stenosis) or complete obstruction of the posterior nasal airway.

The most widely accepted mechanism for the development of choanal atresia is the persistence of the bucconasal membrane beyond the sixth week of gestation.

Choanal atresia is associated with CHARGE syndrome: Coloboma of eye, Heart defects, Choanal Atresia, Retarded growth, Genital defects and Ear defects.

B/L atresia Presents with respiratory obstruction as the newborn later develops cyanosis.

Operative correction of unilateral obstruction may be differed for several years.

61. Stridor is/are caused by all except:

a) Vocal cord palsy

b) Stenosis after tracheostomy

c) Ludwig angina

d) Retropharyngeal abscess

e) None

Correct Answer - E

Answer- None

- It is noisy respiration produced by turbulent airflow through the narrowed air passage.
- Inspiratory stridor: Often produced in obstructive lesions of supraglottis or pharynx
- Expiratory stridor: It is produced in lesions of thoracic trachea, primary & secondary bronchi
- Biphasic stridor: It is seen in lesions of glottis, subglottis & cervical trachea

62. Toby Ayer's test is/are used for:

a) CSF rhinorrhoea

b) Lateral sinus thrombosis

c) Sigmoid sinus thrombosis

d) To check patency of eustachian tube

e) None

Correct Answer - B:C

Answer- (B) Lateral sinus thrombosis (C) Sigmoid sinus thrombosis

The Tobey–Ayer test is used for lateral sinus thrombosis by monitoring cerebrospinal fluid pressure during a lumbar puncture. Tobey-Ayer test & Crowe-Beck test are performed in lateral sinus thrombosis (Sigmoid sinus thrombosis)

63. True about presbycusis:

a) Degeneration of outer Hair cell of organ of Corti in sensory type

b) High frequency is affected first in sensory type

c) Can be treated with hearing aids

d) Usually unilateral hearing loss occurs

e) None

Correct Answer - A:B:C

Answer- (A) Degeneration of outer Hair cell of organ of Corti in sensory type (B) High frequency is affected first in sensory type (C) Can be treated with hearing aids

Presbycusis , or age-related hearing loss, is the cumulative effect of aging on hearing.

It is a progressive and irreversible bilateral symmetrical age-related sensorineural hearing loss resulting from degeneration of the cochlea or associated structures of the inner ear or auditory nerves. Patients of presbycusis can be helped by a hearing aid.

64. True about pure tone audiometry:

a) The frequency tested is 2000-9000Hz

b) Done in silent room

c) Air conduction for right ear is represented on audiogram by symbol 'X'

d) Air conduction for left ear is represented on audiogram by symbol 'O'

e) All

Correct Answer - B

Answer- (B) Done in silent room

In a soundproof room, the patient's ability to hear pure tones in the frequency range of about 125 to 8000 Hz is measured.

Red "O" represents air conduction for the right ear while blue "X" represents air conduction for the left ear.

65. All are true about Meniere's disease except:

- a) Triad of recurrent vertigo, fluctuating sensorineural hearing loss, and tinnitus are found
- b) Treatment consists of use of thiazide
- c) Drop attack occurs
- d) Onset only after > 50 year
- e) None

Correct Answer - D

Answer- (D) Onset only after > 50 year

Meniere's disease is a disease of the inner ear, characterized by the clinical triad of recurrent vertigo, fluctuating sensorineural hearing loss, and tinnitus.

Disease is seen in the age group of 35-60 years.

Males are affected more than females.

The tinnitus is usually low-pitched and roaring & is aggravated during acute attacks.

Aural fullness is a manifestation always present in Meniere's attack.

Patients with severe hydrops should be treated with diuretics, salt restriction.

66. Which of the following is true?

a) Internal laryngeal nerve: supply cricothyroid muscle

b) Internal laryngeal nerve-sensory supply below vocal cord

c) Internal laryngeal nerve-tense vocal cord

d) External laryngeal nerve-tense vocal cord

e) Internal laryngeal nerve-sensory supply above vocal cord

Correct Answer - D:E

Answer- (D) External laryngeal nerve-tense vocal cord (E) Internal laryngeal nerve-sensory supply above vocal cord

All the muscle which move the vocal cords (abductors, adductors or tensor) are supplied by Recurrent Laryngeal nerve.

Above vocal cords - Internal Laryngeal nerve a branch of Superior Laryngeal nerve

Below vocal cords - Recurrent Laryngeal nerve

Cricothyroid muscle- External Laryngeal nerve

67. Which of the following is/are true about posterior epistaxis:

a) Posterior packing is done

b) Often due to chronic hypertension

c) Persistent case- ligation of anterior ethmoidal artery

d) Severe bleeding in comparison with anterior epistaxis

e) More commonly occur in elderly

Correct Answer - A:B:D:E

Answer- (A) Posterior packing is done (B) Often due to chronic hypertension (D) Severe bleeding in comparison with anterior epistaxis (E) More commonly occur in elderly

It is less common.

It is mostly seen from posterosuperior part of nasal cavity.

Seen after 40 years of age

Caused due to hypertension or arteriosclerosis

Features show bleeding is severe

Treated by postnasal pack often required