

**1. In a patient with L4-L5 disc prolapse, which of the following nerve roots can get compressed?**

a) L5

b) S1

c) S2

d) S2-S4

e) L4

Correct Answer - A:E

**Ans.is 'a' i.e.,L5 &'e' i.e.,L4**

Like at every level, there are two nerve roots at L4-L5 - exiting nerve root i.e. L4 nerve root & traversing nerve root i.e. L5 nerve root.

So, herniated disc at the L4-L5 level, can create an L5 radiculopathy or an L4 radiculopathy, depending on where the disc herniation occurs (to the side or to the back of the disc) and which nerve root is affected:?

- Posterolateral (paracentral) - most common (90-95%), *affects the traversing /descending /lower nerve root i.e. L5 nerve root*
- Foraminal (far lateral, extraforaminal) - less common (5-10%), *affects exiting/upper nerve root i.e. L4 nerve root*

## 2. Deformity associated with posterior dislocation of hip joint?

a) Flexion

b) Extension

c) Abduction

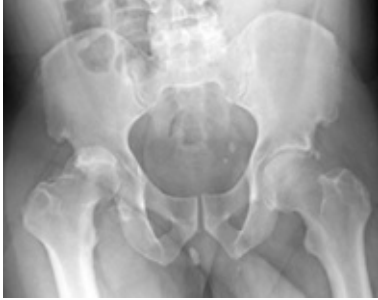d) Adduction

e) Internal rotation

Correct Answer - A:D:E

**Ans. is 'a' i.e., Flexion, 'd' i.e., Adduction & 'e' i.e., Internal rotation**

- Usually, the head of the femur is dislocated posterior to the acetabulum when the thigh is flexed, for example, as may occur in a head-on automobile collision when the knee is driven violently against the dashboard.
- *The significant clinical findings are shortening, adduction, and internal rotation of the extremity.*
- Anteroposterior, lateral and, if fracture of the acetabulum is demonstrated, oblique radiographic projections (Judet views) are required.
- Common associated injuries include fractures of the acetabulum or the femoral head or shaft and sciatic nerve injury



### 3. True regarding achondroplasia is?

a) Autosomal recessive

b) Disproportionate dwarfism

c) Subnormal intelligence

d) Bullet shaped vertebral bodies on radiology

e) Abnormal sexual development

Correct Answer - B:D

**Ans. is 'b' i.e., Disproportionate dwarfism &'d' i.e., Bullet shaped vertebral bodies on radiology**

#### **ACHONDROPLASIA:**

- **Achondroplasia** is a disorder of bone growth that prevents the changing of cartilage (particularly in the long bones of the arms and legs) to bone.

#### **SYMPTOMS:**

**80%-99% of people have these symptoms**

- Abnormality of the metaphysis
- Abnormality of the ribs
- Anteverted nares
- Chronic otitis media
- Depressed nasal bridge
- Frontal bossing
- Genu varum
- Hyperlordosis
- Macrocephaly
- Neonatal short-limb short stature
- Rhizomelia
- Wormian bones

**30%-79% of people have these symptoms**

- Abnormal form of the vertebral bodies
- Conductive hearing impairment
- Dental crowding
- Dental malocclusion
- Diaphyseal thickening
- Hyperhidrosis
- Intrauterine growth retardation
- Joint hyperflexibility
- Kyphosis
- Long thorax
- Midface retrusion
- Muscular hypotonia
- Narrow chest
- Narrow sacroiliac notch
- Obesity
- Obstructive sleep apnea
- Ventriculomegaly

**5%-29% of people have these symptoms**

- Acanthosis nigricans
- Death in infancy
- Dysarthria
- Elbow dislocation
- Hydrocephalus
- Joint stiffness
- Spinal canal stenosis
- Sudden cardiac death

**Percent of people who have these symptoms is not available through HPO**

- Autosomal dominant inheritance
- Brachydactyly
- Brain stem compression
- Flared metaphysis
- Generalized joint laxity
- Infantile muscular hypotonia
- Limited elbow extension
- Limited hip extension

- Lumbar hyperlordosis
- Lumbar kyphosis in infancy
- Malar flattening
- Megalencephaly
- Motor delay
- Recurrent otitis media
- Short femoral neck
- Small foramen magnum
- Spinal stenosis with reduced interpedicular distance
- Trident hand

**RADIOLOGICAL FINDING:**

- The inner contour of the pelvis has a typical, classic "champagne glass" appearance
- Large skull with relatively short base and a narrow and funnel - shaped foramen magnum
- Bullet shaped vertebral bodies
- Long and short tubular bones are short and thick with apparent increased diameter.
- Metaphysis of long bones are widened and flared, physis are notched or V -shaped.
- The spinal canal is narrow with decreased interpedicular distance as one proceeds from L1 to L5.

## 4. Signs of compartment syndrome include?

a) Pain on passive flexion

b) Pain on active flexion

c) Swelling of fingers

d) Pallor

e) Paraesthesia

Correct Answer - B:C:D:E

**Ans. is 'b' i.e., Pain on active flexion, 'c' i.e. Swelling of fingers, 'd' i.e. Pallor & 'e' i.e. Paresthesia**

### **Clinical features of compartment syndrome**

- Four signs are reliable in diagnosing a compartment syndrome :-
  1. Paraesthesia or hypesthesia in nerves traversing the compartment
  2. Pain with passive stretching of the involved muscles (stretch pain)
  3. Pain with active flexion of the muscles
  4. Tenderness over the compartment
- Amongst these, stretch pain is the earliest sign of impending compartment syndrome. The ischemic muscles, when stretched, give rise to pain.
- Passive extension of fingers (stretching the fingers) produce pain in flexor compartment of forearm.
- Other features are Pulselessness, paralysis, Pallor and pain out of proportion to physical findings.
- Peripheral pulses, are present initially and disappear later. Therefore, pulse is not a reliable indicator for compartment syndrome.

## 5. Which of the following statement is/are correct about fracture management in children?

a) Supracondylar fracture of humerus can be managed by closed reduction

b) Lateral condylar fracture of humerus is known as fracture of necessity

c) Lateral condylar fracture of humerus is managed by open reduction and screwing

d) Forearm fracture in children can be managed by closed reduction and casting

e) Femoral neck fracture in adults is managed by surgery and 3 screws

Correct Answer - A:B:C:D:E

**Ans. is 'a' i.e., Supracondylar fracture of humerus can be managed by closed reduction; 'b' i.e., Lateral condylar fracture of humerus is known as fracture of necessity ; 'c' i.e., Lateral condylar fracture of humerus is managed by open reduction and screwing, 'd' i.e., Forearm fracture in children can be managed by closed reduction and casting & 'e' i.e., Femoral neck fracture in adults is managed by surgery and 3 screws**

### **MANGEMENT OF SOME COMMON PEDIATRIC FRACTURES:**

#### **LOCATION OF FRACTURE**

#### **TYPE**

#### **MANAGEMENT**

Undisplaced(Gartland's Immobilization in type1)  
plaster for 3 weeks.

Supracondylar # of humerus	Angulated(Gartland's type 2)	Reduction (closed) under anaesthesia followed by percutaneous pinning. Same as type 2 / open reduction if Open (compound fracture) or associated vascular injury (complicated fracture).
	Completely displaced (Gartland's types 3)	If fracture is stable : Immobilization in above elbow cast in 90 degree flexion & neutral rotation.
Lateral condyle fracture of humerus	undisplaced	If fracture is unstable : Closed reduction and percutaneous pinning (k wire fixation)
	Only displaced	Closed reduction and percutaneous pinning.
Shaft of the forearm bones	displaced and rotated displacement is minimal	ORIF with screws. Closed reduction and elbow cast Conservative treatment by immobilization in
	Undisplaced fracture or valgus impacted	thomas knee splint In situ fixation with three parallel cannulated screws (preferred)
Femur neck		< 60 years :CRIF with 3 parallel cannulated screws> ORIF.
	Displaced	60 - 70 years :CRIF

OLD >3WEEKS

Physiological age < 65 years

>70 YEARS: Bipolar hemiarthroplasty; AMR  
Head is viable: Mc-Murry's osteotomy; Meyer's procedure

Arthroplasty  
:Bipolar

Head hemiarthroplasty not or AMR.

viable With arthritis:

Total hip replacement.

Physiological age > 65 years

Bipolar hemiarthroplasty or AMR.

With arthritis: Total hip replacement.

# of distal third of radius with dislocation or subluxation of inferior (distal) radio-ulnar joint

Galeazzi fractures inferior dislocation

Open reduction of the radius and the distal radio-ulnar joint.

## 6. All are features of inflammatory arthritis except?

a) Morning stiffness

b) X-ray showing sclerosis

c) Elevated ESR

d) Weight gain

e) Swelling of joints

Correct Answer - B:D

**Ans. is 'b' i.e., X-ray showing sclerosis & 'd' i.e., Weight gain**

**Features of inflammatory arthritis :?**

**Presence of some or all four cardinal signs of inflammation:**

- Erythema
- Pain
- Warmth
- Swelling

**Systemic symptoms**

1. Prolonged morning stiffness, often lasting for several hours. (Non-inflammatory arthritis are associated with intermittent stiffness, Stiffness usually lasts less than 1hr).
2. Fatigue
3. Fever
4. Weight Loss

**Laboratory evidence of inflammation**

1. Elevated ESR
2. Thrombocytosis
3. Elevated C reactive protein

i. Anemia of chronic disease.

**X-ray**

- X-ray feature of inflammatory arthritis shows rarefaction while x-ray features in non-inflammatory arthritis reveals sclerosis.

## 7. Risk factor(s) for Leg-Calf-Perthe's disease is/are?

a) Accelerated skeletal growth

b) Growth hormone abnormalities

c) Positive family history

d) Female sex

e) Passive smoking

Correct Answer - C:E

**Ans. is 'c' i.e., Positive family history & 'e' i.e., Passive smoking  
PERTHE'S DISEASE (LEGG-CALVE PERTHE'S DISEASE)**

- Perthe's disease is also known as osteochondritis deformans juvenilis or Coxa piano or Pseudocoxalgia.
- Perthe's disease is an osteochondritis of the epiphysis of the femoral head (capital femoral epiphysis). In the disease, the femoral head becomes partly or wholly avascular and deformed. The disease occurs commonly in males in the age group of 5-10 years.
- Perthe's disease is the most common form of osteochondrosis (osteochondrosis are characterized by avascular necrosis (AVN) and defective endochondral ossification of primary or secondary ossification centres).

### **Etiology of Perthe's disease**

- The etiology remains unknown, but is currently accepted that the disorder is caused by an interruption of the blood supply to the capital femoral epiphysis, causing avascular necrosis.

## **Risk factors**

### **Risk factors for Legg-Calve-Perthes disease include:**

- **Age.** Although Legg-Calve-Perthes disease can affect children of nearly any age, it most commonly begins between ages 4 and 8.
- **Your child's sex.** Legg-Calve-Perthes is up to five times more common in boys than in girls.
- **Race.** White children are more likely to develop the disorder than are black children.
- **Genetic mutations.** In a small number of cases, Legg-Calve-Perthes disease appears to be linked to mutations in certain genes.

## 8. All are true about septic arthritis except –

a) Staph aureus is the most common cause

b) Most common cause is E. coli

c) Common in children

d) Affects growth plate

e) Aspiration of joint fluid used for diagnosis

Correct Answer - B

**Ans. is 'b' i.e., Most common cause is E. coli**

**Septic arthritis (Acute suppurative arthritis)**

- Septic arthritis refers to pyogenic infection of a joint, i.e., infection of a joint by pyogenic organism (bacteria).
- The microbial spectrum is diverse in suppurative arthritis, but staphylococcus aureus infection is most common.
- The joint can become infected by : –
  1. Hematogenous spread from a distant site (most common route).
  2. Direct invasion through a penetrating wound, intra articular injection, arthroscopy.
  3. Direct spread from adjacent osteomyelitis especially in joints where Metaphysis is intra articular e.g., hip and shoulder.

**Clinical features**

- Disease is more common in children.
- **Knee joint is the most commonly affected joint.**
- Other joint which are affected are hip, shoulder and elbow.
- The child is toxic with fever, tachycardia, tachypnea.
- There is severe pain, swelling, and redness over the joint. Movements are severely restricted and the joint is held in the position of ease.

- Weight bearing on limb is not possible.

**Diagnosis:**

- Aspirated synovial fluid in septic arthritis will have markedly increased polymorphonuclear leukocytes

## 9. Hanging cast is used for?

a) Femur #

b) Radius #

c) Humerus #

d) Tibia #

e) Fibula #

Correct Answer - C

**Ans. is 'c' i.e., Humerus #**

**Cast/ Brace**

**Used In**

Hanging cast & "Sugar tong" or Coaptation splints	Fracture shaft humerus
Cylinder cast	Fracture patella
Minnerva cast, Halo device	Cervical spine
Risser's cast, Milwaukee brace	Scoliosis
Boston brace	
Palvic harness, Von Rosen splint,	Congenital (Developmental)
Ifeld or Craig splint	Dysplasia of Hip
Broom stick (Petrie) cast, Snyder sling, Pattern - bottom brace, Toronto brace with universal joint,	
Birmingham brace,	Legg Calve-
Tachdjian brace (trilateral	Perthes Disease

hip abduction orthosis),  
Newington brace, Atlanta  
scottish Rite brace

## 10. True about acute osteomyelitis –

a) Cannot be detected on X-ray before 2 weeks

b) Bone scan detect after 2 weeks

c) Severe pain

d) Secondary osteomyelitis associated with compound fracture is more common than primary variety

e) Limitation of movements

Correct Answer - C:E

**Ans. is 'c' i.e., Severe pain & 'e' i.e., Limitation of movements**

### **ACUTE OSTEOMYELITIS:**

1. It Primary (hematogenous): - Organisms reach the bone through blood stream.
  2. Secondary: - Organism gain entry directly through wound such as in compound fractures or surgical operation.
- Hematogenous osteomyelitis is the commonest form of osteomyelitis and most common source of bone and joint infection is hematogenous.

### **Clinical features :**

- Metaphysis of long bone is the earliest and most common site involved.
- Most common in children.

### **The bones most commonly :**

- Proximal tibial
- Distal femur
- Proximal humerus.

### **Features:**

- Severe pain, fever, malaise, chills & rigors, sweating, and even

shock.

- Local tenderness (finger tip tenderness), raised local temperature, Local erythema and limitation of movements (typically the limb is held still).

**Diagnosis:**

**X-rays**

- Earliest sign : periosteal reaction (periosteal new bone formation) at the metaphysis, which takes about 7-10 days.

**Bone scan**

- Increased uptake by bone in metaphysis within 24 hours of onset of symptoms (earliest sign).

## 11. Correct statement about hand infection?

a) Opening of Felon by fish mouth incision is preferred incision technique

b) Felon is middle volar pulp infection

c) Apical subungual infection- V-shaped piece is removed from the center of the free edge of the nail along with a little wedge of the full thickness of the skin overlying the abscess

d) When the pus extends beneath the nail, it is necessary to remove the some part of nail for adequate drainage of pus

e) None

Correct Answer - C:D

**Ans. c. Apical subungual infection- V-shaped piece is removed from the center of the free edge of the nail along with a little wedge of the full thickness of the skin overlying the abscess ;  
d. When the pus extends beneath the nail, it is necessary to remove the some part of nail for adequate drainage of pus**

- In apical subungual infection: For drainage, a small V shaped piece is removed from the centre of that free edge of the nail along with a little wedge of the full thickness of the skin overlying the abscess.
- In acute paronychia: When the pus extends beneath the nail, it is necessary to remove the proximal one-third of the nail for adequate drainage.
- DO NOT perform a "fish mouth" incision since this may results in: Unstable finger pad, neuroma., and/or loss of sensation"
- The felon should be incised in the area of maximum swelling and tenderness.

## 12. Which of the following are not included in Gurd's criteria?

a) Central nervous system depression disproportionate to hypoxaemia

b) Tachycardia < 110 bpm

c) Deep vein thrombosis

d) Axillary or subconjunctival petechiae

e) Hypoxaemia  $P_{aO_2} < 60$  mm Hg,  $F_{iO_2} = 0.4$

Correct Answer - C

**Ans. c. Deep vein thrombosis**

### 13. Cause(s) of avascular necrosis of femoral Head:

a) Fracture of femoral neck

b) Steroid use

c) alcohol use

d) Sickle cell disease

e) Caisson disease

Correct Answer - A:B:C:D:E

**Answer: A,Fracture of femoral neck B,Steroid use C,alcohol use D,Sickle cell disease E, Caisson disease**

**Cause of avascular necrosis of femoral head:**

- Idiopathic-commonest
- Alcoholism
- Steroid therapy
- Sickle cell disease
- Patient of renal dialysis
- Patient on anticancer drug
- Post-partum necrosis
- Goucher's disease
- Caisson's disease

## 14. Spur sign is/are seen in:

a) Supracondylar fracture of humerus

b) Radial head fracture

c) Acetabulum fracture of pelvis

d) Talus fracture

e) None

Correct Answer - C

**Ans. (c) Acetabulum fracture of pelvis**

- Spur cells-They are irregularly distorted red cells containing several irregularly distributed thorn like projections.
- Cells with this morphologic abnormality are also called acanthocytes.
- They are seen in Splenectomised patients and patients with liver disease.

## 15. True about giant cell sarcoma?

a) Most common age group affected is 20-40year

b) Proximal femur is most common site affected

c) Pulmonary metastasis occur in <3% of cases

d) A locally aggressive tumor

e) May involve sacrum

Correct Answer - A:C:D:E

**Ans. a. Most common age group affected is 20-40year ; c. Pulmonary metastasis occur in <3% of cases; d. A locally aggressive tumor; e. May involve sacrum**

**GCT :**

- It perhaps represents the most aggressive benign tumor and threatens the true definition of a benign cancer because benign pulmonary metastasis develop in approximately 1% to 2% of giant cell tumors.

**CLINICAL FEATURES**

- The tumour is seen commonly in the age group of **20-40 years** i.e., after epiphyseal fusion.
- The bones affected commonly are those around the knee i.e., lower-end of the femur and upper-end of the tibia.
- Lower-end of the radius is another common site.

**The tumour is located at the epiphysis.**

- It often reaches almost up to the joint surface.
- Common presenting complaints are swelling and vague pain.
- Sometimes, the patient, unaware of the lesion, presents for the first time with a pathological fracture through the lesion.

**16. All are true about anterior cruciate ligament except?**

a) Commonly occurs as a result of twisting force

b) May be associated with Segond fracture

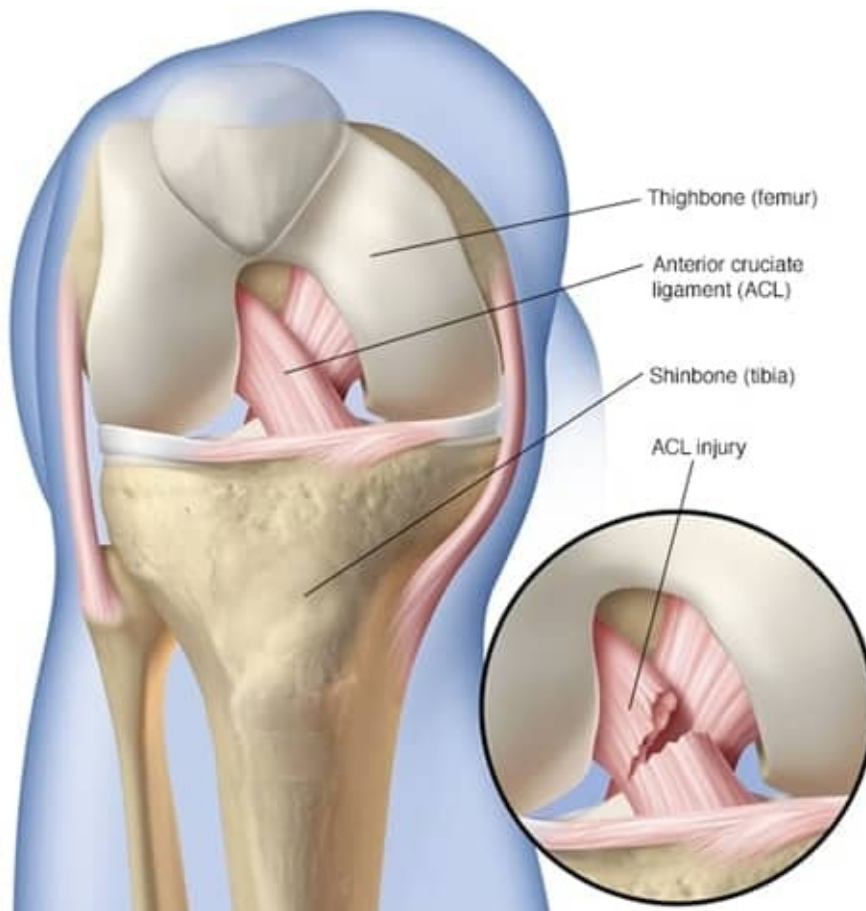
c) Rarely associated with meniscal injury

d) Lachman test is highly sensitive test for tear

e) None

Correct Answer - C

**Ans.(c) Rarely associated with meniscal injury**



### **Symptoms:**

#### **Signs and symptoms of an ACL injury usually include:**

- A loud "pop" or a "popping" sensation in the knee
- Severe pain and inability to continue activity
- Rapid swelling
- Loss of range of motion
- A feeling of instability or "giving way" with weight bearing

#### **Complications**

- Higher risk of developing osteoarthritis in the knee. Arthritis may occur even if you have surgery to reconstruct the ligament.
- Second fracture due to avulsion at the anterolateral capsular attachment. Second fractures have a very high association with ACL tears and, meniscal injuries

#### **Diagnosis:**

- Injury to tear of anterior cruciate ligament can be detected using lachman and anterior drawer test.
- Lachmann test is a similar test to anterior drawer test in which

anterior glide of the tibia is judged with the knee in 10-15 degrees of flexion.

## 17. Which of the following is/are true about Ewing sarcoma:

a) Vascular origin

b) Ewing's sarcoma is second most common primary malignant bone tumour in children after Osteosarcoma

c) Metaphysis of long bone is most common site

d) Fever and weight loss may be present

e) Surgery is very useful in management

Correct Answer - B:D

**Ans. b. Ewing's sarcoma is second most common primary malignant bone tumour in children and adolescent after Osteosarcoma; d. Fever and weight loss may be present**

### **Ewing Sarcoma:**

- Ewing's sarcoma arises from primitive neuroectoderm.
- Most common Site: Femur diaphysis > tibia diaphysis

### **Clinical features:**

- Occurs between 10-20 years of age.
- The patient presents with pain and swelling.
- History of trauma preceding onset, but it is usually incidental.
- Often there is an associated **fever**, in which case it may be confused with osteomyelitis.

### **Treatment**

- This is a **highly radio-sensitive tumour** melts quickly but recurs.
- Treatment consists of control of local tumour by **radiotherapy** , and control of metastasis by **chemotherapy**.
- The most common primary malignant **bone**

**tumors** are **osteosarcoma** (35%), chondrosarcoma (25%), and Ewing's sarcoma (16%).

- Less frequently ( $\leq 5\%$ ) occurring tumors are chordoma, malignant fibrous histiocytoma of bone, and **fibrosarcoma** of bone.
- The most common malignant pediatric bone tumors include **osteosarcoma** and **Ewing sarcoma**.

**18. Which of the following is/are indication of surgical management of fracture of shaft of humerus:**

a) Fracture in elderly

b) Radial nerve involvement after manipulation

c) Pathological fractures

d) Vascular injury

e) Multiple fractures

Correct Answer - B:C:D:E

**Ans. (b) Radial nerve involvement after manipulation, (c) Pathological fractures, (d) Vascular injury, (e) Multiple fractures**

**Fractured Shaft of Humerus: Operative Treatment - Indications :**

**Severe multiple injures :**

- An open fracture .
- Segmental fractures .
- Displaced intra-articular extension of the fracture
- A pathological fracture .
- A floating elbow(simultaneous unstable humeral and forearm fractures)
- Radial nerve palsy after manipulation .
- Non-union
- Problems with nursing care in a dependent person

## 19. Pirani scoring of CTEV includes all except?

a) Curvature of the medial border of the foot

b) Severity of the medial crease

c) Position of the lateral part of the head of the talus

d) Emptiness of the heel

e) Severity of the posterior crease

Correct Answer - A

**Ans.(a) Curvature of the medial border of the foot**

### **PIRANI SCORING**

- The Pirani score is a simple, easy to use tool for assessing the severity of each of the components of a clubfoot.

#### **Pirani Scoring:**

**The components are scored as follows:**

- Each component may score 0, 0.5 or 1
- Hind foot contracture score (HCFS):

#### **Mid foot contracture score (MFCS):**

.. Posterior crease

2.. Empty heel

3.. Rigid equinus

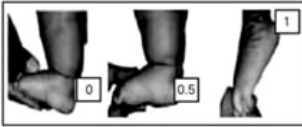
#### **Mid foot contracture score (MFCS):**

.. Medial crease

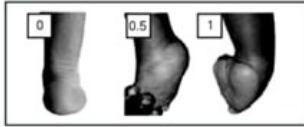
2.. Curvature of lateral border

3.. Position of head of talus

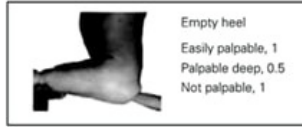**A**



Rigid equinus

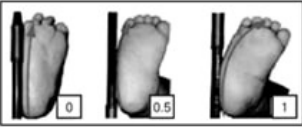


Empty heel

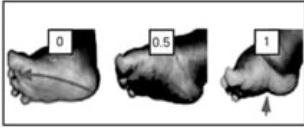


Posterior crease

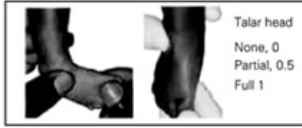**B**



Curved lateral border



Medial crease



Lateral head of talus (LHT)

## 20. True about tuberculosis of Spine:

a) Middle path regimen is used in management

b) Posterior elements of the spine is most commonly affected

c) Commonly spread by hematogenous route from lung

d) Acute onset paraplegia has worse prognosis

e) Lower thoracic and upper lumbar is most common site

Correct Answer - A:C:E

**Ans. a. Middle path regimen is used in management; C. Commonly spread by hematogenous route from lung e. Lower thoracic and upper lumbar is most common site**

### **Route:**

- Lymphogenous and hematogenous spread has been implicated. in thoracolumbar lesions.

### **Site:**

- Upper thoracic spine is the most common site of spinal TB in children, the lower thoracic and upper lumbar vertebrae are usually affected in adults
- Paradiscal is the commonest type.
- Acute onset paraplegia has a better prognosis

### **Management:**

1. Rest,
2. Drugs Intensive Phase: HRO (5-6 months); Continuation Phase: HZ (3-4 months) + HR(4-5 months); Prophylactic Phase: HE (4-5 months),
3. Radiological Follow-up (X-ray, MRI), d. Gradual Mobilisation +/- Spinal braces. management of Abscess/ Sinuses,
4. Management of Neurological complications

- i. Surgery(Excisional surgery Definitive Surgery: Indication of Surgery in Pott's spine),
- j. Post-operative care

**21. A 70 year old lady got compression fracture of L1 vertebra. There is no neurological deficit to this patient. What advise will you give for this Patient:**

a) Vitamin D supplementation

b) Do MRI scan

c) Go for screw fixation of L1 vertebra

d) To take Dexamethasone

e) To take Alendronate

Correct Answer - A:E

**Ans. a. Vitamin D supplementation; e. To take Alendronate**

It is a case of osteoporotic fracture of lumbar spine

**Treatment can be divided into medical & preventive .**

**Medical:**

- High protein diet, androgen, estrogen, Vitamin D, fluoride, alendronate, calcitonin, teripratide, denosumab & strontium (both are antiresorptive agent) .
- Orthopaedic treatment: Exercise & Bracing (ASH brace or Taylor brace)

**22. For assessing the injury of meniscus of knee joint, which of the following test is/are done:**

a) Apley's test

b) Lachmann test

c) McMurray's test

d) Thessaly test

e) Hamilton ruler test

Correct Answer - A:C:D

**Ans. a. Apley's test ; c. McMurray's test; d. Thessaly test**

**Tests for Meniscal Injuries –**

- Apley's grinding test: for meniscus injury
- McMurray's test- This classic test for a torn meniscus is seldom used now that the diagnosis can easily be made by MRI. A positive test is helpful but not pathognomonic a negative test does not exclude a tear .
- Thessaly test: This test has shown a high diagnostic accuracy rate at the level of 95% in detecting meniscal tears

## 23. True about Colle's fracture:

- a) Occur at distal end of radius, about 2 cm from distal articular surface
- b) Fracture also involves radiocarpal joint
- c) Fracture also involves proximal radioulnar joint
- d) Cause ulnar deviation
- e) Common in women

Correct Answer - A:E

**Ans. a. Occur at distal end of radius, about 2 cm from distal articular surface; e. Common in women**

### **Colle's Fracture :**

- This is a Fracture at the distal end of the radius, at its corticocancellous junction (about 2 cm from the distal articular surface), in adults, with typical displacement .
- It nearly always results from a fall on an out-stretched hand c It is commonest fracture in people above forty years
- Particularly common in women because of postmenopausal osteoporosis .
- Displacement- dorsal displacement, dorsal tilt (most characteristic), lateral displacement, dorsal tilt, supination & impaction of fragments
- Complication: Dinner fork deformity & Subluxation of the inferior radio-ulnar joint (distal radiocarpal joint)
- It is most common of all fracture in older people.

## 24. Which of the following is/are true about simple bone cyst:

a) Most commonly occur in adult

b) Commonest site is the upper end of the humerus

c) Cortex may be thin

d) Cause pathological fracture

e) No risk of recurrence after removal

Correct Answer - B:C:D

**Ans. b. Commonest site is the upper end of the humerus c. Cortex may be thin d. Cause pathological fracture**

**Simple Bone Cyst (Also k/a Solitary or Unicameral Cyst)**

- It appear during childhood, in metaphysis in one of the long bones & most commonly In proximal humerus or femur .
- It is not a tumour , it tend to heal spontaneously .
- It is seldom seen in adult
- This condition is usually discovered after a pathological fracture or as an incidental finding on X-ray .
- X-ray shows a well demarcated radiolucent area in the metaphysis often extending up to the physeal plate; the cortex may be thinned & the bone expanded
- Treatment depends on whether the cyst is symptomatic, actively growing or involved in a fracture

## 25. True about ankylosing spondylitis:

- a) Romanus lesion may be found
- b) If left untreated, spine fusion may occur
- c) Predilection of the joints of the axial skeleton
- d) Bony erosions do not occur
- e) all

Correct Answer - A:B:C

**Ans. a. Romanus lesion may be found ;b. If left untreated, spine fusion may occur; c. Predilection of the joints of the axial skeleton**

### **Ankylosing spondylitis (marie-strumpell disease)**

- Ankylosing spondylitis is a chronic progressive inflammatory disease of the sacroiliac joints and the axial skeleton.
- prototype of seronegative (absence of rheumatoid factor) spondyloarthropathies.
- **Inflammatory disorder of unknown cause.**
- Usually begins in the second or third decade with a median age of 23, in 5% symptoms begin after 40.
- **Male to female ratio is 2-3 : 1**
- **Strong correlation with HLA-B27-95% of case**
- **9s are positive for HLA - B27.**
- **Joints involved in ankylosing spondylitis**
- Ankylosing spondylitis primarily affects axial skeleton.
- The disease usually begins in the sacro-iliac joints and usually extends upwards to involve the lumbar, thoracic, and often cervical spine.
- In the worst cases the hips or shoulders are also affected. Hip joint

is the most commonly affected peripheral joint.

- Rarely knee (Ebenzar 4<sup>th</sup>/e 593) and ankle (Apley's 9<sup>th</sup>/e 67) are also involved. Pathology
- Enthesitis i.e. inflammation of the insertion points of tendons, ligaments or joint capsule on bone is one of the hallmarks of this entity of disease.
- Primarily affects axial (spinal) skeleton and sacroiliitis is often the earliest manifestation of A.S..
- Involvement of costovertebral joints frequently occur, leading to diminished chest expansion (normal  $\approx$  5 cm)
- Peripheral joints e.g. shoulders, and hips are also involved in 1/3rd patients.
- Extraarticular manifestations like acute anterior uveitis (in 5%); rarely aortic valve disease, carditis and pulmonary fibrosis also occur.
- Pathological changes proceed in three stages?
- Inflammation with granulation tissue formation and erosion of adjacent bone.
- Fibrosis of granulation tissue
- Ossification of the fibrous tissue, leading to ankylosis of the joint.

### **Radiological features of ankylosing spondylitis**

- Radiographic evidence of sacroiliac joint is the most consistent finding in ankylosing spondylitis and is crucial for diagnosis. The findings are :-
- Sclerosis of the articulating surfaces of SI joints
- Widening of the sacroiliac joint space
- Bony ankylosis of the sacroiliac joints
- Calcification of the sacroiliac ligament and sacro-tuberous ligaments
- Evidence of enthesopathy - calcification at the attachment of the muscles, tendons and ligaments, particularly around the pelvis and around the heel.

### **X-ray of lumbar spine may show :-**

- Squaring of vertebrae : The normal anterior concavity of the vertebral body is lost because of calcification of the anterior longitudinal ligament.
- Loss of the lumbar lordosis.
- Bridging 'osteophytes' (syndesmophytes)
- Bamboo spine appearance

---

## 26. True about boutonniere deformity:

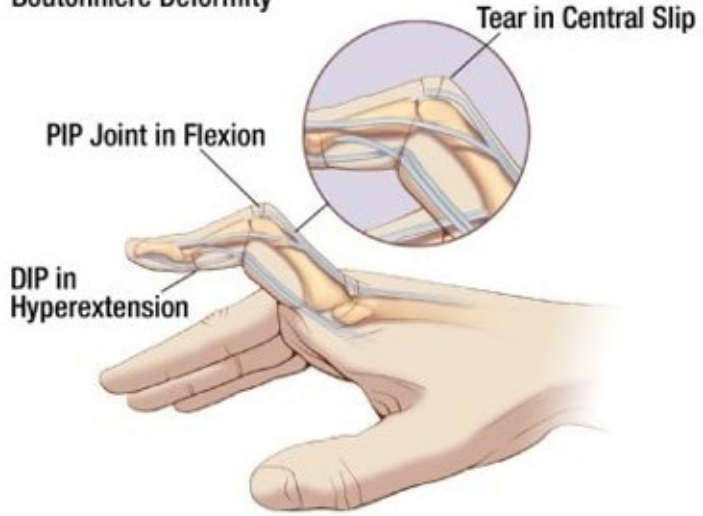
- a) Flexion of proximal interphalangeal joint & hyperextension of distal interphalangeal joint
- b) Hyperextension of proximal interphalangeal joint & flexion of distal interphalangeal joint
- c) Flexion at proximal interphalangeal & extension at metacarpophalangeal joint
- d) Flexion deformity of the proximal interphalangeal joint occur due to tear in central slip of extensor tendon
- e) May occur in rheumatoid arthritis

Correct Answer - A:D:E

**Ans. a. Flexion of proximal interphalangeal joint & hyperextension of distal interphalangeal joint; d. Flexion deformity of the proximal interphalangeal joint occur due to tear in central slip of extensor tendon ; e. May occur in rheumatoid arthritis**

- Boutonniere deformity is a deformed position of the fingers or toes, in which the joint nearest the knuckle (the proximal interphalangeal joint, or PIP) is permanently bent toward the palm while the farthest joint (the distal interphalangeal joint, or DIP) is bent back away (PIP flexion with DIP hyperextension).
- It can be caused by a cut on the top of the finger, which can sever the central slip (tendon) from its attachment to the bone. The tear looks like a buttonhole ("boutonnière" in French). In some cases, the bone actually can pop through the opening.
- Boutonnière deformities may also be caused by **arthritis**.

**Boutonniere Deformity**



## 27. True about applying a plaster is are –

a) Taken out from water once bubbles start coming

b) Taken out from water once bubbles stop coming out

c) Setting is delayed in cold water

d) Cotton padding is overlapped by one third

e) Molding/smoothing of plaster is done by fingers

Correct Answer - B:C:D

**Ans. is 'b' i.e., Taken out from water once bubbles stop coming out; 'c' i.e., Setting is delayed in cold water; 'd' i.e., Cotton padding is overlapped by one third**

- For securing, each turn is overlapped by one third to one half in order to secure layers.
- If a bandage is immersed in cold water the initial set will be delayed and thus "working time" lengthened. However, if a very rapid is required soaking the bandage in warm water will accelerate the rate of reaction.
- Moulding of the bandages to the contours of the limb should be done by constant smoothing with the palms (not by fingers) of the wet hands.

## 28. Radiological features of Perthe's disease is/are –

a) Decreased medial joint space

b) Lateral subluxation

c) Vertical Physis

d) Speckled calcification

e) Wide femoral neck

Correct Answer - B:D:E

**Ans. is, b' i.e., Lateral subluxation; 'd' i.e., Speckled calcification & 'e' i.e., Wide femoral neck**

**Radiological findings in perthe's disease are :-**

- Increased medial joint space
- Widening of femoral neck
- Lateral extrusion (lateral subluxation)
- Metaphyseal cysts and rarefaction of metaphysis
- Horizontal physis with speckled calcification lateral to it
- Fragmentation of femoral head with increased density (irregular densities in the epiphysis).

## 29. Late complication of supracondylar fracture is –

a) Ulnar nerve palsy

b) Cubitus varus

c) Cubitus valgus

d) Myositis ossificans

e) Volkmann's ischemic contracture

Correct Answer - B:D:E

**Ans. 'b' i.e., Cubitus Varus 'd' i.e., Myositis ossificans 'e' i.e., Volkmann ischemic contracture**

**Late Complications :**

**Occurring weeks to months after the fracture and include :**

- Malunion: - It is the commonest complication of supracondylar fracture and results in cubitus varus (Gun stock deformity), Cubitus valgus is rare and may occur occasionally in posterolateral displacement.
- Myositis ossificans and elbow stiffness.
- Volkmann's ischemic contracture

### 30. Complication(s) of fracture of lateral condyle humerus is/are –

a) Cubitus varus deformity

b) Tardy ulnar nerve palsy

c) Cubitus valgus deformity

d) Median nerve injury

e) Non-union

Correct Answer - A:B:C:E

**Ans. is 'a' i.e., Cubitus varus deformity 'b' i.e., Tardy ulnar nerve palsy; 'c' i.e., Cubitus valgus deformity; 'e' i.e., Non-union**

#### **Complications of Lateral condyle of humerus fracture**

- Lateral spur
- Cubitus valgus
- Rarely, cubitus varus
- Tardy ulnar nerve palsy
- Rarely avascular necrosis and myositis ossificans
- Posterolateral instability and recurrent instability

### 31. Following are true regarding hangmans fracture –

a) Fracture of spinous process of C7

b) Fracture of C2 vertebra

c) Listhesis of the fracture vertebra

d) Knot is placed under nape of neck

e) None

Correct Answer - B:C

**Ans. is 'b' i.e., Fracture of C2 vertebra; 'c' i.e., Listhesis of the fracture vertebra**

#### **Hangman's fracture**

- Hangman's fracture is bilateral fracture of the pars interarticularis of axis ( $C_2$ ) with traumatic spondylolisthesis of axis ( $C_2$ ) over  $C_3$  vertebrae. Thus Hangman's fracture is not simply a fracture, but fracture dislocation of axis ( $C_2$ ).
- The mechanism of injury is extension with distraction (in true, judicial hangman's fracture) and hyper-extension, axial compression & flexion (in civilian injuries, which are now more common).
- It is second most common type of Axis ( $C_2$ ) fracture, second only to odontoid fractures.
- Fatalities are common, However, neurological deficit is unusual as the fracture of posterior arch decompress the spinal cord.
- Most of the fatalities occur at the scene of injury, acute post admission mortality is low.
- Successful healing of  $C_2$  traumatic spondylolisthesis is reported to approach 95%. This is most commonly achieved with non-operative

measures, even in the presence of displacement of pars inter-articularis.

- Undisplaced fractures are treated in a semi-rigid orthosis, and displaced fracture are closed reduced & treated with halo-vest.
- Occasionally, the hangman's fracture is associated with a C2/3 facet dislocation. This is a severely unstable injury; open reduction and stabilization is required.

## 32. True about keinbock's disease is/are –

a) AVN of scaphoid

b) More common in males

c) May be associated with cerebral palsy

d) Stage- I shows normal X-ray

e) May cause carpal tunnel syndrome

Correct Answer - B:C:D:E

**Ans. b) More common in males c) May be associated with cerebral palsy d) Stage- I shows normal X-ray e) May cause carpal tunnel syndrome**

**Keinbock's disease :**

- It is avascular necrosis of lunate bone. It is related to overuse and ulnar negative wrist variance and may be associated with sickle cell anemia, steroid abuse, gout and cerebral palsy.
- It usually occurs in 2nd to 5 decade with male preponderance'
- Patients complains of dorsal wrist pain, swelling, warmth, tenderness over the radio lunate joint reduced ROM and decreased grip strength.

**Complications:**

- Stiffness
- Loss of motion
- Weakness
- Carpal tunnel syndrome
- Persistent pain
- Instability
- Degeneration in adjacent joints

### 33. True about location(s) of tumor is/are –

a) Osteosarcoma is diaphyseal

b) Ewing sarcoma is diaphyseal

c) Chondrosarcoma is metaphyseal

d) Fibrosarcoma is diaphyseal

e) Osteoclastoma is epiphyseal

Correct Answer - B:C:D:E

**Ans. b) Ewing sarcoma is diaphyseal c) Chondrosarcoma is metaphyseal d) Fibrosarcoma is diaphyseal e) Osteoclastoma is epiphyseal**

**Epiphyseal tumor:**

- Chondroblastoma
- Giant cell tumor (osteoclastoma)
- Clear cell chondrosarcoma

**Metaphyseal lesion:**

- Osteogenic sarcoma .
- Unicameral (simple) bone cyst .
- Aneurysmal bone cyst .
- Fibrous cortical defect .
- Chondrosarcoma
- Osteochondroma
- Enchondroma .
- Osteoblastoma

**Diaphyseal lesion:**

- Ewing sarcoma
- Lymphomas
- Fibrous dysplasia

- Adamantinoma
- Histiocytosis
- Osteoid osteoma
- Chondromyxoid fibroma
- Fibrosarcoma
- Fibrous cortical defect
- Non ossifying fibroma

**34. A 28 years old lady presented with wrist pain. X-ray wrist is showing lytic eccentric lesion in lower end of radius with soap bubble appearance. What is the next plan of management –**

a) Bone curettage and bone grafting

b) Extended curettage with phenol

c) Biopsy of the lesion

d) Extended curettage with phenol and bone grafting

e) Parathyroid and serum calcium levels measurement

Correct Answer - C

**Ans. is 'c' i.e., Biopsy of the lesion**

- 28 years female with lytic eccentric lesion in lower end of radius and soap bubble appearance suggest the diagnosis of GCT.
- Next plan of management would be biopsy of lesion to confirm the diagnosis.

### 35. True about the sites involved in osteomyelitis is/are –

a) Mainly involves metaphysis

b) Distal tibia is involved commonly

c) Proximal humerus is involved commonly

d) Proximal femur is involved commonly

e) Reaches to site by hematogenous routes

Correct Answer - A:C:E

**Ans. is ,a, i.e., Mainly involves metaphysis;'c' i.e., Proximal humerus is involved commonly 'e' i'e', Reaches to site by hematogenous route**

- Hematogenous osteomyelitis is the commonest form of osteomyelitis and almost common source of bone and joint infection is hematogenous.
- It is caused most commonly by staphylococcus aureus.
- Other causative organisms are streptococcus, pneumococcus, and gram negative bacilli.
- Infection by pseudomonas becomes proportionally much more common in IV drug abuser. But, the most common organism is staphylococcus aureus.

### 36. Compound palmar ganglion is caused by

–

a) Trauma

b) Overuse

c) RA

d) TB

e) SLE

Correct Answer - C:D

**Ans. is 'c' i.e., RA 'd' i.e., TB**

- Rheumatoid arthritis and tuberculosis are the commonest causes.
- Tubercular and rheumatoid compound palmer ganglion is characterized by presence of rice bodies, millet bodies and melon seeds.

### 37. True about compound palmar ganglion –

a) Due to degeneration of flexor retinaculum

b) Hour-glass in shape

c) Surgery is the mainstay of treatment

d) Intrasynovial steroid is the mainstay of treatment

e) May be seen in rheumatoid arthritis

Correct Answer - A:D

**Ans. is 'a' i.e., Due to degeneration of flexor retinaculum; 'd' i.e., Intrasynovial steroid is the mainstay of treatment**

- Compound palmar ganglion is a misnomer because it is neither a ganglion nor compound.
- Chronic inflammation distends the common sheath of flexor tendons both above and below the flexor retinaculum.
- There is hourglass swelling, bulging above and below the flexor retinaculum
- Tubercular and rheumatoid compound palmer ganglion is characterized by presence of rice bodies, millet bodies and melon seeds
- Rheumatoid arthritis and tuberculosis are the commonest causes.

**38. A person has injury on dorsal surface of proximal interphalangeal joint of right middle finger. Which of the following can occur**

a) Rupture of lateral ligament

b) Buttonhole deformity

c) Mallet finger

d) Laceration of the central slip of the extensor

e) None of the above

Correct Answer - A:B:D

**Ans. is 'a' i.e., Rupture of lateral ligament; 'b' i.e., Buttonhole deformity; 'd' i.e., Laceration of the central slip of the extensor  
Injury to dorsal surface of proximal interphalangeal joint (zone II) may cause : -**

- Rupture of central slip of extensor expansion - causing Buttonhole deformity.
- This results in loss of active extension of the PIP joint and persistent flexion of the PIP joint.
- Anterior dislocation of PIP joint may cause rupture of both central clip as well as lateral ligament.

## 39. True about pectus excavatum

a) More common in female

b) In severe cases, mitral valve prolapse may occur

c) May be present at birth

d) Seen in marfan syndrome

e) Impairment of respiratory function

Correct Answer - B:C:D:E

**Ans. is 'b' i.e., In severe cases, mitral valve prolapse may occur; 'c' i.e., May be present at birth; 'd' i.e., Seen in Marfan syndrome i 'e' i.e., Impairment of respiratory function**

### **Pectus Excavatum**

- Also called *funnel chest* is the most common chest wall deformity.
- Males are affected more than females (4:1).
- Pectus excavatum arises from imbalanced or excessive growth of the lower costal cartilages.
- Typically the defect is diagnosed within the first yr of life and worsens over time.
- Depression may range from mildly depressed sternum to sternal depression abutting the vertebral column with displacements of mediastinal structures.

### **Other conditions associated with Pectus Excavatum:**

- **Scoliosis**
- Marfan's syndrome
- Mitral valve prolapse
- Congenital heart diseases

**40. In ponseti technique last deformity in to get corrected in CTEV -**

a) Equinus

b) Talipes

c) Varus

d) Cavus

e) All deformity corrected simultaneously

Correct Answer - A

**Ans (a) Equinus**

**Ponseti's technique**

- This involves first correcting the cavus deformity then the adduction and heel varus and finally the equinus deformity.
- This technique is now mostly accepted technique for CTEV correction as it is based on better understanding of the pathoanatomy of the deformed foot.
- The success of reduction is 90-98 Percent.

## 41. True about avascular necrosis of femur

a) Affected side hip allows weight bearing

b) Asymptomatic cases may occur

c) Radionucleotide scan show increased uptake due to new bone formation in the area around the infarct

d) Trendelenburg sign is negative

e) None of the above

Correct Answer - A:B:C

**Ans. is 'a' i.e., Affected side of hip allow wt. bearing; 'b' i.e., Asymptomatic cases may occur & 'c' i.e., Radionucleotide scan show increased uptake due to new bone formation in the area around the infarct**

### **Causes of AVN**

- Idiopathic (most common)
- Infection- septic arthritis, osteomyelitis
- Hematological malignancies- leukemia, lymphoma
- Alcohol, corticosteroids
- SLE
- Pregnancy
- Cassions disease
- Hyperlipidemia
- Perthes disease
- Ionising radiation

### **CLINICAL FEATURES:**

- Pain
- Decrease range of motion especially internal rotation followed by abduction.

- Sectoral sign or Differential rotation: - Internal rotation is possible in extended position of hip, but as seen as the hip is flexed to 90<sup>0</sup> no internal rotation is possible. This is the characteristic sign of AVN.
  - Trendelenburg's test positive
- Radiological findings:**
- MRI is the most reliable way of diagnosing marrow changes and bone ischaemia

## 42. True about ganglion cyst –

- a) Most common in young male
- b) Contain synovial fluid
- c) Arise from extensor retinaculum
- d) It usually arise from the lunotriquetral joint
- e) Surgical treatment is excision of cyst

Correct Answer - B:E

**Ans. is 'b.i.e', Contain synovial fluid; 'e.i.e., Surgical treatment is excision of cyst**

A ganglion is the commonest cystic swelling at the back (Dorsal aspect) of the wrist.

- Unilocular cyst
  - Arises due to leakage of synovial fluid from a joint or tendon sheath.
  - Filled with mucinous fluid and lined by fibrous tissue
  - Usually develops on the dorsal surface of the scapho-lunate ligament.
  - Palmar wrist ganglia usually arise from the volar scapholunate or scapho-trapezio-trapezoid joint.
  - More common in young (20-40 years) female.
  - No communication between the joint cavity or tendon sheath and the interior of cyst.
  - Painless small swelling sometimes it may cause pain.
- Treatment :**
- Not required.
  - For pain NSAIDs
  - Swelling increase in size it may be aspirated or surgically excised.

### 43. Test for anterior cruciate ligament is/are

a) Lachmann test

b) Apley's grinding test

c) Pivot shift test

d) Anterior drawer

e) KT-1000 knee arthrometer is an objective instrument for ACL reconstruction

Correct Answer - A:C:D:E

**Ans. is 'a' i.e., Lachmann test 'c' i.e., Pivot shift test; 'd' i.e., Anterior drawer & 'e' i.e., KT-1000 knee arthrometer is an objective instrument for ACL reconstruction**

**Following tests are used for ACL injury: -**

- Lachman's test
- Pivot shift test
- Anterior drawer test
- Jerk test
- Flexion-rotation drawer test
- Loose's test

## 44. True about osteomalacia –

a) More common in male

b) Low PTH

c) Increase alkaline phosphatase

d) Decreased calcium level

e) Looser's zone on X-ray

Correct Answer - C:D:E

**Ans. (c) Increase alkaline phosphatase ; (d) Decreased calcium level; (e) Looser's zone on X-ray**

### **Osteomalacia**

- Looser's zone (pseudofractures) are radiolucent zones occurring at the sites of stress in osteomalacia (commonly at pubic rami)
- Osteomalacia is more common in women who live in "purdah" & lack exposure to sunlight
- Serum calcium & phosphate is low & alkaline phosphatase is high
- Muscular weakness (The patient feels very weak. He may difficulty in climbing up & down the stairs)

## 45. True about complex regional pain syndrome:

a) Sudeck's atrophy is an example

b) Pain is out of proportion to precipitating cause

c) Hyperaesthesia of skin may be present

d) Adults are usual sufferer

e) Parasympathetic mediated enhancement of pain

Correct Answer - A:B:C:D

**Ans. a. Sudeck's atrophy is an example ; b. Pain is out of proportion to precipitating cause; c. Hyperaesthesia of skin may be present; d. Adults are usual sufferer**

### **Complex Regional Pain Syndrome**

- A number of clinical syndromes appear under this heading, including Sudeck's atrophy, reflex sympathetic dystrophy, algodystrophy, shoulder -hand syndrome & particularly after a nerve injury-causalgia.
- Precipitating causes are trauma(often trivial), operation or arthroscopy, a peripheral nerve lesion, myocardial infarction, stroke & hemiplegia
- Adults are the usual sufferers but the condition occasionally occur in children

## 46. True about Dupuytren's contracture;

a) Commonly affect ring & small finger

b) May involve penis

c) Involves metacarpo-phalangeal joint

d) Knee reflex diminished

e) Involves neck flexors

Correct Answer - A:B:C

**Ans. a. Commonly affect ring & small finger ; b. May involve penis; c. Involves metacarpo-phalangeal joint**

**Clinical Features of Dupuytren's contracture:**

- Thickened fibrous bands felt over the ulnar side of the palm.
- Thickening of plantar fascia or that of the penile fascia (Peyronie's disease).
- Tenderness over the involved area at the base of the digits.
- Flexion deformity at the MCP and PIP joints of involved fingers

## 47. All are true Volkmann ischemic contracture except

- a) Ischemic muscle is replaced by fibrous
- b) Ulnar nerve palsy may be present
- c) Extension deformity of the wrist & fingers
- d) Flexion at the metacarpophalangeal
- e) Tendon transfer helps in restoring movements

Correct Answer - C

**Ans. c. Extension deformity of the wrist & fingers**

### **VOLKMANN'S ISCHEMIA**

- **Early complication of supracondylar fracture.**
- Ischemic injury to the muscles and nerves of the **flexor compartment** of the fore arm.
- **D/t occlusion of brachial artery.**
- Tissue pressure readings **within 30 mm Hg of the patient's diastolic blood pressure**(perfusion pressure
- Muscles supplied by **anterior interosseus artery are most susceptible**, as it is an end artery.
- **Most commonly affected muscle: flexor pollicis longus & medial half of flexor digitorum profundus.**
- **Median nerve is most commonly involved.**
- Treatment: fasciotomy

## 48. All are true about supracondylar fracture of humerus except:

- a) Posterior shift of distal fragment
- b) Median nerve is most common nerve damaged
- c) Injury of brachial artery may occur
- d) Common in elderly
- e) Volkmann's ischemic contracture may occur

Correct Answer - D

**Ans. d. Common in elderly**

**Supracondylar Fracture of the Humerus:**

**Complications :**

- Immediate- injury to brachial artery & injury to nerve (median nerve- most common, radial nerve-sometime affected)
- Early- Volkmann's ischemia
- Late complication- Malunion(cubitus varus deformity), myositis ossificans & Volkmann\ ischemic contracture .
- Displacement: The distal fragment may be displaced in the following direction
  - Posterior or backward shift
  - Posterior or backward tilt
  - Proximal shift
  - Medial or lateral shift
  - Medial tilt
  - Internal rotation

## 49. Not an Intra-articular fracture:

a) Rolando fracture

b) March fracture

c) Bennett's fracture

d) Barton's fracture

e) Hoffa fracture

Correct Answer - B

### **Ans. b. March fracture**

- March fracture: Fatigue fracture of shaft of second or third metatarsal
- Rolando fracture is a three part or comminuted intraarticular fracture-dislocation of the base of thumb.
- Pilon fracture: It is a communicated intra-articular fracture of the distal end of the tibia
- Bennett's fracture: It is an oblique intra-articular fracture of the base of the first metacarpal with subluxation of the trapezoid' metacarpal joint"
- Barton's fracture (Marginal fracture): Intra-articular fractures through the distal articular surface of the radius, taking a margin, anterior or posterior, of the distal radius with the carpals, displaced anteriorly or posteriorly
- Hoffa fractures are intra-articular and are characterised by a fracture in the coronal plane

## 50. True about Locking compression plate:

a) In steoporotic patients, it should not be used

b) Can be used as buttress plate

c) Usually cause perosteal injury

d) Mechanically superior to a conventional plate

e) Can not be used as compression plate

Correct Answer - B:D

**Ans. b. Can be used as buttress plate ; d. Mechanically superior to a conventional plate**

**Locking Compression Plate:**

- The latest development in plating technique is locking compression plate (LCP) .
- It has rigid plate, Screw construct, which has been found to be mechanically superior to conventional plate .
- LCP can be used as compression plate, as neutralization plate, as a buttress plate, as a bridging plate & as a locked plate .
- It is Particularly suitable for periarticular fractures & fractures in osteoporotic bones

## 51. Osteosclerotic metastases is/are common in cancer of:

a) Prostate

b) Breast

c) Lung

d) Malignant melanoma

e) Renal cell carcinoma

Correct Answer - A:B

**Ans. a. Prostate; b. Breast**

- Metastases are most commonly seen in the pelvis, ribs, vertebral bodies, and proximal limbs.
- These lesions typically have a lytic appearance on plain radiographs, although breast and prostate metastases can be sclerotic or mixed with lytic and sclerotic features.
- Overall, metastases are the most common tumor of bones.
- **Adults:** Approximately 75% of metastases to the bone are derived from prostate, breast, kidney, and lung carcinomas.
- **Children:** Neuroblastoma, Wilms tumor, osteosarcoma, and Ewing sarcoma.
- Kidney and thyroid neoplasms are known for producing a solitary metastasis.
- Metastases to hand and foot bones are uncommon and, if present, the source is usually a lung, colon, or renal neoplasm.

## 52. Following are immediate complications of fracture:

a) Vascular ischemia

b) Neuronal injury

c) Malunion

d) Compartment syndrome

e) Avascular necrosis

Correct Answer - A:B

**Ans. a. Vascular ischemia ; b. Neuronal injury**

**Immediate Complications:**

**Systemic:**

- Hypovolaemic shock
- Local
- Injury to major vessels
- Injury to muscles & tendon
- Injury to joints
- Injury to viscera

**Early complications:**

**Systemic:**

- Hypovolaemic shock
- ARDS: Fat embolism syndrome
- DVT & Pulmonary embolism;
- Aseptic traumatic fever;
- Septicaemia;
- Crush syndrome
- Local

- Infection
- Compartment syndrome
- **Late complications:**
- **Imperfect union of fracture:**
- Delayed union; Non-union; Malunion; Cross union
- **Others:**
- Avascular necrosis; Shortening; Joint stiffness; Sudeck's dystrophy; Osteomyelitis; ischaemic contracture; Myositis ossificans; Osteoarthritis

**53. Which of the following cause malunion except:**

a) Open #

b) Infection

c) Bone grafting

d) Soft tissue interposition

e) Proper alignment of fracture

Correct Answer - C:E

**Ans. c. Bone grafting ; e. Proper alignment of fracture**

- Bone grafting is used in treatment of malunion
- Infection: Both biology & stability of bone healing are hampered by active infection

## 54. True about atypical CTEV

a) Foot is flexed downward

b) Sole crease are not found

c) Difficult to treat than typical variety

d) May occur due to neurological disorder

e) May be associated with Meningomyelocele

Correct Answer - A:C:D:E

**Ans. a. Foot is flexed downward; c. Difficult to treat than typical variety; d. May occur due to neurological disorder; e. May be associated with Meningomyelocele**

### **Atypical Idiopathic Clubfoot:**

- A short and fat or swollen foot.
- The big toe is short and points upward
- A crease runs across the bottom (sole) of the foot from side to side.
- There is a deep crease in the skin above the heel.
- The heel area is rigidly tilted inward.
- The foot is rigidly flexed downward and, the heel cord is very tight, wide, and long.
- The calf muscle is very small and bunched up under the back of the knee.

### **Causes of CTEV**

- CTEV may be either primary or secondary

#### **1. Primary or Idiopathic**

- It is the most common type of CTEV
- Foot deformity (CTEV) is the only manifestation, otherwise musculoskeletal system is normal.

#### **2. Secondary**

- CTEV is a local manifestation of a systemic syndrome.
- Causes are :-
  1. Neurological disorders & neural tube defects eg myelomeningocele, & spinal dysraphism
  2. Paralytic disorder (due to muscular imbalance) as polio, spina bifida, myelodysplasia, & Friedreich's ataxia
  3. Arthrogyposis multiplexa
  4. Larsen syndrome
  5. Freeman- Sheldon syndrome
  6. Diastrophic dwarfism
  7. Sacral agenesis, tibial deficiency, constriction rings & amniotic bands

**55. In young person most common cancer among following is:**

a) Giant cell

b) Osteosarcoma

c) Chondrosarcoma

d) Ewing sarcoma

e) All

Correct Answer - B

**Ans. b. Osteosarcoma**

- Osteosarcoma is the second most common tumour.
- These tumours occur b/w the ages of 15-25 years, constituting the commonest musculo-skeletal tumour at that age

## 56. All are true about septic arthritis except:

a) Staph. Aureus is most common causative organism

b) Common in children

c) Affect growth plate

d) E. coli is the commonest causative organism

e) Aspiration of joint fluid is used for diagnosis

Correct Answer - D

**Ans. d. E. coli is the commonest causative organism**

- It is more common in children & males
- Staphylococcus aureus is the commonest causative organism, other organism are strepto-pneumo & Gonococcus.
- Aspirate the joint & examine the fluid. A WBC & gram stain should be carried out immediately. Sample of fluid are also sent for full microbiological examination & tests for antibiotic sensitivity.

## 57. Features of fat embolism:

a) Bradycardia

b) Hypoxia

c) Hypotension

d) Tachypnoea

e) Petechial rash

Correct Answer - B:D:E

**Ans. b. Hypoxia ; d. Tachypnoea; e. Petechial rash**

**Fat embolism syndrome:**

- Tachycardia
- Slight rise of temperature
- Breathlessness
- Hypoxia from involvement of lung
- Tachypnoea
- Petechial rash
- Respiratory failure
- Drowsy
- Restless
- Coma

## 58. Straight leg raising test is/are positive in:

a) Spinal stenosis

b) Spinal abscess

c) Also called as Trendelenburg test

d) Prolapsed intervertebral disc

e) Sciatica

Correct Answer - D:E

**Ans. d. Prolapsed intervertebral disc; e. Sciatica**

- Pain & limitation of Straight leg raising (SLR) is a feature of prolapsed intervertebral disc when there is irritation or compression of one of the roots of the sciatic nerve.
- Straight leg raising test: This is a test to detect nerve root compression.

## 59. Which of the following is/are true about the gait in sensory deficit

a) Antalgic gait

b) Apraxia

c) Trendelenburg

d) Positive Romberg sign

e) Apraxia gait

Correct Answer - D

**Ans. d. Positive Romberg sign**

**In sensory ataxia the patient is able to maintain the upright position while the eyes are open, but when the eyes are closed he sways. This is a positive Romberg sign.**

**ABNORMAL GAIT:**

- Antalgic gait: occurs in painful conditions of the lower limb .
- Charlie-Chaplin gait: Occurs in tibial torsion.
- Circumduction gait: Occurs in hemiplegia
- Waddling gait: Occurs in bilateral congenital hip dislocation
- High stepping gait: Occurs in foot drop
- Scissoring gait: Occurs in cerebral palsy
- Stiff hip gait: Occurs in ankylosis of the hip
- Trendelenburg gait: Occurs in unstable hip due to congenital dislocation of hip, gluteus medius muscle weakness

## 60. True about Trichomonas vaginitis:

a) Important cause of recurrent abortion

b) T.vaginalis is a flagellated protozoa

c) Metronidazole is used for treatment

d) Strawberry cervix

e) Curdy discharge

Correct Answer - B:C:D

**Ans. b. T.vaginalis is a flagellated protozoa; c. Metronidazole is used for treatment; d. Strawberry cervix**

**Trichomonas vaginitis:**

- It is caused by trichomonas vaginalis, a pear-shaped unicellular flagellate protozoa
- On speculum examination, mucosa of the portio vaginalis part of cervix appear like strawberry
- Infection in genital tract may be responsible for sporadic spontaneous abortion but its relation to recurrent abortion is inconclusive.

## 61. All are true about Pott's spine except:

- a) Thoracic vertebrae T6-T8 is most commonly affected site
- b) Paradiscal is commonest variety
- c) Muscular rigidity & stiffness is common
- d) Posterior part of vertebrae is more affected than anterior part
- e) Back pain is the commonest Presenting symptom

Correct Answer - A:D

**Ans. a. Thoracic vertebrae T6-T8 is most commonly affected site; d. Posterior part of vertebrae is more affected than anterior part**

Tuberculosis (TB) of the spine (Pott's disease) is the most common site of bone infection in TB.

- The lower thoracic and upper lumbar vertebrae are the areas of the spine most often affected.
- Pott's disease results from haematogenous spread of tuberculosis from other sites, often pulmonary. The infection then spreads from two adjacent vertebrae into the adjoining disc space.
- If only one vertebra is affected, the disc is normal, but if two are involved the intervertebral disc, which is avascular, cannot receive nutrients and collapses (seen as narrowing of intervertebral space on X-rays)
- Commonest spine involved in spine TB is Thoracolumbar/Dorsolumbar T12-L1 (Lower thoracic to be precise. **The disease progresses slowly. Signs and symptoms include:**
- Localised back pain is the earliest and commonest complaint
- Paravertebral swelling may be seen
- Neurological signs may occur, leading to paraplegia.

- Stiffness
- Deformity
- Constitutional symptoms

**Diagnosis:**

- Spinal X-ray may not show early disease as 50% of bone mass must be lost for changes to be visible on x-ray. However, plain radiographs can show vertebral destruction and narrowed disc space.
- MRI is useful to demonstrate the extent of spinal compression and can show changes at an earlier stage than plain radiographs. Bone elements visible within the swelling, or abscesses, are strongly indicative of Pott's disease as opposed to malignancy.
- CT scans and nuclear bone scans can also be used.

## 62. True about Clubfoot:

a) Abduction offorefoot

b) Associated with breech presentation

c) Dennis-Brown splint used

d) Adductionofforefoot

e) Associated with spina bifida

Correct Answer - C:D:E

**Ans. c. Dennis-Brown splint used d. Adductionofforefoot e. Associated with spina bifida**

CTEV is the commonest and most important congenital deformity of the foot.

**The deformity consists of following elements :-**

1. Equinus, i.e. Plantar flexion at ankle joint (tibiotalar joint)
2. Inversion of foot at subtalar joint (talocalcaneal joint)
3. Forefoot adduction, at mid-tarsal joints, especially at talo-navicular joint.
4. Sometimes forefoot cavus, i.e. excessive arching of the foot at mid-tarsal joints.

**Treatment:**

- Tendon transfer :- Transfer of tibialis - anterior on the outer side of foot. This can be done only after 5 years.
- Dwyer osteotomy :- Medial open wedge osteotomy of calcaneum to correct heel varus.
- Gradual differential distraction :- In this an external fixator (JESS or Ilizarov) is applied and gradual correction of deformity
- > 10 years:- Triple arthrodesis (subtalar, calcaneo-cuboid, and talonavicularjoints)



### 63. True about Osteosarcoma:

a) Primary osteosarcoma is most commonly occur in age group of less than 20 yr

b) Periosteal reaction is present

c) Present as elevated soft tissue mass

d) Commonly associated with osteoid osteoma

e) Formation of bone by the tumor cells is characteristic

Correct Answer - A:B:C:E

**Ans. a. Primary osteosarcoma is most commonly occur in age group of less than 20 yr; b. Periosteal reaction is present; c. Present as elevated soft tissue mass ; e. Formation of bone by the tumor cells is characteristic**

- Osteosarcoma is primary malignant bone tumor of bone, derived from primitive bone forming mesenchyma and characterized by osteoid formation.

**It is of two types**

- .. Primary
- ?. Secondary

**Associated feature:**

- Paget disease
- Radiation
- Fibrous dysplasia
- Enchondromatosis
- Multiple osteochondroma
- Bone infarction
- Chronic osteomyelitis

**Radiology:**

- The X-ray appearances are variable: hazy osteolytic areas may alternate with unusually dense osteoblastic areas.
- Often the cortex is breached and the tumour extends into the adjacent tissues; when this happens, streaks of new bone appear, radiating outwards from the cortex the so called 'sunburst' effect.
- Where the tumour emerges from the cortex, reactive new bone forms at the angles of periosteal elevation (Codman's triangle).
- While both the sunburst appearance and Codman's triangle are typical of osteosarcoma.

## 64. Commonest cause of acute osteomyelitis:

a) Trauma

b) Surgery

c) Fungal infection

d) Hematogenous route

e) Tubercularinfection

Correct Answer - D

**Ans. d. Hematogenous route**

### **ACUTE OSTEOMYELITIS:**

- 1. It Primary (hematogenous): - Organisms reach the bone through blood stream.
- 2. Secondary: - Organism gain entry directly through wound such as in compound fractures or surgical operation.
- Hematogenous osteomyelitis is the commonest form of osteomyelitis and most common source of bone and joint infection is hematogenous.

## 65. Distal interphalangeal joint involvement occur in:

a) Boutonniere deformity

b) Swan neck deformity

c) Mallet finger

d) Trigger finger

e) Dupuytren's contracture

Correct Answer - A:B:C

**Ans. a. Boutonniere deformity; b. Swan neck deformity; c. Mallet finger**

- In medicine, mallet finger, also baseball finger, dropped finger and (more generally) extensor tendon injury, is an injury of the extensor digitorum tendon of the fingers at the distal interphalangeal joint (DIP).
- **Swan-neck deformity** (PIP joints hyperextended and DIP joints flexed), enlarged knuckles, and subcutaneous nodules are classic clues for rheumatoid arthritis.
- Distal interphalangeal joint- Osteoarthritis, Psoriatic arthritis, Reactive arthritis
- Proximal interphalangeal joint- Osteoarthritis, RA, SLE, Psoriatic arthritis

## 66. Pathological fracture are found in:

a) Bone cyst

b) Osteoporosis

c) Chronic osteomyelitis

d) Osteochondroma

e) Osteogenesis imperfecta

Correct Answer - A:C:D:E

**Ans. a. Bone cyst; b. Osteoporosis; c. Chronic osteomyelitis; d. Osteochondroma; e. Osteogenesis imperfecta**

### **Pathological Fracture**

- A fracture in an abnormal bone is referred to as pathological fracture. Abnormal bone means a bone rendered weak by a disease localized to a particular bone, or by a generalised bone disorder. Bone that fractures spontaneously, or after trivial trauma must be regarded as abnormal until proven otherwise. Vertebral bodies (thoracic & lumbar) are the most often affected bones f/b neck femur & lower end radius (colle's #). Most common cause is osteoporosis

**Other causes of pathological fractures are:**

### **Localized Diseases**

- Chronic infection eg. tubercular & pyogenic
- osteomyelitis.
- Eosinophilic granuloma
- Benign neoplastic lesions
- Solitary bone cyst
- Aneurysmal bone cyst
- Fibrous cortical defect

- Monostotic fibrous dysplasia
- Chondromyxoid fibroma
- Chondroma (Enchondroma)
- Osteoclastoma (giant cell tumor)
- Malignant bone tumor
- Osteosarcoma
- Ewing's tumor
- Chondrosarcoma
- Atrophic bone due to
- Polio
- Radiation (Radiotherapy)
- **Generalised Diseases**
- Congenital/ Developmental
- Osteogenesis imperfecta
- Osteopetrosis
- Ollier's disease (multiple enchondromatosis /dyschondroplasia).
- Polyostotic fibrous dysplasia
- Histiocytosis X
- Gaucher's disease
- Acquired Disorders producing osteopenia
- Osteoporosis (most common cause)
- Osteomalacia
- Hyperparathyroidism
- Renal osteodystrophy
- Paget's disease
- Myeloma
- Other metabolic bone diseases
- Rickets
- Scurvy
- Disseminated malignancy in bones
- Multiple myeloma
- Myelomatosis
- Metastatic carcinoma

## 67. All are true about Slipped capital femoral epiphysis except:

a) Avascular necrosis may occur

b) Usually occur after 10 year of age

c) Obesity is a risk factor

d) Frog-leg lateral view is helpful

e) More common in girls

Correct Answer - E

**Ans. e. More common in girls**

### **SLIPPED FEMORAL CAPITAL EPIPHYSIS (SFCE)**

- Seen in adolescent children in age group of 13-15yrs
- Either overweight or sexually immature
- Presents with endocrinopathies
- Hypothyroidism
- Growth hormone excess
- CRF
- Craniopharyngioma
- Hypogonadism
- Klinefelter's syndrome may present as SFCE
- Treethowan's sign on x-ray
- USG or CT more sensitive in detecting early slip
- Tc 99 scan shows increased uptake
- Rx is prompt surgery

## 68. Fracture site of Monteggia fracture is

a) Proximal ulna

b) Distal end of radius

c) Distal radius

d) Dislocation of radial head

e) Lower radio-ulnar joint dislocation

Correct Answer - A:D

**Ans.a. Proximal ulna; d. Dislocation of radial head**

**Monteggia fracture-dislocations are classified by the Bado system**

- Bado type I injuries are characterized by a proximal ulnar fracture with anterior dislocation of the radial head. This is due to a forceful pronation injury of the forearm and is the most common type.
- Bado type II injuries are "reversed" Monteggia fracture-dislocation injuries.
- Here, there is posterior angulation of the ulnar fracture site and posterior dislocation of the radial head.
- Bado type III and IV are rare injuries.

## 69. True about osteoclastoma

a) Mostly malignant

b) Most common site- mandible & vertebrae

c) Recurrence is common after excision

d) Located at epiphysis

e) All

Correct Answer - C:D

**Ans. c. Recurrence is common after excision; d. Located at epiphysis**

### **Giant cell tumor (Osteoclastoma)**

- GCT is an osteolytic tumor arising from the epiphysis and is common between the age of 20-40 years.
- Though GCT is a benign tumor, it is locally very aggressive.
- Females are affected more than males.

### **Pathological features**

- The commonest sites are lower end of femur and upper end of tibia. Other common sites are lower end radius and upper end of humerus. It may also occur in the spine and sacrum.
- The tumor is encompassed by a fibrous capsule at periphery.
- The presence of tumor giant cells is the hallmark of this tumor.

### **Clinical features**

- Pain at the site of the tumour.
- Gradually increasing local swelling
- Pathological fractures may occur.
- "Eggshell-crackling" sensation on palpation.

### **Radiological features**

- GCT is one of the common cause of a solitary lytic lesion of the

bone. o The radiological features are : -

1. A solitary may be loculated, lytic lesion.
2. Eccentric location, often subchondral.
3. Expansion of the overlying cortex (expansile lesion).
4. 'Soap-bubble' appearance - The tumor is homogenously lytic with trabeculae of the remnants of bone traversing it, giving rise to a loculated appearance.
5. No calcification within the tumor.
6. None or minimal reactive sclerosis around the tumor.
7. Cortex may be thinned out, or perforated at places.
8. Tumour usually does not enter the adjacent joint.

## 70. True about fracture neck Talus:

a) Avascular necrosis of body is common complication

b) Lateral view X-ray is important for diagnosis

c) Displaced fracture require below knee plaster only

d) Displaced fracture require open reduction & internal fixation

e) All

Correct Answer - A:B:D

**Ans. a. Avascular necrosis of body is common complication; b. Lateral view X-ray is important for diagnosis; d. Displaced fracture require open reduction & internal fixation**

### **Fracture Talus (Neck)**

- Talus is the *major weight bearing structure* (the superior articular surface carries a greater load per unit area than any other bone in body), and it has a *vulnerable blood supply* and is a common site for *post traumatic ischemic necrosis*.
- The body of talus is supplied mainly by vessels which enter the talar neck from the tarsal canal. In fractures of the talar neck these vessels are divided; if the fracture is displaced the extraosseous plexus too may be damaged and *body of talus becomes ischemic*.
- Fracture of the talar neck is produced by *violent hyperextension* of ankle. Body of talus fracture is usually a *compression injury* due to *fall from height*.

### **Complications**

- Avascular necrosis of body is *most continuum* complication. The incidence varies with the severity of displacement: in type I < 10%, in type II - 40% , in type III >90%.
- Malunion predispose to osteoarthritis.

- Secondary **Osteoarthritis** of ankle and /or subtalar joint occurs some years after injury in over 50% of patients. There are several causes : articular damage d/t initial trauma, malunion, distortion of articular surface and AVN.

#### **Hawkins Classification**

Type I Undisplaced

Type II Displaced associated with dislocation of subtalar joint

Type III Displaced associated with dislocation at ankle as well as -  
at subtalar joint

Type IV Type 3 + Talonavicular - subluxation or dislocation

#### **Treatment**

- Below knee cast with *foot in plantar flexion* X 4 weeks Further plaster change will allow the foot to be brought up slowly to plantigrade Close / open reduction & internal fixation

## 71. Which of the following is/are not feature(s) of rheumatoid arthritis

a) Pannus formation in joint

b) Osteosclerosis osteoclastic activity in underlying bone

c) Erosion of cartilage

d) Osteophyte

e) Plasma cell infiltration of synovial stroma

Correct Answer - D

**Ans. d. Osteophyte**

**The characteristic histologic features include :**

- Infiltration of synovial stroma by dense perivascular inflammatory cells, consisting of B cells and CD4+ helper T, plasma cells and macrophages;
- Increased vascularity owing to vasodilation and angiogenesis, with superficial hemosiderin deposits;
- Aggregation of organizing fibrin covering portions of the synovium and floating in the joint space as rice bodies;
- Accumulation of neutrophils in the synovial fluid and along the surface of synovium but usually not deep in the synovial stroma;
- Osteoclastic activity in underlying bone, allowing the synovium to penetrate into the bone forming juxta-articular erosions, subchondral cysts, and osteoporosis;
- Pannus formation- Pannus is a mass of synovium and synovial stroma consisting of inflammatory cells granulation tissue, and fibroblasts, which grows over the articular cartilage and causes its erosion.



## 72. Carpal tunnel syndrome is associated with all except:

a) Dupuytren's contracture

b) Myxoedema

c) Idiopathic

d) Rheumatoid arthritis

e) Acromegaly

Correct Answer - A

**Ans. a. Dupuytren's contracture**

**Associated conditions that can lead to carpal tunnel syndrome are:**

1. Idiopathic (most common)
2. Pregnancy
3. Endocrine disorders
  - Hypothyroidism
  - Diabetes mellitus
  - Myxedema
  - Acromegaly
  - Hyperparathyroidism
4. Deposition disorders
  - Rheumatoid disorder
  - Gout
  - Rheumatic disorder
  - Amyloidosis
  - Sarcoidosis
  - Leukemia

- Chronic renal failure

**73. A 65 year old male presented with femur neck fracture. He was managed with closed reduction + cancellous screw. 6 month later X-ray was done in lateral view. X-ray shows non-union & leg shorting. Now, appropriate management options is/are:**

a) Unipolar hemiarthroplasty

b) Bipolar hemiarthroplasty

c) Subtrochanteric osteotomy

d) Osteosynthesis

e) Total hip arthroplasty

Correct Answer - A:B:E

**Ans. a. Unipolar hemiarthroplasty; b. Bipolar hemiarthroplasty; e. Total hip arthroplasty**

**In general, operations for ununited fractures of the femoral neck can be grouped into five general classes:**

- Osteosynthesis, in which a fracture is refixed with new internal fixation devices;
- Subtrochanteric osteotomy
- Prosthetic replacement (hemiarthroplasty)
- Total hip arthroplasty
- Arthrodesis.

**Some general guidelines are as follows:**

- In adults < 60 years old, nonunions in which the femoral head is viable can be treated by angulation osteotomy. This provides a line of weight bearing more directly beneath the femoral head.
- In children and in adults < 21 years old, nonunions in which the femoral head is not viable can be treated with an arthrodesis. In exceptional circumstances' a young adult may be treated with a prosthesis.
- In adults 21 to 60 years old, nonunions in which the femoral head is not viable can be treated with a prosthesis, a total hip arthroplasty, or an arthrodesis, depending on the circumstances in the given Patient and on the experience and preference of the surgeon. Rarely is an arthrodesis indicated in patients older than 50 years of age or in patients with a sedentary occupation.
- In patients > 60 years, non-union, regardless of the viability of the femoral head, usually are treated with a hemiarthroplasty or a total hip arthroplasty'