

1. In a patient with ileal resection, ileoc-coecal vales are spared. Which of the following can develop?

a) Bacterial overgrowth

b) Malabsorption

c) Steatorrhea

d) Cholelithiasis

e) Renal oxalate stones

Correct Answer - B:C:D:E

Answer- B, C, D, E

- Patients with short-bowel syndrome invariably present with a history of several intestinal resections.
- Malabsorption, diarrhea (with or without steatorrhea) is an almost constant clinical findings.
- Terminal ileum resection- watery diarrhea/ steatorrhea, malabsorbtion, megaloblastic anemia, oxalate kidney stones, cholesterol gall stones.

2. Alcohol is a risk factor for which of the following carcinoma(s)?

a) Esophagus

b) Liver

c) Pancreas

d) Cervix

e) Larynx

Correct Answer - A:B:C:D:E

Answer- A, B, C, D, E

- Alcohol most strongly increased the risk for cancers of the oral cavity, pharynx, esophagus and larynx.
- Significant increases in risk also existed for cancers of the stomach, colon, rectum, liver, female breast, and ovaries.
- Alcoholic women are at high risk for in situ and invasive cervical cancer and for cancer of the vagina.

3. True regarding esophageal squamous cell carcinoma is/ are?

a) Barrett's esophagus is a risk factor

b) Common in middle third of esophagus

c) Stomach, jejunum or colon can be used for replacement after surgical removal

d) Chemoradiation has little role in inoperable patients

e) Staging is done by CECT

Correct Answer - B:C:E

Answer- B, C, E

- "The stomach remains the most Preferred esophageal substitute following esophagectomy for cancer.
- Squamous cell carcinoma-**
- It is the most common type of esophageal carcinoma worldwide and in India. It usually occurs in middle 1/3rd (most common) and upper 1/3rd of esophagus. Some may also arise in lower 1/3rd.
- Important risk factors-**
- Plummer -Vinson- Paterson Kelly syndrome
 - Tylosis plamaris et plantaris
 - Human papilloma virus (HPV) infection
 - Flexible endoscopy with biopsy is the primary method for diagnosis of esophageal cancer.
 - CECT chest and abdomen and Positron emission tomography (PET) are one for staging of esophageal cancer.
 - Stomach, jejunum or colon can be used for replacement after

surgical removal

4. True regarding acute sialadenitis is/are?

a) Most common in submandibular glands

b) Most common type is viral

c) Can present with stasis of saliva

d) There may be tender pre-auricular nodes

e) Stone removal may be done by probing through oral route

Correct Answer - B:C:E

Answer- B, C, E, Most common type is viral, Can present with stasis of saliva, Stone removal may be done by probing through oral route

- Sialadenitis is most common in the parotid gland.
- The most common cause of acute inflammation of the salivary glands is mumps virus.
- Sialadenitis due to bacterial infections is most commonly caused by *Staphylococcus aureus*.
- Stone or a kink in the salivary duct can also diminish saliva flow/stasis of saliva.
- Surgical management-
- Abscesses require drainage
- Gland excision incases of recurrent acute sialadenitis.

5. True regarding chronic pancreatitis is/are?

a) Can present with steatorrhea and malabsorption

b) Presents with mid epigastric pain radiating to back

c) Markedly raised level of amylase & lipase

d) Predisposes to carcinoma

e) Complete pancreatectomy relieves pain in majority of patients

Correct Answer - A:B:D:E

Answer- A,Can present with steatorrhea and malabsorption

B,Presents with mid epigastric pain radiating to back

D,Predisposes to carcinoma E,Complete pancreatectomy relieves pain in majority of patients

Etiology

- Alcoholic pancreatitis - most common
- Hyperparathyroidism
- Hypertriglyceridemia
- Autoimmune

Clinical features-

- Abdominal pain is the most common presenting symptom.
- The patient experiences intermittent attacks of severe pain, often in the mid-abdomen or left upper abdomen and occasionally radiating in a bandlike fashion or localized to the midback.
- Chronic pancreatitis include maldigestion, malabsorption, diarrhea, bloating and weight loss. This may be due either to fear of eating or due to pancreatic exocrine insufficiency and steatorrhea & azotorrhea (protein malabsorption).

Serum enzymes-

- Serum amylase and lipase levels are normal or slightly elevated in

chronic pancreatitis.

- In later stage of chronic pancreatitis, atrophy of the pancreatic parenchyma results in normal serum enzyme levels because of fibrosis of the pancreas.

Treatment-

i) Pancreatic duct drainage

- In patients with a dilated pancreatic duct, a Roux-en-Y side-to-side pancreatico jejunostomy is indicated.

ii) Pancreatic resection-

- If the disease is limited to the head of the pancreas, a Whipple operation (pancreaticoduodenectomy) can produce good results.

6. q-SOFA score includes?

a) Pulse rate

b) Respiratory rate

c) Systolic blood pressure

d) Altered mentation

e) Mean arterial pressure

Correct Answer - B:C:D

Answer- B,Respiratory rate C,Systolic blood pressure D,Altered mentation

- It is a validated ICU mortality prediction score, to help identify patients with suspected infection that are at high risk for poor outcome (defined as in-hospital mortality, or ICU length of stay >3 days) outside of the ICU.
- The qSOFA simplifies the SOFA score drastically by only including its 3 clinical criteria.
- It is used in patients > 18 years old in a non-ICU setting (pre-hospital, ward, emergency department, step down unit) with **confirmed or suspected infection.**
- Low blood pressure - 1
- HIGH RESPIRATORY RATE - 1
- Altered mentation- 1

7. True regarding leg ulcers & their location is/are?

a) Arterial insufficiency - tip of the toes

b) Arterial insufficiency - medial side of leg [above medial malleolus]

c) Venous insufficiency - above lateral malleolus

d) Diabetic neuropathic ulcer - planter aspect of metatarsal head

e) Pressure ulcer - heel

Correct Answer - A:C:D:E

Answer- A, Arterial insufficiency - tip of the toes C, Venous insufficiency - above lateral malleolus D, Diabetic neuropathic ulcer - planter aspect of metatarsal head E, Pressure ulcer - heel

Venous ulcer-

- Located below the knee, most often on the inner part (medial) of the ankles. Those associated with lesser saphenous vein insufficiency may occur on outer side (lateral).
- Associated with aching, swollen lower legs that feel more comfortable when elevated.

Arterial ulcer-

- Usually found on the feet, heels or toes. Toes are affected most commonly especially tips.
- The borders of the ulcer appear as though they have been 'punched out'.
- Frequently painful, particularly at night in bed or when the legs are at rest and elevated.

Neurotrophic (diabetic) Ulcers-

- Neuropathic ulcers usually occur on the plantar aspect of the foot under the metatarsal heads or on the plantar aspects of the toes.

Pressure ulcer (pressure sore /decubitus ulcer)-

- The hip and buttock regions account for up to 70% of all pressure injuries, with ischial tuberosity, trochanteric, and sacral locations being most common.
- The lower extremities account for an additional 15-25% of all pressure injuries, with malleolar, heel, patellar, and pretibial locations being most common.

8. TRUE statement regarding hepatocellular carcinoma is/are?

a) Frequently associated with raised AFP

b) Good prognosis even without resection

c) Ultrasound guided biopsy is diagnostic

d) There is extensive vascular invasion

e) Most cases present with resectable tumor

Correct Answer - A:C:D

Answer- A,Frequently associated with raised AFP C,Ultrasound guided biopsy is diagnostic D, There is extensive vascular invasion

- It is the most common primary malignant tumor of liver.
 - Most important risk factor for HCC is HBV infection.
 - Risk factors are chronic alcoholism, food contaminants
- Clinical Features-**
- Hepatocellular carcinomas have a strong propensity for invasion of vascular channels. Extensive intrahepatic metastasis occurs and the tumour occasionally invades the portal vein or inferior vena cava.
 - Unresected hepatocellular carcinoma has a very poor prognosis.
 - The fibrolamellar variant of the HCC is associated with a more favorable prognosis.
- Diagnosis-**
- Liver Biopsy under US or CT guidance- The diagnosis can be established by percutaneous core biopsy or aspiration biopsy in most patients if the biopsy site is selected.
 - MRI is the investigation of choice.

- Serological markers
 - Elevated level of serum alphafetoproteins are seen in 50 - 75% cases.
- Treatment-**
- Only 15-20% of HCC are resectable because of multicentricity, bilobar involvement, portal vein invasion and lymphatic metastasis.

9. TRUE statement regarding pyogenic liver abscess is/ are?

a) More common on left side of liver

b) Surgical drainage is the treatment of choice

c) Most common organism responsible is E. coli

d) X-rays are diagnostic

e) Diagnosis is confirmed by aspiration and culture

Correct Answer - C:E

Answer- C, Most common organism responsible is E. coli E, Diagnosis is confirmed by aspiration and culture

- It can be multiloculated or a single cavity.
- It usually involves the right lobe (-75%)

Clinical features

- the classical description of hepatic abscess is - fever, jaundice and rt. upper quadrant pain; but this is rarely seen (-10% cases)
- most common presentation includes → fever with chills and abdominal pain (Fever is MC symptom)
- Nonspecific symptoms like malaise and anorexia are also seen

Laboratory investigations

- Abnormalities of LFTs are generally seen but are not severe.
- Alkaline phosphatase & transaminases are mildly elevated

Bilirubin is elevated

- Ultrasound and CT are the main diagnostic modalities.
- Diagnosis is confirmed by aspiration and culture.
- (Serology tests are helpful for diagnosing amoebic abscess not pyogenic liver abscess.)

- Treatment involves antibiotics and percutaneous catheter drainage

10. Poor prognosis of breast carcinoma is associated with?

a) Over expression of Her-2/neu

b) Increased estrogen & progesterone receptor expression

c) Triple negative tumor

d) < 2% cells in 'S' phase of mitosis

e) > 65% cells expressing Ki-67 marker

Correct Answer - A:C:E

Answer- A,Over expression of Her-2/neu C,Triple negative tumor E, > 65% cells expressing Ki-67 marker

- A diagnosis of triple negative breast cancer means that the three most common types of receptors i.e. estrogen receptors (ER), Progesterone receptors (PR), and the hormone epidermal growth factor receptor 2 (HER-2/neu gene) are not present in the tumor cells.
- This type of cancer is more common in women with BRCA1 gene mutations.

11. Luminal A breast cancer shows following feature?

a) Low grade tumor

b) Her2 /neu amplification

c) Good prognosis

d) High grade tumor

e) ER negative

Correct Answer - A:C

Answer- A,Low grade tumor C, Good prognosis

- Most common subtype.
- Low grade, Slow growing.
- Best prognosis of all subtypes
- Hormone-receptor (ER and/or PR) positive with high expression.
- HER2 negative/ low expression
- Low expression of the protein Ki-67

12. True regarding epidural hematoma is/are?

a) Arterial bleed

b) More dangerous than subdural variety

c) On CT scan it gives biconvex lenticular hyperdense appearance

d) Located on lateral side of hemisphere

e) Common after Injury at pterion

Correct Answer - A:B:C:D:E

Answer- A,Arterial bleed B,More dangerous than subdural variety C,On CT scan it gives biconvex lenticular hyperdense appearance D,Located on lateral side of hemisphere E,Common after Injury at pterion

- Epidural hematoma brain injuries (also referred to as extradural hemorrhages) involve blood pooling between the outer membrane (the dura) and the skull.

Cause-

- Injury to middle meningeal artery.
- Accumulation of blood-
- b/w skull and dura

Location-

- lateral cerebral convexities

Clinical features-

- Classicalll lucid interval then coma, but more variable.
- Pupillary dilatation with contralateral then bilateral limb weakness.
- Slowly evolving stupor then coma

Radiological features-

- Biconvex (lens shaped or lenticular)
- In Acute cases → Hyperdense (2/3) or mixed density (1/3).

- In chronic cases → Hypodense
- **Surgical intervention-**
- Urgent evacuation

13. In acute abdomen examination signs which are elicited in supine position include?

a) Ilio-psoas sign

b) Obturator sign

c) Rovsing sign

d) Carnett sign

e) Balance sign

Correct Answer - A:B:C:D

Answer- A,Ilio-psoas sign B,Obturator sign C,Rovsing sign D,Carnett sign

Psoas sign(Cope's psoas test or Obratzsova's sign)-

- It indicates irritation to the iliopsoas group of hip flexors in the abdomen.
- It is elicited by performing the psoas test by passively extending the thigh of a patient lying on his side or supine with knees extended.
- A positive psoas sign on the right may suggest appendicitis.

Obturator Sign-

- The obturator sign is based on the same principle as the psoas sign, that stretching a pelvic muscle irritated by an inflamed appendix causes pain.
- To stretch the right obturator internus muscle and elicit the sign, the patient's right hip and knee and then internally rotates the right hip with a patient lying on his side or supine.

Rovsing's sign-

- The patient is said to have a positive Rovsing's sign and may have

appendicitis.

- It is done in supine position.

Carnett's sign-

- Carnett's sign is a finding on clinical examination in which (acute) abdominal pain remains unchanged or increases when the muscles of the abdominal wall are tensed.
- A supine patient can be asked to lift the head and shoulders from the examination table to tense the abdominal muscles.

Ballance sign-

- The presence of a dull percussion note in both flanks of a patient lying in the left decubitus position.

14. FALSE statement regarding urothelial bladder tumor is/are?

- a) Most common variety
- b) Schistosomiasis is not a risk factors
- c) Strongly related to smoking
- d) Pain is the most common presenting feature
- e) Most common site is trigone

Correct Answer - B:D

Answer- B,Schistosomiasis is not a risk factors D,Pain is the most common presenting feature

There are 3 types of bladder cancer-

1. Transitional cell cancer- (90%)
2. Squamous cell carcinoma (5-10%)
3. Adenocarcinoma (2%)

Risk factors-

- Cigarette smoking - it's the most common etiological factor
- Schistosoma haematobium - risk factor for both transitional cell carcinoma & SCC
- Drugs such as Phenacetin & chlorphenazine

Clinical features-

- Painless haematuria is the presenting feature in 85-90% of bladder cancer patients.
- Pain (secondary to clot retention, tumor extension into retro peritoneum or ureteral obstruction or metastasis in bony Pelvis) may rarely occur.

Site-

- Trisone and adjacent postero-lateral wall

15. TRUE regarding hypertrophic gastric polyp is/are?

a) Most common gastric polyp

b) Pre-malignant

c) Mostly non-Hodgkin's lymphoma

d) More common in young adults

e) Surgery is done if they are symptomatic

Correct Answer - A:E

Answer- A,Most common gastric polyp E,Surgery is done if they are symptomatic

They are the most common benign tumor of stomach.

Gastric polyps are of following types -

1) Hyperplastic polyp (75%)

- It is the most common gastric polyp. It is non neoplastic. It has no malignant potential.
- Hyperplastic polyps are also referred to as inflammatory polyps.

2) Adenomatous polyp (Adenoma)

- Adenoma contains proliferative dysplastic epithelium and thereby has malignant potential.

Treatment-

- Gastric polyps that are symptomatic > 2cm or adenomatous, should be removed.

16. True statement(s) regarding lymphedema is/are?

a) Can be complicated by cellulitis

b) Congenital lymphedema is also known as Millroy's disease

c) Commonly caused by Wuchereria bancrofti

d) Lymphoedema congenita more likely to be unilateral

e) Lymphedema precox is more common in males

Correct Answer - A:B:C

Answer- A,Can be complicated by cellulitis B,Congenital lymphedema is also known as Millroy's disease C,Commonly caused by Wuchereria bancrofti

Lymphedema is an interstitial edema of lymphatic origin.

Types-

A. Primary lymphedema-

1) Congenital lymphedema-

- More likely to be bilateral and involve whole leg.
- Familial version of congenital lymphedema is called Milroy's disease.

2) Lymphedema precox-

- Most common form of primary lymphedema (90%).
- Familial version is known as Meige's disease.

B. Secondary lymphedema

- Common organisms causing lymphatic filariasis including Wuchereria bancrofti, Brugia malayi, Brugia timori.
- The most common manifestation of lymphedema is edema.

Complications-

- It can result in chronic eczema, dermatophytosis, onychomycosis,

cellulitis, lymphangitis, lymphadenitis and in severe cases skin ulcers.

17. Steps taken to prevent post-operative incised wound infection is/are?

a) Start antibiotics at least 1 day pre-operatively

b) Shaving of hair

c) One dose of antibiotic just before the incision

d) Shower preoperatively using an antiseptic

e) Prevent intraoperative hypothermia

Correct Answer - C:D:E

Answer- C,One dose of antibiotic just before the incision D,Shower preoperatively using an antiseptic E,Prevent intraoperative hypothermia

- They are defined as infections that occur 30 days after surgery with no implant, or within 1 year if an implant is placed and infection appears to be related to surgery.
- Most SSIs are caused by endogenous microorganisms present on the patient's skin when the surgical incision is made.
- Gram positive bacteria such as Staphylococcus aureus are the most common causative skin-dwelling microorganisms.
- Exogenous sources of microorganisms include surgical instruments, operating room surfaces, the air, and personnel.
- Hair removal was once theorized to reduce the risk of post-operative infection is actually associated with increased incidence of SSI.

Prevention strategies-

Preoperative:

- .. Tobacco cessation at least 30 days prior to elective surgery
- ?. Antimicrobial prophylaxis

- Antimicrobial prophylaxis should be administered only for Class I (clean wound) and II wounds (clean/contaminated wound). Patients with Class III (contaminated wound) or IV wounds (Dirty wound) are presumed to be taking antimicrobial therapy already.

c) Preoperative showering with chlorhexidine gluconate 4% solution the night before surgery.

Appropriate timing of administration:

30 to 60 minutes prior to incision

- 1 -2 hours for antibiotics with longer periods of infusion, such as vancomycin.

Perioperative techniques

- Prevent intraoperative hypothermia

Treatment-

- For superficial SSI this involves opening the wound at skin and subcutaneous level and clearing the wound.

18. True regarding opsite dressing is/are?

a) Wound can be seen

b) Vapor permeable

c) Impermeable to bacteria

d) Water permeable

e) Increased chances of maceration

Correct Answer - A:B:C

Answer- A,Wound can be seen B,Vapor permeable C,Impermeable to bacteria

OPSITE post-op dressing

- It is a transparent adhesive film. The film is moisture vapor permeable.
- OPSITE helps prevent skin maceration.
- OPSITE is resistant to water and body fluids (waterproof).
- It also acts as barrier to bacteria including MRSA.
- Allow constant monitoring on the wound and peri-wound area as wound can be seen.

19. True statement (s) regarding spigelian hernia is/are?

a) Protrudes through linea alba

b) Occurs at the termination of transverse abdominis muscle

c) Occurs at the lateral edge of rectus abdominis muscle

d) Contents of hernia mostly include small intestine

e) Surgery is the treatment of choice

Correct Answer - C:D:E

Answer- C,Occurs at the lateral edge of rectus abdominis muscle D,Contents of hernia mostly include small intestine E,Surgery is the treatment of choice

- Spigelian hernias occur secondary to a defect in the transversus abdominis muscle and rectus sheath aponeurosis.
 - Spigelian hernia contents most often includes small intestine but can also include cecum appendix, sigmoid colon or omentum.
 - Spigelian hernia (or lateral ventral hernia)
 - A spigelian hernia is a hernia through the spigelian fascia close to the level of the arcuate line.
 - Spigelian fascia is the aponeurotic layer between the rectus abdominis muscle medially and the semilunar line laterally.
- Treatment-**
- Once a hernia appears, surgical treatment is the only way to repair it.

20. TRUE regarding 2nd degree superficial burn is/are?

a) Very painful

b) Dry eschar formation

c) No spontaneous healing

d) Blister formation

e) Capillary refilling present

Correct Answer - A:D:E

Answer- A,Very painful D,Blister formation E,Capillary refilling present

Superficial 2nd degree burn (Superficial partial thickness burn)

- Involves only upper dermal layer
- Blister formation occurs
- Erythematous
- Blanch on touch
- Quite painful.
- Heal without scarring in 1- 2 weeks

21. Diagnostic criteria for blood stream infection from central venous catheter includes all except?

- a) Colony count from catheter culture is 5 times more than peripheral blood culture
- b) Blood culture from catheter shows colony formation at least 2 hours before the peripheral blood culture
- c) Quantitative catheter tip culture showing $>10^3$ CFU/ catheter segment whereby the same organism [species and antibiogram] is isolated from the catheter segment and a peripheral blood sample
- d) Apparent source of blood stream infection present
- e) At least one positive peripheral blood culture

Correct Answer - D

Answer- D. Apparent source of blood stream infection present

- It is defined as the presence of bacteremia originating from an intravenous catheter.
- The most common cause of nosocomial bacteremia.
- **Laboratory diagnosis-**
- CRBSI means a patient with an intravascular catheter has at least one positive blood culture obtained from a peripheral vein, clinical manifestations of infections.
- **Long-term catheters-**
- Semi-quantitative growth of 15 cfu/catheter segment of the same microbe from both the insertion site culture, and the catheter hub culture strongly suggests that the catheter is the source of a

bloodstream infection.

22. A patient with history of trauma, presented with multiple fracture/bilateral femoral fracture, respiratory distress & red urine. For evaluation of patient all the following are included in major criteria of Gurd's criteria except?

a) Unexplained decrease in platelets

b) Tachycardia

c) Petechiae

d) CNS depression

e) Pulmonary edema

Correct Answer - A:B

Answer- A,Unexplained decrease in platelets B,Tachycardia

- Gurd's criterion is for the diagnosis of fat embolism syndrome.
- Gurd and Wilson's criteria for FES-
- Axillary & subconjunctival petechiae
- Hypoxemia
- Central nervous system depression
- Pulmonary edema

23. In classification of contaminated wound, which of the following are included?

a) Resection of unprepared bowel

b) Perforated appendix resection

c) Resection of intestinal fistula

d) Inguinal hernia repair

e) Hysterectomy

Correct Answer - A:B

Answer- A,Resection of unprepared bowel B,Perforated appendix resection

Class III (contaminated)-

- Open, fresh accidental wounds. In addition, operations with major breaks in sterile technique (e.g., open cardiac massage) or gross spillage from the gastrointestinal tract, and incisions in which acute, nonpurulent inflammation is encountered.
- Examples: Appendectomy (with perforation/ peritonitis) Bowel Resection (unprepared), bile spillage.

24. True about compression stocking are:

a) Worn even after ulcer heals to prevent recurrence

b) Worn in morning & taken off at night before bedtime

c) Compression occurs maximum at calf

d) Worn only at edema sites

e) Provide calf pump

Correct Answer - A:B:E

Answer- A,Worn even after ulcer heals to prevent recurrence B,Worn in morning & taken off at night before bedtime E,Provide calf pump

- These are specialized elastic hosiery designed to help prevent the occurrence of and guard against further progression of, venous disorders such as edema, phlebitis and thrombosis.
- They also aid in the treatment & prevention of ulcers of the lower legs.
- Compression stockings are tightest at the ankles and gradually become less constrictive toward the knees and thighs. Therefore the compression level is highest around the ankle and lessens towards the top of the hose.
- Stockings are best applied upon waking before the person has got out of bed.

25. Ulcerative colitis true statement is/are?

a) No skip lesion

b) Almost always includes rectum

c) Can present with pain & bloody diarrhea

d) More common in smokers

e) Transmural involvement

Correct Answer - A:B:C

Answer- A,No skip lesion B,Almost always includes rectum C,Can present with pain & bloody diarrhea

26. Indications of hemorrhoidectomy in hemorrhoids include?

a) Large first & second degree hemorrhoids

b) Third & fourth degree hemorrhoids

c) If not able to differentiate prolapsed hemorrhoids & lower rectal prolapse

d) Complicated by strangulations

e) Failure of conservative therapy

Correct Answer - B:D:E

Answer- B,Third & fourth degree hemorrhoids D,Complicated by strangulations E,Failure of conservative therapy

Operative hemorrhoidectomy (excisional hemorrhoidectomy)-

- 3rd & 4th degree: hemorrhoids
- Other degree not cured by conservative methods
- Mixed (combined internal/external) hemorrhoids
- Hemorrhoids complicated by strangulation

27. Sterile OT zone is?

a) Changing room

b) Scrub room

c) Set up room

d) Cleaner room and stores

e) Anaesthesia inducing room

Correct Answer - B:C:E

Answer- B,Scrub room C,Set up room E,Anaesthesia inducing room

- Zone- 3 (Sterile area)
- Operating Theatre
- Scrub Room
- Anaesthesia Room
- Set up Room

28. True about Phylloides tumor is/are?

a) Associated with BRCA 1

b) FNAC can diagnose reliability

c) Treated with mastectomy

d) Axillary lymph nodes are commonly involved

e) Associated with BRCA 2

Correct Answer - C:E

Answer- C,Treated with mastectomy E,Associated with BRCA 2

- It is a rare, predominantly benign tumor that occurs almost exclusively in the female breast. Phyllodes tumor is the most
- commonly occurring nonepithelial neoplasm of the breast.
- Large tumor - simple mastectomy is done

29. Metabolic abnormality seen in congenital hypertrophic pyloric stenosis is?

a) Hypochloremic hypokalemic metabolic alkalosis

b) Hyperchloremic hypokalemic metabolic alkalosis

c) Hypochloremic hypokalemic metabolic acidosis

d) Hyperchloremic hypokalemic metabolic acidosis

e) None

Correct Answer - A

Answer- A. Hypochloremic hypokalemic metabolic alkalosis

- Projectile nonbilious vomiting is the initial symptom of pyloric stenosis. The vomiting usually starts after 3 weeks of age, but symptoms may develop as early as the 1st week of life and as late as the 5 months of life.
- Hypochloremic hypokalemic metabolic alkalosis.

30. Congenital hypertrophic pyloric stenosis causes

a) Bilious vomiting

b) Non bilious vomiting

c) Projectile vomiting

d) Non projectile vomiting

e) None

Correct Answer - B:C

Answer- B,Non bilious vomiting C. Projectile vomiting

- The vomiting may or may not be projectile, however non-bilious vomiting after feed is the characteristic feature.
- In about 10-15% of infants vomitus may contain blood. This bleeding is due to reflux esophagitis, a common association with hypertrophic pyloric stenosis.
- Also know Associated anomalies occur in 6-20% of pts. This includes esophageal atresia, Hirshprung's disease, anorectal anomalies, and intestinal malrotation.

31. Most common post-operative complaint is/are?

a) Pain

b) Nausea

c) Vomiting

d) Sedation

e) Shivering

Correct Answer - A:B:C

Answer- A,Pain B,Nausea C,Vomiting

- Nausea and vomiting episodes still persist as the most common complaint.
- Post-operative nausea and vomiting (PONV) is a common complication of surgery and anaesthesia
- Soreness in the throat if the patient needs artificial ventilation.
- Soreness and swelling around the incision site.

32. False about abdominal artery aneurysm (AAA) is:

a) Surgery is indicated when AAA > 6 cm

b) 90% of AAA is present below renal artery

c) Mortality rate after surgery is > 25%

d) Commonly causes colon ischemia

e) Most common cause is atherosclerosis

Correct Answer - A:C:D

Answer- A,Surgery is indicated when AAA > 6 cm C,Mortality rate after surgery is > 25% D,Commonly causes colon ischemia

- It is the most common true arterial aneurysm.
- Most common site (85-90%) is infrarenal.

Etiology-

- Atherosclerosis is the most common cause.
- Non-specific aorto-arteritis:- the 2nd most common cause.
- The 5 year risk of rupture of aneurysm of < 5 cm is 1 to 2%, where as it is 20-40% for aneurysm > 5cm.

- Investigation

IOC is CECT

Management-

- Operative repair of the aneurysm with insertion of prosthetic graft or aortic stent graft is indicated for-
- For asymptomatic aneurysms AAA repair is indicated if size > 5.5 cms.
- In elective surgery of AAA the operative mortality rate approximates about 1-2% whereas after acute rupture the mortality rate of

emergency surgery generally approximate about 45-50%.

Complications-

- Death (1.8-5% mortality for elective open repair <1% for endovascular repair and 50% if the AAA has ruptured)
- Colon ischemia is 1% for elective repair 15-20% if the AAA has ruptured

33. Hypoparathyroidism can occur in:

a) After thyroid surgery

b) Digeorge syndrome

c) Radical resection of head & neck cancer

d) MEN I

e) All

Correct Answer - A:B:C

**Answer- A,After thyroid surgery B,Digeorge syndrome C,Radical resection of head & neck cancer
Genetic disorders (eg: DeGeorge syndrome)**

- . Abnormal parathyroid gland development
- . Abnormal PTH synthesis
- o Activating mutations of calcium sensing receptor (autosomal dominant hypocalcemia or sporadic isolated hypoparathyroidism)
- . Post-surgical (thyroidectomy parathyroidectomy radical neck dissection)
- o Autoimmune polyglandular syndrome

34. True regarding 10-0 sutures is/are?

a) Thicker than 1-0 sutures

b) Synthetic sutures

c) Diameter is 0.9 mm

d) Stronger than 1-0

e) All of the above

Correct Answer - B

Answer- B. Synthetic sutures

- The larger the size ascribed to the suture, the smaller the diameter be.
- 10-0 sutures- 0.2 (0.020-0.029)

35. True about abdominal aortic aneurysm-

a) Most common below renal artery

b) May presents as pulsatile abdominal mass

c) Atherosclerosis is most common cause

d) For asymptomatic aneurysms repair is indicated if the diameter is >4 cm

e) None

Correct Answer - A:B:C

Answer- A, B, C, Most common below renal artery, (B) May presents as pulsatile abdominal mass (C) Atherosclerosis is most common cause

- 90% of abdominal aortic aneurysm (AAA) of size > 4cm in diameter is due to atherosclerosis.
- Male are more frequently affected than female.
- The aneurysm most commonly arises below the level of renal artery.
- It is usually detected on routine examination as a palpable, pulsatile, expansile, and non tender mass.

36. True about postoperative ileus:

a) Colon recovers earlier than small intestine

b) Small intestine most commonly affected

c) Adhesion is most common cause

d) Usually resolves within 48-72 hour

e) Radiographs show diffusely dilated bowel with air in the colon and rectum

Correct Answer - D:E

Answer- D,Usually resolves within 48-72 hour E,Radiographs show diffusely dilated bowel with air in the colon and rectum

- Ileus that occurs immediately after surgery in the absence of precipitating factors and resolves within 2 to 4 days is referred to as primary or postoperative ileus.
- Postoperative ileus affects the stomach and colon primarily.
- After laparotomy, small bowel motility returns within several hours, gastric motility within 24 to 48 hours, and colonic motility in 48 to 72 hours.
- Abdominal radiographs reveal diffusely dilated bowel throughout the intestinal tract with air in the colon and rectum.

37. True about secondary bacterial peritonitis-

a) Marked leukocytosis with left shift of the WBCs to band forms

b) Usually caused by polymicrobial infection

c) May be associated with appendicular perforation

d) Associated with cirrhosis of the liver

e) None

Correct Answer - A:B:C

Answer- A,Marked leukocytosis with left... B,Usually caused by polymicrobial ... C,May be associated with...

- Secondary peritonitis develops when bacteria contaminate the peritoneum as a result of spillage from an Intraabdominal viscus
- Patients are febrile, with marked leukocytosis and a left shift of the WBCs to band forms.
- Peritoneal infection is usually caused by two or more bacterial strains.

38. Correct statement about intestinal ischemia:

a) Watershed zones are usually affected

b) Arterial ischemic lesion has better demarcation than ischemia caused by impaired venous drainage

c) Crypts may be hyperproliferative

d) Microscopic examination may show coagulative necrosis of the muscularis propria

e) Surface epithelium is normal

Correct Answer - A:B:C:D

Answer- A Watershed zones..., B, Arterial ischemic lesion has better... C, Crypts may be hyperproliferative D, Microscopic examination...

Intestinal responses to ischemia occur in two phases-

1. The initial hypoxic injury occurs at the onset of vascular compromise.
 2. Reperfusion injury, is initiated by restoration of the blood supply and it is at this time that the greatest damage occurs.
- Colon is the most common site of gastrointestinal ischemia, mucosal and mural infarction may involve any level of the gut from stomach to anus.
 - There is coagulative necrosis of the muscularis propria within 2 to 4 days, and perforation may occur.
 - Microscopic examination of ischemic intestine demonstrates the characteristic atrophy or sloughing of surface epithelium.
 - Crypts may be hyperproliferative.

39. True about Colorectal cancer:

a) Right side cancer usually presents with obstructive symptoms

b) May be associated with HNPCC

c) Left-sided cancer presents with alteration in bowel habit

d) Left side colon is more commonly involved

e) All

Correct Answer - B:C:D

Answer- B,May be associated with HNPCC C,Left-sided cancer presents with alteration in bowel habit D,Left side colon is more commonly involved

- Tumors of the left side of the colon which are far more common.It usually present with a change in bowel habit or rectal
- bleeding, while more proximal lesions typically present later with iron deficiency anaemia or a mass.
- Hereditary Nonpolyposis Colon Cancer (Lynch's Syndrome): It is characterized by the development of colorectal carcinoma at an early age.
- Tumors of the left colon can gradually occlude the lumen, causing changes in bowel habits with alternating constipation and increased frequency of defecation.

40. True about thyroid cancer:

a) Follicular cancer is more common in radiation exposed patient

b) Harthle cell carcinoma has better prognosis than follicular cancer

c) Follicular cancer have better prognosis than pupillary cancer

d) Insular variant of papillary carcinoma has better prognosis than papillary cancer

e) Medullary carcinoma is associated with MEN-2b

Correct Answer - E

Answer- E, Medullary carcinoma is associated with MEN-2b

- Medullary thyroid carcinoma in MEN 2B develops earlier and is more aggressive than in MEN 2A.
- Papillary Carcinomas are the most common form of thyroid Cancer.
- Harthle cell carcinoma may have a worse clinical prognosis.

41. True about Schatzki ring:

a) Contain true esophageal muscle

b) Concentric symmetric narrowing of lower esophagus

c) Consists of esophageal mucosa above and gastric mucosa below

d) Dysphagia is usually to solid foods

e) Association with reflux disease

Correct Answer - B:C:D:E

**Answer-B,Concentric symmetric narrowing of lower esophagus
CConsists of esophageal mucosa above and gastric mucosa
below, D,Dysphagia is usually to solid foods E,Association with
reflux disease**

- Schatzki's ring is a thin submucosal circumferential ring in the distal oesophagus, usually at the squamocolumnar junction.
- It consists of esophageal mucosa above and gastric mucosa below.
- It does not have a component of true esophageal muscle the dysphagia is usually to solid foods only and comes on abruptly with nearly complete obstruction.
- There is a strong associatian wlth reflux disease.

42. True about intestinal type of gastric cancer-

a) Incidence decreased nowadays

b) Associated with H. pylori infection

c) More common in male than female

d) Better prognosis than diffuse

e) More common than diffuse type

Correct Answer - A:B:C:D

Answer- A,Incidence decreased nowadays B,Associated with H. pylori infection C,More common in male than female D,Better prognosis than diffuse

- "For unclear reason, the incidence and mortality rates for gastric cancer have decreased markedly during the past 65 years. Gastric cancer incidence has decreased worldwide but remains high in Japan, China, Chile and Ireland" - Harrison 16/e, p 524
- More common in women.
- The prognosis be less favourable.
- Intestinal metaplasia occurs due to persistent irritation of the gastric mucosa, most commonly from H. pylori infection.
- The Lauren system separates gastric adenocarcinoma into intestinal or diffuse types based on histology.

43. Most common post-operatives complaints of patients is/ are:

a) Pain

b) Nausea

c) Vomiting

d) Shivering

e) Sedation

Correct Answer - A:B:C

Answer- A, B, C, Pain (B) Nausea (C) Vomiting

- Nausea, vomiting and pain are most common post-op complications.

44. Correct statement about Intussusception in children is/ are all except-

a) Appendix is the most common leading point

b) Ileocolic is the most common site

c) Usually presents with pain without vomiting

d) Can be corrected by air and barium enema

e) Diagnosis is confirmed on abdominal ultrasound

Correct Answer - A:C

Answer- A,Appendix is the most common leading point C,Usually presents with pain without vomiting

- Most intussusceptions in children are seen from two months to two years of age intussusception is secondary to a pathological lead point, such as a Meckel's diverticulum, enteric duplication cyst or even a small bowel lymphoma.
- Classically, a previously healthy infant presents with colicky pain and vomiting.

45. Non-absorbable suture(s) is/are:

a) Silk

b) Catgut

c) Polypropylene

d) Polyester

e) Nylon

Correct Answer - A:C:D:E

Answer- A,Silk C,Polypropylene D,Polyester E,Nylon

- Non-absorbable sutures are:Silk,Linen,Surgical Steel,Linen,Polyester,Polybutester,Polypropylene,polyethylene, Nylon.

46. Correct statement about surgical site infection-

a) Can occurs due to environmental flora in OT

b) Superficial infection require re-surgical exploration of wound

c) Does not occur later than 14 days post-operative

d) Shaving is beneficial for prevention

e) Can occur even after 1 yr in case of implant left in situ

Correct Answer - A:B

Answer- A,Can occurs due to environmental flora in OT B,Superficial infection require re-surgical exploration of wound

- They can occur anytime from 0 to 30 days after the operation or up to 7 year after a procedure that has involved the implantation of a foreign material.
- Preoperative hair removal(clipping) should be done immediately before an oPeration.

47. Correct statement about electrocautery-

- a) In monopolar mode one electrode used at surgical field and second electrode is attached to patient plate
- b) Patient plate should have conductive jelly to ensure proper contact with body
- c) Burn may be seen at site of patient plate
- d) Cutting has more voltage than coagulation
- e) None

Correct Answer - A:B:C:D

Answer- A, B, C, D, In monopolar mode one electrode used at surgical field and second electrode is attached to patient plate (B) Patient plate should have conductive jelly to ensure proper contact with body (C)Burn may be seen at site of patient plate (D) Cutting has more voltage than coagulation

- High-frequency alternating current can be delivered in either unipolar or bipolar fashion.
- The unipolar (or monopolar) device is composed of a generator, an electrode for application, and an electrode for the returning current to complete the circuit.
- Complications of diathermy: Electrocutation, Explosionanl, Burns.

48. Regarding pre-operative antibiotic prophylaxis, which of the following statement(s) is/are correct:

a) Should be started 2 days before surgery

b) Should be given half an hour prior to surgery

c) Not needed in clean surgery

d) Should be given more than 1 hour before surgery

e) None

Correct Answer - B

Answer- B. Should be given half an hour prior to surgery

- "Antibiotic prophylaxis is indicated for most clean contaminated and contaminated.
- Antibiotics started as late as 7 to 2 hours after bacterial contamination are markedly less effective.

49. All are feature(s) of Beckwith-Wiedemann syndrome except:

a) Omphalocele

b) Macrosomia

c) Hyperglycemia

d) Visceromegaly

e) None

Correct Answer - C

Answer- C. Hyperglycemia

- Beckwith- Wiedemann syndrome is an overgrowth syndrome that is characterized by visceromegaly, macroglossia, macrosomia, omphalocele and hyperinsulinemic hypoglycemia.

50. Grade III (contaminated) wound is/ are-

a) Appendicular perforation

b) Wound contaminated with gross fecal material spillage

c) Wound in urinary tract without unusual contamination

d) Surgery over a clean site

e) Incision through abscess

Correct Answer - B

Answer- B. Wound contaminated with gross fecal material spillage

- Contaminated wounds (class III) include open accidental wounds encountered early after injury, those with extensive introduction of bacteria into a normally sterile area of the body due to major breaks in sterile technique (e.g., open cardiac massage), gross spillage of viscus contents such as from the intestine, or incision through inflamed, albeit nonpurulent tissue.

51. Feature(s) of Patterson Kelly syndrome:

a) Dysphagia

b) More common in male than female

c) Achlorhydria

d) Treatment consists of dilation of oesophagus by oesophageal bougies

e) All

Correct Answer - A:C:D

Answer- A, C, D, Dysphagia (C) Achlorhydria (D) Treatment consists of dilation of oesophagus by oesophageal bougies

- Classical features of this syndrome include dysphagia, iron deficiency anaemia, glossitis, angular stomatitis, koilonychia (spooning of nails) and achlorhydria.
- Affects females past 40 years
- Dilatation of the webbed area by oesophageal bougies

52. All of the following are true about prostate specific antigen except -

a) Normal level is 10-14 ng/ml

b) It may be elevated in BPH and Ca Prostate

c) It is produced by prostate

d) It is a glycoprotein

e) None

Correct Answer - A

Answer- A. Normal level is 10-14 ng/ml

- It is a glycoprotein produced only in the prostatic cells (both benign & malignant).
- Normal serum level → less than 4 ng/ ml
- 4- 10 ng/ml > this range is common for both BHP and Ca.
- More than 10 ng/ml → approx 75% will have cancer.

53. True about pyomyositis-

a) Staphylococcus aureus is the most common causative organism

b) Streptococcus pyogenes is the most common causative organism

c) Quadriceps is one of the most commonly affected muscle

d) Treatment involves drainage of abscess without antibiotic coverage

e) Best detected by MRI

Correct Answer - A:C:E

Answer- A, C, E, Staphylococcus aureus is the most common causative organism (C) Quadriceps is one of the most commonly affected muscle (E) Best detected by MRI

- Pyomyositis is an acute bacterial infection of the skeletal muscle caused by Staphylococcus aureus.
- It may be primary or secondary to a penetrating injury or contiguous anatomic infection.
- It typically affects the major muscles of the lower extremity and the gluteal muscles.
- Patients usually presents with pain, tenderness and edema of the involved muscle group.
- Abscess can develop in the muscle groups. Diagnosis is confirmed by needle aspiration or operative incision and drainage.
- Treatment involves adequate drainage along with antibiotic therapy against Staphylococcus aureus.
- Pyomyositis is characterized by a localized infectious process, conventional purulence, lack of surrounding tissue necrosis



54. True about testicular cancer-

a) Seminoma is more common than non-seminoma

b) Cryptorchidism is associated with seminoma

c) Retroperitoneal LN dissection is done for grade II testicular tumour

d) Usually presents as painless testicular lump

e) Seminomas metastasise mainly via haematogenous route

Correct Answer - A:B:C:D

Answer- A,Seminoma is more common... B,Cryptorchidism... C,Retroperitoneal LN dissection... D,Usually presents...

- Seminoma is the most common type of germ cell tumour.
- A major risk for the development of testicular cancer is cryptorchidism.
- Seminomas metastasise mainly via the lymphatics and haematogenous spread is uncommon.
- Usually the patient presents with a painless testicular lump.

55. True about obstructive jaundice-

a) Cholangiocarcinoma cause intermittent jaundice

b) Courvoisier law related to pancreatic head cancer

c) Cholangitis presents with fever and jaundice

d) Increase in urine urobilinogen

e) Increase in fecal urobilinogen

Correct Answer - B:C

Answer- B,Courvoisier law related to pancreatic head cancer C,Cholangitis presents with fever and jaundice

- examination often demonstrates clinical signs of jaundice, cachexia is often noticeable and a palpable gall bladder is present if the obstruction is in the distal common bile duct (Courvoisier's sign).
- Stone in CBD: Intermittent pain, intermittent fever and Intermittent jaundice are classical of stone in CBD.
- Cholangitis: The most common presentation is fever, epigastric or right upper quadrant pain, and jaundice and is known as Charcot's triad.
- Urine Urobilinogen : Absent
- Stools Sterocobilinogen- Absent

56. True statement regarding surviving sepsis guideline:

a) Activated protein C is useful

b) qSOFA should be assessed in case of prolong stay of patient in ICU

c) Suggest against the use of IV immunoglobulins in patients with sepsis

d) Recommend the use of erythropoietin for treatment of anemia associated with sepsis

e) Recommend empiric broad-spectrum therapy

Correct Answer - B:C:E

Answer- B,qSOFA should be assessed... C,Suggest against the use of IV ... E,Recommend empiric...

- Recombinant human activated protein C was completely omitted from the 2012 guidelines.
- "A higher SOFA score is associated with an increased probability of mortality.
- Patients with suspected infection who are likely to have a prolonged ICU stay or to die in the hospital can be promptly identified at the bedside with qSOFA.
- Recommend empiric broad-spectrum therapy with one or more antimicrobials for patients presenting with sepsis or septic shock to cover all likely pathogens.
- Against using IV hydrocortisone to treat septic shock patients if adequate fluid resuscitation and vasopressor therapy are able to restore hemodynamic stability.

- Recommend against the use of erythropoietin for treatment of anemia associated with sepsis.

57. True about management of peptic ulcer-

a) Vagotomy- decreases acid secretion

b) Early dumping syndrome occurs due to hypoglycaemia

c) Late dumping consists of abdominal and vasomotor symptoms

d) Billroth I gastrectomy has high rate of morbidity and mortality

e) Highly selective vagotomy has low incidence of side effects

Correct Answer - A:D:E

Answer- A,Vagotomy- decreases acid secretion D,Billroth I gastrectomy has high rate of morbidity and mortality E,Highly selective vagotomy has low incidence of side effects

- Highly selective vagotomy has most satisfactory operation for duodenal ulceration, with a low incidence of side effects.
- Billroth I carries with it the morbidity and mortality associated with any gastric resection
- In vagotomy, section of the vagus nerves, which are critically involved in the secretion of gastric acid., reduces the maximal acid output by approximately 50 Per cent.
- Early dumping consists of abdominal and vasomotor symptoms.
- Late dumping is reactive hypoglycaemia. The carbohydrate load in the small bowel causes a rise in the plasma glucose, which
- in turn, causes insulin levels to rise, causing a secondary hypoglycemia.

58. True about surgical occlusive dressing-

a) Maintain moisture in wound

b) Provides mechanical support

c) Prevents microbial entry

d) Wide Mesh is helpful

e) Used for highly exudative wounds

Correct Answer - A:B:C

Answer- A,Maintain moisture in wound B,Provides mechanical support C,Prevents microbial entry

Wound dressings can be categorized into four classes:

- nonadherent fabrics;
- absorptive dressings;
- occlusive dressings;
- creams,
- ointments and solutions
- "Occlusive dressing class provides moisture retention ,mechanial protection and a barrier to bacteria.
- Wide mesh gauze is composition of absorptive dressing.

59. Which of the following nipple discharge is most probably physiological-

a) B/L spontaneous discharge

b) B/L milky discharge with squeezing from multiple ducts

c) U/L bloody discharge

d) U/L bloody discharge with squeezing from a single duct

e) U/L spontaneous serous discharge

Correct Answer - B

Answer- B, B/L milky discharge with squeezing from multiple ducts

- Nipple discharge is classified as pathologic if it is spontaneous, unilateral, bloody, serous, clear, or associated with a mass.
- Physiological discharge is usually bilateral, involves multiple ducts, and is associated with nipple stimulation or breast compression.
- Unilateral, localized to a single duct.
- The most common cause of spontaneous nipple discharge from a single duct is a solitary intraductal papilloma.

60. A patient has Glasgow coma scale score - E1 VT M2. What is not required for his/her management:

a) Head end elevation

b) Total parenteral nutrition

c) Stress ulcer prophylaxis

d) Central line placement

e) None

Correct Answer - E

Answer- None

Domain	Response	Score
Eye openng	Spontaneous	4
	To speech	3
	To pain	2
	None	1
Best verbal response	Oriented	5
	Confused	4
	Inappropriate	3
	Incomprehensible	2
Best motor response	None	1
	Obeying	5
	Localizing	4
	Withdrawal	3
	Flexing	4
	Extending	4
	None	1

		6
		5
Total score	Deep come or death	4
	Fully alert and oriented	5
		3
		1

61. True about Bronchogenic cyst:

a) More common in anterior mediastinum than middle mediastinum

b) May have malignant potential

c) Produce symptoms which are usually compressive in nature

d) Air-fluid may be seen on chest X-ray

e) Mostly asymptomatic

Correct Answer - B:C:D:E

Answer- B, C, D, E, May have malignant potential (C) Produce symptoms which are usually compressive in nature (D) Air-fluid may be seen on chest X-ray (E) Mostly asymptomatic

- Bronchogenic cysts are the most common primary cysts of the anterior mediastinum.
- The diagnosis is confirmed by CT as a spherical fluid- or mucus filled nonenhancing mass. An air fluid level may be present on chest Xray.
- Two thirds of bronchogenic cysts are asymptomatic.
- Malignant degeneration has been reported.

62. True about Fat necrosis in women:

a) History of trauma can be elicited in >90% cases

b) More common in lactating women

c) Can be easily differentiated from malignancy on mammography

d) No malignant

e) None

Correct Answer - D:E

Answer- D,No malignant E,None

- Trauma is presumed to be the cause, though only about 50% of patients give a history of injury.
- Fat necrosis is a rare lesion of the breast.
- A carcinoma, even displaying skin tethering and nipple retraction, and biopsy is required for diagnosis.
- Fat necrosis can mimic cancer by producing a palpable mass or a density on mamnography that may contain calcifications.

63. Correct statement(s) about hypospadias is/are:

a) Urethral opening on ventral aspect

b) Chordae on dorsal aspect

c) May be associated with penile torsion

d) Proximal varieties are more common

e) Coupons spongiosum is deficient

Correct Answer - A:C

Answer- A, C, Urethral opening on ventral aspect (C) May be associated with penile torsion

- There is incomplete development of the prepuce, called a dorsal hood, in which the foreskin is on the sides and dorsal aspect of the penile shaft and absent ventrally.
- There is a variable degree of chordae (a ventral curvature of the penis most apparent on erection)
- "Penile torsion is a fairly common congenital (present from birth) condition that can affect any male infant.

64. True about omphalocele is all, EXCEPT:

a) Umbilical cord inserts into the sac

b) Incidence of approximately 1 in 5000 live births

c) Abdominal wall defect measures ≥ 4 cm in diameter

d) Viscera covered by peritoneum

e) None of the above

Correct Answer - E

Answer- E. None of the above

- Omphalocele refers to a congenital defect of the abdominal wall in which the bowel and solid viscera are covered by peritoneum and amniotic membrane.
- The umbilical cord inserts into the sac.
- The abdominal wall defect measures ≥ 4 cm in diameter. Omphalocele has an incidence of approximately 1 in 5000 live births.
- The abdominal viscera (commonly liver and bowel) are contained within a sac composed of peritoneum and amnion from which the umbilical cord arises at the apex and center.

65. Feature(s) of oesophageal atresia with trachea-oesophageal fistula :

a) Drooling of saliva

b) Associated with oligohydramnios

c) Nasogastric tube cannot pass into stomach

d) May be associated with VACTERL anomalies

e) Abdominal distension

Correct Answer - A:C:D:E

Answer- A, C, D, E, Drooling of saliva (C) Nasogastric tube cannot pass into stomach (D) May be associated with VACTERL anomalies (E) Abdominal distension

- Affected infants present soon after birth with drooling and cyanotic episodes on attempting to feed.
- There may have been polyhydramnios due to failure to swallow amniotic fluid.
- The diagnosis is confirmed when a nasogastric tube goes no further than the upper oesophageal pouch on the chest x-ray and abdominal gas signifies the tracheo-oesophageal fistula.
- The VACTERL association (vertebral, anorectal, cardiac, tracheoesophageal, renal, and limb anomalies) is present in 25% of cases.
- As the neonate coughs and cries, air is transmitted through the fistula into the stomach, resulting in abdominal distension.

66. True statement regarding surviving sepsis guideline:

a) Activated protein C is useful

b) qSOFA should be assessed in case of prolong stay of patient in ICU

c) Suggest against the use of IV immunoglobulins in patients with sepsis

d) Recommend the use of erythropoietin for treatment of anemia associated with sepsis

e) Recommend empiric broad-spectrum therapy

Correct Answer - B:C:E

Answer:(b) qSOFA should be assessed in..., (c) Suggest against the use of IV..., (e) Recommend empiric broad-...

[Ref: Harrison 19th/1758; www.foamcast.org/2017/01/19; jamanetwork.com/journal/Schwartz 9th/128-29]

67. Bilateral Hilar lymphadenopathy is seen in

-

a) Berylliosis

b) Silicosis

c) Amyloidosis

d) Occupational diseases

e) All

Correct Answer - A:B:D

Answer- (A) Berylliosis (B) Silicosis (D) Occupational diseases

- Occupational: Silicosis, coal worker, pneumoconiosis, Berylliosis
- TB (unilateral is more common)
- Castleman's disease
- Angioimmunoblastic lymphadenopathy
- Phenytoin therapy

68. Increased portal venous pressure is seen in

a) Budd chairi syndrome

b) Cirrhosis

c) Portal venous thrombosis

d) IVC obstruction

e) None

Correct Answer - A:B:C:D

Answer- A,Budd chairi syndrome B,Cirrhosis C,Portal venous thrombosis D,IVC obstruction

- MC cause of portal hypertension : Cirrhosis.
- Portal hypertension results in splenomegaly with enlarged, tortuous, and even aneurysmal splenic vessels.
- Most bleeding episodes occur during the first 1 to 2 years after identification of varices.
- Colour Doppler is the investigation of choice for evaluation of PHT.
- Splenic pulp pressure gives a measure of the portal vein pressure.

Posthepatic

- Budd-Chiari syndrome
- Inferior vena caval webs

Hepatic-

- Sinusoidal
- Cirrhosis
- Alcoholic hepatitis

69. Treatment of acute pancreatitis include(s)

-

a) Intravenous fluid

b) Early ERCP

c) NSAIDs

d) Nasogastric tube

e) Ochteride

Correct Answer - A:C:D

Answer- (A) Intravenous fluid (C) NSAIDs (D) Nasogastric tube

- Mainly conservative - fluid resuscitation, analgesics, antibiotics and anti-emetics
- No role for TPN(to rest the pancreas); for nutritional support – enteral (nasogastric) feeding
- In patients with severe acute gall stone pancreatitis and signs of ongoing biliary obstruction and cholangitis, an urgent ERCP should be performed
- In patients with cholangitis – sphincterotomy or a biliary stent
- Indications for surgery: deterioration despite conservative therapy, pancreatic abscess/necrosis.

70. Which of the following suture materials are not cleared by proteolytic enzymes

a) Catgut

b) Vicryl

c) Nylon

d) Polyglactin

e) Polyamide

Correct Answer - B:C:D:E

Anwer- B,Vicryl C,Nylon D,Polyglactin E,Polyamide

A) Natural

- Silk
- Linen
- Cotton

B) Synthetic

- Nylon
- Polypropylene
- Polybutest
- Braided polysters

71. Symptoms of mesenteric ischemia is /are -

a) Severe abdominal pain

b) Degree of tenderness is proportionate to abdominal pain

c) Nausea and vomiting

d) Diarrhea

e) Absent bowel sound

Correct Answer - A:C:D:E

**Answer- (A) Severe abdominal pain (C) Nausea and vomiting
(D) Diarrhea (E) Absent bowel sound**

- Ischaemia affecting the small intestine referred to as mesentric ischaemia.
- **Intestinal ischemia can be of two types-**
- Acute mesenteric ischemia (the common type)
- Chronic mesenteric ischemia
- C/F
- Severe abdominal pain, out ofproportion to the degree of tenderness on exarnination, is the hallmark ofacute mesenteric ischemia.
- Associated symptoms can include nausea, vomiting, and diarrhea.

72. Along with surgical treatment of glioblastoma multiforme, following drug is approved for its treatment

a) Cisplatin

b) Methotrexate

c) Cytarabin

d) Paclitaxel

e) Temozolomide

Correct Answer - A:E

Answer- A,Cisplatin E,Temozolomide

- Carmustine (BCNU)
- Cisplatin
- Bevacizumab (avastin)

73. Most common site of splenic implant in abdomen -

a) Stomach

b) Tail of pancreas

c) Peritoneal cavity

d) Suprarenal gland

e) None

Correct Answer - C

Answer- C. Peritoneal cavity

- Heterotopic splenic implant (splenosis) may occur in the peritoneal cavity, after splenic trauma or splenectomy.
- Splenosis is autotransplantation of splenic tissue after disruption of splenic capsule by trauma or surgery.
- Most common areas of implantation are peritoneum, omentum and mesentery.

74. Which of the following is not true

a) Reef knot is stronger than Granny knot

b) Granny knot is stronger than Reef knot

c) Reef knot is applied for tissue under pressure

d) Reef knot is stronger than Surgeon's knot

e) Reef knot is better than slip knot for bowel anastomosis

Correct Answer - B:D:E

Answer- B,Granny knot is stronger than Reef knot D,Reef knot is stronger than Surgeon's knot E,Reef knot is better than slip knot for bowel anastomosis

- Square knot is formed by wrapping the suture around the needle holder once in opposite direction between ties.
- Usually 3 ties are recommended.
- Square (Reef) knot is more stable than Granny knot - has less tendency to slip when subjected to increased pressure.
- It may be used to tie Surgical gut, virgin silk, surgical cotton and surgical stainless steel.

75. True about chest wall tumor is /are

a) Lipoma is the most common tumor

b) Fibrous dysplasia is a common skeletal sarcoma

c) Desmoid tumor is usually not malignant

d) Chondrosarcoma is the most common malignant tumor

e) Treated by surgical resection with wide surgical margins

Correct Answer - B:D:E

Answer- B,Fibrous dysplasia... D,Chondrosarcoma is the most... E,Treated by surgical resection...

- More than half of the chest wall tumors are malignant.
- **The most common benign chest wall tumors are:**
- Osteochondroma
- Chondroma
- Fibrous dysplasia
- Chondrosarcomas are the most common primary chest wall sarcoma and arise from the anterior tract of ribs and less commonly from the sternum, scapula, or clavicle.
- The most common soft-tissue primary malignant tumors are fibrosarcomas.
- Most chest wall tumors are treated with surgical resection and reconstruction.

76. True about lipoma is/are -

a) Most common benign tumor of adults

b) Multiple lipoma can occur and are called as Dercum's disease

c) Intramuscular lipoma may cause pain

d) Rarely may occur in brain

e) May show slip sign

Correct Answer - A:B:C:E

Answer- A,Most common benign tumor of adults B,Multiple lipoma can occur and are called as Dercum's disease C,Intramuscular lipoma may cause pain E,May show slip sign

- Lipoma is a benign tumor of mature adipose tissue,
- Lipoma is the most common benign tumor in adults.
- Common sites are subcutaneous tissue over the trunk, nape of the neck and limbs.
- Slip sign is positive : Lipoma tends to slip away from the examining finger on gentle pressure.
- Presence of multiple lipomas is known as lipomatosis and multiple lipomas are called Dercum's disease.
- Intramuscular lipoma may interfere with muscle function and causes pain on muscle action.

77. True about Abdominal compartment is /are -

a) Intraabdominal pressure > 15 mm Hg

b) Increased intracranial pressure

c) Decreased cardiac output

d) Hypoventilation

e) Renal failure and oliguria

Correct Answer - B:C:D:E

Answer- (B) Increased intracranial pressure (C) Decreased cardiac output (D) Hypoventilation (E) Renal failure and oliguria

- ACS is defined as an increase in intra- abdominal pressure (IAP) more than 20mm Hg associated with new organ failure/ dysfunction.

Physiological Consequences of Increased Infra-abdominal Pressure-

Decreased-

- Cardiac Output
- Central Venous Return
- Visceral blood flow
- Renal blood flow
- Glomerular filtration
- Increased
- Cardiac rate
- Pulmonary capillary wedge pressure
- Peak inspiratory pressure
- Intrapleural pressure
- Hypoventilation and alteration of ventilation/perfusion distribution

lead to hypoxemia and hypercapnia.

78. True regarding management of axillary lymph nodes in breast carcinoma

- a) All lymph-nodes are dissected
- b) Lymph node dissection is done in modified radical mastectomy
- c) Can be explored through the extended incision of breast
- d) Complete dissection is required if 2 sentinel lymph nodes are positive
- e) None

Correct Answer - B:C

Answer- B,Lymph node dissection is done in modified radical mastectomy C,Can be explored through the extended incision of breast

- All lymph nodes are not dissected in breast carcinoma, specially in stage I & II
- Lymph nodes are dissected in modified radical mastectomy
- Axilla can be explored through the vertical incision taken for breast
- Complete dissection is not required of 1 or 2 sentinel lymph nodes are positive in stage I & II

79. Level VI lymph nodes in neck -

a) Anterior compartment

b) Prelaryngeal

c) Submental

d) Nodes of upper mediastinum

e) Jugular nodes

Correct Answer - A:B

Answer- (A) Anterior compartment (B) Prelaryngeal

- Level VI
- Pretracheal
- Paratracheal
- Prelaryngeal

80. Inflammatory odontogenic cyst is/are

a) Periapical cyst

b) Residual cyst

c) Paradental cyst

d) Eruption cyst

e) Dentigerous cyst

Correct Answer - A:B:C

Answer- A,Periapical cyst B,Residual cyst C,Paradental cyst

- Residual cyst
- Paradental cyst
- Periapical ryst

81. True about blunt abdominal trauma -

- a) Liver is the most common organ affected
- b) Abdominal pelvic CT scanning is helpful for evaluating intra-abdominal and retroperitoneal injuries
- c) $> 100,000$ red cells/ μL in peritoneal lavage is considered positive and is indication for exploratory laparotomy
- d) More than 2m1 of free blood in the abdominal cavity is indication for exploratory laparotomy
- e) FAST-USG is used for initial evaluation

Correct Answer - A:C:E

Answer- (A) Liver is the most common organ affected (C) $> 100,000$ red cells/ μL in peritoneal lavage is considered positive and is indication for exploratory laparotomy (E) FAST-USG is used for initial evaluation

Blunt trauma: In blunt trauma the organs most commonly injured are the solid organs:

- Spleen (MC)
- Liver
- Kidney
- The presence of $> 100,000$ red cells/pl or >500 white cells/pl is deemed positive (this is equivalent to 20 mL of free blood in the abdominal cavity).
- Positive DPL is an indication for emergency exploratory laprotomy.
- Hemodynamically stable patients sustaining blunt trauma are adequately evaluated by abdominal ultrasound or CT.

**82. Most accurate method for the diagnosis
Gastroesophageal Reflux Disease (GERD)
is**

a) Histological study

b) Manometry

c) 24-hour pH recording and electrical impedance measurement

d) Barium swallow studies

e) Upper GI endoscopy

Correct Answer - C

Answer- C. 24-hour pH recording and electrical impedance measurement

- The most sensitive test for diagnosis of GERD is 24-h ambulatory pH monitoring.
- Endoscopy is indicated in patients with reflux symptoms refractory to antisecretory therapy; in those with alarming symptoms such as dysphagia, weight loss, or gastrointestinal bleeding; and in those with recurrent dyspepsia after treatment that is not clearly due to reflux on clinical grounds alone

83. True about neurogenic claudication -

a) Low back pain is present

b) Fixed walking distance

c) Pain immediately relieved by rest

d) Shiny skin of foot

e) Pain relieved by leaning forward

Correct Answer - A:C:E

Answer- (A) Low back pain is present (C) Pain immediately relieved by rest (E) Pain relieved by leaning forward

- Neurogenic claudication is characterized by low back pain radiating to lower limbs (gluteal region, back of thigh & leg).
- These symptoms are especially present when standing upright or walking and usually relieved with leaning forward or sitting down

84. All are true about bilateral breast cancer except

a) Bilaterality is common when the tumor in the primary breast is lobular carcinoma

b) About 5% bilateral cancers are synchronous and 20% bilateral cancers are metachronous

c) More common in women of >50 year of age

d) BRCA mutation cancers are associated higher prevalence of bilateral breast cancer

e) Usually b/1 if familial breast cancer present

Correct Answer - B:C

Answer- B,About 5% bilateral cancers are synchronous and 20% bilateral cancers are metachronous C,More common in women of >50 year of age

BRCA mutation is a risk factor for bilateral breast cancer.

Risk factors for bilateral breast cancer are-

- Young age at diagnosis (<50 years of age).
- multicentric disease
- Lobular invasive carcinoma.
- Radiation exposure
- Familial or hereditary breast cancer.

Bilateral breast cancer are-

- Synchronous (simultaneous)
- Metachronous (sequential)
- Metachronous bilateral breast cancer is more common than synchronous.

85. True about surgical approach in thyroid surgery -

a) Incision is made 1 cm below cricoid cartilage

b) Usually vertical incision is used

c) Thoracic duct may be damaged

d) For lobectomy thyroid is dissected at the isthmus

e) Strap muscles are divided if greater exposure is needed

Correct Answer - A:C:D:E

Answer- (A) Incision is made 1 cm below cricoid cartilage (C) Thoracic duct may be damaged (D) For lobectomy thyroid is dissected at the isthmus (E) Strap muscles are divided if greater exposure is needed

- Kocher transverse collar incision, typically 4 to 5 cm in length, is placed in or parallel to a natural skin crease 1 cm below the cricoid cartilage.
- The subcutaneous tissues and platysma are incised sharply.
- The RLN is most vulnerable to injury in the vicinity of the ligament of Berry.
- If a lobectomy is to be performed, the isthmus is divided flush with the trachea on the contralateral side and suture ligated.

86. True about endemic goiter -

a) Size may increase during pregnancy

b) Usually hypothyroid

c) Same as multinodular goiter

d) Can turn malignant

e) None

Correct Answer - A:B:D

Answer- (A) Size may increase during pregnancy (B) Usually hypothyroid (D) Can turn malignant

- Endemic Goiter is the presence of a goiter caused by nutritional deficiency of Iodine.
- **Effect of pregnancy-**
- Increased endocrine demand the iodine metabolism is characterized by the tendency to develop an endogenous iodine deficiency (ID).
- Diffuse thyroid gland hypertrophy can be visibly observed as a goiter of the neck.
- Endemic Goiter is ultimately caused by reduced thyroid hormone levels it is accompanied by the clinical syndrome of hypothyroidism.
- Irregular, nodular goiters due to repeated bouts of iodine deficiency may progress to thyroid follicular carcinoma.

87. Only simple cholecystectomy is adequate in which stage of gallbladder cancer

a) Stage IA

b) Stage IB

c) Stage III

d) Stage IV

e) None

Correct Answer - A

Answer- A. Stage IA

- According to TNM staging, Simple cholecystectomy is done for T1a which is included in stage-I.
- T1a- simple cholecystectomy
- T1b, II & III- Extended cholecystectomy
- IV- Palliative treatment

88. All are true about basal cell carcinoma EXCEPT:

a) Translucent

b) Retention cyst

c) Cyst of submandibular gland

d) Cyst of minor salivary gland

e) All

Correct Answer - A

Answer- A. Translucent

- Most common site is upper eye lid
- Usually a slow-growing, locally invasive malignant tumour of pluripotential epithelial cells arising from basal epidermis and hair follicles, hence affecting the pilosebaceous skin.
- Basal cell carcinomas usually present as pearly papules containing prominent dilated subepidermal blood vessels (telangiectasias)

89. True about hypertrophic scar -

a) Treated with triamcinolone

b) Results from a prolonged inflammatory phase of wound healing

c) Most common in pigmented skin

d) Grow beyond margin

e) Improve spontaneously with time

Correct Answer - A:B:E

Answer- (A) Treated with triamcinolone (B) Results from a prolonged inflammatory phase of wound healing (E) Improve spontaneously with time

- Hypertrophic scars are characterized by erythematous, pruritic, raised fibrous lesions that typically do not expand beyond the boundaries of the initial injury and may undergo partial spontaneous resolution.
- It results from a prolonged inflammatory phase of wound healing and from unfavourable scar siting.
- Hypertrophic scars are common after thermal injuries and other injuries that involve the deep dermis.
- Intralesional injection of Triamcinolone is also the t/t of choice for intractable hypertrophic scars.

90. Which of the following is/are true about Gastric lymphoma

a) Associated with H.pylori infection

b) Majority belongs to B-cell Hodgkin lymphomas

c) Endoscopic ultrasound is performed to determine the depth of gastric wall invasion

d) Second most common tumor of stomach

e) Diagnosis is made on basis of endoscopic biopsy

Correct Answer - A:C:D:E

Answer- A,Associated with H.pylori infection C,Endoscopic ultrasound is performed to determine the depth of gastric wall invasion D,Second most common tumor of stomach E,Diagnosis is made on basis of endoscopic biopsy

- The stomach is the most common site for extranodal lymphoma.
- B- cell lymphomas of mucosa- associated lymphoid tissue (MALT lymphoma).
- Lymphoma is the second most common primary cancer of the stomach.
- Majority of cases (80%) are associated with chronic gastritis and H. Pylori infection.
- It is most prevalent in sixth decade of life.
- MALTomas express B-cell markers CD 19 and CD 20.
- Diagnosis is made by endoscopic biopsy.
- Endoscopic ultrasound is useful to determine the depth of gastric wall invasion.
- Gastric lymphomas are chemosensitive and chemotherapy alone or

along with surgery is used for the treatment of gastric lymphoma.

91. Feature(s) of superficial partial thickness burn (second degree) is/are -

a) Hairs easily pluckable

b) Severe pain

c) Thrombosed vessel

d) Leathery skin

e) Blistering of skin

Correct Answer - B:E

Answer- (B) Severe pain (E) Blistering of skin

- these superficial dermal burns involve the upper layers of dermis
- Blisters are seen
- Erythematous
- Blanch to touch
- Quite painful
- Heal without scarring in 1 to 2 weeks

93. All are true about succinate dehydrogenase deficient gastrointestinal stromal tumor (SDH-deficient GIST) except

a) More common in children and young adult

b) Negative for DOG-1

c) Most common location is stomach

d) Associated with Carney-Stratakis syndrome

e) Absent c-kit mutation

Correct Answer - B

Answer- B. Negative for DOG-1

Succinate dehydrogenase (SDH) deficient - Gastrointestinal Stromal Tumors (GIST)-

Pathological features-

- SDH deficient - GISTs do not have c-KIT mutation --> absence of c-KIT mutation.
- They strongly express KIT and DOG1/Ano-1, but do not have KIT mutation.

Clinical features-

They may be associated with :-

- .. Carney stratakis syndrome - Paraganglioma with familial GIST
- 2. Carney triad
- These tumors have tendency to appear in children and young adults
- They occur exclusively in stomach.

94. Which of the following is/are true about appendicitis-

a) Both diarrhea and constipation may present

b) Nausea and vomiting usually present

c) Pain on internal rotation of flexed hip

d) Pain on flexion and external rotation of hip

e) Initially pain is located in the periumbilical region

Correct Answer - A:B:C:E

Answer- A,Both diarrhea and constipation may present B,Nausea and vomiting usually presentC,Pain on internal rotation of flexed hip E,Initially pain is located in the periumbilical region

Clinical features-

- Abdominal Pain (most common) is frequently noticed in the periumbilical region.
- Anorexia
- Nausea and vomiting
- Diarrhea or constipation

Signs in Appendicitis-

- Rovsing sign
- Obturator sign
- Psoas sign
- Dunphy sign
- Markle sign
- Mc Burney's sign

95. All are true statement about hernias except

a) Femoral hernia has the highest risk of strangulation of groin hernias

b) Direct inguinal hernia cause more symptoms than indirect

c) Direct inguinal hernia is most common in children

d) Indirect inguinal hernia occur due to patent processus vaginalis

e) Indirect inguinal hernia occur through a defect in fascia transversalis

Correct Answer - B:C

Answer- B,Direct inguinal hernia cause more symptoms than indirect C,Direct inguinal hernia is most common in children

- A femoral hernia has the highest risk of incarceration and strangulation of groin hernias.

96. Difference b/w full thickness and partial thickness grafts -

a) Partial thickness graft have good cosmetic appearance

b) Full thickness graft are good for large area

c) Edema under graft may cause graft failure

d) Thin graft survive transplantation more reliably

e) Minimal contraction in full thickness graft

Correct Answer - C:D:E

Answer- (C) Edema under graft may cause graft failure (D) Thin graft survive transplantation more reliably (E) Minimal contraction in full thickness graft

Type of Graft	Advantages	Disadvantages
Thin Split Thickness	<ul style="list-style-type: none"> - Best Survival - Heals Raqidly 	<ul style="list-style-type: none"> - Least resembles original skin. - Least resistance to trauma. - Poor Sensation - Maximal Secondary - Contraction
Thick Split Thickness	<ul style="list-style-type: none"> - More qualities of narmal skin. - Less Contraction - Looks Better - Fair Sensation - Most resembles normal skin. 	<ul style="list-style-type: none"> - Lower graft survival - Slower healing. - Poorest survival.

- | | | |
|----------------|---|--|
| Full Thickness | <ul style="list-style-type: none">- Minimal Secondary contraction- Resistant to trauma- Good Sensation- Aesthetically pleasing | <ul style="list-style-type: none">- Donor site must be closed surgically.- Donor sites are limited. |
|----------------|---|--|

Edema and necrotic tissue under graft may hamper graft acceptance.

97. Mediastinal mass(s) which is/are more common in posterior mediastinum

a) Lymphoma

b) Thymoma

c) Neurogenic tumor

d) Enterogenous cyst

e) Thyroid carcinoma

Correct Answer - C:D

Answer- C,Neurogenic tumor D,Enterogenous cyst

- Most common tumors in the posterior mediastinum are Neurogenic tumors.
- Posterior mediastinal masses include-
- Lymph node enlargement
- Neuroenteric cyst (Enterogenous cyst)
- Anterior meningocele

98. True about undescended testis

a) U/L more common than B/L

b) Missing testis on palpation may be due to agenesis

c) 10% bilateral

d) Undescended testis may be associated with absent kidney

e) Stephen fowler technique involves renal artery ligation

Correct Answer - A:B:C:D

Answer- A,U/L more common than B/L B,Missing testis on palpation may be due to agenesis C, 10% bilateral D,Undescended testis may be associated with absent kidney

- Cryptorchidism is the most common congenital abnormality of the genitourinary tract.
- Cryptorchidism means hidden testis.
- An absent testis may be due to agenesis or atrophy secondary to intrauterine vascular compromise also known as the "vanishing testis syndrome".
- Bilaterally absent testes is anorchia which is 10% cases.
- More common on Right Side.
- Complications of undescended testes
- Torsion can be seen in incomplete testicular descent
- Sterility is seen in bilateral cases (especially intra-abdominal testes)
- Incomplete testicular descent predisposes to malignant disease; cancer is more common in an incompletely descended testes-orchidopexy may or may not diminish the risk.
- Atrophy of an inguinal testes before puberty may possibly be caused by recurrent minor trauma.



99. True about torsion of testis is all except

a) Presents with sudden pain in testis

b) Commonly associated with pyuria

c) Doppler U/S shows decreased blood flow to the testis

d) Simultaneous orchipexy of the other side should also be done

e) All

Correct Answer - B

Answer- B. Commonly associated with pyuria

- Pyuria is associated with epididymo-orchitis, not with torsion of testis.
- Torsion is the twisting of the testis on the spermatic cord, resulting in strangulation of the blood supply and infarction of testis.
- It is seen commonly in adolescents (10-25 yrs)
- Symptoms -4 it presents as sudden agonising pain in the groin and the lower abdomen. Nausea and vomiting are very common.
- Colour Doppler → detects the decreased blood flow to testis in torsion

100. True about Meckel's diverticulum -

a) Causes volvulus of intestine

b) Due to persistent remnant of the vitellointestinal duct

c) Commonly found on the mesenteric side of the ileum

d) Causes melena

e) Causes haemoptysis

Correct Answer - A:B:D

Answer- (A) Causes volvulus of intestine (B) Due to persistent remnant of the vitellointestinal duct (D) Causes melena

- Meckel's diverticulum is the persistent proximal part of the vitellointestinal duct which normally disappears during intrauterine life.
- Bleeding in Meckel's diverticulum is usually the result of ulceration in ileal mucosa
- Hemorrhage may present as rectal bleeding or melana.
- Volvulus of the intestine around the fibrous band attaching the diverticulum to the umbilicus.
- Mesodiverticular band is a remnant of left vitelline artery.

101. True about tuberculosis -

a) Cavitory lesion suggests inactive disease

b) Rasmussen aneurysm is a complication

c) High grade fever

d) Tubercular bronchiectasis occur in lower lobes

e) All

Correct Answer - B

Answer- B. Rasmussen aneurysm is a complication

- Cavitation is a sign of active disease, and is considered as a sign of reactivation
- Fever in TB is usually low-grade and intermittent.
- Rasmussen's aneurysm is an inflammatory pseudoaneurysmal dilatation of a branch of pulmonary artery adjacent to a tuberculous cavity and life threatening complication of cavity tuberculosis.
- Tuberculosis causes upper lobe bronchiectasis.

102. Condition(s) associated with esophageal carcinoma

a) Achalsia

b) Post-cricoid web

c) Schatzki's ring

d) Paterson-Kelly syndrome

e) Lye ingestion

Correct Answer - A:B:D:E

Answer- A,Achalsia B,Post-cricoid web D,Paterson-Kelly syndrome E,Lye ingestion

Important risk factors for SCC carcinoma are :_

- i) Alcohol and Cigarette smoking.
- .. Mucosal damage from physical agents- Hot tea, Lye ingestion, Radiation induced strictures, Chronic achlasia.
2. other ingested carcinogens - Nitrates, Smoked opiates, Fungal toxins in pickled vegetables
3. Plummer -vinson- Patersol Kelly syndrome (Esophageal (post cricoid) Web + glossitis + Iron deficiency).
4. Tylosis plamaris et plantaris (congenital hyperkeratosis and pitting of palms and soles)
5. Dietary deficiencies of molybednum, Zinc, Vitamin A.
5. Celiac sprue

103. True about pseudocyst

a) Pancreatic fluid collection

b) May be asymptomatic

c) Well-defined wall

d) Fluid collection is always infectious in nature

e) Rich in pancreatic enzymes

Correct Answer - A:B:C:E

Answer- A,Pancreatic fluid collection B,May be asymptomatic C,Well-defined wall E,Rich in pancreatic enzymes

- Pancreatic pseudocyst is the most common complication of both acute and chronic pancreatitis.
- It is not a true cyst as its wall does not have an epithelial lining.
- Fluid of the cyst is rich in pancreatic amylase.
- Most common site for pseudopancreatic cyst is the body and tail of pancreas.

Clinical features-

- Pancreatic pseudocysts show a wide variety of clinical presentations ranging from completely asymptomatic lesions to many symptoms.
- Abdominal pain is MC symptom.

Investigations-

- CECT abdomen is investigation of choice for diagnosis of a pancreatic pseudocyst.

104. Hyperamylasemia is/are seen in all except

a) Pancreatic pseudocyst

b) Cystic fibrosis

c) Macroamylasemia

d) Parotitis

e) Chronic pancreatitis

Correct Answer - B

**Answer- B. Cystic fibrosis
Pancreatitis**

- .. Acute
- 2. Chronic
- Pancreatic pseudocyst
- Pancreatic necrosis
- Pancreatic trauma
- Pancreatic carcinoma
- cystic fibrosis

105. Indications of surgery in tuberculosis include(s)-

a) Streaky hemoptysis

b) Tubercular empyema

c) Persistent bronchopleural fistula

d) Chronic cough

e) AFB +ve bacilli in sputum

Correct Answer - B:C

Answer- (B) Tubercular empyema (C) Persistent bronchopleural fistula

Destroyed lung

1. Persistent bronchopleural fistula
2. Life-threatening hemoptysis (intractable hemorrhage)
3. Aspergilloma in a tuberculous cavity
4. Post surgical complication
5. Performance of diagnostic procedure
6. Tubercular empyema

106. Raised intracranial pressure (ICP) in head injury is/are managed by

a) Furosemide

b) Mannitol

c) Decompressive craniectomy is helpful in decreasing ICP but do not affect neurological outcome

d) Glucose free fluid

e) Hypotonic solution

Correct Answer - A:B:C:D

Answer- A,Furosemide B,Mannitol C,Decompressive craniectomy is helpful in decreasing ICP but do not affect neurological outcome D,Glucose free fluid

A) Initial

- Optimise electrolyte balance
- Sedation
- Seizure control

B) Middle (Intermediate)

- Mannitol/furosemide/hyperventilation as temporising measures
- Heavy sedation

C) Last (Final)

- Induction of thiopentone coma
- Decompressive craniectomy
- Hyperglycemia can aggravate increase ICP, thus glucose free fluid should be used.
- Decompressive craniectomy - Decompressive craniectomy is the surgical removal a large portion of the cranial vault to allow

- for the edematous intracranial contents to expand and subsequently reduce ICP.

107. Which of the following is true about suture technique:

- a) Subcuticular suture is used where cosmetic appearance is important
- b) Vertical mattress causes cause prominent stitch mark scars
- c) Horizontal mattress is used for fragile skin
- d) Vertical mattress is used for fragile skin
- e) None

Correct Answer - A:B:C

Answer- (A) Subcuticular suture is used where cosmetic appearance is important (B) Vertical mattress causes cause prominent stitch mark scars (C) Horizontal mattress is used for fragile skin

- The horizontal mattress stitch is a suture technique used to close wounds.
- This makes it ideal for holding together fragile skin.
- Vertical mattress suture are that it provides closure for both deep and superficial layers, and also allows perfect eversion and vertical opposition of the superficial skin edges.
- Subcuticular suture technique is used in skin where a cosmetic appearance is important and where the skin edges may be approximated easily.

108. True about care of polytrauma patient:

- a) CT scan of whole body can be done to exclude injuries
- b) Long spinal cord injury support is given if spinal cord injury is suspected
- c) Triage of injuries with colour coding like red, yellow, green & black can be done in case of mass casualty
- d) Initial fluid management is done as early as possible
- e) None

Correct Answer - A:B:C:D

Answer- (A) CT scan of whole body can be done to exclude injuries (B) Long spinal cord injury support is given if spinal cord injury is suspected (C) Triage of injuries with colour coding like red, yellow, green & black can be done in case of mass casualty (D) Initial fluid management is done as early as possible

- Because of CT, an increasing amount of both blunt & penetrating trauma has been safely managed nonoperatively.
- 'The availability of high resolution multislice scanners, promoting the development of protocols in some centers that call for early intergration of complete body (i.e. head, cervical mspine, chest, abdomen & pelvis) CT scanning of selected trauma patient.
- Intravenous line is critical for intravenous volume resuscitation.
- Triage system involves a color-coding scheme using red, yellow, green, white, and black tags: Red indicates high priority treatment or transfer, yellow signals medium priority, green indicates ambulatory patients & black for dead or moribund.

109. True about central venous catheterization:

a) Catheter may be placed through subclavian vein

b) If the CVP is low in the presence of a low MAP or cardiac output, then fluid resuscitation is necessary

c) Can be used for gaining venous access in patient with poor peripheral veins

d) Subclavian vein route is safest in term of complications

e) All

Correct Answer - A:B:C

Answer- (A) Catheter may be placed through subclavian vein (B) If the CVP is low in the presence of a low MAP or cardiac output, then fluid resuscitation is necessary (C) Can be used for gaining venous access in patient with poor peripheral veins

- Used for monitoring of CVP administration of fluid to treat hypovolemia & shock, infusion of caustic drug & total Parenteral nutrition, aspiration of emboli, insertion of transcutaneous pacing leads & gaining venous access in patient with poor peripheral veins.
- CVP or right atrial pressure (RAP) is monitored using a catheter inserted via either the internal jugular or the subclavian vein.
- The CVP may help in assessing the need for intravascular fluid replacement.

110. Feature(s) of 3rd degree burn is/are:

a) Blister formation

b) Very painful

c) No spontaneous healing

d) Dry eschar formation

e) Thrombosed vessels can be seen under the skin

Correct Answer - C:D:E

Answer- C, No spontaneous healing D, Dry eschar formation E, Thrombosed vessels can be seen under the skin

- Entire thickness of skin destroyed (into fat)
- Any color (white, black, red, brown), dry, less painful (dermal plexus of nerves destroyed)
- Heal by contraction and scar deposition (no epithelium left in middle of wound)
- Full-thickness Burns (3 degree BURN)- thrombosed vessels can be seen under the skin.

111. True about Babcock forcep:

a) Teeth at end

b) Serration at end

c) Triangular orifice in blades

d) Used for soft delicate tubular structure

e) Curved forcep

Correct Answer - C:D

Answer- C,Triangular orifice in blades D,Used for soft delicate tubular structure

- An instrument with a ratchet & a triangular expansion with fenestrations at the operating end
- It does not have any teeth
- This instrument can be used to hold intestine, thyroid gland, mesoappendix, uterine tube etc.

112. Sacral-teratoma/sacrococcygeal teratoma is a derivative of -

a) Primitive streak

b) Ectoderm

c) Hypoblasts

d) Cranial neuropore

e) None

Correct Answer - A

Answer- A. Primitive streak

Gastrulation & Hensen's node:

- In 2nd week - Gastrulation occurs → Establishes 3rd germ layer (mesoderm).
- Gastrulation begins with primitive streak formation in caudal region of epiblast.
- Primitive node or Hensen's node or primitive knot:
- Thickening formed at cranial end of primitive streak.

Sacrococcygeal formation:

- Failure of Hensen's node to regress can lead to sacrococcygeal formation.
- Incomplete primitive streak regression → leaves caudal remnant → Sacrococcygeal teratoma.
- Arise from residual to totipotential cell rests (Hensen's node).
- Sacrococcygeal teratoma demonstrates tissue derived from all three cell layers.
- Contain varying proportions of mature & immature elements.

113. Gas used in creating pneumoperitonem :

a) Water

b) CO₂

c) O₂

d) Air

e) CO

Correct Answer - B:C:D

Answer-B,CO₂ C,O₂ D,Air

- Gases used for pneumoperitoneum include carbon dioxide (CO₂), air, oxygen, nitrous oxide (N₂O), argon, helium and mixtures of these gases.

114. CO₂ is used in laparoscopy for creating pneumoperitoneum in place of air because:

a) Less absorption from peritoneal surface

b) Fast clearance from body

c) Less solubility in blood

d) Electrocautery is safe to use

e) Less risk of gas embolism

Correct Answer - B:D:E

Answer- B, Fast clearance from body D, Electrocautery is safe to use E, Less risk of gas embolism

- CO₂ gas insufflation is preferred by most laparoscopists because it has a high diffusion coefficient and is a normal metabolic end product rapidly cleared from the body.
- Also, CO₂ is highly soluble in blood and tissues and does not support combustion.
- The risk of gas embolism is lowest with CO₂.
- Cardiac arrhythmias can occur with CO₂ pneumoperitoneum.

**115. Acute haemorrhagic pancreatitis
produce which of the following sign:**

a) Cullen sign

b) Rovsing sign

c) Psoas sign

d) Grey Turner sign

e) Kehr sign

Correct Answer - A:D

Answer- A,Cullen sign D,Grey Turner sign

- Bleeding into the fascial plane can produce bluish discoloration of the flanks (Grey Turner's sign) or umbilicus (Cullen's sign).

116. True about lymphangioma circumscriptum:

a) Compressible swelling

b) Often contain clear fluid

c) Groups of vesicles are found on skin

d) May present at birth or shortly after birth

e) None

Correct Answer - B:C:D

Answer- (B) Often contain clear fluid (C) Groups of vesicles are found on skin (D) May present at birth or shortly after birth

- This type presents as circumscribed lesion which appears as small vesicle or small blister or slightly elevated skin patch
- The size varies from 0.5 to 4 mm in diameter
- A large area of skin may be involved on the inner side of the thigh, buttock on the shoulder or in the axilla
- The whole lesion is soft & spongy
- Fluctuation, fluid thrill & translucency test are always positive. The swelling is not compressible
- The margins of the swelling are indistinct
- The skin vesicles contain clear fluid
- It is usually prominent at puberty and may often start bleeding.

117. True regarding urinary catheterization with 16 French size:

a) It is the suitable size to use in adult female

b) It can cause UTI in long term use

c) Used in management of urethral obstruction

d) Diameter is 4 mm

e) Sterile technique must be used for insertion

Correct Answer - A:B:C:E

Answer- A,It is the suitable size to use in adult female B,It can cause UTI in long term use C,Used in management of urethral obstruction E,Sterile technique must be used for insertion

- Foley's catheter is sterilized by gamma radiation. Usually Foley's catheter is kept for 7 days.
- Size:**
- Adults— 16 F
 - Children— 8 F or 10 F
 - Obstruction of the urethra by an anatomical condition that ,makes it difficult for one to urinate: prostate hypertrophy,
 - prostate cancer, or narrowing of the urethra.

118. Which of the following is/are true about obstructive uropathy:

a) Stricture in ureter is cause

b) Stone in ureter is cause

c) RTA type 4 can occur

d) Absence of hydronephrosis on USG rule out obstructive uropathy

e) When obstruction is above the level of the bladder, bilateral hydroureter and hydronephrosis occurs

Correct Answer - A:B:C

Answer- A,Stricture in ureter is cause B,Stone in ureter is cause C,RTA type 4 can occur

- Any obstruction at or distal to the bladder neck may lead to back pressure affecting both kidneys.
- Obstruction at or proximal to the ureteral orifice leads to unilateral damage.
- Partial obstruction leads to gradual progressive muscular hypertrophy followed by dilation, decompensation and hydronephrotic changes.
- Acquired urinary tract obstruction may be due to inflammatory or traumatic urethral strictures, ureteral or pelvic stones.

119. Which are Radio-opaque stones:

a) Pure uric acid

b) Cysteine

c) Phosphate

d) Oxalate

e) Impure uric acid

Correct Answer - B:D:E

Answer- (B) Cysteine (D) Oxalate (E) Impure uric acid

Renal Calculus-

- Oxalate stones
- Phosphate calculus- struvite
- Uric acid and urate calculi
- Cystine calculus

120. True about branchial fistula:

- a) External opening near the anterior border of sternocleido–mastoid
- b) External opening at junction of upper & middle third of sternocleidomastoid muscle
- c) Develop due to persistence of 2ndbranchial cleft
- d) Open in oropharynx
- e) Move with swallowing

Correct Answer - A:C:D

Answer- A,External opening near the anterior border of sternocleido–mastoid C,Develop due to persistence of 2ndbranchial cleft D,Open in oropharynx

- This is always congenital & occurs due to persistent 2nd branchial cleft.
- The external orifice is nearly always situated in the lower third of the neck near the anterior border of the sternocleidomastoid.
- The patient may complain of a dimple, discharging mucus & the dimple becomes more obvious when the patient is asked to swallow.

121. True about 1st degree haemorrhoid:

a) Painless bleeding

b) Malaenae occur

c) Constipation may be present

d) Prolapse on defaecation

e) Never prolapse

Correct Answer - A:C:E

Answer- A,Painless bleeding C,Constipation may be present E,Never prolapse

Four Degrees of Haemorrhoids

- First degree: bleed only, no prolapse
- Second degree: prolapse, but reduce spontaneously
- Third degree: prolapse and have to be manually reduced
- Fourth degree: permanently prolapsed

122. Which of the following examination is done in supine position:

a) Trendelenburg position

b) Reverse Trendelenburg position

c) Sims position

d) Jack knife position

e) Lloyd-Davies position

Correct Answer - A:B:E

Answer- A,Trendelenburg position B,Reverse Trendelenburg position E,Lloyd-Davies position

- "Trendelenburg position: Lithotomy with head down
- Reverse Trendelenburg position: The patient is supine on the operating table with the table tilted up 15" at the head end to reduce venous engorgement.
- "Most commonly, the patient is examined in the left lateral (Sims) position with the buttocks overlying the edge of the examination couch and with the axis of the torso crossing, rather than parallel with, the edge of the couch.
- The prone jackknife or knee-elbow positions may be used.
- Lloyd-Davies Position: It is also known as the Trendelenburg position with legs apart.

123. Acinic cell carcinoma is/are found in:

a) Breast

b) Parotid

c) Lacrimal gland

d) Pancrease

e) Minor salivary gland

Correct Answer - B:D:E

Answer- (B) Parotid (D) Pancrease (E) Minor salivary gland

- Major Salivary Glands (including parotid)
- Minor Salivary Glands
- Acinar cell carcinoma are malignant epithelial neoplasm (of pancrease)

124. True about lip carcinoma:

a) Common in smoker

b) More common in lower lip

c) More common in upper lip

d) Always painful to touch

e) Distant metastasis is late

Correct Answer - A:B:E

Answer- A,Common in smoker B,More common in lower lip E,Distant metastasis is late

Lower lip is more often involved

- Incidence of oral cancer is six times more in smoker than non-smoker
- Site of predilection is b/w the midline & commissure of the lip
- Mostly, it is squamous cell carcinoma, often seen in males in the age group of 40-70 years
- L, N metastases develop late. Submental & submandibular nodes are the first to be involved; other deep cervical nodes may also get involved later.

125. True about mediastinal teratoma:

a) Most common tumour of anterior mediastinum

b) Most common germ cell tumour of mediastinum

c) More commonly occurs in anterior mediastinum

d) Contain teeth, skin, hair, cartilage and bone

e) Histologically graded as differentiated & undifferentiated

Correct Answer - B:C:D:E

Answer- B,Most common germ cell tumour of mediastinum C,More commonly occurs in anterior mediastinum D,Contain teeth, skin, hair, cartilage and bone E,Histologically graded as differentiated & undifferentiated

- Most common malignancy in young men between age 15 and 35 years.
 - Primary mediastinal germ cell tumors (including teratomas, seminomas, and nonseminomatous malignant germ cell tumors) are a heterogeneous group of benign and malignant neoplasms.
 - Teratomas are the most common type of mediastinal germ cell tumors.
 - They contain two or three embryonic layers that may include teeth, skin, hair (ectodermal), cartilage and bone (mesodermal), or bronchial, intestinal, or pancreatic tissue (endodermal).
- Mediastinal Teratomas may either be-**
- Mature: Well differentiated
 - Immature: Poorly differentiated
 - With malignant transformation

126. True about inguinal hernia in children:

a) Occur due to persistence of processus vaginalis

b) Defect in abdominal may present

c) Most common variety is direct type

d) Difficult to reduce non-operatively

e) More common in girls

Correct Answer - A:B:D

Answer- A,Occur due to persistence of processus vaginalis B,Defect in abdominal may present D,Difficult to reduce non-operatively

- In children, if inguinal (indirect) hernia is present in one side, then processus vaginalis is intact on other side.
- Males are affected about six times more often than females.
- Indirect inguinal hernia- Can occur in any age from childhood to adult.
- Inguinal hernia results from a failure of closure of the processus vaginalis.

127. True regarding testicular tumour:

a) For stage I seminoma- orchidectomy alone used for treatment

b) For stage I seminoma- orchidectomy + radiotherapy used for treatment

c) Stage I non-seminomatous germ cell tumour-orchidectomy +radiotherapy used for treatment

d) Staging is important for planning management

e) β HCG & AFP may be used as marker the response of treatment

Correct Answer - B:D:E

Answer- B,For stage I seminoma- orchidectomy + radiotherapy used for treatment D,Staging is important for planning management E, β HCG & AFP may be used as marker the response of treatment

Testicular Tumour: Staging

- Stage I: The tumour is confined to the testis;
- Stage II: Nodal disease is present but is confined nodes below the diaphragm;
- Stage III: Nodal disease is present above the diaphragm;
- Stage IV: Nonlymphatic metastatic disease
- In confirmed cases, staging is an essential step in planning treatment.
- HCG & NSGCTs when raised, these markers are used to monitor the response to treatment.

128. Feature(s) of Fournier's gangrene:

a) Necrotizing fasciitis of the male genitalia and perineum

b) Diabetes is risk factor

c) Urgent wide surgical excision of the dead and infected tissue is essential

d) Testis need to be removed in all cases

e) None

Correct Answer - A:B:C

Answer- A,Necrotizing fasciitis of the male genitalia and perineum B,Diabetes is risk factor C,Urgent wide surgical excision of the dead and infected tissue is essential

- Fournier's gangrene is a necrotizing fasciitis of the male genitalia and perineum that can be rapidly progressing and fatal if not treated promptly.

Risk factors-

- urethral
- strictures,
- perirectal abscesses,
- poor perineal hygiene,
- diabetes,
- cancer,
- human immunodeficiency virus (HIV)

Clinical features-

- Clinical signs include fevers, perineal and scrotal pain.
- Cellulitis, eschars, necrosis, flaking skin, and crepitus may all be observed.
- Treatment-

- Urgent wide surgical excision of the dead and infected tissue is essential.

129. True about paralytic ileus:

- a) Postoperative ileus primarily affects the stomach and colon
- b) Mostly resolve after 24-72 hours
- c) Return of function occurs in the following order: stomach, large bowel and small bowel.
- d) If opioid is used as postoperative analgesia, then chance increases
- e) Is an anticipated complications of abdominal operations

Correct Answer - A:B:D:E

Answer- (A) Postoperative ileus primarily affects the stomach and colon (B) Mostly resolve after 24-72 hours (D) If opioid is used as postoperative analgesia, then chance increases (E) Is an anticipated complications of abdominal operations

- Etiology
- Post operative
- A degree of ileus usually occurs after any abdominal procedure
- Self-limiting (24-72 hours)
- May be prolonged in Hypoproteinemia or metabolic abnormality
- Intra-abdominal inflammation (peritonitis, abscess, retroperitoneal hemorrhage)
- Reflex ileus: following fractures of spine/ribs, retroperitoneal hemorrhage or application of a plaster jacket
- Metabolic & electrolyte derangements (uremia, hypokalemia, hyponatremia, hypo and hypomagnesemia, diabetic coma, hypoparathyroidism, hypothyroidism)
- Drugs (opiates, psychotropic agents, anticholinergic agents, calcium channel blockers)

- Return of function of the intestine occurs in the following order: small bowel, large bowel and then stomach
- Paralytic ileus, also called pseudo-obstruction, is one of the major causes of intestinal obstruction in infants and children.

130. Which of the following is/are feature(s) of enlarged kidney:

a) Ballotable

b) Upper border can be reached

c) Shift to paracolic gutter on compression

d) Do not move with respiration

e) Dull on percussion on renal angle

Correct Answer - A:E

Answer- A,Ballotable E,Dull on percussion on renal angle

- It is a reniform swelling
- It moves very slightly with respiration as it comes down a little at the height of inspiration.
- It is ballotable
- A sickening sensation is often felt during manipulation
- A hand can be easily insinuated b/w the upper pole of swelling & the costal margin
- Percussion will reveal resonant note in front of a kidney swelling as coils of intestine & colon will always be in front of the kidney.

131. In comparison to ulcerative colitis, which of the following is/are feature(s) of crohn's disease:

a) Transmural inflammation

b) More common in smoker

c) More pANCA positivity

d) TNF-alpha inhibitor role only in CD

e) All

Correct Answer - A:B:D

Answer- (A) Transmural inflammation (B) More common in smoker (D) TNF-alpha inhibitor role only in CD

- Can affect any part of GIT, but me sites – terminal ileum, ileocecal valve, and caecum.

Etiology-

- Smoking is a strong risk factor
- OCPs and Appendectomy increase risk

Morphology-

- Skip lesions
- Thick bowel wall
- Strictures common
- Transmural inflammation
- Non caseating granulomas
- Moderate pseudopolyps
- Deep, knife- like ulcers
- Fibrosis, serositis- Marked

Investigations-

- 70% ASCA +ve (anti Saccharomyces cerevisiae Ab) 10% pANCA positive

Treatment

- Anti-TNF therapy (Infliximab, adalimumab, certolizumab) -first-line agents to induce remission in moderate to severe disease and to maintain remission

132. True about breast cyst:

a) Mostly seen in premenopausal period

b) Most common in young woman

c) Usually unilateral

d) Yellowish-greenish discharge

e) Adhere to underlying skin

Correct Answer - A:C:D

Answer- A,Mostly seen in premenopausal period C,Usually unilateral D,Yellowish-greenish discharge

- Classically seen in perimenopausal women mostly in last decade of reproductive life.
- 50% of cysts are multiple or recurrent.
- Cyst fluid can be straw, colored, opaque, or dark green and may contain fleck of debris.
- Diagnosis can be confirmed by aspiration and/or ultrasound.

133. True about Congenital hypertrophic pyloric stenosis:

a) Shortening of pyloric canal on barium contrast imaging

b) Elongation of pyloric canal on barium contrast imaging

c) Narrowing of pyloric canal on barium contrast imaging

d) Thickened pyloric muscle on USG

e) Child should be given normal saline with KC1

Correct Answer - B:C:D:E

Answer- (B) Elongation of pyloric canal on barium contrast imaging (C) Narrowing of pyloric canal on barium contrast imaging (D) Thickened pyloric muscle on USG (E) Child should be given normal saline with KC1

- Imaging confirmation is sought by most clinician to differentiate from gastroesophageal reflux
- Precaution: Empty stomach via nasogastric tube before study & Remove contrast at end
- Elongation & narrowing of pyloric canal
- String sign=passing of small barium streak through elongated pyloric channel (most specific sign)
- Double/triple track sign: crowding of mucosal folds in pyloric channel

134. Fibrocystic disease differ from fibroadenoma by having:

a) Pain shift with cycle

b) Freely mobile

c) Usually bilateral

d) Firm & rubbery

e) Well demarcated border

Correct Answer - A:C

Answer- A,Pain shift with cycle C,Usually bilateral

- Painful, often multiple, usually bilateral masses in the breast.
- Rapid fluctuation in the size of the masses is common.
- Frequently, pain occurs or increases and size increases during premenstrual phase of cycle.
- These lesions are always associated with benign changes in the breast epithelium.
- The microscopic findings of fibrocystic condition include cyst (gross and microscopic), papillomatosis, adenosis, fibrosis, and ductal epithelial hyperplasia.

Clinical features-

- Pain or tenderness often calls attention to the mass.
- Discharge from the nipple.
- Discomfort occurs or is increased during the premenstrual phase of the cycle.

Fibroadenoma-

- Peak age of incidence is at 20 year
- Present with painless lump

- It is smooth, round bordered, firm to hard in consistency & freely mobile within the breast (so called breast mouse)

135. Test for incompetent valve done by:

a) Cough impulse test

b) Trendelenburg

c) Percussion wave travel in retrograde direction along varicose vein

d) Percussion wave travel in orthograde direction along varicose vein

e) All

Correct Answer - A:B:C

Answer- A,Cough impulse

test B,Trendelenburg C,Percussion wave travel in retrograde direction along varicose vein

- Cough impulse test: saphenoofemoral incompetence
- Trendelenburg I: saphenofemoral incompetence
- Trendelenburg II: Perforator incompetence
- Multiple tourniquet test: Site of perforator incompetence
- Schwartz test: Superficial column of blood

136. Which of the following is/are feature(s) of Keloid:

a) Collagen fibers are randomly arranged

b) Type IV collagen dominates

c) Lesion with healthy margin removed

d) Steroid is very useful

e) Goes beyond margin of wound

Correct Answer - B:D:E

Answer- (B) Type IV collagen dominates (D) Steroid is very useful (E) Goes beyond margin of wound

- Scars are often described as being atrophic, hypertrophic and keloid.
- A hypertrophic scar is defined as excessive scar tissue that does not extend beyond the boundary of the original incision or wound.
- A keloid scar is defined as excessive scar tissue that extends beyond the boundaries of the original incision or wound .
- IgE antibody is least commonly seen in keloid.

keloids grow on particular sites, these are ?

1. Central chests (probably most common, not sure)
2. Back
3. Shoulder
4. Earlobes

Etiology of keloid-

- Key factors: Surgery burns, vaccinations
- Elevated levels of growth factor (more of type .8, collagen)
- Laceration or abrasion

- Over the sternum (incision)
- Inheritance and injection
- Deep pigmented skin
- **Histology of both hypertrophic and keloid scars-**
- Excess collagen with hypervascularity
- keloids where there is more type III collagen.
- Hypertrophic scars improve spontaneously with time, whereas keloid scars do not.
- keloid scars have thicker, more abundant collagen bundles.
- **Treatment-**
- Intralesional injection of steroid (Triamcinolone acetate) is now recommended as the first line of t/t for keloid.

137. All are true about full thickness rectal prolapse except:

a) Elderly are at risk

b) Common in children

c) More common in female

d) sensation of incomplete evacuation

e) May associated with a weak pelvic floor

Correct Answer - B

Answer- B. Common in children

- Common In elderly women who are multipara
- Constipation is important feature
- Tenesmus common
- Some degree of incontinence of faeces & flatus is always present.

138. True about paramedian incision:

a) It is made below umbilicus

b) Better in obese person

c) Cause abdominal hernia

d) Cut anterior surface of rectus sheath

e) Cut posterior surface of rectus sheath

Correct Answer - C:D:E

Answer- (C) Cause abdominal hernia (D) Cut anterior surface of rectus sheath (E) Cut posterior surface of rectus sheath

- Use: provides laterality to the midline incision, allowing lateral structures such as the kidney, adrenals and spleen to be accessed.
- Location: about 2-5 cm to the left or right of the midline incision. Incision is over the medial aspect of the transverse convexity of the rectus.
- Layers of the abdominal wall skin, fascia (camper's and scarpa's) and the anterior rectus sheath are incised.
- Incisions in anterior and posterior sheath is separated by muscle which acts as a buttress, therefore closure and more secure.

139. Which of the following is/are true about renal carcinoma of T3a stage:

- a) Involve Gerota fascia
- b) Involve perinephric fat
- c) Renal vein involvement
- d) Inferior vena cava involvement
- e) Size >10 cm

Correct Answer - B:C:E

Answer- B,Involve perinephric fat C,Renal vein involvement E,Size >10 cm

Stages of renal cell carcinoma

Stage I

- tumor <7cm
- found only in the kidney
- T1, N0, M0
- 5-year survival 95%

Stage II

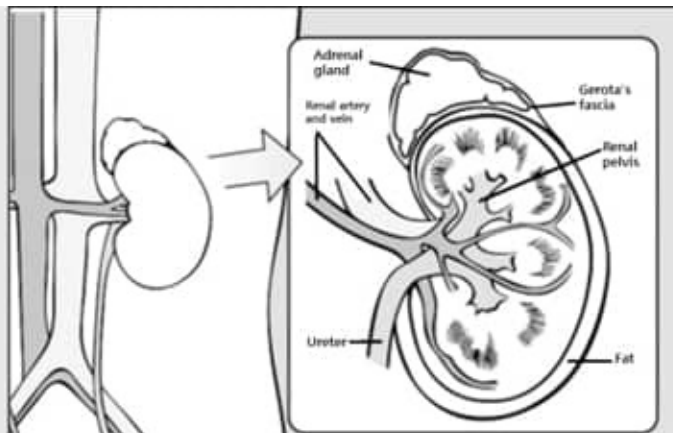
- tumor >7cm
- found only in the kidney
- T2, N0, M0
- 5-year survival 88%


Stage III

- tumor can be any size
- found in the kidney and regional spread of tumor in major blood vessels, the layer of fatty tissue around the kidney, or neighboring lymph nodes
- T1 or T2, T3, N0 or N1, M0
- 5-year survival 59%

Stage IV

- tumor beyond the layer of fatty tissue around the kidney and in the adrenal gland
- distant metastases in the lungs, bones, brain and distant lymph nodes
- T4, any T, any N, M0, M1
- 5-year survival 20%





140. True about extracorporeal shock wave lithotripsy (ECWL):

a) C/I in pregnancy

b) Less satisfactory for hard stones

c) Stone is broken into small pieces which comes out with urine

d) Safer in coagulopathy

e) Endoscopic retrieval is sometimes used for impacted stone fragment produced by lithotripsy

Correct Answer - A:B:C:E

Answer- A,C/I in pregnancy B,Less satisfactory for hard stones C,Stone is broken into small pieces which comes out with urine E,Endoscopic retrieval is sometimes used for impacted stone fragment produced by lithotripsy

- Crystalline stones disintegrate under the impact of shock waves produced by the ESWL machine.
- Ureteric colic is common after ESWL.
- The principal complication of ESWL is infection.
- "Pregnant women and patients with large abdominal aortic aneurysms or uncorrectable bleeding disorders should not be treated with ESWL.

141. True about carcinoma gall bladder:

a) Increased bilirubin level is contraindication for surgery

b) Palliative treatment is for advanced disease

c) Metastatic recurrence is common in liver

d) When gall bladder wall is involved, extended cholecystectomy is done

e) Surgery should be done in all cases

Correct Answer - B:C:D

**Answer- (B) Palliative treatment is for advanced disease
(C) Metastatic recurrence is common in liver (D) When gall bladder wall is involved, extended cholecystectomy is done**

- If GB cancer is found at cholecystectomy & if mucosa alone is involved, then cholecystectomy is sufficient
- If GB wall is involved, then extended cholecystectomy is done
- Radiation has very small benefit. Chemotherapy also has been tried. 5-FU, mitomycin C, doxorubicin are drugs used
- Prognosis is very poor. Aggressive surgery & complete clearance give best results.
- Surgery remains the only curative option for gallbladder cancer.

142. Which of the following is/are true about breast self examination:

a) Performed in different positions like standing, sitting, supine etc

b) T survival rate

c) Done about 2-3 day before menstrual cycle in premeno-pausal women

d) It should be start only after 35 year

e) Monthly breast self-examination (BSE) is recommended

Correct Answer - A

Answer- A. Performed in different positions like standing, sitting, supine etc

- Breast self-examination (BSE) has not been shown to improve survival
- The American Cancer Society no longer recommends monthly BSE beginning at age 20 years.
- Premenopausal women should perform the examination 7-8 days after the menstrual period.
- The breasts should be inspected initially while standing before a mirror with the hands at the sides, overhead, and pressed firmly on the hips to contract the pectoralis muscles.

143. True about Mallory-Weiss tear :

a) Alcoholism is a predisposing factor

b) Tear involves up to muscularis mucosa

c) Tear involves gastric mucosa near gastro-esophageal junction

d) Associated with hiatus hernia

e) Important cause of upper GI bleeding

Correct Answer - A:C:D:E

Answer- (A)Alcoholism is a predisposing factor (C)Tear involves gastric mucosa near gastro-esophageal junction (D)Associated with hiatus hernia (E)Important cause of upper GI bleeding

A Mallory -Weiss tear (MWT) is forceful or retching vomiting may produce a longitudinal mucosal tear immediately below squamo columnar junction at the cardia or gastroesophageal junction mainly and also in oesophagus.

ETIOLOGY:

- Alcoholism
- Hiatus hernia
- NSAID abuse
- The tear involves the mucosa and submucosa but not the muscular layer

144. High imperforate anus is/are associated with:

a) Underdeveloped pelvic & gluteal musculature

b) Associated with maldeveloped urinary system

c) Associated with VACTERL syndrome

d) Fistula formation with bladder

e) Normal anal sphincter mechanism

Correct Answer - A:B:C:D

Answer- (A)Underdeveloped pelvic & gluteal musculature (B)Associated with maldeveloped urinary system (C)Associated with VACTERL syndrome (D)Fistula formation with bladder

- More commonly there is fistula to the urethra or bladder in the male or the upper vagina in the female.
- Patients with high imperforate anus often have deficient pelvic and gluteal innervation and musculature, a high incidence of sacral anomalies.
- Anomalies of the vertebrae and the urinary tract occur in two-third of all patients with high anomalies.
- Imperforate anus is associated with the VACTERL syndrome.

145. Statement true about crush injury & syndrome:

a) Often seen during earthquake

b) Myoglobinuria occurs

c) Presents as glomerulonephritis

d) May cause compartment syndrome

e) May be associated with rhabdomyolysis

Correct Answer - A:B:D:E

Answer- (A)Often seen during earthquake (B)Myoglobinuria occurs (D)May cause compartment syndrome (E)May be associated with rhabdomyolysis

- A crush injury occurs when a body part is subjected to a high degree of force or pressure, usually after being squeezed between two heavy or immobile objects.
- Crush injury includes lacerations, fractures, bleeding bruising compartment syndrome and crush syndrome
- Association between crush injury rhabdomyolysis and acute renal failure seen in earthquake
- The myoglobinuria leads to renal failure from tubular obstruction.

146. True regarding urethral injury:

- a) Straddle injuries are often associated with posterior ure-thral injuries
- b) Pelvic injuries is frequently associated with anterior ure-thral injuries
- c) Problem in voiding
- d) Initial management is insertion of a suprapubic catheter
- e) Suspect if there is blood at the urethral meatus in case of pelvic fracture

Correct Answer - A:D:E

Answer- (A)Straddle injuries are often associated with posterior ure-thral injuries (D)Initial management is insertion of a suprapubic catheter (E)Suspect if there is blood at the urethral meatus in case of pelvic fracture

- Urethral injuries are more common in cases of bilateral pelvic injuries.
- Diagnosis of urethral injury is made by a high index of suspicion in the presence of blood at the urethral meatus, inability to urinate.
- When blood is present at the meatus, retrograde urethrography aids in the diagnosis of urethral injury.

Urethral injuries are-

1. posterior urethra (above the urogenital diaphragm)
 2. anterior urethra (below the urogenital diaphragm)
- Stented Foley catheter- healing of the urethral injury.
 - anterior urethra injuries are associated with straddle injuries.

147. Which of the following is included in management of traumatic brain injury:

a) Mannitol infusion

b) Decompressive craniectomy

c) CT scan

d) Pneumococcal vaccination

e) Antiepileptics

Correct Answer - A:B:C:D:E

Answer- A,Mannitol infusion B,Decompressive craniectomy C,CT scan D,Pneumococcal vaccination E,Antiepileptics

Initial-

- Head up
- Loosen collar
- Optimise ventilation
- Optimise electrolyte balance (hypertonic fluids if necessary), treat hyperglycemia
- Sedation
- Seizure control

Intermediate

- (Mannito/furosemide/hyperventilations temporising measures)
- Heavy sedation
- Paralysis
- CSF drainage by insertion of EVD
- Cooling

Final

- Induction of thiopentone coma
- Decompressive craniectomy

148. Video assisted thoracotomy is/are commonly used for:

a) Pneumonectomy

b) Lung biopsy

c) Hemothorax with active bleeding

d) Repair of large vessel tear in thorax

e) Diagnosis and staging of thoracic malignancies

Correct Answer - A:B:C:E

Answer- A,Pneumonectomy B,Lung biopsy C,Hemothorax with active bleeding E,Diagnosis and staging of thoracic malignancies

- Thoracoscopy or video-assisted thoracoscopic surgery:
- Pneumonectomy, lobectomy and empyema drainage are all possible.
- Lung biopsy and the treatment of-recurent pneumothorax are the, most frequent indications.
- Thotacotomy is required for management of injuries to the lungs, heart, pericardium, and great vessel.

149. Which of the following is/are true regarding parathyroid gland surgery in parathyroid adenoma/hyperplasia:

a) Superior parathyroid gland lies posterior to RLN

b) Gland can be differentiated from surrounding tissue due to its colour

c) The presence of a normal parathyroid gland at operation indicates that the tumor removed is an adenoma rather than parathyroid hyperplasia

d) Intraoperative PTH estimation is done to check status of gland removal

e) 6% person have 5 parathyroid gland

Correct Answer - A:B:C:D

Answer- A,Superior parathyroid gland lies posterior to RLN B,Gland can be differentiated from surrounding tissue due to its colour C,The presence of a normal parathyroid gland at operation indicates that the tumor removed is an adenoma rather than parathyroid hyperplasia D,Intraoperative PTH estimation is done to check status of gland removal

- There are usually four parathyroid glands, which lie on the posterior surface of the thyroid.
- Common sites for ectopic parathyroids are the thyrothymic ligament, superior thyroid poles, tracheoesophageal groove, retroesophageal space, and carotid sheath.

150. Which of the following is/are feature of highly selective vagotomy in comparison to truncal vagotomy with drainage:

a) Better tolerated

b) Dumping is more common

c) Diarrhea is less

d) High recurrence rate

e) Operative mortality rate very less

Correct Answer - A:C:D:E

Answer- A,Better tolerated C,Diarrhea is less D,High recurrence rate E,Operative mortality rate very less

- Highly selective vagotomy (HSV), also called parietal cell vagotomy or proximal gastric vagotomy.
- It preserves the vagal innervation to the antrum and pylorus.
- Gastric emptying of solids is typically normal in patients after parietal cell vagotomy.
- The recurrence rate is higher with HSV than with vagotomy and antrectomy.
- The most popular drainage procedure is the Heineke- Mikulicz pyloroplasty.

151. True about esophageal varices:

a) Left gastric vein is portal vessel involved

b) Occur at mid esophagus level

c) Occur at pharyngeal level

d) Epigastric vein is systemic vein involved

e) Occur at lower end of esophagus

Correct Answer - A:E

Answer- A,Left gastric vein is portal vessel involved E,Occur at lower end of esophagus

- The pharynx extends from the base of the skull down to the inferior border of the cricoid cartilage (around the C6 vertebral level), where it becomes continuous with the esophagus.

152. True about Caroli's disease:

a) Intrahepatic bile duct dilation

b) Jaundice may be seen

c) 1st Serum alkaline phosphatase

d) Not associated with portal hypertension

e) Surgery is treatment of choice localized hepatic involvement

Correct Answer - A:B:C:E

Answer- A,Intrahepatic bile duct dilation B,Jaundice may be seen C,1st Serum alkaline phosphatase E,Surgery is treatment of choice localized hepatic involvement

- Congenital, multiple, irregular dilatations of intrahepatic ducts with stenotic segments in between
 - Complications: intrahepatic stone formation, biliary sepsis
 - Associated with congenital hepatic fibrosis and medullary sponge kidney
 - Premalignant
- Treatment:**
- First line therapy: biliary drainage with ERCP and PTC
 - Diffuse: Liver transplantation
 - Localized: Segmental resection

153. All are true about medullary thyroid carcinoma except:

a) Involves the parafollicular cell

b) Radiosensitive

c) Amyloid stroma is present

d) Elevated level of calcitonin

e) High level of carcinoembryonic antigen

Correct Answer - B

Answer- B. Radiosensitive

- These are tumours of the parafollicular (C cells) derived from the neural crest.
- There is a characteristic amyloid stroma.
- High levels of serum calcitonin and carcinoembryonic antigen are produced medullary tumours.
- Calcitonin levels fall after resection and rise again with recurrence making it a valuable tumour marker in the follow up of patients with this disease.
- Diarrhoea due to 5-hydroxytryptamine or prostaglandins.
- Tumours are not TSH dependent and do not take up radioactive iodine.

154. Which of the following is/are true about breast carcinoma in male except:

a) Often presented at advanced stage at the time of diagnosis

b) Associated with gynaecomastia

c) Staging is different than female

d) Tamoxifene is used in treatment

e) Associated with excess endogenous or exogenous oestrogen

Correct Answer - C

Answer- C. Staging is different than female

- The following conditions have been reported to be associated with an increased risk of breast cancer in men: chronic liver disorders, such as cirrhosis, chronic alcoholism, schistosomiasis; a history of mumps orchitis, undescended testes, or testicular injury; and feminization, genetically or by environmental exposure. In contrast, gynecomastia alone does not appear to be a risk factor

155. Full form of SCIWORA is:

a) Spinal cord injury with radiographic abnormality

b) Spinal cord injury with radiographic aberration

c) Spinal cord injury without radiographic aberration

d) Spinal cord injury without radiographic abnormality

e) Spinal cord injury with vertebral fracture with radiographic abnormality

Correct Answer - D

Answer- D. Spinal cord injury without radiographic abnormality

- SCIWORA (Spinal Cord Injury Without Radiographic Abnormality) was first developed and introduced by Pang and Wilberger who used it to define 'clinical symptoms of traumatic myelopathy with no radiographic or computed tomographic features of spinal fracture or instability.

156. Which of the following is the feature (s) of posterior cranial fossa fracture:

a) Bleeding from ear

b) Discolouration of skin & collection of blood occur in the region of mastoid process

c) Boggy swelling in the nape of the neck

d) Bleeding from nose

e) CSF rhinorrhoea

Correct Answer - B:C

Answer- (B) Discolouration of skin & collection of blood occur in the region of mastoid process (C) Boggy swelling in the nape of the neck

Extravasation of blood in the suboccipital region causing boggy swelling in the nape of the neck.

9th, 10th & 11th cranial nerves may be involved

Battle sign: Discolouration of skin & collection of blood occur in the region of mastoid process.

157. Symptom of overactive bladder are:

a) Increased day time frequency

b) Nocturia

c) Hesitancy

d) Dysuria

e) Urgency

Correct Answer - B:E

Answer- (B) Nocturia (E) Urgency

Symptoms of overactive bladder (OAB) result from sudden and involuntary contractions of the bladder muscles, leading to-

- Sudden need to urinate (urinary urgency) and/or
- Urinary incontinence (leakage of urine)
- urinary frequency (having to urinate often) &
- Nocturia (urinating frequently at night)

158. True about Psoas abscess:

a) Hip extension increases pain

b) Staphylococcus is most common cause

c) Presented with back pain

d) TB can cause

e) Causes referred pain to the hip & groin

Correct Answer - A:C:D:E

Answer- (A) Hip extension increases pain (C) Presented with back pain (D) TB can cause (E) Causes referred pain to the hip & groin

Psoas abscesses may be primary or secondary

Primary psoas abscesses, which occur without associated disease of other organs, are caused by hematogenous spread of *Staphylococcus aureus*.

The most common cause is Crohn's disease.

Mycobacterium tuberculosis as the major causative organism.

159. True about incisional hernia:

- a) Incidence is about 10-15% of all abdominal wall hernia
- b) Less chance in obese person
- c) More common in woman
- d) Commonly caused by lower abdominal surgery
- e) May occur due to improper healing of abdominal incision

Correct Answer - A:C:D:E

Answer- (A) Incidence is about 10-15% of all abdominal wall hernia (C) More common in woman (D) Commonly caused by lower abdominal surgery (E) May occur due to improper healing of abdominal incision

These arise through a defect in the musculofascial layers of the abdominal wall in the region of a postoperative scar.

Incisional hernias are twice as common in women as in men.

"Incisional hernias account for 15% to 20% of all abdominal wall hernias.

Etiology-

Poor surgical technique. Inadequate fascial bites, tension on the fascial edges.

Age

Obesity

ascites,

pregnancy,

160. Which of following is/are true in accordance to revised gastric carcinoma staging:

a) All gastric tumours whose epicentre is within 5 cm of the gastrooesophageal junction and extend into the oesophagus are now classified according to the revised gastric staging

b) 5 Node involvement- N2

c) T1N2M0- Stage II

d) Peritoneal spread is MO

e) Any tumour that perforates the serosa is now classified as T4 disease

Correct Answer - B:C:E

Answer- (B) 5 Node involvement- N2 (C) T1N2M0- Stage II (E) Any tumour that perforates the serosa is now classified as T4 disease

Stage	TNM	Features
0	Ti,NOMO	Node negative; limited to mucosa
IA	T1NOMO	Node negative; invasion of lamina propria or submucosa
IB	T2NOMO T1N1M0	Node negative; invasion of muscularis propria
II	T1N2M0 T2N1M0	Node positive; invasion beyond mucosa but within wall
	T3NOMO	Node negative; extension through wall
IIIA	T2N2M0 T3N1-2M0	Node positive; invasion of muscularis propria or through wall

IIIB	T4N0-1M0	Node negative; adherence to surrounding tissue
IIIC	T4N2M0	Node positive; adherence to surrounding tissue
	T1-4N0-2	Distant metastases
	M1	

161. Dumping syndrome is characterized by all of the following except:

a) Colic

b) Tremors and giddiness

c) Hyperglycemia

d) Epigastric fullness

e) None

Correct Answer - C

Answer- C. Hyperglycemia

Dumping syndrome is a relatively rare disorder in which the stomach contents are delivered too quickly to the small intestine.

It occurs as a physiological reaction to the consumption of too much simple or refined sugar in some persons, when simple sugar exits the stomach too rapidly it attracts fluid into the upper intestine, and the blood volume decreases as it attempts to absorb the sugar.

The vasomotor symptoms comprise general weakness, pallor, sweating, palpitation and light headedness.

symptoms of gastrointestinal disturbance such as epigastric discomfort, nausea, vomiting and possibly an episode of diarrhea is observed.

The biochemical changes that occur in dumping syndrome are hyperinsulinaemia followed by hypoglycaemia

162. Which of the following is/are true Boerhaave syndrome:

a) Occur due to increase in thoracic esophageal pressure

b) More common on left lateral wall of the esophagus

c) Caused by severe vomiting

d) Causes hydro-pneumothorax as complication

e) May be misdiagnosed as myocardial infarction

Correct Answer - A:B:C:D:E

Answer- (A) Occur due to increase in thoracic esophageal pressure (B) More common on left lateral wall of the esophagus (C) Caused by severe vomiting (D) Causes hydro-pneumothorax as complication (E) May be misdiagnosed as myocardial infarction

Boerhaave's syndrome is when a person vomits against a closed glottis causing full thickness oesophageal rupture.

Pressure in oesophagus results in bursting in the lower third which is commonest site.

Clinical features-

- Severe chest pain
- Abdominal pain
- Subcutaneous emphysema
- Shock
- Hanmann's sign- crunching effect of chest
- Mackel's triad- vomiting, chest pain & subcutaneous emphysema
- Most perforations are found above the GEJ on the left lateral wall of the esophagus.

- The pressure in the esophagus rapidly increases & it bursts at its weakest point in the lower third
- MC site of perforation is at the midthoracic esophagus on the right side at the level of the azygos vein.
- May be misdiagnosed as myocardial infarction or as perforated Peptic ulcer or pancreatitis.

163. Features of Reidel thyroiditis are:

a) Presents as a goitre

b) Painful

c) Associated with IgG4 related systemic diseases

d) Fibrosis of interstitial thyroid stroma

e) Present with hypothyroidism

Correct Answer - A:C:D

Answer- (A) Presents as a goitre (C) Associated with IgG4 related systemic diseases (D) Fibrosis of interstitial thyroid stroma

It is a rare disorder that typically occurs in middle-aged women. It presents with an insidious, painless goiter with local symptoms due to compression of the esophagus, trachea, neck veins, or recurrent laryngeal nerves.

Dense fibrosis disrupts normal gland architecture.

Thyroid dysfunction is uncommon.

Treatment is directed to surgical relief of compressive symptoms.

Tamoxifen may also be beneficial

164. True about Sick euthyroid syndrome:

a) Normal TSH

b) T4 to T3 conversion impaired

c) High TSH

d) T4 high

e) Increased reverse T3

Correct Answer - A:B:E

**Answer- (A) Normal TSH (B) T4 to T3 conversion impaired
(E) Increased reverse T3**

The most common hormone pattern in sick euthyroid syndrome (SES) is a decrease in total end unbound T3 level (low T3 syndrome) with normal levels of T4 and TSH.

165. All are true about salivary gland tumor except:

a) Parotid gland is most common site of involvement

b) Warthin tumour almost always found in the parotid gland

c) Minor gland tumours are mostly malignant

d) Parotid tumours are mostly malignant

e) Superficial parotidectomy is done in pleomorphic adenoma

Correct Answer - D

Answer- D. Parotid tumours are mostly malignant

"Warthin's tumor arises almost exclusively in the parotid gland (the only tumor virtually restricted to the parotid)"

The parotid gland is the most common site for salivary tumours. Tumours involving the sublingual gland are extremely rare and are usually.

Tumours of the submandibular gland are uncommon and usually present as a slow-growing painless swelling within the submandibular triangle

166. Preferred shunt procedure in patient with portal hypertension having acceptable operative risk and adequate liver function is -

a) End to side portocaval shunt

b) End to end portocaval shunt

c) Mesocaval shunt

d) Distal splenorenal shunt

e) None

Correct Answer - D

Answer- D. Distal splenorenal shunt

Portosystemic shunt procedures such as splenorenal shunt and mesocaval shunt, may be indicated in patients with complication of portal hypertension.

Given the early occlusion rate and the need for constant surveillance, it is generally advised that TIPS should be reserved for Child C classification of cirrhosis, whereas a distal splenorenal shunt is safe, durable, preferred and effective treatment in patients with acceptable operative risk and still good liver function.

167. True about cleft lip:

a) Occurs d/t defect in fusion of frontal & nasal process

b) Only bilateral cases are associated with cleft palate

c) Repaired in neonatal period

d) Unilateral cases are more common in left side

e) All

Correct Answer - D

Answer- D. Unilateral cases are more common in left side

A midline cleft lip is present when there is failure of fusion between Medial nasal processes.

Left side unilateral cleft is common.

Commonest type of cleft lip is Combined with cleft palate.

Clefting of the lip and/or palate is felt to occur around the eighth week of embryogenesis, either by failure of fusion of the medial nasal process and the maxillary prominence or by failure of mesodermal migration and penetration between the epithelial bilayer of the face.

Repair-

Rule of tens: For increased anesthetic safety, an infant should

1. Be 10 weeks old.

2. Weigh 10 pounds.

3. Have a hemoglobin level of at least 10 mg/dL

168. Which of the following is/are true regarding management of a trauma presenting with shock:

a) Transfusion of PCV:FPP:Platelet should be in 1:1:1 ratio

b) First hemodynamic stabilize the patient, then go for CT scan

c) First go for CT scan, then stabilize the patient

d) CVP line should be placed

e) None

Correct Answer - B:D

Answer- (B) First hemodynamic stabilize the patient, then go for CT scan (D) CVP line should be placed

Hypovolemic shock is the most common type of shock seen in trauma patient & occurs secondary to acute blood loss.

The subclavian to internal jugular vein should be reserved for those patients in whom major venous intra-abdominal injuries or pelvic fractures prevent effective use of femoral approach.

Resuscitation consists of an initial bolus of 2 L of crystalloid solution.

169. All are true about acute appendicitis except:

a) Clinically indifferent from Meckel diverticulum in children

b) Lymphoid hyperplasia may causes acute appendicitis

c) Pain shift to right iliac fossa

d) Ultrasound is more diagnostic than CT scan

e) None

Correct Answer - D

Answer- D. Ultrasound is more diagnostic than CT scan

Pain is the earliest feature, which is frequently first noticed at the periumbilical region

Soon the pain shifts to the RIF and changes in character

E.coli is the most common organism; enterococci is most common.

Risk factors for perforation of appendix

Immunosuppression

Diabetes mellitus

Fecolith obstruction

Pelvic appendix

Previous abdominal surgery

Contrast-Enhanced CT (CECT) – investigation of choice specially in unclassical cases

Ultrasound is more diagnostic than CT scan

170. Which of the following is true about esophageal adenocarcinoma:

a) Obesity is a risk factor

b) Most common in middle & lower 1/3

c) Incidence in Barrett's oesophagus

d) Squamous metaplasia is a risk factor

e) Chronic gastroesophageal reflux an etiology of adenocarcinoma

Correct Answer - A:C:E

Answer- (A) Obesity is a risk factor (C) Incidence in Barrett's oesophagus (E) Chronic gastroesophageal reflux an etiology of adenocarcinoma

Risk factors for esophageal adenocarcinoma (Current Gastroenterology)

Barrett's esophagus

Gastroesophageal Reflux Disease (GERD)

Scleroderma

Smoking

Alcohol

History of colon cancer

Medications Long term use (> 5 years) of Theophylline & agonists.

The most common site of adenocarcinoma esophagus is the lower 1/3rd of esophagus

171. True about intestinal pseudoobstruction:

a) May be caused by hypokalemia

b) Bezoars can cause pseudo-obstruction

c) Neostigmine used in treatment

d) May be associated with diverticulosis

e) Colonoscopy is contraindicated

Correct Answer - A:C

Answer- (A) May be caused by hypokalemia (C) Neostigmine used in treatment

Intestinal pseudo obstruction is caused by the following

1. Disorders of the nervous system (Familial autonomic dysfunction, Hirschsprung disease, Chagas disease)
2. Diseases affecting muscles and nerves (Muscular dystrophy, SLE, Ehlers-Danlos syndrome, hypokalemia)
3. Disorders of the endocrine system (DM, Hypothyroidism, Hyperparathyroidism), and
4. Medication (Narcotics, Laxatives, Tricyclic antidepressants, Phenothiazines). Ogilvie's syndrome is acute intestinal pseudo obstruction.

172. True about sigmoid volvulus:

- a) Most common spontaneous type in adult
- b) Less fiber diet is a risk factor
- c) Treatment include resuscitation & decompression
- d) Most common type of colonic volvulus
- e) Low recurrence after conservative management

Correct Answer - A:C:D

Answer- (A) Most common spontaneous type in adult

(C) Treatment include resuscitation & decompression (D) Most common type of colonic volvulus

Most common site of volvulus

Rotation in sigmoid volvulus nearly always occur in anticlockwise direction

PREDISPOSING FACTOR:

- Age
- Institutionalized or neurologically impaired or psychiatric patients
- Band of adhesion
- Long pelvic meso colon with Narrow attachment
- The initial management is resuscitation followed by endoscopic decompression and detorsion.

173. True about diverticular disease of colon:

a) Right side more common

b) Sign & symptoms indistinguishable from irritable bowel syndrome

c) Profuse & painless bleeding

d) Sigmoid is most common site

e) None

Correct Answer - B:C:D

Answer- (B) Sign & symptoms indistinguishable from irritable bowel syndrome (C) Profuse & painless bleeding (D) Sigmoid is most common site

Diverticula most commonly affect the sigmoid colon.

Diverticula are most often asymptomatic (diverticulosis).

Present clinically with sepsis or haemorrhage.

Complications of Diverticular Disease-

Pain and inflammation (Diverticulitis).

Perforation

Intestinal obstruction

Haemorrhage

Fistula formation

Hemorrhage from colonic diverticula is typically painless & profuse.

174. Which of the following is true about primary lymphoedema:

a) May be congenital

b) Lymphoedema congenita more commonly occur bilaterally

c) Condition improves with massage

d) Lymphatic hyperplasia

e) All

Correct Answer - A:B:C

Answer- (A) May be congenital (B) Lymphoedema congenita more commonly occur bilaterally (C) Condition improves with massage

It is due to an inherited abnormality of the lymphatic system, sometimes termed 'congenital lymphatic dysplasia'.

Primary lymphoedema is much more common in the legs than the arms.

Lymphoedema congenita is more common in males.

Lymphoedema praecox (onset from 2 to 35 years) is three times more common in females

175. All are true about thymoma except:

a) MC tumor in anterior mediastinum

b) Treatment is thymectomy

c) Symptomatic cases present as endocrine abnormalities

d) May be associated with myasthenia gravis

e) Associated with thyroiditis

Correct Answer - C

Answer- C. Symptomatic cases present as endocrine abnormalities

Characteristic Syndromes

Myasthenia Gravis (most common)

Acquired Hypogammaglobulinemia (10%)

Pure Red Cell Aplasia

176. True about invasive thymoma:

a) Benign in nature

b) May be associated with EBV

c) Malignant in nature

d) Epithelial cells are most commonly of the cortical variety

e) None

Correct Answer - A:B:D

Answer- (A) Benign in nature (B) May be associated with EBV (D) Epithelial cells are most commonly of the cortical variety

Invasive thymoma refers to a tumor that is cytologically, benign but locally invasive.

- These tumors are much more likely to metastasize.
- The epithelial cells are most commonly of the cortical variety, with abundant cytoplasm and rounded vesicular nuclei, and are usually mixed with numerous thymocytes.
- By definition, invasive thymomas Penetrate through the capsule into surrounding structures.

177. True about cystosarcoma phylloides:

a) Usually bilateral

b) Usually occur in female over age of 40

c) Not involve nipple-areola complex

d) Treatment is mastectomy of malignant lesions

e) All are benign in nature

Correct Answer - B:C:D

Answer- (B) Usually occur in female over age of 40 (C) Not involve nipple-areola complex (D) Treatment is mastectomy of malignant lesions

It is a malignant tumour

It often metastasises to axillary nodes

It is treated by radical mastectomy

Usually occur in women over the age old 40 years.

178. True about anorectal abscess:

a) Ischiorectal is most common type

b) Primary modality of treatment is antibiotic without drain

c) Rupture can cause fistula formation

d) Common in diabetics

e) Drainage of pus with antibiotics is mainstay of treatment

Correct Answer - C:D:E

Answer- (C) Rupture can cause fistula formation (D) Common in diabetics (E) Drainage of pus with antibiotics is mainstay of treatment

There are four types- abscess-perianal (most common), ischiorectal, submucous & pelvirectal.

Anorectal abscess can rupture inside as well as outside resulting in a fistula.

Treatment is drainage of pus in first instance together with appropriate antibiotics.

179. Which of the following indicate poor prognosis in both Ranson & Glasgow scale of acute pancreatitis:

a) Albumin

b) Alanine aminotransferase

c) Aspartate aminotransferase

d) Lactate dehydrogenase

e) Base deficit

Correct Answer - A:B:C:D

Answer- (A) Albumin (B) Alanine aminotransferase (C) Aspartate aminotransferase (D) Lactate dehydrogenase

Early predictors of severity at 48 hours included 3 Ranson's signs and APACHE II score 8.

A recent scoring system for the early prediction of mortality was developed in acute pancreatitis. This scoring system known as the Bedside Index of Severity in Acute Pancreatitis (BISAP), incorporates five clinical and laboratory parameters obtained within the first 24 hours of hospitalization. BUN >25, Impaired mental status, SIRS, Age >60 years, Pleural effusion on radiography. Presence of three or more of these factors was associated with increased risk for in-hospital mortality.

Modified Glasgow/PANCREAS score

- PaO₂ <8kPa (60mmhg)
- Age > 55 years
- Neutrophils: WBC>15×10⁹/l

- Calcium < 2mmol/l
- Renal function: (Urea > 16mmol/l)
- Enzymes: (AST/ALT>200 iu/Lor LDH > 600 iu/L)
- Albumin <32g/l
- Sugar: (Glucose >10mmol/L)

180. A patient has h/o hypertension & diabetes. The mechanism of higher chance of ulcer in this patient is due to:

a) Hyperglycemias suppress immunity

b) Vascular insufficiency

c) Atherosclerotic changes

d) Venous stasis

e) Tropic skin changes

Correct Answer - A:B:C:E

Answer- (A) Hyperglycemias suppress immunity (B) Vascular insufficiency (C) Atherosclerotic changes (E) Tropic skin changes

Trophic change from peripheral neuropathy, ischaemia as a result of atheroma, and low resistance to infection because of excess sugar in the Tissue.

Neuropathy, abnormal foot biomechanics, peripheral arterial disease (PAD), and poor wound healing.

181. Glasgow coma scale E3M4V5 represents:

a) Spontaneous eye opening

b) Eye opening with pain stimulus

c) Incomprehensible sound

d) Oriented conversation

e) Decorticate posturing

Correct Answer - D

Answer- (D) Oriented conversation

Domain	Response	Score
Eye opening	Spontaneous	4
	To speech	3
	To pain	2
	None	1
Best verbal response	Oriented	5
	Confused	4
	Inappropriate	3
	Incomprehensible	2
Best motor response	None	1
	Obeying	6
	Localizing	5
	Withdrawal	4
	Flexing	3
Total score	Extending	2
	None	1
	Deep coma or death	3
	Fully alert and oriented	15



182. Feature of 3 degree burn:

a) Pain present

b) Transudation of fluid present

c) Whole dermis destroyed

d) Erythematous in appearance

e) Blister formed

Correct Answer - C

Answer- C. Whole dermis destroyed

The whole of the dermis is destroyed of the burns.

- Clinically, they have a hard, leathery feel, The appearance can vary from that similar to the patient's normal skin to charred black depending upon the intensity of the heat. . There is no capillary return after, thrombosed vessels can be seen under the skin.
- These burns are completely anaesthetised: a needle can be stuck deep into the dermis without any pain or bleeding.

183. Complication (s) of Salivary gland operation:

a) Subcutaneous fistula

b) Opposite gland compensatory hypertrophy

c) Gustatory sweating

d) Facial Nerve damage

e) All

Correct Answer - A:C:D

Answer- (A) Subcutaneous fistula (C) Gustatory sweating (D) Facial Nerve damage

Complications of Parotid Gland Surgery-

- Temporary facial nerve weakness
- Transection of the facial nerve and permanent facial weakness
- Sialocele
- Facial numbness
- Permanent numbness of the ear lobe associated with great auricular nerve transection
- Frey's syndrome (Gustatory sweating)

Complications of Submandibular Gland Excision

- Marginal mandibular nerve injury;
- Lingual nerve injury;
- Hypoglossal nerve injury

Complications of parotidectomy-

- Flap necrosis
- Facial nerve palsy
- Fluid collection

- Salivary fistula
- Frey's syndrome

184. True about Typhoid ulcer:

- a) Perforation is common in 2nd & 3rd week after onset of typhoid fever
- b) Perforation may present at multiple site
- c) Commonly involve jejunum
- d) Commonly involve ileum
- e) Peritoneal lavage is contraindicated for perforated ulcer

Correct Answer - A:B:D

Answer- (A) Perforation is common in 2nd & 3rd week after onset of typhoid fever (B) Perforation may present at multiple site (D) Commonly involve ileum

Characteristic Features of Typhoid Ulcers Most common site is mucosa of small intestine (Ileum) in region of lymphoid patches (Payer's patches)

Ulcers are oval

Ulcers are arranged longitudinally (Longitudinal ulcers)

Lie in the long axis of the intestine along the antimesenteric border

Ulcers may be single or multiple

Ulcers may erode and cause complications (Bleeding/perforation)

185. Punched out ulcer is/are seen in:

a) Arterial ulcer

b) Venous ulcer

c) Tubercular ulcer

d) Basal cell carcinoma

e) Gummatous ulcer

Correct Answer - A:E

Answer- (A) Arterial ulcer (E) Gummatous ulcer

Punched out edge: It is mostly seen in gummatous ulcer or in a deep trophic ulcer.

Arterial ulcer- Thae ulcer tends to be punched out

Gummatous ulcers, which occurs in tertiary syphilis, have punched-out indolent edge.

186. Which of the following is/are true regarding renal transplantation except:

a) Curvilinear incision is made in lower quadrant

b) Transplanted kidney is placed in retroperitoneal position

c) Recipients kidney is first removed from renal fossa to make space for donor kidney

d) Anastomosis of external iliac artery with renal artery

e) Donor renal vein is anastomosed with external iliac vein

Correct Answer - C

Answer- (C) Recipients kidney is first removed from renal fossa to make space for donor kidney

A lower quadrant curvilinear (Gibson) incision is made, and the iliac vessels are exposed through a retroperitoneal approach.

The renal artery can be anastomosed end-to-end to the internal iliac. An end-to-side anastomosis of the renal artery to the external iliac artery is more frequently done.

The ureter, which is kept reasonably short to avoid the risk of distal ischaemia, is then anastomosed to the bladder.

187. Which of the following plan of management is/are correct with regard to Cleft lip & cleft palate in children:

a) Unilateral lip only-1 year of age

b) Bilateral lip-1 year of age

c) Bilateral lip should be repaired at 5 month

d) Both soft & hard palate at 1 year in one setting

e) Cleft lip and soft palate at 5-6 months & hard palate at 15-18 months of age

Correct Answer - C:E

Answer- (C) Bilateral lip should be repaired at 5 month (E) Cleft lip and soft palate at 5-6 months & hard palate at 15-18 months of age

Clefting of the lip and/or palate is felt to occur around the eighth week of embryogenesis, either by failure of fusion of the medial nasal process and the maxillary prominence or by failure of mesodermal migration and penetration between the epithelial bilayer of the face.

Repair

Rule of tens: For increased anesthetic safety, an infant should

1. Be 10 weeks old.
2. Weigh 10 pounds.
3. Have a hemoglobin level of at least 10 mg/dL.

188. Which of the following is/are features of Testicular torsion which is not present in epididymoorchitis:

a) Redness of skin

b) Elevation of testis worsen pain

c) Doppler ultrasound scan show absence of the blood supply to the affected testis

d) Fever

e) Dysuria

Correct Answer - B:C

Answer- (B) Elevation of testis worsen pain (C) Doppler ultrasound scan show absence of the blood supply to the affected testis

Epididymoorchitis

- The initial symptom is pain & swelling of epididymis along with fever, malaise & chills
- Scrotal wall becomes red, oedematous & glossy

Testicular torsion

- The scrotum is swollen & tendon. The scrotum may also be normal or red & oedematous.
- The onset of redness of the skin and a mild pyrexia.
- Elevation of the testis reduces the pain in epididymoorchitis and makes it worse in torsion.
- Doppler ultrasound scan will confirm the absence of the blood supply to the affected testis.

189. Which of the following is/are true about primary hyperparathyroidism:

a) Associated with MEN I & II

b) Increase risk of renal stone

c) About 50 gram of gland tissue can be left during surgery to prevent hypocalcemia

d) Cause benign hypertension

e) Mc sporadic cause is hyperplasia

Correct Answer - A:B:C

Answer- (A) Associated with MEN I & II (B) Increase risk of renal stone (C) About 50 gram of gland tissue can be left during surgery to prevent hypocalcemia

Primary hyperparathyroidism is due to excess PTH secretion from a single parathyroid adenoma, hyperplasia, and carcinoma.

Primary hyperparathyroidism MEN 1, MEN2A, isolated familial HPT, and familial HPT with jaw-tumor syndrome.

Inherited in an autosomal dominant.

The classic quartet of stones, bones, abdominal groans and psychic moans renal calculi and calcinosis, pancreatitis and psychiatric disorder develops.

190. Suture number 2-0 corresponds to diameter of:

a) 0.21 mm

b) 0.24 mm

c) 0.27mm

d) 0.30 mm

e) 0.33 mm

Correct Answer - D

Answer- (D) 0.30 mm

The available sizes and diameters of suture are:

- 6-0 = 0.07 mm
- 5-0 = 0.10 mm
- 4-0 = 0.15 mm
- 3-0 = 0.20 mm
- 2-0 = 0.30 mm
- 0 = 0.35 mm
- 1 = 0.40 mm
- 2=0.5mm

191. Psammoma bodies is/are seen in:

a) Medullary carcinoma of thyroid

b) Ependymoma

c) Papillary carcinoma thyroid

d) Follicular carcinoma of thyroid

e) Meningioma

Correct Answer - C:E

Answer- (C) Papillary carcinoma thyroid (E) Meningioma

Psammoma bodies can be seen in :?

- Papillary carcinoma of thyroid.
- Renal cell carcinoma (papillary type)
- Serous cystadenoma of ovary
- Meningioma
- Malignant mesothelioma (Peritoneal & pleural)
- Somatostatinoma (Pancreas)
- Prolactinoma (Pituitary)
- Endometrial papillary serous cystadenocarcinoma

192. Which of the following is/are correct regarding eczema of breast & Paget's disease of nipple:

a) Generally eczema is unilateral whereas paget's disease is bilateral

b) Eczema may be associated with lactation

c) Nipple may be destroyed in Paget's disease while it normally intact in eczema

d) Inversion of nipple may occur in Paget's disease

e) Associated with breast lump in eczema

Correct Answer - B:C:D

Answer- (B) Eczema may be associated with lactation

(C) Nipple may be destroyed in Paget's disease while it normally intact in eczema (D) Inversion of nipple may occur in Paget's disease

Paget's disease of nipple-

- Occurs almost exclusively in women.
- May occur at any age from 24 to 84, although it is most common around the menopause.
- Almost always associated with underlying carcinoma of the breast
- Unilateral, persistent eczematous-type change of the nipple with erythema and scaling.
- Itching or burning sensation.
- Destruction of the nipple.

193. Correct combination (s) of Hernia with their content:

a) Littre hernia: Meckle's diverticulum

b) Richter's hernial-small intestine

c) Pantaloon-hernial sac on either side of inferior gastric artery

d) Hernia-en-glissade-urinary bladder

e) Maydl's hernia-intestine

Correct Answer - A:B:C:D:E

Answer- (A) Littre hernia: Meckle's diverticulum (B) Richter's hernial-small intestine (C) Pantaloon-hernial sac on either side of inferior gastric artery (D) Hernia-en-glissade-urinary bladder (E) Maydl's hernia-intestine

Richter's hernia is a hernia in which the sac contains only a portion of the circumference of the intestine.

Maydl's Hernia - normal-looking loops of intestine are present in the sac

Sliding Hernia (Hernia-en-glissade)- on either side by a portion of the bladder

Saddle-bag, pantaloon hernia- This type of hernia consists of two sacs that staddle the inferior epigastric artery

Littre hernia- A hernia containing a Meckel's diverticulum

194. True about duodenal diverticula:

- a) Most common of the GIT diverticula
- b) Commonly occur on medial border
- c) Often present in periampullary region
- d) It should be treated aggressively due to high malignant potential
- e) It can cause pancreatitis by producing obstruction at the opening of the duct

Correct Answer - B:C:E

Ans. (B) Commonly occur on medial border (C) Often present in periampullary region (E) It can cause pancreatitis by producing obstruction at the opening of the duct

Diverticula of the duodenum representing the second most common site for diverticulum formation after the colon.

Duodenal diverticula occur twice as often in women.

Two thirds to three fourths of duodenal diverticula are found in the periampullary region.

Major complications of duodenal diverticula include obstruction of the biliary or pancreatic ducts.

Hemorrhage; perforation; and rarely, blind loop syndrome

Only those diverticula associated with the ampulla of Vater are significantly related to complications of cholangitis and pancreatitis.

Surgical treatment is required for complications & rarely for persistent symptoms.

195. Which of the following is true about esophagus except:

a) Serosa not present

b) Middle & lower third made up of striated muscle

c) Lower oesophageal sphincter is a zone of relatively high pressure

d) In achalia cardia LOS tone is increased so that food can not pass below

e) It has side to side & antero-posterior curvatures

Correct Answer - B

Answer-(B) Middle & lower third made up of striated muscle

Epithelium is stratified squamous non-keratinized epithelium.

Muscularis mucosa contains only longitudinal layer and no circular layer.

Mucosa is the toughest and strongest layer.

Serosa is absent.

Muscularis externa is made up of skeletal muscle fibers only in the upper third, smooth muscles only in the lower third and both types of muscle fibers in middle third. At upper end the longitudinal coat splits into two bundles and the triangular interval between them is called Laimer's tringle which is filled with circular muscle fiber

196. Which of the following increases risk of urinary stones:

a) Increased urinary citrate

b) 1st Calcium level in blood

c) Hypervitaminosis A

d) Hypoparathyroidism

e) Decrease in urinary colloid

Correct Answer - B:C:E

**Answer- (B) 1st Calcium level in blood (C) Hypervitaminosis A
(E) Decrease in urinary colloid**

Deficiency of vitamin A

Altered urinary solutes and colloids

Decreased urinary citrate

Renal infection

Inadequate urinary drainage and urinary stasis

Prolonged immobilization

Hyperparathyroidism

197. Which of the following is true about digital rectal examination:

a) Index finger is used

b) In BPH rectal mucosa is free whereas in prostate cancer mucosa of rectum is adhered

c) Puborectalis is felt anteriorly

d) Anal sphincter length cannot be assessed

e) None

Correct Answer - A:B

Answer- (A) Index finger is used (B) In BPH rectal mucosa is free whereas in prostate cancer mucosa of rectum is adhered

During digital rectal examination in a male, the finger sequentially palpates on the anterior wall, the prostate gland, the seminal vesicles, and the rectovesical pouch.

Posteriorly is the hollow of the sacrum and the coccyx.

On the anterior wall of the female, the uterine cervix, the uterine fundus (if retroverted), and the rectouterine pouch will be felt.

The rectal wall is palpated for masses and narrowing of the lumen.

198. All are true about BPH except:

- a) Submucosal gland hyperplasia in transition zone
- b) Penile urethra elongation
- c) Prostatic urethra may be compressed
- d) Less than 20ml/second peak flow rate is strong indication for TURP
- e) BPH occur due to growth in peripheral zone of prostate

Correct Answer - B:D:E

Answer- (B) Penile urethra elongation (D) Less than 20ml/second peak flow rate is strong indication for TURP (E) BPH occur due to growth in peripheral zone of prostate

Benign Prostatic Hyperplasia (BPH)

Prostate it is divided into the peripheral zone (PZ), which lies mainly posteriorly and from which most carcinomas arise, and a central zone (CZ).

There is also a periurethral transitional zone (TZ), from which most benign prostatic hyperplasia (BPH) arises.

BPH typically affects the submucous group of glands in the transitional zone.

A flow rate $< 10 \text{ ml s}^{-1}$ will be sufficient for most urologists to recommend treatment.

199. True statement (s) about laproscopic cholecystectomy:

a) Cosmetically better

b) Bleeding is more common in open cholecystectomy than laproscopic cholecystectomy

c) Veress needle is used in closed technique

d) Laproscopic with attached video camera is inserted through umbilical port

e) Previous abdominal surgery is absolute contraindication

Correct Answer - A:C:D

Answer- (A) Cosmetically better (C) Veress needle is used in closed technique (D) Laproscopic with attached video camera is inserted through umbilical port

Initially, a small incision is made in the upper edge of the umbilicus. With the closed technique a special hollow insufflation needle (Veress needle) that is spring-loaded with a retractable cutting outer sheath is inserted into the peritoneal cavity and used for insufflation. Bleeding has been the most common cause for conversion to an open procedure.

200. Bilateral parotid swelling is/are seen in all except :

a) Mump

b) Epstein-Barr virus

c) Sarcoidosis

d) Brucella

e) Sjogren syndrome

Correct Answer - D

Answer- (D) Brucella

Viral infections

Mumps

Influenza

Epstein-Barr virus

Coxsackievirus A

Cytomegalovirus

HIV HCV

- Sarcoidosis
- Sjogren's syndrome
- Metabolic disorders
- Diabetes mellitus
- Chronic pancreatitis
- Hepatic cirrhosis

201. Common tumour(s) found in anterior mediastinum:

a) Teratoma

b) Cervical thymoma

c) Lymphoma

d) Schwannoma

e) Thyroid carcinoma

Correct Answer - A:B:C

Answer- A, Teratoma B, Cervical thymoma C, Lymphoma Thymoma

- Teratoma
- Parathyroid adenoma
- Bronchogenic cyst
- Aneurysms
- Lymphoma
- Lipoma
- Spinal lesions
- Goitre

202. True about thyroid tumor:

a) Follicular -lymphatic metastasis more common than papillary

b) Papillary- blood metastasis more common than follicular

c) Hurthle- lymphatic spread is common

d) Hurthle-less aggressive than follicular carcinoma

e) Follicular- invasion of capsule & vascular spaces in capsular region

Correct Answer - D:E

Answer- D,Hurthle-less aggressive than follicular carcinoma E, Follicular- invasion of capsule & vascular spaces in capsular region

Hurthle cell carcinoma is a subtype of follicular carcinoma.

The tumor contains an abundance of oxyphilic cells, or oncocytes.

It appears in an older age group.

Higher chance of spread to lymph node compared to follicular carcinoma.

Treatment is surgical.

Follicular Carcinoma-

Microscopically, there is invasion of the capsule and of the vascular spaces in the capsular region.

Blood borne metastases are more common.

**203. Burn involving one lower limbs in adult
correspondence to area:**

a) 4.5 %

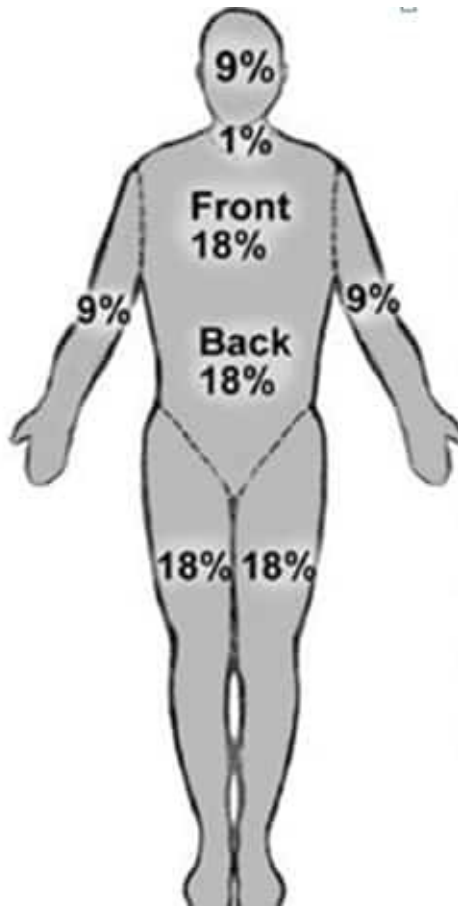
b) 9 %

c) 13.5%

d) 18%

e) 27%

Correct Answer - D
Answer- (D) 18%



Adult body Part	% of total BSA
Head	9%
Neck	1%
Leg	18%
Anterior trunk	18%
Posterior trunk	18%
Arm	9%

204. True about physiological hernia

- a) Herniation of Foregut
- b) Herniation of Foregut + midgut
- c) Herniation of Midgut
- d) Goes back around 4 week after herniation
- e) Goes back around 10 week of fetus age

Correct Answer - C:D:E

Answer- C,Herniation of Midgut D,Goes back around 4 week after herniation E,Goes back around 10 week of fetus age

It is a natural phenomenon that occurs in early pregnancy.

It usually occurs from around 6-8 weeks up until 13 week in-utero, after which the bowel returns to the abdominal cavity.

At approximately 10-11 weeks the abdomen enlarges and the intestines return to the abdominal cavity.

At -8 weeks gestational age and is due to a number of factors including Rapid growth of the cranial end of the midgut (which will form the small intestine).

205. Inguinal hernial surgery may be complicated by :

a) Testicular atrophy

b) Urinary retention

c) Impotence

d) Constipation

e) Pain

Correct Answer - A:B:E

**Answer- A,Testicular atrophy B,Urinary retention E, Pain
Complication during surgery**

- Injury to iliac vessel-the most serious but rare
- Injury to urinary bladder

Early postoperative period

- Pain-Pain is common due to incision in the skin & some degree of retraction of structures such as inguinal ligament downwards & conjoint tendon upwards
- Bleeding
- Urinary retention is common, more so in males
- Abdominal distension

Intermediate- between 3 & 7 ila*

- Seroma
- Wound infection

Late

- Inguinodynia
- Testicular atrophy

206. Indication of circumcision includes:

a) Hypospadias

b) Epispadias

c) Phimosis

d) Balanitis

e) Balanoposthitis

Correct Answer - C:D:E

Answer- C,Phimosis D,Balanitis E, Balanoposthitis

Indication- religious & phimosis

Medical indications for circumcision in boys include-

1. recurrent attacks of balanoposthitis
2. recurrent urinary tract infections
3. In adults, inability to retract for intercourse, abnormally tight frenulum, balanitis

207. All are true about squamous cell carcinoma of skin except:

a) It is called marjolin ulcer when develops in scar

b) Radiotherapy may be used in treatment

c) Hematogenous spread is common & occur early

d) May develop in chronic ulcer

e) Lymphatic spread is chief way of spreading

Correct Answer - C

Answer- (C) Hematogenous spread is common & occur early

SCC is a malignant tumour of keratinising cells of the epidermis or its appendages.

Also arises from the stratum basale of the epidermis.

SCC is the second most common form of skin cancer.

Usually affects the elderly.

SCC is also associated with chronic inflammation.

When a SCC appears in a scar it is known as a Marjolin' ulcer.

Associated with UV light exposure, chronic inflammation and viral infection.

"SCC is treated by wide excision or radiotherapy.

Lymphatic spread is the chief method of spread even though it occurs relatively late.

208. True about Buerger disease

- a) Affects larger artery only
- b) Younger males are more commonly affected
- c) Phlebitis migrans is characteristic
- d) Cold intolerance
- e) Veins may involved

Correct Answer - B:C:E

Answer- B,Younger males are more commonly affected C,Phlebitis migrans is characteristic E,Veins may involved

Also called as Thromboangiitis Obliterans

It is a inflammatory occlusive vascular disorder involving small and medium sized arteries and veins in upper and lower extremities.

It involves tibial and radial arteries and sometimes secondarily extending to veins and nerves of extremities.

The clinical features of thromboangiitis obliterans includes a triad of claudication of the affected extremity, Raynaud's phenomenon, and migratory superficial vein thrombophlebitis.

209. True about ulcer:

a) Arterial ulcer-painless

b) Venous ulcer-penetrates deep fascia

c) Arterial ulcer- punched out

d) Neuropathic ulcer- may involve bone

e) Trophic ulcer- Puched out edge

Correct Answer - C:D:E

Answer- C,Arterial ulcer- punched out D,Neuropathic ulcer- may involve bone E,Trophic ulcer- Puched out edge

Puched out edge: It is mostly seen in gummatous ulcer or in a deep trophic ulcer.

Arterial ulcer- Thae ulcer tends to be punched out

Gummatous ulcers, which occurs in tertiary syphilis, have punched-out indolent edge.

Neurogenic ulcer- it burrows deep inside, may involve bone & also called as perforating ulcer.

Venous ulcer- Depth-superficial, does not penetrate deep fascia.

210. True about Amoebic liver abscess:

a) More common in right lobe

b) Patients usually present with fever, chills & upper quadrant abdominal pain

c) Usually multiple

d) Abscess cavity contains anchovy sauce -like fluid

e) Most commonly presents with jaundice

Correct Answer - A:B:D

Answer- A,More common in right lobe B,Patients usually present with fever, chills & upper quadrant abdominal pain D,Abscess cavity contains anchovy sauce -like fluid

Amoebic liver abscess is the most frequent extraintestinal manifestation of *Entamoeba histolytica* infection.

The right lobe (posterior superior quadrant) of the liver is more commonly affected than the left lobe.

The abscess contains a chocolate-colored fluid that resembles anchovy paste and consists predominantly of necrotic hepatocytes.

Anorexia, fever, night sweats, malaise, cough and weight loss.