Medicine Collection

Question Bank with Answers & Explanations

Generated on April 18, 2026

90 Topics • 2055 Questions

Need help or updates?
■ *Click here to contact the creator of this PDF*

Viewer Guide

Navigation Tips:

- Use the outline/bookmarks pane (left side in most PDF viewers) to jump between sections.
- Click links at the bottom of each question to switch between Part A (questions) and Part B (answers).
- Master Index links take you to topic parts.

Viewer Settings:

- Adobe Reader: View > Show/Hide > Navigation Panes > Bookmarks
- Chrome: Install PDF viewer extension if needed.
- Mobile: Use apps like Adobe Acrobat or Xodo for outline support.

■ *For queries & support: Message @Neet_pg_bot on Telegram*

DIRECTORY EXPLORER

Click a folder below to open it.

» **01_Cardiology**

» **02_Emergency Medicine**

» **03_Endocrinology**

» **04_Nephrology**

» **05_Gastrointestinal System**

» **06_Hematology**

» **07_Neurology**

» **08_Rheumatology**

» **09_Hepatobiliary System**

» **10_Pulmonology**

» **11_Infections**

» **12_Oncology**

» **13_Miscellaneous Topics**

» **14_Miscellaneous**

» 01_Cardiology

« Back to Parent Directory

Path: 01_Cardiology

• 001 Valvular Heart Disease	***Questions***	***Answers***
• 002 Heart Sounds And Murmurs	***Questions***	***Answers***
• 003 Takotsubo Brugada Syndrome Rhd And Infective Endocarditis	***Questions***	***Answers***
• 004 Ecg And Arrhythmias	***Questions***	***Answers***
• 005 Ischemic Heart Disease	***Questions***	***Answers***
• 006 Systemic Htn Pulmonary Htn	***Questions***	***Answers***
• 007 Chf Bbb Tachycardia Bradycardia And Heart Block	***Questions***	***Answers***
• 008 Diseases Of The Pericardium And Cardiomyopathies	***Questions***	***Answers***
• 009 Previous Year Questions	***Questions***	***Answers***

» 02_Emergency Medicine

« Back to Parent Directory

Path: 02_Emergency Medicine

• 010 Emergency Cardiovascular Care Protocols Bcls Acls Mechanical Ventilation And Causes Of Pulseless Electrical Activity	***Questions***	***Answers***
• 011 Massive Transfusion Protocol Ards Snakebite Aha Updates Altitude Sickness	***Questions***	***Answers***
• 012 Previous Year Questions	***Questions***	***Answers***

» 03_Endocrinology

« Back to Parent Directory

Path: 03_Endocrinology

• 013 Diabetes Mellitus-I	***Questions***	***Answers***
• 014 Diabetes Mellitus-Ii	***Questions***	***Answers***
• 015 Dka And Hyperosmolar Coma Pancreatic Neuroendocrine Tumors	***Questions***	***Answers***
• 016 Disorders Of Adrenal Gland And Cushing Syndrome - I	***Questions***	***Answers***
• 017 Diseases Of Thyroid	***Questions***	***Answers***
• 018 Disorders Of Parathyroid Gland And Men Syndromes	***Questions***	***Answers***
• 019 Diseases Of Anterior Pituitary	***Questions***	***Answers***
• 020 Previous Year Questions	***Questions***	***Answers***

» 04_Nephrology

« Back to Parent Directory

Path: 04_Nephrology

• 021 Disorders Of Electrolyte Imbalance	***Questions***	***Answers***
• 022 Electrolyte Imbalance	***Questions***	***Answers***
• 023 Ciliopathies Pkd Ttp	***Questions***	***Answers***
• 024 Kidney Urine Analysis	***Questions***	***Answers***
• 025 Aki Diabetic Nephropathy Renal Stones	***Questions***	***Answers***
• 026 Chronic Kidney Disease	***Questions***	***Answers***
• 027 Renal Tubular Acidosis And Renal Artery Stenosis	***Questions***	***Answers***
• 028 Nephrotic And Nephritic Syndromes	***Questions***	***Answers***
• 029 Previous Year Questions	***Questions***	***Answers***

» 05_Gastrointestinal System

« Back to Parent Directory

Path: 05_Gastrointestinal System

• 030 Zollinger Ellison Syndrome	***Questions***	***Answers***
• 031 Inflammatory Bowel Disease-I	***Questions***	***Answers***
• 032 Inflammatory Bowel Disease-Ii	***Questions***	***Answers***
• 033 Irritable Bowel Syndrome	***Questions***	***Answers***
• 034 Peptic Ulcer And Gastrointestinal Bleeding	***Questions***	***Answers***
• 035 Diarrhea Malabsorption Syndromes - I	***Questions***	***Answers***
• 036 Previous Year Questions	***Questions***	***Answers***

» 06_Hematology

« Back to Parent Directory

Path: 06_Hematology

• 037 Chronic Lymphocytic Leukemia	***Questions***	***Answers***
• 038 Chronic Myeloid Leukemia	***Questions***	***Answers***
• 039 Acute Myeloid Leukemia	***Questions***	***Answers***
• 040 Acute Lymphocytic Leukemia	***Questions***	***Answers***
• 041 Multiple Myeloma Plasma Cell Disorders	***Questions***	***Answers***
• 042 Hodgkin S And Non-Hodgkin S Lymphoma	***Questions***	***Answers***
• 043 Thalassemia And Hereditary Spherocytosis	***Questions***	***Answers***
• 044 Sickle Cell Disease G6Pd Deficiency And Other Hemolytic Anemias	***Questions***	***Answers***
• 045 Platelet Disorders And Hematology Images	***Questions***	***Answers***
• 046 Blood Components And Complications Of Blood Transfusion	***Questions***	***Answers***
• 047 Previous Year Questions	***Questions***	***Answers***

» 07_Neurology

« Back to Parent Directory

Path: 07_Neurology

• 048 Epilepsy And Eeg	***Questions***	***Answers***
• 049 Basics Of Cranial Nerves Mechanical Thrombectomy Stroke	***Questions***	***Answers***
• 050 Stroke Tia And Image Based Questions	***Questions***	***Answers***
• 051 Guillian Barre Syndrome And Alzheimer S Disease	***Questions***	***Answers***
• 052 Syringomelia Conus Medullaris Channelopathies And Sah	***Questions***	***Answers***
• 053 Myasthenia Gravis	***Questions***	***Answers***
• 054 Multiple Sclerosis Neuromyelitis Optica Spectrum Disorder And Als	***Questions***	***Answers***
• 055 Cns Hemorrhage Headaches And Migraine	***Questions***	***Answers***
• 056 Parkinsonism And Parkinson S Disease	***Questions***	***Answers***
• 057 Meningitis And Cns Infections	***Questions***	***Answers***
• 058 Intracranial Pathologies Icp Brain Death Tumors And Neurocysticercosis	***Questions***	***Answers***
• 059 Previous Year Questions	***Questions***	***Answers***

» 08_Rheumatology

« Back to Parent Directory

Path: 08_Rheumatology

• 060 Vasculitis Syndromes - I	***Questions***	***Answers***
• 061 Sle Anti Phospholipid Syndrome	***Questions***	***Answers***
• 062 Rheumatoid Arthritis	***Questions***	***Answers***
• 063 Crystal Arthropathy	***Questions***	***Answers***
• 064 Scleroderma And Sjogren Syndrome	***Questions***	***Answers***
• 065 Autoimmune And Inflammatory Diseases In Medicine	***Questions***	***Answers***
• 066 Previous Year Questions	***Questions***	***Answers***

» 09_Hepatobiliary System

« Back to Parent Directory

Path: 09_Hepatobiliary System

• 067 Viral Hepatitis Nafld Ali	***Questions***	***Answers***
• 068 Hepatorenal And Hepatopulmonary Syndrome And Alcoholic Hepatitits	***Questions***	***Answers***
• 069 Autoimmune Liver Disease Cholestasis Hepatotoxicity	***Questions***	***Answers***
• 070 Liver Cirrhosis And Its Complications	***Questions***	***Answers***
• 071 Wilson Disease And Hemochromatosis	***Questions***	***Answers***
• 072 Hereditary Hyperbilirubinemia Budd Chiari Syndrome	***Questions***	***Answers***
• 073 Previous Year Questions	***Questions***	***Answers***

» 10_Pulmonology

« Back to Parent Directory

Path: 10_Pulmonology

• 074 Cystic Fibrosis Obstructive Sleep Apnea	***Questions***	***Answers***
• 075 Pulmonary Embolism Dvt And Fat Embolism	***Questions***	***Answers***
• 076 Bronchiectasis Pneumonia	***Questions***	***Answers***
• 077 Bronchial Asthma And Copd	***Questions***	***Answers***
• 078 Tuberculosis	***Questions***	***Answers***
• 079 Respiratory Physiology And Failure	***Questions***	***Answers***
• 080 Interstitial Lung Disease Pulmonary Alveolar Protienosis Pneumoconiosis	***Questions***	***Answers***
• 081 Pleural Effusion And Pneumothorax	***Questions***	***Answers***
• 082 Abg Analysis - I	***Questions***	***Answers***
• 083 Images In Pulmonology	***Questions***	***Answers***
• 084 Previous Year Questions	***Questions***	***Answers***

» 11_Infections

« Back to Parent Directory

Path: 11_Infections

• 085 Puo Dengue Nipah Zika And Pneumocystis Jirovecii	***Questions***	***Answers***
• 086 Aspergillosis Aids And Covid-19	***Questions***	***Answers***
• 087 Previous Year Questions	***Questions***	***Answers***

» 12_Oncology

« Back to Parent Directory

Path: 12_Oncology

	Questions	*Answers*
• 088 Previous Year Questions		

» 13_Miscellaneous Topics

« Back to Parent Directory

Path: 13_Miscellaneous Topics

	Questions	*Answers*
• 089 Previous Year Questions		

» 14_Miscellaneous

« Back to Parent Directory

Path: 14_Miscellaneous

	Questions	*Answers*
• 090 Previous Year Questions		

Part A — All Questions

• [01_Cardiology] 001 Valvular Heart Disease

« Back to Folder Directory

[01_Cardiology] 001 Valvular Heart Disease — Quick Jump

Q1 (p. 18)	*Q2 (p. 18)*	*Q3 (p. 21)*	*Q4 (p. 21)*	*Q5 (p. 21)*	*Q6 (p. 22)*
Q7 (p. 22)	*Q8 (p. 23)*	*Q9 (p. 24)*	*Q10 (p. 25)*	*Q11 (p. 25)*	*Q12 (p. 25)*
Q13 (p. 26)	*Q14 (p. 26)*	*Q15 (p. 27)*	*Q16 (p. 27)*	*Q17 (p. 28)*	*Q18 (p. 28)*
Q19 (p. 28)	*Q20 (p. 29)*	*Q21 (p. 29)*	*Q22 (p. 30)*	*Q23 (p. 30)*	*Q24 (p. 30)*

Q1: A 52-year-old male presents with worsening shortness of breath and fatigue. An echocardiogram shows left ventricular dilation and significant aortic regurgitation. Which of the following are the possible conditions causing Aortic regurgitation? Ankylosing Spondylitis Aortic Dissection Marfan's Syndrome Syphilis (Q850418)

A. 1,2,3

B. 2,3,4

C. 1,3,4

D. 1,2,3,4

See Answer in Part B → Q1

@Neet_pg_bot

Q2: Match the following murmurs with the respective conditions. S.No Murmur Condition 1) a) Mitral Stenosis 2) b) Aortic Stenosis 3) c) Mitral Regurgitation 4) d) Aortic Regurgitation (Q850444)

A. 1-a, 2-b, 3-c, 4-d

B. 1-c, 2-a, 3-d, 4-b

C. 1-a, 2-c, 3-b, 4-d

D. 1-d, 2-b, 3-c, 4-a

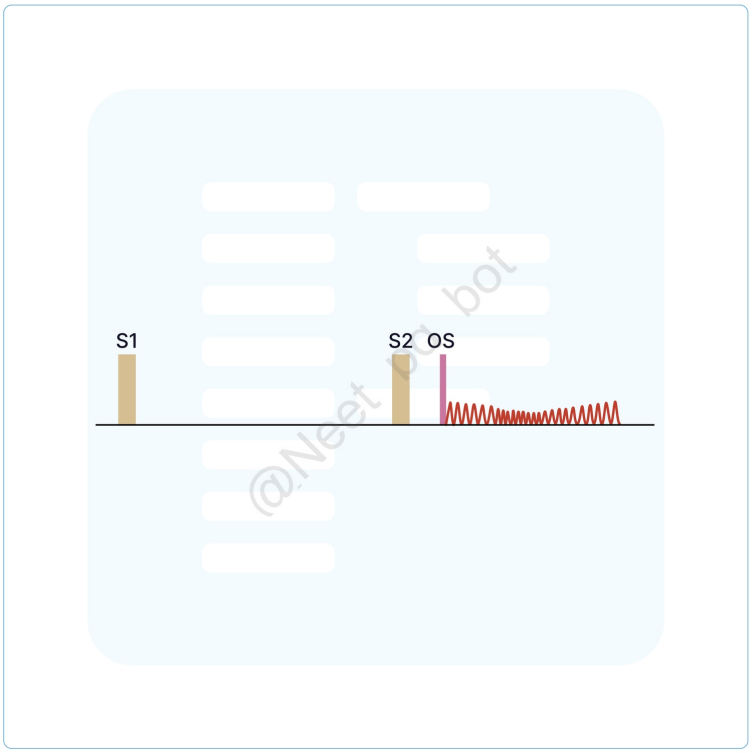

@Neet_pg_bot

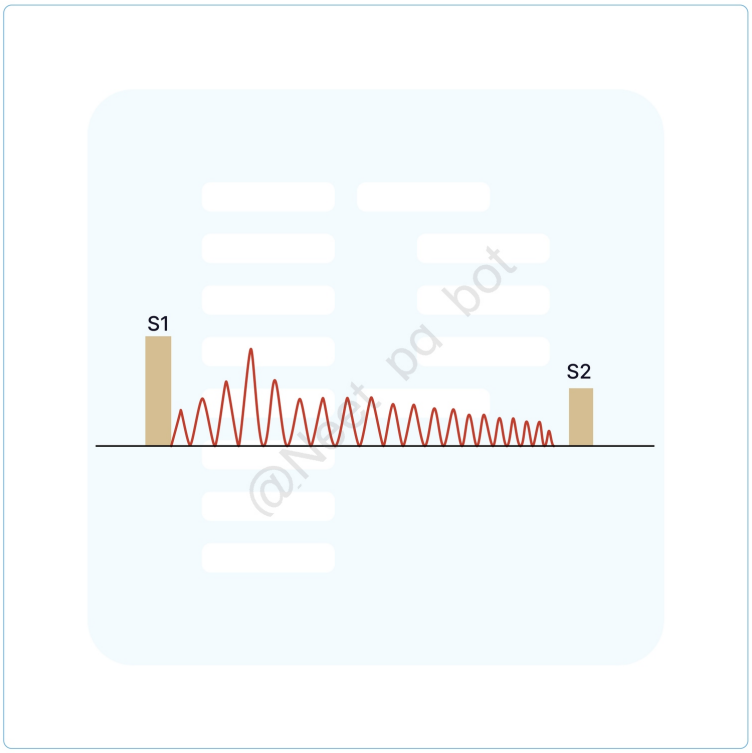

@Neet_pg_bot



@Neet_pg_bot

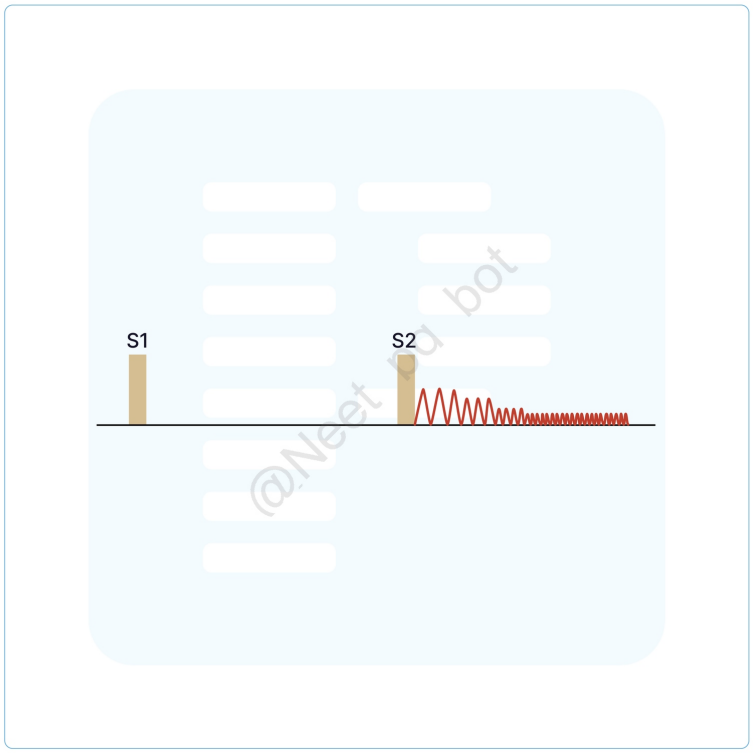

@Neet_pg_bot

See Answer in Part B → Q2

@Neet_pg_bot

Q3: A 25 year old woman diagnosed with scleroderma presents with exertional dyspnea. You auscultate a high-pitched, decrescendo diastolic murmur at the second left intercostal space, radiating along the left sternal border that increases with inspiration. Which of the following is correct about this case? (Q850440)

A. Graham Steell murmur

B. Austin Flint murmur

C. Carey-Coombs murmur

D. Gibson's murmur

See Answer in Part B → Q3

@Neet_pg_bot

Q4: A 65-year-old male presents to the clinic with complaints of left arm pain and intermittent dizziness. O/E, you find a notable difference in blood pressure readings: 150/90 mmHg in the right arm and 100/60 mmHg in the left arm. Which condition is least likely to cause this variation? (Q850438)

A. Coarctation of the aorta

B. Aortic dissection

C. Supravalvular aortic stenosis

D. Takayasu arteritis

See Answer in Part B → Q4

@Neet_pg_bot

Q5: Match the following cardiac valvular disorders with their specific murmur type: Valvular defect Murmur 1. Aortic stenosis a. Pansystolic murmur increasing with inspiration 2. Mitral regurgitation b. Mid-diastolic rumble with opening snap 3. Mitral stenosis c. Harsh systolic murmur radiating to the carotids 4. Tricuspid

regurgitation d. Holosystolic murmur radiating to the axilla (Q850436)

A. 1-b, 2-a, 3-d, 4-c

B. 1-c, 2-b, 3-a, 4-d

C. 1-c, 2-d, 3-b, 4-a

D. 1-d, 2-a, 3-c, 4-b

See Answer in Part B → Q5

@Neet_pg_bot

Q6: A 6-year-old girl with a history of Tetralogy of Fallot repair 12 months ago presents with abdominal swelling and pedal oedema. Cardiac auscultation reveals an early diastolic murmur, and ECG shows right ventricular and atrial enlargement. Considering the suspicion of pulmonary regurgitation, which investigation is most appropriate for further evaluation? (Q850433)

A. Transthoracic echocardiography

B. Cardiac magnetic resonance imaging

C. Transesophageal echocardiography

D. Cardiac catheterisation

See Answer in Part B → Q6

@Neet_pg_bot

Q7: A 10-year-old girl presents with exercise intolerance and occasional chest pain. Examination reveals a systolic ejection murmur at the left upper sternal border and elevated jugular venous pressure. An echocardiogram shows a peak systolic gradient of 70 mmHg across the pulmonary valve, raising suspicion for pulmonary valve stenosis. Which of the following set of statements is true regarding this condition? Pulmonic stenosis is always congenital. Dysplastic valves leading to pulmonary stenosis are seen in Noonan syndrome. Severe PS is defined by peak systolic gradient across the PV>64 mmHg Percutaneous balloon valvuloplasty is indicated for all

patients. Pulmonic stenosis usually leads to right ventricular hypertrophy. (Q850431)

A. 2 and 5

B. 3 and 4

C. 2,3 and 5

D. 1,2 and 5

See Answer in Part B → Q7

@Neet_pg_bot

Q8: A 75-year-old male with a history of long-standing hypertension and atrial fibrillation presents with progressive fatigue & bilateral leg swelling. O/E, the patient has distended neck veins with the following waveform with a blowing holosystolic murmur that increases with inspiration and radiating to epigastrium. What is the most likely diagnosis? (Q850429)

A. Pulmonary hypertension

B. Tricuspid regurgitation

C. Pulmonary stenosis

D. Mitral regurgitation

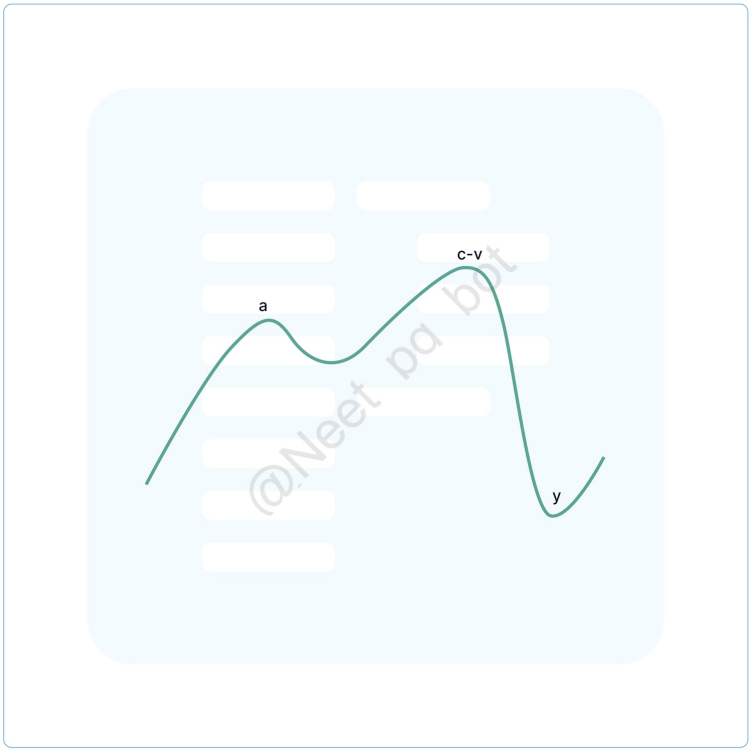

@Neet_pg_bot

See Answer in Part B → Q8

@Neet_pg_bot

Q9: A 66-year-old female presents with fatigue, abdominal discomfort, and swelling in her legs. On examination, she has jugular venous distention with giant ‘a’ waves, hepatomegaly, and ascites. Auscultation reveals a diastolic murmur at the lower left sternal border, which increases in intensity with inspiration. What’s the most likely diagnosis? (Q850426)

A. Mitral stenosis

B. Tricuspid stenosis

C. Constrictive pericarditis

D. Aortic stenosis

See Answer in Part B → Q9

@Neet_pg_bot

Q10: A 69-year-old man presents with severe aortic regurgitation. He reports increasing fatigue, breathlessness, and episodes of dizziness. On auscultation, a diastolic murmur is heard along with a water-hammer pulse, and an echocardiogram shows significant left ventricular dilation and an ejection fraction of 55%. What is the most appropriate management for this patient? (Q850425)

A. Medical management

B. Transcatheter aortic valve implantation

C. Intra-aortic balloon counterpulsation

D. Aortic valve replacement

See Answer in Part B → Q10

@Neet_pg_bot

Q11: Match the following signs with specific features Signs Features 1. Muller Sign a) Systolic pulsations of the Spleen 2. Rosenbach sign b) Visible systolic pulsation of the uvula 3. Gerhardt's sign c) Jarring motion of the head with each heartbeat 4. De-Musset sign d) Systolic pulsations of the Liver (Q850421)

A. 1-b, 2-d, 3-a, 4-c

B. 1-a, 2-c, 3-b, 4-d

C. 1-c, 2-a, 3-d, 4-b

D. 1-d, 2-b, 3-c, 4-a

See Answer in Part B → Q11

@Neet_pg_bot

Q12: A 72-year-old male presents with complaints of worsening dyspnea, angina and orthopnea. Physical examination reveals a loud diastolic murmur at the left sternal border and a widened pulse pressure. An echocardiogram indicates significant left ventricular dilation. What is the likely estimated regurgitant volume in this condition

to label as severe valvular dysfunction? (Q850419)

A. < 35 ml/beat

B. > 35 ml/beat

C. < 60 ml/beat

D. > 60 ml/beat

See Answer in Part B → Q12

@Neet_pg_bot

Q13: A 32-year-old female presents with palpitations, chest discomfort, and fatigue. A mid-systolic click and late systolic murmur are heard at the apex. Echocardiography shows mitral valve leaflets billowing into the left atrium during systole. Which of the following is leading cause of this presentation? (Q850397)

A. Inflammation of the mitral valve due to rheumatic fever

B. Fibrotic changes affecting the mitral valves

C. Rupture of the tendinae of the mitral valve

D. Myxomatous degeneration of mitral valve apparatus.

See Answer in Part B → Q13

@Neet_pg_bot

Q14: A 65-year-old woman reports experiencing mild chest pain and shortness of breath on exertion. On examination, harsh ejection- systolic murmur is noted, best heard at the right second intercostal space and radiating to the carotids. An Echocardiogram shows an aortic valve area of 0.9 cm^2. Which stage of aortic stenosis is present and what is the ideal management? (Q850417)

A. Stage B and TAVR

B. Stage D and Statins

C. Stage B and Statins

D. Stage D and TAVR

See Answer in Part B → Q14

@Neet_pg_bot

Q15: A 72-year-old patient presents with angina and shortness of breath on exertion. Physical examination reveals a slow-rising carotid pulse and a systolic ejection murmur. Which of the following is most likely to be observed in this patient? (Q850415)

A. Triple vessel disease

B. Right atrial enlargement

C. Medial displacement of heaving apex

D. Junctional Tacycardia

See Answer in Part B → Q15

@Neet_pg_bot

Q16: A 65-year-old patient presents to the clinic with increasing fatigue and shortness of breath on exertion. O/E a harsh, systolic crescendo-decrescendo ejection murmur is noted at the right second intercostal space. Which of the following is not seen in this condition ? (Q850413)

A. Left axis deviation

B. Angina pectoris

C. Syncope on exertion

D. Water Hammer pulse

See Answer in Part B → Q16

@Neet_pg_bot

Q17: A 72-year-old woman presents with fatigue and progressive shortness of breath, particularly when climbing stairs. During the physical examination, a harsh, systolic ejection murmur is heard at the right second intercostal space, radiating to the carotids. Which of the following factors is least likely to be associated with the development of the condition? (Q850412)

A. Mediastinal irradiation

B. Mutation in NOTCH1

C. Prior rheumatic inflammation

D. Systemic lupus erythematosus

See Answer in Part B → Q17

@Neet_pg_bot

Q18: A 65-year-old male presents with recurrent syncopal episodes. Auscultation reveals an ejection systolic murmur heard at the right 2 nd intercostal space and radiates to the carotids. The murmur also becomes higher-pitched when heard at the apex. ECG shows left axis deviation with a normal sinus rhythm. Which condition is most likely in this patient? (Q850410)

A. Sick Sinus syndrome

B. Aortic stenosis

C. Complete heart block

D. Pulmonary stenosis

See Answer in Part B → Q18

@Neet_pg_bot

Q19: A 50-year-old female patient presents with exertional dyspnea and a history of rheumatic fever. Echocardiogram shows severe mitral stenosis with calcification. Which of the following is the most appropriate management strategy for her

condition? (Q850408)

A. Initiate warfarin therapy

B. Percutaneous mitral balloon commissurotomy (PMBC)

C. Schedule for mitral valve replacement

D. Start beta-blockers and diuretics

See Answer in Part B → Q19

@Neet_pg_bot

Q20: A 48-year-old female presents with worsening exertional dyspnea and fatigue. She has a history of rheumatic fever during her childhood. Examination shows diastolic murmur at the cardiac apex with pronounced opening snap. Which of the following findings is least likely to be present in this case? (Q850406)

A. Left atrial enlargement

B. Reduced mitral valve area

C. Right ventricular hypertrophy

D. Heaving apex beat

See Answer in Part B → Q20

@Neet_pg_bot

Q21: A 40-year-old female with a history of rheumatic heart disease comes to the OPD for a regular follow-up. Echocardiography confirmed the presence of severe mitral regurgitation . When considering her treatment options, which of the following interventions should not be included in her management plan? (Q850404)

A. Use of Apixaban if her CHA2DS2-VASc score ≥2

B. Cardiac resynchronization therapy, when indicated

C. Mitral valve repair if EF < 60%

D. Vitamin K antagonists

See Answer in Part B → Q21

@Neet_pg_bot

Q22: A 65-year-old female presents to the clinic with complaints of fatigue, shortness of breath on exertion, and palpitations. On physical examination, a systolic thrill is palpable at the cardiac apex. Echocardiography showed severe backflow of blood from the left ventricle to the left atrium during ventricular systole. What kind of murmur is most likely to be heard during cardiac auscultation of this patient? (Q850401)

A. Continuous murmur

B. An opening snap followed by a diastolic murmur

C. Holosystolic murmur, best heard at the apex

D. Crescendo decrescendo systolic murmur best heard at the base

See Answer in Part B → Q22

@Neet_pg_bot

Q23: Which of the following is not a cause of primary chronic mitral regurgitation? (Q850400)

A. Ischemic cardiomyopathy

B. Rheumatic fever

C. Infective endocarditis

D. Radiation

See Answer in Part B → Q23

@Neet_pg_bot

Q24: A 65-year-old diabetic male with mitral valve prolapse presents with palpitations. Pulse 130/min irregular, BP on admission is 160/100 mmHg. He also has a history of infective endocarditis. Which of the following statements regarding his management is not true? (Q850398)

A. Anticoagulation therapy should be avoided due to low CHADS2Vasc score

B. Beta-blockers should be initiated for his palpitations

C. Mitral valve repair is preferred over mitral valve replacement

D. Prophylactic antibiotics should be initiated

See Answer in Part B → Q24

@Neet_pg_bot

• [01_Cardiology] 002 Heart Sounds And Murmurs

« Back to Folder Directory

[01_Cardiology] 002 Heart Sounds And Murmurs — Quick Jump

Q1 (p. 32)	*Q2 (p. 32)*	*Q3 (p. 33)*	*Q4 (p. 33)*	*Q5 (p. 34)*	*Q6 (p. 34)*
Q7 (p. 34)	*Q8 (p. 35)*	*Q9 (p. 35)*	*Q10 (p. 35)*	*Q11 (p. 36)*	*Q12 (p. 37)*
Q13 (p. 37)	*Q14 (p. 38)*	*Q15 (p. 39)*	*Q16 (p. 39)*	*Q17 (p. 39)*	*Q18 (p. 40)*
Q19 (p. 41)	*Q20 (p. 41)*	*Q21 (p. 41)*	*Q22 (p. 42)*	*Q23 (p. 42)*	*Q24 (p. 43)*
Q25 (p. 43)					

Q1: A 55-year-old man presents with gradually worsening shortness of breath and fatigue. He has a history of tuberculosis treated 10 years ago. Physical examination reveals elevated jugular venous pressure (JVP) that rises paradoxically with inspiration. Which of the following is the most likely diagnosis? (Q850497)

A. Pulmonary embolism

B. Restrictive cardiomyopathy

C. TB pericardial effusion

D. Constrictive pericarditis

See Answer in Part B → Q1

@Neet_pg_bot

Q2: Which of the following statements is correct about grades of murmurs? (Q850755)

A. Grade 1 murmur is very loud and audible even without a stethoscope

B. Grade 2 murmur is faint but audible with a stethoscope

C. Grade 4 murmur has a loud intensity without thrill

D. Grade 6 murmur is very faint and heard with difficulty

See Answer in Part B → Q2

@Neet_pg_bot

Q3: Match the following murmurs to their characteristics Murmurs Characteristics 1. Mitral Stenosis A. High-pitched, crescendo-decrescendo murmur best heard at the right upper sternal border. 2. Aortic Stenosis B. Holosystolic murmur radiating to the axilla, often with a displaced apical impulse. 3. Patent Ductus Arteriosus C. Early diastolic decrescendo murmur best heard along the left sternal border. 4. Hypertrophic Cardiomyopathy D. "Machine-like" continuous murmur heard best at the left infraclavicular area. 5. Mitral Regurgitation E. Loud S1, opening snap, and low-pitched diastolic murmur heard best at the apex. 6. Aortic Regurgitation F. Systolic ejection murmur, often with a crescendo-decrescendo pattern, best heard at the right upper sternal border, radiating to the carotids. (Q850756)

A. 1 - E, 2 - F, 3 - D, 4 - A, 5 - B, 6 - C

B. 1 - E, 2 - F, 3 - A, 4 - D, 5 - C, 6 - B

C. 1 - F, 2 - E, 3 - D, 4 - A, 5 - C, 6 - B

D. 1 - F, 2 - E, 3 - A, 4 - D, 5 - B, 6 - C

See Answer in Part B → Q3

@Neet_pg_bot

Q4: A 35-year-old male presents with exertional chest pain and dyspnea. On physical examination, you note a harsh mid systolic murmur that is loudest at the left sternal border and increases in intensity with the Valsalva maneuver. Which of the following is the most likely cause? (Q850752)

A. Hypertrophic Cardiomyopathy

B. Aortic Stenosis

C. Pulmonary Stenosis

D. Atrial Septal Defect

See Answer in Part B → Q4

@Neet_pg_bot

Q5: A 45-year-old male presents shortness of breath on exertion. Examination reveals a pansystolic murmur heard best at the apex of the heart, radiating to the axilla. The intensity of the murmur does not change with inspiration. Which of the following is the most likely diagnosis? (Q850753)

A. Chronic Mitral Regurgitation

B. Chronic Tricuspid Regurgitation

C. Aortic Stenosis

D. Acute Mitral Regurgitation

See Answer in Part B → Q5

@Neet_pg_bot

Q6: A 7-year-old child is brought to the clinic for evaluation of high blood pressure detected during a routine check-up. On physical examination, the blood pressure is higher in the arms compared to the legs. A continuous murmur is heard over the back, near the left scapula. Which of the following is the most likely diagnosis? (Q850754)

A. Takayau Arteritis

B. Coarctation of the Aorta

C. Atrial Septal Defect

D. Aortic Dissection

See Answer in Part B → Q6

@Neet_pg_bot

Q7: In aortic regurgitation, capillary pulsations can be seen in the nail beds. What is this sign called? (Q850751)

A. Quincke’s sign

B. Duroziez’s sign

C. de Musset’s sign

D. Hill sign

See Answer in Part B → Q7

@Neet_pg_bot

Q8: From the list of ECG findings given below which will not be seen in mitral stenosis? (Q850749)

A. Tall R waves in V1-V3

B. Bifid P wave

C. Atrial fibrillation

D. Tall tented T-waves

See Answer in Part B → Q8

@Neet_pg_bot

Q9: Which of the following schematic represents murmur of mitral stenosis? (Q850748)

See Answer in Part B → Q9

@Neet_pg_bot

Q10: A 60-year-old male with presents with shortness of breath and pedal edema. Auscultation reveals a loud diastolic sound. Chest X-ray is given below. What is the treatment? (Q850746)

A. Diuretics

B. Pericardiocentesis

C. Beta-blockers

D. Glyceryl trinitrate

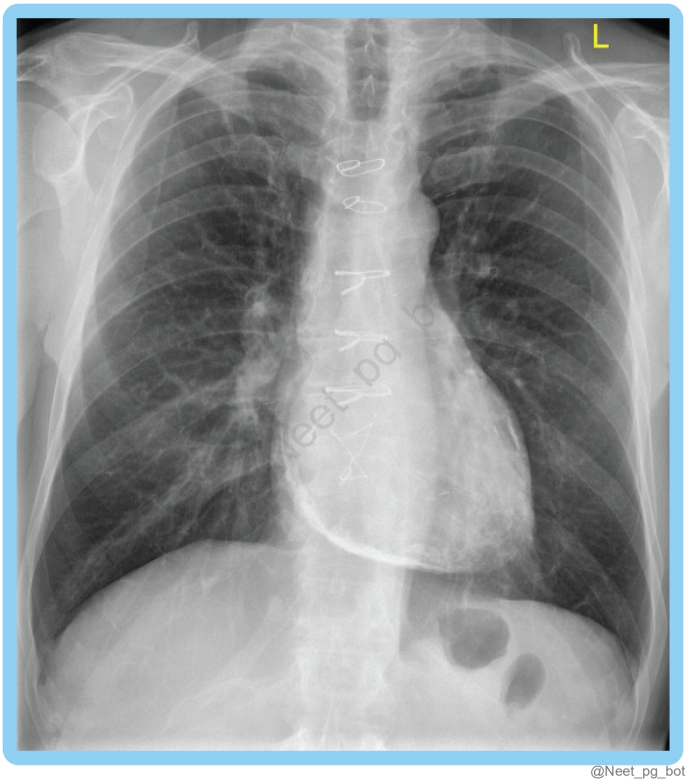

See Answer in Part B → Q10

@Neet_pg_bot

Q11: A 45-year-old woman recently diagnosed with adenocarcinoma lung presents with sudden dyspnoea, tachycardia, and hypotension. Examination reveals elevated JVP and an abnormal drop of 15mm Hg in systolic blood pressure during inspiration. An ECG was performed and is given below. What is the most appropriate next step in management? (Q850745)

A. Intravenous diuretics

B. Pericardiocentesis

C. Start vasopressors

D. Schedule elective cardiac surgery

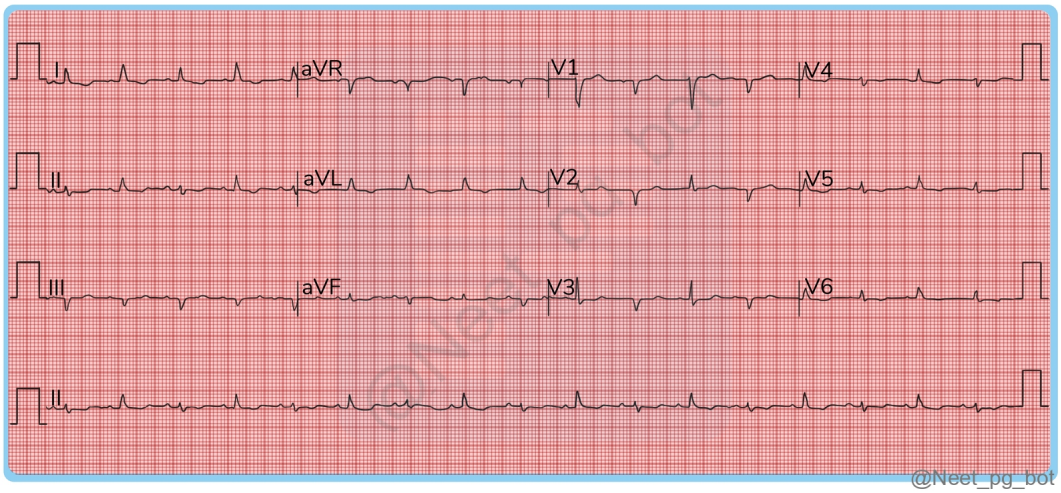

See Answer in Part B → Q11

@Neet_pg_bot

Q12: A 60-year-old man with a history of heart failure presents with worsening edema and jugular venous distention. You observe a steep x and steep y descent in the jugular venous waveform. Which of the following conditions is most likely responsible for these findings? (Q850500)

A. Constrictive pericarditis

B. Tricuspid regurgitation

C. Pericardial tamponade

D. Acute Pericarditis

See Answer in Part B → Q12

@Neet_pg_bot

Q13: A 65-year-old man presents with palpitations and lightheadedness. His ECG shows an unequal number of P waves and R waves and his jugular venous pressure tracing is shown below. Which of the following conditions is responsible for this finding? (Q850498)

A. Atrial fibrillation

B. Complete heart block

C. Tricuspid stenosis

D. Electromechanical dissociation

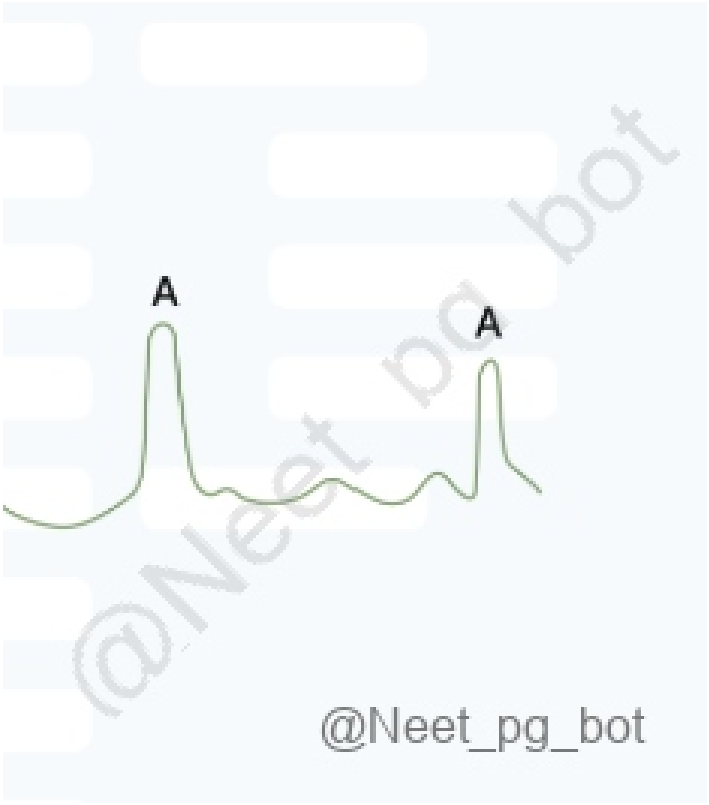

See Answer in Part B → Q13

@Neet_pg_bot

Q14: Loud first heart sound (S1) in mitral stenosis indicates? (Q850476)

A. Reduced LV compliance

B. Increased left atrial pressure

C. Severe calcified mitral stenosis

D. Hypertrophy of the right ventricle

See Answer in Part B → Q14

@Neet_pg_bot

Q15: A 70-year-old woman with a history of ischemic cardiomyopathy, hypertension, and diabetes presents with worsening shortness of breath and fatigue. On physical examination, you hear both an S3 and an S4 heart sound. Which of the following best explains the presence of both heart sounds in this patient? (Q850495)

A. Atrial fibrillation with mitral stenosis

B. Acute mitral regurgitation

C. Combined systolic and diastolic heart failure

D. Severe aortic stenosis

See Answer in Part B → Q15

@Neet_pg_bot

Q16: A 35-year-old woman presents with palpitations. On examination, hyperdynamic precordium is noted with soft S1 and pansystolic murmur. Which of the following is the most likely cause? (Q850494)

A. Hyperthyroidism

B. Mitral stenosis

C. Mitral regurgitation

D. Myxedema heart

See Answer in Part B → Q16

@Neet_pg_bot

Q17: A 25-year-old man presents to the ER with recurrent episodes of palpitations, dizziness, and occasional chest discomfort. Auscultation shows loud S1 and normal split S2. An ECG of the condition is given below. What is the most likely diagnosis for this patient's condition? (Q850491)

A. Atrial Fibrillation

B. Wolff-Parkinson-White (WPW) Syndrome

C. Myocardial Infarction

D. Brugada syndrome

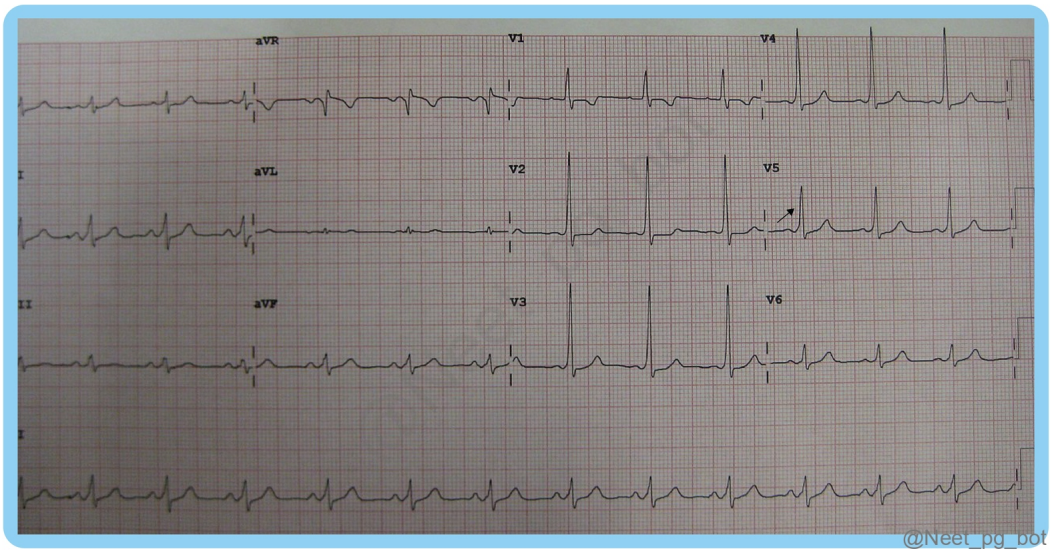

See Answer in Part B → Q17

@Neet_pg_bot

Q18: A 6-year-old boy is brought my mother as he gets very breathless during physical activities and had hospitalization for recurrent pneumonia episodes. Inspection shows a right parasternal heave, no cyanosis and auscultation reveals a systolic ejection murmur. Which is correct auscultatory finding seen in this case? (Q850488)

A. Narrow split S2

B. Paradoxical split S2

C. Wide split fixed S2

D. Wide split variable S2

See Answer in Part B → Q18

@Neet_pg_bot

Q19: A 3-year-old girl presents to the clinic with a history of recurrent respiratory infections and exercise intolerance. On physical examination, a holosystolic murmur is noted at the left lower sternal border. Which of the following is correct about heart sound finding in this case? (Q850487)

A. Wide Fixed split S2

B. Paradoxical split S2

C. Narrow split S2

D. Wide split variable S2

See Answer in Part B → Q19

@Neet_pg_bot

Q20: A 45-year-old man presents with progressive dyspnea and occasional dizziness. On auscultation, a harsh crescendo-decrescendo systolic murmur is noted at the left sternal border, which increases with the Valsalva maneuver. There is also evidence of a jerky carotid pulse. Which of the following will be heard on auscultation in this case? (Q850485)

A. Wide split S2

B. Fixed split S2

C. Paradoxical split S2

D. Physiological split S2

See Answer in Part B → Q20

@Neet_pg_bot

Q21: Narrow split S2 heart sound is heard in which of the following conditions? (Q850484)

A. Mitral regurgitation

B. Aortic stenosis

C. Atrial septal defect

D. Pulmonary hypertension

See Answer in Part B → Q21

@Neet_pg_bot

Q22: Match the following Heart sound Condition seen 1) Wide Split S2 a) RBBB 2) Paradoxical Splitting S2 b) Mitral regurgitation 3) Fixed Splitting S2 c) LBBB 4) Narrow Split S2 d) Hypertrophic cardiomyopathy e) ASD (Q850482)

A. 1-b, 2-c, 3-e, 4-d

B. 1-a, 2-e, 3-b, 4-c

C. 1-b, 2-d, 3-b, 4-e

D. 1-c, 2-a, 3-b, 4-e

See Answer in Part B → Q22

@Neet_pg_bot

Q23: A 28-year-old woman comes with a history of fever, chest pain, weight loss, and night sweats. During cardiac auscultation, the physician notes a characteristic sound that persists on breath holding. ECG shows global ST segment elevation with concavity upwards. What is this finding called on auscultation known as? (Q850481)

A. Opening snap

B. Pericardial friction rub

C. Pericardial knock

D. Pleural rub

See Answer in Part B → Q23

@Neet_pg_bot

Q24: Which of the following features would raise suspicion for a diagnosis of Carney complex? (Q850480)

A. Association with tuberous sclerosis

B. Presence of skin pigmentation abnormalities

C. Restrictive cardiomyopathy

D. A-V nodal block

See Answer in Part B → Q24

@Neet_pg_bot

Q25: During the cardiac cycle, the closing of the aortic valve takes place at ? (Q850478)

A. End of isovolumetric contraction

B. End of rapid filling phase

C. Start of isovolumetric relaxation

D. Start of ejection

See Answer in Part B → Q25

@Neet_pg_bot

• [01_Cardiology] 003 Takotsubo Brugada Syndrome Rhd And Infective Endocarditis

« Back to Folder Directory

[01_Cardiology] 003 Takotsubo Brugada Syndrome Rhd And Infective Endocarditis — Quick Jump

Q1 (p. 44)	*Q2 (p. 44)*	*Q3 (p. 45)*	*Q4 (p. 45)*	*Q5 (p. 45)*	*Q6 (p. 46)*
Q7 (p. 46)	*Q8 (p. 47)*	*Q9 (p. 47)*	*Q10 (p. 48)*	*Q11 (p. 48)*	*Q12 (p. 48)*
Q13 (p. 49)	*Q14 (p. 49)*	*Q15 (p. 50)*	*Q16 (p. 50)*	*Q17 (p. 50)*	*Q18 (p. 51)*
Q19 (p. 51)	*Q20 (p. 52)*	*Q21 (p. 52)*	*Q22 (p. 53)*	*Q23 (p. 53)*	*Q24 (p. 53)*
Q25 (p. 54)	*Q26 (p. 54)*	*Q27 (p. 54)*	*Q28 (p. 55)*	*Q29 (p. 55)*	*Q30 (p. 56)*
Q31 (p. 57)					

Q1: A 78 year old man, three months after undergoing transcatheter aortic valve replacement presents with high grade fever with chills and rigors. What is the most common causative organism in TAVR-associated infective endocarditis? (Q850454)

A. Streptococcus viridans

B. Enterococcus spp

C. Staphylococcus aureus

D. Candida spp.

See Answer in Part B → Q1

@Neet_pg_bot

Q2: Which of the following is a minor criterion for diagnosing infective endocarditis based on 2023 Duke-ISCVID criteria? (Q850473)

A. Two negative blood cultures

B. Echocardiogram showing valve perforation

C. PCR from a sterile body site identifying a typical pathogen

D. Two positive blood cultures

See Answer in Part B → Q2

@Neet_pg_bot

Q3: Which of the following is a typical organism causing infective endocarditis based on 2023 Duke-ISCVID criteria? (Q850472)

A. Enterococcus faecalis

B. Streptococcus pneumoniae

C. Pseudomonas aeruginosa

D. Streptococcus pyogenes

See Answer in Part B → Q3

@Neet_pg_bot

Q4: A 70 year old man with a prosthetic aortic valve has a fever, positive blood cultures for Enterococcus faecalis, valve vegetations visualized on echocardiography. Cardiac Computed Tomography shows a valve abscess. Which finding is a new major criterion for infective endocarditis in the 2023 Duke-ISCVID criteria? (Q850471)

A. Direct visual evidence of vegetations during surgery

B. Echocardiogram revealing vegetation

C. Positive blood cultures with Enterococcus faecalis

D. Development of a new onset murmur

See Answer in Part B → Q4

@Neet_pg_bot

Q5: A 65 year old male patient with a history of rheumatic heart disease presents to the dental clinic for a tooth extraction. He has a prosthetic heart valve placed two

years ago and reports a penicillin allergy. Which of the following prophylactic antibiotic regimens should be administered to this patient before his dental procedure to prevent infective endocarditis? (Q850470)

A. Amoxicillin 2g orally 1 hour before the procedure

B. Ampicillin 2g IV or IM within 1 hour before the procedure

C. Clarithromycin 500 mg orally 1 hour before the procedure

D. Cefazolin 1g IV or IM 30 minutes before the procedure

See Answer in Part B → Q5

@Neet_pg_bot

Q6: A 55 year old man with a history of prosthetic valve deployment presents with fever, chills, and fatigue. Blood cultures reveal methicillin-resistant Staphylococcus aureus. The patient has a prosthetic valve and shows evidence of vegetation on echocardiography. What is the appropriate antibiotic regimen for managing this patient's infection? (Q850469)

A. Vancomycin + Gentamicin + Rifampin

B. Vancomycin + Daptomycin

C. Nafcillin + Gentamicin + Rifampin

D. Ampicillin + Gentamicin

See Answer in Part B → Q6

@Neet_pg_bot

Q7: Which of the following is a minor criterion under the Modified Duke's Criteria for infective endocarditis? (Q850468)

A. Positive echocardiographic findings of vegetation

B. Two positive blood cultures with a typical organism

C. Presence of a prosthetic valve

D. Abscess formation on echocardiogram

See Answer in Part B → Q7

@Neet_pg_bot

Q8: A 60 year-old man with a mechanical aortic valve presents with 2 weeks of fever, fatigue, and shortness of breath. He has a history of a dental procedure done 3 weeks back. Blood cultures are negative. FDG-PET/CT shows abnormal uptake around the valve. Which major criterion from the Modified Duke's Criteria does this patient meet? (Q850467)

A. Negative blood culture for a typical organism

B. Evidence of endocardial involvement by FDG-PET/CT

C. Osler nodes and Janeway lesions

D. Recent history of dental procedure

See Answer in Part B → Q8

@Neet_pg_bot

Q9: A 30 year old woman who is known case of rheumatic heart disease and mitral regurgitation presents with complaints of fever for past 2 weeks.Echo showed vegetations on both surfaces of mitral valve.Blood cultures grew staphylococcus aureus. Which of the following would be immunological phenomenon seen in these patient? (Q850464)

A. Janeway lesions and Osler's nodes

B. Roth spots and Osler nodes

C. Carditis and Arthritis

D. Splinter hemorrhages in nails and clubbing

See Answer in Part B → Q9

@Neet_pg_bot

Q10: In the context of infective endocarditis, what role do MSCRAMMs play in the disease process? (Q850463)

A. They enhance the immune response against pathogens during bacteremia.

B. They facilitate bacterial adherence to nonbacterial thrombotic endocarditis (NBTE) or injured endothelium.

C. They are responsible for the formation of emboli that lead to tissue infarction.

D. They promote the breakdown of vegetation formed in the heart.

See Answer in Part B → Q10

@Neet_pg_bot

Q11: A 65 year old male with ischemic cardiomyopathy and a history of benign prostatic hyperplasia presents with fever, malaise, and a new heart murmur. He recently underwent a urinary catheterisation for urinary retention. Blood cultures are positive for gram-positive cocci. What is the most likely causative organism of his infective endocarditis? (Q850461)

A. Staphylococcus aureus

B. Streptococcus gallolyticus

C. Enterococcus faecalis

D. Haemophilus species

See Answer in Part B → Q11

@Neet_pg_bot

Q12: A 68 year old farmer with a prosthetic valve presents with fever, night sweats, and fatigue 6 months post-surgery. Blood cultures are negative. He has goats and cows on his farm . Which organism is most likely responsible for his prosthetic valve

endocarditis? (Q850460)

A. Staphylococcus epidermidis

B. Coxiella burnetii

C. Mycobacterium chimaera

D. Enterococcus faecalis

See Answer in Part B → Q12

@Neet_pg_bot

Q13: A 3 year girl with a history of patent ductus arteriosus presents with high grade fever. Her recent echocardiogram shows vegetations along the inner lining of her aorta. Which of the following conditions is the most likely diagnosis for this patient based on her symptoms and history? (Q850459)

A. Acute bacterial endocarditis

B. Subacute bacterial endocarditis

C. Infective endarteritis

D. Fungal endocarditis

See Answer in Part B → Q13

@Neet_pg_bot

Q14: A 72 year female with a history of mitral valve prolapse presents with a fever and fatigue for last > 2 weeks. Physical examination reveals a new heart murmur and petechiae on her extremities. Blood cultures are sent. What is the leading organism associated with this patient's probable condition? (Q850458)

A. Staphylococcus aureus

B. Streptococcus viridans

C. Enterococcus faecalis

D. HACEK organisms

See Answer in Part B → Q14

@Neet_pg_bot

Q15: Which of the following lists the valves in order of frequency of involvement in infective endocarditis, from most to least commonly affected? (Q850456)

A. Mitral valve > Aortic valve > Tricuspid valve > Pulmonic valve

B. Aortic valve > Mitral valve > Pulmonic valve > Tricuspid valve

C. Tricuspid valve > Mitral valve > Aortic valve > Pulmonic valve

D. Pulmonic valve > Aortic valve > Tricuspid valve > Mitral valve

See Answer in Part B → Q15

@Neet_pg_bot

Q16: Which of the following statements is false regarding right-sided infective endocarditis (IE)? (Q850455)

A. Right-sided infective endocarditis is more commonly associated with enterococci than left-sided infective endocarditis.

B. Staphylococcus aureus is the most common pathogen in right-sided infective endocarditis

C. Injecting particles are more likely to reach the right-sided valves compared to the left-sided valves

D. Right-sided infective endocarditis has a better long-term prognosis compared to left-sided infective endocarditis

See Answer in Part B → Q16

@Neet_pg_bot

Q17: A 72 year old woman presents with severe chest pain and shortness of breath after the death of her husband. She has no history of heart disease. ECG shows STE of 2 mm in lead I , aVL, V2-V4. Bedside echocardiogram shows left ventricular

ballooning and cardiac biomarkers are elevated. What is the most likely diagnosis? (Q850403)

A. Anterior wall MI

B. Takotsubo Cardiomyopathy

C. Inferior wall MI

D. Pulmonary Embolism

See Answer in Part B → Q17

@Neet_pg_bot

Q18: Which of the following is the most common echocardiographic finding associated with rheumatic carditis in children? (Q850453)

A. Aortic regurgitation

B. Mitral regurgitation

C. Aortic stenosis

D. Mitral stenosis

See Answer in Part B → Q18

@Neet_pg_bot

Q19: A 12 year old girl presents with involuntary, jerky movements in her hands and feet, worsening with stress or purposeful tasks and does not interferes with eating. Her mother tells that for 3 months she had developed arthritis that caused her to limp for a week with swelling of knee and ankle joints. Work up shows increased PR interval, What is the most appropriate initial treatment? (Q850451)

A. Penicillin prophylaxis

B. Haloperidol

C. Intravenous immunoglobulin (IVIG)

D. Carbamazepine

See Answer in Part B → Q19

@Neet_pg_bot

Q20: A 25 year woman presents with a history of exertional dyspnea, palpitations, and episodes of syncope. She recalls experiencing multiple episodes of sore throat as a child, followed by joint pains, for which she received no definitive treatment. On auscultation, there is a diastolic murmur at the apex and a loud S1. An echocardiogram reveals mitral valve orifice < 1.5 cm 2 with left atrial enlargement. What is the next most appropriate step in management? (Q850450)

A. Mitral balloon valvotomy

B. Mitral valve repair

C. ACE Inhibitors and rate control drugs

D. Immediate mitral valve replacement

See Answer in Part B → Q20

@Neet_pg_bot

Q21: A 35-year-old woman presents with progressive exertional dyspnea, fatigue, and occasional palpitations. O/E, she has an irregular pulse, a loud S1, an opening snap, and a low-pitched diastolic rumble at the apex. She recalls a childhood illness with fever and joint pain requiring hospitalization. Which of the following investigations is NOT primarily used in diagnosing her condition? (Q850449)

A. Echocardiography

B. Electrocardiogram

C. Blood cultures

D. Chest X-ray

See Answer in Part B → Q21

@Neet_pg_bot

Q22: Which of the following is not a part of the major criteria for a low-risk population? (Q850445)

A. Carditis

B. Polyarthritis

C. Chorea

D. Polyarthralgia

See Answer in Part B → Q22

@Neet_pg_bot

Q23: Which of the following is correct about St Vitus's dance? (Q850443)

A. It is an early manifestation of rheumatic fever

B. It occurs in all patients with rheumatic fever

C. It is associated with emotional lability

D. It is a minor diagnostic criteria

See Answer in Part B → Q23

@Neet_pg_bot

Q24: A 5 year old boy presents with fever and migratory joint pain. On auscultation, a soft mid-diastolic murmur is heard at the apex. Echocardiography reveals mitral valve inflammation. Which of the following is most likely present in this patient? (Q850442)

A. Mitral stenosis murmur

B. Austin Flint murmur

C. Carey Coombs murmur

D. Graham Steele Murmur

See Answer in Part B → Q24

@Neet_pg_bot

Q25: Which of the following clinical features is most commonly associated with Acute Rheumatic fever in the Indian population? (Q850437)

A. Polyarthritis

B. Erythema Marginatum

C. Subcutaneous Nodules

D. Pulmonary Hypertension

See Answer in Part B → Q25

@Neet_pg_bot

Q26: A 10 y/o boy presents with fever, joint pain, and a recent history of sore throat. Examination reveals a heart murmur suggestive of mitral regurgitation. Laboratory tests show elevated antistreptolysin O titers. Which of the following best explains the pathogenesis of his condition? (Q850435)

A. Direct invasion of heart valves by Streptococcus bacteria

B. Immune response triggered by molecular mimicry between bacterial antigens and heart tissue

C. Autoimmune destruction of heart valves due to viral infection

D. Genetic mutations in heart muscle proteins

See Answer in Part B → Q26

@Neet_pg_bot

Q27: A 11 year boy with a history of acute rheumatic fever without carditis presents for follow-up. Based on the AHA guidelines, what is the recommended duration for continuing secondary prophylaxis in this patient? (Q850432)

A. Continue prophylaxis for 1 more year

B. Continue prophylaxis until the age of 25

C. Continue prophylaxis on lifelong basis

D. Continue prophylaxis until the age of 21

See Answer in Part B → Q27

@Neet_pg_bot

Q28: Which of the following is not an indication for ICD implantation? (Q850430)

A. Chagas disease

B. Wolff-Parkinson-White syndrome

C. Hypertrophic cardiomyopathy

D. Long QT syndrome

See Answer in Part B → Q28

@Neet_pg_bot

Q29: A 13 year old male is brought to ER by his father who noticed agonal breathing at 5 am in morning. He is the only child in family. Urgent ECG is done. What finding is noted? (Q850423)

A. Delta waves

B. Deep Q waves

C. Coved ST elevation

D. Epsilon waves

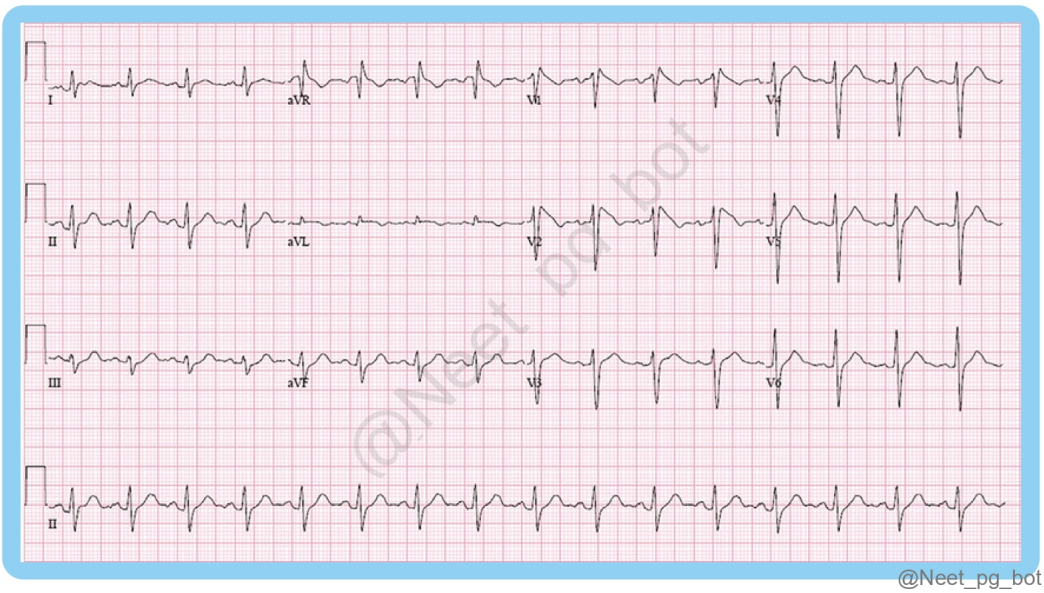

See Answer in Part B → Q29

@Neet_pg_bot

Q30: A 15-year-old male presents to the ED after experiencing a brief episode of syncope. He reports occasional palpitations and dizziness. His family history is significant for sudden cardiac death at a young age. An ECG of leads V1-V3 is given below. Which of the following management options is most appropriate for this patient, given the findings? (Q850411)

A. Prescribe a beta-blocker and advise lifestyle modifications

B. Perform Troponin I levels

C. It is also called Broken heart syndrome

D. Deploy implantable cardioverter-defibrillator.

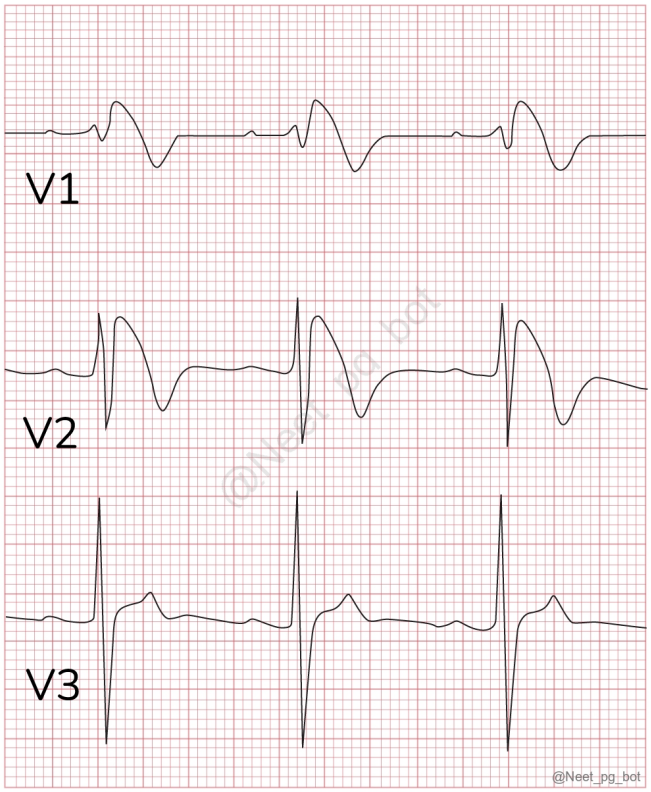

See Answer in Part B → Q30

@Neet_pg_bot

Q31: A 68 year old postmenopausal woman presents to the emergency department with chest pain and dyspnea after a recent stressful event. Her ECG shows ST-segment elevation and cardiac biomarkers are elevated. What is the most appropriate next step in management of this patient? (Q850407)

A. Administer intravenous anticoagulation therapy

B. Implant an implantable cardioverter-defibrillator.

C. Initiate inotropic support immediately.

D. Perform coronary angiography

See Answer in Part B → Q31

@Neet_pg_bot

• [01_Cardiology] 004 Ecg And Arrhythmias

« Back to Folder Directory

[01_Cardiology] 004 Ecg And Arrhythmias — Quick Jump

Q1 (p. 58)	*Q2 (p. 59)*	*Q3 (p. 59)*	*Q4 (p. 60)*	*Q5 (p. 60)*	*Q6 (p. 61)*
Q7 (p. 62)	*Q8 (p. 62)*	*Q9 (p. 63)*	*Q10 (p. 64)*	*Q11 (p. 64)*	*Q12 (p. 65)*
Q13 (p. 66)	*Q14 (p. 66)*	*Q15 (p. 67)*	*Q16 (p. 68)*	*Q17 (p. 68)*	*Q18 (p. 69)*
Q19 (p. 70)	*Q20 (p. 71)*	*Q21 (p. 71)*			

Q1: A 68-year-old smoker man with a history of hypertension presents to the ER with complaints of palpitations and shortness of breath for the past 2 hours. On examination, his pulse is irregularly irregular with a rate of 140 beats per minute. An ECG of the patient is given below. He has poorly controlled COPD. Which of the following statements about his condition is incorrect? (Q850694)

A. Multiple ectopic foci due to structural damage to heart

B. Start beta blockers followed by warfarin

C. CHADS2VASc score is used to decide the need for anticoagulation

D. Amiodarone is used for chemical cardioversion

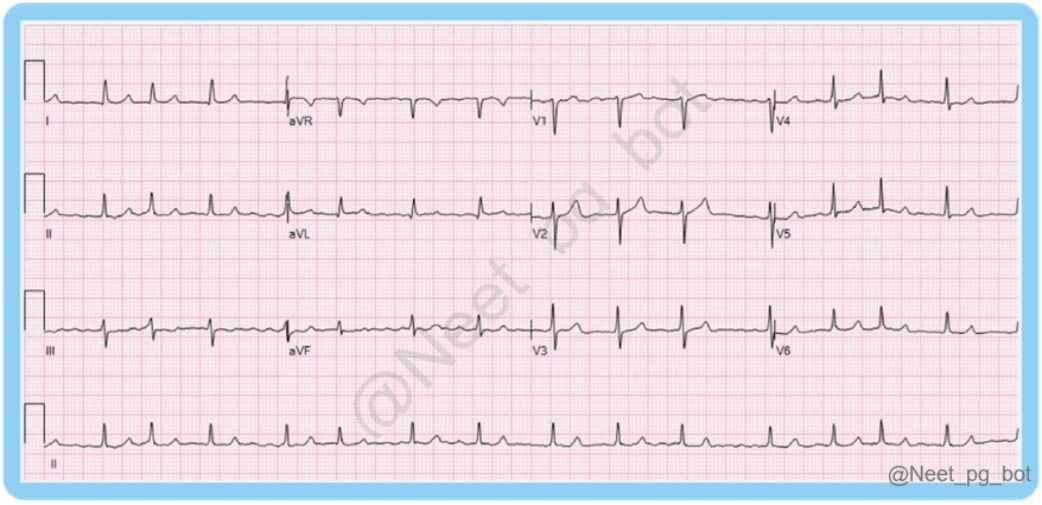

See Answer in Part B → Q1

Q2: A 68-year-old male patient with a history of hypertension presents to the emergency department in acute distress. He is diaphoretic, tachycardic, and complains of severe chest pain. BP is 90/60 mm Hg. His ECG is given below. Given the patient's condition, what is the most appropriate immediate management for this patient? (Q850728)

A. Amiodarone

B. Radiofrequency catheter ablation

C. Digoxin

D. Synchronized cardioversion



See Answer in Part B → Q2

@Neet_pg_bot

Q3: A 42-year-old woman diagnosed with stage IV breast cancer presents to the emergency department with confusion and breathing difficulty. BP on admission is 80/60 mm Hg. The ECG is attached below. Which of the following would be the most likely diagnosis in this patient? (Q850726)

A. Malignant pericardial effusion

B. Cardiac tamponade

C. Acute pericarditis

D. Constrictive pericarditis

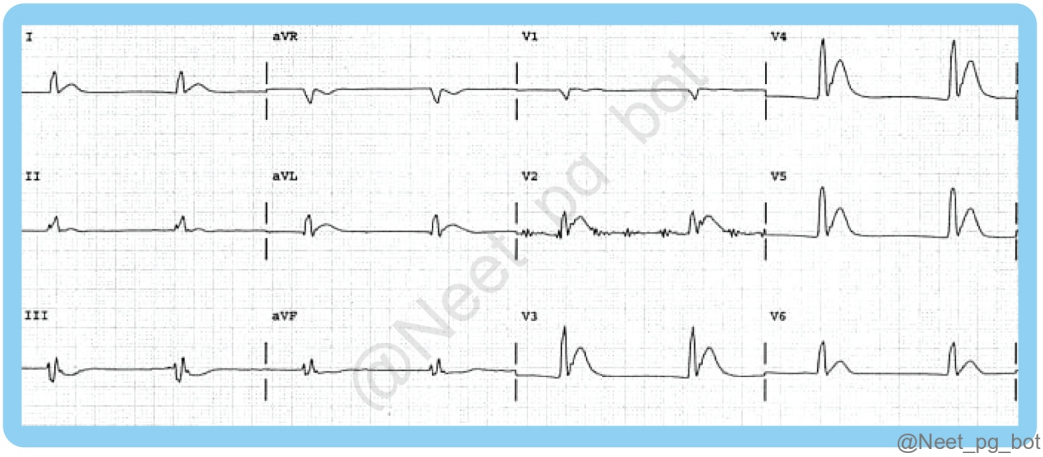

See Answer in Part B → Q3

@Neet_pg_bot

Q4: A 45-year-old man is brought to the emergency department with confusion and muscle weakness. His laboratory results show a serum potassium level of 7.2 mEq/L.Which of the following T-wave morphologies is most likely to be seen on this patient's ECG? (Q850722)

See Answer in Part B → Q4

@Neet_pg_bot

Q5: A 55-year-old alcoholic presents to the emergency department with sweating and palpitations. He is a known case of T2DM on metformin and Glipizide. Labs show plasma glucose 65 mg/dl, serum creatinine 2.0 mg/dl, BUN 70 mg/dl and serum potassium of 5.8 meq/dl. ECG is shown below. What is the next best step in the management of this patient? (Q850714)

A. Call nephrology for urgent hemodialysis

B. Stop metformin

C. Give IV dextrose with thiamine

D. Send to cath lab

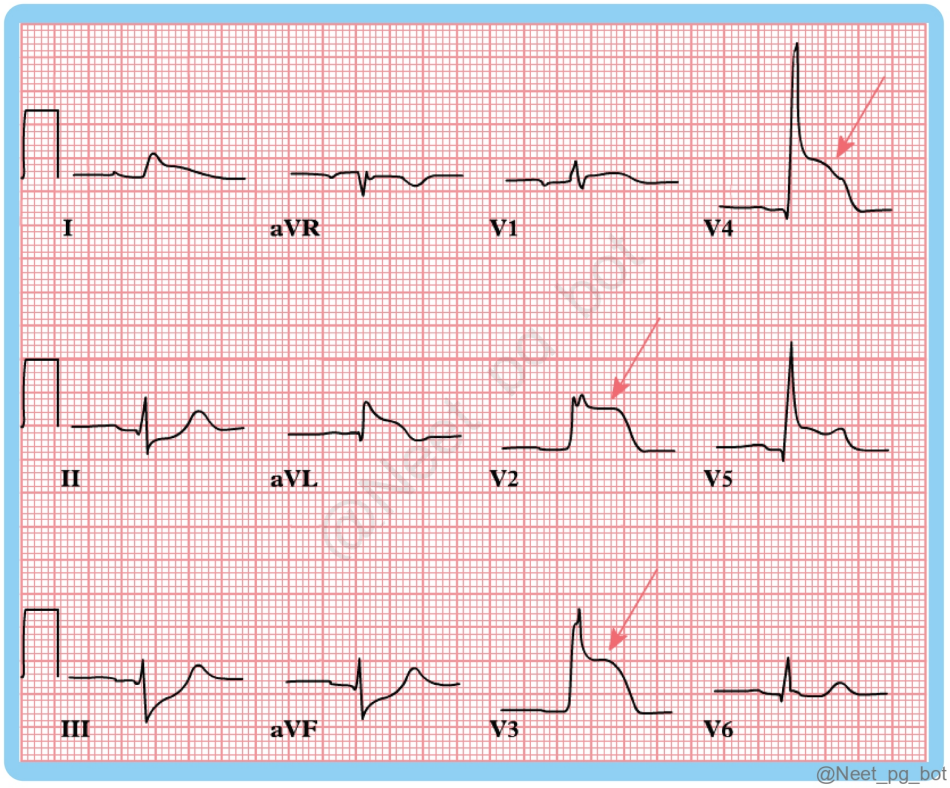

See Answer in Part B → Q5

@Neet_pg_bot

Q6: A 62-year-old man presents to the emergency department with palpitations and lightheadedness. His ECG shows a rapid, regular rhythm with a rate of 150 beats per minute, as shown below Which of the following conditions is most likely to be associated with this ECG finding? (Q850708)

A. Ventricular tachycardia

B. AV nodal re-entrant tachycardia

C. Wolf-Parkinson-White syndrome

D. Hypothermia

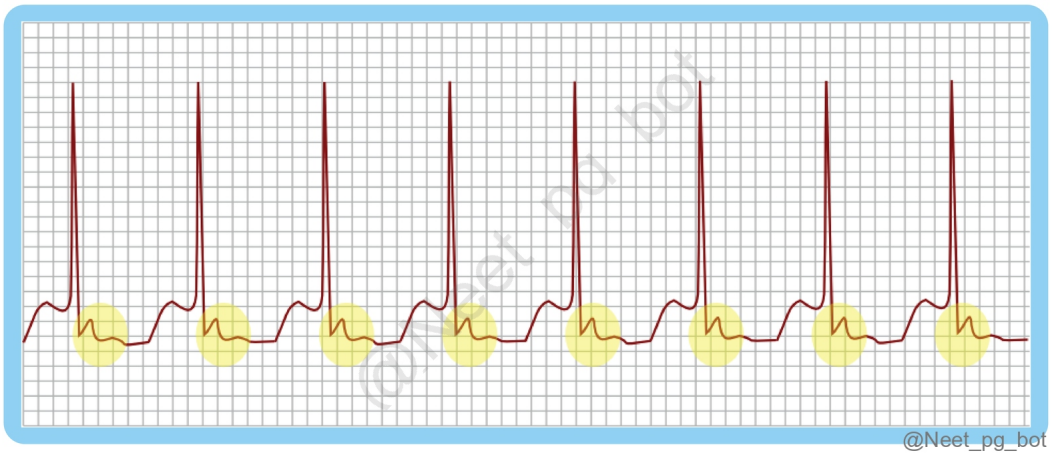

See Answer in Part B → Q6

@Neet_pg_bot

Q7: Match the following tachyarrhythmias with their respective pharmacological interventions Tachyarrhythmia Treatment 1. Atrial Fibrillation in Hypertension A. Adenosine 2. Stable Monomorphic Ventricular Tachycardia B. Esmolol followed by Anticoagulation 3. Torsades de Pointes C. Magnesium Sulfate 4. AV nodal re-entrant tachycardia D. Amiodarone (Q850706)

A. 1-B, 2-D, 3-C, 4-A

B. 1-B, 2-A, 3-D, 4-C

C. 1-D, 2-B, 3-A, 4-C

D. 1-A, 2-C, 3-B, 4-D

See Answer in Part B → Q7

@Neet_pg_bot

Q8: A 62-year-old woman presents to the ER with palpitations and lightheadedness. She is on azithromycin and cough syrup by her GP. BP on admission is 100/60 mm Hg. Her ECG is given below: Which of the following is the most appropriate immediate management for this patient? (Q850703)

A. Administer intravenous amiodarone

B. Perform immediate electrical cardioversion

C. Administer intravenous magnesium sulfate

D. Start oral beta-blocker therapy

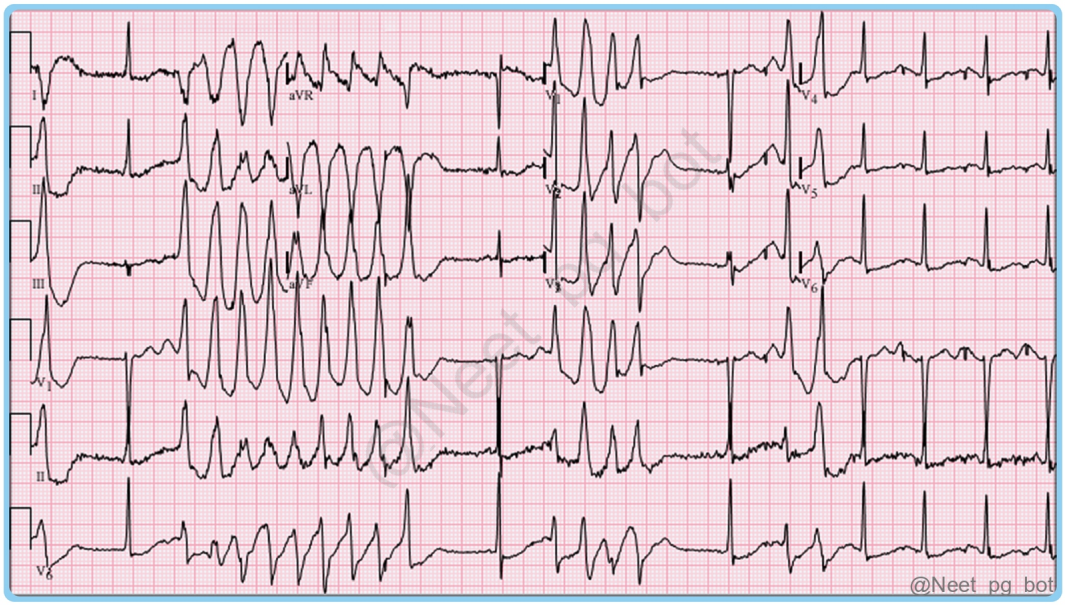

See Answer in Part B → Q8

@Neet_pg_bot

Q9: A 65-year-old male with a history of prior myocardial infarction presents to the emergency department with severe palpitations, dizziness, and chest pain. He suddenly becomes pulseless and BP is unrecordable. An ECG shows wide QRS complexes, a regular rhythm, and a ventricular rate of 160 bpm. What is the most appropriate initial treatment for this patient? (Q850701)

A. Intravenous Adenosine

B. Intravenous Magnesium Sulfate

C. Defibrillation

D. Intravenous Procainamide

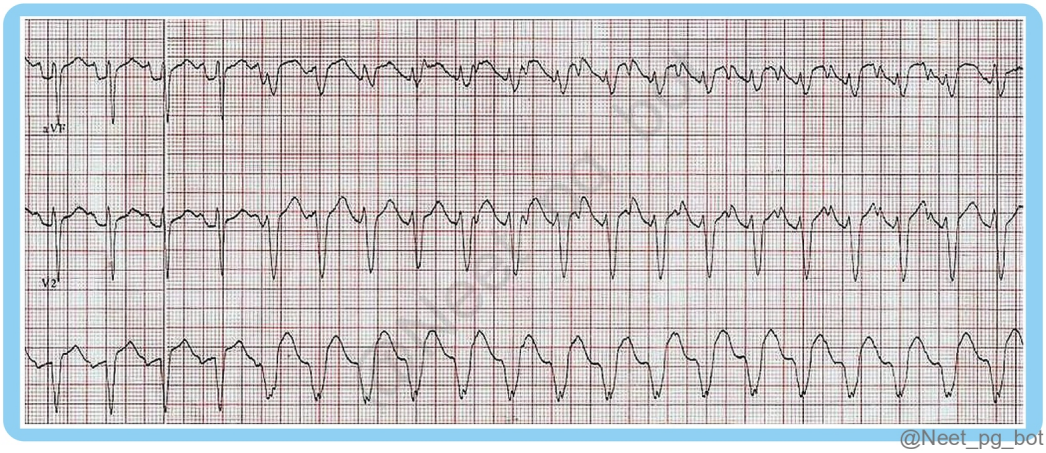

See Answer in Part B → Q9

@Neet_pg_bot

Q10: Which of the following is correct about Wolff-Parkinson-White syndrome? Accessory pathway between the atria and ventricles that lacks the decremental property Prolonged PR interval, delta waves, and narrow QRS complexes. Short PJ interval The drug of choice for an acute episode of palpitations is procainamide (Q850699)

A. 1 and 4 only

B. 2 and 3 only

C. 4 only

D. 1, 2, 3, and 4

See Answer in Part B → Q10

@Neet_pg_bot

Q11: A 25-year-old female presents with sudden onset palpitations. ECG is shown below. You successfully terminated the arrhythmia using the Valsalva maneuver. Which of the following best describes the primary mechanism by which this maneuver terminates the arrhythmia? (Q850697)

A. Vagus induced decreased firing of the sinoatrial node

B. Vagus induced an increased sympathetic tone to the heart

C. Transient block in AV node conduction

D. Mechanical disruption of accessory pathways

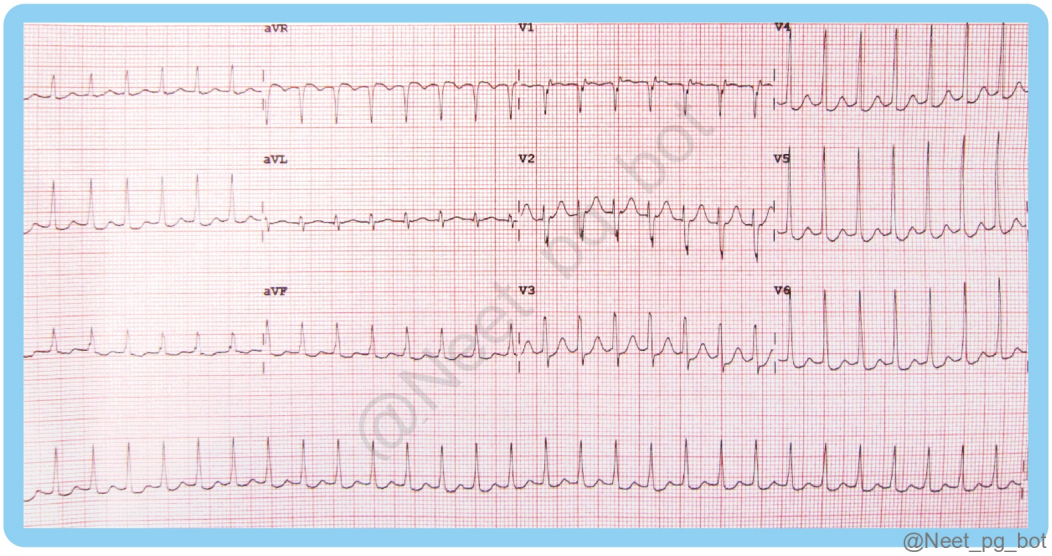

See Answer in Part B → Q11

@Neet_pg_bot

Q12: A 50-year-old man comes to your clinic for a annual medical check-up. He has Hypertension and takes Ramipril and Amlodipine. Office BP recording is 124/ 80 mm Hg. What is the ECG findings shown below? What is the most likely finding based on this ECG? (Q850534)

A. Left ventricular hypertrophy

B. Normal sinus rhythm

C. Second-degree AV block

D. Right bundle branch block

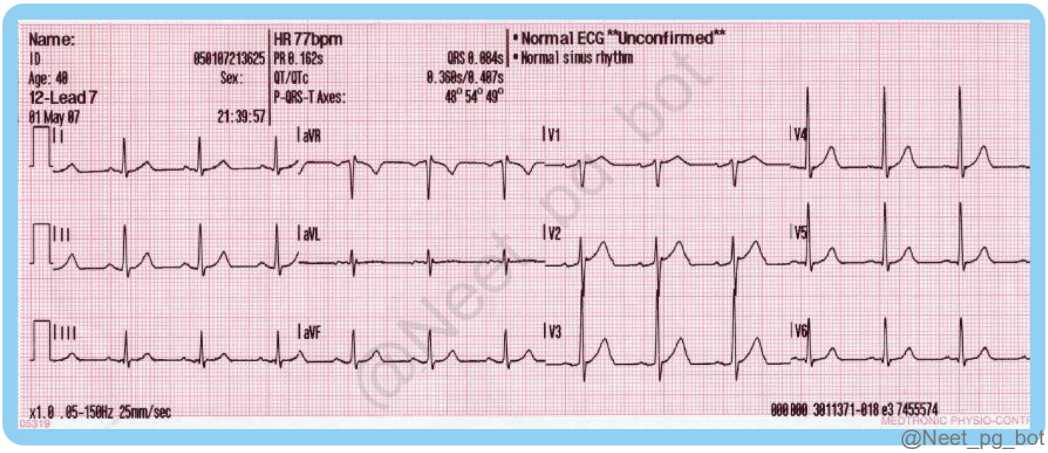

See Answer in Part B → Q12

@Neet_pg_bot

Q13: A 70-year-old patient is diagnosed with stokes adam syndrome. Which is correct about management of this patient? (Q850692)

A. Dual chamber pacemaker

B. Triple chamber pacemaker

C. Transcutaneous pacemaker

D. Transvenous pacemaker

See Answer in Part B → Q13

@Neet_pg_bot

Q14: A 74-year-old patient comes to the emergency department with complaints of intermittent dizziness and lightheadedness. An electrocardiogram (ECG) is performed, as shown below. Based on the ECG findings and the clinical scenario, what type of atrioventricular block is most likely present in this patient? (Q850687)

A. Mobitz Type I - Wenckebach

B. Infranodal conduction defect

C. First-degree AV block

D. Third-degree AV block

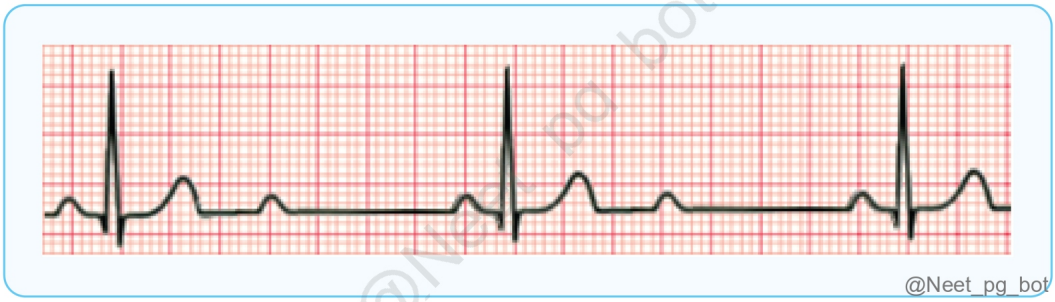

See Answer in Part B → Q14

@Neet_pg_bot

Q15: A 72-year-old man is brought to the ER due to sudden onset syncope in the bathroom. His medical history includes hypertension and a prior myocardial infarction. ECG of the patient is given below. What is the most appropriate initial management for this patient? (Q850685)

A. Oral beta-blockers

B. Temporary pacing

C. Permanent pacemaker placement

D. IV atropine 0.4 mg

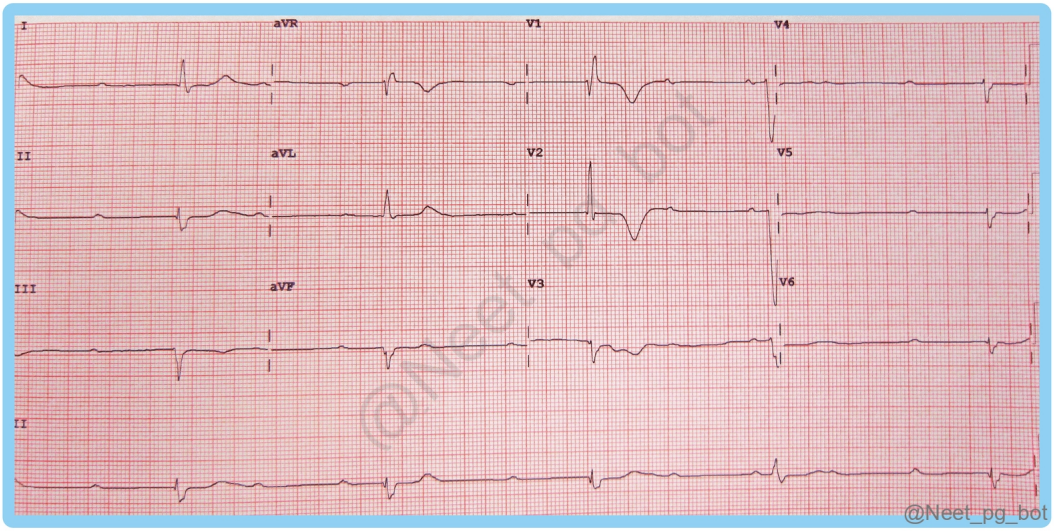

See Answer in Part B → Q15

@Neet_pg_bot

Q16: A 68-year-old male patient presents to the ER with complaints of fatigue and occasional lightheadedness. He has a history of hypertension and coronary artery disease. During the examination, he describes episodes of near-syncope. The physician performs an ECG to evaluate his symptoms. What is the most likely diagnosis based on the ECG findings? (Q850668)

A. First-degree heart block

B. Mobitz Type I

C. Mobitz Type II

D. Complete heart block



See Answer in Part B → Q16

@Neet_pg_bot

Q17: A 58-year-old woman comes to the clinic for an annual medical check up. She has a history of mild hypertension, which is well-controlled with medication. She reports no symptoms such as palpitations, dizziness, or chest pain. An ECG of the patient is given below. What is the most likely diagnosis based on the ECG findings? (Q850631)

A. Second-Degree AV Block

B. First-Degree AV Block

C. Third-Degree AV Block

D. Bundle Branch Block

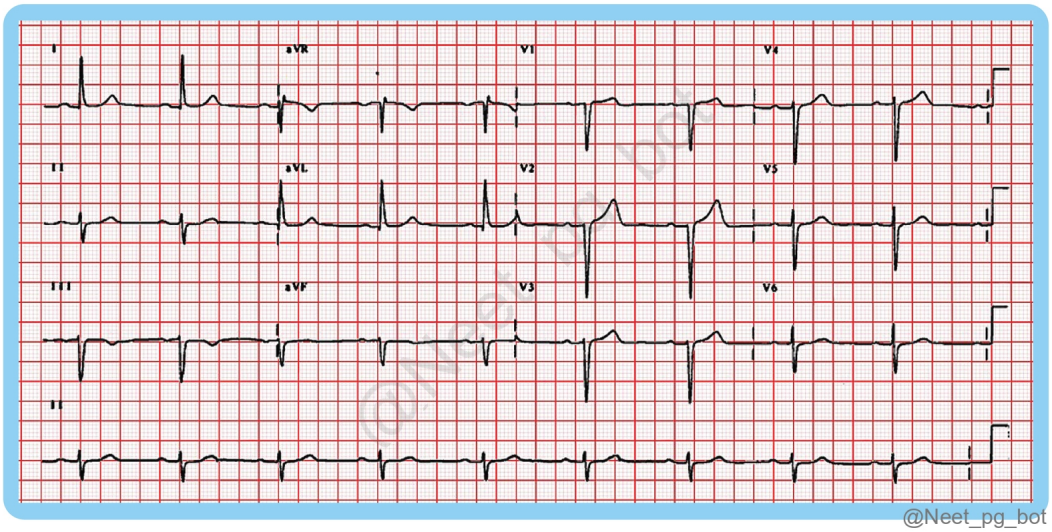

See Answer in Part B → Q17

@Neet_pg_bot

Q18: A 25-year-old male presents with recurrent palpitations and dizziness. An ECG of the patient is given below. Which of the following statements is true regarding this patient's diagnosis? (Q850625)

A. He is at risk for pre-excited atrial fibrillation leading to dangerously fast ventricular rates

B. The accessory pathway is the Bundle of James, facilitating rapid conduction.

C. ECG shows prolonged PR interval with delta waves

D. Adenosine is drug of choice for this condition

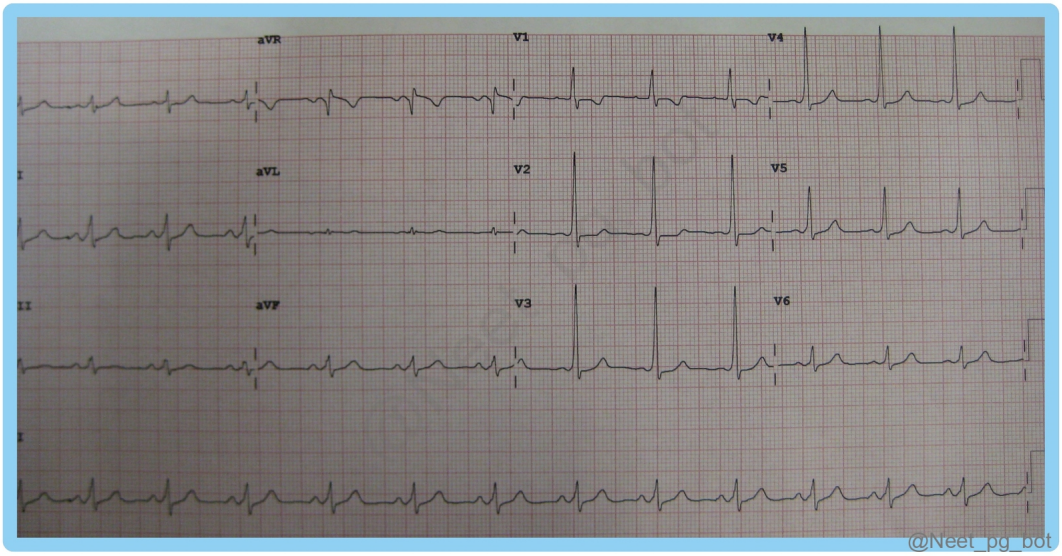

See Answer in Part B → Q18

@Neet_pg_bot

Q19: A 28-year-old male presents to the emergency department with palpitations and lightheadedness. He has no significant past medical history and is otherwise healthy. After a thorough examination, an ECG is obtained. Based on the patient's presentation and the findings of the ECG, what is the most likely diagnosis? (Q850619)

A. Atrial Fibrillation

B. Wolff-Parkinson-White (WPW) Syndrome

C. First-degree AV Block

D. Second degree heart block

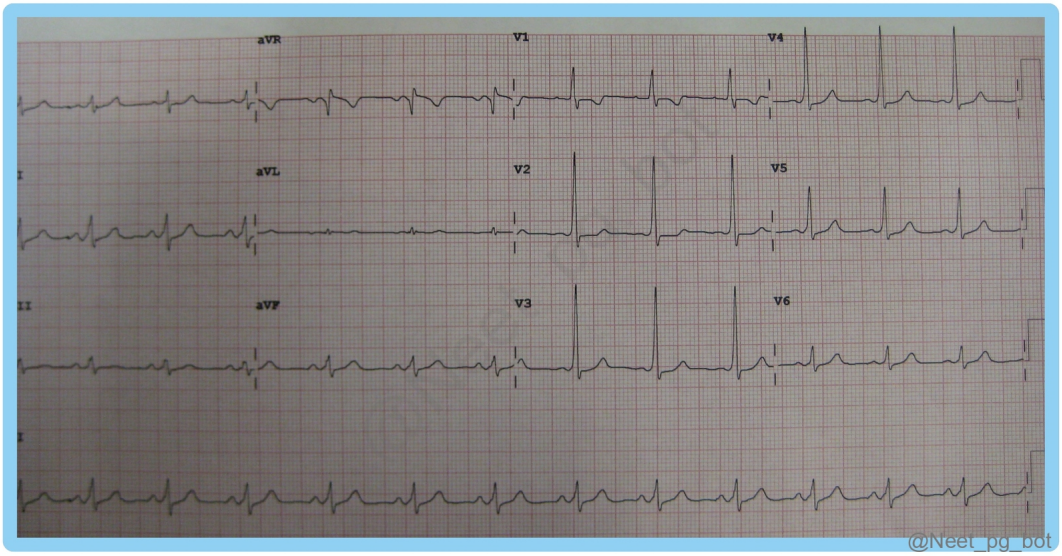

See Answer in Part B → Q19

@Neet_pg_bot

Q20: A 2-year-old child is referred to your hospital for a suspected congenital heart condition due to central cyanosis. On examination, there is a prominent jugular venous pulsation and a pansystolic murmur at the left lower sternal border. ECG shows Himalayan P waves. Which condition will you suspect? (Q850611)

A. Ebstein’s Anomaly

B. Atrial septal defect

C. Ventricular septal defect

D. Tetralogy of Fallot

See Answer in Part B → Q20

@Neet_pg_bot

Q21: A 60-year-old woman with a history of hypertension and diabetes presents with a one-month history of mild exertional dyspnea. She denies chest pain but has noticed some occasional palpitations. Physical examination reveals a blood pressure of 140/90 mmHg and regular heart sounds. You order an ECG, which is shown below. What is

the most likely diagnosis based on this ECG? (Q850602)

A. Normal axis

B. Right axis deviation

C. Left axis deviation

D. Extreme axis deviation

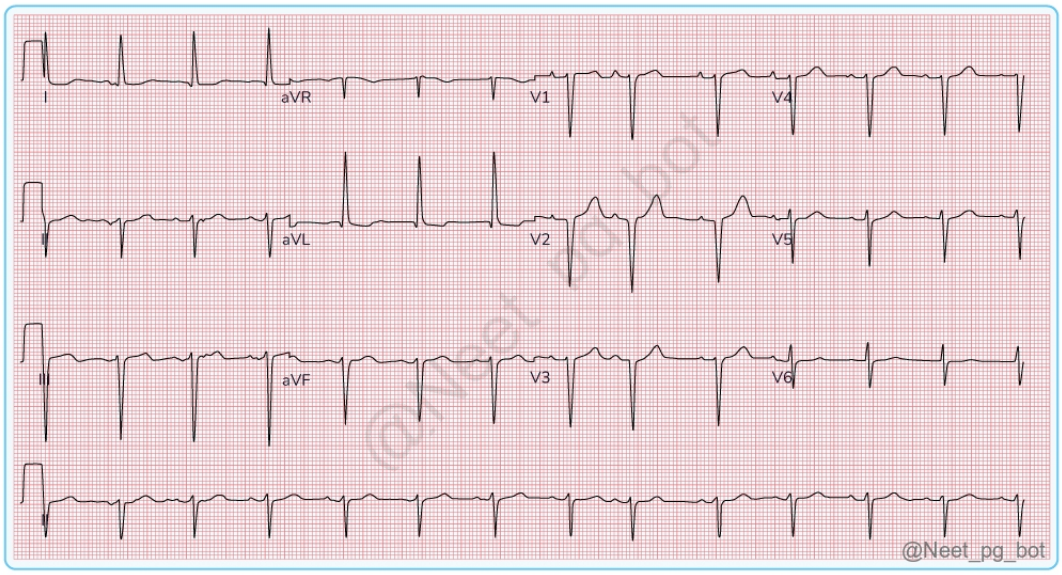

See Answer in Part B → Q21

@Neet_pg_bot

• [01_Cardiology] 005 Ischemic Heart Disease

« Back to Folder Directory

[01_Cardiology] 005 Ischemic Heart Disease — Quick Jump

Q1 (p. 73)	*Q2 (p. 73)*	*Q3 (p. 74)*	*Q4 (p. 74)*	*Q5 (p. 75)*	*Q6 (p. 75)*
Q7 (p. 76)	*Q8 (p. 76)*	*Q9 (p. 77)*	*Q10 (p. 77)*	*Q11 (p. 78)*	*Q12 (p. 79)*
Q13 (p. 79)	*Q14 (p. 80)*	*Q15 (p. 80)*	*Q16 (p. 81)*	*Q17 (p. 81)*	*Q18 (p. 82)*
Q19 (p. 82)	*Q20 (p. 83)*	*Q21 (p. 84)*	*Q22 (p. 85)*	*Q23 (p. 85)*	*Q24 (p. 85)*
Q25 (p. 86)	*Q26 (p. 86)*	*Q27 (p. 87)*	*Q28 (p. 87)*		

Q1: A 35-year-old woman comes at 8 am to the ER with chest pain that started last evening and has progressively worsened. She describes the pain as a burning sensation accompanied by a sour taste in her mouth, which began shortly after dinner. She has had similar experiences previously. This morning she passed a black stool. ECG and Echocardiography shows normal results. What is next investigation to be performed in this patient? (Q850457)

A. 24 hour pH monitoring

B. Endoscopy

C. hs-CTn

D. Coronary CT angiography

See Answer in Part B → Q1

@Neet_pg_bot

Q2: A 70-year-old male presents with an acute onset of severe dyspnea and shock 5 days after receiving fibrinolysis for STEMI. On examination, an early systolic murmur is heard at the apex. Echocardiography reveals valvular dysfunction. What is the most likely cause of his condition? (Q850499)

A. Ventricular septal rupture

B. Papillary muscle rupture

C. Ventricular aneurysm

D. Ventricular rupture

See Answer in Part B → Q2

@Neet_pg_bot

Q3: A 65-year-old male patient presents 6 weeks after experiencing an ST-elevation myocardial infarction . He reports malaise, fever, and chest discomfort that worsens with deep breathing. On examination, a pericardial friction rub is heard. Laboratory tests reveal leukocytosis and an elevated ESR. What is the most appropriate initial treatment for this condition? (Q850496)

A. Glucocorticosteroids

B. Aspirin

C. Colchicine

D. Rescue PCI

See Answer in Part B → Q3

@Neet_pg_bot

Q4: A 60-year-old female with a history of hypertension and hyperlipidemia presents with severe chest pain for 3 hours. She has a blood pressure of 180/110 mmHg and a history of active peptic ulcer disease. Her ECG shows ST-elevation in leads V2-V4. What is the most appropriate treatment option for this patient? (Q850493)

A. Streptokinase

B. Tissue plasminogen activator

C. Coronary artery bypass surgery

D. Percutaneous coronary intervention

See Answer in Part B → Q4

@Neet_pg_bot

Q5: A 60-year-old male with a history of hypertension and hyperlipidemia presents with chest pain lasting 45 minutes. His ECG shows STE in lead I, avL, V5, V6. Which of the following statements about his management is correct? (Q850490)

A. Beta blockers should be avoided in all patients with STEMI.

B. First line drug for the management of STEMI is Streptokinase

C. LMWH provides more reliable anticoagulation than UFH.

D. Leading cause of death after 24 hours of hospitalization is cardiac rupture

See Answer in Part B → Q5

@Neet_pg_bot

Q6: A 65-year-old male presents with central chest pain for the last 3 hours radiating to the left shoulder. On admission, blood pressure is 150/100 mmHg, and his oxygen saturation is 95% on room air. Which of the following drugs should be avoided in this patient? (Q850486)

A. Administer morphine IV for pain relief

B. Administer nifedipine to relieve chest pain

C. Administer clopidogrel loading dose for platelet inhibition

D. Administer sublingual nitroglycerin (0.4 mg) to reduce myocardial oxygen demand

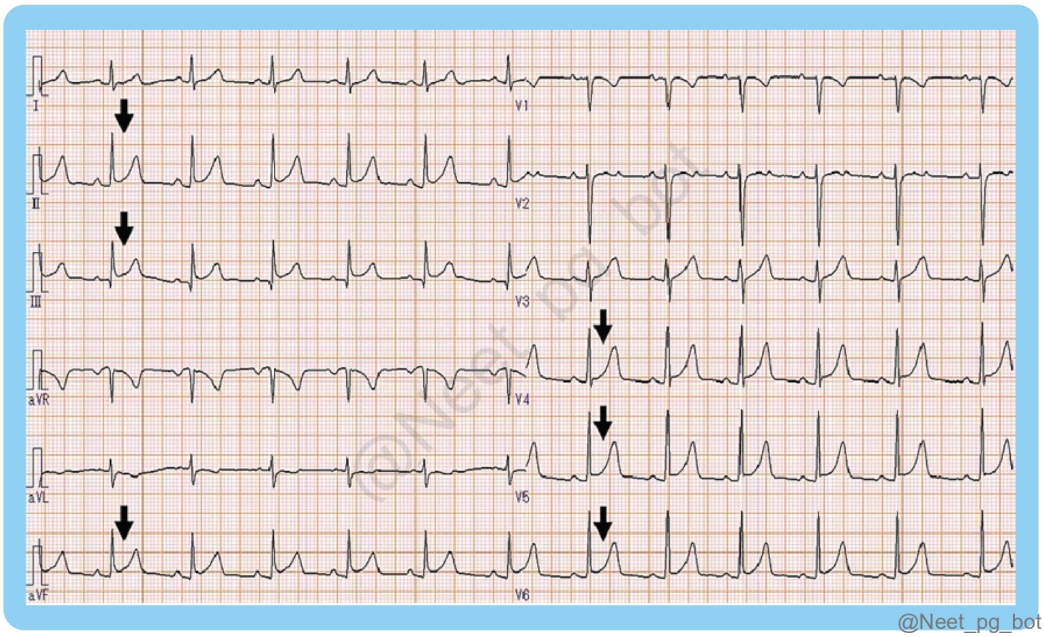

See Answer in Part B → Q6

@Neet_pg_bot

Q7: Which of the following would provide the least accurate diagnosis of Myocardial infarction? (Q850483)

A. Echocardiography

B. Coronary angiography

C. High sensitivity Troponin I

D. Radionuclide ventriculography

See Answer in Part B → Q7

@Neet_pg_bot

Q8: A 58-year-old male smoker was managed with primary PCI for STEMI 4 days ago. On the day of planned discharge he again develops central chest pain. Which of the following should be done in this patient to identify a reinfarction? (Q850479)

A. Troponin T

B. Creatine Kinase-MB

C. Lactate Dehydrogenase

D. Heart fatty acid-binding Protein

See Answer in Part B → Q8

@Neet_pg_bot

Q9: A 58-year-old male presents with chest pain, and an ECG reveals the following changes Based on these findings, which coronary artery is most likely affected? (Q850477)

A. Left Circumflex Artery

B. Right Coronary Artery

C. Anterior Interventricular Artery

D. Posterior Descending Artery

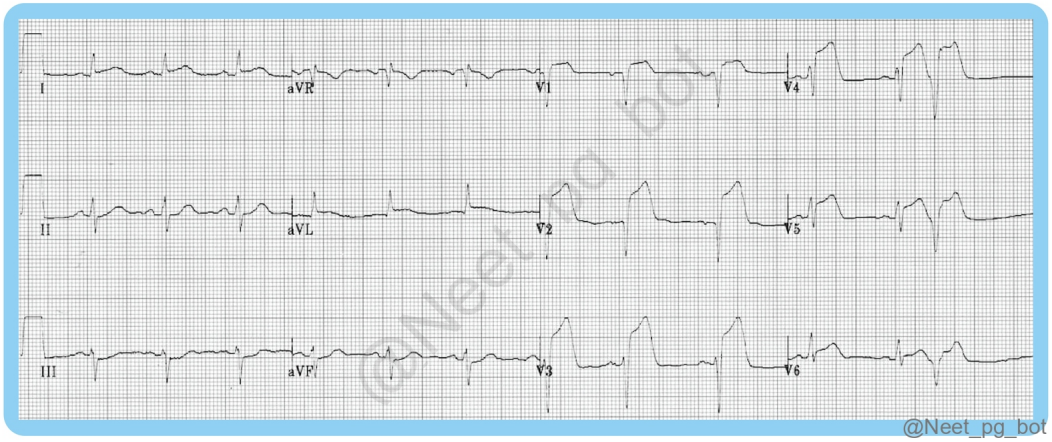

See Answer in Part B → Q9

@Neet_pg_bot

Q10: A 65-year-old male patient with a history of coronary artery disease undergoes angiography, which reveals a thrombus in the right coronary artery (RCA). Based on this finding, which area of the heart is most likely to be affected by an infarct?

(Q850475)

A. Anterior wall

B. Lateral wall

C. Inferior wall

D. Septal wall

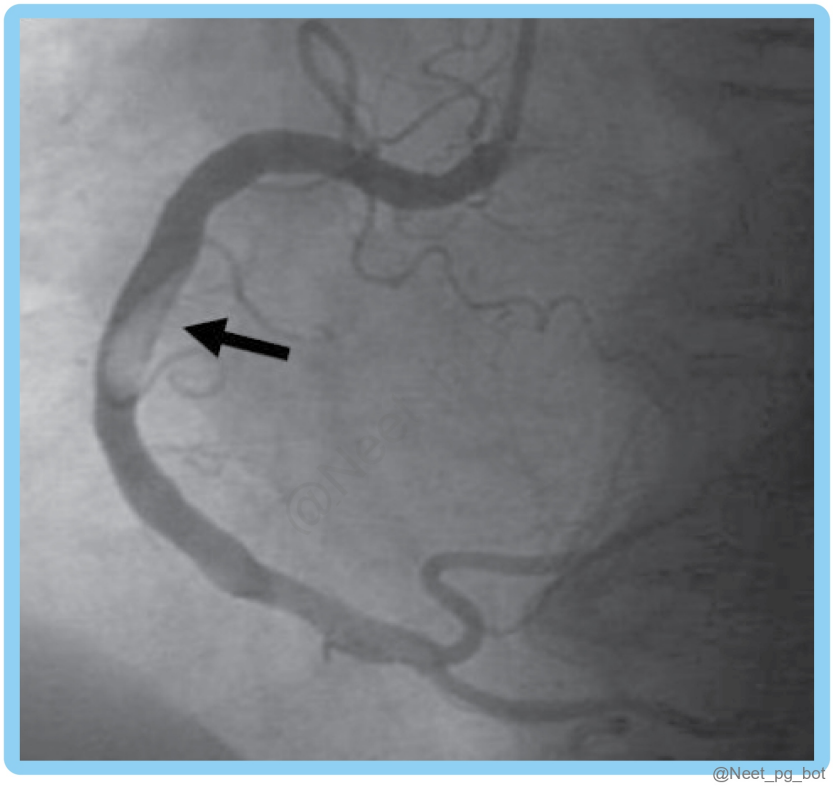

See Answer in Part B → Q10

@Neet_pg_bot

Q11: Which of the following is correct placement for Lead II on the ECG? (Q850474)

A. Left arm (+) to Left arm (–)

B. Right arm (+) to Left arm (–)

C. Left arm (–) to Left leg (+)

D. Right arm (–) to Left leg (+)

See Answer in Part B → Q11

@Neet_pg_bot

Q12: A 56-year-old smoker male presented to the emergency department with chest pain radiating to interscapular area. On examination unequal radial artery pulse is palpated with BP of 180/110 mm Hg. Clinical diagnosis is: (Q850466)

A. Aortic dissection

B. Preductal coarctation of aorta

C. Aortic transection

D. Postductal coarctation of aorta

See Answer in Part B → Q12

@Neet_pg_bot

Q13: A 60-year-old male presents with a sudden onset of severe chest pain that radiates to his left arm. This pain started about 60 minutes ago while he was having his breakfast. His medical history includes hypertension and hyperlipidemia. An ECG has been performed and cardiac biomarkers are significantly elevated. What is the most likely cause of his presentation? (Q850465)

A. Coronary artery spasm

B. Coronary artery embolism

C. Spontaneous coronary artery dissection

D. Plaque rupture

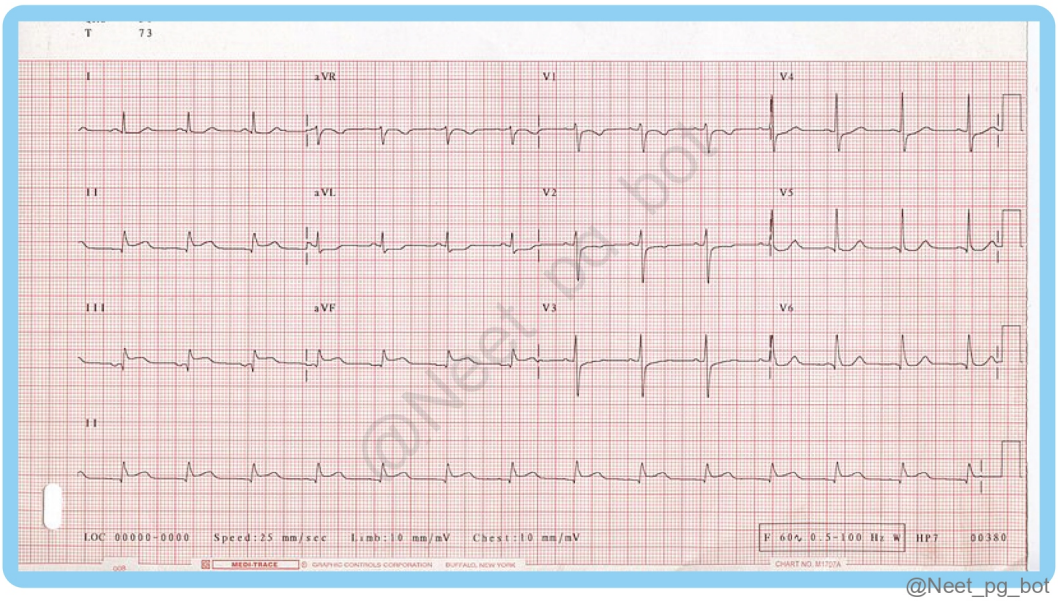

@Neet_pg_bot

See Answer in Part B → Q13

@Neet_pg_bot

Q14: A 72-year-old man underwent PCI with drug-eluting stents for double vessel disease yesterday. Today he develops chest pain with ECG showing ST-segment depression and cTn levels rising to five times the 99th percentile of the upper limit. What type of MI is seen in this case? (Q850462)

A. Type 1

B. Type 2

C. Type 3

D. Type 4

See Answer in Part B → Q14

@Neet_pg_bot

Q15: Which of the following is correct about predisposition to atherosclerosis in these vessels? (Q850396)

A. Popliteal arteries > Coronary arteries > Circle of Willis > Abdominal aorta

B. Coronary arteries > Abdominal aorta > Circle of Willis > Popliteal arteries

C. Abdominal aorta > Coronary arteries > Popliteal arteries > Circle of Willis

D. Coronary arteries > Circle of Willis > Abdominal aorta > Popliteal arteries

See Answer in Part B → Q15

@Neet_pg_bot

Q16: A 58-year-old man presents with chest pain at rest for the past 4 hours. He has a history of hypertension and hyperlipidemia. ECG shows ST-segment depression in lead II, III, aVF and his cardiac troponin levels are elevated. What is the most appropriate next step in managing this patient's condition? (Q850452)

A. Immediate coronary artery bypass grafting

B. Thrombolysis

C. High-intensity Atorvastatin and ACEI

D. Aspirin and Ticagrelor

See Answer in Part B → Q16

@Neet_pg_bot

Q17: A 59-year-old woman with T2DM presents to ER with chest discomfort at rest radiationg to jaw and nausea for past 2 hours. ECG shows T wave inversion and ST depression in lead II, III, aVF. Trop I value is greater than 99th centile of upper reference limit. Which of the following is the most likely diagnosis? (Q850448)

A. Stable angina

B. Unstable angina

C. Non-ST elevation MI

D. ST elevation MI

See Answer in Part B → Q17

@Neet_pg_bot

Q18: Check out this ECG finding and select the condition(s) that can present with this change? Hyperkalemia Variant Angina Digoxin (Therapeutic doses) Left Ventricular Hypertrophy (LVH) Chronic Stable Angina (Q850441)

A. 1 and 3

B. 1 and 2

C. 2, 3, and 5

D. 1, 2 and 5



See Answer in Part B → Q18

@Neet_pg_bot

Q19: A 65-year-old woman presents to the ER with early morning episode of chest pain lasting 15 minutes which is relieved by sublingual nitroglycerin. She has had similiar episodes in past and her husband says that metoprolol was started which worsend her chest pain episodes so they stopped the medication. Past medical history is significant for Raynaud phenomenon. ECG is given below. There is no elevation of cardiac markers on serial evaluation. Which of the following is the most likely diagnosis? (Q850434)

A. Stable angina

B. Unstable angina

C. Prinzmetal angina

D. Myocardial infarction

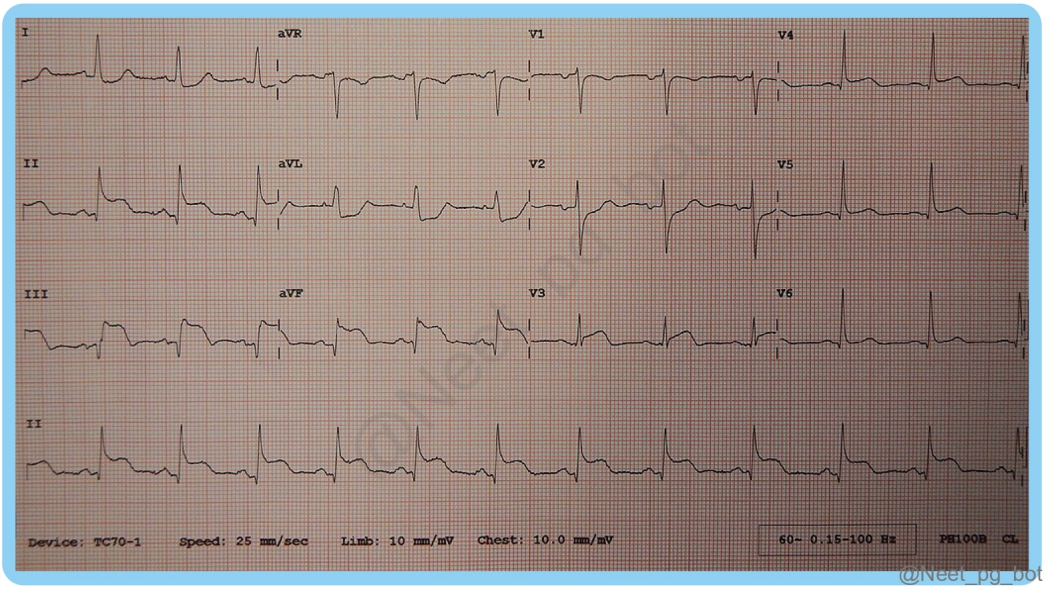

See Answer in Part B → Q19

@Neet_pg_bot

Q20: A 62-year-old male presents to ER central chest pain at rest and shortness of breath for last one hour. His medical history includes hypertension and hyperlipidemia. Troponin I is elevated. Which of the following is the most appropriate initial management for this patient's condition? (Q850428)

A. Send for PCI

B. Chewable Aspirin and Atorvastatin

C. Enoxaparin and Eptifibatide

D. IV atropine followed by temporary pacing

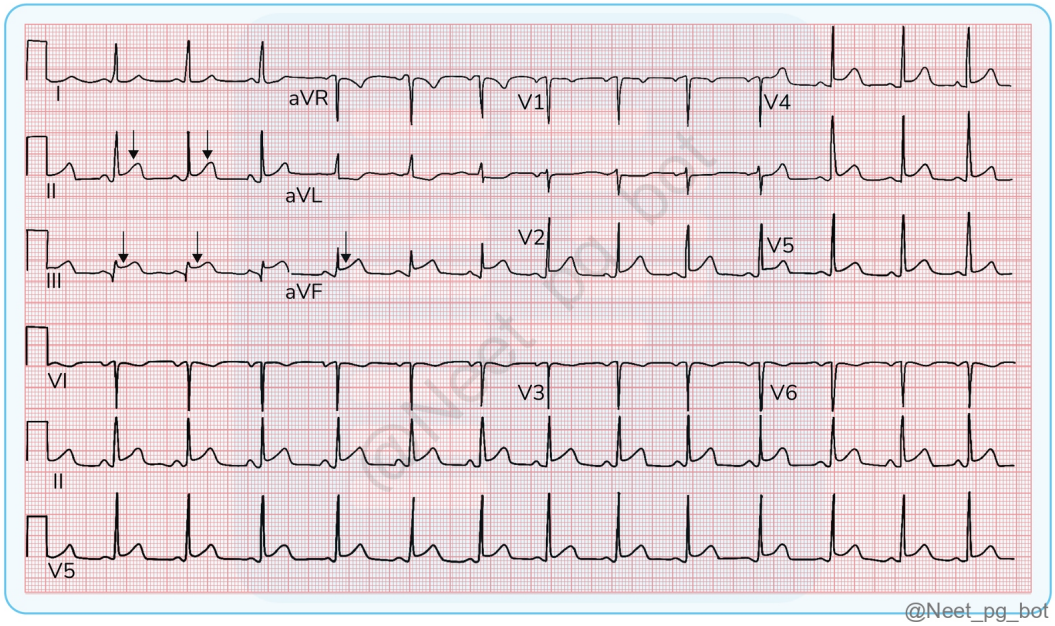

See Answer in Part B → Q20

@Neet_pg_bot

Q21: A 65-year-old woman is known case of chronic stable angina and has undergone PCI with stenting last year. Today morning, she presents to the ER with a 60-minute episode of chest discomfort that occurred while she was watching television. She describes the pain as a tightness in his chest, radiating to her left arm. She has a history of T2DM and has deranged lipid profile. An ECG reveals inverted T-waves. Which of the following is the best next step in the management of this patient? (Q850422)

A. Cardiac biomarkers

B. Send to Cath lab for PCI

C. Treadmill test

D. Myocardial perfusion imaging

See Answer in Part B → Q21

@Neet_pg_bot

Q22: What is the revascularization procedure of choice for two different cases, Patient A with triple vessel disease and Patient B with left anterior descending artery blockage with EF < 40%? (Q850420)

A. A: CABG; B: PCI with stenting

B. CABG for both A and B

C. A: PCI with stenting; B: CABG

D. A: PCI with Bare metal stenting ; B: PCI with drug eluting stenting

See Answer in Part B → Q22

@Neet_pg_bot

Q23: A 65-year-old male with chronic stable angina presents with chest pain during routine activities. His current medications include aspirin, metoprolol, isosorbide mononitrate and atorvastatin, but his symptoms persist. Coronary angiography reveals 90% stenosis of the right coronary artery. and 70% in LCX. What is the most appropriate intervention? (Q850416)

A. Increase the dose of beta-blockers

B. Increase the dose of Long acting nitrates

C. PCI with drug-eluting stenting

D. Refer for coronary artery bypass grafting

See Answer in Part B → Q23

@Neet_pg_bot

Q24: A 60-year-old man with a history of CAD presents with recurrent syncope. Considering his intermediate to high risk for CAD, which imaging modality would be most appropriate for further evaluation? (Q850414)

A. Myocardial Perfusion Imaging

B. Stress Echocardiography

C. Multigated Acquisition (MUGA) Scanning

D. Treadmill test

See Answer in Part B → Q24

@Neet_pg_bot

Q25: A 60-year-old male smoker presents with chest pain on climbing stairs. He is started on low-dose aspirin, statins and metoprolol by his GP. His symptoms have worsened despite medical therapy. What is the next best step in diagnosing the extent of his coronary artery disease? (Q850409)

A. Stress echocardiography

B. Myocardial perfusion imaging

C. Coronary angiography

D. Coronary computed tomography angiography

See Answer in Part B → Q25

@Neet_pg_bot

Q26: A 60-year-old male undergoes a treadmill ECG stress test and develops 2 mm of horizontal ST-segment depression after 12 minutes of exercise. He reports non-limiting chest pain (angina index = 1). What is his Duke Treadmill Score (DTS) and his risk category? (Q850405)

A. DTS = 0; Intermediate risk

B. DTS = 5; Low risk

C. DTS = -2; Intermediate risk

D. DTS = -8; High risk

See Answer in Part B → Q26

@Neet_pg_bot

Q27: An elderly male with a history of cigarette smoking and hypertension develops chest pain after an evening walk. The pain is relieved after lying down for a few minutes. A treadmill stress test reveals ST-segment depression. What is the most likely cause attributed to this clinical presentation? (Q850402)

A. Hypertrophic Cardiomyopathy

B. Prinzmetal Angina

C. Non-ST-Elevation Myocardial Infarction (NSTEMI)

D. Chronic Stable Angina

See Answer in Part B → Q27

@Neet_pg_bot

Q28: Arrange the following structures of an atherosclerotic plaque inside a blood vessel from the innermost to the outermost layer: Fibrous cap Necrotic core Foam cell layer Media (Q850399)

A. Fibrous cap → Foam cell layer→ Necrotic core → Media

B. Necrotic core → Media → Foam cell layer → Fibrous cap

C. Foam cell layer → Fibrous cap → Media→ Necrotic core

D. Foam cell layer → Necrotic core → Fibrous cap → Media

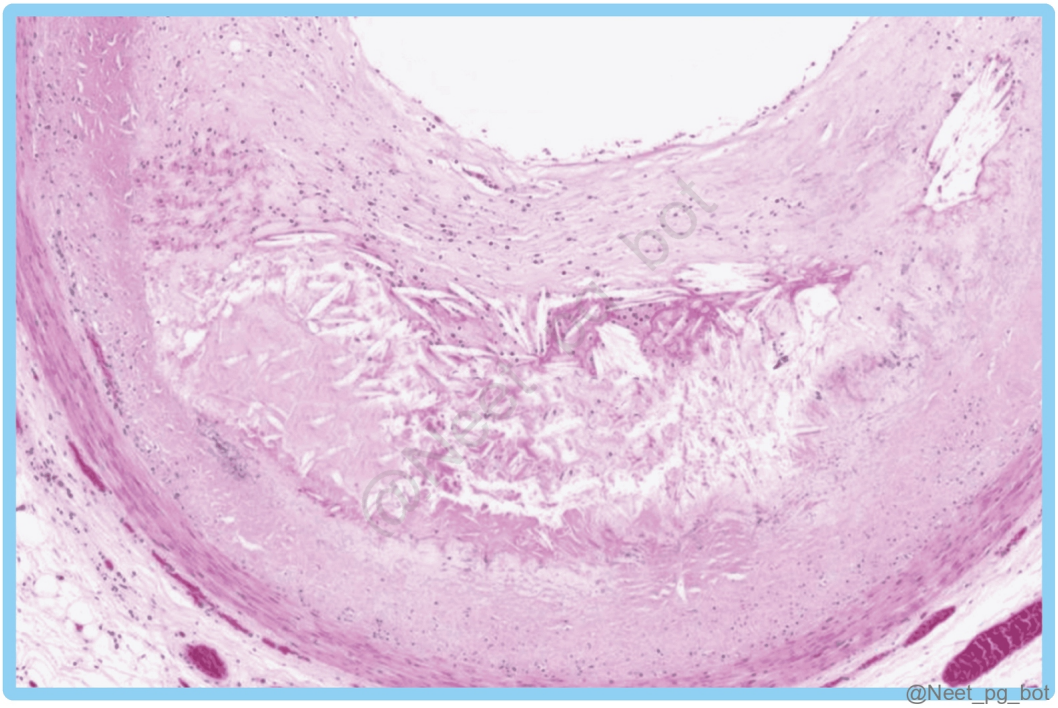

See Answer in Part B → Q28

@Neet_pg_bot

• [01_Cardiology] 006 Systemic Htn Pulmonary Htn

« Back to Folder Directory

[01_Cardiology] 006 Systemic Htn Pulmonary Htn — Quick Jump

Q1 (p. 89) *Q2 (p. 89)* *Q3 (p. 90)* *Q4 (p. 90)* *Q5 (p. 90)* *Q6 (p. 91)*
Q7 (p. 91) *Q8 (p. 92)* *Q9 (p. 92)* *Q10 (p. 93)*

Q1: A 55-year-old male presented to the clinic for a routine check-up last week. Automated Office Blood Pressure (AoBP) readings of 142/94, 138/86, and 138/90 mmHg. Ambulatory blood pressure monitoring (ABPM) was advised and the average 24-hour blood pressure is 138/86 mmHg. According to the ACC/AHA hypertension classification, what category does his blood pressure fall into? (Q850501)

A. Normal blood pressure

B. Elevated blood pressure

C. Stage 1 hypertension

D. Stage 2 hypertension

See Answer in Part B → Q1

@Neet_pg_bot

Q2: A 60-year-old male with a BMI of 30 presents with frequent headaches and dizziness. His office blood pressure is recorded as 126/74 mmHg, but home readings range between 150/94 mmHg and 156/90 mmHg. Ambulatory blood pressure monitoring confirms these findings with higher readings outside the office. Which of the following is the most appropriate management plan for this patient? (Q850503)

A. Lifestyle modifications alone is sufficient

B. Initiate antihypertensive therapy

C. Increase clinic visit frequency to monitor blood pressure

D. Diagnosis to be reconfirmed in 3 to 6 months

See Answer in Part B → Q2

@Neet_pg_bot

Q3: During a lecture on cardiovascular physiology, a professor explained that conditions causing unequal arm blood pressure often involve branches of the aortic arch. Which of the following conditions is not likely to cause a difference in blood pressure between the arms? (Q850504)

A. Aortic dissection involving the ascending aorta

B. Coarctation of the aorta distal to the left subclavian artery

C. Takayasu arteritis affecting the aortic arch

D. Subclavian artery stenosis

See Answer in Part B → Q3

@Neet_pg_bot

Q4: A 28-year-old male with a history of resistant hypertension and periodic muscle cramps is being investigated. Lab tests show hypokalemia, low plasma renin activity, and low aldosterone levels. Genetic testing reveals a mutation in the epithelial sodium channel (ENaC). What is the most likely diagnosis? (Q850505)

A. Gordan syndrome

B. Liddle syndrome

C. Congenital adrenal hyperplasia (CAH)

D. Pheochromocytoma

See Answer in Part B → Q4

@Neet_pg_bot

Q5: A 65-year-old man with a long-standing history of hypertension presents with occasional episodes of dizziness and transient visual disturbances. Neurological examination and fundoscopy are normal. A carotid doppler is performed to visualize the carotid arteries. Which of the following findings is not expected to be seen in this patient? (Q850507)

A. Increased peak systolic velocity

B. Normal intima-media thickness

C. String sign

D. Turbulent blood flow in the carotid arteries

See Answer in Part B → Q5

@Neet_pg_bot

Q6: A 70-year-old male with a history of hypertension and not on medications has chronic kidney disease . His laboratory tests indicate an estimated glomerular filtration rate of 60 mL/min and elevated protein in his urine. His present blood pressure is 142/90 mmHg. Considering his condition, which of the following antihypertensive medications is most appropriate to initiate? (Q850508)

A. Amlodipine

B. Lisinopril

C. Hydrochlorothiazide

D. Metoprolol

See Answer in Part B → Q6

@Neet_pg_bot

Q7: Which of the following is most appropriate step cabout management of poorly controlled asthmatic on daily Formoterol and medium dose inhaled steroids and is still having nocturnal attacks daily? (Q850509)

A. Start Oral corticosteroids

B. Add LAMA

C. Start high dose inhaled corticosteroids

D. Start IV steroids

See Answer in Part B → Q7

@Neet_pg_bot

Q8: A 55-year-old male presents with severe headache, nausea, and confusion. His blood pressure is recorded at 190/130 mmHg. Neurological examination reveals altered mental status, and the patient appears distressed. A fundoscopic exam shows retinal haemorrhages. What is the most appropriate classification of this patient's condition? (Q850510)

A. Hypertensive urgency

B. Hypertensive emergency

C. Malignant hypertension

D. Essential hypertension

See Answer in Part B → Q8

@Neet_pg_bot

Q9: A 65-year-old man with a history of type 2 diabetes and hypertension presents to his primary care physician for a follow-up appointment. His blood pressure is 160/95 mmHg. The physician wants to start an antihypertensive medication. What is the target blood pressure for this patient? (Q850512)

A. < 140/90 mmHg

B. < 135/85 mmHg

C. < 130/80 mmHg

D. < 150/90 mmHg

See Answer in Part B → Q9

@Neet_pg_bot

Q10: Which of the following is incorrect regarding the image given? (Q850513)

A. Can help identify the white-coat effect in patients

B. Continuous readings for a full 24-hour period

C. Measures both awake and sleep averages

D. Used to investigate hypertension only

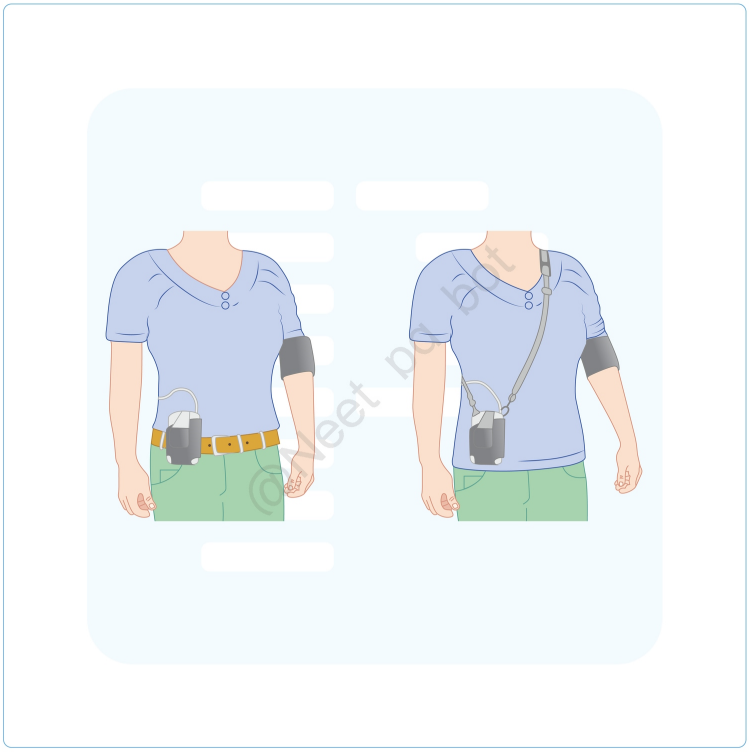

@Neet_pg_bot

See Answer in Part B → Q10

@Neet_pg_bot

• [01_Cardiology] 007 Chf Bbb Tachycardia Bradycardia And Heart Block

« Back to Folder Directory

[01_Cardiology] 007 Chf Bbb Tachycardia Bradycardia And Heart Block — Quick Jump

Q1 (p. 94)	*Q2 (p. 94)*	*Q3 (p. 95)*	*Q4 (p. 95)*	*Q5 (p. 95)*	*Q6 (p. 96)*
Q7 (p. 97)	*Q8 (p. 98)*	*Q9 (p. 98)*	*Q10 (p. 99)*	*Q11 (p. 100)*	*Q12 (p. 100)*
Q13 (p. 100)	*Q14 (p. 101)*	*Q15 (p. 101)*	*Q16 (p. 102)*	*Q17 (p. 103)*	*Q18 (p. 103)*

Q1: Which of the following statements is false about first-degree atrioventricular block? (Q850536)

A. Minor Jones criteria in Rheumatic fever

B. Serial prolongation of PR interval

C. Can be physiological

D. Consistent PR interval with no missed beats

See Answer in Part B → Q1

@Neet_pg_bot

Q2: A 65-year-old man treated with PCI for STEMI develops syncope and is found to have a 2:1 AV block with broad QRS on his ECG. Which of the following is the most likely mechanism behind his AV block, and how would atropine administration affect his condition? (Q850573)

A. The block is most likely in the AV node, and atropine will improve AV conduction.

B. The block is most likely in the His-Purkinje system, and atropine will improve AV conduction.

C. The block is most likely in the AV node, and atropine may increase the degree of AV block.

D. The block is most likely in the His-Purkinje system, and atropine may increase the degree of AV block.

See Answer in Part B → Q2

@Neet_pg_bot

Q3: Which among the following are included in the criteria for Metabolic syndrome 1) Waist circumference > 102 cm in men 2) Waist circumference > 88 cm in women 3) HDL > 50 mg/dL in men 4) BP 115/80 mm Hg 5) Fasting plasma glucose > 100 mg/dL 6) LDL > 200 mg/dL (Q850570)

A. 1, 2, 3, 4, 5

B. 1, 4, 5, 6

C. 1, 2, 5

D. 2, 4, 5, 6

See Answer in Part B → Q3

@Neet_pg_bot

Q4: Drug causing maximum mortality reduction in a patient with HFrEF? (Q850564)

A. Ramipril

B. Carvedilol

C. Spironolactone

D. Canagliflozin

See Answer in Part B → Q4

@Neet_pg_bot

Q5: A patient presents with sudden onset breathlessness. On arrival his vitals were, PR- 130 bpm, BP- 180/110 mmHg and spO 2 - 82% in room air. X-ray done is as shown below.What is the most appropriate next step in managing this patient? (Q850562)

A. Furosemide and Esmolol

B. Furosemide and NTG

C. Furosemide and Diltizaem

D. Furosemide and Digoxin

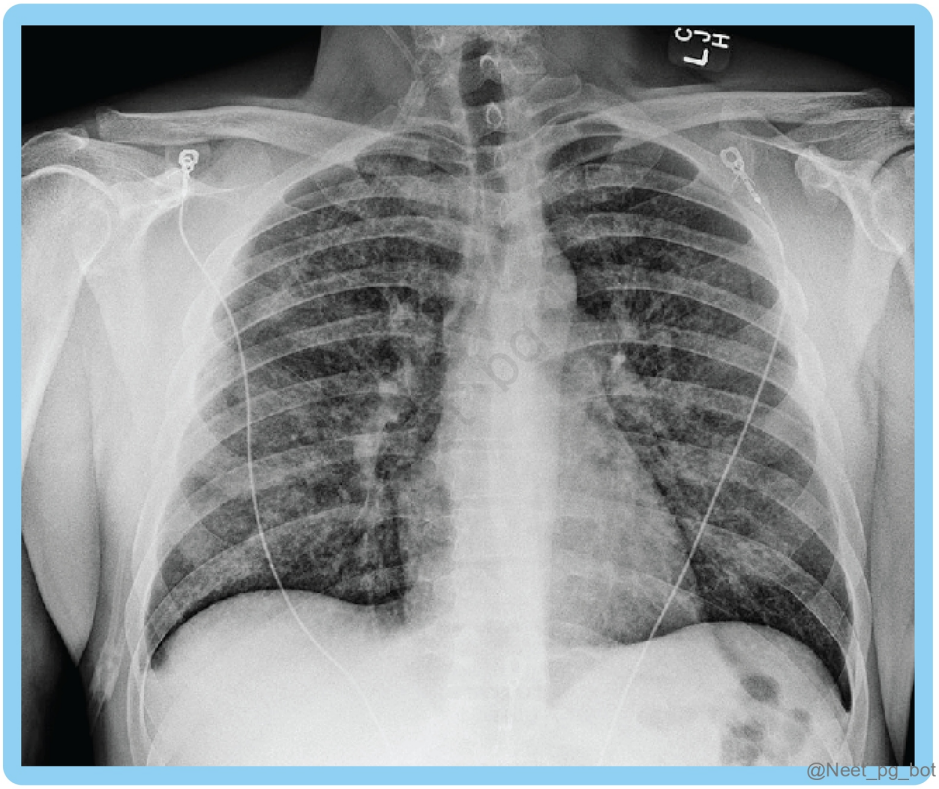

See Answer in Part B → Q5

@Neet_pg_bot

Q6: A 75-year-old man is a known case of triple vessel disease, presented with fatigue. Echocardiography done showed global reduction in contractility and reduced ejection fraction. What is the most likely electrolyte disturbance seen in this patient? (Q850555)

A. Hyponatremia and Hypokalemia

B. Hypernatremia and Hyperkalemia

C. Hyponatremia and Hyperkalemia

D. Hypernatremia and Hypokalemia

See Answer in Part B → Q6

@Neet_pg_bot

Q7: A 50-year-old male comes with complaints of shortness of breath that worsens upon lying down for the past 1 week. On examination, pulse-130 bpm, BP-150/90 mmHg, neck veins are distended, S3+ on cardiac auscultation. He had developed MI last year and was treated. CXR is shown below. Which among the following is not part of the major Framingham's criteria? (Q850549)

A. Dyspnoea worse upon lying down

B. Neck vein distention

C. HR-130 bpm

D. S3

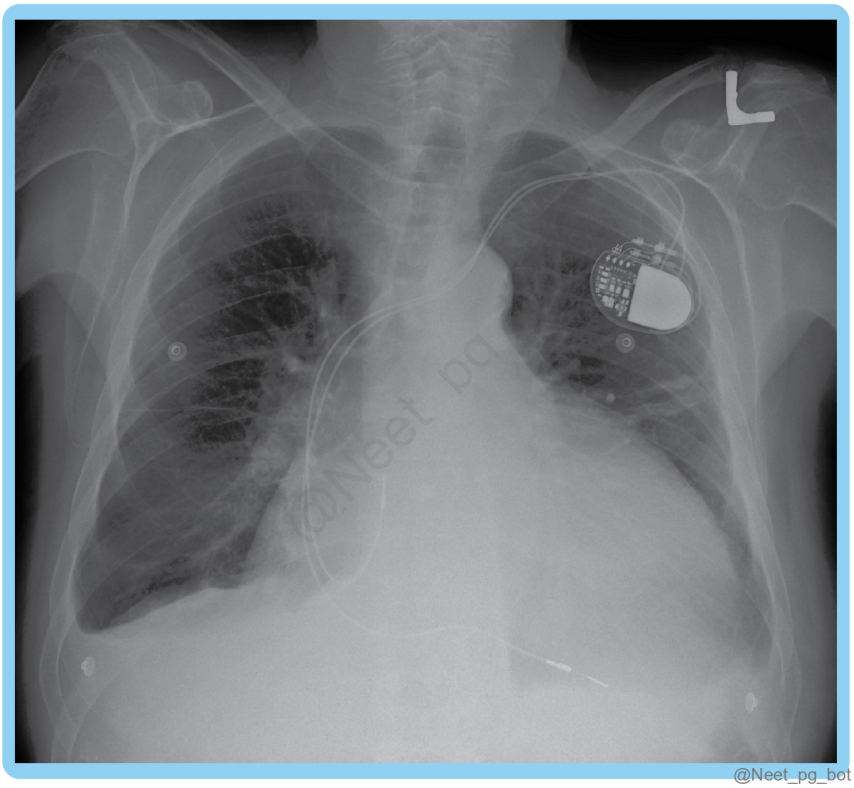

See Answer in Part B → Q7

@Neet_pg_bot

Q8: A 68-year-old male is presented with sudden loss of consciousness and collapses. ECG on arrival at ER is shown below and significant perioral pallor was noted while tracing was being done. What is the diagnosis? (Q850544)

A. Third-degree atrioventricular block

B. Mobitz II heart block

C. Mobitz I block

D. First degree heart block



See Answer in Part B → Q8

@Neet_pg_bot

Q9: Identify the type of heart block from the ECG given below. (Q850539)

A. First-degree AV block

B. 2nd degree heart block, intra nodal conduction delay

C. 2nd degree heart block, Infra nodal conduction delay

D. Third-degree atrioventricular block

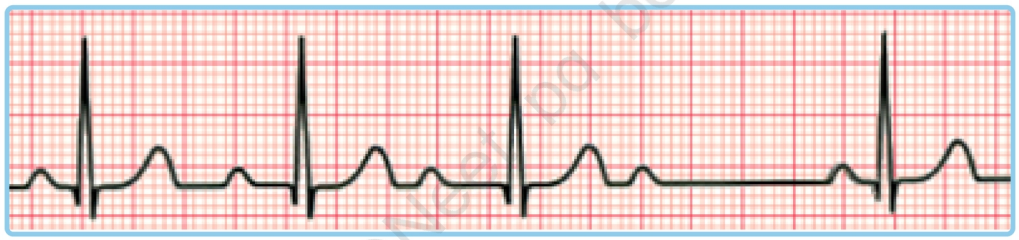

See Answer in Part B → Q9

@Neet_pg_bot

Q10: A 68-year-old smoker presents with breathing trouble and sudden onset palpitations. The ECG is given below and has an irregular rhythm with an average heart rate of 150 beats per minute. What is the most likely diagnosis based on the ECG findings? (Q850516)

A. Atrial Fibrillation

B. Multifocal Atrial Tachycardia

C. Atrial Flutter

D. Sinus Tachycardia

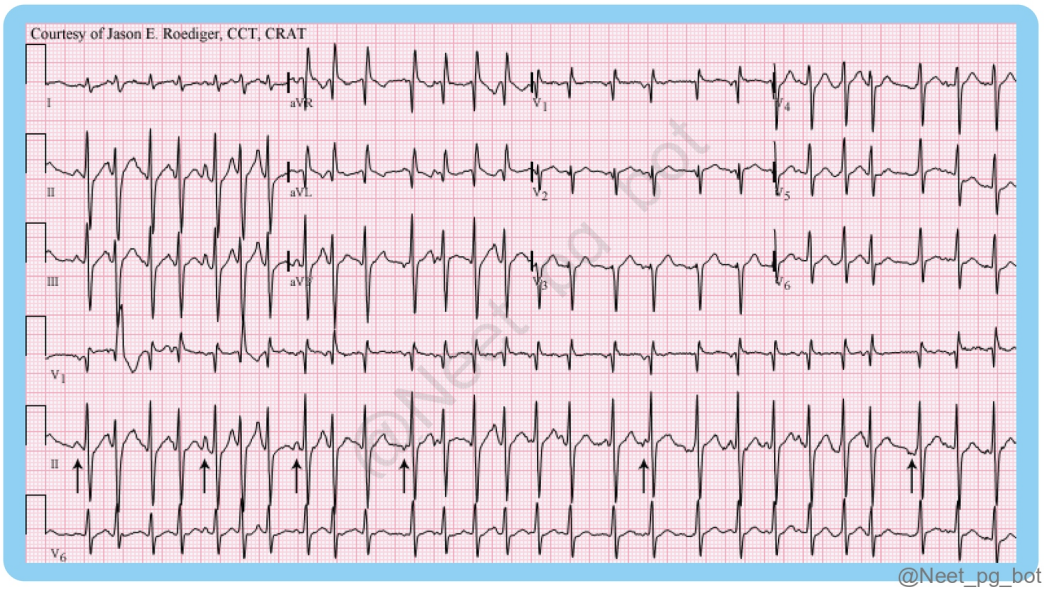

See Answer in Part B → Q10

@Neet_pg_bot

Q11: Which of the following statements on transvenous pacing is wrong? (Q850532)

A. Central venous access is needed

B. Intracardiac lead placement is done

C. Permanent method of pacing

D. Required in inferior wall MI

See Answer in Part B → Q11

@Neet_pg_bot

Q12: A 72-year-old male presents with an inferior wall STEMI. He starts developing altered mental status and heart rate is 38 bpm, blood pressure 80/50 mmHg. Which of the following will be used to manage his bradycadia? (Q850530)

A. IV atropine 1 mg every 3-5 minutes

B. IV atropine 2 mg every 3-5 minutes

C. IV atropine 0.5 mg every 3-5 minutes

D. IV atropine 0.6 mg every 3-5 minutes

See Answer in Part B → Q12

@Neet_pg_bot

Q13: A 38-year-old man with a history of fatigue and daily headaches is found to have a blood pressure 150/100 mmHg on multiple occasions. His chest X-ray shows cardiomegaly and echocardiography shows reduced mitral inflow with concentric hypertrophy of heart. Which of the following is correct about this patient? (Q850529)

A. Systolic malfunction of left ventricle

B. Mitral stenosis

C. Diastolic dysfunction of Left ventricle

D. Mitral regurgitation

See Answer in Part B → Q13

@Neet_pg_bot

Q14: You are performing an annual medical check up of a 48-year-old man corporate executive. What is the most likely diagnosis based on the ECG findings? {{caption_text}} (Q850526)

A. Brugada Syndrome

B. Ventricular Tachycardia

C. Left Bundle Branch Block (LBBB)

D. Right Bundle Branch Block (RBBB)

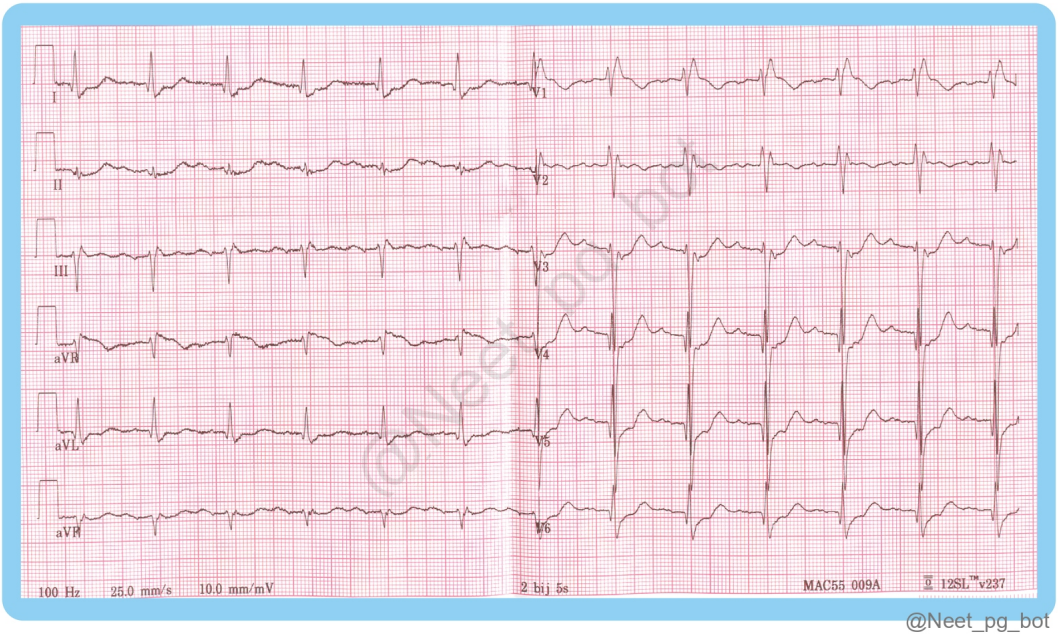

@Neet_pg_bot

See Answer in Part B → Q14

@Neet_pg_bot

Q15: A 60 year old man presents with central chest pain and breathing difficulty for the last 6 hours. He had tested positive for RT-PCR SARS COV-2 yesterday. Auscultation shows bilateral basal crepitations. ECG shows non-specific ST segment changes. Both NT pro-BNP levels and Troponin I levels are elevated. In cath lab coronary angiography is normal. Diagnosis is? (Q850524)

A. Myocarditis

B. Anterior wall Myocardial infarction

C. Broken heart syndrome

D. Acute pericarditis

See Answer in Part B → Q15

@Neet_pg_bot

Q16: A 65-year-old diabetic male develops MI and is taken up for thrombolysis in the district hospital. ECG shows which of the following? (Q850523)

A. Ventricular tachycardia

B. Premature Ventricular Contractions (PVCs)

C. Right Bundle Branch Block (RBBB)

D. Left Bundle Branch Block (LBBB)

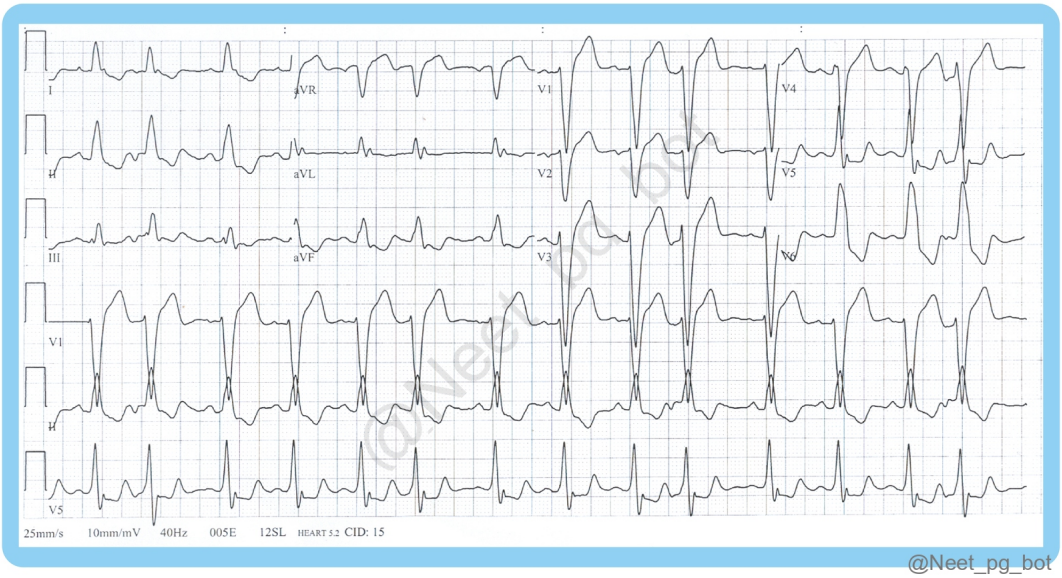

See Answer in Part B → Q16

@Neet_pg_bot

Q17: Calculate the heart rate of the ECG shown below (Q850522)

A. 60 beats per minute

B. 75 beats per minute

C. 100 beats per minute

D. 50 beats per minute



See Answer in Part B → Q17

@Neet_pg_bot

Q18: A 65-year-old smoker with COPD presents to the ER with palpitations and shortness of breath. His ECG shows an irregular rhythm with at least three distinct P-wave morphologies and a heart rate of 120 beats per minute. BP 100/60 mm Hg. Which of the following is the most appropriate management to prevent recurrence of

this rythm disorder (Q850520)

A. Electrical cardioversion

B. Intravenous Diltiazem

C. LTOT with LAMA and LABA

D. IV amiodarone

See Answer in Part B → Q18

@Neet_pg_bot

• [01_Cardiology] 008 Diseases Of The Pericardium And Cardiomyopathies

« Back to Folder Directory

[01_Cardiology] 008 Diseases Of The Pericardium And Cardiomyopathies — Quick Jump

Q1 (p. 105)	*Q2 (p. 105)*	*Q3 (p. 106)*	*Q4 (p. 106)*	*Q5 (p. 106)*	*Q6 (p. 108)*
Q7 (p. 109)	*Q8 (p. 110)*	*Q9 (p. 110)*	*Q10 (p. 111)*	*Q11 (p. 112)*	*Q12 (p. 112)*
Q13 (p. 113)	*Q14 (p. 114)*	*Q15 (p. 114)*	*Q16 (p. 114)*	*Q17 (p. 115)*	*Q18 (p. 116)*
Q19 (p. 117)	*Q20 (p. 118)*	*Q21 (p. 118)*	*Q22 (p. 119)*	*Q23 (p. 120)*	

Q1: A 25 year old male presents with exertional dyspnea and chest pain while playing table tennis. Echocardiography shows systolic anterior movement of mitral valve with LV free wall thickness of 30 mm. He informs you about the sudden death of his elder brother while dancing at a marriage party. Which of the following is the best intervention for management of this patient? (Q850596)

A. Mitral valvotomy

B. Implantable cardioverter defibrillator

C. Propranolol with Disopyramide

D. Surgical myomectomy

See Answer in Part B → Q1

@Neet_pg_bot

Q2: A 55 year old woman presents with acute chest pain and difficulty breathing after learning of the death of her daughter in an air crash. Her ECG shows ST-segment elevation in lead I, aVL, V2-V4. Cardiac biomarkers are elevated. Bed side echocardiography reveals ballooning of the left ventricular apex. What is the most likely diagnosis? (Q850637)

A. Myocardial Infarction

B. Takotsubo Cardiomyopathy

C. Aortic Dissection

D. Brudaga syndrome

See Answer in Part B → Q2

@Neet_pg_bot

Q3: A 55-year-old patient presents with sharp chest pain, fever, and inspiratory catch on taking deep breath 3 weeks after undergoing coronary artery bypass surgery. Which of the following is the most likely underlying mechanism? (Q850635)

A. Constrictive pericarditis

B. Post cardiac injury syndrome

C. Electro-mechanical dissociation

D. Autoimmune myocarditis

See Answer in Part B → Q3

@Neet_pg_bot

Q4: A post-mortem study reveals deposits between the pericardial layers with a “bread and butter” appearance. Which of the following is most consistent with this form of pericarditis? (Q850633)

A. Hemorrhagic pericarditis

B. Purulent pericarditis

C. Fibrinous pericarditis

D. Caseous pericarditis

See Answer in Part B → Q4

@Neet_pg_bot

Q5: A 50 year old alcoholic presents with worsening fatigue, shortness of breath, and leg swelling. The Chest X-ray and Cardiac MRI of the patient are given below. Which of the following statements regarding the treatment of her condition is false? (Q850624)

A. Low dose diuretics should be administered to maintain an euvolemic state.

B. ACE inhibitors are recommended for heart failure with reduced ejection fraction.

C. Beta-blockers should not be used in patients with chronic heart failure.

D. Cardiac resynchronization will reduce symptoms

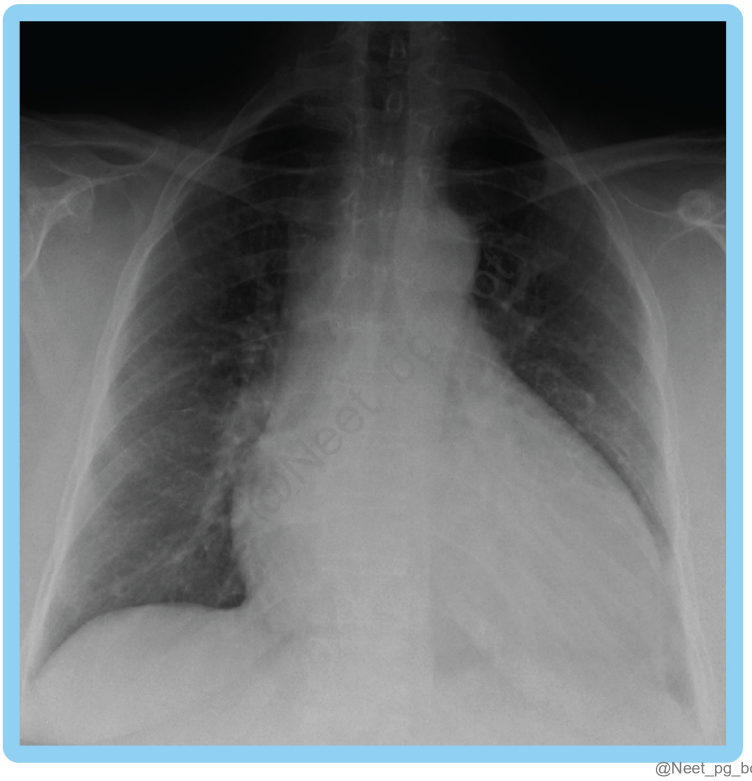

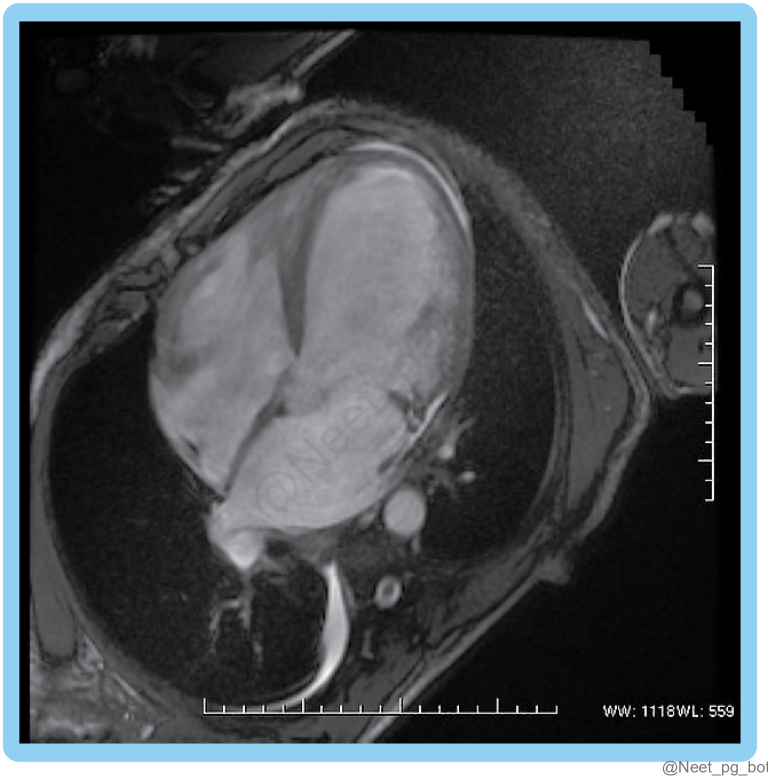

See Answer in Part B → Q5

@Neet_pg_bot

Q6: A 50 year old alcoholic presents with shortness of breath and finding shown in the image. Auscultation reveals pan-systolic murmur. Which of the following findings is most consistent with the diagnosis of this patient? (Q850622)

A. Increased dynamic LV outflow tract obstruction

B. Increased Left ventricular diastolic dimension

C. Double Apical impulse

D. Point of maximum impulse displaced medially



See Answer in Part B → Q6

@Neet_pg_bot

Q7: A 55 year old male presents to the emergency department with fatigue, shortness of breath, and swollen legs. CXR is shown below. Echocardiography shows global hypokinesia with reduced thickness of cardiac chambers. Which of the following is NOT a recognised cause of this patient's diagnosis? (Q850620)

A. Sarcoidosis

B. Chagas disease

C. Scleroderma

D. Heavy metal exposure to lead

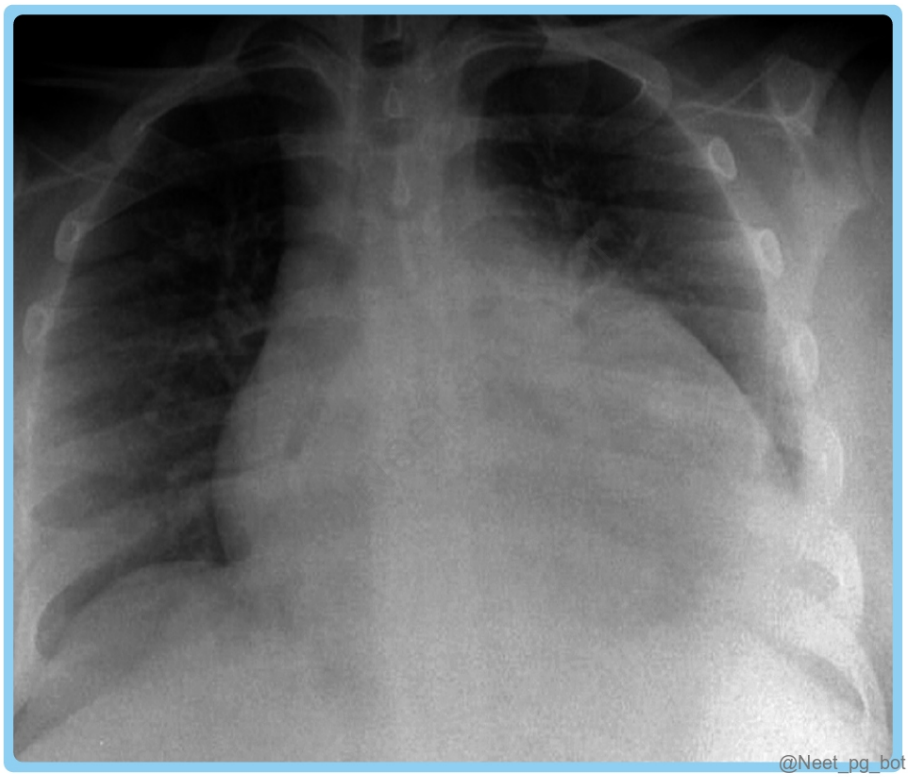

See Answer in Part B → Q7

@Neet_pg_bot

Q8: All of the following are correct about restrictive cardiomyopathy except? (Q850616)

A. Echo shows dilated atria with normal size ventricles and increased LV and RV end diastolic pressures

B. Cardiac MRI shows starry sky appearance due to amyloidosis

C. Absent y descent and steep x descent

D. Endomyocardial biopsy is the gold standard for diagnosing cardiac amyloidosis.

See Answer in Part B → Q8

@Neet_pg_bot

Q9: A 60-year-old male presents with ascites, shortness of breath, and bilateral ankle edema. Kussmaul's sign is noted. An echocardiogram shows normal systolic function but diastolic dysfunction with a speckled pattern in the ventricular wall. The chest X-ray of the patient is given below. Which of the following statements is correct about the diagnosis of this patient? (Q850610)

A. Thinned out, small-size atria

B. Rapid y descent in JVP

C. Atrial fibrillation is rare in these patients.

D. Endomyocardial Fibroelastosis is the leading cause



See Answer in Part B → Q9

@Neet_pg_bot

Q10: A 45-year-old man presents with worsening fatigue, shortness of breath, and ankle swelling. His medical history includes joint pain, elevated liver enzymes, hyperpigmentation, and diabetes. He has recently been diagnosed with a metabolic

disorder. An echocardiogram reveals elevated filling pressures and bilateral atrial enlargement. Which of the following best explains the underlying pathophysiology of this patient's condition? (Q850607)

A. Increased contractility due to myocardial hypertrophy

B. Impaired diastolic filling due to stiffened ventricular walls

C. Dilated ventricular chambers leading to heart failure

D. Obstruction of blood flow through the left ventricle

See Answer in Part B → Q10

@Neet_pg_bot

Q11: A 30-year-old female marathon runner collapses and is found unresponsive during a race. Despite attempts at resuscitation, she is pronounced dead in the ER. Her family reports that she had previously experienced episodes of dizziness and palpitations during training. You re-evaluate her ECG done at time of admission which shows epsilon waves. Which of the following conditions is most likely to contribute to sudden cardiac death in this young athlete? (Q850603)

A. Arrhythmogenic RV dysplasia

B. Commotio cordis

C. HCM

D. Atherosclerotic coronary artery disease

See Answer in Part B → Q11

@Neet_pg_bot

Q12: Which of the following medications is not contraindicated in patients with hypertrophic cardiomyopathy? (Q850601)

A. Amlodipine

B. Verapamil

C. Furosemide

D. Digoxin

See Answer in Part B → Q12

@Neet_pg_bot

Q13: A 45-year-old male presents with sharp chest pain worsened by lying down and relieved by sitting up. He had a recent viral illness. A friction rub is heard on cardiac auscultation, and the ECG shows the following. What is the most likely diagnosis? (Q850515)

A. Myocardial infarction

B. Pulmonary embolism

C. Acute pericarditis

D. Aortic dissection

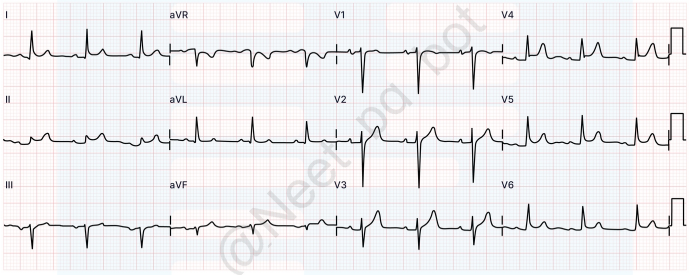

@Neet_pg_bot

See Answer in Part B → Q13

@Neet_pg_bot

Q14: A 30-year-old male presents with exertional chest pain and occasional fainting spells. His family history includes a relative who experienced sudden cardiac death. An echocardiogram reveals asymmetric septal hypertrophy. Which of the following is not a characteristic investigatory finding in this condition? (Q850592)

A. Brockenbrough-Braunwald-Morrow sign

B. Deep, narrow Q waves in the lateral leads

C. Left ventricle free wall thickness >10 mm

D. Increased precordial voltages

See Answer in Part B → Q14

@Neet_pg_bot

Q15: A 15-year-old male presents to the ED after experiencing syncope while playing basketball. He has a palpable double impulse at the apex, and an ECG shows signs of left ventricular hypertrophy. An echocardiogram reveals asymmetric septal thickening with left ventricular outflow tract obstruction. Which of the following examination findings would not be expected in this patient? (Q850589)

A. Palpable double impulse at the apex

B. Late-peaking ejection systolic murmur best heard at the left sternal border

C. Pulsus bisferiens on peripheral pulse examination

D. Prominent y descent in jugular venous pressure (JVP)

See Answer in Part B → Q15

@Neet_pg_bot

Q16: A 30-year-old athlete presents with recurrent syncope and exertional chest pain. Exam shows a hyperdynamic apex beat and a mid-systolic murmur at the left lower sternal border. Echocardiography reveals asymmetric septal hypertrophy and systolic anterior motion of the mitral valve. What is the most likely mechanism of his symptoms? (Q850584)

A. Diastolic heart failure due to a dilated left ventricle

B. Mitral valve prolapse

C. Left ventricular outflow tract obstruction

D. Aortic stenosis

See Answer in Part B → Q16

@Neet_pg_bot

Q17: A 60-year-old male presents with signs of peripheral oedema and ascites. A chest X-ray reveals the following, and echocardiography confirms a thickened pericardium. Which of the following is not correct regarding his likely condition? (Q850580)

A. Diastolic collapse of the ventricles

B. JVP shows a prominent “y” descent

C. Commonly caused by tuberculosis in endemic regions

D. CT scan can assist in visualizing pericardial calcification

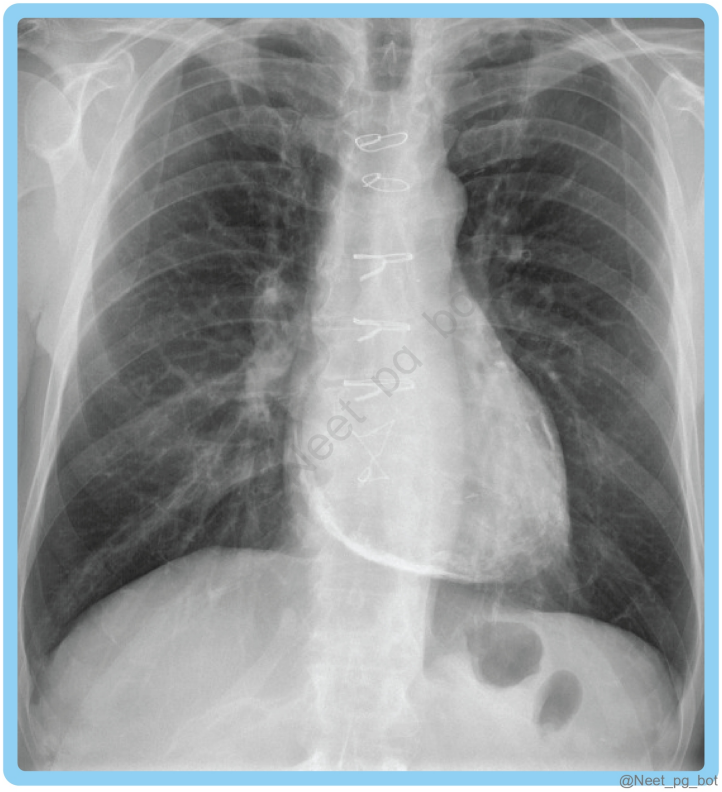

See Answer in Part B → Q17

@Neet_pg_bot

Q18: A 45-year-old male presents with fatigue, abdominal swelling, and peripheral oedema. On examination, he has elevated jugular venous pressure, hepatomegaly, and a loud diastolic sound. There is also a rise in JVP during inspiration. Which of the following is the most likely diagnosis? (Q850579)

A. Cardiac Tamponade

B. Constrictive pericarditis

C. Dilated cardiomyopathy

D. Restrictive cardiomyopathy

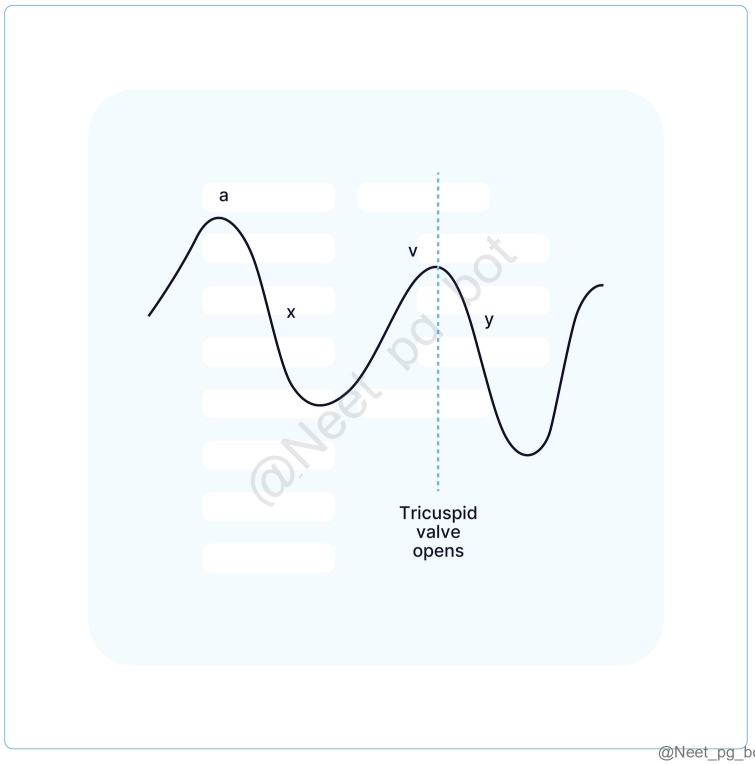

See Answer in Part B → Q18

@Neet_pg_bot

Q19: A 25-year-old male is brought to the emergency department after a high-speed car accident. His vitals are heart rate of 120 bpm, blood pressure of 80/50 mmHg, and he is pale with cold, clammy skin. He has a deep laceration on his lower thigh and is actively bleeding. Which of the following is the most appropriate initial management step? (Q850578)

A. Echocardiography guided pericardiocentesis

B. Emergency resuscitative thoracotomy

C. Start intravenous fluid resuscitation

D. Apply a tourniquet to the thigh

See Answer in Part B → Q19

@Neet_pg_bot

Q20: A 60 year old woman with stage 4 carcinoma breast presents to the ED with severe shortness of breath. On examination, she is hypotensive with a blood pressure of 80/60 mmHg, has distended neck veins with a jugular venous pressure of 12 cm H2O, and her heart sounds are muffled. An echocardiogram shows the following: What is the most appropriate immediate and definitive treatment for this patient? (Q850572)

A. Intravenous saline infusion

B. Pericardiocentesis

C. Diuretics

D. Surgical drainage (pericardiotomy)

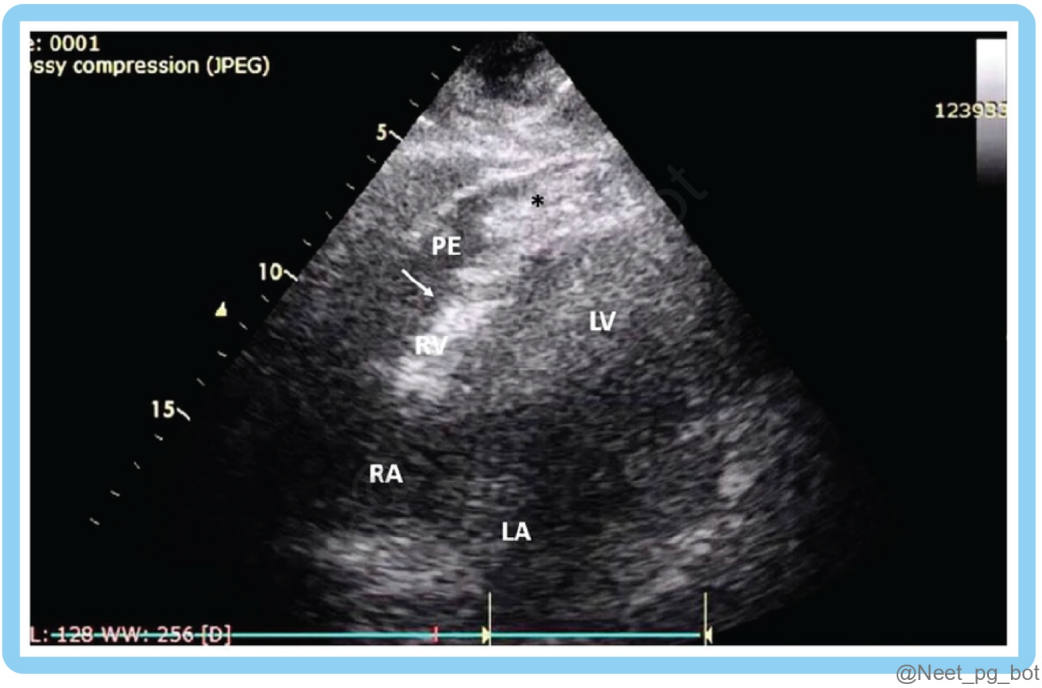

@Neet_pg_bot

See Answer in Part B → Q20

@Neet_pg_bot

Q21: Which of the following is a classic finding in cardiac tamponade? (Q850571)

A. Pulsus paradoxus

B. S3 heart sound

C. Pulsus alternans

D. High-pitched systolic murmur

See Answer in Part B → Q21

@Neet_pg_bot

Q22: A 65-year-old man presents to the emergency department with complaints of shortness of breath, fatigue, and mild chest discomfort. On examination, his blood pressure is low, and his heart sounds are faint on auscultation. The physician orders an echocardiogram, which shows the following Based on these findings, which of the following ECG pattern would you most likely expect to see? (Q850557)

A. High-voltage QRS complexes

B. ST-segment elevation in all leads

C. Prolonged PR interval

D. Electrical alternans

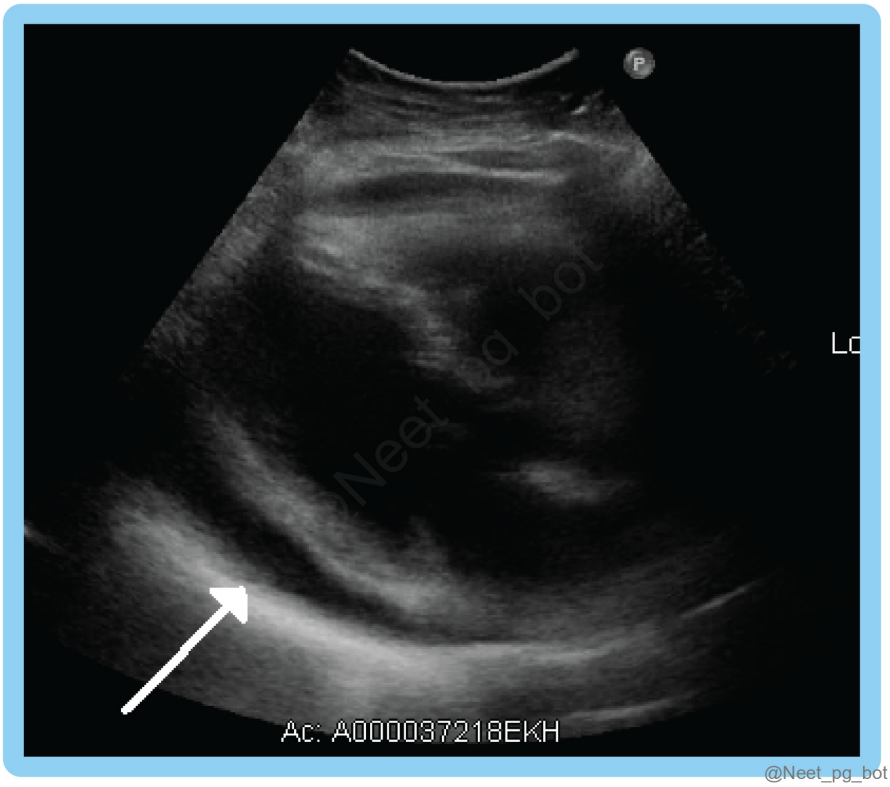

See Answer in Part B → Q22

@Neet_pg_bot

Q23: A 60 y/o male with acute pericarditis who has not responded to NSAIDs and colchicine is now experiencing frequent recurrences. He does not tolerate glucocorticoids well. What additional treatment can be considered? (Q850553)

A. Increase the dose of NSAIDs

B. Start azathioprine

C. Begin a higher dose of colchicine

D. Stop all medications and monitor

See Answer in Part B → Q23

@Neet_pg_bot

• [01_Cardiology] 009 Previous Year Questions

« Back to Folder Directory

[01_Cardiology] 009 Previous Year Questions — Quick Jump

Q1 (p. 121)	*Q2 (p. 122)*	*Q3 (p. 122)*	*Q4 (p. 122)*	*Q5 (p. 123)*	*Q6 (p. 123)*
Q7 (p. 124)	*Q8 (p. 124)*	*Q9 (p. 124)*	*Q10 (p. 125)*	*Q11 (p. 125)*	*Q12 (p. 126)*
Q13 (p. 126)	*Q14 (p. 126)*	*Q15 (p. 127)*	*Q16 (p. 127)*	*Q17 (p. 128)*	*Q18 (p. 129)*
Q19 (p. 130)	*Q20 (p. 130)*	*Q21 (p. 130)*	*Q22 (p. 131)*	*Q23 (p. 131)*	*Q24 (p. 132)*
Q25 (p. 132)	*Q26 (p. 132)*	*Q27 (p. 133)*	*Q28 (p. 133)*	*Q29 (p. 134)*	*Q30 (p. 134)*
Q31 (p. 135)	*Q32 (p. 135)*	*Q33 (p. 136)*	*Q34 (p. 136)*	*Q35 (p. 137)*	*Q36 (p. 137)*
Q37 (p. 138)	*Q38 (p. 138)*	*Q39 (p. 139)*	*Q40 (p. 140)*	*Q41 (p. 140)*	*Q42 (p. 141)*
Q43 (p. 141)	*Q44 (p. 142)*	*Q45 (p. 142)*	*Q46 (p. 142)*	*Q47 (p. 143)*	*Q48 (p. 144)*
Q49 (p. 144)	*Q50 (p. 145)*	*Q51 (p. 146)*	*Q52 (p. 146)*	*Q53 (p. 147)*	*Q54 (p. 148)*
Q55 (p. 148)	*Q56 (p. 149)*	*Q57 (p. 150)*	*Q58 (p. 150)*	*Q59 (p. 150)*	*Q60 (p. 151)*
Q61 (p. 151)	*Q62 (p. 152)*	*Q63 (p. 152)*	*Q64 (p. 153)*	*Q65 (p. 153)*	*Q66 (p. 154)*
Q67 (p. 154)	*Q68 (p. 155)*	*Q69 (p. 155)*	*Q70 (p. 155)*	*Q71 (p. 156)*	*Q72 (p. 156)*
Q73 (p. 156)	*Q74 (p. 157)*	*Q75 (p. 157)*	*Q76 (p. 158)*	*Q77 (p. 158)*	*Q78 (p. 159)*
Q79 (p. 160)	*Q80 (p. 160)*	*Q81 (p. 161)*	*Q82 (p. 161)*	*Q83 (p. 162)*	*Q84 (p. 162)*
Q85 (p. 162)	*Q86 (p. 163)*	*Q87 (p. 163)*	*Q88 (p. 164)*	*Q89 (p. 164)*	*Q90 (p. 164)*
Q91 (p. 165)	*Q92 (p. 166)*	*Q93 (p. 166)*	*Q94 (p. 166)*	*Q95 (p. 167)*	*Q96 (p. 167)*
Q97 (p. 168)	*Q98 (p. 168)*	*Q99 (p. 168)*	*Q100 (p. 169)*	*Q101 (p. 169)*	*Q102 (p. 170)*
Q103 (p. 170)	*Q104 (p. 170)*	*Q105 (p. 171)*	*Q106 (p. 171)*	*Q107 (p. 172)*	*Q108 (p. 172)*
Q109 (p. 172)	*Q110 (p. 173)*	*Q111 (p. 174)*	*Q112 (p. 174)*	*Q113 (p. 175)*	*Q114 (p. 176)*
Q115 (p. 176)	*Q116 (p. 177)*	*Q117 (p. 178)*	*Q118 (p. 179)*	*Q119 (p. 179)*	*Q120 (p. 180)*
Q121 (p. 181)	*Q122 (p. 181)*	*Q123 (p. 182)*	*Q124 (p. 183)*	*Q125 (p. 183)*	*Q126 (p. 183)*
Q127 (p. 184)	*Q128 (p. 184)*	*Q129 (p. 185)*	*Q130 (p. 185)*	*Q131 (p. 186)*	*Q132 (p. 187)*
Q133 (p. 187)	*Q134 (p. 188)*	*Q135 (p. 188)*	*Q136 (p. 189)*	*Q137 (p. 189)*	*Q138 (p. 190)*
Q139 (p. 190)	*Q140 (p. 191)*	*Q141 (p. 191)*	*Q142 (p. 191)*	*Q143 (p. 192)*	*Q144 (p. 192)*
Q145 (p. 192)	*Q146 (p. 193)*	*Q147 (p. 194)*	*Q148 (p. 194)*		

Q1: An alcoholic patient presents with palpitations, dizziness, and syncopal attacks. On examination, irregularly irregular pulse is seen. What will be seen on JVP? (Q866781)

A. Absent a wave

B. Large a wave

C. Canon a wave

D. Steep y descent

See Answer in Part B → Q1

@Neet_pg_bot

Q2: A 25-year-old female with a previous history of rheumatic fever. Examination shows a loud S1 and mid-diastolic murmur is having which of the following valvular heart disease? (Q866784)

A. TS

B. MR

C. MS

D. AR

See Answer in Part B → Q2

@Neet_pg_bot

Q3: A female patient complains of chest pain while waking up in the morning. Pain is more in winter months. Which of the following best describes this patient? (Q866827)

A. Fixed plaque obstruction

B. Ach-induced coronary vasoconstriction

C. Subendocardial ischemia due to increased demand of myocardium

D. Increased sympathomimetic drive in morning hours

See Answer in Part B → Q3

@Neet_pg_bot

Q4: Which type of pulse is based on the Frank-Starling law? (Q865309)

A. Pulsus bisferiens

B. Pulsus paradoxus

C. Pulsus alternans

D. Pulsus parvus

See Answer in Part B → Q4

@Neet_pg_bot

Q5: Mitral stenosis murmur corresponds to which wave of ECG? (Q865310)

A. QRS complex

B. T wave

C. P wave

D. ST segment

See Answer in Part B → Q5

@Neet_pg_bot

Q6: A 62-year-old male presents with sudden onset of shortness of breath and B/L pedal edema. He is compliant with his antihypertensive medications, and blood pressure is well controlled. ECG reveals an ejection fraction of 60%, concentric left ventricular hypertrophy, left atrial enlargement, and grade 2 diastolic dysfunction. Which of the following is the most appropriate next step to improve his condition? (Q865331)

A. Perform coronary angiography to rule out ischemic cardiomyopathy

B. Initiate loop diuretics and SGLT2 inhibitors for management of HFpEF

C. Start digoxin to enhance myocardial contractility

D. Initiate ivabradine to reduce heart rate and improve diastolic filling

See Answer in Part B → Q6

@Neet_pg_bot

Q7: Which of the following is not a symptom of cardiac failure? (Q865338)

A. Right hypochondriac pain

B. Non-pulsatile elevation of JVP

C. Orthopnea

D. Paroxysmal nocturnal dyspnea

See Answer in Part B → Q7

@Neet_pg_bot

Q8: A 45-year-old male presents to a PHC for a routine check-up. His blood pressure readings on two separate occasions are 148/90 mmHg and 152/96 mmHg. He is asymptomatic and has no known comorbidities. What is the most appropriate next step in management according to current hypertension guidelines? (Q865381)

A. Initiate treatment only if BP exceeds 160/100 mmHg

B. Start Amlodipine 5 mg once daily and advise follow-up in 1 month

C. Refer to a higher center for further evaluation

D. Start the patient on IV anti-hypertensive drugs

See Answer in Part B → Q8

@Neet_pg_bot

Q9: A 30 year old man with 6 month past history of PND and SOB. On examination, JVP is elevated with irregularly irregular pulse and tender hepatomegaly and MDM. past medical history of ARF. Which of the following is not seen in this patient? (Q866488)

A. Presystolic accentuation of mid-diastolic murmur is hallmark feature

B. Patient has increased risk of embolic stroke

C. Absent a wave in JVP

D. Right heart failure

See Answer in Part B → Q9

@Neet_pg_bot

Q10: A patient presents with palpitations and an irregularly irregular pulse. He presents within 2 hours of symptom onset, and has no history of diabetes or other comorbidities. What is the most appropriate initial management? (Q866489)

A. TEE for starting anticoagulation

B. Cardioversion

C. Control ventricular rate with verapamil

D. Wait and watch

See Answer in Part B → Q10

@Neet_pg_bot

Q11: A patient presents with frothy sputum, dyspnea, and paroxysmal nocturnal dyspnea (PND) and subsequently dies. Autopsy lung histopathology shows hemosiderin-laden macrophages. Which of the following is least likely to occur in this patient? (Q866493)

A. Volume overload

B. RV failure

C. Pulmonary vein obstruction

D. Protein losing enteropathy

See Answer in Part B → Q11

@Neet_pg_bot

Q12: A female patient comes to the ER with palpitations and syncopal attacks following exercise. She has had similar episodes in the past. An ECG was performed as follows. What is the most probable diagnosis? {{caption_text}} (Q853362)

A. Uhl's disease

B. Arrhythmogenic Right Ventricular Dysplasia

C. Hypertrophic Cardiomyopathy

D. Brugada's syndrome

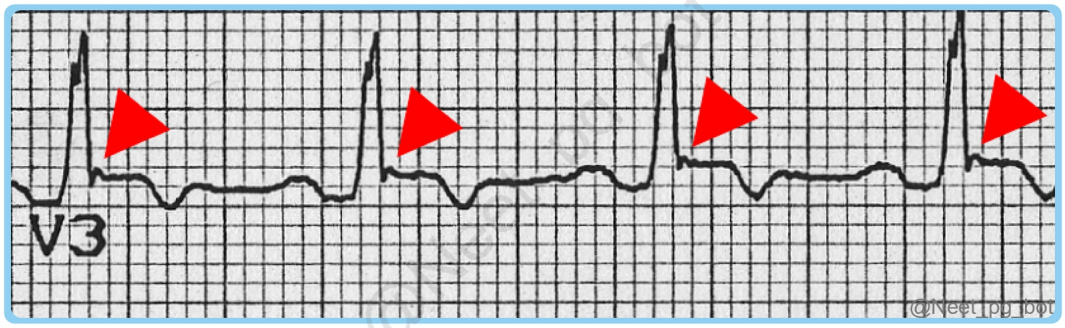

See Answer in Part B → Q12

@Neet_pg_bot

Q13: Which of the following is associated with a Graham-Steel murmur? (Q852672)

A. Ventricular septal defect (VSD)

B. Hypertrophic obstructive cardiomyopathy (HOCM)

C. Pulmonary regurgitation

D. Aortic regurgitation

See Answer in Part B → Q13

@Neet_pg_bot

Q14: A 65-year-old male with chronic stable angina presents with worsening chest pain during routine activities. His current medications include aspirin, clopidogrel, metoprolol, and atorvastatin, but his symptoms persist. ECG shows ST-segment depression in V5-V6, and coronary angiography reveals 80% stenosis of the left anterior descending (LAD) artery. What is the most appropriate intervention? (Q852747)

A. Increase the dose of beta-blockers

B. Add Ranolazine

C. Percutaneous coronary intervention (PCI) with drug-eluting stent (DES)

D. Refer for coronary artery bypass grafting (CABG)

See Answer in Part B → Q14

@Neet_pg_bot

Q15: A 72 y/o woman presents with severe chest pain and shortness of breath after a stressful argument. She is post-menopausal with no history of heart disease. O/E, she is slightly tachycardic with normal blood pressure. An echocardiogram shows left ventricular ballooning during systole, and cardiac enzymes are minimally elevated. What is the most likely diagnosis? (Q852748)

A. Hypertensive Heart Disease

B. Takotsubo Cardiomyopathy

C. Coronary Artery Disease

D. Pulmonary Embolism

See Answer in Part B → Q15

@Neet_pg_bot

Q16: A 68-year-old man with long-standing hypertension presents to the emergency department with severe chest pain, profuse sweating, and marked tachycardia. He appears acutely ill and hypotensive. His ECG finding is given below. What is the most

appropriate immediate management? (Q852749)

A. Amiodarone

B. Radiofrequency catheter ablation

C. Digoxin

D. Synchronized cardioversion

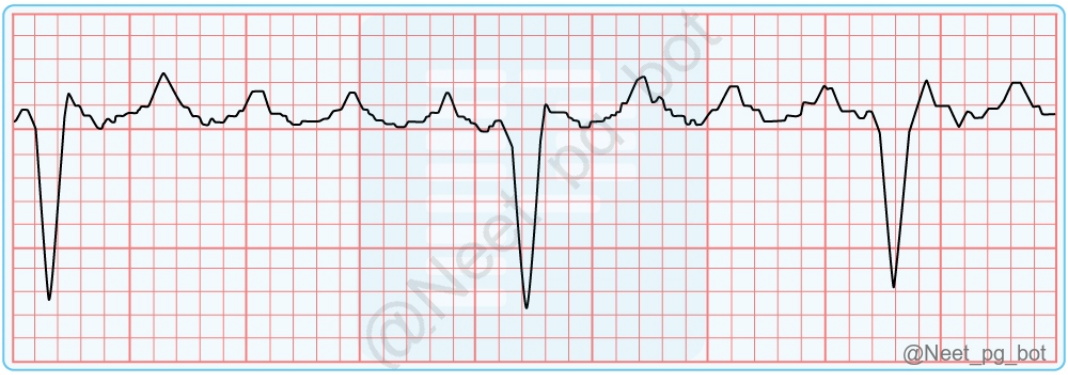

See Answer in Part B → Q16

@Neet_pg_bot

Q17: A 58-year-old woman comes to the clinic for a routine follow-up. She has a history of mild hypertension, which is well-controlled with medication. She reports no symptoms such as palpitations, dizziness, or chest pain. An ECG of the patient is given below. What is the most likely diagnosis based on the ECG findings? {{caption_text}} (Q852750)

A. Second-Degree AV Block

B. First-Degree AV Block

C. Third-Degree AV Block

D. Bundle Branch Block

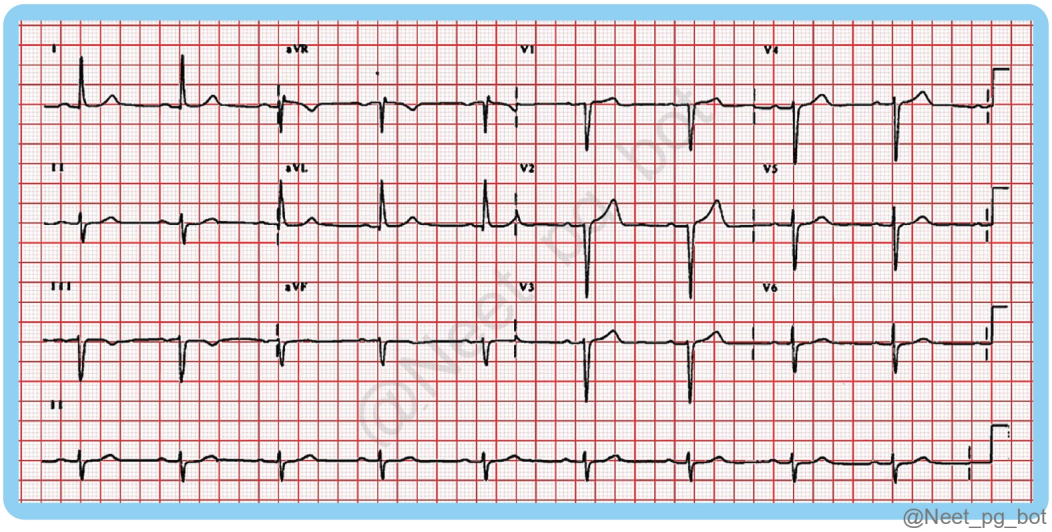

See Answer in Part B → Q17

@Neet_pg_bot

Q18: A patient of CKD has tachycardia. An ECG is taken and shown below. What's the most likely diagnosis? (Q844166)

A. Hyperkalemia

B. Hypokalemia

C. Hypercalcemia

D. Hypocalcemia

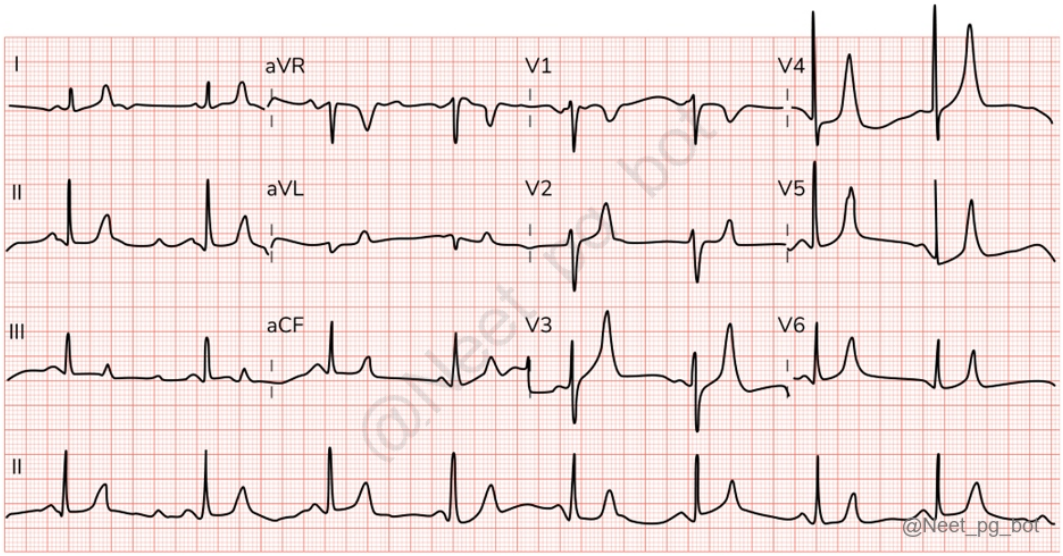

See Answer in Part B → Q18

@Neet_pg_bot

Q19: A 60-year-old lady presents with SOB and angina pectoris episodes. Work up shows aortic stenosis. Which of the following is the reason behind these chest pain episodes? (Q844172)

A. Increased pressure in aorta

B. Decreased pressure in aorta

C. Increased oxygen consumption in heart

D. Increase in volume overload of heart

See Answer in Part B → Q19

@Neet_pg_bot

Q20: Patient presents with features of right heart failure and exhibits a rapid Y descent on cardiac examination. What is the most likely diagnosis? (Q844245)

A. Constrictive pericarditis

B. Cardiac tamponade

C. Pulmonary hypertension

D. Right ventricular infarction

See Answer in Part B → Q20

@Neet_pg_bot

Q21: A pulmonary artery hypertension patient presented with an irregularly irregular pulse with loud P2 on auscultation. Which JVP finding will be seen in this patient? (Q844316)

A. Absent a waves

B. Cannon a waves

C. Rapid x descent

D. Rapid y descent

See Answer in Part B → Q21

@Neet_pg_bot

Q22: A young athlete underwent testing for a competition and was found to have hypertrophic cardiomyopathy. Which of the following will increase the murmur in this condition? (Q844250)

A. Handgrip

B. Valsalva maneuver

C. Squatting

D. Leaning forward

See Answer in Part B → Q22

@Neet_pg_bot

Q23: Which of the following drugs will cause Torsades de pointes if given with erythromycin? (Q844254)

A. Astemizole

B. Levofloxacin

C. Amoxicillin

D. Ceftriaxone

See Answer in Part B → Q23

@Neet_pg_bot

Q24: A patient presents with shortness of breath. Vitals are HR= 120/min, BP= 90/60. Echo shows diastolic collapse of ventricles. CT showed money bag appearance. Which is best for management of this patient? (Q844256)

A. Start diuretic with BP monitoring

B. Intra aortic balloon pump

C. Pericardiocentesis

D. Ventricular assist device

See Answer in Part B → Q24

@Neet_pg_bot

Q25: What is the next best step in management of a pulseless patient with the following rhythm? (Q844260)

A. Defibrillate and continue chest compression

B. Defibrillate and check pulse

C. Check pulse and give synchronized DC

D. Give synchronized DC and continue chest compression



See Answer in Part B → Q25

@Neet_pg_bot

Q26: A patient with a history of hypertension presents with atrial fibrillation, shortness of breath and Bilateral basal crackles on auscultation. Least important in management would be: (Q844277)

A. Start on anticoagulants like warf or Doac

B. Start beta blocker

C. Cardioversion to correct rhythm if hemodynamically remain unstable even after medical management

D. Iv Digoxin to control rate

See Answer in Part B → Q26

@Neet_pg_bot

Q27: The PR interval was measured at 0.21 seconds in a routine ECG of the patient. What is the correct Interpretation? (Q844281)

A. Second degree HB

B. First degree HB

C. Normal rhythm

D. Complete HB

See Answer in Part B → Q27

@Neet_pg_bot

Q28: A 70 year old male patient presents to the OPD with multiple, recurrent fainting episodes. An ECG was taken and it shows P waves at a rate of 75 bpm and qrs complexes at a rate of 35 bpm. What is the diagnosis? (Q860467)

A. Mobitz type II heart block

B. Stokes adams syndrome

C. First degree heart block

D. Wolf parkinson white syndrome

See Answer in Part B → Q28

@Neet_pg_bot

Q29: A 48-year-old man presents with progressive fatigue and breathlessness. On examination, he has distended neck veins, hepatomegaly, ascites, and peripheral edema. Chest X-ray is shown below. Which of the following is the most likely diagnosis? (Q860471)

A. Acute pericarditis

B. Bronchial asthma

C. Constrictive pericarditis

D. Atrial myxoma

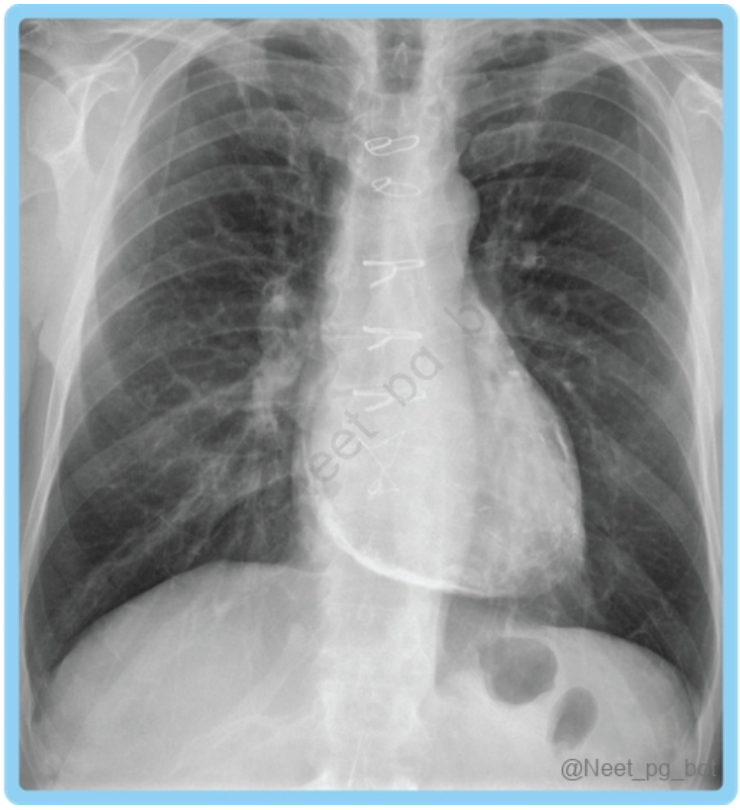

See Answer in Part B → Q29

@Neet_pg_bot

Q30: A patient has muffled heart sounds with low blood pressure. What is the correct JVP finding? (Q860477)

A. Steep x descent

B. Absent y descent

C. Steep y descent

D. Blunted x descent

See Answer in Part B → Q30

@Neet_pg_bot

Q31: A young male patient presents with sudden onset chest pain for one hour with ECG showing STE in lead 2,3 and aVF. Which is the best treatment for this case of inferior wall MI in a multispecialty hospital? (Q860480)

A. Alteplase

B. Streptokinase

C. Primary angioplasty

D. Dabigatran

See Answer in Part B → Q31

@Neet_pg_bot

Q32: "A 45-year-old female presents to the emergency department with breathlessness. She has a history of a viral infection and chest pain from 7 days ago. A chest X-ray reveals a "water bottle" heart. All of the following statements are true except:" (Q840110)

A. Pulsus paradoxus is observed

B. Loud S1

C. Emergency pericardiocentesis may be required

D. ECG showing RA and RV collapse requires immediate intervention

See Answer in Part B → Q32

@Neet_pg_bot

Q33: Which of the following conditions is indicated by the symptoms of chest pain and breathlessness in a 55-year-old male, as revealed by the provided ECG? (Q840116)

A. Unstable angina

B. Non-ST elevation myocardial infarction (NSTEMI)

C. Acute myocarditis

D. Posterior wall myocardial infarction (MI)

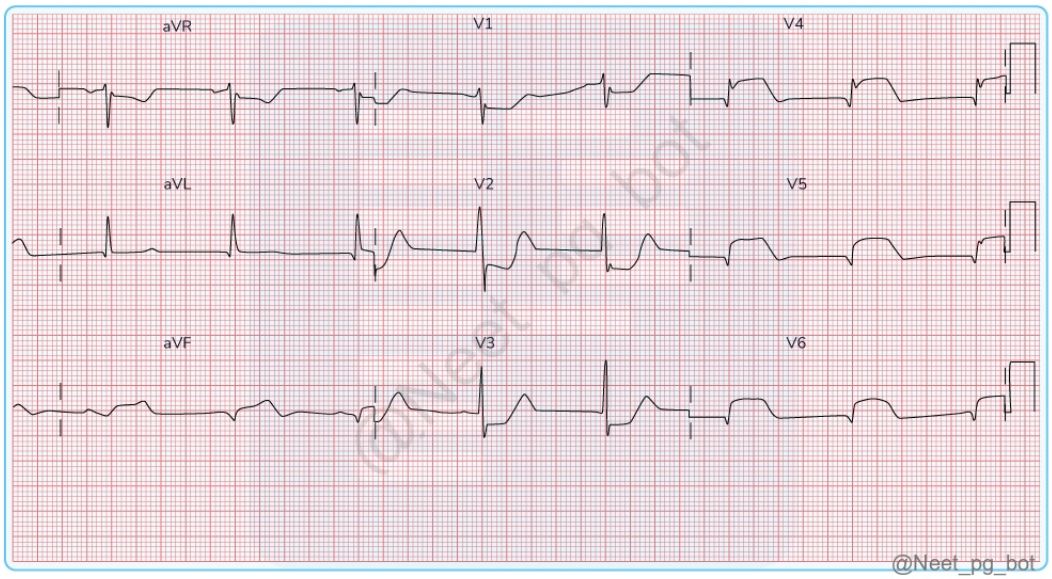

See Answer in Part B → Q33

@Neet_pg_bot

Q34: Which of the following statements is false regarding a 35-year-old male presenting to the emergency department with unconsciousness and the given ECG findings? (Q840119)

A. Atrial fibrillation can occur in structurally normal hearts

B. Direct current cardioversion should always be performed immediately

C. IV digoxin can be used when AF is associated with heart failure

D. Pulse deficit is a useful clinical clue in AF

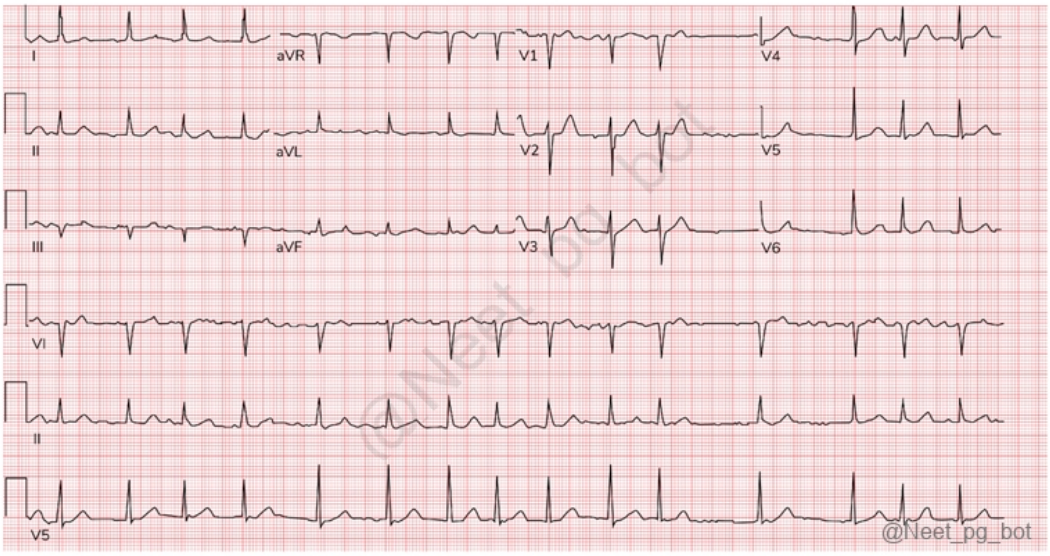

See Answer in Part B → Q34

@Neet_pg_bot

Q35: A 21-year-old man presents with episodes of chest pain. Physical examination reveals a bisferiens pulse and a heaving apex. What is the most likely diagnosis? (Q860218)

A. Dilated Cardiomyopathy (DCM)

B. Hypertrophic Cardiomyopathy (HCM)

C. Mitral Stenosis

D. Aortic Stenosis

See Answer in Part B → Q35

@Neet_pg_bot

Q36: Based on the given ECG, identify which wall of the myocardium was affected in this patient? (Q860223)

A. Inferior wall

B. Anterior wall

C. Posterior wall

D. Lateral wall

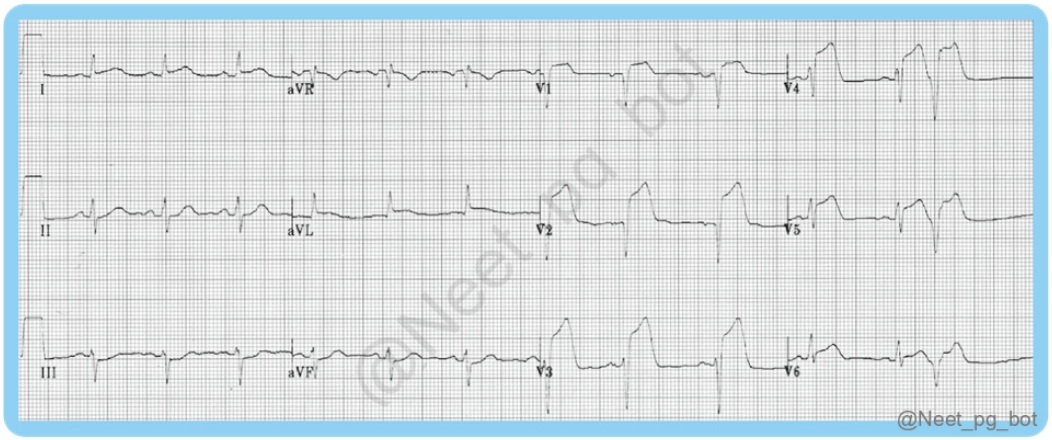

See Answer in Part B → Q36

@Neet_pg_bot

Q37: In which of the following scenarios is Rescue Percutaneous Coronary Intervention (PCI) indicated? (Q860242)

A. Failed thrombolysis

B. Chronic stable angina

C. Prinzmetal's angina

D. NSTEMI

See Answer in Part B → Q37

@Neet_pg_bot

Q38: A 30-year-old man with a past history of tuberculosis now complains of abdominal distension and pedal edema. On examination, his neck veins are

prominent. His chest x-ray is given below. Which of the following findings will be seen in this patient? (Q860246)

A. Pulsus bisferiens

B. Kussmaul sign

C. Non pulsatile elevated JVP

D. SBP rises from 80 mmHg to 60 mmHg

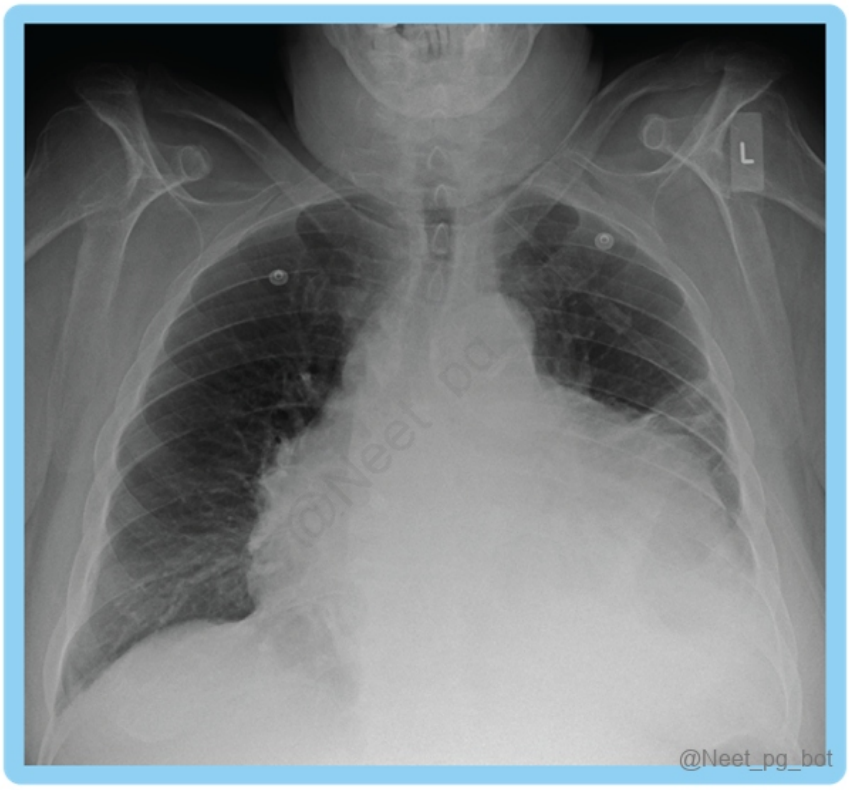

See Answer in Part B → Q38

@Neet_pg_bot

Q39: Which of the following is seen in subclinical acute myocarditis? (Q857252)

A. Palpitations

B. Elevated pro-BNP, Trop T

C. Low LVEF on 2D ECHO

D. Elevated creatinine levels

See Answer in Part B → Q39

@Neet_pg_bot

Q40: Which of the following describes an aortic regurgitation murmur? (Q857263)

A. Ventricular contraction

B. Ejection systolic murmur

C. Diastolic murmur

D. Systolic murmur

See Answer in Part B → Q40

@Neet_pg_bot

Q41: What does the ECG in the following image depict? (Q857267)

A. Pericarditis

B. Viral myocarditis

C. Torsades de pointes

D. Cardiac tamponade

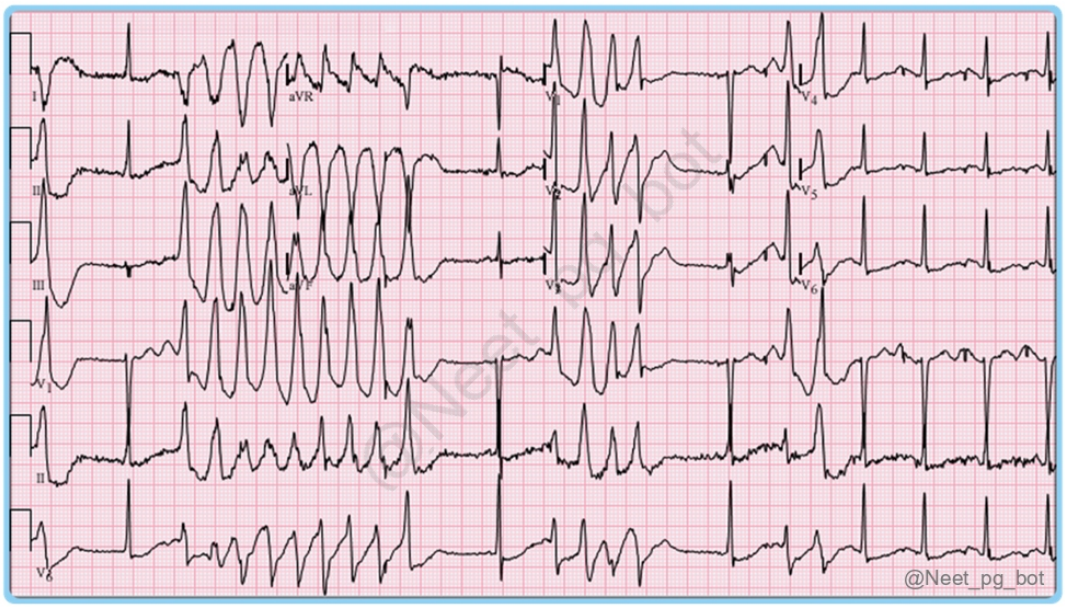

See Answer in Part B → Q41

@Neet_pg_bot

Q42: What is the correct order for cardiac auscultation, from superior to inferior? a. Pulmonary b. Tricuspid c. Mitral (Q857280)

A. a > b > c

B. b > a > c

C. c > a > b

D. c > b > a

See Answer in Part B → Q42

@Neet_pg_bot

Q43: Which of the following jvp findings seen in a patient with muffled heart sounds, hypotension and raised JVP? (Q820395)

A. Absent x descent

B. Absent y descent

C. C waves are enlarged

D. A waves are absent

See Answer in Part B → Q43

@Neet_pg_bot

Q44: Which of the following is correct regarding Wolf Parkinson's white syndrome? (Q820427)

A. Short PJ Interval

B. Broad QRS interval

C. Tall Tented T waves

D. Prolonged PR interval

See Answer in Part B → Q44

@Neet_pg_bot

Q45: The patient presented with pedal oedema, raised JVP till mandible and ascites. What is the most likely diagnosis? (Q820445)

A. Cardiac failure

B. Renal failure

C. Liver failure

D. Brain injury

See Answer in Part B → Q45

@Neet_pg_bot

Q46: A 20 year old male who is an IV drug user. on examination, a temperature of 38.5 C, and some spots can be noted over the fundus. CBC showed a leukocyte count of 20,000/cu mm. Blood has been sent for culture. Infective endocarditis is suspected.

How many minor duke's criteria are satisfied for the diagnosis? (Q830821)

A. 1

B. 2

C. 3

D. 4

See Answer in Part B → Q46

@Neet_pg_bot

Q47: A 10-year-old boy's father noticed agonal respiration at 5 AM while he was asleep. He was rushed to the ER where an ECG was performed as given. What could be the diagnosis? (Q854656)

A. Early repolarization syndrome

B. Brugada Syndrome

C. Hypertrophic cardiomyopathy

D. Atrial fibrillation

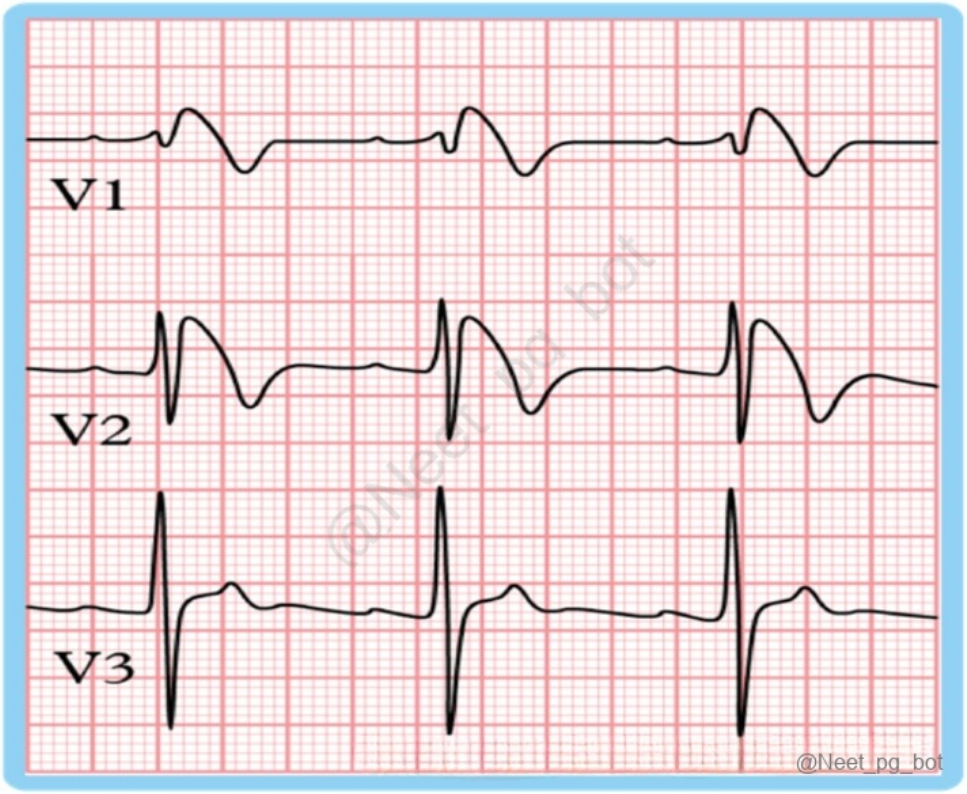

See Answer in Part B → Q47

@Neet_pg_bot

Q48: All of the following are the causes of high-output cardiac failure, except? (Q854694)

A. Cor pulmonale

B. Beri Beri

C. Anemia

D. Systemic AV shunt

See Answer in Part B → Q48

@Neet_pg_bot

Q49: What does the ECG depict in the following image? (Q854707)

A. First-degree heart block

B. Second-degree intra-nodal heart block

C. Complete heart block

D. AV dissociation



See Answer in Part B → Q49

@Neet_pg_bot

Q50: A 75-year-old woman with Type 2 diabetes mellitus and hypertension, developed features of heart failure and expired. The post-mortem cardiac biopsy slide is given below. What is the likely diagnosis? (Q854713)

A. Dilated Cardiomyopathy

B. Restrictive cardiomyopathy

C. Hypertrophic cardiomyopathy

D. Takotsubo cardiomyopathy

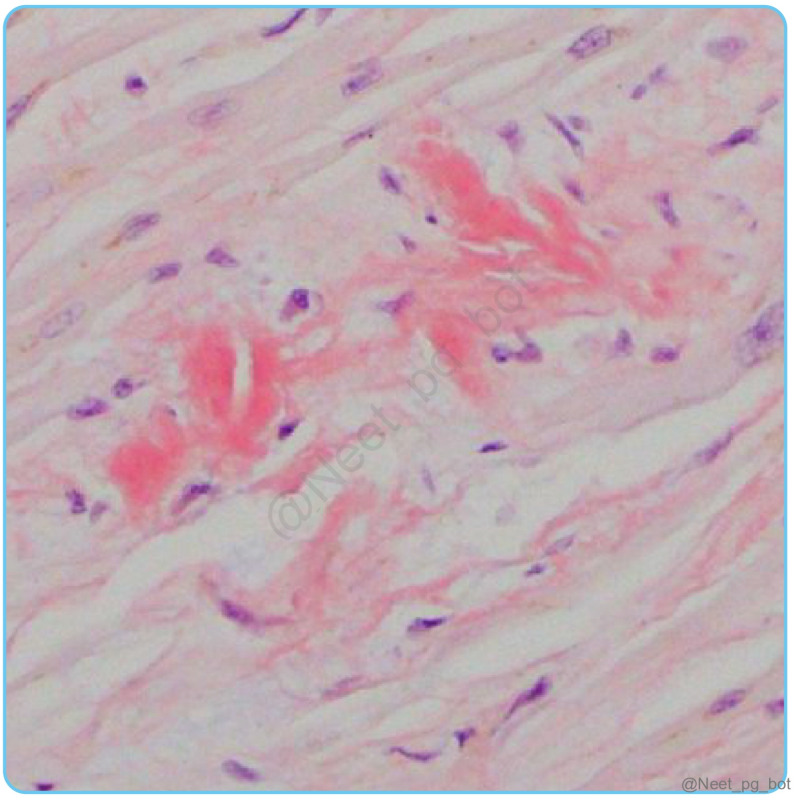

See Answer in Part B → Q50

@Neet_pg_bot

Q51: A 60-year-old diabetic male with central chest pain, shortness of breath and palpitations came to the emergency department. An ECG was taken, which showed NSTEMI. Which of the following is the right treatment? (Q854724)

A. Aspirin + Clopidogrel

B. Aspirin + Statin

C. Aspirin + Clopidogrel + LMWH

D. Aspirin + LMWH

See Answer in Part B → Q51

@Neet_pg_bot

Q52: Which of the following statements about the culture taken in a suspected case of infective endocarditis is correct? (Q854726)

A. Two samples from peripheral lines 30 minutes apart

B. Three samples from peripheral lines 1 hour apart

C. One sample only from the peripheral line

D. Two peripheral samples, two days apart

See Answer in Part B → Q52

@Neet_pg_bot

Q53: Identify the condition associated with the murmur depicted in the image below. (Q855412)

A. Mitral Regurgitation

B. Aortic Regurgitation

C. Aortic Stenosis

D. Mitral Stenosis



See Answer in Part B → Q53

@Neet_pg_bot

Q54: A 40-year-old female patient came with complaints of chest pain, palpitation, and shortness of breath. On examination, a mid-diastolic murmur was heard, and a prominent 'a' wave was found on JVP. What is the most likely diagnosis? (Q855479)

A. Mitral stenosis

B. Tricuspid stenosis

C. Mitral regurgitation

D. Tricuspid regurgitation

See Answer in Part B → Q54

@Neet_pg_bot

Q55: A patient who is a known case of hypertension on multiple antihypertensive medications came to the OPD. His ECG finding is given below. Which of the following drugs is responsible for the ECG finding? (Q855489)

A. Prazosin

B. Metoprolol

C. Hydrochlorothiazide

D. Spironolactone



See Answer in Part B → Q55

@Neet_pg_bot

Q56: A patient presents with dyspnea and distended neck veins that increase on inspiration. There is no murmur. What is the diagnosis? (Q858032)

A. Constrictive pericarditis

B. Aortic regurgitation

C. Tricuspid stenosis

D. Pulmonary arterial hypertension

See Answer in Part B → Q56

@Neet_pg_bot

Q57: Which of the following drugs reduce mortality in a patient with heart failure? (Q858361)

A. Metoprolol

B. Furosemide

C. Prazosin

D. Torsemide

See Answer in Part B → Q57

@Neet_pg_bot

Q58: A 65-year-old man with known lung cancer presents with acute shortness of breath and chest discomfort. On examination, percussion over the left infrascapular area is dull, and breath sounds are markedly decreased. He has hypotension, tachycardia, elevated JVP, and muffled heart sounds. What is the most likely diagnosis? (Q793802)

A. Cardiac tamponade

B. Chronic constrictive pericarditis

C. Pulmonary embolism

D. Left-sided pleural effusion

See Answer in Part B → Q58

@Neet_pg_bot

Q59: Identify the conduction abnormality from the ECG given below? (Q855705)

A. First degree heart block

B. Ventricular tachycardia

C. Third degree heart block

D. Second degree heart block

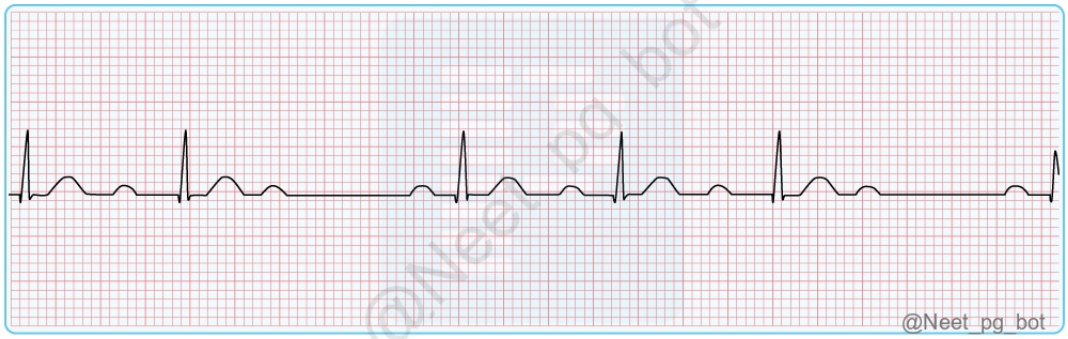

See Answer in Part B → Q59

@Neet_pg_bot

Q60: A 45-year-old patient with suspected mitral stenosis is found to have a soft or absent first heart sound on auscultation. Which of the following conditions is least likely to cause a soft or absent S1? (Q855710)

A. Severe mitral valve calcification

B. Aortic regurgitation

C. First degree heart block

D. Advanced mitral stenosis

See Answer in Part B → Q60

@Neet_pg_bot

Q61: Which of the following is the initial treatment of choice for managing the condition in a female patient who comes to the hospital with palpitations, having stable vital signs and an ECG showing the following? (Q855330)

A. Amiodarone

B. Adenosine

C. DC cardioversion

D. Primary PCI

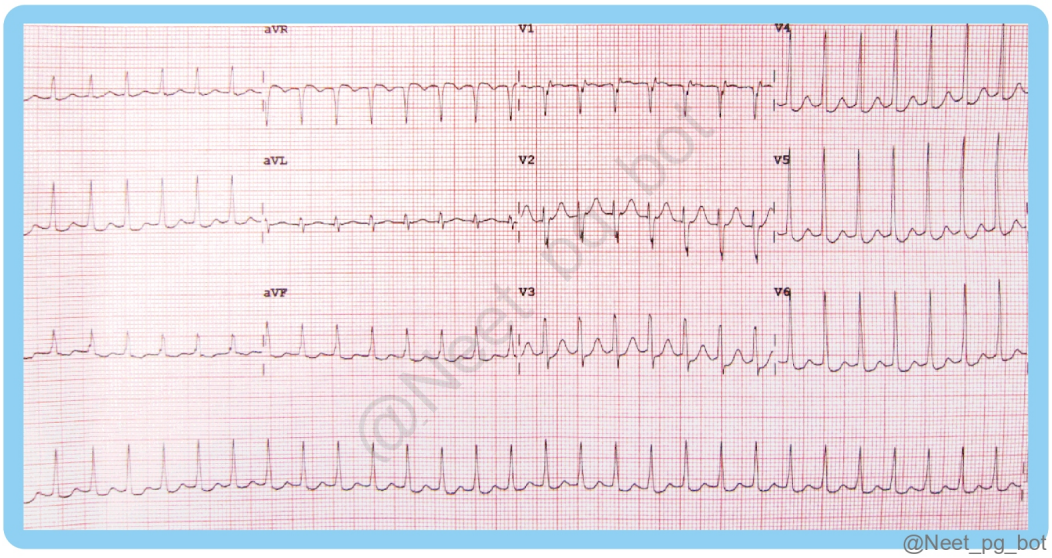

See Answer in Part B → Q61

@Neet_pg_bot

Q62: A patient with heart disease has breathlessness when going to the bathroom. What grade does he belong to? (Q855360)

A. NYHA 3

B. NYHA 4

C. mMRC 4

D. mMRC 5

See Answer in Part B → Q62

@Neet_pg_bot

Q63: Based on the ECG given below, which of the following is not used in the management of the condition? (Q855364)

A. Verapamil

B. Metoprolol

C. Amiodarone

D. Non-synchronised DC shock

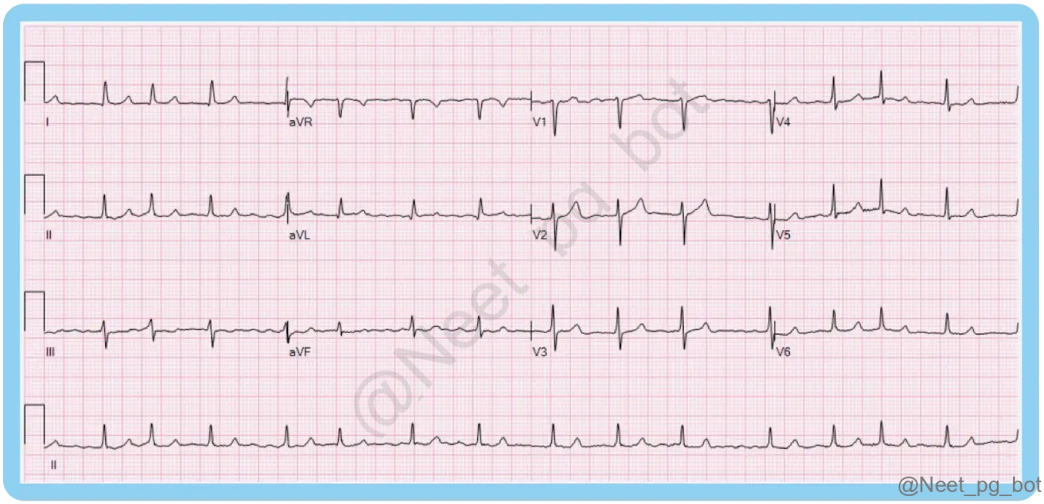

See Answer in Part B → Q63

@Neet_pg_bot

Q64: Which of the following foods is not included in the DASH diet? (Q857042)

A. Rich in potassium

B. Rich in calcium

C. Rich in sodium

D. Rich in magnesium

See Answer in Part B → Q64

@Neet_pg_bot

Q65: A patient has presented with features of cardiac tamponade. Which of the following is correct regarding this condition? (Q857043)

A. Pulsus Paradoxus is always present

B. Kussmaul sign is always present

C. Tall A wave is present

D. Jugular veins column is visibly distended without pulsations

See Answer in Part B → Q65

@Neet_pg_bot

Q66: What is the clinical diagnosis for a young male who has no symptoms but is found to have a wide fixed split S2 during auscultation? (Q857046)

A. ASD

B. VSD

C. TOF

D. BAV

See Answer in Part B → Q66

@Neet_pg_bot

Q67: Which of the following is contraindicated in a patient with Wolff–Parkinson–White (WPW) syndrome presenting with atrial fibrillation? (Q857052)

A. Treadmill test

B. Electrophysiological studies

C. Oral beta blocker

D. Procainamide

See Answer in Part B → Q67

@Neet_pg_bot

Q68: Which of the following is not correct about Defibrillation? (Q857055)

A. Only be used by a trained person

B. Decrease in success rate with delay in initiation

C. Improve prognosis

D. 1 minute gap between 2 shocks

See Answer in Part B → Q68

@Neet_pg_bot

Q69: Modified duke criteria are used for diagnosis of? (Q857066)

A. Infective endarteritis

B. Infectious mononucleosis

C. Inflammatory myopathy

D. Infective endocarditis

See Answer in Part B → Q69

@Neet_pg_bot

Q70: Which of the following indicators shall be seen with use of a small-sized BP cuff? (Q857069)

A. False elevation of BP

B. Falsely low value of BP

C. Cancels the effects of calcified arteries

D. Increases trans arm impedance

See Answer in Part B → Q70

@Neet_pg_bot

Q71: Elderly male patient has presented with recurrent falls. Which of the following medicines is responsible? (Q857070)

A. Prazocin

B. Metformin

C. Acarbose

D. Thiazide

See Answer in Part B → Q71

@Neet_pg_bot

Q72: What is the waist to hip ratio that is associated with an increased risk of heart disease? (Q857072)

A. > 0.80 in males

B. > 0.80 in females

C. > 0.85 in males

D. > 0.85 in females

See Answer in Part B → Q72

@Neet_pg_bot

Q73: Best management of a hemodynamically stable patient with ECG showing Broad QRS complex with antidromic tachycardia is? (Q857074)

A. Oral verapamil

B. Oral Beta-blocker

C. Cardioversion

D. Intravenous Procainamide

See Answer in Part B → Q73

@Neet_pg_bot

Q74: What is the diagnosis for a 23-year-old female who has been experiencing fever for the past week and displays the following rhythm on the monitor? {{caption_text}} (Q857095)

A. Atrial fibrillation

B. Atrial flutter

C. Supra ventricular tachyarrhythmia

D. Ventricular tachyarrhythmia



See Answer in Part B → Q74

@Neet_pg_bot

Q75: An intern observed that a patient in the ward was unresponsive, and an ECG which was performed urgently showed a rhythm as depicted below. DC shock was delivered but the arrhythmia persisted and the patient is still unresponsive. What is the next best step in the management of this patient? (Q857615)

A. Synchronized cardioversion

B. Start CPR

C. Deliver another DC shock

D. 1 mg epinephrine



See Answer in Part B → Q75

@Neet_pg_bot

Q76: Pulsus paradoxus is seen in: (Q857626)

A. Coronary artery disease

B. Severe Asthma or Chronic Obstructive Pulmonary Disease

C. Atrial Fibrillation

D. Right ventricular myocardial infarction

See Answer in Part B → Q76

@Neet_pg_bot

Q77: A 64-year-old man presents with complaints of palpitations and syncope. He has a history of inferior-wall myocardial infarction a year ago. Holter study was done and his 24 hour ECG strip obtained is given below. What is the long-term treatment for this condition? (Q857641)

A. Amiodarone

B. Atropine only

C. Permanent pacemaker

D. Atropine and isoproterenol

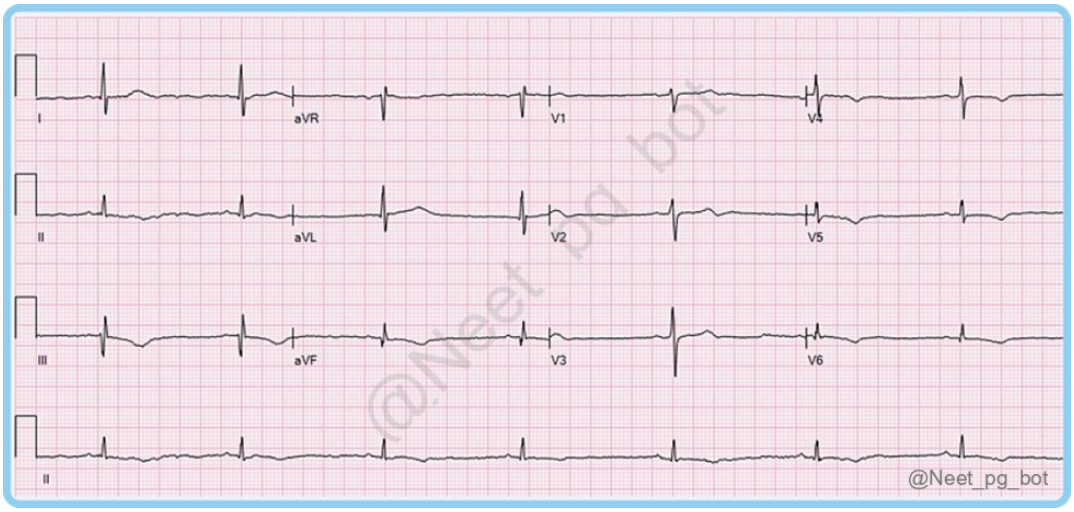

See Answer in Part B → Q77

@Neet_pg_bot

Q78: A 5 year old child has flexible fingers and can even touch the back of his hand with his wrist extended. The child also demonstrates the sign shown in the image below. On auscultation, a click is heard after S1, followed by a late systolic murmur. What is the probable diagnosis? (Q857653)

A. Ehlers-Danlos syndrome

B. Marfan’s syndrome

C. Loeys-Dietz syndrome

D. Osteogenesis imperfecta

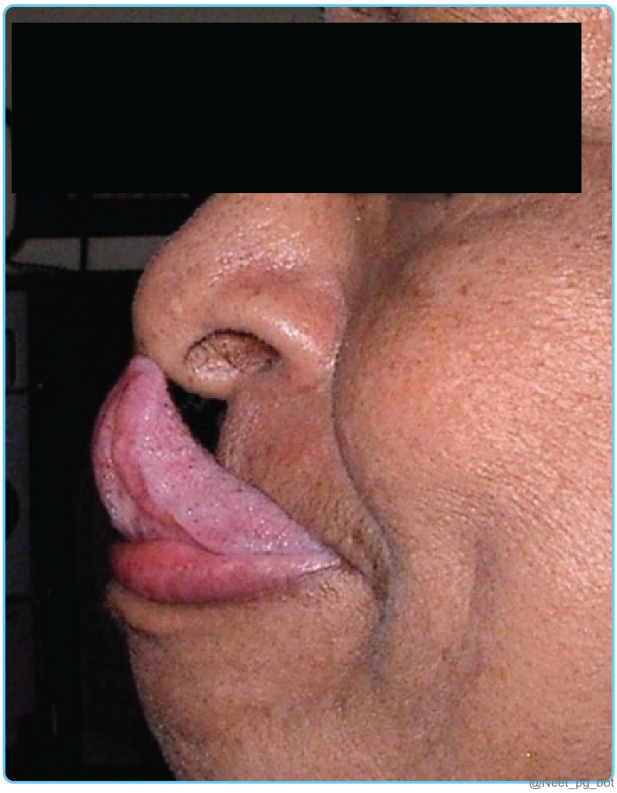

See Answer in Part B → Q78

@Neet_pg_bot

Q79: Which of the following is the most appropriate position for placement of single lead pacemaker ? (Q857654)

A. Right ventricle

B. Left atrium

C. Left ventricle

D. Superior vena cava

See Answer in Part B → Q79

@Neet_pg_bot

Q80: What is the most probable diagnosis for a female patient, aged 65, who visits the outpatient department with symptoms of breathlessness and fatigue? During examination, the patient's neck veins were engorged, and her jugular venous pulse displayed a swift X and Y descent. (Q857667)

A. Constrictive pericarditis

B. Cardiac tamponade

C. Dilated cardiomyopathy

D. Restricted cardiomyopathy

See Answer in Part B → Q80

@Neet_pg_bot

Q81: A 35 year old female patient with fever and malar rashes was found to have vegetations on either side of the heart valves. What can be the diagnosis of the patient? (Q857674)

A. Infective endocarditis

B. Libman sacks endocarditis

C. Rheumatic Heart Disease

D. None of the above

See Answer in Part B → Q81

@Neet_pg_bot

Q82: PR segment in ECG indicates: (Q857686)

A. Atrial depolarization

B. Atrioventricular nodal conduction

C. Ventricular depolarization

D. Ventricular repolarization

See Answer in Part B → Q82

@Neet_pg_bot

Q83: Most sensitive and specific marker for MI is? (Q857691)

A. Troponin

B. Cytokeratin

C. Myoglobin

D. CPK-MM

See Answer in Part B → Q83

@Neet_pg_bot

Q84: Which of the following is given lifelong for patient receiving prosthetic mitral valve replacement? (Q857693)

A. Aspirin

B. Clopidogrel

C. Atorvastatin

D. Warfarin

See Answer in Part B → Q84

@Neet_pg_bot

Q85: A 68-year-old male presents with palpitations and shortness of breath. His medical history includes hypertension, diabetes, and coronary artery disease. On examination, irregularly irregular heartbeats are noted. An electrocardiogram (ECG) reveals irregularly irregular rhythm , no P waves, and absence of an isoelectric baseline. His blood pressure is 132/84 mmHg, heart rate 130 bpm, and oxygen saturation 94% on room air. Given the patient's clinical presentation and history,

which of the following treatment options should be considered as a first-line approach for managing this case? (Q855706)

A. Amiodarone

B. Metoprolol

C. Electrical cardioversion

D. Direct oral anticoagulant (DOAC) therapy

See Answer in Part B → Q85

@Neet_pg_bot

Q86: All are true regarding heart failure except: (Q855713)

A. Regardless of ejection fraction and the type of heart failure, the 5-year mortality rate is around 50%

B. Non-cardiovascular death is more in HFrEF-30-40% as compared to HFpEF-15%

C. Angiotensin converting enzyme (ACE) inhibitors cause cough in 15% and angioedema in 1%

D. Atrial fibrillation is common in elderly and is the cause of stroke in quarter of the stroke cases

See Answer in Part B → Q86

@Neet_pg_bot

Q87: In atrial fibrillation, choose the correct statements: Novel oral anticoagulants (NOACs) used in the treatment of moderate to severe MS Anticoagulants should be given in patients with ischemic stroke due to atrial fibrillation NOACs are contraindicated in prosthetic valves All patients with atrial fibrillation who are not candidates for cardiac surgery can be started on beta-blockers (Q855730)

A. 1,2,3 and 4 correct

B. 1,2 and 3 correct

C. 2 and 3 correct

D. 1 and 4 correct

See Answer in Part B → Q87

@Neet_pg_bot

Q88: A 60 year old male patient with critical mitral stenosis presented with atrial fibrillation. He has a history of multiple episodes of transient ischemic attacks. Which of the following are true regarding the prevention of stroke in this patient? Only aspirin is given Warfarin is given Direct oral anticoagulants are not indicated Mitral valvotomy should be recommended (Q855731)

A. 1 only

B. 2 and 3

C. 2,3 and 4

D. 1,2,3 and 4

See Answer in Part B → Q88

@Neet_pg_bot

Q89: For the diagnosis of resistant hypertension, the patient should have uncontrolled hypertension despite taking three antihypertensive drugs. This should include at least one: (Q856598)

A. Calcium channel blocker

B. Beta blocker

C. Alpha blocker

D. Diuretic

See Answer in Part B → Q89

@Neet_pg_bot

Q90: Identify the disease? (Q856617)

A. Tricuspid stenosis

B. Mitral stenosis

C. Dilated cardiomyopathy

D. Hypertrophic obstructive cardiomyopathy

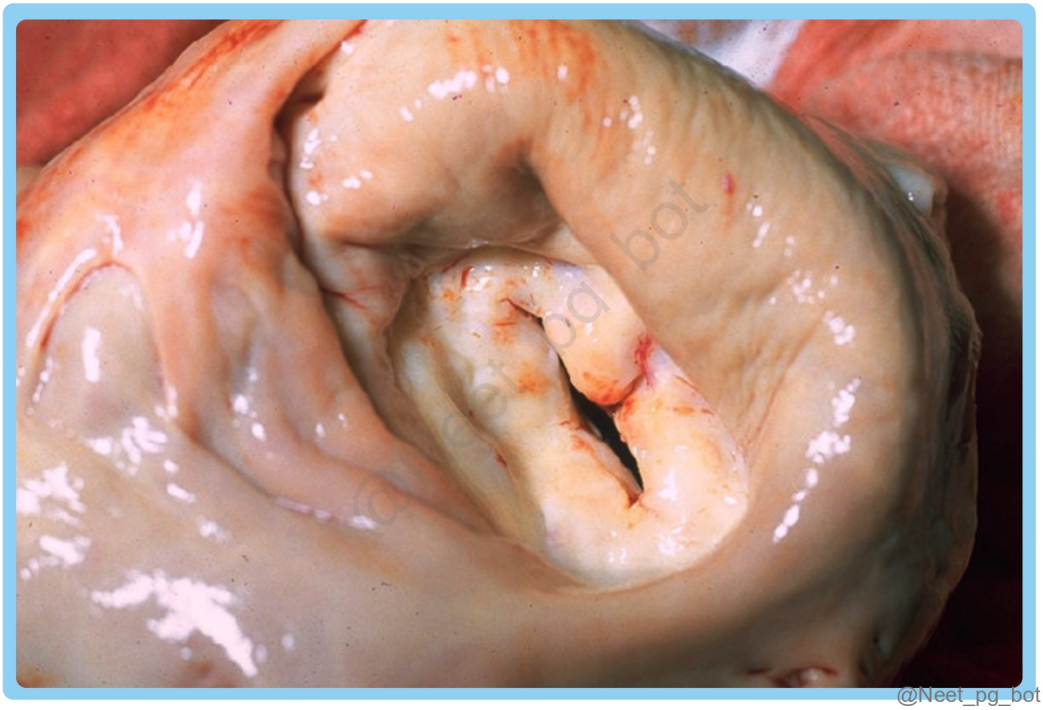

See Answer in Part B → Q90

@Neet_pg_bot

Q91: A patient who is a known case of atherosclerosis underwent a circumflex artery bypass. The stent is now placed successfully. He's already taking lisinopril, verapamil, and metoprolol. Which drug should be added? (Q856117)

A. PDE 3 inhibitor

B. Direct oral anticoagulant

C. P2Y12 receptor blocker

D. PDE 5 inhibitor

See Answer in Part B → Q91

@Neet_pg_bot

Q92: A male patient had feeble femoral pulses with an upper-limb blood pressure of 186/90 mmHg. Chest x-ray showed enlarged intercostal arteries. What is the likely diagnosis? (Q856118)

A. Coarctation of aorta

B. Atrial septal defect

C. Bicuspid aortic valve

D. Patent ductus arteriosus

See Answer in Part B → Q92

@Neet_pg_bot

Q93: A 45-year-old woman with a history of hypertension presented to the emergency room with loss of consciousness, chest pain, and diaphoresis. On examination, she was grossly unstable, and the bilateral pulses were unequal. ECG showed nonspecific ST-T changes. What is the next best investigation? (Q856130)

A. MRI

B. Transoesophageal echocardiography

C. Cardiac enzymes

D. X-ray

See Answer in Part B → Q93

@Neet_pg_bot

Q94: A 50-year-old man presents with a history of recurrent retrosternal chest pain, with each episode lasting for 3-5 min and subsiding with sublingual nitrate. ECG

shows left ventricular hypertrophy and flat T-wave. He has a known case of hypertension, diabetes mellitus, and hypercholesterolemia and is currently on aspirin, atenolol, metformin, and lovastatin. What is the next best step in management? (Q856171)

A. IV glyceryl trinitrate infusion

B. Injection enoxaparin

C. Add clopidogrel

D. Increase the dose of beta blocker

See Answer in Part B → Q94

@Neet_pg_bot

Q95: Evaluation of a patient revealed the presence of a mid-diastolic murmur. JVP showed prominent a-waves. What is the likely diagnosis? (Q856199)

A. Mitral stenosis

B. Tricuspid stenosis

C. Mitral regurgitation

D. Tricuspid regurgitation

See Answer in Part B → Q95

@Neet_pg_bot

Q96: A 20-year-old woman presents with breathlessness and chest pain. She is a known case of mitral stenosis. Her pulse is irregularly irregular. No thrombus is seen on echocardiography. What is the best agent to prevent future thrombotic events? (Q856202)

A. Dabigatran

B. Aspirin 150mg

C. Oral warfarin

D. Aspirin + Clopidogrel

See Answer in Part B → Q96

@Neet_pg_bot

Q97: Resistant hypertension is defined as? (Q856945)

A. BP >160/90 mmHg with one antihypertensive

B. BP >140/90 mmHg with one antihypertensive

C. BP >160/90 mmHg with three or more antihypertensive

D. BP >140/90 mmHg with three or more antihypertensive

See Answer in Part B → Q97

@Neet_pg_bot

Q98: Which among the following investigations is the most suitable for diagnosing myocardial infarction (MI) within a timeframe of 2-4 hours of onset of chest pain? (Q856953)

A. LDH

B. CKMB

C. Troponin-T

D. BNP

See Answer in Part B → Q98

@Neet_pg_bot

Q99: Which of the following treatment options is not suitable for managing a patient with non-ST-elevation myocardial infarction (NSTEMI)? (Q856335)

A. Aspirin

B. Clopidogrel

C. Streptokinase

D. Prasugrel

See Answer in Part B → Q99

@Neet_pg_bot

Q100: A 65 year old male patient presented to the emergency room with symptoms of palpitation, dizziness. On examination pulse is 180 beats per minute and his blood pressure is 70 mmHg systolic. The electrocardiogram (ECG) reveals a narrow QRS complex tachycardia with a regular heart rate. What should be the next course of action in managing this patient? (Q856342)

A. DC cardioversion

B. Adenosine

C. Valsalva Maneuver

D. Verapamil

See Answer in Part B → Q100

@Neet_pg_bot

Q101: What would be the most appropriate approach for a patient experiencing chest pain for the past 3 hours, where an ECG shows ST depression in anterior chest leads and T wave inversion? (Q856351)

A. Intra aortic balloon pump(IABP)

B. Thrombolysis with alteplase

C. Prophylaxis for arrhythmia

D. Aspirin with heparin

See Answer in Part B → Q101

@Neet_pg_bot

Q102: A 45-year-old female patient presents to the clinic with complaints of increasing fatigue and shortness of breath. Upon auscultation, the physician detects a pan systolic murmur that is best heard at the right side of the heart. The murmur radiates to the axilla and is louder during inspiration. The patient denies any history of fever, chest pain, or recent infections. What is the most probable diagnosis for this patient's condition based on the described findings? (Q856358)

A. Aortic stenosis

B. Mitral valve prolapse

C. Ventricular septal defect

D. Tricuspid regurgitation

See Answer in Part B → Q102

@Neet_pg_bot

Q103: Correct sequence after p wave: A - ‘a’ wave B - 1 st heart sound C - Rapid filling of ventricles D - ‘t’ wave (Q856377)

A. ABCD

B. ABDC

C. CABD

D. ACBD

See Answer in Part B → Q103

@Neet_pg_bot

Q104: Water hammer pulse is seen in which of the following conditions? (Q855002)

A. Aortic stenosis

B. Aortic regurgitation

C. Aortic stenosis and aortic regurgitation

D. Mitral regurgitation

See Answer in Part B → Q104

@Neet_pg_bot

Q105: A 70-year-old man with a known history of DM and HTN on regular medications presents with a history of progressively worsening dyspnoea on exertion. On examination, there's elevated JVP, positive hepatojugular reflux, crackles at the lung bases, hepatomegaly, ascites and pedal oedema. What is your provisional diagnosis? (Q855008)

A. Heart failure

B. Hypertrophic cardiomyopathy

C. Mitral regurgitation

D. Portal hypertension

See Answer in Part B → Q105

@Neet_pg_bot

Q106: Which of the following is not a radiological finding in a patient with left heart failure? (Q855046)

A. Kerley B lines

B. Focal oligemia

C. Increased venous blood in lung

D. Change in upper lobe circulation

See Answer in Part B → Q106

@Neet_pg_bot

Q107: A 60-year-old man presented with an episode of acute onset dizziness and loss of consciousness, which lasted for a few seconds, followed by a regain of full consciousness. There were no similar episodes in the past. Which of the following is a true statement regarding this scenario? (Q855052)

A. ECG to rule out atrial fibrillation

B. If ECG is normal, CT scan should be done

C. Tilt-table testing

D. Vestibular neuritis is a possible condition that can cause these symptoms

See Answer in Part B → Q107

@Neet_pg_bot

Q108: A 58-year-old male patient has been diagnosed with hypertension. On examination, there is no existing cardiovascular disease, no hypertension-mediated organ damage (HMOD), and renal function is normal. He should be immediately started on pharmacological management if his blood pressure is more than (Q855064)

A. >130/80 mmHg

B. >160/100 mmHg

C. >150/100 mmHg

D. >140/90 mmHg

See Answer in Part B → Q108

@Neet_pg_bot

Q109: A 65-year-old male patient presented with chest pain, exertional dyspnea and syncope. He was diagnosed with a case of aortic stenosis and his chest x-ray was taken which is shown below. What is the most likely diagnosis? (Q859523)

A. Dilated aortic root

B. Widening of aortic knob

C. Widening of the vascular pedicle

D. Post stenotic dilatation of aorta

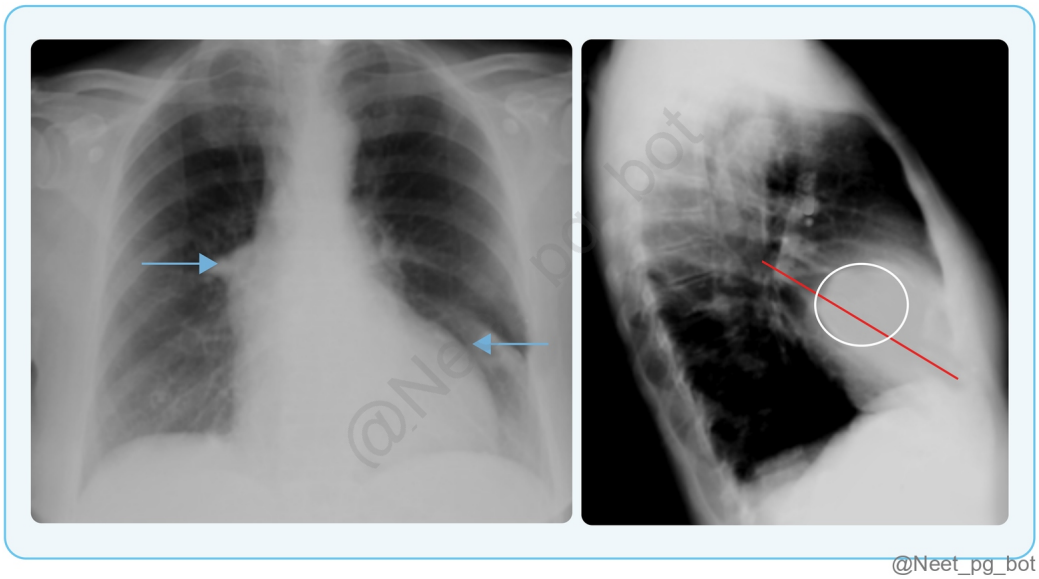

See Answer in Part B → Q109

@Neet_pg_bot

Q110: The device seen in the following image is? (Q859525)

A. Cardiac pacemaker

B. Chemo port device

C. Travel tract for accessory

D. Chest X-ray artefact

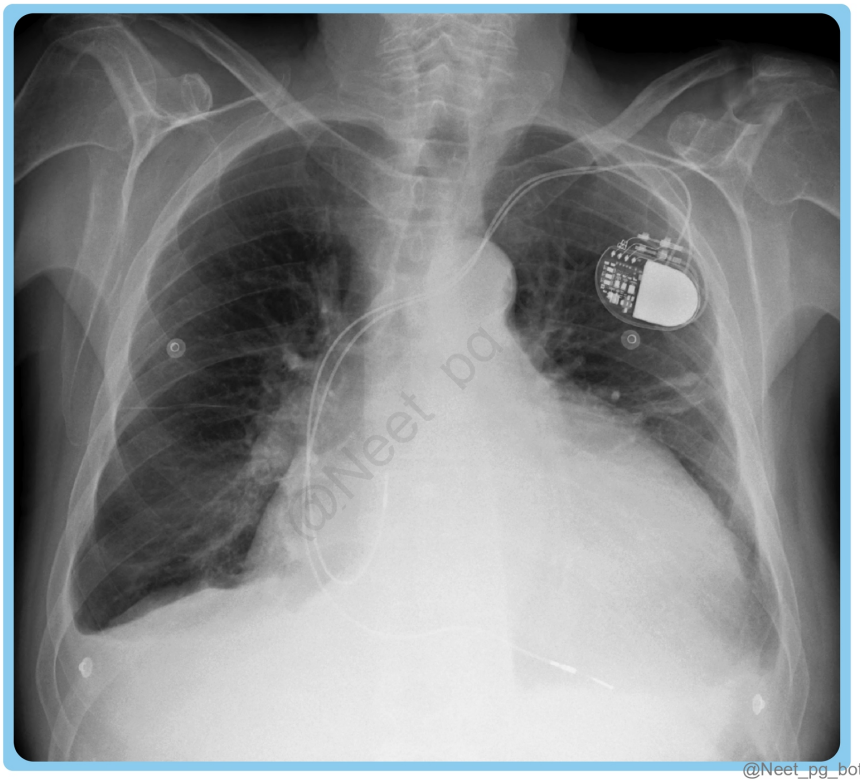

See Answer in Part B → Q110

@Neet_pg_bot

Q111: A 55-year-old male patient came to the hospital complaining of palpitations. During the examination, a diastolic murmur is detected in the left third intercostal space, along with the presence of a pistol shot sound over the femoral arteries. What is the diagnosis here? (Q859528)

A. Aortic regurgitation

B. Aortic stenosis

C. Tricuspid regurgitation

D. Mitral regurgitation

See Answer in Part B → Q111

@Neet_pg_bot

Q112: A person with dyspnea has a slight limitation in physical activity and doing ordinary activity causes symptoms but he is asymptomatic at rest. To which class does he belong, based on the New York Heart Association functional classification? (Q859529)

A. Class I

B. Class II

C. Class III

D. Class IV

See Answer in Part B → Q112

@Neet_pg_bot

Q113: A 56-year-old woman who had a heart attack 2 years ago is currently experiencing a cough and difficulty breathing while walking short distances. Physical examination revealed dullness upon percussion and reduced breath sounds on the right side. A chest x-ray indicated the presence of moderate pleural effusion. Thoracocentesis, guided by ultrasound, was performed and the laboratory results are provided below. Pleural fluid findings: Appearance: turbid pH: 7.1 Protein: 3.2 g/dL Lactate dehydrogenase: 80 U/L (normal serum LDH- 50-150 U/L) Pleural fluid protein/serum protein ratio: 0.34 Pleural fluid LDH /serum LDH: 0.3 Glucose: 54 mg/dL WBC count: 4000 cells/µL with >50% lymphocytes Adenosine deaminase: 30 U/L AFB smear microscopy: Negative Gram staining and microscopy: No organisms, no pus cells (Q859532)

A. Parapneumonic pleural effusion

B. Malignant pleural effusion

C. Congestive heart failure

D. Tubercular pleural effusion

See Answer in Part B → Q113

@Neet_pg_bot

Q114: What is the most likely diagnosis for a 45-year-old man who experiences chest pain and difficulty breathing that worsens when lying down but improves when sitting upright, and has muffled heart sounds during examination? (Q859534)

A. Pericardial effusion

B. Tetralogy of Fallot

C. Transposition of great arteries

D. Pulmonary hypertension

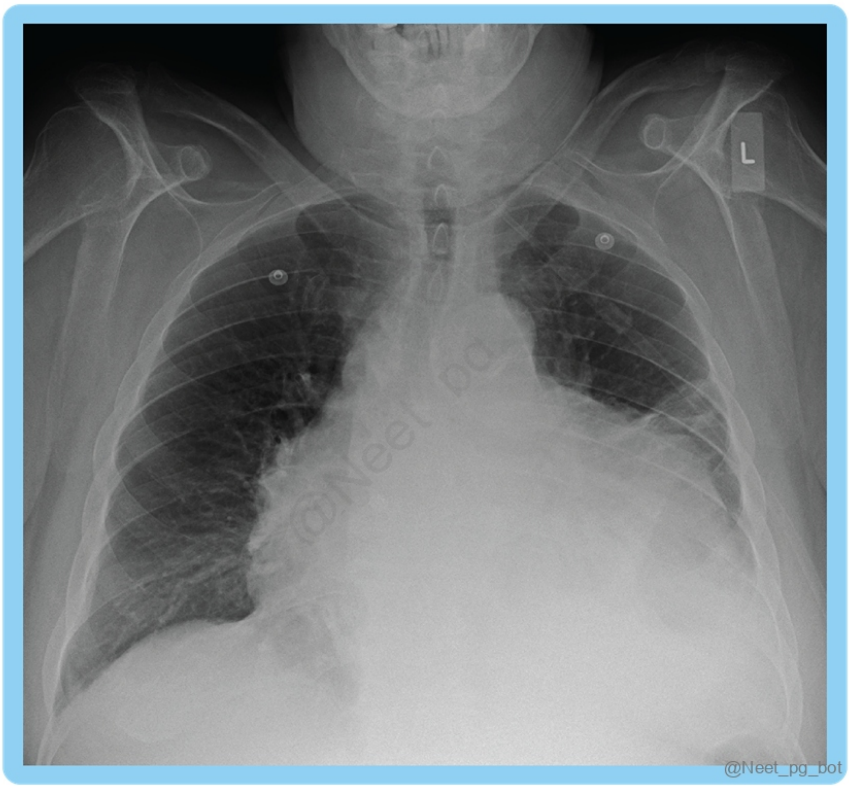

See Answer in Part B → Q114

@Neet_pg_bot

Q115: A 62-year-old man with a history of coronary artery disease presents with sudden onset palpitations, dizziness, and mild chest discomfort. His blood pressure is 90/60 mmHg and ECG is given below. What is the most likely diagnosis? (Q859535)

A. Atrial fibrillation

B. Atrial flutter

C. Ventricular tachycardia

D. Ventricular fibrillation

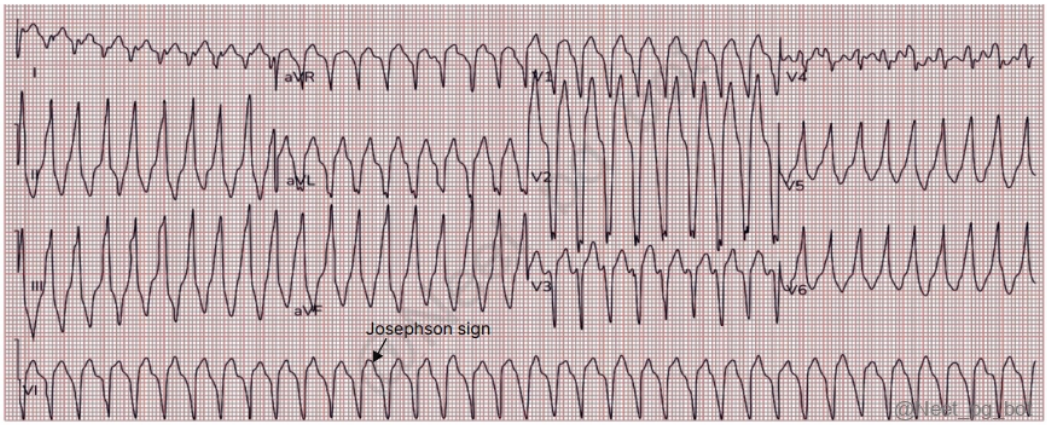

See Answer in Part B → Q115

@Neet_pg_bot

Q116: Based on the ECG given below, what is the most likely diagnosis? (Q859537)

A. Normal ECG

B. Ventricular fibrillation

C. Ventricular tachycardia

D. Misplaced leads

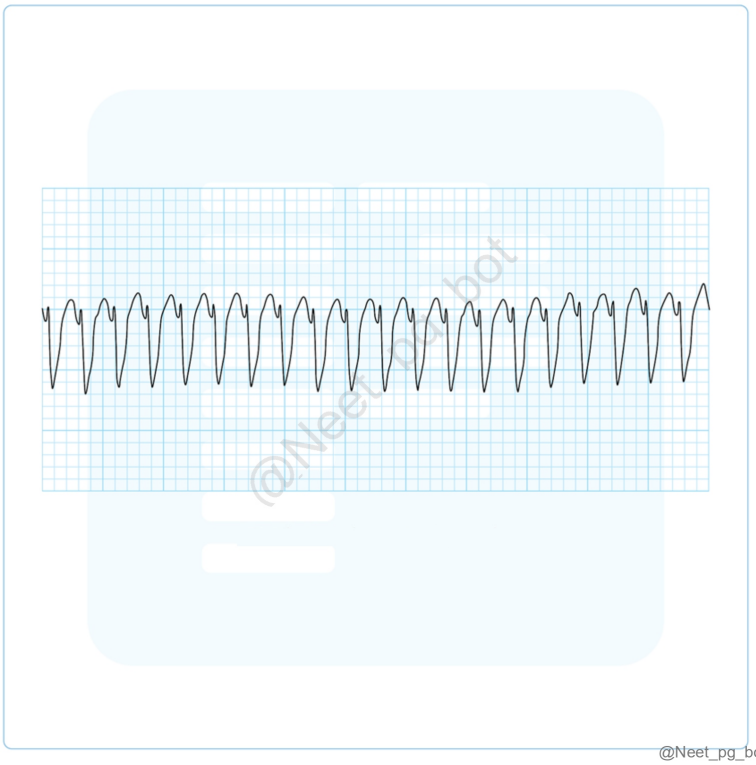

See Answer in Part B → Q116

@Neet_pg_bot

Q117: HV interval in the below given His bundle electrogram is for conduction: (Q859559)

A. Through the His-Purkinje system

B. From AV node to bundle of His

C. Purkinje to ventricular fibres

D. From a bundle of His and bundle branches to ventricles

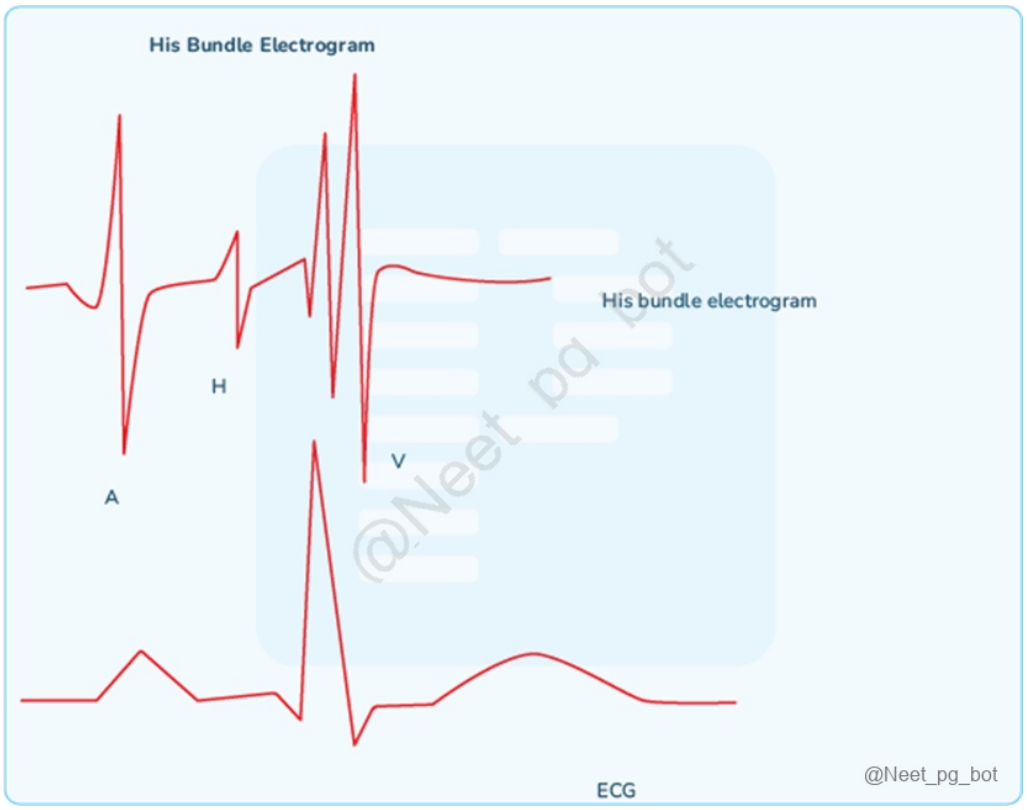

See Answer in Part B → Q117

@Neet_pg_bot

Q118: A 50-year-old man presents with recurrent episodes of chest pain which is seen only on exertion or exercise and lasts 2-5 minutes. He was assessed and was diagnosed with a case of stable angina however his BP was consistently elevated. What is the most appropriate antihypertensive for this patient (Q859560)

A. Atenolol

B. Thiazides

C. Enalapril

D. Amlodipine

See Answer in Part B → Q118

@Neet_pg_bot

Q119: A postoperative cardiac surgery patient developed sudden hypotension, raised central venous pressure, and pulsus paradoxus at the 4 th postoperative hour. The most probable diagnosis is. (Q859565)

A. Ventricular dysfunction

B. Cardiac tamponade

C. CHF

D. Excessive mediastinal effusion

See Answer in Part B → Q119

@Neet_pg_bot

Q120: A male patient in his youth comes to the clinic complaining of a persistent high fever over the past 5 days. During the examination of his hands, painless lesions are observed, and a new regurgitant murmur is detected. The echocardiogram reveals the existence of a mass on the mitral valve. Based on these findings, which of the following abdominal findings would be expected in this case? (Q859791)

A. Ascites

B. Splenomegaly

C. Hepatomegaly

D. Portal hypertension



See Answer in Part B → Q120

@Neet_pg_bot

Q121: Which of the following leads to a continuous murmur? (Q859800)

A. Peripheral Pulmonic stenosis

B. Severe Pulmonary artery hypertension

C. Type A aortic dissection

D. Rupture of cardiac chamber

See Answer in Part B → Q121

@Neet_pg_bot

Q122: A hypertensive patient who is non-compliant with medication presents with sudden-onset breathlessness. A chest X-ray reveals findings consistent with pulmonary edema. How will you manage this patient? (Q855894)

A. Intravenous salbutamol

B. Intravenous nitroglycerin

C. Nebulization with salbutamol

D. Oxygen and antibiotics

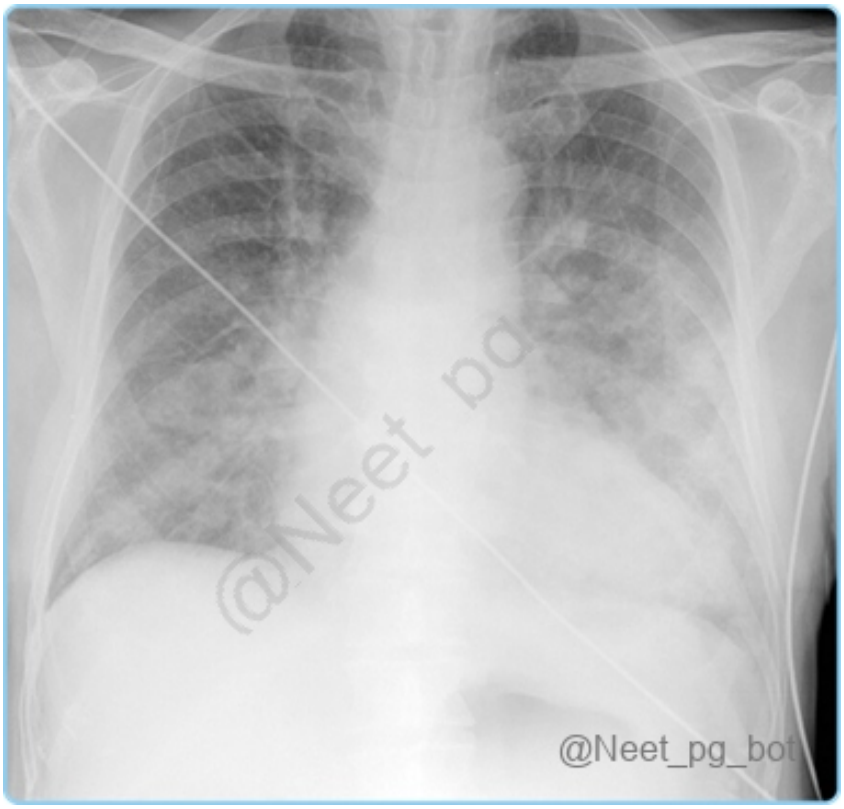

See Answer in Part B → Q122

@Neet_pg_bot

Q123: A patient on antidepressants presents with hypotension. An ECG reveals wide QRS complexes and right axis deviation. How will you manage this patient? (Q855897)

A. Antiarrhythmics

B. Intravenous sodium bicarbonate

C. Propranolol

D. Phenytoin

See Answer in Part B → Q123

@Neet_pg_bot

Q124: A 25-year-old patient is undergoing tooth extraction for dental caries. Which of the following does not require prophylaxis against infective endocarditis? (Q855912)

A. Prior history of endocarditis

B. Atrial septal defect

C. Unrepaired cyanotic heart disease

D. Prosthetic heart valves

See Answer in Part B → Q124

@Neet_pg_bot

Q125: A patient presents to you with an irregularly irregular pulse of 120/minute and a pulse deficit of 20. Which of the following would be the jugular venous pressure (JVP) finding? (Q855932)

A. Absent p wave

B. Absent a wave

C. Cannon a wave

D. Raised JVP with normal waveform

See Answer in Part B → Q125

@Neet_pg_bot

Q126: An 11-year-old child with a history of streptococcal pharyngitis presents with fever and arthralgia. There is no past history of rheumatic heart disease or carditis. How often is 600,000 IU of benzathine penicillin recommended for prophylaxis of

rheumatic heart disease? (Q856007)

A. Immediately

B. Thrice weekly lifelong

C. Once in three weeks for 5 years or till the age of 18, whichever is longer

D. Once in three weeks for 10 years or till the age of 25, whichever is longer

See Answer in Part B → Q126

@Neet_pg_bot

Q127: A man on diuretics presents with weakness. An ECG shows flat T waves and prominent U waves. What is the most likely diagnosis? (Q856009)

A. Hypocalcemia

B. Hypomagnesemia

C. Hyperkalemia

D. Hypokalemia

See Answer in Part B → Q127

@Neet_pg_bot

Q128: A patient with coronary artery disease presents to you with chest pain and palpitations. The ECG is shown below. Which of the following can be used in the management? (Q856017)

A. Oral metoprolol

B. Oral amiodarone

C. Intravenous amiodarone

D. Intravenous metoprolol

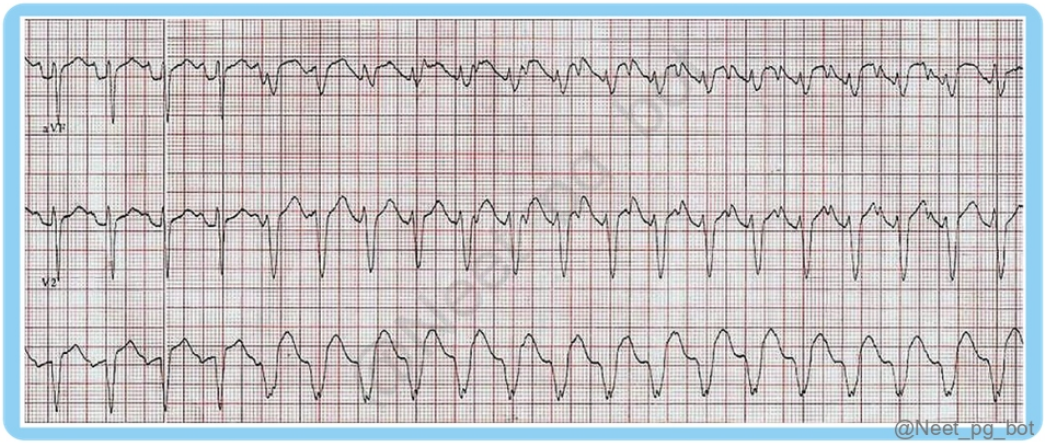

See Answer in Part B → Q128

@Neet_pg_bot

Q129: A 20-year-old female presents with septic shock, blood pressure 58/30 mmHg, and MAP 58 mmHg. She has received 30 mL/kg of crystalloid fluid, but her MAP remains <65 mmHg. What is the next best step in management? (Q865315)

A. Start dopamine

B. Start noradrenaline

C. Repeat crystalloid fluid

D. Start vasopressin

See Answer in Part B → Q129

@Neet_pg_bot

Q130: A patient presents to the ER with central chest pain. He has a past medical history of heart disease. ECG is shown below. What is the diagnosis? (Q866785)

A. Anterolateral MI

B. Inferolateral MI

C. Acute pericarditis

D. Constrictive pericarditis

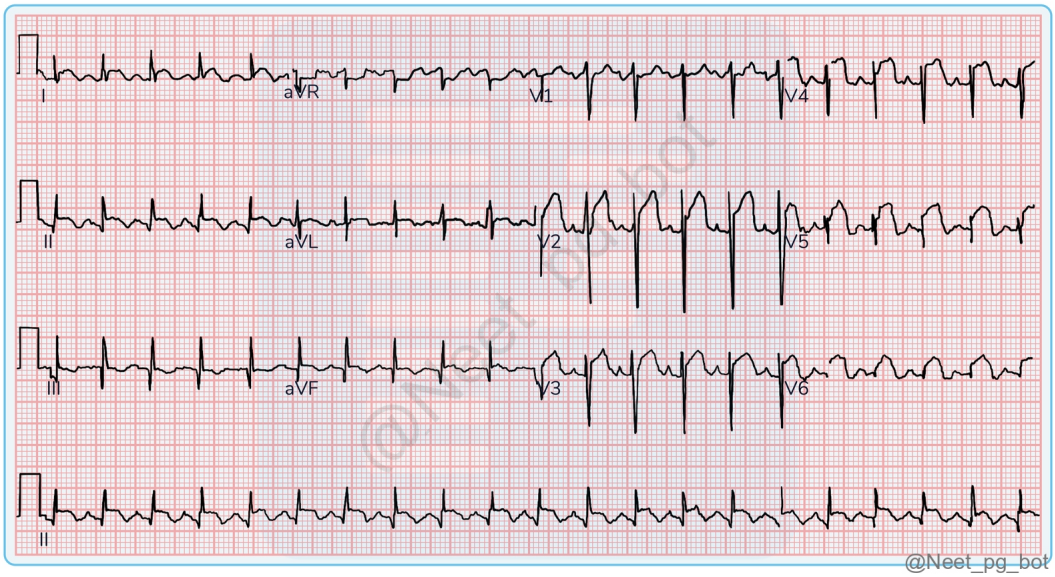

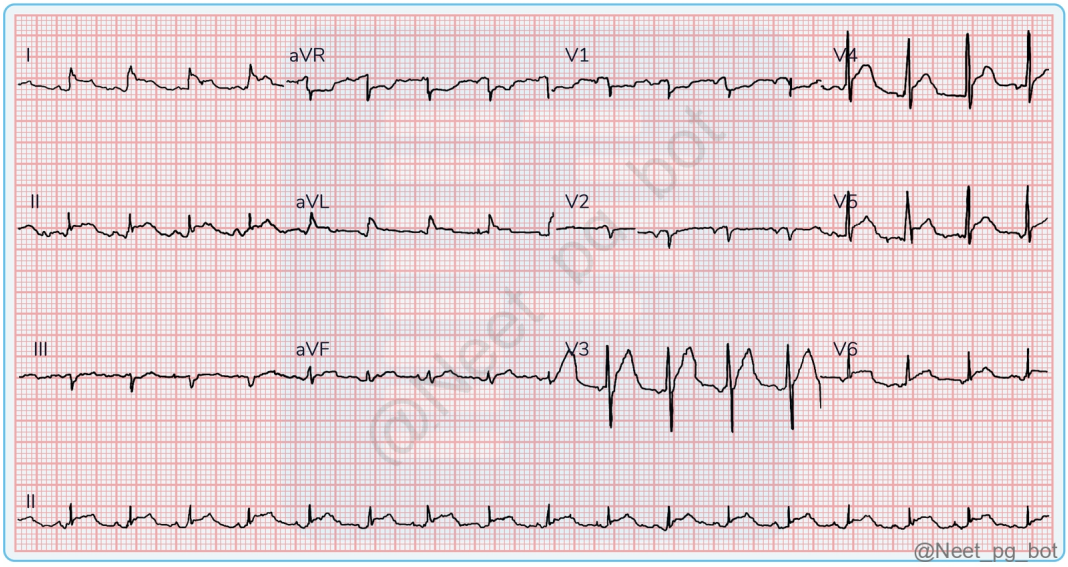

See Answer in Part B → Q130

@Neet_pg_bot

Q131: A patient after MI develops a broad QRS complex tachycardia. His BP is 120/85 mm Hg. ECG is given below. Best management? (Q866787)

A. Amiodarone iv

B. Labetalol iv

C. Metoprolol iv

D. Nitroglycerin iv

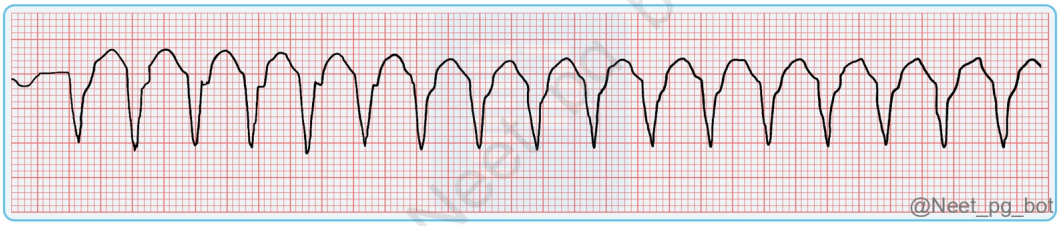

See Answer in Part B → Q131

@Neet_pg_bot

Q132: A man presents to the emergency department unconscious and hypotensive. His ECG reveals narrow complex tachycardia. What is the next best step in management? (Q840106)

A. Synchronized DC cardioversion

B. Carotid massage

C. IV adenosine 6 mg

D. IV amiodarone

See Answer in Part B → Q132

@Neet_pg_bot

Q133: A 70-year-old man collapsed in his house and was rushed to the hospital. On arrival, his ECG tracing was as shown below. Which of the following is the best intervention for this patient? (Q859568)

A. Use of automated external defibrillator

B. Injection of vasopressin 40 IU

C. Injection of Adrenaline 1mg IV

D. Injection of Atropine 0.5mg IV

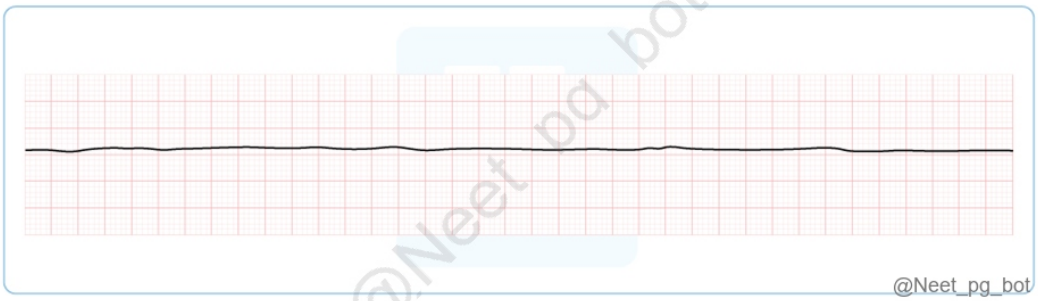

See Answer in Part B → Q133

@Neet_pg_bot

Q134: Which of these conditions will cause a large ‘P’ wave in ECG? (Q879158)

A. Mitral stenosis

B. Aortic stenosi

C. Aortic regurgitation

D. Tricuspid stenosis

See Answer in Part B → Q134

@Neet_pg_bot

Q135: Which of the following conditions does NOT share the same initial mechanism leading to heart failure as the others? (Q879211)

A. High salt intake

B. Anemia

C. Fever

D. Thyrotoxicosis

See Answer in Part B → Q135

@Neet_pg_bot

Q136: A 20-year-old athlete died during a practice session, and the attending doctor declared him dead on arrival and sent for an autopsy. The gross specimen of his heart is shown below. What is the plausible cause and advice to the family? (Q879215)

A. Cardiac arrest, check cholesterol in family members

B. Cardiac arrest due to hypertrophic cardiomyopathy, screen family members

C. Sudden cardiac death due to valvular pathology caused by rheumatic etiology

D. Cardiac arrest due to arrhythmias and heart blockwith no significant lesion on cardiac autopsy



See Answer in Part B → Q136

@Neet_pg_bot

Q137: A patient presents with exertional dyspnea and pedal oedema. His echocardiogram shows a dilated left ventricle with reduced systolic function. Which of the following statements regarding this condition is false? (Q879444)

A. Pulmonary hypertension may develop in this patient

B. Ejection fraction will be reduced in this condition

C. Long-term anticoagulation is not needed for this patient

D. Beta blockers are indicated in chronic management

See Answer in Part B → Q137

@Neet_pg_bot

Q138: Which of the following conditions is characterized by the absence of P waves? (Q793825)

A. Ventricular tachycardia

B. Focal atrial tachycardia

C. Ventricular fibrillation

D. Atrial fibrillation

See Answer in Part B → Q138

@Neet_pg_bot

Q139: Interpret the ECG given below. (Q793832)

A. Ventricular fibrillation

B. Atrial fibrillation

C. Supra ventricular tachycardia

D. Ventricular tachycardia

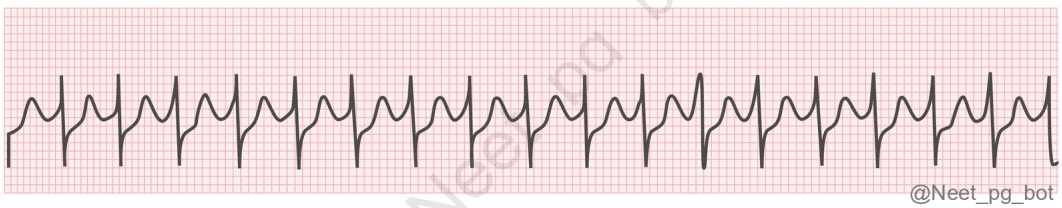

See Answer in Part B → Q139

@Neet_pg_bot

Q140: J-wave is seen in? (Q793859)

A. Hypothermia

B. Heat stroke

C. High-altitude pulmonary edema

D. Drowning

See Answer in Part B → Q140

@Neet_pg_bot

Q141: A 26-year-old male patient, an accident victim started developing difficulty in breathing . On examination, his BP as 80/40 mmHg and pulses were feeble, JVP was found to be elevated with an absent Y descent, and heart sounds were muffled . What is the most likely diagnosis? (Q793863)

A. Constrictive pericarditis

B. Cardiac tamponade

C. Acute pericarditis

D. Cardiac failure

See Answer in Part B → Q141

@Neet_pg_bot

Q142: A known hypertensive patient is brought to the ER with palpitations and breathlessness. On examination, his BP was 220/140 with signs of encephalopathy. All of the following can be used to treat this condition except? (Q793876)

A. IV Nicardipine

B. IV Mannitol

C. IV Esmolol

D. IV Sodium Nitroprusside

See Answer in Part B → Q142

@Neet_pg_bot

Q143: A patient with chronic stable angina is having signs of heart failure. The use of which of the following drugs can decrease mortality? (Q793889)

A. Nifedipine

B. Digoxin

C. Lisinopril

D. Torsemide

See Answer in Part B → Q143

@Neet_pg_bot

Q144: A person collapses following a road traffic accident, and you begin performing CPR. The rescue team arrives with an automated external defibrillator (AED). Which of the following is the most appropriate next step? (Q793901)

A. Continue 5 rounds of CPR @ 30:2 followed by application of AED

B. Continue CPR while the team applies the AED paddles

C. Stop CPR and let them apply paddles

D. Handover the patient and leave

See Answer in Part B → Q144

@Neet_pg_bot

Q145: What is the probable diagnosis based on the ECG given below? (Q793909)

A. Hypokalemia

B. Hyperkalemia

C. Hypothermia

D. Hypocalcemia

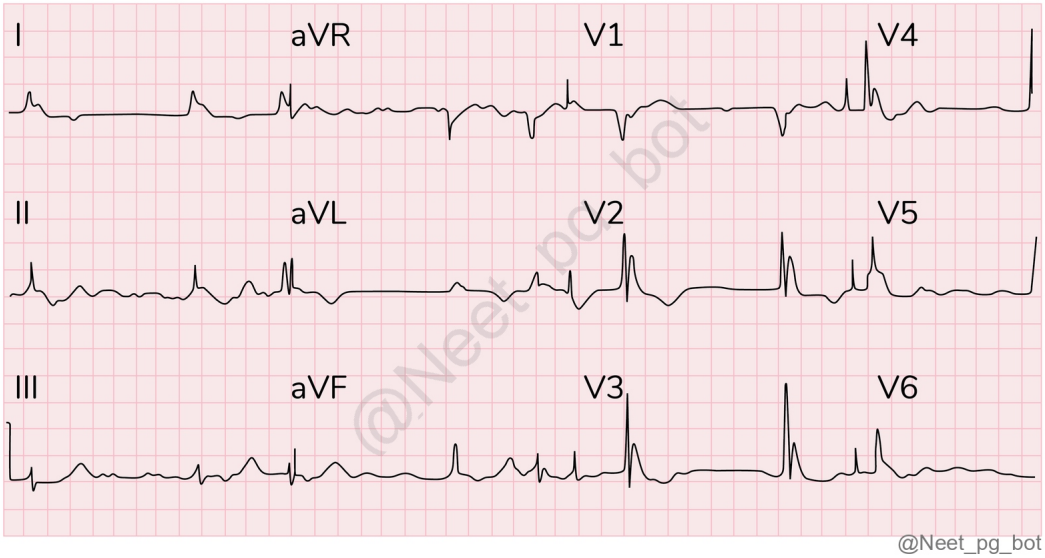

See Answer in Part B → Q145

@Neet_pg_bot

Q146: A 19-year-old woman with no comorbidities presented with numbness and paraesthesia of the fingers along with the characteristic finding shown in the image below. She has no other illnesses, and she says these episodes occur when she is under excess stress or during cold temperatures . What is the most likely diagnosis ? (Q793945)

A. Primary Raynaud’s phenomenon

B. Secondary Raynaud’s phenomenon

C. Cold sores

D. Scleredema



See Answer in Part B → Q146

@Neet_pg_bot

Q147: Identify the false statement regarding management of NSTEMI (Q793962)

A. Aspirin loading dose should be initated immediately

B. ACC/AHA guidelines call for either a P2Y12 inhibitor (clopidogrel, prasugrel or ticagrelor) as a class I recommendation

C. Glycoprotein IIB/IIIA inhibitors are useful adjuncts

D. Fibrinolytic therapy is useful in acute coronary syndrome without ST-segment elevation

See Answer in Part B → Q147

@Neet_pg_bot

Q148: A 16-year-old female presents with recent episodes of palpitations and shortness of breath. On examination, she has a systolic murmur at the cardiac apex.

Laboratory evaluation shows elevated anti-streptolysin O titers and erythrocyte sedimentation rate. An echocardiogram reveals moderate regurgitation in the mitral valve. A biopsy of her heart tissue is performed, and a pathology image is provided below. Which of the following statements about this pathology is not true? (Q828964)

A. Present in myocardium and endocardium only

B. Fibrinoid necrosis in the center

C. Uncommon in chronic stages

D. Anitschkow cells

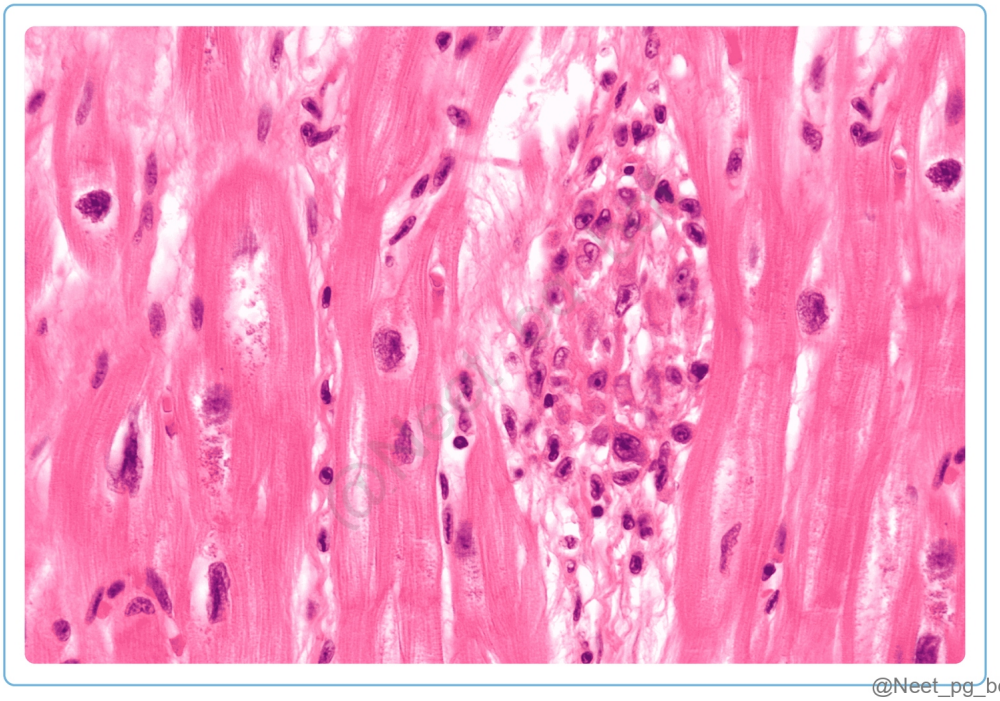

See Answer in Part B → Q148

@Neet_pg_bot

• [02_Emergency Medicine] 010 Emergency Cardiovascular Care Protocols Bcls Acls Mechanical Ventilation And Causes Of Pulseless Electrical Activity

« Back to Folder Directory

[02_Emergency Medicine] 010 Emergency Cardiovascular Care Protocols Bcls Acls Mechanical Ventilation And Causes Of Pulseless Electrical Activity — Quick Jump

Q1 (p. 196) *Q2 (p. 196)* *Q3 (p. 197)* *Q4 (p. 197)* *Q5 (p. 198)* *Q6 (p. 198)*
Q7 (p. 199) *Q8 (p. 199)* *Q9 (p. 199)* *Q10 (p. 200)* *Q11 (p. 200)* *Q12 (p. 201)*
Q13 (p. 201)

Q1: You are walking in a park when you notice an elderly person collapse in front of you. Which of the following is the first step in managment of this patient? (Q850935)

A. Initiate chest compressions

B. Check for scene safety

C. Call for help

D. Check carotid pulse

See Answer in Part B → Q1

@Neet_pg_bot

Q2: You are intern posted in ICU. Nurse calls you to assist for a sepsis patient whose ECG monitor is showing the following display and she has started chest compressions. Which of the following is the first step in managment of this patient? (Q850936)

A. Intubate the patient

B. Defibrillation

C. Cardioversion

D. Amiodarone

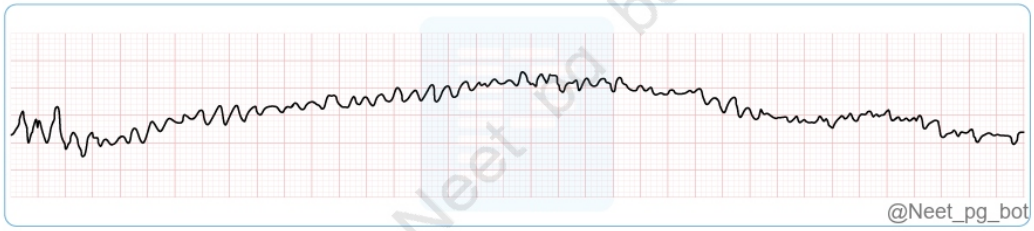

See Answer in Part B → Q2

@Neet_pg_bot

Q3: 65 year old patient with anterior wall MI develops asystole. Which of the following is the first step in management of this patient? (Q850937)

A. Asses for reversible causes

B. Check pulse

C. Chest compressions @30:2

D. 10 ml of 1:10,000 Epinephrine

See Answer in Part B → Q3

@Neet_pg_bot

Q4: Assertion: Cardioversion is the preferred treatment for hemodynamic compromise caused by supraventricular tachycardia Reason: Synchronized direct current (DC) shock is administered at the peak of the R wave to avoid R on T phenomenon (Q850938)

A. Both assertion and reason are true, and the reason is a correct explanation of the assertion.

B. Both assertion and reason are true, but the reason is not a correct explanation of the assertion.

C. The assertion is true, but the reason is false.

D. The assertion is false, but the reason is true.

See Answer in Part B → Q4

@Neet_pg_bot

Q5: You are resuscitating a patient with following ECG tracing in ER. CPR is given @30:2 and 10 ml of 1: 10,000 adrenaline is given twice at interval of 3 minutes but the tracing is still the same. What is next best step in management of this patient? (Q850939)

A. Repeat 10 ml of 1: 10,000 adrenaline iv

B. Repeat 1 ml of 1: 10,000 adrenaline iv

C. Give DC shock 200J biphasic

D. Give DC shock 360J monophasic

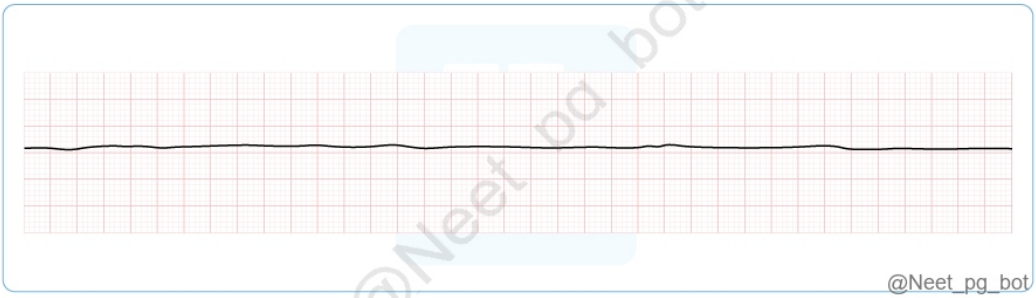

See Answer in Part B → Q5

@Neet_pg_bot

Q6: Blood pressure of a 65-year-old male in the ICU crashes. ECG tracing shows Ventricular fibrillation. 200 J biphasic shock is given to patient. Which of the following is next best step for management of this patient? (Q850940)

A. Amiodarone

B. Start CPR

C. Secure advanced airway

D. Epinephrine

See Answer in Part B → Q6

@Neet_pg_bot

Q7: An alcoholic is admitted with diagnosis acute pancreatitis. On day 2 evening, he is shifted to ICU for Ventilator assistance for ARDS. Which of the following statements is not correct regarding the management of this patient? (Q850941)

A. Set tidal volume of 12 mL/kg lean body weight

B. Prone positioning

C. Set FiO2 at 1.0 and then titrate down to maintain pO2 55- 80 mm Hg

D. Adjust Respiratory rate to keep pH > 7.3

See Answer in Part B → Q7

@Neet_pg_bot

Q8: A 58-year-old male patient with chronic obstructive pulmonary disease (COPD) is admitted to the hospital and placed on mechanical ventilation. His arterial blood gas analysis shows the following values: PaO2: 86 mmHg, PaCO2: 50 mmHg and pH: 7.32. Which of the following management strategies should be prioritized for this patient? (Q850942)

A. Decrease the tidal volume to improve ventilation.

B. Increase the FiO2 immediately to avoid oxygen toxicity.

C. Increase PEEP to improve oxygenation and maintain lung recruitment.

D. Increase the expiratory time to promote CO2 washout

See Answer in Part B → Q8

@Neet_pg_bot

Q9: A 35-year-old male with Guillain-Barré Syndrome develops progressive respiratory muscle weakness and is placed on mechanical ventilation. Which of the following ventilator modes is most appropriate in this setting? (Q850943)

A. Pressure Support Ventilation

B. Synchronized Intermittent Mandatory Ventilation

C. Assist-Control Mechanical Ventilation

D. Continuous Positive Airway Pressure

See Answer in Part B → Q9

@Neet_pg_bot

Q10: A 60-year-old male is on mechanical ventilation for acute hypoxemic respiratory failure (Type 1). His latest ABG shows: pH: 7.43, PaCO■: 38 mmHg, PaO■: 54 mmHg, HCO■■: 24 mEq/L. Which of the following changes should be made to improve his oxygenation? (Q850944)

A. Increase tidal volume

B. Increase FiO■

C. Decrease respiratory rate

D. Increase minute ventilation

See Answer in Part B → Q10

@Neet_pg_bot

Q11: A 28-year-old male is admitted to the ICU after sustaining blunt chest trauma in a motor vehicle accident. Chest imaging reveals pulmonary contusions. After 48 hours, he develops severe hypoxemia with PaO■/FiO■ ratio of 110, bilateral infiltrates on chest X-ray, and no signs of left heart failure. What is the most appropriate next step in management? (Q850945)

A. Insert a wide-bore needle in the fifth intercostal space

B. Start intravenous furosemide to reduce pulmonary edema

C. Begin low tidal volume mechanical ventilation

D. Initiate high-flow nasal cannula oxygen therapy

See Answer in Part B → Q11

@Neet_pg_bot

Q12: A 45-year-old male presents with acute shortness of breath, orthopnea, and bilateral pulmonary crackles. Work up shows elevated Pro-NT- BNP levels and ABG shows type 1 respiratory failure with pO2=60 mm Hg. Which of the following is best to improve his oxygenation status? (Q850946)

A. High-flow nasal cannula

B. Urgent intubation

C. Non-rebreather mask

D. NIV using Bi-PAP

See Answer in Part B → Q12

@Neet_pg_bot

Q13: A 68-year-old male with a history of COPD presents with increasing dyspnea, productive cough, and confusion. Arterial blood gas (ABG) shows pH 7.30, pCO■ 58 mmHg, and pO■ 55 mmHg. He is hemodynamically stable. What is the next best step in management? (Q850947)

A. Immediate endotracheal intubation

B. Noninvasive positive-pressure ventilation

C. Intravenous antibiotics only

D. High-flow nasal cannula oxygen therapy

See Answer in Part B → Q13

@Neet_pg_bot

• [02_Emergency Medicine] 011 Massive Transfusion Protocol Ards Snakebite Aha Updates Altitude Sickness

« Back to Folder Directory

[02_Emergency Medicine] 011 Massive Transfusion Protocol Ards Snakebite Aha Updates Altitude Sickness — Quick Jump

Q1 (p. 202)	*Q2 (p. 202)*	*Q3 (p. 203)*	*Q4 (p. 203)*	*Q5 (p. 204)*	*Q6 (p. 204)*
Q7 (p. 204)	*Q8 (p. 205)*	*Q9 (p. 205)*	*Q10 (p. 206)*	*Q11 (p. 206)*	*Q12 (p. 207)*
Q13 (p. 207)	*Q14 (p. 208)*	*Q15 (p. 208)*	*Q16 (p. 209)*	*Q17 (p. 209)*	*Q18 (p. 209)*

Q1: A 60-year-old man collapses at a shopping mall. Bystanders start CPR and activate EMS. On arrival, paramedics find the patient unresponsive, pulseless, and in ventricular fibrillation on the monitor. What is the next best step for his managment? (Q850671)

A. Begin chest compressions and administer 1 mg epinephrine immediately, then attempt defibrillation

B. Deliver one shock with a biphasic defibrillator followed by immediate chest compressions, then secure airway

C. Deliver three stacked shocks followed by pulse check and atropine administration

D. Perform synchronized cardioversion followed by amiodarone if rhythm persists

See Answer in Part B → Q1

@Neet_pg_bot

Q2: A 35-year-old male mountaineer plans a rapid ascent to an altitude of 4500 meters for a climbing expedition. He has a history of experiencing symptoms like fatigue, non-productive cough, and difficulty breathing during previous high-altitude trips. Based on the scenario, which of the following strategies should the mountaineer implement to effectively prevent symptoms, and what is the main treatment he should consider if symptoms develop? (Q850690)

A. Maintain an average altitude gain exceeding 300 m per day, and begin immediate treatment with acetazolamide

B. Ascend rapidly without acclimatization, and use supplemental oxygen if symptoms develop

C. Ascend slowly with a maximum altitude gain of 300 m per day, and prioritize descent of 1000 meters if symptoms occur

D. Use alcohol to relax during the ascent, and rely solely on portable hyperbaric chambers if symptoms arise

See Answer in Part B → Q2

@Neet_pg_bot

Q3: A 28-year-old male skier is found unresponsive in the snow with a core body temperature of 27°C (81°F). Which of the following is NOT a treatment approach for managing his hypothermia? (Q850682)

A. Administer warm intravenous fluids at 40-42°C

B. Utilize extracorporeal membrane oxygenation to provide rewarming and circulatory support

C. Use passive external rewarming by layering him with wet clothing

D. Perform active internal rewarming using warm saline lavage of body cavities

See Answer in Part B → Q3

@Neet_pg_bot

Q4: A 40-year-old male fisherman is rescued after being exposed to cold water for several hours. Upon examination, his core body temperature is 29°C (84°F). He shows signs of lethargy, dilated pupils, and a slow heart rate. Which of the following statements about his condition is false? (Q850680)

A. Mild hypothermia typically presents with symptoms like shivering and increased muscle tone.

B. In moderate hypothermia shivering generally stops as the body temperature approaches 30°C.

C. Severe hypothermia can lead to unresponsiveness and increased risk of cardiac dysrhythmias.

D. Osborn waves are typically absent in hypothermic patients with temperatures below 28°C.

See Answer in Part B → Q4

@Neet_pg_bot

Q5: A 30-year-old male hiker ascends rapidly from sea level to an altitude of 4500 meters over 24 hours. Two days after his arrival, he begins to experience increasing fatigue, a non-productive cough, and difficulty breathing during physical activity. His oxygen saturation is 60% on examination, and he exhibits tachypnea and cyanosis. Based on the scenario, which factors do not contribute to the patient's clinical features? (Q850677)

A. Low hypoxic ventilatory response (HVR)

B. Use of sleep medications during ascent

C. Recent heavy physical exertion prior to ascent

D. Extended acclimatization period before ascent

See Answer in Part B → Q5

@Neet_pg_bot

Q6: A 34-year-old woman, 36 weeks pregnant, is brought to the emergency department after collapsing at home. Upon arrival, she is unresponsive and in cardiac arrest. CPR is initiated immediately. The team begins advanced cardiac life support for pregnancy. Which of the following is the correct to optimize maternal and fetal outcomes? (Q850676)

A. Delay chest compressions to position the patient for cesarean section.

B. Perform left uterine displacement.

C. Administer 2 mg epinephrine IV every 5 minutes.

D. Delay defibrillation to avoid harm to the fetus.

See Answer in Part B → Q6

@Neet_pg_bot

Q7: A 58-year-old man suffers a witnessed cardiac arrest in the emergency room. After 3 cycles of CPR , iv epinephrine, 2 defibrillation shocks, he achieves return of spontaneous circulation (ROSC). He is now unresponsive, with a blood pressure of 88/50 mmHg and SpO■ of 92% on 10 L/min oxygen by face mask. Which of the following is the most appropriate next step in management? (Q850674)

A. Administer 1 mg epinephrine IV every 3–5 minutes and continue chest compressions

B. Perform immediate coronary angiography and stenting regardless of ECG findings

C. Optimize oxygenation and ventilation, and assess for need of vasopressors and targeted temperature management

D. Discontinue resuscitation efforts and observe, as ROSC has been achieved

See Answer in Part B → Q7

@Neet_pg_bot

Q8: A 55-year-old man experiences a sudden cardiac arrest while jogging in a park. A bystander witnesses the collapse. According to the Adult OHCA Chain of Survival, what is the correct sequence of actions performed by the emergency responders in this scenario? (Q850673)

A. Early recognition and Prevention → Activation of Emergency Response → Defibrillation → High-Quality CPR → Recovery→ Post-Cardiac Arrest Care

B. Activation of Emergency Response → High-Quality CPR → Defibrillation → Advanced Resuscitation → Post-Cardiac Arrest Care → Recovery

C. High-Quality CPR → Activation of Emergency Response → Advanced Resuscitation → Defibrillation → Post-Cardiac Arrest Care → Recovery

D. High-Quality CPR → Activation of Emergency Response → Defibrillation → Advanced Resuscitation → Post-Cardiac Arrest Care → Recovery

See Answer in Part B → Q8

@Neet_pg_bot

Q9: 4-year-old child is found unresponsive at home. The parents initiate CPR, and the child is transported to the emergency department. Upon arrival, the medical team begins CPR and attaches a defibrillator. The rhythm check shows asystole. What is the next step in managing this child according to the Pediatric cardiac arrest Algorithm? (Q850672)

A. Deliver a shock immediately

B. Administer Amiodarone IV/IO

C. Administer Epinephrine and continue CPR

D. Administer Lidocaine IV/IO

See Answer in Part B → Q9

@Neet_pg_bot

Q10: Which of the following statements about massive transfusion is not correct? (Q850645)

A. PRBC should be administered first to address hypoxia and acidosis in bleeding patient

B. 1:1:0.25 ratio of PRBC: FFP: SDP

C. Blood products should be warmed before infusion to prevent coaguloapthy

D. ABO grouping is not required for platelet transfusion

See Answer in Part B → Q10

@Neet_pg_bot

Q11: A 35-year-old farmer is brought to ER 2 hours after being bitten by a snake on his left ankle. He has severe swelling of the left leg, gingival bleeding, and incoagulable blood on the 20-minute whole blood clotting time test. You decide to administer ASV . Twenty minutes after starting the ASV infusion, the patient develops urticaria, cough, and abdominal pain. His blood pressure drops to 85/50 mmHg. Which of the following is the most appropriate next step in management? (Q850669)

A. Discontinue ASV infusion permanently

B. Continue ASV infusion and administer corticosteroids

C. Stop ASV infusion temporarily and treat with epinephrine

D. Administer heparin to counteract coagulopathy

See Answer in Part B → Q11

@Neet_pg_bot

Q12: A 28-year-old farmer is brought to the ER 30 minutes after being bitten by a snake on his right leg. He presents with severe pain and swelling at the bite site, and examination reveals two puncture wounds. His blood pressure is 90/60 mmHg and he has gingival bleeding. The 20-minute whole blood clotting time test shows that the blood is incoagulable. Which of the following is the most appropriate next step in management? (Q850666)

A. Administer crypoprecipitate

B. Administer 150-200 ml of polyvalent antivenom

C. Apply a tight tourniquet above the bite site

D. Administer heparin to manage coagulopathy

See Answer in Part B → Q12

@Neet_pg_bot

Q13: A 32-year-old farmer is brought to the emergency department after being bitten by a snake while working in his field in rural India. He presents with severe local pain, swelling, and gum bleeding. Within 2 hours, he develops diplopia, dysphagia, and progressive weakness in his limbs. Laboratory tests show prolonged prothrombin time and decreased fibrinogen levels. Which of the following snakes is most likely responsible for this envenomation? (Q850661)

A. Cobra

B. Russell's viper

C. Saw-scaled viper

D. Krait

See Answer in Part B → Q13

@Neet_pg_bot

Q14: A 60-year-old woman is admitted to the ICU with sepsis secondary to a urinary tract infection. After 48 hours, she develops acute hypoxemic respiratory failure. Her chest X-ray shows bilateral infiltrates, and her PaO2/FiO2 ratio is 180 mmHg on PEEP of 8 cm H2O. An echocardiogram shows normal cardiac function. Which of the following is the most appropriate next step in management? (Q850660)

A. Initiate high-frequency oscillatory ventilation

B. Start inhaled nitric oxide therapy

C. Begin low tidal volume ventilation with 6 mL/kg lean body weight

D. Administer high-dose corticosteroids

See Answer in Part B → Q14

@Neet_pg_bot

Q15: A 45-year-old man is admitted to the ICU with severe pneumonia. He develops worsening respiratory symptoms and bilateral infiltrates on chest X-ray within 5 days. Which of the following best describes the pathophysiological mechanism occurring in the alveoli during the early phase of this patient's condition? (Q850655)

A. Increased surfactant production

B. Thickening of the alveolar basement membrane

C. Accumulation of protein-rich edema fluid

D. Fibrosis of the alveolar walls

See Answer in Part B → Q15

@Neet_pg_bot

Q16: A 55 year-old male presents to the emergency department with fever, tachypnea, and altered mental status. BP is 100/60 mm Hg Laboratory results show: WBC: 14,000/μL Serum lactate: 1.8 mmol/L Creatinine: 1.8 mg/dL (baseline 0.9 mg/dL) Chest X-ray reveals a right lower lobe infiltrate. The patient requires 6 L/min of oxygen to maintain pO2 of 90 mm Hg. Which of the following is the most accurate diagnosis for this patient? (Q850652)

A. Systemic Inflammatory Response Syndrome

B. Sepsis

C. Acute Tubular necrosis

D. Septic shock

See Answer in Part B → Q16

@Neet_pg_bot

Q17: A 30-year-old trauma patient underwent massive transfusion protocol after a road traffic accident. Six hours later, he develops acute onset dyspnea, hypoxia, and bilateral pulmonary infiltrates on chest X-ray. He is afebrile, Pulse 100/min with BP 124/ 80 mm Hg. JVP is normal and pro NT BNP levels are normal. What is the most likely diagnosis? (Q850648)

A. Transfusion-associated circulatory overload

B. Transfusion-related acute lung injury

C. Mismatched blood transfusion

D. Laryngospasm due to citrate induced hypocalcemia

See Answer in Part B → Q17

@Neet_pg_bot

Q18: A 28-year-old male is brought to the trauma center following a motorcycle accident. He is unconscious BP 70/40 mmHg and shows signs of active bleeding. Massive transfusion protocol is initiated. After receiving 4 units of PRBCs rapidly, he develops muscle twitching. ABG shows metabolic alkalosis. ECG shows normal sinus rythm with QT prolongation. What is the most appropriate immediate next step in his management? (Q850646)

A. Administer intravenous calcium gluconate to correct citrate-induced hypocalcemia, which is causing neuromuscular irritability and QT prolongation.

B. Start platelet transfusion immediately to correct dilutional thrombocytopenia, as prolonged transfusion leads to bleeding due to thrombocytopenia.

C. Give sodium bicarbonate to treat the developing metabolic alkalosis resulting from massive transfusion.

D. Transfuse cryoprecipitate to correct fibrinogen deficiency and prevent DIC-like picture often seen after >10 units of PRBC.

See Answer in Part B → Q18

@Neet_pg_bot

• [02_Emergency Medicine] 012 Previous Year Questions

« Back to Folder Directory

[02_Emergency Medicine] 012 Previous Year Questions — Quick Jump

Q1 (p. 211) *Q2 (p. 211)* *Q3 (p. 211)* *Q4 (p. 212)* *Q5 (p. 212)* *Q6 (p. 213)*
Q7 (p. 213) *Q8 (p. 213)* *Q9 (p. 214)* *Q10 (p. 214)* *Q11 (p. 215)* *Q12 (p. 215)*
Q13 (p. 215)

Q1: An RTA patient has received 4 packed RBC within a few hours. Which of the following will be seen? (Q866789)

A. Hypernatremia

B. Hyponatremia

C. Hypocalcemia

D. Hyperkalemia

See Answer in Part B → Q1

@Neet_pg_bot

Q2: Which is the best confirmatory method to ensure the central line is in the jugular vein? (Q866816)

A. Chest x-ray

B. Blood pH

C. Blood color

D. ETCO2

See Answer in Part B → Q2

@Neet_pg_bot

Q3: Young male has sustained Femur shaft fracture after RTA and internal fixation was done. 2 days later he develops shortness of breath with confusion and petechial rash. Diagnosis is? (Q866513)

A. FES

B. ARDS

C. Pulmonary embolism

D. Pleural effusion

See Answer in Part B → Q3

@Neet_pg_bot

Q4: Which of the following is not part of the clinical criteria for anaphylaxis? Urticaria, lip/tongue edema Wheeze and respiratory distress Abdominal cramps and vomiting Hypertension (Q840144)

A. 1, 2, and 3

B. 1 and 2

C. 2 and 3

D. 4

See Answer in Part B → Q4

@Neet_pg_bot

Q5: A 65-year-old patient with type 2 diabetes mellitus experiences hypoglycemia and falls, resulting in incoherent speech. CT scan reveals a large acute subdural hematoma (SDH) >30 cc. What is the most appropriate immediate management? (Q860237)

A. Administer intravenous mannitol and observe

B. Start dual antiplatelet therapy (aspirin + clopidogrel)

C. Emergent surgical evacuation (craniotomy or burr hole)

D. Stabilize the patient and schedule routine neurosurgical consultation

See Answer in Part B → Q5

@Neet_pg_bot

Q6: What medication can be administered to a patient who experiences altered consciousness, sweating, rapid heartbeat, persistent erection, and increased saliva production, with a blood pressure reading of 150/90 mm Hg after visiting a temple with their grandmother? (Q854658)

A. ASV

B. Adrenaline

C. Steroid

D. Prazosin

See Answer in Part B → Q6

@Neet_pg_bot

Q7: A patient was being treated in ICU for sepsis. The initial ABG shows pH= 6.9, pO 2 = 80 mm Hg. pCO 2 = 55 mmHg, HCO 3 = 10 meq/L. A repeat ABG after 2 hours shows pH=7.1, pCO 2 = 20 mmHg, pO 2 = 140 mm Hg, and HCO 3 = 10 meq/L. Which is most plausible to explain the change seen in the ABG report? (Q854662)

A. Excessive air and less heparin in the ABG sample

B. Excess air and more heparin in the ABG sample

C. Less air and more heparin in the ABG sample

D. Less air and less heparin in the ABG sample

See Answer in Part B → Q7

@Neet_pg_bot

Q8: Which of the following statements regarding the management of frostbite is incorrect? (Q855609)

A. Amputation in severe cases

B. Rewarming is done

C. Antibiotics and analgesics not used

D. The area is dried and cleaned

See Answer in Part B → Q8

@Neet_pg_bot

Q9: During a scorching summer afternoon, a man, who had been toiling in a field, unexpectedly collapsed. Upon examination, there were no apparent physical indications of dehydration, although his radial pulse was detectable. The doctor determined that the man's serum electrolyte levels were within the normal range. Shockingly, the man's body temperature measured 106 degrees Fahrenheit. Considering these circumstances, which of the following should be administered as an initial form of immediate assistance? (Q857001)

A. Inject epinephrine immediately

B. Cover with hot damp sheets

C. Cover with cool damp sheets

D. Start CPR

See Answer in Part B → Q9

@Neet_pg_bot

Q10: According to the ABCD2 scoring, which factors indicate a greater likelihood of a patient with TIA experiencing a future stroke? (Q856931)

A. Age <60 years

B. SBP>140 mm Hg and DBP <90 mmHg

C. Duration of TIA >5 mins

D. Diabetes

See Answer in Part B → Q10

@Neet_pg_bot

Q11: The recommended temperature of a water bath for a patient with frostbite is (Q858462)

A. 37 degree C

B. 42 degree C

C. 32 degree C

D. 30 degree C

See Answer in Part B → Q11

@Neet_pg_bot

Q12: All of the following is used in the management of breathless patients at a high altitude of 3000 mts except. (Q858463)

A. Intravenous digoxin

B. Oxygen supplementation

C. Immediate descent

D. Acetazolamide

See Answer in Part B → Q12

@Neet_pg_bot

Q13: A 47-year-old woman was brought to the casualty in an unconscious state after having suddenly collapsed. As there was no pulse, cardiopulmonary resuscitation was started and the monitor showed the following rhythm. What is the next step? (Q859792)

A. Defibrillation

B. Synchronized cardioversion

C. 1mg epinephrine

D. 0.5mg atropine



See Answer in Part B → Q13

@Neet_pg_bot

• [03_Endocrinology] 013 Diabetes Mellitus-I

« Back to Folder Directory

[03_Endocrinology] 013 Diabetes Mellitus-I — Quick Jump

Q1 (p. 217) *Q2 (p. 217)* *Q3 (p. 218)* *Q4 (p. 218)* *Q5 (p. 218)* *Q6 (p. 219)*
Q7 (p. 220) *Q8 (p. 220)* *Q9 (p. 220)* *Q10 (p. 221)* *Q11 (p. 221)* *Q12 (p. 222)*
Q13 (p. 222) *Q14 (p. 222)* *Q15 (p. 223)* *Q16 (p. 223)* *Q17 (p. 223)* *Q18 (p. 224)*
Q19 (p. 224)

Q1: You are a doctor in armed forces and are tasked with doing medical examination of new recruits. Your next candidate has a blood report that mentions a FBS of 116 mg/dl. Which of the following terms will you use to describe this blood report? (Q850583)

A. Impaired fasting glucose

B. Impaired glucose tolerance

C. Diabetes mellitus

D. Secondary diabetes

See Answer in Part B → Q1

@Neet_pg_bot

Q2: In type 1 DM, stage III of beta cell destruction presents as which of the following? (Q850609)

A. Autoimmune - , Symptomatic, Dysglycemia

B. ■■■■Autoimmune +, Symptomatic, Hyperglycemia

C. Autoimmune - , Asymptomatic, Normoglycemia

D. Autoimmune + , Asymptomatic, Normoglycemia

See Answer in Part B → Q2

@Neet_pg_bot

Q3: Which of the following insulin preparations need to given once a week? (Q850608)

A. Icodec

B. Glargine

C. Degludec

D. Determir

See Answer in Part B → Q3

@Neet_pg_bot

Q4: Which of the following dermatological diseases is most specific to a patient of diabetes mellitus with RBS of 220 mg/dl and RIA showing low fasting insulin levels? (Q850604)

A. Necrobiosis lipoidica diabeticorum

B. Acanthosis nigricans

C. Diabetic dermopathy

D. Intertriginous candidiasis

See Answer in Part B → Q4

@Neet_pg_bot

Q5: A 17-year-old male with thalassemia major presents with fatigue, hyperpigmented skin, and recently diagnosed diabetes mellitus. He has been receiving regular blood transfusions since early childhood. On examination, he has discoloration of the skin shown below, mild hepatomegaly, and lab reports show elevated serum ferritin and fasting blood glucose of 180 mg/dL.Which of the following should not be done in the initial management of this patient? (Q850597)

A. Start basal bolus insulin

B. Start iron chelation therapy

C. Phlebotomy

D. Monitor for cardiac iron overload with MRI T2



@Neet_pg_bot

See Answer in Part B → Q5

@Neet_pg_bot

Q6: Which of the following genetic factors is most strongly associated with an increased risk of developing Type 1 Diabetes Mellitus? (Q850595)

A. HLA-B27

B. HLA-DR3 DR4

C. HLA DR2

D. HLA DR 5

See Answer in Part B → Q6

@Neet_pg_bot

Q7: 25-year-old thin asymptomatic male is found to have fasting hyperglycemia during a routine checkup. His father and grandmother were diabetics.Genetic testing confirms a glucokinase mutation, consistent with MODY type 2. Which is correct management? (Q850593)

A. Start insulin

B. Start Metformin

C. Start semaglutide

D. No treatment required

See Answer in Part B → Q7

@Neet_pg_bot

Q8: Which of the following is most important intervention to reduce the progression of macrovascular complications of diabetes mellitus (Q850591)

A. Tight glycaemic control with HbA1c < 7%

B. Tight BP control and statins

C. Cessation of smoking

D. Limitation of sedentary activities

See Answer in Part B → Q8

@Neet_pg_bot

Q9: Which of the following is not a microvascular complication of diabetes mellitus? (Q850587)

A. Diabetic retinopathy

B. Diabetic neuropathy

C. Diabetic foot

D. Diabetic nephropathy

See Answer in Part B → Q9

@Neet_pg_bot

Q10: Which of the following is most important intervention for a newly diagnosed type 2 diabetes mellitus patient with HbA1c of 7%? (Q850586)

A. Hypocaloric diet

B. Carbohydrate counting

C. Light aerobic activity

D. Start cereals with low glycemic index

See Answer in Part B → Q10

@Neet_pg_bot

Q11: A 12-year-old girl presents with abdominal pain, vomitting and prostration for past one day. O/E: pulse:100/min, BP: 100/60 mm Hg and RR=20/min with a fruity-smelling breath. Work up shows plasma glucose level of 350 mg/dL and a positive urine ketone test. Which of the following is next step for managment of this patient? (Q850540)

A. Start regular insulin drip at 0.05–0.1 U/kg/hr

B. Give normal saline bolus

C. Perform ABG

D. Check serum electrolytes

See Answer in Part B → Q11

@Neet_pg_bot

Q12: A 50-year-old woman presents for a routine check-up. She has no family history of diabetes or hypertension. According to the American Diabetes Association (ADA) guidelines, what is the most appropriate screening recommendation for her? (Q850568)

A. No screening is necessary until age 60

B. Screen now and re-screen every 3 years if normal

C. Screen every year regardless of results

D. Screen only if symptoms of diabetes appear

See Answer in Part B → Q12

@Neet_pg_bot

Q13: Which of the following is best for monitoring of diabetes mellitus? (Q850566)

A. Continous glucose monitoring

B. HbA1c

C. Post prandial blood glucose

D. Self monitoring of blood glucose

See Answer in Part B → Q13

@Neet_pg_bot

Q14: Which of the following tests is the most appropriate for short-term monitoring of glycemic control in a diabetic patient ? (Q850563)

A. HbA1c

B. Fructosamine

C. Fasting Blood Glucose

D. Oral Glucose Tolerance Test (OGTT)

See Answer in Part B → Q14

@Neet_pg_bot

Q15: Glycosylated Hemoglobin is not reliable in diagnosis of which of the following types of diabetes mellitus? (Q850560)

A. Bronze diabetes

B. Type 1 Diabetes mellitus

C. Type 1.5 Diabetes mellitus

D. Type 2 Diabetes mellitus

See Answer in Part B → Q15

@Neet_pg_bot

Q16: Which of the following values is not used for diagnosis of diabetes mellitus? (Q850556)

A. Random Blood sugar of 250 mg/dl with classic symptoms

B. Post prandial value of 200 mg/dl

C. Fasting blood sugar of 140 mg/dl in an asymptomatic patient

D. HbA1c value of 7.8% in asymptomatic patient

See Answer in Part B → Q16

@Neet_pg_bot

Q17: Which of the following drugs is most likely to cause drug-induced diabetes by impairing insulin secretion from the pancreas? (Q850550)

A. Glucocorticoids

B. Thiazide diuretics

C. Phenytoin

D. β-lactam antibiotics

See Answer in Part B → Q17

@Neet_pg_bot

Q18: An 8-year-old boy is brought to ER with a 2-day history of vomiting, abdominal pain and prostration. On examination, he is drowsy, with sunken eyes, dry tongue, cold extremities, a thready pulse of 140/min, BP of 80/50 mmHg and RR =30/min. His RBS : 460 mg/dL, urine shows 4+ ketones and ABG shows pH= 7.2 , pC02 =20 mm Hg and HCO3 = 5 meq/L. What is the most appropriate next step in management? (Q850548)

A. Start IV insulin infusion at 0.1 U/kg/hr

B. Start normal saline with insulin drip

C. Give bolus of normal saline

D. Normal saline with insulin bolus followed insulin drip

See Answer in Part B → Q18

@Neet_pg_bot

Q19: Which of the following statements about Type 1.5 Diabetes Mellitus is incorrect? (Q850545)

A. Characterized by autoimmune destruction of beta cells

B. Start basal bolus insulin if C- peptide > 0.8 ng/ml

C. It is often misdiagnosed as Type 2 DM

D. Avoid use of sulfonlyureas

See Answer in Part B → Q19

@Neet_pg_bot

• [03_Endocrinology] 014 Diabetes Mellitus-Ii

« Back to Folder Directory

[03_Endocrinology] 014 Diabetes Mellitus-Ii — Quick Jump

Q1 (p. 226)	*Q2 (p. 226)*	*Q3 (p. 227)*	*Q4 (p. 227)*	*Q5 (p. 227)*	*Q6 (p. 228)*
Q7 (p. 228)	*Q8 (p. 228)*	*Q9 (p. 229)*	*Q10 (p. 229)*	*Q11 (p. 229)*	*Q12 (p. 230)*
Q13 (p. 230)	*Q14 (p. 231)*	*Q15 (p. 231)*	*Q16 (p. 232)*	*Q17 (p. 232)*	*Q18 (p. 232)*
Q19 (p. 233)					

Q1: A 22-year-old female with newly diagnosed Type 1 Diabetes Mellitus is struggling to maintain postprandial glucose levels despite basal-bolus insulin therapy. Her endocrinologist decides to add an adjunctive medication approved for both type 1 and type 2 diabetes mellitus. Which of the following drugs fits this indication? (Q850634)

A. Empagliflozin

B. Linagliptin

C. Pramlintide

D. Semaglutide

See Answer in Part B → Q1

@Neet_pg_bot

Q2: A 65-year-old woman with poorly controlled diabetes mellitus presents to the emergency department with fever, facial pain, and a black necrotic eschar on her nasal turbinates. A CT scan shows sinus involvement and extension to the brain. What is the most appropriate initial management for this patient? (Q850781)

A. Fluconazole

B. Immediate surgical debridement and intravenous amphotericin B

C. Doxycyline and Azithromycin

D. Piperacillin Tazobactum

See Answer in Part B → Q2

@Neet_pg_bot

Q3: A 55-year-old woman with a 10-year history of type 2 diabetes presents for a routine eye examination with compliants of visual loss. On examination, she is found to have microaneurysms, retinal haemorrhages, cotton wool spots and macular edema. What is the most effective management option for her symptomatic foveal oedema? (Q850780)

A. Pan-retinal laser photocoagulation

B. Intravitreal anti-VEGF injections

C. Corticosteroid injections

D. Routine observation and follow-up

See Answer in Part B → Q3

@Neet_pg_bot

Q4: Best screening test for evaluation of diabetic nephropathy is (Q850779)

A. HbA1c

B. BUN: Creatinine ratio

C. Creatinine clearance

D. Urinary protein to creatinine ratio

See Answer in Part B → Q4

@Neet_pg_bot

Q5: All of the following are correct about diabetic neuropathy except? (Q850778)

A. Affects unmyelinated type C fibers

B. Third nerve palsy presents with pupillary involvement

C. Orthostatic hypotension occurs due to involvement of type B fibers

D. Clonidine is used for management of diabetic diarrhea

See Answer in Part B → Q5

@Neet_pg_bot

Q6: Which of the following is not correct about Type 2 diabetes mellitus? (Q850776)

A. Polygenic inheritance

B. Increased insulin levels

C. Beta cell exhaustion

D. Increased PPAR-γ activity

See Answer in Part B → Q6

@Neet_pg_bot

Q7: Which of the following is correct about mechanism of action of Acarbose? (Q850774)

A. Increases insulin secretion from pancreatic beta cells

B. Inhibits α-glucosidase in intestinal brush border

C. Increases glucose uptake in peripheral tissues

D. Enhances insulin sensitivity in peripheral tissues

See Answer in Part B → Q7

@Neet_pg_bot

Q8: Which of the following is not correct about complications seen in Diabetes mellitus? (Q850640)

A. Blindness incidence is increased by 25 times

B. Foot gangrene and amputation risk is increased by 100 times

C. Most common site of diabetic foot ulcer is heel

D. Diabetic nephropathy is leading cause of Chronic kidney disease

See Answer in Part B → Q8

@Neet_pg_bot

Q9: Which of the following is not correct about SGLT2i (Q850638)

A. Lowering of SBP

B. Used in HFreEF in non diabetic population

C. Cause afferent arteriolar dilatation

D. Increased risk of mycotic genital infections

See Answer in Part B → Q9

@Neet_pg_bot

Q10: Which of the following is the earliest renal abnormality in diabetic nephropathy? (Q850636)

A. Microalbuminuria

B. Nodular glomerulosclerosis

C. Increased glomerular filtration rate

D. Proteinuria (>300 mg/day)

See Answer in Part B → Q10

@Neet_pg_bot

Q11: 50-year-old man with T2DM presents with consistently elevated early morning blood glucose levels. His continous glucose monitoring does not show any noctural hypoglycemia. His current insulin regimen includes twice-daily intermediate-acting insulin. Which of the following is the most likely explanation for his fasting hyperglycaemia? (Q850615)

A. Excess dose of insulin given the day before

B. Increased insulin sensitivity between 4 am to 8 am

C. Inreased insulin resistance between 4 am to 8 am

D. Beta cell exhausation

See Answer in Part B → Q11

@Neet_pg_bot

Q12: Which of the following drugs slows the progression of diabetic nephropathy and is an aldosterone antagonist? (Q850632)

A. Finrenone

B. Empagliflozin

C. Linagliptin

D. ACEi

See Answer in Part B → Q12

@Neet_pg_bot

Q13: A 52-year-old obese male with poorly controlled Type 2 Diabetes Mellitus is started on semaglutide. Which of the following statements is not true regarding this drug? (Q850629)

A. It acts via GLP-1 receptor agonism, enhancing glucose-dependent insulin secretion

B. It may cause abdominal pain and elevated serum amylase levels suggestive of pancreatitis

C. It can cause transient worsening of diabetic retinopathy, especially in patients with rapid glycemic improvement

D. It commonly causes fluid retention and weight gain due to PPAR-γ activation

See Answer in Part B → Q13

@Neet_pg_bot

Q14: A 50-year-old woman with Type 2 diabetes mellitus presents with extreme fatigue and thirst. She is non-compliant with her medications. Her blood pressure is 170/100 mmHg, and labs show: Random plasma glucose: 286 mg/dL HbA1c: 11.2% Urine glucose: +++ Serum creatinine: 2 mg/dL eGFR: 25 mL/min Serum potassium: 6.5 mEq/L Which of the following is NOT appropriate for managing this patient? (Q850628)

A. Monitor urine albumin creatinine ratio

B. Start Metformin with Sitagliptin

C. Start Amlodipine

D. Start Empagliflozin

See Answer in Part B → Q14

@Neet_pg_bot

Q15: You are educating a mother of 8-year-old girl with type 1 Diabetes Mellitus about insulin administration techniques. Which of the following statements is incorrect regarding insulin delivery? (Q850626)

A. The preferred site for subcutaneous insulin injection is the anterior abdominal wall.

B. Insulin pens should be held at a 90° angle to the skin for optimal delivery

C. Repeated insulin injections at the same site can cause lipohypertrophy

D. Repeat the insulin injection spot after 5-7 days

See Answer in Part B → Q15

@Neet_pg_bot

Q16: A 60-year-old diabetic patient collapsed in the bathroom in the morning and died. She was on metformin and glipizide for the last 10 years. Her latest HbA1c was 11%. What can be a possible cause of this event? (Q850623)

A. Autonomic neuropathy

B. Congestive chronic heart failure

C. Pericardial tamponade

D. Catastrophic CNS hemorrhage

See Answer in Part B → Q16

@Neet_pg_bot

Q17: A 55-year-old man with T2DM is brought to ER in unconcious state. Work up shows ABG pH=7.38, pCO2 40 mm Hg HCO3 = 26 meq/L, Sodium 140 meq/L , K =5.5 meq/L urine ketostix is negative, RBS : 150 mg/dl and serum lactate is normal. Which of the following is correct about next step in managment of this patient? (Q850621)

A. NCCT head

B. Normal saline followed by insulin drip

C. Administer 50% dextrose

D. Draw blood culture and start empirical antimicrobials

See Answer in Part B → Q17

@Neet_pg_bot

Q18: Which of the following drug will worsen cardiovascular mortality in a diabetic patient who underwent a CABG? (Q850618)

A. Semaglutide

B. Empagliflozin

C. Rosiglitazone

D. Tirzepatide

See Answer in Part B → Q18

@Neet_pg_bot

Q19: Which form of insulin is used for basal delivery in basal bolus regimen? (Q850617)

A. Lispro

B. N.P.H

C. Glargine

D. Glulisine

See Answer in Part B → Q19

@Neet_pg_bot

• [03_Endocrinology] 015 Dka And Hyperosmolar Coma Pancreatic Neuroendocrine Tumors

« Back to Folder Directory

[03_Endocrinology] 015 Dka And Hyperosmolar Coma Pancreatic Neuroendocrine Tumors — Quick Jump

Q1 (p. 234)	*Q2 (p. 234)*	*Q3 (p. 235)*	*Q4 (p. 235)*	*Q5 (p. 236)*	*Q6 (p. 236)*
Q7 (p. 236)	*Q8 (p. 237)*	*Q9 (p. 237)*	*Q10 (p. 238)*	*Q11 (p. 238)*	*Q12 (p. 239)*
Q13 (p. 239)	*Q14 (p. 240)*	*Q15 (p. 240)*	*Q16 (p. 241)*	*Q17 (p. 241)*	*Q18 (p. 242)*

Q1: A 45-year-old man comes with recurrent episodes of loss of consciousness, tremors, excessive sweating, and confusion. A tumour of the pancreas is suspected, and the serum proinsulin level (on a 72-hour fasting test) is raised. Which of the following investigations would be most preferred? (Q850664)

A. Computed tomography

B. MRI

C. Manual Palpation and Intraoperative Ultrasound

D. Endoscopic Ultrasound (EUS)

See Answer in Part B → Q1

@Neet_pg_bot

Q2: A 48-year-old woman presents with a 6-month history of recurrent diarrhoea, weight loss, and intermittent abdominal pain. She also reports flushing and has recently developed diabetes without prior risk factors. Examination shows steatorrhea and a mild erythematous rash. Blood tests reveal elevated fasting plasma glucose. A pancreatic somatostatinoma is suspected.Which of the following investigations is NOT routinely used in the initial diagnosis of this condition? (Q850691)

A. Measurement of fasting somatostatin levels

B. CT/MRI imaging

C. Somatostatin receptor imaging

D. Biopsy with immunohistochemistry

See Answer in Part B → Q2

@Neet_pg_bot

Q3: Assertion : In diabetic ketoacidosis (DKA), potassium levels can appear normal or even elevated initially despite a total body potassium deficiency. Reason : Potassium shifts from the intracellular to the extracellular space due to insulin deficiency and acidosis, temporarily raising serum potassium levels. (Q850688)

A. Both assertion and reason are correct, and the reason correctly explains the assertion.

B. Both assertion and reason are correct, but the reason does not correctly explain the assertion.

C. The assertion is correct, but the reason is incorrect.

D. The assertion is incorrect, but the reason is correct.

See Answer in Part B → Q3

@Neet_pg_bot

Q4: A 45-year-old male with type 1 diabetes presents with increased thirst, frequent urination, nausea, vomiting, and abdominal pain. On examination, he has dry mucous membranes, tachypnea, and a fruity odour to his breath. His blood pressure is 90/60 mmHg. Labs show blood glucose of 450 mg/dL, bicarbonate of 18 mEq/L, and pH of 7.28. Which of the following statements is FALSE? (Q850686)

A. Kussmaul breathing is deep, laboured, and rapid.

B. Fruity odour on the breath is caused by acetone.

C. Dehydration in DKA is associated with dry mucous membranes and poor capillary refill.

D. Fever is always present in DKA and indicates infection.

See Answer in Part B → Q4

@Neet_pg_bot

Q5: A 23-year-old male with Type 1 Diabetes Mellitus presents to the emergency department with nausea, vomiting, and abdominal pain. He reports that he has not taken his insulin for the past two days. On examination, he appears dehydrated, with deep and rapid breathing. Laboratory tests reveal high blood glucose, ketonemia, and metabolic acidosis. Which of the following statements about the pathophysiology of the patient's condition is TRUE? (Q850684)

A. Insulin deficiency leads to increased glucose utilization by the cells.

B. Elevated counterregulatory hormones increase glycogen synthesis, reducing blood glucose levels.

C. Lipolysis increases free fatty acids (FFA) in the liver, leading to ketogenesis.

D. Increased glucose utilization prevents hyperglycemia and osmotic diuresis.

See Answer in Part B → Q5

@Neet_pg_bot

Q6: A 35-year-old patient presents to the clinic with persistent diarrhoea, which has led to significant dehydration. After evaluation, it is determined that the diarrhoea is secretory. The patient has a history of diabetes, which is uncontrolled. Which of the following statements best describes the management and mechanisms associated with secretory diarrhoea in this patient? (Q850683)

A. Secretory diarrhoea primarily results from the malabsorption of nutrients

B. The main goal of management is reducing intestinal secretion

C. Antisecretory agents like Racecadotril and Crofelemer may help reduce fluid loss

D. Secretory diarrhoea shows a high osmotic gap that is not related to food intake

See Answer in Part B → Q6

@Neet_pg_bot

Q7: Which of the following toxin-producing bacteria does a VIPoma mimic? (Q850679)

A. Shigella dysenteriae

B. Vibrio cholerae

C. Corynebacterium diphtheriae

D. Bordetella pertussis

See Answer in Part B → Q7

@Neet_pg_bot

Q8: Identify the true statement about the condition where the patient presents with high plasma somatostatin levels, steatorrhea, hypochlorhydria, and diabetes mellitus due to a tumour. (Q850675)

A. The tumour primarily occurs in the stomach

B. This is usually a small tumour that often goes unnoticed

C. This is rarely associated with MEN 1 syndrome

D. Metastasis is rare and is treated using chemotherapy for localized disease

See Answer in Part B → Q8

@Neet_pg_bot

Q9: A 54-year-old female presents with significant weight loss and a characteristic rash as in the image. Blood tests reveal elevated plasma glucagon levels exceeding 1000 pg/mL. A CT scan shows a large mass in the tail of the pancreas. Which of the following statements regarding her condition is correct? (Q850667)

A. The mass is commonly found in the head of the pancreas

B. The initial treatment includes antibiotics and steroids

C. The rash seen is necrolytic migratory erythema

D. Surgical resection is the treatment option for this condition

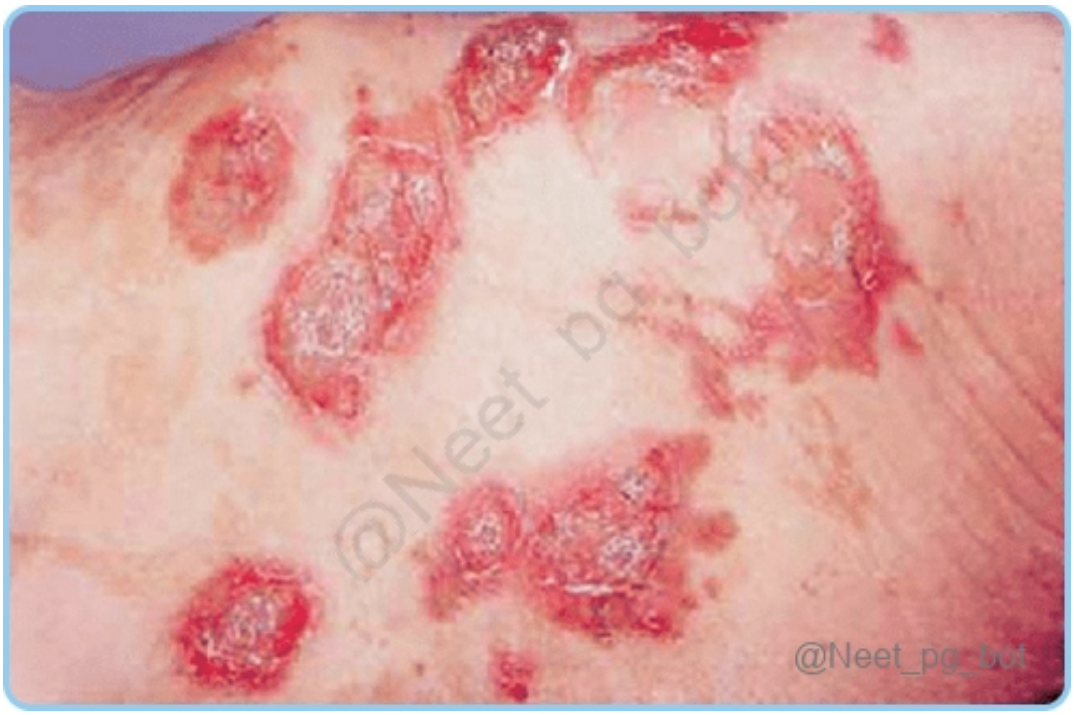

See Answer in Part B → Q9

@Neet_pg_bot

Q10: A 65-year-old female with type 2 diabetes on SGLT2 inhibitors is brought to the emergency department unconscious. Lab results show pH 7.2, $HCO3^{-}$ 15 mEq/L, RBS 210 mg/dl, and plasma beta-hydroxybutyrate 2.8 mmol/L with normal lactate. Urine analysis reveals the presence of ketones. What condition is most consistent with these findings? (Q850639)

A. Lactic Acidosis

B. Diabetic Ketoacidosis

C. Euglycemic Diabetic Ketoacidosis

D. Hyperglycemic Hyperosmolar State

See Answer in Part B → Q10

@Neet_pg_bot

Q11: A 40-year-old male comes to the clinic with recurrent episodes of hypoglycemia and loss of consciousness. On further evaluation, he is found to have a tumour on the pancreas. Which of the following is not a component of Whipple's triad to suspect insulinoma? (Q850662)

A. Symptoms of hypoglycemia

B. Low plasma glucose concentration

C. Subsequent improvement of symptoms with the use of glucose treatment

D. Elevated fasting insulin levels

See Answer in Part B → Q11

@Neet_pg_bot

Q12: A 45-year-old woman with diabetes presents to the emergency department with confusion, fatigue, dizziness, palpitations, sweating, and tremors. Her blood glucose is 48 mg/dL. Which of the following is least likely to cause hypoglycemia in this patient? (Q850658)

A. Insulin

B. Sulfonylureas

C. Metformin

D. Meglitinides

See Answer in Part B → Q12

@Neet_pg_bot

Q13: A 55-year-old man presents with persistent abdominal pain and unintentional weight loss over the past 3 months. He reports no significant past medical history and denies any changes in bowel habits. A CT scan of the abdomen reveals a well-circumscribed mass in the pancreas. Laboratory tests show elevated serum glucose levels but normal levels of other pancreatic hormones. Which of the following is the most likely diagnosis for this patient? (Q850654)

A. Insulinoma

B. Gastrinoma

C. Non-functioning pancreatic NET

D. Glucagonoma

See Answer in Part B → Q13

@Neet_pg_bot

Q14: A 75-year-old man with poorly controlled type 2 diabetes presents to the emergency department with confusion and increased thirst over the past week. On examination, he has dry mucous membranes, a weak pulse, and a blood pressure of 85/50 mmHg. Laboratory tests show: (Plasma glucose: 1000 mg/dL, Serum osmolality: 360 mOsm/kg, Serum sodium: 130 mEq/L, Arterial blood gas: pH 7.38, bicarbonate 18 mEq/L). Which of the following is the most appropriate initial treatment for this patient? (Q850653)

A. Administer IV Ringer Lactate

B. Administer IV 0.9% normal saline

C. Start IV insulin bolus of 1 unit/kg with IV Potassium

D. Administer oral hypoglycemic agents

See Answer in Part B → Q14

@Neet_pg_bot

Q15: A 70-year-old woman with type 2 diabetes is admitted for confusion and severe dehydration. Her blood glucose is 900 mg/dL, and serum osmolality is elevated. Arterial blood gas reveals a normal pH and bicarbonate. Which of the following clinical signs would NOT be expected in this patient? (Q850650)

A. Hypotension

B. Tachycardia

C. Kussmaul breathing

D. Fever

See Answer in Part B → Q15

@Neet_pg_bot

Q16: A 28-year-old female with type 1 diabetes presents to the emergency department with increased thirst, frequent urination, nausea, abdominal pain, and signs of dehydration, including dry mucous membranes, tachycardia, and hypotension (BP: 98/60 mmHg). On examination, her vital signs include a heart rate of 110 bpm, respiratory rate of 22 breaths/min, and a blood pressure of 98/60 mmHg. Laboratory results show a blood glucose level of 350 mg/dL, serum bicarbonate of 18 mEq/L, and a pH of 7.30. What is the next step in management based on the ISPAD 2022 guidelines? (Q850647)

A. Start intravenous fluids and initiate insulin therapy

B. Administer subcutaneous insulin and monitor glucose

C. Provide oral hydration and adjust the diet accordingly

D. Ensure airway patency and consider nasogastric tube insertion

See Answer in Part B → Q16

@Neet_pg_bot

Q17: A 28-year-old male presents with tachycardia, hypotension, and drowsiness. He has a sweet smell of acetone on his breath. Laboratory results show a random blood sugar of 400 mg/dL, serum bicarbonate level of 12 mEq/L, arterial pH of 7.1, and serum β-hydroxybutyrate level of 6 mmol/L. What diagnosis is most consistent with this patient's condition? (Q850644)

A. Mild Diabetic Ketoacidosis

B. Moderate Diabetic Ketoacidosis

C. Severe Diabetic Ketoacidosis

D. Hyperglycemic Hyperosmolar State

See Answer in Part B → Q17

@Neet_pg_bot

Q18: A 40-year-old male with poorly controlled type 1 diabetes presents with vomiting and shortness of breath. He appears dehydrated and tachycardic, with a fruity odour on his breath. His lab results show elevated blood glucose and ketones. Which of the following is not a risk factor for his condition? (Q850642)

A. Infection

B. Pancreatitis

C. Hypothyroidism

D. Inadequate insulin administration

See Answer in Part B → Q18

@Neet_pg_bot

• [03_Endocrinology] 016 Disorders Of Adrenal Gland And Cushing Syndrome - I

« Back to Folder Directory

[03_Endocrinology] 016 Disorders Of Adrenal Gland And Cushing Syndrome - I — Quick Jump

Q1 (p. 243)	*Q2 (p. 244)*	*Q3 (p. 244)*	*Q4 (p. 245)*	*Q5 (p. 245)*	*Q6 (p. 246)*
Q7 (p. 246)	*Q8 (p. 247)*	*Q9 (p. 247)*	*Q10 (p. 248)*	*Q11 (p. 248)*	*Q12 (p. 248)*
Q13 (p. 249)	*Q14 (p. 249)*	*Q15 (p. 249)*	*Q16 (p. 250)*	*Q17 (p. 250)*	*Q18 (p. 250)*
Q19 (p. 251)	*Q20 (p. 251)*	*Q21 (p. 252)*			

Q1: 16-year-old boy is brought to the ER due to fever, vomiting, and irritability for 2 days. Vitals are thready pulse 120/min, BP is 80/60 mm Hg with cold clammy extremities. General physical examination shows petechiae on extremities, CNS examination shows nuchal rigidity and kernig sign. CBC show TLC of 25000 cells/ cu.mm and platelet count of 15,000/cu.mm Gram stain of CSF is shown and rest of the lab report is awaited. Which of the following is not correct about managment of this patient? {{caption_text}} (Q850558)

A. Normal saline bolus

B. Hydrocortisone

C. Ceftriaxone and Vancomycin

D. Fludrocortisone

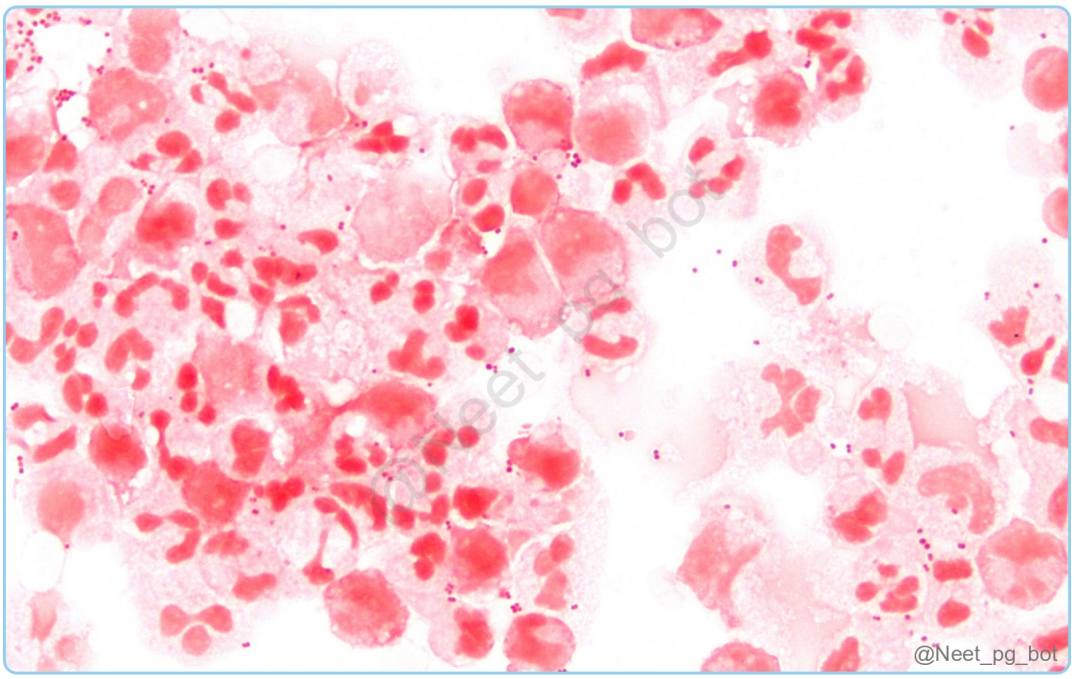

See Answer in Part B → Q1

@Neet_pg_bot

Q2: A 30-year-old male presents to the clinic with complaints of hyperpigmented skin, lethargy, and abdominal pain occasionally. His vitals are blood pressure of 158/90mmHg, heart rate of 102/min, and a temperature of 98 ° F (37 ° C). Keeping in view the suspicion of primary hyperaldosteronism, which of the following set of metabolic findings correlates with this diagnosis? (Q876269)

A. Hyperkalaemia, hyponatremia, and normal renin

B. Hyponatremia only

C. Hypernatremia, hypokalaemia, and low renin

D. Hypercalcemia only

See Answer in Part B → Q2

@Neet_pg_bot

Q3: 40-year-old woman diagnosed with cushing syndrome presents with headaches and increased skin pigmentation over the past few months. She underwent a bilateral adrenalectomy six months ago. Which of the following is false about her condition? (Q850612)

A. Rapid expansion of pituitary tumor

B. Low ACTH level

C. Prevented by prophylactic radiation therapy before adrenalectomy

D. Occurs due to lack of negative feedback

See Answer in Part B → Q3

@Neet_pg_bot

Q4: Which of the following is first investigation to be performed in patient with ACTH dependant cushing syndrome? (Q850606)

A. MRI Pituitary

B. High dose dexamethasone suppression test

C. Low dose dexamethasone suppression test

D. Inferior petrosal sinus sampling

See Answer in Part B → Q4

@Neet_pg_bot

Q5: Which of the following is not a clinical feature of Cushing syndrome? (Q850600)

A. Hypokalemia

B. Increased susceptibility to infections

C. Menorrhagia

D. Wasting of gluteal musculature

See Answer in Part B → Q5

@Neet_pg_bot

Q6: 50-year-old man presents with severe cough for 3 months and hemoptysis episodes for past 3 days. Physical examination shows hypertension, purple abdominal wall striae, changes in hands as shown. Endobronchial lung biopsy is shown below. Which of the following is the most likely cause in this patient? (Q850594)

A. Carcinoid tumor

B. Oat cell cancer of lung

C. Squamous cell cancer of lung

D. Large cell cancer of lung



See Answer in Part B → Q6

@Neet_pg_bot

Q7: 35 year old bollywood actor develops flushing episodes, asthma like symptoms and frequent episodes of watery diarrhea . 24 hour urinary 5 HIAA levels are elevated. Which of the following drugs will be suitable for managment of GI complaints of this patient? (Q850588)

A. Loperamide

B. Telotristat ethyl

C. Somatostatin analogues

D. Racecadotril

See Answer in Part B → Q7

@Neet_pg_bot

Q8: 30 year old patient with pheochromocytoma is undergoing surgery for tumor resection. Which drug should be prepared by anaesthesiologist as a standy infusion and will not cause post operative hypotension? (Q850585)

A. Labetalol

B. Phenoxybenzamine

C. Nitroprusside

D. Phentolamine

See Answer in Part B → Q8

@Neet_pg_bot

Q9: Which of the following is the most sensitive and specific diagnostic test for detecting pheochromocytoma? (Q850581)

A. Plasma free metanephrine

B. Plasma-fractionated metanephrine

C. 24 hr urinary total metanephrine

D. 24 hr urinary catecholamines

See Answer in Part B → Q9

@Neet_pg_bot

Q10: Which of the following drugs is used for managment of pre-operative hypertension in pheochromocytoma (Q850575)

A. Selective beta-blocker alone before surgery

B. Phenoxybenzamine + Phentolamine

C. Phenoxybenzamine + Propranolol

D. Propranolol and Phentolamine

See Answer in Part B → Q10

@Neet_pg_bot

Q11: Which of the following is imaging modality of choice for pheochromocytoma? (Q850567)

A. MRI abdomen

B. Gallium 68 dotatate PET/CT

C. MIBG scan

D. Somatostatin receptor Scinitgraphy

See Answer in Part B → Q11

@Neet_pg_bot

Q12: A 45-year-old woman presents with persistent hypertension, weight gain, and muscle weakness. Lab results reveal elevated cortisol levels and suppressed ACTH. Which of the following is the next best investigation for work up of this patient? (Q850525)

A. High dose dexamethasone suppresion test

B. Low dose dexamethasone suppression test

C. CT abdomen

D. MRI pituitary

See Answer in Part B → Q12

@Neet_pg_bot

Q13: Which of the following statements is incorrect regarding a patient with mineralocorticoid excess? (Q850552)

A. Excess aldosterone causes hypokalemic metabolic alkalosis

B. Serum sodium may remain normal despite total body sodium overload

C. Long-standing hypokalemia can lead to proximal muscle weakness

D. ACE inhibitors can falsely elevate aldosterone levels

See Answer in Part B → Q13

@Neet_pg_bot

Q14: Which of the following is not correct about primary addison disease? (Q850546)

A. Increased Serum creatinine

B. Orthostatic hypotension

C. Skin color changes to pale alabaster

D. Hyperkalemia

See Answer in Part B → Q14

@Neet_pg_bot

Q15: Which of the following is not a clinical feature of glucocorticoid deficiency (Q850543)

A. Hypoglycemia

B. Eosinopenia

C. Orthostatic hypotension

D. Hyponatremia

See Answer in Part B → Q15

@Neet_pg_bot

Q16: Which part of the nephron is affected in Gordon syndrome? (Q850541)

A. Distal convoluted tubule

B. Proximal nephron

C. Ascending limb of the loop of Henle

D. Descending limb of the loop of Henle

See Answer in Part B → Q16

@Neet_pg_bot

Q17: All of the following are clinical manifestations of Liddle’s syndrome except? (Q850537)

A. Hypokalemia

B. Hyporeninemia

C. Hypertension

D. Hyperaldosteronism

See Answer in Part B → Q17

@Neet_pg_bot

Q18: 45-year-old woman presents to the clinic with complaints of persistent high blood pressure despite medication and muscle weakness. On examination BP is

170/100 mmHg. Work up shows results pH= 7.46, serum potassium: 3.2 mEq/L, serum sodium: 142 mEq/L and increased aldosterone levels. CT abdomen shows adrenal mass size of 2cm. Which of the following test is used to confirm the diagnosis? (Q850535)

A. Plasma renin activity

B. Saline infusion test

C. ACTH stimulation test

D. Petrosal sinus sampling

See Answer in Part B → Q18

@Neet_pg_bot

Q19: 50-year-old hypertensive male presents with muscle weakness and frequent headaches. Work up shows hypokalemic metabolic alkalosis with low plasma aldosterone and low renin. Which of the following is the most likely diagnosis? (Q850531)

A. Liddle syndrome

B. Conn syndrome

C. Addison disease

D. Bilateral adrenal hyperplasia

See Answer in Part B → Q19

@Neet_pg_bot

Q20: 30 year old patient presents with hypertension and hypokalemic metabolic alkalosis. CT scan shows mass over the kidney of size 1.5 cm with elevated ARR. What is the next best step for management of this patient? (Q850528)

A. Spironolactone on life-long basis

B. Adrenalectomy

C. Adrenal venous sampling

D. Dexamethasone suppression test

See Answer in Part B → Q20

@Neet_pg_bot

Q21: A 35-year-old man presents with episodic headaches, palpitations, and excessive sweating. He is found to have labile hypertension and an adrenal mass on testing. Genetic testing confirms a ret proto-oncogene mutation, and ultrasound shows bilateral thyroid nodules. Which of the following is the major catecholamine produced by this tumor? (Q850527)

A. Epinephrine

B. Nor epinephrine

C. Dopamine

D. Metanephrine

See Answer in Part B → Q21

@Neet_pg_bot

• [03_Endocrinology] 017 Diseases Of Thyroid

« Back to Folder Directory

[03_Endocrinology] 017 Diseases Of Thyroid — Quick Jump

Q1 (p. 253)	*Q2 (p. 253)*	*Q3 (p. 254)*	*Q4 (p. 254)*	*Q5 (p. 255)*	*Q6 (p. 255)*
Q7 (p. 256)	*Q8 (p. 256)*	*Q9 (p. 256)*	*Q10 (p. 257)*	*Q11 (p. 257)*	*Q12 (p. 258)*
Q13 (p. 258)	*Q14 (p. 259)*	*Q15 (p. 259)*	*Q16 (p. 260)*	*Q17 (p. 260)*	*Q18 (p. 261)*
Q19 (p. 261)	*Q20 (p. 262)*	*Q21 (p. 262)*	*Q22 (p. 262)*	*Q23 (p. 263)*	*Q24 (p. 263)*
Q25 (p. 264)	*Q26 (p. 264)*	*Q27 (p. 265)*	*Q28 (p. 265)*	*Q29 (p. 266)*	*Q30 (p. 266)*
Q31 (p. 267)	*Q32 (p. 267)*	*Q33 (p. 268)*	*Q34 (p. 268)*	*Q35 (p. 268)*	*Q36 (p. 269)*

Q1: An elderly woman is brought to the emergency department with altered behavior after a week of poor oral intake. She has a known history of hypothyroidism and has been irregular with her medications. On examination, she is bradycardic and hypotensive. Arterial blood gas analysis reveals respiratory acidosis, and serum sodium levels are low. Which of the following findings is least likely to be present in this patient? (Q884031)

A. Hypoglycemia

B. Hyperthermia

C. Rhabdomyolysis

D. Hypercapnia

See Answer in Part B → Q1

@Neet_pg_bot

Q2: A 64-year-old woman from an iodine-deficient region has had a slowly progressive multinodular thyroid enlargement for 18 years. She was asymptomatic and euthyroid until recently. She now presents with palpitations, weight loss, and tremors. Investigations show: TSH - Suppressed Free T4 - Normal T3 - Disproportionately elevated Thyroid scintigraphy - Heterogeneous uptake with multiple hot and cold areas FNAC from different nodules shows mixed polyclonal and

monoclonal populations Which of the following represents the most important pathophysiological change responsible for her current disease state? (Q884023)

A. Development of autoimmune TSH-receptor antibodies

B. Emergence of nodules with functional autonomy

C. Progressive iodine deficiency causing diffuse hyperplasia

D. Malignant transformation of polyclonal nodules

See Answer in Part B → Q2

@Neet_pg_bot

Q3: A 32-year-old woman presents with a painless thyroid nodule. Ultrasound shows a hypoechoic solid lesion with microcalcifications and irregular margins. FNAC reveals nuclear grooves and intranuclear cytoplasmic inclusions. Which thyroid malignancy is most likely to account for the majority of thyroid cancers worldwide? (Q884024)

A. Follicular carcinoma

B. Papillary carcinoma

C. Medullary thyroid carcinoma

D. Anaplastic carcinoma

See Answer in Part B → Q3

@Neet_pg_bot

Q4: Which of the following is/ are recognised risk factors for thyroid carcinoma in a patient presenting with a thyroid nodule? History of head and neck irradiation during childhood Male gender Slowly enlarging, mobile thyroid nodule in a middle-aged woman Hoarseness of voice or vocal cord paralysis PET-avid thyroid nodule on 18-FDG imaging (Q884025)

A. 1, 2, 4 and 5

B. 1 and 4 only

C. 1, 3 and 4

D. Only 1

See Answer in Part B → Q4

@Neet_pg_bot

Q5: A 19-year-old woman is evaluated for persistent biochemical thyrotoxicosis detected during routine screening. She has mild tachycardia but no weight loss, tremor, or ophthalmopathy. Her mother and maternal uncle are known to have "high thyroid hormone levels" but have never required treatment. Investigations show: Free T4 - High Free T3 - High TSH - Normal Which of the following best explains this patient's condition? (Q884026)

A. Activating mutation of the TSH receptor

B. Impaired feedback due to thyroid hormone receptor-β mutation

C. Autonomous hyperfunctioning thyroid nodules

D. TSH-secreting pituitary adenoma

See Answer in Part B → Q5

@Neet_pg_bot

Q6: A 27-year-old woman presents with weight loss, tremors and palpitations for 2 months. She has no neck pain or fever. Examination shows no goiter or thyroid tenderness. Laboratory evaluation shows: TSH - Suppressed Free T4 - Elevated ESR - Normal Thyroid radionuclide uptake - Very low Serum thyroglobulin - Normal Which of the following is the most likely diagnosis? (Q884027)

A. Subacute granulomatous thyroiditis

B. Graves' disease

C. Thyrotoxicosis factitia

D. Toxic multinodular goitre

See Answer in Part B → Q6

@Neet_pg_bot

Q7: A 38-year-old woman presents with weight gain, constipation, and cold intolerance. Laboratory evaluation shows low free T4 with elevated TSH. Which of the following conditions is least likely to produce this biochemical pattern? (Q884028)

A. Postpartum autoimmune thyroiditis

B. Lithium-induced thyroid dysfunction

C. Sheehan syndrome

D. Chronic autoimmune thyroiditis

See Answer in Part B → Q7

@Neet_pg_bot

Q8: A 2-month-old infant presents with persistent constipation, poor feeding, prolonged jaundice and hypotonia. Examination reveals macroglossia and no palpable thyroid gland in the neck. Laboratory evaluation shows: TSH - markedly elevated Free T4 - very low Which of the following statements regarding this condition is true? (Q884029)

A. Most cases are caused by defects in thyroid hormone synthesis

B. High circulating T4 levels are required to normalize TSH in early life

C. The disorder is more common in males

D. Thyroid hormone replacement can be delayed until 1 year of age

See Answer in Part B → Q8

@Neet_pg_bot

Q9: A patient with autoimmune thyroid disease is suspected to have autoimmune polyendocrine syndrome type 2 (APS-2). Which of the following pairs of additional diseases, when present together with autoimmune thyroid disease, would confirm the diagnosis of APS-2? (Q884030)

A. Hypoparathyroidism + Chronic mucocutaneous candidiasis

B. Addison's disease + Type 1 diabetes mellitus

C. Pernicious anemia + Vitiligo

D. Celiac disease + Sjögren syndrome

See Answer in Part B → Q9

@Neet_pg_bot

Q10: A 61-year-old woman from an iodine-deficient region presents with a gradually enlarging neck mass for 16 years. She is clinically euthyroid. On raising both arms above her head, she develops facial flushing and venous congestion. Her CT scan shows substernal extension with mild tracheal narrowing. Thyroid ultrasound reveals multiple nodules of varying size. Which of the following statements regarding her condition is correct? (Q884022)

A. Most nodules represent monoclonal neoplastic transformation

B. Sudden onset of neck pain most commonly indicates malignant change

C. Radioiodine can reduce goitre volume by nearly half and ablate autonomous nodules

D. Thyroxine suppression therapy is the preferred long-term treatment

See Answer in Part B → Q10

@Neet_pg_bot

Q11: An elderly woman is brought to the emergency department in winter with progressive drowsiness for 2 days. On examination, she is hypothermic, bradycardic, hypotensive, and has non-pitting facial puffiness. She is hypoventilating. Laboratory evaluation reveals hyponatremia, hypoglycemia, and hypercapnia. What is the most

likely diagnosis? (Q884032)

A. Septic shock

B. Cardiogenic shock

C. Myxedema coma

D. Acute adrenal crisis

See Answer in Part B → Q11

@Neet_pg_bot

Q12: A 64-year-old man is admitted with severe community-acquired pneumonia requiring ICU care. He has no prior thyroid disease. Thyroid profile shows: Total T3 - Low Free T4 - Normal TSH - Normal Reverse T3 - Elevated What is the most appropriate interpretation of this thyroid profile? (Q884033)

A. Primary hypothyroidism

B. Secondary hypothyroidism

C. Sick euthyroid syndrome

D. Thyroid hormone resistance

See Answer in Part B → Q12

@Neet_pg_bot

Q13: A neonate is born with a large scalp defect as shown. The mother had been treated for hyperthyroidism during early pregnancy. Which of the following drugs is most likely responsible for this congenital anomaly? (Q884034)

A. Propylthiouracil

B. Methimazole

C. Radioactive iodine

D. Levothyroxine

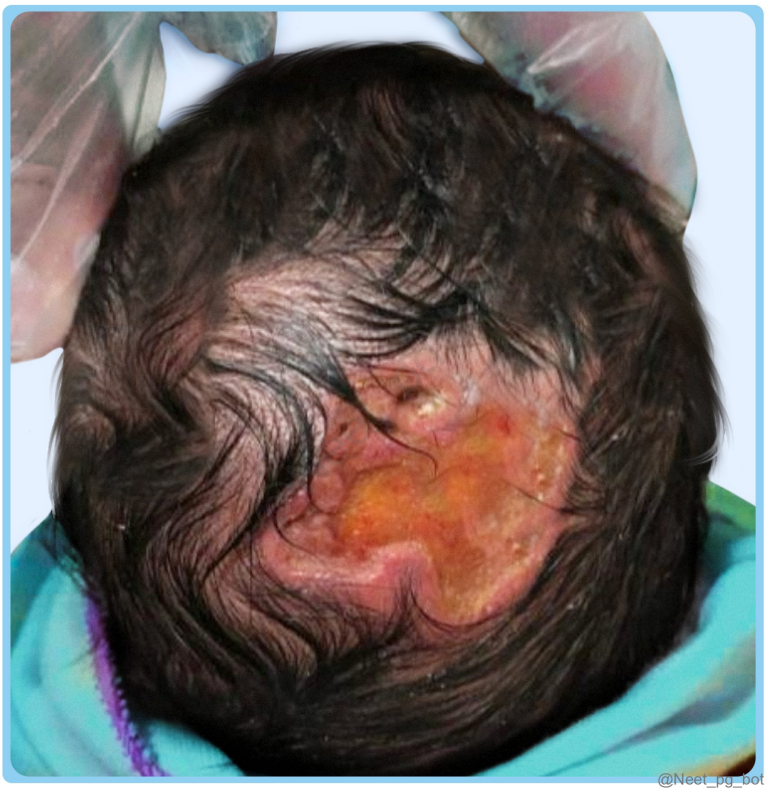

See Answer in Part B → Q13

@Neet_pg_bot

Q14: A 32-year-old woman with Graves' disease has persistent hyperthyroidism despite 12 months of carbimazole therapy. She is a smoker and has mild exophthalmos. She is not pregnant and is not breastfeeding. She wishes to conceive in the future. Which of the following is the most appropriate next step? (Q884035)

A. Radioiodine therapy without any additional medication

B. Radioiodine therapy with concurrent oral prednisone

C. Radioiodine therapy after immediate conception

D. Total thyroidectomy without further evaluation

See Answer in Part B → Q14

@Neet_pg_bot

Q15: A 25-year-old primigravida at 9 weeks of gestation presents with palpitations, tremors and excessive sweating. Thyroid function tests confirm hyperthyroidism. Which is the most appropriate initial drug of choice? (Q884036)

A. Methimazole

B. Carbimazole

C. Propylthiouracil

D. Propranolol

See Answer in Part B → Q15

@Neet_pg_bot

Q16: A 42-year-old woman presents with a slowly progressive anterior neck swelling for 4 years. She has no palpitations, tremor, weight loss, or menstrual irregularities. Examination reveals a soft, symmetrically enlarged, non-tender thyroid gland with no palpable nodules. Thyroid function tests are normal. Which of the following best explains the pathogenesis of her condition? (Q884037)

A. Activating mutation of the TSH receptor

B. Chronic iodine deficiency causing diffuse follicular hyperplasia

C. Autoimmune destruction of thyroid follicles

D. Somatic mutations causing monoclonal nodular proliferation

See Answer in Part B → Q16

@Neet_pg_bot

Q17: A 29-year-old woman with no prior thyroid illness presents with intermittent tremors and heat intolerance for 10 days. She delivered her second child 5 months ago. There is no neck pain, fever, or sore throat. Examination shows a small, soft, non-tender thyroid gland. Investigations reveal: TSH - Suppressed Free T4 - Elevated ESR - Normal Anti-TPO antibodies - Positive 99mTc-pertechnetate uptake - Suppressed Which of the following best describes the expected course of this illness?

(Q884038)

A. Progression to permanent thyrotoxicosis requiring radioiodine

B. Spontaneous resolution after a transient hypothyroid phase

C. Requirement of prolonged glucocorticoid therapy

D. Lifelong antithyroid drug therapy due to high relapse rate

See Answer in Part B → Q17

@Neet_pg_bot

Q18: A 29-year-old woman with known primary hypothyroidism is 11 weeks pregnant and is on regular levothyroxine therapy. She is clinically well. Which of the following is the recommended upper limit of serum TSH that should be maintained in her at this gestational age? (Q884039)

A. < 1.5 mIU/L

B. < 2.5 mIU/L

C. < 3.0 mIU/L

D. < 4.0 mIU/L

See Answer in Part B → Q18

@Neet_pg_bot

Q19: Which of the following is not a feature of hypothyroidism? (Q850927)

A. Pericardial efffusion

B. Pleural efffusion

C. Carpal tunnel syndrome

D. Diarrhea

See Answer in Part B → Q19

@Neet_pg_bot

Q20: Which of the following is the most appropriate preoperative management to prevent thyroid storm in a pateint of grave's disease who is scheduled for total thyroidectomy? (Q850785)

A. Start propranolol 7 days before and perform surgery once heart rate normalizes

B. Start methimazole and wait till acheiving euthyroid status

C. Start methimazole, potassium iodide, propranolol and wait till achieving euthyroid status

D. Take consent for high risk emergency surgery with careful intraoperative monitoing

See Answer in Part B → Q20

@Neet_pg_bot

Q21: A 45-year-old woman with a history of multinodular goitre undergoes a CT angiogram with iodinated contrast for suspected pulmonary embolism. Two weeks later, she presents with palpitations, heat intolerance, and weight loss. Her thyroid function tests show suppressed TSH and elevated T3 and T4. Which of the following best explains this patient's current condition? (Q850786)

A. Wolff-Chaikoff effect

B. Jod-Basedow effect

C. Thyroid storm

D. Hashitoxicosis

See Answer in Part B → Q21

@Neet_pg_bot

Q22: A 52-year-old woman presents with a 2-week history of palpitations, anxiety, and weight loss. On examination, her heart rate is 110 bpm and regular, and she has a painful goitre. Thyroid function tests show decreased TSH level and elevated free T3

& T4 levels. A thyroid scan shows very low uptake. Which of the following is the most likely diagnosis? (Q850787)

A. Graves' disease

B. Toxic multinodular goiter

C. Subacute thyroiditis

D. TSH-secreting pituitary adenoma

See Answer in Part B → Q22

@Neet_pg_bot

Q23: 35-year-old woman presents with a history of weight loss, palpitations and heat intolerance. On examination, she has a diffuse goitre, ophthalmopathy and fine tremors in her outstretched hands. Her thyroid function tests show: TSH: < 0.01 mIU/L (normal range: 0.4-4.0 mIU/L) Free T4: 35 pmol/L (normal range: 10-20 pmol/L) Free T3: 12 pmol/L (normal range: 3.5-6.5 pmol/L) Which of the following is the most likely cause of her hyperthyroidism? (Q850790)

A. Toxic multinodular goiter

B. Graves' disease

C. TSH-secreting pituitary adenoma

D. Jod Basedow effect

See Answer in Part B → Q23

@Neet_pg_bot

Q24: 50 year old patient was diagnosed with atrial fibrillation. Diagnostic work up showed high T4, high T3 and high TSH. Which of the following is next best investigation for this patient? (Q850795)

A. MRI Head

B. USG neck

C. TSH receptor antibody titer

D. Radioactive thyroid scan

See Answer in Part B → Q24

@Neet_pg_bot

Q25: On the Thyroid function test, TSH is suppressed, Free T4 level is normal, and Free T3 is increased. Which of the following is the most likely diagnosis? (Q850796)

A. Subclinical hyperthyroidism

B. Euthyroid sick syndrome

C. Primary Hyperthyroidism

D. T3 thyrotoxicosis

See Answer in Part B → Q25

@Neet_pg_bot

Q26: RAIU scan was performed for a 35 year old lady with hypertension and palpitations. Diagnosis is? (Q850925)

A. Toxic multinodular goiter

B. Graves' disease

C. Thyroiditis

D. Thyroid adenoma



See Answer in Part B → Q26

@Neet_pg_bot

Q27: A 32-year-old woman presents with palpitations, weight loss, and heat intolerance for the past 3 months. On examination, she has a diffuse goitre and mild proptosis. Thyroid function tests show suppressed TSH and elevated free T4 and T3. Which of the following is the most appropriate next step in management? (Q850926)

A. Radioiodine ablation

B. Total thyroidectomy

C. Start propranolol and carbimazole

D. MRI Brain

See Answer in Part B → Q27

@Neet_pg_bot

Q28: A 45-year-old woman presents with palpitations, vomiting, diarrhea and marked agitation following an abrupt discontinuation of her antithyroid medication following a UTI. On examination, she is diaphoretic with proptosis and diffuse neck swelling with prominent jugular pulsations . Vitals are pulse: 120/min, BP 160/100 mm Hg, RR 24/min Temp: 39 C. Which of the following is best drug for managment of this patient? (Q850784)

A. Saturated solution of potassium iodide

B. Propylthiouracil

C. Liothyronine

D. Propranolol

See Answer in Part B → Q28

@Neet_pg_bot

Q29: Which of the following is correct description of myxedema seen in patients with hypothyroidism? (Q850928)

A. Increased dermal collagen deposition

B. Accumulation of dermal glycosaminoglycans

C. Dermal saponification of fat

D. Dermal fibrosis

See Answer in Part B → Q29

@Neet_pg_bot

Q30: A 45-year-old woman comes with complaints of extensive hair loss, menorrhagia and weight gain. Work up shows elevated TSH , low T3, low T4 levels and anti TPO antibody present status. She has no known cardiovascular disease. Which of the following is the most appropriate next step regarding this patient? (Q850929)

A. Start levothyroxine 25 µg daily

B. Start levothyroxine 100 µg daily

C. Start liothyronine (T3) 5 µg three times daily

D. Observe and repeat thyroid function tests in 3 months

See Answer in Part B → Q30

@Neet_pg_bot

Q31: A known case of autoimmune thyroiditis presents with confusion and seizures. EEG shows generalized slowing without epileptiform discharges. Vitals are pulse 60/min. BP 120/100 mm Hg and temp 37.2 C. Work up shows High TSH, low T4, low T3, blood counts and CRP is normal. Which of the following is correct about diagnosis and management? (Q851050)

A. Hashimoto's encephalopathy and Hydrocortisone

B. Myxedema coma and iv Liothyronine

C. Myxedema coma and iv Levothyroxine

D. Thyroid storm and NG tube Propylthiouracil

See Answer in Part B → Q31

@Neet_pg_bot

Q32: Most common cardiovascular finding in case of young female with Grave's disease is? (Q851051)

A. Sinus Tachycardia

B. Atrial fibrillation

C. Ejection systolic murmur

D. Widened pulse pressure

See Answer in Part B → Q32

@Neet_pg_bot

Q33: Which of the following is not correct about Grave's associated ophthalmopathy? (Q851052)

A. Occurs in the absence of hyperthyroidism in 10% of patients

B. Earliest manifestation is proptosis and diplopia

C. Can cause loss of vision and papilledema

D. Lid lag can occur in causes other than grave' disease

See Answer in Part B → Q33

@Neet_pg_bot

Q34: In a patient with suspected hyperthyroidism, what is the initial screening test to be considered? (Q851053)

A. TSH and free T4

B. TSH and unbound T3

C. TSH and ultrasound neck

D. TSH and RAIU

See Answer in Part B → Q34

@Neet_pg_bot

Q35: A 68-year-old man with ischemic cardiomyopathy has been on amiodarone for 1 year. Routine screening reveals: TSH: 9.4 mIU/L (↑) Free T4: Low-normal Free T3: Normal He has no neck pain or thyroid tenderness. Which of the following thyroid disorders is least likely to be related to amiodarone therapy? (Q884019)

A. Failure to escape from the Wolff-Chaikoff effect

B. Iodine-induced hyperthyroidism due to autonomous nodules

C. Destructive thyroiditis-like thyrotoxicosis

D. Painless autoimmune thyroiditis (silent/postpartum)

See Answer in Part B → Q35

@Neet_pg_bot

Q36: A 61-year-old man with long-standing multinodular goitre has been on amiodarone for ventricular arrhythmia for the past 9 months. He presents with palpitations, weight loss and tremors. Thyroid function tests show suppressed TSH with elevated free T4 and T3. Colour Doppler ultrasound of the thyroid shows markedly increased vascularity. Which of the following statements is correct regarding his condition? (Q884020)

A. Thyrotoxicosis is due to drug-induced lysosomal destruction of thyroid follicles

B. Radioiodine uptake is typically very low due to follicular cell destruction

C. It results from iodine-induced autonomous hormone synthesis

D. First-line therapy is systemic glucocorticoids

See Answer in Part B → Q36

@Neet_pg_bot

• [03_Endocrinology] 018 Disorders Of Parathyroid Gland And Men Syndromes

« Back to Folder Directory

[03_Endocrinology] 018 Disorders Of Parathyroid Gland And Men Syndromes — Quick Jump

Q1 (p. 270)	*Q2 (p. 270)*	*Q3 (p. 271)*	*Q4 (p. 272)*	*Q5 (p. 272)*	*Q6 (p. 272)*
Q7 (p. 273)	*Q8 (p. 273)*	*Q9 (p. 273)*	*Q10 (p. 274)*	*Q11 (p. 275)*	*Q12 (p. 276)*
Q13 (p. 276)	*Q14 (p. 277)*	*Q15 (p. 277)*	*Q16 (p. 278)*	*Q17 (p. 278)*	*Q18 (p. 278)*
Q19 (p. 279)	*Q20 (p. 279)*	*Q21 (p. 280)*	*Q22 (p. 280)*	*Q23 (p. 282)*	*Q24 (p. 282)*
Q25 (p. 282)	*Q26 (p. 283)*	*Q27 (p. 283)*	*Q28 (p. 284)*	*Q29 (p. 285)*	*Q30 (p. 285)*
Q31 (p. 285)	*Q32 (p. 286)*				

Q1: A 64 y/o man presents with 1 week of confusion, lethargy, constipation, and polydipsia. He also has unintentional weight loss. Examination shows cachexia. Laboratory investigations: Serum calcium: 16.8 mg/dL, Serum albumin: 3.8 g/dL, Serum phosphorus: 2.1 mg/dL If this patient had metabolic alkalosis and a history of consuming large quantities of over-the-counter heartburn relief tablets, which of the following would be the most likely diagnosis? (Q890423)

A. Primary hyperparathyroidism

B. Familial hypocalciuric hypercalcemia

C. Milk-alkali syndrome

D. Vitamin D intoxication

See Answer in Part B → Q1

@Neet_pg_bot

Q2: Which of the following interventions is the initial therapy for a patient with severe, acute symptomatic hypocalcemia with tetany, laryngeal spasm, and seizures? (Q890445)

A. Oral calcium carbonate

B. Intravenous calcium infusion

C. Subcutaneous teriparatide

D. Intravenous bisphosphonates

See Answer in Part B → Q2

@Neet_pg_bot

Q3: A physician taps the patient's face just anterior to the ear lobe, below the zygomatic arch. This produces the following characteristic finding. This physical sign is associated with which of the following electrolyte abnormalities? (Q890444)

A. Hypercalcemia

B. Hypocalcemia

C. Hypermagnesemia

D. Hypokalemia



See Answer in Part B → Q3

@Neet_pg_bot

Q4: Which of the following ECG changes is characteristically associated with significant hypocalcemia? (Q890443)

A. Shortened QT interval

B. Prolonged QT interval

C. Prominent U waves

D. Peaked T waves

See Answer in Part B → Q4

@Neet_pg_bot

Q5: Which of the following is characteristic of a patient diagnosed with pseudopseudohypoparathyroidism (PPHP)? (Q890442)

A. Hypocalcemia, hyperphosphatemia, elevated PTH

B. Hypocalcemia, hypophosphatemia, elevated PTH

C. Hypercalcemia, hypophosphatemia, suppressed PTH

D. Normal calcium, normal phosphate, normal PTH

See Answer in Part B → Q5

@Neet_pg_bot

Q6: Which of the following disorders is characterised by hypocalcemia with hyperphosphatemia in the absence of renal failure? (Q890440)

A. Vitamin D deficiency

B. Pseudohypoparathyroidism

C. Hungry bone syndrome

D. Malabsorption syndrome

See Answer in Part B → Q6

@Neet_pg_bot

Q7: A 68 y/o woman with chronic kidney disease presents with progressive confusion, lethargy, polyuria, and polydipsia. Examination shows severe dehydration. Laboratory results reveal: Serum calcium: 16.2 mg/dL, BUN: 52 mg/dL, Creatinine: 2.4 mg/dL. Which of the following is the most appropriate initial step in management? (Q890439)

A. Intravenous zoledronic acid

B. Intravenous hydration with normal saline

C. Intravenous furosemide

D. Subcutaneous calcitonin

See Answer in Part B → Q7

@Neet_pg_bot

Q8: Which of the following is the treatment of hypercalcemia caused by vitamin D intoxication, often leading to normalisation of serum calcium over several days? (Q890437)

A. Thiazide diuretics

B. Glucocorticoids

C. Lithium

D. Calcimimetics

See Answer in Part B → Q8

@Neet_pg_bot

Q9: The hand X-ray shown is most characteristic of which condition? (Q890435)

A. Rheumatoid arthritis

B. Acromegaly

C. Hyperparathyroidism

D. Osteoarthritis



See Answer in Part B → Q9

@Neet_pg_bot

Q10: A 65 y/o man with untreated primary hyperparathyroidism presents with severe pain in his right thigh. An X-ray is as follows. Based on the described condition, which of the following histologic findings is most characteristic of this lesion? (Q890432)

A. Mosaic pattern of lamellar bone with cement lines

B. Replacement of marrow elements by fibrous tissue and giant multinucleated osteoclasts

C. Accumulation of unmineralized osteoid matrix

D. Malignant proliferation of plasma cells

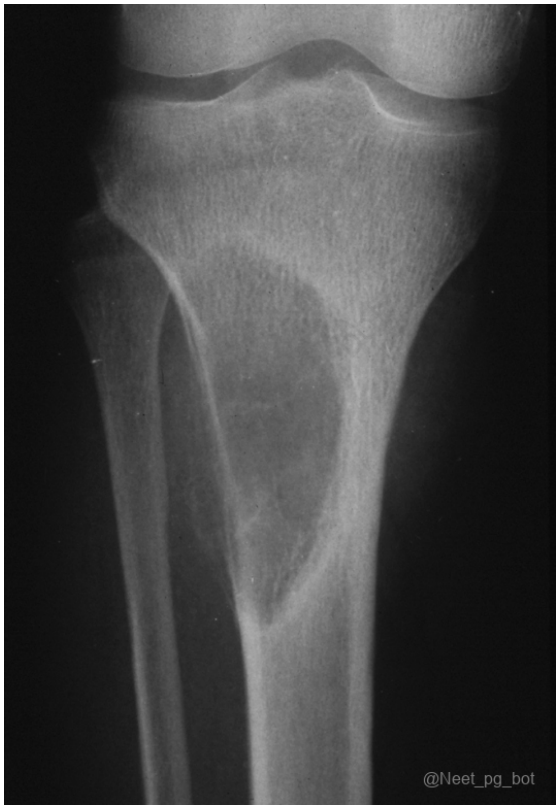

See Answer in Part B → Q10

@Neet_pg_bot

Q11: A patient presents with bone pain and an elevated alkaline phosphatase. A radiograph of the lumbar spine shows enlargement of a vertebral body with marked cortical thickening of the superior and inferior end plates, producing a "picture-frame" appearance. Which of the following is the most likely diagnosis? (Q890431)

A. Primary hyperparathyroidism

B. Paget's disease of bone

C. Fibrous dysplasia

D. Osteomalacia

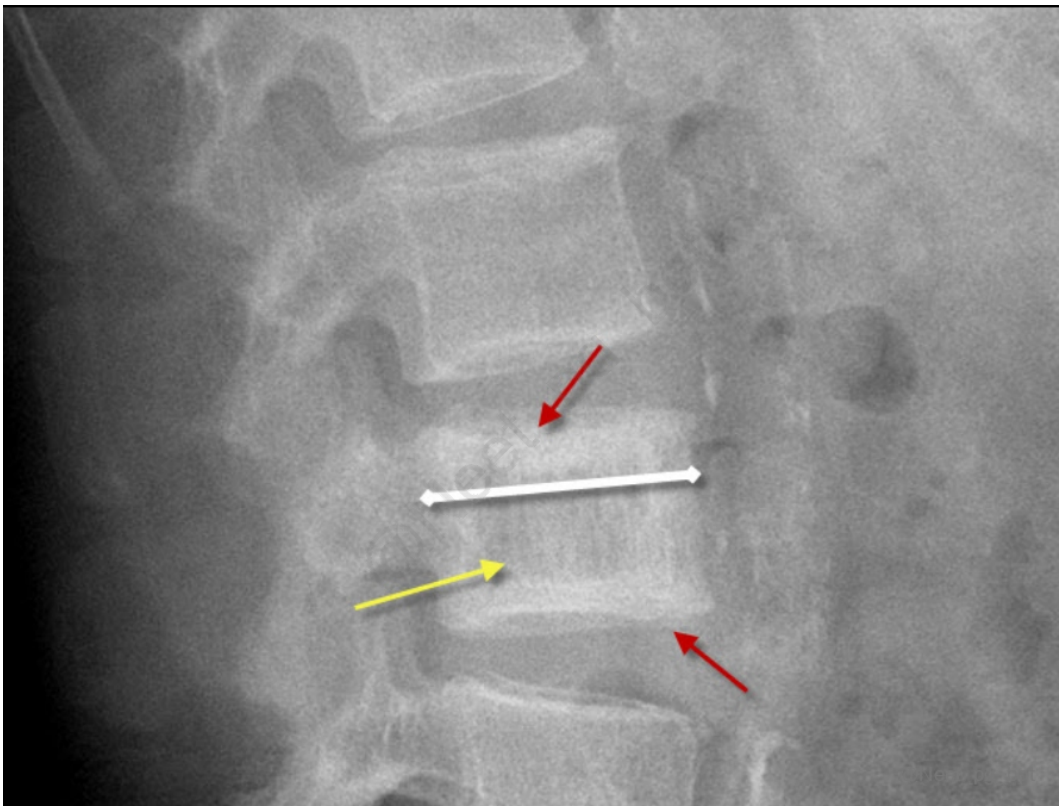

See Answer in Part B → Q11

@Neet_pg_bot

Q12: In differentiating Familial Hypocalciuric Hypercalcemia (FHH) from primary hyperparathyroidism, which of the following urinary biochemical findings most strongly supports a diagnosis of FHH? (Q890430)

A. 24-hour urinary calcium >300 mg

B. Calcium-to-creatinine clearance ratio (CCCR) >0.02

C. Calcium-to-creatinine clearance ratio (CCCR) <0.01

D. Frank hematuria

See Answer in Part B → Q12

@Neet_pg_bot

Q13: Which of the following biochemical patterns is most characteristic of primary hyperparathyroidism? (Q890429)

A. Low calcium, high phosphate, high PTH

B. High calcium, low phosphate, high PTH

C. High calcium, high phosphate, low PTH

D. Low calcium, low phosphate, low PTH

See Answer in Part B → Q13

@Neet_pg_bot

Q14: Which of the following findings represents the most common underlying cause of primary hyperparathyroidism? (Q890428)

A. Parathyroid carcinoma

B. Diffuse hyperplasia of all four parathyroid glands

C. Solitary parathyroid adenoma

D. Multiple parathyroid adenomas

See Answer in Part B → Q14

@Neet_pg_bot

Q15: Which of the following conditions causes hypercalcemia primarily due to increased bone turnover, in which bone resorption exceeds bone formation? (Q890426)

A. Milk-alkali syndrome

B. Vitamin D intoxication

C. Hyperthyroidism

D. Sarcoidosis

See Answer in Part B → Q15

@Neet_pg_bot

Q16: Which of the following gastrointestinal symptoms is most commonly associated with hypercalcemia? (Q890424)

A. Diarrhoea

B. Hyperactive bowel sounds

C. Constipation

D. Hematochezia

See Answer in Part B → Q16

@Neet_pg_bot

Q17: A 65-year-old patient presents with constipation, abdominal pain, nausea, vomiting, confusion, and bone pain. Laboratory tests reveal elevated calcium levels. Considering the role of the calcium-sensing receptor (CaSR) in calcium homeostasis, which of the following is regulated by CaSR? (Q850696)

A. PTH

B. FGF-23

C. Vitamin D3

D. Calcitonin

See Answer in Part B → Q17

@Neet_pg_bot

Q18: A 28-year-old woman presents with complaints of irregular menstrual cycles and infertility & reports increased headaches and visual changes over the past few months. An MRI reveals a large pituitary tumor. Family history is significant for several

relatives with breast and thyroid cancers. Which syndrome is most likely associated with her condition? (Q850741)

A. McCune-Albright Syndrome

B. Von Hippel-Lindau (VHL) Disease

C. Cowden Syndrome

D. Carney Complex

See Answer in Part B → Q18

@Neet_pg_bot

Q19: 40-year-old man presents with salt wasting, salt craving and postural hypotension. He has a family history of autoimmune disorders. Laboratory tests reveal elevated blood glucose levels and positive autoantibodies. Autoimmune Polyendocrine Syndrome is suspected. Which of the following statements regarding the diagnosis is not true? (Q850736)

A. Associated with Addison disease

B. Associated with Autoimmune thyroiditis

C. Associated with Celiac disease

D. Associated with Hypoparathyroidism

See Answer in Part B → Q19

@Neet_pg_bot

Q20: A 35-year-old man presents with recurrent kidney stones, abdominal pain, and peptic ulcers. His blood pressure is elevated, and he has a family history of thyroid carcinoma. Laboratory tests reveal high serum calcium and parathyroid hormone levels. What is the most likely diagnosis? (Q850735)

A. MEN Type 1

B. MEN Type 4

C. MEN Type 2B

D. MEN Type 2A

See Answer in Part B → Q20

@Neet_pg_bot

Q21: A 3-year-old boy with growth delays and leg bowing has not improved after six months of vitamin D treatment. Labs show low calcium, low phosphate, and elevated alkaline phosphatase. Genetic testing indicates a Vitamin D gene mutation. What is the best management option? (Q850733)

A. Increase in vitamin D dosage

B. Initiate phosphate supplementation

C. Administer Calcium

D. Administer Calcitriol

See Answer in Part B → Q21

@Neet_pg_bot

Q22: A 6-year-old boy presents with a history of recurrent fractures and pain in his lower limbs.He has a history of poor dietary intake, particularly low dairy consumption. Clinical examination leads to the findings similar to the images given below. Based on these observations, which of the following lab findings would be most consistent with his condition? (Q850731)

A. Low Parathyroid hormone, High Calcium

B. Low Calcium, High Phosphate

C. High Calcium, Low Phosphate

D. High Parathyroid hormone, Low Calcium

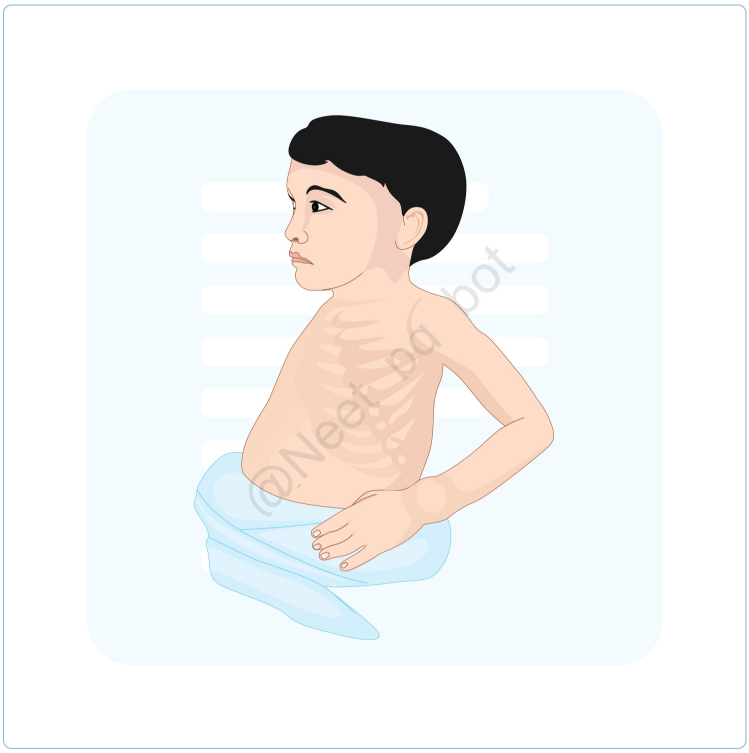

@Neet_pg_bot



@Neet_pg_bot

See Answer in Part B → Q22

@Neet_pg_bot

Q23: A 65-year-old woman with a history of chronic kidney disease secondary to hypertension presents with symptoms of nausea, vomiting, and confusion. On Investigating her Lab values are Serum calcium: 12.0 mg/dL (normal range: 8.5-10.5 mg/dL) Serum phosphate: 4.9 mg/dL (normal range: 2.5-4.5 mg/dL) Serum PTH: 200 pg/mL (normal range: 10-65 pg/mL) Which of the following is the most likely diagnosis of this patient? (Q850729)

A. Primary Hyperparathyroidism

B. Secondary Hyperparathyroidism

C. Pseudohypoparathyroidism

D. Tertiary Hyperparathyroidism

See Answer in Part B → Q23

@Neet_pg_bot

Q24: An 8-year-old boy presents with characteristic skeletal and developmental defects, such as short stature and shortened 4th and 5th metacarpals. Laboratory findings show elevated PTH levels, hypocalcemia, and hyperphosphatemia. Genetic testing reveals a deficiency in the Gsα subunit. Based on these findings, what is the most likely diagnosis? (Q850727)

A. Pseudopseudohypoparathyroidism (PPHP)

B. Pseudohypoparathyroidism type 1a (PHP1A)

C. Pseudohypoparathyroidism type 1b (PHP1B)

D. Hypoparathyroidism

See Answer in Part B → Q24

@Neet_pg_bot

Q25: A 45-year-old adult patient presents with symptoms of chronic hypocalcemia. Which of the following features is associated with this condition? (Q850723)

A. Extrapyramidal symptoms like dystonia

B. Tissue deposition of calcium due to hyperphosphatemia

C. Skin infections such as candidiasis

D. All of the above

See Answer in Part B → Q25

@Neet_pg_bot

Q26: A 65-year-old woman with primary hyperparathyroidism presents with nausea, vomiting, confusion, and dehydration. She shows signs of hypovolemia and altered mental status. Labs reveal high serum calcium, low phosphate, and elevated PTH. What is the first line of treatment? (Q850720)

A. Intravenous Bisphosphonates

B. Aggressive hydration with normal saline

C. Peritoneal dialysis

D. Calcitonin nasal spray

See Answer in Part B → Q26

@Neet_pg_bot

Q27: A 52-year-old man diagnosed with hypoparathyroidism six months ago after neck surgery presents with tingling in his hands and feet, muscle cramps, and fatigue. His lab results indicate low serum calcium, elevated phosphate, and severely low parathyroid hormone (PTH) levels. What is the most appropriate treatment for his condition? (Q850717)

A. Initiate intravenous calcium gluconate therapy

B. Administration of Alendronate

C. Administration of Teriparatide

D. Start oral calcium and Vitamin D supplement

See Answer in Part B → Q27

@Neet_pg_bot

Q28: A 45-year-old woman undergoes total thyroidectomy for a large goiter. Two days post-surgery, investigations reveal low serum calcium and low parathyroid hormone (PTH) levels. During clinical examination, the following observation is made. What is this sign known as ? (Q850712)

A. Trousseau sign

B. Chvostek sign

C. Hoffman's sign

D. Brudzinski's sign



See Answer in Part B → Q28

@Neet_pg_bot

Q29: A 45-year-old woman presents to the emergency department with muscle cramps, tingling in her fingers, and a tight sensation around her mouth. She has a history of thyroid surgery for papillary carcinoma. Examination revealed increased neuromuscular excitability. Lab results show low PTH, low calcium, and elevated phosphate levels. Which syndrome is most likely associated with this presentation? (Q850707)

A. Cushing's syndrome

B. McCune-Albright Syndrome

C. Turner syndrome

D. DiGeorge syndrome

See Answer in Part B → Q29

@Neet_pg_bot

Q30: A 58-year-old man with chronic kidney disease (CKD) returns for a follow-up, reporting fatigue, bone pain, and muscle weakness. Examination reveals bone tenderness, and lab tests show elevated parathyroid hormone (PTH) levels. Which of the following findings is not typically associated with this condition? (Q850704)

A. Elevated serum calcium levels

B. Raised serum alkaline phosphatase levels

C. Elevated serum phosphate levels

D. Raised urinary albumin creatinine ratio

See Answer in Part B → Q30

@Neet_pg_bot

Q31: A 39-year-old woman presents with persistent constipation, abdominal pain, and intermittent lower back pain. She has a history of recurrent kidney stones and reports fatigue. Lab tests reveal elevated calcium and decreased phosphate levels. She has been advised to undergo a sestamibi Tc-99 scan. Which of the following is not an indication for surgery in this condition? (Q850700)

A. Nephrolithiasis

B. Renal impairment

C. Age >50 years

D. Osteoporosis

See Answer in Part B → Q31

@Neet_pg_bot

Q32: A 60-year-old female presents with complaints of abdominal pain, constipation, and recent episodes of confusion and depression. Laboratory tests reveal elevated serum calcium and alkaline phosphatase (SAP) levels and decreased phosphate levels. Which of the following clinical features is not typically associated with this condition? (Q850698)

A. Recurrent nephrolithiasis

B. Osteitis fibrosa cystica

C. Tetany

D. Urinary tract infection

See Answer in Part B → Q32

@Neet_pg_bot

• [03_Endocrinology] 019 Diseases Of Anterior Pituitary

« Back to Folder Directory

[03_Endocrinology] 019 Diseases Of Anterior Pituitary — Quick Jump

Q1 (p. 287)	*Q2 (p. 287)*	*Q3 (p. 288)*	*Q4 (p. 288)*	*Q5 (p. 289)*	*Q6 (p. 289)*
Q7 (p. 290)	*Q8 (p. 290)*	*Q9 (p. 291)*	*Q10 (p. 291)*	*Q11 (p. 291)*	*Q12 (p. 292)*
Q13 (p. 292)	*Q14 (p. 293)*	*Q15 (p. 293)*	*Q16 (p. 293)*	*Q17 (p. 294)*	*Q18 (p. 294)*
Q19 (p. 295)	*Q20 (p. 295)*	*Q21 (p. 296)*	*Q22 (p. 296)*	*Q23 (p. 296)*	*Q24 (p. 297)*
Q25 (p. 298)	*Q26 (p. 298)*	*Q27 (p. 299)*	*Q28 (p. 299)*	*Q29 (p. 300)*	*Q30 (p. 301)*

Q1: Which of the following is the sequence of hormonal supplementation in a patient of Panhypopituitarism (Q850924)

A. Glucocorticoids → Thyroid hormones → Growth hormone → Sex hormones

B. Glucocorticoid → thyroid hormone → Sex hormones → Growth hormone

C. Thyroid hormones → Sex hormones → Glucocorticoids → Growth hormone

D. Sex hormones → Growth hormone → Glucocorticoids → Thyroid hormones

See Answer in Part B → Q1

@Neet_pg_bot

Q2: A 38-year-old woman with a known pituitary adenoma presents with a sudden onset of severe headache, vomiting and rapidly progressive visual loss. MRI brain suggests an acute haemorrhage within the pituitary gland. Which of the following conditions is not associated with increased risk of developing this emergency? (Q890236)

A. Acute hypovolemic shock

B. Sickle cell anaemia

C. Poorly controlled diabetes mellitus

D. Graves’ disease

See Answer in Part B → Q2

@Neet_pg_bot

Q3: A 14-year-old boy presents with progressive headache, vomiting, declining school performance and polyuria. MRI brain reveals the following finding. Which of the following statements about this lesion is most accurate? (Q890235)

A. In the papillary variant, calcifications are commonly seen

B. In the adamantinomatous variant, calcifications are rare

C. Complete surgical excision is usually curative

D. Biopsy shows cholesterol crystals within the cyst

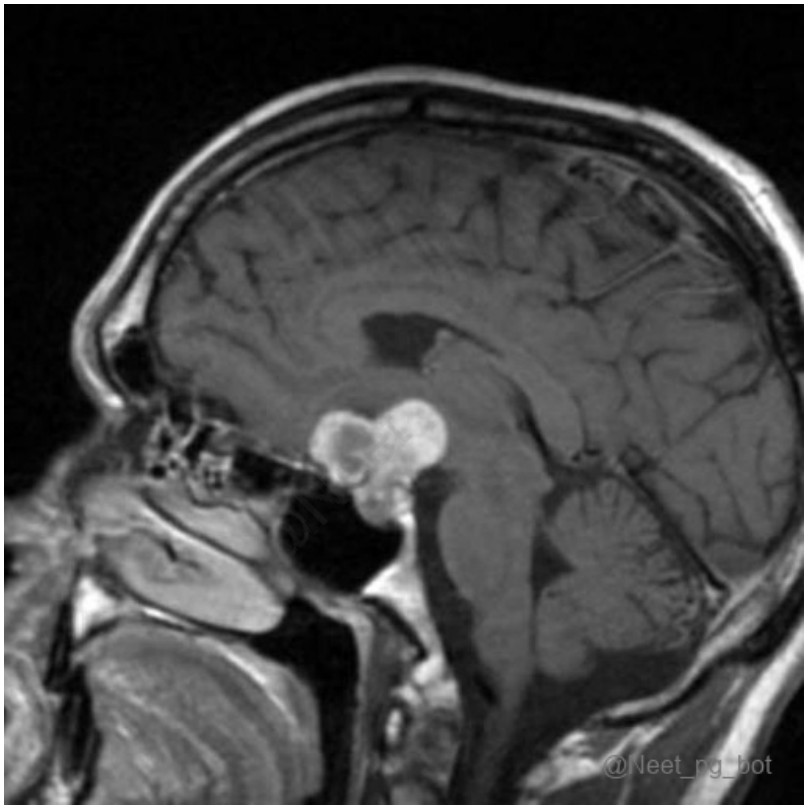

See Answer in Part B → Q3

@Neet_pg_bot

Q4: A 49-year-old man presents with gradually progressive lethargy, loss of appetite and intermittent vomiting for several months. He also reports excessive thirst and passing large volumes of urine. MRI brain shows a suprasellar mass with mixed cystic-solid components and areas of calcification. Which of the following is the most common initial clinical presentation of this condition? (Q890234)

A. Bitemporal hemianopia

B. Hypogonadotropic hypogonadism

C. Persistent headache

D. Central diabetes insipidus

See Answer in Part B → Q4

@Neet_pg_bot

Q5: A 28-year-old man is diagnosed with a hereditary endocrine tumour syndrome and is being planned for surveillance imaging. In which of the following conditions is routine pituitary tumour screening not required? (Q890233)

A. MEN 1

B. MEN 4

C. Carney complex

D. MEN 2

See Answer in Part B → Q5

@Neet_pg_bot

Q6: A 34-year-old woman presents with secondary amenorrhea and spontaneous galactorrhea for 6 months. She also complains of gradually worsening peripheral vision. MRI brain reveals a 16-mm pituitary lesion. Which of the following visual field defects is most likely in this patient? (Q890232)

A. Bitemporal superior quadrantanopia

B. Homonymous superior quadrantanopia

C. Central scotoma

D. Monocular temporal hemianopia

See Answer in Part B → Q6

@Neet_pg_bot

Q7: A 55-year-old man presents with progressive fatigue and recent visual field defects. MRI shows a large sellar mass compressing the pituitary gland. Which of the following findings would be least likely to be present in this patient? (Q890231)

A. Increased adiponectin levels

B. Hypogonadotropic hypogonadism

C. Secondary hypothyroidism

D. Diffuse mucocutaneous hyperpigmentation

See Answer in Part B → Q7

@Neet_pg_bot

Q8: A 28-year-old woman presents with oligomenorrhea and spontaneous galactorrhea. Serum prolactin is 78 ng/mL. MRI of the sellar region is planned. Which of the following lesion sizes would classify the pituitary tumour as a microadenoma? (Q890230)

A. < 5 mm

B. < 8 mm

C. < 10 mm

D. < 15 mm

See Answer in Part B → Q8

@Neet_pg_bot

Q9: A 46-year-old man presents with progressively worsening headache and difficulty seeing objects in the peripheral field of vision. MRI reveals a large sellar mass compressing the optic chiasm. Hormonal evaluation shows mildly elevated serum prolactin with low cortisol and low TSH levels. Which of the following cell types is the most likely origin of this tumour? (Q890229)

A. Lactotroph cells

B. Corticotroph cells

C. Gonadotroph cells

D. Thyrotroph cells

See Answer in Part B → Q9

@Neet_pg_bot

Q10: A 27-year-old woman presents with 6 months of amenorrhea, spontaneous galactorrhea and infertility. Serum prolactin is 120 ng/mL. Which of the following is the most appropriate next step in evaluation? (Q884050)

A. MRI of pituitary fossa

B. Serum free T4 and TSH levels

C. Serum LH and FSH levels

D. Start cabergoline therapy

See Answer in Part B → Q10

@Neet_pg_bot

Q11: A 29-year-old woman presents with secondary amenorrhea and milky nipple discharge for 6 months. She also reports an inability to conceive despite regular unprotected intercourse. Which of the following clinical features would be least likely to be part of her underlying disorder? (Q884049)

A. Galactorrhea

B. Infertility

C. Diminished libido

D. Visual field defect

See Answer in Part B → Q11

@Neet_pg_bot

Q12: A 40-year-old man presents with progressive increase in ring and shoe size, coarse facial features, excessive sweating, arthralgia and new-onset diabetes mellitus. Serum IGF-1 is elevated, and growth hormone fails to suppress following an oral glucose tolerance test. MRI sella reveals a pituitary mass. What is the most common underlying aetiology of his condition? (Q884048)

A. Ectopic GHRH secretion from bronchial carcinoid

B. Pure somatotroph pituitary adenoma

C. Lactotroph adenoma with stalk effect

D. Hypothalamic hamartoma

See Answer in Part B → Q12

@Neet_pg_bot

Q13: A 23-year-old woman undergoes dynamic pituitary testing. Following TRH administration, her serum growth hormone (GH) levels show a paradoxical rise. Which of the following clinical conditions is most likely to show this response? (Q884047)

A. Acromegaly

B. Simple protein-energy malnutrition

C. Cushing syndrome

D. Chronic kidney disease

See Answer in Part B → Q13

@Neet_pg_bot

Q14: A 15-year-old boy receiving recombinant growth hormone therapy for constitutional short stature presents with progressive weight gain, facial puffiness and new-onset impaired fasting glucose. Which of the following adverse effects is he least likely to develop due to growth hormone therapy? (Q884046)

A. Slipped capital femoral epiphysis

B. Tinnitus

C. Pseudotumor cerebri

D. Hypotension

See Answer in Part B → Q14

@Neet_pg_bot

Q15: A 4-year-old boy is brought in with proportionate short stature, frontal bossing and recurrent episodes of fasting hypoglycemia. His serum growth hormone levels are markedly elevated, but IGF-1 levels are very low. Which of the following is the most likely underlying abnormality? (Q884045)

A. Congenital GHRH deficiency

B. Inactivating mutation of the growth hormone receptor

C. Isolated pituitary somatotroph hypoplasia

D. Congenital absence of IGF-1 production

See Answer in Part B → Q15

@Neet_pg_bot

Q16: A patient with acromegaly presents with large spade-like hands and impaired glucose tolerance. The pituitary MRI shows a somatotrope adenoma. Which of the following is the preferred medical therapy to shrink the tumor preoperatively? (Q850805)

A. Cabergoline

B. Lanreotide

C. Bromocriptine

D. Pegvisomant

See Answer in Part B → Q16

@Neet_pg_bot

Q17: Which of the following diseases is mismatched with its hormonal profile and management (Q850922)

A. Lymphocytic hypophysitis - variable deficiency in pituitary hormone Sheehan syndrome - treated with hormone replacement therapy Langerhans cell histiocytosis of pituitary - ADH deficiency present

B. Lymphocytic hypophysitis - Glucocorticoid to reduce inflammation Sheehan syndrome - Panhypopituitarism Langerhans cell histiocytosis of pituitary - surgical excision of the lesion

C. Lymphocytic hypophysitis - Glucocorticoid to reduce inflammation Sheehan syndrome - ADH deficiency present Langerhans cell histiocytosis of pituitary-thyroid hormone replacement is essential.

D. Lymphocytic hypophysitis - Surgical excision if vision is affected Sheehan syndrome - Thyroid hormone replacement after Corticosteroids are stabilized Langerhans cell histiocytosis of pituitary - Chemotherapy is systemic involvement present

See Answer in Part B → Q17

@Neet_pg_bot

Q18: A 60-year-old male with a history of pituitary adenoma presents with sudden-onset severe headache, palpitations, excessive sweating, and hypotension. Lab results show severe hypoglycemia, and imaging reveals hemorrhage within the pituitary and deviation of the pituitary stalk. What is the initial management for this

patient? (Q850921)

A. Urgent surgical decompression

B. High dose IV glucocorticoid

C. IV dextrose administration

D. Oral hydrocortisone

See Answer in Part B → Q18

@Neet_pg_bot

Q19: Match the following pituitary gland disorders with their respective serum hormone levels. Pituitary gland disorder Serum hormone levels 1. Hypopituitarism a) Severe ↓ ACTH and GH, other hormones maybe ↓ or normal 2. Sheehan syndrome b) GH, ACTH, TSH, LH, FSH, prolactin, ADH ↓ 3. Pituitary apoplexy c) GH, ACTH, TSH, LH, FSH normal or ↓; prolactin ↑ 4. Stalk effect d) GH, ACTH, TSH, LH, FSH, prolactin ↓ and ADH normal (Q850920)

A. 1-c, 2-b, 3-d, 4-a

B. 1-b, 2-d, 3-a , 4-c

C. 1-d, 2-a, 3-c, 4-b

D. 1-a, 2-c, 3-b, 4-d

See Answer in Part B → Q19

@Neet_pg_bot

Q20: Which of the following is not true regarding the stalk effect of the pituitary? (Q850918)

A. Hyperprolactinemia occurs due to a hypersecreting macroadenoma

B. There is reduced secretion of dopamine in the pituitary stalk

C. Significant deficiencies in other pituitary hormones are not present

D. Prolactin level is usually less than 200 ng/ml

See Answer in Part B → Q20

@Neet_pg_bot

Q21: A 32 year old nulliparous woman comes to the OB-GYN department for investigation of infertility. She also complains of occasional headaches and galactorrhoea. Lab tests and imaging lead to a diagnosis of prolactinoma. If we want to restore fertility in this patient, which of the following is the treatment of choice in this patient? (Q850917)

A. Cabergoline therapy till pregnancy is confirmed

B. Bromocriptine therapy till pregnancy is confirmed

C. Radiotherapy for mass reduction of tumor

D. Transsphenoidal resection of the mass

See Answer in Part B → Q21

@Neet_pg_bot

Q22: A 40-year-old man presents with erectile dysfunction and galactorrhea. Blood tests confirm elevated prolactin levels and an MRI reveals a macroadenoma. Which of the following management strategies is most appropriate for this patient? (Q850916)

A. Trans sphenoidal surgery

B. Start cabergoline

C. Observation & regular follow-up with MRI

D. Start Lanreotide

See Answer in Part B → Q22

@Neet_pg_bot

Q23: A 28-year-old woman presents to her primary care physician with complaints of irregular menstrual cycles, galactorrhea, and difficulty conceiving. Laboratory tests reveal elevated serum prolactin levels. MRI of the patient is given below. Which of the following statements about the given condition is not true? (Q850915)

A. Female-to-Male ratio is approximately 20:1 for microadenomas

B. Men generally present with symptoms earlier than women

C. Macroadenoma may cause bitemporal hemianopia

D. Prolactin levels correlate with the size of the tumor



See Answer in Part B → Q23

@Neet_pg_bot

Q24: Which of the following is the most appropriate initial management for a patient with Sheehan syndrome? (Q850914)

A. Immediate thyroid hormone replacement

B. Hydrocortisone administration

C. Fludrocortisone administration

D. GH administration

See Answer in Part B → Q24

@Neet_pg_bot

Q25: A 32-year-old woman experiences severe postpartum hemorrhage during delivery, requiring a blood transfusion. Two weeks later, she reports fatigue, weight loss and failure of lactation. Which of the following hormone replacement will not be required in this case? (Q850913)

A. Hydrocortisone

B. Melatonin

C. Thyroxine

D. Somatotropin

See Answer in Part B → Q25

@Neet_pg_bot

Q26: 45-year-old man presents with headaches, frequent change in shoe size and visual field defects. MRI head is shown below. IGF-1 is elevated and GH levels remain elevated on glucose challenge. Which of the following is the most appropriate management for this patient? (Q850912)

A. Initiate treatment with oral cabergoline

B. Start long-acting Octreotide

C. Perform transsphenoidal surgical resection

D. Initiate external beam radiation therapy

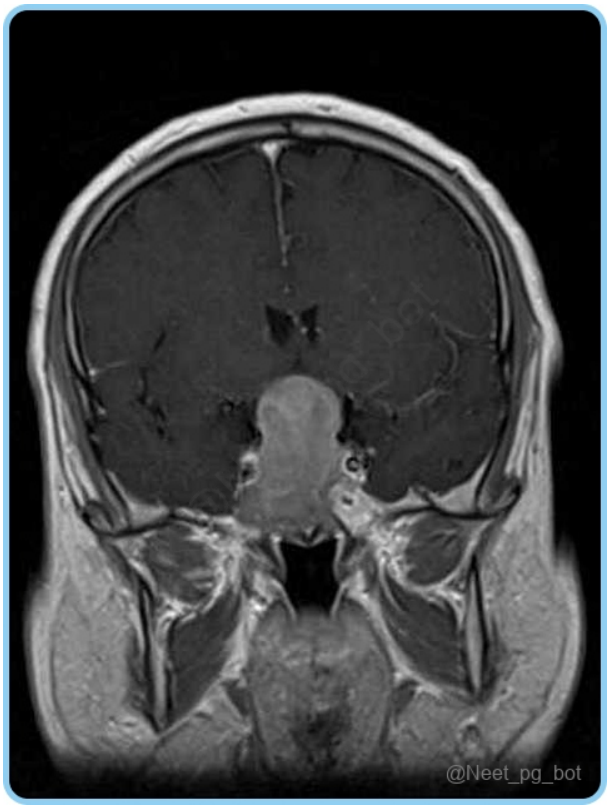

See Answer in Part B → Q26

@Neet_pg_bot

Q27: 50-year-old woman presents with increase in size of hand and feet with voice changes and carpal tunnel syndrome. IGF -1 levels are increased. Which of the following findings will likely not be seen in this case? (Q850911)

A. Hypoglycemic attacks

B. Galactorrhea

C. Bitemporal Hemianopia

D. Colonic polyps

See Answer in Part B → Q27

@Neet_pg_bot

Q28: A 45-year-old man presents with spade like hands, coarse facies and increased spacing between his lower teeth. Which of the following is screening test for this case? (Q850910)

A. IGF-1 levels

B. IGF-2 levels

C. GH Levels

D. GH levels after 2 hour of glucose challenge test



See Answer in Part B → Q28

@Neet_pg_bot

Q29: Prolactin levels can be increased in all of the following conditions except? (Q850909)

A. Acromegaly

B. Primary hypothyroidism

C. Secondary hypothyroidism

D. Prolactinoma

See Answer in Part B → Q29

@Neet_pg_bot

Q30: Best test to confirm the diagnosis of acromegaly is? (Q850806)

A. IGF-1

B. IGF-2

C. Oral Glucose Tolerance Test

D. MRI pituitary

See Answer in Part B → Q30

@Neet_pg_bot

• [03_Endocrinology] 020 Previous Year Questions

« Back to Folder Directory

[03_Endocrinology] 020 Previous Year Questions — Quick Jump

Q1 (p. 302)	*Q2 (p. 303)*	*Q3 (p. 303)*	*Q4 (p. 303)*	*Q5 (p. 304)*	*Q6 (p. 304)*
Q7 (p. 304)	*Q8 (p. 305)*	*Q9 (p. 305)*	*Q10 (p. 306)*	*Q11 (p. 306)*	*Q12 (p. 306)*
Q13 (p. 307)	*Q14 (p. 307)*	*Q15 (p. 307)*	*Q16 (p. 308)*	*Q17 (p. 308)*	*Q18 (p. 309)*
Q19 (p. 309)	*Q20 (p. 310)*	*Q21 (p. 310)*	*Q22 (p. 311)*	*Q23 (p. 311)*	*Q24 (p. 311)*
Q25 (p. 312)	*Q26 (p. 312)*	*Q27 (p. 312)*	*Q28 (p. 313)*	*Q29 (p. 313)*	*Q30 (p. 313)*
Q31 (p. 314)	*Q32 (p. 314)*	*Q33 (p. 315)*	*Q34 (p. 315)*	*Q35 (p. 316)*	*Q36 (p. 316)*
Q37 (p. 317)	*Q38 (p. 317)*	*Q39 (p. 318)*	*Q40 (p. 318)*	*Q41 (p. 318)*	*Q42 (p. 319)*
Q43 (p. 319)	*Q44 (p. 319)*	*Q45 (p. 320)*	*Q46 (p. 320)*	*Q47 (p. 321)*	*Q48 (p. 321)*
Q49 (p. 321)	*Q50 (p. 322)*	*Q51 (p. 322)*	*Q52 (p. 323)*	*Q53 (p. 323)*	*Q54 (p. 324)*
Q55 (p. 325)	*Q56 (p. 325)*	*Q57 (p. 325)*	*Q58 (p. 326)*	*Q59 (p. 327)*	*Q60 (p. 327)*
Q61 (p. 327)	*Q62 (p. 328)*	*Q63 (p. 328)*	*Q64 (p. 328)*	*Q65 (p. 329)*	*Q66 (p. 329)*
Q67 (p. 330)	*Q68 (p. 330)*	*Q69 (p. 330)*	*Q70 (p. 331)*	*Q71 (p. 331)*	*Q72 (p. 331)*
Q73 (p. 332)	*Q74 (p. 333)*	*Q75 (p. 333)*	*Q76 (p. 333)*	*Q77 (p. 334)*	*Q78 (p. 334)*
Q79 (p. 334)	*Q80 (p. 335)*	*Q81 (p. 335)*	*Q82 (p. 336)*	*Q83 (p. 336)*	*Q84 (p. 336)*
Q85 (p. 337)	*Q86 (p. 337)*	*Q87 (p. 338)*	*Q88 (p. 338)*	*Q89 (p. 339)*	*Q90 (p. 339)*
Q91 (p. 340)	*Q92 (p. 340)*	*Q93 (p. 340)*	*Q94 (p. 341)*	*Q95 (p. 341)*	*Q96 (p. 342)*
Q97 (p. 342)	*Q98 (p. 342)*	*Q99 (p. 343)*	*Q100 (p. 343)*	*Q101 (p. 343)*	*Q102 (p. 344)*
Q103 (p. 344)					

Q1: A patient presents with weight gain, thinning of hair, and dry skin. Diagnosis is Hashimoto’s thyroiditis. Which antibody is seen in this case? (Q866788)

A. Anti-TPO antibody

B. Anti TSH

C. Anti TBG

D. Long-acting thyroid-stimulating antibody

See Answer in Part B → Q1

@Neet_pg_bot

Q2: A patient has developed a cough and weight loss for the last 3 months. Biopsy of lung mass shows expression of chromogranin and synaptophysin. Which paraneoplastic syndrome will most likely occur in this patient? (Q866793)

A. Hypercalcemia

B. Cushing syndrome

C. Gynaecomastia

D. SIADH

See Answer in Part B → Q2

@Neet_pg_bot

Q3: A patient presents with palpitations, headache, and sweating. His BP is 180/100 mmHg. 24-hour urinary metanephrine values are elevated. What is the diagnosis? (Q866794)

A. Carcinoid tumor

B. Pheochromocytoma

C. Carcinoid crisis

D. Neuroblastoma

See Answer in Part B → Q3

@Neet_pg_bot

Q4: A known case of hyperthyroidism, who is not on medication, is scheduled for total thyroidectomy. The PAC check was not done properly. What is the leading complication that can occur during surgery? (Q866801)

A. Hyperthermia

B. Hypothermia

C. Arrhythmia

D. Hypothyroidism

See Answer in Part B → Q4

@Neet_pg_bot

Q5: Patient presents with hypertension and hypokalemic metabolic alkalosis. CT scan shows a mass over the kidney with elevated ARR. What is the next best step for the management of this patient? (Q866803)

A. Spironolactone on a lifelong basis

B. Adrenalectomy

C. ACTH stimulation test

D. Dexamethasone suppression test

See Answer in Part B → Q5

@Neet_pg_bot

Q6: A female presents with amenorrhea and galactorrhea. Serum prolactin is elevated. MRI shows pituitary adenoma. Best management for this patient? (Q866806)

A. Bromocriptine

B. Letrozole

C. Tamoxifen

D. Goserelin

See Answer in Part B → Q6

@Neet_pg_bot

Q7: Hyperpigmentation in Addison’s disease is due to increased secretion of: (Q866480)

A. Cortisol

B. ACTH

C. Aldosterone

D. Renin

See Answer in Part B → Q7

@Neet_pg_bot

Q8: A patient presents with palpitations, headache and diaphoresis + elevated 24 hour urine metanephrine levels. Which of the following drugs can be used both preoperatively and intraoperatively for control of BP? (Q866494)

A. Phenoxybenzamine

B. Esmolol

C. Clonidine

D. Labetalol

See Answer in Part B → Q8

@Neet_pg_bot

Q9: A 56-year-old diabetic patient is currently on Metformin and Insulin Glargine. His HbA1c is 8.2%, indicating suboptimal glycemic control. Echocardiography reveals a reduced ejection fraction (EF) of 35%. Which of the following is the most appropriate agent to add to his current regimen? (Q866500)

A. Pioglitazone

B. Glimepiride

C. Sitagliptin

D. Empagliflozin

See Answer in Part B → Q9

@Neet_pg_bot

Q10: A patient presents with salt wasting, craving, hyperkalemia, metabolic acidosis, and skin pigmentation. What is the most likely diagnosis? (Q866509)

A. Addison’s disease

B. Cushing’s syndrome

C. Conn’s syndrome

D. Pheochromocytoma

See Answer in Part B → Q10

@Neet_pg_bot

Q11: A known type 1 diabetic presents with glucose 799 mg/dL, Na■ 128 mEq/L, Cl■ 88 mEq/L, and signs of dehydration. Which of the following is NOT used in the initial management? (Q866515)

A. 0.9% Normal saline

B. 3% Saline

C. IV infusion insulin

D. Potassium monitoring

See Answer in Part B → Q11

@Neet_pg_bot

Q12: A female patient with type 1 DM and hypothyroidism presented with chronic oral mucocutaneous candidiasis for 5 years. She is diagnosed with autoimmune polyendocrinopathy syndrome type 1. Which of the following is incorrect about this condition? (Q853349)

A. DM type-1 association is high

B. Starts in infancy

C. Hypoparathyroidism

D. High association with candidiasis

See Answer in Part B → Q12

@Neet_pg_bot

Q13: A patient presents with hypotension, hyponatremia and blackening of the knuckles and perioral area. Which of the following conditions is most likely associated with these symptoms? (Q844204)

A. Conn syndrome

B. Cushing's syndrome

C. Primary ACTH deficiency

D. Addison’s disease

See Answer in Part B → Q13

@Neet_pg_bot

Q14: A patient with a history of Wilson's disease presents with neurological manifestations. Which of the following is the best diagnostic modality? (Q844223)

A. Serum ceruloplasmin

B. Urinary copper excretion

C. Hepatic parenchymal demonstration of copper

D. Anti-tissue transglutaminase (Anti-tTG) antibody

See Answer in Part B → Q14

@Neet_pg_bot

Q15: A patient presents with large sweaty hands, macroglossia, and frontal bossing. Select the best test for confirmation of the diagnosis: (Q844227)

A. GHRH levels

B. IGF- 1

C. IGF- 2

D. GH levels after glucose suppression

See Answer in Part B → Q15

@Neet_pg_bot

Q16: In a patient with type 1 diabetes at the 3rd stage of beta cell damage, which of the following conditions is most likely to be observed? (Q844327)

A. Autoimmune positive + normoglycemia

B. Autoimmune negative + normoglycemia

C. Autoimmune positive + dysglycemia

D. Autoimmune negative + dysglycemia

See Answer in Part B → Q16

@Neet_pg_bot

Q17: A patient presents with features of hyperthyroidism, characterized by decreased TSH levels and elevated free T3 and T4. Which of the following statements about this condition is NOT true? (Q844328)

A. The condition will improve simultaneously with improvement in the thyrotoxic state.

B. In 10% of cases, the condition is present without hyperthyroidism.

C. Severe disease can cause vision loss.

D. No specs criteria is used for this condition.



See Answer in Part B → Q17

@Neet_pg_bot

Q18: A young woman presents with weight loss, tachycardia, heat intolerance, and tremors. On examination, she has exophthalmos. What is the most likely diagnosis? (Q844329)

A. Parkinson's disease

B. Graves' disease

C. Addison's disease

D. Alzheimer's disease

See Answer in Part B → Q18

@Neet_pg_bot

Q19: In Type 1 Diabetes Mellitus, what characterizes stage 3 of beta-cell destruction? (Q844286)

A. Symptomatic hyperglycemia

B. Dysglycemic symptomatic

C. Normoglycemic symptomatic

D. Dysglycemic asymptomatic

See Answer in Part B → Q19

@Neet_pg_bot

Q20: Which of the following antidiabetic drugs can cause glucosuria? (Q860437)

A. Glimepiride

B. Exenatide

C. Acarbose

D. Empagliflozin

See Answer in Part B → Q20

@Neet_pg_bot

Q21: A diabetic patient came to the outpatient department with complaints of fatigue and frequent urination. On examination vitals are stable and an HbA1c is done. What is the cut-off percentage used for determining controlled diabetes? (Q860444)

A. 6.0

B. 6.5

C. 7.0

D. 7.5

See Answer in Part B → Q21

@Neet_pg_bot

Q22: Which of the following is associated with MEN-1 syndrome? (Q860448)

A. Parathyroid adenoma

B. Parotid tumor

C. Renal cell carcinoma

D. Pheochromocytoma

See Answer in Part B → Q22

@Neet_pg_bot

Q23: All of the below are features of Conn's syndrome except? (Q860462)

A. Metabolic alkalosis

B. Metabolic acidosis

C. Hypertension

D. Muscle cramps

See Answer in Part B → Q23

@Neet_pg_bot

Q24: A 45-year-old man presents to the outpatient department with symptoms of headache, renal stones, and abdominal pain. Serum calcium is low and PTH is high. Which of the following hormone and associated disease might be causing these symptoms? (Q840096)

A. Parathyroid and Primary hyperparathyroidism

B. Catecholamines and Pheochromocytoma

C. Thyroxine and Hypothyroidism

D. Mineral and bone disorders

See Answer in Part B → Q24

@Neet_pg_bot

Q25: A 45-year-old man presents to the outpatient department with proximal muscle weakness, purple stretch marks, obesity, and easy bruising. What is the underlying condition? (Q840099)

A. Hyperthyroidism

B. Hypercortisolism

C. Hyperparathyroidism

D. Hyperaldosteronism

See Answer in Part B → Q25

@Neet_pg_bot

Q26: All of the following are criteria for diagnosis of diabetes ketoacidosis, except? (Q840103)

A. Serum glucose of more than 250 mg

B. Anion gap of more than 10-12

C. Serum bicarbonate less than 15 mmol

D. Serum potassium less than 3.5 mEq

See Answer in Part B → Q26

@Neet_pg_bot

Q27: Which of the following is the diagnostic test for carcinoid tumors? (Q860132)

A. 24-hour urinary catecholamines

B. Serum calcitonin levels

C. Serum chromogranin A

D. Urinary 5-hydroxyindoleacetic acid

See Answer in Part B → Q27

@Neet_pg_bot

Q28: Which of the following tests is the best for assessing long-term control of diabetes mellitus? (Q860233)

A. Glycosylated Hemoglobin

B. Glycated Albumin

C. Serum Fructosamine

D. Urine Sugar

See Answer in Part B → Q28

@Neet_pg_bot

Q29: Which of the following anti-diabetic drug is recently approved to be used in patients with heart failure with low ejection fraction and reduced urine output? (Q857286)

A. Linagliptin

B. Empagliflozin

C. Pioglitazone

D. Degludec

See Answer in Part B → Q29

@Neet_pg_bot

Q30: A child is brought to the ER in an unconscious state after severe vomiting and abdominal pain episodes. HR = 100/min and BP=100/60 mm Hg. Work up shows: pH=7.2 Blood glucose 300 mg/dl Ketone 3+. What should be the best management? (Q857287)

A. Infusion of 0.05 – 0.1 U/kg dose insulin after 1 hour of IVF

B. 0.1 Unit/kg insulin stat followed infusion of 0.5 U- 0.1 U/kg dose insulin and IVF

C. 0.1 U/kg insulin subcutaneous stat followed by IVF

D. IVF followed by subcutaneous 0.1 U/kg insulin

See Answer in Part B → Q30

@Neet_pg_bot

Q31: A 26-year-old female presents with palpitations, weight loss, tremors, sweating and diarrhoea. What is the next test that will help establish the diagnosis for this patient? (Q857288)

A. TSH and free T4

B. Anti Thyroid Peroxidase antibodies

C. Total T3

D. USG Neck

See Answer in Part B → Q31

@Neet_pg_bot

Q32: A patient with a history of rheumatoid arthritis (RA) presented to the ER with hypotension. She was on medication for RA but abruptly stopped them. On examination, her HR = 110 bpm, BP is 80/40 mm Hg, blood sugar = 50 mg/dl, Na = 130 meq/L and K = 6.0 meq/L. What should be the most appropriate management? (Q854674)

A. Fast IV fluids

B. Hydrocortisone

C. Dopamine infusion

D. Soda bicarbonate

See Answer in Part B → Q32

@Neet_pg_bot

Q33: Which of the following is not a component of metabolic syndrome? (Q854734)

A. LDL

B. Fasting glucose

C. Abdominal circumference

D. Blood pressure

See Answer in Part B → Q33

@Neet_pg_bot

Q34: A female patient presents with severe restlessness, palpitations, and tremors to the emergency department. She is a known case of bronchial asthma. On examination, the neck looks swollen. Blood pressure is elevated, and tachycardia is noted. ECG shows atrial fibrillation. Which of the following drugs is used for immediate management in this patient? (Q855431)

A. Diltiazem

B. Propranolol

C. Esmolol

D. Propylthiouracil

See Answer in Part B → Q34

@Neet_pg_bot

Q35: A 25-year-old male patient came with complaints of palpitations, sweating, and restlessness. He has a complaint of sweaty palms. Clinical findings are depicted in the image given below. What is the diagnostic finding seen in this patient? (Q855441)

A. Anti-thyroglobulin antibody

B. Anti-thyroid peroxidase antibody

C. Thyroid receptor antibody

D. Elevated ultrasensitive thyrotropin levels

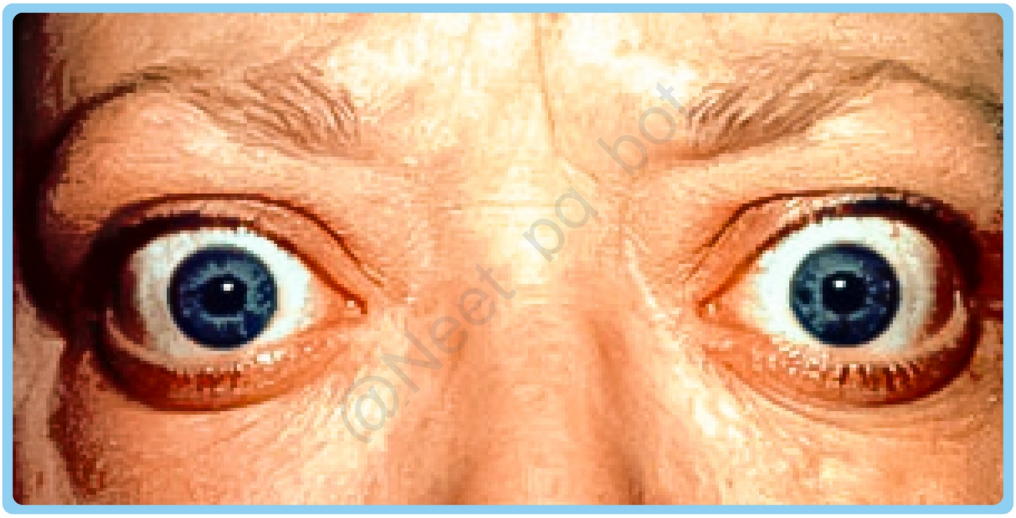

@Neet_pg_bot

See Answer in Part B → Q35

@Neet_pg_bot

Q36: A patient came to medical OPD with complaints of polyuria. He has a history of undergoing total hypophysectomy. His Na + levels were found to be 155 mEq/L, and his urine osmolarity was 200 mOsm/L. What is the definitive management in this patient? (Q855498)

A. DDAVP for 2 weeks and then discontinue

B. DDAVP supplementation for lifelong

C. Upsetting of receptors, so no treatment required

D. Thiazides for 2 weeks

See Answer in Part B → Q36

@Neet_pg_bot

Q37: A 29-year-old male patient presents with coarse facial features and gradual enlargement of the hands and feet for the past decade. He has been diagnosed with acromegaly based on elevated levels of IGF-1 and growth hormone that did not suppress after a 75 g glucose challenge test. What drug is recommended for treatment? (Q858019)

A. Lanreotide depot formulation

B. Terlipressin

C. Ketoconazole

D. Leuprolide

See Answer in Part B → Q37

@Neet_pg_bot

Q38: A patient presents with complaints of sudden onset headache, palpitation, and profuse sweating. The patient has had multiple similar episodes in the past. During these episodes, the patient's blood pressure is elevated. A 24-hour urine metanephrine is elevated. What is the most likely diagnosis? (Q858021)

A. Addison's disease

B. Renal artery stenosis

C. Pheochromocytoma

D. Hyperthyroidism

See Answer in Part B → Q38

@Neet_pg_bot

Q39: In a 60-year-old male, what is the primary etiology typically associated with Cushing's disease? (Q858034)

A. Small-cell lung cancer

B. Adrenal tumor

C. Ectopic ACTH syndrome

D. Pituitary microadenoma

See Answer in Part B → Q39

@Neet_pg_bot

Q40: A 30-year-old female patient presented with bone pain and recurrent episodes of renal colic. Her family reported a history of abnormal behavior. Work up shows elevated serum calcium, low phosphate and elevated SAP. Which of the following is best for further work up of this patient? (Q858035)

A. MRI neck

B. Tc-99m MIBI stress test

C. Sestamibi SPECT /CT

D. CT scan of abdomen

See Answer in Part B → Q40

@Neet_pg_bot

Q41: Which medication is recommended as the primary treatment for high blood sugar in a 19-year-old woman with a medical history of type 1 diabetes mellitus, who has been brought to the emergency room due to symptoms of confusion, vomiting, and abdominal pain, and subsequently diagnosed with diabetic ketoacidosis? (Q793941)

A. Regular insulin

B. Lente insulin

C. Glyburide

D. 70/30 insulin

See Answer in Part B → Q41

@Neet_pg_bot

Q42: Which of the following is seen in MEN 2B syndrome? (Q855719)

A. Café au lait spot

B. Medullary thyroid carcinoma

C. Parathyroid adenoma

D. Optic nerve glioma

See Answer in Part B → Q42

@Neet_pg_bot

Q43: Which of the following is a characteristic feature of Kallmann syndrome? (Q855313)

A. Anosmia

B. Syndactyly in males

C. Precocious puberty in females

D. White forelock

See Answer in Part B → Q43

@Neet_pg_bot

Q44: What would be the most suitable course of action for managing a 65-year-old male who presented with symptoms of weakness, lethargy, excessive cold intolerance,

and slow ankle jerk? His thyroid function test (TFT) revealed a TSH level of 16 Mu/L (normal range: 0.4 - 4.0 mu / l), T4 level of 0.3 ng/dl (normal range: 0.6 - 1.6 ng / dl), and T3 level of 70 pg /dl. (Q857050)

A. Start levothyroxine at 100 micrograms and decrease the dose gradually

B. Start levothyroxine at 25 micrograms and increase the dose gradually

C. Start levothyroxine at 25 micrograms and decrease the dose gradually

D. Give T3 and T4 drugs simultaneously

See Answer in Part B → Q44

@Neet_pg_bot

Q45: Fulminant diabetes mellitus is seen in? (Q857056)

A. Diabetic ketoacidosis

B. Coxsackie B virus

C. Non ketonic hyperosmolar coma

D. Autoimmune pancreatitis

See Answer in Part B → Q45

@Neet_pg_bot

Q46: A comatose elderly patient with a weight of approximately 70 kilograms is presented to the emergency department. During examination, it was determined that the patient's serum glucose levels were 500mg/dL, arterial pH is 7.30, and there is an elevation in plasma ketones levels. However, the serum potassium levels are within the normal range. In order to treat this patient, which of the following should be added to the saline solution? (Q857668)

A. Insulin

B. Bicarbonate

C. Potassium

D. 14 units of regular insulin intravenously

See Answer in Part B → Q46

@Neet_pg_bot

Q47: Addison's disease is characterized by all of the following symptoms except? (Q857672)

A. Hyperglycemia

B. Hyponatremia

C. Hyperkalemia

D. Hypotension

See Answer in Part B → Q47

@Neet_pg_bot

Q48: What is the preferred medication for treating Hyperthyroidism during the second trimester of pregnancy? (Q857684)

A. Propyl Thiouracil

B. Carbimazole

C. Sodium iodide

D. Radioactive iodine

See Answer in Part B → Q48

@Neet_pg_bot

Q49: A 30-year-old female patient came to the outpatient department with complaints of neck swelling. She gives a history of weight loss and palpitations. On examination, she has exophthalmos and a diffusely enlarged thyroid gland. What are the essential

investigations that should be done for the patient? Thyroid scan Fine needle aspiration cytology (FNAC) Thyroid function tests Ultrasound of neck Anti-thyroid antibody (Q855715)

A. 1,2,3,4 and 5

B. 1,3,5 only

C. 3,4,5 only

D. 1,3,4 and 5 only

See Answer in Part B → Q49

@Neet_pg_bot

Q50: In a PHC, which of the following initial screening tests are used to diagnose diabetes? HbA1c >6.5 Fasting blood sugar >126mg/dl Random blood sugar >200mg/dl 2-hour post glucose load blood sugar (Q855721)

A. 1 and 2

B. 2 and 3

C. 2 and 4

D. 1,2 and 3

See Answer in Part B → Q50

@Neet_pg_bot

Q51: During her pregnancy, a woman who had Grave's disease was consistently taking. Consequently, the newborn suffered from aplasia cutis congenita. Which specific medication could be attributed to the occurrence of this condition? (Q856948)

A. Carbimazole

B. Levothyroxine

C. Methylthiouracil

D. Hydrouracil

See Answer in Part B → Q51

@Neet_pg_bot

Q52: Which of the following conditions are most commonly associated with elevated TSH levels and decreased T4 levels? (Q856970)

A. Hypoparathyroidism

B. Pituitary Adenoma

C. Grave's disease

D. Hashimoto's thyroiditis

See Answer in Part B → Q52

@Neet_pg_bot

Q53: A diabetic patient walks into your clinic and does “namaste”. The image is given below. What could be the probable cause? (Q856286)

A. Flexor tenosynovitis

B. Cheiroarthropathy

C. Dupuytrens contracture

D. Ankyloses



@Neet_pg_bot

See Answer in Part B → Q53

@Neet_pg_bot

Q54: A 12-year-old child who is known to have type 1 diabetes mellitus presents with confusion and drowsiness. Her mother says that she seems to be breathing very fast. On examination, mucous membranes are dry, and blood pressure is 70/50 mmHg. Random blood glucose is 415 mg/d,l and urine ketones are 4+. What is the next best step in management? (Q855056)

A. 2-3 L of normal saline over 1-3 hours

B. Insulin infusion at 0.1 units/kg/hour

C. Arterial blood gas

D. Insulin bolus of 0.1 units/kg given

See Answer in Part B → Q54

@Neet_pg_bot

Q55: A patient came to the hospital with complaints of lethargy, increased sleep, and weight gain. Investigations revealed low plasma TSH concentration. However, on the administration of TRH, the TSH levels increased. Which of the conditions is likely in this patient? (Q858428)

A. Hyperthyroidism due to disease in the pituitary

B. Hypothyroidism due to disease in the pituitary

C. Hypothyroidism due to disease in the hypothalamus

D. Hyperthyroidism due to disease in the hypothalamus

See Answer in Part B → Q55

@Neet_pg_bot

Q56: A 55-year-old man with a known pituitary adenoma presents with sudden, severe headache, vomiting, and rapidly decreasing responsiveness. On examination, his blood pressure is 80/50 mmHg. Which of the following findings is most characteristic of pituitary apoplexy? (Q858432)

A. Hypertension

B. Shock

C. Unconsciousness

D. Fatigue

See Answer in Part B → Q56

@Neet_pg_bot

Q57: What is a macrovascular complication that develops in the advanced stages of diabetes? (Q859745)

A. Coronary artery disease

B. Foot ulcer

C. Nephropathy

D. Retinopathy

See Answer in Part B → Q57

@Neet_pg_bot

Q58: What is the disease depicted in the image below? (Q859778)

A. Acromegaly

B. PCOS

C. Cushing’s syndrome

D. Advanced obesity

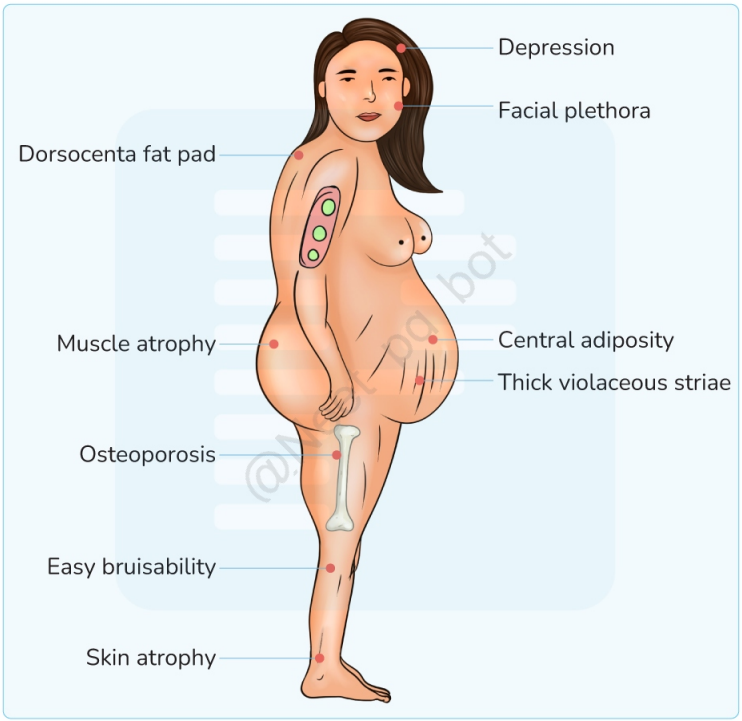

See Answer in Part B → Q58

@Neet_pg_bot

Q59: A 30-year-old man presents with sudden onset of a headache, palpitation, and profuse sweating. He had several such episodes in the past. During these episodes, his BP is found to be high. A 24-hour urinary metanephrine is elevated. What is the most likely aetiology? (Q859793)

A. Fibromuscular dysplasia

B. Renal artery stenosis

C. Pheochromocytoma

D. Hyperthyroidism

See Answer in Part B → Q59

@Neet_pg_bot

Q60: A patient with diabetes mellitus for the past 5 years presents with vomiting and abdominal pain. She is non-compliant with medication and appears dehydrated. Investigations revealed a blood sugar value of 500 mg/dL and the presence of ketone bodies. What is the next best step in management? (Q855846)

A. Intravenous fluids with long-acting insulin

B. Intravenous fluids

C. Intravenous insulin

D. Intravenous fluids with regular insulin

See Answer in Part B → Q60

@Neet_pg_bot

Q61: A female patient with a negative urine pregnancy test presents to you with galactorrhea. An MRI was done, which revealed a large pituitary tumor. If the patient is not willing to undergo surgery, which of the following is the best drug for treatment? (Q855929)

A. Bromocriptine

B. Promethazine

C. Octreotide

D. Clozapine

See Answer in Part B → Q61

@Neet_pg_bot

Q62: Which of the following is not seen in MEN 2B syndrome? (Q856016)

A. Megacolon

B. Parathyroid adenoma

C. Mucosal neuroma

D. Marfanoid habitus

See Answer in Part B → Q62

@Neet_pg_bot

Q63: A lung cancer patient has hyperpigmentation of palmar and sole creases. Which of the following is responsible for this presentation? (Q860465)

A. Melanocyte Stimulating Hormone (MSH)

B. C-peptide

C. Neuropeptide Y

D. Melanin

See Answer in Part B → Q63

@Neet_pg_bot

Q64: Which of the following mutations is associated with the Philadelphia chromosome? (Q860473)

A. Inversion

B. Insertion

C. Reciprocal translocation

D. Deletion

See Answer in Part B → Q64

@Neet_pg_bot

Q65: Most common cause of hypercalcemia in a hospitalized patient is: (Q857290)

A. Malignancy

B. Parathyroid Adenoma

C. Parathyroid hyperplasia

D. Follicular thyroid CA

See Answer in Part B → Q65

@Neet_pg_bot

Q66: Which of the following is not used in management of tumor lysis syndrome? (Q793977)

A. Urine acidification

B. IV fluids

C. Dialysis

D. Rasburicase

See Answer in Part B → Q66

@Neet_pg_bot

Q67: What is the most frequently observed delayed symptom of radiation therapy for the head and neck? (Q859545)

A. Dysphagia

B. Xerostomia

C. Myelopathy

D. Dysgeusia

See Answer in Part B → Q67

@Neet_pg_bot

Q68: For which of the following cancers is prophylactic cranial irradiation (PCI) routinely recommended as part of standard management (Q859648)

A. Lung cancer

B. Liver cancer

C. Prostate cancer

D. Breast cancer

See Answer in Part B → Q68

@Neet_pg_bot

Q69: A patient with osteoarthritis, for the last 3 months, has been taking ibuprofen and has developed occult GI bleeding. Which is correct about the cause? (Q866795)

A. PGE-2 and prostacyclin production were reduced

B. Increased acid production

C. PGE-1 and prostacyclin production were reduced

D. Mucosal injury due to inhibition of COX-2

See Answer in Part B → Q69

@Neet_pg_bot

Q70: 30 year old male is found to have anemia (MCV 110 fl) with leukonychia and enlarged spleen. The clinical diagnosis is? (Q866825)

A. Portal Hypertension

B. Plummer-Vinson syndrome

C. Achalasia cardia

D. Tylosis palmaris

See Answer in Part B → Q70

@Neet_pg_bot

Q71: Which classification is used for Barrett esophagus? (Q866826)

A. Prague classification

B. Savary-Miller classification

C. Johnson classification

D. Forrest classification

See Answer in Part B → Q71

@Neet_pg_bot

Q72: 24-year-old female presents with dysphagia, weight loss and bronchiectasis. Which investigation should be done to confirm the diagnosis. Barium swallow was shown? (Q866504)

A. Esophageal manometry

B. Upper GI endoscopy

C. CT chest

D. CECT chest



See Answer in Part B → Q72

@Neet_pg_bot

Q73: Which of the following is not associated with celiac disease? (Q853345)

A. IgA transglutaminase positive

B. IgG antigliadin positive

C. Modified Marsh classification

D. HLA DQ6 and HLA DQ11

See Answer in Part B → Q73

@Neet_pg_bot

Q74: A known case of ulcerative colitis is not responding to an anti-TNF alpha agent. Which JAK inhibitor is preferred for moderate to severe ulcerative colitis? (Q853355)

A. Vedolizumab

B. Tofacitinib

C. Ozanimod

D. Leflunomide

See Answer in Part B → Q74

@Neet_pg_bot

Q75: A 70-year-old male patient presents with a complaint of dysphagia, particularly for solids, which has been progressively worsening over the past few months. Additionally, he has experienced significant weight loss and cachexia over the same period. Which of the following diagnostic choices is best for this patient? (Q860394)

A. UGIE

B. Manometry

C. Barium swallow

D. Barium meal follow through

See Answer in Part B → Q75

@Neet_pg_bot

Q76: Which of the following symptoms suggests the use of steroids in IgA vasculitis? (Q840121)

A. Joint inflammation

B. Gastrointestinal hemorrhage

C. Abdominal discomfort

D. Dermatological eruption

See Answer in Part B → Q76

@Neet_pg_bot

Q77: In which of the following conditions is pneumomediastinum commonly found? (Q860160)

A. Pulsion diverticulum

B. Boerhaave syndrome

C. Mallory-Weiss syndrome

D. Pericarditis

See Answer in Part B → Q77

@Neet_pg_bot

Q78: A 42-year-old female presents with complaints of recurrent episodes of abdominal pain and cramps. An endoscopy is done and she is diagnosed with ulcerative colitis. She currently has 3-4 episodes of bloody stools per day. What is the appropriate initial treatment? (Q854665)

A. Budesonide

B. Sulfasalazine

C. Azathioprine

D. Bezlotoxumab

See Answer in Part B → Q78

@Neet_pg_bot

Q79: A patient was taking ampicillin for an upper respiratory tract infection. Then he started having watery diarrhoea for the past 3 days. Which is the drug of choice to

manage this condition? (Q854689)

A. Metronidazole

B. Fidaxomicin

C. Ciprofloxacin

D. Bezlotoxumab

See Answer in Part B → Q79

@Neet_pg_bot

Q80: A 49-year-old male is experiencing recurring episodes of watery diarrhea, dehydration, hypokalemia, and achlorhydria. Which type of neuroendocrine tumor could potentially cause these symptoms? (Q858363)

A. Insulinoma

B. Somatostatinoma

C. VIPoma

D. Glucagonoma

See Answer in Part B → Q80

@Neet_pg_bot

Q81: Mark the correct statement regarding inflammatory bowel disease. (Q855605)

A. Skip lesions are present in Crohn’s disease

B. Mucosal layers are involved in Crohn’s while transmural involvement seen in ulcerative colitis

C. Inflammatory bowel disease doesn’t have a genetic predisposition

D. Crohn’s is curable through surgical resection of the affected segment

See Answer in Part B → Q81

@Neet_pg_bot

Q82: Which of the following are not included in the components of the MELD (2016) score? (Q856338)

A. Bilirubin

B. INR

C. Albumin

D. Creatinine

See Answer in Part B → Q82

@Neet_pg_bot

Q83: What is the probable diagnosis of a patient who has significant abdominal swelling and laboratory analysis of the fluid obtained through paracentesis reveals SAAG <1.1? (Q856355)

A. Congestive heart failure

B. Myxoedema

C. Budd Chiari syndrome

D. Tuberculosis

See Answer in Part B → Q83

@Neet_pg_bot

Q84: What is not a characteristic feature of Wilson's disease? (Q856381)

A. Autosomal recessive disease

B. No free radical injury

C. ATP7B gene involved

D. Presents before age 40 with liver disease

See Answer in Part B → Q84

@Neet_pg_bot

Q85: A 15-year-old girl presented with fatigue, chronic diarrhoea, weight loss, bone pain and abdominal distension. Investigations revealed iron deficiency anemia and osteoporosis. Which of the following is the single best test to be done for her evaluation? (Q858444)

A. TSH levels

B. C-peptide levels

C. Urine sugar and ketone

D. IgA tissue transglutaminase antibody

See Answer in Part B → Q85

@Neet_pg_bot

Q86: A patient with inflammatory bowel disease presents with the following lesion. What is the most likely diagnosis? (Q859643)

A. Erythema nodosum

B. Pyoderma gangrenosum

C. Diabetic ulcer

D. Venous ulcer



See Answer in Part B → Q86

@Neet_pg_bot

Q87: Match the following? a. Trisomy 13 1. Huntington's disease b. Trisomy 18 2. Patau syndrome c. Trinucleotide repeat sequence 3. Sickle disease d. Hb point mutation of glutamate to valine 4. Edward syndrome (Q857256)

A. a-2, b-4, c-1, d-3

B. b-1, a-3, d-2, c-4

C. a-2, b-1, c-4, d-3

D. a-4, b-1, c-3, d-2

See Answer in Part B → Q87

@Neet_pg_bot

Q88: How much sodium deficit needs to be corrected in a 40 kg female with a serum sodium level of 120 mEq/L to achieve a desired sodium concentration of 140 mEq/L? (Q830815)

A. 400 mEq

B. 300 mEq

C. 200 mEq

D. 100 mEq

See Answer in Part B → Q88

@Neet_pg_bot

Q89: During the medication review of an elderly male patient with a history of COPD, hypertension, and diabetes, what criteria should the physician consider? (Q830826)

A. Duke’s criteria

B. Light criteria

C. Beer’s criteria

D. Jones criteria

See Answer in Part B → Q89

@Neet_pg_bot

Q90: What vitamin deficiency is responsible for the following symptoms in a patient: tingling sensation in the hands and feet, generalized weakness, easy fatigability, pallor, and ataxia? (Q793810)

A. Vitamin B1

B. Vitamin B12

C. Vitamin B2

D. Vitamin B3

See Answer in Part B → Q90

@Neet_pg_bot

Q91: Cat scratch disease is caused by? (Q793845)

A. Bartonella henselae

B. Bartonella quintana

C. Bartonella bacilliformis

D. Borrelia burgdorferi

See Answer in Part B → Q91

@Neet_pg_bot

Q92: A man brings his father who became unconscious while working in a field in the host sun at 42 degrees Celsius in May. One examination, there were no physical signs of dehydration. His serum electrolyte values were normal. The physician found that the body temperature was 106 F. Which of the following symptoms is least likely to be seen in this patient? (Q793895)

A. Nausea

B. Hypotension

C. Sweating

D. Headache

See Answer in Part B → Q92

@Neet_pg_bot

Q93: What is the most likely diagnosis for a tall male with a lack of pubic and axillary hair, underdeveloped genitalia, elevated levels of LH and FSH, and a karyotype of XXY? (Q793914)

A. Vanishing testis syndrome

B. Klinefelter’s syndrome

C. Noonan syndrome

D. Adrenal hyperplasia

See Answer in Part B → Q93

@Neet_pg_bot

Q94: A 25-year-old female with systemic lupus erythematosus presents with weight gain, moon facies, buffalo hump, and hirsutism. Which of the following is the most appropriate next investigation? (Q879210)

A. Serum ACTH and Serum cortisol levels

B. Serum ACTH and low-dose dexamethasone suppression test

C. Low-dose followed by high-dose dexamethasone suppression test

D. Serum ACTH and High-dose dexamethasone suppression test

See Answer in Part B → Q94

@Neet_pg_bot

Q95: A 10-year-old child is on long-term oral corticosteroid therapy for nephrotic syndrome. On examination, he has moon facies, truncal obesity, and a buffalo hump. There is no history of weight loss or hyperpigmentation. Most likely diagnosis is: (Q879213)

A. Addison’s disease

B. Cushing’s syndrome

C. Congenital adrenal hyperplasia

D. Hypothyroidism

See Answer in Part B → Q95

@Neet_pg_bot

Q96: PTH is increased in (Q879216)

A. Immobility

B. Familial hypocalciuric hypercalcemia

C. Vitamin D toxicity

D. Thiazide diuretics

See Answer in Part B → Q96

@Neet_pg_bot

Q97: A patient presents with complaints of sudden onset headache, palpitation, and profuse sweating . The patient has had multiple similar episodes in the past. During these episodes, the patient's blood pressure is elevated . A 24-hour urine metanephrine is elevated . What is the most likely diagnosis? (Q794485)

A. Addison's disease

B. Renal artery stenosis

C. Pheochromocytoma

D. Hyperthyroidism

See Answer in Part B → Q97

@Neet_pg_bot

Q98: 70 year old man presents with low back ache and progressive pallor. On work up, KFT is deranged. LFT is normal with normal level of Albumin, but gamma globulins are disproportionately increased. X ray spine shows multiple lytic lesions. Which of the following is the cell of origin of the diagnosis of this patient? (Q820435)

A. Lymphocyte

B. Plasma cell

C. Histiocytes

D. Monocytes

See Answer in Part B → Q98

@Neet_pg_bot

Q99: Calcitonin is a marker of which malignancy? (Q820447)

A. Papillary thyroid cancer

B. Follicular thyroid cancer

C. Medullary thyroid cancer

D. Anaplastic thyroid cancer

See Answer in Part B → Q99

@Neet_pg_bot

Q100: What should be done next in the management of a patient who is diabetic and presents with symptoms of vomiting and abdominal pain? Upon examination, the patient displays hyperventilation, sweet breath, and low blood pressure. The blood glucose level is 320 mg/dL, and urine ketones are detected. (Q793814)

A. IV insulin drip

B. IV soda-bicarbonate

C. Check blood ketone levels

D. IVF and check K+

See Answer in Part B → Q100

@Neet_pg_bot

Q101: A 25-year-old P1L1 woman is planning for her second child. She has been recently diagnosed with Grave's disease. Which of the following is the antithyroid drug to be used in early gestation? (Q793948)

A. Propylthiouracil

B. Methimazole

C. Carbimazole

D. All the above

See Answer in Part B → Q101

@Neet_pg_bot

Q102: Patient is identified as having a tumor in the ileum leading to urinary 5 HIAA being elevated. What is the diagnosis? (Q793830)

A. Carcinoid tumor

B. Neuroblastoma

C. Leiomyoma

D. Chromaffinoma

See Answer in Part B → Q102

@Neet_pg_bot

Q103: What is the probable diagnosis for a 50-year-old woman with a skin lesion visible in the provided image, which initially appeared small but has now spread to her entire limb and abdomen? Despite being on anticoagulation therapy, she has a longstanding history of diabetes and recurring deep vein thrombosis episodes. (Q793836)

A. Insulinoma

B. Gastrinoma

C. Glucagonoma

D. VIPoma



See Answer in Part B → Q103

@Neet_pg_bot

• [04_Nephrology] 021 Disorders Of Electrolyte Imbalance

« Back to Folder Directory

[04_Nephrology] 021 Disorders Of Electrolyte Imbalance — Quick Jump

Q1 (p. 346) *Q2 (p. 346)* *Q3 (p. 347)* *Q4 (p. 347)* *Q5 (p. 347)* *Q6 (p. 348)*
Q7 (p. 348) *Q8 (p. 349)* *Q9 (p. 349)* *Q10 (p. 350)* *Q11 (p. 350)* *Q12 (p. 350)*
Q13 (p. 351) *Q14 (p. 351)* *Q15 (p. 352)*

Q1: A 32-year-old woman with a history of Sjögren syndrome presents with excessive thirst and passage of large volumes of urine. Labs are show below: Serum sodium: 154 mEq/L Plasma osmolality: 310 mOsm/kg Urine osmolality: 120 mOsm/kg Serum chloride: 104 mEq/L Serum potassium: 4.1 mEq/L Serum magnesium: 1.9 mg/dL (normal) Serum calcium: 9.2 mg/dL ABG: pH = 7.35, pCO 2 = 38 mm Hg, HCO 3 =24 mEq/L Which of the following is the most likely diagnosis? (Q850514)

A. Bartter syndrome

B. Gitelman syndrome

C. Distal renal tubular acidification defect/ Type 1 RTA

D. Impaired tubular response to ADH

See Answer in Part B → Q1

@Neet_pg_bot

Q2: 25-year-old man presents with complaints of polyuria, polydipsia and dizziness on change of posture. He has a recent history of head trauma. Work up shows RBS: 100 mg/dl, serum sodium: 152 mEq/L, plasma osmolality: 308 mOsm/kg, Urine osmolality: 90 mOsm/kg. Serum copeptin levels are low and fail to rise with hypertonic saline stimulation. Which of the following is the most likely diagnosis? (Q850517)

A. Central diabetes insipidus

B. Nephrogenic diabetes insipidus

C. Primary polydipsia

D. Syndrome of inappropriate ADH secretion

See Answer in Part B → Q2

@Neet_pg_bot

Q3: Which of the following scenario will not lead to nephrogenic diabetes insipidus? (Q850518)

A. Patient of bipolar disorder on lithium

B. HIV patient with cerebral toxoplasmosis

C. Laxative abuse

D. Sickle cell anaemia

See Answer in Part B → Q3

@Neet_pg_bot

Q4: Which of the following causes will lead to nephrogenic diabetes insipidus? a. Hypercalcemia b. Toxoplasmosis c. Laxative abuse d. Sickle cell anaemia (Q850519)

A. a,b

B. a,b,c

C. b,c,d

D. a,c,d

See Answer in Part B → Q4

@Neet_pg_bot

Q5: 58-year-old male smoker, recently diagnosed with small-cell lung carcinoma, presents with cough and shortness of breath. On examination, he is alert and oriented (GCS 15/15), vitals are stable, and he appears euvolemic. Laboratory tests show:

Serum sodium: 120 mEq/L Serum osmolality: 255 mOsm/kg Urine osmolality: 650 mOsm/kg Which of the following is the most appropriate initial management for this patient? (Q850521)

A. 3% hypertonic saline bolus

B. 3% hypertonic saline infusion

C. Oral salt tablets with loop diuretics

D. Tolvaptan

See Answer in Part B → Q5

@Neet_pg_bot

Q6: 22-year-old female presents with recurrent episodes of muscle cramps, weakness, and fatigue. Blood pressure is 110/70 mmHg. ECG shows a QT interval of 500 msec. Labs show serum potassium: 2.8 mEq/L, serum magnesium: 1.1 mg/dL, serum calcium: normal, 24 hour urinary calcium: low, plasma renin activity: high, aldosterone: high. Diagnosis is? (Q850561)

A. Barter syndrome

B. Gitelman syndrome

C. Liddle syndrome

D. Gordon syndrome

See Answer in Part B → Q6

@Neet_pg_bot

Q7: 10-year-old boy presents with growth retardation and recurrent episodes of muscle weakness. BP is 100/60 mmHg. Labs reveal: serum potassium: 2.6 mEq/L, serum magnesium: normal, serum calcium: normal, 24-hour urinary calcium: high, plasma renin activity: high, aldosterone: high. What is the most likely diagnosis? (Q850565)

A. Bartter syndrome

B. Gitelman syndrome

C. Liddle syndrome

D. Gordon syndrome

See Answer in Part B → Q7

@Neet_pg_bot

Q8: 25-year-old HIV-positive male presents with a GTCS episode and headache. MRI brain shows calcification in basal ganglia. On admission, serum sodium is 120 mEq/L, serum osmolality is 260 mOsm/kg, urine osmolality is 620 mOsm/kg, and urine sodium is 48 mEq/L. There is no edema, normal JVP and normal BP with no significant change on positional variation. Diagnosis? (Q850569)

A. Cerebral salt wasting

B. SIADH

C. Adrenal insufficiency

D. Psychogenic polydipsia

See Answer in Part B → Q8

@Neet_pg_bot

Q9: A patient is found to have hypotonic euvolemic hyponatremia with inappropriately concentrated urine. Which of the following respiratory conditions is least likely to cause this disorder? (Q890249)

A. Small cell carcinoma of the lung

B. Asthma

C. Respiratory failure requiring positive-pressure ventilation

D. Primary pulmonary emphysema

See Answer in Part B → Q9

@Neet_pg_bot

Q10: A 45-year-old man presents with headache, nausea and confusion 5 days after starting a new medication. He is clinically euvolemic. His investigations reveal: Serum sodium - 116 mEq/L Plasma osmolality - Low Urine osmolality - Inappropriately high Which of the following drugs is least likely to be responsible for this condition? (Q890250)

A. Carbamazepine

B. Demeclocycline

C. Desmopressin

D. Selective serotonin reuptake inhibitors (SSRIs)

See Answer in Part B → Q10

@Neet_pg_bot

Q11: A 60-year-old man presents with progressive headache, nausea, lethargy and confusion. Examination shows no signs of dehydration or oedema. Investigations reveal: Serum sodium: 122 mEq/L Plasma osmolality: Low Urine osmolality: Inappropriately high Urine sodium: >40 mmol/L Which of the following tumours is least likely to be associated with this condition? (Q890251)

A. Small cell carcinoma of the lung

B. Thymoma

C. Ewing’s sarcoma

D. Chromophobe pituitary adenoma

See Answer in Part B → Q11

@Neet_pg_bot

Q12: A 38-year-old man is admitted following a subarachnoid haemorrhage. On day 4 of hospitalisation, he develops dizziness and postural hypotension. He is passing large volumes of urine. Laboratory evaluation shows: Serum sodium: 118 mEq/L Urine sodium: 140 mmol/L Urine output: High Central venous pressure: Low Which of the following is the most likely diagnosis? (Q890252)

A. Syndrome of inappropriate ADH secretion

B. Cerebral salt wasting

C. Central diabetes insipidus

D. Primary polydipsia

See Answer in Part B → Q12

@Neet_pg_bot

Q13: A 58-year-old man is brought to the emergency department with a sudden onset of confusion, repeated vomiting and headache. Examination shows no signs of dehydration or oedema. His laboratory investigations reveal: Serum sodium - 114 mEq/L Plasma osmolality - Low Urine osmolality - Inappropriately high Urine sodium - 52 mmol/L Which of the following is the most appropriate initial management? (Q890253)

A. Infusion of hypertonic (3%) saline

B. Infusion of hypotonic (0.45%) saline

C. Infusion of normal (0.9%) saline

D. Administration of DDAVP

See Answer in Part B → Q13

@Neet_pg_bot

Q14: A 62-year-old man with small-cell carcinoma of the lung has persistent asymptomatic hyponatremia (Na■ 124-128 mEq/L) for 3 weeks. He is clinically euvolemic and has been poorly compliant with fluid restriction. Which of the following

is the drug of choice for long-term management? (Q890254)

A. Furosemide

B. Tolvaptan

C. Demeclocycline

D. Fludrocortisone

See Answer in Part B → Q14

@Neet_pg_bot

Q15: A 56-year-old man with a history of chronic alcoholism is admitted with altered sensorium. His serum sodium is 110 mEq/L. He is treated in a local hospital and discharged after 3 days. Two days later, he presents again with progressive quadriparesis, slurred speech, difficulty in swallowing, and preserved consciousness. His Brain MRI shows a symmetric lesion in the central pons. What is the most likely diagnosis? (Q890255)

A. Wernicke encephalopathy

B. Central pontine myelinolysis

C. Acute disseminated encephalomyelitis

D. Brainstem infarction

See Answer in Part B → Q15

@Neet_pg_bot

• [04_Nephrology] 022 Electrolyte Imbalance

« Back to Folder Directory

[04_Nephrology] 022 Electrolyte Imbalance — Quick Jump

Q1 (p. 353)	*Q2 (p. 353)*	*Q3 (p. 354)*	*Q4 (p. 354)*	*Q5 (p. 354)*	*Q6 (p. 355)*
Q7 (p. 355)	*Q8 (p. 355)*	*Q9 (p. 356)*	*Q10 (p. 356)*	*Q11 (p. 356)*	*Q12 (p. 357)*
Q13 (p. 357)	*Q14 (p. 358)*	*Q15 (p. 358)*	*Q16 (p. 358)*	*Q17 (p. 359)*	*Q18 (p. 359)*
Q19 (p. 359)	*Q20 (p. 360)*	*Q21 (p. 360)*	*Q22 (p. 360)*	*Q23 (p. 361)*	*Q24 (p. 361)*
Q25 (p. 361)	*Q26 (p. 362)*	*Q27 (p. 362)*	*Q28 (p. 363)*	*Q29 (p. 363)*	*Q30 (p. 363)*

Q1: Which of the following conditions is least likely to be associated with hyperphosphatemia? (Q850713)

A. Hypoparathyroidism

B. Pseudohypoparathyroidism

C. Pseudo-pseudo-hypoparathyroidism

D. Chronic kidney disease

See Answer in Part B → Q1

@Neet_pg_bot

Q2: Which of the following causes non anion gap acidosis? (Q850747)

A. Diarrhea

B. Ethylene glycol poisoning

C. Starvation

D. Glue sniffing

See Answer in Part B → Q2

@Neet_pg_bot

Q3: First line management of life-threatening hypercalcemia? (Q850744)

A. Normal saline

B. Lasix infusion

C. Hemodialysis

D. Zolendronate

See Answer in Part B → Q3

@Neet_pg_bot

Q4: Hypomagenesemia is seen in all except? (Q850743)

A. Renal failure

B. Alcoholism

C. Gitelman syndrome

D. Amphotericin B

See Answer in Part B → Q4

@Neet_pg_bot

Q5: A 25 year old lady with eclampsia was given magnesium sulfate by the Pritchard regimen. She developed areflexia of bilateral ankle jerks and knee jerks with a respiratory rate of 8/min. Which of the following will be used? (Q850742)

A. Calcium gluconate

B. Calcium carbonate

C. Sevelamer

D. Lanthanum carbonate

See Answer in Part B → Q5

@Neet_pg_bot

Q6: A 5 year old child with jaw swelling is diagnosed with Burkitt lymphoma based on histopathology reports. You have started chemotherapy. Which of the following electrolyte imbalance will not be seen in this case? (Q850740)

A. Hyperphosphatemia

B. Hyperkalemia

C. Hypocalcemia

D. Hypernatremia

See Answer in Part B → Q6

@Neet_pg_bot

Q7: Euvolemic hyponatremia is seen with? (Q850738)

A. Secondary Addison disease

B. Primary Addison disease

C. Cushing syndrome

D. Congestive heart failure

See Answer in Part B → Q7

@Neet_pg_bot

Q8: Tolvaptan can be used in management of all except? (Q850737)

A. Hypervolemic hyponatremia

B. Hypovolemic hyponatremia

C. Euvolemic hyponatremia

D. SIADH

See Answer in Part B → Q8

@Neet_pg_bot

Q9: A 62-year-old man is brought to the emergency department with sudden onset confusion, vomiting, and a generalized tonic-clonic seizure. He has a history of small cell lung carcinoma and was recently started on chemotherapy. On examination, he is drowsy and disoriented. Laboratory investigations reveal a serum sodium level of 112 mEq/L.What is the most appropriate immediate management for this patient? (Q850734)

A. Bolus of 3% saline

B. Slow correction with 3% saline over 24 hours

C. Slow correction with 3% saline over 46 hours

D. Water restriction with oral salt capsules

See Answer in Part B → Q9

@Neet_pg_bot

Q10: While drawing blood for estimation of ionized calcium, all of the following pre-analytical factors can alter the test result except? (Q850732)

A. Prolonged tourniquet application

B. Isometric hand exercise during sampling

C. Exposure of sample to air before analysis

D. Haemolysis of sample

See Answer in Part B → Q10

@Neet_pg_bot

Q11: Which of the following causes a steroid-responsive hypercalcemia? (Q850730)

A. Vitamin D intoxication

B. Multiple myeloma

C. Lung cancer

D. Parathyroid carcinoma

See Answer in Part B → Q11

@Neet_pg_bot

Q12: Which of the following is correct about Chvostek sign? (Q850724)

A. Twitching of the ipsilateral perioral levator and zygomaticus muscles

B. Twitching of the ipsilateral corrugator cili and zygomaticus muscles

C. Twitching of the contralateral perioral levator and zygomaticus muscles

D. Twitching of the contralateral corrugator cili and zygomaticus muscles

See Answer in Part B → Q12

@Neet_pg_bot

Q13: Post thyroid surgery patient has developed muscle cramps followed by breathing difficulty due to bronchospasm. ECG shows QTc prolongation. Which of the following would be used for management? (Q850721)

A. KCL infusion 40meq/L

B. KCL infusion 40 meq/L with salbutamol nebulization

C. 10 ml of 10% calcium gluconate diluted in 50 ml of 5% dextrose over 10 min

D. 10 ml of 10% calcium gluconate over 1 min

See Answer in Part B → Q13

@Neet_pg_bot

Q14: Which of the following conditions classically presents with elevated serum calcium, normal phosphate, and normal serum alkaline phosphatase (SAP)? (Q850718)

A. Osteoporosis

B. Paget disease

C. Multiple myeloma

D. Primary Hyperparathyroidism

See Answer in Part B → Q14

@Neet_pg_bot

Q15: Which of the following is the leading cause of hypoparathyroidism? (Q850716)

A. Autoimmunity

B. Hemochromatosis

C. Wilson disease

D. Riedel Struma

See Answer in Part B → Q15

@Neet_pg_bot

Q16: 30-year-old patient came in with a severe headache and seizure episode. Serum sodium on admission was 98 meq/L. You have started correction with 3% saline and now after 24 hours of infusion sodium is 110 meq/L. The patient develops quadriparesis and altered sensorium. Which investigation will you perform now? (Q850574)

A. MRI Head

B. LP for CSF

C. Brainstem evoked potentials

D. EEG

See Answer in Part B → Q16

@Neet_pg_bot

Q17: Leading cause of hypercalcemia in hospitalized patients? (Q850709)

A. Sarcoidosis

B. Oat cell cancer of lung

C. Non small cell cancer of lung

D. Inferior parathyroid adenoma

See Answer in Part B → Q17

@Neet_pg_bot

Q18: Which of the following will have no role in immediate management of acute onset hyperkalemia? (Q850670)

A. Albuterol nebulization

B. Soda bicarbonate

C. Sodium polystyrene sulfonate

D. 50 ml of 50% dextrose with 10 units of regular insulin

See Answer in Part B → Q18

@Neet_pg_bot

Q19: All of the following cause hyperkalemia except? (Q850665)

A. Yellow oleander

B. Prolonged immobilization

C. Autoimmune polyglandular syndrome

D. Cushing syndrome

See Answer in Part B → Q19

@Neet_pg_bot

Q20: All of the following cause hypokalemia except? (Q850663)

A. Thyrotoxicosis

B. Salbutamol

C. Lupus nephritis

D. Conn syndrome

See Answer in Part B → Q20

@Neet_pg_bot

Q21: Which of the following causes hypokalemia? (Q850659)

A. Tumor lysis syndrome

B. Crush injury

C. Hemolysis

D. Massive transfusion

See Answer in Part B → Q21

@Neet_pg_bot

Q22: Which of the following is a cause of chloride-resistant metabolic alkalosis? (Q850657)

A. Chronic vomiting

B. Bartter syndrome

C. Infantile hypertrophic pyloric stenosis

D. Gastric outlet obstruction

See Answer in Part B → Q22

@Neet_pg_bot

Q23: Which of the following is not a cause of chloride responsive metabolic alkalosis? (Q850651)

A. Gastric adenocarcinoma

B. IHPS

C. Ascites

D. Chronic vomiting

See Answer in Part B → Q23

@Neet_pg_bot

Q24: Which of the following is fluid of choice for metabolic alkalosis? (Q850643)

A. Normal saline

B. Ringer lactate

C. 5% dextrose

D. Isolyte-P

See Answer in Part B → Q24

@Neet_pg_bot

Q25: For a patient of acute onset hypernatremia Na= 158 meq/L with confusion and seizures, which of the following fluids is not to be used? (Q850641)

A. 5% Dextrose

B. N/2 saline

C. N/4 saline

D. Normal saline

See Answer in Part B → Q25

@Neet_pg_bot

Q26: Which of the following is correct about the rate of correction for chronic hyponatremia? (Q850630)

A. 4-6 meq/ d

B. 6-8 meq/d

C. 8-10 meq/d

D. 10-12 meq/d

See Answer in Part B → Q26

@Neet_pg_bot

Q27: A 60-kg male runner develops cramps, disorientation, and seizures after completing a marathon. On admission, serum sodium is 120 mEq/L and serum potassium is 3.2 meq/L. What is the approximate sodium deficit in this patient? (Q850627)

A. 180 meq

B. 360 meq

C. 420 meq

D. 720 meq

See Answer in Part B → Q27

@Neet_pg_bot

Q28: Which of the following is not a cause of hypervolemic hyponatremia? (Q850599)

A. HFrEF

B. CLD

C. Nephrotic syndrome

D. Atypical pneumonia

See Answer in Part B → Q28

@Neet_pg_bot

Q29: Which of the following is not seen in patients with hypokalemia? (Q850577)

A. Ileus

B. Polyuria

C. Atrial arrhythmias

D. Metabolic acidosis

See Answer in Part B → Q29

@Neet_pg_bot

Q30: Sudden shrinkage of brain cells in acute hypernatremia encountered in neonate on day 2 of life can lead to development of: (Q850576)

A. Intra- parenchymal bleeding

B. Osmotic demyelination syndrome

C. Paralytic ileus

D. Tachyarrhythmias

See Answer in Part B → Q30

@Neet_pg_bot

• [04_Nephrology] 023 Ciliopathies Pkd Ttp

« Back to Folder Directory

[04_Nephrology] 023 Ciliopathies Pkd Ttp — Quick Jump

Q1 (p. 365) *Q2 (p. 365)* *Q3 (p. 366)* *Q4 (p. 366)* *Q5 (p. 366)* *Q6 (p. 367)*
Q7 (p. 367) *Q8 (p. 367)* *Q9 (p. 368)* *Q10 (p. 369)* *Q11 (p. 369)* *Q12 (p. 370)*
Q13 (p. 370)

Q1: Which of the following is not correct about thrombotic thrombocytopenic purpura? (Q850750)

A. Deficiency of ultra large multimers of vWF

B. Microangiopathic haemolytic anaemia

C. Deficiency of ADAMTS13

D. Treated with plasma exchanges

See Answer in Part B → Q1

@Neet_pg_bot

Q2: A 32-year-old woman presents with fever, confusion, and generalized weakness for 3 days. On examination, she has pallor, multiple petechiae, and a right-sided facial droop. Laboratory investigations reveal: Hemoglobin: 7.8 g/dL Platelet count: 25,000/mm³ Peripheral smear shows numerous schistocytes LDH: markedly elevated Creatinine: 1.2 mg/dL Which of the following is the most likely diagnosis? (Q850758)

A. Thrombotic Thrombocytopenic Purpura

B. Henoch–Schönlein Purpura

C. Haemolytic Uremic Syndrome

D. Tubulointerstitial Kidney Disease

See Answer in Part B → Q2

@Neet_pg_bot

Q3: 30-year-old man presents with dull aching bilateral flank pain. BP is 160/100 mmHg. Family history reveals that his father died of brain haemorrhage at age 60. What is the first investigation that should be done in this case? (Q850759)

A. NCCT: KUB

B. CECT: KUB

C. Ultrasound abdomen

D. DTPA scan

See Answer in Part B → Q3

@Neet_pg_bot

Q4: What is the leading cause of death in ADPKD? (Q850760)

A. Renal failure

B. Rupture of berry aneurysm

C. Renal cell cancer

D. CV mortality

See Answer in Part B → Q4

@Neet_pg_bot

Q5: In a follow-up visit of a 40-year-old man diagnosed with ADPKD based on Ravine criteria, which investigation should be done to screen for intracranial aneurysm and risk of subarachnoid bleeding? (Q850761)

A. Lumbar puncture

B. MRA

C. NCCT head

D. Transcranial doppler

See Answer in Part B → Q5

@Neet_pg_bot

Q6: Which is the most common cardiac valvular lesion seen in patients of ADPKD? (Q850762)

A. Mitral valve prolapse

B. Tricuspid valve prolapse

C. Pulmonic insufficiency

D. Tricuspid insufficiency

See Answer in Part B → Q6

@Neet_pg_bot

Q7: Which is the most common cardiac valvular lesion seen in patients of carcinoid syndrome? (Q850763)

A. Tricuspid insufficiency and pulmonic stenosis

B. Tricuspid stenosis and pulmonic insufficiency

C. Mitral insufficiency and pulmonic stenosis

D. Mitral stenosis and pulmonic insufficiency

See Answer in Part B → Q7

@Neet_pg_bot

Q8: Which of the following is not correct about autosomal dominant tubulointerstitial kidney disease? (Q850764)

A. Enlarged kidneys

B. Medullary cysts

C. UMOD gene defect

D. Increased incidence of gout

See Answer in Part B → Q8

@Neet_pg_bot

Q9: 5-year-old child developed vomiting, cramping and bloody diarrhea that was managed with ORS and antibiotics. After 1 week the patient is admitted due to anuria for the last 24 hours and encephalopathy. Work up shows Hb 7gm%, TLC 15000 / cu.mm, platelet count 50,000 /cu.mm, LDH is elevated and peripheral smear is shown below. What is the diagnosis? (Q850765)

A. Hemolytic uremic syndrome (HUS)

B. Thrombotic thrombocytopenic purpura (TTP)

C. Acute tubular necrosis (ATN)

D. Henoch–Schönlein purpura (HSP)

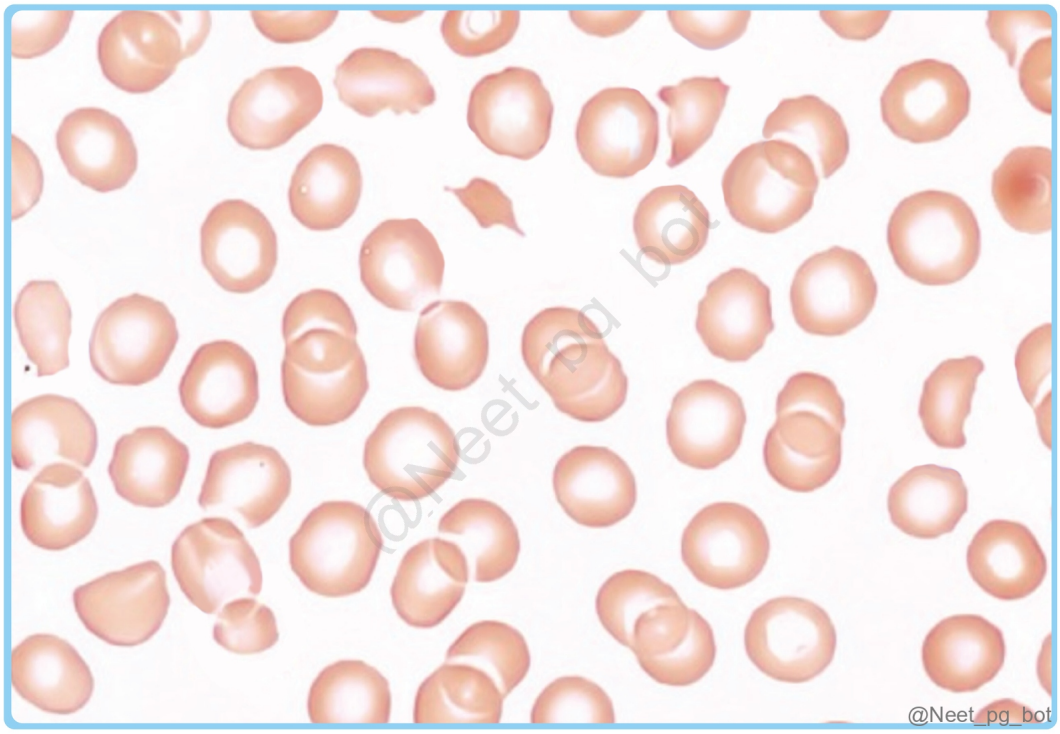

See Answer in Part B → Q9

@Neet_pg_bot

Q10: The leading extra-renal manifestation of autosomal recessive polycystic kidney disease is? (Q850766)

A. Hepatic cysts

B. Hepatic fibrosis

C. Berry aneurysm

D. Arachnoid cysts

See Answer in Part B → Q10

@Neet_pg_bot

Q11: Which of the following is correct about genetic aspects of Autosomal recessive polycystic kidney disease? (Q850767)

A. PKHD1 gene, chromosome 6

B. PKD1 gene, chromosome 16

C. PKD2 gene, chromosome 4

D. UMOD gene, chromosome 16

See Answer in Part B → Q11

@Neet_pg_bot

Q12: 35-year-old man is treated with amoxicillin + clavulanic acid for lobar pneumonia. After 10 days of therapy, he develops fever, maculopapular rash, and decreased urine output. Labs show serum creatinine of 3.2 mg/dL. Urinalysis reveals mild proteinuria, microscopic hematuria, and numerous WBCs. Wright's stain of the urine demonstrates eosinophiluria. Which of the following is the most likely diagnosis? (Q850768)

A. Acute tubular necrosis

B. Acute interstitial nephritis

C. Rapidly progressive glomerulonephritis

D. Nephrolithiasis

See Answer in Part B → Q12

@Neet_pg_bot

Q13: All of the following are correct about Renal vein thrombosis except? (Q850769)

A. Seen with membranous glomerulopathy

B. Associated with ADAMTS 13 deficiency

C. CT angiography is 100% sensitive

D. Oral anticoagulation is first line treatment

See Answer in Part B → Q13

• [04_Nephrology] 024 Kidney Urine Analysis

« Back to Folder Directory

[04_Nephrology] 024 Kidney Urine Analysis — Quick Jump

Q1 (p. 372) *Q2 (p. 372)* *Q3 (p. 373)* *Q4 (p. 373)* *Q5 (p. 374)* *Q6 (p. 375)*
Q7 (p. 375) *Q8 (p. 375)* *Q9 (p. 376)* *Q10 (p. 376)* *Q11 (p. 376)* *Q12 (p. 377)*
Q13 (p. 377)

Q1: A known Type II DM, 70 year old patient was under medication. He aslo takes Telmisartan. Patients current lab values: HbA1c- 8.5, eGFR- 50 mL/min/1.73 m. Normal potassium levels. What is the next appropriate step to decrease the risk of further eGFR decrement? (Q882282)

A. Shift to Ramipril

B. Increase the dose of antidiabetic meds

C. Start Carvedilol

D. Increase Telmisartan dose

See Answer in Part B → Q1

@Neet_pg_bot

Q2: Oval fat bodies in urine are seen in all of the following conditions except? (Q851037)

A. Minimal change disease

B. Focal segmental glomerulosclerosis

C. Membranous nephropathy

D. Fat embolism syndrome

See Answer in Part B → Q2

@Neet_pg_bot

Q3: 28-year-old man presents to the emergency department after ingesting a large quantity of over-the-counter cough syrup in a suicide attempt. He complains of severe abdominal pain and confusion. ABG shows high anion gap metabolic acidosis. Urinalysis microscopy is shown below. Which of the following is the most appropriate initial treatment? (Q851038)

A. Sodium bicarbonate infusion

B. Hemodialysis

C. Fomepizole

D. N-acetylcysteine

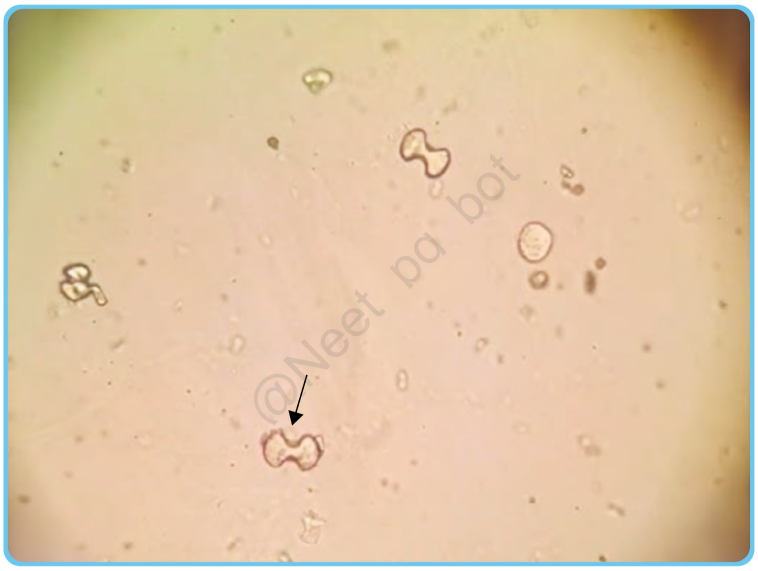

@Neet_pg_bot

See Answer in Part B → Q3

@Neet_pg_bot

Q4: 25-year-old patient is having recurrent kidney stones. Urine microscopy is shown below. Which of the following drugs will prevent recurrence of these kidney stones.

(Q851039)

A. Thiazides

B. Furosemide

C. Tiopronin

D. Mercaptopurine



@Neet_pg_bot

See Answer in Part B → Q4

@Neet_pg_bot

Q5: Eosinophiluria is typically seen in all of the following conditions except: (Q851040)

A. Allergic interstitial nephritis

B. Atheroembolic kidney disease

C. Pyelonephritis

D. Tubulointerstitial nephritis

See Answer in Part B → Q5

@Neet_pg_bot

Q6: The presence of broad casts on urine microscopy is most suggestive of which condition? (Q851041)

A. Acute tubular necrosis

B. Acute interstitial nephritis

C. Chronic kidney disease

D. Thrombotic thrombocytopenic purpura

See Answer in Part B → Q6

@Neet_pg_bot

Q7: What is the diagnostic cutoff used to define hematuria on urine microscopy? (Q851042)

A. > 1 RBC/ HPF in centrifuged sediment X 3 reports

B. > 5 RBC/ HPF in centrifuged urine sediment X 3 reports

C. > 50 RBC/ HPF in centrifuged urine sediment X 3 reports

D. > 500 RBC/ HPF in centrifuged urine sediment X 3 reports

See Answer in Part B → Q7

@Neet_pg_bot

Q8: What is the hallmark feature of glomerular hematuria? (Q851043)

A. RBC casts

B. Dysmorphic RBC

C. Low C3

D. Cola color urine

See Answer in Part B → Q8

@Neet_pg_bot

Q9: Muddy brown granular casts are seen in? (Q851044)

A. ATN

B. CGN

C. AIN

D. AGN

See Answer in Part B → Q9

@Neet_pg_bot

Q10: What is the recommended screening test for diabetic nephropathy? (Q851045)

A. 24-hour urine protein estimation

B. Serum creatinine

C. Spot urine albumin-to-creatinine ratio

D. Urine dipstick for protein

See Answer in Part B → Q10

@Neet_pg_bot

Q11: 24-year-old man presents with red-colored urine after trauma due to being repeatedly punched in the abdomen during a street fight. On keeping the urine sample standing, the color clears in the next few hours. Which of the following is the most likely cause? (Q851046)

A. Hematuria

B. Hemoglobinuria

C. Myoglobinuria

D. Porphyria

See Answer in Part B → Q11

@Neet_pg_bot

Q12: 9-year-old boy presents with his urine turned dark red after playing football. On examination, he has no hepatosplenomegaly. Laboratory studies reveal normal blood lactate after forearm exercise testing but elevated creatine kinase. Which of the following is the cause? (Q851047)

A. Orthostatic haematuria

B. Muscle glycogen phosphorylase deficiency

C. Trauma

D. Acid maltase deficiency

See Answer in Part B → Q12

@Neet_pg_bot

Q13: 35-year-old woman diagnosed with rheumatoid arthritis presents with swelling of the face and legs for 2 weeks. Urine is frothy. On urine microscopy, the following are observed: 3 RBC per HPF Oval fat bodies Maltese crosses under polarized light 4+ proteinuria Which of the following is the most likely diagnosis? (Q851048)

A. Acute glomerulonephritis

B. Minimal change disease

C. Membranous glomerulopathy

D. Membranoproliferative glomerulopathy

See Answer in Part B → Q13

@Neet_pg_bot

• [04_Nephrology] 025 Aki Diabetic Nephropathy Renal Stones

« Back to Folder Directory

[04_Nephrology] 025 Aki Diabetic Nephropathy Renal Stones — Quick Jump

Q1 (p. 379)	*Q2 (p. 379)*	*Q3 (p. 380)*	*Q4 (p. 380)*	*Q5 (p. 380)*	*Q6 (p. 381)*
Q7 (p. 381)	*Q8 (p. 382)*	*Q9 (p. 382)*	*Q10 (p. 383)*	*Q11 (p. 384)*	*Q12 (p. 385)*
Q13 (p. 386)	*Q14 (p. 386)*	*Q15 (p. 386)*	*Q16 (p. 387)*	*Q17 (p. 387)*	*Q18 (p. 387)*
Q19 (p. 388)	*Q20 (p. 388)*	*Q21 (p. 389)*	*Q22 (p. 389)*		

Q1: 65-year-old man with hypertension and diabetes undergoes a coronary angiography. Two days later, his serum creatinine rises from 1.2 mg/dL to 2.0 mg/dL. Urine output is normal. Urinalysis shows muddy brown casts.Which of the following is the most likely diagnosis? (Q851006)

A. Contrast-associated AKI

B. Athero-embolic kidney disease

C. Pre-renal Azotemia

D. Acute glomerulonephritis

See Answer in Part B → Q1

@Neet_pg_bot

Q2: 5-year-old child with chronic kidney disease presents with bow legs. He has low sunlight exposure. Laboratory investigations reveal: Serum calcium: 7 mg/dL (low) Serum phosphate: 6.3 mg/dL (elevated) Alkaline phosphatase: Elevated Vitamin D3 levels: Low What is the most appropriate next step in management? (Q851016)

A. Phosphate binder

B. Calcium acetate + Vitamin D3

C. Only vitamin D3

D. Haemodialysis

See Answer in Part B → Q2

@Neet_pg_bot

Q3: Nephrologist has started empirical hemodialysis in a patient with sepsis whose BUN is 150 mg/dl and progressive decline in renal function. Which of the following is the leading side effect anticipated in this case? (Q851015)

A. Infection

B. Hypotension

C. Cerebral oedema

D. Hyponatremia

See Answer in Part B → Q3

@Neet_pg_bot

Q4: All of the following drugs are useful in reducing progression of Diabetic Nephropathy except? (Q851014)

A. ACEi

B. Finrenone

C. Sitagliptin

D. Empagliflozin

See Answer in Part B → Q4

@Neet_pg_bot

Q5: Which of the following are common complications of acute kidney injury ? a. Bleeding b. Anemia c. Pericardial effusion d. Hypomagnesemia (Q851013)

A. a,b

B. b,c

C. a,b,c

D. a,b,c,d

See Answer in Part B → Q5

@Neet_pg_bot

Q6: Kidney injury molecule -1 is a transmembrane protein expressed in (Q851012)

A. PCT

B. DCT

C. Collecting duct

D. Pyramids

See Answer in Part B → Q6

@Neet_pg_bot

Q7: 25-year-old patient is having recurrent kidney stones. Urine microscopy is shown below. Which of the following drugs will prevent recurrence of these kidney stones. (Q851011)

A. Thiazides

B. Furosemide

C. Tiopronin

D. Mercaptopurine

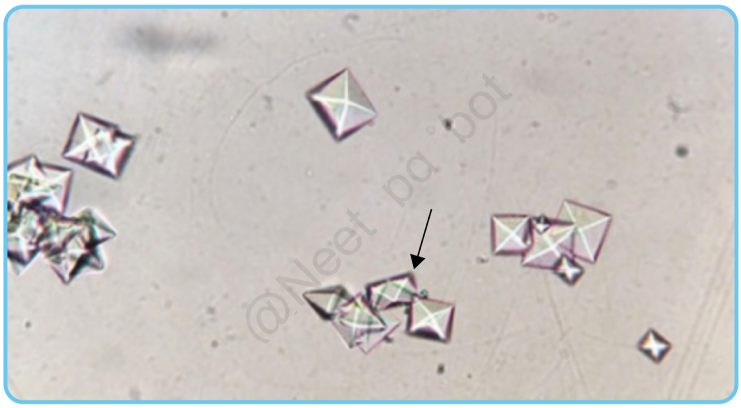

@Neet_pg_bot

See Answer in Part B → Q7

@Neet_pg_bot

Q8: RBC casts are seen in all except? (Q851010)

A. Acute glomerulonephritis

B. Malignant hypertension

C. Thrombotic microangiopathy

D. Mismatched blood transfusion

See Answer in Part B → Q8

@Neet_pg_bot

Q9: The patient is having recurrent kidney stones. Work up shows 24-hour urinary calcium excretion is three times normal and envelope shaped crystals are found in

urine. The current stone in the renal pelvis was 1.5 cm and was successfully managed with ESWL. Which of the following dietary advice is best suited for this patient? (Q851009)

A. Restriction of calcium in diet

B. Restriction of sodium in diet

C. Restriction of calories and vitamin D3 in diet

D. Restriction of carbonated energy drinks

See Answer in Part B → Q9

@Neet_pg_bot

Q10: Which of the following is the leading cause of kidney stones whose crystals are shown below? (Q851008)

A. Proteus mirabilis infection

B. Idiopathic hypercalciuria

C. Idiopathic hyperoxaluria

D. Defective transport of basic amino acids



@Neet_pg_bot

See Answer in Part B → Q10

@Neet_pg_bot

Q11: Which of the following is the leading cause of kidney stones whose crystals are shown below? (Q851007)

A. Proteus mirabilis infection

B. Idiopathic hypercalciuria

C. Idiopathic hyperoxaluria

D. Defective transport of basic amino acids

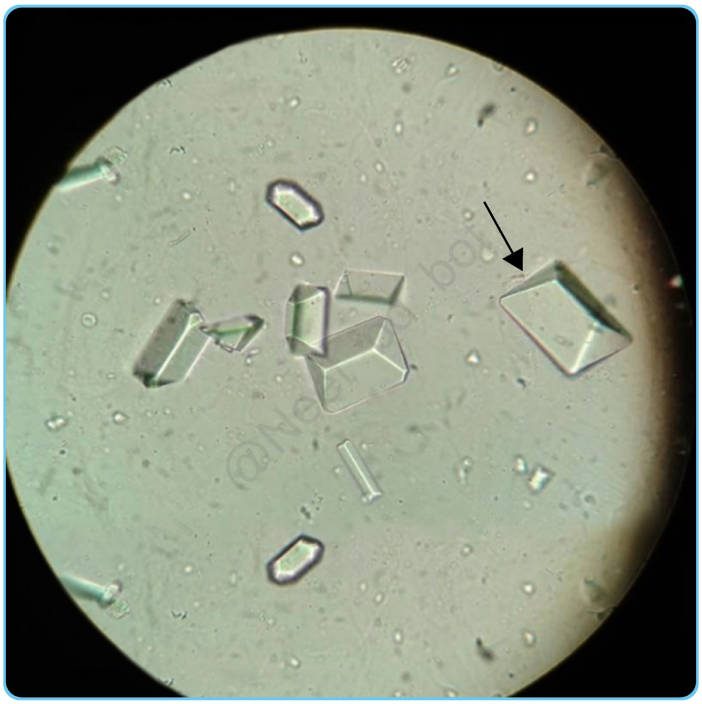

@Neet_pg_bot

See Answer in Part B → Q11

@Neet_pg_bot

Q12: A 65-year-old man is admitted with a CURB score of 3 for pneumonia for the past 2 days. His urine output in the last 24 hours is 100 ml and BP is 90/60 mm Hg on Norepinephrine infusion. p02/FiO2 is 350. Labs are: Serum creatinine: 3.5 mg/dL Urine output: 300 mL/24 hr Urine sodium: 45 mEq/L Urine osmolality: 320 mOsm/kg pH= 7.2, pCO2= 30 mm Hg, HCO3 = 10 meq/ L Which of the following is the correct diagnosis of this patient? (Q850995)

A. Acute interstitial nephritis

B. Acute tubular necrosis

C. Acute respiratory distress syndrome

D. Systemic inflammatory response syndrome

See Answer in Part B → Q12

@Neet_pg_bot

Q13: A 4-year-old child weighing 12 kg presents for routine evaluation. His height is 100 cm, and laboratory testing shows a serum creatinine level of 1 mg/dL. Using the updated bedside Schwartz formula (eGFR = 0.41 × height in cm / serum creatinine), what is the estimated GFR of this child? (Q851005)

A. 20 mL/min/1.73 m²

B. 32 mL/min/1.73 m²

C. 41 mL/min/1.73 m²

D. 55 mL/min/1.73 m²

See Answer in Part B → Q13

@Neet_pg_bot

Q14: Non oliguric acute kidney injury is seen with (Q851004)

A. Kanamycin

B. Captopril

C. Telmisartan

D. Cyclosporine

See Answer in Part B → Q14

@Neet_pg_bot

Q15: A 35 year old man got electrocuted from a high tension cable while flying kites and presents with extensive burns. 12 hours after admission urine output is 100 ml, urine heme is positive with few RBC and CK is elevated. Diagnosis is? (Q851003)

A. Rhabdomyolysis

B. Pre- renal AKI due to hypoperfusion of kidneys

C. Post renal AKI due to debris occluding ureters

D. Hematuria due to renal injury by electrocution

See Answer in Part B → Q15

@Neet_pg_bot

Q16: All of the following are causes of pre renal AKI except? (Q851002)

A. NSAIDS

B. ACEI

C. Amphotericin B

D. Cyclosporine

See Answer in Part B → Q16

@Neet_pg_bot

Q17: Neutrophil Gelatinase-Associated Lipocalin is used as a biomarker for? (Q851001)

A. Immunodeficiency

B. Kidney injury

C. Pancreatic injury

D. Sepsis

See Answer in Part B → Q17

@Neet_pg_bot

Q18: Which of the following electrolyte abnormalities is not correct about patient in acute kidney injury due to acute glomerulonephritis? (Q851000)

A. Hyponatremia

B. Normal anion gap metabolic acidosis

C. Hyperkalemia

D. Hyperphosphatemia

See Answer in Part B → Q18

@Neet_pg_bot

Q19: Sodium nitroprusside test on urine is positive in which of the following kidney stones? (Q850999)

A. Calcium oxalate stones

B. Uric acid stones

C. Cystinuria

D. Struvite stones

See Answer in Part B → Q19

@Neet_pg_bot

Q20: 72-year-old man with a history of coronary artery disease underwent coronary angiography 2 weeks ago. He now presents with progressive renal dysfunction, livedo reticularis over the lower limbs, and blue-toe lesions. Laboratory investigations show: Serum creatinine: 3.2 mg/dL (baseline 1.1 mg/dL) Eosinophilia: 12% Urinalysis: mild proteinuria, bland sediment Which of the following is the most likely diagnosis? (Q850998)

A. Acute tubular necrosis

B. Athero-embolic kidney disease

C. Rapidly progressive glomerulonephritis

D. Post-renal obstruction

See Answer in Part B → Q20

@Neet_pg_bot

Q21: 20-year-old patient with T1DM comes for a follow up visit. Which of the following is the earliest finding in diabetic nephropathy? (Q850997)

A. Hyperfiltration

B. Diffuse glomerulosclerosis

C. Kimmel stein Wilson changes

D. Armani ebstein changes

See Answer in Part B → Q21

@Neet_pg_bot

Q22: A 60-year-old diabetic patient underwent coronary angiography for suspected triple vessel disease. After the procedure he develops oliguria and rising serum creatinine. Labs are Baseline serum creatinine: 1.5 mg/dL Current serum creatinine: 3.0 mg/dL Urine output: 0.35 mL/kg/hr for 18 hours According to KDIGO criteria, what is the stage of acute kidney injury in this patient? (Q850996)

A. Stage 1

B. Stage 2

C. Stage 3

D. Stage 4

See Answer in Part B → Q22

@Neet_pg_bot

• [04_Nephrology] 026 Chronic Kidney Disease

« Back to Folder Directory

[04_Nephrology] 026 Chronic Kidney Disease — Quick Jump

Q1 (p. 390)	*Q2 (p. 390)*	*Q3 (p. 391)*	*Q4 (p. 391)*	*Q5 (p. 391)*	*Q6 (p. 392)*
Q7 (p. 392)	*Q8 (p. 392)*	*Q9 (p. 393)*	*Q10 (p. 393)*	*Q11 (p. 394)*	*Q12 (p. 394)*
Q13 (p. 394)	*Q14 (p. 395)*	*Q15 (p. 395)*	*Q16 (p. 395)*	*Q17 (p. 396)*	*Q18 (p. 396)*

Q1: A 60-year-old type 2 Diabetic patient with eGFR of 30 ml/min came with a headache and shortness of breath on climbing stairs fast. BP is 160/100 mmHg. Which of the following combination would not be suitable for this case profile? (Q850988)

A. ACEi with Furosemide

B. ACEi with Amiloride

C. ACEi with Metazolone

D. ACEi with Patiromer

See Answer in Part B → Q1

@Neet_pg_bot

Q2: A 46-year-old man, 6 months after kidney transplantation, presents with malaise, rising creatinine, oliguria, and edema. Urine cytology shows renal tubular epithelial cells with large basophilic intranuclear inclusions. Which organism is the most likely cause? (Q869059)

A. Cytomegalovirus

B. Epstein–Barr virus

C. BK polyomavirus

D. Adenovirus

See Answer in Part B → Q2

@Neet_pg_bot

Q3: Which of the following is used for the management of dialysis disequilibrium? (Q869058)

A. Mannitol

B. Dexamethasone

C. 5% dextrose

D. N/2 in 5% dextrose

See Answer in Part B → Q3

@Neet_pg_bot

Q4: What is the most common complication of recurrent haemodialysis? (Q850994)

A. Dialysis dysequilibrium

B. Dialysis dementia

C. Peripheral neuropathy

D. Accelerated atherosclerosis

See Answer in Part B → Q4

@Neet_pg_bot

Q5: What is the most common acute complication of haemodialysis? (Q850993)

A. Bleeding

B. Infection

C. Hypotension

D. Myocardial infarction

See Answer in Part B → Q5

@Neet_pg_bot

Q6: A 72-year-old patient undergoing hemodialysis suddenly develops symptoms of dizziness, significant leg cramps, and chest pain during the treatment session. Which of the following is the most common acute complication occurring in patients undergoing dialysis? (Q850992)

A. Cardiac arrhythmias

B. Hypotension

C. Anaphylactoid reactions

D. Muscle cramps

See Answer in Part B → Q6

@Neet_pg_bot

Q7: Which of the following will help in differentiating acute kidney injury from chronic kidney disease? (Q850991)

A. Urine albumin

B. Size of kidney

C. Serum creatinine

D. Urine output

See Answer in Part B → Q7

@Neet_pg_bot

Q8: A 60-year-old man with chronic kidney disease eGFR of 45 ml/min presents with complaints of increasing fatigue and dyspnoea on exertion. On evaluation, he is found to have Hb=7 gm/dl with normocytic normochromic anaemia. What is the next step in management? (Q850990)

A. Oral iron therapy

B. Intravenous iron infusion

C. Blood transfusion

D. Darbepoetin alfa

See Answer in Part B → Q8

@Neet_pg_bot

Q9: CKD patient with G5A3 status presents with chest pain for 6 hours. Auscultation shows a friction rub. ECG shows PR segment depression with global ST elevation. Which of the following should be done for management of this patient? (Q850989)

A. Call nephrologist for urgent hemodialysis

B. Start IVF with Colchicine/ NSAIDS

C. Arrange for pericardial drainage procedure

D. Start Morphine, oxygen 6L /min and chewable aspirin

See Answer in Part B → Q9

@Neet_pg_bot

Q10: In annual medical check up of type 2 DM patient with HbA1c of 10% which of the following tests will identify primary kidney disease? (Q850964)

A. UACR >2.5 mg/mmol on two occasions

B. Urine dipstick for protein 2+ on two occasions

C. Serum creatinine rise by 1.5-1.9 times over 48 hours

D. Urine output < 0.5 ml/kg/ hour for 24 hours

See Answer in Part B → Q10

@Neet_pg_bot

Q11: A CKD patient is determined to have adynamic bone disease. Which of the following is the best explanation for this presentation? (Q850987)

A. Excessive use of vitamin D preparations and phosphate binders

B. Less use of vitamin D preparations and phosphate binders

C. High levels of FGF-23

D. Low levels of FGF-23

See Answer in Part B → Q11

@Neet_pg_bot

Q12: Cardiovascular disease is the leading cause of morbidity and mortality in patients at every stage of CKD. Which of the following correlates best with this morbidity and mortality pattern? (Q850986)

A. Elevated Phosphate levels

B. Elevated Calcium levels

C. Elevated H+ levels

D. Increased Total body water

See Answer in Part B → Q12

@Neet_pg_bot

Q13: Which of the following is calcimimetic agent that enhances the sensitivity of parathyroid cells to the suppressive effect of calcium? (Q850985)

A. Etelcalcetide

B. Teriparatide

C. Sodium Zirconate cyclosilicate

D. Lanthanum

See Answer in Part B → Q13

@Neet_pg_bot

Q14: CKD patient presents with sudden onset chest pain and sweating. Which of the following is best practice for further management of this patient? (Q850984)

A. Troponin I

B. Serial Troponin I

C. Serial Troponin I + ECG

D. Troponin I + ECG

See Answer in Part B → Q14

@Neet_pg_bot

Q15: A 45-year-old patient with chronic kidney disease is being evaluated for kidney transplantation. Doppler shows iliac artery calcification. Laboratory investigations reveal: Serum calcium: 8 mg/dL Serum phosphate: 6.5 mg/dL Alkaline phosphatase: Elevated Vitamin D3: Low What is the most appropriate next step in management? (Q850968)

A. Sevelamer

B. Sevelamer + Calcitriol

C. Calcium supplementation + Calcitriol

D. Haemodialysis

See Answer in Part B → Q15

@Neet_pg_bot

Q16: A 45-year-old diabetic patient with an HbA 1 c of 12% is calculated by MDRD formula to have e-GFR of 50 ml/min/m 2 . Which is not correct about this patient? (Q850967)

A. Less ammonium ion production

B. Increased urinary chloride

C. Associated with severe protein catabolism

D. Start oral bicarbonate supplementation in grade 3 CKD

See Answer in Part B → Q16

@Neet_pg_bot

Q17: Which of the following is the leading cause of chronic kidney disease? (Q850966)

A. Chronic Glomerulonephritis

B. Autosomal dominant polycystic kidney disease

C. Diabetes insipidus

D. Hypertension

See Answer in Part B → Q17

@Neet_pg_bot

Q18: A 38-year-old man with type 2 diabetes mellitus for the last 3 years undergoes an annual renal evaluation. His serum creatinine is 0.9mg/dL. Urine albumin excretion is 2 mg/mmol on multiple occasions. Which of the following represents the earliest renal abnormality in diabetic nephropathy? (Q850965)

A. Microalbuminuria (30–300 mg/day)

B. Decline in GFR <60 mL/min/1.73 m²

C. Glomerular hyperfiltration

D. Armani Ebstein changes in proximal convoluted tubule

See Answer in Part B → Q18

@Neet_pg_bot

• [04_Nephrology] 027 Renal Tubular Acidosis And Renal Artery Stenosis

« Back to Folder Directory

[04_Nephrology] 027 Renal Tubular Acidosis And Renal Artery Stenosis — Quick Jump

Q1 (p. 398)	*Q2 (p. 398)*	*Q3 (p. 399)*	*Q4 (p. 399)*	*Q5 (p. 399)*	*Q6 (p. 400)*
Q7 (p. 401)	*Q8 (p. 401)*	*Q9 (p. 401)*	*Q10 (p. 402)*	*Q11 (p. 402)*	*Q12 (p. 403)*

Q1: Which of the following is most likely based on the lab values given? Blood pH: 7.32 Na + : 130mEq/L K + : 2.8 mEq/L Cl - : 110 mEq/L HCO 3 : 12 mEq/L Urea: 25 mg/dL Creatinine: 0.6 mg/dL Urinary pH: 9.4 (Q850782)

A. RTA 1

B. RTA 2

C. RTA 3

D. RTA 4

See Answer in Part B → Q1

@Neet_pg_bot

Q2: 60-year-old smoker presents with difficult to control hypertension and is on Ramipril, amlodipine and thiazides. Duplex imaging shows increased flow velocity in bilateral renal artery. Which of the following is the leading cause of this presentation? (Q850789)

A. Fibromuscular dysplasia

B. Atherosclerosis

C. Takayasu arteritis

D. TTP

See Answer in Part B → Q2

@Neet_pg_bot

Q3: 65-year-old man with hypertension presents with sudden onset breathlessness. He is found to have bilateral crackles, pink frothy sputum, and hypoxemia requiring non-invasive ventilation. His BP is persistently high despite ramipril, amlodipine and hydrochlorothiazide for past 6 months. Echo shows preserved LV ejection fraction. Duplex Doppler of renal arteries demonstrates markedly increased flow velocity bilaterally. Likely cause of this presentation is? (Q850792)

A. Thrombo-embolic disease of kidney

B. Atherosclerosis

C. Athero-embolic kidney disease

D. Fibromuscular dysplasia

See Answer in Part B → Q3

@Neet_pg_bot

Q4: Renal tubular acidosis that presents with hyperkalemia is? (Q850794)

A. RTA 1

B. RTA 2

C. RTA 3

D. RTA 4

See Answer in Part B → Q4

@Neet_pg_bot

Q5: 25-year-old young female is diagnosed with hypertension. Work up shows renal artery stenosis and renal angiogram image is shown. Diagnosis is: (Q850812)

A. Polyarteritis nodosa

B. Microscopic polyangiitis

C. Fibromuscular dysplasia

D. Takayasu arteritis



@Neet_pg_bot

See Answer in Part B → Q5

@Neet_pg_bot

Q6: Which is not correct about RTA 1? (Q850813)

A. Hypokalemia

B. Hypercalciuria

C. Positive Urinary anion gap

D. High urinary NH 4 +

See Answer in Part B → Q6

@Neet_pg_bot

Q7: Which type of Renal tubular acidosis is related to Fanconi syndrome? (Q850814)

A. RTA 1

B. RTA 2

C. RTA 3

D. RTA 4

See Answer in Part B → Q7

@Neet_pg_bot

Q8: Which of the following drugs most commonly causes Type 2 (proximal) renal tubular acidosis? (Q850816)

A. Acetazolamide

B. Furosemide

C. Amiloride

D. Spironolactone

See Answer in Part B → Q8

@Neet_pg_bot

Q9: A 28-year-old woman presents with recurrent renal stones and bone pain. Investigations reveal: Serum potassium: 3.1 mEq/L Serum bicarbonate: 16 mEq/L Urine pH: 6.5 (not decreasing below 5.5 even after acid load) Positive urinary anion gap Which of the following is the most likely diagnosis? (Q850817)

A. Proximal RTA (Type 2)

B. Distal RTA (Type 1)

C. Hyperkalemic RTA (Type 4)

D. Carbonic anhydrase inhibitor–induced RTA

See Answer in Part B → Q9

@Neet_pg_bot

Q10: A 35-year-old woman with recurrent episodes of weakness and bone pain has xerostomia and Schirmer test of filter paper wetting of < 5 mm at 5 minutes. Laboratory results show: Serum potassium: 2.8 mEq/L Serum bicarbonate: 15 mEq/L Urine pH: 6.7 (does not fall below 5.5 on ammonium chloride loading) Positive urinary anion gap ANA and anti-SSA antibodies: positive Which of the following best explains her presentation? (Q850818)

A. Distal RTA due to autoimmune interstitial nephritis in Sjögren syndrome

B. Distal RTA due to autoimmune interstitial nephritis in Scleroderma

C. Distal RTA due to autoimmune interstitial nephritis in lupus nephritis

D. Distal RTA due to autoimmune interstitial nephritis in mixed connective tissue disorder

See Answer in Part B → Q10

@Neet_pg_bot

Q11: 10-year-old boy is evaluated for growth retardation and polyuria. Investigations reveal: Serum bicarbonate: 14 mEq/L Serum potassium: 3.2 mEq/L Urine pH: 4.8 after ammonium chloride loading Fractional excretion of bicarbonate: 20% No nephrolithiasis or nephrocalcinosis Aminoaciduria and glucosuria are also present Which of the following is the most likely diagnosis? (Q850820)

A. Distal RTA (Type 1)

B. Proximal RTA (Type 2) due to Fanconi syndrome

C. Hyperkalemic RTA (Type 4)

D. Distal RTA associated with Sjögren syndrome

See Answer in Part B → Q11

@Neet_pg_bot

Q12: 55-year-old man with long-standing diabetes mellitus presents with weakness. His medications include lisinopril and spironolactone. Investigations show: Serum bicarbonate: 18 mEq/L Serum potassium: 5.9 mEq/L Serum sodium: 132 mEq/L Urine pH: 5.2 Transtubular potassium gradient (TTKG): 3 (low) Which of the following best explains his presentation? (Q850821)

A. Distal RTA due to impaired H■ secretion in α-intercalated cells

B. Proximal RTA due to defective bicarbonate reabsorption

C. Hyperkalemic RTA due to hypoaldosteronism/aldosterone resistance

D. Distal RTA due to excess glycogen deposition in distal tubule

See Answer in Part B → Q12

@Neet_pg_bot

• [04_Nephrology] 028 Nephrotic And Nephritic Syndromes

« Back to Folder Directory

[04_Nephrology] 028 Nephrotic And Nephritic Syndromes — Quick Jump

Q1 (p. 404) *Q2 (p. 405)* *Q3 (p. 405)* *Q4 (p. 406)* *Q5 (p. 407)* *Q6 (p. 407)*
Q7 (p. 408) *Q8 (p. 408)* *Q9 (p. 408)* *Q10 (p. 409)* *Q11 (p. 409)* *Q12 (p. 410)*
Q13 (p. 411) *Q14 (p. 411)* *Q15 (p. 411)*

Q1: A 32-year-old man presents with generalized edema and frothy urine. Laboratory evaluation reveals 24-hour urine protein of 8 g/day, serum albumin of 2.2 g/dL, serum cholesterol of 310 mg/dL, and serum creatinine of 1.3 mg/dL. A kidney biopsy is performed and light microscopy is shown below. Which of the following is the most likely diagnosis? (Q850823)

A. Minimal change disease

B. Focal segmental glomerulosclerosis

C. Membranous nephropathy

D. Amyloidosis

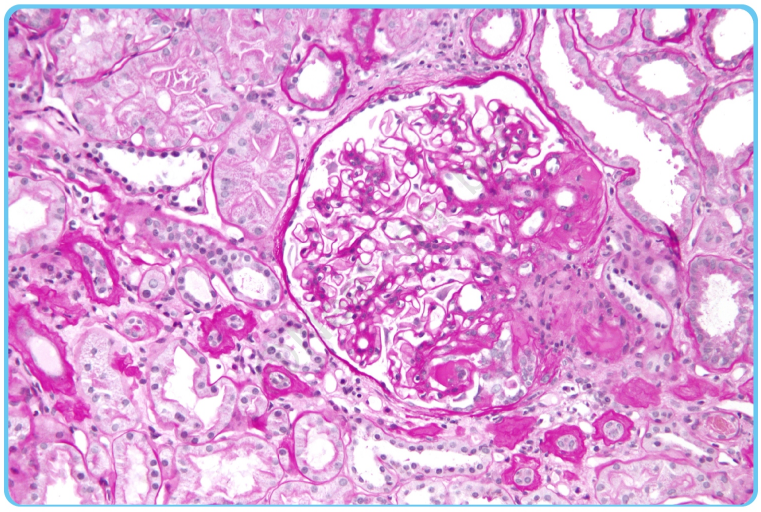

@Neet_pg_bot

See Answer in Part B → Q1

@Neet_pg_bot

Q2: A 4-year-old child presents with swelling all over the body. Workup shows proteinuria >40 mg /m 2 BSA with hypoalbuminemia. KFT is normal. C3 levels are normal. USG shows normal-sized kidneys. What is the best treatment for this case? (Q850824)

A. Steroids plus spironolactone

B. Steroids plus hydrochlorothiazide

C. Steroids plus ACEI

D. Steroids plus cyclophosphamide

See Answer in Part B → Q2

@Neet_pg_bot

Q3: A 5-year-old girl presents with fever, abdominal pain, and dysuria. The consultant performs the imaging study shown. Which investigation has been performed? (Q850827)

A. Intravenous pyelography

B. Retrograde pyelography

C. Voiding cystourethrography

D. DTPA scan



See Answer in Part B → Q3

@Neet_pg_bot

Q4: Patient presents with pitting pedal oedema for the past 2 weeks. Labs: LFT = normal, serum albumin= 2 gm/dl, KFT= deranged with massive proteinuria, Hb A1c 10% and Echo report is normal. USG abdomen shows bilaterally enlarged kidneys. Kidney biopsy was done. Which of the following histopathological reports is most likely to be seen? (Q850831)

A. Diffuse glomerulosclerosis

B. Nodular glomerulosclerosis

C. A-beta 2 microglobulin deposits

D. Apple green birefringence for Congo red deposits

See Answer in Part B → Q4

@Neet_pg_bot

Q5: 30-year-old man presents with periorbital oedema. Urine examination shows massive proteinuria and hypoalbuminemia. He undergoes a kidney biopsy and Congo red staining shows apple-green birefringence under polarized light. What is the most likely diagnosis? (Q850834)

A. Amyloidosis

B. Minimal change disease

C. Diabetic nephropathy

D. Membranous nephropathy

See Answer in Part B → Q5

@Neet_pg_bot

Q6: A 40-year-old man presents with leg swelling and frothy urine. Labs show nephrotic-range proteinuria and low serum albumin. Kidney biopsy shows diffuse GBM thickening with subepithelial deposits, and immunofluorescence reveals granular IgG and C3 along the capillary wall. Which marker is most specific for primary membranous nephropathy? (Q850835)

A. Anti-dsDNA antibody

B. Anti-PLA2 receptor antibody

C. Anti-GBM antibody

D. ANCA antibody

See Answer in Part B → Q6

@Neet_pg_bot

Q7: Renal vein thrombosis is most commonly associated with which of the following conditions? (Q850838)

A. Membranous glomerulonephropathy (MGN)

B. Membranoproliferative glomerulonephritis (MPGN)

C. Minimal change disease

D. Focal segmental glomerulosclerosis (FSGS)

See Answer in Part B → Q7

@Neet_pg_bot

Q8: 40-year-old man with nephrotic syndrome due to membranous glomerulonephropathy in on steroids with cyclophosphamide. He presents with sudden onset flank pain and hematuria. On examination, the left kidney is enlarged and tender. Which of the following is the most likely diagnosis? (Q850839)

A. Acute pyelonephritis

B. Hydronephrosis with pyelonephritis

C. Renal Abscess

D. Renal vein thrombosis

See Answer in Part B → Q8

@Neet_pg_bot

Q9: 2-year-old child with a history of severe watery diarrhea and dehydration is brought to the emergency. He develops sudden onset hematuria and flank mass.

Examination reveals unilateral enlarged tender kidney. Which of the following is the most likely diagnosis? (Q850841)

A. Haemolytic uremic syndrome

B. Pre-renal acute kidney injury

C. Renal vein thrombosis

D. Hydronephrosis due to ureteric stone

See Answer in Part B → Q9

@Neet_pg_bot

Q10: Most common cause of Primary glomerulonephritis is? (Q850842)

A. Post-streptococcal glomerulonephritis (PSGN)

B. Rapidly progressive glomerulonephritis (RPGN)

C. Henoch–Schönlein purpura (HSP)

D. Berger disease (IgA nephropathy)

See Answer in Part B → Q10

@Neet_pg_bot

Q11: 10-year-old boy presents with cola-colored urine, periorbital puffiness, and mild hypertension. He had a sore throat 2 weeks ago. Urine examination shows red blood cell casts and mild proteinuria. Serum C3 is decreased while C4 remains normal. Which of the following is the most likely diagnosis? (Q850844)

A. IgA nephropathy

B. Post-streptococcal glomerulonephritis

C. Membranous glomerulopathy

D. Rapidly progressive glomerulonephritis

See Answer in Part B → Q11

@Neet_pg_bot

Q12: A 15-year-old boy presents with periorbital edema, dyspnea, and dark-colored urine for 2 days. His BP is 160/100 mmHg, and urine microscopy shows 100 dysmorphic RBCs/HPF with S. creatinine 1.5 mg/dL. Kidney biopsy was done and H&E and IF findings are shown below. Which of the following correctly describes the pathogenesis of this condition? (Q850850)

A. Type III hypersensitivity with subepithelial humps

B. Type III hypersensitivitywith subendothelial deposits

C. Type IIhypersensitivity with anti-GBM deposition

D. Type III hypersensitivity with thickening of basement membrane

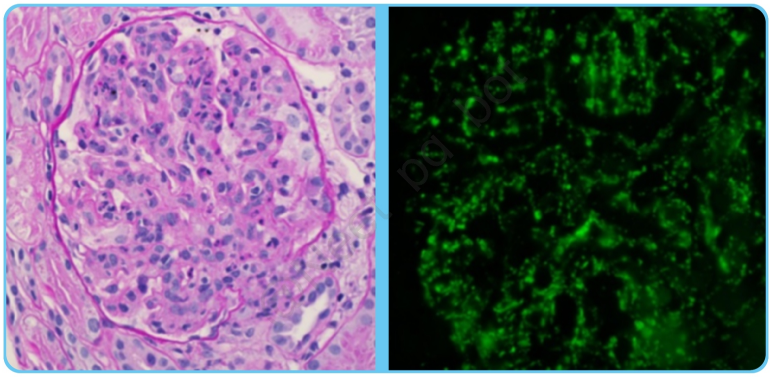

@Neet_pg_bot

See Answer in Part B → Q12

@Neet_pg_bot

Q13: Kidney biopsy showing diffuse endocapillary hypercellularity with diffuse subendothelial immune deposits is most consistent with which of the following conditions? (Q850853)

A. Post-streptococcal glomerulonephritis (PSGN)

B. Lupus nephritis

C. Rapidly progressive glomerulonephritis (RPGN)

D. Berger disease

See Answer in Part B → Q13

@Neet_pg_bot

Q14: A 20-year-old college student presents with recurrent episodes of cola-colored urine 1–2 days after upper respiratory infections. Urinalysis shows dysmorphic RBCs and mild proteinuria. Renal biopsy demonstrates mesangial proliferation with IgA deposits on immunofluorescence. Which of the following best explains the pathophysiology of his condition? (Q850857)

A. Immune complex formation against glucose-deficient IgA1

B. Immune complex formation against galactose-deficient IgA1

C. Antibody formation against glomerular basement membrane antigens

D. T-cell mediated podocyte injury leading to foot process effacement

See Answer in Part B → Q14

@Neet_pg_bot

Q15: A 45-year-old man with a history of IV drug use and HCV positivity presents with edema and fatigue. Labs show 3.8 g/day proteinuria, microscopic hematuria, and low C3. Kidney biopsy specimen under light microscopy is shown below. What is the most likely diagnosis? (Q850860)

A. Focal segmental glomerulosclerosis

B. Membranous nephropathy

C. Membranoproliferative glomerulonephritis

D. Minimal change disease

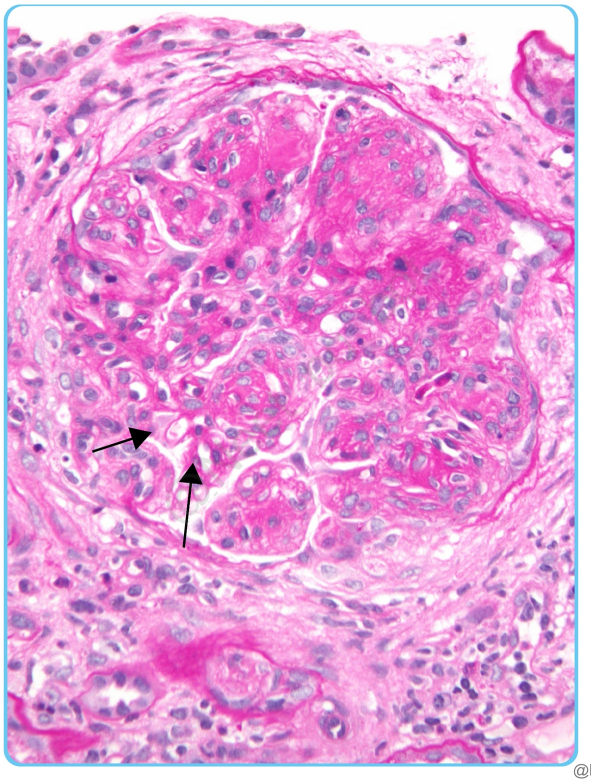

See Answer in Part B → Q15

@Neet_pg_bot

• [04_Nephrology] 029 Previous Year Questions

« Back to Folder Directory

[04_Nephrology] 029 Previous Year Questions — Quick Jump

Q1 (p. 413)	*Q2 (p. 413)*	*Q3 (p. 414)*	*Q4 (p. 414)*	*Q5 (p. 414)*	*Q6 (p. 415)*
Q7 (p. 416)	*Q8 (p. 416)*	*Q9 (p. 417)*	*Q10 (p. 417)*	*Q11 (p. 418)*	*Q12 (p. 418)*
Q13 (p. 419)	*Q14 (p. 419)*	*Q15 (p. 419)*	*Q16 (p. 420)*	*Q17 (p. 420)*	*Q18 (p. 421)*
Q19 (p. 421)	*Q20 (p. 422)*	*Q21 (p. 423)*	*Q22 (p. 423)*	*Q23 (p. 423)*	*Q24 (p. 424)*
Q25 (p. 424)	*Q26 (p. 425)*	*Q27 (p. 425)*	*Q28 (p. 425)*	*Q29 (p. 426)*	*Q30 (p. 426)*
Q31 (p. 427)	*Q32 (p. 427)*	*Q33 (p. 427)*	*Q34 (p. 428)*	*Q35 (p. 428)*	*Q36 (p. 429)*
Q37 (p. 429)	*Q38 (p. 429)*	*Q39 (p. 430)*	*Q40 (p. 430)*	*Q41 (p. 431)*	*Q42 (p. 431)*
Q43 (p. 431)	*Q44 (p. 432)*	*Q45 (p. 432)*	*Q46 (p. 432)*		

Q1: A 29-year-old male patient presents with multiple oral and genital ulcers. The patient claims these ulcers resolve spontaneously and that he experiences such episodes at least four times a year. Ocular examination reveals features of anterior uveitis. What is the likely diagnosis? (Q856261)

A. Rheumatoid arthritis

B. Psoriatic arthritis

C. SLE

D. Behcet’s disease

See Answer in Part B → Q1

@Neet_pg_bot

Q2: What is the most probable cause of the muteness, quadriplegia, and rigidity observed in an elderly female patient who had a previous medical history of severe vomiting and was aggressively treated for severe dehydration at a different hospital one week ago? (Q855368)

A. Malignant hyperthermia

B. Severe catatonia

C. Rapid sodium correction

D. Neuroleptic malignant syndrome

See Answer in Part B → Q2

@Neet_pg_bot

Q3: In methanol intoxication, which of the subsequent electrolyte abnormalities is observed? (Q855370)

A. Metabolic alkalosis with high anion gap

B. Metabolic acidosis with high anion gap

C. Metabolic acidosis with normal anion gap

D. Metabolic alkalosis with normal anion gap

See Answer in Part B → Q3

@Neet_pg_bot

Q4: AKIN and RIFLE criteria is used for classification of which of the folowing coditions? (Q857655)

A. Acute kidney injury

B. Chronic kidney failure

C. Acute glomerulonephritis

D. Nephrotic syndrome

See Answer in Part B → Q4

@Neet_pg_bot

Q5: Which of the following conditions is associated with hypokalemic metabolic alkalosis with hypertension? (Q855709)

A. Barter syndrome

B. Liddle syndrome

C. Gitelman syndrome

D. Gordon syndrome

See Answer in Part B → Q5

@Neet_pg_bot

Q6: Identify the urinary crystal shown below: (Q855724)

A. Calcium oxalate

B. Calcium phosphate

C. Uric acid

D. Cysteine

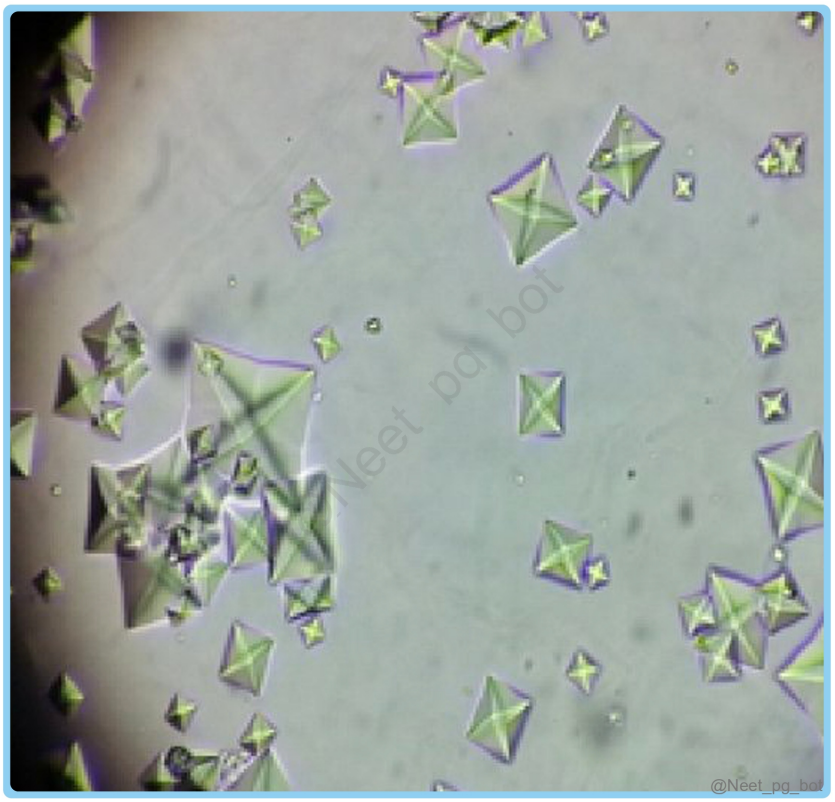

See Answer in Part B → Q6

@Neet_pg_bot

Q7: Which of the following is not true about syndrome of inappropriate antidiuretic hormone secretion (SIADH)? (Q856599)

A. Urinary sodium <20 mEq/L

B. Serum sodium <135 mEq/L

C. Urine osmolality >100 mOsm/kg

D. Patient can be clinically euvolemic to hypervolemic

See Answer in Part B → Q7

@Neet_pg_bot

Q8: A 40-year-old male presents with complaints of episodes of palpitations, headache, and profuse sweating for the past few days. MIBG scan shows a deep-seated tumour in the adrenal medulla. Which of the following statements is incorrect regarding the condition described? (Q856115)

A. Diagnosed by urine VMA & catecholamines

B. Surgical excision is the definitive treatment

C. Propranolol is given initially to manage hypertension

D. Can present as hypertension alone and sometimes with vomiting and pain abdomen

See Answer in Part B → Q8

@Neet_pg_bot

Q9: A patient presents with a seizure. On evaluation, urine osmolality is 1000 mOsm/kg, and serum osmolality is 270 mOsm/kg. Which electrolyte abnormality can be expected in this patient? (Q856120)

A. Hypernatremia

B. Hyponatremia

C. Hyperkalaemia

D. Hypokalaemia

See Answer in Part B → Q9

@Neet_pg_bot

Q10: Hemodialysis is an indication for all the below conditions except? (Q856921)

A. Uremic encephalopathy

B. Peripheral neuropathy

C. Metabolic acidosis

D. Uremic pericarditis

See Answer in Part B → Q10

@Neet_pg_bot

Q11: Which of the following options represents the most severe manifestation of Chronic Kidney Disease (CKD)? (Q856933)

A. Decreased GFR

B. Increased creatinine

C. Hyperkalaemia

D. Proteinuria

See Answer in Part B → Q11

@Neet_pg_bot

Q12: A 56-year-old man presents to the casualty with severe shortness of breath and fatigue for the past 3 hours. He reports a history of vomiting and epigastric pain 2 days back, for which he took an anti-emetic. His past medical history is significant for hypertension and diabetes mellitus type 1. As the CBG valve of this patient showed 356mg/dL, the physician advises immediate ABG analysis, which reveals a pH=7.32, pCO 2 =38mEq/L, and HCO 3 -=15mEq/L. This report showed a type of acidosis with an increased anion gap. Which of the following conditions does not belong to the same classification of metabolic acidosis as in this patient? (Q856972)

A. Renal failure

B. Lactic acidosis

C. Renal aciduria

D. Aspirin poisoning

See Answer in Part B → Q12

@Neet_pg_bot

Q13: An increased anion gap is seen in: (Q855362)

A. Respiratory acidosis

B. Respiratory alkalosis

C. Metabolic acidosis

D. Metabolic alkalosis

See Answer in Part B → Q13

@Neet_pg_bot

Q14: A 55-year-old man with long-standing diabetes mellitus and end-stage renal disease (eGFR <20 mL/min) is being evaluated for renal transplantation. Which of the following statements correctly describes an ideal candidate outcome or consideration for renal graft transplant in a patient with diabetic nephropathy? (Q856285)

A. The survival rate of graft is 95% in the first year

B. The transplantation is cost effective after the second transplant year

C. The life expectancy is doubled in a diabetic patient with renal transplant

D. The treatment of chronic rejection has improved over the last 10 years

See Answer in Part B → Q14

@Neet_pg_bot

Q15: Calculate the sodium deficit in the male patient, who weighs 60 kg, using the provided serum electrolyte values: pH of 7.42, sodium (Na+) level of 120 mEq/L, and serum chloride (CI-) level of 90 mEq/L. (Q856302)

A. 20 mEq

B. 200 mEq

C. 400 mEq

D. 720 mEq

See Answer in Part B → Q15

@Neet_pg_bot

Q16: In the given acid-base nomogram diagram, areas marked A and D indicated which of the following conditions? (Q856341)

A. Chronic respiratory acidosis, acute metabolic alkalosis

B. Acute metabolic alkalosis, acute respiratory acidosis

C. Acute respiratory acidosis, acute respiratory alkalosis

D. Acute respiratory acidosis, acute metabolic alkalosis

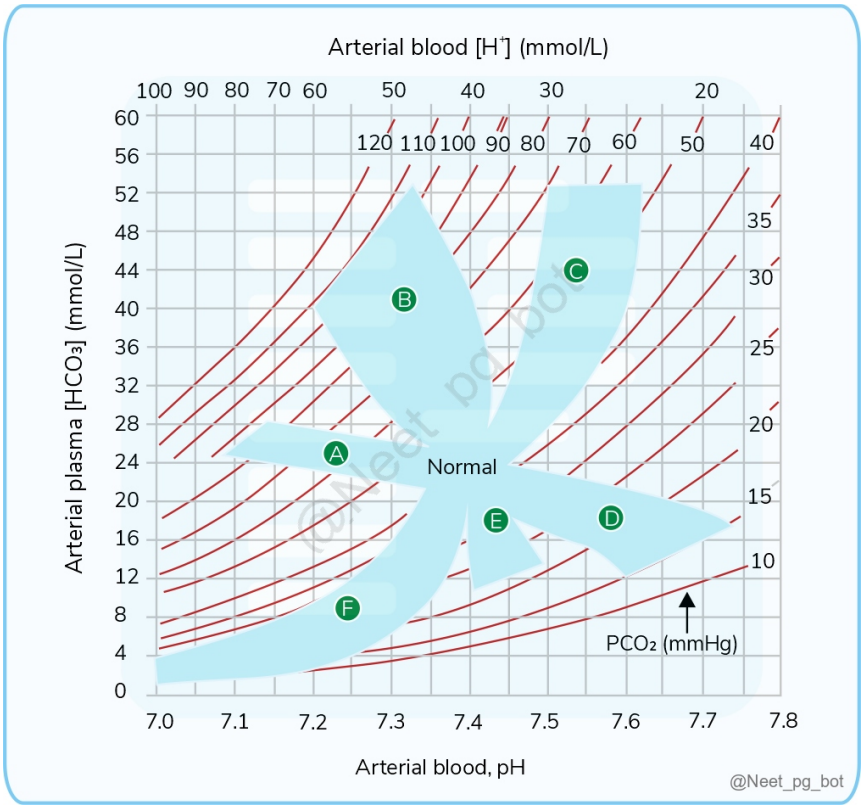

See Answer in Part B → Q16

@Neet_pg_bot

Q17: A mutation in the gene for the aquaporin channel leads to which of the following conditions? (Q855043)

A. Liddle’s syndrome

B. Nephrogenic DI

C. Cystic fibrosis

D. Barter syndrome

See Answer in Part B → Q17

@Neet_pg_bot

Q18: A 30-year-old woman presents to the OPD with palpitation and weight loss. On examination of her legs the following lesion was found which on applying pressure, the indentation does not persist on release. ECG shows sinus rhythm. What is the probable cause of the oedema? (Q859558)

A. Myxedema

B. Nephrotic syndrome

C. Chronic lymphangitis

D. Dilated cardiomyopathy

See Answer in Part B → Q18

@Neet_pg_bot

Q19: A hepatitis B-positive adult presents with massive proteinuria (>3.5 g/day). Renal biopsy was performed as shown below. What is the most likely diagnosis? (Q859566)

A. Focal segmental glomerulosclerosis

B. Membranous glomerulonephritis

C. Membranoproliferative glomerulonephritis

D. Minimal change disease

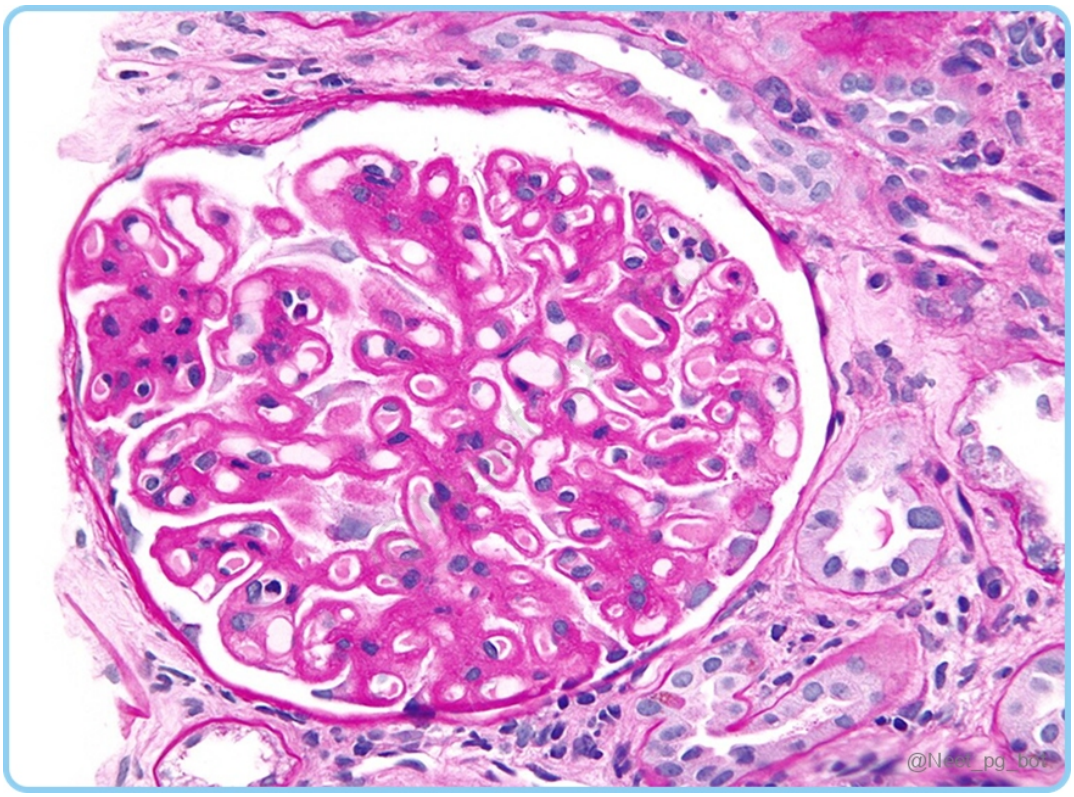

See Answer in Part B → Q19

@Neet_pg_bot

Q20: Which of the following agents is most likely causing the condition in a 60-year-old woman, who had a kidney transplant 2 months ago, and is now experiencing a high fever, severe difficulty in breathing, and a dry cough with a hacking sound? A chest x-ray shows widespread interstitial infiltrates in both lungs, and urine examination reveals the presence of cells with an 'owl-eye' appearance. (Q859782)

A. Adenovirus

B. Cytomegalovirus

C. Influenza virus

D. Respiratory syncytial

See Answer in Part B → Q20

@Neet_pg_bot

Q21: A patient exhibits symptoms of increased urination, nighttime urination, and involuntary urination, along with a recorded 24-hour urine volume of 7 litres. He has a urine osmolarity of 260 mOsm/L. The ADH assay shows a recorded value of 0.8 pg/ml, and an MRI of the brain reveals the absence of a bright spot on T1-weighted imaging. What is the probable diagnosis? (Q859788)

A. Nephrogenic DI

B. Primary polydipsia

C. Pituitary DI

D. Mannitol infusion

See Answer in Part B → Q21

@Neet_pg_bot

Q22: A 10-year-old male child presents with headache and cola-colored urine. His parents report throat pain 2 weeks ago. Work up shows RBC casts in urine and his KFT is increased two fold. What is the likely light microscopy finding in this case? (Q859810)

A. Spike and dome appearance

B. Starry sky appearance

C. Enlarged hypercellular glomeruli with obliteration of bowman space

D. Electron dense deposits

See Answer in Part B → Q22

@Neet_pg_bot

Q23: Which of the following clinical conditions are correctly matched with their anion gap status? Starvation – Increased anion gap Diabetic ketoacidosis – Increased anion

gap Severe vomiting – Increased anion gap (Q879184)

A. Only b is correct

B. a and b are correct

C. a and c are correct

D. Only a is correct

See Answer in Part B → Q23

@Neet_pg_bot

Q24: An 8-year-old child with a history of GTCS came with an episode of convulsions for more than 45 minutes. What will be the appropriate management for this patient? (Q860439)

A. Lorazepam followed by levetiracetam

B. Valproate followed by gabapentin

C. Carbamazepine followed by lorazepam

D. Levetiracetam followed by valproate

See Answer in Part B → Q24

@Neet_pg_bot

Q25: A patient after RTA had a renal shut down. Work-up shows: FeNa: < 1%, Urine osmolality: 300 mOsm/kg, Urinary sodium: 40 mEq/L. Most likely diagnosis? (Q866812)

A. Acute Tubular Necrosis

B. Pre-renal AKI

C. Post-renal AKI

D. Renal AKI

See Answer in Part B → Q25

@Neet_pg_bot

Q26: A 58-year-old male presents with complaints of burning micturition. Prostatic examination was normal. Urinalysis shows >50 pus cells per high power field, but urine culture shows no growth. What is the most likely diagnosis? (Q865326)

A. Chronic bacterial prostatitis

B. Acute bacterial prostatitis

C. Granulomatous prostatitis

D. Sterile pyuria

See Answer in Part B → Q26

@Neet_pg_bot

Q27: A 56-year-old diabetic male presents with a complicated urinary tract infection and is found to be hypotensive. His blood pressure does not respond to intravenous fluids. Which of the following is the most appropriate antibiotic to manage his condition? (Q865371)

A. Amoxicillin-Clavulanate

B. Nitrofurantoin

C. Meropenem

D. Ciprofloxacin

See Answer in Part B → Q27

@Neet_pg_bot

Q28: A 60-year-old man with chronic kidney disease presents with complaints of increasing fatigue, dyspnea on exertion, and signs of congestive heart failure. On

evaluation, he is found to have anemia. Work up shows Hb=7 gm/dl and Peripheral Smear shows Normocytic normochromic anemia. What is the next step in management of this case? (Q866502)

A. Oral iron therapy

B. IV iron infusion

C. Blood transfusion

D. Darbepoetin alfa

See Answer in Part B → Q28

@Neet_pg_bot

Q29: A patient has undergone an acute renal allograft transplantation. What would indicate its rejection? (Q853353)

A. Rise of creatinine by more than 10% is suggestive of acute rejection.

B. Rise of creatinine by more than 5% is suggestive of acute rejection.

C. Serum creatinine does not rise in acute renal allograft rejection.

D. Any rise in serum creatinine will be suggestive of acute renal allograft rejection.

See Answer in Part B → Q29

@Neet_pg_bot

Q30: As per KDIGO, which of the following falls under G3b? (Q853357)

A. 45-59

B. 60-89

C. 30-44

D. 15-29

See Answer in Part B → Q30

@Neet_pg_bot

Q31: A 25-year-old male presents with hematuria. Which of the following are seen in glomerular hematuria? Statements: Brown-colored urine Dysuria absent Crystals present Edema rare (Q853360)

A. 1 only

B. 1, 2

C. 1, 2, 3

D. 1, 2, 4

See Answer in Part B → Q31

@Neet_pg_bot

Q32: What is the recommended treatment for nephrotic syndrome in children? (Q852685)

A. Steroids

B. Steroids and cyclophosphamide

C. Cyclophosphamide

D. ACE inhibitors

See Answer in Part B → Q32

@Neet_pg_bot

Q33: A 55-year-old woman with a history of type 2 diabetes presents for a routine follow-up. Her serum creatinine and potassium levels are normal, but she has microalbuminuria and an HbA1c of 8%. Her blood pressure and pulse are within normal limits, and she is currently on metformin for diabetes management. What should be the next step in her management? (Q852754)

A. Begin a thiazide diuretic

B. Start insulin therapy

C. Stop Metformin and start a different OHA

D. Start an ACE inhibitor

See Answer in Part B → Q33

@Neet_pg_bot

Q34: Which of the following is most likely based on the lab values given? Blood pH: 7.3 (indicating mild acidosis) Sodium (Na+): 134 mEq/L (mildly decreased) Potassium (K+): 2.8 mEq/L (hypokalemia) Chloride (Cl-): 113 mEq/L (elevated) Bicarbonate (HCO■■): 12 mEq/L (low, indicating metabolic acidosis) Blood Urea Nitrogen (BUN): 3 mg/dL (low-normal) Creatinine: 0.6 mg/dL (normal) Urinary pH: 9.4 (alkaline) (Q844330)

A. Renal Tubular Acidosis (RTA) Type 1 (Distal RTA)

B. Renal Tubular Acidosis (RTA) Type 2 (Proximal RTA)

C. Renal Tubular Acidosis (RTA) Type 4

D. High Anion Gap Metabolic Acidosis (HAGMA)

See Answer in Part B → Q34

@Neet_pg_bot

Q35: A patient having hypertension is on thiazides and is complaining of fatigue and hypokalemia. Which of the following drugs can prevent potassium loss? (Q860435)

A. Furosemide

B. Amiloride

C. Acetazolamide

D. Indapamide

See Answer in Part B → Q35

@Neet_pg_bot

Q36: A patient with RTA is passing red color urine due to myoglobinuria. Which of the following will most likely be seen in this patient? (Q866811)

A. Hypernatremia

B. Hyperkalemia

C. Hyponatremia

D. Hypokalemia

See Answer in Part B → Q36

@Neet_pg_bot

Q37: A 30-year-old male is admitted to the medicine ward with complaints of vomiting and diarrhea. Lab investigations reveal a serum potassium level of 3.2 mEq/L. All of the following can be signs of underlying dyselectrolytemia except: (Q840102)

A. Ventricular tachycardia

B. Quadriplegia

C. Diabetes insipidus

D. Cerebral edema

See Answer in Part B → Q37

@Neet_pg_bot

Q38: Which of the following is the most likely condition responsible for a 35-year-old male experiencing nausea, diarrhea, and vomiting, with ABG results indicating pH of 7.55, PCO2 of 50 mmHg, and HCO3- of 44 mmol? (Q840111)

A. Respiratory Acidosis

B. Respiratory Alkalosis

C. Metabolic Acidosis

D. Metabolic Alkalosis

See Answer in Part B → Q38

@Neet_pg_bot

Q39: Which of the following best characterizes the acid-base status of a 45-year-old diabetic patient presenting to the emergency department with abdominal pain, tachypnea, and tachycardia, whose arterial blood gas analysis reveals the following: pH: 7.34 Sodium (Na): 135 Potassium (K): 5 Bicarbonate (HCO3): 12 Chloride (Cl): 92 RBS = 450 mg/dl (Q840113)

A. Non-Anion Gap Metabolic Acidosis (NAGMA)

B. High Anion Gap Metabolic Acidosis (HAGMA)

C. Compensated Metabolic Alkalosis

D. Respiratory Acidosis

See Answer in Part B → Q39

@Neet_pg_bot

Q40: Which of the following is not a cause of chronic bipedal edema? (Q840123)

A. Chronic liver disease

B. Nephrotic syndrome

C. Chronic venous insufficiency

D. Lupus nephritis

See Answer in Part B → Q40

@Neet_pg_bot

Q41: A patient presented with complaints of pain in the flank region with hematuria. On investigation, an X-ray shows multiple calcifications (stones) in both kidneys. What is the probable diagnosis? (Q857275)

A. Parathyroid Adenoma

B. Renal calculi

C. Polycystic kidney disease

D. CKD

See Answer in Part B → Q41

@Neet_pg_bot

Q42: A young patient developed hyperpigmentation of distal fingers after being hospitalized post-adrenalectomy. What could be the possible cause? (Q857289)

A. Addison’s disease

B. Conn's syndrome

C. Nelson syndrome

D. Cushing syndrome

See Answer in Part B → Q42

@Neet_pg_bot

Q43: A 5 year old male child was brought to the hospital with complaints of flank pain and fatigue with a history of red coloured urine. On investigation there were more than 20 RBC/ hpf and microscopy showed dysmorphic RBC. What is the most likely diagnosis? (Q820455)

A. Minimal change disease

B. PSGN

C. UTI

D. Bladder calculi

See Answer in Part B → Q43

@Neet_pg_bot

Q44: A patient with hyperkalemia and elevated urea levels underwent dialysis. Towards the end of the session, she became drowsy and had a sudden seizure episode. On examination, the patient was hypotensive. What is the treatment for this condition? (Q855427)

A. Bumetanide

B. Ethacrynic acid

C. Nesiritide

D. IV Mannitol

See Answer in Part B → Q44

@Neet_pg_bot

Q45: Which one of the following medications is not employed for the urgent (immediate) treatment of hyperkalemia? (Q855701)

A. 10% calcium gluconate over 10 min

B. Salbutamol nebulisation

C. Insulin-dextrose

D. Injection MgSO4

See Answer in Part B → Q45

@Neet_pg_bot

Q46: All of the following aid in the localization of the lesion to the spinal cord except? (Q855322)

A. Contralateral hemiplegia

B. Fasciculation at the level of lesion

C. Upper motor neuron lesion and lower motor neuron lesion

D. Bladder involvement

See Answer in Part B → Q46

@Neet_pg_bot

• [05_Gastrointestinal System] 030 Zollinger Ellison Syndrome

« Back to Folder Directory

[05_Gastrointestinal System] 030 Zollinger Ellison Syndrome — Quick Jump

Q1 (p. 434) *Q2 (p. 434)* *Q3 (p. 434)* *Q4 (p. 435)*

Q1: A patient is undergoing an endoscopy for epigastric pain. The report shows a giant duodenal ulcer in the duodenal cap, and a second one is noted in the second part of the duodenum. Which investigation should be done next in this patient? (Q850867)

A. Secretin study

B. Somatostatin scintigraphy

C. Endoscopic ultrasound

D. Breath urea test

See Answer in Part B → Q1

@Neet_pg_bot

Q2: 30-year-old man is having peptic ulcers refractory to PPI. Work up shows elevated serum calcium. Which of the following investigations will not be useful in assessment of this patient? (Q850869)

A. Serum PTH assay

B. Tc 99 Sestamibi SPECT CT

C. Gene sequencing for RET gene

D. MRI head

See Answer in Part B → Q2

@Neet_pg_bot

Q3: Which of the following is correct about location of ZES? (Q850871)

A. Bounded by the duodenum (D2-D3), pancreas, and confluence of the cystic and common bile ducts

B. Bounded by the duodenum(D2-D3), pancreas, and confluence of the common hepatic and common bile ducts

C. Bounded by the jejunum, pancreas, and confluence of the cystic and common bile ducts

D. Bounded by the jejunum, pancreas, and confluence of the common hepatic and common bile ducts

See Answer in Part B → Q3

@Neet_pg_bot

Q4: Functional imaging of choice for diagnosis of ZES is? (Q850872)

A. Ga-68 DOTATE PET-CT

B. Octreoscan

C. Portal vein sampling

D. Selective arterial secretin injection

See Answer in Part B → Q4

@Neet_pg_bot

• [05_Gastrointestinal System] 031 Inflammatory Bowel Disease-I

« Back to Folder Directory

[05_Gastrointestinal System] 031 Inflammatory Bowel Disease-I — Quick Jump

Q1 (p. 436) *Q2 (p. 436)* *Q3 (p. 436)* *Q4 (p. 437)* *Q5 (p. 437)* *Q6 (p. 438)*
Q7 (p. 438) *Q8 (p. 438)* *Q9 (p. 439)* *Q10 (p. 439)* *Q11 (p. 439)* *Q12 (p. 440)*
Q13 (p. 440) *Q14 (p. 441)* *Q15 (p. 441)*

Q1: Which of the following test is best correlates well with histologic inflammation and predicts relapses in a patient with ulcerative colitis? (Q850874)

A. Faecal Calprotectin

B. Faecal Lactoferrin

C. Faecal Elastase

D. Faecal Chymotrypsin

See Answer in Part B → Q1

@Neet_pg_bot

Q2: Which of the following clinical findings is not seen in patient of ulcerative colitis ? (Q850876)

A. Hepatic Tympanitic note

B. Tenderness over colon

C. Bleeding on digital rectal examination

D. Peri-anal fistula

See Answer in Part B → Q2

@Neet_pg_bot

Q3: Which of the following is not a component of Vienna and Montreal classification for Crohn disease? (Q850878)

A. Age at diagnosis

B. Location

C. Behaviour

D. Biomarkers

See Answer in Part B → Q3

@Neet_pg_bot

Q4: Which of the following is not correct about microscopic features of Crohn's disease? (Q850880)

A. Non caseating granuloma in all layers of bowel wall

B. Apthoid ulceration

C. Subepithelial collagen bands

D. Sub-serosal lymphoid aggregates

See Answer in Part B → Q4

@Neet_pg_bot

Q5: All of the following are used to assess severity of ulcerative colitis except? (Q850883)

A. > 6 bloody stools per day

B. Pulse> 90 /min

C. BP < 90/60 mm Hg

D. Haemoglobin < 10.5 gm%, ESR> 30 mm /hr

See Answer in Part B → Q5

@Neet_pg_bot

Q6: Which of the following features will not be seen in patients with Crohn’s disease? (Q850885)

A. Entero-vesical fistula

B. Enterocutaneous fistula

C. Nephrolithiasis

D. Proctitis

See Answer in Part B → Q6

@Neet_pg_bot

Q7: Which of the following is correct radiological finding of ischemic colitis? (Q850887)

A. String sign

B. Thumb print sign

C. Pipe stem colon

D. Lead pipe colon

See Answer in Part B → Q7

@Neet_pg_bot

Q8: IBD is usually associated with extraintestinal features. Which of the following hepatobiliary features is not seen in Patients with IBD? (Q850889)

A. Fatty liver

B. Cholelithiasis

C. Primary sclerosing cholangitis

D. Primary biliary cholangitis

See Answer in Part B → Q8

@Neet_pg_bot

Q9: Which of the following is correct about joint involvement seen in patient with IBD? (Q850891)

A. Migratory peripheral arthritis, Sacroilitis and HLA B27 positive

B. Erosive small joint arthritis, Sacroilitis and HLA B27 positive

C. Migratory peripheral arthritis, tenosynovitis and HLA B27 positive

D. Erosive small joint arthritis, tenosynovitis and HLA B27 positive

See Answer in Part B → Q9

@Neet_pg_bot

Q10: A 28-year-old woman with a history of migraine presents with a 3-month history of bloody diarrhoea and tenesmus. Labs show Hb 10 gm%, CRP positive, and sigmoidoscopy showing erythema, mucosal friability starting from the rectum and extending proximally. Which of the following drugs will be started for the management of this patient? (Q850894)

A. Sulphasalazine

B. Mesalamine

C. Azathioprine

D. Methylprednisolone

See Answer in Part B → Q10

@Neet_pg_bot

Q11: Which of the following small molecule is approved for treatment of ulcerative colitis? (Q850896)

A. Tofacitnib

B. Ustekinumab

C. Certolizumab

D. Azathioprine

See Answer in Part B → Q11

@Neet_pg_bot

Q12: A 35-year-old patient with ulcerative colitis presents with severe abdominal distension, pain, fever, and tachycardia. Abdominal X-ray shows colonic dilatation >6 cm. Ultrasound show no free fluid in peritoneal cavity. What is the first-line medical management for this condition? (Q850898)

A. Intravenous corticosteroids

B. Oral mesalamine

C. Azathioprine

D. Subtotal colectomy

See Answer in Part B → Q12

@Neet_pg_bot

Q13: Leading cause of death in patients with Crohn’s disease? (Q850900)

A. Infection

B. Lymphoma of gut

C. Adenocarcinoma of gut

D. Malabsorption

See Answer in Part B → Q13

@Neet_pg_bot

Q14: Which of the following is the most commonly acquired hospital acquired diarrheal illness? (Q850901)

A. Staph aureus

B. Clostridium difficile

C. Shigella

D. Isospora belli

See Answer in Part B → Q14

@Neet_pg_bot

Q15: Patient on ceftriaxone develops watery loose stools and low-grade fever. Blood counts show TLC of 15000 cells/cu.mm. Which of the following test will help in quick detection of an incriminating organism? (Q850903)

A. NAAT for toxin A and Toxin B in stool

B. EIA for toxin A and toxin B in stool

C. Colonoscopy showing pseudo-membranes

D. Stool culture for Cl. Difficile

See Answer in Part B → Q15

@Neet_pg_bot

• [05_Gastrointestinal System] 032 Inflammatory Bowel Disease-Ii

« Back to Folder Directory

[05_Gastrointestinal System] 032 Inflammatory Bowel Disease-Ii — Quick Jump

Q1 (p. 442) *Q2 (p. 442)* *Q3 (p. 442)* *Q4 (p. 443)* *Q5 (p. 443)* *Q6 (p. 444)* *Q7 (p. 444)*

Q1: Which of the following is first investigation to be done in patient with acute lower GI Bleeding with hemodynamic instability? (Q850899)

A. Colonoscopy

B. Upper GI endoscopy

C. Sigmoidoscopy

D. Digital rectal examination

See Answer in Part B → Q1

@Neet_pg_bot

Q2: Which of the following investigations is best for detecting lesions of active Crohn’s disease? (Q850902)

A. Wireless capsule endoscopy

B. MR enterography

C. CT enterography

D. Barium enema

See Answer in Part B → Q2

@Neet_pg_bot

Q3: Which of the following classification system is used exclusively for determination of severity of ulcerative colitis? (Q850904)

A. Truelove and Witts

B. Montreal classification

C. Vienna classification

D. Marsh classification

See Answer in Part B → Q3

@Neet_pg_bot

Q4: 50-year-old man presents with complaints of blood and mucus in thin ribbon like stool, tenesmus and weight loss. MRI abdomen shows bowel wall thickening in descending colon and perirectal fat thickening and enlarged lymph nodes. First differential diagnosis is? (Q850905)

A. Colorectal cancer

B. Ulcerative colitis

C. Microscopic colitis

D. Crohn’s disease

See Answer in Part B → Q4

@Neet_pg_bot

Q5: Patient with ulcerative colitis presents with ulcerated lesions with violaceous edges surrounded by a margin of erythema on both shins. Diagnosis is? (Q850906)

A. Erythema nodosum

B. Pyoderma gangrenosum

C. Pyoderma vegetans

D. Sweet syndrome

See Answer in Part B → Q5

@Neet_pg_bot

Q6: Which of the following is the most common extraintestinal feature seen in IBD? (Q850907)

A. Metabolic bone disorder

B. Arthritis

C. Ocular involvement

D. Hepatobiliary involvement

See Answer in Part B → Q6

@Neet_pg_bot

Q7: 32-year-old male with ulcerative colitis presents with increased frequency of bloody diarrhea (8–10 times/day) for the past week, associated with abdominal pain and fever. On examination, his pulse is 110/min, BP 100/60 mmHg, temperature 38.2°C. Abdominal examination reveals diffuse tenderness without guarding. Labs are shown below. Which of the following is the most appropriate next step in management Hemoglobin: 9.8 g/dL ESR: 68 mm/hr CRP: markedly elevated Stool culture: negative for pathogens (Q850908)

A. Oral mesalamine

B. Sulfasalazine enema

C. Initiate intravenous corticosteroids

D. Schedule Proctolectomy immediately

See Answer in Part B → Q7

@Neet_pg_bot

• [05_Gastrointestinal System] 033 Irritable Bowel Syndrome

« Back to Folder Directory

[05_Gastrointestinal System] 033 Irritable Bowel Syndrome — Quick Jump

Q1 (p. 445)	*Q2 (p. 445)*	*Q3 (p. 446)*	*Q4 (p. 446)*	*Q5 (p. 446)*	*Q6 (p. 447)*
Q7 (p. 447)	*Q8 (p. 448)*	*Q9 (p. 448)*	*Q10 (p. 448)*	*Q11 (p. 449)*	*Q12 (p. 449)*
Q13 (p. 450)	*Q14 (p. 450)*	*Q15 (p. 450)*	*Q16 (p. 451)*	*Q17 (p. 451)*	*Q18 (p. 452)*

Q1: Patients with Irritable Bowel Syndrome (IBS) have demonstrated preferential activation of which brain region in response to distal colonic stimulation, correlating with altered attention processes and response selection? (Q890588)

A. Mid-cingulate cortex

B. Cerebellum

C. Occipital lobe

D. Hippocampus

See Answer in Part B → Q1

@Neet_pg_bot

Q2: A 35 y/o man with constipation-predominant Irritable Bowel Syndrome (IBS-C) has persistent symptoms despite lifestyle modification and over-the-counter laxatives. He has started on a medication that inhibits the gastrointestinal sodium-hydrogen exchanger 3 (NHE3). Which medication has most likely been prescribed? (Q890596)

A. Tenapanor

B. Prucalopride

C. Eluxadoline

D. Rifaximin

See Answer in Part B → Q2

@Neet_pg_bot

Q3: A 42 y/o woman with irritable bowel syndrome (IBS) reports recurrent lower abdominal cramping and pain shortly after meals. To optimise symptom control for her postprandial pain pattern, what is the most appropriate change to her dosing schedule? (Q890595)

A. Take the medication 30 minutes before meals

B. Take the medication with the first bite of food

C. Take the medication 1 hour after meals

D. Take the medication only at bedtime

See Answer in Part B → Q3

@Neet_pg_bot

Q4: A 68 y/o woman with constipation-predominant Irritable Bowel Syndrome (IBS-C) and mild cognitive impairment presents with dry mouth, blurred vision, and difficulty initiating urination shortly after starting a new medication for abdominal cramping and pain. Which of the following agents is most likely responsible for her symptoms? (Q890594)

A. Linaclotide

B. Peppermint oil

C. Hyoscyamine

D. Lubiprostone

See Answer in Part B → Q4

@Neet_pg_bot

Q5: Pharmacologic agents targeting serotonin receptors are used in the management of irritable bowel syndrome (IBS). While 5-HT■ agonists stimulate intestinal

peristalsis, drugs that act as serotonin antagonists (5-HT■ antagonists) fall under which therapeutic category for IBS? (Q890593)

A. Stool-bulking agents

B. Prescription antidiarrheals

C. Osmotic laxatives

D. Antiflatulence therapy

See Answer in Part B → Q5

@Neet_pg_bot

Q6: A patient with irritable bowel syndrome (IBS) is being treated with paroxetine. On follow-up, the patient reports fatigue and jaundice. Paroxetine is most commonly associated with which pattern of hepatic injury? (Q890592)

A. Fatty liver (steatosis)

B. Granulomatous hepatitis

C. Hepatitis (hepatocellular injury)

D. Vascular injury

See Answer in Part B → Q6

@Neet_pg_bot

Q7: Which of the following clinical features, if reported by a patient, most strongly suggests inflammatory bowel disease (IBD) or another organic pathology rather than irritable bowel syndrome (IBS)? (Q890591)

A. Relief of abdominal pain with defecation

B. Presence of visible mucus in the stool

C. Waking from sleep due to diarrhoea (nocturnal diarrhoea)

D. Sensation of incomplete evacuation

See Answer in Part B → Q7

@Neet_pg_bot

Q8: Which of the following sets of diagnostic tests is recommended as part of the initial evaluation for a patient with diarrhoea-predominant irritable bowel syndrome who has no alarm features? (Q890590)

A. Complete blood count (CBC), faecal calprotectin, and serologic testing for celiac disease

B. Colonoscopy with random biopsies and stool examination for ova and parasites

C. Abdominal CT scan and erythrocyte sedimentation rate (ESR)

D. Hydrogen breath test and upper gastrointestinal endoscopy (EGD)

See Answer in Part B → Q8

@Neet_pg_bot

Q9: Which demographic profile is most strongly associated with an increased risk of developing post-infectious irritable bowel syndrome (IBS) following an episode of acute gastroenteritis? (Q890589)

A. Male patients over the age of 50

B. Female patients of younger age

C. Male patients of younger age

D. Female patients over the age of 60

See Answer in Part B → Q9

@Neet_pg_bot

Q10: A 30-year young female is diagnosed as having IBS. Which of the following is not a feature of irritable bowel syndrome? (Q850815)

A. Dyspepsia and bloating

B. Recurrent abdominal pain

C. Constipation alternating with diarrhoea

D. Nocturnal diarrhoea

See Answer in Part B → Q10

@Neet_pg_bot

Q11: A 34 y/o woman has a 2-year history of recurrent abdominal cramping and frequent loose, watery stools that worsen with stress and meals. She is diagnosed with diarrhoea-predominant irritable bowel syndrome (IBS-D). Which of the following cellular abnormalities is most likely to be identified in her colonic mucosa? (Q890587)

A. Decreased density of mast cells in the lamina propria

B. Increased number of serotonin-containing enterochromaffin cells

C. Atrophy of myenteric plexus ganglion cells

D. Reduced expression of cholecystokinin (CCK) receptors

See Answer in Part B → Q11

@Neet_pg_bot

Q12: Which pathophysiologic abnormality is most consistently observed in patients with IBS, particularly those with the diarrhoea-predominant subtype, during simulated visceral stimulation? (Q890586)

A. Decreased contractile activity in the rectosigmoid colon

B. Higher threshold for pain perception during rectal balloon inflation

C. Exaggerated sensory response to visceral stimulation (visceral hypersensitivity)

D. Generalised somatic hypersensitivity involving skin and muscle

See Answer in Part B → Q12

@Neet_pg_bot

Q13: According to the Rome IV criteria, which of the following symptoms is a mandatory prerequisite for establishing a diagnosis of irritable bowel syndrome (IBS)? (Q890585)

A. Abdominal bloating and distention

B. Recurrent abdominal pain

C. Chronic watery diarrhoea

D. Feeling of incomplete evacuation

See Answer in Part B → Q13

@Neet_pg_bot

Q14: 65-year-old man with obesity and hypertension develops haematochezia needing hospitalization. Which of the following is probable cause? (Q850828)

A. Diverticulitis

B. Colorectal cancer

C. Irritable bowel syndrome

D. Internal Haemorrhoids

See Answer in Part B → Q14

@Neet_pg_bot

Q15: A 30-year-old lady with GERD symptoms underwent a UGI endoscopy that shows loss of vascular pattern, multiple rings and trachealization appearance of oesophagus. Which of the following is correct diagnosis? (Q850826)

A. IBS-D

B. Barrett oesophagus

C. Eosinophilic esophagitis

D. Achalasia cardia

See Answer in Part B → Q15

@Neet_pg_bot

Q16: A 35-year-old female presents with chronic abdominal pain, bloating, and alternating diarrhea and constipation. Following a diagnosis of Irritable Bowel Syndrome (IBS), which dietary approach is considered the most effective for managing her symptoms? (Q850825)

A. Low gluten diet

B. Atkins diet

C. Ketogenic diet

D. Low FODMAP diet

See Answer in Part B → Q16

@Neet_pg_bot

Q17: A 28-year-old patient presents with months of recurrent abdominal pain and diarrhea, now alternating with constipation. He also reports weight loss, low-grade fever, and laboratory findings of normocytic anemia with elevated inflammatory markers. What is the most likely diagnosis? (Q850822)

A. IBS

B. IBD

C. Tropical sprue

D. Bacterial overgrowth syndrome

See Answer in Part B → Q17

@Neet_pg_bot

Q18: Which of the following is correct about mechanism of action of Lubiprostone used in IBS-C? (Q850819)

A. Increase intestinal chloride secretion

B. 5HT4 receptor agonist

C. 5HT4 receptor antagonist

D. Guanylate cyclase -C agonist

See Answer in Part B → Q18

@Neet_pg_bot

• [05_Gastrointestinal System] 034 Peptic Ulcer And Gastrointestinal Bleeding

« Back to Folder Directory

[05_Gastrointestinal System] 034 Peptic Ulcer And Gastrointestinal Bleeding — Quick Jump

Q1 (p. 453) *Q2 (p. 453)* *Q3 (p. 454)* *Q4 (p. 454)* *Q5 (p. 454)* *Q6 (p. 455)*
Q7 (p. 455) *Q8 (p. 456)* *Q9 (p. 456)* *Q10 (p. 456)* *Q11 (p. 457)* *Q12 (p. 458)*
Q13 (p. 458) *Q14 (p. 458)*

Q1: A 30-year-old alcoholic patient presents with vomiting episode and hematemesis. On examination pulse thready 120/min, BP is 80/60 mmHg with cold clammy hands and feet. Per abdomen shows splenomegaly. Which is next best step in management of this patient? (Q850830)

A. UGIE

B. Large-bore IV access and rapid blood transfusion

C. Octreotide infusion

D. Bolus terlipressin

See Answer in Part B → Q1

@Neet_pg_bot

Q2: An elderly man had undergone PCI with stenting 6 weeks ago. Today he passed fresh blood in stool and then collapses in the washroom. On admission pulse is 130 /min, low volume and BP is 80/60 mm Hg. His wife tells that yesterday he was complaining of melena. Medication history is of use of aspirin and clopidogrel for last 6 weeks. Which of the following investigations should be done to determine source of bleeding? (Q850832)

A. Upper GI Endoscopy

B. Colonoscopy

C. Stool for occult blood

D. USG abdomen

See Answer in Part B → Q2

@Neet_pg_bot

Q3: Alcoholic patient with bleeding oesophageal varices is stabilized in ICU. Which of the following interventions will be done in this patient to prevent recurrence of such an event? (Q850833)

A. Endoscopic variceal ligation

B. Trans-jugular intrahepatic portosystemic shunting

C. Octreotide infusion with albumin

D. Terlipressin with midodrine

See Answer in Part B → Q3

@Neet_pg_bot

Q4: Patient with upper GI bleeding and pedal oedema is found to have ‘cerebriform appearance of stomach mucosa’ on UGI endoscopy. Diagnosis is? (Q850836)

A. Gastric antral vascular ectasia

B. Menetrier disease

C. GIST

D. MALToma

See Answer in Part B → Q4

@Neet_pg_bot

Q5: Which of the following is most common site of Mallory Weiss syndrome? (Q850837)

A. Lower 1/3 rd of Oesophagus

B. Middle 1/3 rd of Oesophagus

C. Lower Oesophageal sphincter

D. Pylorus of stomach

See Answer in Part B → Q5

@Neet_pg_bot

Q6: Alcoholic went for a party and did binge drinking. He developed coffee ground vomitus episodes and developed cold clammy extremities. Post volume resuscitation UGI endoscopy was done revealed a ulcer in first part of duodenum. Which of the tests will be done to determine the aetiology of this presentation? (Q850840)

A. Ultrasound abdomen for liver echotexture

B. Urease test

C. Doppler to measure portal vein pressure

D. Oesophageal manometry

See Answer in Part B → Q6

@Neet_pg_bot

Q7: H. Pylori can lead to development of all of the following except? (Q850843)

A. MALToma

B. Duodenal ulcer

C. Gastric adenocarcinoma

D. Barrett oesophagus

See Answer in Part B → Q7

@Neet_pg_bot

Q8: You have given triple therapy to a patient with documented H. Pylori infection by urease test. Which is correct about follow up of this patient? (Q850845)

A. Call after 4 weeks of treatment completion and do urea breath test

B. Call after 4 weeks of treatment completion and do repeat endoscopy

C. Call after 4 weeks of treatment completion and do stool PCR for toxin A and toxin B

D. Call after 4 weeks of treatment completion and give reassurance

See Answer in Part B → Q8

@Neet_pg_bot

Q9: 60 year old obese man is having osteoarthritis and he is taking ibuprofen daily for the past 3 months. He developed epigastric pain and occult GI bleeding. Which of the following is correct about the cause? (Q850846)

A. PGE2 and prostacyclin production reduced with decreased mucosal barrier

B. Increased acid production due to ibuprofen

C. PGE1 and prostacyclin production reduced with decreased mucosal barrier

D. Mucosal injury due to inhibition of COX-2

See Answer in Part B → Q9

@Neet_pg_bot

Q10: 30-year-old alcoholic male presents with diffuse abdominal pain and prostration. On examination guarding and rigidity of anterior abdominal wall is noted. Urgent X ray abdomen is done. Past medical records show multiple hospital visits for epigastric pain and positive “clo test’. Which of the following is the cause of this presentation? (Q850847)

A. Viscus perforation

B. Necrotising pancreatitis

C. Pseudo-pancreatic cyst

D. Acute mesenteric insufficiency

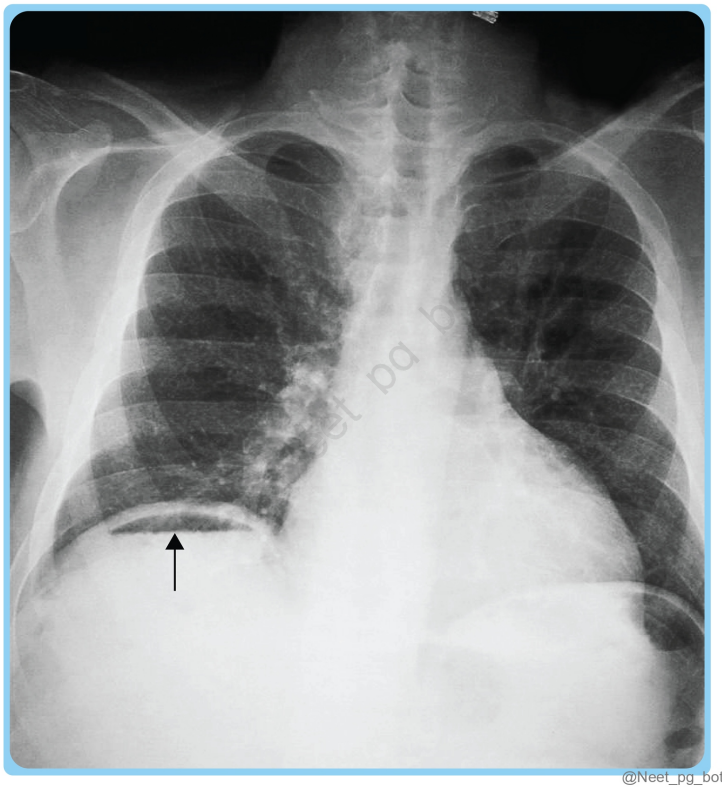

See Answer in Part B → Q10

@Neet_pg_bot

Q11: A 65-year-old patient with a history of atrial fibrillation presents with vomiting and sudden onset severe diffuse abdominal pain that is disproportionate to physical examination findings. On examination, the abdomen is soft with minimal tenderness, but tachycardia is noted. Laboratory studies reveal elevated lactate levels. What is the most appropriate next step to confirm the diagnosis? (Q850848)

A. Abdominal X-ray

B. CT angiography

C. Colonoscopy

D. Upper gastrointestinal endoscopy

See Answer in Part B → Q11

@Neet_pg_bot

Q12: HIV positive truck driver presents with odynophagia. UGIE shows serpiginous ulcers in oesophagus. Biopsy from ulcer base shows basophilic intranuclear and intracytoplasmic bodies. Which is the likely cause of this presentation? (Q850849)

A. HSV

B. CMV

C. Candida

D. Varicella zoster

See Answer in Part B → Q12

@Neet_pg_bot

Q13: 40-year-old female patient presents with dysphagia for past one year to solid food items . On examination, she has pallor with cheilosis and koilonychia. The diagnosis is? (Q850851)

A. Plummer Vinson syndrome

B. Oesophageal cancer

C. Achalasia cardia

D. Tylosis palmaris

See Answer in Part B → Q13

@Neet_pg_bot

Q14: Which of the following conditions will have "watermelon appearance of stomach mucosa" on upper GI endoscopy? (Q850852)

A. Gastric antral vascular ectasia

B. Menetrier disease

C. MALToma

D. Gastrointestinal stromal tumor

See Answer in Part B → Q14

@Neet_pg_bot

• [05_Gastrointestinal System] 035 Diarrhea Malabsorption Syndromes - I

« Back to Folder Directory

[05_Gastrointestinal System] 035 Diarrhea Malabsorption Syndromes - I — Quick Jump

Q1 (p. 460)	*Q2 (p. 460)*	*Q3 (p. 461)*	*Q4 (p. 461)*	*Q5 (p. 462)*	*Q6 (p. 462)*
Q7 (p. 463)	*Q8 (p. 463)*	*Q9 (p. 463)*	*Q10 (p. 464)*	*Q11 (p. 464)*	*Q12 (p. 465)*
Q13 (p. 465)	*Q14 (p. 466)*	*Q15 (p. 466)*	*Q16 (p. 467)*	*Q17 (p. 467)*	*Q18 (p. 467)*
Q19 (p. 468)	*Q20 (p. 468)*	*Q21 (p. 469)*	*Q22 (p. 469)*	*Q23 (p. 469)*	*Q24 (p. 470)*

Q1: Which of the following GI condition will have intestinal biopsy finding of normal villi with epithelial cells vacuolated with fat post prandially? (Q850870)

A. Abetalipoproteinemia

B. Agammaglobulinemia

C. Intestinal lymphangiectasia

D. Intestinal lymphoma

See Answer in Part B → Q1

@Neet_pg_bot

Q2: Which of the following organisms is most classically associated with gastroenteritis due to ingestion of a preformed toxin? (Q890578)

A. Salmonella enterica

B. Staphylococcus aureus

C. Shigella dysenteriae

D. Campylobacter jejuni

See Answer in Part B → Q2

@Neet_pg_bot

Q3: A 40 y/o woman presents with acute, profuse watery diarrhoea and severe dehydration after consuming contaminated water. Stool microscopy findings are shown below. She is hypotensive, with laboratory evidence of prerenal azotemia. Which of the following statements best distinguishes this presentation from osmotic diarrhoea in terms of fluid and electrolyte pathophysiology? (Q890577)

A. The diarrhoea would cease immediately upon stopping oral intake

B. The diarrhoea persists despite a 24-hour fast

C. The stool pH is acidic due to bacterial fermentation

D. The primary driver of fluid loss is nutrient malabsorption

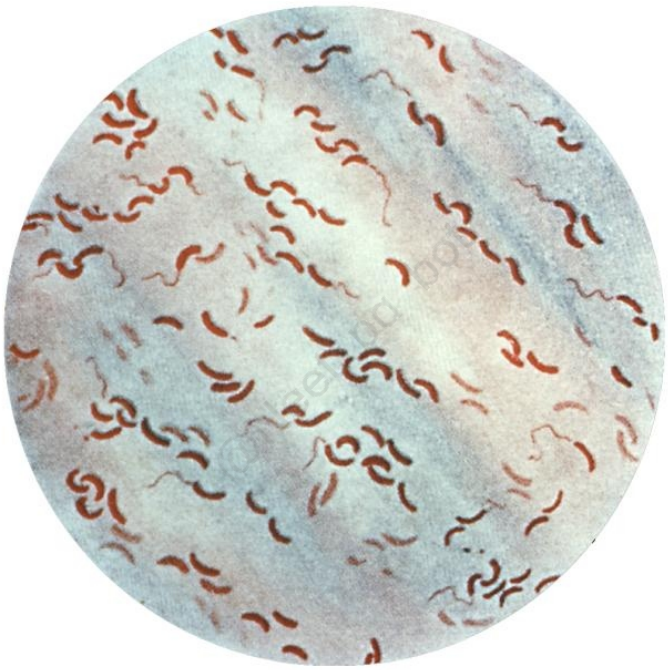

@Neet_pg_bot

See Answer in Part B → Q3

@Neet_pg_bot

Q4: A history of exposure to contaminated water in a patient presenting with diarrhoea most strongly raises concern for which of the following etiologic agents? (Q890576)

A. Staphylococcus aureus

B. Giardia lamblia

C. Clostridioides difficile

D. Cytomegalovirus

See Answer in Part B → Q4

@Neet_pg_bot

Q5: A 22 y/o man with 2 days of fever and right lower-quadrant abdominal pain with mild diarrhoea. O/E, he has tenderness at McBurney's point. Laparoscopy reveals the terminal ileum is thickened and inflamed with mesenteric lymphadenopathy. Which organism is the most likely etiologic agent responsible for this presentation? (Q890575)

A. Campylobacter jejuni

B. Yersinia enterocolitica

C. Shigella dysenteriae

D. Giardia lamblia

See Answer in Part B → Q5

@Neet_pg_bot

Q6: In the evaluation of diarrhoea in an immunocompromised adult, which of the following viral agents should be considered a potential aetiology? (Q890574)

A. Hepatitis A virus

B. Adenovirus

C. Hepatitis C virus

D. Epstein-Barr virus

See Answer in Part B → Q6

@Neet_pg_bot

Q7: Which pathophysiologic mechanism is primarily responsible for the diarrhoea observed in patients with bile acid malabsorption? (Q890572)

A. Osmotic retention of water by unabsorbed fatty acids

B. Stimulation of active colonic fluid and electrolyte secretion

C. Exudation of protein and fluid due to mucosal inflammation

D. Inhibition of pancreatic enzyme activity

See Answer in Part B → Q7

@Neet_pg_bot

Q8: A 30 y/o woman presents with chronic diarrhoea and hypokalemia. Stool analysis shows a low faecal osmotic gap (<50 mOsm/kg). Factitious diarrhoea due to laxative abuse is suspected. Which of the following is the most appropriate diagnostic test to confirm the diagnosis? (Q890571)

A. Urine D-xylose test

B. Stool laxative screen

C. 72-hour faecal fat collection

D. Serum chromogranin A

See Answer in Part B → Q8

@Neet_pg_bot

Q9: Which of the following faecal osmotic gap values is most characteristic of secretory diarrhoea? (Q890570)

A. >125 mOsm/kg

B. >100 mOsm/kg

C. >50 mOsm/kg

D. <50 mOsm/kg

See Answer in Part B → Q9

@Neet_pg_bot

Q10: Which of the following clinical features is most characteristic of diarrhoea originating from the small intestine? (Q890568)

A. Frequent passage of small-volume stools

B. Presence of tenesmus

C. Large-volume watery stools

D. Frank hematochezia (bright red blood)

See Answer in Part B → Q10

@Neet_pg_bot

Q11: A 27 y/o man develops abdominal bloating, crampy pain, and diarrhoea shortly after consuming milk. Stool analysis is performed while he is symptomatic. Which of the following stool profiles is most consistent with lactose intolerance? (Q890566)

A. High pH (>7.0) and a low stool osmotic gap (<50 mOsm/kg)

B. Low pH (<6.0) and a high stool osmotic gap (>100 mOsm/kg)

C. High pH (>7.0) and a high stool osmotic gap (>100 mOsm/kg)

D. Low pH (<6.0) and a low stool osmotic gap (<50 mOsm/kg)

See Answer in Part B → Q11

@Neet_pg_bot

Q12: A 34 y/o man with Crohn's disease undergoes surgical resection. Six months later, he presents with progressive weight loss and bulky, foul-smelling, floating stools despite a balanced diet.Which of the following pathophysiologic mechanisms best explains his steatorrhea? (Q890565)

A. Stimulation of colonic fluid secretion by unabsorbed bile acids

B. Hepatic bile acid synthesis compensating for faecal losses

C. Depletion of the circulating bile acid pool

D. Primary failure of pancreatic enzyme secretion

See Answer in Part B → Q12

@Neet_pg_bot

Q13: A 16-year-old boy presents with intensely itchy vesicular skin lesions on elbows and knees. Her mother says that she is giving him rice based diet only and he does not tolerate cereals. Skin biopsy was performed from the lesions and IF staining is shown below. Which of the following is the most likely diagnosis? (Q850854)

A. Bullous pemphigoid

B. Pemphigus vulgaris

C. Dermatitis herpetiformis

D. Psoriasis

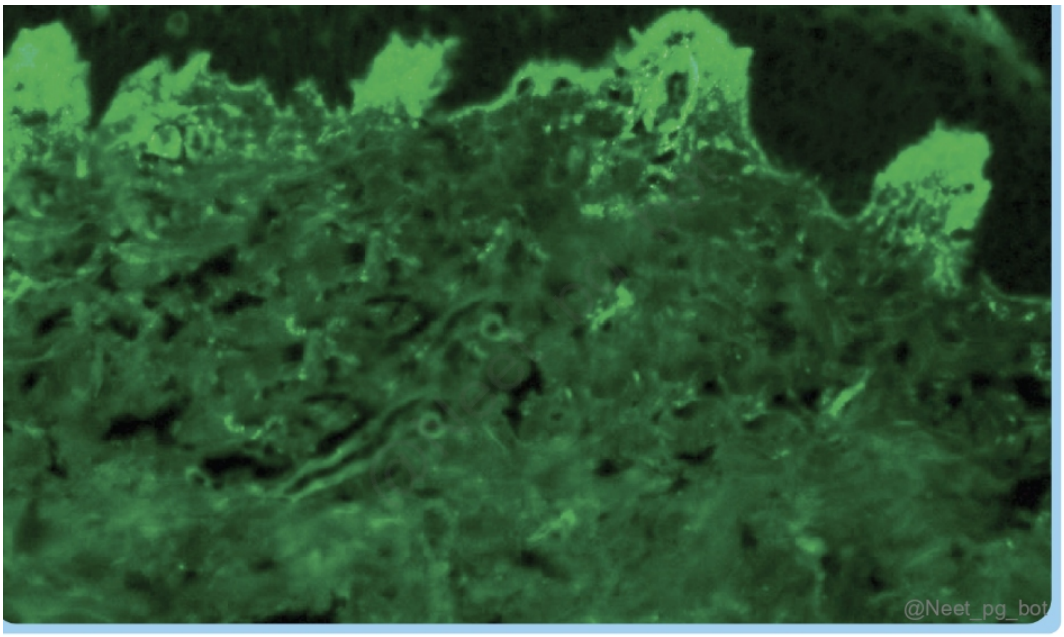

See Answer in Part B → Q13

@Neet_pg_bot

Q14: Which of the following diseases is not a cause of protein losing enteropathy? (Q850868)

A. Ulcerative colitis

B. Menetrier's disease

C. Intestinal lymphangiectasia

D. Abetalipoproteinemia

See Answer in Part B → Q14

@Neet_pg_bot

Q15: Gold standard investigation for steatorrhea is? (Q850866)

A. 72-hour faecal fat estimation

B. Breath triolein test

C. PIVKA test

D. Small intestinal mucosal biopsy

See Answer in Part B → Q15

@Neet_pg_bot

Q16: You are asked to evaluate lab reports of patient with peripheral oedema. Serum albumin is low and serum globulin is low. Which of the following is likely cause? (Q850865)

A. Cirrhosis

B. Minimal change disease

C. Protein losing enteropathy

D. SCID

See Answer in Part B → Q16

@Neet_pg_bot

Q17: Stool alpha1 anti-trypsin levels are used for diagnosis of which of the following disease? (Q850864)

A. Alpha 1 antitrypsin deficiency

B. Protein losing enteropathy

C. Small bowel syndrome

D. Abetalipoproteinemia

See Answer in Part B → Q17

@Neet_pg_bot

Q18: Which of the following is correct treatment of tropical sprue? (Q850863)

A. Tetracycline with folic acid

B. Ceftriaxone with TMP-SMX

C. Ofloxacin with Ornidazole

D. Budesonide ileal release preparation

See Answer in Part B → Q18

@Neet_pg_bot

Q19: 30-year-old woman with scleroderma was having steatorrhea and anaemia. She was found to have vitamin B12 deficiency and elevated serum folate levels. Which is next best investigation to be done in this patient? (Q850862)

A. Anti topoisomerase antibody

B. Duodenal aspirate for bacterial titers

C. Small intestinal mucosal biopsy

D. Breath urea test

See Answer in Part B → Q19

@Neet_pg_bot

Q20: 30-year-old woman with scleroderma was having steatorrhea and anaemia. She was found to have vitamin B12 deficiency and elevated serum folate levels. Which of the following is probable cause of her malabsorptive diarrhoea? (Q850861)

A. Chronic pancreatitis

B. Autoimmune gastritis

C. Small intestinal bacterial overgrowth

D. Whipple’s disease

See Answer in Part B → Q20

@Neet_pg_bot

Q21: Severity of celiac sprue is determined by which classification? (Q850859)

A. Forrest

B. Marsh

C. Vienna and Montreal

D. Truelove and Witts

See Answer in Part B → Q21

@Neet_pg_bot

Q22: Middle aged man presented with arthralgias, diarrhoea, weight loss and abdominal pain. Small intestinal mucosal biopsy shows PAS positive macrophages laden with intracellular bacteria. Which of the following is correct about management of this patient? (Q850858)

A. Oral TMP-SMX

B. Ceftriaxone

C. Ceftriaxone plus oral TMP-SMX

D. Tetracycline plus oral TMP-SMX

See Answer in Part B → Q22

@Neet_pg_bot

Q23: Which of the following is not correct about celiac sprue? (Q850856)

A. Lactase deficiency

B. Steatorrhea

C. Secretory diarrhoea

D. Lipid laden intestinal epithelial cells that appears normal after 72 hours fasting

See Answer in Part B → Q23

@Neet_pg_bot

Q24: Which of the following is correct about celiac sprue? (Q850855)

A. Demonstration of host genetic factors HLA DQ2 DQ8 is a must for diagnosis

B. BROW cereals intake is mainstay of managing the disease

C. Presents with iron deficiency anaemia

D. Leading cause is colonization of gut by Tropheryma whippelli

See Answer in Part B → Q24

@Neet_pg_bot

• [05_Gastrointestinal System] 036 Previous Year Questions

« Back to Folder Directory

[05_Gastrointestinal System] 036 Previous Year Questions — Quick Jump

Q1 (p. 471)	*Q2 (p. 471)*	*Q3 (p. 471)*	*Q4 (p. 472)*	*Q5 (p. 472)*	*Q6 (p. 473)*
Q7 (p. 473)	*Q8 (p. 474)*	*Q9 (p. 475)*	*Q10 (p. 475)*	*Q11 (p. 476)*	*Q12 (p. 476)*
Q13 (p. 477)	*Q14 (p. 477)*	*Q15 (p. 477)*	*Q16 (p. 478)*	*Q17 (p. 478)*	*Q18 (p. 478)*
Q19 (p. 479)	*Q20 (p. 479)*				

Q1: What is not a characteristic feature of Wilson's disease? (Q856381)

A. Autosomal recessive disease

B. No free radical injury

C. ATP7B gene involved

D. Presents before age 40 with liver disease

See Answer in Part B → Q1

@Neet_pg_bot

Q2: Which classification is used for Barrett esophagus? (Q866826)

A. Prague classification

B. Savary-Miller classification

C. Johnson classification

D. Forrest classification

See Answer in Part B → Q2

@Neet_pg_bot

Q3: 30 year old male is found to have anemia (MCV 110 fl) with leukonychia and enlarged spleen. The clinical diagnosis is? (Q866825)

A. Portal Hypertension

B. Plummer-Vinson syndrome

C. Achalasia cardia

D. Tylosis palmaris

See Answer in Part B → Q3

@Neet_pg_bot

Q4: A patient with osteoarthritis, for the last 3 months, has been taking ibuprofen and has developed occult GI bleeding. Which is correct about the cause? (Q866795)

A. PGE-2 and prostacyclin production were reduced

B. Increased acid production

C. PGE-1 and prostacyclin production were reduced

D. Mucosal injury due to inhibition of COX-2

See Answer in Part B → Q4

@Neet_pg_bot

Q5: 24-year-old female presents with dysphagia, weight loss and bronchiectasis. Which investigation should be done to confirm the diagnosis. Barium swallow was shown? (Q866504)

A. Esophageal manometry

B. Upper GI endoscopy

C. CT chest

D. CECT chest



See Answer in Part B → Q5

@Neet_pg_bot

Q6: A 70-year-old male patient presents with a complaint of dysphagia, particularly for solids, which has been progressively worsening over the past few months. Additionally, he has experienced significant weight loss and cachexia over the same period. Which of the following diagnostic choices is best for this patient? (Q860394)

A. UGIE

B. Manometry

C. Barium swallow

D. Barium meal follow through

See Answer in Part B → Q6

@Neet_pg_bot

Q7: In which of the following conditions is pneumomediastinum commonly found? (Q860160)

A. Pulsion diverticulum

B. Boerhaave syndrome

C. Mallory-Weiss syndrome

D. Pericarditis

See Answer in Part B → Q7

@Neet_pg_bot

Q8: A patient with inflammatory bowel disease presents with the following lesion. What is the most likely diagnosis? (Q859643)

A. Erythema nodosum

B. Pyoderma gangrenosum

C. Diabetic ulcer

D. Venous ulcer



See Answer in Part B → Q8

@Neet_pg_bot

Q9: A 15-year-old girl presented with fatigue, chronic diarrhoea, weight loss, bone pain and abdominal distension. Investigations revealed iron deficiency anemia and osteoporosis. Which of the following is the single best test to be done for her evaluation? (Q858444)

A. TSH levels

B. C-peptide levels

C. Urine sugar and ketone

D. IgA tissue transglutaminase antibody

See Answer in Part B → Q9

@Neet_pg_bot

Q10: A 49-year-old male is experiencing recurring episodes of watery diarrhea, dehydration, hypokalemia, and achlorhydria. Which type of neuroendocrine tumor could potentially cause these symptoms? (Q858363)

A. Insulinoma

B. Somatostatinoma

C. VIPoma

D. Glucagonoma

See Answer in Part B → Q10

@Neet_pg_bot

Q11: What is the probable diagnosis of a patient who has significant abdominal swelling and laboratory analysis of the fluid obtained through paracentesis reveals SAAG <1.1? (Q856355)

A. Congestive heart failure

B. Myxoedema

C. Budd Chiari syndrome

D. Tuberculosis

See Answer in Part B → Q11

@Neet_pg_bot

Q12: Which of the following are not included in the components of the MELD (2016) score? (Q856338)

A. Bilirubin

B. INR

C. Albumin

D. Creatinine

See Answer in Part B → Q12

@Neet_pg_bot

Q13: Mark the correct statement regarding inflammatory bowel disease. (Q855605)

A. Skip lesions are present in Crohn's disease

B. Mucosal layers are involved in Crohn's while transmural involvement seen in ulcerative colitis

C. Inflammatory bowel disease doesn't have a genetic predisposition

D. Crohn's is curable through surgical resection of the affected segment

See Answer in Part B → Q13

@Neet_pg_bot

Q14: A patient was taking ampicillin for an upper respiratory tract infection. Then he started having watery diarrhoea for the past 3 days. Which is the drug of choice to manage this condition? (Q854689)

A. Metronidazole

B. Fidaxomicin

C. Ciprofloxacin

D. Bezlotoxumab

See Answer in Part B → Q14

@Neet_pg_bot

Q15: A 42-year-old female presents with complaints of recurrent episodes of abdominal pain and cramps. An endoscopy is done and she is diagnosed with ulcerative colitis. She currently has 3-4 episodes of bloody stools per day. What is the appropriate initial treatment? (Q854665)

A. Budesonide

B. Sulfasalazine

C. Azathioprine

D. Bezlotoxumab

See Answer in Part B → Q15

@Neet_pg_bot

Q16: A known case of ulcerative colitis is not responding to an anti-TNF alpha agent. Which JAK inhibitor is preferred for moderate to severe ulcerative colitis? (Q853355)

A. Vedolizumab

B. Tofacitinib

C. Ozanimod

D. Leflunomide

See Answer in Part B → Q16

@Neet_pg_bot

Q17: Which of the following is not associated with celiac disease? (Q853345)

A. IgA transglutaminase positive

B. IgG antigliadin positive

C. Modified Marsh classification

D. HLA DQ6 and HLA DQ11

See Answer in Part B → Q17

@Neet_pg_bot

Q18: Which of the following symptoms suggests the use of steroids in IgA vasculitis? (Q840121)

A. Joint inflammation

B. Gastrointestinal hemorrhage

C. Abdominal discomfort

D. Dermatological eruption

See Answer in Part B → Q18

@Neet_pg_bot

Q19: Patient is identified as having a tumor in the ileum leading to urinary 5 HIAA being elevated. What is the diagnosis? (Q793830)

A. Carcinoid tumor

B. Neuroblastoma

C. Leiomyoma

D. Chromaffinoma

See Answer in Part B → Q19

@Neet_pg_bot

Q20: What is the probable diagnosis for a 50-year-old woman with a skin lesion visible in the provided image, which initially appeared small but has now spread to her entire limb and abdomen? Despite being on anticoagulation therapy, she has a longstanding history of diabetes and recurring deep vein thrombosis episodes. (Q793836)

A. Insulinoma

B. Gastrinoma

C. Glucagonoma

D. VIPoma



See Answer in Part B → Q20

@Neet_pg_bot

• [06_Hematology] 037 Chronic Lymphocytic Leukemia

« Back to Folder Directory

[06_Hematology] 037 Chronic Lymphocytic Leukemia — Quick Jump

Q1 (p. 481) *Q2 (p. 481)* *Q3 (p. 482)* *Q4 (p. 482)* *Q5 (p. 482)* *Q6 (p. 483)*
Q7 (p. 483) *Q8 (p. 484)* *Q9 (p. 484)* *Q10 (p. 484)* *Q11 (p. 485)* *Q12 (p. 485)*
Q13 (p. 485)

Q1: 70-year-old retired man presents with low grade fever, painless swelling in the neck and fatigue for the past 3 months. Examination reveals generalized lymphadenopathy and mild splenomegaly. CBC shows WBC 85,000/µL with absolute lymphocyte count 65,000/µL. Peripheral smear shows numerous small mature-appearing lymphocytes and smudge cells. Which of the following is the investigation of choice to confirm the diagnosis? (Q850873)

A. Peripheral blood flow cytometry

B. Bone marrow aspiration showing lymphoblasts > 20%

C. FISH analysis for 17p deletion

D. PCR for ZAP-70 expression

See Answer in Part B → Q1

@Neet_pg_bot

Q2: A 65-year-old man on an annual medical check-up is found to have lymphocytosis on routine CBC (total leukocyte count: 11,000/µL; absolute lymphocyte count: 4,200/µL). He is asymptomatic with no lymphadenopathy or organomegaly. Peripheral smear shows mature-appearing small lymphocytes. Flow cytometry reveals a monoclonal B-cell population with CLL immunophenotype. Which of the following features will help distinguish this condition from CLL? (Q850875)

A. Presence of B symptoms

B. Absolute B-cell count < 5 × 10y/L

C. Positive Coombs test

D. Expression of CD19, CD20, CD5

See Answer in Part B → Q2

@Neet_pg_bot

Q3: Radiation exposure is associated with increased risk of several hematological malignancies. Which of the following is least likely to be related to radiation exposure (Q850877)

A. ALL

B. AML

C. CML

D. CLL

See Answer in Part B → Q3

@Neet_pg_bot

Q4: Which of the following peripheral smear findings is not seen in CLL? (Q850879)

A. Spherocytes

B. Smudge cells

C. Prolymphocytes

D. Lymphoblasts

See Answer in Part B → Q4

@Neet_pg_bot

Q5: Which of the following statements regarding Richter transformation is correct? (Q850881)

A. Transformation of CLL into diffuse large B-cell lymphoma

B. Transformation of follicular lymphoma into diffuse large B-cell lymphoma

C. Transformation of marginal zone lymphoma into diffuse large B-cell lymphoma

D. Transformation of mantle cell lymphoma into diffuse large B-cell lymphoma

See Answer in Part B → Q5

@Neet_pg_bot

Q6: Leading cause of death in patients diagnosed with CLL? (Q850882)

A. Hypo-gammaglobulinemia

B. Heart disease

C. Kidney failure

D. Hyper viscosity syndrome

See Answer in Part B → Q6

@Neet_pg_bot

Q7: Known case of CLL is admitted with shortness of breath on minimal activity. Work up shows Hb= 7 gm%, TLC 25000 cells/cu.mm, platelet count of 50K/cu.mm, reticulocyte count is 2% with low haptoglobin and elevated LDH. Which of the following test would help in further evaluation of this patient? (Q850884)

A. Direct coombs test

B. ZAP-70

C. FISH

D. Treadmill test

See Answer in Part B → Q7

@Neet_pg_bot

Q8: Which of the following is drug used in CLL acts is inhibitor of antiapoptotic protein BCL-2? (Q850886)

A. Venetoclax

B. Ibrutinib

C. Idelalisib

D. Duvelisib

See Answer in Part B → Q8

@Neet_pg_bot

Q9: Evan syndrome is defined as? (Q850888)

A. Autoimmune hemolytic anemia + autoimmune thrombocytopenia

B. Autoimmune hemolytic anemia + autoimmune granulocytopenia

C. Pure red cell aplasia + autoimmune granulocytopenia

D. Pure red cell aplasia + autoimmune thrombocytopenia

See Answer in Part B → Q9

@Neet_pg_bot

Q10: Which of the following is not a component of Rai staging system used in CLL? (Q850890)

A. Lymphocytosis

B. Lymphadenopathy

C. Hepatosplenomegaly

D. Autoimmune hemolytic anemia

See Answer in Part B → Q10

@Neet_pg_bot

Q11: Which of the following is not a component of CLL prognostic index? (Q850893)

A. Age

B. Beta 2 microglobulin

C. Clinical staging

D. BCL-2

See Answer in Part B → Q11

@Neet_pg_bot

Q12: What secondary malignancy can be seen in patients with CLL? (Q850895)

A. Skin and prostate cancer

B. Oro-pharyngeal cancer

C. Ca- larynx

D. Hepatocellular cancer

See Answer in Part B → Q12

@Neet_pg_bot

Q13: A 62-year-old man presents with generalized lymphadenopathy and mild splenomegaly. Peripheral smear shows small-to-medium sized lymphoid cells with irregular nuclear contours. Lymph node biopsy reveals a diffuse proliferation of small lymphocytes with cleaved nuclei. Immunophenotyping shows CD19+, CD20+, CD5+, cyclin D1+, and negative for CD23. Which is the most likely diagnosis? (Q850897)

A. Chronic lymphocytic leukemia

B. Mantle cell lymphoma

C. Follicular lymphoma

D. Marginal zone lymphoma

See Answer in Part B → Q13

@Neet_pg_bot

• [06_Hematology] 038 Chronic Myeloid Leukemia

« Back to Folder Directory

[06_Hematology] 038 Chronic Myeloid Leukemia — Quick Jump

Q1 (p. 487) *Q2 (p. 487)* *Q3 (p. 487)* *Q4 (p. 488)* *Q5 (p. 488)* *Q6 (p. 489)*
Q7 (p. 489) *Q8 (p. 489)* *Q9 (p. 490)* *Q10 (p. 490)* *Q11 (p. 491)*

Q1: Which of the following is correct about the Philadelphia chromosome? (Q850439)

A. Balanced translocation between long arms of chromosome 9 and 22

B. Balanced translocation between short arms of chromosome 9 and 22

C. Unbalanced translocation between long arms of chromosome 9 and 22

D. Unbalanced translocation between short arms of chromosome 9 and 22

See Answer in Part B → Q1

@Neet_pg_bot

Q2: Which of the following is correct about CML? (Q850533)

A. Reciprocal exchange between breakpoint Cluster Region gene on chromosome 22, ABL1 gene on chromosome 9

B. Reciprocal exchange between breakpoint Cluster Region gene on chromosome 9, ABL1 gene on chromosome 22

C. Non-reciprocal exchange between breakpoint Cluster Region gene on chromosome 22, ABL1 gene on chromosome 9

D. Non-reciprocal exchange between breakpoint Cluster Region gene on chromosome 9, ABL1 gene on chromosome 22

See Answer in Part B → Q2

@Neet_pg_bot

Q3: Best for management of gatekeeper mutation T315I that prevents binding and causes resistance to known TKI in Chronic myeloid leukemia is? (Q850538)

A. Dasatinib

B. Nilotinib

C. Bosutinib

D. Ponatinib

See Answer in Part B → Q3

@Neet_pg_bot

Q4: Bcr-abl1 fusion gene is seen in which of the following blood cancers? (Q850559)

A. ALL

B. AML

C. CLL

D. Hairy cell leukemia

See Answer in Part B → Q4

@Neet_pg_bot

Q5: Which of the following findings is not seen in patients with CML? (Q850582)

A. Basophilia

B. Low serum Vitamin B12 levels

C. Low NAP score

D. Reticulin fibrosis in bone marrow

See Answer in Part B → Q5

@Neet_pg_bot

Q6: A 48-year-old male presents with fatigue and early satiety. On examination massive splenomegaly is seen. Work up is shown below. What is next best investigation to be done in this case CBC Bone marrow aspiration report Hb: 10.5 g/dL TLC: 1.5 × 10■ /mm³ Platelets: 4.0 × 10■ /mm³ Myeloblasts: 2% , Promyelocytes: 15% , Myelocytes: 25% , Metamyelocytes: 20% Band forms & neutrophils: 18% , Basophils: 6%, Blasts + promyelocytes together: <10%, NAP score: low (Q850605)

A. Bone marrow biopsy

B. Peripheral blood FISH for BCR-ABL1

C. Peripheral blood RT-PCR for BCR-ABL1

D. G-banding cytogenetics

See Answer in Part B → Q6

@Neet_pg_bot

Q7: A 35-year-old male with CML in chronic phase is started on imatinib. At diagnosis, bone marrow cytogenetics showed t(9;22)(q34;q11) in all metaphases. The treating physician now wants to assess whether he has achieved deep molecular remission. Which is the most appropriate investigation at this stage? (Q850613)

A. Conventional karyotyping from bone marrow aspirate

B. FISH for BCR-ABL on peripheral blood

C. Quantitative RT-PCR for BCR-ABL transcript levels

D. Qualitative PCR for BCR-ABL transcript

See Answer in Part B → Q7

@Neet_pg_bot

Q8: Which of the following is the most common presenting feature of CML? (Q850649)

A. Lymphadenopathy

B. Splenomegaly

C. Petechiae

D. Bone pain

See Answer in Part B → Q8

@Neet_pg_bot

Q9: Which of the following drugs is approved for CML in case of failure of >2 or more TKI (Q850656)

A. Omacetaxine

B. Dasatinib

C. Bosutinib

D. Nilotinib

See Answer in Part B → Q9

@Neet_pg_bot

Q10: 48-year-old man presents with fatigue, headache, and visual blurring. Examination reveals splenomegaly. CBC shows: Hb 9.8 g/dL, TLC 1.2 × 10■/µL, platelet count 650 × 10^3/µL. Peripheral smear shows marked myeloid proliferation with occasional myeloblasts. Fundoscopy reveals retinal vein engorgement. Which of the following is the most appropriate immediate next step in management? (Q850678)

A. Start imatinib therapy

B. Leukapheresis

C. Hydroxyurea + hydration

D. Allopurinol prophylaxis

See Answer in Part B → Q10

@Neet_pg_bot

Q11: 70-year-old male presents with fatigue, unintentional weight loss, and recurrent respiratory infections over the last 6 months. Examination reveals pallor and mild splenomegaly. CBC shows: Hb: 9.8 g/dL TLC: 28,000/µL (Monocytes: 5,500/µL) Platelets: 110,000/µL Peripheral smear shows monocytosis with occasional myelocytes and metamyelocytes. Bone marrow aspirate is hypercellular with increased monocytes, <20% blasts, and dysplastic features in granulocytic and megakaryocytic lineages. Cytogenetic analysis is negative for the Philadelphia chromosome Diagnosis is? (Q850681)

A. CML

B. AML

C. CMML

D. JMML

See Answer in Part B → Q11

@Neet_pg_bot

• [06_Hematology] 039 Acute Myeloid Leukemia

« Back to Folder Directory

[06_Hematology] 039 Acute Myeloid Leukemia — Quick Jump

Q1 (p. 492) *Q2 (p. 492)* *Q3 (p. 493)* *Q4 (p. 494)* *Q5 (p. 494)* *Q6 (p. 495)*
Q7 (p. 495) *Q8 (p. 496)* *Q9 (p. 496)* *Q10 (p. 496)*

Q1: Arsenic trioxide is used for treatment of which of the following malignancy? (Q850715)

A. Acute promyelocytic leukemia

B. Acute myelomonocytic leukemia

C. Acute monocytic leukemia

D. Acute megakaryocytic leukemia

See Answer in Part B → Q1

@Neet_pg_bot

Q2: 34-year-old female presented with progressive pallor and organomegaly. Work up shows low Hb, platelet count of 25000/mm3. raised PT and aPTT. Peripheral smear is given. Which of the following fusion gene is affected? (Q850689)

A. PML RARA

B. RUNX1 RUNX1T1

C. IGH NSD2

D. BCR ABL

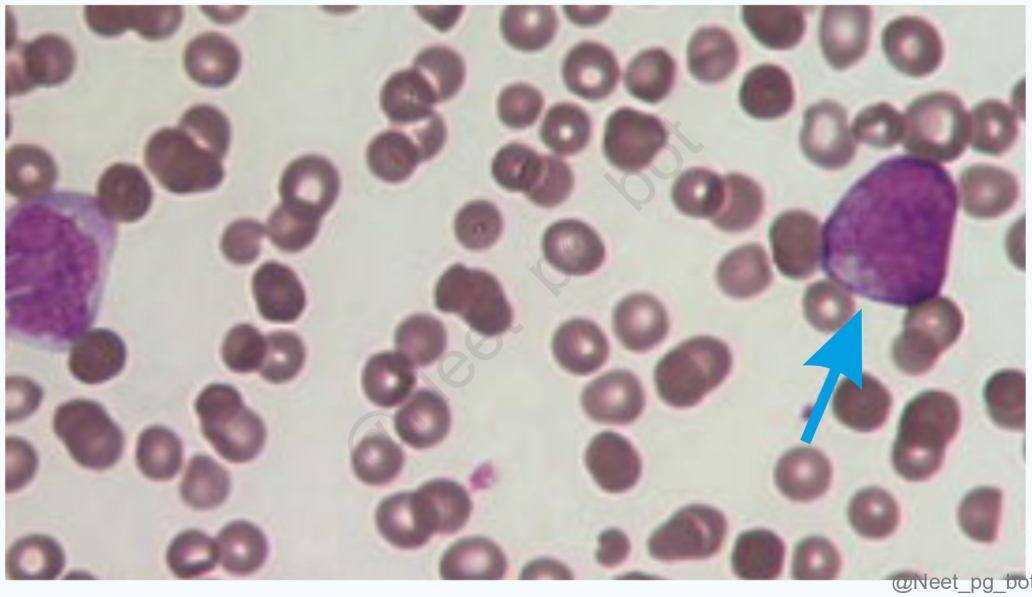

See Answer in Part B → Q2

@Neet_pg_bot

Q3: A 60-year-old man presents with recurrent episodes of bleeding from nose and progressive pallor. Peripheral smear shows the presence of cells shown below. Which of the following is the most common chromosomal abnormality seen in this condition? (Q850693)

A. t (8:21)

B. t (15:17)

C. t (14:18)

D. Inv (16)



See Answer in Part B → Q3

@Neet_pg_bot

Q4: A 45-year-old male presents with fatigue, progressive pallor and recurrent nasal bleeds. Bone marrow aspiration shows 10% myeloblasts with abnormal eosinophils. Cytogenetic analysis reveals inv(16) (p13;q22). Which of the following is the most appropriate diagnosis? (Q850695)

A. Myelodysplastic syndrome

B. Acute myeloid leukemia

C. Chronic myelomonocytic leukemia

D. Chronic myeloid leukemia

See Answer in Part B → Q4

@Neet_pg_bot

Q5: A 60-year-old man presented with early satiety and abdominal pain. On examination grossly enlarged spleen and liver is palpable Work up shows low Hb with WBC-50000/mm3 and platelet count of 6 lac/cu.mm. Which of the following will cause this presentation? (Q850702)

A. t (9:22)

B. Del 1q

C. t (15:17)

D. Del 3q

See Answer in Part B → Q5

@Neet_pg_bot

Q6: Which of the following chromosomal aberrations occur in topoisomerase II inhibitor–associated acute myeloid leukemia? (Q850705)

A. t (15:17)

B. inv16

C. 11q23

D. t (8:21)

See Answer in Part B → Q6

@Neet_pg_bot

Q7: Which type of AML shows extensive infiltration of skin, soft tissues, gingiva and meninges? (Q850710)

A. AML with maturation

B. Acute promyelocytic leukemia

C. Acute myelomonocytic leukemia

D. Acute monocytic leukemia

See Answer in Part B → Q7

@Neet_pg_bot

Q8: Which of the following genetic mutations is not responsible for AML (Q850711)

A. NPM1

B. FLT3-ITD

C. CEBPA

D. NOTCH1

See Answer in Part B → Q8

@Neet_pg_bot

Q9: A 28-year-old female with acute promyelocytic leukemia is started on ATRA therapy. After 10 days, she develops fever, dyspnea, weight gain, and pulmonary infiltrates on chest X-ray. Which of the following is the most appropriate treatment for this complication? (Q850719)

A. Discontinue ATRA permanently

B. Initiate high-dose corticosteroids

C. Start broad-spectrum antibiotics

D. Urgent leukapheresis

See Answer in Part B → Q9

@Neet_pg_bot

Q10: Which of the following clinical features is/are seen in patient with AML Gum hypertrophy Skin infiltration Lower extremity weakness Papilledema (Q850725)

A. 1,2

B. 1,2,3

C. 1,3,4

D. 1,2,3,4

See Answer in Part B → Q10

@Neet_pg_bot

• [06_Hematology] 040 Acute Lymphocytic Leukemia

« Back to Folder Directory

[06_Hematology] 040 Acute Lymphocytic Leukemia — Quick Jump

Q1 (p. 498) *Q2 (p. 498)* *Q3 (p. 498)* *Q4 (p. 499)* *Q5 (p. 499)* *Q6 (p. 500)*
Q7 (p. 500) *Q8 (p. 500)* *Q9 (p. 501)*

Q1: Adult T cell leukemia is caused by which of the following viruses? (Q850770)

A. HTLV-1

B. EBV

C. HPV

D. Polyoma virus

See Answer in Part B → Q1

@Neet_pg_bot

Q2: Which of the following is not correct about CNS leukemia? (Q850771)

A. LP is restricted to patients with platelet count less than 20K /cu mm

B. Intrathecal methotrexate to be given after performing lumbar puncture

C. LP is routine diagnostic test during work up of patient of ALL

D. Cell count > 5 cells/uL or leukemic blast cells on morphology is diagnostic

See Answer in Part B → Q2

@Neet_pg_bot

Q3: A 10-year-old patient presents with fatigue and bleeding. Peripheral blood shows anaemia, thrombocytopenia and neutropenia. Bone marrow flow cytometry shows blasts positive for both CD19, CD79a , CD13, CD33, along with cytoplasmic

myeloperoxidase. Which of the following is the most likely diagnosis? (Q850772)

A. B cell ALL

B. T cell ALL

C. Biphenotypic ALL

D. AML

See Answer in Part B → Q3

@Neet_pg_bot

Q4: Which of the following is correct about complete molecular response in patients with ALL? (Q850773)

A. Patient in remission, MRD not detectable, < 1 leukemia cell in 1,000 BM cells

B. Patient in remission, MRD not detectable, < 1 leukemia cell in 10,000 BM cells

C. Patient in remission, MRD not detectable, < 1 leukemia cell in 100,000 BM cells

D. Patient in remission, MRD not detectable, < 1 leukemia cell in 100,0000 BM cells

See Answer in Part B → Q4

@Neet_pg_bot

Q5: Which of the following types of ALL is associated with the Philadelphia chromosome? (Q850775)

A. Common ALL

B. Mature B cell ALL

C. T cell ALL

D. Pro B- ALL

See Answer in Part B → Q5

@Neet_pg_bot

Q6: What drugs are used in pre-phase therapy for a patient with Acute lymphoblastic leukemia? (Q850777)

A. Rasburicase

B. Allopurinol

C. Dexamethasone plus vincristine

D. Dexamethasone plus methotrexate

See Answer in Part B → Q6

@Neet_pg_bot

Q7: A 12-year-old boy with relapsed B-cell ALL is planned for therapy with CAR-T cells. In this context, CAR stands for which of the following? (Q850783)

A. Chimeric Antigen Receptor

B. Chimeric Antibody Receptor

C. Clustered Antigen Receptor

D. Chimeric Antigen Recognition

See Answer in Part B → Q7

@Neet_pg_bot

Q8: Which of the following is an anti CD-19 targeting antibody used in acute lymphoblastic leukemia? (Q850788)

A. Blinatumomab

B. Rituximab

C. Ruxolitinib

D. Dasatinib

See Answer in Part B → Q8

@Neet_pg_bot

Q9: The most common benign tumor in children is? (Q850791)

A. Hemangioma

B. Acute lymphoblastic lymphoma

C. Cerebellar astrocytoma

D. Medulloblastoma

See Answer in Part B → Q9

@Neet_pg_bot

• [06_Hematology] 041 Multiple Myeloma Plasma Cell Disorders

« Back to Folder Directory

[06_Hematology] 041 Multiple Myeloma Plasma Cell Disorders — Quick Jump

Q1 (p. 502) *Q2 (p. 502)* *Q3 (p. 503)* *Q4 (p. 503)* *Q5 (p. 505)* *Q6 (p. 505)*
Q7 (p. 505) *Q8 (p. 506)* *Q9 (p. 506)* *Q10 (p. 506)* *Q11 (p. 507)* *Q12 (p. 507)*

Q1: Which of the following is not a biomarker of malignancy in patient with symptomatic multiple myeloma (Q850793)

A. M protein on urinary or serum electrophoresis

B. Involved: uninvolved free light chain ratio > 100

C. > 1 focal lesion on MRI studies

D. Clonal bone marrow plasma cell percentage > 60%

See Answer in Part B → Q1

@Neet_pg_bot

Q2: A 72-year-old man presents with 3 months of low back pain, fatigue, and weight loss. Examination shows pallor and mild splenomegaly. Investigations reveal: Hemoglobin: 8.5 g/dL Serum calcium: 12.2 mg/dL Creatinine: 2.3 mg/dL Serum protein electrophoresis: M-spike in γ-region MRI spine: Multiple lytic lesions Peripheral smear: 25% plasma cells What is the most likely diagnosis? (Q850797)

A. Multiple myeloma

B. Monoclonal gammopathy of undetermined significance (MGUS)

C. Smoldering multiple myeloma

D. Primary plasma cell leukemia

See Answer in Part B → Q2

@Neet_pg_bot

Q3: You calculated eGFR of multiple myeloma on a follow up visit as 20 ml/min. Which of the following is the leading cause of this presentation? (Q850800)

A. Amyloidosis

B. Hypercalcemia

C. Pyelonephritis

D. Tubular damage by bence jones proteins

See Answer in Part B → Q3

@Neet_pg_bot

Q4: Comment on agarose gel electrophoresis and immunofixation reports? (Q850801)

A. Monoclonal Ig A kappa

B. Monoclonal Ig G kappa

C. Monoclonal Ig G kappa lambda

D. Polyclonal

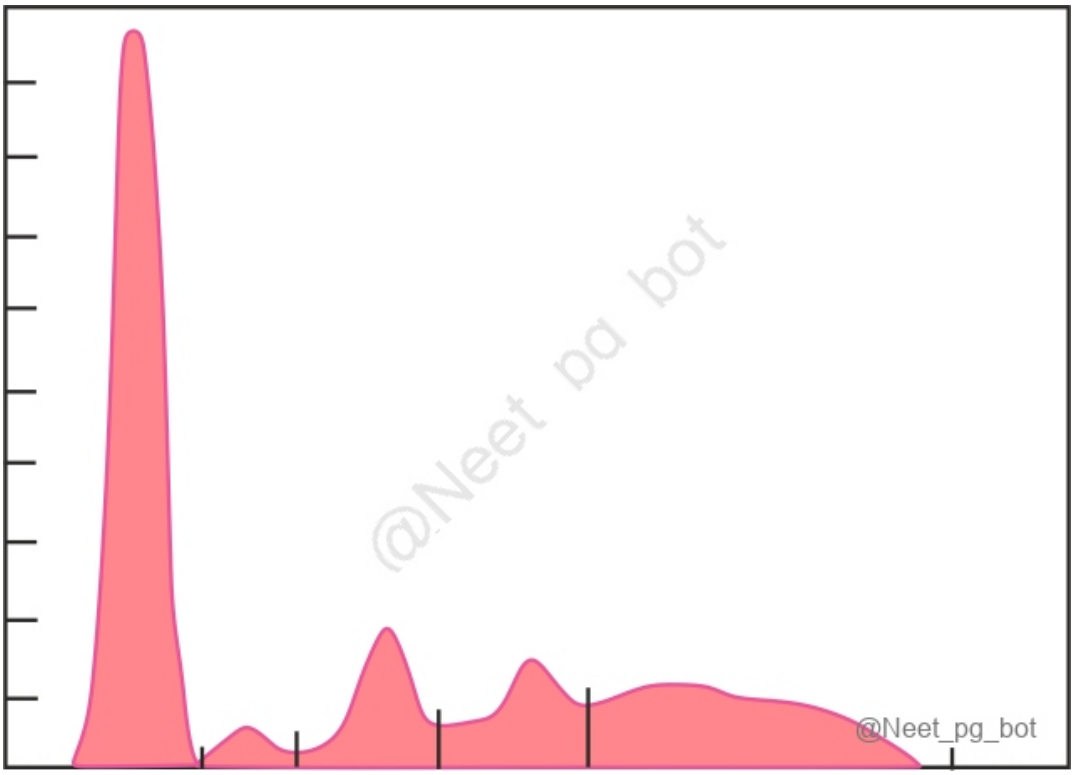

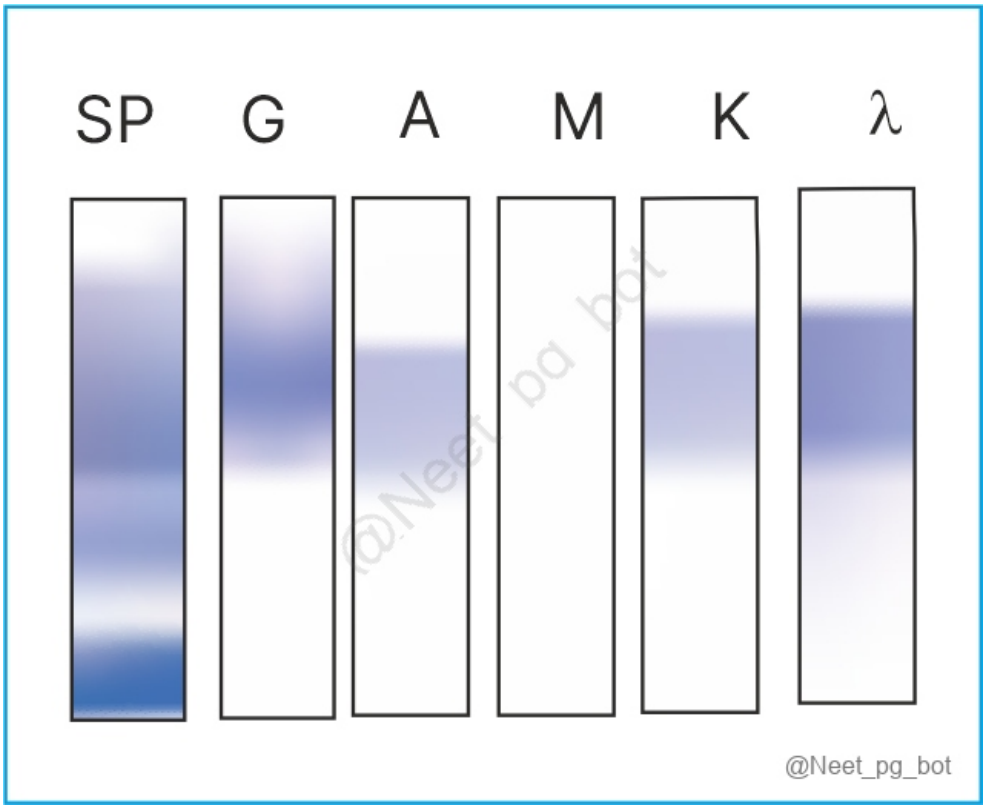

See Answer in Part B → Q4

@Neet_pg_bot

Q5: Which of the following is incorrect about histopathological findings in multiple myeloma? (Q850802)

A. Clock face chromatin

B. Intracytoplasmic Dutcher bodies

C. Mott cells

D. Eccentric nucleus with basophilic cytoplasm

See Answer in Part B → Q5

@Neet_pg_bot

Q6: Earliest manifestation of tubular damage in multiple myeloma due to bence jones proteins causes? (Q850803)

A. Glucosuria and aminoaciduria

B. Hematuria

C. Proteinuria

D. Metabolic alkalosis

See Answer in Part B → Q6

@Neet_pg_bot

Q7: Which of the following is not correct about multiple myeloma? (Q850804)

A. Increased anion gap

B. Pseudohyponatremia

C. Hyperviscosity

D. Reduced creatinine clearance

See Answer in Part B → Q7

@Neet_pg_bot

Q8: A 70-year-old male presents with progressive fatigue, recurrent headaches, blurred vision, and episodes of epistaxis for the past 2 months. On examination, there is pallor and mild hepatosplenomegaly. Labs are shown below. What is the most likely diagnosis? Hb: 8.5 g/dL Serum protein electrophoresis: M spike in the β–γ region Immunofixation: IgM monoclonal protein Bone marrow: infiltration with small lymphocytes and plasma cells (Q850807)

A. Multiple myeloma

B. Chronic lymphocytic leukemia

C. Waldenström macroglobulinemia

D. Monoclonal gammopathy of undetermined significance

See Answer in Part B → Q8

@Neet_pg_bot

Q9: A 70-year-old man presents with pallor and a low back ache. MRI spine shows lytic lesions in L5 and S1. In his past medical history, he had pneumonia last winter. Workup shows Hb 7 gm/dl, deranged RFT and serum calcium 11.2 mg/dl. Which of the following investigations is the next best test for the suspected diagnosis of this patient? (Q850808)

A. Serum electrophoresis

B. Peripheral blood flow cytometry

C. Serum free light chain assay

D. Bone marrow biopsy

See Answer in Part B → Q9

@Neet_pg_bot

Q10: Which of the following is correct about multiple myeloma? 1. Decreased anion gap 2. Glucosuria and aminoaciduria 3. Hypoviscosity 4. Increased creatinine clearance (Q850809)

A. 1,2

B. 1,4

C. 1,2,3

D. 1,2,4

See Answer in Part B → Q10

@Neet_pg_bot

Q11: A 70 year old man recently diagnosed with multiple myeloma has been declared non eligible for transplantation due to poor cardiovascular health. Which of the following drug combinations is used for management of this patient? (Q850810)

A. Lenalidomide + dexamethasone + Bortezomib + daratumumab

B. Rituximab + cyclophosphamide + Vincristine

C. Adriamycin + bleomycin+ Vinblastine

D. Fludarabine + cyclophosphamide+ Rituximab + daratumumab

See Answer in Part B → Q11

@Neet_pg_bot

Q12: A 60-year-old female presents with weakness, back pain and repeated infections. Work up shows M spike on serum electrophoresis. Bone marrow biopsy shows 15% plasma cells. The prognosis of this patient is best determined by which of the following? (Q850811)

A. Ig G and albumin

B. Hb and albumin

C. Albumin and LDH

D. Albumin and beta 2 Micro-globulin

See Answer in Part B → Q12

@Neet_pg_bot

• [06_Hematology] 042 Hodgkin S And Non-Hodgkin S Lymphoma

« Back to Folder Directory

[06_Hematology] 042 Hodgkin S And Non-Hodgkin S Lymphoma — Quick Jump

Q1 (p. 509)	*Q2 (p. 509)*	*Q3 (p. 509)*	*Q4 (p. 510)*	*Q5 (p. 511)*	*Q6 (p. 512)*
Q7 (p. 512)	*Q8 (p. 513)*	*Q9 (p. 513)*	*Q10 (p. 514)*	*Q11 (p. 514)*	*Q12 (p. 514)*
Q13 (p. 515)	*Q14 (p. 516)*	*Q15 (p. 516)*	*Q16 (p. 516)*	*Q17 (p. 517)*	*Q18 (p. 517)*

Q1: Which of the following neoplasms has the highest incidence of causing tumor lysis syndrome (Q851117)

A. Burkitt lymphoma

B. DLBCL

C. AML

D. ALL

See Answer in Part B → Q1

@Neet_pg_bot

Q2: Lumbar puncture and CSF cytology is part of diagnostic workup of all except? (Q851127)

A. ALL

B. AML

C. NHL

D. HL

See Answer in Part B → Q2

@Neet_pg_bot

Q3: A 72-year-old man presents with progressive abdominal distension and early satiety for 3 months. USG shows multiple enlarged para-aortic lymph nodes. CT abdomen confirms bulky retroperitoneal lymphadenopathy. Excisional biopsy of a lymph node was done and is shown below. Immunohistochemistry is positive for CD10, CD19, CD20, and BCL6. Which of the following is the most likely diagnosis? (Q851124)

A. Burkitt lymphoma

B. DLBCL

C. Follicular lymphoma

D. Mycosis fungoides

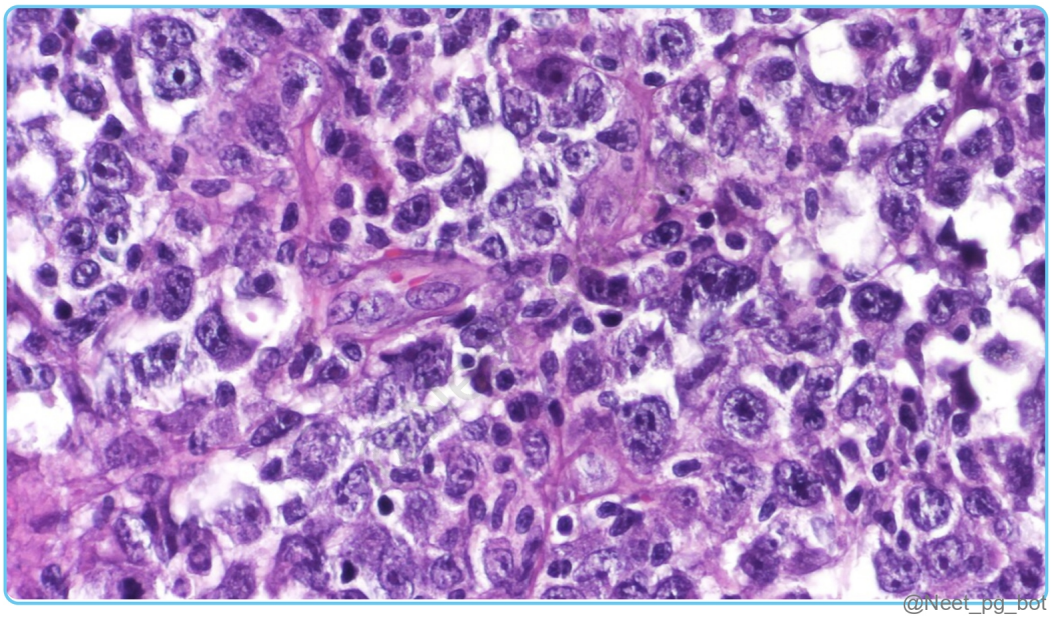

See Answer in Part B → Q3

@Neet_pg_bot

Q4: Which of the following is the most common type of Non-Hodgkin lymphoma (NHL)? (Q851123)

A. Nodular sclerosis

B. Mixed cellularity

C. Nodular lymphocytic predominant

D. Diffuse large B cell lymphoma

See Answer in Part B → Q4

@Neet_pg_bot

Q5: A 62-year-old man presents with generalized redness and scaling of the skin involving more than 80% of his body surface area, associated with intense itching. Examination reveals generalized lymphadenopathy and hepatosplenomegaly. Peripheral smear is shown below. Which of the following is the most likely diagnosis? (Q851122)

A. Mycosis fungoides

B. Sézary syndrome

C. Psoriasis vulgaris

D. Adult T-cell leukemia/lymphoma

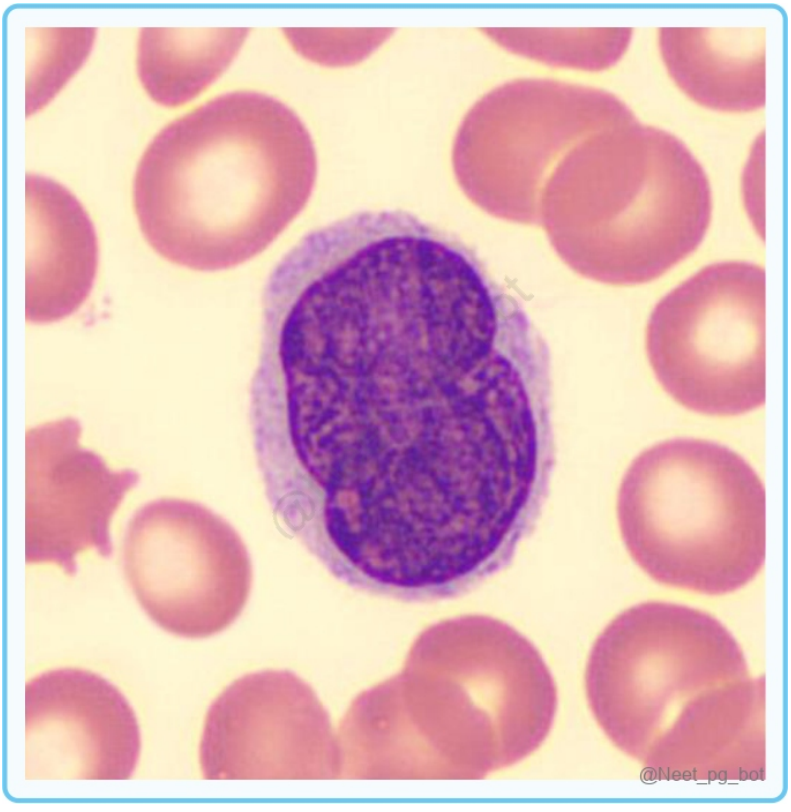

See Answer in Part B → Q5

@Neet_pg_bot

Q6: A 48-year-old man on medical tourism presents with generalized lymphadenopathy, skin rash, and hypercalcemia. Peripheral smear is shown below. Which of the following is the most likely diagnosis? (Q851121)

A. Sézary syndrome

B. Adult T-cell leukemia/lymphoma

C. Mycosis fungoides

D. Multiple myeloma

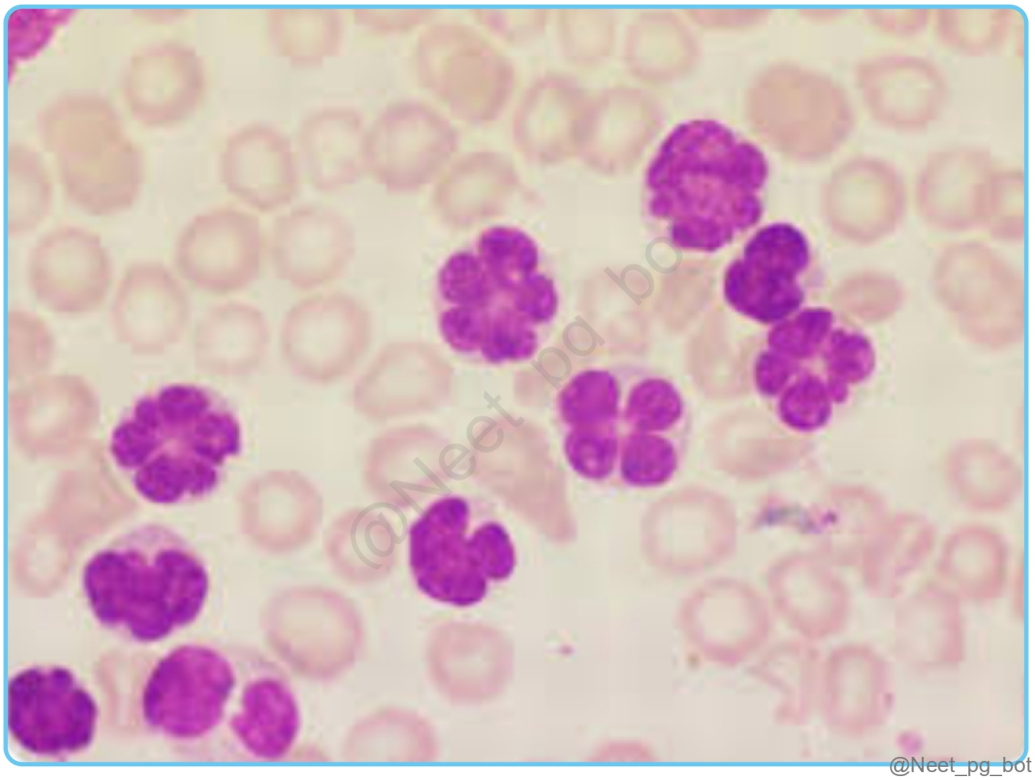

See Answer in Part B → Q6

@Neet_pg_bot

Q7: A 54-year-old woman presents with painless, generalized lymphadenopathy. Lymph node biopsy shows a nodular growth pattern with centrocytes and

centroblasts. Immunohistochemistry is positive for CD10 and BCL2. Which chromosomal translocation is most commonly associated with this lymphoma? (Q851120)

A. t(2:5)

B. t(2:8)

C. t(14:18)

D. t(11:14)

See Answer in Part B → Q7

@Neet_pg_bot

Q8: Which of the following lymphoma is seen in a 30 year old woman with SLE? (Q851119)

A. Extra nodal marginal zone B cell lymphoma

B. Diffuse large B cell lymphoma

C. Enteropathy associated T cell lymphoma

D. MALToma

See Answer in Part B → Q8

@Neet_pg_bot

Q9: Which of the following is not correct about burkitt lymphoma? (Q851118)

A. Most common chromosomal translocation is t(8:22)

B. Non endemic form presents with ascites

C. Biopsy shows sheets of monotonous cells with basophilic cytoplasm with interspersed macrophages

D. CD10, CD19, CD20, and BCL-6 positive and BCL-2 negative

See Answer in Part B → Q9

@Neet_pg_bot

Q10: Which of the following is incorrect about Hodgkin’s lymphoma? (Q851094)

A. B-cell tumor

B. HIV and EBV are risk factor

C. CD19, CD20, CD23, PAX-5 positive cells

D. Genetic aberration on chromosome 9

See Answer in Part B → Q10

@Neet_pg_bot

Q11: Which of the following chromosomal translocations is correct about anaplastic lymphoma? (Q851114)

A. t(2:5)

B. t(8:14)

C. t(8:22)

D. t(11:14)

See Answer in Part B → Q11

@Neet_pg_bot

Q12: A 45-year-old male presents with fever, night sweats, fatigue, and unintentional weight loss for 2 months. On examination, he has generalized lymphadenopathy and mild hepatosplenomegaly. Laboratory tests reveal anemia, elevated ESR, and hypergammaglobulinemia. Excision lymph node biopsy is shown. Which of the following viruses is implicated in its pathology (Q851108)

A. HIV

B. EBV

C. HCV

D. HHV8

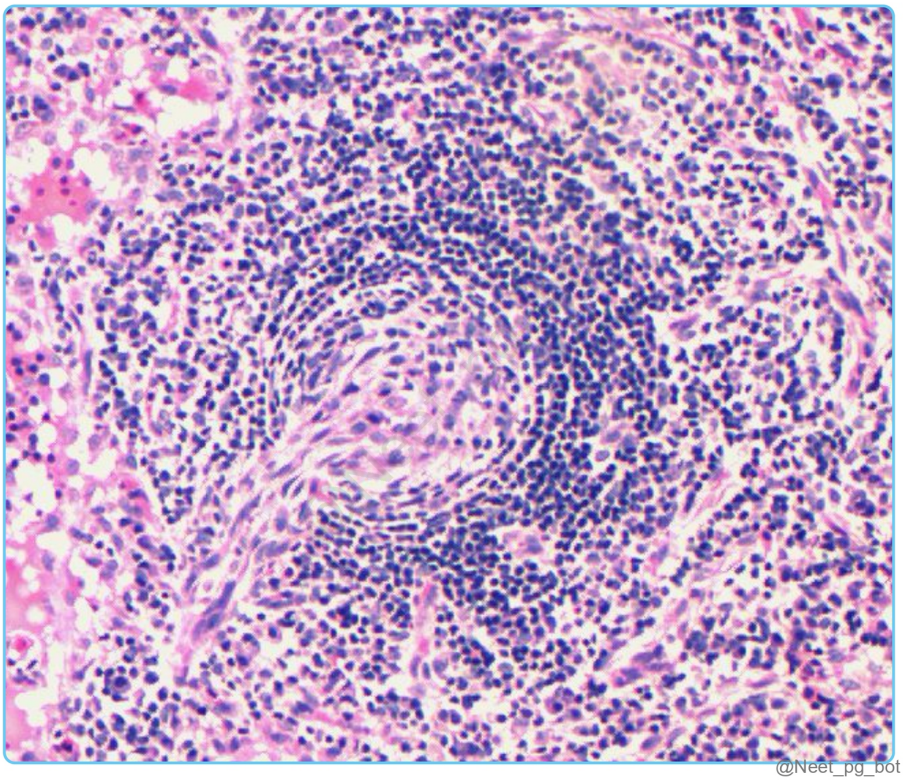

See Answer in Part B → Q12

@Neet_pg_bot

Q13: A patient is diagnosed with lymphoplasmacytic lymphoma (LPL). Which of the following viruses is most strongly associated with this condition? (Q851106)

A. EBV

B. HIV

C. HCV

D. HHV8

See Answer in Part B → Q13

@Neet_pg_bot

Q14: Which organism causes primary effusion lymphoma? (Q851104)

A. EBV

B. HIV

C. HCV

D. HHV8

See Answer in Part B → Q14

@Neet_pg_bot

Q15: A 28-year-old male presents with painless cervical lymphadenopathy for 3 months. He also reports intermittent fever, night sweats, and unintentional weight loss. Excisional lymph node biopsy shows classical Reed-Sternberg cells that are CD15+, CD30+, and weakly PAX-5+, with negative CD20. Staging scans reveal involvement of cervical and mediastinal lymph nodes without extranodal disease. What is the treatment of choice for this patient? (Q851103)

A. ABVD

B. R-CHOP

C. PCR

D. FCR

See Answer in Part B → Q15

@Neet_pg_bot

Q16: Which of the following is not a category B symptom in ann arbor classification for HL? (Q851101)

A. Unexplained weight loss of > 10% during 6 months

B. Unexplained cough > 2weeks

C. Unexplained fever > 38 C in last month

D. Recurrent drenching night sweats

See Answer in Part B → Q16

@Neet_pg_bot

Q17: A 20 year old girl presents with breathing difficulty at rest. On examination enlarged cervical lymph are palpated with rubbery consistency. CXR shows hilar lymphadenopathy. Biopsy shows large cells with abundant cytoplasm and bilobed nuclei. Which of the following is/are correct about this condition 1. Stellate inclusions in cytoplasm 2. Langhans type of giant cells 3. Aberration in chromosome 9 4. CD15 and CD 30 positivity (Q851099)

A. only 1

B. 1,2

C. 2,3

D. 3,4

See Answer in Part B → Q17

@Neet_pg_bot

Q18: A 20 year old girl presents with breathing difficulty at rest. On examination enlarged cervical lymph are palpated with rubbery consistency. CXR shows hilar lymphadenopathy. Biopsy shows large cells with abundant cytoplasm and bilobed nuclei. What is the diagnosis? (Q851097)

A. Sarcoidosis

B. Pulmonary TB

C. Langhans cell histiocytosis

D. Lymphoma

See Answer in Part B → Q18

@Neet_pg_bot

• [06_Hematology] 043 Thalassemia And Hereditary Spherocytosis

« Back to Folder Directory

[06_Hematology] 043 Thalassemia And Hereditary Spherocytosis — Quick Jump

Q1 (p. 519) *Q2 (p. 519)* *Q3 (p. 520)* *Q4 (p. 520)* *Q5 (p. 520)* *Q6 (p. 521)*
Q7 (p. 521) *Q8 (p. 521)* *Q9 (p. 522)* *Q10 (p. 522)* *Q11 (p. 522)* *Q12 (p. 523)*

Q1: In a child with thalassemia major, which of the following drugs should be started to reduce transfusion dependency? (Q851128)

A. Luspatercept

B. Deferoxamine

C. Deferiprone

D. Deferasirox

See Answer in Part B → Q1

@Neet_pg_bot

Q2: A 4-year-old child with anemia, chipmunk facies and splenomegaly is found to have low Hb A and elevated HbF and HbA2. He has received multiple blood transfusions for which no records are available Which of the following is least likely to occur as a complication in this case? (Q851129)

A. Lung fibrosis

B. Cardiomyopathy

C. Diabetes

D. Infections with capsulated organisms

See Answer in Part B → Q2

@Neet_pg_bot

Q3: Investigation of choice for diagnosis of beta thalassemia ? (Q851130)

A. NESTROFT

B. Gene sequencing

C. HPLC

D. Hemoglobin electrophoresis

See Answer in Part B → Q3

@Neet_pg_bot

Q4: Earliest radiological finding in patients with beta thalassemia is (Q851131)

A. Widening of diploic spaces of skull

B. Lytic lesion in vertebrae

C. Squaring of metacarpals

D. AVN of metacarpals

See Answer in Part B → Q4

@Neet_pg_bot

Q5: A 2 year old child is undergoing workup for severe anemia. Labs show Low MCV, Increased MCHC. USG abdomen shows enlarged spleen with acoustic shadows in gall bladder. Which of the following is not correct about this patient? (Q851133)

A. Peripheral smear shows RBC that lack central pallor

B. Black pigmented gall stones in gall bladder

C. Counsel about Elective splenectomy

D. Defective gene on chromosome 14

See Answer in Part B → Q5

@Neet_pg_bot

Q6: In a transfusion dependent thalassemia major child, deferoxamine should be started at serum ferritin values > _____ ug/L (Q851134)

A. 500

B. 1000

C. 1500

D. 2000

See Answer in Part B → Q6

@Neet_pg_bot

Q7: A 10 year old boy presents with pallor. Work up shows Hb= 8 gm%, Peripheral smear has anisocytosis with poikilocytosis, Hemoglobin electrophoresis report has Hb A = 60%, HbF = 34%, HbA2 = 6%. Diagnosis is? (Q851135)

A. Thalassemia minor

B. Thalassemia major

C. Thalassemia intermedia

D. Thalassemia trait

See Answer in Part B → Q7

@Neet_pg_bot

Q8: Which of the following is incorrect about Hb Barts? (Q851136)

A. Extremely low oxygen affinity

B. Causes functional tissue hypoxia

C. Unstable structure so precipitates in RBC

D. Presents as non immunogenic hydrops fetalis

See Answer in Part B → Q8

@Neet_pg_bot

Q9: In a newly diagnosed beta thalassemia major patient which manifestation will not be seen? (Q851137)

A. Ectopic hematopoiesis

B. Reticulocyte count of 0.1%

C. Ineffective erythropoiesis

D. Elevated LDH and low Haptoglobin levels

See Answer in Part B → Q9

@Neet_pg_bot

Q10: You are counseling parents of a 3 year old severely anaemic child diagnosed with hereditary spherocytosis about surgical options. Which of the following will you inform them about? (Q851138)

A. Splenectomy

B. Gall bladder removal

C. Splenectomy plus gall bladder removal

D. Nephrectomy

See Answer in Part B → Q10

@Neet_pg_bot

Q11: Which of the following tests is used in diagnosis of hereditary spherocytosis? (Q851139)

A. Acidified lysis test

B. Acid glycerol lysis test

C. Sucrose hemolysis test

D. Flow cytometry for CD55 and CD59

See Answer in Part B → Q11

@Neet_pg_bot

Q12: A 25-year-old man of Southeast Asian origin presents with anemia and fatigue. CBC shows : Hemoglobin: 9.2 g/dL, MCV: 68 fL, MCH: 22 pg/dl. Peripheral smear shows microcytosis, hypochromia, and numerous target cells. Supravital staining with brilliant cresyl blue reveals multiple small inclusions in RBCs giving a “golf ball” appearance. Which of the following is the most likely diagnosis? (Q851140)

A. β-thalassemia minor

B. HbH disease

C. Sideroblastic anemia

D. Hereditary spherocytosis

See Answer in Part B → Q12

@Neet_pg_bot

• [06_Hematology] 044 Sickle Cell Disease G6Pd Deficiency And Other Hemolytic Anemias

« Back to Folder Directory

[06_Hematology] 044 Sickle Cell Disease G6Pd Deficiency And Other Hemolytic Anemias — Quick Jump

Q1 (p. 524)	*Q2 (p. 524)*	*Q3 (p. 525)*	*Q4 (p. 525)*	*Q5 (p. 525)*	*Q6 (p. 526)*
Q7 (p. 526)	*Q8 (p. 526)*	*Q9 (p. 527)*	*Q10 (p. 527)*	*Q11 (p. 528)*	*Q12 (p. 528)*
Q13 (p. 528)	*Q14 (p. 529)*	*Q15 (p. 529)*	*Q16 (p. 529)*	*Q17 (p. 530)*	*Q18 (p. 531)*
Q19 (p. 531)	*Q20 (p. 532)*	*Q21 (p. 532)*			

Q1: All of the following are complications of sickle cell disease except? (Q851153)

A. Stroke

B. Pulmonary hypertension

C. Vitreous hemorrhage

D. Neonatal jaundice

See Answer in Part B → Q1

@Neet_pg_bot

Q2: A 15-year-old male with sickle cell anemia presents with hematuria and flank pain. Urinalysis shows isosthenuria (urine specific gravity ~1.010). Which of the following is the most likely explanation? (Q851199)

A. Medullary infarction causing papillary necrosis

B. Glomerulonephritis due to immune complex deposition

C. Recurrent urinary tract infection causing tubular damage

D. Hyperfiltration injury from chronic anemia

See Answer in Part B → Q2

@Neet_pg_bot

Q3: For prenatal diagnosis of sickle cell anemia which is the best test? (Q851195)

A. NESTROFT

B. Sickling test

C. DNA analysis

D. Hb electrophoresis

See Answer in Part B → Q3

@Neet_pg_bot

Q4: Heinz bodies in G6PD deficiency is? (Q851193)

A. Denatured Hemoglobin

B. DNA remnants

C. RNA remnants

D. Iron granules

See Answer in Part B → Q4

@Neet_pg_bot

Q5: Which of the following is correctly matched? (Q851191)

A. Heinz bodies: Asplenia

B. Howell Jolly bodies: G6PD

C. Cabot rings : Dyserythropoiesis

D. Pappenheimer bodies: Lead poisoning

See Answer in Part B → Q5

@Neet_pg_bot

Q6: Which of the following is correct about Paroxysmal nocturnal hemoglobinuria (Q851188)

A. Extravascular hemolysis

B. Sucrose hemolysis test is gold standard

C. Thrombosis of hepatic veins

D. Hypocellular bone marrow that becomes hypercellular in late stages

See Answer in Part B → Q6

@Neet_pg_bot

Q7: A 6-year-old boy is brought to the clinic with multiple petechiae over his lower limbs and mild gum bleeding for 2 days. He had an upper respiratory infection about 3 weeks ago. Examination shows scattered ecchymoses and petechial rash but no hepatosplenomegaly or lymphadenopathy. CBC reveals: Hemoglobin: 12.4 g/dL, Total leukocyte count: 8,500/mm³ and Platelet count: 35,000/mm³ Peripheral smear confirms thrombocytopenia with normal RBC and WBC morphology. Coagulation profile is normal. What is the most likely diagnosis and next step in management? (Q851185)

A. Acute lymphoblastic leukemia; bone marrow biopsy

B. Acute immune thrombocytopenic purpura; observation

C. Hemophilia A; factor VIII assay

D. Thrombotic thrombocytopenic purpura; plasma exchange

See Answer in Part B → Q7

@Neet_pg_bot

Q8: A patient with acute kidney injury is found to have hemolytic uremic syndrome. Which of the following is not correct about this patient? (Q851183)

A. Thrombocytopenia

B. Microangiopathic hemolytic anemia

C. Schistocytes

D. Antibodies to ADAMTS13

See Answer in Part B → Q8

@Neet_pg_bot

Q9: A 45-year-old diabetic with an HbA1c of 10% has been detected with a low EGFR of 10, has come for a hemodialysis session. His Hb is 6gm% with normocytic normochromic anemia. Which of the following is the first-line treatment for this patient? (Q851179)

A. Oral iron

B. Darbepoeitin

C. Hemodialysis

D. Roxadustat

See Answer in Part B → Q9

@Neet_pg_bot

Q10: Which of the following is correct about anemia of chronic disease? (Q851155)

A. Low serum iron, elevated serum ferritin, low erythropoietin

B. Low serum iron, low serum ferritin, low erythropoietin

C. High serum iron, low serum ferritin, low erythropoietin

D. High serum iron, elevated serum ferritin, low erythropoietin

See Answer in Part B → Q10

@Neet_pg_bot

Q11: A 55-year-old woman presents with fatigue, glossitis, and paresthesias. Laboratory tests show macrocytic anemia and low vitamin B12 levels. Further testing reveals the presence of parietal cell antibodies. What is the most common underlying cause of her condition? (Q851154)

A. Alcoholism

B. Autoimmune gastritis

C. Malabsorption syndrome

D. Ileal resection

See Answer in Part B → Q11

@Neet_pg_bot

Q12: Which of the following is true about hand and foot syndrome seen in sickle cell anemia? (Q851141)

A. Usually seen after 5 year of age

B. Infection with capsulated organisms causing osteomyelitis of small bones of hands

C. Causes swan neck joint deformities

D. X-ray-shows periostitis and soft tissue swelling

See Answer in Part B → Q12

@Neet_pg_bot

Q13: Which of the following is correct about sickle cell anaemia? (Q851152)

A. Beta 7 valine residues cause polymerization of HbS on deoxygenation

B. Beta 7 valine residues cause polymerization of HbS on oxygenation

C. Beta 6 glutamate residues cause polymerization of HbS on oxygenation

D. Beta 6 glutamate residues cause polymerization of HbS on deoxygenation

See Answer in Part B → Q13

@Neet_pg_bot

Q14: A patient is suspected of having sickle cell anemia. Which of the following hemoglobin electrophoresis patterns is most consistent with this diagnosis? (Q851151)

A. HbA absent , Hb S present, Hb F elevated, Hb A2 elevated

B. HbA present ,Hb S present, Hb F elevated, Hb A2 elevated

C. HbA present ,Hb S present , Hb F elevated, Hb A2 elevated

D. HbA absent , Hb S present, Hb F reduced , Hb A2 elevated

See Answer in Part B → Q14

@Neet_pg_bot

Q15: Which of the following is the earliest embryonic hemoglobin to appear? (Q851150)

A. Gower 1

B. Gower 2

C. Portland

D. Fetal hemoglobin

See Answer in Part B → Q15

@Neet_pg_bot

Q16: A 15 year old patient presents with anemia with splenomegaly. P. Smear is shown below. Comment on the Peripheral smear shown below (Q851149)

A. Hereditary spherocytosis

B. Hereditary elliptocytosis

C. Hemolytic uremic syndrome

D. Pyropokilocytosis

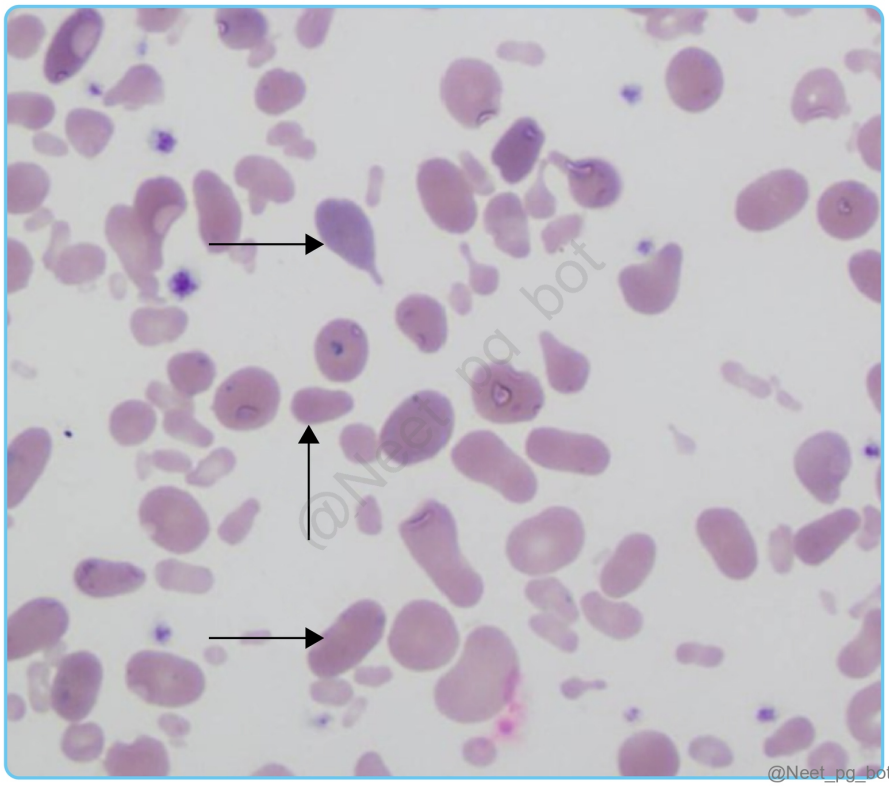

See Answer in Part B → Q16

@Neet_pg_bot

Q17: A 5 year child born to consanguineous marriage is brought with complaints of pain in both hands over the metacarpals. Work up shows low Hb with increased reticulocyte count, increased LDH and low haptoglobin levels. Spleen is not palpable. Hb electrophoresis report is awaited. He has had previous hospitalizations for acute abdomen. Diagnosis is? (Q851148)

A. Sickle cell anemia

B. Beta Thalassemia

C. Hereditary spherocytosis

D. ITP

See Answer in Part B → Q17

@Neet_pg_bot

Q18: Which of the following drugs can be used in patients with G6PD? (Q851147)

A. Primaquine

B. Artesunate

C. Dapsone

D. Rasburicase

See Answer in Part B → Q18

@Neet_pg_bot

Q19: Peripheral smear of a neonate with jaundice shows normocytic normochromic anemia with anisocytosis and poikilocytosis with RBC showing unevenly distributed hemoglobin " hemighosts" or "blister cells". This is seen in which of the following? (Q851146)

A. Abetalipoproteinemia

B. Hemolytic uremic syndrome

C. G6PDdeficiency

D. Pyruvate kinase deficiency

See Answer in Part B → Q19

@Neet_pg_bot

Q20: A 5 year old child is brought with complaints of pain in hands. On examination he has severe pallor, elevated LDH and low haptoglobin. The HPLC report is shown below. Which of the following is the drug of choice for this patient? (Q851144)

A. Hydroxy urea

B. Azacytidine

C. Voxeletor

D. Bortezomib

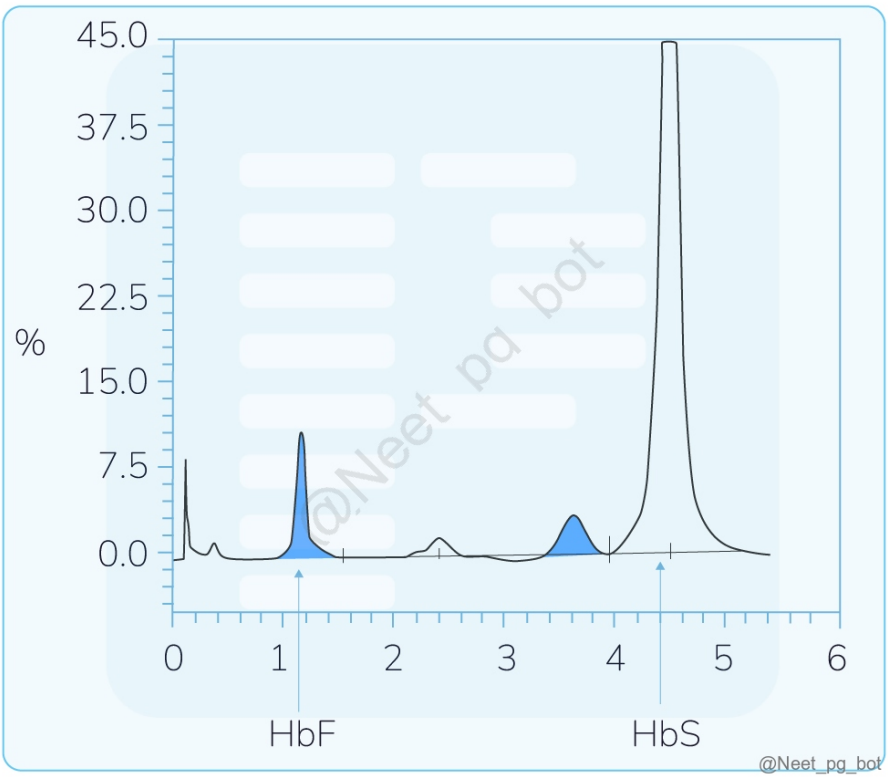

See Answer in Part B → Q20

@Neet_pg_bot

Q21: Which of the following treatments is curative in sickle cell anemia? (Q851142)

A. Hyroxyurea

B. Hematopoietic stem cell transplantation

C. Voxelotor

D. Packed RBC transfusions

See Answer in Part B → Q21

@Neet_pg_bot

• [06_Hematology] 045 Platelet Disorders And Hematology Images

« Back to Folder Directory

[06_Hematology] 045 Platelet Disorders And Hematology Images — Quick Jump

Q1 (p. 534)	*Q2 (p. 535)*	*Q3 (p. 535)*	*Q4 (p. 536)*	*Q5 (p. 536)*	*Q6 (p. 537)*
Q7 (p. 537)	*Q8 (p. 537)*	*Q9 (p. 538)*	*Q10 (p. 538)*	*Q11 (p. 538)*	*Q12 (p. 539)*
Q13 (p. 540)	*Q14 (p. 540)*	*Q15 (p. 541)*	*Q16 (p. 542)*	*Q17 (p. 543)*	*Q18 (p. 543)*
Q19 (p. 544)	*Q20 (p. 545)*	*Q21 (p. 545)*	*Q22 (p. 546)*	*Q23 (p. 546)*	*Q24 (p. 547)*

Q1: A 6-year-old boy presents with recurrent skin and respiratory infections since infancy. Examination reveals partial albinism and peripheral neuropathy. Peripheral smear is shown below. Which of the following is the most likely underlying defect? (Q851167)

A. Defective lysosomal trafficking

B. NADPH oxidase deficiency

C. Defective adhesion molecule

D. Myeloperoxidase deficiency

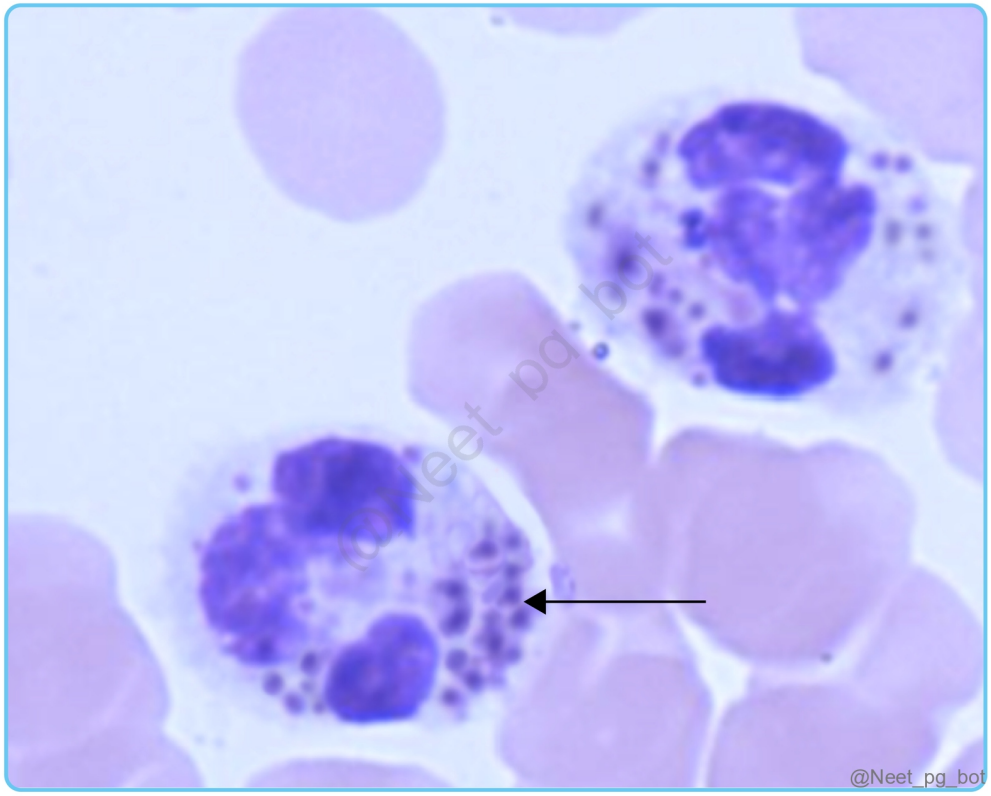

See Answer in Part B → Q1

@Neet_pg_bot

Q2: Which of the following statements regarding von Willebrand disease is not true? (Q866839)

A. Type 2 vWD is associated with a moderate bleeding tendency

B. Type 3 vWD is associated with a complete absence of factor VIII

C. Type 1 vWD presents with severe bleeding since childhood

D. Type 2 vWD includes subtypes with varying defects in the von Willebrand factor

See Answer in Part B → Q2

@Neet_pg_bot

Q3: Which of the following is the correct presentation of Bernard–Soulier syndrome? (Q851177)

A. Presence of large platelets with thrombocytopenia and defective platelet adhesion

B. Small platelets, eczema, recurrent infections, and thrombocytopenia due to an X-linked disorder

C. Umbilical stump bleeding on day 1 of life

D. Normal platelet count with defective platelet aggregation caused by absent GPIIb/IIIa receptors

See Answer in Part B → Q3

@Neet_pg_bot

Q4: Which of the following is correct about the mechanism of action of Ticagrelor? (Q851176)

A. Inhibiting P2Y12 , ADP receptor

B. Acetylation of COX-1

C. Blocking activated glycoprotein Gp IIb/IIIa

D. Inhibiting production of COX-1

See Answer in Part B → Q4

@Neet_pg_bot

Q5: What is the life span of a platelet in the body? (Q851175)

A. 3-5 days

B. 5-7 days

C. 7-10 days

D. 10-14 days

See Answer in Part B → Q5

@Neet_pg_bot

Q6: A 30 year old multigravida post-partum female developed multiple bruises and ecchymosis after delivery. coagulogram shows prolonged aPTT, normal TT and normal PT. and TT and a mixing study that does not correct with normal pooled plasma. The Bethesda assay using factor-specific deficient plasma is planned. What is the first differential diagnosis? (Q851174)

A. Von Willebrand disease

B. HELLP syndrome

C. Acquired Hemophilia A

D. DIC

See Answer in Part B → Q6

@Neet_pg_bot

Q7: Which of the following cause/s lead to DIC? a. Fulminant hepatic failure b. Acute promyelocytic leukemia c. Carcinoma prostate d. Fungal sepsis (Q851173)

A. b,c,d

B. a,c,d

C. a,b,d

D. a,b,c,d

See Answer in Part B → Q7

@Neet_pg_bot

Q8: A 9-year old with acquired factor IX deficiency. However, the coagulation abnormality corrected after administration of Vitamin K. What is the most likely diagnosis? (Q851172)

A. Classic Hemophilia

B. Pernicious anemia

C. Hepatitis A

D. Bile duct obstruction

See Answer in Part B → Q8

@Neet_pg_bot

Q9: Which of the following are used in non transfusion therapy for hemophilia A? a. Factor VIII concentrate b. Cryoprecipitate c. DDAVP d. Epsilon amino caproic acid (Q851171)

A. a,b

B. a,c

C. a,d

D. c,d

See Answer in Part B → Q9

@Neet_pg_bot

Q10: Which clotting factor has the longest half life? (Q851170)

A. 2

B. 7

C. 9

D. 13

See Answer in Part B → Q10

@Neet_pg_bot

Q11: The following inclusions inside RBC are called _____ (Q851169)

A. Dohle bodies

B. Pappenheimer bodies

C. Howell Jolly bodies

D. Dutcher bodies

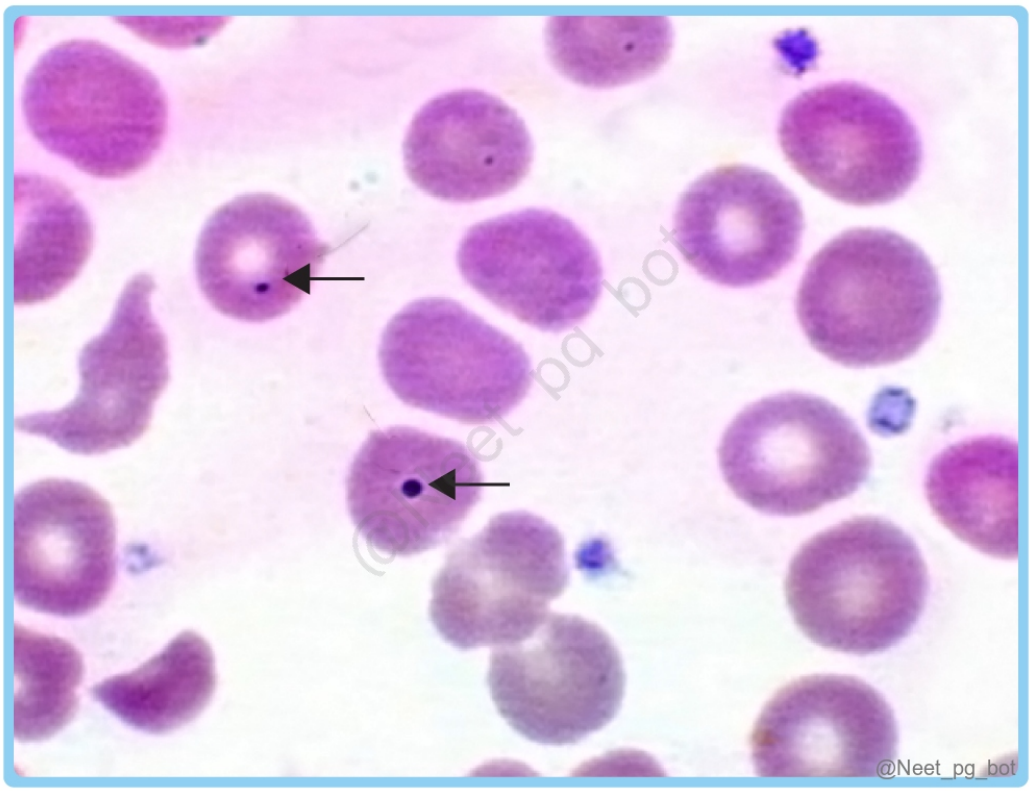

See Answer in Part B → Q11

@Neet_pg_bot

Q12: The following inclusions in neutrophils are seen in? (Q851168)

A. Burns

B. Chediak higashi granules

C. Celiac sprue

D. Whipple disease

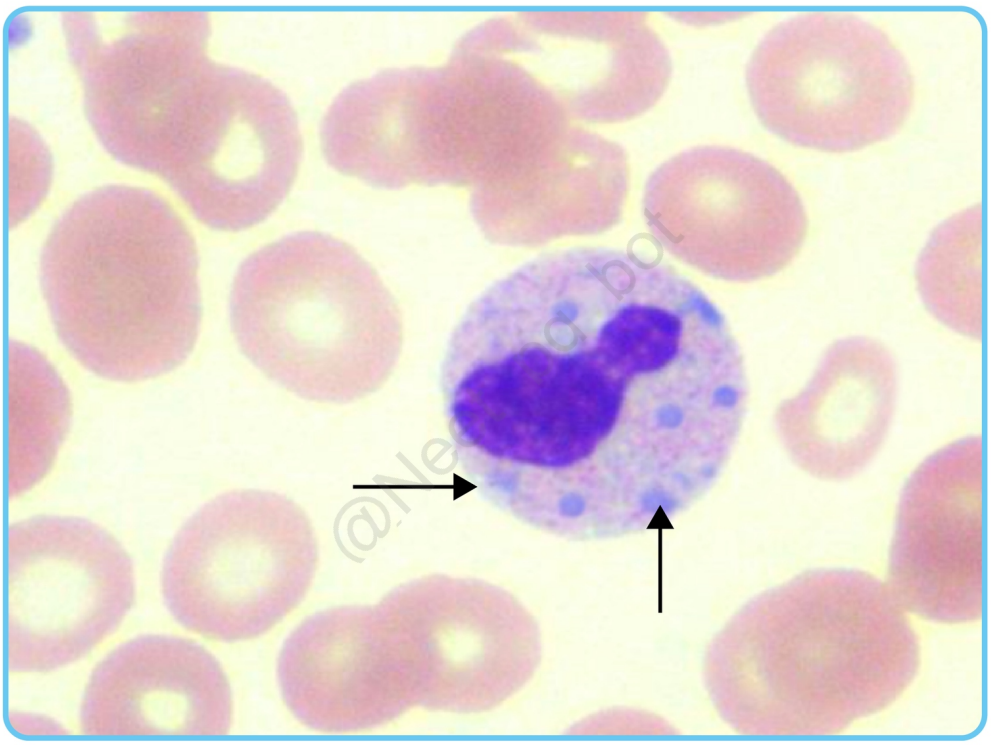

See Answer in Part B → Q12

@Neet_pg_bot

Q13: Which of the following is not correct about ITP? (Q851143)

A. Secondary ITP occurs due to autoimmune causes like SLE and infections like HIV , HCV

B. Wet purpura heralds life threatening bleed

C. Severe ITP needs emergency splenectomy

D. Eltrombopag is used in patients who relapse

See Answer in Part B → Q13

@Neet_pg_bot

Q14: Which of the following is correct about the neutrophil shown in peripheral smear? (Q851166)

A. Chediak higashi Syndrome

B. Myelodysplastic syndrome

C. Perinicious anemia

D. Burns



See Answer in Part B → Q14

@Neet_pg_bot

Q15: The following feature is seen in which of the following conditions (Q851165)

A. Plasma cell dyscrasia

B. Multiple lineage dysplasia

C. Myelofibrosis

D. Leukemoid reaction



See Answer in Part B → Q15

@Neet_pg_bot

Q16: A 60-year-old man presents with progressive fatigue, early satiety, and weight loss over 3 months. Examination reveals massive splenomegaly. Laboratory findings: Hemoglobin: 8.5 g/dL, WBC: 3,000/µL, Platelets: 90,000/µL, Peripheral smear is shown below.. Which of the following is the most likely diagnosis? (Q851164)

A. Chronic myeloid leukemia

B. Myelofibrosis

C. Polycythemia vera

D. Aplastic anemia

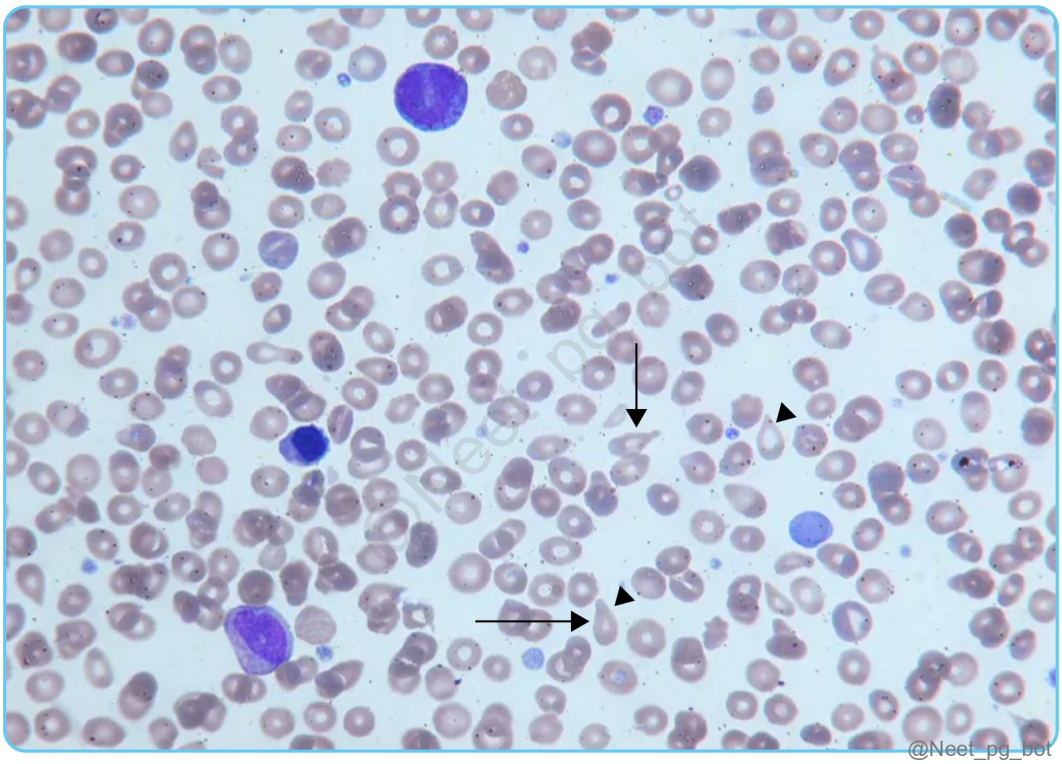

See Answer in Part B → Q16

@Neet_pg_bot

Q17: A patient diagnosed with Acute promyelocytic leukemia develops bleeding from body orifices. Which of the following coagulogram report will be seen in this case? (Q851163)

A. PT increased, BT increased, aPTT increased

B. PT increased, BT normal, aPTT increased

C. PT normal, BT increased, aPTT increased

D. PT normal, BT normal , aPTT increased

See Answer in Part B → Q17

@Neet_pg_bot

Q18: All of the following are contraindications to use of the following instruments in hematology except? (Q851162)

A. Consumptive coagulopathy

B. Local site infection

C. Patient on warfarin

D. Low platelet count 40,000/uL



See Answer in Part B → Q18

@Neet_pg_bot

Q19: A 5-year-old boy presents with petechiae over his legs, pallor and decreased urine output. His mother reports that he had bloody diarrhea a week ago. The examination shows mild edema and hypertension. Laboratory results reveal: Hemoglobin: 7.8 g/dL, platelet count: 65,000/µL, Creatinine: 2.5 mg/dL, Peripheral smear: schistocytes present. Which of the following is the most likely diagnosis? (Q851161)

A. Immune thrombocytopenic purpura

B. Hemolytic uremic syndrome

C. Henoch Scholein Purpura

D. Post-infectious-glomerulonephritis

See Answer in Part B → Q19

@Neet_pg_bot

Q20: Which of the following causes non thrombocytopenic purpura? (Q851160)

A. HUS

B. TTP

C. DIC

D. HSP

See Answer in Part B → Q20

@Neet_pg_bot

Q21: An 18-year-old boy with severe hemophilia A (factor VIII activity <1%) is scheduled for wisdom tooth extraction. His past history includes multiple episodes of hemarthrosis but no inhibitors to factor VIII. Which of the following is the best strategy to prevent perioperative bleeding? (Q851159)

A. Administer desmopressin (DDAVP) before the procedure

B. Transfuse fresh frozen plasma 1 hour before surgery

C. Give prophylactic factor VIII concentrate to raise levels to ≥50% before the procedure

D. Start oral tranexamic acid only after the extraction

See Answer in Part B → Q21

@Neet_pg_bot

Q22: A 16-year-old girl presents with a history of heavy menstrual bleeding since menarche and frequent gum bleeding after brushing her teeth. She reports prolonged bleeding after a tooth extraction last year. There is no history of joint swelling or muscle hematomas. Examination reveals pallor but no petechiae or ecchymoses. Laboratory results show: Hemoglobin: 9.5 g/dL, Platelet count: 250,000/µL, PT: Normal, aPTT: Mildly prolonged, Bleeding time: Prolonged, Ristocetin cofactor assay: Decreased. Which of the following is the most likely diagnosis? (Q851158)

A. Hemophilia A

B. Bernard–Soulier syndrome

C. Von Willebrand disease

D. Glanzmann thrombasthenia

See Answer in Part B → Q22

@Neet_pg_bot

Q23: A 4-year-old boy presents with a history of easy bruising and frequent nosebleeds since infancy. His parents report prolonged bleeding after minor cuts, but there is no history of deep muscle or joint bleeds. Examination reveals petechiae and multiple ecchymoses over the extremities. Laboratory findings show:Platelet count: 250,000/µL, PT: Normal, aPTT: Normal, Bleeding time: Prolonged, Platelet aggregation absent with ADP, collagen, and epinephrine; normal with ristocetin. Which of the following is the most likely diagnosis? (Q851157)

A. Bernard–Soulier syndrome

B. Hemophilia A

C. Glanzmann thrombasthenia

D. Von Willebrand disease

See Answer in Part B → Q23

@Neet_pg_bot

Q24: Elective splenectomy is done in which of the following conditions? a. Beta thalassemia major with 50% increase in transfusion requirement over last one year b. Hereditary spherocytosis with severe anemia by 5 years of age c. Chronic ITP non responsive to steroids d. Myelopthisis (Q851156)

A. a,b

B. a,c

C. a,b,c

D. a,b,c,d

See Answer in Part B → Q24

@Neet_pg_bot

• [06_Hematology] 046 Blood Components And Complications Of Blood Transfusion

« Back to Folder Directory

[06_Hematology] 046 Blood Components And Complications Of Blood Transfusion — Quick Jump

Q1 (p. 548)	*Q2 (p. 548)*	*Q3 (p. 549)*	*Q4 (p. 549)*	*Q5 (p. 549)*	*Q6 (p. 550)*
Q7 (p. 550)	*Q8 (p. 550)*	*Q9 (p. 551)*	*Q10 (p. 552)*	*Q11 (p. 552)*	*Q12 (p. 552)*
Q13 (p. 553)	*Q14 (p. 553)*	*Q15 (p. 554)*	*Q16 (p. 554)*	*Q17 (p. 554)*	*Q18 (p. 555)*
Q19 (p. 555)	*Q20 (p. 555)*				

Q1: Which is the correct ratio for acute hypovolemic coagulopathy requiring massive transfusion? (Q851027)

A. 1 RBCC: 1 plasma: 0.25 platelet concentrate

B. 1 RBCC: 1 plasma: 0.5 platelet concentrate

C. 1 RBCC: 1 plasma: 1 platelet concentrate

D. 1 RBCC: 1 plasma: 4 platelets concentrate

See Answer in Part B → Q1

@Neet_pg_bot

Q2: Which transfusion reaction is most strongly associated with HLA antibodies in donor plasma? (Q851036)

A. TRALI

B. TACO

C. Acute hemolytic reaction

D. Sepsis

See Answer in Part B → Q2

@Neet_pg_bot

Q3: 30-year-old man receives a unit of O■ packed RBCs. Within 10 minutes, he develops fever, chills, hypotension, and flank pain. Which investigation will be most specific for confirming the diagnosis? (Q851035)

A. Indirect antiglobulin test

B. Direct antiglobulin Coombs test

C. Blood cultures from patient

D. Reticulocyte count

See Answer in Part B → Q3

@Neet_pg_bot

Q4: The patient is started on blood transfusion in a post operative room and within 5 minutes you notice that the patient develops a rash all over the body with cold clammy extremities. pulse is 120/min, BP is 80/60 mm Hg with inspiratory rhonchi in bilateral lungs The blood group of the patient is 0+ and the patient was given 0+ blood as verified by the blood bank. Which of the following is the first differential diagnosis? (Q851034)

A. Alloimmunization

B. Anaphylaxis

C. TACO

D. Mismatched blood transfusion

See Answer in Part B → Q4

@Neet_pg_bot

Q5: Which of the following blood components has the highest chances of causing transfusion transmitted infection? (Q851033)

A. Platelet concentrate

B. Packed RBC

C. Plasma

D. Whole blood

See Answer in Part B → Q5

@Neet_pg_bot

Q6: Which of the following is not correct about usage and storage of blood components? (Q851032)

A. Packed RBC can be stored for up to 42 days at 4 °C

B. Platelets can be stored for 3–7 days at 20–24 °C

C. Granulocyte concentrate at room temperature and used within 24 hours of end of collection

D. Plasma is cryopreserved at –4 °C and should be used within 1 hour of thawing

See Answer in Part B → Q6

@Neet_pg_bot

Q7: Deleucocytation is defined as ? (Q851031)

A. <1–5. 10 6 leukocytes per unit of blood components

B. <1–5. 10 7 leukocytes per unit of blood components

C. <1–5. 10 8 leukocytes per unit of blood components

D. <1–5. 10 9 leukocytes per unit of blood components

See Answer in Part B → Q7

@Neet_pg_bot

Q8: High efficiency deleucocytation is being done using the filter shown in the image. It will reduce all of the following complications of blood transfusion except? (Q851030)

A. Mismatched blood transfusion

B. Febrile non hemolytic transfusion reaction

C. Transmission of CMV

D. Alloimmunization

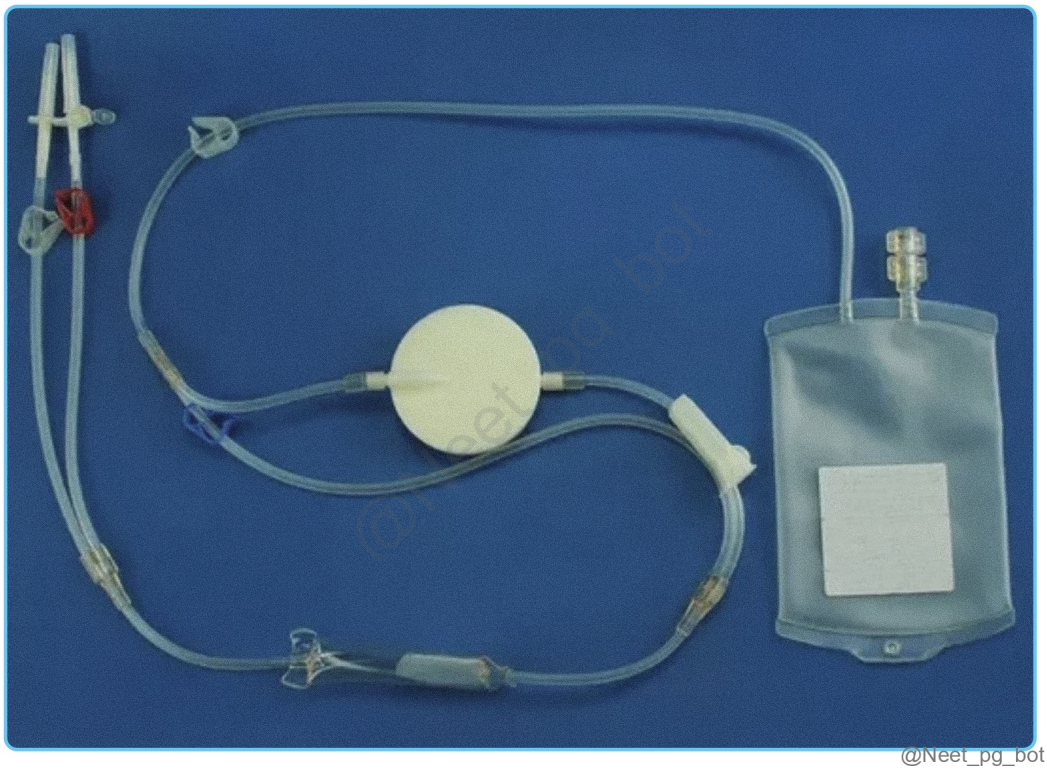

See Answer in Part B → Q8

@Neet_pg_bot

Q9: Which of the following is immunodominant sugar in patient with blood group A (Q851029)

A. N-acetyl- glucosamine

B. N- acetyl- galactosamine

C. Galactose

D. Fucose

See Answer in Part B → Q9

@Neet_pg_bot

Q10: Which of the following blood groups is a universal plasma donor? (Q851028)

A. A

B. B

C. AB

D. O

See Answer in Part B → Q10

@Neet_pg_bot

Q11: An unbooked 30 year old multigravida in the 36 weeks of pregnancy is having severe anemia with Hb of 6.8 gm/dl. She was prescribed 2 units of PRBC . She develops high grade fever 40 C with chills and rigors, hypotension and bleeding from IV cannula site 1 hour after completion of transfusion. Diagnosis is? (Q851017)

A. Mismatched Blood transfusion

B. Febrile non hemolytic transfusion reaction

C. Transfusion transmitted bacterial infection

D. TRALI

See Answer in Part B → Q11

@Neet_pg_bot

Q12: “Lethal triad of death” includes (Q851026)

A. Acidosis, hypothermia and coagulopathy

B. Alkalosis, hypothermia and coagulopathy

C. Acidosis, hyperthermia and coagulopathy

D. Alkalosis, hyperthermia and coagulopathy

See Answer in Part B → Q12

@Neet_pg_bot

Q13: Which of the following complications can occur after multiple blood transfusions? 1. Hypokalemia 2. Hyperkalemia 3. Hypocalcemia 4. Metabolic acidosis (Q851025)

A. 1,3

B. 2,3

C. 1,2,3

D. 1,3,4

See Answer in Part B → Q13

@Neet_pg_bot

Q14: Cryoprecipitate can be used in all of the following cases except (Q851024)

A. Type II vWD

B. Type III vWD

C. Haemophilia A in absence of factor VIII concentrate

D. Hemophilia B in absence of factor IX concentrate

See Answer in Part B → Q14

@Neet_pg_bot

Q15: A stable patient without fever or infection has severe thrombocytopenia. At what platelet count threshold is platelet transfusion generally indicated? (Q851023)

A. < 5,000 / uL

B. <10,000/ uL

C. <20,000/ uL

D. <50,000/ uL

See Answer in Part B → Q15

@Neet_pg_bot

Q16: The RTA victim was given 6 units of whole blood in the last 6 hours. Which of the following complications is most likely in this patient? (Q851022)

A. Hypokalemia

B. Hyponatremia

C. Hypocalcemia

D. Hypercalcemia

See Answer in Part B → Q16

@Neet_pg_bot

Q17: A 65-year-old man with chronic kidney disease on maintenance hemodialysis receives 2 units of PRBCs over 4 hours for severe anemia. Shortly after transfusion, he develops acute dyspnea, elevated JVP, hypertension, and bilateral basal crackles. Which of the following is the most likely diagnosis? (Q851021)

A. Transfusion-related acute lung injury

B. Transfusion-associated circulatory overload

C. Febrile non-hemolytic reaction

D. Acute hemolytic reaction

See Answer in Part B → Q17

@Neet_pg_bot

Q18: A 30 year old woman on steroids for SLE had received one unit of blood transfusion after her recent delivery of a healthy boy baby. 10 days later she developed fever, rashes and diarrhea. Which complication of blood transfusion would you suspect? (Q851020)

A. Mismatched blood transfusion

B. Graft versus host disease

C. Febrile non-hemolytic transfusion reaction

D. Transfusion transmitted infection

See Answer in Part B → Q18

@Neet_pg_bot

Q19: Which of the following is not correct about TRALI (Q851019)

A. Donor antibodies bind to recipient neutrophils in pulmonary endothelium causing release or pro inflammatory cytokines

B. Usually occurs within 6 hours of transfusion

C. Bilateral interstitial infiltrates due to cardiogenic pulmonary edema

D. Reduced incidence by taking plasma from only male donor

See Answer in Part B → Q19

@Neet_pg_bot

Q20: The leading cause of death due to blood transfusion is? (Q851018)

A. TACO

B. TRALI

C. Mismatched blood transfusion

D. Dilutional coagulopathy

See Answer in Part B → Q20

@Neet_pg_bot

• [06_Hematology] 047 Previous Year Questions

« Back to Folder Directory

[06_Hematology] 047 Previous Year Questions — Quick Jump

Q1 (p. 557)	*Q2 (p. 557)*	*Q3 (p. 558)*	*Q4 (p. 558)*	*Q5 (p. 559)*	*Q6 (p. 559)*
Q7 (p. 560)	*Q8 (p. 560)*	*Q9 (p. 561)*	*Q10 (p. 561)*	*Q11 (p. 562)*	*Q12 (p. 562)*
Q13 (p. 562)	*Q14 (p. 563)*	*Q15 (p. 563)*	*Q16 (p. 564)*	*Q17 (p. 564)*	*Q18 (p. 565)*
Q19 (p. 565)	*Q20 (p. 566)*	*Q21 (p. 566)*	*Q22 (p. 566)*	*Q23 (p. 567)*	*Q24 (p. 567)*
Q25 (p. 567)	*Q26 (p. 568)*	*Q27 (p. 568)*	*Q28 (p. 569)*	*Q29 (p. 569)*	*Q30 (p. 570)*
Q31 (p. 570)	*Q32 (p. 570)*	*Q33 (p. 571)*			

Q1: A 60-year-old female presents with weakness, back pain and repeated infections. Work up shows M spike on serum electrophoresis. Prognosis is determined by which of the following factors? (Q866809)

A. IgG and albumin

B. IgM and albumin

C. Albumin and LDH

D. Albumin and β■-microglobulin

See Answer in Part B → Q1

@Neet_pg_bot

Q2: A girl experiences prolonged menstrual bleeding and has normal platelet count, PT, and aPTT, but an increased bleeding time, which was determined to be due to a deficiency of GpIIb-IIIa after further analysis. What is the diagnosis? (Q859787)

A. Bernard Soulier syndrome

B. Glanzmann thrombasthenia

C. Haemophilia A

D. Von Willebrand disease

See Answer in Part B → Q2

@Neet_pg_bot

Q3: A 30-year-old female with a history of recurrent headaches presented for further evaluation. On further workup, haemoglobin and total WBC count were normal, while an elevated platelet count was seen. Bone marrow aspiration showed increased megakaryocytes and a JAK2 mutation. Which is the most likely diagnosis? (Q859739)

A. Polycythemia vera

B. Essential thrombocytosis

C. Primary myelofibrosis

D. Chronic myelogenous leukaemia

See Answer in Part B → Q3

@Neet_pg_bot

Q4: A 68-year-old male came to the physician with complaints of chronic back pain, easy fatigability and a history of multiple urinary tract infections in the last 3 months. His ESR is elevated, and an x-ray of his skull is shown below. Which of the following investigations is useful for diagnosis? (Q859531)

A. MRI brain

B. PET scan

C. Head CT scan with contrast

D. Serum electrophoresis

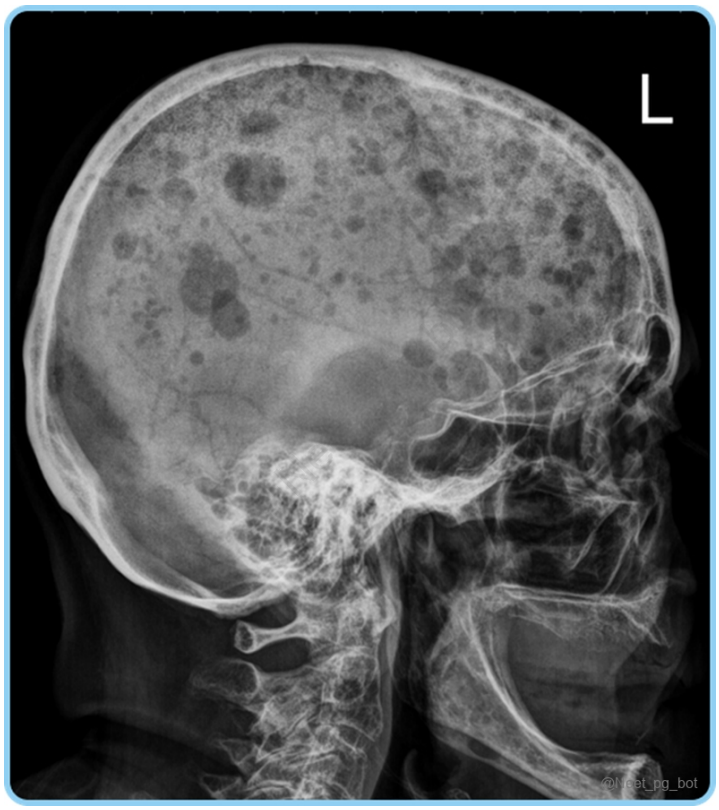

See Answer in Part B → Q4

@Neet_pg_bot

Q5: A ten-year-old boy was brought to the OPD with fever and swelling of his hands after playing football. He gives a history of previous episodes of swelling of his hands. On imaging, his spleen was found to be shrunken. Which of the following is a likely diagnosis? (Q855013)

A. Sickle cell anaemia

B. Malaria

C. Pancreatitis

D. Measles

See Answer in Part B → Q5

@Neet_pg_bot

Q6: Thrombocytopenia, eczema and recurrent infections are seen in: (Q854999)

A. Wiskott-Aldrich syndrome

B. Chediak-Higashi syndrome

C. Thrombocytopenia - absent radius syndrome

D. Hermansky-Pudlak syndrome

See Answer in Part B → Q6

@Neet_pg_bot

Q7: For hairy cell leukemia, which drug is considered the preferred choice? (Q856268)

A. Rituximab

B. Vemurafenib

C. Cladribine

D. Interferon-alpha

See Answer in Part B → Q7

@Neet_pg_bot

Q8: A 65-year-old woman was brought to the emergency department with symptoms of breathlessness anemia and severe bone pain. On evaluation a hemoglobin level was found to be 5.4 g/dl, urea level of 86 mg/dl, creatinine level of 6 mg/dl, calcium level of 12, and potassium level of 4.4 and the bone marrow aspiration revealed over 60% of plasma cells. Which of the following could be the appropriate next course of action for the management of this patient? (Q856938)

A. Urgent consultation for dialysis

B. Dexamethasone + lenalidomide

C. Dexamethasone + fluids

D. Bone marrow transplantation

See Answer in Part B → Q8

@Neet_pg_bot

Q9: A 62-year-old male patient with heart failure is scheduled for a heart transplant. His renal function test is deranged, and haemoglobin is 6gm%. The physician ordered 2 units of whole blood. Four hours after transfusion, he developed severe respiratory distress. On examination, he is hypoxemic, has tachycardia and his mean arterial pressure is elevated. Which of the following are the best investigations for the above scenario? Chest X-ray Brain natriuretic peptide (BNP) level Absolute neutrophil count Leucocyte antibodies Platelets (Q856626)

A. 4 and 5

B. 3 and 5

C. 1 and 2

D. 2 only

See Answer in Part B → Q9

@Neet_pg_bot

Q10: An elderly woman presented with symptoms of confusion, thirst, and abdominal pain. On examination, she had pallor and thoracic spine tenderness. X-ray spine showed osteolytic lesions. Her lab investigations showed the following findings. What is the most likely diagnosis? Hb - 6.9g/dl WBC 4000/cm3 with normal differential count Serum calcium 13mg/dl Creatinine 2.3mg/dl Total protein 9g/dl Albumin 2.4g/dl (Q856590)

A. Metastatic breast cancer

B. Multiple myeloma

C. Primary hyperparathyroidism

D. Milk alkali syndrome

See Answer in Part B → Q10

@Neet_pg_bot

Q11: Which of the following interfere with iron absorption? (Q857690)

A. Vitamin C

B. Phytates

C. Oxalate

D. Myoglobin

See Answer in Part B → Q11

@Neet_pg_bot

Q12: What is the interpretation of elevated serum Calcium levels in a patient with normal serum alkaline phosphatase, PTH, and Vitamin D3 levels? (Q857688)

A. Vitamin D intoxication

B. Hyperparathyroidism

C. Multiple myeloma

D. Nutritional rickets

See Answer in Part B → Q12

@Neet_pg_bot

Q13: Which of the following investigations should be conducted in a 7-month-old child who has a hemoglobin level of 6.3, a history of recurrent blood transfusions, an MCV of 70 fl, normal MCH, normal MCHC, and a peripheral smear indicating a hypochromic microcytic image? (Q857031)

A. Serum iron

B. Direct coomb’s test

C. Osmotic fragility test

D. Hb electrophoresis

See Answer in Part B → Q13

@Neet_pg_bot

Q14: What is the diagnosis of a 50-year-old man who presents with symptoms of anemia, fever, and recurrent nosebleeds? The patient has hepatosplenomegaly and lab investigations indicate a hemoglobin level of 6g/dL, a total leukocyte count of 40,000/cu.mm with 10% blasts, and a platelet count of 12,000/cu.mm. Further investigation reveals the presence of t(8;21) in the blasts. (Q857007)

A. Acute lymphoblastic leukemia

B. Acute myeloblastic leukemia

C. Preleukemia

D. Aleukemic leukemia

See Answer in Part B → Q14

@Neet_pg_bot

Q15: A 68-year-old male came to the physician with complaints of chronic back pain, easy fatigability, and a past history of multiple urinary tract infections in the last 3 months. His ESR is elevated, x-ray of his skull is shown below. Which of the following investigations is useful for diagnosis? (Q856997)

A. MRI brain

B. PET scan

C. Head CT scan with contrast

D. Serum electrophoresis

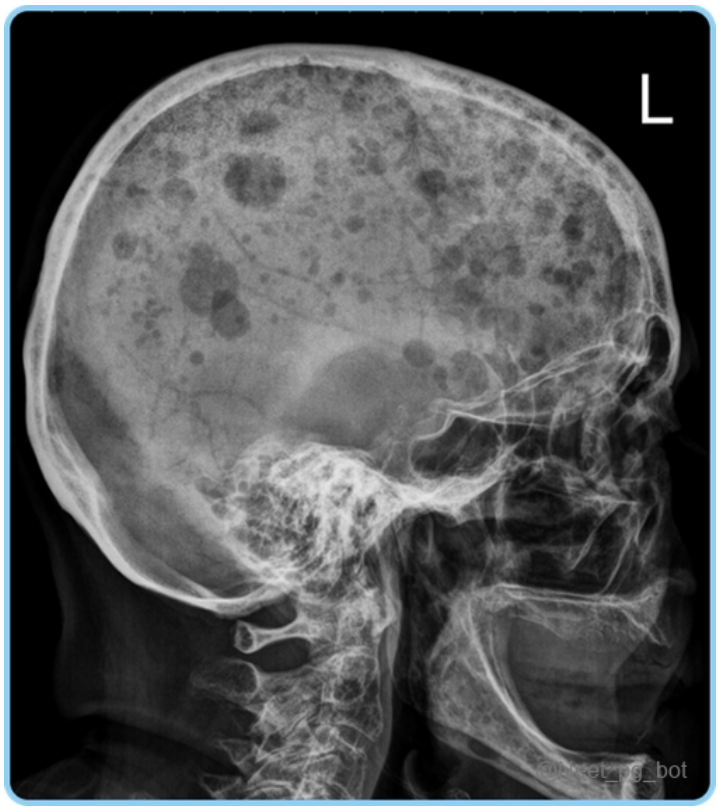

See Answer in Part B → Q15

@Neet_pg_bot

Q16: A female patient presents to the AIIMS emergency department with severe fatigue. She is a known case of chronic stable angina. While collecting a blood sample, you notice the blood has a brownish hue. What is the underlying diagnosis? (Q855354)

A. Carboxy-hemoglobinemia

B. Sideroblastic anaemia

C. Methemoglobinemia

D. Sulfhemoglobinemia

See Answer in Part B → Q16

@Neet_pg_bot

Q17: A young woman presents with recurrent headaches, easy bruising, and episodes of visual blurring. Her platelet count is elevated, while her red blood cell (RBC) and white blood cell (WBC) counts are normal. What is the most likely diagnosis? (Q860145)

A. Essential Thrombocytosis

B. Polycythemia Vera

C. Chronic Myeloid Leukemia (CML)

D. Acute Myeloid Leukemia (AML)

See Answer in Part B → Q17

@Neet_pg_bot

Q18: A child with progressive pallor and bone has an elevated HbS based on the HPLC report. Which is the best treatment to manage hemolysis in this patient? (Q866807)

A. Hydroxyurea

B. Azacytidine

C. Voxelator

D. Bortezomib

See Answer in Part B → Q18

@Neet_pg_bot

Q19: What defect is seen in Bernard Soulier syndrome? (Q866817)

A. Deficiency of GpIIb/IIIa receptor

B. Deficiency of GpIb receptors

C. Deficiency of von Willebrand factor

D. Deficiency of ADP receptors

See Answer in Part B → Q19

@Neet_pg_bot

Q20: Which of the following is not a feature of thrombotic thrombocytopenic purpura? (Q853347)

A. Thrombocytopenia

B. Thrombosis

C. Microangiopathic hemolytic anemia

D. Renal failure

See Answer in Part B → Q20

@Neet_pg_bot

Q21: What is the mutation seen in Sickle cell anemia? (Q853348)

A. Glu → Val (6)

B. Lys → Arg

C. Glu → Lysine

D. Ala → Gly (9)

See Answer in Part B → Q21

@Neet_pg_bot

Q22: In hemolytic anemia, which of the following statements are true? Indirect Van den Bergh test is positive. Serum conjugated bilirubin is raised. Serum transaminases are raised. Urobilinogen is high. GGT is elevated. (Q853352)

A. 1, 3, 5

B. 1, 4

C. 2, 5

D. 1, 4, 5

See Answer in Part B → Q22

@Neet_pg_bot

Q23: Which of the following statements regarding von Willebrand disease is incorrect? (Q844288)

A. Type 2 von Willebrand disease is associated with a moderate bleeding tendency

B. Type 3 von Willebrand disease causes almost complete absence of von Willebrand factor, resulting in very low factor VIII levels.Type 3 von Willebrand disease is associated with a complete absence of factor VIII

C. Type 1 von Willebrand disease presents with severe bleeding since childhood

D. Type 2 von Willebrand disease includes subtypes with varying defects in von Willebrand factor.

See Answer in Part B → Q23

@Neet_pg_bot

Q24: Which of the following is incorrect regarding myelodysplastic syndrome? (Q840143)

A. More commonly seen in females

B. Treatment-induced MDS is not dependent on age

C. Median age of onset 70 years

D. It can be radiation-induced

See Answer in Part B → Q24

@Neet_pg_bot

Q25: A 46-year-old male presents to the outpatient department with a history of lower back pain and painful urination. Upon investigation, he is found to have normocytic normochromic anemia and hypercalcemia. Serum protein electrophoresis reveals an M-spike in the gamma region. Which of the following tests is most appropriate to confirm the diagnosis of multiple myeloma? (Q860141)

A. Liver function test

B. Bence Jones protein in urine

C. Urine albumin-to-creatinine ratio (UACR) test

D. Heat and acetic acid test

See Answer in Part B → Q25

@Neet_pg_bot

Q26: A patient presents with fatigue, pallor, and weakness. Laboratory tests reveal low hemoglobin and a markedly low reticulocyte count, while white blood cell and platelet counts remain normal. Which of the following is the most likely diagnosis? (Q860244)

A. Aplastic Anemia

B. Pure Red Cell Aplasia

C. Iron Deficiency Anemia

D. Hemolytic Anemia

See Answer in Part B → Q26

@Neet_pg_bot

Q27: A 26-year-old female presents with menorrhagia and excessive bleeding after a minor surgery. She gave the history of her father and sister having the same bleeding issues and the pattern of inheritance was determined to be autosomal dominant. What is the most likely disorder? (Q857254)

A. Von Willebrand disease

B. Hemophilia A

C. Christmas disease

D. Factor 10 deficiency

See Answer in Part B → Q27

@Neet_pg_bot

Q28: Which of the following is NOT a complication of blood transfusion in a 25-year-old mother who developed acute postpartum haemorrhage, hypovolemic shock, and underwent major blood transfusion after delivering a baby boy? (Q857272)

A. Hypocalcemia

B. Hypokalemia

C. Hypothermia

D. Hyperkalemia

See Answer in Part B → Q28

@Neet_pg_bot

Q29: Elective splenectomy is preferred in which of the following conditions? (Q858020)

A. G6PD deficiency-Glucose-6-phosphate dehydrogenase deficiency

B. Paroxysmal nocturnal hemoglobinuria

C. Hereditary spherocytosis

D. Hairy cell leukemia

See Answer in Part B → Q29

@Neet_pg_bot

Q30: Which of the following is not a feature of Gaisböck syndrome? (Q858031)

A. Hypotension

B. Erythrocytosis

C. Normal leukocyte counts

D. Obesity

See Answer in Part B → Q30

@Neet_pg_bot

Q31: A 60-year-old man presents with fatigue, pallor, weight loss, and heaviness in the left hypochondrium, for the past 2 months. Abdominal palpation reveals splenomegaly. His hemogram and peripheral smear results are given below. What is the most likely diagnosis? Hemogram: Hb-10 gm/dl WBC count – 1,65,000/cu.mm (leukocytosis) Platelet count – 3 lakhs/mm 3 Peripheral smear: Metamyelocytes – 15% Promyeloblasts – 30% Myeloblasts – 45% (Q793841)

A. Chronic lymphocytic leukemia

B. Chronic myeloid leukemia

C. Acute lymphoblastic leukemia

D. Acute myeloid leukemia

See Answer in Part B → Q31

@Neet_pg_bot

Q32: What would be the most appropriate course of action for managing a patient presenting with fatigue, a haemoglobin level below 9 g/dl, and sickle-shaped red blood cells on peripheral smear examination? (Q793796)

A. Administer IV antibiotics

B. Blood transfusion

C. Administer desferoxamine

D. Wait and watch

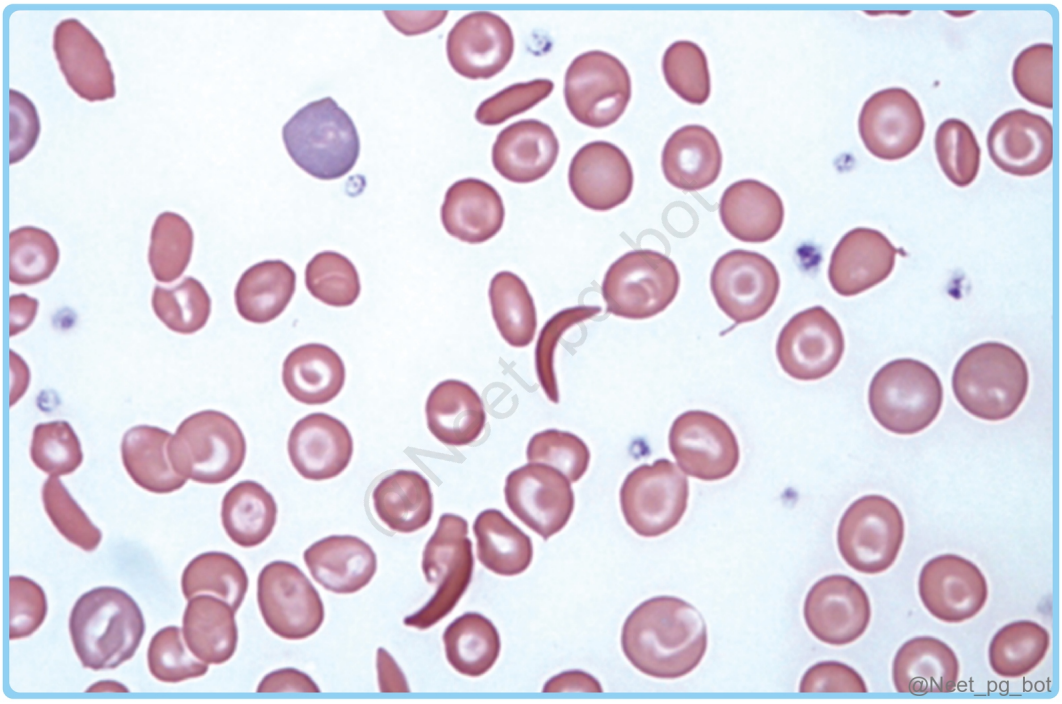

See Answer in Part B → Q32

@Neet_pg_bot

Q33: An elderly woman presented with symptoms of confusion, thirst, and abdominal pain. On examination, she had pallor and thoracic spine tenderness. Her lab investigations showed the following findings. An x-ray of her skull is shown below. What is the most likely diagnosis? Hb-6.9g/dl WBC 4000/cm3 with normal differential count Serum calcium 13mg/dl Creatinine 2.3mg/dl Albumin 2.4g/dl Urinalysis: positive for Bence-Jones proteins (Q793847)

A. Metastatic breast cancer

B. Multiple myeloma

C. Primary hyperparathyroidism

D. Milk alkali syndrome



See Answer in Part B → Q33

@Neet_pg_bot

• [07_Neurology] 048 Epilepsy And Eeg

« Back to Folder Directory

[07_Neurology] 048 Epilepsy And Eeg — Quick Jump

Q1 (p. 573) *Q2 (p. 573)* *Q3 (p. 574)* *Q4 (p. 574)* *Q5 (p. 574)* *Q6 (p. 575)*
Q7 (p. 576) *Q8 (p. 576)* *Q9 (p. 578)* *Q10 (p. 579)* *Q11 (p. 579)* *Q12 (p. 580)*
Q13 (p. 580) *Q14 (p. 580)* *Q15 (p. 581)* *Q16 (p. 581)* *Q17 (p. 582)* *Q18 (p. 582)*
Q19 (p. 583) *Q20 (p. 583)* *Q21 (p. 583)* *Q22 (p. 584)* *Q23 (p. 584)* *Q24 (p. 585)*
Q25 (p. 585)

Q1: Most common childhood epilepsy syndrome is? (Q851091)

A. Janz Syndrome

B. Lennox-Gastaut Syndrome

C. Rolandic epilepsy

D. Febrile seizures

See Answer in Part B → Q1

@Neet_pg_bot

Q2: Match each drug with its preferred use for the corresponding type of seizure. 1. Focal seizures a. Lorazepam 2. Dravet syndrome b. Clobazam 3. Febrile seizures prophylaxis c. Cannabinoids 4. Status epilepticus d. Carbamazepine (Q851113)

A. 1-d, 2-c, 3-b, 4-a

B. 1-c, 2-d, 3-b, 4-a

C. 1-b, 2-d, 3-a, 4-c

D. 1-d, 2-b, 3-a, 4-c

See Answer in Part B → Q2

@Neet_pg_bot

Q3: A 27-year-old woman with a history of seizures and poor medication adherence presents to the ER after a 6-minute seizure followed by another, with impaired consciousness between episodes. She is unresponsive and has labored breathing. Which of the following is correct about managment this patient? (Q851112)

A. IV Lorazepam followed by phenytoin infusion

B. Rectal diazepam followed by midazolam drip

C. Intranasal midazolam

D. IV midazolam infusion

See Answer in Part B → Q3

@Neet_pg_bot

Q4: A 4 year girl presents to the clinic with a frequent seizure episodes. You notice she has port-wine stain on her forehead and upper eyelid. Neuroimaging reveals tram-track calcifications in the brain. Which type of seizures is seen in this condition ? (Q851111)

A. Focal seizures

B. Myoclonic jerks

C. Atonic seizures

D. Febrile seizures

See Answer in Part B → Q4

@Neet_pg_bot

Q5: Which of the following manifestations is earliest to be seen in this neurocutaneous disorder (Q851110)

A. A

B. B

C. C

D. All of the above



See Answer in Part B → Q5

@Neet_pg_bot

Q6: Which of the following is not correct about SSPE? (Q851107)

A. Delayed neurological complication of measles vaccine

B. CSF IgG Measles antibody

C. Periodic generalized high-voltage slow-wave complexes

D. Isoprinosine improves survival

See Answer in Part B → Q6

@Neet_pg_bot

Q7: A 10 year boy unvaccinated child is brought to hospital with increased irritability, social withdrawal, and difficulty in school. On examination he has myoclonic jerks and motor difficulties. EEG shows periodic spikes of slow-wave discharges occurring every 4–10 seconds. Select the best investigation to be performed in this patient? (Q851105)

A. CSF electrophoresis showing oligoclonal bands

B. CSF showing albuminocytogical dissociation

C. CSF shows Anti measles antibody

D. CSF IgG index

See Answer in Part B → Q7

@Neet_pg_bot

Q8: Match the following conditions with their respective EEGs. 1) Focal seizure a) 2) Absence seizure b) 3) Hypsarrythmia c) 4) Periodic sharp wave complexes d) (Q851102)

A. 1-c, 2-a, 3-d, 4-b

B. 1-b, 2-d, 3-c, 4-a

C. 1-d, 2-c, 3-b, 4-a

D. 1-d, 2-b, 3-c, 4-a

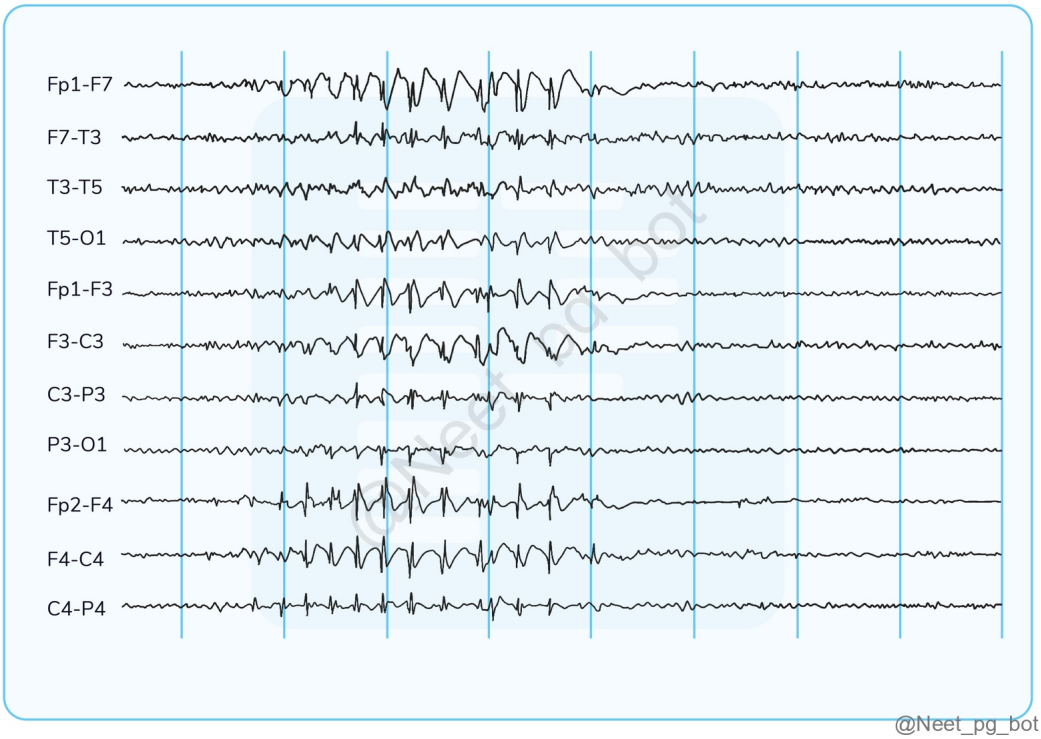

@Neet_pg_bot

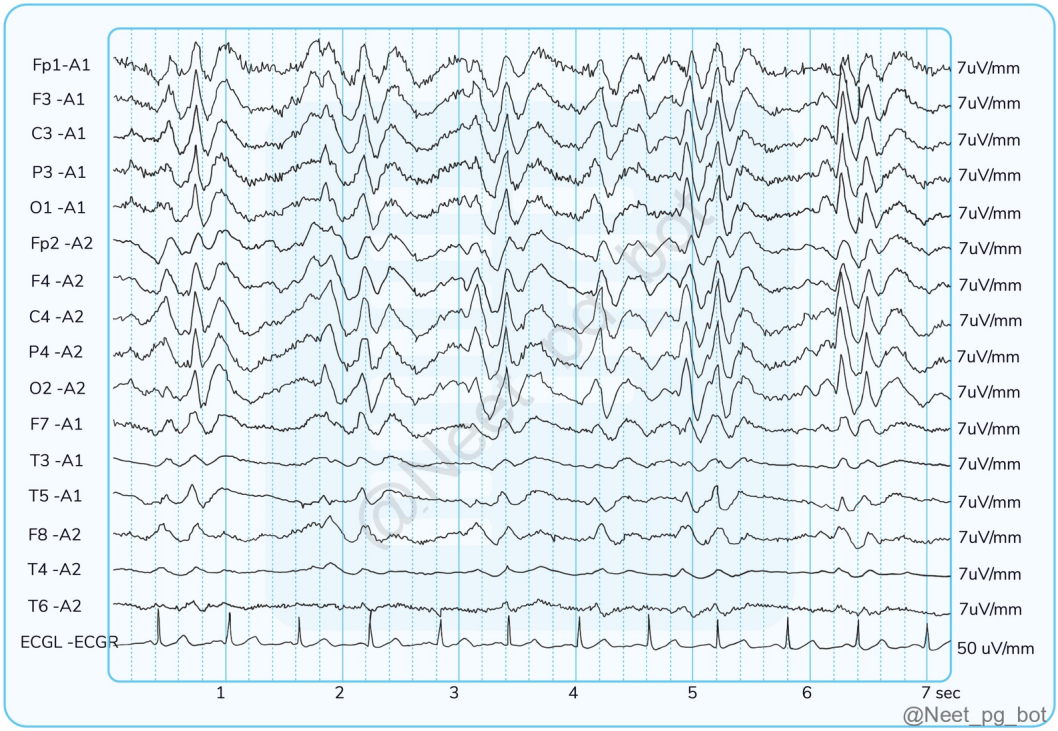

@Neet_pg_bot

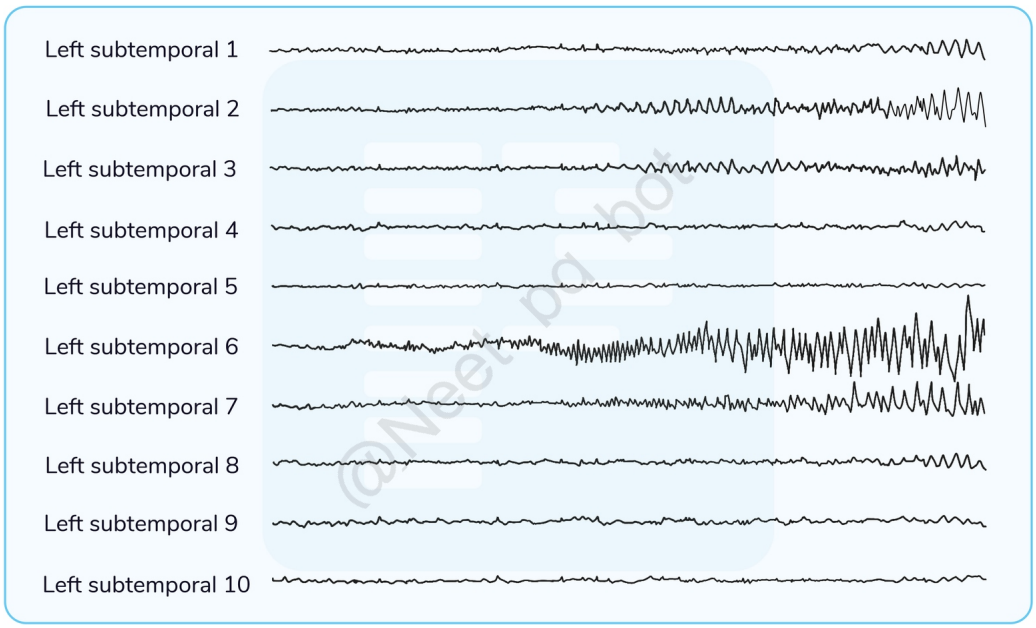

@Neet_pg_bot



@Neet_pg_bot

See Answer in Part B → Q8

@Neet_pg_bot

Q9: A 62 y/o man presents with rapid cognitive decline, visual disturbances, and myoclonus. An EEG shows localized frontal intermittent rhythmical delta activity (FIRDA) that evolves to periodic sharp wave complexes (PSWC) after a few weeks. Based on this presentation and EEG findings, which of the following conditions is most likely associated with his symptoms? (Q851100)

A. Hepatic encephalopathy

B. Creutzfeldt-Jakob disease

C. Renal encephalopathy

D. Alzheimer's disease

See Answer in Part B → Q9

@Neet_pg_bot

Q10: A 2-day-old neonate born at 39 weeks gestation by venthouse is having jitteriness. Which of the following is correct about this presentation? (Q851098)

A. Benign Rolandic epilepsy

B. Subtle seizure

C. Febrile seizures

D. Myoclonic seizures

See Answer in Part B → Q10

@Neet_pg_bot

Q11: A 25 y/o woman with a history of catamenial epilepsy reports an increase in seizure frequency just before her menstrual period. She is currently taking carbamazepine and is newly started on OCPs by her GP for contraception. What is the most appropriate advice for her regarding her current situation? (Q851096)

A. Change to Levetiracetam due to high risk of neural tube defects

B. Switch to Valproate to reduce risk of neural tube defects

C. Consider alternative contraception methods due to carbamazepine's effect on oral contraceptives.

D. Stop all antiseizure medications while trying to conceive.

See Answer in Part B → Q11

@Neet_pg_bot

Q12: Which of the following antiepileptic drugs can worsen generalized seizures, particularly absence or myoclonic types, and should be avoided in idiopathic generalized epilepsy? (Q851095)

A. Valproate

B. Lamotrigine

C. Carbamazepine

D. Topiramate

See Answer in Part B → Q12

@Neet_pg_bot

Q13: Which statement about Mesial Temporal Lobe Epilepsy Syndrome is false? (Q851092)

A. EEG may show unilateral or bilateral anterior temporal spikes.

B. MRI typically reveals an enlarged hippocampus with trilaminar architecture.

C. It is often refractory to anticonvulsants but may respond well to surgical intervention.

D. Auras, postictal disorientation and memory loss can occur.

See Answer in Part B → Q13

@Neet_pg_bot

Q14: A 30 y/o man is brought to the neurology clinic for evaluation after a brief period of unconsciousness. He is awake and alert during the examination. An EEG is performed while his eyes are closed. What is the frequency range recorded in the patient's EEG? (Q851076)

A. 8-13 Hz

B. >13 Hz

C. <4 Hz

D. 4-8 Hz

See Answer in Part B → Q14

@Neet_pg_bot

Q15: A 7 y/o girl presents to the pediatric neurology clinic with a history of multiple seizure types. Her parents report that she has experienced GTCS, atonic seizures where she suddenly drops to the ground, and atypical absence seizures. The child has also shown signs of cognitive impairment. Which of the following statements is true regarding her condition? (Q851090)

A. Characterized by bilateral myoclonic jerks that are most frequent in the morning.

B. The EEG findings show diffuse, symmetric, bilateral 4 to 6 Hz polyspike and wave discharges.

C. Valproate and Topiramate are used in treatment.

D. The condition typically presents in early adolescence.

See Answer in Part B → Q15

@Neet_pg_bot

Q16: A 25 y/o man is brought to the ED after experiencing a generalized tonic-clonic seizure. An EEG is performed after the seizure. Which of the following statements is true regarding the EEG findings associated with his seizure? (Q851089)

A. The interictal EEG shows electrodecremental response

B. During the tonic phase, the EEG typically shows a progressive increase in generalized low-voltage fast activity.

C. The postictal EEG usually reveals localized spikes corresponding to the seizure focus.

D. The EEG during the clonic phase shows low frequency polyspikes with variable amplitude

See Answer in Part B → Q16

@Neet_pg_bot

Q17: A 25-year-old patient with a recently diagnosed PNET experiences recurrent episodes of fainting, often preceded by sweating, tremors and confusion. What is the most likely cause? (Q851088)

A. Orthostatic Hypotension

B. Vasovagal Syncope

C. Metabolic cause

D. Electrolyte imbalance

See Answer in Part B → Q17

@Neet_pg_bot

Q18: A 6-month-old infant presents with brief episodes of sudden flexion of the trunk and limbs, lasting a few seconds. EEG shows hypsarrhythmia, and during the episodes, there's marked background suppression on the EEG. What is the most likely diagnosis? (Q851087)

A. Absence seizures

B. Atonic seizures

C. Epileptic spasms

D. Lennox-Gastaut syndrome

See Answer in Part B → Q18

@Neet_pg_bot

Q19: A 23 year patient presents with sudden, brief muscle jerks on loud auditory stimuli and dementia. T2/FLAIR MRI shows hyperintensity in the pulvinar nucleus of the thalamus. What is the first differential diagnosis? (Q851086)

A. Epileptic spasms

B. Juvenile Myoclonic Epilepsy

C. Variant Creutzfeldt-Jakob Disease (vCJD)

D. Anoxic brain injury

See Answer in Part B → Q19

@Neet_pg_bot

Q20: A 7 year child is brought to the clinic due to frequent episodes of "daydreaming" during school, which last for a few seconds and are accompanied by subtle eyelid blinking. Which of the following is correct about this condition? (Q851084)

A. Episodes can be stopped by hyperventilation

B. Episodes are triggered by photic stimulation

C. < 2.5 Hz spike and slow wave pattern

D. Occur due to defect of sodium channel closure in thalamocortical circuit

See Answer in Part B → Q20

@Neet_pg_bot

Q21: A 35 y/o woman experiences sudden unresponsiveness during conversations, followed by repetitive hand movements and lip-smacking. Afterwards, she seems confused and does not remember the event. Which of the following is the most likely diagnosis? (Q851083)

A. Absence Seizure

B. Panic Attack

C. Focal Seizure with Impaired Awareness

D. Focal Seizure with Intact Awareness

See Answer in Part B → Q21

@Neet_pg_bot

Q22: A 32 y/o woman experiences involuntary movements that begin in her right hand and progressively spread to her right arm and face. She remains fully aware throughout the episode. What is the most likely diagnosis? (Q851080)

A. Absence seizure

B. Todd’s paralysis

C. Epilepsia partialis continua

D. Jacksonian march

See Answer in Part B → Q22

@Neet_pg_bot

Q23: A 20-year-old student experiences episodes of sudden drop attacks with brief loss of consciousness and confusion after the episode. What is the likely diagnosis? (Q851079)

A. Orthostatic hypotension

B. Atonic seizures

C. GTCS

D. Myoclonic seizure

See Answer in Part B → Q23

@Neet_pg_bot

Q24: A 15-year-old boy is brought to the OPD with complaints of repeated episodes of blank staring, and lip-smacking movements lasting around 1–2 minutes. He is confused afterward and has no memory of the episode. Diagnosis is? (Q851078)

A. Focal seizure

B. Absence seizures

C. Pseudo seizures

D. Generalised tonic-clonic seizure

See Answer in Part B → Q24

@Neet_pg_bot

Q25: A 19-year-old medical student collapses in the anatomy dissection hall. His friends report a brief period of limb jerking lasting about 10–15 seconds during the episode. He regained consciousness in a minute, he appeared pale around the lips with sweating on forehead. Diagnosis is? (Q851077)

A. Vasovagal syncope

B. GTCS

C. Pseudoseizures

D. Focal seizures with secondary generalization

See Answer in Part B → Q25

@Neet_pg_bot

• [07_Neurology] 049 Basics Of Cranial Nerves Mechanical Thrombectomy Stroke

« Back to Folder Directory

[07_Neurology] 049 Basics Of Cranial Nerves Mechanical Thrombectomy Stroke — Quick Jump

Q1 (p. 586)	*Q2 (p. 586)*	*Q3 (p. 587)*	*Q4 (p. 587)*	*Q5 (p. 588)*	*Q6 (p. 588)*
Q7 (p. 588)	*Q8 (p. 589)*	*Q9 (p. 589)*	*Q10 (p. 590)*	*Q11 (p. 590)*	*Q12 (p. 590)*
Q13 (p. 591)	*Q14 (p. 591)*	*Q15 (p. 592)*	*Q16 (p. 592)*	*Q17 (p. 593)*	*Q18 (p. 593)*
Q19 (p. 593)	*Q20 (p. 594)*	*Q21 (p. 594)*	*Q22 (p. 595)*	*Q23 (p. 595)*	*Q24 (p. 595)*
Q25 (p. 596)	*Q26 (p. 596)*	*Q27 (p. 597)*	*Q28 (p. 597)*		

Q1: A 50-year-old woman with T2DM is brought in by her family due to strange behaviour. Her daughter says that she noticed that her mother at her wedding was applying makeup only to the left side of her face and eating food from only the left half of her plate. When asked to copy simple shapes such as a triangle, square, and circle her drawings are incomplete and poorly organized. Which of the following brain regions is most likely affected? (Q851256)

A. Left parietal lobe

B. Right parietal lobe

C. Left temporal lobe

D. Right temporal lobe

See Answer in Part B → Q1

@Neet_pg_bot

Q2: A 60 -year-old retired banker and right-handed man is brought with complaints of speech difficulties. He speaks fluently and with normal grammar, and appears to understand both verbal and written commands. However, when asked to repeat phrases, he is unable to do so. His naming and reading comprehension are intact. Which of the following regions is most likely affected? (Q851269)

A. Broca’s area

B. Wernicke’s area

C. Arcuate fasciculus

D. Angular gyrus

See Answer in Part B → Q2

@Neet_pg_bot

Q3: Which of the following is not a feature of Weber syndrome? (Q851268)

A. Contralateral lower face weakness

B. Eye down and out (ipsilateral)

C. Vertical gaze palsy

D. Hemiplegia (contralateral)

See Answer in Part B → Q3

@Neet_pg_bot

Q4: A 65-year-old woman presents to ER with history of suddenly falling down with difficulty in swallowing. On examination patient can stick out her tongue without any deviation, and gag reflex is diminished. Ipsilateral nystagmus is noted with ataxia of limbs, ipsilateral face numbness with a contralateral pain and temperature loss. Diagnosis is? (Q851267)

A. Brown sequard syndrome

B. Wallenberg Syndrome

C. Locked in syndrome

D. Medial Medullary Syndrome

See Answer in Part B → Q4

@Neet_pg_bot

Q5: A 70-year-old diabetic man presents with sudden right-sided weakness. On examination, there is loss of proprioception and vibration on the right side of the body, and his tongue deviates to the left on protrusion. Facial sensation is intact. What is the most likely diagnosis? (Q851266)

A. Lateral medullary syndrome

B. Medial medullary syndrome

C. Central pontine myelinosis

D. Anterior cerebral artery stroke

See Answer in Part B → Q5

@Neet_pg_bot

Q6: A 38-year-old Formula 1 driver suffers a high-speed crash. At the hospital, he is unable to move his limbs, talk, or drink from a straw. Examination reveals quadriplegia with bilateral long tract signs, with absent gag reflex, but a nurse notices that he can move his eyes vertically on command. What is the most likely diagnosis? (Q851265)

A. Brain stem death

B. Locked in syndrome

C. Vegetative state

D. Decerebrate posturing

See Answer in Part B → Q6

@Neet_pg_bot

Q7: A 62-year-old patient presents with left-sided arm and leg weakness, right-sided facial paralysis with lateral rectus gaze palsy and nystagmus. Which of the following syndromes is consistent with these symptoms? (Q851264)

A. Foville Syndrome

B. Benedikt syndrome

C. Millard Gubler

D. Wallenberg syndrome

See Answer in Part B → Q7

@Neet_pg_bot

Q8: A 60-year-old male presents to neurology follow-up OPD four weeks after a stroke with persistent allodynia, especially while taking a bath with warm water. Which of the following is correct about this case? (Q851263)

A. Complex regional pain syndrome type I

B. Thalamic infarct

C. Internal capsule infarct

D. Complex regional pain syndrome type II

See Answer in Part B → Q8

@Neet_pg_bot

Q9: A 25-year-old woman presents with double vision. On examination, she has paralysis of vertical gaze and pupils that constrict during accommodation but not in response to light (light-near dissociation). CT head shows mass arising in pineal region. Diagnosis is? (Q851262)

A. M.Gravis

B. Neurosyphilis

C. Internuclear opthalmoplegia

D. Perinaud syndrome

See Answer in Part B → Q9

@Neet_pg_bot

Q10: A 60-year-old man presents with a sudden onset drooping of left eye and balance issues. On examination, he has left-sided ptosis, dilated left pupil, and the left eye is "down and out." He demonstrates significant right-sided ataxia. He is unable to move his eyes vertically . Diagnosis is? (Q851261)

A. Weber syndrome

B. Nonthangel syndrome

C. Benedikt syndrome

D. Millard gubler syndrome

See Answer in Part B → Q10

@Neet_pg_bot

Q11: A 35-year-old alcoholic patient presents with palpitations for the last 2 hours. On examination, he has an irregularly irregular pulse, BP 130/100 mm Hg, and a GCS of 15/15. Higher mental functions and cranial nerve examination are normal. There is no focal neurological deficit. What is the most appropriate next step in management? (Q851260)

A. Thrombolysis as patient is in window period

B. Control ventricular rate

C. Start anticoagulation with warfarin

D. Start anticoagulation with novel oral anticoagulants

See Answer in Part B → Q11

@Neet_pg_bot

Q12: A patient presents with sudden onset aphasia and right sided arm weakness for the past 4 hours. On examination he has irregularly irregular pulse. Which of the

following investigations will be done to determine etiology of this case presentation? (Q851259)

A. Transthoracic echocardiography

B. Carotid doppler

C. Transesophageal echaocardiography

D. MRI Brain

See Answer in Part B → Q12

@Neet_pg_bot

Q13: A 54-year-old male presents with a sudden onset of double vision and left-sided weakness. On examination he has a right-sided ptosis, a dilated pupil that does not react to light, and an outward deviation of the right eye. The left side of his body shows spastic weakness with hyperreflexia. MRI reveals an ischemic lesion in the midbrain. Which of the following structures is most likely involved in this patient's condition? (Q851258)

A. Occulomotor motor and red nucleus

B. Oculomotor nerve and crus cerebri

C. Occulomotor nerve and superior cerebellar penduncle

D. Occulomotor nerve and substania nigra

See Answer in Part B → Q13

@Neet_pg_bot

Q14: A patient with stroke cannot perform simple actions on command, such as waving goodbye or pretending to brush teeth, even though they understand what to do and have no muscle weakness. When spoken a phrase "Repeat after me: 'The sky is blue'", the patient struggles to repeat it but speaks fluently and understands spoken language. Which lobe is most likely affected? (Q851257)

A. Right Parietal

B. Right Temporal

C. Left Parietal

D. Left Temporal

See Answer in Part B → Q14

@Neet_pg_bot

Q15: A 60-year-old man presents with sudden onset of right-sided face and arm weakness at the breakfast table at 8 am. He arrives at the ER at 4 pm in the evening. His pulse is 100/min, BP 180/100 mm Hg, NIHSS is 6, and GCS is 13/15. NCCT head shows hypodensity in the left MCA territory and CTA reveals a M1 left MCA occlusion. . Which of the following is the best intervention for management of this patient? (Q851178)

A. Rapid lowering of BP with nicardipine to achieve target BP 140/100 mm Hg

B. Thrombectomy

C. Secure airway

D. Schedule for thrombolysis after lowering of BP

See Answer in Part B → Q15

@Neet_pg_bot

Q16: A 60-year-old hypertensive man presents with sudden onset slurred speech and difficulty comprehending language. NCCT head scan reveals an ischemic stroke. The stroke likely involves which of the following vessels? (Q851198)

A. Left anterior cerebral artery

B. Left middle cerebral artery

C. Right middle cerebral artery

D. Right anterior cerebral artery

See Answer in Part B → Q16

@Neet_pg_bot

Q17: A 40-year old lady complains of difficulty in kneading the dough for past 6 months. On examination she has atrophy of right hand muscles and fasiculations are noted in thenar muscles. Select the site of lesion? (Q851197)

A. Right anterior horn cells in spinal cord

B. Left anterior horn cells in spinal cord

C. Right Parietal Lobe

D. Left Parietal Lobe

See Answer in Part B → Q17

@Neet_pg_bot

Q18: Gait apraxia and urinary incontinence are clinical features associated with damage to which lobe of the brain? (Q851196)

A. Temporal

B. Parietal

C. Occipital

D. Frontal

See Answer in Part B → Q18

@Neet_pg_bot

Q19: A 65 year man can recognise voices of family members while talking over mobile phone. But when he meets them in person he is not able to recognise them. Lesion is present in which part of brain? (Q851194)

A. Frontal lobe

B. Temporal Lobe

C. Parietal Lobe

D. Occipital Lobe

See Answer in Part B → Q19

@Neet_pg_bot

Q20: A 60-year-old right-handed woman is brought by her husband after he notices she has trouble doing dishes and confuses her left and right sides since last evening. On examination, she cannot perform simple calculations, but her speech is fluent. The lesion is most likely in which structure? (Q851192)

A. Right Temporal Lobe

B. Left Temporal Lobe

C. Left Parietal Lobe

D. Right Parietal Lobe

See Answer in Part B → Q20

@Neet_pg_bot

Q21: A patient presents with sudden onset weakness affecting the face, arm, and leg on one side of the body without sensory loss or cortical signs. Which is the most likely site of lesion? (Q851190)

A. Anterior limb of internal capsule

B. Posterior limb of internal capsule

C. Genu of internal capsule

D. Thalamus

See Answer in Part B → Q21

@Neet_pg_bot

Q22: A 70-year-old male presents to ER with sudden-onset right-sided arm weakness and difficulty speaking which started 2 hours ago. His medical history includes hypertension, hyperlipidemia, and a prior TIA. His BP is 160/100 mm Hg. A CT scan of the head rules out hemorrhagic stroke. Which of the following is the most appropriate initial management for this patient? (Q851189)

A. Administer intravenous Alteplase immediately.

B. Start intravenous heparin for anticoagulation therapy.

C. Intubate the pateint

D. Control BP with Labetalol

See Answer in Part B → Q22

@Neet_pg_bot

Q23: A 65-year-old diabetic male presents to the emergency department with a sudden onset of right-sided weakness and slurred speech that resolved completely within 2 hours. His blood pressure is 160/90 mmHg. Based on his ABCD2 score of 6, what is the most appropriate immediate management? (Q851187)

A. Start oral aspirin 81 mg daily alone

B. Combination of ticagrelor plus aspirin

C. Warfarin with target INR 2-3

D. Tenecteplase

See Answer in Part B → Q23

@Neet_pg_bot

Q24: Which of the following is not correct about ABCD2 score for diagnosis of Transient ischemic attack? (Q851186)

A. Age > 60 years

B. Elevated BP

C. Past history of stroke

D. Duration of symptoms

See Answer in Part B → Q24

@Neet_pg_bot

Q25: A 60-year-old man presents with sudden onset right arm weakness and slurred speech for 1 hour. His blood pressure is 170/100 mm Hg. He has a history of atrial fibrillation and is on warfarin; current INR is 2.0. NCCT head shows no intracranial hemorrhage. CT angiography reveals a left MCA occlusion. Which of the following is the most appropriate next step in management? (Q851184)

A. Intravenous Alteplase

B. Mechanical thrombectomy after confirming salvageable tissue with CT perfusion

C. Cardiology consult for chemical cardioversion

D. Mannitol and dual antiplatelet therapy

See Answer in Part B → Q25

@Neet_pg_bot

Q26: A 58-year-old right-handed man is brought to the ER for speaking fluently but producing nonsensical words and sentences. He has difficulty understanding spoken commands. Neurological exam shows no significant motor weakness. Which of the following vessels is most likely involved? (Q851182)

A. Superior division of left middle cerebral artery

B. Inferior division of left middle cerebral artery

C. Left anterior cerebral artery

D. Left posterior cerebral artery

See Answer in Part B → Q26

@Neet_pg_bot

Q27: A 65-year-old male presents with sudden onset of vertigo, dysphagia, hoarseness, and left-sided facial numbness. On examination, he has left-sided Horner's syndrome, right-sided loss of pain and temperature sensation in the body, and left-sided cerebellar signs. Which of the following is the most likely diagnosis? (Q851181)

A. Parinaud syndrome

B. Dejerine syndrome

C. Wallenberg syndrome

D. Weber syndrome

See Answer in Part B → Q27

@Neet_pg_bot

Q28: A 65-year-old hypertensive man presents with a sudden onset of right-sided weakness affecting his face, arm, and leg. The NCCT head shows an intraparenchymal bleed in left side basal ganglia. Which of the following vessels is most likely involved in this pathology? (Q851180)

A. Internal carotid artery

B. Posterior communicating artery

C. Penentrating branches of lenticulostriate arteries

D. Anterior communicating artery

See Answer in Part B → Q28

@Neet_pg_bot

• [07_Neurology] 050 Stroke Tia And Image Based Questions

« Back to Folder Directory

[07_Neurology] 050 Stroke Tia And Image Based Questions — Quick Jump

Q1 (p. 598)	*Q2 (p. 598)*	*Q3 (p. 599)*	*Q4 (p. 600)*	*Q5 (p. 600)*	*Q6 (p. 601)*
Q7 (p. 602)	*Q8 (p. 603)*	*Q9 (p. 604)*	*Q10 (p. 605)*	*Q11 (p. 606)*	*Q12 (p. 606)*
Q13 (p. 607)	*Q14 (p. 608)*	*Q15 (p. 608)*	*Q16 (p. 609)*	*Q17 (p. 610)*	*Q18 (p. 611)*
Q19 (p. 611)	*Q20 (p. 612)*	*Q21 (p. 613)*	*Q22 (p. 614)*	*Q23 (p. 614)*	*Q24 (p. 614)*
Q25 (p. 615)	*Q26 (p. 616)*	*Q27 (p. 616)*	*Q28 (p. 617)*	*Q29 (p. 618)*	

Q1: A 62-year-old woman presents with chronic burning pain, numbness, and tingling on the right side of her body not relieved with NSAIDs. The symptoms began 2 months after she suffered a stroke. On examination, she has hyperesthesia and allodynia on the right side. The clinician suspected it to be due to lacunar infarct. What could be the likely site of infarct causing her present symptoms? (Q851217)

A. Ventroposterolateral thalamus

B. Posterior limb of internal capsule

C. Genu of internal capsule

D. Cortical pontocerebellar tract

See Answer in Part B → Q1

@Neet_pg_bot

Q2: An elderly patient presented with a history of slowing of movements, frequent falls and forgetfulness. MRI done is as shown below. Which among the following is not a feature of this condition? (Q852414)

A. Defective downward gaze

B. Resting tremors

C. Poor response to levodopa

D. Gunslinger’s gait

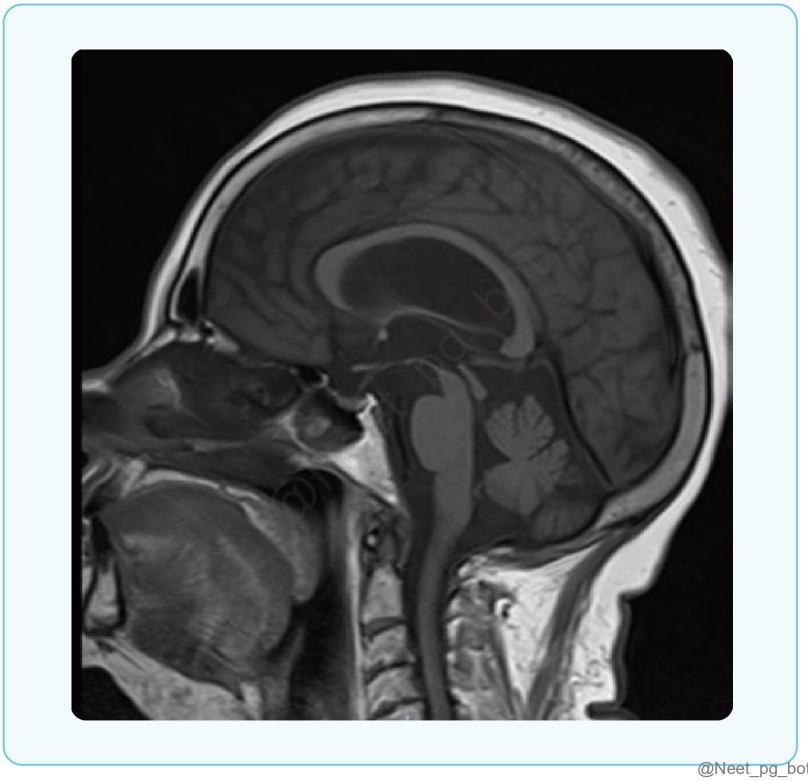

See Answer in Part B → Q2

@Neet_pg_bot

Q3: Which of the following clinical signs of upper motor neuron lesion is described correctly ? (Q851230)

A. Babinski’s sign - Lateral stroke of the sole resulting in flexion of all toes

B. Gordon’s sign - A stroke beneath and in front of the lateral malleolus causing an extensor plantar response.

C. Oppenheim’s sign - Apply pressure along the medial aspect of tibia causing an extensor plantar response

D. Chaddock’s sign - Squeeze the calf muscles to produce extensor plantar response.

See Answer in Part B → Q3

@Neet_pg_bot

Q4: A 5 year old female child presented to the casualty with recurrent seizures and left sided hemiplegia. On physical examination, a reddish skin lesion was found since birth over the right side of her forehead involving the right eye, nose and cheek. On CT imaging of the brain, the following picture was seen. What is the probable diagnosis? (Q851229)

A. Von Hippel Lindau syndrome

B. Sturge Weber syndrome

C. Neurofibromatosis

D. Ataxia telangiectasia



See Answer in Part B → Q4

@Neet_pg_bot

Q5: A 15 year old adolescent male patient came with his parents with complaints of neuropsychiatric symptoms such as tremors and an irritable mood. On physical

examination, stigmata of liver disease and the following ophthalmological finding is seen. Which of the following is correct about this condition? (Q851228)

A. Defect in P type ATP ase ATP7B protein

B. Defect in P type ATP ase ATP7A protein

C. ATP7B gene defect with increased ceruloplasmin

D. ATP7A gene defect with increased ceruloplasmin



See Answer in Part B → Q5

@Neet_pg_bot

Q6: A 30 year old male patient was brought to the ER with a history of RTA and sustained multiple injuries. On primary assessment, he was disoriented and complained of severe headache. Meningeal signs are noted. On neuroimaging the following image was seen. What is the most probable diagnosis in this patient? (Q851227)

A. Intracerebral hemorrhage

B. Subdural hemorrhage

C. Subarachnoid hemorrhage

D. Extradural hemorrhage



See Answer in Part B → Q6

@Neet_pg_bot

Q7: A 75 year old male patient came to the OPD with complaints of recent onset stooping, broad based abnormal gait, short-term memory loss and urge incontinence. On radiological investigation, the following image is obtained. What is the probable diagnosis? (Q851226)

A. Parkinson’s disease

B. Alzheimer’s disease

C. Normal pressure hydrocephalus

D. Idiopathic intracranial hypertension

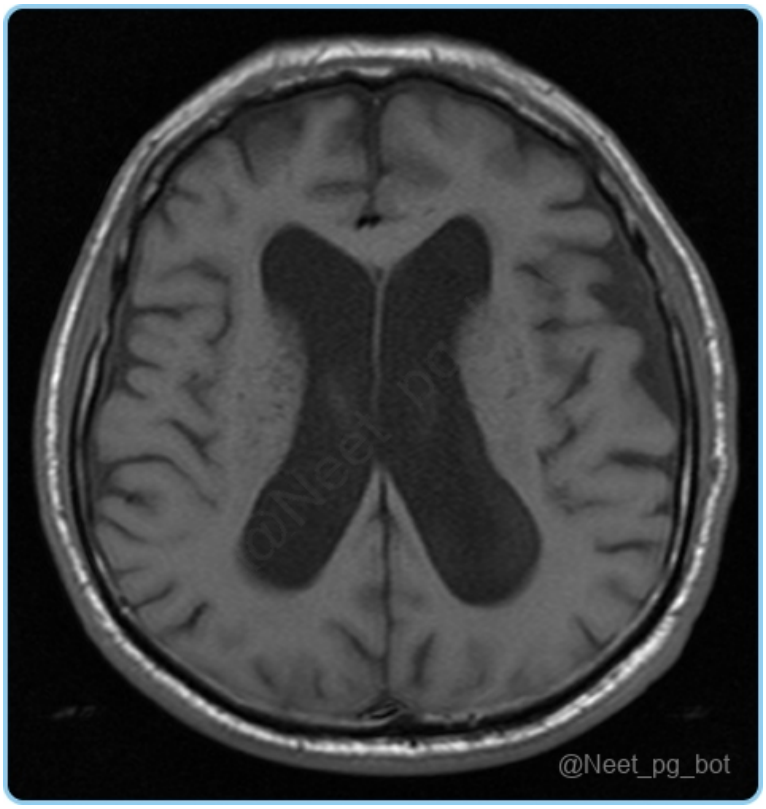

See Answer in Part B → Q7

@Neet_pg_bot

Q8: A 13 year old male patient presented with complaints of poor scholastic performance, history of recurrent seizures since infancy and the following incidental finding on his back. What does the incidental finding denote and probable diagnosis of this patient? (Q851225)

A. Neurofibroma and Neurofibromatosis

B. Adenoma sebaceum and Tuberous sclerosis

C. Shagreen patch and Tuberous sclerosis

D. Cafe-au-lait spots and Neurofibromatosis



See Answer in Part B → Q8

@Neet_pg_bot

Q9: A 45-year-old woman presents with progressive hearing loss in the right ear, occasional imbalance while walking, and a sensation of fullness in the ear. On examination, she has decreased corneal reflex on the right side. MRI of the brain is shown below. Which of the following is the most likely diagnosis? (Q851224)

A. Vestibular schwannoma

B. Cerebellar Astrocytoma

C. Craniopharyngioma

D. Prion disease

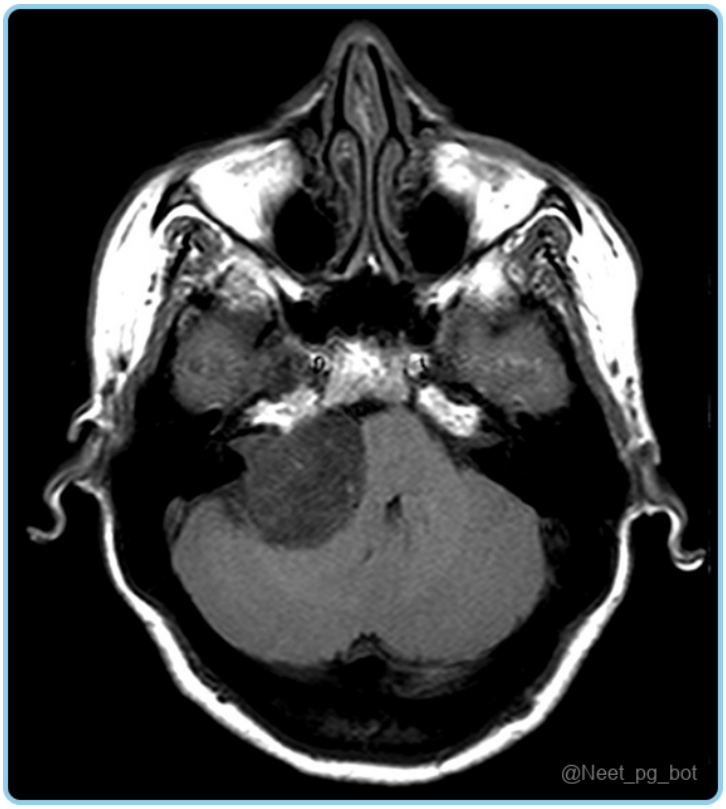

See Answer in Part B → Q9

@Neet_pg_bot

Q10: A 9-year-old child presents with progressive dystonia, difficulty walking, and slurred speech. On examination, he has oromandibular dystonia and choreoathetosis. MRI brain shows bilateral hypointensity of the globus pallidus with a central area of hyperintensity. Which of the following is the most likely diagnosis? (Q851223)

A. Pantothenate kinase-associated neurodegeneration

B. Huntington disease

C. Craniopharyngioma

D. Prion disease

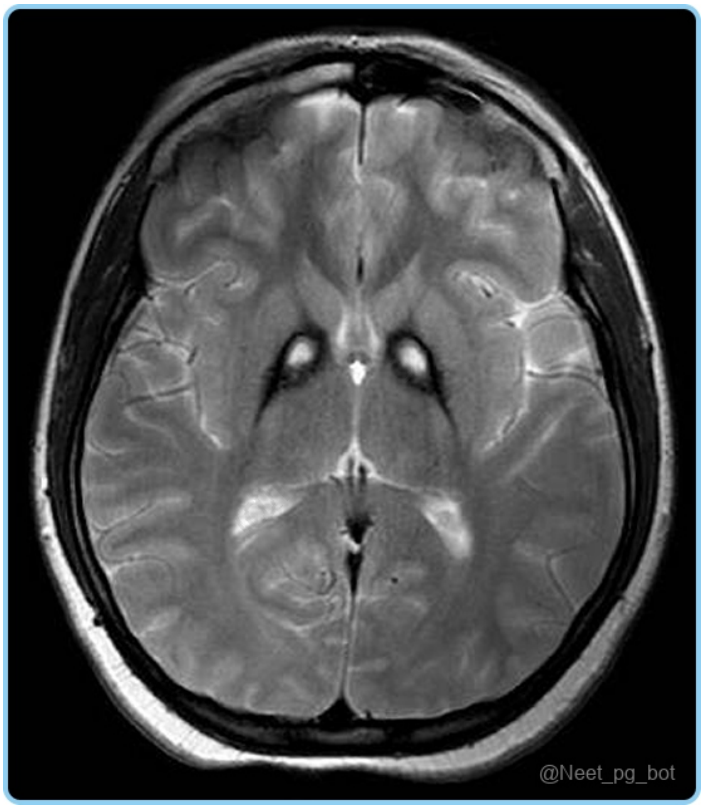

See Answer in Part B → Q10

@Neet_pg_bot

Q11: Which of the following is a CT finding of Pneumocephalus? (Q851222)

A. Mount Fuji Sign

B. Air Bubble Sign

C. Peaking Sign

D. All of the above

See Answer in Part B → Q11

@Neet_pg_bot

Q12: A 5-year-old is having daily headaches and difficulty copying from the board. He was found to have bitemporal hemianopia, and an MRI of the head was done. Which

of the following is not correct about this condition? {{caption_text}} (Q851221)

A. Cystic swelling with calcification

B. Derived from Rathke pouch

C. Compression of optic chiasma

D. Leading infratentorial brain tumor in children

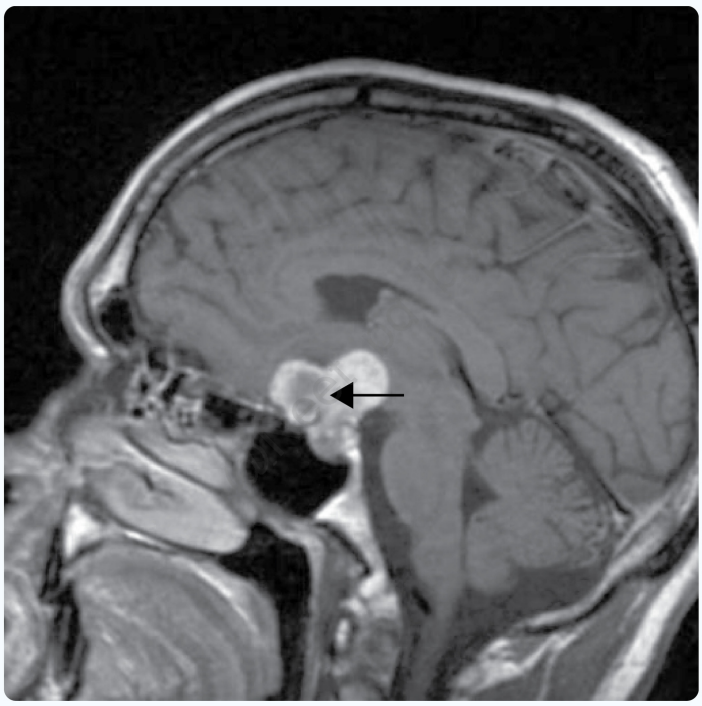

@Neet_pg_bot

See Answer in Part B → Q12

@Neet_pg_bot

Q13: Which of the following is incorrect about variant creutzfeldt-jakob disease? (Q851220)

A. Periodic sharp wave complexes on EEG

B. Cortical ribboning in MRI

C. Increased intensity in the basal ganglia

D. JEV-specific IgM in CSF by MAC■ELISA

See Answer in Part B → Q13

@Neet_pg_bot

Q14: A 35-year-old male presents to the ER after a fall, initially conscious but rapidly deteriorates following a brief lucid interval. The CT image is given below. What is the diagnosis? {{caption_text}} (Q851219)

A. Epidural hematoma

B. Subarachnoid hemorrhage

C. Subdural hematoma

D. Intracerebral hematoma



See Answer in Part B → Q14

@Neet_pg_bot

Q15: Based on the MRI finding (shown below) , Which of the following criteria and corresponding treatment used in this condition? {{caption_text}} (Q851218)

A. Brighton’s criteria, IV Steroids

B. Brighton’s criteria, IV Immunoglobulin

C. McDonald’s criteria, IV Steroids

D. McDonald’s criteria, IV Immunoglobulin

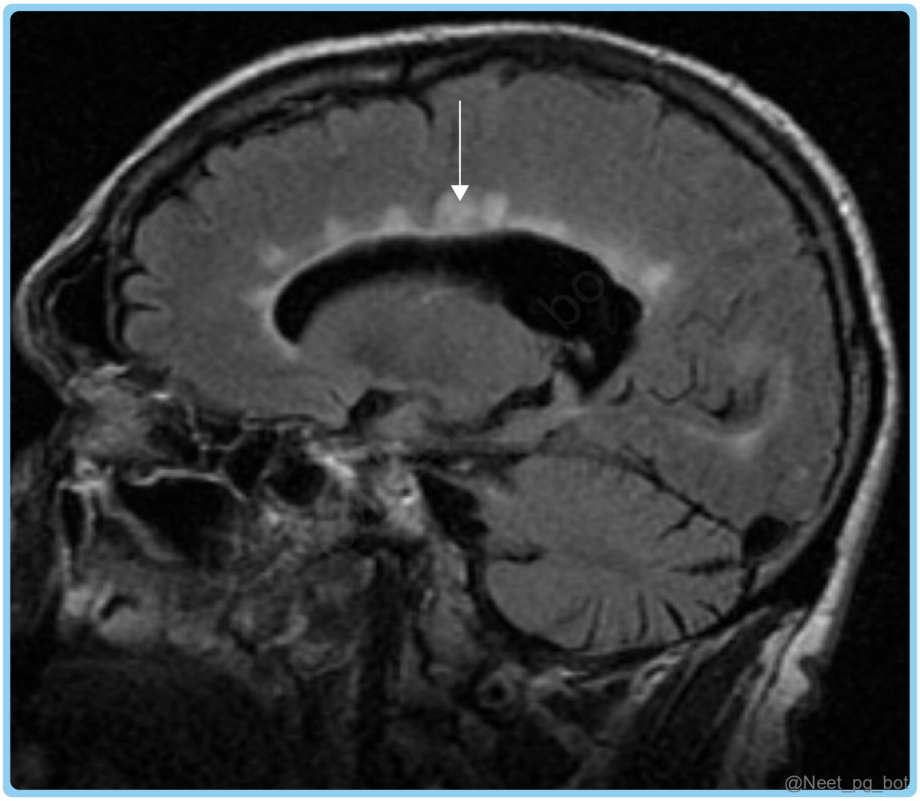

See Answer in Part B → Q15

@Neet_pg_bot

Q16: A 68-year-old male presents to the ER with a sudden onset of headache and right-sided arm weakness that started while brushing his teeth in morning at 7 am. He is known case of hypertension and says he slept on couch last night while watching TV. On examination at 9 am he has irregularly irregular pulse, his arm weakness has improved significantly (power grade 4/5) and he can talk, drink water, chew food and walk normally. NCCT head is normal. Which of the following is the cause of this

presentation? (Q851201)

A. Spontaneous subarachnoid hemorrhage with resorption

B. Cerebral embolism with spontaneous reperfusion

C. Neuronal death due to cerebral anoxia

D. Saturday night palsy due to neurapraxia

See Answer in Part B → Q16

@Neet_pg_bot

Q17: A 30-year-old female who delivered a male baby via C-section owing to eclampsia developed a sudden onset headache, seizures, visual disturbances, and altered sensorium 2 days following delivery. BP is 180/120 mm Hg. An MRI head is shown. What is the likely diagnosis? {{caption_text}} (Q851216)

A. Reversible cerebral vasoconstriction syndrome (RCVS)

B. CADASIL

C. Post partum TIA

D. Posterior reversible encephalopathy syndrome (PRES)

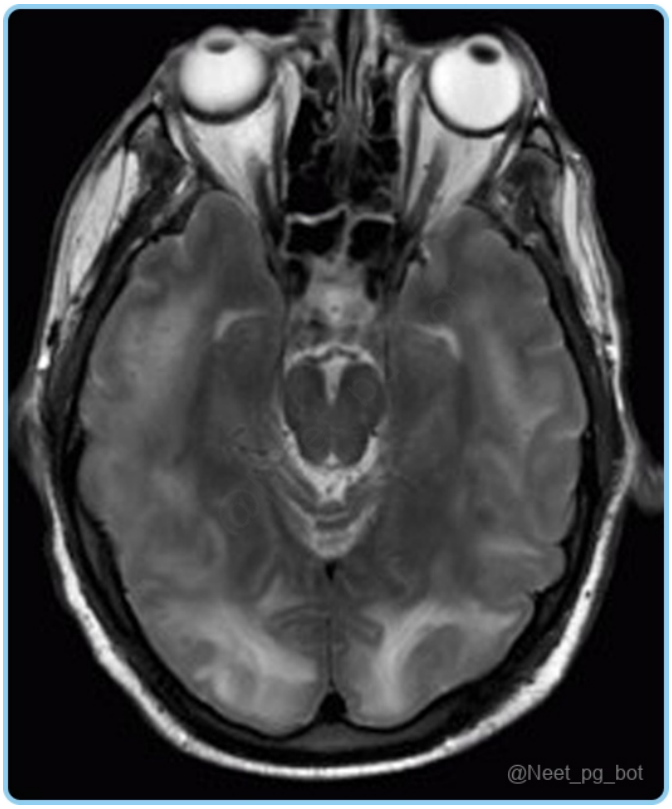

See Answer in Part B → Q17

@Neet_pg_bot

Q18: Which among the following statements is/are false regarding CADASIL ? 1) Autosomal Dominant inheritance 2) Predominantly causes Large-vessel stroke 3) Characteristic symptom is Migraine with aura 4) Notch-3 gene is involved (Q851215)

A. 2

B. 1,3

C. 1,2

D. 2,3

See Answer in Part B → Q18

@Neet_pg_bot

Q19: Child presented with reccurent TIA events. Cerebral angiography was performed. Which among the following is false regarding this condition? {{caption_text}} (Q851214)

A. Involves occlusion of predominantly large arteries

B. Associated with vascular inflammation

C. Anticoagulation is contraindicated

D. Can present in adults with brain hemorrhage

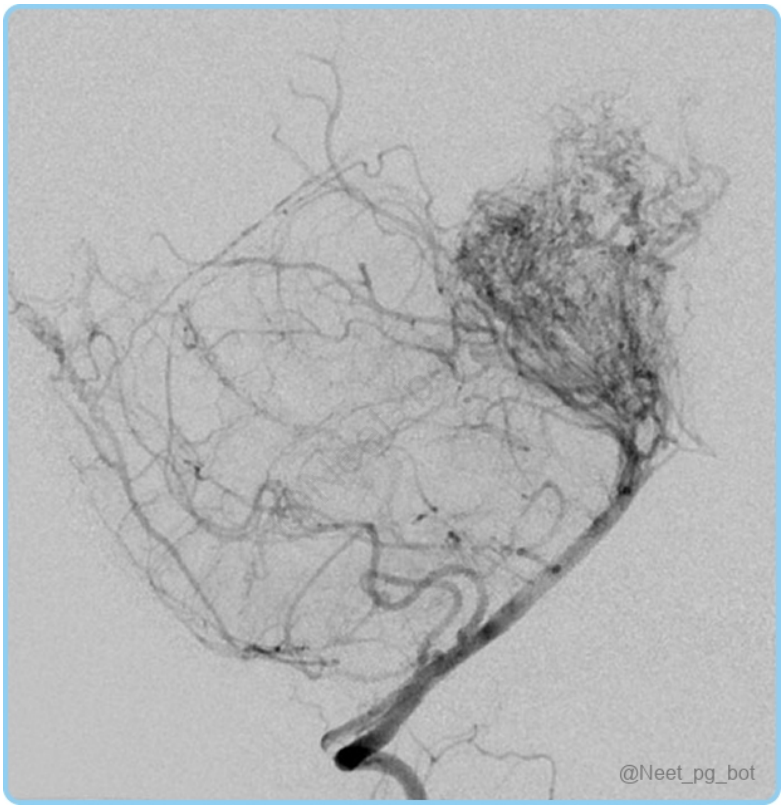

See Answer in Part B → Q19

@Neet_pg_bot

Q20: A 35 year old woman presents with sudden onset headache, seizures and focal neurological deficits. BP on admission is 160/100 mm Hg. She has a history of oral contraceptive use. CECT head is shown below. What is the most appropriate initial treatment for this patient? {{caption_text}} (Q851213)

A. Thrombolysis

B. Heparin

C. Oral warfarin immediately

D. Thrombectomy

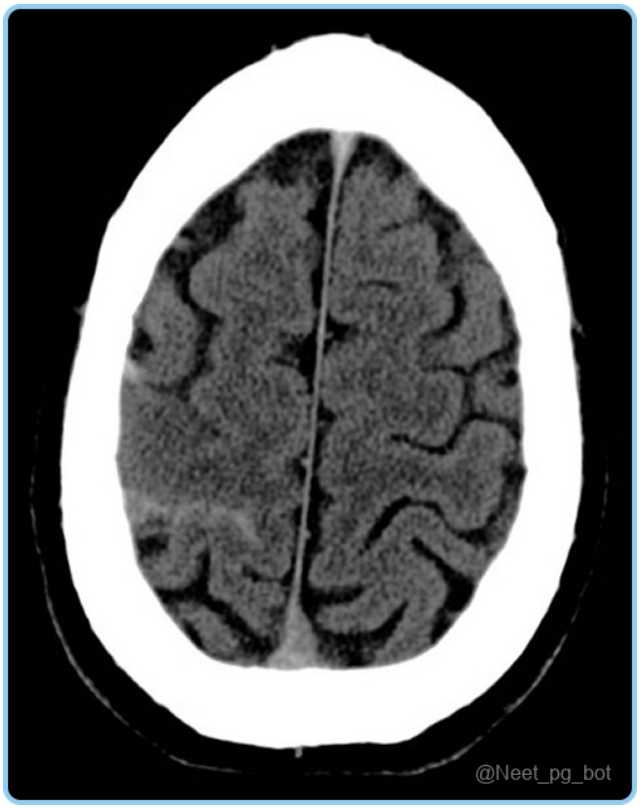

See Answer in Part B → Q20

@Neet_pg_bot

Q21: As an intern in the medicine ward, you are asked to guide the nursing staff about the various supportive care measures to improve the outcome in of Acute ischemic stroke patients who are managed with thrombolysis. Which among the following will you not advise? (Q851212)

A. Monitor vitals and place in head end elevated position

B. Perform urinary catheterisation for input output charting

C. Pneumatic compression stockings to prevent deep vein thrombosis.

D. Give antipyretics to patients with fever to prevent infarct expansion

See Answer in Part B → Q21

@Neet_pg_bot

Q22: Which of the following is a contraindication to thrombolysis in a patient with acute ischemic stroke? (Q851211)

A. CT showing ischemic changes in > 1/3 MCA territory

B. CT scan showing Hyperdense MCA sign

C. Large Hematochezia episode 10 days ago requiring banding

D. Recent epistaxis requiring nasal packing

See Answer in Part B → Q22

@Neet_pg_bot

Q23: A 58 year old T2DM male with hypertension presents to the emergency department 2 hours after developing sudden onset of right sided arm weakness and face asymetry. His blood pressure is 170/90 mmHg, and a NCCT head shows no hemorrhage. He is on metformin, metoprolol and atorvastatin. What is the most appropriate initial treatment for this patient? (Q851210)

A. Thrombolysis with alteplase

B. Antiplatelet therapy with aspirin

C. Mechanical thrombectomy

D. Immediate blood pressure reduction followed by Alteplase

See Answer in Part B → Q23

@Neet_pg_bot

Q24: A 50 year old male patient came to the ER with complaints of headache, blurring of vision and right sided hemiparesis for 2 hours. He is a known case of diabetes mellitus and hypertension. On examination pulse is 92/min with BP 190/110 mm Hg. What is the most appropriate statement regarding management of this patient? {{caption_text}} (Q851209)

A. Blood pressure of the patient should be reduced to <140/90 with nicardipine

B. The head end of the patient's bed should be flat to prevent coning of the brain.

C. Immediate intravenous thrombolysis is recommended since the patient is in window period

D. Urgent lowering of BP with nicardipine followed by thrombolysis since patient is in window period



See Answer in Part B → Q24

@Neet_pg_bot

Q25: A 65 year old male presents to the emergency department with a sudden onset of right sided weakness, slurred speech and facial drooping for the past 1 hour. NCCT head is normal. What is the appropriate scoring done to confirm the diagnosis of this

patient? (Q851208)

A. ABCD2

B. CHADS2VASc

C. NIHSS

D. Agatson

See Answer in Part B → Q25

@Neet_pg_bot

Q26: A 70 year old woman presents to the ER with sudden-onset slurred speech and right-sided facial weakness that resolved after 90 minutes. The resident has asked you to calculate ABCD2 score. Which of the following is not a component of this score (Q851207)

A. Blood pressure

B. History of stroke

C. Diabetes mellitus

D. Duration of symptoms

See Answer in Part B → Q26

@Neet_pg_bot

Q27: A 45-year-old man with hypertension presents to the ER at 6 am in morning with excruciating headache and sudden onset face, arm and leg weakness. On examination GCS is 8 and blood pressure is 220/110 mmHg. NCCT head is shown. Cause of this presentation is? {{caption_text}} (Q851206)

A. Ruptured saccular aneurysm

B. Rupture of penetrating arteries supplying internal capsule

C. Dural sinus thrombosis

D. Posterior reversible encephalopathy syndrome



See Answer in Part B → Q27

@Neet_pg_bot

Q28: A 60-year-old man is brought to ER with sudden onset of right-sided arm weakness and difficulty speaking. His gaze is deviated to the left, and he has a right homonymous hemianopia. Which of the following is the most likely location of the thrombus causing this patient's symptoms? (Q851203)

A. Left MCA, Non dominant hemisphere

B. Left MCA, Dominant hemisphere

C. Left PCA, Dominant hemisphere

D. Right PCA, Non Dominant hemisphere

See Answer in Part B → Q28

@Neet_pg_bot

Q29: A 60 year old man presents with sudden onset right face deviation and arm weakness for last 8 hours. BP on admission is 185/110 mm Hg. NCCT head shows hypodensity in parietal lobe and CTA shows clot in M2 segment of MCA. Which is the best intervention for this patient? (Q851202)

A. Endovascular coiling

B. CT perfusion with endovascular thrombectomy

C. Lower BP with Nicardipine followed by Tenecteplase

D. Lower BP with Nicardipine followed by Aspirin loading 325 mg

See Answer in Part B → Q29

@Neet_pg_bot

• [07_Neurology] 051 Guillian Barre Syndrome And Alzheimer S Disease

« Back to Folder Directory

[07_Neurology] 051 Guillian Barre Syndrome And Alzheimer S Disease — Quick Jump

Q1 (p. 619) *Q2 (p. 619)* *Q3 (p. 620)* *Q4 (p. 620)* *Q5 (p. 620)* *Q6 (p. 621)*
Q7 (p. 621) *Q8 (p. 622)* *Q9 (p. 622)* *Q10 (p. 623)* *Q11 (p. 623)* *Q12 (p. 623)*
Q13 (p. 624) *Q14 (p. 624)*

Q1: A 30-year-old man from Pune presents with recurrent falls in stairs from past 3 days with leg muscle weakness and root pains in both legs. On examination flaccid paralysis is noted in both legs with arreflexia. Sensory examination shows distinct level below T10 where radicular pain is being felt. Bladder was catheterized due to urinary incontience. MRI spine shows inflammation of spinal cord. He had a diarrheal episodes 2 weeks ago. Diagnosis is? (Q851492)

A. Acute inflammatory demyelinating polyneuropathy

B. Miller Fisher syndorme

C. Transverse Myelitis

D. Chronic inflammatory demyelinating polyneuropathy

See Answer in Part B → Q1

@Neet_pg_bot

Q2: Which of the following is not correct about GBS? (Q851493)

A. Prolonged F wave latency

B. Diaphragmatic paralysis

C. Pseudo-bulbar weakness may cause difficulty in handling secretions

D. Proprioception loss

See Answer in Part B → Q2

@Neet_pg_bot

Q3: Which of the following statements is incorrect regarding the types of Guillain-Barré syndrome? (Q851494)

A. AIDP is the most common form in adults

B. AMSAN has best prognosis amongst all variants

C. AMAN involves axonal degeneration in children and young adults

D. Miller-Fisher syndrome is associated with anti-GQ1b antibodies

See Answer in Part B → Q3

@Neet_pg_bot

Q4: A 35-year-old man presents with a 2-day history of progressive weakness that started in his legs after returning from his international trip. Today he cannot get up from bed and is having hand weakness. On examination, distal arreflexia is noted with power grade 1/5 for muscles at all joints of lower limbs and 3/5 for upper limbs. CSF study shows cytoalbuminological dissociation. Which criteria are used for diagosis of this condition? (Q851495)

A. Brighton

B. Macdonald'

C. Adam and Victor

D. Dubois

See Answer in Part B → Q4

@Neet_pg_bot

Q5: A 40-year-old man presents with a one-day history of progressive weakness, initially localised to his legs but now involving the arms. He tells about the inability to button his shirt along with fatigue during minimal exertion. On examination, there is

flaccid quadriparesis with absent deep tendon reflexes. What is the next best step in the management of this patient? (Q851496)

A. Nerve conduction studies

B. Lumbar puncture for cytoalbuminological dissociation

C. Anti GM1 and Anti GQ1 antibody titers

D. PCR stool for C. jejuni

See Answer in Part B → Q5

@Neet_pg_bot

Q6: A 50-year-old man presents with difficulty in walking due to imbalance following a recent viral illness. He also reports double vision. Examination reveals bilateral ptosis, ophthalmoplegia, and areflexia. He has a history of alcohol use but no diabetes or hypertension.What is the most appropriate treatment? (Q851497)

A. Intravenous immunoglobulin

B. Corticosteroids

C. Thiamine with dextrose

D. Dextrose

See Answer in Part B → Q6

@Neet_pg_bot

Q7: A 20-year-old female presents with acute dysphagia, particularly for liquids, and nasal regurgitation, following a recent dengue fever. Examination reveals bilateral facial weakness and areflexia in the upper limbs. Brain and cervical spine MRI is normal, while cerebrospinal fluid analysis shows elevated protein with normal opening pressure, cells and glucose. What is the most likely diagnosis? (Q851498)

A. Acute pharyngeal cervicobrachial neuropathy

B. Miller-Fisher syndrome

C. Multiple sclerosis

D. Botulism

See Answer in Part B → Q7

@Neet_pg_bot

Q8: A 75-year-old man presents with progressive memory loss, difficulty in performing daily activities, and mood changes. His family notes that he often repeats the same questions and becomes easily confused. Neurological examination reveals no focal deficits, but cognitive testing indicates significant impairment in memory and language skills. What is the possible neurotransmitter status for this condition? (Q851499)

A. Increased Acetylcholine, decreased Norepinephrine, decreased Serotonin

B. Decreased Acetylcholine, decreased Norepinephrine, decreased Serotonin

C. Normal Acetylcholine, increased Norepinephrine, normal Serotonin

D. Increased Acetylcholine, increased Norepinephrine, decreased Serotonin

See Answer in Part B → Q8

@Neet_pg_bot

Q9: A 30-year-old man with Down syndrome is being monitored for cognitive decline due to his increased risk for Alzheimer's disease. Why is this patient at a higher risk for developing Alzheimer's disease? (Q851500)

A. Presenilin 1 gene mutation

B. Overexpression of the APP gene

C. Mutation in the ApoE4 gene

D. Release of pro-inflammatory cytokines and promoting insulin resistance

See Answer in Part B → Q9

@Neet_pg_bot

Q10: Which of the following neurodegenerative disorders is not classified as a tauopathy? (Q851501)

A. Alzheimer’s disease

B. Punch-drunk syndrome

C. Parkinson’s disease

D. Pick's disease

See Answer in Part B → Q10

@Neet_pg_bot

Q11: A 60-year-old woman has been diagnosed with early-stage Alzheimer's disease. Her husband reports that she frequently struggles to remember recent events and has begun to repeat herself in conversations. Additionally, she has difficulty managing her finances and has gotten lost while driving to familiar places. Despite these issues, she insists that she is “just fine” and is not concerned about her memory. Which term best describes the unawareness of her cognitive decline? (Q851502)

A. Subjective cognitive decline

B. Anosognosia

C. Apraxia

D. Confabulation

See Answer in Part B → Q11

@Neet_pg_bot

Q12: A 74-year-old woman is brought to a memory clinic by her daughter, who reports increasing forgetfulness over the past year. The daughter notes that her mother often misplaces items, struggles to find the right words during conversations,

and repeats questions she has just asked. Recently, she became lost while driving to her regular grocery store, which she has frequented for years. On examination, she has difficulty following a conversation, and signs of apraxia are present. There are no significant findings on routine laboratory tests, and an FDG-PET is ordered. Which finding in FDG-PET is most consistent with the diagnosis of this patient's condition? (Q851503)

A. Hypometabolism in the posterior temporal-parietal cortex

B. Cerebral atrophy

C. Widened third ventricle

D. Detection of amyloid depositions

See Answer in Part B → Q12

@Neet_pg_bot

Q13: A 75-year-old woman with moderate Alzheimer's disease has been on Donepezil for the past year. On routine follow-up, her cognitive abilities are declining further, and the physician decides to add another medication. Which treatment would be most appropriate to consider at this stage? (Q851504)

A. Rivastigmine

B. Memantine

C. Lecanemab

D. Galantamine

See Answer in Part B → Q13

@Neet_pg_bot

Q14: Which of the following is NOT part of the clinical triad of Normal Pressure Hydrocephalus (NPH)? (Q851508)

A. Ataxia

B. Urinary incontinence

C. Dementia

D. Visual disturbances

See Answer in Part B → Q14

@Neet_pg_bot

• [07_Neurology] 052 Syringomelia Conus Medullaris Channelopathies And Sah

« Back to Folder Directory

[07_Neurology] 052 Syringomelia Conus Medullaris Channelopathies And Sah — Quick Jump

Q1 (p. 626)	*Q2 (p. 626)*	*Q3 (p. 627)*	*Q4 (p. 627)*	*Q5 (p. 628)*	*Q6 (p. 629)*
Q7 (p. 629)	*Q8 (p. 629)*	*Q9 (p. 630)*	*Q10 (p. 630)*	*Q11 (p. 631)*	*Q12 (p. 631)*
Q13 (p. 631)	*Q14 (p. 632)*	*Q15 (p. 632)*	*Q16 (p. 633)*	*Q17 (p. 633)*	*Q18 (p. 633)*
Q19 (p. 634)	*Q20 (p. 634)*	*Q21 (p. 635)*			

Q1: Which of the following is used to prevent delayed cererbral ischemia in aneurysmal bleeding? (Q851241)

A. Nifedipine

B. Amlodipine

C. Nimodipine

D. Felodipine

See Answer in Part B → Q1

@Neet_pg_bot

Q2: A 45-year-old male presents with poorly localized burning pain in the lower torso and legs. Then he noticed progressive weakness in both arms and legs over the past 3 months. On neurological examination, there is spasticity and hyperreflexia in both upper and lower limbs, with preserved perianal sensation. Which of the following is the most likely site of pathology? (Q851651)

A. Extradural compression

B. Intradural compression

C. Foramen magnum syndrome

D. Intramedullary compression

See Answer in Part B → Q2

@Neet_pg_bot

Q3: A patient presented with complaints of radicular pain on the lower back associated with loss of sensations over sacrum and urinary incontinence. There was weakness, started over lower limbs one month back and now weakness is present over upper limbs. What is the ideal imaging of choice to diagnose this condition? (Q851650)

A. CECT

B. MRI

C. CT angiography

D. X-ray LS spine AP and lateral view

See Answer in Part B → Q3

@Neet_pg_bot

Q4: Which among the following is seen in this spinal cord lesion as shown below? (Q851253)

A. C/L loss of vibration sense below the level of lesion

B. C/L loss of thermal sensation at and above the same level

C. I/L loss of muscle tone at the level of lesion

D. C/L loss of pain 2 segments above the level of lesion

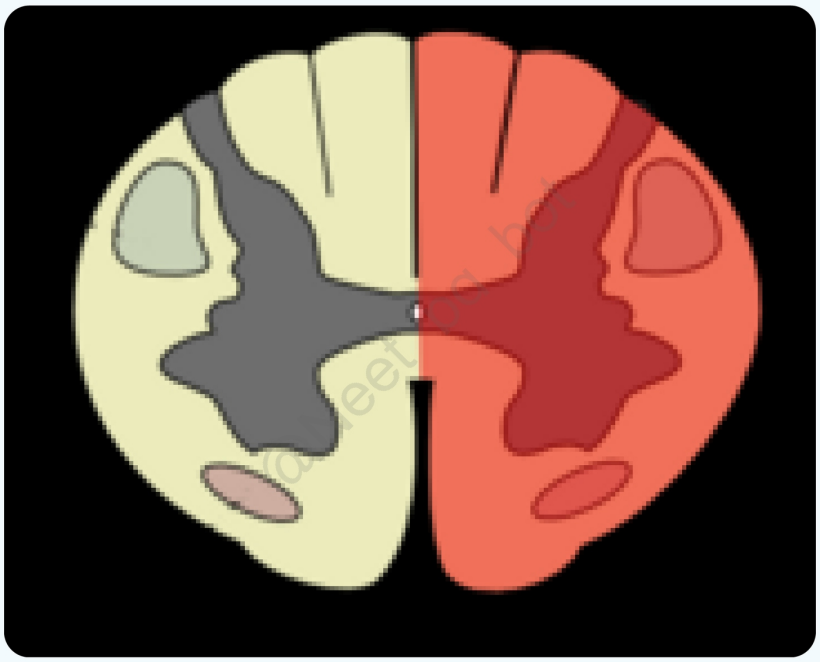

See Answer in Part B → Q4

@Neet_pg_bot

Q5: A 30 year old female presents with complaints of progressive weakness of lower limbs, numbness, difficulty walking and recent onset forgetfulness. On examination, bilateral loss of vibration sense is noted, bilateral ankle jerks are absent with bilateral babinski sign. Romberg sign is present with eyes closed. Peripheral blood smear done was normal. What is the most likely diagnosis? (Q851252)

A. Subacute combined demyelination of Spinal cord

B. Tabes dorsalis

C. Friedrich ataxia

D. Brown sequard syndrome

See Answer in Part B → Q5

@Neet_pg_bot

Q6: A 32-year-old woman presents with sudden symmetrical onset of both lower extremity weakness, numbness, and urinary retention. She reports a history of a respiratory tract infection two weeks ago. Neurological examination reveals reduced muscle strength and sensory loss below the mid-thoracic region, along with hyperreflexia. MRI of the spine shows a focal area of increased T2 signal in the thoracic spinal cord without evidence of compression. What is the most likely diagnosis? (Q851251)

A. Multiple sclerosis

B. Guillain-Barré syndrome

C. Transverse myelitis

D. Amyotrophic lateral sclerosis

See Answer in Part B → Q6

@Neet_pg_bot

Q7: A 55-year-old man presents with multiple episodes of involuntary urine passage in clothes, lower back pain and bilateral lower limb weakness. On examination, he has saddle anesthesia, intact knee jerks and absent ankle jerks. What is the most likely diagnosis? (Q851250)

A. Conus medullaris syndrome

B. Cauda Equina Syndrome

C. Transverse myelitis

D. Spinal shock

See Answer in Part B → Q7

@Neet_pg_bot

Q8: Which of the following findings is least likely to be seen in cauda equina syndrome? (Q851249)

A. Back pain

B. Saddle anesthesia

C. Brisk bulbocavernosus reflex

D. Impotence

See Answer in Part B → Q8

@Neet_pg_bot

Q9: Which of the following statements is wrong about conus medullaris syndrome? (Q851248)

A. Loss of anal reflex

B. Urinary incontinence

C. Bilateral saddle anesthesia

D. Priapism

See Answer in Part B → Q9

@Neet_pg_bot

Q10: A 45-year-old woman presents with progressive weakness and sensory loss in her arms, along with muscle wasting in her hands. MRI reveals a large intramedullary spinal cord tumor, with an associated syrinx. What is the management? (Q851247)

A. Tumor resection

B. Radiation therapy

C. Chemotherapy

D. Decompression

See Answer in Part B → Q10

@Neet_pg_bot

Q11: Which of the following statements about syringomyelia is wrong? (Q851246)

A. A developmental cavity in the cervical cord

B. Symptoms begin in adolescence or early adulthood

C. The majority linked with Chiari type 2 malformation

D. Sensory loss in a cape distribution

See Answer in Part B → Q11

@Neet_pg_bot

Q12: Which gene mutation is primarily associated with hyperkalemic periodic paralysis? (Q851231)

A. KCNJ2

B. CACNA1S

C. SCN4A

D. RYR1

See Answer in Part B → Q12

@Neet_pg_bot

Q13: A 52-year-old woman presents with a sudden, severe "thunderclap" headache followed by brief loss of consciousness. NCCT head reveals blood in the basal cisterns. CT angiography shows a ruptured anterior communicating artery aneurysm. She is alert and oriented (Hunt and Hess grade II). BP on admission is 160/100 mm Hg. Which of the following is the most appropriate definitive treatment to prevent rebleeding in this patient? (Q851240)

A. Administration of nimodipine to prevent vasospasm

B. Strict blood pressure control with IV labetalol

C. Surgical clipping of the aneurysm

D. Endovascular coiling of the aneurysm

See Answer in Part B → Q13

@Neet_pg_bot

Q14: A 45-year-old patient presents to the ER with a sudden headache described as the "worst headache of their life." A non-contrast head CT is normal. Despite this, the suspicion of subarachnoid hemorrhage remains high. What is the most appropriate next step in the evaluation of this patient? (Q851239)

A. Repeat the head CT scan in 24 hours

B. Lumbar puncture to assess for xanthochromia

C. Immediate cerebral angiography

D. Perform a Time-of-Flight Magnetic Resonance Angiography (TOF-MRA)

See Answer in Part B → Q14

@Neet_pg_bot

Q15: A 26-year-old woman is brought to the emergency department with sudden-onset severe headache. On admission, her GCS is 12/15 and non-contrast CT head shows blood in the Sylvian fissure. On day 4 of hospitalization, she becomes increasingly drowsy and develops slow speech. Repeat CT reveals no new hemorrhage or infarct. She has polyuria, and her serum sodium is 125 mEq/L. On examination, she appears dehydrated. What is the most likely cause of her clinical deterioration? (Q851238)

A. Rebleeding from the aneurysm

B. Spasm of feeder vessel

C. Delayed cerebral ischemia

D. Cerebral salt-wasting syndrome

See Answer in Part B → Q15

@Neet_pg_bot

Q16: A 45-year-old woman presents with a sudden onset severe headache for past 6 hours and nuchal rigidity. CTA shows berry aneurysm at posterior communicating artery. Which of the following clinical features is most likely associated with this scenario? (Q851237)

A. 6th cranial nerve palsy

B. Visual field defects

C. 3rd cranial nerve palsy

D. Occipital pain

See Answer in Part B → Q16

@Neet_pg_bot

Q17: A 25-year-old female presents to the ER with a sudden onset of severe headache with prostration. On examination, BP 180/100 mm Hg and nuchal rigidity is noted. The NCCT head shows blood in the Sylvian fissure. Which is the next best step in the management of this patient? (Q851236)

A. Lowering of BP

B. Cerebral angiography

C. Nimodipine

D. Mannitol

See Answer in Part B → Q17

@Neet_pg_bot

Q18: Which of the following is correct about Anderson Tawil syndrome? (Q851235)

A. Sodium channelopathy affecting the cardiac conduction system

B. Potassium channelopathy affecting skeletal muscle and cardiac conduction

C. Calcium channelopathy affecting cardiac muscle

D. Abnormal chloride transport in skeletal and cardiac muscle

See Answer in Part B → Q18

@Neet_pg_bot

Q19: A 19-year-old male presents to the emergency department with a sudden onset of generalized muscle weakness, particularly in his legs, after a day of strenuous exercise followed by a high-carbohydrate meal. He reports experiencing similar episodes of muscle weakness in the past, often triggered by exercise or large meals. What is the most appropriate first-line treatment for this patient's acute presentation? (Q851234)

A. Oral potassium supplementation

B. Intravenous potassium

C. Acetazolamide

D. Beta-blockers

See Answer in Part B → Q19

@Neet_pg_bot

Q20: An 18-year-old male presents to the emergency department with a sudden onset of severe muscle weakness, primarily in his legs, which started a few hours after consuming a large, carbohydrate-heavy meal following exercise. He reports similar episodes in the past, often triggered by large meals or after rest following physical activity. His vital signs are stable, and he has no respiratory involvement. Blood work reveals a serum potassium level of 2.3 mEq/L. What is the most likely underlying mechanism for this patient's condition? (Q851233)

A. Sodium channel dysfunction causing an inability to generate action potentials

B. Potassium channel dysfunction leading to excessive potassium loss

C. Calcium or sodium channel mutations causing abnormal potassium influx into cells

D. Excessive release of acetylcholine at the neuromuscular junction

See Answer in Part B → Q20

@Neet_pg_bot

Q21: A 23-year-old male presents to the clinic with complaints of muscle stiffness, especially in his face and hands, following exposure to cold weather. He reports that his symptoms worsen with repeated movements and improve with rest. Upon examination, his muscles are stiff but not weak. His symptoms do not improve with warming. What is the most likely diagnosis? (Q851232)

A. Myotonic Dystrophy

B. Paramyotonia Congenita

C. Hypokalemic Periodic Paralysis

D. Becker Muscular Dystrophy

See Answer in Part B → Q21

@Neet_pg_bot

• [07_Neurology] 053 Myasthenia Gravis

« Back to Folder Directory

[07_Neurology] 053 Myasthenia Gravis — Quick Jump

Q1 (p. 636) *Q2 (p. 636)* *Q3 (p. 637)* *Q4 (p. 637)* *Q5 (p. 638)* *Q6 (p. 638)*
Q7 (p. 638) *Q8 (p. 639)* *Q9 (p. 639)* *Q10 (p. 640)*

Q1: A 45-year-old woman presents with fluctuating muscle weakness that worsens with repetitive activity and improves with rest. She also reports more pronounced symptoms in the evening. Neurological examination shows normal deep tendon reflexes. Workup reveals positive anti-MuSK antibodies and negative anti-acetylcholine receptor (AChR) antibodies. Which of the following best describes the underlying mechanism of her condition? (Q851549)

A. T-cell mediated destruction of anterior horn cells

B. Autoantibodies disrupt clustering of acetylcholine receptors

C. Disruption of post synaptic voltage-gated calcium channels

D. Inhibition of acetylcholine release from synaptic vesicles

See Answer in Part B → Q1

@Neet_pg_bot

Q2: A 35-year-old woman presents with fluctuating muscle weakness, especially affecting her speech and swallowing. Repetitive nerve stimulation shows a decremental response. Her blood tests are negative for acetylcholine receptor (AChR) antibodies. Which of the following antibodies is most likely responsible for her symptoms? (Q851550)

A. Anti-dsDNA antibodies

B. Anti-MuSK antibodies

C. Anti-TPO antibodies

D. Anti-Ro antibodies

See Answer in Part B → Q2

@Neet_pg_bot

Q3: A 20-year-old woman who is known case of myasthenia gravis presents to the clinic with worsening symptoms, including difficulty in lifting her arms and shortness of breath. On examination, you notice that her eyelids are drooping, and she has double vision. What is the most significant risk associated with her current condition if not addressed promptly? (Q851551)

A. Impaired vision

B. Aspiration due to swallowing difficulties

C. Respiratory failure

D. Muscle atrophy

See Answer in Part B → Q3

@Neet_pg_bot

Q4: A 28-year-old woman presents to the ER with acute muscle weakness, double vision, and difficulty swallowing. He has a history of myasthenia gravis and has been experiencing increased fatigue over the past few days. Which of the following clinical features would best help differentiate a myasthenic crisis from a cholinergic crisis? (Q851552)

A. Muscle fasciculations

B. Small pupils

C. Response to edrophonium

D. Pallor and sweating

See Answer in Part B → Q4

@Neet_pg_bot

Q5: A 40-year-old female presents with symptoms of fluctuating double vision and drooping eyelids that worsen through the day. On neuro-examination DTRs are normal and power of all muscle groups except ocular muscles is normal. Blood tests confirms the presence of Anti-MuSK antibody. What is the most appropriate management strategy for this patient? (Q851553)

A. Initiate high-dose corticosteroids as the first-line treatment

B. Recommend immediate thymectomy regardless of symptom severity

C. Start anticholinesterase medications and consider immunosuppressants if symptoms persist

D. Advise the patient to undergo regular monitoring without any treatment

See Answer in Part B → Q5

@Neet_pg_bot

Q6: A 45-year-old woman presents with fluctuating muscle weakness, particularly affecting her eyelids and causing double vision. She also has difficulty in swallowing and develops dysarthria after speaking continously for few minutes. Which of the following diagnostic tests would confirm the suspicion of Myasthenia Gravis? (Q851554)

A. Single Fiber EMG showing increased Jitter

B. Nerve conduction velocity showing slowed conduction of impulses

C. Ice pack test

D. Tensilon test

See Answer in Part B → Q6

@Neet_pg_bot

Q7: A 28-year-old woman presents with diplopia that develops daily in evening hours along with difficulty in swallowing. On examination left eye ptosis is noted. Ice pack test shows improvement in ptosis. Repetitive nerve stimulation shows a decremental

response. The report of antibody panel is awaited. Which of the following will not be useful in management of this patient? (Q851556)

A. Physostigmine

B. Plasma Exchange

C. Pyridostigmine

D. Intravenous immunoglobulin

See Answer in Part B → Q7

@Neet_pg_bot

Q8: A 45-year-old man known case of myasthenia gravis presents to the emergency department with severe muscle weakness and respiratory distress. On examination he is using accessory muscles of respiration, spO2 on room air is 85% and he cannot speak full sentences. ABG shows pH: 7.2, pC02 50 mm Hg and HCO3= 27 meq/L. Which of the following treatments is most appropriate for immediate management of this patient's condition? (Q851557)

A. IVIg

B. Endotracheal intubation and IVIg

C. High flow nasal cannula and IVIg

D. Plasma exchange (PLEX)

See Answer in Part B → Q8

@Neet_pg_bot

Q9: A 60-year-old man presents with progressive muscle weakness, dry mouth, and absent tendon reflexes. He has a history of smoking. Electrophysiological testing reveals post-tetanic potentiation of motor response to nerve stimulation at a frequency of 20–50/sec. Which of the following treatments is most appropriate for this patient? (Q851558)

A. Corticosteroids

B. 3,4-Diaminopyridine

C. Azathioprine

D. Intravenous immunoglobulin (IVIg)

See Answer in Part B → Q9

@Neet_pg_bot

Q10: A 50-year-old woman presents with arm weakness, diplopia, and ptosis. Strength improves with repeated activity, and deep tendon reflexes are absent. Repetitive nerve stimulation shows a decremental response at low frequency. Which of the following best explains the underlying defect? (Q851560)

A. Pre junctional defect affecting P/Q voltage gated calcium channels

B. Leading cause is thymic hyperplasia

C. Antibodies Target clustering of Ach receptors

D. Increased effficiency of neuromuscular transmission

See Answer in Part B → Q10

@Neet_pg_bot

• [07_Neurology] 054 Multiple Sclerosis Neuromyelitis Optica Spectrum Disorder And Als

« Back to Folder Directory

[07_Neurology] 054 Multiple Sclerosis Neuromyelitis Optica Spectrum Disorder And Als — Quick Jump

Q1 (p. 641)	*Q2 (p. 641)*	*Q3 (p. 642)*	*Q4 (p. 642)*	*Q5 (p. 642)*	*Q6 (p. 643)*
Q7 (p. 643)	*Q8 (p. 644)*	*Q9 (p. 644)*	*Q10 (p. 644)*	*Q11 (p. 645)*	*Q12 (p. 645)*
Q13 (p. 645)	*Q14 (p. 646)*	*Q15 (p. 646)*	*Q16 (p. 647)*	*Q17 (p. 648)*	*Q18 (p. 648)*
Q19 (p. 648)	*Q20 (p. 649)*				

Q1: Which of the following is not correct about neuromyelitis optica spectrum disorder? (Q851527)

A. Eye pain with eye movement

B. Longitudinally extensive transverse myelitis

C. Unilateral thinning of optic nerve

D. Afferent pupillary defect

See Answer in Part B → Q1

@Neet_pg_bot

Q2: A 45-year-old man presents with asymmetric muscle weakness in the arms and legs. Nerve conduction studies reveal focal demyelination with conduction block. Anti GM1 antibody is present. Which of the following conditions is most likely indicated by these findings? (Q851540)

A. Amyotrophic Lateral Sclerosis

B. Multifocal Motor Neuropathy with Conduction Block

C. Acute inflammatory demyelinating polyneuropathy

D. Charcot-Marie-Tooth Disease

See Answer in Part B → Q2

@Neet_pg_bot

Q3: Which of the following is not correct about Spinal muscular atrophy? (Q851539)

A. Cognitive milestones are delayed

B. Tongue fasiculations

C. Risdiplam increases the production of SMN protein

D. Respiratory infections

See Answer in Part B → Q3

@Neet_pg_bot

Q4: A 55-year-old woman with Amyotrophic Lateral Sclerosis is experiencing significant difficulty swallowing . CXR shows evidence of bronchiectasis, Which treatment option is most appropriate for potentially extending survival? (Q851537)

A. Riluzole

B. Monthly broad spectrum antibiotics with N-acetlycystiene

C. Percutaneous Gastrostomy (PEG)

D. Tofersen

See Answer in Part B → Q4

@Neet_pg_bot

Q5: A 62-year-old man presents with left hand grip weakness for past one week with difficulty swallowing. On examination tongue fasiculations are present, depressed gag reflex with right leg showing spasticity with brisk knee and ankle jerks. His daughter tells that their grandfather also died due to some neurological illness. Which of the following tests will be least contributory for diagnosis of this patient? (Q851536)

A. Electromyography

B. Genetic testing

C. Spinal fluid analysis

D. Nerve conduction studies

See Answer in Part B → Q5

@Neet_pg_bot

Q6: Which of the following signs or symptoms is not associated with Amyotrophic Lateral Sclerosis (ALS) ? (Q851535)

A. Fasciculations

B. Hoffman sign

C. Sensory loss

D. Muscle wasting

See Answer in Part B → Q6

@Neet_pg_bot

Q7: A 55-year-old man presents with progressive weakness in his limbs, accompanied by muscle wasting and dysarthria. Neurological examination reveals both upper and lower motor neuron signs. Based on the clinical features, which of the following conditions is the most likely diagnosis? (Q851533)

A. Progressive Muscular Atrophy

B. Progressive Lateral Sclerosis

C. Amyotrophic Lateral Sclerosis

D. Progressive Bulbar Palsy

See Answer in Part B → Q7

@Neet_pg_bot

Q8: Which of the following is not correct about Amyotrophic lateral sclerosis? (Q851532)

A. Bunina bodies

B. SOD1 gene mutations

C. Extraocular muscle weakness

D. Can coexist with Frontotemporal dementia

See Answer in Part B → Q8

@Neet_pg_bot

Q9: Which of the following treatments will be used to manage acute attack of NMOSD? (Q851530)

A. Azathioprine

B. Plasmapheresis

C. Cyclophosphamide

D. Monoclonal antibodies

See Answer in Part B → Q9

@Neet_pg_bot

Q10: A 30-year-old female experiences bilateral vision loss and lower limb weakness. MRI of the spinal cord shows lesions spanning more than three vertebral segments. What is the most specific test for diagnosis? (Q851528)

A. Oligoclonal bands in CSF

B. AQP4-IgG antibody testing

C. Evoked potential studies

D. Brain MRI findings

See Answer in Part B → Q10

@Neet_pg_bot

Q11: A 28-year-old woman presents with subacute onset of blurry vision in one eye and painful eye movements. She reports tingling in both legs and occasional urinary urgency over the past few months. MRI brain shows periventricular white matter lesions perpendicular to the lateral ventricles. CSF shows oligoclonal bands. What is the most likely diagnosis? (Q851513)

A. Neuromyelitis optica

B. Acute disseminated encephalomyelitis

C. Multiple sclerosis

D. Neurosarcoidosis

See Answer in Part B → Q11

@Neet_pg_bot

Q12: 30-year-old is diagnosed as case of Neuromyelitis optica. Which of the following cells of brain is damaged in this condition? (Q851525)

A. Neurons

B. Astrocytes

C. Oligodendrocytes

D. Microglia

See Answer in Part B → Q12

@Neet_pg_bot

Q13: 40 year old woman is diagnosed with autoimmune demyelinating astrocytopathy. Which of the following areas of brain are targetted by AQP4 antibodies seen in this condition? (Q851524)

A. Area postrema

B. Spinal cord

C. Circumventricular areas

D. All of the above

See Answer in Part B → Q13

@Neet_pg_bot

Q14: A 38-year-old African woman presents with four months of progressive bilateral visual loss and temporal headaches. Neurological examination reveals spastic paraplegia and brisk knee jerks and ankle jerks. Work up shows Anti- aquaporin-4 antibodies. Which of the following is not seen in this condition ? (Q851523)

A. Crossed hemiplegia

B. Diencephalic syndrome

C. Cloud like tumefactive lesions on MRI head

D. Intracranial hypertension

See Answer in Part B → Q14

@Neet_pg_bot

Q15: A 36-year-old caucasian woman on medical tourism visit presents with a history of recent onset left lower limb weakness, gait unsteadiness, and paresthesias. She experiences an electric shock sensation that radiates down her spine when flexing her neck. An MRI of the brain is given below. What is the most appropriate treatment for this patient's condition? (Q851522)

A. High-dose IV corticosteroids

B. Oral dimethyl fumarate

C. Ocrelizumab

D. Baclofen

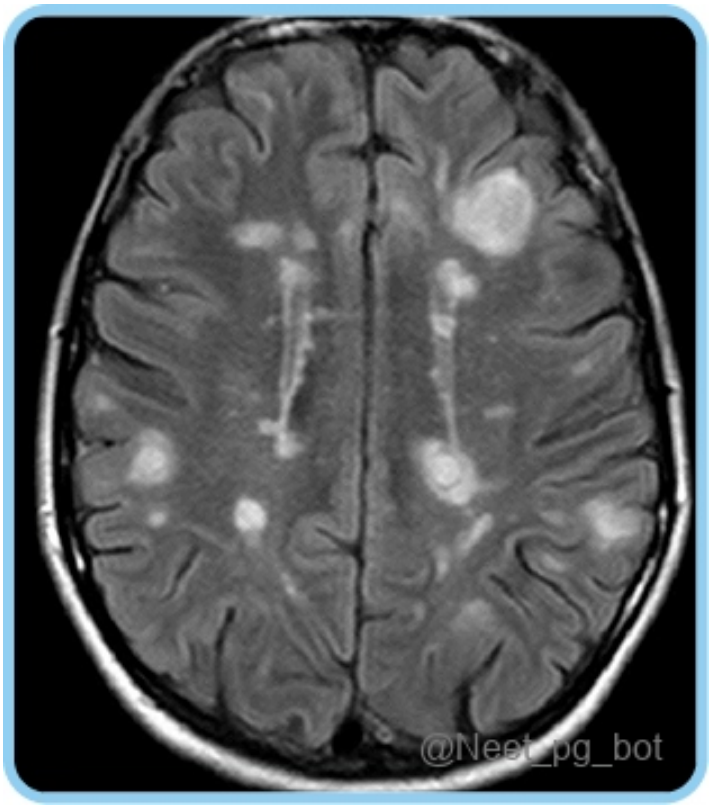

See Answer in Part B → Q15

@Neet_pg_bot

Q16: A 30-year-old woman presents with a 2-day history of acute, painful vision loss in her left eye, associated with a dull ache that worsens with eye movement. She also reports episodes of leg weakness, difficulty maintaining balance, and tingling sensations in her arms. Her medical history includes recurrent episodes of blurred vision and fatigue, particularly worsening in warm conditions. What is the diagnostic test of choice for this condition? (Q851521)

A. Visual evoked potential

B. Lumbar puncture

C. MRI of the brain and spinal cord

D. CSF electrophoresis for oligoclonal bands

See Answer in Part B → Q16

@Neet_pg_bot

Q17: What additional Mcdonald criteria are required for a diagnosis of Multiple Sclerosis in patient with 2 or more attacks and clinical evidence of 2 or more lesions? (Q851520)

A. None, dissemination in space and in time are met

B. Presence of enhancing and non-enhancing lesions on MRI

C. Presence of CSF oligoclonal bands

D. New T2 or enhancing MRI lesion compared to baseline

See Answer in Part B → Q17

@Neet_pg_bot

Q18: Which of the following statements regarding one and a half syndrome in multiple sclerosis is not true? (Q851518)

A. It is characterized by ipsilateral horizontal gaze palsy

B. Limited adduction of the ipsilateral eye

C. The contralateral eye exhibits exotropia and abduction nystagmus.

D. Vertical gaze and convergence are impaired in this syndrome.

See Answer in Part B → Q18

@Neet_pg_bot

Q19: A 45-year-old woman who is a known case of multiple sclerosis has come for follow up consultation. On examination, the left eye has slowed adduction when

attempting to look to the right, and there is horizontal nystagmus in the right eye when it is abducting. Which of the following best explains the underlying pathology of this patient's symptoms? (Q851516)

A. Lesion in the right sixth cranial nerve

B. Lesion in the left sixth cranial nerve

C. Lesion in the left medial longitudinal fasciculus

D. Lesion in the right medial longitudinal fasciculus



See Answer in Part B → Q19

@Neet_pg_bot

Q20: A 34-year-old woman with a known diagnosis of multiple sclerosis visited a sauna in her gym. After the visit her vision becomes blurry and her leg weakness worsened that she had to be assisted by gym staff to her house. This presentation is called? (Q851515)

A. Lhermitte's symptoms

B. Uthoff's symptoms

C. Ancillary symptoms

D. Internuclear oopthalmoplegia

See Answer in Part B → Q20

@Neet_pg_bot

• [07_Neurology] 055 Cns Hemorrhage Headaches And Migraine

« Back to Folder Directory

[07_Neurology] 055 Cns Hemorrhage Headaches And Migraine — Quick Jump

Q1 (p. 650)	*Q2 (p. 650)*	*Q3 (p. 651)*	*Q4 (p. 651)*	*Q5 (p. 652)*	*Q6 (p. 652)*
Q7 (p. 652)	*Q8 (p. 653)*	*Q9 (p. 653)*	*Q10 (p. 654)*	*Q11 (p. 654)*	*Q12 (p. 655)*
Q13 (p. 655)	*Q14 (p. 655)*	*Q15 (p. 656)*	*Q16 (p. 657)*	*Q17 (p. 658)*	*Q18 (p. 658)*
Q19 (p. 659)	*Q20 (p. 660)*	*Q21 (p. 660)*			

Q1: A 40-year-old woman reports experiencing recurrent headaches that last between 6 and 48 hours. She often feels fatigued and has mood changes before the headaches begin. According to the International Headache Society's criteria, which features are essential for diagnosing her condition as migraine? (Q851065)

A. Bilateral pricking pain with nausea

B. Unilateral pain with photophobia without nausea

C. Unilateral throbbing pain with phonophobia

D. Bilateral pain with photophobia and nausea

See Answer in Part B → Q1

@Neet_pg_bot

Q2: A 35-year-old woman presents with a 9-month history of frequent headaches occurring at least 3 times per week. She describes the pain as a dull, bilateral ache that feels like a tight band around her head. The headaches are often accompanied by neck tension, stress, and fatigue. Which of the following is the most appropriate first-line treatment for this patient's condition? (Q851075)

A. Amitriptyline, starting at 20 mg daily, with gradual increases as needed.

B. Combination of Ibuprofen 400 mg plus acetaminophen 1000 mg.

C. Aspirin and Botulinum toxin type A injections

D. Combination of massage therapy and acupuncture

See Answer in Part B → Q2

@Neet_pg_bot

Q3: A 58-year-old man presents with recurrent, sharp, electric shock-like pain on the right side of her face, affecting her jaw and cheek. The pain is triggered by light touch, such as brushing her teeth or shaving. She reports these episodes happening multiple times a day and lasting only a few seconds. Which of the following statements is TRUE regarding her condition? (Q851074)

A. The most likely diagnosis is glossopharyngeal neuralgia, as the pain is localized to the jaw and oral cavity and is triggered by chewing.

B. Most commonly caused by vascular compression of the trigeminal nerve, often by the superior cerebellar artery.

C. The primary treatment is surgical decompression of the glossopharyngeal nerve.

D. This patient's condition is most likely to involve the ophthalmic branch (V1) of the trigeminal nerve.

See Answer in Part B → Q3

@Neet_pg_bot

Q4: Match the following: 1. Naratriptan a) 5-HT1F Agonist 2. Lasmiditan b) Dopamine Receptor Antagonist 3. Rimegepant c) 5-HT1B/1D Agonist 4. Prochlorperazine d) CGRP Receptor Antagonist (Q851073)

A. 1-d, 2-c, 3-b, 4-a

B. 1-a, 2-c, 3-b, 4-d

C. 1-c, 2-a, 3-d, 4-b

D. 1-b, 2-d, 3-c, 4-a

See Answer in Part B → Q4

@Neet_pg_bot

Q5: A patient with left-sided facial paralysis and arm weakness for the last eight hours. BP on admission is 160/100 mm Hg. Her CT head is normal. What is the next step in the management of this patient? (Q851072)

A. Monitor Blood pressure and neurology consult

B. IV labetalol

C. IV thrombolysis

D. Nimodipine

See Answer in Part B → Q5

@Neet_pg_bot

Q6: A 45-year-old male presents with a history of recurrent headaches. After a thorough evaluation, he is diagnosed with a headache that has a stinging character and characterized by the following features: Duration: 5-240 seconds Attacks: 3-200 attacks per day. Which of the following treatments is most appropriate for this condition? (Q851071)

A. High-flow oxygen

B. Sumatriptan

C. IV Lidocaine

D. Verapamil

See Answer in Part B → Q6

@Neet_pg_bot

Q7: A 70-year-old female presents with a 3-month history of new-onset headaches, scalp tenderness, and jaw claudication. She also reports significant fatigue and unintentional weight loss. Laboratory studies reveal an elevated erythrocyte sedimentation rate (ESR) and C-reactive protein (CRP). What is the most appropriate next step in the management of this patient? (Q851070)

A. Start high-dose corticosteroids

B. Perform temporal artery biopsy

C. Initiate aspirin therapy

D. Refer for imaging studies of the carotid arteries

See Answer in Part B → Q7

@Neet_pg_bot

Q8: Match the variants of Migraine in Column A with their characteristic clinical features in Column B: Column A Column B 1. Ophthalmoplegic Migraine A. Associated with blindness and scintillating scotomas 2. Cluster Headaches B. Retro-orbital pain in males 3. Retinal Migraine C. Associated with occulomotor palsy 4. Familial Hemiplegic Migraine D. Presents with hemiplegia and can be confused with stroke E. Diagnosis often involves neuroimaging to rule out cerebrovascular accidents (Q851069)

A. 1-C, 2-E, 3-A, 4-B

B. 1-C, 2-B, 3-A, 4-D

C. 1-B, 2-E, 3-C, 4-D

D. 1-B, 2-E, 3-A, 4-B

See Answer in Part B → Q8

@Neet_pg_bot

Q9: A 35-year-old man with a history of chronic migraines visits his physician to discuss treatment options. He is interested in triptans but has some health concerns that he wants to clarify. Which of the following is NOT a contraindication for triptans based on the provided information? (Q851068)

A. History of coronary artery disease

B. History of seasonal allergies

C. Wolff-Parkinson-White syndrome

D. Concurrent use with MAO inhibitors

See Answer in Part B → Q9

@Neet_pg_bot

Q10: A 28-year-old woman completes the MIDAS questionnaire during her follow-up for chronic migraines. Her headaches have significantly impacted her work and social life. What is the primary purpose of the MIDAS assessment? (Q851067)

A. To determine the specific medication needed for treatment.

B. To assess the frequency of headache attacks.

C. To evaluate headache-related disability and its impact on daily activities.

D. To classify the type of headache.

See Answer in Part B → Q10

@Neet_pg_bot

Q11: A 35-year-old obese NRI woman presents to her doctor with a history of frequent migraines. She reports experiencing about ten migraine attacks per month. Her father is a diabetic and underwent CABG recently. She says due to ill health of her father her symptoms tend to last upto 24 hours. Her recent lipid profile is deranged. Which of the following preventive treatments is most appropriate for this patient? (Q851066)

A. Rizatriptan

B. Fremanezumab

C. Propranolol

D. Rimegepant

See Answer in Part B → Q11

@Neet_pg_bot

Q12: A 17-year-old boy is brought to the ER after collapsing at a rave party. His friends report that he had been dancing intensely and suddenly developed a severe headache followed by a generalized tonic-clonic seizure. On arrival, he is unconscious with a BP of 180/100 mmHg. NCCT brain shows an hyperdensity in the basal ganglia region. Urine toxicology screen is positive for benzoylecgonine. Which of the following is the most likely cause of his presentation? (Q851054)

A. Acute hypertensive crisis due to pheochromocytoma

B. Intracranial aneurysm rupture

C. Cocaine-induced vasospasm and hypertension

D. Amphetamine-induced serotonin syndrome

See Answer in Part B → Q12

@Neet_pg_bot

Q13: Which of the following types of headaches is not classified as a primary headache? (Q851064)

A. Tension-type headache

B. Medication overuse headache

C. Migraine

D. Cluster headache

See Answer in Part B → Q13

@Neet_pg_bot

Q14: A newborn delivered by forceps has a high-pitched cry and bulging anterior fontanelle. The mother notes that the baby seems unusually irritable. Which of the following is the most appropriate initial diagnostic step and management? (Q851063)

A. CT head and surgical evacuation

B. USG skull and phenobarbitone

C. USG skull with phenytoin

D. X-ray skull and lamotrigine

See Answer in Part B → Q14

@Neet_pg_bot

Q15: A 75-year-old man with atrial fibrillation on warfarin presents with progressive confusion and unsteady gait over the past month. His wife reports he had a minor fall 6 weeks ago. On examination, he is confused, has mild right sided weakness. NCCT brain is given below. Which of the following is correct about this patient? (Q851062)

A. Arterial bleeding with craniotomy

B. Arterial bleeding with craniotomy and ligation of bleeder

C. Venous bleeding with craniotomy

D. Venous bleeding with burr hole surgery



See Answer in Part B → Q15

@Neet_pg_bot

Q16: A 25-year-old man presents to the emergency department after being struck in the temporal region during a hockey game. Initially conscious at the scene, he now presents with decreasing consciousness, right-sided pupillary dilation, and left hemiparesis. CT head shows a lentiform hyperdense lesion in the right temporal region with 12mm midline shift. Which of the following is most appropriate treatment of this patient? (Q851061)

A. Observe and monitor neurological status

B. Start mannitol and hyperventilate

C. Burr hole followed by craniotomy and ligation of the bleeder

D. Conservative management with anticonvulsants

See Answer in Part B → Q16

@Neet_pg_bot

Q17: A 75-year-old man on warfarin (INR 2.5) falls and hits his head. He is initially alert and oriented, but after 2 hours, becomes progressively drowsy and confused. His CT scan is given below. Which of the following is the most likely diagnosis? (Q851060)

A. Epidural hematoma

B. Subdural hematoma

C. Intraparenchymal hemorrhage

D. Subarachnoid hemorrhage



See Answer in Part B → Q17

@Neet_pg_bot

Q18: A 52-year-old man presents with headache, left-sided facial, arm, and leg weakness. His sensorium is fast deteriorating, and he is a known case of rheumatic heart disease on warfarin. His INR is 10. The NCCT head is given below. Which of the

following is correct about his management? (Q851059)

A. Vitamin K 10mg IV only

B. Fast infusion of fresh frozen plasma

C. Fast infusion of fresh frozen plasma and urgent neurosurgery

D. 4-factor Prothrombin Complex Concentrate and Vitamin K 10mg IV

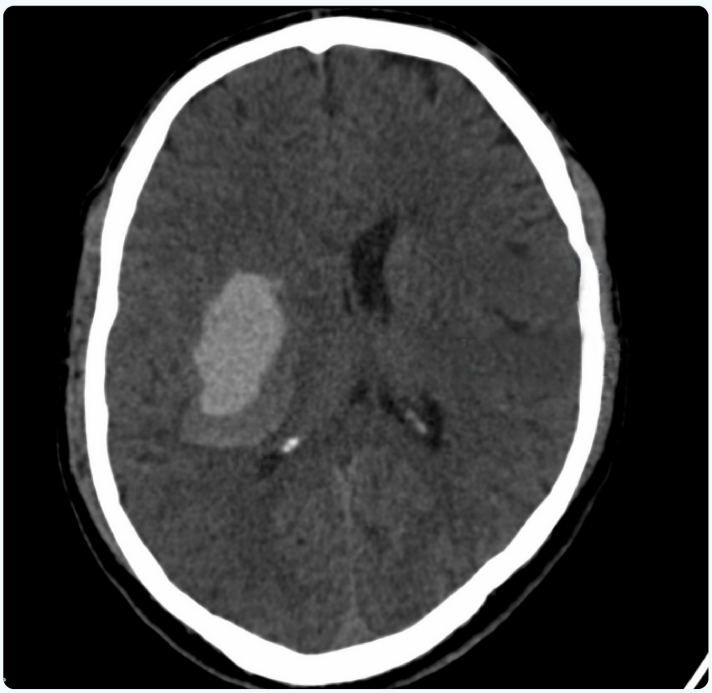

See Answer in Part B → Q18

@Neet_pg_bot

Q19: A 50-year-old hypertensive man suddenly develops facial asymetry and right arm weakness during a meeting. His BP on arrival is 220/130 mmHg. CT shows putaminal hemorrhage. What is the most appropriate immediate management? (Q851058)

A. IV Mannitol

B. Immediate surgical evacuation

C. Nicardipine to achieve target BP of 140/90 mm Hg or lesser

D. Sodium nitroprusside to achieve target BP of 140/90 mm Hg or lesser

See Answer in Part B → Q19

@Neet_pg_bot

Q20: A 65-year-old hypertensive male presents with sudden onset weakness of right face and arm, along with difficulty speaking. He is unable to form words properly but appears to understand commands. Brain imaging shows an acute infarct. Which division of the MCA is most likely involved? (Q851057)

A. Superior division of left MCA

B. Inferior division of left MCA

C. Main trunk of left MCA

D. Penentrating branches of lenticulostriate artery

See Answer in Part B → Q20

@Neet_pg_bot

Q21: An 82-year-old normotensive, non-diabetic man presents with sudden onset confusion and headache. MRI shows multiple lobar hemorrhages. Which is the MOST likely diagnosis? (Q851055)

A. Cerebral amyloid angiopathy

B. Berry aneurysm rupture

C. Hypertensive crisis

D. Venous sinus thrombosis

See Answer in Part B → Q21

@Neet_pg_bot

• [07_Neurology] 056 Parkinsonism And Parkinson S Disease

« Back to Folder Directory

[07_Neurology] 056 Parkinsonism And Parkinson S Disease — Quick Jump

Q1 (p. 661) *Q2 (p. 662)* *Q3 (p. 662)* *Q4 (p. 663)* *Q5 (p. 663)* *Q6 (p. 664)*
Q7 (p. 664) *Q8 (p. 665)* *Q9 (p. 665)* *Q10 (p. 666)* *Q11 (p. 667)* *Q12 (p. 667)*
Q13 (p. 668) *Q14 (p. 668)* *Q15 (p. 669)* *Q16 (p. 669)* *Q17 (p. 669)* *Q18 (p. 670)*
Q19 (p. 670)

Q1: A 60-year-old man presents with a 1-year history of progressive unsteadiness while walking, slurred speech, and frequent falls. He also reports urinary urgency and mild orthostatic dizziness. Neurological examination reveals cerebellar signs including dysmetria and truncal ataxia. MRI is shown below. Which of the following is the most likely diagnosis? (Q851452)

A. Parkinson disease

B. Progressive supranuclear gaze palsy

C. Multi-system atrophy

D. Spinocerebellar ataxia



See Answer in Part B → Q1

@Neet_pg_bot

Q2: Which of the following pathological features is seen in Frontotemporal dementia? (Q851470)

A. α-synuclein-positive Lewy bodies

B. β-amyloid plaques and neurofibrillary tangles

C. Tau-positive neuronal inclusions

D. Prion protein accumulation in the brain

See Answer in Part B → Q2

@Neet_pg_bot

Q3: A 70-year-old man with advanced Parkinson's disease is considered for deep brain stimulation after experiencing significant motor fluctuations and dyskinesias despite optimal medication therapy. Which of the following brain structures is most commonly targeted in DBS to improve tremor, bradykinesia, and rigidity? (Q851468)

A. Ventral Intermediate Nucleus of the Thalamus

B. Subthalamic Nucleus

C. Globus Pallidus Internus

D. Caudate Nucleus

See Answer in Part B → Q3

@Neet_pg_bot

Q4: Which of the following is correct about istradefylline? (Q851467)

A. COMT inhibitor

B. Anticholinergic drug

C. Adenosine A2A receptor antagonists

D. Dopamine agonists

See Answer in Part B → Q4

@Neet_pg_bot

Q5: A 65-year-old man with Parkinson's disease is currently on levodopa with carbidopa but is experiencing significant motor fluctuations and "wearing off" between doses. His neurologist is considering adding a medication to improve his overall motor function. Which of the following is a commonly used dopamine agonist that could be added to his treatment regimen? (Q851465)

A. Apomorphine

B. Selegiline

C. Entacapone

D. Trihexyphenidyl

See Answer in Part B → Q5

@Neet_pg_bot

Q6: A 70-year-old man with a diagnosis of Parkinson's disease has been experiencing increased motor fluctuations despite being on a stable dose of levodopa for the past two years. He reports that his symptoms improve shortly after taking his medication but then return before his next dose is due. The physician considers adding a medication to help extend the effect of his current treatment. Which of the following is the most appropriate addition to his regimen? (Q851463)

A. Dopamine agonist

B. COMT inhibitor

C. Anticholinergic agent

D. Beta blocker

See Answer in Part B → Q6

@Neet_pg_bot

Q7: A 68-year-old woman presents with a 1-year history of progressive difficulty controlling her right arm. She reports that her arm occasionally moves on its own, and she has trouble performing simple tasks like buttoning her shirt. On examination, she has dystonic posturing of the right hand, mild bradykinesia, and intermittent myoclonic jerks. Her cognitive function appears intact except for mild apraxia. What is the most likely diagnosis? (Q851461)

A. Parkinson's disease

B. Corticobasal syndrome

C. Multiple system atrophy

D. Progressive supranuclear palsy

See Answer in Part B → Q7

@Neet_pg_bot

Q8: A 65-year-old man presents with his family, who report that over the past year, he has developed significant personality changes. He has become socially inappropriate, often acting impulsively and showing a lack of empathy. He also struggles to initiate tasks and frequently forgets appointments. On examination, his language production is impaired, though his comprehension remains intact. What is the most likely diagnosis? (Q851459)

A. Alzheimer's disease

B. Vascular dementia

C. Frontotemporal dementia

D. Lewy body dementia

See Answer in Part B → Q8

@Neet_pg_bot

Q9: A 65-year-old male presents with frequent, unexplained falls. On examination, impaired downward gaze, neck hyperextension, and square wave jerks in his eye movements are present. MRI head is shown below. Diagnosis is? (Q851456)

A. Multiple system atrophy (MSA)

B. Progressive supranuclear gaze palsy (PSP)

C. Huntington chorea disease (HD)

D. Parkinson disease (PD)

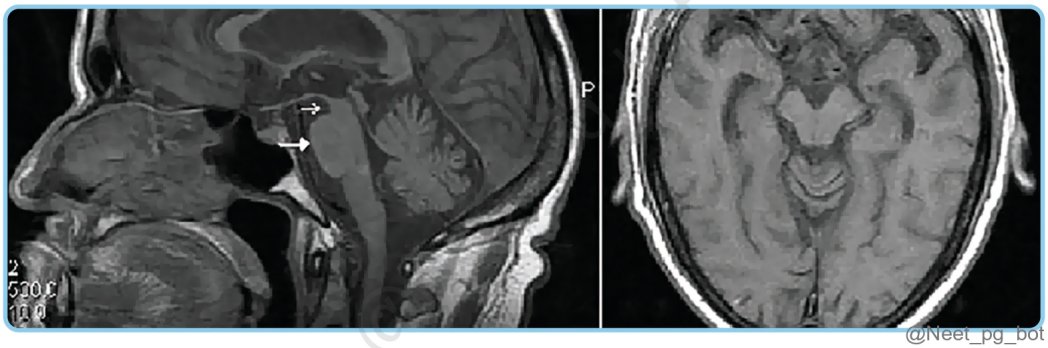

@Neet_pg_bot

See Answer in Part B → Q9

@Neet_pg_bot

Q10: 60 year old man with multiple system atrophy is having dizzy spells and tilt table test is positive. MRI head is shown below. Which of the following is most appropriate treatment for this case? (Q851454)

A. Tertrabenazine

B. Levodopa plus Carbidopa

C. Midodrine

D. Hydrocortisone



See Answer in Part B → Q10

@Neet_pg_bot

Q11: Which of the following is a must have criteria for diagnosis of Parkinson disease ? (Q851349)

A. Bradykinesia

B. Cog wheel rigidity

C. Postural instability

D. Tremors that worsen with goal directed activity

See Answer in Part B → Q11

@Neet_pg_bot

Q12: Which of the following is not correct about managment of Parkinson disease? (Q851451)

A. Rotigotine is ergot derived D2 receptor agonist

B. Entacapone reduces wearing off phenomenon with levodopa

C. Amantadine reduces levodopa induced peak dose dyskinesias

D. Istradefylline is adjunct to levodopa to reduce off time

See Answer in Part B → Q12

@Neet_pg_bot

Q13: Which gene is responsible for development of juvenile-onset Parkinson's disease? (Q851416)

A. PARK-GBA

B. PARK-LRRK2

C. PARK-Parkin

D. All of the above

See Answer in Part B → Q13

@Neet_pg_bot

Q14: Which of the following is not a clinical feature of atypical parkinsonism? (Q851415)

A. Slow ocular saccades

B. Resting pill rolling tremor

C. Early gait impairment

D. Poor response to Levodopa

See Answer in Part B → Q14

@Neet_pg_bot

Q15: A 15-year-old boy is brought by his parents due to involuntary movements of his hands, behavioral changes such as irritability and poor concentration affecting school performance and attendance. On examination, choreiform movements in hands are noted along with pallor. Work up shows elevated transaminases and increased PT and urine examination showing proteinuria and glucosuria. Which of the following is first differential diagnosis for this patient? (Q851414)

A. Wilson's Disease

B. Sydenham Chorea

C. Huntington's Disease

D. Spinocerebellar Ataxia

See Answer in Part B → Q15

@Neet_pg_bot

Q16: Which of the following medications is least likely to contribute to the development of drug induced parkinsonism? (Q851412)

A. Haloperidol

B. Risperidone

C. Domperidone

D. Metoclopramide

See Answer in Part B → Q16

@Neet_pg_bot

Q17: A 68-year-old man presents with difficulty in initiating movements like getting out of a chair or toilet seat . He experiences a resting tremor in his right hand and has noticed a decline in his balance, leading to several near falls. His Family members

notice that he does not do activitites that he once liked. He is at risk of developing all of the following except? (Q851409)

A. REM sleep disorders

B. Decreased sweating

C. Restless leg syndrome

D. Urinary urgency

See Answer in Part B → Q17

@Neet_pg_bot

Q18: Which of the following indicates that patient is having atypical parkinsonism? (Q851400)

A. Tremors that disappear on goal-directed activity

B. Recurrent falls due to downward gaze palsy

C. Pill rolling tremors with low frequency

D. Bradykinesia

See Answer in Part B → Q18

@Neet_pg_bot

Q19: Involvement of the marked area of brain will result in which of the following disease? (Q851350)

A. Weber syndrome

B. Parkinson disease

C. Nonthangel syndrome

D. Perinaud syndrome

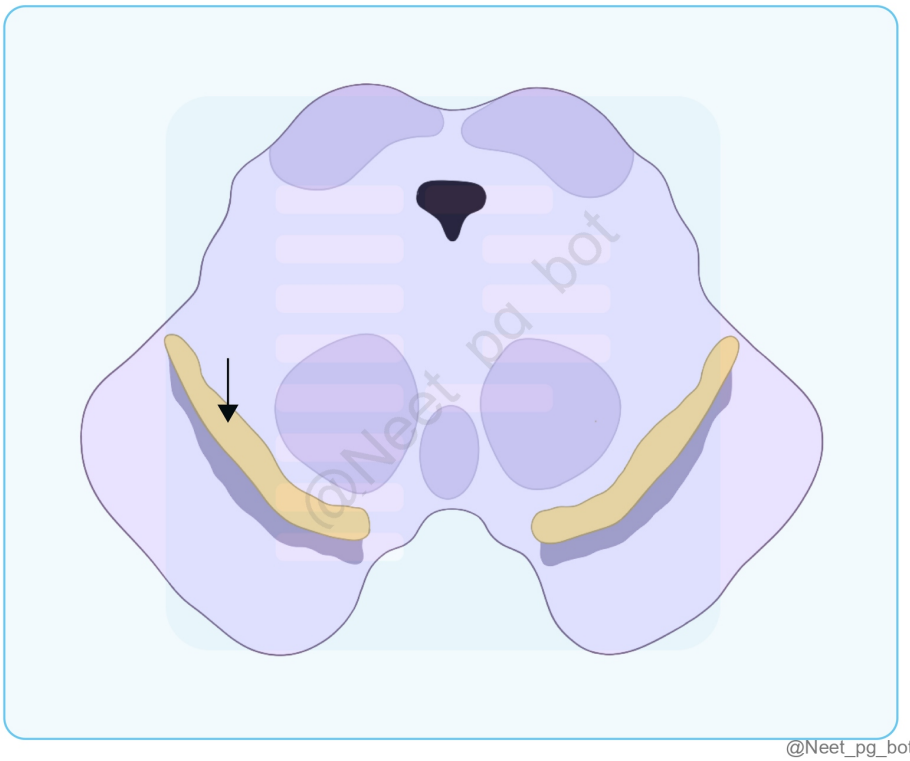

See Answer in Part B → Q19

@Neet_pg_bot

• [07_Neurology] 057 Meningitis And Cns Infections

« Back to Folder Directory

[07_Neurology] 057 Meningitis And Cns Infections — Quick Jump

Q1 (p. 672)	*Q2 (p. 673)*	*Q3 (p. 674)*	*Q4 (p. 674)*	*Q5 (p. 675)*	*Q6 (p. 675)*
Q7 (p. 676)	*Q8 (p. 676)*	*Q9 (p. 676)*	*Q10 (p. 677)*	*Q11 (p. 677)*	*Q12 (p. 678)*
Q13 (p. 679)	*Q14 (p. 680)*	*Q15 (p. 680)*	*Q16 (p. 680)*	*Q17 (p. 681)*	*Q18 (p. 682)*
Q19 (p. 683)	*Q20 (p. 683)*	*Q21 (p. 683)*	*Q22 (p. 684)*	*Q23 (p. 685)*	*Q24 (p. 685)*

Q1: A 32 year old HIV-positive truck driver presents with fever, headache and drowsiness. Lumbar puncture is performed, and CSF shows elevated opening pressure with 20 lymphocytes /cu.mm with low sugar and protein of 60 mg/dl. MRI of the brain is shown below. Which of the following is the most likely diagnosis? (Q851546)

A. Tuberculous meningitis

B. Cryptococcal meningitis

C. Cytomegalovirus encephalitis

D. Toxoplasmosis

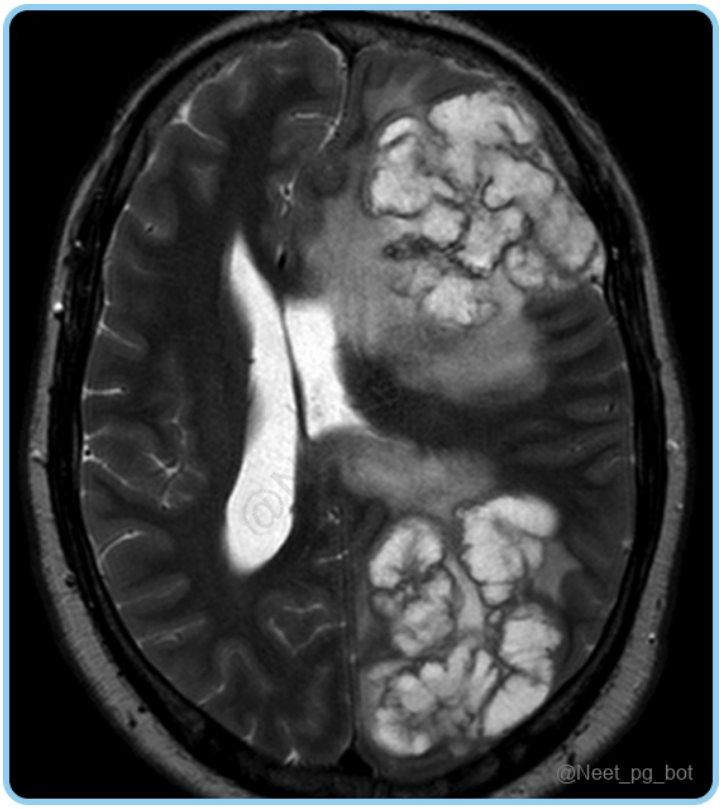

See Answer in Part B → Q1

@Neet_pg_bot

Q2: A 65-year-old male presents with a gradually progressive cognitive decline over recent months and episodic, irregular jerky movements, with an EEG finding shown below. What is the most likely underlying diagnosis? (Q890931)

A. Subacute sclerosing panencephalitis

B. Progressive multifocal leukoencephalopathy

C. Creutzfeldt-Jakob disease

D. Neurosyphilis



See Answer in Part B → Q2

@Neet_pg_bot

Q3: Which of the following findings would you not expect to see in a patient's CSF analysis with Herpes simplex virus encephalitis? (Q890929)

A. Elevated protein levels

B. Mild to moderate lymphocytic pleocytosis

C. Elevated red blood cell count

D. Profoundly decreased glucose

See Answer in Part B → Q3

@Neet_pg_bot

Q4: A 42-year-old male is brought to the emergency department with a 2-day history of high fever, confusion, and new-onset focal seizures preceded by the smell of burning rubber. Cerebrospinal fluid polymerase chain reaction is positive for a double-stranded DNA virus. MRI of the brain is most likely to reveal abnormal

hyperintensities in which of the following areas? (Q890928)

A. Bilateral cerebellar hemispheres

B. Temporal lobe

C. Basal ganglia and thalami

D. Parieto-occipital cortex

See Answer in Part B → Q4

@Neet_pg_bot

Q5: A 45-year-old male with a history of untreated HIV infection presents with a 4-week history of progressively worsening headache, low-grade fever, night sweats, and recent-onset double vision. MRI of the brain reveals hydrocephalus and abnormal enhancements of the basal cisterns. Which of the following CSF profiles is most consistent with this patient's likely diagnosis? (Q890925)

A. Neutrophilic pleocytosis, low glucose, markedly elevated protein

B. Lymphocytic pleocytosis, low glucose, markedly elevated protein

C. Lymphocytic pleocytosis, normal glucose, normal protein

D. Monocytic pleocytosis, normal glucose, markedly elevated protein

See Answer in Part B → Q5

@Neet_pg_bot

Q6: Which of the following is the most appropriate empirical treatment for a suspected case of meningococcal meningitis? (Q890923)

A. Intravenous Penicillin G

B. Intravenous Ceftriaxone and Vancomycin

C. Oral Ciprofloxacin

D. Intravenous Cefotetan

See Answer in Part B → Q6

@Neet_pg_bot

Q7: A 26-year-old pregnant woman in her second trimester presents to the emergency department with a 2-day history of high-grade fever, severe headache, and vomiting. She recently attended a crowded indoor school gathering. On examination, she exhibits marked neck stiffness and a rapidly spreading petechial rash over her trunk and lower extremities. Which of the following statements is false regarding the disease she is most likely suffering from? (Q890919)

A. Deficiency of C5-C9 components significantly increases the risk of this infection.

B. Oral ciprofloxacin is the preferred agent for chemoprophylaxis in this patient.

C. Cultures typically become sterile within 24 hours of initiating appropriate therapy.

D. The causative organism is an aerobic, Gram-negative diplococcus.

See Answer in Part B → Q7

@Neet_pg_bot

Q8: Which of the following is the most frequently identified pathogen responsible for meningitis following the implantation of an indwelling central nervous system device? (Q890917)

A. Streptococcus pneumoniae

B. Coagulase-negative staphylococci

C. Pseudomonas aeruginosa

D. Group B streptococci

See Answer in Part B → Q8

@Neet_pg_bot

Q9: A 30-year-old previously healthy male presents with the acute triad of high-grade fever, severe headache, and neck stiffness. Examination reveals positive Kernig's and Brudzinski's signs. Which of the following is the most common cause of community-acquired bacterial meningitis? (Q890916)

A. Staphylococcus aureus

B. Neisseria meningitidis

C. Streptococcus pneumoniae

D. Listeria monocytogenes

See Answer in Part B → Q9

@Neet_pg_bot

Q10: A 30-year-old man from the village is admitted with high-grade fever and altered sensorium. On examination, bilateral Babinski and exaggerated ankle jerks were noted. Nuchal rigidity is absent. Workup shows Hb:7 gm%, TLC: 10K/cu.mm, platelet count: 1.5 Lac/cu.mm, elevated LDH, LFT is normal, and Serum creatinine is 1.5mg/dl. What is the best course of action for this patient? (Q851555)

A. LP followed by IV acyclovir

B. Peripheral smear followed by IV Artensunate

C. LP followed by IV Dexamethasone

D. Lateral flow assay followed by IV Sulphamethoxazole plus Trimethoprim

See Answer in Part B → Q10

@Neet_pg_bot

Q11: A 42■year■old HIV positive man with CD4 count 80 cells/mm³ presents with 3 weeks of visual blurring, weakness in right arm and dysarthria. MRI brain (FLAIR sequence) shows multiple asymmetric hyperintense lesions in the frontal and parietal white matter, with no mass effect and no contrast enhancement. Which of the following is the most likely cause? (Q851548)

A. JC virus

B. BK virus reactivation

C. Cerebral toxoplasmosis

D. CMV encephalitis

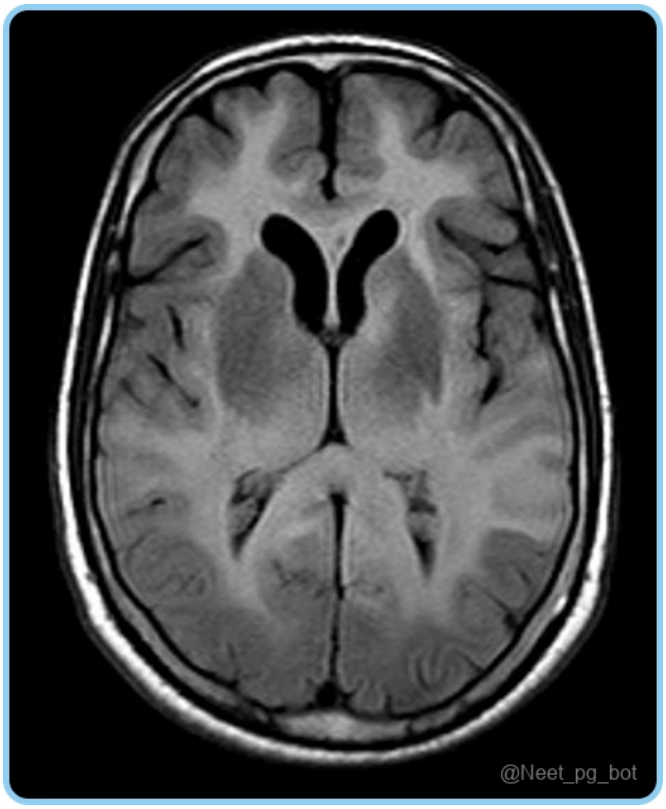

See Answer in Part B → Q11

@Neet_pg_bot

Q12: A 25 year old HIV positive man presents with complaints of a severe headache, fever, and confusion. His CD4+ T-cell count is 80 cells/μL. Neurological examination reveals right-sided hand weakness and difficulty speaking. An MRI of the patient is given below. Which of the following is the most appropriate next step in management? (Q851547)

A. Initiate treatment with sulfadiazine and pyrimethamine with leucovorin

B. Perform a brain biopsy to confirm the diagnosis.

C. Order a chest X-ray to rule out tuberculosis.

D. Start empiric treatment for bacterial meningitis.

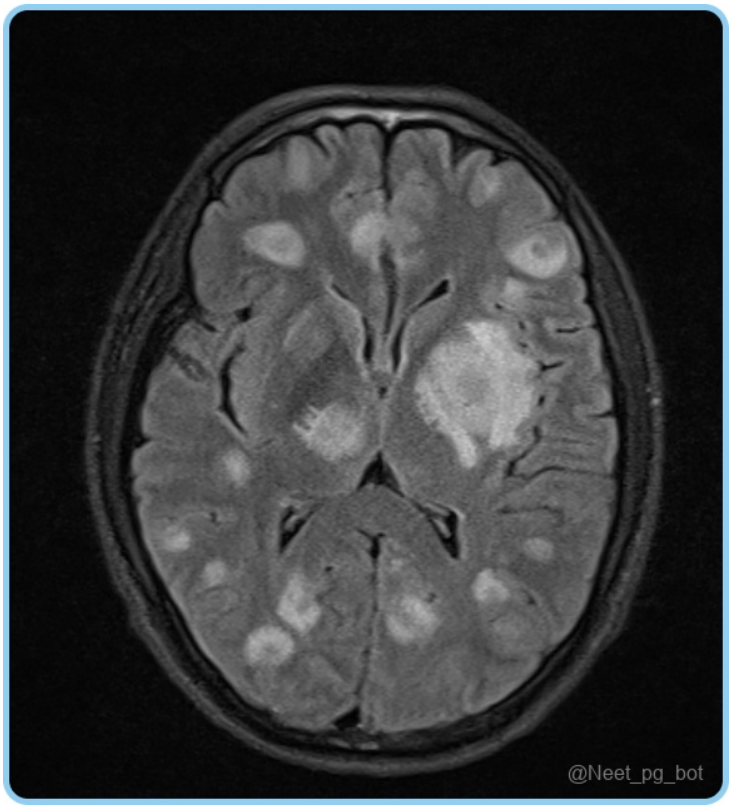

See Answer in Part B → Q12

@Neet_pg_bot

Q13: A 2-week-old infant presents with lethargy, poor feeding, irritability, and a bulging fontanelle. Born prematurely at 34 weeks with low birth weight, a lumbar puncture reveals cloudy cerebrospinal fluid (CSF) with high white blood cell count, decreased glucose, and elevated protein levels. Which is not a causative factor for this infant's condition? (Q851517)

A. Group B Streptococcus

B. Escherichia coli

C. Streptococcus pneumoniae

D. Listeria monocytogenes

See Answer in Part B → Q13

@Neet_pg_bot

Q14: A 34-year-old male HIV positive truck driver presents with severe headache. Examination shows nuchal rigidity and altered mental status. Lumbar puncture shows elevated opening pressure, low glucose, normal protein and encapsulated yeast on India ink staining. What is the most appropriate initial treatment? (Q851545)

A. Liposomal amphotericin B with High-dose IV fluconazole

B. Liposomal amphotericin B with capsofungin

C. Liposomal amphotericin B plus 5 Flucytosine

D. Oral corticosteroids plus broad-spectrum antibiotics

See Answer in Part B → Q14

@Neet_pg_bot

Q15: A 45 y/o patient presents with fever, headache, neck stiffness, and photophobia. On examination, the patient is lethargic and lumbar puncture reveals elevated CSF opening pressure, PMN leukocytosis, decreased glucose levels, and increased protein concentration. Which of the following will not be seen in this patient? (Q851544)

A. Woltman sign

B. Brudzinki sign

C. Jolt accentuation

D. Kernig sign

See Answer in Part B → Q15

@Neet_pg_bot

Q16: A 68 year old patient with diabetic nephropathy presents to the ER with fever, headache, and neck stiffness. Blood cultures are pending, and a lumbar puncture reveals elevated CSF protein, decreased glucose, and neutrophilic pleocytosis. Which

of the following is the most appropriate empirical antibiotic regimen? (Q851543)

A. Ceftriaxone and Vancomycin

B. Ceftriaxone and Gentamycin

C. Ampicillin + Ceftriaxone + Vancomycin

D. Meropenem and Vancomycin

See Answer in Part B → Q16

@Neet_pg_bot

Q17: A 36 year old HIV positive patient presents with double vision, vomitting epsiodes with daily frontal headaches that dont respond to painkillers. Patient is not cooperative during physical examination due to headache. Fundus examination shows papilledema. Neuroimaging is performed. Which of the following is not correct about immediate management of this patient? (Q851542)

A. Lumbar puncture for CSF CBNAAT for MTB

B. Empirical ATT

C. IV dexamathasone

D. Mannitol

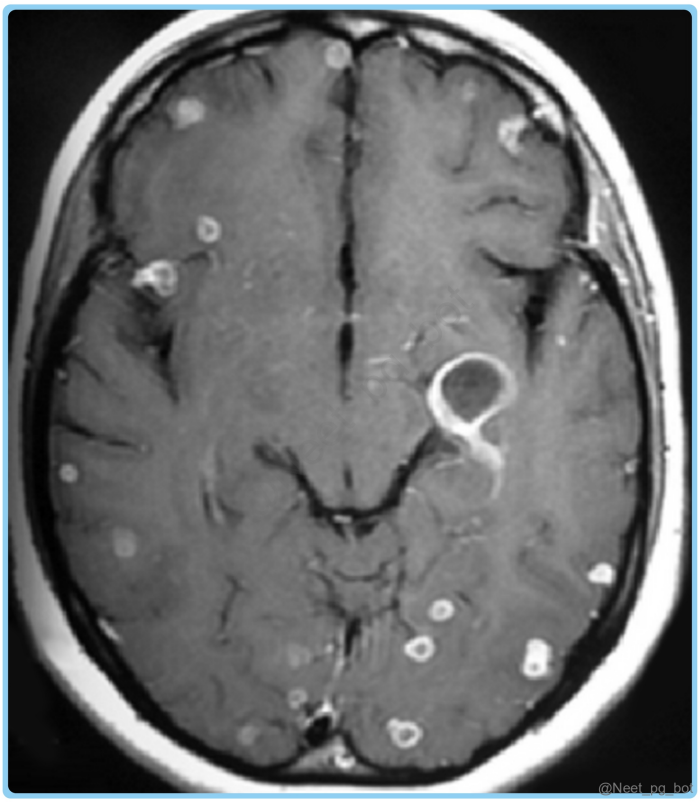

See Answer in Part B → Q17

@Neet_pg_bot

Q18: A 38 year old man presented to ER with inability to stand and sit up in bed since yesterday evening. He reports that the weakness began as slipping in stairs multiple times in last 3 days along with tingling in his fingertips. Power in both legs at all joints is grade 2/5 and bilateral ankle jerks are absent. Which is not correct about this patient? (Q851541)

A. Electrodiagnostics show absent F waves

B. MRI shows spinal cord inflammation

C. Cytoabuminological dissociation

D. Bladder and Bowel are spared

See Answer in Part B → Q18

@Neet_pg_bot

Q19: Which of the following is not required for management of Post dural puncture headache? (Q851538)

A. Intravenous caffeine

B. Low volume blood patch

C. Bladder catheterization and laxatives

D. Plenty of fluids

See Answer in Part B → Q19

@Neet_pg_bot

Q20: During a lumbar puncture, the needle passes through several anatomical layers before reaching the subarachnoid space. Which of the following is the correct sequence of structures pierced during this procedure? (Q851534)

A. Skin → Ligamentum flavum → Supraspinous ligament → Interspinous ligament → Dura → Arachnoid

B. Skin → Supraspinous ligament → Interspinous ligament → Ligamentum flavum → Arachnoid → Dura

C. Skin → Supraspinous ligament → Ligamentum flavum → Interspinous ligament → Dura → Arachnoid

D. Skin → Supraspinous ligament → Interspinous ligament → Ligamentum flavum → Dura → Arachnoid

See Answer in Part B → Q20

@Neet_pg_bot

Q21: A 45 y/o male with a history of HIV infection presents to the ED with headache, fever, photophobia, and neck stiffness. His CD4 count is 80 cells/mm³. Lumbar puncture reveals an elevated opening pressure, low glucose, and elevated protein levels. India ink staining of the cerebrospinal fluid showed the following picture. Which of the following is the most appropriate initial treatment regimen for this

patient? (Q851531)

A. Fluconazole monotherapy

B. Amphotericin B and Flucytosine

C. Voriconazole monotherapy

D. Caspofungin and Fluconazole



See Answer in Part B → Q21

@Neet_pg_bot

Q22: A 25 year old HIV positive male is brought to the emergency after developing high grade fever and altered sensorium for past 2 days. Meningeal signs are absent and bilateral babinski sign is noted. MRI head shows predominant temporal lobe inflammation. Which of the following is correct about immediate managment of this patient? (Q851529)

A. Start empirical Artesunate

B. Start Empirical acyclovir

C. Start empirical ATT plus dexamethasone

D. Start empirical Liposomal amphotericin B with 5 flucytosine

See Answer in Part B → Q22

@Neet_pg_bot

Q23: Which of the following accurately describes the CSF findings in viral encephalitis caused by HSV-1? (Q851526)

A. Lymphocytic pleocytosis with low glucose levels

B. Lymphocytic pleocytosis with normal glucose levels

C. Lymphocytic pleocytosis with cob web coagulum

D. Lymphocytic pleocytosis with elevated glucose levels

See Answer in Part B → Q23

@Neet_pg_bot

Q24: A 45-year-old male presents to the emergency with fever, severe headache and confusion for last 3 days. Nuchal rigidity is present. Fundus is normal. CSF study shows 1000 cells with 10% lymphocytes and 90% PMN cells , CSF /plasma sugar 0.4 and CSF protein 80 mg/dl. What is the next best step in managment of this patient? (Q851519)

A. IV Cannula and start IV fluids at 20 ml per kg per hour

B. Empirical Ceftriaxone plus Vancomycin

C. Empirical ATT plus dexamethasone

D. NCCT head

See Answer in Part B → Q24

@Neet_pg_bot

• [07_Neurology] 058 Intracranial Pathologies Icp Brain Death Tumors And Neurocysticercosis

« Back to Folder Directory

[07_Neurology] 058 Intracranial Pathologies Icp Brain Death Tumors And Neurocysticercosis — Quick Jump

Q1 (p. 686)	*Q2 (p. 687)*	*Q3 (p. 688)*	*Q4 (p. 688)*	*Q5 (p. 688)*	*Q6 (p. 689)*
Q7 (p. 689)	*Q8 (p. 690)*	*Q9 (p. 690)*	*Q10 (p. 691)*	*Q11 (p. 692)*	*Q12 (p. 693)*
Q13 (p. 694)	*Q14 (p. 694)*	*Q15 (p. 695)*	*Q16 (p. 695)*	*Q17 (p. 696)*	*Q18 (p. 696)*
Q19 (p. 697)	*Q20 (p. 697)*	*Q21 (p. 697)*	*Q22 (p. 698)*	*Q23 (p. 699)*	

Q1: A 25 year rickshaw puller presents with daily headaches and multiple episodes of focal seizures. MRI head is shown below. Which of the following is first line intervention in this patient? (Q851450)

A. Albendazole

B. A.T.T

C. Dexamethasone

D. Albendazole and praziquental

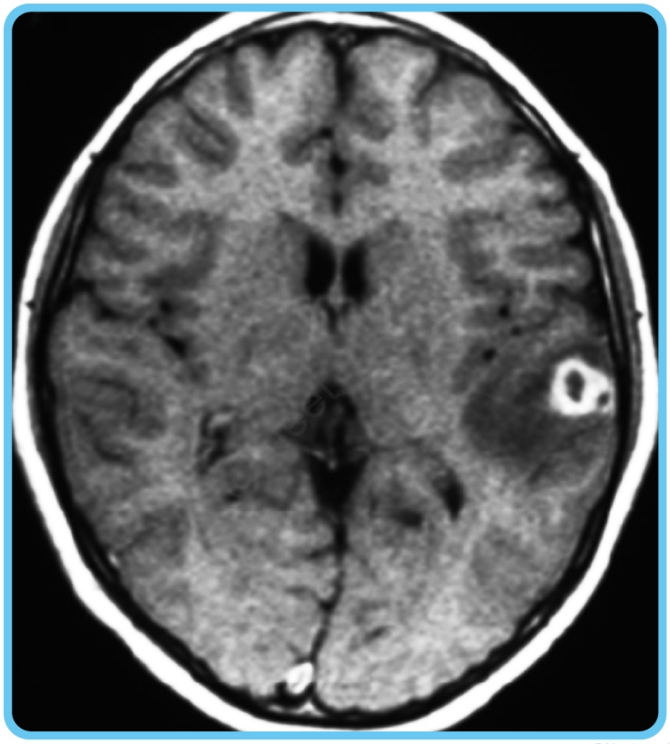

See Answer in Part B → Q1

@Neet_pg_bot

Q2: A 30 year old man presented with high grade fever, headache and vomitting for past 5 days. MRI head shows double rim sign in left temporal lobe . Guided aspiration from lesion shows gram positive filamentous bacteria stained with a positive modified ZN staining and paraffin bait technique. What is the likely organism causing this? (Q851514)

A. Mycobacterium Tuberculosis

B. Atypical mycobacteria

C. Actinomyces israelli

D. Nocardia

See Answer in Part B → Q2

@Neet_pg_bot

Q3: Which of the following is the most common brain tumour in childhood? (Q851512)

A. Pilocytic astrocytoma

B. Medulloblastoma

C. Ependymoma

D. Metastasis

See Answer in Part B → Q3

@Neet_pg_bot

Q4: Match the following syndromes with their most commonly seen brain tumours respectively. 1. Von Hippel Landau a) Bilateral vestibular schwannomas 2. Tuberous sclerosis b) Glioma 3. Neurofibromatosis 2 c) Hemangioblastoma of the cerebellum 4. Li Fraumeni Syndrome d) Subependymal giant cell astrocytoma (Q851511)

A. 1-c, 2-d, 3-a, 4-b

B. 1-b, 2-d, 3-c, 4-a

C. 1-d, 2-a, 3-b, 4-c

D. 1-b, 2-d, 3-a, 4-c

See Answer in Part B → Q4

@Neet_pg_bot

Q5: A 40 year old man with a known brain tumour has recently undergone radiation therapy. During a follow-up visit, his doctor ordered imaging studies to evaluate the tumour. The physician wants to determine whether the changes observed on the imaging are due to tumour progression or necrosis resulting from treatment. Which imaging technique can help differentiate between the two? (Q851510)

A. Computed Tomography

B. Gadolinium-enhanced Magnetic Resonance Imaging

C. MR Spectroscopy

D. PET CT

See Answer in Part B → Q5

@Neet_pg_bot

Q6: A 75-year-old male presents with recent onset frontal headache and seizures. Fundus reveals papilledema. MRI brain reveals a ring-enhancing lesion in the right frontal lobe with surrounding edema. MR Spectroscopy shows a high choline peak, low N-acetylaspartate (NAA), and elevated lipid-lactate peaks. Which of the following is the most likely diagnosis? (Q851509)

A. Tuberculoma

B. Neurocysticercosis

C. Brain tumor

D. Brain abscess

See Answer in Part B → Q6

@Neet_pg_bot

Q7: Identify the correct statements on CNS tumours Calcifications are found in Meningioma and Oligodendroglioma Craniopharyngioma are present as suprasellar mass Giant cell Astrocytoma and Ependymoma occur as Intraventricular tumours Metastatic lesions occur at white matter-gray matter junction (Q851507)

A. 1,2

B. 1,2,4

C. 1,2,3

D. 1,2,3,4

See Answer in Part B → Q7

@Neet_pg_bot

Q8: Which of the following is the most common primary malignant brain tumour in adults? (Q851506)

A. Meningioma

B. Glioma

C. Metastasis from oat cell cancer of lung

D. CNS Lymphoma

See Answer in Part B → Q8

@Neet_pg_bot

Q9: A 30 year female presents with repeated episodes of GTCS since last 3 months. Neuroimaging is shown below. Which of the following treatment regimens is most appropriate? (Q851505)

A. Valproate

B. Praziquantel + Valproate

C. Steroids + Albendazole + Praziquantel

D. Steroids + Albendazole + Praziquental + Valproate



See Answer in Part B → Q9

@Neet_pg_bot

Q10: A 30-year-old man presents with progressive headaches, fever, weight loss, and left arm weakness over the past month. He remembers taking a long duration of antibiotic course for a respiratory illness in his childhood, but the specific details he is unable to recall. CT head is shown below. What is the most likely diagnosis? (Q851471)

A. Neurocysticercosis

B. Tuberculoma

C. Brain abscess

D. Metastasis

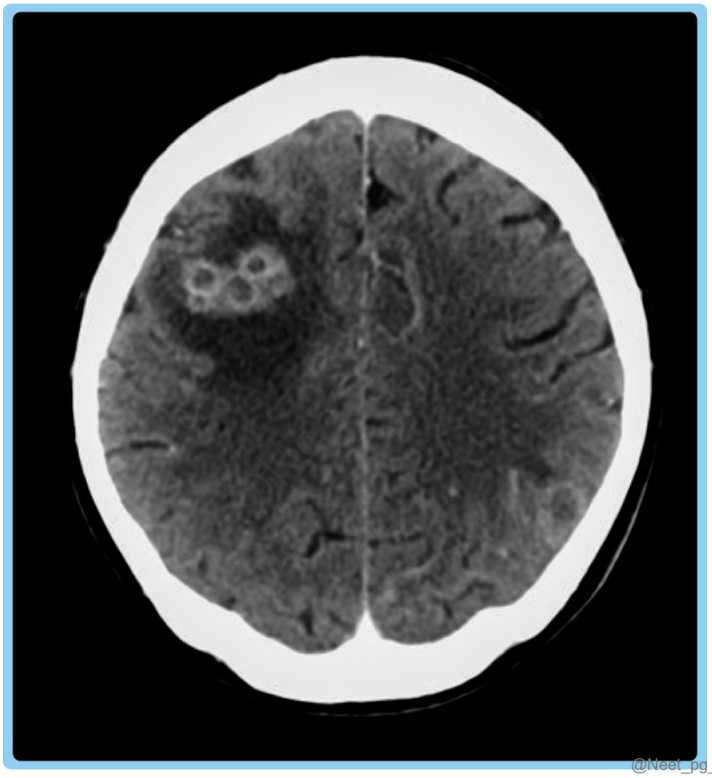

See Answer in Part B → Q10

@Neet_pg_bot

Q11: A 28 year old female presents with recurrent headaches and occasional seizures. Neuroimaging is done. Which stage of development of parasite is shown below? (Q851458)

A. Vesicular Stage

B. Colloidal Stage

C. Granulonodular Stage

D. Calcified Stage



See Answer in Part B → Q11

@Neet_pg_bot

Q12: A 35 year old male presents with multiple episodes of GTCS and persistent headaches. Neuroimaging of patient is shown. Which of the following tests will help in confirmation of diagnosis of this patient? (Q851453)

A. PCR CBNAAT for MTB

B. Enzyme-Linked Immunotransfer Blot

C. Susceptibility-weighted imaging

D. Fundoscopic Exam

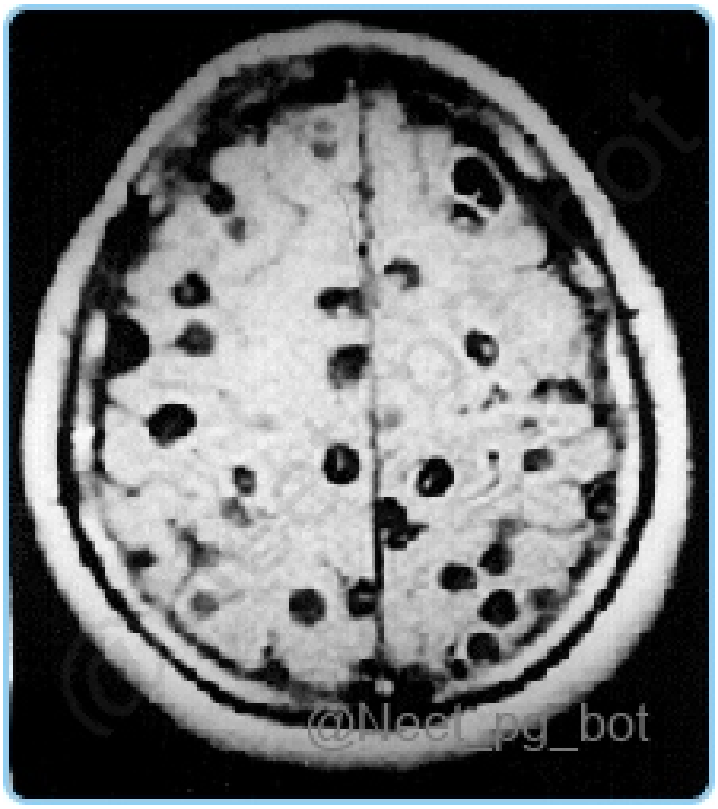

See Answer in Part B → Q12

@Neet_pg_bot

Q13: A 50 year hypertensive man suddenly develops face, arm and leg weakness. Imaging confirms a large putaminal bleed. What type of brain herniation is most likely to occur in this case? (Q851296)

A. Subfalcine herniation

B. Foraminal herniation

C. Transtentorial herniation

D. Cingulate herniation

See Answer in Part B → Q13

@Neet_pg_bot

Q14: 32 year man presents with recurrent seizures. MRI brain shows multiple hypointense lesions with scolex. What is the most likely cause of his condition? 1. Consumption of semi cooked pork containing Cysticerci cellulosae 2. Feco-oral 3. Consumption of semi cooked beef containing Cysticercus bovis 4. Autoinfection (Q851369)

A. 1

B. 1,2

C. 2,4

D. 1,2,3,4

See Answer in Part B → Q14

@Neet_pg_bot

Q15: An elderly diabetic patient living alone is found unconscious and unresponsive by the maid. On admission, pulse is 100/min, BP =90/60 mm Hg. Workup shows RBS is 200 mg/dl, urine ketostix is 1+, pH =7.42, pC02= 40 mm Hg, HCO3= 26 meq, Na = 130 meq/L and K= 4.0 meq/L and procalcitonin and CRP is normal . Which is the next best step in management of this patient? (Q851367)

A. Start normal saline drip and urgent NCCT head

B. Start normal saline drip and insulin drip

C. Give 50 ml of 50% dextrose

D. Give bolus 10 units of regular insulin followed by insulin drip

See Answer in Part B → Q15

@Neet_pg_bot

Q16: A 50 year woman presents with seizure episode. She in ER she tells that she wakes up with daily early morning frontal headaches and vomiting. NCCT head shows intracranial space-occupying lesion in frontal lobe with dural tail sign. Which of the following cranial nerves is most likely to be involved in this patient? (Q851364)

A. I

B. II

C. III

D. IV

See Answer in Part B → Q16

@Neet_pg_bot

Q17: 38-year-old HIV-positive man presents with recurrent seizures and altered sensorium. MRI brain reveals multiple ring-enhancing lesions with perilesional edema in the basal ganglia and frontal lobe, showing the "concentric target" sign. What is the most likely cause of his seizures? (Q851338)

A. Cerebral toxoplasmosis

B. Primary CNS Lymphoma

C. Neurocysticercosis

D. Tuberculoma

See Answer in Part B → Q17

@Neet_pg_bot

Q18: Which of the following is not a correct component in brain death evaluation? (Q851337)

A. Apnea test with pCO■ rise to ≥60 mmHg or ≥20 mmHg above baseline

B. Positive caloric stimulation test

C. Pupils are fixed and non reactive to light

D. Absence of blinking on touching cornea with wisp of cotton

See Answer in Part B → Q18

@Neet_pg_bot

Q19: 30-year-old biker is brought to the emergency room after a head injury. On examination, he is unconscious with an ipsilateral mid-dilated fixed pupil. NCCT head shows lenticular hyperdensity. Which of the following is the most likely cause and urgent next step? (Q851335)

A. Uncal herniation due to epidural hematoma; immediate burr hole surgery required

B. Cingulate herniation due to epidural hematoma; immediate burr hole surgery required

C. Cingulate herniation due to epidural hematoma; urgent craniotomy

D. Subdural hematoma causing contralateral pupil dilation; urgent craniotomy

See Answer in Part B → Q19

@Neet_pg_bot

Q20: Adult patient involved in a high-speed road traffic accident had a normal CT scan on admission but died within 6 hours. Autopsy reveals petechial hemorrhages in the corpus callosum and retraction balls. The diagnosis is? (Q851333)

A. Diffuse axonal injury

B. SAH

C. SDH

D. EDH

See Answer in Part B → Q20

@Neet_pg_bot

Q21: A patient diagnosed with TB meningitis develops posturing as shown in the diagram. Which of the following is correct about the cause of this presentation (Q851332)

A. Inhibition of the rubrospinal with overactivity of vestibulospinal and reticulospinal pathways

B. Stimulation of the rubrospinal tract with simultaneous facilitation of vestibulospinal and reticulospinal tracts

C. Intact or overactive rubrospinal tract with loss of extensor facilitation from vestibulospinal and reticulospinal tracts

D. Loss of rubrospinal tract activity with strong extensor inhibition from vestibulospinal and reticulospinal tracts

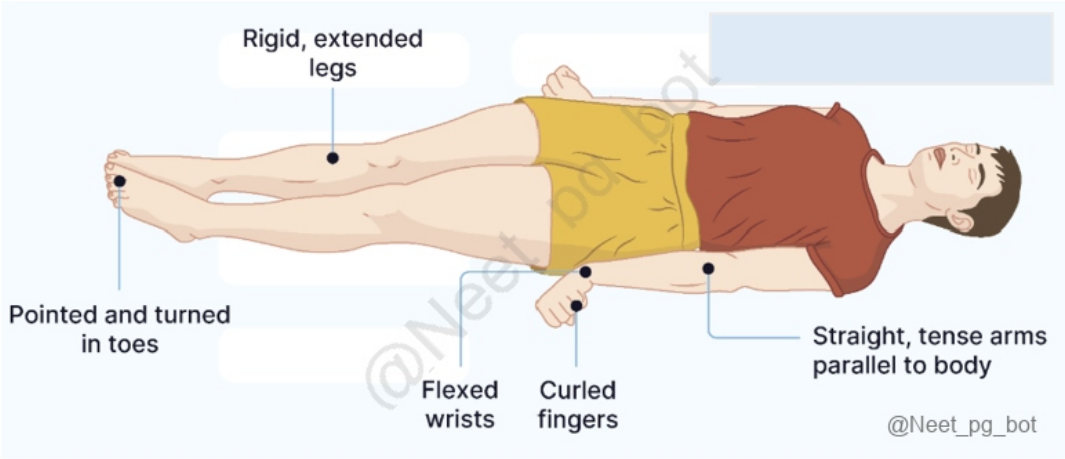

See Answer in Part B → Q21

@Neet_pg_bot

Q22: 60-year-old hypertensive man is brought to ER with sudden onset right-sided weakness and aphasia. His BP is 190/100 mmHg. CT scan done 1 hour after admission shows putaminal bleed and midline shift. Which of the following is not useful for management of this patient? (Q851331)

A. Ventriculostomy

B. Start IV dexamethasone

C. Mannitol

D. Labetalol

See Answer in Part B → Q22

@Neet_pg_bot

Q23: A 35 year old biker male is brought to the ED after a road traffic accident. He is unconscious with a GCS score of 9/15. Vitals are Pulse 60/min with BP: 160/100 mmHg and irregular respiration. What is the first step in managing of this patient? (Q851330)

A. Elective Hyperventilation

B. Administer mannitol

C. Elevate head end of bed and secure airway

D. Burr hole surgery

See Answer in Part B → Q23

@Neet_pg_bot

• [07_Neurology] 059 Previous Year Questions

« Back to Folder Directory

[07_Neurology] 059 Previous Year Questions — Quick Jump

Q1 (p. 700)	*Q2 (p. 700)*	*Q3 (p. 701)*	*Q4 (p. 701)*	*Q5 (p. 702)*	*Q6 (p. 702)*
Q7 (p. 702)	*Q8 (p. 703)*	*Q9 (p. 703)*	*Q10 (p. 703)*	*Q11 (p. 704)*	*Q12 (p. 704)*
Q13 (p. 705)	*Q14 (p. 706)*	*Q15 (p. 706)*	*Q16 (p. 706)*	*Q17 (p. 707)*	*Q18 (p. 707)*
Q19 (p. 707)	*Q20 (p. 708)*	*Q21 (p. 708)*	*Q22 (p. 709)*	*Q23 (p. 710)*	*Q24 (p. 710)*
Q25 (p. 710)	*Q26 (p. 711)*	*Q27 (p. 711)*	*Q28 (p. 712)*	*Q29 (p. 712)*	*Q30 (p. 713)*
Q31 (p. 714)	*Q32 (p. 714)*	*Q33 (p. 715)*	*Q34 (p. 715)*	*Q35 (p. 716)*	*Q36 (p. 717)*
Q37 (p. 717)	*Q38 (p. 718)*	*Q39 (p. 719)*	*Q40 (p. 719)*	*Q41 (p. 720)*	*Q42 (p. 720)*
Q43 (p. 721)	*Q44 (p. 721)*	*Q45 (p. 721)*	*Q46 (p. 722)*	*Q47 (p. 722)*	*Q48 (p. 723)*
Q49 (p. 723)	*Q50 (p. 723)*	*Q51 (p. 724)*	*Q52 (p. 724)*	*Q53 (p. 724)*	*Q54 (p. 725)*
Q55 (p. 726)	*Q56 (p. 726)*	*Q57 (p. 727)*	*Q58 (p. 727)*	*Q59 (p. 727)*	*Q60 (p. 728)*
Q61 (p. 728)	*Q62 (p. 728)*	*Q63 (p. 729)*	*Q64 (p. 730)*	*Q65 (p. 730)*	*Q66 (p. 730)*
Q67 (p. 731)	*Q68 (p. 731)*	*Q69 (p. 732)*	*Q70 (p. 732)*	*Q71 (p. 732)*	*Q72 (p. 733)*
Q73 (p. 733)	*Q74 (p. 733)*	*Q75 (p. 734)*	*Q76 (p. 734)*	*Q77 (p. 735)*	*Q78 (p. 735)*
Q79 (p. 736)	*Q80 (p. 736)*	*Q81 (p. 737)*	*Q82 (p. 737)*	*Q83 (p. 737)*	*Q84 (p. 738)*
Q85 (p. 738)	*Q86 (p. 739)*	*Q87 (p. 739)*	*Q88 (p. 739)*	*Q89 (p. 740)*	*Q90 (p. 740)*
Q91 (p. 741)	*Q92 (p. 741)*	*Q93 (p. 741)*	*Q94 (p. 742)*	*Q95 (p. 742)*	*Q96 (p. 743)*
Q97 (p. 743)	*Q98 (p. 743)*	*Q99 (p. 744)*	*Q100 (p. 744)*		

Q1: Where is the site of the lesion that leads to the occurrence of hemiballismus in a patient displaying forceful, flinging movements? (Q855718)

A. Putamen

B. Subthalamic nucleus

C. Caudate nucleus

D. Globus pallidus

See Answer in Part B → Q1

@Neet_pg_bot

Q2: A 45 year old male patient presented with a history of bilateral lower limb weakness which progressed to his upper limbs in a year. On examination, he had weakness in both lower limbs and wasting in the left upper limb. Babinski sign was positive and the deep tendon reflexes were absent. He has no sensory loss or any autonomic dysfunction. What is the likely diagnosis? (Q856621)

A. MS

B. ALS

C. GBS

D. Tropical spastic paraparesis

See Answer in Part B → Q2

@Neet_pg_bot

Q3: Which of the following drugs is preferred in the management of primary progressive multiple sclerosis? (Q856612)

A. Natalizumab

B. Ocrelizumab

C. Fingolimod

D. Alemtuzumab

See Answer in Part B → Q3

@Neet_pg_bot

Q4: Treatment of choice for an acute attack of cluster headache is: (Q856604)

A. Oral sumatriptan

B. Subcutaneous sumatriptan

C. 100% oxygen at 6 L/minute

D. 100% oxygen at 8 L/minute

See Answer in Part B → Q4

@Neet_pg_bot

Q5: A 50-year-old man presents with sudden right-sided weakness and aphasia for 2 hours. His blood pressure is 160/110 mmHg, and non-contrast CT of the brain is normal. To identify a possible large vessel occlusion, what is the next best step in management? (Q856595)

A. CT angiography

B. MRI to look for intact

C. Tab labetalol 10 mg stat

D. Thrombolysis

See Answer in Part B → Q5

@Neet_pg_bot

Q6: True about electroencephalogram (EEG) is all except: (Q855720)

A. 1-5% of the population can have epileptiform discharges

B. Scalp EEG may be helpful in localizing frontal lobe epilepsy

C. Doing EEG is mandatory for diagnosis of seizures

D. Progressive multifocal leukoencephalopathy shows triphasic and slow waves on EEG

See Answer in Part B → Q6

@Neet_pg_bot

Q7: Which of the following does not show both hyperkinetic and hypokinetic movements? (Q855708)

A. Parkinson’s disease

B. Wilson’s disease

C. Neurodegeneration with brain iron accumulation

D. Huntington’s chorea

See Answer in Part B → Q7

@Neet_pg_bot

Q8: Which of the following is not a major diagnostic criterion for neuromyelitis optica? (Q855707)

A. Area postrema syndrome

B. Acute myelitis

C. Focal epilepsy

D. Optic neuritis

See Answer in Part B → Q8

@Neet_pg_bot

Q9: What is the GCS of a patient with a head injury who opens her eyes in response to a loud voice, localizes pain and is confused and disoriented but can answer questions? (Q857650)

A. E3 M5 V4

B. E3 M6 V5

C. E4 M4 V5

D. E3 M5 V5

See Answer in Part B → Q9

@Neet_pg_bot

Q10: A 55-year-old woman is diagnosed with a slow-growing, well-circumscribed meningioma on MRI. She has mild headaches but no major neurological deficits. Histopathology confirms a WHO Grade I meningioma. What is the treatment of choice for this patient? (Q857040)

A. Reassurance

B. Surgical excision

C. Chemotherapy

D. Radiotherapy

See Answer in Part B → Q10

@Neet_pg_bot

Q11: A 20 year old male was brought for psychiatric evaluation for intellectual disability. On examination, his IQ was 45. He has a long face, large ears, large testis and a cardiac murmur and history of poor intellectual function is present in the paternal family. What is his diagnosis? (Q857039)

A. Cushing's syndrome

B. Rett syndrome

C. Fragile X syndrome

D. William syndrome

See Answer in Part B → Q11

@Neet_pg_bot

Q12: The following clinical examination was performed. What lesion would cause an exaggerated reflex? (Q855348)

A. Polyneuropathy

B. Radiculopathy

C. Upper motor neuron

D. Lower motor neuron

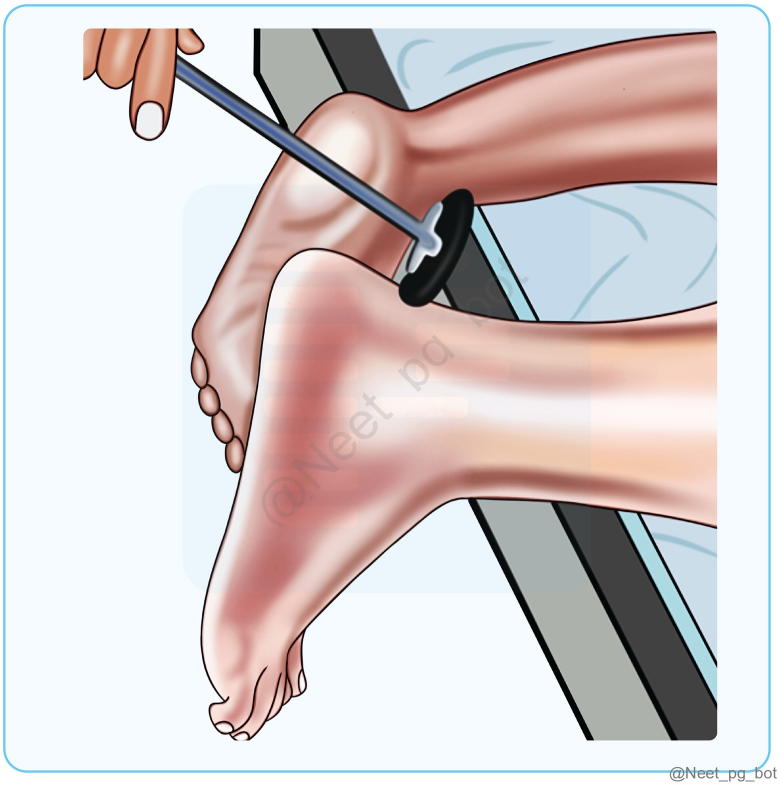

See Answer in Part B → Q12

@Neet_pg_bot

Q13: Which of the following is not characteristic of Brown Sequard syndrome? (Q855338)

A. Complete transection of spinal cord

B. Ipsilateral loss of vibration & touch

C. Contralateral loss of pain & temperature

D. Ipsilateral loss of proprioception

See Answer in Part B → Q13

@Neet_pg_bot

Q14: A 37-year-old woman presents with headaches for 6 months. She has been taking analgesics regularly. The headache recently increased in severity for 3 days but was reduced by stopping the analgesic. What is the likely diagnosis? (Q856148)

A. Medication overuse headache

B. Tension headache

C. Chronic migraine

D. Cluster headache

See Answer in Part B → Q14

@Neet_pg_bot

Q15: A 50-year-old male patient presented with left-sided hemiparesis. Damage to which part of the internal capsule leads to this presentation? (Q855714)

A. Retrolentiform

B. Sublentiform

C. Anterior limb

D. Posterior limb

See Answer in Part B → Q15

@Neet_pg_bot

Q16: Bell's palsy involves: (Q858357)

A. Ipsilateral upper and lower halves of the face

B. Contralateral upper and lower halves of the face

C. Ipsilateral lower half of the face

D. Contralateral lower half of the face

See Answer in Part B → Q16

@Neet_pg_bot

Q17: A young male patient presents with ptosis and muscle weakness which reportedly worsens in the evening and improves in the morning. This is relieved by neostigmine. What is the likely diagnosis? (Q858354)

A. Myasthenia gravis

B. Huntington chorea

C. Amyotrophic lateral sclerosis

D. External ophthalmoplegia

See Answer in Part B → Q17

@Neet_pg_bot

Q18: A young male patient presents with ptosis and muscle weakness which reportedly worsens in the evening and improves in the morning. This is relieved by neostigmine. What is the likely diagnosis? (Q858037)

A. Myasthenia gravis

B. Huntington chorea

C. Amyotrophic lateral sclerosis

D. External ophthalmoplegia

See Answer in Part B → Q18

@Neet_pg_bot

Q19: A woman presents with a history of headaches for the past 9 months that worsen in a recumbent position and improves as the day progresses. She also gives a history of taking oral contraceptives. Fundal examination shows papilledema. There are no focal

neurological deficits. What is the probable cause of her headaches? (Q858028)

A. Myasthenia gravis

B. Temporal arteritis

C. Chronic migraine

D. Pseudotumor cerebri

See Answer in Part B → Q19

@Neet_pg_bot

Q20: A 26-year-old male with a history of respiratory tract infection 4 weeks ago is unable to stand or walk for the past 2 weeks and the weakness is progressive, ascending, and symmetrical in nature. The lower limbs were involved before and gradually the upper limbs were also affected. On examination you note areflexia. Pain and proprioception are preserved. Which of the following could be the diagnosis? (Q858017)

A. Guillain-Barré syndrome

B. Myasthenia gravis

C. Polymyositis

D. Multiple sclerosis

See Answer in Part B → Q20

@Neet_pg_bot

Q21: A young patient presents with a severe headache. He has never experienced a headache of this severity before. He has hypertension and nuchal rigidity on examination. Which of the following could be the diagnosis? (Q858014)

A. Cluster headache

B. Subarachnoid haemorrhage

C. Encephalitis

D. Meningitis



See Answer in Part B → Q21

@Neet_pg_bot

Q22: A patient presented with a fever for 11 days with neck rigidity. A lumbar puncture was done, and it showed predominantly lymphocytes, sugar- 50mg, and protein- 3000mg/dl. Cobweb coagulum was noted. Gram-staining was negative. The patient's chest X-ray shows upper lobe involvement with hilar lymph node enlargement. (Q858012)

A. Tuberculous meningitis

B. Bacterial meningitis

C. Fungal meningitis

D. Viral meningitis

See Answer in Part B → Q22

@Neet_pg_bot

Q23: A 78-year-old woman presents with a progressive decline in daily activity. She gives a history of convulsions and visual hallucinations. She does not talk to anyone and keeps looking at the sky. Pathological examination shows the presence of Lewy bodies within the neurons. What is the most probable diagnosis? (Q855496)

A. Parkinson's disease

B. Prion disease

C. Huntington's chorea

D. Alzheimer's disease

See Answer in Part B → Q23

@Neet_pg_bot

Q24: A young female presents with ptosis showing diurnal variation. CT chest shows an anterior mediastinal mass identified as thymus gland cancer. Which receptor is affected in this patient? (Q866790)

A. Presynaptic ACh Receptor

B. Post-synaptic ACh Receptor

C. Voltage-gated calcium channels at the NMJ

D. Acetylcholinesterase

See Answer in Part B → Q24

@Neet_pg_bot

Q25: A male patient presented to the emergency room with seizures. He has a history of fever, headache, and confusion. An MRI brain was done, and it showed inflammation involving the bitemporal lobe. What is the most likely etiology for this presentation? (Q855465)

A. Cytomegalovirus

B. Toxoplasma gondii

C. Herpes simplex virus

D. Mycobacterium tuberculosis

See Answer in Part B → Q25

@Neet_pg_bot

Q26: Visual field testing of a patient revealed the following type of loss. Where is the likely site of lesion in the optic pathway? (Q859569)

A. Frontal visual field

B. Occipital lobe

C. Optic radiation

D. Optic chiasma

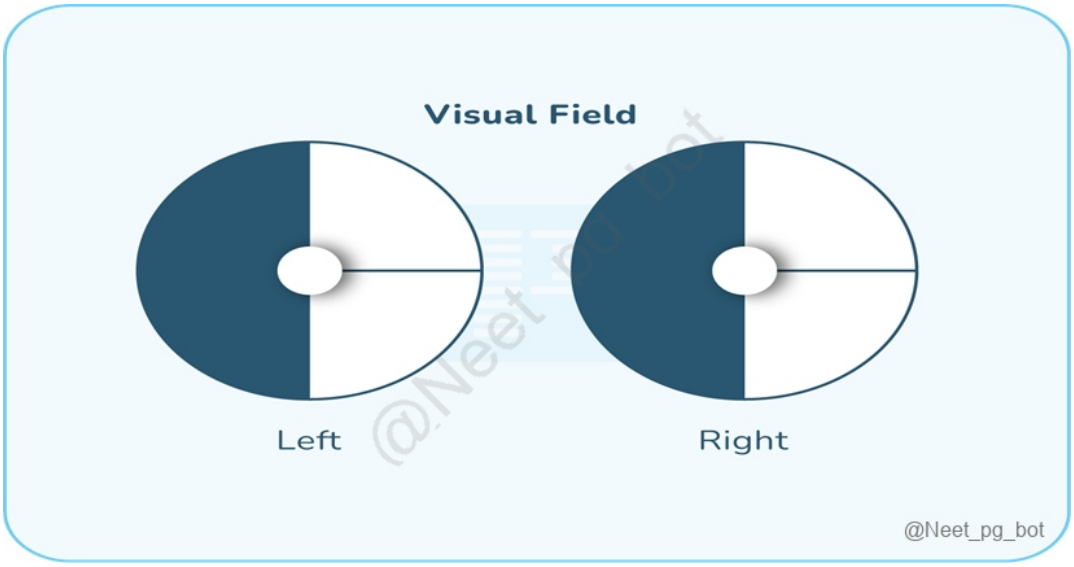

See Answer in Part B → Q26

@Neet_pg_bot

Q27: A Patient presents with progressive back pain and weakness in both lower limbs. Which findings would support the diagnosis of compressive myelopathy? (Q879162)

A. Hypotonia

B. Absent Babinski sign

C. Knee clonus

D. Normal cremasteric reflex

See Answer in Part B → Q27

@Neet_pg_bot

Q28: Which one of the following drugs is NOT indicated in the management of status epilepticus? Valproate Ethosuximide Fosphenytoin Levetiracetam (Q879159)

A. 1, 2

B. 2, 3

C. 2, 4

D. 1, 3, 4

See Answer in Part B → Q28

@Neet_pg_bot

Q29: A female patient presents to you with a unilateral headache. It is associated with nausea, photophobia, and phonophobia. What is the drug of choice for acute management? (Q855890)

A. Flunarizine

B. Sumatriptan

C. Propranolol

D. Topiramate

See Answer in Part B → Q29

@Neet_pg_bot

Q30: The cerebrospinal fluid (CSF) specimen of a patient is shown below, along with microscopy. The report shows mononuclear cytosis, elevated proteins, and low sugars. What is the likely etiology? (Q855849)

A. Tuberculous meningitis

B. Aseptic meningitis

C. Bacterial meningitis

D. Chemical meningitis



@Neet_pg_bot

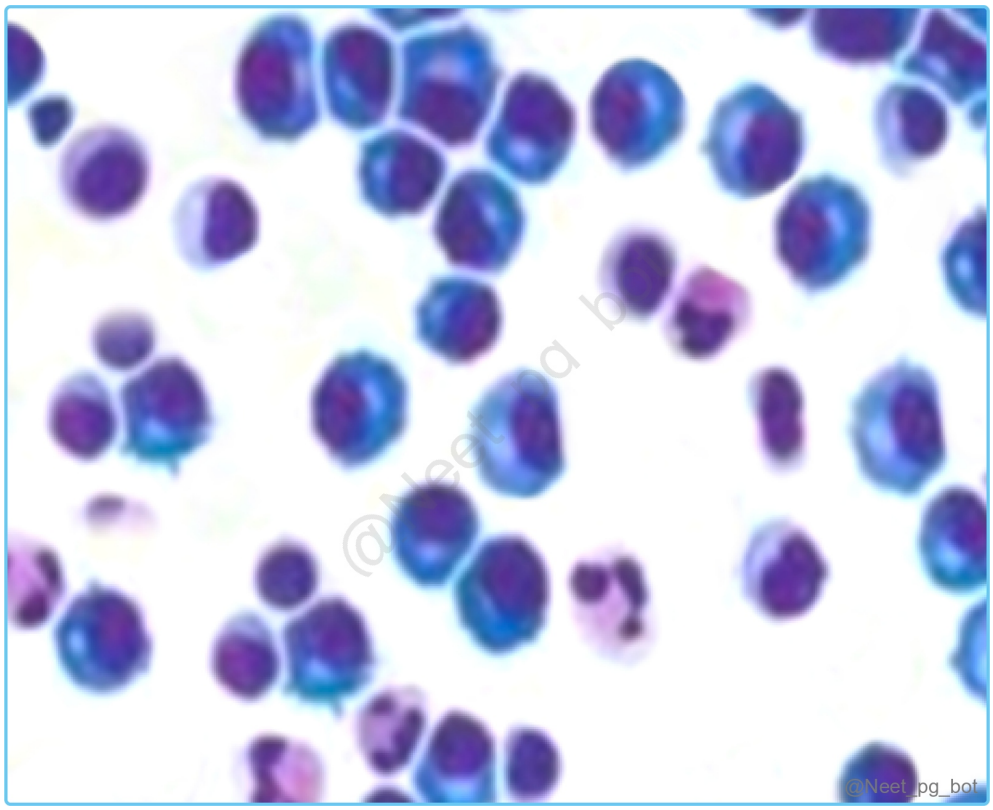

See Answer in Part B → Q30

@Neet_pg_bot

Q31: Which of the following is the most important pathophysiological mechanism for Berry aneurysm? (Q859807)

A. Endothelial injury of vessel due to HTN

B. Muscle intimal elastic lamina layer defect

C. Endothelial layer defect

D. Adventitia defect

See Answer in Part B → Q31

@Neet_pg_bot

Q32: Which of the following statements about tremors are true? PD is characterized by resting tremor Tremor consist of alternate contraction of agonist and antagonist muscle in an oscillating rhythmic manner Essential tremor is an uncommon movement disorder. Normal individuals can have physiologic tremors that manifest as mild high frequency, postural or action tremors (Q859801)

A. 1,2,3 only

B. 2,3,4 only

C. 1,2,4 only

D. All of the above

See Answer in Part B → Q32

@Neet_pg_bot

Q33: A 60-year-old woman presents with weakness in right arm for 6 hours. The weakness gradually became lesser and later resolved. She is a known case of diabetes and hypertension and is obese. Which of the following is the probable diagnosis of this case? (Q859797)

A. Compressive neuropathy

B. Transient ischaemic attack

C. Ischaemic stroke

D. Diabetic neuropathy

See Answer in Part B → Q33

@Neet_pg_bot

Q34: A patient who is 66 years old and has a history of chronic hypertension, arrives at the emergency room with changes in mental state and high blood pressure measuring 210/110 mm Hg. A brain CT scan shows bleeding within the brain tissue. The typical location of this bleeding in similar cases is? (Q859794)

A. Putamen

B. Thalamus

C. Pons

D. Cerebellum

See Answer in Part B → Q34

@Neet_pg_bot

Q35: A patient was asked to copy the face of a clock and his drawing is shown below. What is the correct term to be used here? (Q859790)

A. Confabulation

B. Hemispatial neglect

C. Kinetic apraxia

D. Asterixis

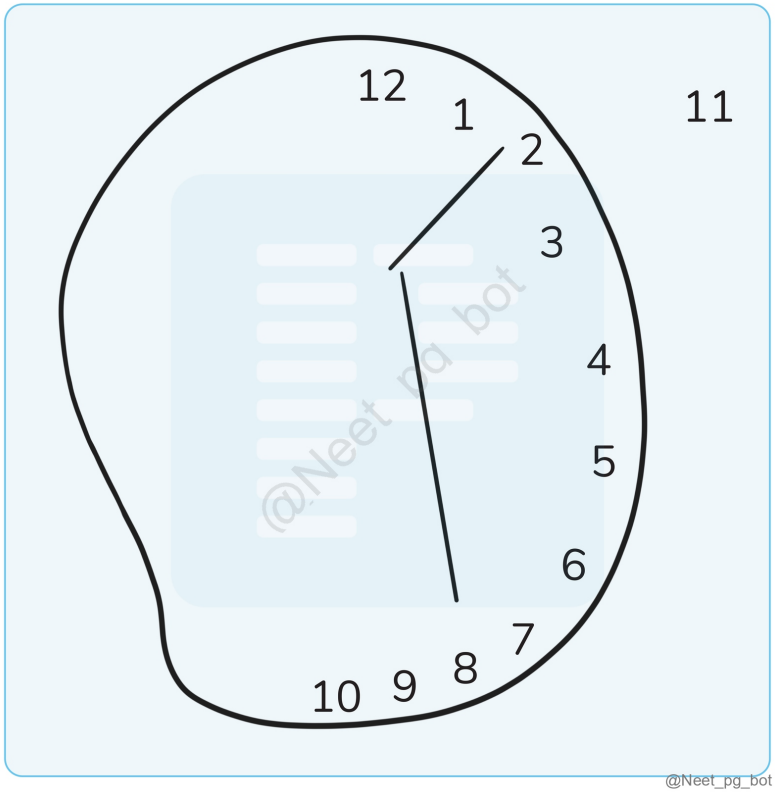

See Answer in Part B → Q35

Q36: A 28-year-old patient develops rapid-onset psychiatric symptoms such as anxiety, depression, and personality changes, which are soon followed by ataxia and cognitive decline. The FLAIR MRI (shown below) demonstrates characteristic findings. What is the most likely diagnosis? (Q859752)

A. Alzheimer's disease

B. Vascular dementia

C. Sporadic CJD

D. Variant CJD

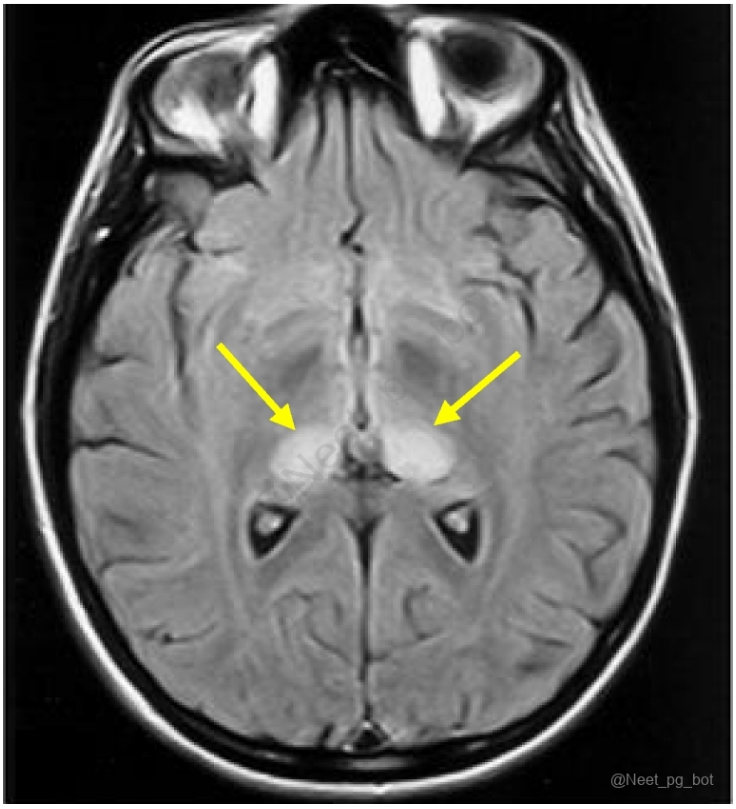

See Answer in Part B → Q36

Q37: What is the most probable cause for a 22-year-old man who has a high-grade fever, a purpuric rash, and a CSF sample showing gram-negative diplococci? (Q859751)

A. Neisseria meningitidis

B. Pseudomonas aeruginosa

C. Streptococcus pneumoniae

D. E.coli



See Answer in Part B → Q37

@Neet_pg_bot

Q38: A male patient presents with sensory loss and weakness of limbs for 3 months. He also has angular stomatitis. On examination, there is loss of proprioception, vibration sensations, UMN-type lower limb weakness, and absent ankle reflex. What is the most probable diagnosis? (Q855473)

A. Extradural cord compression

B. Amyotrophic lateral sclerosis

C. Multiple sclerosis

D. Subacute combined degeneration of the cord

See Answer in Part B → Q38

@Neet_pg_bot

Q39: A 28-year-old male was brought to the emergency room with a history of RTA. GCS progressively declines over hours and axial T2 MRI shows multiple small hypointense lesions at the corticomedullary junction and basal ganglia. What is the diagnosis? (Q859567)

A. Diffuse axonal injury

B. Extensive subarachnoid haemorrhage

C. Hypoxic cerebral injury

D. Multiple haemorrhagic contusion

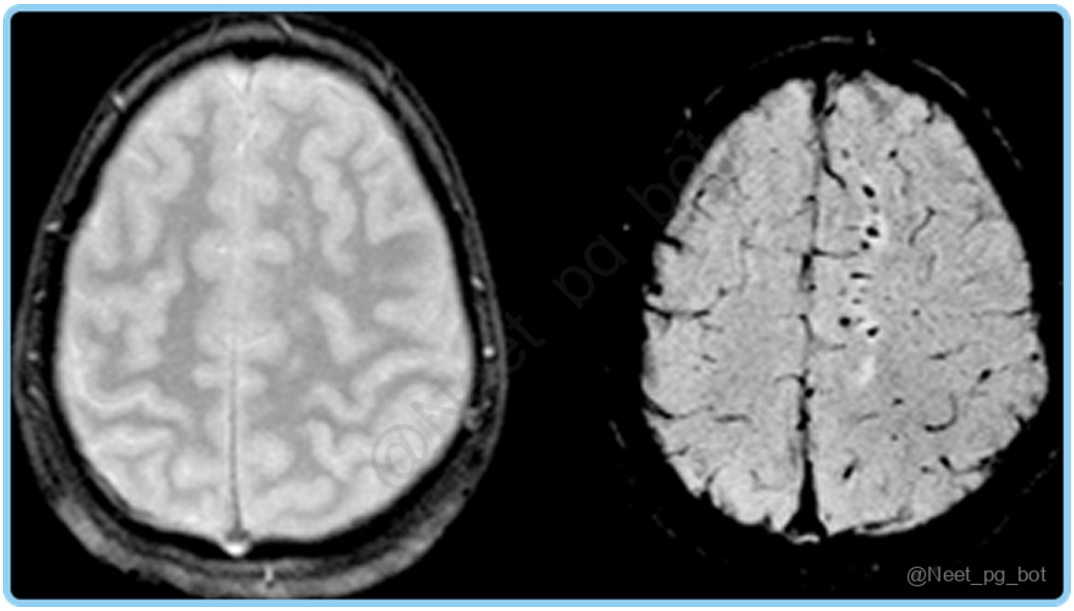

See Answer in Part B → Q39

@Neet_pg_bot

Q40: Which type of aphasia is seen in the lesions of the posterior part of the superior temporal gyrus? (Q858441)

A. Fluent

B. Non-fluent

C. Anomic

D. Conduction

See Answer in Part B → Q40

@Neet_pg_bot

Q41: An elderly woman is brought to the OPD with complaints of behavioural change, a history of multiple falls, urinary incontinence, and dementia. What is your diagnosis? (Q858429)

A. Normal pressure hydrocephalus

B. Frontotemporal dementia

C. Parkinson disease

D. Creutzfeldt-Jakob disease

See Answer in Part B → Q41

@Neet_pg_bot

Q42: A lesion at which level produces incongruous homonymous hemianopia with Wernicke's pupil? (Q855068)

A. Optic tract

B. Visual cortex

C. Optic radiation

D. Optic nerve

See Answer in Part B → Q42

@Neet_pg_bot

Q43: Which of the following causes the slowing of conduction in multiple sclerosis? (Q855012)

A. Gliosis

B. Loss of myelin sheath

C. Defect at node of Ranvier

D. Leaky Na + channel

See Answer in Part B → Q43

@Neet_pg_bot

Q44: In hemiplegia caused by an ischemic stroke, which region of the internal capsule is impacted? (Q856288)

A. Retrolentiform

B. Sublentiform

C. Anterior limb

D. Posterior limb

See Answer in Part B → Q44

@Neet_pg_bot

Q45: A 32-year-old woman who visits the clinic with complaints of frequent falls and walking difficulties. She also has a history of smoking and type-1 diabetes but no history of hypertension or coronary artery disease. During examination, the patient exhibits weakness in both lower limbs, absent DTR, as well as an unsteady gait. But, there is a decrease in proprioception and vibration sense in both lower limbs. Which

of the following statements is correct about the above condition? (Q856263)

A. Only the dorsal column is involved

B. All these patients with a neurological impairment will show macrocytosis

C. Vitamin B12 supplements do not improve this condition

D. Copper deficiency may produce similar symptoms

See Answer in Part B → Q45

@Neet_pg_bot

Q46: Calculate the GCS Score in an intubated patient, with findings of eye movements to pain and abnormal flexion? (Q857028)

A. E2VTM4

B. E2VTM3

C. E2VIM3

D. E2VNTM3

See Answer in Part B → Q46

@Neet_pg_bot

Q47: Which of the following arteries could have been involved in a patient who presents with vertigo, diplopia, hoarseness, dysphagia, left Horner's syndrome, and numbness in the left face and right side limbs? (Q856941)

A. Posterior inferior cerebellar artery

B. Superior cerebellar artery

C. Anterior inferior cerebellar artery

D. Basilar artery

See Answer in Part B → Q47

@Neet_pg_bot

Q48: Which of the following options has not been used as treatment for Guillain Barre syndrome? (Q856925)

A. Steroids

B. Plasmapheresis

C. IVIG

D. Ventilator support

See Answer in Part B → Q48

@Neet_pg_bot

Q49: A 30-year-old man presented with excessive fatiguability towards the end of the day that improved with rest. He also gives a history of ptosis and difficulty in speech and swallowing. What is the most likely diagnosis? (Q856190)

A. Myasthenia gravis

B. Lambert-Eaton syndrome

C. Duchenne muscular dystrophy

D. Systemic lupus erythematosus

See Answer in Part B → Q49

@Neet_pg_bot

Q50: Patient came with fever headache and nuchal rigidity. LP shows gram negative diplococci in gram stain. Which of the following will be used for chemoprophylaxis in close contacts of a patient with meningococcal meningitis? (Q866451)

A. Amoxicillin

B. Doxycycline

C. Ethambutol

D. Rifampicin

See Answer in Part B → Q50

@Neet_pg_bot

Q51: A patient had features of resting tremors, bradykinesia, and postural instability. He became bedridden and died due to respiratory failure. A brain biopsy is likely to show which of the following? (Q860433)

A. Lewy bodies

B. Hirano bodies

C. Guarneri bodies

D. Negri bodies

See Answer in Part B → Q51

@Neet_pg_bot

Q52: Seizures are seen in what percentage of RTA patients with brain contusion/loss of consciousness? (Q860388)

A. Development of seizures in 17%

B. Development of seizures in 45%

C. Development of seizures in 75%

D. No relation between trauma and seizures

See Answer in Part B → Q52

@Neet_pg_bot

Q53: What is the confirmatory test for the above condition? (Q844325)

A. CBNAAT of CSF

B. PET Scan

C. NMR Spectroscopy

D. MRI aerial scan

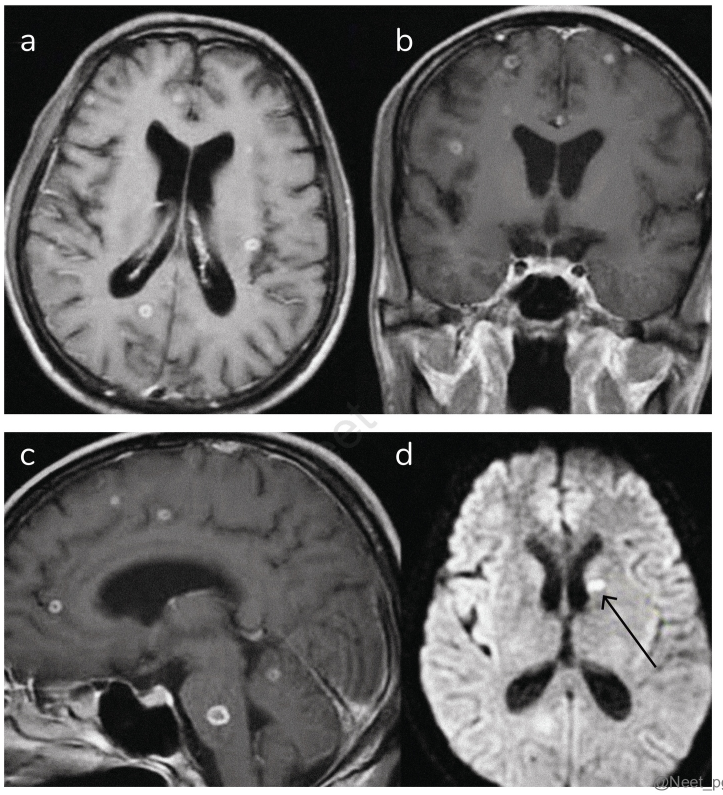

See Answer in Part B → Q53

@Neet_pg_bot

Q54: Patient is having a headache and confusion. A brain tumor diagnosis is made. Family history reveals brain and kidney tumors. Choose the correct option: (Q844242)

A. Neurofibromatosis

B. Li fraumeni syndrome

C. VHL Syndrome

D. Churg strauss syndrome

See Answer in Part B → Q54

@Neet_pg_bot

Q55: A 62-year-old patient presents with left-sided arm and leg weakness, right-sided facial paralysis, and difficulty with horizontal eye movements. Based on the clinical presentation, which of the following syndromes is most consistent with these symptoms? (Q844211)

A. Foville syndrome

B. Benedict's syndrome

C. Millard-Gubler syndrome

D. Wallenberg syndrome

See Answer in Part B → Q55

@Neet_pg_bot

Q56: A 35-year-old woman presents with fluctuating muscle weakness, especially affecting her speech and swallowing. Repetitive nerve stimulation shows a decremental response. Her blood tests are negative for acetylcholine receptor (AChR) antibodies. Which of the following antibodies is most likely responsible for her symptoms? (Q852752)

A. Anti-dsDNA antibodies

B. Anti-MuSK antibodies

C. Anti-TPO antibodies

D. Anti-Ro antibodies

See Answer in Part B → Q56

@Neet_pg_bot

Q57: The CSF findings in bacterial meningitis would include which of the following? (Q852676)

A. Elevated protein and decreased glucose

B. Normal white blood cell count

C. Decreased protein and elevated glucose

D. Elevated WBC count with normal glucose

See Answer in Part B → Q57

@Neet_pg_bot

Q58: In children with Guillain-Barré Syndrome (GBS), all are true except? (Q853356)

A. Areflexia of the affected limb is a mandatory diagnostic criteria

B. Plasmapheresis is not preferred in refractory cases

C. Intravenous immunoglobulin is the first line of management

D. Albuminocytological dissociation in CSF is characteristic

See Answer in Part B → Q58

@Neet_pg_bot

Q59: LMN (Lower Motor Neuron) lesions are associated with which of the following? Decrease in muscle tone Spastic paralysis Babinski positive Fasciculations (Q853351)

A. 1, 2

B. 1, 4

C. 1, 2, 3, 4

D. 1, 2, 3

See Answer in Part B → Q59

@Neet_pg_bot

Q60: A patient presented with a blood pressure of 220/120 mmHg in an altered sensorium. He also had an episode of vomiting and a history of weakness on the left side of his body. Which of the following is incorrect regarding hypertensive management in this case? (Q853346)

A. In hemorrhagic stroke, reduce the BP to less than 160/100 mmHg with antihypertensives to prevent rebleed

B. In hemorrhagic stroke, aggressive use of IV antihypertensive if SBP > 220

C. In the ER, multiple blood pressure readings should be taken before starting antihypertensive therapy

D. In ischemic stroke, BP should be reduced to <140/90 mmHg immediately

See Answer in Part B → Q60

@Neet_pg_bot

Q61: A patient presents with sudden-onset aphasia and right-sided arm weakness for the past 4 hours. After stabilizing the patient and confirming the diagnosis of ischemic stroke with urgent neuroimaging, which investigation is most appropriate to determine the etiology of this stroke? (Q866491)

A. Transthoracic echocardiography (TTE)

B. Carotid doppler

C. Transesophageal echocardiography (TEE)

D. MRI brain

See Answer in Part B → Q61

@Neet_pg_bot

Q62: Patient came with severe headache and seizures. Sodium on admission was 98 meq/L. We have started correction with 3% saline and now after 24 hours of infusion

sodium is 110 meq/L. Patient develops mutism and altered sensorium. Which investigation will you perform now? (Q866483)

A. MRI Head

B. LP for CSF biochemistry

C. Brainstem evoked potentials

D. EEG

See Answer in Part B → Q62

@Neet_pg_bot

Q63: The patient is having the following hand movements. In which of the following conditions would this be seen? (Q860476)

A. Thyrotoxicosis

B. Hypercarbia

C. Hemiballismus

D. Hypoxia

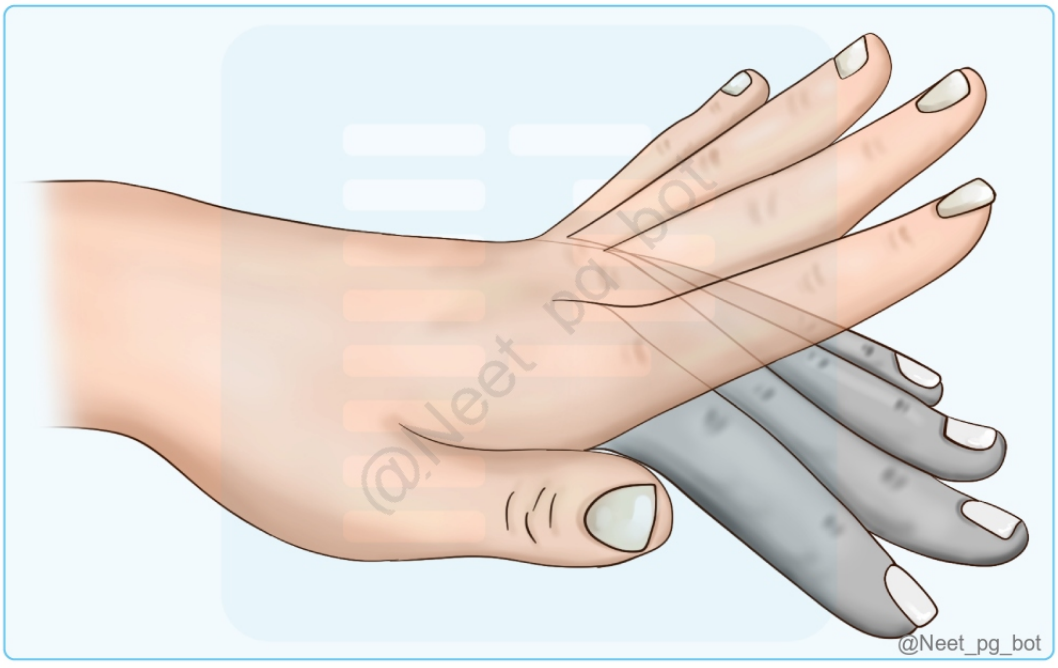

See Answer in Part B → Q63

@Neet_pg_bot

Q64: A 30-year-old female with seizures was prescribed carbamazepine & erythromycin. A few days later, she developed ataxia. What is the most likely cause of her symptoms? (Q865385)

A. Carbamazepine toxicity

B. Erythromycin toxicity

C. Worsening of the underlying disease

D. A separate, unrelated neurological condition

See Answer in Part B → Q64

@Neet_pg_bot

Q65: Which of the following statements about Multiple Sclerosis (MS) is incorrect? (Q865373)

A. 70% of patients with MS develop optic neuritis during course of illness

B. Oral steroids are given for acute relapses

C. Loss of color perception and depth perception is proportional to visual loss

D. Examination of fundus can be normal and can show papillitis

See Answer in Part B → Q65

@Neet_pg_bot

Q66: A 65-year-old known case of Parkinson's disease presents with oropharyngeal dysphagia and recurrent episodes of aspiration pneumonitis, complaints of excessive respiratory secretions. Chest imaging reveals bilateral bronchiectasis. What is the most appropriate long-term management for this patient? (Q865367)

A. High-frequency chest wall oscillation therapy

B. Nebulized N-acetylcysteine (NAC) to reduce secretions

C. PEG tube placement

D. Macrolide therapy

See Answer in Part B → Q66

@Neet_pg_bot

Q67: A 20-year-old male presents with severe headache, vomiting & photophobia. On examination, neck rigidity and Brudzinski's sign are positive. A CT scan of the brain shows hydrocephalus and no haemorrhage. CSF examination is normal. What is the most likely diagnosis? (Q865322)

A. Normal Pressure Hydrocephalus

B. Bacterial Meningitis

C. Viral Encephalitis

D. Subarachnoid Haemorrhage

See Answer in Part B → Q67

@Neet_pg_bot

Q68: Which of the following is one of the earliest presenting symptoms in a patient with Multiple Sclerosis? (Q865298)

A. Sensory disturbances

B. Ataxia

C. Vertigo

D. Facial palsy

See Answer in Part B → Q68

@Neet_pg_bot

Q69: A patient presents with contralateral face, arm, and leg weakness. NCCT shows intracerebral hemorrhage (ICH). What is the most likely location of the CNS bleed? (Q866823)

A. Basal ganglia

B. Midbrain

C. Pons

D. Medulla

See Answer in Part B → Q69

@Neet_pg_bot

Q70: The infant is being evaluated for recurrent episodes of seizures. ECG shows Hypsarrhythmia. Which drug is preferred for management? (Q866822)

A. ACTH

B. Vigabatrin

C. Valproate

D. Carbamazepine

See Answer in Part B → Q70

@Neet_pg_bot

Q71: A patient had a road traffic accident (RTA). NCCT head was normal on admission. The patient later died after several days in the ICU due to coma. Brain biopsy revealed multiple punctate hemorrhages. What is the diagnosis? (Q866814)

A. Ischemic injury

B. Diffuse axonal injury

C. Intraventricular bleeding

D. Subdural hemorrhage

See Answer in Part B → Q71

@Neet_pg_bot

Q72: What is the probable diagnosis for a patient who exhibits miosis, anhidrosis, mild ptosis, and a persistent small pupil even in low light conditions? (Q866808)

A. Adie’s tonic people

B. Horner syndrome

C. Marcus Gunn pupil

D. Argyll Robertson pupil

See Answer in Part B → Q72

@Neet_pg_bot

Q73: A 30-year-old male presents with deep-seated retro-orbital pain of cluster headache. What is the best management? (Q866802)

A. Verapamil

B. Oxygen

C. Lithium

D. Topiramate

See Answer in Part B → Q73

@Neet_pg_bot

Q74: A patient presents with symmetrical leg weakness and areflexia. He had developed diarrhoea 2 weeks ago. He was diagnosed as having GBS. What is the cause? (Q866792)

A. Demyelination of A, B-fibers

B. Demyelination of B-fibers

C. Demyelination of the spinal cord

D. Cord inflammation

See Answer in Part B → Q74

@Neet_pg_bot

Q75: A 35-year-old female with progressive limb weakness for the past 1 year. On examination, muscle fasciculations and hypertonia are noted, and the sensory system is intact. What is the diagnosis? (Q866791)

A. ALS

B. Spinal muscular atrophy

C. Multifocal motor neuropathy

D. Becker muscular dystrophy

See Answer in Part B → Q75

@Neet_pg_bot

Q76: A 60 year old man present with sudden onset of right sided hemiparesis for last 3 hours. BP is 200/100 mmHg. NCCT Head showed brain bleed and right hemiparesis. All of the following are to be done for management, Except? (Q820357)

A. Thrombolysis

B. BP Control

C. Edema management

D. Elective hyperventilation

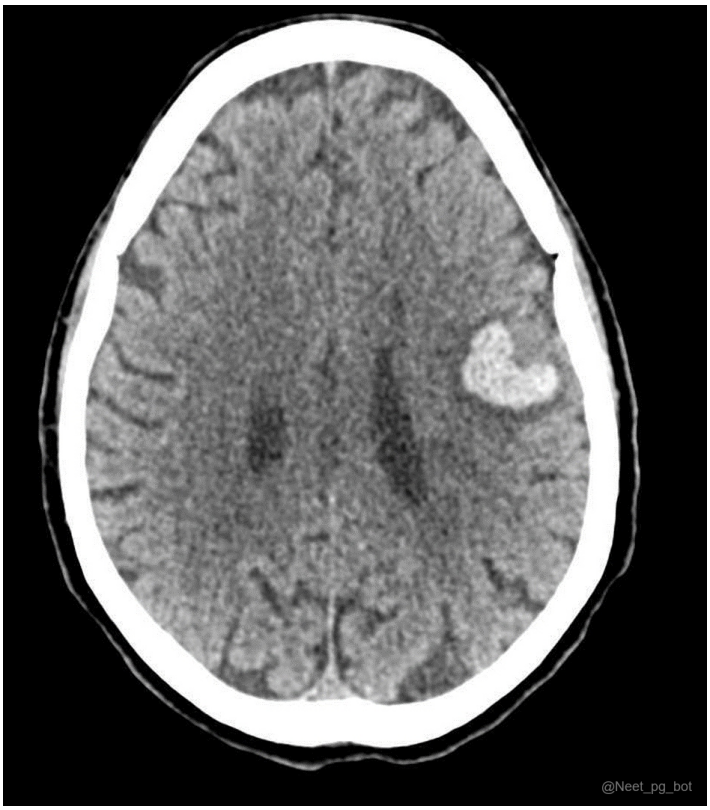

See Answer in Part B → Q76

@Neet_pg_bot

Q77: A stroke patient presents with an inability to identify objects but can determine the colour, texture, and shape of objects. Which of the following lobes is involved? (Q854720)

A. Frontal lobe

B. Parietal lobe

C. Temporal lobe

D. Occipital lobe

See Answer in Part B → Q77

@Neet_pg_bot

Q78: A 30-year-old patient presents with high-grade fever for the past week. On examination neck stiffness and Kernig's sign were positive. CSF analysis showed lymphocytosis protein - 8 g/L, glucose - 20 mg/dl while RBS = 140 mg/dl. What is your diagnosis? (Q854684)

A. Tubercular meningitis

B. Coxsackie meningitis

C. Bacterial meningitis

D. HSV -1 encephalitis

See Answer in Part B → Q78

@Neet_pg_bot

Q79: Antibody seen in Acute Inflammatory Demyelinating Polyneuropathy will belong to which class? (Q820419)

A. Ig G

B. Ig M

C. Ig E

D. Ig A

See Answer in Part B → Q79

@Neet_pg_bot

Q80: In a patient diagnosed with Dialysis Dementia, what deposition is seen in the cerebral cortex? (Q820411)

A. Amyloid β■

B. Amyloid β■ microglobulin

C. Amyloid transthyretin

D. Amyloid β

See Answer in Part B → Q80

@Neet_pg_bot

Q81: Scissoring gait will occur due to increases firing of Which of the following nerve? (Q820407)

A. Superior gluteal nerve

B. Inferior gluteal nerve

C. Obturator nerve

D. Femoral nerve

See Answer in Part B → Q81

@Neet_pg_bot

Q82: 65-year-old man is brought to the hospital with complaints of suddenly not making any sense while speaking using non-sensical grammar though he can speak quickly. He could communicate effectively prior to this. Which of the following defect is present in this patient? (Q820399)

A. Motor aphasia

B. Anomic aphasia

C. Fluent aphasia

D. Conduction aphasia

See Answer in Part B → Q82

@Neet_pg_bot

Q83: A 50-year-old man presents with movement disorder and tremors in hand, along with the development of cognitive and emotional problems. Which of the following medical disorders is the likely diagnosis? (Q820387)

A. Parkinson's disease

B. Frederich's ataxia

C. Alzheimer’s disease

D. Huntington's disease

See Answer in Part B → Q83

@Neet_pg_bot

Q84: A 60-year-old patient weighing 80 kilograms has been diagnosed with an acute ischemic stroke and is recommended for thrombolysis with alteplase. What should the initial stat dose in milligrams be? (Q820359)

A. 8

B. 10

C. 12

D. 15

See Answer in Part B → Q84

@Neet_pg_bot

Q85: A patient is brought to the OPD by his wife complaining about difficulty in expressing emotions and not taking part in daily activities. On examination, resting tremors and rigidity are noted. Given the possible diagnosis, which part of the brain is affected in this patient? (Q855454)

A. Basal ganglia

B. Hippocampus

C. Cerebellum

D. Premotor cortex

See Answer in Part B → Q85

@Neet_pg_bot

Q86: An elderly patient was brought to the OPD with complaints of tremors, stoop posture and slow movements. His son also gives a history of the patient forgetting day to day activities. What is the possible cause of this condition? (Q857283)

A. Normal pressure hydrocephalus (NPH)

B. Hypothyroidism

C. Lewy body

D. Vitamin B12 deficiency

See Answer in Part B → Q86

@Neet_pg_bot

Q87: A 35-year-old male patient suffers from schizophrenia. He is currently receiving clozapine treatment. Why does he require frequent blood monitoring? (Q857278)

A. Agranulocytosis

B. Myocarditits

C. Cerebral bleed

D. Seizures

See Answer in Part B → Q87

@Neet_pg_bot

Q88: What is observed in the case of an abnormal accumulation of misfolded protein? (Q857270)

A. Creutzfeldt jakob disease

B. Nephritic syndrome

C. Sickle cell anemia

D. Megaloblastic anemia

See Answer in Part B → Q88

@Neet_pg_bot

Q89: A 30-year-old woman presents with ptosis, diplopia, and generalized muscle weakness that worsens with activity and improves with rest. She has difficulty chewing and swallowing, especially in the evening. A Tensilon test is positive. Which investigation is most likely to confirm the diagnosis? (Q860245)

A. CT scan of the chest

B. SFEMG

C. Anti-acetylcholine receptor antibody test

D. MRI of the brain

See Answer in Part B → Q89

@Neet_pg_bot

Q90: 25 year old HIV positive patient presents with autonomic dysreflexia and flaccid quadriplegia. The results of a lumbar puncture are as follows Opening Pressure: 150 mm water Cells: 5 lymphocytes/ cu.mm Sugar: 85 mg/dl (RBS 120 mg/dl) Protein: 100 mg/dl Color: normal Based on these findings, which of the following is the most likely diagnosis? (Q860235)

A. Cryptococcal meningitis

B. Transverse myelitis

C. Tuberculosis Meningitis

D. Acute inflammatory demyelinating polyneuropathy

See Answer in Part B → Q90

@Neet_pg_bot

Q91: A 30-year-old man experiences initial paralysis in both legs, which then progresses to affect both upper limbs as well. Over time, he shows slight improvement in upper limbs but no improvement in his lower trunk and both legs. Based on this description, what is the most likely diagnosis? (Q860213)

A. Diplegia

B. Quadriplegia

C. Paraplegia

D. Monoplegia

See Answer in Part B → Q91

@Neet_pg_bot

Q92: A lumbar puncture was performed on a patient in a sitting position, and the patient is now experiencing a very severe headache. Which of the following is NOT a recommended management strategy for a post-lumbar puncture headache? (Q860155)

A. Lie in a supine position

B. Administer intravenous caffeine

C. Restrict water intake

D. Perform a low-volume blood patch

See Answer in Part B → Q92

@Neet_pg_bot

Q93: A 30-year-old woman presents with a unilateral throbbing headache that worsens with exposure to bright light. She occasionally skips breakfast. What is the most likely diagnosis? (Q860148)

A. Hunger headache

B. Migraine

C. Tension headache

D. Cluster headache

See Answer in Part B → Q93

@Neet_pg_bot

Q94: A 16-year-old girl presents with generalized muscle weakness and protrusion of the eyelids (ptosis) that worsens as the day progresses. What is the most likely diagnosis? (Q860120)

A. Myasthenia Gravis

B. Fibromyalgia

C. Myotonic Dystrophy

D. Guillain-Barré Syndrome

See Answer in Part B → Q94

@Neet_pg_bot

Q95: All of the following is a risk factor for secondary headache and need further workup except? (Q840124)

A. 50 years old with first severe headache

B. Presence of cord-like vessels in the temporal area

C. Cocaine abuse

D. Subacute worsening of headache symptoms

See Answer in Part B → Q95

@Neet_pg_bot

Q96: A 45-year-old male presents to the outpatient department with complaints of daytime sleepiness and nighttime sleeplessness. His wife reports that he snores at night. Which of the following statements about his condition is incorrect? (Q840105)

A. The tone of the pharyngeal muscles is increased

B. Low oxygen saturation triggers waking up at night

C. Episodes of apnea increase stress on the heart

D. Low oxygen stimulates respiratory effort

See Answer in Part B → Q96

@Neet_pg_bot

Q97: Which of the following type of hypersensitivity reactions is seen in myasthenia gravis? (Q793907)

A. Type 1 hypersensitivity reaction

B. Type 2 hypersensitivity reaction

C. Type 3 hypersensitivity reaction

D. Type 4 hypersensitivity reaction

See Answer in Part B → Q97

@Neet_pg_bot

Q98: What is the diagnosis for a 24-year-old female patient who presents with fever, headache, ataxia, nausea, and vomiting for the past 3 days? The patient exhibits neck rigidity and hip and knee flexion upon passive flexion of the neck. A lumbar puncture was performed, and the CSF findings are provided below. Opening pressure – increased Color – cloudy white WBCs – 7000/µl; neutrophil predominant Sugar – 15 mg/dl CSF/serum glucose ratio – 0.2 Protein – 70 mg/dl Latex agglutination – positive Limulus lysate test – negative (Q793904)

A. Bacterial meningitis

B. Tubercular meningitis

C. Viral meningitis

D. Fungal meningitis

See Answer in Part B → Q98

@Neet_pg_bot

Q99: A patient with a unilateral hypoglossal nerve (CN XII) lesion is asked to protrude the tongue. What finding is expected? (Q793874)

A. Tongue deviation to the contralateral side

B. Tongue deviation to the same side

C. Falling of the tongue

D. Inability in tongue protrusion

See Answer in Part B → Q99

@Neet_pg_bot

Q100: A child is brought with a 2-week history of not feeding well and excessive irritability. History of TB for sister is present and is taking treatment for it. In workup, LP was performed. Which of the following is likely to be found in CSF? (Q820371)

A. Lymphocytosis, low sugar, and high protein

B. Lymphocytosis, high sugar, and high protein

C. Neutrophils, low sugar and low protein

D. Neutrophils, low sugar and high protein

See Answer in Part B → Q100

@Neet_pg_bot

• [08_Rheumatology] 060 Vasculitis Syndromes - I

« Back to Folder Directory

[08_Rheumatology] 060 Vasculitis Syndromes - I — Quick Jump

Q1 (p. 746)	*Q2 (p. 746)*	*Q3 (p. 747)*	*Q4 (p. 747)*	*Q5 (p. 748)*	*Q6 (p. 748)*
Q7 (p. 748)	*Q8 (p. 749)*	*Q9 (p. 749)*	*Q10 (p. 750)*	*Q11 (p. 750)*	*Q12 (p. 751)*
Q13 (p. 751)	*Q14 (p. 751)*	*Q15 (p. 752)*			

Q1: A 68-year-old female presents with a new-onset severe headache, scalp tenderness, and jaw pain while chewing. Laboratory investigations reveal ESR 85 mm/hr, CRP 45 mg/L, and mild normochromic anemia. A biopsy of the temporal artery shows panarteritis with inflammatory mononuclear cell infiltrates and giant cell formation. In the analysis of T cells from the arterial lesion, which cytokines are primarily produced and play a crucial role in disease progression? (Q851671)

A. IL-4 and IL-5

B. IL-2 and IFN-γ

C. IL-10 and TGF-β

D. IL-6 and TNF-α

See Answer in Part B → Q1

@Neet_pg_bot

Q2: A 72-year-old female presents with a new-onset headache, jaw claudication, and visual symptoms. Her ESR is 92 mm/hr and CRP is elevated. Temporal artery biopsy is planned, but immediate treatment is necessary. Which of the following is the most appropriate initial management strategy? (Q851675)

A. Wait for biopsy results before starting any treatment

B. Start prednisone 40-60 mg/day immediately

C. Begin methotrexate and low-dose aspirin

D. Start tocilizumab alone

See Answer in Part B → Q2

@Neet_pg_bot

Q3: A 6-year-old boy presents with a bilateral lower extremity rash that appeared 2 weeks after an upper respiratory tract infection. He also complains of abdominal pain and joint pain. On examination, there is a symmetrically distributed palpable purpuric rash present over both lower extremities, predominantly on the extensor surfaces. Which of the following is the most likely diagnosis based on the clinical presentation and image findings? (Q851678)

A. Immune thrombocytopenic purpura (ITP)

B. IgA vasculitis (Henoch-Schönlein purpura)

C. Meningococcemia

D. Kawasaki disease

See Answer in Part B → Q3

@Neet_pg_bot

Q4: A 7-year-old boy presents with palpable purpura, abdominal pain, and joint pain. Laboratory studies show normal platelet count with elevated IgA levels. Which of the following statements about this condition is incorrect? (Q851680)

A. Renal biopsy is essential for confirming the diagnosis

B. Glucocorticoids help reduce arthralgias and abdominal discomfort

C. Glucocorticoids have not proven benefit in treating skin and renal manifestations

D. Complement levels are typically normal in this condition

See Answer in Part B → Q4

@Neet_pg_bot

Q5: A 19-year-old Asian female presents with persistent malaise, fever, night sweats, and unequal blood pressure readings in both arms (right arm 130/80 mmHg, left arm 100/70 mmHg). ESR is elevated at 85 mm/hr, and MR angiography shows ostial narrowing of the left subclavian artery with pan-arteritis. Which statement describes the pathogenesis and initial management? (Q851682)

A. Primarily intimal disease; start anti-TNF therapy

B. Panarteritis; tocilizumab superior to steroids

C. Adventitial inflammation; methotrexate first-line

D. Panarteritis with intimal proliferation; start prednisone

See Answer in Part B → Q5

@Neet_pg_bot

Q6: A 4-year-old child presents with fever, rash, and strawberry tongue. The child has circumoral pallor and a sandpaper-like rash. Laboratory investigations reveal elevated inflammatory markers. Which of the following statements is most likely to be true regarding this presentation? (Q851684)

A. IVIG with high-dose aspirin is the first-line treatment

B. The rash begins over the face and shows circumoral erythema

C. Throat culture is essential for diagnosis and Penicillin is the treatment of choice

D. Coronary artery involvement is seen in the majority of untreated cases

See Answer in Part B → Q6

@Neet_pg_bot

Q7: Match the markers (Column B) with the correct vasculitis (Column A). a. Granulomatosis with Polyangiitis (GPA) 1. C-ANCA b. Polyarteritis Nodosa (PAN) 2. P-ANCA 3. Proteinase-3 4. Myeloperoxidase (Q851686)

A. a → 1,3 b → 2,4

B. a → 2,4 b → 1,3

C. a → 1,3 b → None

D. a → None b → 1,3

See Answer in Part B → Q7

@Neet_pg_bot

Q8: A 45-year-old patient presents with fever, purpura, and arthralgias. Biopsy shows small vessel vasculitis with absent immune deposits. Lab tests reveal C-ANCA antibodies. Which of the following is most consistent with this clinical picture? (Q851688)

A. Microscopic polyangiitis with segmental necrotizing glomerulonephritis

B. Granulomatosis with polyangiitis with pauci-immune glomerulonephritis

C. Churg-Strauss syndrome with peripheral eosinophilia

D. Mixed cryoglobulinemia with Hepatitis-C

See Answer in Part B → Q8

@Neet_pg_bot

Q9: A 25-year-old man from Turkey presents with recurrent painful oral ulcers, genital ulcers, and bilateral red eyes. Examination reveals bilateral anterior uveitis and erythema nodosum on his legs. After the needle prick, he develops an erythematous papule in 48 hours. Laboratory studies show elevated IL-1, TNF-α, and increased neutrophil activity. Which of the following best describes the pathogenesis and clinical features of this condition? (Q851690)

A. ANCA-mediated vasculitis with small vessel involvement

B. Auto-inflammatory vasculitis with T-cell mediated immunity and neutrophilic inflammation

C. Antibody-mediated disease with preferential renal involvement

D. IgA-mediated vasculitis with predominant GI manifestations

See Answer in Part B → Q9

@Neet_pg_bot

Q10: A 30-year-old man presents with recurrent oral ulcers, genital ulcers, and bilateral uveitis. He develops pustules 48 hours after the needle prick. Further examination reveals erythema nodosum and non-erosive arthritis of the knees. Based on clinical criteria, Behcet's Disease is diagnosed. Which of the following represents the most appropriate initial management strategy? (Q851692)

A. High-dose steroids alone for all manifestations

B. Targeted therapy based on organ involvement: colchicine for mucocutaneous, topical steroids for anterior uveitis

C. Immediate cyclophosphamide for all patients

D. Anticoagulation alone for all manifestations

See Answer in Part B → Q10

@Neet_pg_bot

Q11: A 4-year-old Asian boy presents with 6 days of fever, bilateral conjunctival injection without exudate, strawberry tongue, and cervical lymphadenopathy >1.5 cm. On day 7, he develops erythema of palms and soles. Laboratory studies show elevated TNF-α and pro-BNP. Which of the following best describes the pathogenesis of this condition? (Q851694)

A. Direct viral invasion of coronary vessels with late thrombosis

B. Immune-mediated medium vessel vasculitis with coronary artery predilection

C. Bacterial toxin-mediated endothelial damage with early thrombosis

D. Primary autoimmune arteritis with small vessel involvement

See Answer in Part B → Q11

@Neet_pg_bot

Q12: A 3-year-old boy presents with 6 days of fever, bilateral conjunctivitis, strawberry tongue, and polymorphous rash. Initial labs show elevated CRP, ESR, and thrombocytosis. Which of the following represents the most appropriate initial diagnostic test and treatment strategy? (Q851695)

A. Blood culture and broad-spectrum antibiotics

B. Echocardiogram and IVIG 2g/kg plus high-dose aspirin

C. Throat culture and penicillin

D. Viral panel and supportive care

See Answer in Part B → Q12

@Neet_pg_bot

Q13: A 40-year-old man with a history of asthma presents with worsening dyspnea, peripheral neuropathy, and palpable purpura on his lower limbs. He also has a history of sinusitis. Blood tests reveal marked eosinophilia and a positive p-ANCA. What is the most likely diagnosis? (Q851696)

A. Wegener's Granulomatosis

B. Churg-Strauss Syndrome

C. Microscopic Polyangiitis

D. Polyarteritis Nodosa

See Answer in Part B → Q13

@Neet_pg_bot

Q14: Which of the following vasculitis syndromes is not classified as an ANCA-associated vasculitis according to the Chapel Hill Classification? (Q851697)

A. Granulomatosis with Polyangiitis (GPA)

B. Microscopic Polyangiitis (MPA)

C. Eosinophilic Granulomatosis with Polyangiitis (EGPA)

D. Polyarteritis Nodosa (PAN)

See Answer in Part B → Q14

@Neet_pg_bot

Q15: A 4-year-old kid comes to your clinic with his mother. His mother complains that he has had an acute fever and abdominal pain for 2 days. You examine the child and find out that the skin on the buttocks and extensor surfaces of arms and legs are covered with small round patches of blue-purple discoloration. You also find out that the kid has hematuria. You have diagnosed it as a case of Henoch Schonlein Purpura. Henoch-Schonlein purpura, a vasculitis, is characterized by which of the following symptoms? (Q882172)

A. Erythromelalgia

B. Glomerulonephritis, hematochezia and palpable purpura

C. Lhermitte’s sign

D. Virchow’s triad

See Answer in Part B → Q15

@Neet_pg_bot

• [08_Rheumatology] 061 Sle Anti Phospholipid Syndrome

« Back to Folder Directory

[08_Rheumatology] 061 Sle Anti Phospholipid Syndrome — Quick Jump

Q1 (p. 753) *Q2 (p. 753)* *Q3 (p. 754)* *Q4 (p. 755)* *Q5 (p. 755)* *Q6 (p. 755)*
Q7 (p. 756) *Q8 (p. 756)* *Q9 (p. 757)* *Q10 (p. 757)* *Q11 (p. 758)* *Q12 (p. 758)*
Q13 (p. 758) *Q14 (p. 759)*

Q1: A 25-year-old woman presents with fatigue, joint pain, and a photosensitive rash. She reports mouth ulcers and hair loss. Laboratory tests show positive ANA and elevated anti-ds DNA antibodies. Further examination reveals elevated levels of IFN-α. Which of the following is a consequence of elevated IFN-α in this condition? (Q851381)

A. Decreased B cell activation

B. Enhanced clearance of apoptotic cells

C. Suppression of T cell activity

D. Increased antibodies production

See Answer in Part B → Q1

@Neet_pg_bot

Q2: A 30-year-old woman presents with a history of recurrent fever, myalgia, photosensitivity, and joint pain. On examination, multiple erythematous plaques with adherent scales are noted on her face and scalp. What is the most likely diagnosis? (Q851385)

A. Urticarial eruptions

B. Malar rash

C. Subacute cutaneous lupus erythematosus (SCLE)

D. Discoid lupus erythematosus



See Answer in Part B → Q2

@Neet_pg_bot

Q3: A 26-year-old woman presents with chest pain worsened by deep breathing, shortness of breath, fatigue, joint pain, and a photosensitive facial rash. Physical examination reveals tenderness over the chest wall and mild joint swelling. Laboratory tests show positive ANA and elevated anti-dsDNA antibodies. A chest X-ray shows mild pleural effusion. Which of the following pulmonary complications is most likely associated with her condition? (ARDS: Acute Respiratory Distress Syndrome) (Q851390)

A. ARDS

B. Shrinking lung syndrome

C. Pulmonary hypertension

D. Pleuritis

See Answer in Part B → Q3

@Neet_pg_bot

Q4: A 28-year-old woman presents with joint pain and skin rashes after being treated with trimethoprim-sulfamethoxazole for a recent infection. She has a history of Systemic lupus erythematosus. Laboratory tests reveal positive anti-dsDNA antibodies. Which of the following antibodies would be more specific for diagnosing the cause of her symptoms? (Q851392)

A. Anti-Ro

B. Anti-RNP

C. Anti-C1q

D. Antihistone

See Answer in Part B → Q4

@Neet_pg_bot

Q5: A 27-year-old woman presents with joint pain, fatigue, and a malar rash. Laboratory tests reveal positive ANA and anti-dsDNA antibodies. According to the EULAR/ACR classification criteria, which of the following criteria is not required for diagnosis? (Q851394)

A. Antiphospholipid antibodies

B. Serositis

C. Neuropsychiatric symptoms

D. Ocular symptoms

See Answer in Part B → Q5

@Neet_pg_bot

Q6: A 25-year-old woman presents with fatigue, a malar rash, and joint pain. Laboratory tests show positive anti-dsDNA, anti-Smith antibodies, and a positive

ANA. She undergoes a renal biopsy that reveals features consistent with lupus nephritis. Based on the SLICC criteria, which of the following statements is true? (Q851395)

A. Four clinical criteria must be met to confirm SLE

B. Renal biopsy indicating lupus with lupus autoantibodies is sufficient

C. At least 2 clinical criteria with one antibody confirms SLE

D. Presence of Anti-ds, Anti-Sm and ANA confirms SLE

See Answer in Part B → Q6

@Neet_pg_bot

Q7: A 32-year-old woman with known systemic lupus erythematosus presents with new-onset hypertension and elevated creatinine. Urinalysis shows hematuria and proteinuria. Renal biopsy reveals glomerular inflammation involving >50% of glomeruli. Which class of lupus nephritis does this most likely represent? (Q851398)

A. Class V

B. Class II

C. Class III

D. Class IV

See Answer in Part B → Q7

@Neet_pg_bot

Q8: A 28-year-old woman with a history of SLE presents with increased fatigue, severe joint pain and pleuritis with features suggestive of coronary artery disease. Laboratory tests indicate elevated serum creatinine. Which of the following management strategies is most appropriate for this patient? (Q851403)

A. High-dose glucocorticoids and Cyclophosphamide

B. Hydroxychloroquine and NSAIDs for symptom relief

C. Low-dose glucocorticoids, along with azathioprine

D. Conservative management with close monitoring and supportive care

See Answer in Part B → Q8

@Neet_pg_bot

Q9: A 35-year-old woman with a history of hypertension presents with fever, rash, and joint pain. Laboratory tests show positive ANA and anti-histone antibodies. She has no signs of renal or neurological involvement. Which of the following medications is most likely responsible for her symptoms? (Q851405)

A. Metoprolol

B. Hydrochlorothiazide

C. Hydralazine

D. Amlodipine

See Answer in Part B → Q9

@Neet_pg_bot

Q10: A 45-year-old man with TB on ATT isoniazid therapy presents with fatigue, fever, joint pain, and a rash. Laboratory tests reveal a positive antinuclear antibody (ANA) test, and anti-histone antibodies are detected. Which of the following ANA staining patterns is most likely found in this patient? (Q851407)

A. Diffuse

B. Speckled

C. Nucleolar

D. Centromere

See Answer in Part B → Q10

@Neet_pg_bot

Q11: A 35-year-old woman with a history of recurrent miscarriages and recent episodes of deep vein thrombosis is found to have elevated anti-β2-glycoprotein I antibodies. Which of the following pathophysiological mechanisms is primarily responsible for her condition? (Q851410)

A. Deactivation of the complement pathway

B. Increased apoptosis of endothelial cells

C. Decreased platelet activation

D. Impaired fibrinolysis

See Answer in Part B → Q11

@Neet_pg_bot

Q12: A 30-year-old woman presents with a history of recurrent miscarriages, having experienced three miscarriages before 10 weeks of gestation and an unprovoked deep vein thrombosis (DVT) in her left leg six months ago, which required anticoagulation therapy. She is diagnosed with antiphospholipid syndrome. Which of the following is not a diagnostic criterion of antiphospholipid syndrome? (Q851413)

A. Vascular thrombosis of artery, vein or any small vessel

B. 3 or more unexplained consecutive miscarriages before 10 weeks of gestation

C. Positive titer for APLA antibodies on a single occasion

D. One or more unexplained deaths of a normal fetus at or after 10 weeks

See Answer in Part B → Q12

@Neet_pg_bot

Q13: A 32-year-old woman with a known history of antiphospholipid syndrome (APS) was admitted to the hospital due to arterial thrombosis. She had a history of deep vein

thrombosis (DVT) one year ago, for which she was treated with warfarin. She has been adherent to her warfarin therapy, with a target INR of 2.5. Investigations show the following reports. INR: 2.1 Lupus antibody: Positive Anticardiolipin antibody: Positive Anti-β2 glycoprotein I antibodies: Positive What would be the most appropriate adjustment to her treatment after this arterial thrombosis episode? (Q851418)

A. Administration of oral hydroxychloroquine

B. Increase the dose of warfarin with a target INR of 3.0 to 4.0

C. Switch to direct oral thrombin inhibitor

D. Switch to low-dose aspirin with prophylactic dose low molecular weight heparin.

See Answer in Part B → Q13

@Neet_pg_bot

Q14: Which of the following assay tests cannot detect lupus anticoagulant antibodies? (Q851421)

A. Enzyme-linked immunosorbent assay

B. Activated thromboplastin time

C. Kaolin clotting time

D. Dilute Russell viper venom test

See Answer in Part B → Q14

@Neet_pg_bot

• [08_Rheumatology] 062 Rheumatoid Arthritis

« Back to Folder Directory

[08_Rheumatology] 062 Rheumatoid Arthritis — Quick Jump

Q1 (p. 760) *Q2 (p. 760)* *Q3 (p. 761)* *Q4 (p. 761)* *Q5 (p. 762)* *Q6 (p. 762)*
Q7 (p. 763) *Q8 (p. 763)* *Q9 (p. 764)* *Q10 (p. 764)* *Q11 (p. 765)*

Q1: A 45-year-old female complains of morning stiffness lasting over an hour and pain in her hands and wrists. On examination, there is swelling and tenderness of multiple small joints in her hands. Laboratory results show a positive rheumatoid factor (RF) and anti-cyclic citrullinated peptide (anti-CCP) antibodies. X-ray reveals soft tissue swelling and early joint space narrowing. Which of the following joint involvement patterns is most characteristic of this condition? (Q851422)

A. Symmetrical involvement of small joints, particularly the MCP and PIP joints

B. Asymmetrical involvement of small joints, particularly the MCP and PIP joints

C. Symmetrical involvement of the DIP joints

D. Asymmetrical involvement of the DIP joints

See Answer in Part B → Q1

@Neet_pg_bot

Q2: A 52-year-old woman presents with joint pain and swelling, particularly in her hands and wrists, over the past 6 months. She has a family history of autoimmune diseases, and laboratory tests show positive rheumatoid factor (RF) and anti-citrullinated protein antibodies (anti-CCP). Which of the following statements is true regarding the etiopathogenesis of this patient's condition? (Q851424)

A. Crystal disposition in the joint spaces leads to joint inflammation

B. Presence of HLA-DR β 1 is strongly associated with this condition

C. Joint destruction occurs due to mechanical damage to the articular cartilage

D. Pregnancy can aggravate the symptoms of this condition

See Answer in Part B → Q2

@Neet_pg_bot

Q3: A 32-year-old woman with long-standing rheumatoid arthritis presents with difficulty extending the DIP joint and flexing the PIP joint of her middle finger. On examination, the PIP joint is flexed while the DIP joint is hyperextended. Which of the following deformities best matches this presentation? (Q851426)

A. Boutonniere deformity

B. Swan neck deformity

C. Z-line deformity

D. Mallet finger deformity

See Answer in Part B → Q3

@Neet_pg_bot

Q4: A 45-year-old male presents to the clinic with joint pain and morning stiffness lasting more than one hour. Based on the EULAR classification criteria for rheumatoid arthritis, which of the following combinations of clinical, serological, and laboratory findings is most likely to lead to a definitive diagnosis of rheumatoid arthritis? (Q851428)

A. Swelling in 3 small joints, positive anti-citrullinated protein antibodies (ACPA) at high titers, and elevated C-reactive protein (CRP), symptoms for 8 weeks

B. Swelling in 1 large joint, positive rheumatoid factor at low titers, normal ESR, and symptoms for 4 weeks

C. Swelling in 6 small joints, negative ACPA, elevated ESR, and symptoms for 5 weeks

D. Swelling in 4 large joints, positive ACPA at low titers, normal CRP, and symptoms for 12 weeks

See Answer in Part B → Q4

@Neet_pg_bot

Q5: A 60-year-old male with a history of working in coal mines presents with progressive shortness of breath and a chronic cough. He reports that years ago, he was diagnosed with a joint condition that caused swelling and stiffness, particularly in his hands and wrists. Laboratory testing reveals he is positive for HLA-DR4. A chest X-ray shows multiple rounded opacities in both lung fields. A lung biopsy showed the following picture. What is the most likely diagnosis? (Q851430)

A. Caplan syndrome

B. Secondary Sjögren's syndrome

C. Felty syndrome

D. Lofgren syndrome

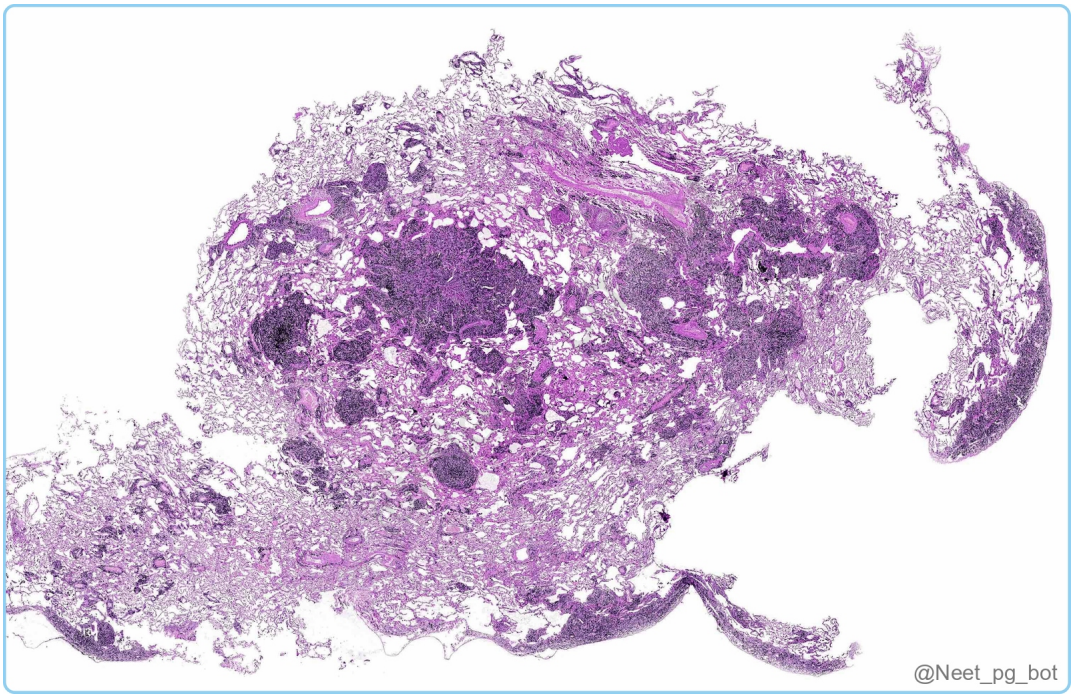

See Answer in Part B → Q5

@Neet_pg_bot

Q6: A 32-year-old male presents with multiple subcutaneous nodules on his arms and back, along with joint pain and stiffness primarily affecting his hands and knees. He

has erythema nodosum and a positive family history of similar conditions. Which of the following is a common ocular extra-articular manifestation associated with this condition? (Q851432)

A. Keratoconjunctivitis sicca

B. Uveitis

C. Iritis

D. Iridocyclitis

See Answer in Part B → Q6

@Neet_pg_bot

Q7: A 52-year-old man presents with bilateral pain, swelling, and stiffness in his hands and wrists for the past 4 months. His symptoms are worse in the morning and improve throughout the day. The physical exam shows synovitis in the metacarpophalangeal joints. Considering the high specificity for rheumatoid arthritis, which initial investigation is most appropriate to confirm the diagnosis in this patient? (Q851434)

A. Anti-nuclear antibody test

B. Anti-cyclic citrullinated peptide antibody

C. Synovial fluid analysis

D. MRI of the affected joints

See Answer in Part B → Q7

@Neet_pg_bot

Q8: A 55-year-old female patient presents with significant joint pain, stiffness, and swelling affecting multiple joints. Her Disease Activity Score (DAS28) is 5.4, indicating high disease activity. She has not responded adequately to lifestyle modifications and NSAIDs. Which medication is considered this patient's first-line disease-modifying antirheumatic drug (DMARD)? (Q851435)

A. Sulfasalazine

B. Methotrexate

C. Leflunomide

D. Hydroxychloroquine

See Answer in Part B → Q8

@Neet_pg_bot

Q9: A 45-year-old female patient with rheumatoid arthritis presents with persistent joint pain and swelling despite being on methotrexate and low-dose prednisolone for the past six months. Her Disease Activity Score (DAS28) is 5.4, indicating high disease activity. What is the most appropriate next step in her management? (Q851437)

A. Increase the dose of methotrexate

B. Initiate oral triple therapy

C. Switch from methotrexate to leflunomide

D. Continue methotrexate for 3 more months

See Answer in Part B → Q9

@Neet_pg_bot

Q10: A 60-year-old man with rheumatoid arthritis is being evaluated for remission after 6 months of treatment. According to the ACR/EULAR remission criteria, which of the following is NOT correct? (Q851438)

A. Tender joint count ≤1

B. Simplified Disease Activity Index (SDAI) score of ≤ 3.2

C. CRP ≤1 mg/dL

D. Patient global assessment ≤ 1

See Answer in Part B → Q10

Q11: Match the following: 1. Swan neck deformity a) {{caption_text}} 2. Boutonniere deformity b) 3. Z-line deformity c) 4. Mallet finger deformity d) {{caption_text}} (Q851440)

A. 1-c, 2-b, 3-d, 4-a

B. 1-b, 2-d, 3-a, 4-c

C. 1-a, 2-c, 3-b, 4-d

D. 1-d, 2-a, 3-c, 4-b

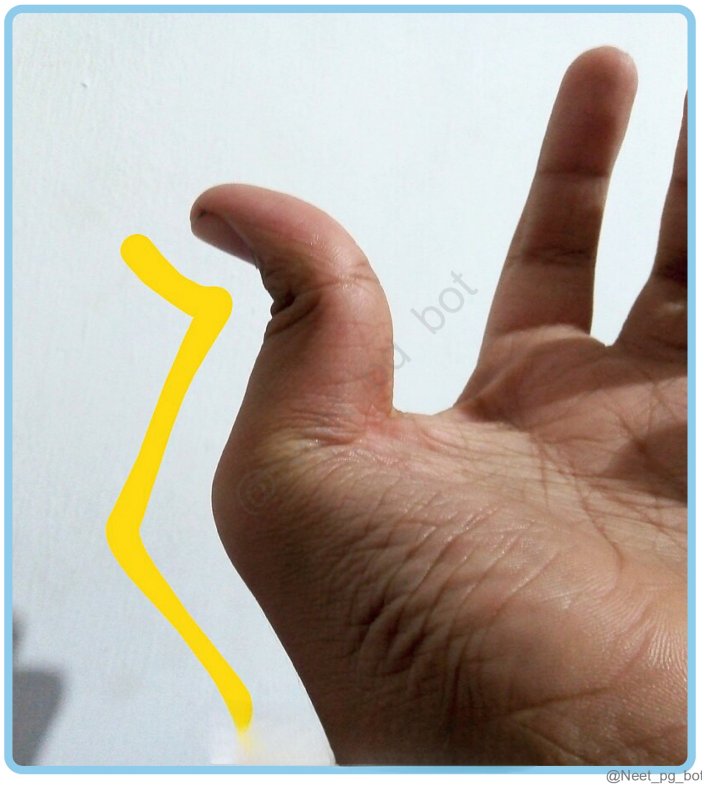

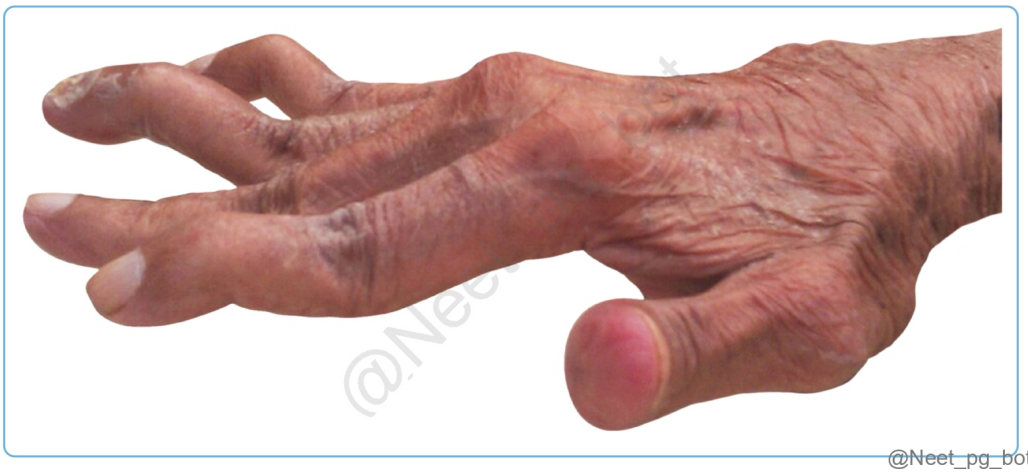
@Neet_pg_bot


@Neet_pg_bot



@Neet_pg_bot

See Answer in Part B → Q11

@Neet_pg_bot

• [08_Rheumatology] 063 Crystal Arthropathy

« Back to Folder Directory

[08_Rheumatology] 063 Crystal Arthropathy — Quick Jump

Q1 (p. 768) *Q2 (p. 768)* *Q3 (p. 769)* *Q4 (p. 769)* *Q5 (p. 770)* *Q6 (p. 770)*
Q7 (p. 771) *Q8 (p. 771)* *Q9 (p. 772)* *Q10 (p. 773)*

Q1: A 62-year-old man presents with sudden, severe pain in his right big toe, waking him from sleep. The joint is swollen, red, and extremely tender. He has a history of high uric acid levels and recently consumed protein-rich meals. What is the most likely diagnosis? (Q851618)

A. Pseudogout

B. Saturnine gout

C. Podagra

D. Psoriatic arthritis

See Answer in Part B → Q1

@Neet_pg_bot

Q2: A 43-year-old man presents with severe pain in his right big toe, redness, and swelling, as shown in the image. He has a history of hypertension and recently increased her consumption of red meat. Which of the following best explains the pathophysiological process leading to her condition? (Q851620)

A. Increased renal tubular secretion of uric acid

B. Decreased production of purines

C. Impaired renal excretion of uric acid

D. Increased breakdown of uric acid



See Answer in Part B → Q2

@Neet_pg_bot

Q3: A 60-year-old woman with a history of elevated uric acid levels reports that she experienced a painful episode in her right big toe two months ago. Since that time, she has had no symptoms and feels completely normal. She is concerned about the possibility of future attacks. What stage of the associated condition is this patient most likely experiencing now? (Q851621)

A. Asymptomatic Hyperuricemia

B. Acute Gout Attack

C. Intercritical Gout

D. Chronic Gouty Arthritis

See Answer in Part B → Q3

@Neet_pg_bot

Q4: A 58-year-old man presents with a sudden onset of severe pain in his left knee, accompanied by swelling and redness. He has a history of elevated uric acid levels. The physician suspects gout and plans to perform a joint aspiration for diagnostic purposes. Which of the following findings would most likely confirm the diagnosis of gout? (Q851622)

A. The presence of rhomboid-shaped crystals under polarised light

B. Elevated white blood cell count with neutrophilic predominance

C. Needle-shaped crystals exhibiting negative birefringence

D. Thickened synovial fluid with a high percentage of lymphocytes

See Answer in Part B → Q4

@Neet_pg_bot

Q5: A 46-year-old man presents to the OPD with severe pain, redness, and swelling in his right knee. Examination reveals tender swelling and redness at the base of the right 1st toe. Serum urate levels are normal, but arthrocentesis reveals negatively birefringent needle-shaped crystals under polarised light. Which of the following is the drug of choice for this acute attack? (Q851623)

A. Canakinumab

B. Oral colchicine

C. Intra-articular glucocorticoid injection

D. Allopurinol

See Answer in Part B → Q5

@Neet_pg_bot

Q6: A 48-year-old man had an acute gout attack treated successfully with NSAIDs. His labs show markedly elevated serum uric acid and high 24-hour urinary uric acid excretion. Which drug is the best choice for long-term management? (Q851624)

A. Pegloticase

B. Allopurinol

C. Febuxostat

D. Anakinra

See Answer in Part B → Q6

@Neet_pg_bot

Q7: A 45-year-old male with stage 2 chronic kidney disease presents with painful swelling at the base of his left big toe. He was diagnosed with an acute gouty attack and treated with oral glucocorticoids. Which anti-gout medication can be used to reduce the risk of another attack without dose modification? (Q851625)

A. Probenecid

B. Allopurinol

C. Febuxostat

D. Lesinurad

See Answer in Part B → Q7

@Neet_pg_bot

Q8: A 65-year-old man presents to the emergency department with sudden swelling, redness, and severe pain in both knees. He has experienced intermittent joint pain for the past few months. Polarised light microscopy of joint aspiration reveals rhomboid-shaped crystals exhibiting positive birefringence. Which statement best explains the pathogenesis of his condition? (Q851627)

A. Excessive mechanical wear and tear of the articular cartilage

B. Deposition of calcium pyrophosphate crystals in cartilage matrix vesicles

C. Excess purine production causes crystal deposition in the joints

D. Autoimmune reaction leading to pannus formation in the joint



See Answer in Part B → Q8

@Neet_pg_bot

Q9: A 75-year-old woman presents to the clinic with chronic pain and swelling in her shoulder joint. Radiographs reveal calcific tendinitis in the rotator cuff. A joint aspiration is performed, and the synovial fluid is analysed. If this patient has calcium apatite deposition disease, what type of crystal is most likely to be seen in the patient's synovial fluid? (Q851629)

A. Positively birefringent rhomboid-shaped crystals

B. Strong birefringent bipyramidal crystals

C. Negatively birefringent needle-shaped crystals

D. Microcrystals with no birefringence

See Answer in Part B → Q9

@Neet_pg_bot

Q10: Match each condition with its corresponding key synovial fluid characteristics: Conditions Key Characteristics 1. Normal a. Yellow, Cloudy, >50,000 WBC 2. Non-inflammatory b. Colorless, Clear, <200 WBC 3. Inflammatory c. Yellow, Opaque, Positive Gram Stain 4. Septic d. Xanthochromic or Red, Bloody 5. Hemarthrosis e. Straw-like, Clear, 200 - 2000 WBC (Q851630)

A. 1 - b, 2 - e, 3 - a, 4 - c, 5 - d

B. 1 - a, 2 - b, 3 - e, 4 - d, 5 - c

C. 1 - c, 2 - d, 3 - b, 4 - e, 5 - a

D. 1 - b, 2 - c, 3 - a, 4 - d, 5 - e

See Answer in Part B → Q10

@Neet_pg_bot

• [08_Rheumatology] 064 Scleroderma And Sjogren Syndrome

« Back to Folder Directory

[08_Rheumatology] 064 Scleroderma And Sjogren Syndrome — Quick Jump

Q1 (p. 774) *Q2 (p. 775)* *Q3 (p. 776)* *Q4 (p. 777)* *Q5 (p. 777)* *Q6 (p. 778)*
Q7 (p. 778) *Q8 (p. 779)* *Q9 (p. 779)* *Q10 (p. 780)* *Q11 (p. 780)* *Q12 (p. 781)*

Q1: A 45-year-old lady presents with skin changes, reporting that her fingers have become thick and tight. She has developed painful ulcers on her fingertips that heal slowly. The physician notes shiny, taut skin on her face and limited neck extension. The given image shows the patient's facial features. Which of the following findings is not typically associated with the skin changes observed in this patient? {{caption_text}} (Q851373)

A. Bilateral symmetrical skin thickening

B. Hyperpigmentation in sun-exposed areas

C. Fixed flexion contractures of the fingers

D. Telangiectasia on the face and hands



See Answer in Part B → Q1

@Neet_pg_bot

Q2: Which of the following statements about the histopathological examination (HPE) of the images is correct? A) {{caption_text}} B) {{caption_text}} Image A shows a thickened dermis with collagen accumulation and loss of adipose tissue. Image B demonstrates normal glomerular architecture with no signs of injury. Image B shows vascular lesions and ischemic glomerular changes. Image A is characterized by alveolar septal fibrosis leading to gas exchange impairment. (Q851375)

A. 3 and 4

B. 2 and 4

C. Only 2

D. 1 and 3

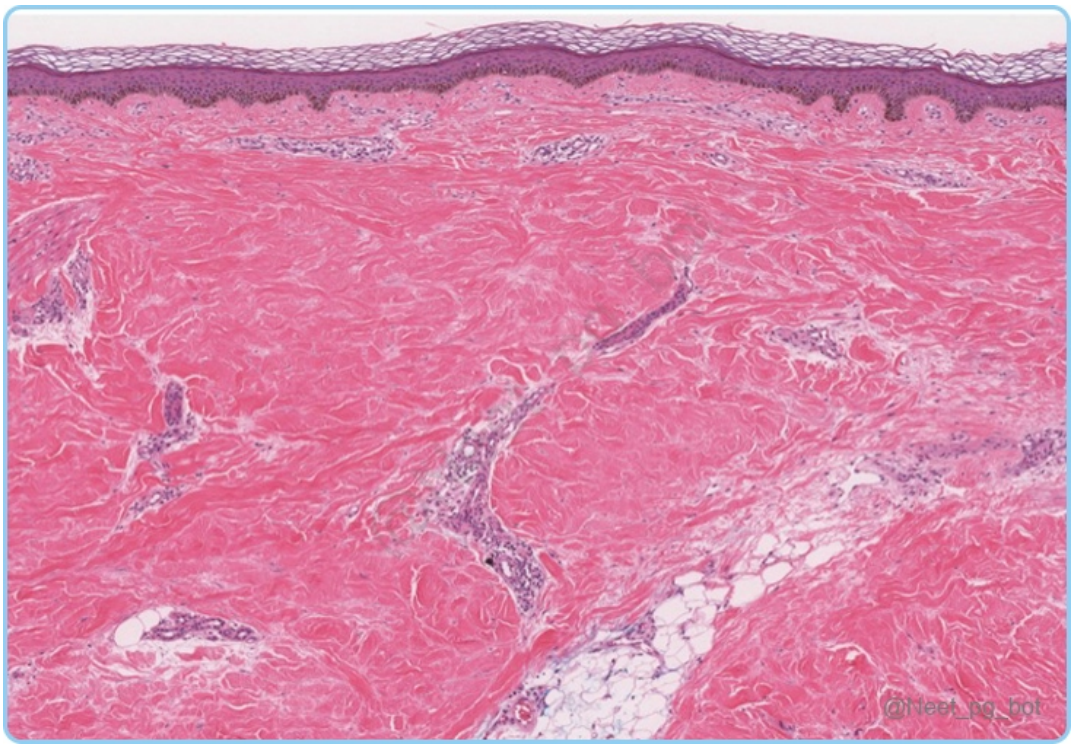

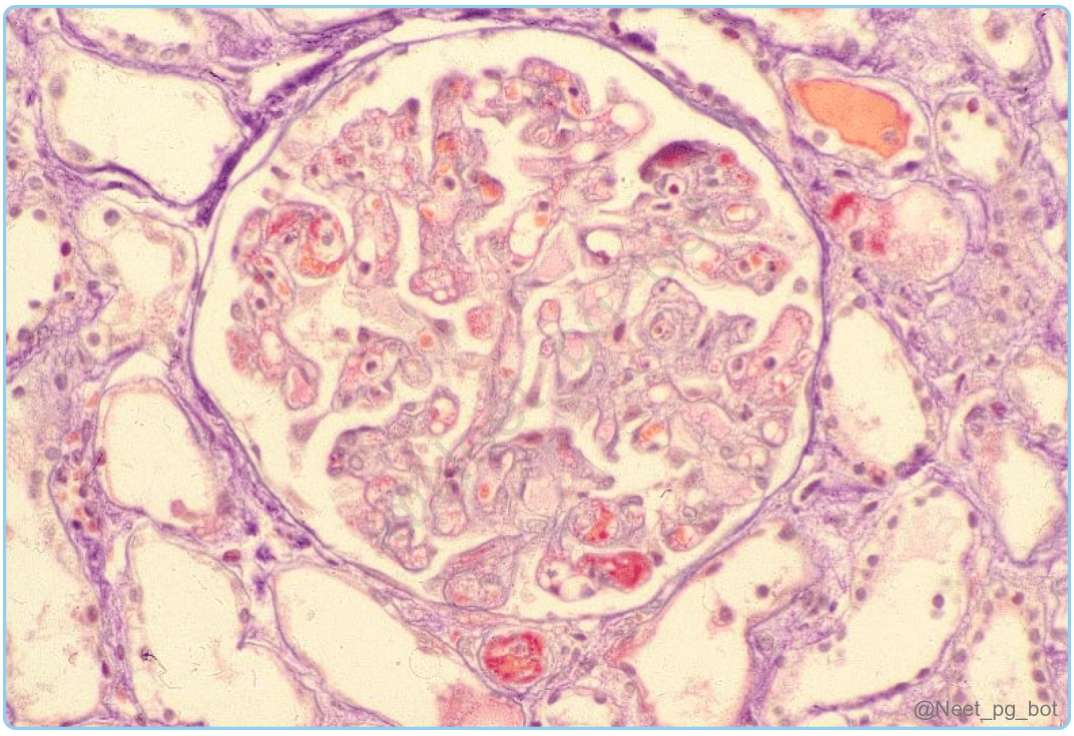

See Answer in Part B → Q2

@Neet_pg_bot

Q3: A 52-year-old woman presents with skin changes, including thickened and tight skin on her fingers, as well as pain and ulcerations at the fingertips. On examination, she has a shiny appearance to her skin and visible telangiectasia on her face. Which of the following options includes one pulmonary and one cardiac manifestation correctly associated with her clinical features? (Q851376)

A. Tuberculosis; Congestive cardiac failure

B. Cavitation; Pericarditis

C. Pulmonary arterial hypertension; Constrictive pericarditis

D. Non-caseating granuloma; Atrial myxoma

See Answer in Part B → Q3

@Neet_pg_bot

Q4: A 45-year-old woman with systemic sclerosis presents with new-onset hypertension and episodes of cold-induced finger discoloration. Which statement about her renal and vascular manifestations is false? (Q851377)

A. Scleroderma renal crisis presents with accelerated hypertension and can cause renal failure.

B. Raynaud's phenomenon is the most common extracutaneous feature and can lead to ulcers.

C. Anti-centromere antibodies increase the risk of scleroderma renal crisis.

D. Nailfold capillaroscopy distinguishes between primary and secondary Raynaud’s.

See Answer in Part B → Q4

@Neet_pg_bot

Q5: A 45-year-old woman presents with symptoms including skin thickening on her fingers, fatigue, and shortness of breath with episodes of painful swelling in her fingertips and difficulty swallowing. During her examination, a specific immunofluorescence test is performed, revealing the presence of several autoantibodies. Which of the following auto-antibodies is most likely associated with severe skin involvement and interstitial lung disease in this patient? (Q851378)

A. Centromere Proteins

B. Topoisomerase I (Scl-70)

C. RNA Polymerase III

D. U1-RNP

See Answer in Part B → Q5

@Neet_pg_bot

Q6: A 60-year-old woman presents with severe fatigue, dry mouth, difficulty swallowing, and episodes of coldness and color changes in her fingers. She reports dyspnea on exertion and has a history of gastrointestinal reflux. There is no visible skin thickening. Laboratory tests show positive anti-nuclear antibodies and anti-Scl-70 antibodies. Which condition is she most likely experiencing? (Q851379)

A. Limited Scleroderma

B. Diffuse Scleroderma

C. Sine Sclerosis

D. Sjögren's Syndrome

See Answer in Part B → Q6

@Neet_pg_bot

Q7: A 25-year-old female presents with episodes of sequential color changes in her fingers (white, blue, and red) triggered by cold exposure. She has no underlying conditions, normal nail fold capillaroscopy, and symmetric involvement. Which of the following is the most likely diagnosis (Q851380)

A. Secondary Raynaud's Due To Scleroderma

B. Primary Raynaud's Phenomenon

C. Acrocyanosis

D. Secondary Raynaud's Due To SLE

See Answer in Part B → Q7

@Neet_pg_bot

Q8: A 42-year-old female with diffuse cutaneous systemic sclerosis presents with severe headache, blurred vision, and blood pressure of 180/100 mmHg. Laboratory findings show creatinine of 2.8 mg/l, without thrombocytopenia or fragmented RBCs in peripheral smear. She has recently started on prednisolone 20mg daily for severe skin involvement. Which of the following is the most appropriate immediate management? (Q851382)

A. Start calcium channel blockers and taper steroids

B. Immediate initiation of short-acting ACE inhibitors

C. Start plasmapheresis for suspected TTP

D. Increase steroid dose to control inflammation

See Answer in Part B → Q8

@Neet_pg_bot

Q9: A 42-year-old female with diffuse cutaneous systemic sclerosis presents with worsening dyspnea and reduced lung function tests showing a restrictive pattern. Which of the following is the most appropriate treatment choice? (Q851383)

A. High-dose oral glucocorticoids

B. Cyclophosphamide

C. Hydroxychloroquine

D. Thalidomide

See Answer in Part B → Q9

@Neet_pg_bot

Q10: A 45-year-old woman presents with dry eyes and a dry mouth that has been persistent for the past 8 months. She also reports joint stiffness, fatigue, and recent dental caries. Histology reveals lymphocytic infiltration in the salivary glands. Which of the following factors is most directly implicated in the pathogenesis of her condition? (Q851386)

A. CD8+ T cell infiltration in exocrine glands

B. Hypergammaglobulinemia with elevated B-cell activation

C. Mutations in the CFTR gene

D. Eosinophilic infiltration in minor salivary glands

See Answer in Part B → Q10

@Neet_pg_bot

Q11: A 47-year-old female presents with a history of persistent dry mouth and a gritty sensation in her eyes. Her clinical evaluation is significant for dry mucous membranes and parotid gland swelling. A labial salivary gland biopsy is performed, and the histopathological examination reveals inflammatory infiltration. Based on the histopathological findings in the provided image, which of the following features would most specifically support a diagnosis? (Q851391)

A. Presence of multiple non-caseating granulomas

B. Lymphocytic foci surrounding ducts with a focus score ≥ 1 per 4 mm^2 area

C. Diffuse infiltration predominantly by neutrophils

D. Eosinophilic infiltration with periductal fibrosis

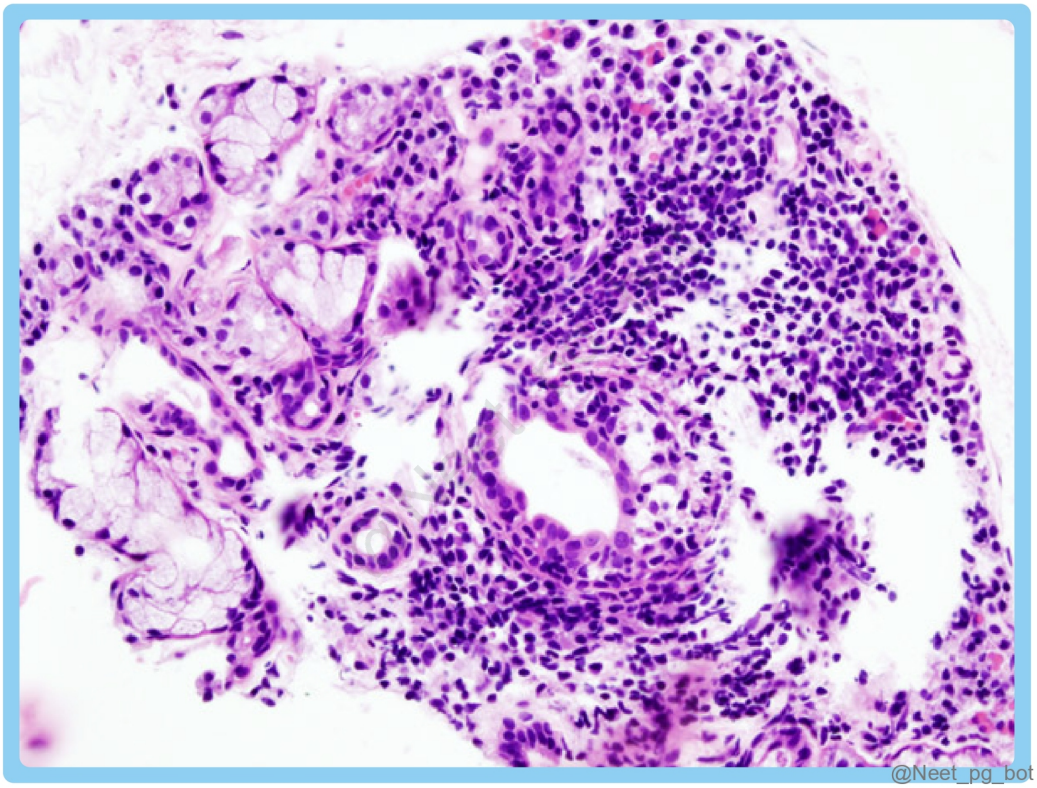

See Answer in Part B → Q11

@Neet_pg_bot

Q12: A patient diagnosed with Sjogren Syndrome reports persistent dry eyes, despite using artificial tears. Which of the following treatments would be considered next to alleviate the ocular symptoms? (Q851397)

A. Oral corticosteroids

B. Antihistamines

C. Topical cyclosporine eye drops

D. NSAIDs

See Answer in Part B → Q12

@Neet_pg_bot

• [08_Rheumatology] 065 Autoimmune And Inflammatory Diseases In Medicine

« Back to Folder Directory

[08_Rheumatology] 065 Autoimmune And Inflammatory Diseases In Medicine — Quick Jump

Q1 (p. 782)	*Q2 (p. 783)*	*Q3 (p. 784)*	*Q4 (p. 785)*	*Q5 (p. 785)*	*Q6 (p. 786)*
Q7 (p. 787)	*Q8 (p. 788)*	*Q9 (p. 788)*	*Q10 (p. 789)*	*Q11 (p. 789)*	*Q12 (p. 790)*
Q13 (p. 790)	*Q14 (p. 791)*	*Q15 (p. 791)*	*Q16 (p. 791)*		

Q1: A 30 y/o woman presents with a persistent cough, fatigue, and painful red nodules on her lower legs. Her ACE levels were found to be elevated and her chest x-ray findings are given below. She has a family history of autoimmune diseases and carries the HLA-DRB1*03 haplotype. What pathophysiological feature is most likely contributing to her condition? (Q851419)

A. Accumulation of neutrophils and eosinophils in lung tissue.

B. Interaction between antigen-presenting cells and T-helper cells leading to granuloma formation.

C. Decreased production of cytokines such as IL-2 and IFN-γ.

D. High levels of cyclosporine in the serum affecting T-cell activity.



See Answer in Part B → Q1

@Neet_pg_bot

Q2: A 35-year-old woman presents to the ED with severe chest pain and palpitations. She has a history of recurrent cough and fatigue over the past year. O/E, she has slight oedema in her lower extremities and a heart murmur. The chest X-ray of the patient is given below. Which of the following features is least likely associated with this patient's condition? (Q851423)

A. Anterior uveitis leading to vision changes.

B. Elevated alkaline phosphatase and portal hypertension.

C. Hypocalcemia and hypocalciuria with increased PTH.

D. Congestive heart failure



See Answer in Part B → Q2

@Neet_pg_bot

Q3: A 40-year-old woman has been suffering from a persistent cough, progressive shortness of breath, and fatigue for the past several months. A chest X-ray shows bilateral hilar lymphadenopathy. The patient also has a skin rash, as shown in the image below. Which of the following statements regarding this patient's diagnosis is false? (Q851425)

A. HRCT scan shows reticulonodular opacities.

B. PET scan indicates increased metabolic activity.

C. CD4:CD8 T-cell ratio in BAL < 3.5.

D. Biopsy shows non-caseating granulomas.

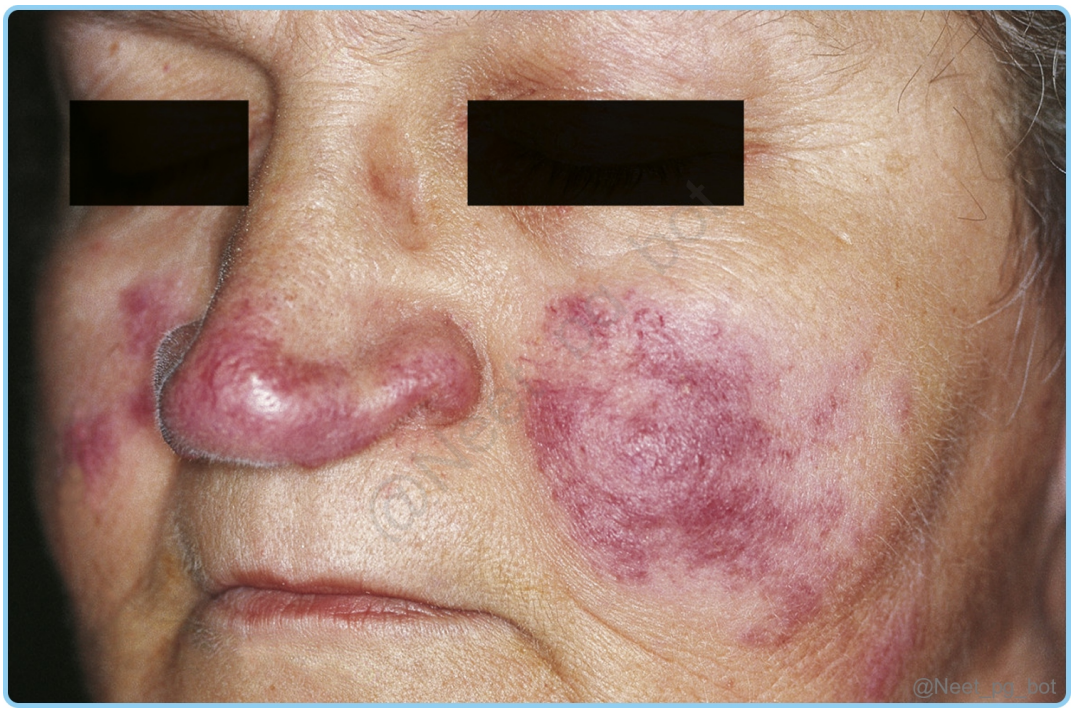

See Answer in Part B → Q3

@Neet_pg_bot

Q4: A 45 y/o woman diagnosed with sarcoidosis presents with worsening pulmonary symptoms, including shortness of breath and a persistent dry cough. She has also developed erythema nodosum on her legs. After a thorough evaluation, her physician decides that treatment is necessary to improve her quality of life and prevent complications. Which of the following treatment options is considered first-line for this patient's condition? (Q851427)

A. Methotrexate 10–20 mg/week.

B. Prednisolone 20–40 mg/day.

C. Infliximab at higher doses.

D. Hydroxychloroquine 200 mg/day.

See Answer in Part B → Q4

@Neet_pg_bot

Q5: Which of the following organs is least commonly involved in sarcoidosis? (Q851429)

A. Spleen

B. Heart

C. Skin

D. Brain

See Answer in Part B → Q5

@Neet_pg_bot

Q6: A 45 y/o woman presents with progressive muscle weakness and a distinctive rash on her eyelids and knuckles. She also exhibits a rash like in the given image. She reports difficulty swallowing and has experienced some joint pain. Which of the following statements about this patient's condition is false? (Q851431)

A. The rash may precede or accompany the muscle weakness.

B. Weakness is typically asymmetric, affecting distal muscles more than proximal.

C. Nail bed telangiectasias are a common finding.

D. Patients may present with only a rash and no muscle weakness.



See Answer in Part B → Q6

@Neet_pg_bot

Q7: A 50 y/o woman presents with muscle weakness that has progressively worsened over the last 2 months. She also reports a red rash on her knuckles and upper eyelids. The histopathology image of muscle biopsy is given below. MxA staining is positive. Which of the following statements regarding her condition is false? (Q851433)

A. Serum CK is elevated

B. Anti-TIF1 antibodies are associated with a favourable prognosis.

C. Perifascicular atrophy is characteristic of dermatomyositis.

D. Anti-MDA5 antibodies are linked to a higher risk of rashes, ulcers and ILD.

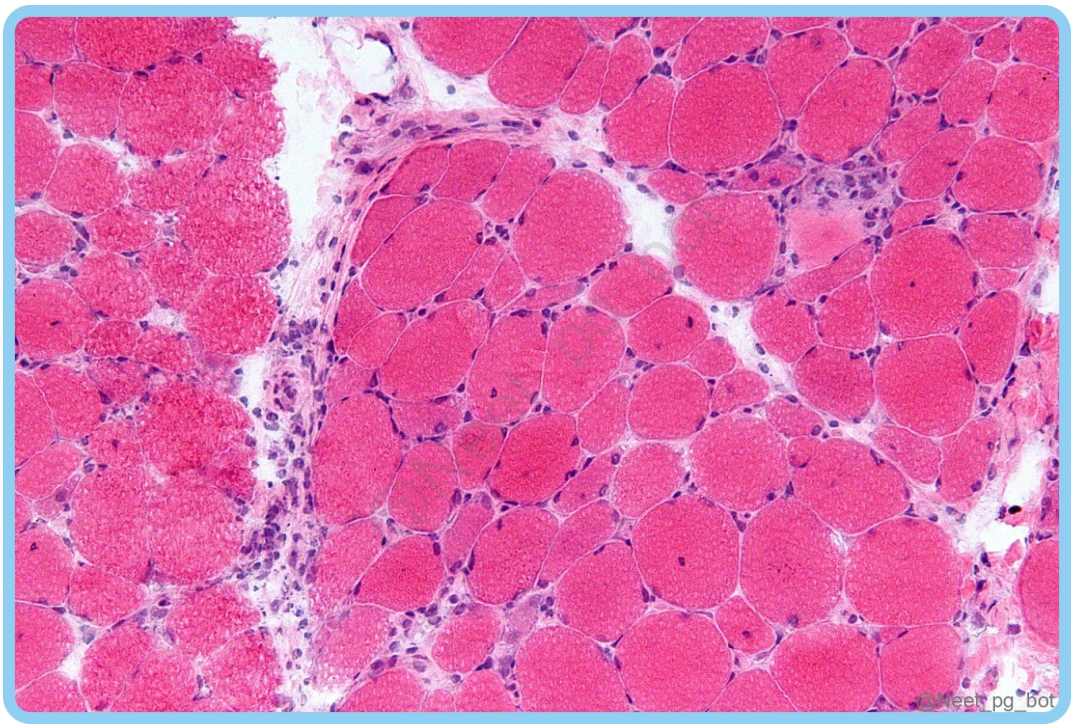

See Answer in Part B → Q7

@Neet_pg_bot

Q8: A 45-year-old woman has 3 months of progressive proximal muscle weakness, difficulty climbing stairs, and elevated creatine kinase (CK) levels. EMG indicates inflammatory myopathy, and a muscle biopsy shows endomysial infiltration with CD8+ T cells. What is the most likely diagnosis? (Q851436)

A. Polymyositis

B. Antisynthetase syndrome

C. Dermatomyositis

D. Overlap syndrome

See Answer in Part B → Q8

@Neet_pg_bot

Q9: A 35 y/o male presents with painful, recurrent oral ulcers lasting around 20 days. He also reports a history of genital ulcers and occasional skin lesions resembling erythema nodosum. Recently, he has developed blurred vision and redness in both eyes. Examination reveals anterior uveitis and multiple deep oral ulcers. A pathergy test is positive. What is the most likely diagnosis? (Q851439)

A. Behçet's disease

B. Cogan syndrome

C. Overlap syndrome

D. Antisynthetase syndrome

See Answer in Part B → Q9

@Neet_pg_bot

Q10: A 34 y/o male presents with a 2-year history of lower back stiffness and pain that improves with activity. He also has occasional knee and hip pain. Examination reveals reduced lumbar spine mobility and tenderness over the sacroiliac joints. What additional clinical feature is most likely associated with this condition? (Q851441)

A. High fever and night sweats

B. Symmetrical small joint swelling

C. Generalized muscle weakness

D. Recurrent anterior uveitis

See Answer in Part B → Q10

@Neet_pg_bot

Q11: A 26 year old male is evaluated for long-standing back pain and stiffness. Modified Schober’s test shows restricted lumbar flexion. Physical examination reveals limited chest expansion. Which additional finding would most likely be present? (Q851442)

A. Free lateral bending of the spine

B. Loss of lumbar lordosis

C. Hypermobile cervical spine

D. Absence of tenderness over the sacroiliac joints

See Answer in Part B → Q11

@Neet_pg_bot

Q12: A 20 y/o male presents with persistent back pain that improves with physical activity. He has a family history of inflammatory arthritis and shows HLA-B27 positivity. Imaging reveals sacroiliitis. Which of the following combinations fulfils the diagnostic criteria for axial spondyloarthritis? (Q851443)

A. History of joint pain plus normal X-ray findings

B. HLA-B27 positivity plus a history of allergic rhinitis

C. HLA-B27 positivity plus two other spondyloarthritis features

D. Elevated CRP levels plus a positive Schober's test

See Answer in Part B → Q12

@Neet_pg_bot

Q13: A 35 y/o female with ankylosing spondylitis is experiencing episodes of uveitis. Which would be the most appropriate drug to address both her uveitis and her underlying condition? (Q851444)

A. Anakinra

B. Adalimumab

C. Sulfasalazine

D. Tofacitinib

See Answer in Part B → Q13

@Neet_pg_bot

Q14: Which organ is most commonly associated with inflammatory pseudotumour in children? (Q851445)

A. Lungs

B. Liver

C. Brain

D. Kidneys

See Answer in Part B → Q14

@Neet_pg_bot

Q15: A 65 y/o male presents with abdominal pain, jaundice, and weight loss. Imaging reveals a mass in the liver, and laboratory tests show elevated IgG4 levels. A biopsy is performed to confirm the diagnosis. What is most likely associated with IgG4-related inflammatory pseudotumor? (Q851446)

A. Epithelioid cell granulomas

B. Caseating granulomas

C. Necrotising vasculitis

D. Storiform fibrosis

See Answer in Part B → Q15

@Neet_pg_bot

Q16: A 45 y/o patient presents with mild abdominal pain, weight loss, and obstructive jaundice. Imaging reveals a "sausage-shaped" pancreas and a subsequent CT scan shows diffuse pancreatic enlargement. The patient's condition is suspected to be related to an inflammatory process rather than malignancy. Which of the following is the most appropriate first-line treatment for this condition? (Q851447)

A. Rituximab

B. Surgical resection

C. Glucocorticoids

D. Antibiotics

See Answer in Part B → Q16

@Neet_pg_bot

• [08_Rheumatology] 066 Previous Year Questions

« Back to Folder Directory

[08_Rheumatology] 066 Previous Year Questions — Quick Jump

Q1 (p. 793)	*Q2 (p. 793)*	*Q3 (p. 794)*	*Q4 (p. 794)*	*Q5 (p. 794)*	*Q6 (p. 795)*
Q7 (p. 796)	*Q8 (p. 796)*	*Q9 (p. 797)*	*Q10 (p. 797)*	*Q11 (p. 798)*	*Q12 (p. 798)*
Q13 (p. 798)	*Q14 (p. 799)*	*Q15 (p. 799)*	*Q16 (p. 800)*	*Q17 (p. 800)*	*Q18 (p. 801)*
Q19 (p. 802)	*Q20 (p. 803)*	*Q21 (p. 803)*	*Q22 (p. 804)*	*Q23 (p. 804)*	*Q24 (p. 805)*
Q25 (p. 805)	*Q26 (p. 805)*	*Q27 (p. 806)*	*Q28 (p. 806)*	*Q29 (p. 807)*	*Q30 (p. 807)*
Q31 (p. 808)	*Q32 (p. 808)*	*Q33 (p. 809)*	*Q34 (p. 809)*	*Q35 (p. 809)*	*Q36 (p. 810)*
Q37 (p. 810)	*Q38 (p. 811)*	*Q39 (p. 811)*	*Q40 (p. 812)*	*Q41 (p. 812)*	

Q1: Which among the following is more common in limited cutaneous systemic sclerosis when compared to diffuse cutaneous systemic sclerosis? (Q855000)

A. Esophageal dysmotility

B. Myopathy

C. Interstitial lung disease

D. Scleroderma renal crisis

See Answer in Part B → Q1

@Neet_pg_bot

Q2: A young patient presents to the clinic with erythematous lesions over the exposed areas of the skin, like hands, arms, and chest. He also complains of arthralgia and breathlessness. Measuring which among the following antibodies will be useful in diagnosing the underlying conditions? (Q855716)

A. Antihistone antibodies

B. Anti-dsDNA antibodies

C. Anticentromere antibodies

D. Antinuclear antibodies

See Answer in Part B → Q2

@Neet_pg_bot

Q3: A patient presents with severe pain and swelling in his knee joint for 10 days. He also complains of pain and discomfort during urination. He says that he had diarrhea one month ago and he has been unwell since then. What is the most likely diagnosis? (Q857037)

A. Reactive arthritis

B. Enteropathic arthritis

C. Rheumatoid arthritis

D. Psoriatic arthritis

See Answer in Part B → Q3

@Neet_pg_bot

Q4: Takayasu arteritis most commonly involves: (Q857628)

A. Pulmonary artery

B. Coronary arteries

C. Abdominal aorta

D. Arch of aorta

See Answer in Part B → Q4

@Neet_pg_bot

Q5: Identify the deformity depicted in the image: (Q857669)

A. Swan neck deformity

B. Boutonniere deformity

C. Z line deformity

D. Mallet finger deformity

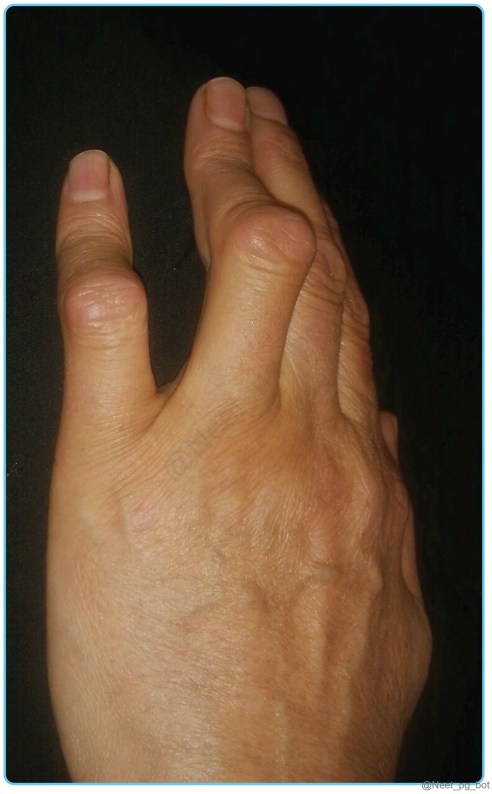

See Answer in Part B → Q5

@Neet_pg_bot

Q6: A patient presents with flaccid bullous lesions as shown in the image below involving the entire trunk and oral cavity. Acantholytic cells are seen on Tzank smear. What is the most probable diagnosis? (Q857670)

A. Pemphigus foliaceus

B. Pemphigus vulgaris

C. Dermatitis herpetiformis

D. Bullous pemphigoid



See Answer in Part B → Q6

@Neet_pg_bot

Q7: A patient presented with sinusitis, ulcerative lesions on the nasopharynx, nodular lesions with cavitations of the lung, and renal failure. Which of the following is the most useful investigation in this patient? (Q855703)

A. Test for ANCA

B. Biopsy to show granuloma

C. AFB staining of sputum

D. BAL

See Answer in Part B → Q7

@Neet_pg_bot

Q8: A patient with giant cell arteritis presented with headache, jaw claudication, polymyalgia rheumatica, and mononeuritis multiplex. What should be the first-line treatment for this patient? (Q856110)

A. Abatacept

B. Tocilizumab

C. Steroids

D. Aspirin

See Answer in Part B → Q8

@Neet_pg_bot

Q9: A woman presents with numbness of her fingertips. On examination, her face is tightened. The antinuclear antibody(ANA) is found to be positive and immunofluorescence shows the nucleolar pattern. What is the likely diagnosis? (Q856134)

A. Systemic sclerosis

B. Sjogren's syndrome

C. Systemic lupus erythematosus

D. Rheumatoid arthritis

See Answer in Part B → Q9

@Neet_pg_bot

Q10: A 36-year-old woman presented with claudication in the forearm, transient loss of vision, and abdominal pain. Femoral pulses were weak. Fundus examination revealed retinal haemorrhages. What is the likely diagnosis? (Q856162)

A. Polyarteritis nodosa

B. Thromboangitis obliterans

C. Takayasu arteritis

D. Microscopic polyangiitis

See Answer in Part B → Q10

@Neet_pg_bot

Q11: Which of the following conditions is not associated with Iritis ? (Q856936)

A. SLE

B. Behcet’s disease

C. Ulcerative colitis

D. Rheumatoid arthritis

See Answer in Part B → Q11

@Neet_pg_bot

Q12: Which of the following is not a first-line drug for the management of a patient with rheumatoid arthritis? (Q855602)

A. Sulfasalazine

B. Hydroxychloroquine

C. Methotrexate

D. Azathioprine

See Answer in Part B → Q12

@Neet_pg_bot

Q13: Which of the following is true about polyarteritis nodosa? (Q855005)

A. Necrotising inflammation of large vessels

B. Patient has hypogammaglobulinemia

C. 90% is associated with ANCA positivity

D. 30% is associated with Hepatitis B

See Answer in Part B → Q13

@Neet_pg_bot

Q14: Which of the following is associated with pauci-immune glomerulonephritis? (Q855062)

A. SLE nephritis

B. Anti-GBM glomerulonephritis

C. IgA nephropathy

D. Granulomatosis with polyangiitis (GPA)

See Answer in Part B → Q14

@Neet_pg_bot

Q15: A 54-year-old female patient visits you with symptoms of finger swelling, heartburn, and occasional joint pain. During the examination, her hands appeared shiny, tight, and thickened with non-pitting oedema. Additionally, she has interstitial lung disease and tests positive for ANA antibodies, topoisomerase I antibodies, and anti-RNA polymerase III antibodies. What is the likely diagnosis? (Q859521)

A. Limited cutaneous systemic sclerosis

B. Diffuse cutaneous systemic sclerosis

C. Raynaud's phenomenon

D. Peutz-jeghers syndrome

See Answer in Part B → Q15

@Neet_pg_bot

Q16: A 45-year-old woman complains of dryness in her mouth and eyes and has positive anti-Ro and anti-La antibodies. The image below shows a positive test result with a score of less than 5 mm in 5 minutes without anaesthesia. What is the probable diagnosis? (Q859562)

A. Scleroderma

B. Dehydration

C. Lacrimal duct stones

D. Sjogren syndrome

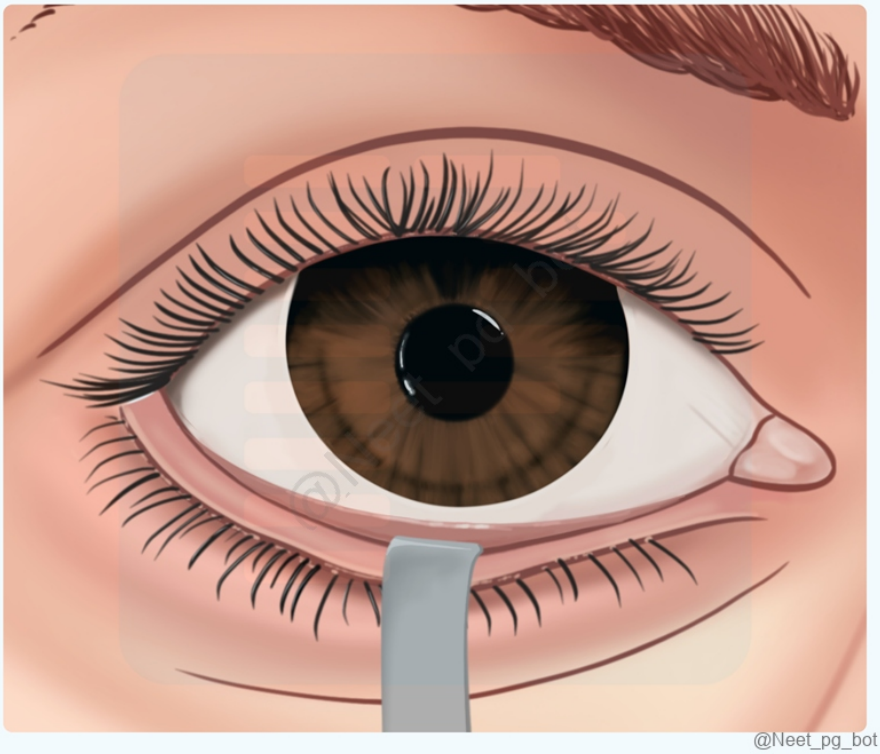

See Answer in Part B → Q16

@Neet_pg_bot

Q17: A 21-year-old woman with no comorbidities presented with numbness and paraesthesia of the fingers of both hands along with the characteristic finding as shown in the image below. She has no other illnesses and she says these episodes occur

when she is under excess stress or during cold climates. What is the most likely diagnosis? (Q859563)

A. Primary Raynaud’s phenomenon

B. Secondary Raynaud’s phenomenon

C. Cold sores

D. Scleroderma



See Answer in Part B → Q17

@Neet_pg_bot

Q18: A 65-year-old man is experiencing chronic pain in his hands, knees, and hips, with increased pain in the hands during writing or typing. Additionally, he has morning stiffness in his joints that lasts for about 30 minutes. On examination, Heberden's and Bouchard's nodes are visible in the hands, and an X-ray of the knee shows narrowed joint space with osteophytes. What is the most likely diagnosis? (Q859786)

A. Osteoporosis

B. Osteoarthritis

C. Rheumatoid arthritis

D. Bone tumour

See Answer in Part B → Q18

@Neet_pg_bot

Q19: A 52-year-old woman presented with changes in the hand as shown below. There is decreased motion in the small joints and loss of wrinkle lines on the facial skin. Her chest radiograph showed prominent bilateral lower lobe infiltrates. Which of the following is the most likely diagnosis? (Q859796)

A. Rheumatoid arthritis

B. Scleroderma

C. Systemic lupus Erythematosus

D. Pneumonia



See Answer in Part B → Q19

@Neet_pg_bot

Q20: A woman presents with fever, arthralgia, ulcers, fatigue for the past six months, and new-onset hematuria. Urine examination reveals RBC casts and proteinuria. What is the likely diagnosis? (Q855963)

A. Acute interstitial nephritis

B. Post-streptococcal glomerulonephritis

C. Lupus nephritis

D. IgA nephropathy

See Answer in Part B → Q20

@Neet_pg_bot

Q21: A 40-year-old female patient presents with dry mouth and a gritty sensation in the eyes. She has normal anion gap metabolic acidosis and hypokalemia. She also has enlarged salivary glands. What is the best investigation to arrive at a diagnosis? (Q879214)

A. Serum ACE levels and chest x-ray

B. Improvement on trial with methylprednisolone

C. Schirmer test and auto-antibody measurement

D. Salivary gland scintigraphy

See Answer in Part B → Q21

@Neet_pg_bot

Q22: After confirming a diagnosis of gout, which of the following drugs is a purine analog that would be most appropriate for management? (Q860474)

A. Allopurinol

B. Capecitabine

C. Cytarabine

D. Febuxostat

See Answer in Part B → Q22

@Neet_pg_bot

Q23: A child presents with kawasaki disease with multiple small coronary artery aneurysms. Treatment is? (Q866821)

A. Aspirin lifelong

B. Aspirin for 4 weeks

C. Aspirin for 6 weeks

D. Aspirin and clopidogrel for 6 weeks

See Answer in Part B → Q23

@Neet_pg_bot

Q24: Which of the following is the most common clinical feature observed during the progression of systemic lupus erythematosus (SLE)? (Q865303)

A. Photosensitivity

B. Nephrotic syndrome

C. Arthralgia & myalgia

D. Anemia and thrombocytopenia

See Answer in Part B → Q24

@Neet_pg_bot

Q25: A patient presents with morning stiffness and tests positive for anti-CCP antibodies. Which of the following histological features is most characteristic of the underlying disease? (Q866467)

A. Pannus formation and erosive joint damage

B. Non-caseating granulomas

C. Subepidermal blister with IgA deposits

D. Tophi with monosodium urate crystals

See Answer in Part B → Q25

@Neet_pg_bot

Q26: Patient presents with dry cough, dyspnea and stridor since 1 month. HPE of hilar LN shows stellate granulomas with giant cells and circular lamellated concretions on histopathology. Which of the following is the most likely diagnosis? (Q866484)

A. Sarcoidosis

B. Tuberculosis

C. GPA

D. Hypersensitivity pneumonitis

See Answer in Part B → Q26

@Neet_pg_bot

Q27: Anti-Scl-70 (anti-topoisomerase I) antibody in systemic sclerosis is most commonly associated with which of the following manifestations? (Q866490)

A. Interstitial Lung Disease

B. Raynaud's phenomenon

C. Calcinosis cutis

D. Gastric Antral Vascular Ectasia

See Answer in Part B → Q27

@Neet_pg_bot

Q28: A 42-year-old woman presents with recurrent bluish discoloration of her fingers on exposure to cold, tightening of the skin over her hands and face, difficulty swallowing, and shortness of breath. On examination, she has shiny, taut skin over her fingers and visible telangiectasias. What does this ANA pattern indicate, and what is the most likely diagnosis? {{caption_text}} (Q853354)

A. Speckled pattern, SLE

B. Nuclear pattern, SLE

C. Anti-centromere pattern, CREST

D. Homogeneous pattern, systemic sclerosis

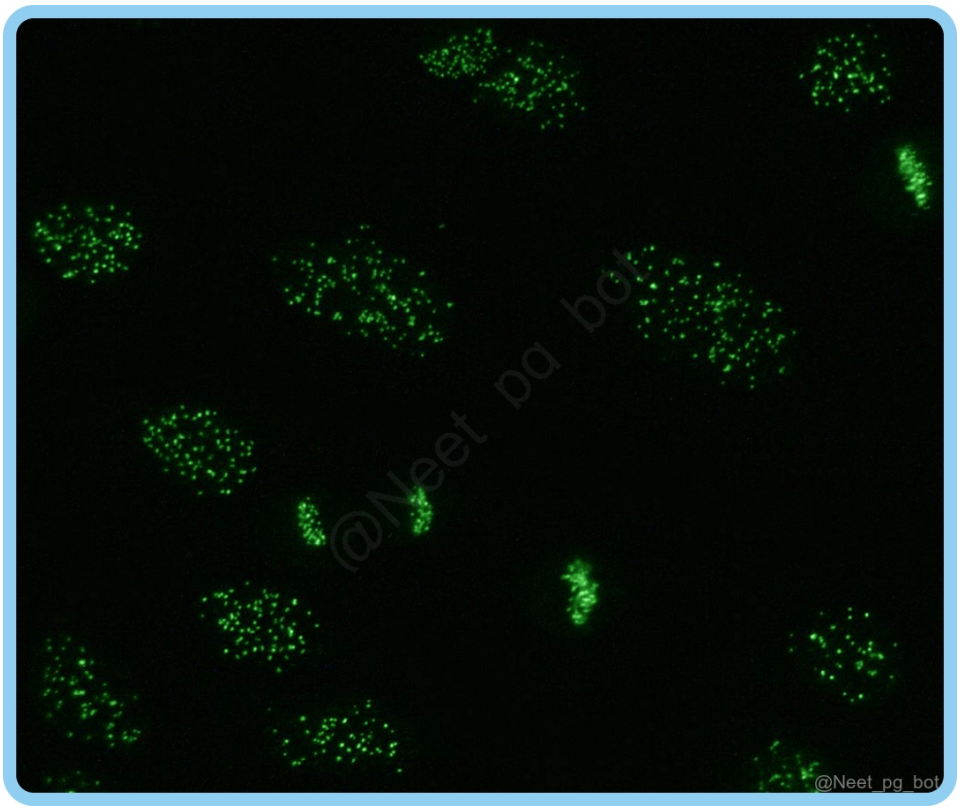

See Answer in Part B → Q28

@Neet_pg_bot

Q29: A patient presented with uveitis, enthesitis, and sacroiliitis. Which of the following is most likely associated with this condition? (Q853359)

A. HLA-B27

B. HLA-B57

C. HLA-B51

D. HLA-B5

See Answer in Part B → Q29

@Neet_pg_bot

Q30: A male patient presents with oral ulcers and ulcers in the anal canal. He is diagnosed with Behçet's disease. Which of the following is not seen in this condition? (Q853361)

A. Ulcer over the dorsum of the penis

B. It is more similar to Crohn's disease than ulcerative colitis

C. Bilateral panuveitis

D. Pathergy test positive is a criterion of ISG diagnostic criteria

See Answer in Part B → Q30

@Neet_pg_bot

Q31: A patient presents with joint swelling, a pan systolic murmur, negative rheumatoid factor (RF), and elevated ESR. What is the most likely diagnosis? (Q844177)

A. Acute rheumatic fever

B. Seronegative rheumatoid arthritis (RA)

C. Juvenile spondyloarthropathy

D. Ankylosing spondylitis

See Answer in Part B → Q31

@Neet_pg_bot

Q32: A 35-year-old male has had chronic hypercalcemia for the last 1.5 years, but PTH levels are normal. Which of the following is most likely the cause? (Q866804)

A. Malignancy

B. Sarcoidosis

C. Parathyroid hyperplasia

D. C.K.D

See Answer in Part B → Q32

@Neet_pg_bot

Q33: Which of the following is not true about ankylosing spondylitis? (Q840125)

A. Affect males more than females

B. HLA B27 associated

C. Involvement of sacroiliac joints

D. Its non erosive and only joints are affected

See Answer in Part B → Q33

@Neet_pg_bot

Q34: A 35-year-old woman experiences skin thickening, muscle weakness, and pale peripheries upon cold exposure. Her creatine kinase is increased with positive ANA, and biopsy revealed scl-70 positivity and perifascicular infiltration. What is the antibody linked to this condition? (Q857284)

A. Anti PM /Scl antibody

B. Anti Jo1 antibody

C. Anti centromere antibody

D. Antinuclear antibody

See Answer in Part B → Q34

@Neet_pg_bot

Q35: 40 year lady presents with difficulty in eating due to persistent dry mouth. She also has grittiness in eyes due to dry eyes. On examination, dental caries is noted with enlarged cervical lymph nodes. Possible diagnosis is: (Q820431)

A. MCTD

B. Sarcoidosis

C. Sjogren syndrome

D. Wegener’s granulomatosis

See Answer in Part B → Q35

@Neet_pg_bot

Q36: A 38-year-old male patient complains of paranasal sinus pain and bloody nasal discharge over the past few days. He has a history of previous hemoptysis and hematuria. Imaging studies reveal multiple bilateral nodular cavitary infiltrates. Which of the following antibodies is likely to be positive in this patient? (Q830817)

A. c-ANCA

B. ANA

C. Anti-histone antibodies

D. Anti-Jo 1 antibodies

See Answer in Part B → Q36

@Neet_pg_bot

Q37: A 40-year-old woman presents with bilateral symmetrical tenderness in the joints of her hands and wrists. She also complains of early morning stiffness of > 1 hour. On examination, no erythema or redness was found. What could be the diagnosis? (Q854728)

A. Osteoarthritis

B. Psoriatic Arthritis

C. Gout

D. Rheumatoid arthritis

See Answer in Part B → Q37

@Neet_pg_bot

Q38: A young man came to the medical OPD with complaints of early morning backache and stiffness, which improves on exercise, and persistent red eyes. On examination, lung expansion was less than 3 cm. X-ray is shown in the image given below. What is the most probable diagnosis? (Q855417)

A. Ankylosing Spondylitis

B. Paget's Disease

C. Healed Tuberculosis

D. Osteopetrosis



See Answer in Part B → Q38

@Neet_pg_bot

Q39: A 50-year-old woman presented with difficulty in activities like climbing stairs, getting up from a chair, and combing hair. Violaceous erythema of the upper eyelids was noted. What is the most probable diagnosis? (Q858036)

A. Inclusion body myositis

B. Dermatomyositis

C. Polymyositis

D. Scleroderma

See Answer in Part B → Q39

@Neet_pg_bot

Q40: A 50-year-old woman presented with difficulty in activities like climbing stairs, getting up from a chair, and combing hair. Violaceous erythema of the upper eyelids was noted. What is the most probable diagnosis? (Q858351)

A. Inclusion body myositis

B. Dermatomyositis

C. Polymyositis

D. Scleroderma

See Answer in Part B → Q40

@Neet_pg_bot

Q41: What is the most probable diagnosis for a young male patient who experiences drooping eyelids that worsens as the day progresses, along with increased fatigue towards the end of the day which improves with rest? Additionally, the patient notices a significant decrease in drooping when placing an ice pack over their eyes. (Q793852)

A. Myasthenia gravis

B. Huntington chorea

C. Amyotrophic lateral sclerosis

D. External ophthalmoplegia

See Answer in Part B → Q41

@Neet_pg_bot

• [09_Hepatobiliary System] 067 Viral Hepatitis Nafld Ali

« Back to Folder Directory

[09_Hepatobiliary System] 067 Viral Hepatitis Nafld Ali — Quick Jump

Q1 (p. 814)	*Q2 (p. 814)*	*Q3 (p. 815)*	*Q4 (p. 815)*	*Q5 (p. 815)*	*Q6 (p. 816)*
Q7 (p. 816)	*Q8 (p. 817)*	*Q9 (p. 817)*	*Q10 (p. 818)*	*Q11 (p. 818)*	*Q12 (p. 819)*
Q13 (p. 819)	*Q14 (p. 819)*	*Q15 (p. 820)*	*Q16 (p. 820)*	*Q17 (p. 821)*	*Q18 (p. 821)*
Q19 (p. 822)	*Q20 (p. 822)*	*Q21 (p. 822)*	*Q22 (p. 823)*	*Q23 (p. 823)*	*Q24 (p. 824)*
Q25 (p. 824)	*Q26 (p. 825)*	*Q27 (p. 825)*			

Q1: A 45-year-old patient presents with elevated liver enzymes and is suspected to have Hepatitis C. Which of the following statements regarding the investigations for Hepatitis C is correct? (Q851477)

A. Antibodies appear within 1-2 weeks.

B. Hepatitis C RNA confirms active infection.

C. Biopsy is essential for all diagnoses.

D. Genotype 1 has higher spontaneous clearance.

See Answer in Part B → Q1

@Neet_pg_bot

Q2: Hepatitis C Virus is most commonly associated with which of the following? (Q851491)

A. SLE

B. Scleroderma

C. Cryoglobulinemia

D. Polyarteritis Nodosa

See Answer in Part B → Q2

@Neet_pg_bot

Q3: Which of the following statements regarding Occult Hepatitis B Infection is false? (Q851490)

A. OBI can lead to hepatitis B transmission through blood products.

B. Individuals with seropositive OBI have detectable HBsAg in their serum

C. OBI may lead to reactivation of HBV in immunocompromised patients.

D. OBI can contribute to the development of HCC.

See Answer in Part B → Q3

@Neet_pg_bot

Q4: A 45-year-old patient presents with gas gangrene and signs of acute liver injury. Which of the following management strategies is most appropriate for this patient? (Q851489)

A. Initiate antiviral therapy with acyclovir and provide supportive care.

B. Start high-dose intravenous penicillin and perform aggressive surgical débridement.

C. Administer a combination of ampicillin, gentamicin, and metronidazole.

D. Implement hyperbaric oxygen therapy and monitor for bleeding complications.

See Answer in Part B → Q4

@Neet_pg_bot

Q5: A 45-year-old male presents to the emergency department with jaundice, fatigue, and right upper quadrant pain. He has a history of heavy alcohol use, and reports increased consumption over the past month. Laboratory tests show elevated aminotransferases and bilirubin levels. Which of the following investigations is most appropriate to determine the cause of his acute liver injury? (Q851488)

A. Liver Biopsy

B. Ultrasound of the abdomen

C. Toxicology Screen

D. Viral Hepatitis Serology

See Answer in Part B → Q5

@Neet_pg_bot

Q6: A 40-year-old woman presents to the emergency department with complaints of fatigue, nausea, and right upper quadrant discomfort. O/E, she appears mildly jaundiced with yellowing of the sclera. She is drowsy but can be easily aroused. Her family reports that she has been more irritable than usual, displaying some behavioural changes. She denies any recent travel or known infections but admits to consuming alcohol excessively over the past month. Which of the following signs or symptoms is most characteristic of the severity of her condition? (Q851487)

A. Elevated serum bilirubin levels

B. Normal liver function tests

C. Increased appetite

D. Significant weight loss

See Answer in Part B → Q6

@Neet_pg_bot

Q7: A 60-year-old male with a history of cirrhosis presents to the hospital with confusion and altered mental status. On examination, he is disoriented to time and space, exhibits lethargy, is somnolent but arousable, and displays bizarre behavior. According to the West Haven Criteria, what is the appropriate grade of his hepatic encephalopathy? (Q851486)

A. Grade 1

B. Grade 2

C. Grade 3

D. Grade 4

See Answer in Part B → Q7

@Neet_pg_bot

Q8: A 45-year-old male with a history of heavy alcohol consumption presents to the emergency department with fatigue, jaundice, and right upper quadrant abdominal pain. Laboratory tests reveal elevated direct bilirubin, alkaline phosphatase, and lactate dehydrogenase levels. His reticulocyte count is high, and the Coombs test is negative. The clinical features are consistent with Zieve syndrome. Which of the following is the most appropriate management for this patient? (Q851485)

A. Initiate corticosteroid therapy

B. Recommend immediate liver transplantation

C. Advise complete abstinence from alcohol

D. Start intravenous fluids and monitor in the hospital

See Answer in Part B → Q8

@Neet_pg_bot

Q9: A 48-year-old woman with a BMI of 32 kg/m² presents to the clinic with fatigue and mild abdominal discomfort. Laboratory tests reveal elevated liver transaminases, and an abdominal ultrasound shows hepatic steatosis. To further evaluate her condition, it is essential to exclude other potential causes of liver disease. Which of the following investigations should be performed first to rule out other liver diseases? (Q851484)

A. Liver biopsy

B. Blood tests for viral hepatitis markers

C. CT scan of the abdomen

D. NAFLD Fibrosis Score

See Answer in Part B → Q9

@Neet_pg_bot

Q10: A 50-year-old male with a history of obesity and type 2 diabetes presents for a routine check-up. His liver function tests show mildly elevated transaminases, and an ultrasound of the abdomen reveals fatty infiltration of the liver. He denies any alcohol consumption. His BMI is 35 kg/m², and his blood pressure is 145/90 mmHg. Based on these findings, he is diagnosed with non-alcoholic fatty liver disease (NAFLD). Which of the following is the most likely initiating factor in the pathogenesis of NAFLD in this patient? (Q851483)

A. Hepatitis C infection

B. Alcohol consumption

C. Insulin resistance

D. Autoimmune hepatitis

See Answer in Part B → Q10

@Neet_pg_bot

Q11: A 35-year-old male with chronic Hepatitis B presents with symptoms of fatigue, jaundice, and abdominal discomfort. Laboratory tests reveal elevated liver transaminases and the presence of Hepatitis D virus (HDV). His viral load is moderately elevated, and liver biopsy shows moderate fibrosis. The patient has no contraindications to antiviral therapy. Which of the following is the most appropriate treatment option for Hepatitis D in this patient? (Q851482)

A. Entecavir

B. Lamivudine

C. Pegylated Interferon-α

D. Hepatitis B Immunoglobulin

See Answer in Part B → Q11

@Neet_pg_bot

Q12: A 45-year-old man with a history of chronic Hepatitis B virus (HBV) infection presents to the clinic with new-onset fatigue and abdominal discomfort. Laboratory tests reveal the presence of high titers of IgM antibodies against Hepatitis D virus (HDV). Based on the information provided, which of the following statements is true regarding the serological response to HDV infection in this patient? (Q851481)

A. The delta antigen is consistently present in the blood during the infection.

B. The presence of IgM anti-HDV indicates a simultaneous infection with HBV and HDV.

C. Anti-HDV antibodies are not necessary for diagnosing HDV infection.

D. The patient will develop IgG anti-HDV antibodies immediately after infection.

See Answer in Part B → Q12

@Neet_pg_bot

Q13: A 35-year-old intravenous drug user presents to the clinic with fatigue and jaundice. Testing reveals infection with Hepatitis D virus (HDV). Which of the following statements about HDV transmission is true? (Q851480)

A. HDV is an independent RNA virus.

B. HDV is commonly transmitted via close personal contact in non-endemic regions.

C. Effective Hepatitis B vaccination indirectly prevents HDV infection.

D. Mother-to-child transmission is the primary route of HDV spread globally.

See Answer in Part B → Q13

@Neet_pg_bot

Q14: A 50-year-old patient with Hepatitis C genotype 1 seeks treatment. Which statement about Hepatitis C therapy is correct? (Q851479)

A. Pre-2011 therapy achieved an SVR of 70% for genotype 1 after 6 months.

B. DAAs offer effective, well-tolerated interferon-free regimens.

C. Ribavirin is free of major side effects like anemia or teratogenicity.

D. Liver transplantation eliminates the risk of reinfection and cirrhosis in grafts.

See Answer in Part B → Q14

@Neet_pg_bot

Q15: A 32-year-old man presents with fatigue and mild abdominal discomfort. He reports that he recently experienced nausea and dark urine. Laboratory tests reveal elevated liver enzymes. Which of the following is the most likely finding in this patient's blood tests? (Q851448)

A. Positive HBsAg

B. Positive anti-HBs

C. Negative HBsAg

D. Positive IgG anti-HBc

See Answer in Part B → Q15

@Neet_pg_bot

Q16: A 30-year-old male presents to the outpatient clinic for routine screening. He admits to a history of injection drug use. Which of the following is the most likely mode of Hepatitis C transmission in this patient? (Q851476)

A. Sexual contact

B. Vertical transmission from mother to child

C. Sharing needles and injecting equipment

D. Blood transfusion with screened blood products

See Answer in Part B → Q16

@Neet_pg_bot

Q17: A 35-year-old male presents with symptoms of nausea, jaundice, and abdominal pain after returning from a trip to a region with poor sanitation. He has no significant medical history. His liver function tests show elevated bilirubin, ALT, and AST levels. HEV IgM antibodies are positive. What is the most appropriate treatment plan for this patient? (Q851475)

A. Ribavirin therapy

B. Peginterferon

C. Supportive care with hydration and rest

D. Both A and C

See Answer in Part B → Q17

@Neet_pg_bot

Q18: A 40-year-old male presents with nausea, fatigue, and mild abdominal pain for the past week. He recently returned from a camping trip in a developing country. On examination, he has mild jaundice and tender hepatomegaly. His lab tests show elevated liver enzymes (ALT, AST), and positive anti-HAV IgM antibodies. What is the most likely mode of transmission for his condition? (Q851474)

A. Sharing needles

B. Fecal-oral route

C. Sexual contact

D. Respiratory droplets

See Answer in Part B → Q18

@Neet_pg_bot

Q19: A newborn infant is delivered to an HBsAg-positive mother. What is the most appropriate post-exposure prophylaxis for this infant? (Q851473)

A. Hepatitis B vaccine only

B. Hepatitis B Immune Globulin (HBIG) only

C. HBIG and Hepatitis B vaccine

D. No intervention is necessary

See Answer in Part B → Q19

@Neet_pg_bot

Q20: A 38-year-old female with a 5-year history of chronic Hepatitis B presents for evaluation. Her most recent lab results show HBsAg positive, HBeAg positive, ALT at 200 IU/L, and total bilirubin at 1.2 mg/dL. She is experiencing fatigue and mild abdominal discomfort. She has a history of taking herbal supplements for liver health and consumes alcohol occasionally. Which of the following is not an appropriate treatment plan for this patient? (Q851472)

A. Start tenofovir or entecavirir

B. Consider lamivudine as a second-line treatment

C. Stop alcohol completely

D. Continue herbal supplements for liver support

See Answer in Part B → Q20

@Neet_pg_bot

Q21: A 50-year-old male presents to the emergency department with acute jaundice, fever, fatigue, and right upper quadrant pain. He has a history of heavy alcohol use. On examination, he has icterus of the sclera and tenderness in the right upper. His laboratory results are as follows: HBsAg: Positive HBeAg: Positive ALT: 150 IU/L AST: 120 IU/L Total Bilirubin: 3.0 mg/dL Alkaline Phosphatase: 100 IU/L Which

management strategy is most appropriate? (Q851469)

A. Start entecavir therapy immediately

B. Begin tenofovir therapy immediately

C. Supportive care and stop alcohol

D. Both A and C

See Answer in Part B → Q21

@Neet_pg_bot

Q22: A 45-year-old male with acute Hepatitis B presents with the following lab results: ALT 4100 IU/L AST 3900 IU/L Total bilirubin 60 μmol/L (3.5 mg/dL) Despite the very high aminotransferase levels, his bilirubin remains moderately elevated. What does this suggest about the severity of liver cell damage? (Q851466)

A. Severe liver cell damage causing acute liver failure

B. The severity of damage cannot be determined from ALT levels alone

C. Mild liver cell damage causing fulminant hepatitis

D. Transition to chronic Hepatitis B with moderate liver damage

See Answer in Part B → Q22

@Neet_pg_bot

Q23: A 30-year-old male presents to the clinic for routine screening. He reports no recent illness but has a history of multiple sexual partners. He is concerned about Hepatitis B infection due to a friend's recent diagnosis. Laboratory tests are conducted to assess his Hepatitis B status. Test Result HBsAg Negative Anti-HBs Positive HBeAg Negative Anti-HBe Negative Anti-HBc Negative What does this lab profile indicate about the patient's Hepatitis B status? (Q851464)

A. Has an active acute Hepatitis B infection.

B. Has recovered from a previous Hepatitis B infection.

C. Is a healthy carrier of Hepatitis B.

D. Has been immunized against Hepatitis B.

See Answer in Part B → Q23

@Neet_pg_bot

Q24: A public health nurse is conducting an educational session on Hepatitis B transmission in a community with a high prevalence of the virus. During the session, she discusses various transmission routes and their associated risks for chronic infection. Which of the following statements about Hepatitis B transmission is incorrect? (Q851462)

A. Vertical transmission occurs from an HBsAg-positive mother to her infant.

B. Risk of chronic infection is higher in individuals infected at a younger age.

C. Sharing needles among drug users is a common mode of transmission.

D. Chronic infection is primarily associated with sexual transmission in adults.

See Answer in Part B → Q24

@Neet_pg_bot

Q25: A 26-year-old man presents with complaints of fatigue, loss of appetite, and mild abdominal discomfort. His partner recently tested positive for Hepatitis B. Laboratory tests reveal mildly elevated liver enzymes. Which of the following findings would you least likely find in this patient? (Q851460)

A. Mild splenomegaly

B. Cervical lymphadenopathy

C. Tender liver

D. Caput medusae

See Answer in Part B → Q25

@Neet_pg_bot

Q26: A 30-year-old man presents to the clinic for evaluation of elevated liver enzymes. He reports feeling fatigued and has noticed some jaundice. His medical history is significant for recent unprotected sexual contact with a partner who is Hepatitis B positive. Laboratory tests reveal that HBsAg is positive, and further testing shows the presence of HBeAg. Which of the following does the presence of HBeAg indicate in this patient? (Q851457)

A. Low viral replication and reduced infectivity

B. Active viral replication and high infectivity

C. Recovery from a previous Hepatitis B infection

D. Chronic infection with no active viral replication

See Answer in Part B → Q26

@Neet_pg_bot

Q27: A 28-year-old woman presents to the clinic with fatigue, loss of appetite, and mild jaundice. She reports that she had a recent exposure to a friend who was diagnosed with Hepatitis B. Laboratory tests reveal that HBsAg is negative, but her liver enzymes are elevated. Which of the following is the most likely finding in this patient's blood tests? (Q851455)

A. Positive anti-HBs only

B. Positive IgM anti-HBc

C. Positive IgG anti-HBc

D. Positive HBcAg

See Answer in Part B → Q27

@Neet_pg_bot

• [09_Hepatobiliary System] 068 Hepatorenal And Hepatopulmonary Syndrome And Alcoholic Hepatitits

« Back to Folder Directory

[09_Hepatobiliary System] 068 Hepatorenal And Hepatopulmonary Syndrome And Alcoholic Hepatitits — Quick Jump

Q1 (p. 826)	*Q2 (p. 826)*	*Q3 (p. 827)*	*Q4 (p. 827)*	*Q5 (p. 827)*	*Q6 (p. 828)*
Q7 (p. 828)	*Q8 (p. 829)*	*Q9 (p. 829)*	*Q10 (p. 829)*	*Q11 (p. 830)*	*Q12 (p. 831)*
Q13 (p. 831)	*Q14 (p. 832)*	*Q15 (p. 832)*	*Q16 (p. 833)*		

Q1: Give the correct sequencing of the pathophysiology of hepatorenal syndrome. Renal vasoconstriction Systemic vasodilation Vasopressin release Cytokine release (Q851281)

A. 1,2,3,4

B. 4,3,2,1

C. 4,2,3,1

D. 3,4,2,1

See Answer in Part B → Q1

@Neet_pg_bot

Q2: Which of the following is not a feature of hepatorenal syndrome? (Q851282)

A. Stepwise decrease in serum creatinine

B. Jaundice which begins in the sclera

C. Altered mental status

D. Increased risk of bleeding

See Answer in Part B → Q2

@Neet_pg_bot

Q3: A 56-year-old man with a history of cirrhosis due to chronic hepatitis C presents with worsening ascites, oliguria, and fatigue. Physical examination reveals tense ascites, mild jaundice, and peripheral edema. Laboratory investigations show: Serum creatinine: 2.3 mg/dL (baseline: 0.9 mg/dL) Serum sodium: 126 mEq/L Urine sodium: <10 mEq/L Albumin infusion is planned as part of his management. What is the recommended dosage of albumin infusion for this patient? (Q851283)

A. 1g/kg per day

B. 5g/kg per day

C. 2g/kg per day

D. 3g/kg per day

See Answer in Part B → Q3

@Neet_pg_bot

Q4: Which of the following is not a characteristic feature of Type 1 hepatorenal syndrome? (Q851284)

A. Doubling of serum creatinine over 2 weeks

B. Urine output less than 500mL/day

C. Normal urine sediment

D. High urinary sodium

See Answer in Part B → Q4

@Neet_pg_bot

Q5: A 52-year-old male with a long history of cirrhosis presents to the clinic with worsening shortness of breath over the past few months. He reports that his breathlessness worsens when standing and improves when lying down. Physical examination reveals spider angiomas. Pulse oximetry shows an oxygen saturation of 85% on room air. A contrast-enhanced echocardiogram (bubble study) is performed,

and delayed bubbles are seen in the left atrium. What is the most likely diagnosis? (Q851285)

A. Hepatopulmonary syndrome

B. Atelectasis

C. Chronic obstructive pulmonary disease (COPD)

D. Recurrent pulmonary emboli

See Answer in Part B → Q5

@Neet_pg_bot

Q6: Which of the following conditions causes intrapulmonary shunting? (Q851286)

A. Hepatopulmonary syndrome (HPS)

B. Portopulmonary hypertension

C. Recurrent pulmonary emboli

D. Pneumonia

See Answer in Part B → Q6

@Neet_pg_bot

Q7: A 45-year-old male with a history of cirrhosis presents with worsening dyspnea.Physical examination reveals clubbing and cyanosis, which worsen when the patient sits upright and decrease in oxygen saturation when the patient changes position from supine to upright.Which of the following is considered the gold standard diagnostic method for confirming this condition? (Q851287)

A. Pulmonary angiography

B. Transesophageal echocardiogram (TEE)

C. Radioactive lung perfusion scan

D. Bubble contrast echocardiography

See Answer in Part B → Q7

@Neet_pg_bot

Q8: Which of the following laboratory findings does not typically indicate alcoholic hepatitis? (Q851288)

A. Serum bilirubin more than 3 mg/dL

B. Elevated aspartate aminotransferase (AST) to 50 U/L - 400 U/L

C. AST:ALT (alanine aminotransferase) ratio of more than 1.5

D. Absolute value of AST/ALT greater than 600 U/L

See Answer in Part B → Q8

@Neet_pg_bot

Q9: What amount of alcohol consumption is generally considered to significantly increase the risk of developing alcoholic hepatitis? (Q851289)

A. More than 10 grams per day

B. More than 20 grams per day

C. More than 30 grams per day

D. More than 50 grams per day

See Answer in Part B → Q9

@Neet_pg_bot

Q10: A 52-year-old man with a history of heavy alcohol consumption presents with jaundice, abdominal pain, and fatigue. A liver biopsy is performed to assess the extent of liver damage. Which of the following findings is most characteristic of this condition? Histopathology image given below: (Q851290)

A. Russell bodies

B. Dutcher bodies

C. Mallory-Denk bodies

D. Kamino bodies

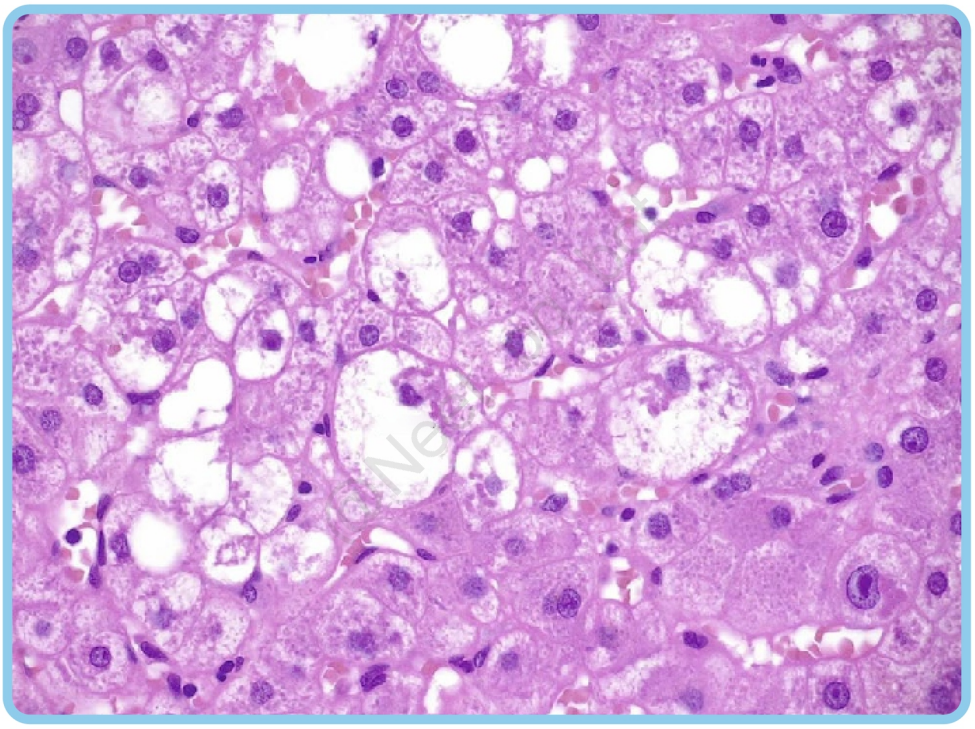

See Answer in Part B → Q10

@Neet_pg_bot

Q11: A 50-year-old male with a history of heavy alcohol use presents with jaundice and altered sensorium. Laboratory tests reveal elevated bilirubin, AST > ALT, hypoalbuminemia, and prolonged PT/INR. Which of the following findings is most suggestive of the presence of hepatic encephalopathy in this patient? (Q851291)

A. Asterixis

B. Hyperbilirubinemia

C. Ascites

D. Gynaecomastia

See Answer in Part B → Q11

@Neet_pg_bot

Q12: A 45-year-old man with a long history of heavy alcohol use presents with fatigue, jaundice, and abdominal distension. Physical examination reveals hepatomegaly, spider angiomas, and ascites. What is the most specific investigation to diagnose his condition? (Q851292)

A. γ-glutamyl transferase assay (GGT)

B. PT/INR

C. Serum bilirubin

D. AST/ALT ratio

See Answer in Part B → Q12

@Neet_pg_bot

Q13: A 30-year-old male patient succumbed to death, history revealed that the patient was admitted for liver failure 1 week back. Biopsy done is as shown below. What type of inclusions are seen in the biopsy, and what is the likely diagnosis? {{caption_text}} (Q851293)

A. Intracytoplasmic - ALD

B. Intranuclear - ALD

C. Intracytoplasmic - Viral hepatitis

D. Intranuclear - Viral hepatitis

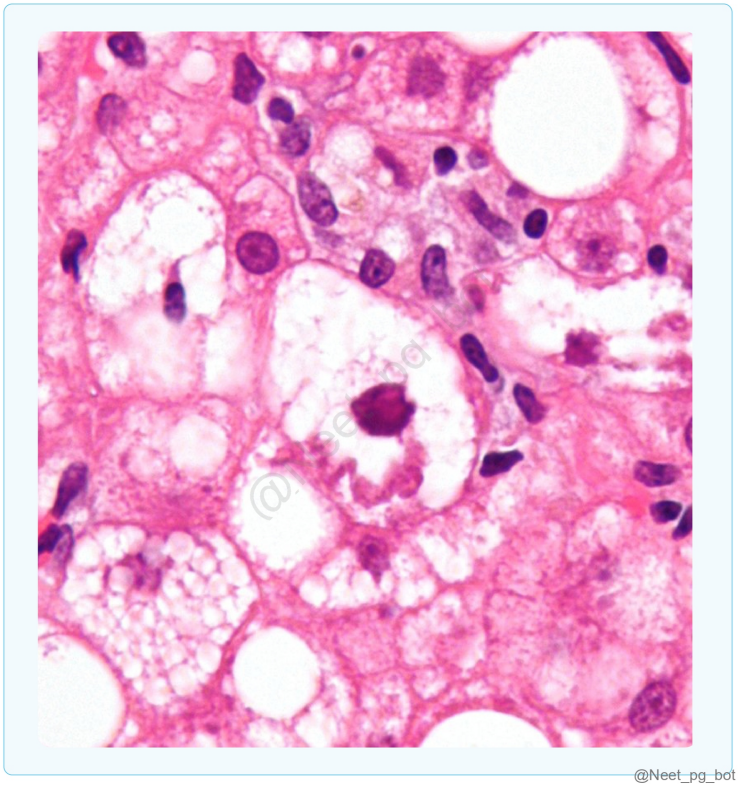

See Answer in Part B → Q13

@Neet_pg_bot

Q14: Which among the following are components of the MELD 3.0 score? 1) Male sex 2) Albumin 3) Creatinine 4) AST 5) INR 6) Serum Na+ (Q851294)

A. 1,2,3,5,6

B. 2,3,5,6

C. 1,3,4,5,6

D. 2,3,4,5

See Answer in Part B → Q14

@Neet_pg_bot

Q15: A female patient who is a known alcoholic presented to OPD with jaundice and malaise. Her initial reports were PT: 24 sec (N: 11-14sec); AST: 70 Units/L (N: 10-40 U/L) ; ALT: 70 Units/L (N: 8-55 U/L); Bilirubin: 2 mg/dL (N: 0.2-1.3 mg/dL). What is the preferred management of choice? (Q851295)

A. Only lifestyle modifications

B. Oral steroids

C. Zinc + Vit-E supplements

D. Liver transplant

See Answer in Part B → Q15

@Neet_pg_bot

Q16: Which among the following is not a component of Liver FibroTest? (Q851297)

A. Haptoglobin

B. Hyaluronic acid

C. γ-GT (GGT)

D. Total bilirubin

See Answer in Part B → Q16

@Neet_pg_bot

• [09_Hepatobiliary System] 069 Autoimmune Liver Disease Cholestasis Hepatotoxicity

« Back to Folder Directory

[09_Hepatobiliary System] 069 Autoimmune Liver Disease Cholestasis Hepatotoxicity — Quick Jump

Q1 (p. 834)	*Q2 (p. 834)*	*Q3 (p. 835)*	*Q4 (p. 835)*	*Q5 (p. 836)*	*Q6 (p. 836)*
Q7 (p. 836)	*Q8 (p. 837)*	*Q9 (p. 837)*	*Q10 (p. 838)*	*Q11 (p. 838)*	*Q12 (p. 838)*
Q13 (p. 839)	*Q14 (p. 839)*	*Q15 (p. 840)*	*Q16 (p. 840)*	*Q17 (p. 840)*	*Q18 (p. 841)*
Q19 (p. 842)	*Q20 (p. 843)*	*Q21 (p. 843)*	*Q22 (p. 844)*	*Q23 (p. 844)*	

Q1: A 12 y/o girl has elevated liver enzymes. She has vitiligo and is asymptomatic. Labs show ALT 320 U/L, AST 280 U/L, negative ANA and ASMA, and polyclonal hypergammaglobulinemia. Viral hepatitis serologies are negative. Which of the following autoantibodies is most specific for this subtype? (Q890466)

A. Antimitochondrial antibody (AMA)

B. Anti-liver kidney microsome type 1 (anti-LKM1)

C. Anti-soluble liver antigen (anti-SLA)

D. Perinuclear antineutrophil cytoplasmic antibody (pANCA)

See Answer in Part B → Q1

@Neet_pg_bot

Q2: Which of the following autoantibodies is found in approximately 65% of patients with primary sclerosing cholangitis (PSC) and can aid in distinguishing it from other cholestatic liver diseases? (Q890481)

A. Antimitochondrial antibody (AMA)

B. Anti-smooth muscle antibody (ASMA)

C. Perinuclear antineutrophil cytoplasmic antibody (pANCA)

D. Anti-liver kidney microsome type 1 (anti-LKM1)

See Answer in Part B → Q2

@Neet_pg_bot

Q3: A 48 y/o woman has 6 months of fatigue and nocturnal pruritus and has Hashimoto thyroiditis. The exam shows excoriations and xanthelasma. Ultrasound reveals a normal biliary tree. Labs show: Alkaline phosphatase: 450 U/L (↑↑), AST: 55 U/L, ALT: 60 U/L, Total bilirubin: 1.0 mg/dL, ANA: positive (1:40). What is the most appropriate next step to confirm the diagnosis? (Q890480)

A. Endoscopic retrograde cholangiopancreatography (ERCP)

B. Serum antimitochondrial antibody (AMA) titer

C. Percutaneous liver biopsy

D. Serum IgG4 level

See Answer in Part B → Q3

@Neet_pg_bot

Q4: A patient with primary biliary cholangitis (PBC) fails to achieve an adequate biochemical response to first-line therapy with ursodeoxycholic acid (UDCA). Which of the following agents is an established second-line treatment shown to produce significant biochemical improvement in this subset of patients? (Q890479)

A. Azathioprine

B. Prednisone

C. Obeticholic acid

D. Ribavirin

See Answer in Part B → Q4

@Neet_pg_bot

Q5: A 52 y/o woman presents with progressive fatigue and generalised pruritus, worse in the evening. Examination shows excoriations and xanthelasma. Laboratory results are as follows: Total bilirubin: 1.2 mg/dL, Alkaline phosphatase: 580 U/L (↑↑), AST: 65 U/L, ALT: 72 U/L, GGT: 350 U/L. Which of the following serologic markers is most likely to be positive? (Q890478)

A. Antinuclear antibody (ANA)

B. Antimitochondrial antibody (AMA)

C. Anti-smooth muscle antibody (ASMA)

D. Perinuclear antineutrophil cytoplasmic antibody (pANCA)

See Answer in Part B → Q5

@Neet_pg_bot

Q6: Which of the following pairs of symptoms represents the most prominent and characteristic clinical manifestations in symptomatic patients with primary biliary cholangitis? (Q890477)

A. Right upper quadrant pain and fever

B. Fatigue and pruritus

C. Arthralgias and skin rash

D. Nausea and vomiting

See Answer in Part B → Q6

@Neet_pg_bot

Q7: Which of the following autoantibodies detected in patients with autoimmune hepatitis is specifically associated with a worse prognosis? (Q890476)

A. Antinuclear antibody (ANA)

B. Anti-smooth muscle antibody (ASMA)

C. Anti-soluble liver antigen (anti-SLA)

D. Anti-liver kidney microsome type 1 (anti-LKM1)

See Answer in Part B → Q7

@Neet_pg_bot

Q8: A patient with autoimmune hepatitis is treated with standard first-line therapy, including corticosteroids and azathioprine, but fails to achieve biochemical remission. The clinician plans to escalate immunosuppressive therapy. Which of the following agents is the next drug of choice in this setting? (Q890475)

A. Methotrexate

B. Cyclosporine

C. Mycophenolate mofetil

D. Ursodeoxycholic acid

See Answer in Part B → Q8

@Neet_pg_bot

Q9: A patient with mild autoimmune hepatitis (aminotransferases <2× the upper limit of normal) requires initial corticosteroid therapy with minimal systemic effects. Which of the following corticosteroids is an alternative first-line option in this setting? (Q890474)

A. Dexamethasone

B. Methylprednisolone

C. Budesonide

D. Hydrocortisone

See Answer in Part B → Q9

@Neet_pg_bot

Q10: A patient with acute hepatitis is HBsAg positive with anti-HDV antibodies. To represent HDV superinfection on chronic hepatitis B rather than HBV-HDV coinfection. Which antibody profile confirms HDV superinfection? (Q890472)

A. IgM anti-HBc positive

B. IgG anti-HBc positive

C. Anti-HBs positive

D. IgM anti-HAV positive

See Answer in Part B → Q10

@Neet_pg_bot

Q11: Which of the following autoantibodies is considered the serologic hallmark of Type II autoimmune hepatitis? (Q890470)

A. Antinuclear antibody (ANA)

B. Anti-smooth muscle antibody (ASMA)

C. Anti-liver kidney microsome type 1 antibody (anti-LKM1)

D. Anti-soluble liver antigen (anti-SLA)

See Answer in Part B → Q11

@Neet_pg_bot

Q12: A patient on long-term antibiotic therapy develops chronic hepatitis with elevated aminotransferases. Serologic testing reveals positive ANA and anti-smooth muscle antibodies. Which antimicrobial agent is associated with this pattern of hepatotoxicity? (Q890468)

A. Amoxicillin-clavulanate

B. Erythromycin estolate

C. Ciprofloxacin

D. Nitrofurantoin

See Answer in Part B → Q12

@Neet_pg_bot

Q13: A 30-year-old woman presents to the clinic with fatigue, jaundice, and abdominal discomfort. Lab tests show elevated liver enzymes (AST and ALT). Further testing reveals positive antinuclear antibodies (ANA) and anti-smooth muscle antibodies (ASMA). A liver biopsy demonstrates interface hepatitis with plasma cell infiltration . Given the specific autoantibody profile and the histological findings, which of the following options is associated with the condition and is most relevant to consider in this patient? (Q851299)

A. Type 1 Autoimmune Hepatitis

B. Type 2 Autoimmune Hepatitis

C. Primary Biliary Cholangitis

D. Drug-Induced Liver Injury

See Answer in Part B → Q13

@Neet_pg_bot

Q14: A 7-year-old girl presents 20 hours after accidentally ingesting a large amount of iron supplements. Initially, she had abdominal pain, vomiting, and diarrhea, but these symptoms have resolved. Her vital signs are stable. What stage of iron toxicity is she experiencing? (Q851309)

A. Stage I

B. Stage II

C. Stage III

D. Stage IV

See Answer in Part B → Q14

@Neet_pg_bot

Q15: A 35-year-old man presents with complaints of nausea and abdominal pain after ingesting 20 paracetamol tablets approximately 8 hours ago. His vital signs are stable, but he has mild jaundice. Which of the following is the most appropriate next step in management? (Q851308)

A. Administer activated charcoal orally.

B. Start intravenous N-acetylcysteine therapy.

C. Perform a liver biopsy to assess damage.

D. Refer for liver transplantation.

See Answer in Part B → Q15

@Neet_pg_bot

Q16: A 28-year-old woman presents with a 2-day history of fatigue, jaundice, and dark urine after taking high doses of acetaminophen for headaches over the past week. Laboratory tests reveal elevated aminotransferases (>10,000 IU/L) and an INR of 2.5. What is the most likely underlying cause of her clinical presentation? (Q851307)

A. Glutathione depletion with NAPQI buildup

B. Enhanced glucuronidation of acetaminophen

C. Increased glutathione levels leading to liver injury

D. Inhibition of CYP2E1 by acetaminophen

See Answer in Part B → Q16

@Neet_pg_bot

Q17: A 26-year-old patient is treated with a combination of oxycodone and acetaminophen (325 mg per tablet). The patient has a history of opioid tolerance. What is a potential risk associated with this combination? (Q851306)

A. Increased risk of renal toxicity.

B. Decreased effectiveness of acetaminophen.

C. Greater likelihood of unintentional acetaminophen overdose.

D. Development of opioid dependency.

See Answer in Part B → Q17

@Neet_pg_bot

Q18: A 30-year-old woman presents with progressive jaundice and pruritus. She has a past medical history of ulcerative colitis. Her LFT revealed an elevated alkaline phosphatase & gamma-glutamyl transferase (GGT) and a prolonged prothrombin time. The liver biopsy is shown below. Which of the following serologic findings is most likely to be present in this patient? {{caption_text}} (Q851305)

A. Anti-liver kidney microsomal-1 antibodies (Anti-LKM-1)

B. Anti-mitochondrial antibody (AMA)

C. Perinuclear anti-neutrophil cytoplasmic antibody (pANCA)

D. Anti-centromere antibody

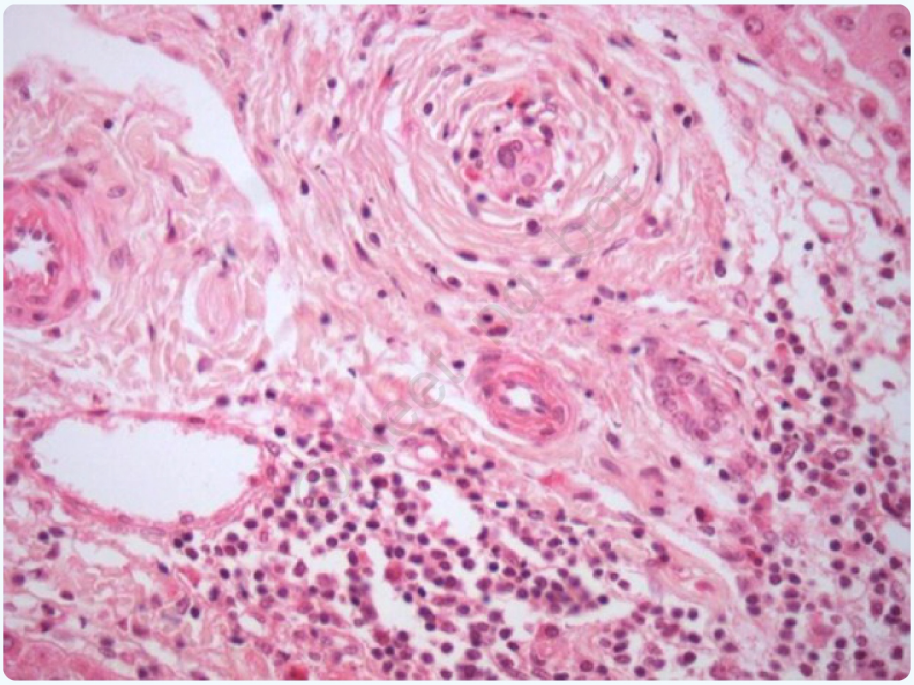

See Answer in Part B → Q18

@Neet_pg_bot

Q19: A 40-year-old male presents with a 6-month history of progressive fatigue and pruritus. He reports a recent onset of jaundice. His past medical history is significant for ulcerative colitis. Laboratory tests reveal elevated serum alkaline phosphatase and bilirubin, and atypical pANCA are positive. An MRCP is given below. Which of the following is the most likely diagnosis? {{caption_text}} (Q851304)

A. Primary Biliary Cholangitis

B. Primary Sclerosing Cholangitis

C. Choledocholithiasis

D. Chronic Pancreatitis

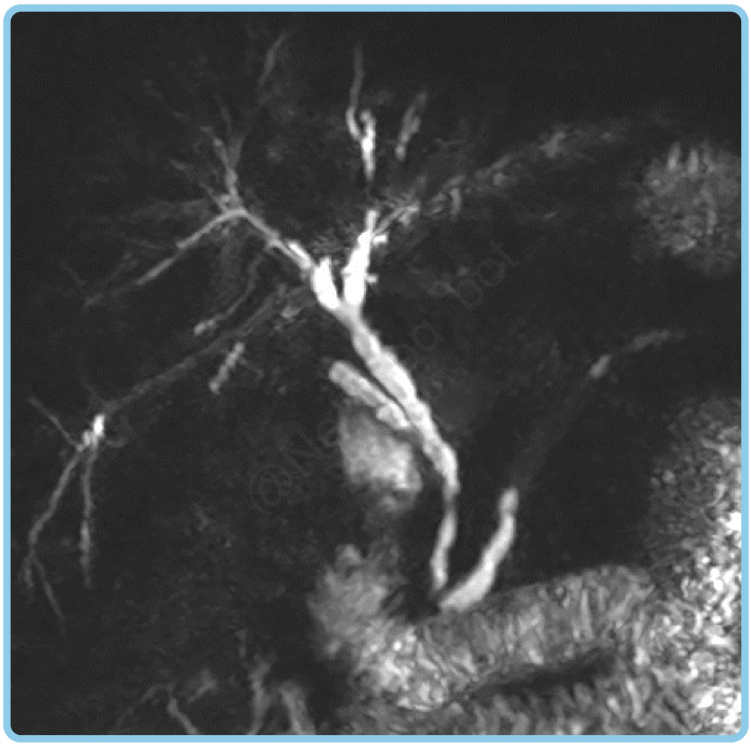

See Answer in Part B → Q19

@Neet_pg_bot

Q20: A 50-year-old woman presents with fatigue and pruritus. Laboratory tests show elevated alkaline phosphatase and positive antimitochondrial antibodies (AMAs). Which of the following is the most appropriate next step in the management of this patient? (Q851303)

A. Initiate ursodeoxycholic acid therapy

B. Schedule for liver transplantation evaluation

C. Start antiviral therapy for hepatitis

D. Refer for endoscopic retrograde cholangiopancreatography (ERCP)

See Answer in Part B → Q20

@Neet_pg_bot

Q21: Which of the following best describes the primary underlying mechanism of injury in Primary Biliary Cholangitis (PBC)? (Q851302)

A. Autoimmune-mediated destruction of bile ducts

B. Genetic mutation affecting bile acid metabolism

C. Viral infection leading to bile duct inflammation

D. Cholestasis due to gallstone obstruction

See Answer in Part B → Q21

@Neet_pg_bot

Q22: Which of the following statements regarding Autoimmune Hepatitis is False? (Q851301)

A. SGPT is significantly raised

B. Albumin ↓ and γ-globulin ↑↑

C. It is a diagnosis of exclusion

D. RA factor is negative

See Answer in Part B → Q22

@Neet_pg_bot

Q23: A 45-year-old woman presents with fatigue, jaundice, abdominal discomfort, and significant weight loss for three months. She reports itchy skin. Laboratory tests show elevated liver enzymes and positive antinuclear antibodies (ANA) and anti-smooth muscle antibodies (ASMA). She has a family history of autoimmune diseases. Which of the following clinical features is most commonly associated with the above scenario? (Q851300)

A. Splenomegaly

B. Weight gain

C. Presence of anti-mitochondrial antibodies (AMA)

D. Elevated alkaline phosphatase levels

See Answer in Part B → Q23

@Neet_pg_bot

• [09_Hepatobiliary System] 070 Liver Cirrhosis And Its Complications

« Back to Folder Directory

[09_Hepatobiliary System] 070 Liver Cirrhosis And Its Complications — Quick Jump

Q1 (p. 846)	*Q2 (p. 846)*	*Q3 (p. 847)*	*Q4 (p. 847)*	*Q5 (p. 847)*	*Q6 (p. 848)*
Q7 (p. 848)	*Q8 (p. 849)*	*Q9 (p. 850)*	*Q10 (p. 851)*	*Q11 (p. 851)*	*Q12 (p. 851)*
Q13 (p. 852)	*Q14 (p. 852)*	*Q15 (p. 853)*	*Q16 (p. 854)*	*Q17 (p. 854)*	*Q18 (p. 854)*
Q19 (p. 855)	*Q20 (p. 855)*	*Q21 (p. 856)*			

Q1: A 55-year-old male with a history of liver cirrhosis presents to the emergency department with hematemesis and signs of shock. He is diagnosed with acute variceal bleeding. What is the most appropriate initial management? (Q851351)

A. Administer intravenous terlipressin followed by prophylactic intravenous antibiotics

B. Start intravenous antibiotics and perform urgent endoscopy for band ligation

C. Administer intravenous vasopressin and initiate fresh frozen plasma transfusion

D. Begin intravenous corticosteroids and monitor for signs of hepatic encephalopathy

See Answer in Part B → Q1

@Neet_pg_bot

Q2: A 50-year-old male with a history of alcohol abuse and long-term hypertension presents with hematemesis, abdominal distension, and splenomegaly. He is hypotensive and tachycardic, with elevated liver enzymes, low platelets, and a high INR. Endoscopy reveals esophageal varices. Which of the following most likely explains the development of this condition? (Q851361)

A. Portal venous thrombosis leads to increased collateral circulation

B. Increased portal blood flow to the liver

C. Increased portal pressure forcing blood into collateral vessels

D. Reduced portal vascular resistance

See Answer in Part B → Q2

@Neet_pg_bot

Q3: A 62-year-old man with alcoholic cirrhosis presents to the emergency department with confusion, disorientation, and asterixis. His family reports increasing drowsiness and difficulty concentrating over the past few days. Investigations reveal normal electrolytes and elevated ammonia levels. What is the most appropriate initial treatment to lower ammonia? (Q851360)

A. Increase the protein intake

B. Zinc supplementation

C. Rifaximin

D. Lactulose

See Answer in Part B → Q3

@Neet_pg_bot

Q4: A 60-year-old woman with decompensated cirrhosis due to hepatitis B presents for evaluation of liver transplantation. All the following are indications for liver transplantation except? (Q851359)

A. Autoimmune hepatitis

B. Caroli’s disease

C. Fulminant hepatitis

D. Portal vein thrombosis

See Answer in Part B → Q4

@Neet_pg_bot

Q5: A 62-year-old male with a history of cirrhosis due to chronic hepatitis C presents with worsening abdominal distension, jaundice, and decreased urine output over the past week. He exhibits signs of confusion and ascites resistant to diuretics. Laboratory tests reveal a serum creatinine level of 2.5 mg/dL. Given this presentation, which of the following is the most definitive management of this condition? (Q851358)

A. Hemodialysis

B. Liver transplantation

C. Vasoconstrictor therapy with Terlipressin

D. Albumin infusion

See Answer in Part B → Q5

@Neet_pg_bot

Q6: A 54-year-old female with diabetes, obesity, and recent laparoscopic surgery presents to the emergency department with high fever, chills, rapid heart rate, extreme fatigue, and worsening abdominal pain. The physician suspects Systemic Inflammatory Response Syndrome (SIRS) and decides to perform an investigation as part of the diagnostic criteria. Which investigation should be performed? (Q851357)

A. Blood culture

B. Urine culture

C. Urine routine microscopy

D. Complete blood count

See Answer in Part B → Q6

@Neet_pg_bot

Q7: A 62-year-old male with malnutrition and alcoholic liver disease presents with increasing abdominal distension, shortness of breath, fever, and significant weight loss. The ascitic fluid shows a neutrophil count greater than 250/μL. Which of the following statements about this condition are true? 1. Ascitic fluid appears

transparent 2. Most commonly caused by Escherichia coli 3. Cefotaxime can be used for treatment 4. Norfloxacin administration may help to prevent it (Q851356)

A. 1, 2, 3

B. 1, 2, 4

C. 2, 3, 4

D. 1, 2, 3, 4

See Answer in Part B → Q7

@Neet_pg_bot

Q8: A 70-year-old male with a history of congestive heart failure, hypertension, and chronic kidney disease is scheduled for a procedure as depicted in the image below. What is the name of the procedure? {{caption_text}} (Q851355)

A. Pericardiocentesis

B. Thoracentesis

C. Paracentesis

D. Diagnostic peritoneal lavage



See Answer in Part B → Q8

@Neet_pg_bot

Q9: A 58-year-old female with chronic alcoholism, hepatitis C, and hypertension presents with abdominal distension, shortness of breath while lying flat, and fatigue. Ultrasound shows splenomegaly and an increased amount of peritoneal fluid. What are the expected serum-ascites albumin gradient (SAAG) and ascitic protein levels in this case? (Q851354)

A. <1.1 g/dL and <2.5 g/dL

B. ≥1.1 g/dL and <2.5 g/dL

C. <1.1 g/dL and ≥2.5 g/dL

D. ≥1.1 g/dL and ≥2.5 g/dL

See Answer in Part B → Q9

@Neet_pg_bot

Q10: A 62-year-old male with chronic liver disease, hepatitis C, and diabetes presents to the emergency department with worsening abdominal distension, shortness of breath, and fatigue. His swelling has worsened despite cutting sodium intake and increasing diuretics, and a fluid thrill is noted on examination. Which of the following medications is contraindicated in this case? (Q851353)

A. Clonidine

B. Amiloride

C. Midodrine

D. Propranolol

See Answer in Part B → Q10

@Neet_pg_bot

Q11: A 58-year-old man with chronic hepatitis and alcohol use presents with abdominal distension, discomfort, shortness of breath, and a weight gain of 5 kg over two weeks. Physical examination reveals thrombocytopenia, splenomegaly, and ascites. With approximately 120 mL of peritoneal fluid, which physical examination sign is most likely to be observed? (Q851352)

A. Fluid thrill

B. Shifting dullness

C. Puddle sign

D. All of the above

See Answer in Part B → Q11

@Neet_pg_bot

Q12: A 52-year-old male presents with progressive fatigue, abdominal distension, and worsening jaundice over the past three months. Examination reveals ascites, spider angiomata, and palmar erythema. Laboratory tests show elevated liver enzymes with

a significantly elevated AST/ALT ratio, and an ultrasound indicates a nodular liver. What role do kupffer cells play in the pathogenesis of this condition? (Q851339)

A. Activate CYP2E1

B. Increase the fatty acid uptake

C. Convert acetaldehyde to acetate

D. Induce cytokine production

See Answer in Part B → Q12

@Neet_pg_bot

Q13: A 60-year-old male with a history of alcohol use and chronic hepatitis presents with abdominal swelling, fatigue, difficulty eating, dark stools, and black vomitus. Examination shows splenomegaly, ascites and dilated veins around the umbilicus. Which of the following is the investigation of choice for this condition? (Q851348)

A. CT imaging

B. Blood counts

C. Endoscopy

D. Doppler ultrasound

See Answer in Part B → Q13

@Neet_pg_bot

Q14: A 58-year-old obese female with a history of DVT and recent appendectomy presents with worsening abdominal pain, swelling, fatigue, dark stools, and leg swelling. Examination reveals splenomegaly and findings, which are shown in the image below. Which of the following pathologies is most likely responsible for this condition? (Q851347)

A. Constrictive pericarditis

B. Veno-occlusive disease

C. Portal vein thrombosis

D. Inferior vena caval webs



See Answer in Part B → Q14

@Neet_pg_bot

Q15: A 55-year-old male with a history of chronic alcohol use presents with worsening abdominal swelling, fatigue, dizziness, increased abdominal size, and loss of appetite. Examination shows a hepatic venous pressure gradient (HVPG) of over 5 mm Hg. What is one of the earliest signs of this condition? (Q851346)

A. Puddle sign

B. Splenomegaly

C. Coffee ground vomitus

D. Caput medusae

See Answer in Part B → Q15

@Neet_pg_bot

Q16: A 52-year-old male with chronic hepatitis presents with fatigue, mild abdominal discomfort, decreased appetite, and occasional jaundice over the past few months but denies significant weight loss or night sweats. A liver biopsy showed fibrosis with expansion of most portal zones and occasional bridging. What Metavir fibrosis stage does this indicate? (Q851345)

A. F1

B. F2

C. F3

D. F4

See Answer in Part B → Q16

@Neet_pg_bot

Q17: A 47-year-old woman with a history of non-alcoholic fatty liver disease (NAFLD) presents for routine follow-up. She reports mild fatigue but denies significant abdominal pain or jaundice. On examination, she has no stigmata of chronic liver disease. The physician wants to assess the degree of liver fibrosis. Which of the following is the best non-invasive test to evaluate liver stiffness? (Q851344)

A. Computed tomography

B. Abdominal ultrasound

C. Magnetic resonance imaging

D. Transient elastography

See Answer in Part B → Q17

@Neet_pg_bot

Q18: A 58-year-old female with a history of chronic hepatitis C and cirrhosis presents with increasing abdominal distension, jaundice, and fatigue. On examination, she has ascites and spider nevi. Laboratory tests reveal elevated bilirubin levels, low albumin, and elevated liver enzymes. All of the following are criteria for Child-Pugh score classification except? (Q851343)

A. Ascites

B. Albumin

C. Bilirubin

D. AST/ALT

See Answer in Part B → Q18

@Neet_pg_bot

Q19: A 62-year-old male with cirrhosis presents to the emergency department with upper gastrointestinal bleeding and a Child-Pugh score of 10. Which scoring system is most appropriate for assessing his mortality risk related to liver disease? (Q851342)

A. PELD score

B. Rockall risk score

C. Forrest classification system

D. MELD score

See Answer in Part B → Q19

@Neet_pg_bot

Q20: A 68-year-old man with a history of cirrhosis presents with increased fatigue, and examination reveals multiple vascular lesions on the skin. His liver function tests show significant elevations in AST and ALT. What is the primary pathophysiological mechanism responsible for the formation of these lesions in cirrhosis? (Q851341)

A. Due to engorged superficial veins

B. Chronic Hypoxia

C. Because of platelet-derived growth factor

D. Increased vascularity due to estrogen



See Answer in Part B → Q20

@Neet_pg_bot

Q21: A 72-year-old male with chronic hepatitis C presents with severe fatigue, confusion, and increasing abdominal girth. Examination reveals jaundice, asterixis, and bilateral oedema. Laboratory tests show elevated bilirubin, transaminases, prolonged prothrombin time, and thrombocytopenia. An endoscopy shows the presence of non-bleeding varices. What is the most likely diagnosis? (Q851340)

A. Compensated cirrhosis

B. Alcoholic hepatitis

C. Acute liver failure

D. Decompensated cirrhosis

See Answer in Part B → Q21

@Neet_pg_bot

• [09_Hepatobiliary System] 071 Wilson Disease And Hemochromatosis

« Back to Folder Directory

[09_Hepatobiliary System] 071 Wilson Disease And Hemochromatosis — Quick Jump

Q1 (p. 858) *Q2 (p. 859)* *Q3 (p. 860)* *Q4 (p. 861)* *Q5 (p. 861)* *Q6 (p. 862)*
Q7 (p. 863) *Q8 (p. 863)* *Q9 (p. 864)* *Q10 (p. 864)* *Q11 (p. 865)* *Q12 (p. 865)*
Q13 (p. 866)

Q1: A 25-year-old male presents with fatigue, tremors, jaundice, and cognitive impairment. On examination, hepatomegaly is noted, and an ophthalmologic evaluation reveals a distinctive finding. Laboratory tests show elevated liver enzymes and increased copper levels. What is the underlying pathological mechanism causing this condition? (Q851384)

A. Reduced renal filtration of copper

B. Increased degradation of ceruloplasmin

C. Defective biliary excretion of copper

D. Impaired hepatic metabolism of ceruloplasmin



See Answer in Part B → Q1

@Neet_pg_bot

Q2: A 9-month-old pediatric patient presents with hypotonia, seizures, and delays in achieving developmental milestones. The child exhibits characteristic facial features, including a prominent forehead, sparse eyebrows, and distinct hair appearance. Laboratory results reveal decreased levels of copper and ceruloplasmin. What is the pattern of inheritance for this condition? (Q851387)

A. Autosomal recessive

B. Mitochondrial inheritance

C. X-linked recessive

D. Autosomal dominant



See Answer in Part B → Q2

@Neet_pg_bot

Q3: A 22-year-old male presents with symptoms of fatigue, jaundice, and abdominal pain. He also exhibits neurological manifestations, including tremors, dystonia, and personality changes. Laboratory investigations reveal elevated free serum copper levels, and liver function tests show increased ALT and AST. Based on these findings, which area of the brain is primarily implicated in the neurological symptoms of this condition? (Q851388)

A. Corpus callosum

B. Basal ganglia

C. Cerebellum

D. Hippocampus

See Answer in Part B → Q3

@Neet_pg_bot

Q4: During an eye camp, an elderly patient presented with a distinct ring around the cornea, as given below. The patient was referred to a higher centre for further evaluation. Several weeks later, the patient returned from the higher centre, reporting a progressive loss of vision. Upon examination, it was noted that a cataract had developed. Based on the initial observation and the current condition. Which of the following types of cataracts is most likely to be observed in this patient? (Q851389)

A. Stellate cataract

B. Snowflake cataract

C. Oil droplet cataract

D. Sunflower cataract



See Answer in Part B → Q4

@Neet_pg_bot

Q5: Which of the following investigation parameters is not generally considered definitive for the evaluation of Wilson's disease? (Q851393)

A. Serum copper levels

B. MRI of the brain

C. Liver biopsy

D. 24-hour urine excretion of copper

See Answer in Part B → Q5

@Neet_pg_bot

Q6: A 22-year-old patient presents with neurological symptoms such as tremors, dysarthria, and gait disturbances. An MRI of the brain is performed and reveals hyperintensities at the sites given below. Based on these findings and the clinical presentation, what is the most likely diagnosis? (Q851396)

A. Huntington's disease

B. Multiple sclerosis

C. Wilson’s disease

D. Parkinson’s disease



See Answer in Part B → Q6

@Neet_pg_bot

Q7: A 24-year-old patient presents with the following symptoms: tremors, dysarthria, irritability, and impulsive behavior, along with jaundice and the presence of Kayser-Fleischer rings on slit-lamp examination. What is the best treatment approach for this condition? (Q851399)

A. Penicillamine

B. Trientine

C. Zinc acetate

D. Dimercaprol

See Answer in Part B → Q7

@Neet_pg_bot

Q8: A 28-year-old patient who is a known case of Wilson's disease presents to the emergency department with acute liver failure. He has neurological symptoms and liver dysfunction. Upon evaluation, laboratory results reveal the following: Serum bilirubin: 12 mg/dL. Serum aspartate transferase (AST): 250 IU/L. Prothrombin time prolongation: 15 seconds. Based on these results, calculate the NAZER prognostic score for this patient and the next step in treatment accordingly. (Q851401)

A. NAZER score of 5; no need for transplantation

B. NAZER score of 8; medical management is sufficient

C. NAZER score of 9; liver transplantation is indicated

D. NAZER score of 11; monitor the patient without intervention

See Answer in Part B → Q8

@Neet_pg_bot

Q9: A 38-year-old woman presents with symptoms of fatigue, arthralgia, and new-onset diabetes. Her family history reveals that her father was diagnosed with hemochromatosis. Further evaluations show significantly elevated serum ferritin and transferrin saturation levels and that she carries both the C282Y and H63D mutations in the HFE gene. Based on her clinical presentation and genetic findings, which type of hemochromatosis is she most likely experiencing? (Q851402)

A. Type 1

B. Type 2

C. Type 3

D. Type 4

See Answer in Part B → Q9

@Neet_pg_bot

Q10: A 45-year-old male presents to the clinic with complaints of fatigue, joint pain, and a noticeable change in skin color, described as a slate-gray hue. He reports a

family history of liver disease and diabetes. Blood tests reveal elevated serum ferritin and transferrin saturation levels. Which of the following clinical features, once developed, progresses even after successful treatment of the condition? (Q851404)

A. Hepatomegaly

B. Cardiac arrhythmia

C. Arthropathy

D. Hypogonadism

See Answer in Part B → Q10

@Neet_pg_bot

Q11: A 45-year-old man presents with fatigue, joint pain, and new-onset diabetes. He has a family history of liver disease and reports high alcohol intake. Which biochemical test would be a strong indicator of hemochromatosis in this patient? (Q851406)

A. Plasma iron levels

B. Serum ferritin levels

C. Fasting serum transferrin saturation

D. Liver biopsy

See Answer in Part B → Q11

@Neet_pg_bot

Q12: A 25-year-old female comes with fatigue, joint pains, and a slate-gray appearance of the skin. After evaluation and detailed history, the physician suspects hemochromatosis. Which of the following statements about screening for hemochromatosis is false? (Q851408)

A. All adult first-degree relatives should be tested for C282Y and H63D mutations.

B. Genetic testing for the C282Y and H63D mutations is recommended if screening tests are abnormal.

C. Children of diagnosed individuals under 18 years old should always be screened for hemochromatosis.

D. Screening is done using transferrin saturation and ferritin levels.

See Answer in Part B → Q12

@Neet_pg_bot

Q13: A 45-year-old male patient with a confirmed diagnosis of hereditary hemochromatosis presents with symptoms of fatigue, diabetes, and joint pain. Laboratory tests reveal elevated serum ferritin levels of 2000 μg/dl. Which of the following is the most appropriate initial treatment for this patient? (Q851411)

A. Deferoxamine parenteral chelation therapy

B. Liver transplantation

C. Deferiprone oral chelation therapy

D. Phlebotomy

See Answer in Part B → Q13

@Neet_pg_bot

• [09_Hepatobiliary System] 072 Hereditary Hyperbilirubinemia Budd Chiari Syndrome

« Back to Folder Directory

[09_Hepatobiliary System] 072 Hereditary Hyperbilirubinemia Budd Chiari Syndrome — Quick Jump

Q1 (p. 867) *Q2 (p. 867)* *Q3 (p. 868)* *Q4 (p. 868)* *Q5 (p. 869)* *Q6 (p. 869)*
Q7 (p. 870) *Q8 (p. 870)* *Q9 (p. 870)*

Q1: A 3-month-old infant presents with jaundice. Laboratory tests reveal elevated bilirubin levels, with a higher proportion of unconjugated bilirubin. The infant's mother mentions that the jaundice has been present since birth and that the infant has not shown any signs of hemolysis. What is the most likely underlying cause of this infant's condition related to bilirubin metabolism? (Q851561)

A. Impaired uptake of bilirubin by hepatocytes

B. Defective conjugation of bilirubin due to UGT1A1 mutation

C. Reduced biliary excretion of bilirubin due to MRP2 mutation

D. Increased production of bilirubin due to hemolysis

See Answer in Part B → Q1

@Neet_pg_bot

Q2: A 17-year-old male presents to the clinic for a routine check-up. His laboratory tests reveal serum bilirubin levels of 45 μmol/L (2.6 mg/dL) with normal liver function tests. He reports occasional mild jaundice, particularly after periods of stress and fasting. There is no history of hemolysis or liver disease. The patient has been asymptomatic otherwise. What is the most likely diagnosis for this patient based on the provided information? (Q851562)

A. Crigler-Najjar Syndrome Type I

B. Crigler-Najjar Syndrome Type II

C. Dubin-Johnson Syndrome

D. Gilbert Syndrome

See Answer in Part B → Q2

@Neet_pg_bot

Q3: A 2-week-old infant is brought to the emergency department due to jaundice. The mother reports that the infant's skin has become increasingly yellow since birth. Laboratory tests reveal a serum bilirubin level of 450 μmol/L (26 mg/dL), and the infant appears lethargic. There are no signs of hemolysis, and a physical examination shows no other abnormalities. What is the most likely diagnosis for this infant based on the provided information? (Q851563)

A. Crigler-Najjar Syndrome Type I

B. Crigler-Najjar Syndrome Type II

C. Dubin-Johnson Syndrome

D. Rotor Syndrome

See Answer in Part B → Q3

@Neet_pg_bot

Q4: A 30-year-old woman presents to the clinic with intermittent jaundice that worsens during her menstrual cycle and when taking oral contraceptives. Laboratory tests reveal elevated conjugated bilirubin levels, but her liver function tests are otherwise normal. A liver ultrasound shows no significant abnormalities, and she has no history of significant liver disease. What is the most likely diagnosis for this patient based on the provided information? (Q851564)

A. Dubin-Johnson Syndrome

B. Rotor Syndrome

C. Budd-Chiari Syndrome

D. Crigler-Najjar Syndrome Type II

See Answer in Part B → Q4

@Neet_pg_bot

Q5: A 28-year-old man presents to the clinic with intermittent jaundice and dark urine. His laboratory tests show elevated conjugated bilirubin levels and urine tests reveal bilirubinuria. An ultrasound of the liver is unremarkable, and a cholecystography shows a normal gallbladder. The patient has no significant past medical history and is otherwise asymptomatic. What is the most likely diagnosis for this patient based on the provided information? (Q851565)

A. Crigler-Najjar Syndrome Type I

B. Gilbert Syndrome

C. Rotor Syndrome

D. Dubin-Johnson Syndrome

See Answer in Part B → Q5

@Neet_pg_bot

Q6: A 35-year-old woman presents to the emergency department with abdominal pain, severe ascites, and jaundice that developed over the past month. On examination, she has hepatomegaly and splenomegaly. Laboratory tests show elevated liver enzymes and bilirubin levels. A Doppler ultrasound of the abdomen reveals occlusion of multiple hepatic veins. What is the most likely diagnosis for this patient based on the provided information? (Q851566)

A. Dubin-Johnson Syndrome

B. Budd-Chiari Syndrome

C. Gilbert Syndrome

D. Rotor Syndrome

See Answer in Part B → Q6

@Neet_pg_bot

Q7: A 32-year-old woman presents with 2 months of progressive abdominal pain and distension. On examination, she has spider angiomas, hepatomegaly, and moderate ascites. Laboratory studies show haemoglobin 18.2 g/dL, WBC 13,000/μL, platelets 650,000/μL, and normal liver enzymes. Doppler ultrasound reveals hepatic vein thrombosis. Which of the following is the most common cause of the suspected condition? (Q851567)

A. Myeloproliferative disorders

B. Vitamin B12 deficiency

C. Inflammatory bowel disease

D. Chronic hepatitis C

See Answer in Part B → Q7

@Neet_pg_bot

Q8: A 35-year-old woman presents with 3 weeks of progressive abdominal pain and ascites. Laboratory studies show elevated LFTs and a prolonged PT. Doppler ultrasound reveals hepatic vein thrombosis. After initial diagnosis, which of the following represents the most appropriate sequential management approach? (Q851568)

A. Proceed directly to liver transplantation

B. Initiate anticoagulation, followed by assessment for predisposing causes and TIPS if needed

C. Start diuretics alone and monitor symptoms

D. Perform surgical shunting as primary therapy

See Answer in Part B → Q8

@Neet_pg_bot

Q9: Which of the following statements is true regarding how the Bromsulphthalein test helps distinguish between Rotor syndrome and Dubin-Johnson syndrome? (Q851569)

A. Dubin johnson syndrome - prolonged retention of BSP in the bloodstream Rotor syndrome - BSP is rapidly cleared.

B. Dubin Johnson syndrome - delayed excretion with prolonged retention of BSP occurs, Rotor syndrome - early excretion with no delayed retention.

C. Both Rotor syndrome and DJS show prolonged retention of BSP, making the test ineffective in differentiation.

D. Dubin Johnson syndrome - BSP is taken up slowly by the liver but is excreted rapidly, Rotor syndrome - BSP is taken up rapidly by the liver but is excreted slowly

See Answer in Part B → Q9

@Neet_pg_bot

• [09_Hepatobiliary System] 073 Previous Year Questions

« Back to Folder Directory

[09_Hepatobiliary System] 073 Previous Year Questions — Quick Jump

Q1 (p. 872)	*Q2 (p. 872)*	*Q3 (p. 873)*	*Q4 (p. 873)*	*Q5 (p. 873)*	*Q6 (p. 874)*
Q7 (p. 875)	*Q8 (p. 875)*	*Q9 (p. 876)*	*Q10 (p. 876)*	*Q11 (p. 877)*	*Q12 (p. 877)*
Q13 (p. 878)	*Q14 (p. 878)*	*Q15 (p. 879)*	*Q16 (p. 879)*	*Q17 (p. 879)*	*Q18 (p. 880)*
Q19 (p. 880)	*Q20 (p. 881)*	*Q21 (p. 881)*	*Q22 (p. 882)*	*Q23 (p. 882)*	

Q1: Which of the following conditions leads to the development of wing beating tremor? (Q857675)

A. Wilson’s disease

B. Huntington’s chorea

C. Parkinsonism

D. Sydenham’s chorea

See Answer in Part B → Q1

@Neet_pg_bot

Q2: A 45-year-old man with known alcoholic cirrhosis presents with confusion and 3 days of hematemesis. Examination reveals icterus, hepatosplenomegaly, tense ascites, and asterixis. Vitals: BP 100/60 mmHg, pulse 104/min. Which of the following is appropriate in the initial management of this patient? Start propranolol to stop variceal bleeding Perform a diagnostic ascitic tap to rule out spontaneous bacterial peritonitis (SBP) Start IV antibiotics and IV octreotide infusion Give IV albumin after large-volume paracentesis or if renal dysfunction develops (Q879181)

A. 1,2

B. 2,3,4

C. 1,2,3

D. 1,2,3,4

See Answer in Part B → Q2

@Neet_pg_bot

Q3: A patient presents with fever, jaundice, and malaise. Based on the serology reports provided, what is the most likely diagnosis? Serology Reports: HBsAg: Positive Anti-HBc: Positive Anti-HCV: Negative (Q856023)

A. Acute hepatitis D

B. Acute hepatitis B

C. Chronic hepatitis B

D. Chronic hepatitis C

See Answer in Part B → Q3

@Neet_pg_bot

Q4: Laboratory investigations of a patient being evaluated for jaundice show elevated bilirubin and alkaline phosphatase levels. Levels of the remaining liver enzymes are normal. What is the likely diagnosis? (Q855949)

A. Obstructive jaundice

B. Hemolytic jaundice

C. Hepatic jaundice

D. Prehepatic jaundice

See Answer in Part B → Q4

@Neet_pg_bot

Q5: A patient with a history of chronic liver disease presents with abdominal distension, jaundice, and pruritis. Ascitic fluid analysis revealed a neutrophil count of

650 per cubic mm. What is the most likely diagnosis? (Q855935)

A. Spontaneous bacterial peritonitis

B. Malignant ascites

C. Tubercular ascites

D. Intestinal obstruction



See Answer in Part B → Q5

@Neet_pg_bot

Q6: A patient presents to the emergency department with a history of ingestion of ten tablets of paracetamol. He has developed oliguria, and liver function tests show deranged values. Which of the following can be used in the management of this condition? (Q855921)

A. N-acetylcysteine

B. Dopamine

C. Ursodeoxycholic acid

D. Furosemide

See Answer in Part B → Q6

@Neet_pg_bot

Q7: What clinical examination is being performed in the image? (Q859798)

A. Shifting dullness

B. Ascites

C. Puddle sign

D. Fluid thrill



See Answer in Part B → Q7

@Neet_pg_bot

Q8: What is the most probable diagnosis for a 40-year-old man whose lab reports indicate positive IgG Anti-HBc and negative HBsAg? (Q859795)

A. Recovering from hepatitis B

B. Hepatitis B in the remote past

C. Immunization with HBsAg

D. Both B & C

See Answer in Part B → Q8

@Neet_pg_bot

Q9: A 53-year-old patient was brought to the emergency room with a history of alcohol abuse, altered sensorium, and rapid shallow breathing. His abdomen is distended with palpable hepatomegaly and splenomegaly and sclerae are icteric. The other examination findings are given below. Laboratory tests show that the AST: ALT ratio is 3:1. What is the most likely cause of this patient's presentation? (Q859785)

A. Alcoholic liver disease

B. Acute viral hepatitis

C. Autoimmune hepatitis

D. Acetaminophen poisoning

See Answer in Part B → Q9

@Neet_pg_bot

Q10: A 30-year-old female presents with unsteady gait, forgetfulness, and labile moods. During a physical exam, the neurologist notices the findings shown in the image below. The most likely diagnosis is: (Q859784)

A. Neurofibromatosis 2

B. Wilson's disease

C. Neurofibromatosis 1

D. Cataract



See Answer in Part B → Q10

@Neet_pg_bot

Q11: What is the child-Turcotte-Pugh class for the patient who has a serum bilirubin 2.5 mg/dl, serum albumin 3 g/dl, prothrombin time 5 seconds (INR =2), no encephalopathy, and mild ascites? (Q854983)

A. Class A

B. Class B

C. Class C

D. Class D

See Answer in Part B → Q11

@Neet_pg_bot

Q12: A chronic alcoholic male patient presented with abdominal distension, reduced urine output, and pedal oedema. His serum creatinine was 1.6 mg/dL. What is the next line of management for this patient? (Q856197)

A. Methylprednisolone

B. Heparin

C. Torsemide

D. Octreotide plus albumin

See Answer in Part B → Q12

@Neet_pg_bot

Q13: A young male patient has the following serological status: HbsAg positive, IgM anti Hbc negative, IgG Anti-Hbc positive and HBeAg positive. Select the best treatment for this patient? (Q866810)

A. Lamivudine

B. Ombitasvir

C. Ritonavir

D. Abacavir

See Answer in Part B → Q13

@Neet_pg_bot

Q14: A 20-year-old male presented with a history of yellowing of the skin and eyes for last one week after trekking on weekend. He had experienced a similar episode of yellowing 2 years ago for 2 weeks. Labs shows S. bilirubin level 2.4 mg/dL, unconjugated bilirubin at 2.1 mg/dL and conjugated bilirubin at 0.3 mg/dL. His AST and ALT levels are normal. What is the most likely diagnosis for this patient? (Q857009)

A. Dubin-Johnson syndrome

B. Crigler-Najjar type 1 syndrome

C. Gilbert syndrome

D. Rotor syndrome

See Answer in Part B → Q14

@Neet_pg_bot

Q15: Which benzodiazepine is suitable for the safe administration to a 40-year-old chronic alcoholic experiencing withdrawal symptoms, based on the liver function tests that indicated AST levels of 140 IU/L, ALT levels of 110 IU/L, and GGT levels of 500 IU/L? (Q855317)

A. Diazepam

B. Alprazolam

C. Clonazepam

D. Lorazepam

See Answer in Part B → Q15

@Neet_pg_bot

Q16: Which of the following is not a component of Child-Pugh scoring? (Q858010)

A. Albumin

B. Bilirubin

C. Prothrombin Time

D. Serum Creatinine

See Answer in Part B → Q16

@Neet_pg_bot

Q17: A 30-year-old male is found to be positive for HBsAg and HBeAg and is diagnosed with chronic hepatitis B. The viral load of the patient was 2 × 10■ IU/mL, and SGPT is found to be doubled. What is the appropriate management in this patient? (Q855436)

A. Lamivudine for 30+ weeks

B. Tenofovir for >40 weeks

C. Pegylated interferon for 52 weeks

D. Combined pegylated interferon with lamivudine

See Answer in Part B → Q17

@Neet_pg_bot

Q18: A 40-year-old patient presents with right upper quadrant discomfort and grade Il steatohepatitis of the liver. He has a history of regular intake of 2-3 alcoholic drinks daily and has a BMI of 29. What will be the most appropriate advice to the patient? (Q854719)

A. Lifestyle modification + Regular exercise

B. Lifestyle modification + vitamin E + Ursodeoxycholic acid

C. Lifestyle modification + Pioglitazone

D. Lifestyle modification

See Answer in Part B → Q18

@Neet_pg_bot

Q19: The work-up of a 25-year-old hotel worker shows the following profile: HbsAg = Negative Anti HBsAg= Negative HBeAg = Negative Anti Hbe = Negative Total anti-HBc = IgG positive What is the diagnosis? (Q854667)

A. Chronic hepatitis B

B. Inactive carrier

C. Hepatitis B in remote past

D. Window period/ Gap period

See Answer in Part B → Q19

@Neet_pg_bot

Q20: A 55-year-old man with a history of chronic alcoholism presents unconscious and hypotensive. He stopped drinking 7 days ago. Ultrasound shows coarse liver echotexture and mild portal vein dilatation. There is no history of recent alcohol withdrawal symptoms. What is the most appropriate next step in management? (Q840114)

A. Administer lactulose and wait for stool passage.

B. Perform emergency endoscopy to assess for varices.

C. Initiate treatment with thiamine and chlordiazepoxide.

D. Conduct a CT scan of the brain.

See Answer in Part B → Q20

@Neet_pg_bot

Q21: Patient presents with fatigue, pruritus and jaundice. Examination reveals hepatomegaly. LFT shows gross SAP elevation and elevated conjugated bilirubin. What is the most specific test to support diagnosis of PBC? (Q866508)

A. Anti-mitochondrial antibody

B. Antinuclear antibody

C. Anti-smooth muscle antibody

D. Anti L.K.M-1

See Answer in Part B → Q21

@Neet_pg_bot

Q22: A 5 year old boy presented with hematemesis and was found to have splenomegaly, on examination. There was a past history of exchange transfusion in this child for neonatal jaundice. What is the probable diagnosis? (Q866830)

A. Splenic vein thrombosis

B. Portal vein thrombosis

C. Budd chiari syndrome

D. Liver cirrhosis

See Answer in Part B → Q22

@Neet_pg_bot

Q23: A 20-year-old male presented with a 1 weak history of yellow skin and sclerae but is otherwise asymptomatic . He gives a history of viral upper respiratory infection 10 days ago, which resolved 2 days back. There is a history of a similar episode of icterus 2 years back when the patient had long hours of basketball practice . The current serum bilirubin is 2.4 mg/dl, unconjugated bilirubin is 2.1mg/dl, and conjugated bilirubin is 0.3mg/dl. Serum AST and ALT levels are normal . Which of the following is the most likely diagnosis ? (Q793887)

A. Dubin-Johnson syndrome

B. Criggler-Najar type 1 syndrome

C. Gilbert syndrome

D. Rotor syndrome

See Answer in Part B → Q23

@Neet_pg_bot

• [10_Pulmonology] 074 Cystic Fibrosis Obstructive Sleep Apnea

« Back to Folder Directory

[10_Pulmonology] 074 Cystic Fibrosis Obstructive Sleep Apnea — Quick Jump

Q1 (p. 883) *Q2 (p. 883)* *Q3 (p. 884)* *Q4 (p. 884)* *Q5 (p. 884)* *Q6 (p. 885)*
Q7 (p. 885) *Q8 (p. 886)* *Q9 (p. 886)* *Q10 (p. 887)* *Q11 (p. 887)* *Q12 (p. 887)*
Q13 (p. 888) *Q14 (p. 888)* *Q15 (p. 889)* *Q16 (p. 890)*

Q1: A 16-year-old female with cystic fibrosis presents with increased productive cough, fever, and worsening shortness of breath. Her sputum culture grows Pseudomonas aeruginosa. Which of the following best explains why this organism commonly causes respiratory infections in cystic fibrosis patients? (Q851570)

A. Defective neutrophil chemotaxis to the site of infection

B. Abnormal periciliary fluid layer leading to impaired mucociliary clearance

C. Direct immunosuppressive effect of the CFTR protein mutation

D. Increased expression of bacterial adhesion molecules on respiratory epithelium

See Answer in Part B → Q1

@Neet_pg_bot

Q2: A 3-month-old infant presents with failure to thrive, recurrent respiratory infections, and elevated sweat chloride. Genetic testing reveals two copies of the F508del mutation in the CFTR gene. This mutation results in a protein that fails to reach the cell surface due to degradation in the endoplasmic reticulum. Which class of CFTR mutation does this represent, and what percentage of CF patients carry at least one copy of this mutation? (Q851571)

A. Class I mutation; ~30% of patients

B. Class II mutation; ~70% of patients

C. Class III mutation; ~50% of patients

D. Class IV mutation; ~40% of patients

See Answer in Part B → Q2

@Neet_pg_bot

Q3: A 3-year-old boy comes to the emergency department with difficulty breathing and a productive cough. He has a history of recurrent sinusitis and otitis media and usually responds well to antibiotics. Crackles and wheezing are heard on pulmonary auscultation and CVS examination shows the cardiac point of maximum impulse on the right 5th intercostal space. Which of them is not seen in this condition? (Q851572)

A. Dynein arm defect

B. Normal sweat chloride test

C. CFTR mutation

D. Defective mucociliary clearance

See Answer in Part B → Q3

@Neet_pg_bot

Q4: A 7-year-old child presents with a chronic productive cough, nasal polyps, and poor weight gain despite normal appetite. Which of the following is the most likely associated condition? (Q851573)

A. Primary ciliary dyskinesia

B. Asthma

C. Cystic fibrosis

D. Bronchopulmonary dysplasia

See Answer in Part B → Q4

@Neet_pg_bot

Q5: A 2-month-old infant presents with recurrent respiratory infections and failure to thrive. Physical examination reveals digital clubbing and productive cough. A sweat test shows elevated chloride levels, but the genotype analysis for common CFTR mutations is inconclusive. Which of the following investigations is the next best step for confirming the diagnosis of cystic fibrosis in this patient? (Q851574)

A. Bronchoalveolar lavage

B. Nasal potential difference measurement

C. Chest X-ray

D. Genetic panel including rare CFTR mutations

See Answer in Part B → Q5

@Neet_pg_bot

Q6: A newborn screening for CF shows elevated immunoreactive trypsinogen (IRT) levels. What is the next best step in the diagnostic process? (Q851575)

A. Repeat the IRT test in 6 months

B. Genetic testing for CFTR mutations

C. Chest X-ray

D. Fecal elastase levels

See Answer in Part B → Q6

@Neet_pg_bot

Q7: Which of the following therapies directly targets the basic molecular defect in cystic fibrosis for a patient with a G551D mutation? (Q851576)

A. Pancreatic enzyme supplements

B. Lumacaftor

C. Ivacaftor

D. Hypertonic saline nebulization

See Answer in Part B → Q7

@Neet_pg_bot

Q8: A 45-year-old obese male (BMI- 40) presents with complaints of loud snoring and daytime sleepiness. His wife reports that he complains of disturbed sleep due to waking up out of breath because of an obstruction of the airway. Polysomnography reveals repetitive episodes showing: Sharp inspiratory uptake Flattened/plateau wave Scooped out breathing pattern Flow limitation Oxygen desaturation What is the correct sequence of pathophysiologic events leading to his symptoms? (Q851577)

A. REM sleep → Hypoxia → Pharyngeal dilator muscle relaxation → Airway narrowing → snoring

B. Pharyngeal dilator muscle relaxation → Airway narrowing → Flow limitation → Hypoxia → Cortical arousal

C. Obesity → Flow limitation → Airway collapse → Snoring → Bradycardia → Hypoxia

D. Hypoxia → Airway collapse → Flow limitation → Bradycardia → Cortical arousal

See Answer in Part B → Q8

@Neet_pg_bot

Q9: A 45-year-old man presents with complaints of daytime sleepiness and morning headaches, and his wife reports loud snoring with episodes of gasping during sleep. His BMI is 32 kg/m², neck circumference is 44 cm, and he has retrognathia. His blood pressure is 148/92 mmHg. Which of the following combinations of additional clinical features and diagnostic findings would not be seen with obstructive sleep apnea in this patient? (Q851578)

A. Fragmented sleep on PSG

B. Central obesity, elevated sweat chloride, pancreatic insufficiency

C. Nondipping nocturnal blood pressure pattern

D. Frequent arousals with oxygen desaturation

See Answer in Part B → Q9

@Neet_pg_bot

Q10: Which of the following statements is incorrect regarding risk factors of Obstructive Sleep Apnea? (Q851579)

A. Premenopausal women have the same risk for OSA as postmenopausal women

B. A 10% increase in body weight is associated with a >30% increase in apnea-hypopnea index (AHI)

C. Approximately 40-60% of OSA cases are attributable to excess body weight

D. Men have approximately twice the risk of developing OSA compared to women

See Answer in Part B → Q10

@Neet_pg_bot

Q11: A 52-year-old man presents to his primary care physician with complaints of excessive daytime sleepiness and his spouse reports loud snoring with disturbed sleep due to breathing pauses during sleep. His BMI is 34 kg/m² and neck circumference is 43 cm. Which of the following should be the INITIAL step in evaluating this patient? (Q851580)

A. Order an overnight polysomnography immediately

B. Start CPAP therapy based on symptoms

C. Obtain detailed sleep history with standardized sleepiness questionnaires and perform focused physical examination

D. Order overnight home oximetry

See Answer in Part B → Q11

@Neet_pg_bot

Q12: A 45-year-old man is diagnosed with moderate obstructive sleep apnea (AHI=22/hour) based on polysomnography. He has daytime sleepiness, BMI of 35

kg/m², and hypertension. Which of the following is the most appropriate initial treatment approach for this patient? (Q851581)

A. Prescribe oral appliance therapy as first-line treatment

B. Initiate CPAP therapy with appropriate pressure titration and provide supportive care

C. Recommend uvulopalatopharyngoplasty without trying conservative measures

D. Lifestyle modification and weight loss

See Answer in Part B → Q12

@Neet_pg_bot

Q13: A 45-year-old male reports persistent daytime sleepiness, often dozing off during meetings and while watching television. He completes the Epworth Sleepiness Scale (ESS) and scores 12. What does a score of 12 indicate? (Q851583)

A. Unlikely to be abnormally sleepy.

B. Average daytime sleepiness.

C. Possibly excessively sleepy; consider medical attention.

D. Excessively sleepy; seek immediate medical attention.

See Answer in Part B → Q13

@Neet_pg_bot

Q14: A 52-year-old obese male presents to the clinic with excessive daytime sleepiness hypoventilation and difficulty breathing at night. His BMI is 32 kg/m², and arterial blood gas analysis shows a Paco2 of 48 mmHg recorded during the day. The patient reports loud snoring and episodes of gasping during sleep. He has a history of severe obesity and is suspected of having obstructive sleep apnea. Based on the scenario, which of the following diagnoses is most likely? (Q851594)

A. Central Hypoventilation Syndrome

B. Obesity Hypoventilation Syndrome

C. Congenital Central Hypoventilation Syndrome

D. Simple Obstructive Sleep Apnea

See Answer in Part B → Q14

@Neet_pg_bot

Q15: A 25-year-old tall male presents to the emergency department with acute retrosternal chest pain and difficulty breathing after a vigorous bout of coughing. He reports having experienced frequent coughing spells over the past week due to a respiratory infection. On physical examination, subcutaneous emphysema is noted in the neck region. The chest X-ray of the patient is given below. Which of the following statements best describes a potential cause of this patient's condition? (Q851595)

A. The condition is likely caused by a foreign body in the airway.

B. Increased intra-alveolar pressure from excessive coughing can lead to alveolar rupture.

C. This condition is primarily associated with high BMI individuals.

D. Always a result of blunt trauma.

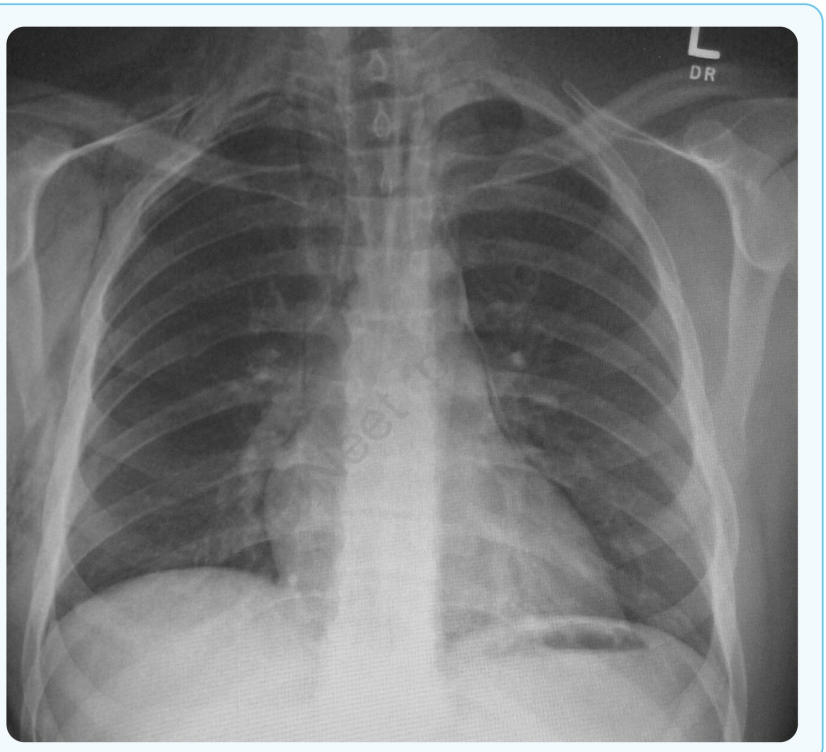

@Neet_pg_bot

See Answer in Part B → Q15

@Neet_pg_bot

Q16: A 7-year-old boy presents to the emergency department with chest pain and difficulty breathing after experiencing a severe coughing fit. A chest X-ray is performed and is given below. Which of the following statements is true regarding the management of this condition? (Q851597)

A. The primary diagnostic tool for this condition is a CT scan.

B. Surgical intervention is always required for treatment.

C. Conservative management is usually sufficient for most patients with this condition.

D. Prophylactic antibiotics are necessary for all patients diagnosed.

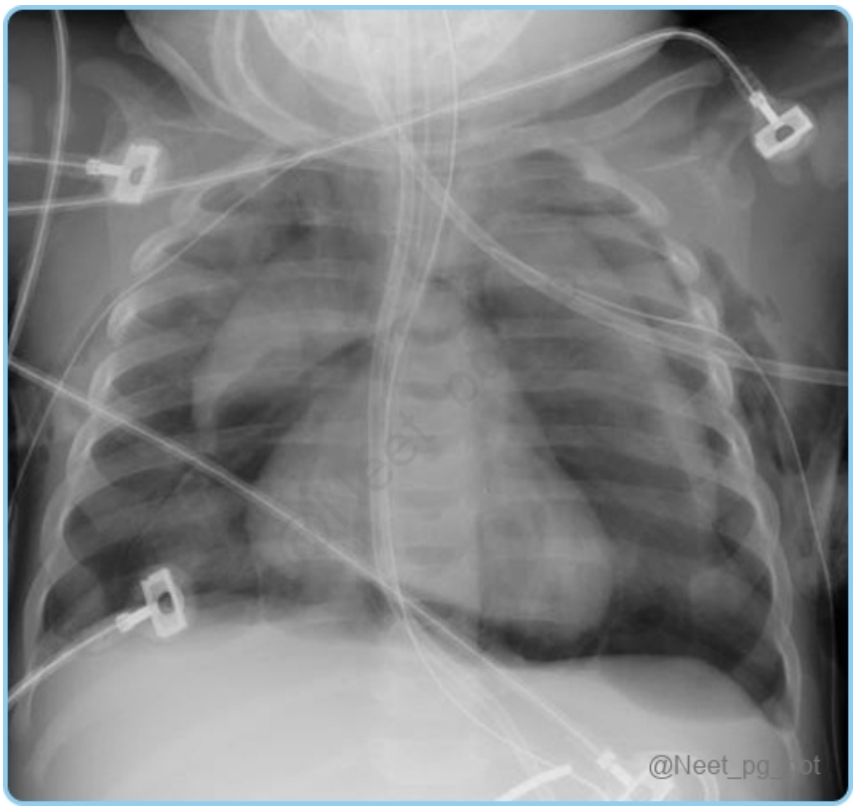

See Answer in Part B → Q16

@Neet_pg_bot

• [10_Pulmonology] 075 Pulmonary Embolism Dvt And Fat Embolism

« Back to Folder Directory

[10_Pulmonology] 075 Pulmonary Embolism Dvt And Fat Embolism — Quick Jump

Q1 (p. 892)	*Q2 (p. 892)*	*Q3 (p. 893)*	*Q4 (p. 893)*	*Q5 (p. 893)*	*Q6 (p. 894)*
Q7 (p. 894)	*Q8 (p. 895)*	*Q9 (p. 895)*	*Q10 (p. 895)*	*Q11 (p. 896)*	*Q12 (p. 897)*
Q13 (p. 897)	*Q14 (p. 898)*	*Q15 (p. 898)*			

Q1: A 30-year-old male develops respiratory distress, confusion, and a chest petechial rash two days after surgery for multiple long bone fractures from a motor vehicle accident. Suspecting Fat Embolism Syndrome (FES), which diagnostic test is used to detect fat in this condition? (Q851917)

A. Chest CT

B. Bronchoalveolar lavage (BAL)

C. Intracranial Doppler ultrasonography

D. Head CT

See Answer in Part B → Q1

@Neet_pg_bot

Q2: A 60 y/o woman presents with sudden shortness of breath and pleuritic chest pain. She had a total hip replacement 10 days ago. O/E, she is tachycardic with low oxygen levels. What is the most likely cause of her symptoms? (Q851892)

A. Fat embolism

B. Tumor emboli

C. Air emboli

D. Pulmonary embolism

See Answer in Part B → Q2

@Neet_pg_bot

Q3: Which of the following statements regarding causes of DVT is true? (Q851893)

A. Factor V Leiden increases the effectiveness of activated protein C.

B. Prothrombin gene mutation decreases the concentration of prothrombin in the blood.

C. Cancer increases the risk of DVT fourfold compared to the general population.

D. Pregnancy reduces the risk of venous stasis.

See Answer in Part B → Q3

@Neet_pg_bot

Q4: A 62 y/o hypertensive woman with a history of recent surgery presents with sudden onset of dyspnea and chest pain. ABG analysis reveals hypoxemia. A CT angiogram confirms the presence of a pulmonary embolism. What describes changes in the lung in this condition? (Q851895)

A. Increased pulmonary compliance

B. Decreased alveolar-arterial oxygen gradient

C. Increased physiologic dead space

D. Improved gas exchange efficiency

See Answer in Part B → Q4

@Neet_pg_bot

Q5: A 45 y/o man presents with chest pain and dyspnea. A CT scan shows multiple pulmonary emboli. He is diagnosed with right ventricular dysfunction secondary to the emboli. Which of the following best explains the cause of the same? (Q851896)

A. Left ventricular failure

B. Microinfarctions of the right ventricle

C. Decreased pulmonary vascular resistance

D. Improved coronary perfusion

See Answer in Part B → Q5

@Neet_pg_bot

Q6: A 58 y/o woman with a history of DVT presents to the hospital with sudden onset chest pain, tachycardia, and cyanosis. She is diagnosed with a massive pulmonary embolism. What is the most likely clinical finding that indicates acute cor pulmonale? (Q851898)

A. Loud S1 heart sound

B. Jugular venous distention

C. Bradycardia

D. Elevated blood pressure

See Answer in Part B → Q6

@Neet_pg_bot

Q7: A 62 y/o male presents to the emergency with a history of prolonged immobility after recent hip surgery. His vital signs are as follows: respiratory rate of 28 bpm, heart rate of 110 bpm, and blood pressure of 90/60 mmHg. The D-dimer level is 900 mg/dL, and the CTPA scan shows filling defects. What is the most common symptom associated with this condition at the initial stage of presentation? (Q851900)

A. Syncope

B. Pleuritic chest pain

C. Unexplained dyspnea

D. Hemoptysis

See Answer in Part B → Q7

@Neet_pg_bot

Q8: A 62 y/o woman with a history of breast cancer is treated with chemotherapy. She presents with swelling and localised tenderness in her right leg. She was recently hospitalised for surgery and has been bedridden for the past three weeks. Examination shows pitting edema confined to the right leg, but no collateral veins and no previous DVT history. What is the patient's risk for DVT based on the Wells Criteria? (Q851901)

A. DVT unlikely

B. Low probability

C. Moderate probability

D. High probability

See Answer in Part B → Q8

@Neet_pg_bot

Q9: A 65y/o man presents to the emergency department with a sudden onset of pleuritic chest pain, dyspnea, and mild hypotension. His echocardiogram shows right ventricular (RV) dysfunction, but his systemic arterial pressure remains normal. Which of the following is the most appropriate next step in management? (Q851904)

A. Immediate anticoagulation and observation

B. Fibrinolytic therapy

C. Catheter-directed thrombolysis

D. Surgical embolectomy

See Answer in Part B → Q9

@Neet_pg_bot

Q10: A 60 y/o male with a history of recent surgery presents with acute onset dyspnea and pleuritic chest pain. His ECG findings show sinus tachycardia. Which of the following investigations would most directly confirm the diagnosis of pulmonary embolism (PE)? (Q851906)

A. Chest X-ray

B. Ventilation-perfusion (V/Q) scan

C. CT pulmonary angiogram

D. D-Dimer

See Answer in Part B → Q10

@Neet_pg_bot

Q11: A 70-year-old woman with atrial fibrillation presents with sudden-onset dyspnea and pleuritic chest pain. She is hypotensive, tachycardic, and confused. Chest X-ray shows a wedge-shaped opacity in the right lung as shown in image. What is the most appropriate initial management? {{caption_text}} (Q851909)

A. Initiation of oral anticoagulation

B. Starting her on intravenous unfractionated heparin

C. Administration of thrombolytic therapy

D. Performing a surgical embolectomy

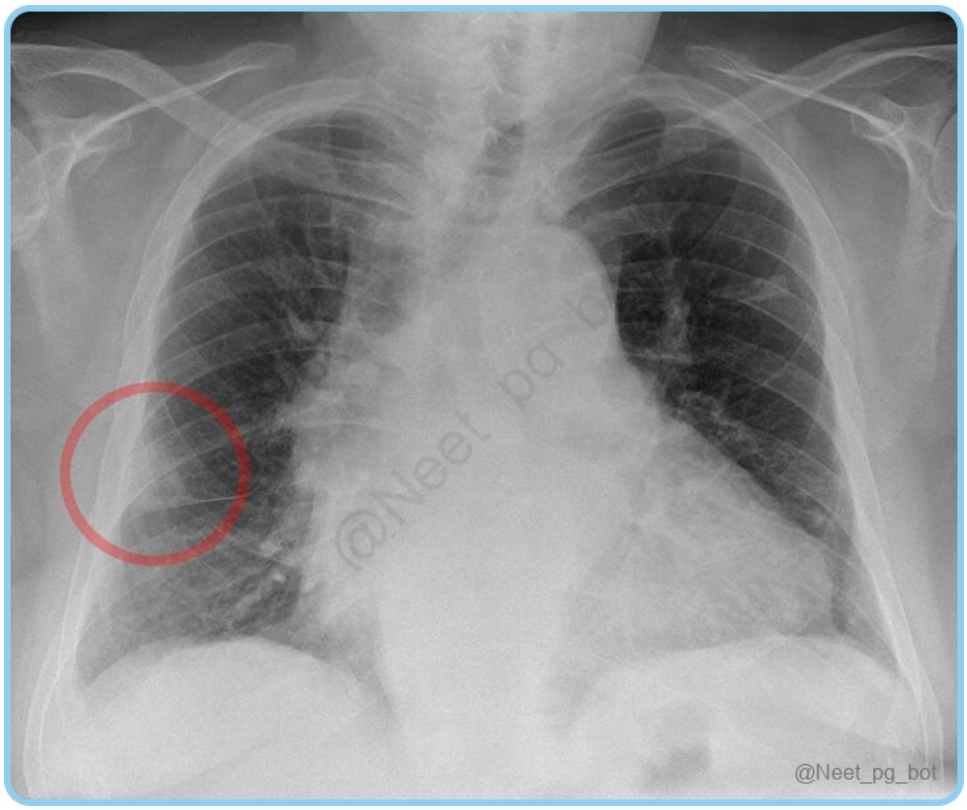

See Answer in Part B → Q11

@Neet_pg_bot

Q12: A 72 y/o woman presents to the ED with sudden onset dyspnea and chest pain. On examination, she is hypotensive (systolic BP 85 mm Hg), has tachycardia, and exhibits signs of altered consciousness. An echocardiogram shows right ventricular (RV) dysfunction. What is the most likely diagnosis? (Q851910)

A. Submassive pulmonary embolism

B. Massive pulmonary embolism

C. Pneumonia

D. Myocardial infarction

See Answer in Part B → Q12

@Neet_pg_bot

Q13: A 28 y/o man is admitted to the ED following a motorcycle accident resulting in multiple fractures of the right femur and left humerus. Two days post-injury, he developed sudden onset dyspnea, altered mental status, and a petechial rash around his neck and conjunctiva. What is the most likely diagnosis? (Q851911)

A. Acute Respiratory Distress Syndrome (ARDS)

B. Fat Embolism Syndrome (FES)

C. Pulmonary Embolism (PE)

D. Deep Vein Thrombosis (DVT)

See Answer in Part B → Q13

@Neet_pg_bot

Q14: A 28 y/o male presents to the ED after sustaining multiple long bone fractures in a motorcycle accident. Two days post-injury, he exhibits tachypnea, confusion, and a petechial rash on his torso. Which of the following is NOT a part of the diagnostic criteria for the patient's likely condition? (Q851913)

A. Sudden thrombocytopenia

B. Elevated white blood cell count

C. Elevated erythrocyte sedimentation rate (ESR)

D. Petechial rash

See Answer in Part B → Q14

@Neet_pg_bot

Q15: A 40-year-old male presents to the emergency department after sustaining multiple long bone fractures in a car accident. Two days later, he developed respiratory distress, confusion, and a petechial rash. His oxygen saturation is dropping, and the medical team begins supportive care, including fluid resuscitation and monitoring. Which of the following is the best option for expanding plasma volume and potentially limiting lung injury in this patient with FES? (Q851918)

A. Normal saline

B. Ringer lactate solution

C. Albumin

D. Corticosteroids

See Answer in Part B → Q15

@Neet_pg_bot

• [10_Pulmonology] 076 Bronchiectasis Pneumonia

« Back to Folder Directory

[10_Pulmonology] 076 Bronchiectasis Pneumonia — Quick Jump

Q1 (p. 900)	*Q2 (p. 900)*	*Q3 (p. 901)*	*Q4 (p. 901)*	*Q5 (p. 902)*	*Q6 (p. 902)*
Q7 (p. 903)	*Q8 (p. 904)*	*Q9 (p. 904)*	*Q10 (p. 905)*	*Q11 (p. 905)*	*Q12 (p. 907)*
Q13 (p. 907)	*Q14 (p. 908)*	*Q15 (p. 908)*	*Q16 (p. 909)*	*Q17 (p. 910)*	*Q18 (p. 910)*
Q19 (p. 910)	*Q20 (p. 911)*				

Q1: Which of the following statements are false regarding primary lung abscesses? (Q851712)

A. Most cases are polymicrobial infections.

B. Hematologic dissemination is one of the causes

C. Poor dental hygiene is an independent risk factor for developing lung abscesses

D. Staphylococcus aureus can cause lung abscesses in individuals with alcohol use disorder.

See Answer in Part B → Q1

@Neet_pg_bot

Q2: A 55-year-old patient presents with fever, productive cough, and pleuritic chest pain. A chest CT scan reveals a fluid collection in the pleural space with a thickened pleura. Which of the following is the most likely diagnosis? (Q851740)

A. Empyema

B. Lung abscess

C. Pneumonia

D. Pulmonary edema

See Answer in Part B → Q2

@Neet_pg_bot

Q3: A 55-year-old patient presents with a productive cough, fever, and shortness of breath. A chest X-ray reveals a lobar consolidation. Which of the following is the most likely causative organism of community-acquired pneumonia in this patient? (Q851739)

A. Klebsiella pneumoniae

B. Haemophilus influenzae

C. Streptococcus pneumoniae

D. Pseudomonas aeruginosa

See Answer in Part B → Q3

@Neet_pg_bot

Q4: A 35-year-old HIV-positive patient presents with a non-productive cough, dyspnea, and low-grade fever. A Gomori methenamine silver stain of a bronchoalveolar lavage specimen was done. What is the most appropriate treatment for this patient? (Q851738)

A. Azithromycin

B. Amphotericin B

C. Co-trimoxazole

D. Itraconazole

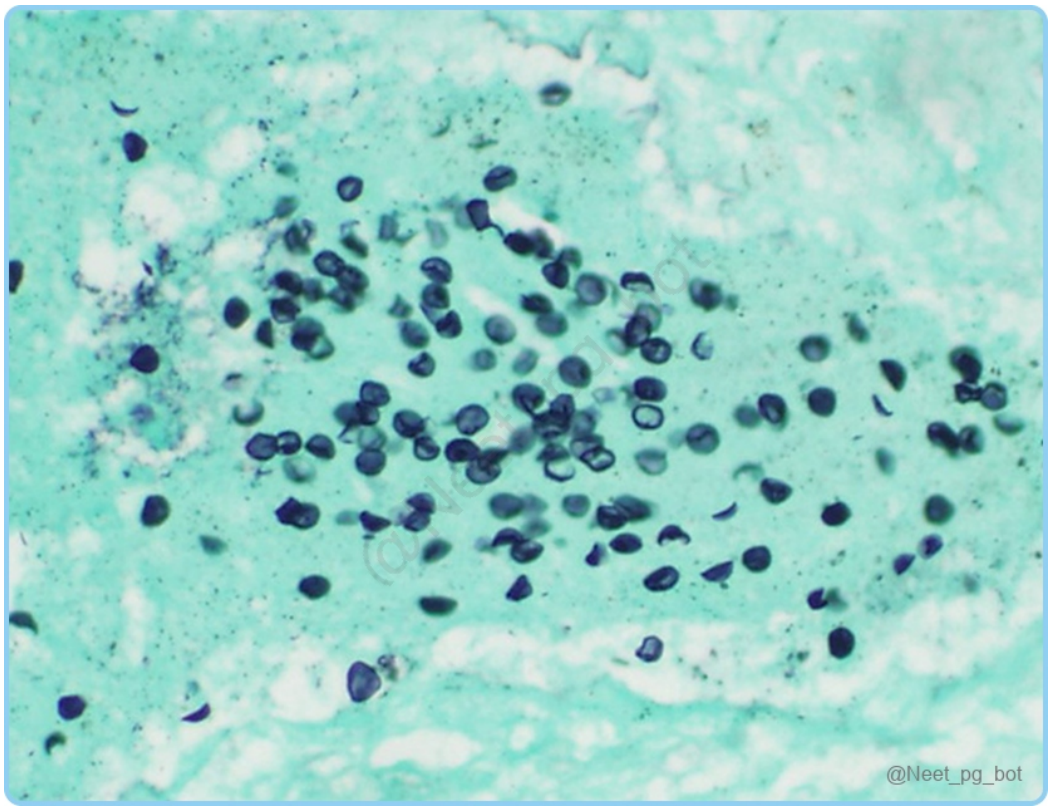

See Answer in Part B → Q4

@Neet_pg_bot

Q5: A 60-year-old male presents with fever, cough, and chest discomfort. His chest X-ray reveals right lower lobe consolidation. Which of the following features would be more consistent with atypical pneumonia? (Q851737)

A. Gradual onset with a dry cough

B. High-grade fever

C. Lobar consolidation on chest X-ray

D. Productive cough with purulent sputum

See Answer in Part B → Q5

@Neet_pg_bot

Q6: A 70 y/o man with COPD presents with 3 days of worsening shortness of breath, fever, and productive cough. He appears confused and has a respiratory rate of 32/min, BP of 85/55 mmHg, and BUN of 25 mg/dL. What is the most appropriate management? (Q851736)

A. Outpatient treatment with azithromycin

B. Inpatient treatment with levofloxacin and azithromycin

C. ICU admission with piperacillin-tazobactam and vancomycin

D. Inpatient treatment with amoxicillin alone

See Answer in Part B → Q6

@Neet_pg_bot

Q7: A 65 y/o woman is admitted to the hospital with a high fever, productive cough, and pleuritic chest pain. A physical examination reveals diminished breath sounds on the right side, and she appears confused. The chest X-ray is given below. Despite this, the physician considers further testing. Which of the following investigations should be prioritized next to confirm the causative organism of the suspected diagnosis? (Q851725)

A. Sputum Gram stain and culture

B. Complete Blood Count

C. CT chest

D. Influenza testing

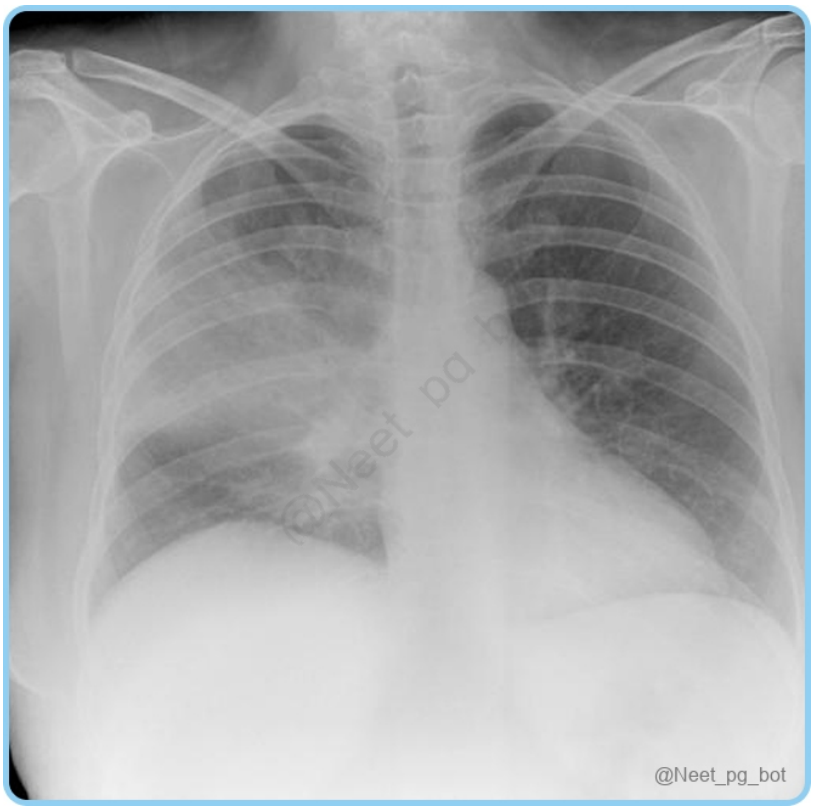

See Answer in Part B → Q7

@Neet_pg_bot

Q8: Which of the following statements are true regarding breath sounds? (Q851724)

A. Vesicular breath sounds are soft, low-pitched sounds heard at the bronchus

B. Bronchial sounds are loud, high-pitched best heard at lung bases of normal lung

C. Egophony is the increased resonance of voice sounds heard when auscultating the lungs

D. Whispered pectoriloquy rules out the presence of lung consolidation

See Answer in Part B → Q8

@Neet_pg_bot

Q9: A 65 year old man presents to the ED with a 5-day history of fever, productive cough, and worsening shortness of breath. On examination, he exhibits tachypnea, and

his sputum is thick and yellowish. He complains of sharp pleuritic chest pain when taking deep breaths. The physician notes increased vocal fremitus and egophony on examination. Based on the clinical features presented, which of the following findings is most likely to be noted upon auscultation of this patient's lungs? (Q851723)

A. Absence of breath sounds

B. Wheezing

C. Ronchi

D. Presence of crackles and bronchial breath sounds

See Answer in Part B → Q9

@Neet_pg_bot

Q10: Match the following conditions of pneumonia to their respective causative organisms: 1. Alcoholic patient with Pneumonia a) Legionella pneumophila 2. Pneumonia due to contact with Bats b) Coxiella burnetii 3. Pneumonia after Hotel/cruise c) Pneumococcus pneumonia 4. Pneumonia due to contact with Goat/sheep d) Histoplasmosis (Q851722)

A. 1-c, 2-d, 3-a, 4-b

B. 1-d, 2-b, 3-a, 4-c

C. 1-a, 2-b, 3-d, 4-a

D. 1-b, 2-c, 3-d, 4-a

See Answer in Part B → Q10

@Neet_pg_bot

Q11: A 60 y/o woman presents with the characteristic fingers as shown in the image, along with chronic cough, daily production of large amounts of purulent sputum and a history of recurrent lung infections over the past several years. Her CT scan revealed the following findings. A biopsy of the affected lung tissue is performed. Which of the following histopathological findings is most likely present? (Q851702)

A. Chronic inflammatory destruction of bronchial walls with loss of smooth muscle and elastic tissue

B. Presence of caseating granulomas

C. Extensive alveolar damage

D. Bronchiectatic cavities lined exclusively by ciliated epithelium



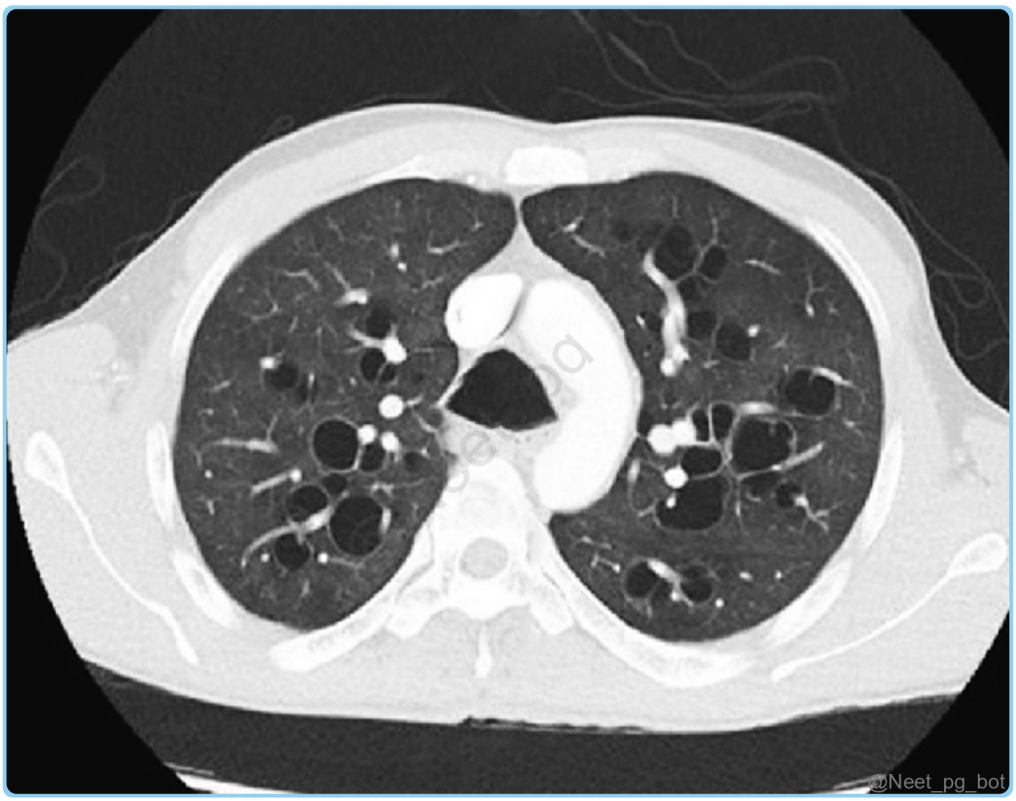

See Answer in Part B → Q11

@Neet_pg_bot

Q12: A 25-year-old student presents with a 10-day history of dry cough, mild fever, and fatigue, but has been able to attend daily activities. Chest X-ray shows patchy infiltrates and a physical exam reveals mild crackles. Which of the following is the least likely causative agent of this patient's condition? (Q851711)

A. Mycoplasma pneumoniae

B. Chlamydia pneumoniae

C. Legionella pneumophila

D. Klebsiella pneumoniae

See Answer in Part B → Q12

@Neet_pg_bot

Q13: A 70 y/o male with a h/o DM presents to the ER with a persistent cough, high fever, and shortness of breath. He recently returned from a week-long cruise in the Caribbean. O/E, he has decreased breath sounds on one side, and a chest X-ray reveals infiltrates that are suggestive of pneumonia. Given the patient's history and recent travel, which of the following is the most likely causative organism for his pneumonia? (Q851710)

A. Streptococcus pneumoniae

B. Legionella species

C. Haemophilus influenzae

D. Mycoplasma pneumoniae

See Answer in Part B → Q13

@Neet_pg_bot

Q14: Which of the following represents the correct order of pathological stages in classic pneumonia? (Q851709)

A. Edema Stage → Gray Hepatization → Red Hepatization → Resolution Stage

B. Edema Stage → Red Hepatization → Gray Hepatization → Resolution Stage

C. Gray Hepatization → Red Hepatization → Edema Stage → Resolution Stage

D. Red Hepatization → Resolution Stage → Edema Stage → Gray Hepatization

See Answer in Part B → Q14

@Neet_pg_bot

Q15: A 45 y/o man with a history of bronchiectasis presents for follow-up after sputum analysis reveals Mycobacterium avium complex (MAC) infection. What is the recommended treatment regimen for this patient's infection? (Q851708)

A. Itraconazole + Rifampin + Ethambutol

B. Macrolide + Rifampin + Ethambutol

C. Macrolide + Isoniazid + Ethambutol

D. Rifampin + Isoniazid + Pyrazinamide

See Answer in Part B → Q15

@Neet_pg_bot

Q16: A 35 y/o male presents with a chronic productive cough, dyspnea, and occasional hemoptysis. A chest radiograph of the patient is given. Which investigation would be most appropriate for confirming the provisional diagnosis? (Q851707)

A. Sputum analysis

B. Chest computed tomography (CT)

C. Pulmonary function tests (PFTs)

D. Bronchoscopy



See Answer in Part B → Q16

@Neet_pg_bot

Q17: A 30 y/o woman with a history of recurrent lung infections presents to the emergency. She reports increased sputum volume and a change in sputum colour. O/E, she demonstrates wheezing and crackles. What does the change in sputum production most likely indicate? (Q851706)

A. Initiation of effective airway clearance therapy

B. Worsening infection and inflammation

C. The onset of remission in chronic lung disease

D. Onset of allergic reaction

See Answer in Part B → Q17

@Neet_pg_bot

Q18: Which of the following is commonly associated with bronchiectasis affecting the lower lobes? (Q851705)

A. Cystic Fibrosis

B. Allergic Bronchopulmonary Aspergillosis

C. Nontuberculous mycobacterial infection

D. Chronic Recurrent Aspiration

See Answer in Part B → Q18

@Neet_pg_bot

Q19: A 40 y/o man, a non-smoker, presents with shortness of breath, chronic cough, and repeated respiratory infections. His chest CT shows emphysema and bronchiectasis. Lab results indicate low alpha-1 antitrypsin levels. What is the most likely reason for the bronchiectasis seen in this patient? (Q851704)

A. Idiopathic airway dilation

B. Recurrent infections due to defective chloride transport

C. Impaired ciliary function leading to mucus retention

D. Increased neutrophil elastase activity causing damage

See Answer in Part B → Q19

@Neet_pg_bot

Q20: A 35 y/o female with asthma presents with worsening cough, wheezing, and episodes of hemoptysis. Chest imaging reveals central bronchiectasis, and blood tests show elevated total IgE levels and eosinophil count. What is the most likely cause of the bronchiectasis? (Q851703)

A. Cystic fibrosis

B. Primary ciliary dyskinesia

C. Allergic bronchopulmonary aspergillosis (ABPA)

D. Idiopathic bronchiectasis

See Answer in Part B → Q20

@Neet_pg_bot

• [10_Pulmonology] 077 Bronchial Asthma And Copd

« Back to Folder Directory

[10_Pulmonology] 077 Bronchial Asthma And Copd — Quick Jump

Q1 (p. 912)	*Q2 (p. 912)*	*Q3 (p. 913)*	*Q4 (p. 913)*	*Q5 (p. 913)*	*Q6 (p. 914)*
Q7 (p. 914)	*Q8 (p. 915)*	*Q9 (p. 915)*	*Q10 (p. 916)*	*Q11 (p. 916)*	*Q12 (p. 916)*
Q13 (p. 917)	*Q14 (p. 917)*	*Q15 (p. 918)*	*Q16 (p. 918)*	*Q17 (p. 919)*	*Q18 (p. 919)*
Q19 (p. 920)	*Q20 (p. 920)*	*Q21 (p. 920)*	*Q22 (p. 921)*	*Q23 (p. 921)*	*Q24 (p. 922)*
Q25 (p. 922)	*Q26 (p. 922)*	*Q27 (p. 923)*	*Q28 (p. 923)*		

Q1: A 55-year-old male with a history of heavy smoking presents with a cough and sputum production for 4 months. Which statement is true regarding his condition? (Q851771)

A. Diagnosis requires symptoms for at least 2 consecutive months.

B. Smoking cessation is the only intervention that positively impacts COPD

C. Inhaled bronchodilators are the primary treatment for chronic bronchitis.

D. Hemoptysis is the initial symptom indicative of chronic bronchitis.

See Answer in Part B → Q1

@Neet_pg_bot

Q2: A 68-year-old male patient with COPD presents with severe respiratory distress. Before initiating Non-Invasive Ventilation (NIV), which of the following conditions would be considered as absolute contraindication? (Q852141)

A. Severe hypoxemia with pH < 7.1

B. Lack of spontaneous breathing or gasping

C. Post upper gastrointestinal surgery

D. Massive retention of secretions despite bronchoscopy

See Answer in Part B → Q2

@Neet_pg_bot

Q3: Which of the following statements regarding the management of COPD is correct ? (Q852140)

A. Inhaled corticosteroids (ICS) should be used as monotherapy in all COPD patients

B. Long-acting bronchodilators are the mainstay of treatment for moderate to severe COPD

C. Antibiotics are routinely prescribed for the prevention of COPD exacerbations

D. Pulmonary rehabilitation is only recommended for patients with mild COPD

See Answer in Part B → Q3

@Neet_pg_bot

Q4: A 62-year-old male with chronic obstructive pulmonary disease (COPD) reports increasing breathlessness over the past few months. He now has to stop for breath after walking about 100 metres on level ground. According to the modified Medical Research Council (mMRC) dyspnoea scale, which grade best describes his level of breathlessness? (Q852139)

A. Grade 1

B. Grade 2

C. Grade 3

D. Grade 4

See Answer in Part B → Q4

@Neet_pg_bot

Q5: Which of the following interventions has been shown to significantly improve survival in patients with chronic obstructive pulmonary disease (COPD)? (Q852138)

A. Pulmonary rehabilitation

B. Smoking cessation

C. Oral glucocorticoids during exacerbations

D. Pneumococcal vaccination

See Answer in Part B → Q5

@Neet_pg_bot

Q6: A 65-year-old male with a history of chronic obstructive pulmonary disease (COPD) presents for routine follow-up. He reports increased breathlessness while walking on level ground and has experienced two exacerbations in the past year. According to the 2023 GOLD classification, which group does this patient belong to? (Q852137)

A. Group A: Low risk, low symptoms

B. Group B: Low risk, high symptoms

C. Group C: High risk, low symptoms

D. Group D: High risk, high symptoms

See Answer in Part B → Q6

@Neet_pg_bot

Q7: A 68-year-old woman with a history of Chronic Obstructive Pulmonary Disease (COPD) is evaluated for her BODE Index score. Her current Body Mass Index (BMI) is 20 kg/m², her post-bronchodilator FEV1 is 42% of the predicted value, she reports a mMRC dyspnoea score of 3, and she walks 340 metres during a 6-minute walk test. What is her total BODE Index score? (Q852136)

A. 4

B. 5

C. 6

D. 7

See Answer in Part B → Q7

@Neet_pg_bot

Q8: A 70-year-old male with a long-standing history of chronic obstructive pulmonary disease (COPD) presents to the clinic with worsening breathlessness and cough. His smoking history is significant for 45 pack-years. O/E, he has bilateral wheezes and a respiratory rate of 24 breaths per minute. His oxygen saturation is 89% on room air, and spirometry confirms a post-bronchodilator FEV1/FVC ratio of 60%. Which of the following is the most appropriate first-line treatment to improve his breathlessness and reduce the risk of exacerbations? (Q852135)

A. Oral theophylline combined with ICS

B. Long-acting bronchodilator (LABA) combined with an inhaled glucocorticoid

C. Long-term oxygen therapy

D. Pulmonary rehabilitation

See Answer in Part B → Q8

@Neet_pg_bot

Q9: A 62-year-old woman with a history of chronic obstructive pulmonary disease (COPD) presents with increased breathlessness, cough, and sputum production over the last two days. She appears distressed and has a respiratory rate of 28 breaths per minute. Her oxygen saturation is 88% on room air. Which of the following management strategies is most appropriate for her immediate treatment? (Q852134)

A. Initiate high-flow oxygen therapy to maintain oxygen saturation above 95%

B. Start nebulised bronchodilator therapy with salbutamol and ipratropium

C. Begin intravenous glucocorticoids immediately

D. Order a chest X-ray before any treatment is provided

See Answer in Part B → Q9

@Neet_pg_bot

Q10: A 55-year-old man presents with a 6-month history of worsening breathlessness, chronic cough, and occasional sputum production. He has a 30-pack-year smoking history. On examination, there is no finger clubbing, and pulse oximetry shows oxygen saturation of 92% on room air. Spirometry reveals an FEV1/FVC ratio of 60% post-bronchodilator. What is the most appropriate next investigation to assess the severity of his condition? (Q851777)

A. Chest X-ray

B. Blood gas analysis

C. High-resolution computed tomography (HRCT)

D. Spirometry with post-bronchodilator FEV1%

See Answer in Part B → Q10

@Neet_pg_bot

Q11: A 65-year-old man with a 40-pack-year smoking history presents with chronic productive cough, worsening breathlessness. Physical examination shows hoover sign with drowsiness. ABG shows PC02 =70 mm Hg and PO2= 70 mm Hg. Which of the following is best for immediate management of this patient? (Q851776)

A. Long term of oxygen therapy

B. Non invasive ventilation

C. LABA + LAMA

D. LABA + LAMA + ICS

See Answer in Part B → Q11

@Neet_pg_bot

Q12: A 65-year-old male patient presents with a history of chronic cough and sputum production for the past several years. He is thin and exhibits significant breathlessness primarily during physical activity, but he reports minimal symptoms at rest. Arterial blood gas analysis shows a normal PaCO2. Which of the following is the most likely diagnosis for this patient? (Q851775)

A. Chronic bronchitis

B. Asthma

C. Emphysema

D. Interstitial lung disease

See Answer in Part B → Q12

@Neet_pg_bot

Q13: A 65-year-old patient with a history of chronic obstructive pulmonary disease (COPD) presents with worsening shortness of breath and edema. Right heart catheterization reveals a mean pulmonary artery pressure of 30 mmHg. Which of the following statements about pulmonary hypertension (PH) in this patient is most accurate? (Q851773)

A. Pulmonary hypertension in COPD is primarily caused by increased left atrial pressure.

B. The prognosis of COPD is directly proportional to age.

C. Right ventricular hypertrophy may be observed on an electrocardiogram (ECG).

D. Treatment options for pulmonary hypertension in COPD primarily include corticosteroids.

See Answer in Part B → Q13

@Neet_pg_bot

Q14: A 60-year-old male with a long history of smoking presents to the clinic with chronic cough and wheezing. He mentions that he had multiple respiratory infections during childhood and was born with low birth weight. Which of the following factors is most likely to have the greatest impact on the progression of his Chronic

Obstructive Pulmonary Disease (COPD)? (Q851772)

A. Airway hyper-reactivity

B. Tobacco smoke

C. Recurrent infections

D. Impaired lung growth

See Answer in Part B → Q14

@Neet_pg_bot

Q15: A 10-year-old boy presents with wheezing and shortness of breath, worsening at night. His symptoms are triggered by dust and pet dander. Spirometry shows an obstructive pattern that improves with a bronchodilator. What is the underlying mechanism? (Q851755)

A. IgG-mediated immune complexes.

B. IgE-mediated mast cell degranulation.

C. Bronchial irritation from pollutants.

D. Viral infection causing airway remodeling.

See Answer in Part B → Q15

@Neet_pg_bot

Q16: A 65-year-old male presents with progressive dyspnea and a history of smoking for 25 years. Imaging studies reveal abnormal enlargement of air spaces distal to the terminal bronchioles. Which of the following types of emphysema is most likely seen in this patient? (Q851770)

A. Panacinar emphysema

B. Paraseptal emphysema

C. Centriacinar emphysema

D. Bullous emphysema

See Answer in Part B → Q16

@Neet_pg_bot

Q17: A 58-year-old male, with a 30-year history of smoking, presents with a chronic productive cough for the last 2 years, worsening shortness of breath, and recent weight loss. Examination reveals bilateral wheezing and peripheral edema imaging shows alveolar wall destruction beyond terminal bronchiole. Which of the following pathophysiological mechanisms is primarily responsible for his condition? (Q851768)

A. Pulmonary vascular remodeling

B. Alpha-1 antitrypsin deficiency

C. Airflow limitation due to loss of elastic tissue

D. Hypersecretion of mucus from goblet cells

See Answer in Part B → Q17

@Neet_pg_bot

Q18: A 42-year-old woman presents to the emergency department with worsening asthma symptoms, fever, and a rash consisting of purpura on her lower extremities. Laboratory findings reveal eosinophilia (1200 cells/μL) and elevated inflammatory markers. A biopsy of the skin lesion shows extravascular granulomas. Which of the following statements about her condition is false? (Q851767)

A. Patients often present with systemic symptoms like malaise and weight loss.

B. The condition typically involves necrotizing vasculitis affecting small and medium-sized blood vessels.

C. Cardiac involvement may lead to complications such as myocarditis and pericarditis.

D. It primarily affects large blood vessels, leading to significant vascular occlusion.

See Answer in Part B → Q18

@Neet_pg_bot

Q19: A 45-year-old male presents with chronic shortness of breath, dry cough, fatigue, and weight loss for the past six months. He works in a pigeon breeding facility and reports worsening symptoms over time. High-resolution CT (HRCT) of the chest reveals reticular changes, ground-glass opacities, and traction bronchiectasis. Which of the following statements about his condition is true? (Q851766)

A. It is caused by a Type I hypersensitivity reaction mediated by IgE antibodies.

B. Pulmonary fibrosis is a known complication of chronic HP.

C. Acute HP presents with symptoms several days after antigen exposure.

D. HRCT is typically normal in hypersensitivity pneumonitis.

See Answer in Part B → Q19

@Neet_pg_bot

Q20: Which of the following statements best characterizes brittle asthma? (Q851765)

A. Symptoms develop gradually over a few days, allowing time for preventive action.

B. It is characterized by sudden exacerbations with little or no warning.

C. Patients with brittle asthma typically have heightened awareness of airway narrowing.

D. The primary cause of brittle asthma is well understood and easily managed.

See Answer in Part B → Q20

@Neet_pg_bot

Q21: A 35-year-old male with a history of asthma presents with symptoms occurring four times a week, occasional nighttime awakenings, and the need for rescue inhaler use three times a week. His post-bronchodilator FEV1 is 72% of the predicted value. According to the asthma classification guidelines, how would you categorize the severity and control of his asthma? (Q851764)

A. Mild asthma, controlled

B. Moderate asthma, partly controlled

C. Severe asthma, uncontrolled

D. Moderate asthma, uncontrolled

See Answer in Part B → Q21

@Neet_pg_bot

Q22: A 30-year-old patient with a history of asthma presents with symptoms occurring more than three times a week and nocturnal awakenings at least once a week. After evaluating the patient's condition, the physician decides to initiate treatment. Which of the following is the most appropriate initial step in the management of this patient? (Q851763)

A. Increase the dose of short-acting β2-agonist.

B. Start regular inhaled glucocorticoids (ICS).

C. Start prednisolone at the lowest effective dose.

D. Add a long-acting β2-agonist (LABA).

See Answer in Part B → Q22

@Neet_pg_bot

Q23: A 24-year-old male presents with recurrent episodes of chest tightness, wheezing, and shortness of breath 10 minutes after running. The symptoms usually resolve within 30 minutes. Which of the following is the most appropriate pre-exercise treatment? (Q851762)

A. Long-acting beta agonist (LABA) taken daily

B. Short-acting beta agonist (SABA) used 15 minutes before exercise

C. Inhaled corticosteroid (ICS) used immediately after exercise

D. Leukotriene receptor antagonist (LTRA) taken during an acute episode

See Answer in Part B → Q23

@Neet_pg_bot

Q24: A 28-year-old woman presents with a history of recurrent wheezing and shortness of breath, particularly during the winter months. She reports that her symptoms worsen with cold air and after respiratory infections. She does not have any known allergies, and her skin prick tests for common allergens are negative. What is the most likely diagnosis? (Q851761)

A. Atopic asthma

B. Occupational asthma

C. Intrinsic asthma

D. Cough-variant asthma

See Answer in Part B → Q24

@Neet_pg_bot

Q25: A 10-year-old girl presents with recurrent wheezing and difficulty breathing, especially during spring. Her symptoms worsen at night and with exercise. She has a family history of asthma. Physical examination reveals wheezing and a skin prick test shows positive reactions to grass pollen. What is the most likely diagnosis? (Q851760)

A. Exercise-induced asthma

B. Extrinsic asthma

C. Intrinsic Asthma

D. Non-atopic asthma

See Answer in Part B → Q25

@Neet_pg_bot

Q26: A 40-year-old man presents to the clinic with a history of asthma. He reports that he has been using his rescue inhaler (SABA) more frequently, experiencing symptoms on most days and waking up at least twice a week due to shortness of breath. His current management includes as-needed SABA but no regular controller medication. What is the most appropriate next step in his asthma management? (Q851758)

A. Continue current treatment and monitor symptoms.

B. Start low-dose inhaled corticosteroids for daily control.

C. Increase the dosage of the SABA.

D. Add a leukotriene receptor antagonist for better control.

See Answer in Part B → Q26

@Neet_pg_bot

Q27: A 35-year-old man presents with complaints of wheezing and shortness of breath that have worsened over the past few weeks. He notes that his symptoms often occur at night and are triggered by exposure to dust and exercise. Spirometry shows a FEV1/FVC ratio of 65%. After using a short-acting β2-agonist, his FEV1 increases by 20%. Which of the following findings would most likely be observed in this patient? (Q851757)

A. Increased total lung capacity

B. Decreased DLCO

C. Increased forced vital capacity

D. Decreased residual volume

See Answer in Part B → Q27

@Neet_pg_bot

Q28: Which of the following statements about the Hygiene hypothesis is incorrect? (Q851756)

A. Clean environments may impair immune system maturation in children.

B. Endotoxin exposure is essential for proper immune development.

C. Fetal immune system is suppressed to prevent rejection of maternal tissue.

D. Lack of exposure to germs is linked to a decreased risk of developing asthma.

See Answer in Part B → Q28

@Neet_pg_bot

• [10_Pulmonology] 078 Tuberculosis

« Back to Folder Directory

[10_Pulmonology] 078 Tuberculosis — Quick Jump

Q1 (p. 925)	*Q2 (p. 925)*	*Q3 (p. 926)*	*Q4 (p. 926)*	*Q5 (p. 927)*	*Q6 (p. 928)*
Q7 (p. 929)	*Q8 (p. 929)*	*Q9 (p. 929)*	*Q10 (p. 930)*	*Q11 (p. 930)*	*Q12 (p. 930)*
Q13 (p. 931)	*Q14 (p. 931)*	*Q15 (p. 932)*	*Q16 (p. 932)*		

Q1: What is the duration of the longer MDR-TB regimen? (Q851824)

A. 18-20 months

B. 12 months

C. 6-10 months

D. 24-36 months

See Answer in Part B → Q1

@Neet_pg_bot

Q2: A 35-year-old woman presents with a enlarged cervical lymph nodes on left side with matted consistency. CXR and excision lymph node biopsy report is shown below . What is the most likely diagnosis? (Q851779)

A. Hodgkin’s lymphoma

B. Metastatic carcinoma

C. Tuberculous lymphadenitis

D. Sarcoidosis

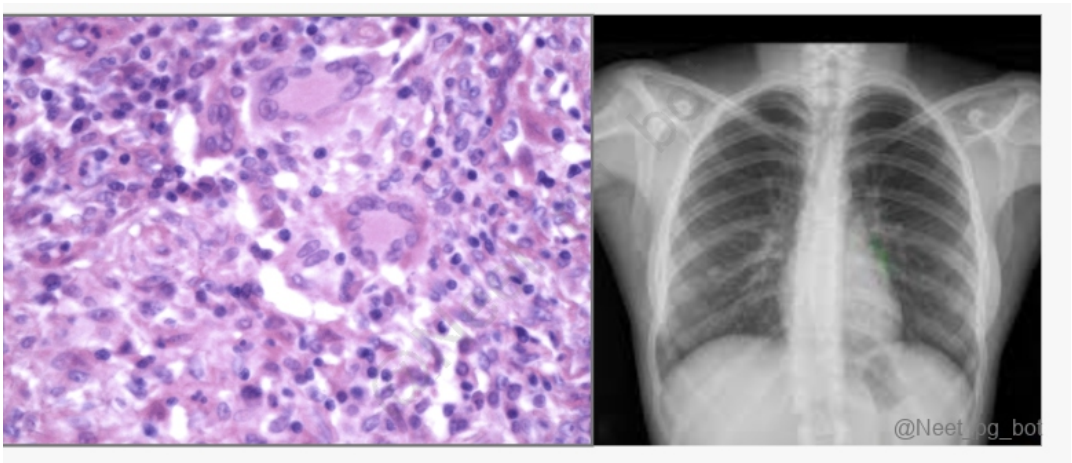

See Answer in Part B → Q2

@Neet_pg_bot

Q3: A 40-year-old man presents with fever, pleuritic chest pain, and dyspnea. Physical examination revealed dullness to percussion and absent breath sounds on the left side. Chest X-ray shows a left-sided pleural effusion. Thoracentesis reveals straw-coloured fluid with a protein concentration of 5 g/dL and a WBC count of 1500/μL with lymphocyte predominance. The acid-fast bacilli (AFB) smear is negative. What is the most likely diagnosis? (Q851780)

A. Parapneumonic effusion

B. Tuberculous pleuritis

C. Malignant pleural effusion

D. Congestive heart failure

See Answer in Part B → Q3

@Neet_pg_bot

Q4: A 25-year-old man presents with a 2-week history of headaches, low-grade fever, irritability, and confusion. On examination, he has neck stiffness and cranial nerve VI palsy. Lumbar puncture reveals a CSF leukocyte count of 800/μL (lymphocyte predominance), protein of 400 mg/dL, and low glucose. AFB smear is negative. What

is the most likely diagnosis? (Q851782)

A. Viral meningitis

B. Bacterial meningitis

C. Tuberculous meningitis

D. Cryptococcal meningitis

See Answer in Part B → Q4

@Neet_pg_bot

Q5: A 30-year-old man presents with chronic back pain, fatigue, and weight loss. MRI of the spine reveals destruction of the lower thoracic vertebrae with a paravertebral abscess tracking into the psoas muscle. What is the most likely diagnosis? (Q851785)

A. Pyogenic bacterial osteomyelitis

B. Spinal tuberculosis

C. Vertebral metastasis

D. Disc herniation

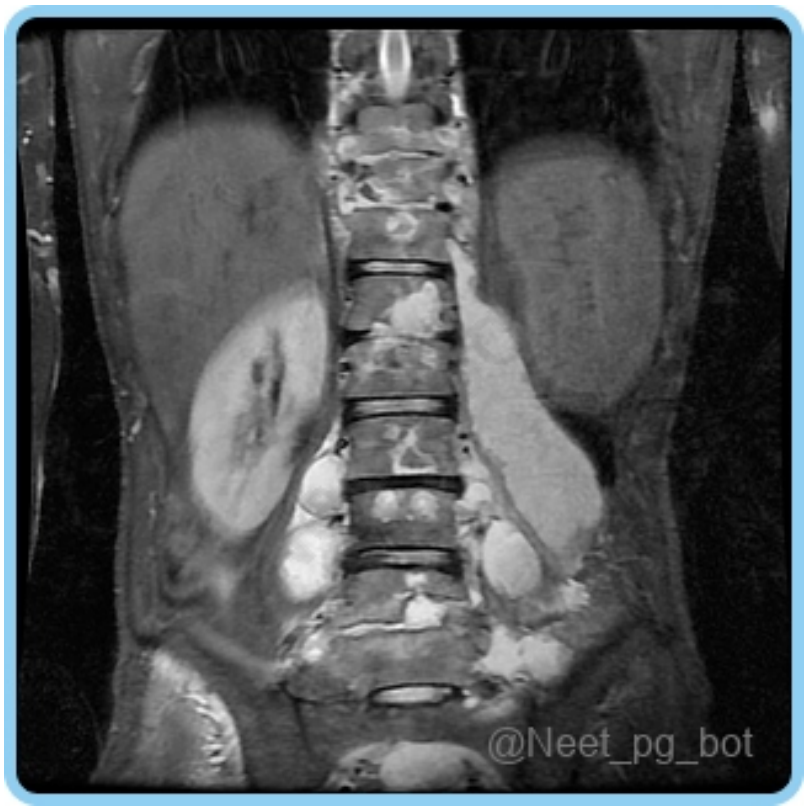

See Answer in Part B → Q5

@Neet_pg_bot

Q6: A 40-year-old woman presents with a history of pelvic pain, menstrual irregularities, and frequent urination over the past few months. She reports that her symptoms have worsened and she experiences occasional hematuria. Urinalysis shows pyuria, but urine cultures are negative. A pelvic ultrasound reveals abnormalities in the fallopian tubes. What is the most likely diagnosis? (Q851786)

A. Urinary tract infection

B. Genitourinary tuberculosis

C. Pelvic inflammatory disease (PID)

D. Can be either B or C

See Answer in Part B → Q6

@Neet_pg_bot

Q7: A 9-year-old boy presents with fever and pleuritic chest pain. Chest X-ray shows a small calcified lesion in the lower right lung and enlarged hilar lymph nodes. He also has a rash on his legs resembling erythema nodosum. What is the most likely diagnosis? (Q851793)

A. Acute bacterial pneumonia

B. Primary pulmonary tuberculosis

C. Cystic fibrosis

D. Viral lower respiratory tract infection

See Answer in Part B → Q7

@Neet_pg_bot

Q8: Which finding is not typically present in primary tuberculosis? (Q851795)

A. Hilar lymphadenopathy

B. Perihilar infiltrate

C. Non-caseating granuloma

D. Pleural effusion

See Answer in Part B → Q8

@Neet_pg_bot

Q9: In the pathophysiology of postprimary tuberculosis, which of the following immunological events is most critical for the development of cavitary lesions in the lung apices and how does it contribute to tissue destruction? (Q851798)

A. Activation of B cells leads to antibody production, which facilitates phagocytosis of M. tuberculosis.

B. Release of IL-4 and IL-10 from T-helper cells, promoting a Th2 response that leads to fibrosis and walling off of the infection.

C. Secretion of TNF-α and IFN-γ by activated T cells, resulting in macrophage activation and the subsequent formation of caseous necrosis.

D. Induction of a robust innate immune response mediated by neutrophils, resulting in rapid clearance of bacteria and prevention of necrosis.

See Answer in Part B → Q9

@Neet_pg_bot

Q10: Which of the following matches the type of tuberculosis focus with its correct location? Type of TB Focus Location 1. Assman Focus a. Subpleural 2. Ghon Focus b. Infraclavicular 3. Puhl Lesion c. Supraclavicular 4. Rich Focus d. Brain (Q851800)

A. 1-b, 2-a, 3-c, 4-d

B. 1-a, 2-c, 3-d, 4-b

C. 1-c, 2-d ,3-a, 4-b

D. 1-d, 2-b, 3-c, 4-a

See Answer in Part B → Q10

@Neet_pg_bot

Q11: What is the primary purpose of Interferon-gamma release assays (IGRAs) to tuberculosis? (Q851801)

A. To confirm active TB disease

B. To diagnose latent TB infection

C. To monitor treatment response

D. To assess the severity of lung disease

See Answer in Part B → Q11

@Neet_pg_bot

Q12: Which of the following best describes the principle behind the LAMP test? (Q851805)

A. Amplifying RNA to detect TB

B. Isothermal amplification of DNA at a constant temperature

C. PCR amplification with thermal cycling

D. Culture growth of Mycobacterium tuberculosis

See Answer in Part B → Q12

@Neet_pg_bot

Q13: A 34-year-old man with advanced HIV infection (CD4 count of 50 cells/mm³) is diagnosed with pulmonary tuberculosis (TB) and started on anti-tuberculosis treatment. Two weeks later, he initiated antiretroviral therapy (ART). After 3 weeks on ART, he returns to the clinic complaining of worsening cough, fever and night sweats. Physical examination reveals enlarged cervical lymph nodes and increased lung crackles on auscultation. His viral load has dropped significantly, but his CD4 count remains low. What is the most likely diagnosis? (Q851807)

A. Drug-resistant TB

B. Immune reconstitution inflammatory syndrome (IRIS)

C. ART toxicity

D. New opportunistic infection

See Answer in Part B → Q13

@Neet_pg_bot

Q14: Match the drugs used in the initial treatment of tuberculosis with their dosage. Drugs Dosage (mg/kg) a.Isoniazid i.10 b.Rifampicin ii.15 c.Pyrazinamide iii.5 d.Ethambutol iv.25 (Q851819)

A. a-iii,b-i,c-iv,d-ii

B. a-i,b-ii,c-iii,d-iv

C. a-iv,b-iii,c-ii,d-i

D. a-ii,b-iii,c-iv,d-i

See Answer in Part B → Q14

@Neet_pg_bot

Q15: Which of the following is not a component of the shorter MDR-TB regimen? (Q851822)

A. 6 months of levofloxacin

B. 5 months of clofazimine

C. 5 months of ethambutol

D. 5 months of isoniazid

See Answer in Part B → Q15

@Neet_pg_bot

Q16: A 41-year-old man with a history of night sweats, fever, and weight loss presents with anal fistulae. Physical examination and imaging suggest an abscess near the rectum. Which diagnostic step should be prioritized to investigate a possible cause? (Q851825)

A. Evaluation for rectal tuberculosis

B. Screening for Crohn’s disease

C. Colonoscopy with biopsy for malignancy

D. Culture and sensitivity of fistula discharge

See Answer in Part B → Q16

@Neet_pg_bot

• [10_Pulmonology] 079 Respiratory Physiology And Failure

« Back to Folder Directory

[10_Pulmonology] 079 Respiratory Physiology And Failure — Quick Jump

Q1 (p. 933) *Q2 (p. 933)* *Q3 (p. 934)* *Q4 (p. 934)* *Q5 (p. 935)* *Q6 (p. 938)*
Q7 (p. 938) *Q8 (p. 938)*

Q1: A 72 y/o male, a k/c/o COPD presents to the ED with shortness of breath and confusion. He has been experiencing increased fatigue and worsening dyspnea over the past few days. O/E he has a respiratory rate of 30 bpm. Arterial blood gas analysis shows: PaO2: 58 mmHg, PaCO2: 52 mmHg and pH: 7.2. Which type of respiratory failure is most likely in this patient? (Q852142)

A. Type 1 Respiratory Failure

B. Type 2 Respiratory Failure

C. Type 3 Respiratory Failure

D. Type 4 Respiratory Failure

See Answer in Part B → Q1

@Neet_pg_bot

Q2: A 65 y/o female undergoes elective hip replacement surgery. Postoperatively, she develops shortness of breath and a decreased oxygen saturation level. She reports significant pain at the surgical site and is reluctant to take deep breaths due to discomfort. O/E, her respiratory rate is elevated, and auscultation reveals diminished breath sounds at the bases. A chest X-ray shows areas of atelectasis. What type of respiratory failure is most likely in this patient? (Q852143)

A. Type 1 Respiratory Failure

B. Type 2 Respiratory Failure

C. Type 3 Respiratory Failure

D. Type 4 Respiratory Failure

See Answer in Part B → Q2

@Neet_pg_bot

Q3: A 55 y/o male with h/o pneumonia is admitted to the hospital with severe shortness of breath. O/E, his oxygen saturation is 85%, and arterial blood gas analysis shows: PaO2: 55 mmHg PaCO2: 40 mmHg pH: 7.38 He is anxious and struggling to breathe. What is the most appropriate initial treatment for this patient's respiratory failure? (Q852144)

A. Intubation and mechanical ventilation

B. Noninvasive ventilation (NIV)

C. Oxygen therapy via a nonrebreathing mask

D. Continuous positive airway pressure (CPAP)

See Answer in Part B → Q3

@Neet_pg_bot

Q4: A 30 y/o female presents with h/o wheezing and shortness of breath. A pulmonary function test shows a flow-volume loop with a distinct "scooped" appearance during expiration, particularly at lower lung volumes. Which condition does this flow-volume loop most likely represent? (Q852145)

A. Pulmonary Fibrosis

B. Asthma

C. Retrosternal Goiter

D. Normal

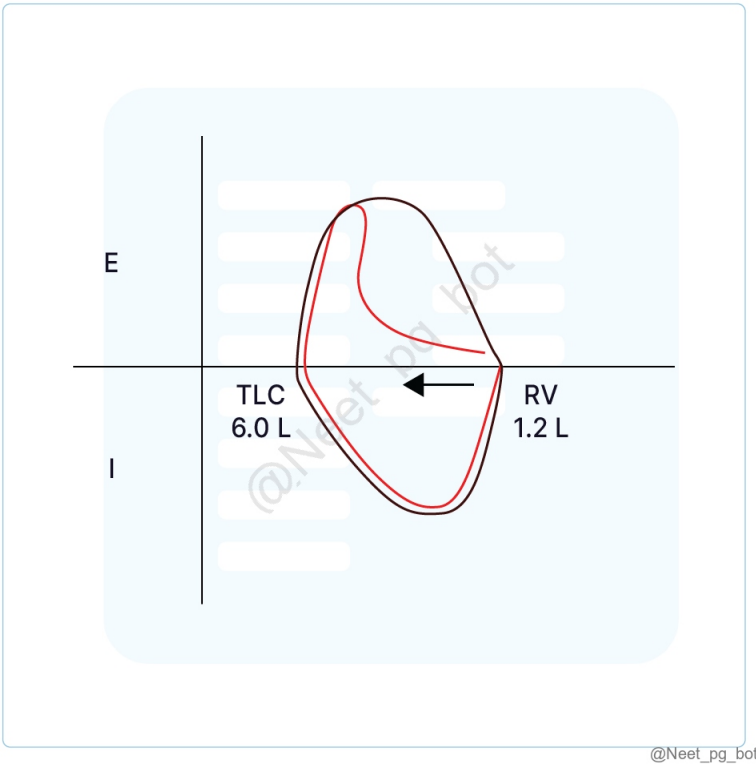

See Answer in Part B → Q4

@Neet_pg_bot

Q5: Match the following diseases with their respective flow volume curves: 1. Asthma a) 2. Extrathoracic Obstruction b) 3. Fixed Obstruction c) 4. Restrictive Airway Disorders d) (Q852146)

A. 1-d, 2-a, 3-c, 4-b

B. 1-a, 2-c, 3-d, 4-b

C. 1-b, 2-d, 3-a, 4-c

D. 1-c, 2-b, 3-d, 4-a

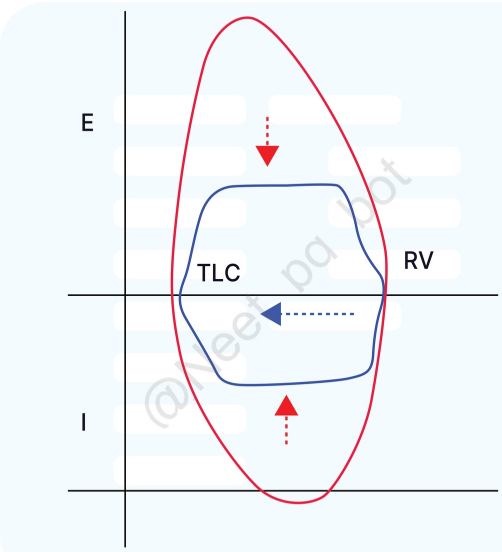

@Neet_pg_bot

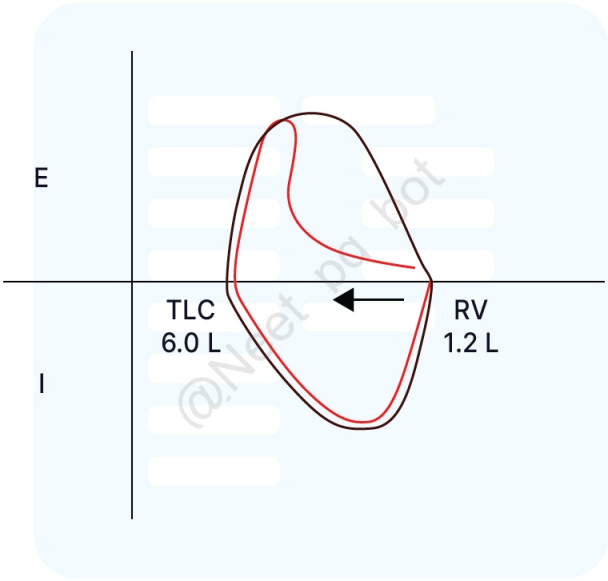

@Neet_pg_bot

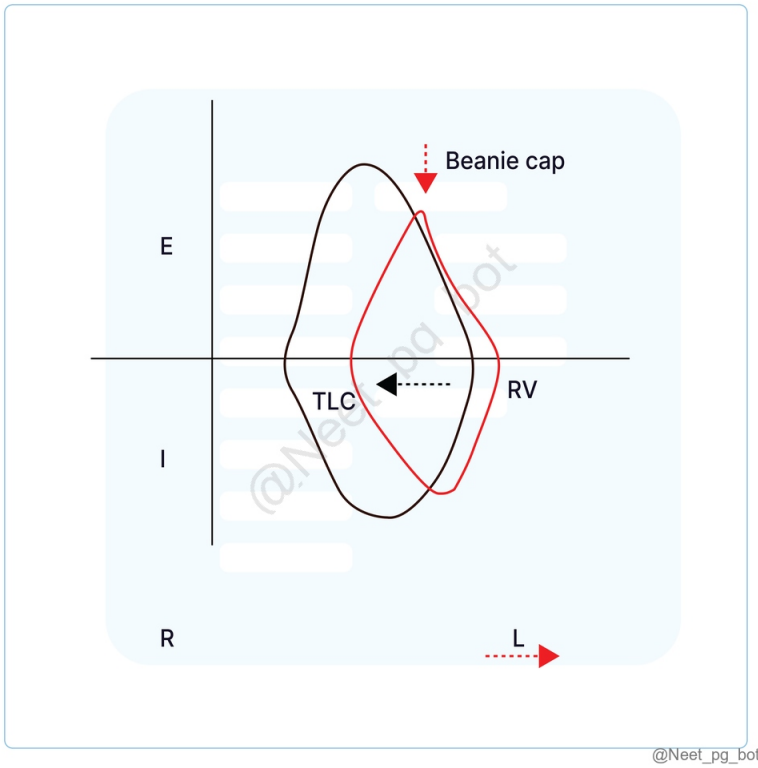

@Neet_pg_bot

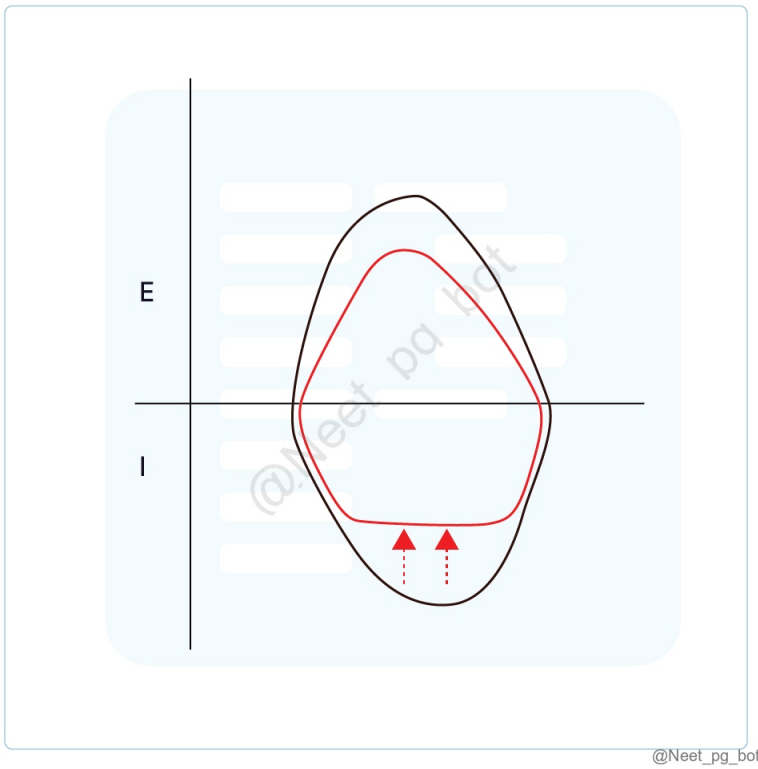

@Neet_pg_bot

See Answer in Part B → Q5

@Neet_pg_bot

Q6: A 72-year-old female patient presents with progressive shortness of breath and a persistent dry cough. She has a history of pulmonary fibrosis diagnosed two years ago. Spirometry shows reduced lung volumes. Which of the following is most likely true regarding this patient's spirometry results? (Q852147)

A. FVC is likely to be increased.

B. FEV1/FVC ratio is likely > 80%.

C. TLC is likely normal or increased.

D. RV is likely normal or increased.

See Answer in Part B → Q6

@Neet_pg_bot

Q7: A 45 y/o man with a history of COPD presents with shortness of breath, cough, and increased sputum production. His arterial blood gas (ABG) analysis shows hypoxemia, and his calculated A-a gradient is elevated. Which of the following is the most likely cause for the elevated A-a gradient in this patient? (Q852148)

A. Ventilation-perfusion mismatch

B. Hypoventilation

C. Reduced cardiac output

D. Low-inspired oxygen (FiO2)

See Answer in Part B → Q7

@Neet_pg_bot

Q8: A 50 y/o male presents with worsening dyspnea. His pulmonary function test reveals a significant reduction in DLCO. Which of the following is the most likely cause for the low DLCO? (Q852149)

A. Pulmonary hemorrhage

B. Obesity

C. Pulmonary fibrosis

D. Acute Congestive Heart Failure

See Answer in Part B → Q8

@Neet_pg_bot

• [10_Pulmonology] 080 Interstitial Lung Disease Pulmonary Alveolar Protienosis Pneumoconiosis

« Back to Folder Directory

[10_Pulmonology] 080 Interstitial Lung Disease Pulmonary Alveolar Protienosis Pneumoconiosis — Quick Jump

Q1 (p. 940) *Q2 (p. 941)* *Q3 (p. 941)* *Q4 (p. 942)* *Q5 (p. 942)* *Q6 (p. 943)*
Q7 (p. 943) *Q8 (p. 944)* *Q9 (p. 944)* *Q10 (p. 945)* *Q11 (p. 945)* *Q12 (p. 945)*
Q13 (p. 946)

Q1: A 50-year-old man who has worked in the glass manufacturing industry for over 20 years presents with progressive dyspnea, a chronic dry cough, and fatigue. On examination, he has bilateral crackles on auscultation. A high-resolution CT scan reveals a crazy-paving pattern in the lungs. What is the most likely cause of his condition? (Q851836)

A. Hypersensitivity pneumonitis

B. Idiopathic pulmonary fibrosis

C. Asbestosis

D. Silicosis



See Answer in Part B → Q1

@Neet_pg_bot

Q2: A 45-year-old man with a history of working in mining for over 20 years presents with chronic cough, shortness of breath, and fatigue. Chest X-ray reveals nodular opacities, primarily in the upper lobes. Which of the following complications is he at an increased risk of? (Q851837)

A. Pulmonary embolism

B. Pneumothorax

C. Tuberculosis

D. Pleural effusion

See Answer in Part B → Q2

@Neet_pg_bot

Q3: A 70-year-old retired shipyard worker presents with exertional dyspnea and a persistent dry cough. Pulmonary function tests reveal a restrictive pattern. Which of the following radiographic findings is most characteristic of asbestosis? (Q851838)

A. Upper lobe nodular opacities

B. Cavitary lesions

C. Bilateral pleural plaques

D. Hyperinflated lungs

See Answer in Part B → Q3

@Neet_pg_bot

Q4: A 45-year-old man with a long history of smoking presents with worsening dyspnea and a recent diagnosis of lung cancer. A lung biopsy reveals changes consistent with interstitial lung disease. Which type of ILD is most commonly associated with smoking? (Q851839)

A. Lymphangioleiomyomatosis

B. Lymphocytic interstitial pneumonitis

C. Pulmonary Alveolar Proteinosis

D. Langerhans cell histiocytosis

See Answer in Part B → Q4

@Neet_pg_bot

Q5: A 42-year-old woman presents with worsening asthma, shortness of breath, and wheezing. She has a history of recurrent sinusitis and recent purpuric skin lesions on her legs. Lab tests show eosinophilia and positive p-ANCA. A chest CT reveals ground-glass opacities and lower lobe consolidation. What is the most likely diagnosis? (Q851840)

A. Wegener Granulomatosis

B. Sarcoidosis

C. Hypersensitivity pneumonia

D. Churg Strauss Syndrome

See Answer in Part B → Q5

@Neet_pg_bot

Q6: A 55-year-old man presents with worsening dyspnea on exertion and a dry cough. Examination reveals finger clubbing. Which findings might be observed during an interstitial lung disease (ILD) evaluation? Wheeze Inspiratory crackles Dullness to percussion Pigeon Breeder's Lung Increased tactile fremitus (Q851841)

A. 1,3,5

B. 2,3,4

C. 3,4,5

D. 1,2,4

See Answer in Part B → Q6

@Neet_pg_bot

Q7: A 55-year-old male presents with a 6-week history of cough, dyspnea, fever, and fatigue. Respiratory examination reveals inspiratory rales and pulmonary function tests reveal restrictive lung features. HRCT of the thorax shows patchy subpleural consolidative opacities with a ground-glass appearance and a reversed halo sign. A lung biopsy shows a uniform appearance of granulation tissue within the alveolar sac. What is the most likely diagnosis? (Q851842)

A. Atypical pneumonia

B. Cryptogenic organising pneumonia

C. Interstitial pulmonary fibrosis

D. Acute respiratory distress syndrome

See Answer in Part B → Q7

@Neet_pg_bot

Q8: Match the following types of hypersensitivity pneumonitis with their respective causative antigen. Disease Antigen 1. Farmer's lungs A. Mycobacterium Avium complex 2. Tobacco grower's lungs B. Isocyanates 3. Hot tub lungs C. Thermophilic actinomyces 4. Chemical worker lungs D. Penicillium casei 5. Cheese washer's lungs E. Aspergillus clavatus (Q851843)

A. 1-E, 2-A, 3-D, 4-C, 5-B

B. 1-C, 2-E, 3-A, 4-B, 5-D

C. 1-D, 2-C, 3-B, 4-E, 5-A

D. 1-A, 2-B, 3-E, 4-D, 5-C

See Answer in Part B → Q8

@Neet_pg_bot

Q9: A 60-year-old male with a history of smoking presents with progressively worsening dyspnea and a non-productive cough for the past 6 months. HRCT findings, including subpleural reticulation, honeycombing, and traction bronchiectasis, suggest idiopathic pulmonary fibrosis (IPF). What is the treatment of choice for this condition? (Q851844)

A. Monotherapy with Corticosteroid

B. Pirfenidone + Nintedanib

C. Prednisolone + Rituximab

D. Lung transplantation

See Answer in Part B → Q9

@Neet_pg_bot

Q10: A 62-year-old woman with a history of progressive dyspnea and a chronic dry cough is being evaluated for suspected interstitial lung disease (ILD). She denies any history of smoking or exposure to environmental toxins. Physical examination reveals fine bibasilar inspiratory crackles. Which of the following is the investigation of choice for confirming the diagnosis? (Q851845)

A. Pulmonary function test

B. Bronchoalveolar lavage

C. Fiberoptic bronchoscopy with cryo biopsy

D. HRCT of thorax

See Answer in Part B → Q10

@Neet_pg_bot

Q11: A 59-year-old man presents with recurrent cough, dyspnea, and fatigue for 8 months. His occupation as a bird breeder with exposure to bird droppings suggests hypersensitivity pneumonitis. Pulmonary function testing (PFT) reveals a restrictive pattern. Which of the following disorders should be considered in the differential diagnosis based on the PFT restrictive pattern? (Q851846)

A. COPD

B. Idiopathic interstitial pneumonia

C. Asthma

D. Bronchiectasis

See Answer in Part B → Q11

@Neet_pg_bot

Q12: A 50-year-old woman presents with worsening shortness of breath and cough, producing copious sputum containing gelatinous material. Laboratory tests reveal no evidence of infectious processes. The physician suspects pulmonary alveolar

proteinosis. Which mechanism is most responsible for her condition? (Q851847)

A. Deficiency of surfactant proteins due to genetic mutation

B. Autoimmune response leading to GM-CSF blockade

C. Exposure to silica dust causing alveolar damage

D. Allergic reaction to environmental pollutants

See Answer in Part B → Q12

@Neet_pg_bot

Q13: A 52-year-old male presents with progressive dyspnea and a chronic cough with gelatinous sputum. Pulmonary function tests show a restrictive pattern and a normal FEV1/FVC ratio. A chest X-ray reveals bilateral patchy opacifications and a high-resolution CT shows a crazy paving pattern with no signs of infection. What is the most characteristic finding of this condition? (Q851848)

A. Increased neutrophilic infiltration

B. Positive Periodic Acid-Schiff (PAS) staining

C. Granuloma formation

D. Honeycombing fibrosis

See Answer in Part B → Q13

@Neet_pg_bot

• [10_Pulmonology] 081 Pleural Effusion And Pneumothorax

« Back to Folder Directory

[10_Pulmonology] 081 Pleural Effusion And Pneumothorax — Quick Jump

Q1 (p. 947)	*Q2 (p. 948)*	*Q3 (p. 949)*	*Q4 (p. 949)*	*Q5 (p. 949)*	*Q6 (p. 950)*
Q7 (p. 950)	*Q8 (p. 951)*	*Q9 (p. 952)*	*Q10 (p. 952)*	*Q11 (p. 953)*	*Q12 (p. 953)*
Q13 (p. 954)	*Q14 (p. 954)*	*Q15 (p. 955)*	*Q16 (p. 955)*	*Q17 (p. 956)*	

Q1: A 35-year-old male presents with fever, left-sided chest pain, and dyspnea. Upon physical examination, decreased breath sounds are noted on the left side. A chest X-ray reveals the findings presented below. A thoracentesis is performed, yielding a milky white fluid with elevated lactate dehydrogenase (LDH) and the presence of cholesterol crystals. Considering these findings, what underlying agent could be responsible for this presentation? (Q851878)

A. Pneumococcus

B. Staphylococcus aureus

C. Malignancy

D. Mycobacterium tuberculosis

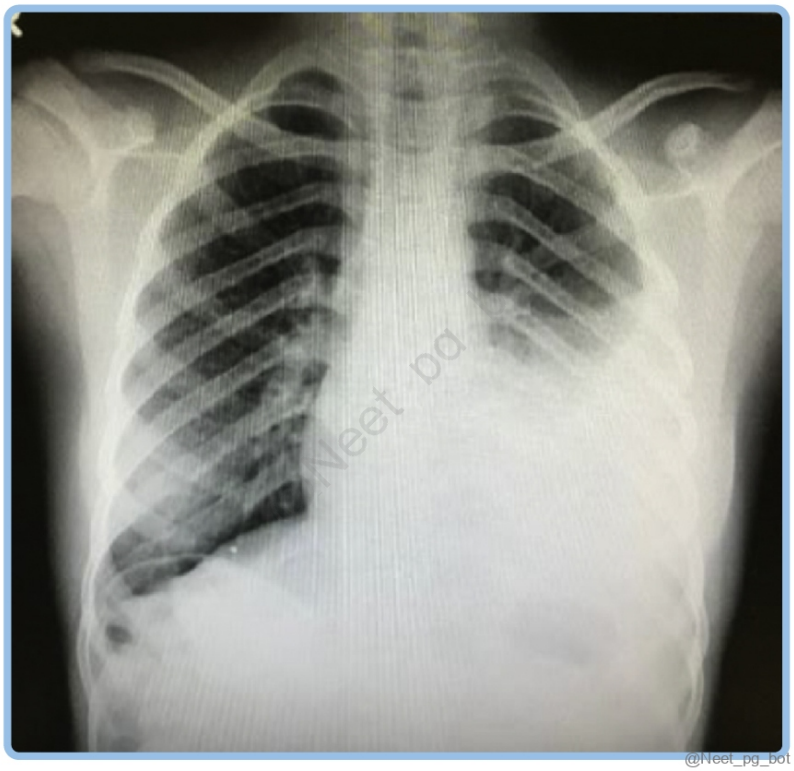

See Answer in Part B → Q1

@Neet_pg_bot

Q2: Match the ABG values in Column A with their corresponding acid-base disorders in Column B. Column A Column B 1. pH 7.48, pCO2 45, HCO3 35 A. Fully compensated respiratory acidosis 2. pH 7.32, pCO2 28, HCO3 14 B. Partially compensated metabolic alkalosis 3. pH 7.40, pCO2 30, HCO3 20 C. Partially compensated metabolic acidosis 4. pH 7.38, pCO2 68, HCO3 32 D. Fully compensated respiratory alkalosis (Q851993)

A. 1-B, 2-C, 3-D, 4-A

B. 1-C, 2-B, 3-A, 4-D

C. 1-A, 2-D, 3-C, 4-B

D. 1-D, 2-A, 3-B, 4-C

See Answer in Part B → Q2

@Neet_pg_bot

Q3: A 35-year-old male presents with severe substernal chest pain, difficulty breathing, and puffy swelling of the chest wall after multiple episodes of vomiting due to binge drinking. Upon examination, auscultation reveals a characteristic crunching sound. A chest X-ray demonstrates the presence of subcutaneous emphysema. Based on the clinical presentation, what is the next best step in managing this patient? (Q851890)

A. Administer intravenous antibiotics

B. Perform an urgent thoracotomy

C. Provide supplemental oxygen

D. Obtain a CT scan of the chest

See Answer in Part B → Q3

@Neet_pg_bot

Q4: A 35-year-old male presents to the emergency department after experiencing sudden chest pain and shortness of breath. He is a long-time smoker with no history of lung disease. A chest X-ray confirms a right-sided pneumothorax. Which type of pneumothorax is this patient most likely experiencing? (Q851889)

A. Secondary spontaneous pneumothorax

B. Traumatic pneumothorax

C. Primary spontaneous pneumothorax

D. Tension pneumothorax

See Answer in Part B → Q4

@Neet_pg_bot

Q5: A 55-year-old female with a history of COPD presents to the emergency department with sudden onset left-sided chest pain. A chest X-ray reveals a small

left-sided pneumothorax with a depth of 0.5 cm. The patient is otherwise stable, with no significant respiratory distress and a normal vital sign profile. What is the most appropriate management for this patient? (Q851887)

A. Administer high-flow oxygen and observe for 24 hours

B. Perform needle aspiration

C. Discharge with follow-up in 2-4 weeks

D. Thoracoscopy with pleural abrasion

See Answer in Part B → Q5

@Neet_pg_bot

Q6: A 28-year-old male presents to the emergency department after a motorcycle accident. He is experiencing severe shortness of breath and sharp left-sided chest pain. On examination, he has tachycardia and low oxygen saturation. A chest X-ray confirms a large left-sided pneumothorax. Vitals are HR: 120 bpm, BP: 70/40. What would be the most appropriate first step in the management of this patient? (Q851886)

A. Insert a thoracostomy tube

B. Administer supplemental oxygen

C. Perform needle decompression

D. Schedule video-assisted thoracoscopic surgery (VATS)

See Answer in Part B → Q6

@Neet_pg_bot

Q7: A patient with chest pain and shortness of breath with a heart rate of 145 beats per minute is being examined in the casualty. Which of the following clinical features is not seen in a pneumothorax? (Q851885)

A. Absent breath sounds

B. Hamman’s sign

C. Jugular venous distension

D. Hypotension

See Answer in Part B → Q7

@Neet_pg_bot

Q8: A child was brought to the hospital with noticeable difficulty in breathing. On examination, he has tachycardia, tachypnea, and asymmetrical lung expansion. A supine chest X-ray is taken and shown below. Identify the marked sign/structure in this patient's chest radiograph. (Q851883)

A. Collapsed lung

B. Visceral pleura

C. Hemidiapraghm depression

D. Deep sulcus sign

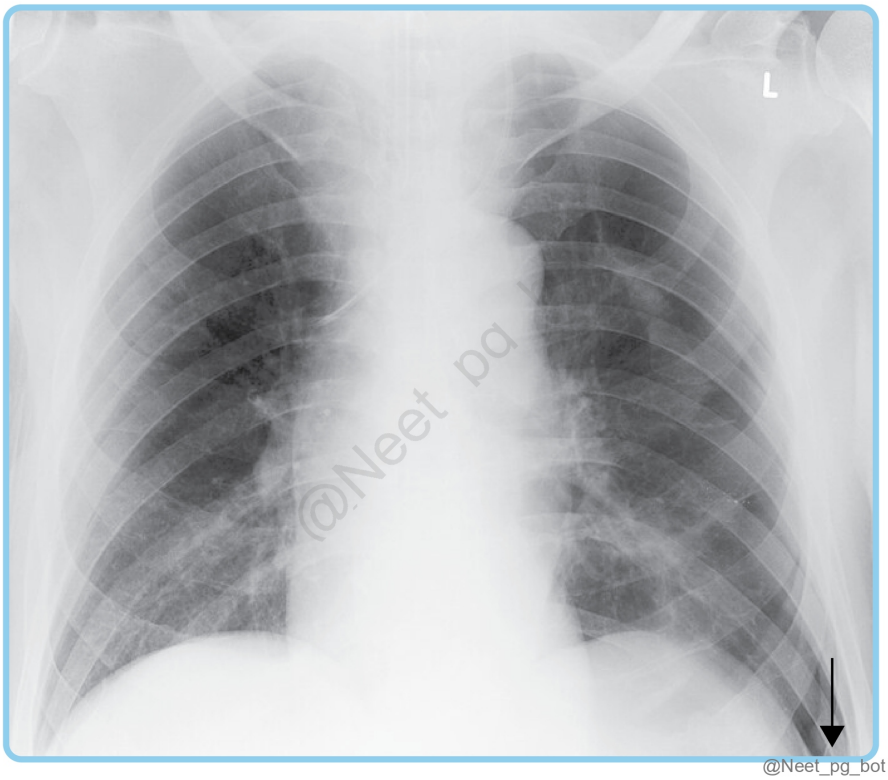

See Answer in Part B → Q8

@Neet_pg_bot

Q9: A 45-year-old male comes to the emergency department after a fall from height. He developed shortness of breath, tachypnea, and chest pain since the fall. A chest X-ray was taken shown below. What would be the pathophysiology for the development of this condition? (Q851882)

A. Rupture of apical pleural blebs

B. Preexisting COPD

C. Blunt trauma to the chest

D. Iatrogenic injury

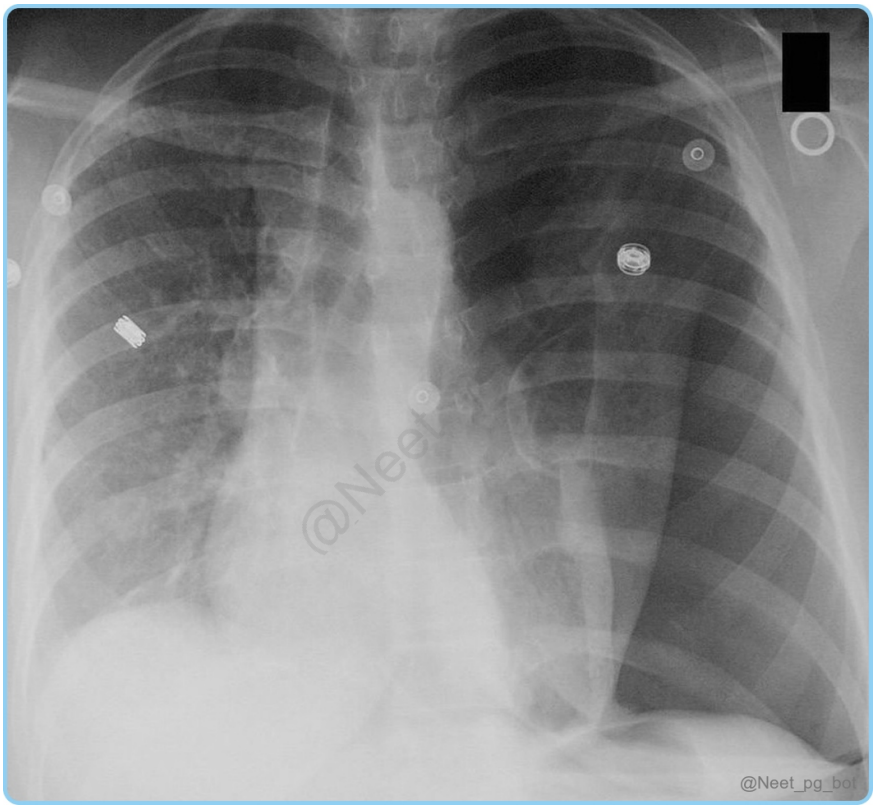

See Answer in Part B → Q9

@Neet_pg_bot

Q10: Which of the following statements regarding normal pleural fluid characteristics is accurate? (Q851855)

A. Normal pleural fluid typically contains over 3,000 WBCs/mm^3.

B. The glucose level in normal pleural fluid is typically lower than that of plasma.

C. Normal pleural fluid pH ranges from 7.60 to 7.64.

D. Lactate dehydrogenase (LDH) levels in normal pleural fluid are similar to those in plasma.

See Answer in Part B → Q10

@Neet_pg_bot

Q11: A 65-year-old male patient with Parkinson's disease has been experiencing fluctuations in his motor function, To help manage these "on-off" features, new medication to his treatment regimen. However, the patient later presented with respiratory distress, chest discomfort, and diminished breath sounds on examination. Which medication is likely to be the possible cause of these respiratory symptoms? (Q851876)

A. Amantadine

B. Levodopa

C. Bromocriptine

D. Pramipexole

See Answer in Part B → Q11

@Neet_pg_bot

Q12: A 55-year-old male who has worked in the shipyard industry presents with shortness of breath and persistent pain in the right lower chest. On examination, there is dullness to percussion and decreased breath sounds on the right side. A CT scan reveals diffuse pleural thickening and nodular masses. A biopsy is performed to confirm the diagnosis. Which immunohistochemical marker is most likely to be positive? (Q851873)

A. CD-117

B. Chromogranin

C. Calretinin

D. Vimentin

See Answer in Part B → Q12

@Neet_pg_bot

Q13: A 63-year-old female with metastatic adenocarcinoma of the lung presents with worsening dyspnea and a moderate-sized left-sided pleural effusion. After therapeutic thoracentesis reveals exudative fluid with low glucose levels and positive cytology for malignant cells, her symptoms improve, but the effusion is expected to reaccumulate. What is the most appropriate next step for long-term symptomatic relief? (Q851870)

A. Insertion of a small indwelling pleural catheter

B. Serial therapeutic thoracentesis

C. Tube thoracostomy without a sclerosing agent

D. Initiation of diuretics and oxygen therapy

See Answer in Part B → Q13

@Neet_pg_bot

Q14: A resident physician is preparing to perform a thoracentesis on a patient with a large pleural effusion. The patient is seated, and the procedure is to be performed under ultrasound guidance. Which of the following steps is crucial for the correct execution of the thoracentesis procedure? (Q851868)

A. Insert the needle below the lower rib to avoid injury

B. Perform the procedure at the 2nd intercostal space in the midclavicular line

C. Ensure the patient is in a supine position for optimal access

D. Insert the needle above the upper border of the lower rib in the targeted intercostal space

See Answer in Part B → Q14

@Neet_pg_bot

Q15: A 55-year-old woman presents with shortness of breath and cough. Chest X-ray shows a left-sided pleural effusion. Thoracentesis reveals the following findings. Using Light's criteria, which statement is true regarding this pleural effusion? Pleural fluid protein: 4.0 g/dL Serum protein: 6.8 g/dL Pleural fluid LDH: 280 U/L Serum LDH: 450 U/L (Q851865)

A. It is definitely transudative.

B. It meets the criteria for an exudative effusion.

C. It cannot be classified without further testing.

D. It is likely due to congestive heart failure.

See Answer in Part B → Q15

@Neet_pg_bot

Q16: A 60-year-old female with a known diagnosis of metastatic mesothelioma presents with worsening dyspnea and right-sided chest pain that is constant. Chest imaging is given below. What clinical finding is most likely to be present? (Q851861)

A. Hyperresonance to percussion

B. Egophony at the superior aspect of the effusion

C. Increased tactile fremitus

D. Bronchial breath sounds over the effusion

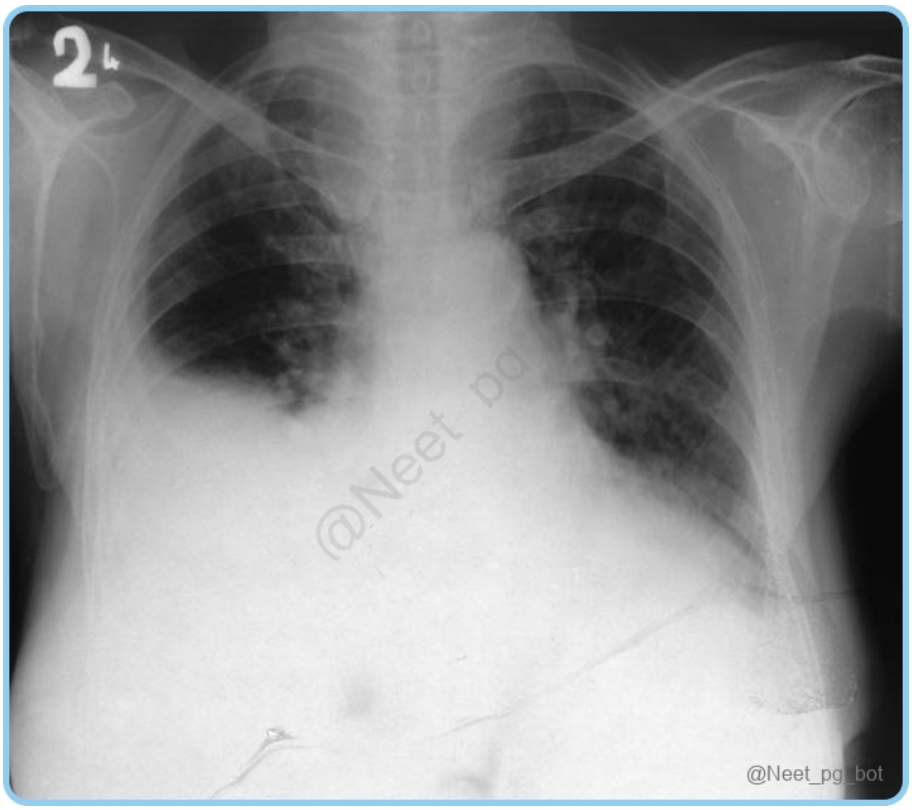

See Answer in Part B → Q16

@Neet_pg_bot

Q17: A patient presents with dyspnea and pleuritic chest pain. A chest X-ray shows a pleural effusion. Pleural fluid analysis reveals elevated protein and LDH levels. Which of the following conditions is the likely cause of this exudative pleural effusion? (Q851857)

A. Urinothorax

B. Esophageal rupture

C. Congestive heart failure

D. Nephrotic syndrome

See Answer in Part B → Q17

@Neet_pg_bot

• [10_Pulmonology] 082 Abg Analysis - I

« Back to Folder Directory

[10_Pulmonology] 082 Abg Analysis - I — Quick Jump

Q1 (p. 957)	*Q2 (p. 957)*	*Q3 (p. 958)*	*Q4 (p. 958)*	*Q5 (p. 959)*	*Q6 (p. 959)*
Q7 (p. 960)	*Q8 (p. 960)*	*Q9 (p. 961)*	*Q10 (p. 961)*	*Q11 (p. 962)*	*Q12 (p. 962)*
Q13 (p. 963)	*Q14 (p. 963)*	*Q15 (p. 964)*	*Q16 (p. 964)*	*Q17 (p. 964)*	*Q18 (p. 965)*
Q19 (p. 966)	*Q20 (p. 966)*	*Q21 (p. 966)*	*Q22 (p. 967)*		

Q1: A 45-year-old woman presents to the emergency department with diarrhea for the past three days. She reports fatigue and mild abdominal cramping. Laboratory tests show the following: Arterial blood gas pH 7.30 HCO■■ 15 mmol/L PaCO■ 38 mmHg Serum electrolytes Na■ 140 mmol/L Cl■ 115 mmol/L K■ 4.5 mmol/L What is the type of acidosis? (Q851932)

A. Normal Anion Gap Metabolic Acidosis

B. High Anion Gap Metabolic Acidosis

C. Respiratory Acidosis

D. None of the above

See Answer in Part B → Q1

@Neet_pg_bot

Q2: A 35-year-old male presents to the emergency complaining of chronic pain. He was diagnosed with lymphoma 6 months back. His HR is 96/min, and his RR is 38/min. An ABG sample is withdrawn, which shows pH 7.42, pCO 2 =25 mmHg, and HCO3=18 mmHg. What is the likely acid-base disorder? (Q882164)

A. Metabolic acidosis, partially compensated

B. Respiratory acidosis, partially compensated

C. Respiratory acidosis, fully compensated

D. Respiratory alkalosis, fully compensated

See Answer in Part B → Q2

@Neet_pg_bot

Q3: Match the acid base disorder with their respective etiology Condition Acid - base disorder 1. Ureterostomy a. High anion gap Metabolic acidosis 2. Opium poisoning b. Normal anion gap metabolic acidosis 3. Prolonged NG suction c. Respiratory acidosis 4. Salicylate poisoning d. Metabolic alkalosis (Q851995)

A. 1-b, 2-a, 3-c, 4-d

B. 1-b , 2-c ,3-d, 4-a

C. 1-c, 2-d, 3-a, 4-b

D. 1-d, 2-b, 3-a, 4-c

See Answer in Part B → Q3

@Neet_pg_bot

Q4: A 28-year-old woman at 32 weeks gestation presents with severe abdominal pain, vomiting, and rapid breathing. Vitals: BP 110/70 mmHg, HR 112/min, RR 28/min. Based on the Davenport diagram, which areas represent her acid-base status initially and after 12 hours if untreated? (Q851994)

A. Initially: Area C, After 12 hours: Area F

B. Initially: Area D, After 12 hours: Area F

C. Initially: Area A, After 12 hours: Area B

D. Initially: Area F, After 12 hours: Area C

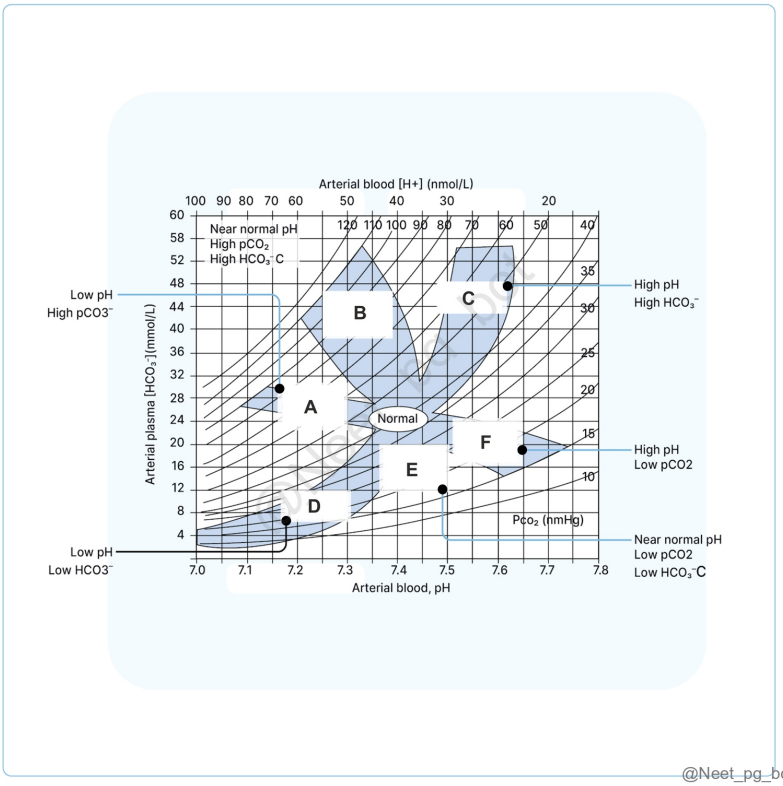

@Neet_pg_bot

See Answer in Part B → Q4

@Neet_pg_bot

Q5: A 50-year-old alcoholic presents with severe abdominal pain. His ABG shows pH: 7.20 HCO3: 12 mEq/L Na+: 140 mEq/L Cl-: 98 mEq/L. Which of the following options correctly justifies the diagnosis? (Q851992)

A. Delta ratio 0.4 - Pure NAGMA

B. Delta ratio 1.5 - Pure HAGMA

C. Delta ratio 0.6 - Mixed HAGMA and NAGMA

D. Delta ratio 2.2 - HAGMA with metabolic alkalosis

See Answer in Part B → Q5

@Neet_pg_bot

Q6: A 45-year-old diabetic patient presents to the emergency department with nausea and vomiting for 2 days. ABG shows: pH: 7.28 pCO■: 35 mmHg HCO■■: 12 mEq/L Na■: 138 mEq/L Cl■: 102 mEq/L What is the most likely acid-base disorder? (Q851991)

A. Simple metabolic acidosis

B. Metabolic acidosis with respiratory alkalosis

C. Metabolic acidosis with respiratory acidosis

D. Metabolic alkalosis and respiratory alkalosis

See Answer in Part B → Q6

@Neet_pg_bot

Q7: A 68-year-old woman with a history of chronic kidney disease and recent severe pneumonia is admitted to the intensive care unit. She has been experiencing increased shortness of breath, confusion, and fatigue. Laboratory tests reveal the following: Arterial blood gas: pH 7.28, HCO■■ 18 mmol/L, PaCO■ 50 mmHg Serum electrolytes: Na■ 140 mmol/L, K■ 4.2 mmol/L, Cl■ 100 mmol/L Based on the laboratory results and clinical presentation, what type of acid-base disorder is this patient experiencing? (Q851990)

A. Metabolic acidosis—respiratory alkalosis

B. Metabolic acidosis—respiratory acidosis

C. Metabolic alkalosis—respiratory acidosis

D. Metabolic acidosis—metabolic alkalosis

See Answer in Part B → Q7

@Neet_pg_bot

Q8: A 72-year-old man with a history of chronic kidney disease and COPD presents to the emergency department with confusion, shortness of breath, and fatigue. He has been experiencing increased nausea and vomiting over the past week. Laboratory tests

reveal: Arterial blood gas: pH 7.29, HCO■■ 18 mmol/L, PaCO■ 60 mmHg Serum electrolytes: Na■ 138 mmol/L, K■ 4.8 mmol/L, Cl■ 102 mmol/L Based on the provided laboratory results, what type of acid-base disorder is this patient experiencing? (Q851989)

A. Respiratory acidosis

B. Metabolic acidosis

C. Mixed respiratory and metabolic acidosis

D. Fully compensated metabolic acidosis

See Answer in Part B → Q8

@Neet_pg_bot

Q9: A 65-year-old man with a history of chronic obstructive pulmonary disease presents to the emergency department with light-headedness and confusion along with tingling sensation of his limbs. He has also been experiencing persistent vomiting for the past three days due to food poisoning. Arterial blood gas shows the following findings pH - 7.48 HCO3- - 38 mEq/L PaCO2 - 40 mm hg Which of the following is correct about this patient? (Q851988)

A. Fully compensated metabolic alkalosis

B. Partially compensated metabolic alkalosis

C. Uncompensated metabolic alkalosis

D. Normal acid-base balance

See Answer in Part B → Q9

@Neet_pg_bot

Q10: A 50-year-old woman with a history of hypertension presents to the emergency department with confusion and muscle cramps. She reports having persistent vomiting for the last two days after taking an over-the-counter medication for indigestion. On examination, she has a blood pressure of 130/85 mmHg and shows

signs of mild dehydration. Laboratory results reveal: Arterial blood gas: pH 7.48, HCO■■ 30 mmol/L, PaCO■ 45 mmHg Serum electrolytes: Na■ 140 mmol/L, K■ 3.0 mmol/L, Cl■ 88 mmol/L What is the most likely diagnosis for this patient based on the laboratory findings? (Q851987)

A. Respiratory acidosis

B. Metabolic acidosis

C. Metabolic alkalosis

D. Respiratory alkalosis

See Answer in Part B → Q10

@Neet_pg_bot

Q11: 60-year-old man with a history of chronic kidney disease presents to the emergency department with fatigue and extreme shortness of breath. Laboratory tests reveal: Arterial blood gas: pH 7.30, HCO■■ 12 mmol/L, PaCO■ 30 mmH Serum electrolytes: Na■ 140 mmol/L, Cl■ 104 mmol/L, K■ 5.0 mmol/L Which of the following is correct about this patient's status? (Q851933)

A. Metabolic acidosis with respiratory alkalosis

B. Metabolic acidosis with respiratory acidosis

C. Uncompensated metabolic acidosis

D. Metabolic acidosis with metabolic alkalosis

See Answer in Part B → Q11

@Neet_pg_bot

Q12: A 62-year-old female with known COPD presents with increased muscle weakness and difficulty in breathing. On examination she appears confused and her arterial blood gas (ABG) results are as follows: pH: 7.29 PaCO■: 65 mm Hg HCO■■: 26 mEq/L PaO■: 65 mm Hg. Which of the following best describes the underlying mechanism for this patient's presentation? (Q851791)

A. Increased metabolic rate leading to excess CO■ production

B. Impaired ventilatory control due to central respiratory depression

C. Impaired responsiveness of the respiratory reflexes to states of hypoxia and hypercapnia

D. Decreased oxygen-carrying capacity of the blood

See Answer in Part B → Q12

@Neet_pg_bot

Q13: A 30-year-old male presents with: ABG: pH: 7.20, PaCO2: 25 mmHg, HCO3-: 10 mEq/L, Na+: 140 mEq/L, Cl-: 100 mEq/L, and Blood lactate: 12 mmol/L. Calculate: Anion gap Expected PaCO2 compensation (Q851931)

A. AG=30, Expected PaCO2=25±2

B. AG=30, Expected PaCO2=30±2

C. AG=25, Expected PaCO2=25±2

D. AG=25, Expected PaCO2=30±2

See Answer in Part B → Q13

@Neet_pg_bot

Q14: A 75-year-old man presents to the emergency department with severe abdominal pain, vomiting, frequent urination, confusion, and labored, deep breathing and he is difficult to arouse. Lab investigations reveal the following findings Na+ - 135 mEq/L K+ - 5.2 mEq/L Cl - 100 mEq/L HCO3 - 15 mEq/L Serum pH - 7.15 What is the least likely cause of these findings? (Q851930)

A. Methanol poisoning

B. Diabetic ketoacidosis

C. Renal tubular acidosis

D. Renal failure

See Answer in Part B → Q14

@Neet_pg_bot

Q15: An intern reviews the following electrolyte levels for a patient: Sodium (Na■): 140 mEq/L Chloride (Cl■): 100 mEq/L Bicarbonate (HCO■■): 24 mEq/L Potassium (K■): 4.0 mEq/L What is the calculated anion gap for this patient? (Q851929)

A. 12 mEq/L

B. 16 mEq/L

C. 20 mEq/L

D. 24 mEq/L

See Answer in Part B → Q15

@Neet_pg_bot

Q16: A 28-year-old anxious female presents with hyperventilation during a panic attack. ABG shows: pH: 7.48 PaCO2: 20 mmHg HCO3-: 22 mEq/L Which acid-base disorder is present? (Q851919)

A. Uncompensated respiratory alkalosis

B. Partially compensated respiratory alkalosis

C. Fully compensated respiratory alkalosis

D. Mixed respiratory and metabolic alkalosis

See Answer in Part B → Q16

@Neet_pg_bot

Q17: A 65-year-old male with severe COPD presents with worsening breathlessness. His ABG shows: pH: 7.28, PaCO2: 65 mmHg, HCO3-: 30 mEq/L Which stage of respiratory acidosis does this represent? (Q851915)

A. Uncompensated respiratory acidosis

B. Partially compensated respiratory acidosis

C. Fully compensated respiratory acidosis

D. Mixed respiratory and metabolic acidosis

See Answer in Part B → Q17

@Neet_pg_bot

Q18: Which of the following statements regarding the test shown in the image, done prior to arterial blood sampling is not true? (Q851905)

A. Preferred site for arterial sampling is the radial artery between the flexor carpi radialis tendon and the styloid process

B. Both ulnar and radial arteries should be released simultaneously after occlusion

C. The presence of collaterals is confirmed if the hand becomes flushed after releasing one artery

D. Pressure should be applied to the site for 5 minutes after blood sampling to prevent hematoma



@Neet_pg_bot

See Answer in Part B → Q18

@Neet_pg_bot

Q19: A 28-year-old woman presents to the emergency department with anxiety, dizziness, and circumoral numbness. She also reports chest tightness and difficulty taking a deep breath. Physical examination reveals tachypnea and carpopedal spasms. Arterial blood gas shows pH: 7.48, PaCO2: 28 mmHg, HCO3: 22 mEq/L, PaO2: 98 mmHg. Which of the following sets of additional findings would be most consistent with this acid-base disorder? (Q851902)

A. Hypoxemia, cyanosis, and metabolic acidosis

B. Paresthesias, reduced cerebral blood flow and decreased ionized calcium

C. Hypertension, pulmonary edema, and increased ionized calcium

D. Somnolence, asterixis, and increased cerebral blood flow

See Answer in Part B → Q19

@Neet_pg_bot

Q20: A 25-year-old pregnant woman at 28 weeks gestation presents with light-headedness and tingling sensations in her fingers. Her respiratory rate is 24/min. Arterial blood gas shows: pH: 7.46 PaCO■: 32 mmHg HCO■■: 23 mEq/L Which of the following best explains the pathogenesis of her acid–base disturbance? (Q851802)

A. Direct CNS depression causing decreased respiratory drive

B. Progesterone-mediated increase in ventilatory response

C. Compensatory hyperventilation from metabolic acidosis

D. Increased tidal volume due to mechanical pressure of the gravid uterus

See Answer in Part B → Q20

@Neet_pg_bot

Q21: A 65-year-old man with severe COPD presents with worsening confusion and somnolence. Arterial blood gas shows: pH: 7.25 PaCO2: 70 mmHg HCO3: 32 mEq/L PaO2: 55 mmHg. Which of the following represents the most appropriate initial management approach? (Q851796)

A. Rapidly normalize PaCO2 with mechanical ventilation

B. Provide controlled oxygen therapy and treat underlying COPD exacerbation

C. Give sodium bicarbonate to correct acidemia

D. Observe and monitor without intervention

See Answer in Part B → Q21

@Neet_pg_bot

Q22: A 68-year-old man with severe COPD presents with progressive confusion, daytime sleepiness, and morning headaches over the past month. On examination, he has a coarse tremor and asterixis. Arterial blood gas shows pH 7.32, PaCO2 68 mmHg, HCO3- 34 mEq/L. Which combination of additional findings would be most consistent with this patient's acid-base disorder? (Q851794)

A. Acute anxiety, hallucinations, and respiratory distress

B. Sleep disorders, personality changes, and polycythemia

C. Acute dyspnea, psychosis, and normal bicarbonate

D. Muscle weakness, confusion, and metabolic acidosis

See Answer in Part B → Q22

@Neet_pg_bot

• [10_Pulmonology] 083 Images In Pulmonology

« Back to Folder Directory

[10_Pulmonology] 083 Images In Pulmonology — Quick Jump

Q1 (p. 968) *Q2 (p. 969)* *Q3 (p. 969)* *Q4 (p. 970)* *Q5 (p. 971)* *Q6 (p. 972)*
Q7 (p. 973) *Q8 (p. 974)* *Q9 (p. 974)* *Q10 (p. 975)* *Q11 (p. 976)*

Q1: A 62-year-old male with a history of smoking presents with chronic cough, weight loss, and recent hemoptysis. A chest X-ray is done and is provided below. Which of the following is the most likely primary source of this lesion? (Q851891)

A. Renal cell carcinoma

B. Breast carcinoma

C. Gastric adenocarcinoma

D. Thyroid carcinoma

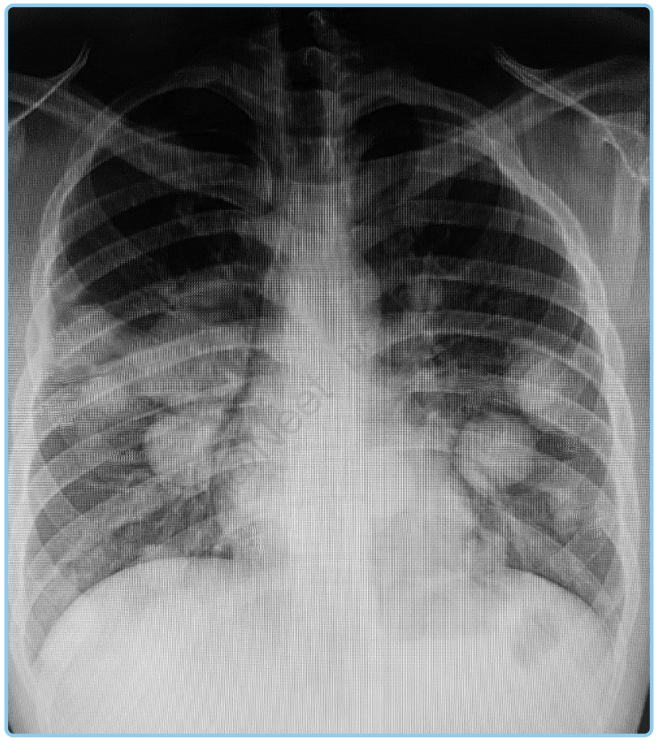

@Neet_pg_bot

See Answer in Part B → Q1

Q2: A 65-year-old male with a history of chronic liver disease presents with progressive shortness of breath, fatigue, and mild chest discomfort over the past few weeks. On examination, there is decreased bilateral breath sound intensity with dullness on percussion at the lung bases. A chest X-ray shows the following features. What is the most likely diagnosis? (Q851894)

A. Bilateral Hydrothorax

B. Empyema Thoracis

C. Hydropneumothorax

D. Congestive Heart Failure with Pleural Effusion

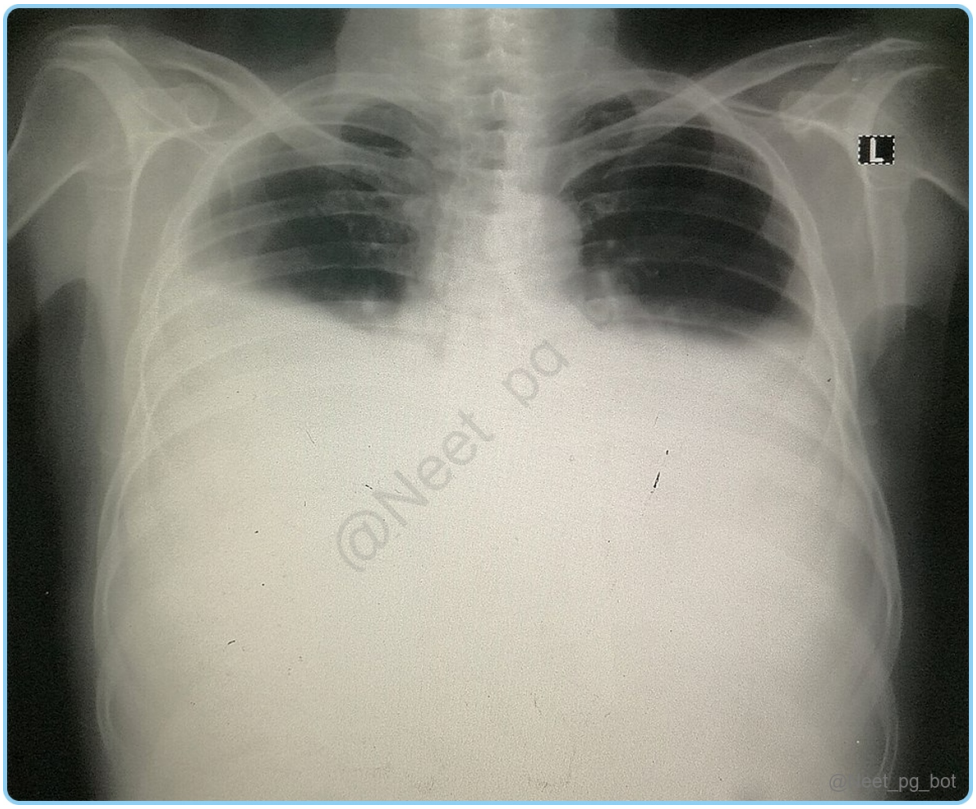

See Answer in Part B → Q2

Q3: A 65-year-old man visits OPD with the following presentation as shown in the image. His chest CT shows bronchiectasis. Which of the following statements is incorrect regarding this patient's digital finding? (Q851897)

A. The condition involves proliferation of connective tissue at the nail base

B. It can be associated with cystic fibrosis and lung cancer

C. The condition always indicates irreversible tissue changes

D. The pathogenesis involves platelet-derived growth factors

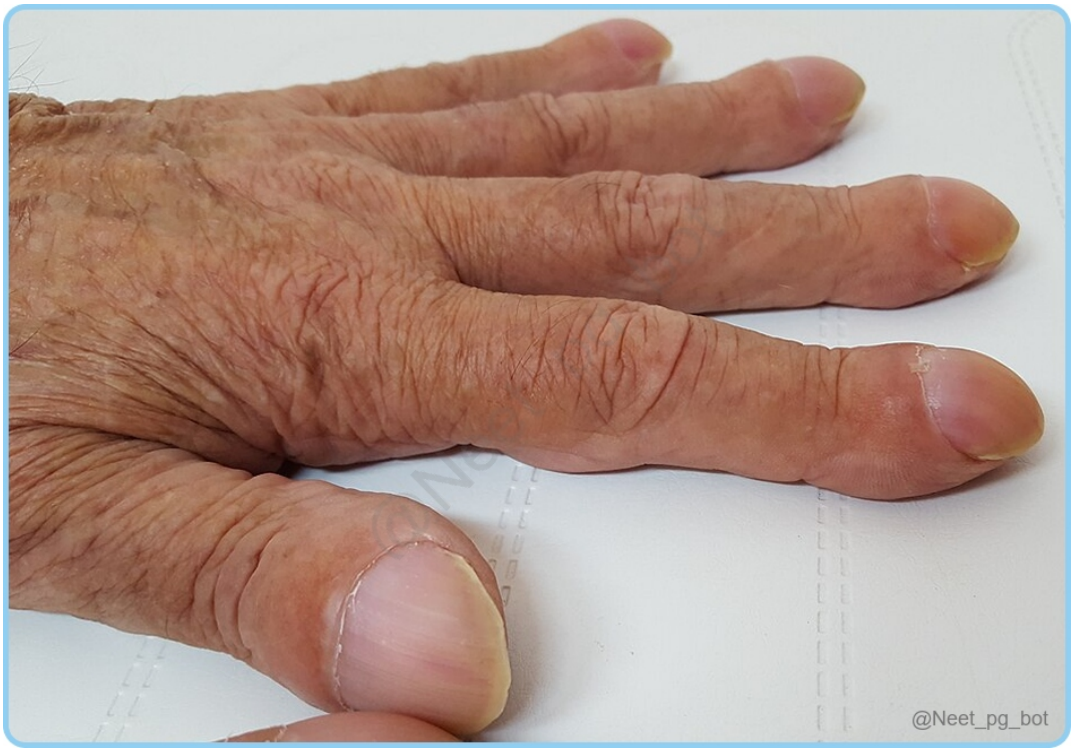

See Answer in Part B → Q3

@Neet_pg_bot

Q4: A 25-year-old male presents to the emergency department with sudden onset of right-sided chest pain and mild shortness of breath. He is tall, thin, and a smoker. Physical examination reveals decreased breath sounds on the right side with hyperresonance on percussion. Chest X-ray is given below. The patient is hemodynamically stable with oxygen saturation of 96% on room air. What is the most appropriate initial management? (Q851899)

A. Discharge with follow-up in 2-4 weeks

B. Needle aspiration

C. Immediate tube thoracostomy

D. High-flow oxygen and observation for 24 hours

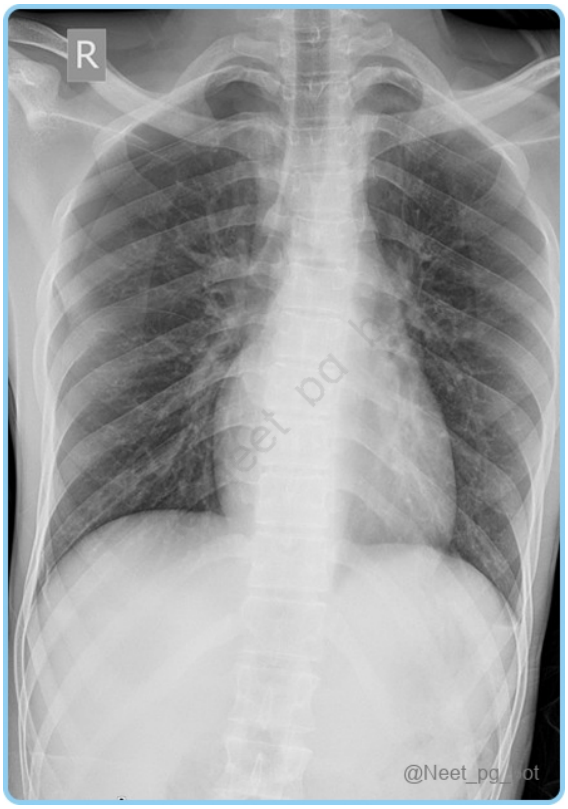

See Answer in Part B → Q4

@Neet_pg_bot

Q5: A 28-year-old male is brought to the emergency department after a motor vehicle accident with chest trauma. He is in severe respiratory distress with BP 80/50 mmHg, HR 142/min, RR 32/min. Physical examination reveals absent breath sounds. The X-ray is attached below. What is the most appropriate next step in management? (Q851903)

A. CT Head for identifying possible cerebral injury

B. Start high-flow oxygen

C. Immediate needle decompression

D. Intercostal tube

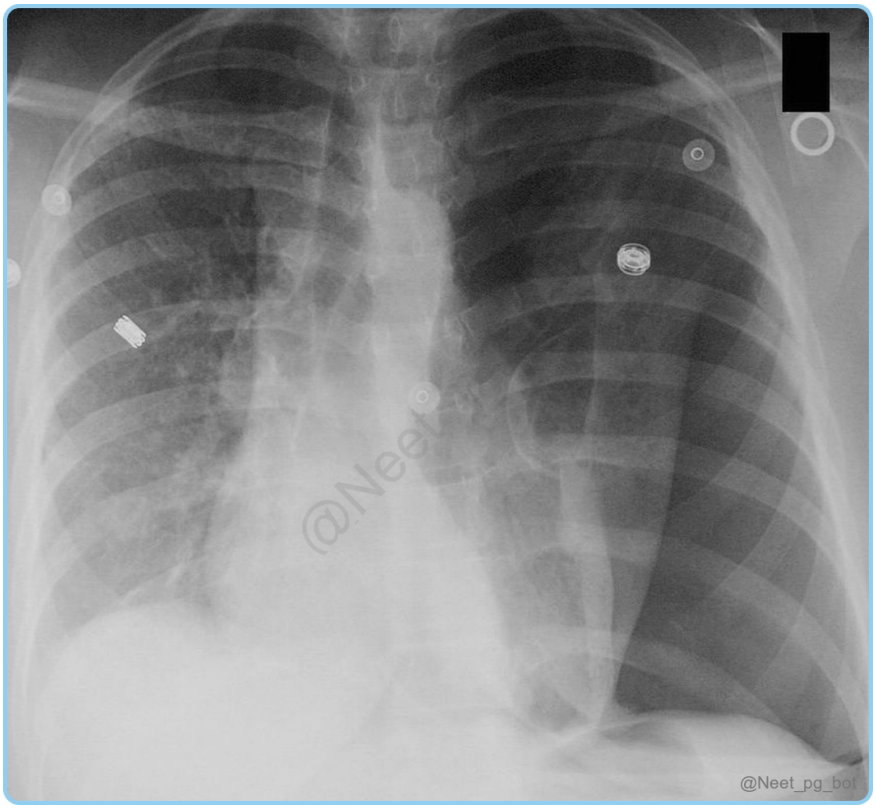

See Answer in Part B → Q5

@Neet_pg_bot

Q6: A 68-year-old female receiving a blood transfusion for severe anemia develops acute dyspnea, tachypnea, and hypertension 30 minutes into the transfusion. Her blood pressure is 168/95 mmHg, and chest auscultation reveals bilateral crackles. Which of the following represents the most appropriate immediate management? (Q851908)

A. Continue transfusion but at a slower rate

B. Stop transfusion and administer diuretics

C. Administer acetaminophen and continue transfusion

D. Stop transfusion and start steroids

See Answer in Part B → Q6

Q7: A 65-year-old male presents to the emergency department with acute dyspnea and bilateral crackles. His blood pressure is 160/90 mmHg, heart rate 110/min, and respiratory rate 28/min. Physical examination reveals jugular venous distention, bilateral pedal edema, and an S3 gallop. Chest X-ray is given below. His pulmonary capillary wedge pressure (PCWP) is 25 mmHg. Which of the following is the most appropriate initial management? (Q851914)

A. High-flow oxygen and observation

B. Immediate intubation

C. IV furosemide and nitrates

D. Antibiotics and steroids

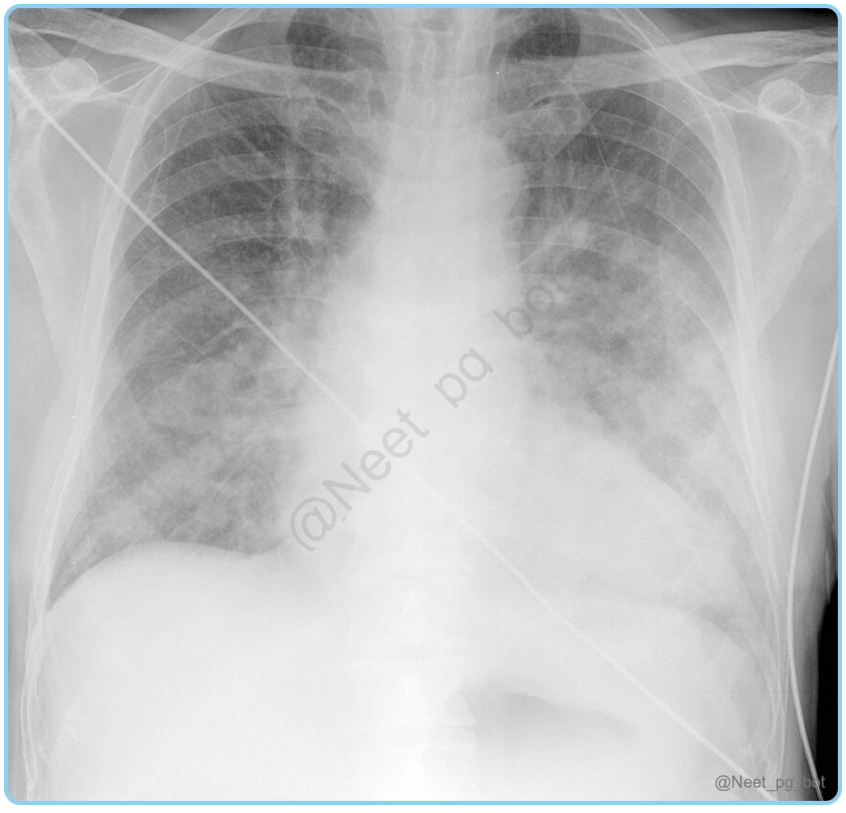

See Answer in Part B → Q7

Q8: A 65-year-old male with a 40-pack-year smoking history presents with progressive dyspnea, productive cough, and weight loss. Physical examination reveals a barrel chest, decreased breath sounds, and prolonged expiration. Chest X-ray is given below. His FEV1/FVC ratio is 0.65 and doesn't improve with bronchodilators. Which of the following is the most likely pathological finding in this patient? (Q851921)

A. Inflammation of bronchial walls with mucus hypersecretion

B. Permanent enlargement of airspaces distal to terminal bronchioles

C. Bronchial wall thickening with reversible airway obstruction

D. Interstitial fibrosis with restrictive pattern

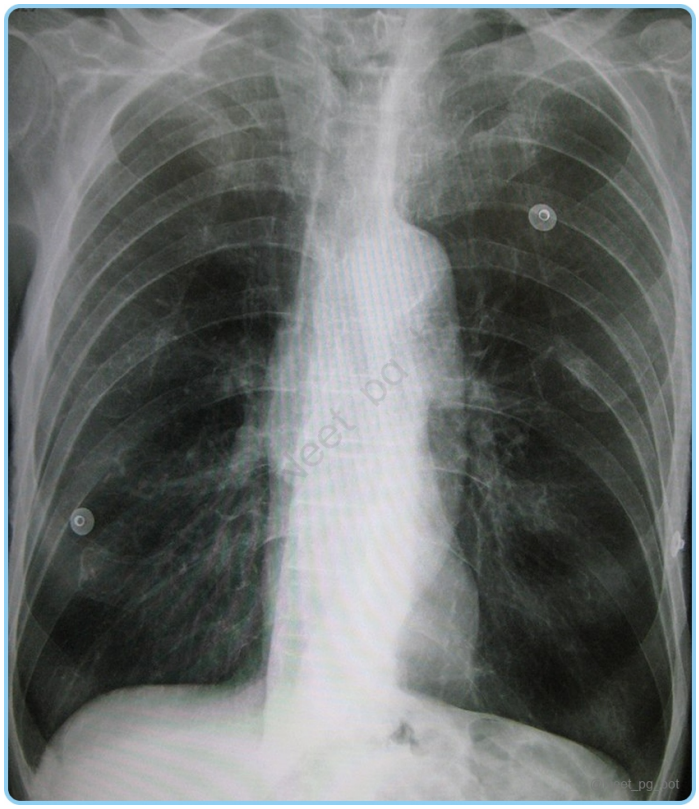

See Answer in Part B → Q8

@Neet_pg_bot

Q9: A 55-year-old man with a history of deep vein thrombosis is brought to the emergency department by his wife after he suddenly developed sharp, stabbing chest pain and shortness of breath while at home. He describes the pain as worse when taking a deep breath. The X-ray taken is displayed below. What is the most likely diagnosis? (Q851924)

A. Pneumonia

B. Atelectasis

C. Pulmonary infarction due to pulmonary embolism

D. Lung abscess

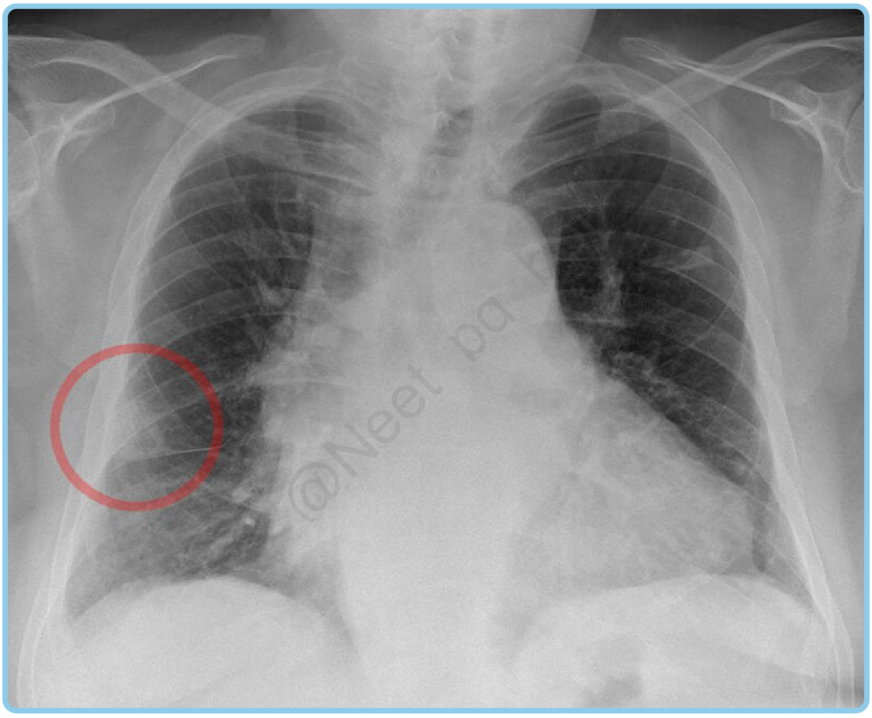

See Answer in Part B → Q9

@Neet_pg_bot

Q10: A 65-year-old male patient presents to the pulmonary clinic with a history of progressive shortness of breath and a chronic cough. He is a long-term smoker and has a family history of respiratory diseases. A spirometry test is performed, and the

flow-volume loop is plotted. What is the most likely diagnosis based on the patient's symptoms and the shape of his flow-volume loop? (Q851927)

A. Restrictive lung disease

B. Obstructive lung disease

C. Normal lung function

D. Fixed upper airway obstruction

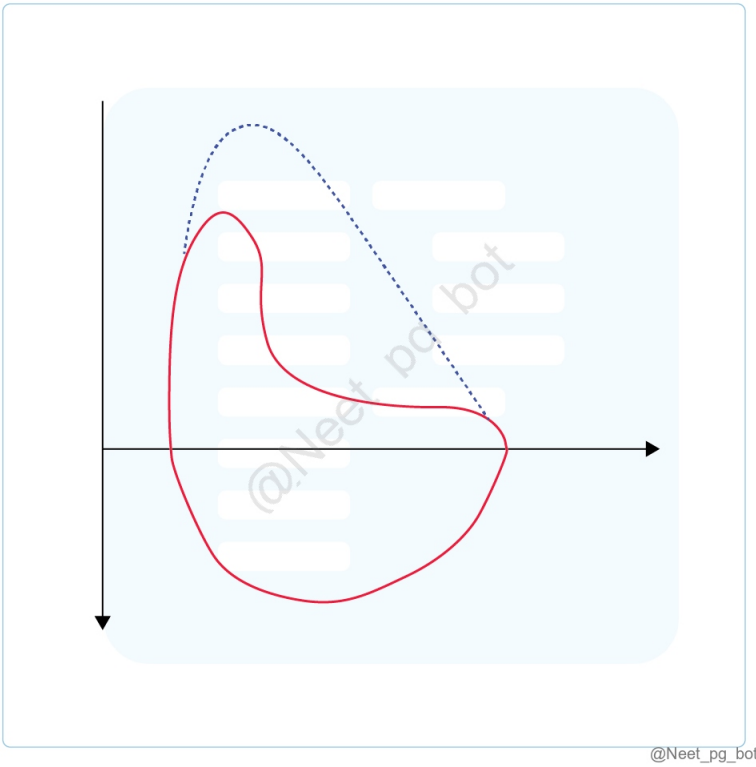

See Answer in Part B → Q10

@Neet_pg_bot

Q11: Match the Condition with the Correct Description on X-ray: 1. Pneumatocele a. 2. Tuberculosis (TB) b. 3. Miliary TB c. 4. Lung Abscess d. (Q851928)

A. 1 - b, 2 - c, 3 - a, 4 - d

B. 1 - a, 2 - b, 3 - c, 4 - d

C. 1 - d, 2 - c, 3 - b, 4 - a

D. 1 - c, 2 - b, 3 - d, 4 - a



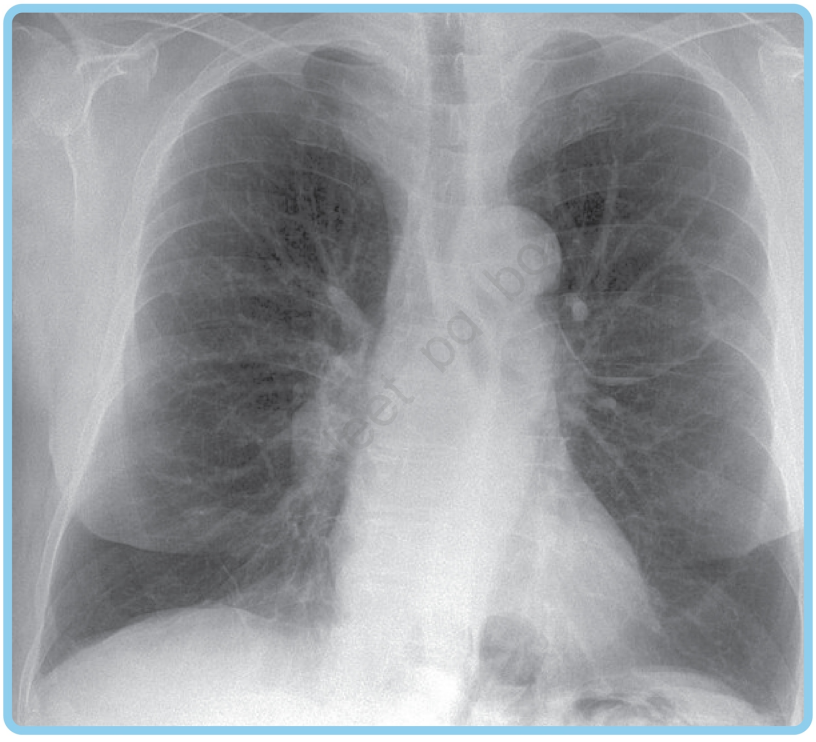

@Neet_pg_bot



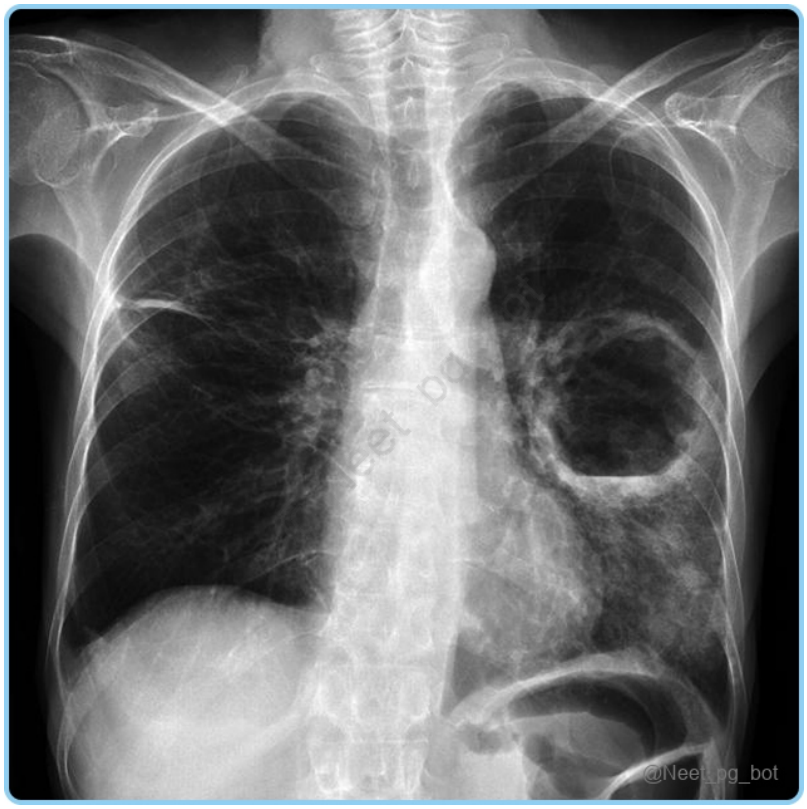

See Answer in Part B → Q11

@Neet_pg_bot

• [10_Pulmonology] 084 Previous Year Questions

« Back to Folder Directory

[10_Pulmonology] 084 Previous Year Questions — Quick Jump

Q1 (p. 980)	*Q2 (p. 981)*	*Q3 (p. 981)*	*Q4 (p. 982)*	*Q5 (p. 982)*	*Q6 (p. 983)*
Q7 (p. 984)	*Q8 (p. 984)*	*Q9 (p. 984)*	*Q10 (p. 985)*	*Q11 (p. 985)*	*Q12 (p. 986)*
Q13 (p. 986)	*Q14 (p. 986)*	*Q15 (p. 987)*	*Q16 (p. 988)*	*Q17 (p. 988)*	*Q18 (p. 989)*
Q19 (p. 989)	*Q20 (p. 990)*	*Q21 (p. 991)*	*Q22 (p. 991)*	*Q23 (p. 991)*	*Q24 (p. 992)*
Q25 (p. 992)	*Q26 (p. 993)*	*Q27 (p. 993)*	*Q28 (p. 994)*	*Q29 (p. 994)*	*Q30 (p. 995)*
Q31 (p. 995)	*Q32 (p. 995)*	*Q33 (p. 996)*	*Q34 (p. 996)*	*Q35 (p. 997)*	*Q36 (p. 997)*
Q37 (p. 997)	*Q38 (p. 998)*	*Q39 (p. 999)*	*Q40 (p. 999)*	*Q41 (p. 1000)*	*Q42 (p. 1001)*
Q43 (p. 1002)	*Q44 (p. 1002)*	*Q45 (p. 1003)*	*Q46 (p. 1003)*	*Q47 (p. 1004)*	*Q48 (p. 1005)*
Q49 (p. 1005)	*Q50 (p. 1005)*	*Q51 (p. 1006)*	*Q52 (p. 1006)*	*Q53 (p. 1007)*	*Q54 (p. 1007)*
Q55 (p. 1008)	*Q56 (p. 1008)*	*Q57 (p. 1009)*	*Q58 (p. 1009)*	*Q59 (p. 1010)*	*Q60 (p. 1011)*
Q61 (p. 1011)	*Q62 (p. 1012)*	*Q63 (p. 1012)*	*Q64 (p. 1013)*	*Q65 (p. 1014)*	*Q66 (p. 1014)*
Q67 (p. 1014)	*Q68 (p. 1015)*	*Q69 (p. 1016)*	*Q70 (p. 1016)*	*Q71 (p. 1016)*	*Q72 (p. 1017)*
Q73 (p. 1017)	*Q74 (p. 1018)*	*Q75 (p. 1018)*	*Q76 (p. 1019)*	*Q77 (p. 1020)*	*Q78 (p. 1020)*
Q79 (p. 1021)	*Q80 (p. 1021)*	*Q81 (p. 1022)*	*Q82 (p. 1023)*	*Q83 (p. 1023)*	*Q84 (p. 1024)*
Q85 (p. 1024)	*Q86 (p. 1025)*	*Q87 (p. 1025)*	*Q88 (p. 1025)*	*Q89 (p. 1026)*	*Q90 (p. 1027)*
Q91 (p. 1027)					

Q1: A chronic smoker presented with shortness of breath, bilateral pitting pedal edema, and abdominal distension. On examination, jugular venous pulse was found to be elevated and liver was palpable 8 cm below the costal margin. An abnormality in which of the following structures is responsible for the patient's symptoms? (Q856629)

A. 1

B. 2

C. 3

D. 4

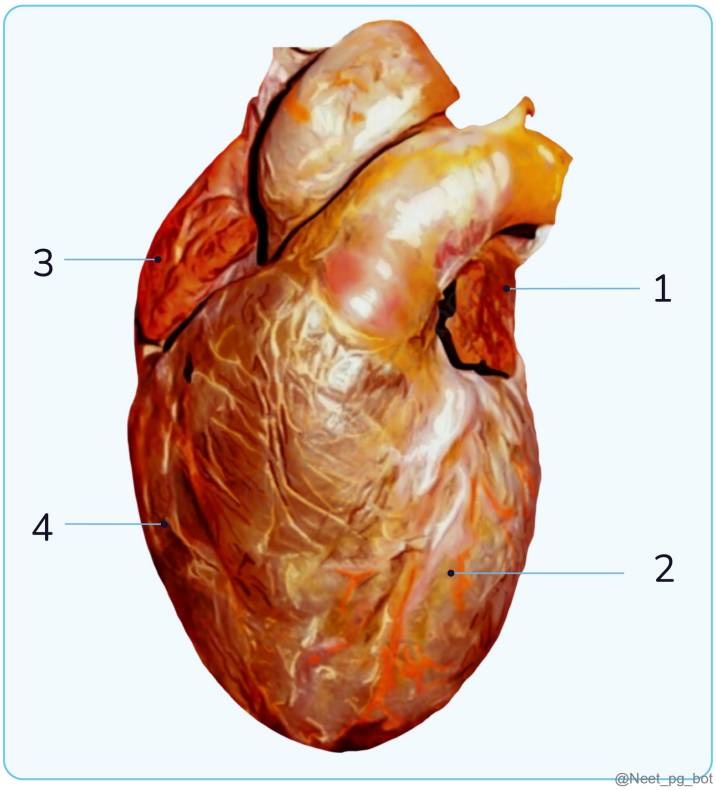

See Answer in Part B → Q1

@Neet_pg_bot

Q2: A 60-year-old male patient who is a known case of COPD presented with acute exacerbation and is admitted to the ICU. Which of the following statements is correct with regards to the initial management of this patient? (Q854995)

A. Non-invasive PPV should be given

B. Invasive PPV should be given

C. IV corticosteroids should be administered

D. Permissive hypercapnia is allowed

See Answer in Part B → Q2

@Neet_pg_bot

Q3: When you are posted as an intern in the emergency department, a 67 year old man with a known case of diabetic and CKD for 15 yrs is brought to you with complaints of persistent cough, shortness of breath, fever, fatigue, and chest pain. He has been tested positive for COVID 19. Which of the following features will prompt you to get this patient admitted to a dedicated COVID health center? A. Respiratory rate of 33/min B. SpO 2 88% C. Multiple comorbidities D. Chest pain E. Age (Q856965)

A. A & B only

B. A, B, C & E only

C. A, B, & C only

D. None of the above

See Answer in Part B → Q3

@Neet_pg_bot

Q4: High anion gap acidosis with low bicarbonate levels is seen in all of the following conditions except: (Q856957)

A. Renal tubular acidosis

B. Diabetic ketoacidosis

C. Lactic acidosis

D. Salicylate poisoning

See Answer in Part B → Q4

@Neet_pg_bot

Q5: What should be your subsequent course of action for the patient, who has been intubated and his X-ray as depicted in the radiograph? (Q856937)

A. Suction

B. Chest physiotherapy

C. Start antibiotics and send and samples for culture

D. Ultrasound-guided aspiration

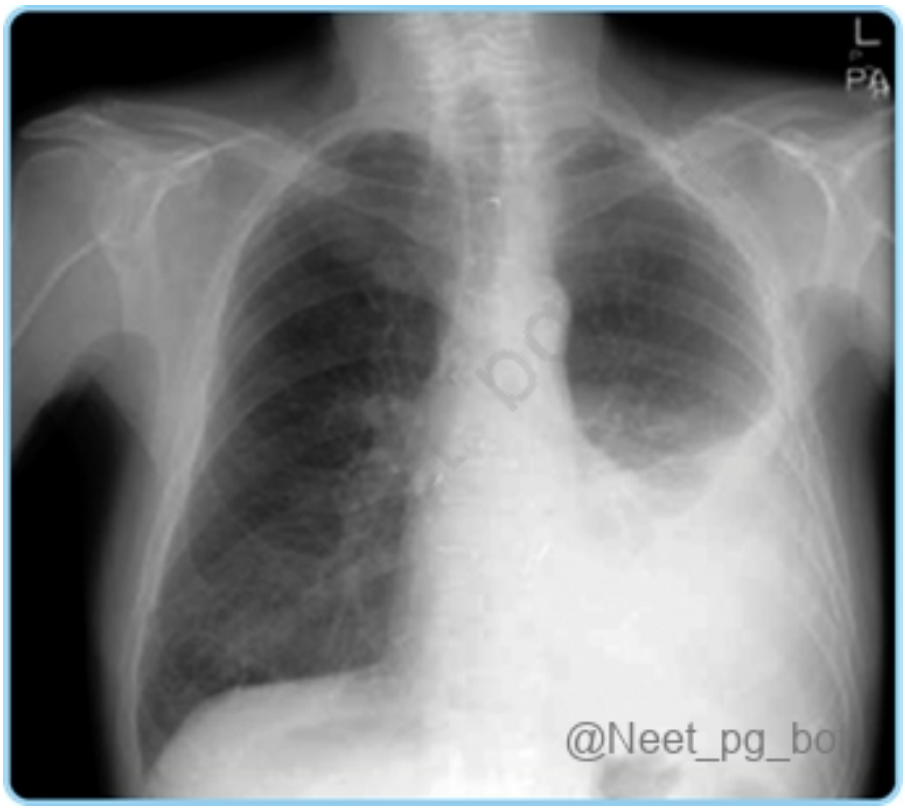

See Answer in Part B → Q5

@Neet_pg_bot

Q6: A 50-year-old individual who is a chronic smoker came with complaints of recurrent episodes of coughing up blood without any accompanying symptoms of fever or weight loss. On chest x-ray there were no abnormalities seen, and the sputum test is also negative for acid-fast bacilli (AFB). Which of the following options could be the next effective diagnostic test? (Q856926)

A. MRI

B. CT

C. Fiberoptic bronchoscopy

D. Bronchography

See Answer in Part B → Q6

@Neet_pg_bot

Q7: A 68-year-old man presents with a cough with yellowish sputum. Auscultation revealed bronchial breath sounds. He is hemodynamically stable and not confused. On examination, his respiratory rate is 20/min, and his blood pressure is 110/70 mmHg. Lab reports show urea levels of 44 mg/dL. What is the next best step in the management of this patient? (Q856194)

A. Given antibiotics and send the patient home

B. Admit to ICU without mechanical ventilation

C. Admit to ICU with invasive mechanical ventilation

D. Consider admission in a non-ICU setting

See Answer in Part B → Q7

@Neet_pg_bot

Q8: A woman with hysteria who was hyperventilating developed carpo-pedal spasms. What could be the likely cause for this? (Q856163)

A. Respiratory acidosis

B. Metabolic acidosis

C. Respiratory alkalosis

D. Metabolic alkalosis

See Answer in Part B → Q8

@Neet_pg_bot

Q9: A diabetic woman presents with persistent vomiting after eating outside food. Her BP is 90/60 mmHg. ABG shows: pH: 7.52 HCO■■: 30 mEq/L PaCO■: 20 mmHg

Na■: 123 mEq/L K■: 3.2 mEq/L Cl■: 67 mEq/L What is the most likely cause of these ABG findings? (Q856157)

A. Isolated vomiting induced metabolic alkalosis

B. Diabetic ketoacidosis (DKA)

C. Septic shock

D. Mixed disorder: Vomiting + Early DKA

See Answer in Part B → Q9

@Neet_pg_bot

Q10: A middle-aged man with chronic renal failure on dialysis presents with sudden collapse to the casualty with laboured breathing. ECG shows tall, tented T waves. What is the most likely acid-base imbalance that can be seen in this patient? (Q856141)

A. pH-7.14, pCO2-20 mmHg, HCO3- 5 mEq/L

B. pH-7.14, pCO2-20 mmHg, HCO3- 34 mEq/L

C. pH-7.54, pCO2- 34 mmHg, HCO3- 27 mEq/L

D. pH-7.4, pCO2- 40 mmHg, HCO3- 27 mEq/L

See Answer in Part B → Q10

@Neet_pg_bot

Q11: A 10-year-old child with AIDS presented with a fever and productive cough. On auscultation, bronchial breath sounds and crepitations were heard in the right infra-scapular region. Chest x-ray showed right lower lobe consolidation. The CD4 count was 55 cells/mm3. What is the most common causative organism for this condition? (Q856122)

A. Pneumocystis jirovecii

B. Streptococcus pneumonia

C. Staphylococcus aureus

D. Mycoplasma

See Answer in Part B → Q11

@Neet_pg_bot

Q12: A patient presents with fever, nocturnal cough, breathlessness, and wheezing for 4 weeks. The absolute eosinophil count is >5000/µL. Chest x-ray shows a miliary pattern. What is the likely diagnosis? (Q856099)

A. Bronchial asthma

B. Miliary tuberculosis

C. Tropical pulmonary eosinophilia

D. Hypersensitivity pneumonitis

See Answer in Part B → Q12

@Neet_pg_bot

Q13: The arterial blood gas analysis findings of a patient are as follows: pH=7.30, HCO3=10 mEq/L, paCO2= 30 mmHg, which is suggestive of a partially compensated metabolic acidosis. What is the mechanism for the secondary disorder? (Q855004)

A. Hypoventilation causing decreased CO2 washout

B. Hyperventilation causing decreased CO2 washout

C. Increased tubular reabsorption of HCO3-

D. Increased excretion of H+

See Answer in Part B → Q13

@Neet_pg_bot

Q14: Acid-base imbalance is suspected in a patient. Which of the following would you use to determine it? Arterial pH Venous pH Venous pO2 Venous pCO2 (Q856625)

A. 1,2

B. 1,2,3

C. 1,2,4

D. 1,2,3,4

See Answer in Part B → Q14

@Neet_pg_bot

Q15: Identify the pathology from the given flow-volume loop: (Q856623)

A. Fixed distal airway obstruction

B. Fixed central airway obstruction

C. Variable intrathoracic obstruction

D. Variable extra thoracic obstruction

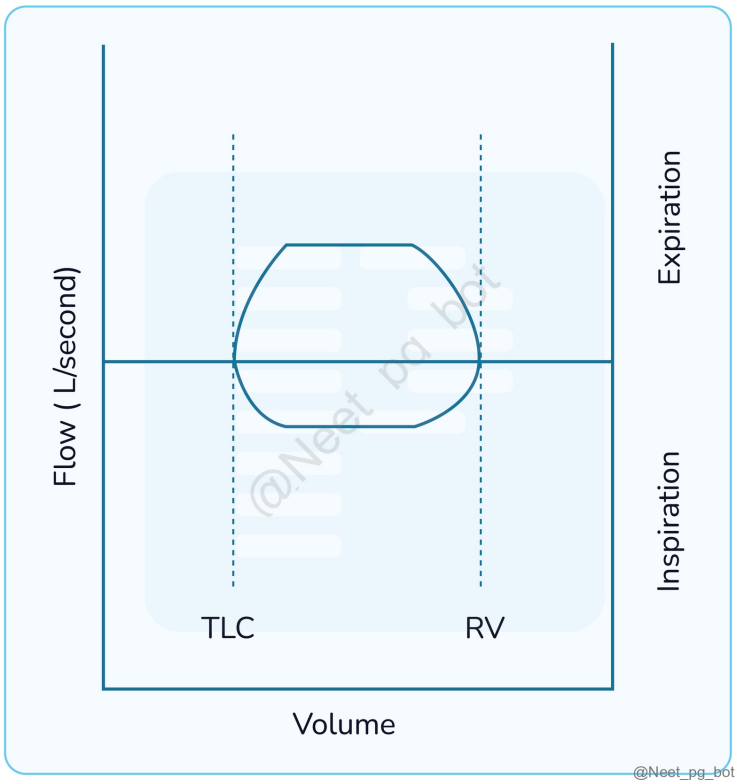

See Answer in Part B → Q15

@Neet_pg_bot

Q16: A 35-year-old female patient with class II pulmonary hypertension presents with a negative vasoreactive test. Which of the following is used in the next step of management? (Q856608)

A. Iloprost

B. Ambrisentan

C. Nifedipine

D. Epoprostenol

See Answer in Part B → Q16

@Neet_pg_bot

Q17: During the discharge of a COVID patient who was treated with steroids and remdesivir, which of the following will you inform him about? Repeat RT-PCR after 7 days of discharge Watch for the persistence of Anosmia Watch for headache and nasal discharge Monitor glucose levels Watch for Sinusitis like symptoms (Q856591)

A. 1, 3 and 4

B. 2, 3 and 4

C. 3, 4 and 5

D. 1,2,3,4 and 5

See Answer in Part B → Q17

@Neet_pg_bot

Q18: A patient came with hypoxemia and a normal alveolar-arterial oxygen gradient. What can be the cause? (Q855711)

A. Right-to-left shunt

B. Ventilation/perfusion mismatch

C. Hypoventilation

D. Alveolar membrane damage

See Answer in Part B → Q18

@Neet_pg_bot

Q19: A patient with a history of fever for the past 4 days and sudden onset of breathlessness was admitted to ICU as he was deteriorating. He was unresponsive to the incremental flow rate of oxygen and his oxygen saturation was progressively decreasing. A chest x-ray was ordered and the findings are shown in the image below. What is the most likely diagnosis? (Q857678)

A. Atelectasis

B. Mediastinitis

C. Pulmonary fibrosis

D. ARDS

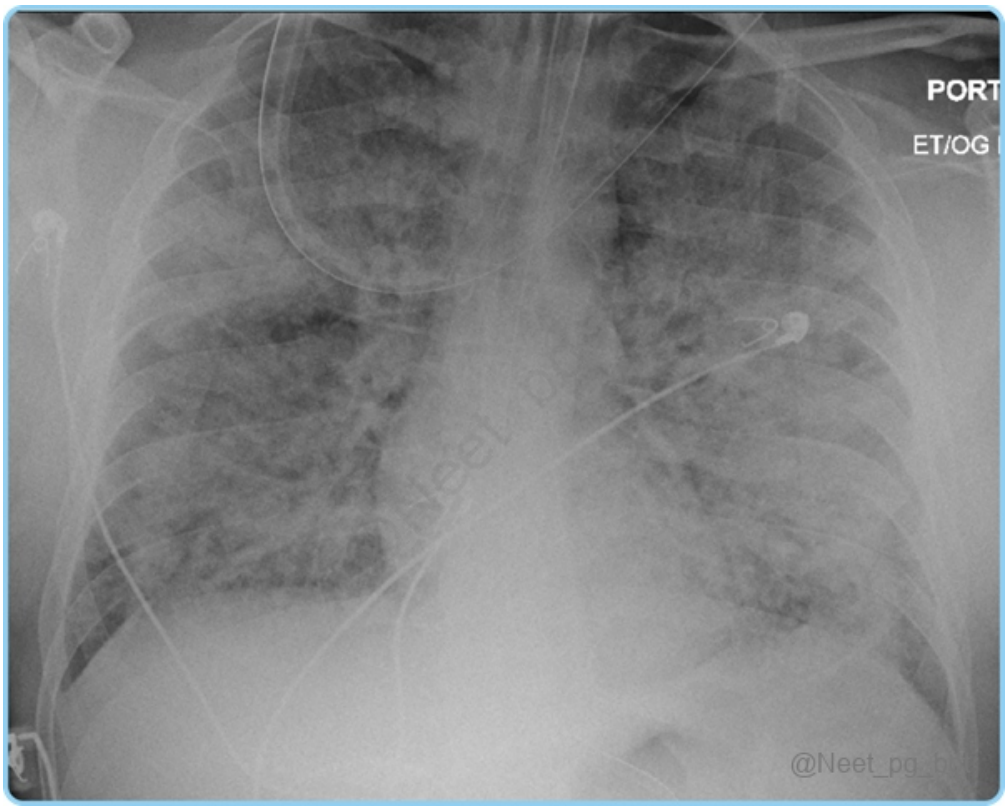

See Answer in Part B → Q19

@Neet_pg_bot

Q20: A 45-year-old female presents to the emergency department with the following arterial blood gas (ABG) results: pH 7.55, PaCO 2 40 mmHg, HCO 3 - 32 mEq/L. Which of the following conditions is most likely responsible for these findings? (Q857651)

A. Metabolic acidosis

B. Metabolic alkalosis

C. Respiratory acidosis

D. Respiratory alkalosis

See Answer in Part B → Q20

@Neet_pg_bot

Q21: Which of the following findings from a pleural fluid aspirate will suggest an exudative pleural effusion? Normal values Total S. Protein: 6-8 gm% S.LDH: 140-280 IU S. glucose: 140-200 (Q857644)

A. Pleural: Serum protein ratio > 0.5, pleural: Serum LDH ratio > 0.6 or pleural LDH > ■ of serum LDH

B. Pleural fluid protein = 4.5 gm% and glucose = 30 mg%

C. Pleural fluid LDH = 90IU and glucose = 30 mg%

D. Pleural fluid protein = 3.5gm% and glucose = 90 mg%

See Answer in Part B → Q21

@Neet_pg_bot

Q22: The following patient has presented after chest trauma. On examination, crepitus is felt. The clinical diagnosis is? (Q857053)

A. Subcutaneous emphysema

B. Gas gangrene

C. Acute tubular necrosis

D. SVC syndrome

See Answer in Part B → Q22

@Neet_pg_bot

Q23: Which of the following imaging tests should be performed to confirm a diagnosis of pulmonary embolism in a patient? (Q857034)

A. Doppler echocardiography

B. CT pulmonary angiography

C. Ventilation perfusion scan of lungs

D. MR pulmonary angiography

See Answer in Part B → Q23

@Neet_pg_bot

Q24: A male patient presents to the emergency department with the following arterial blood gas (ABG) values: pH: 7.2 pCO2: 81 mmHg HCO3: 40 mEq/L What is the most likely diagnosis? (Q856014)

A. Respiratory alkalosis

B. Metabolic acidosis

C. Respiratory acidosis

D. Metabolic alkalosis

See Answer in Part B → Q24

@Neet_pg_bot

Q25: A 48-year-old woman presents with progressive shortness of breath and a dry cough for the past 6 months. HRCT chest is given below. All of the following are true about this condition except: (Q879457)

A. End inspiratory coarse crackles are heard

B. Honeycombing with reticular markings is visible on HRCT

C. Both pneumococcal and influenza vaccines are advised for such patients

D. Rheumatoid arthritis is associated with this condition

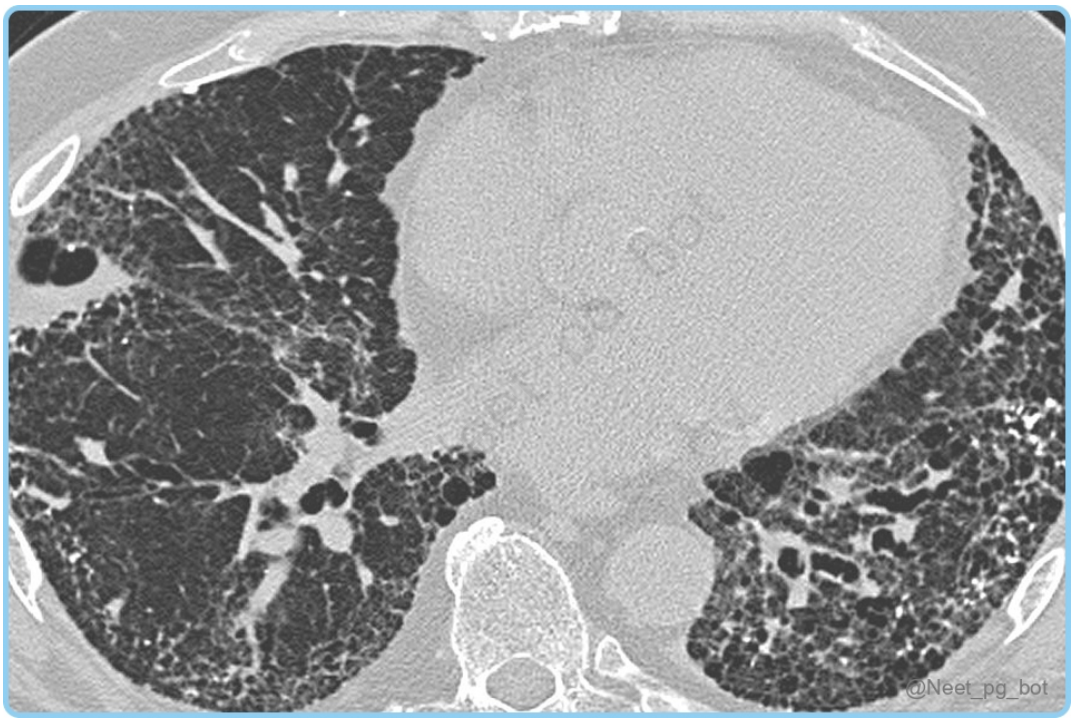

See Answer in Part B → Q25

@Neet_pg_bot

Q26: A 58-year-old woman with rheumatoid arthritis, treated with methotrexate for 4 months, develops worsening shortness of breath and a nonproductive cough. Physical examination reveals bilateral fine crackles at the lung bases. Chest CT demonstrates bilateral ground-glass opacities consistent with interstitial lung involvement. What is the most likely diagnosis? (Q879212)

A. Methotrexate-induced pneumonitis

B. Bacterial pneumonia

C. Congestive heart failure

D. Sarcoidosis

See Answer in Part B → Q26

@Neet_pg_bot

Q27: Which of the following risk factors is most likely to be associated with invasive pulmonary aspergillosis? (Q879209)

A. HIV patient with CD4+ count < 50

B. Febrile neutropenia

C. Patient on steroids

D. Diabetes mellitus

See Answer in Part B → Q27

@Neet_pg_bot

Q28: According to GOLD guidelines, what is the approximate cutoff value of FEV■ (% predicted) associated with clinically significant resting hypoxemia in chronic COPD patients? (Q879208)

A. 20%

B. 30%

C. 40%

D. 50%

See Answer in Part B → Q28

@Neet_pg_bot

Q29: According to GOLD COPD classification, which of the following is/are correct? Mild - FEV1/FVC < 0.7 and FEV1 >80% Moderate - FEV1/FVC < 0.7 and FEV1 >50 % but < 80% Severe - FEV1/FVC < 0.7 and FEV1 > 40% but < 50% Very severe - FEV1/FVC < 0.7 and FEV1 < 40% (Q879176)

A. 1

B. 1, 2

C. 1, 2, 3

D. 2, 3, 4

See Answer in Part B → Q29

@Neet_pg_bot

Q30: According to GOLD guidelines, which of the following are appropriate next steps in management of this acute COPD exacerbation in a smoker with RR 30/min, pulse 112/min, resting Sa02 87% room air and pCO2 60 mm Hg? a. Antibiotics b. Systemic corticosteroids c. Anti-virals d. Nebulized bronchodilators (Q879161)

A. a,c,d

B. a,b,d

C. b,c,d

D. a,b,c,d

See Answer in Part B → Q30

@Neet_pg_bot

Q31: A 50-year-old male patient undergoing treatment for lung cancer complains of difficulty in breathing and dizziness. Upon examination, diminished breath sounds are noted over the left inferior-scapular region. What is the most probable diagnosis? (Q830830)

A. Constrictive pericarditis

B. Pleural effusion

C. Cardiac tamponade

D. Pneumothorax

See Answer in Part B → Q31

@Neet_pg_bot

Q32: In bronchial asthma, what is the minimum percentage increase in the FEV1/FVC ratio that indicates a reversible obstruction following the administration of bronchodilators? (Q830825)

A. >12%

B. >20%

C. >10%

D. >18%

See Answer in Part B → Q32

@Neet_pg_bot

Q33: A male patient with infertility presents a disorder comprising the triad of situs inversus, chronic sinusitis, and bronchiectasis. Which of the following is the correct diagnosis? (Q860392)

A. Kartagener's syndrome

B. Cystic fibrosis

C. Mucovicidosis

D. Klinefelter syndrome

See Answer in Part B → Q33

@Neet_pg_bot

Q34: A 55-year-old man presents with altered sensorium and deep labored breathing. ABG is given below. What is the most likely acid-base disorder? pH: 7.20 pCO■: 31 mmHg HCO■■:16 mEq/L Na■: 130 mEq/L Cl■: 84 mEq/L PaO■: 80 mmHg (Q866496)

A. Metabolic acidosis

B. Metabolic alkalosis

C. Respiratory acidosis

D. Respiratory alkalosis

See Answer in Part B → Q34

@Neet_pg_bot

Q35: Multidrug-resistant (MDR) tuberculosis shows resistance to which of the following drugs? (Q856022)

A. Isoniazid, rifampicin, and fluoroquinolone

B. Fluoroquinolones

C. Isoniazid and rifampicin

D. Isoniazid, rifampicin, and kanamycin

See Answer in Part B → Q35

@Neet_pg_bot

Q36: A patient was admitted to the ICU 48 hours after an accident in which he sustained a fracture of the femur. The oxygen saturation in the rebreathing unit was 100% but his SpO2 remained at 60%. The patient is in a state of confusion. Diffuse petechiae are noted on examination. Chest radiograph showed lung fields to be clear. What is the most likely diagnosis? (Q857033)

A. Pulmonary embolism

B. Fat embolism

C. ARDS

D. Occult pneumothorax

See Answer in Part B → Q36

@Neet_pg_bot

Q37: A 35-year-old female patient presents with fever, breathlessness, and cough with expectoration. A CT scan was done, which is shown below. What is the most likely diagnosis? (Q855908)

A. Consolidation with air bronchogram

B. Mediastinal mass

C. Pleural effusion

D. Diaphragmatic hernia



See Answer in Part B → Q37

@Neet_pg_bot

Q38: A patient presents with fever, night sweats, ptosis, and bilateral facial nerve palsy. Investigations show leukocytosis and bilateral hilar lymphadenopathy. Which of the following is the most likely diagnosis? (Q855905)

A. Sarcoidosis

B. Tuberculosis

C. Lymphoma

D. Hypersensitive pneumonitis

See Answer in Part B → Q38

@Neet_pg_bot

Q39: A 45-year patient working in a factory for the past 20 years presents with breathlessness. HRCT chest shows pleural thickening and fibrosis. Diagnosis is? (Q859808)

A. Asbestosis

B. Coal worker pneumoconiosis

C. Silicosis

D. Berylliosis

See Answer in Part B → Q39

@Neet_pg_bot

Q40: The flow-volume curve of a patient after spirometry is given below. The most likely diagnosis in this patient is: (Q859564)

A. Asbestosis

B. COPD

C. Myasthenia gravis

D. Vocal cord paralysis

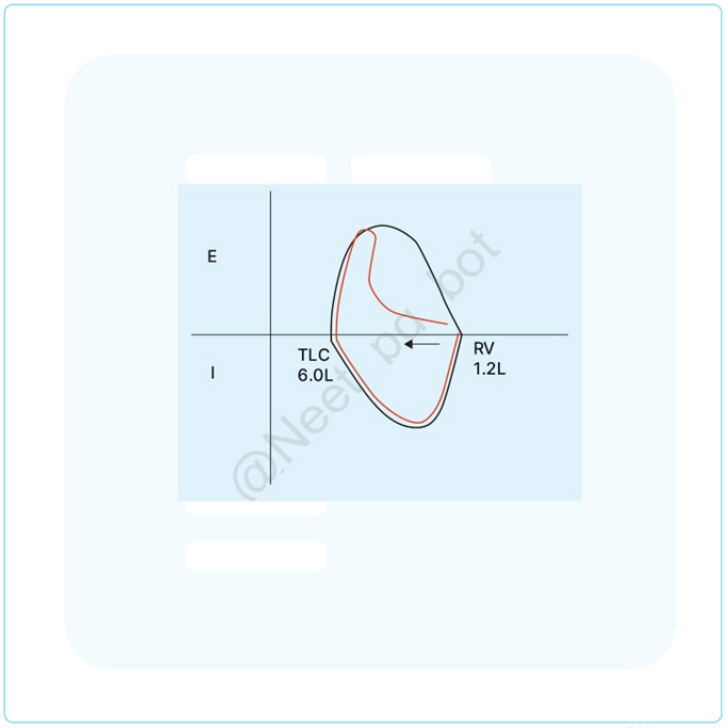

@Neet_pg_bot

See Answer in Part B → Q40

@Neet_pg_bot

Q41: A 46-year-old chronic alcoholic male presents to the OPD with fever, headache, shortness of breath, chest pain, and productive cough with red currant jelly sputum for the last two days. On examination, there was bronchial breathing on the right side, increased vocal fremitus, increased vocal resonance, and a dull note on percussion. The patient's radiograph is shown below. Which is the most likely causative agent? (Q859561)

A. Streptococcus pneumoniae

B. Klebsiella pneumoniae

C. Pseudomonas aeruginosa

D. Haemophilus influenza

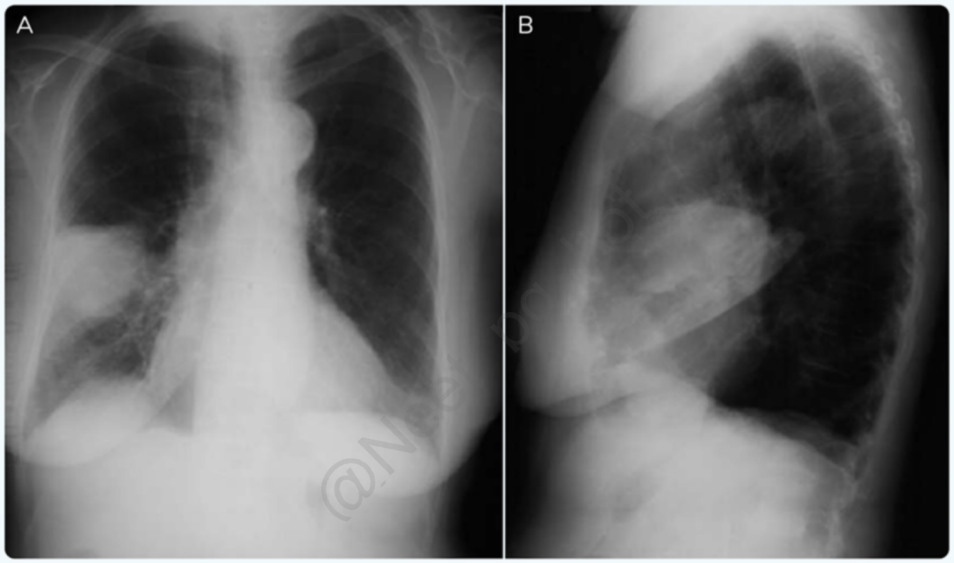

@Neet_pg_bot

See Answer in Part B → Q41

@Neet_pg_bot

Q42: Identify the condition in the following X-ray. (Q859538)

A. Hydropneumothorax

B. Pleural effusion

C. Pericardial effusion

D. Pneumothorax

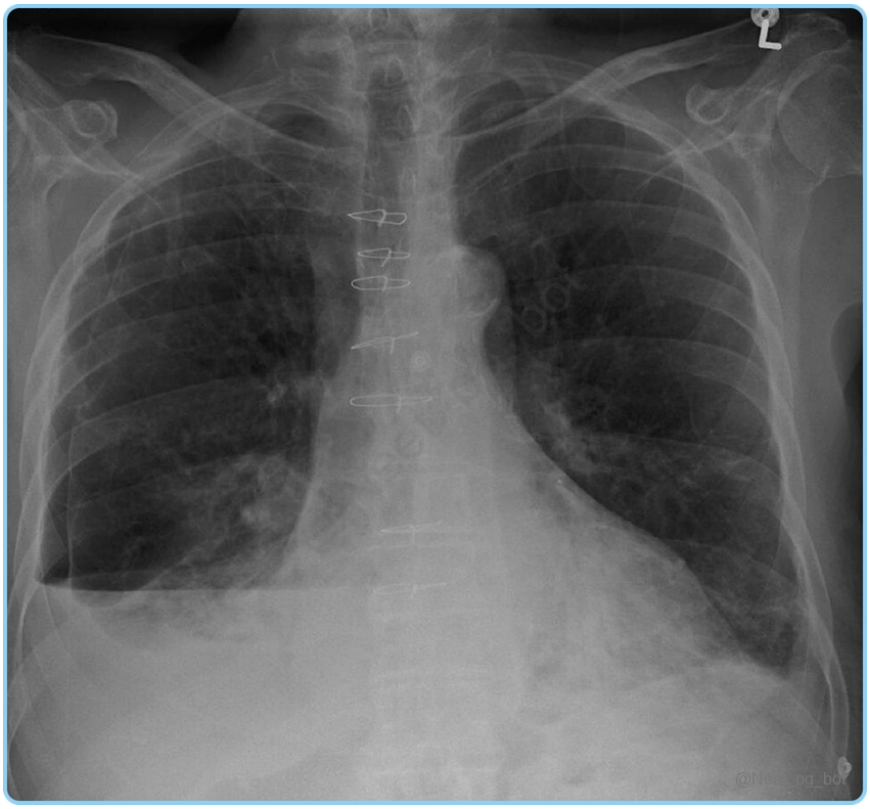

See Answer in Part B → Q42

@Neet_pg_bot

Q43: A 55-year-old patient presented with chronic projectile vomiting and weight loss. What is the expected metabolic abnormality to be seen here? (Q859530)

A. Hypokalemic hypochloremic metabolic alkalosis with hyponatremia

B. Hypokalemic hypochloremic metabolic alkalosis with hypernatremia

C. Hypokalemic hypochloremic metabolic alkalosis with hypercalcemia

D. Hypokalemic hypochloremic metabolic acidosis with hyponatremia

See Answer in Part B → Q43

@Neet_pg_bot

Q44: A 55-year-old male presented with tachypnea and mental confusion. His blood sugar is 350mg/dl, pH-7.2, HCO3-10, pCO2-30. What is the metabolic abnormality? (Q858450)

A. Metabolic alkalosis

B. Metabolic acidosis

C. Respiratory alkalosis

D. Respiratory acidosis

See Answer in Part B → Q44

@Neet_pg_bot

Q45: A 20-year-old man presents to the emergency department with respiratory distress and hypotension following a trauma. He has subcutaneous emphysema, and there is an absence of air entry into the right side of the lungs. What is the next best step? (Q858434)

A. Start IV fluids with a large bore cannula

B. Needle decompression into the 5 th intercostal space anterior to the midaxillary line

C. Take the patient to the ICU and intubate him

D. Start positive pressure ventilation

See Answer in Part B → Q45

@Neet_pg_bot

Q46: A 53-year-old woman underwent hip replacement surgery. A week after the surgery, the patient developed swelling of the legs associated with pain on palpation. Her heart rate is 70 beats per min. There is no history of hemoptysis or significant weight loss. There is no previous history of pulmonary embolism. What is the risk of developing pulmonary embolism in the patient based on Well's score? (Q855016)

A. Low

B. High

C. Moderate

D. Cannot comment without d-dimer values

See Answer in Part B → Q46

@Neet_pg_bot

Q47: Patient presents with recurrent lung infections and CXR is given below. What is the most likely diagnosis? (Q844230)

A. Kartagener syndrome

B. Cystic fibrosis

C. Digeorge syndrome

D. Down syndrome

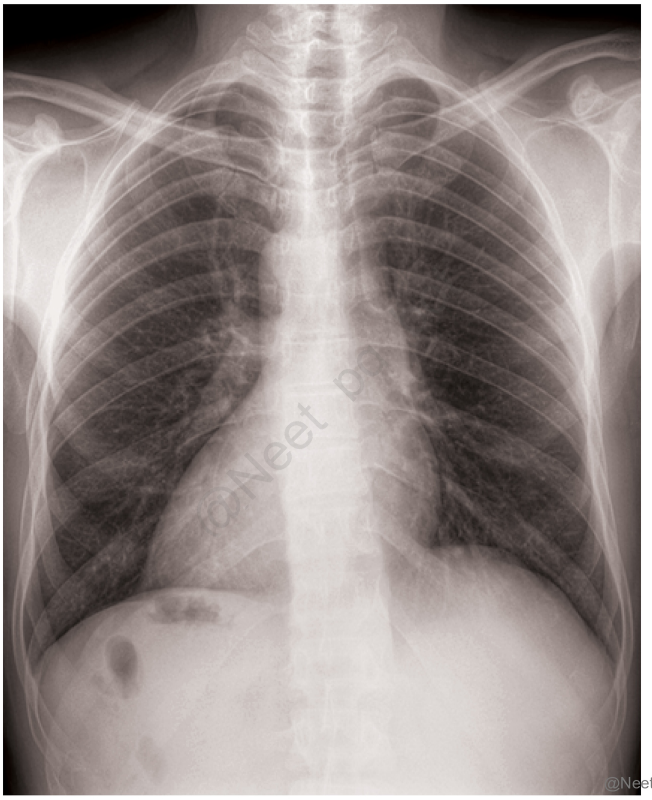

See Answer in Part B → Q47

@Neet_pg_bot

Q48: A 33-year-old woman is being evaluated for daytime sleepiness and memory loss which have been present for the past 1 year. Her BMI is 43, her BP is 170/98 mmHg. In an awake state, ABG shows pO2 70 mmHg, pCO2 53 mmHg, HCO3 33 mmol/L. What is the most likely diagnosis? (Q820347)

A. Obesity Hypoventilation Syndrome

B. Central Sleep Apnea

C. Narcolepsy

D. Obstructive sleep Apnea

See Answer in Part B → Q48

@Neet_pg_bot

Q49: A 40-year-old man presents with daytime sleepiness and impaired concentration and memory. On examination his BMI is 41 kg/m2, BP is 160/100 mm Hg. His awake ABG analysis is given: PaO 2 = 66mm Hg PaCO 2 = 50 mm Hg HCO 3 = 28 mEq/L What is the most likely diagnosis? (Q857285)

A. Obstructive sleep apnea

B. Narcolepsy

C. Obesity hypo-ventilation syndrome

D. Central sleep apnea

See Answer in Part B → Q49

@Neet_pg_bot

Q50: Match the following medical conditions with their corresponding descriptions: A Caplan syndrome 1 Initially observed in coal workers B Asbestosis 2 Presents with a characteristic "crazy pavement" appearance C Mesothelioma 3 Affects the pleura D

Sarcoidosis 4 Exhibits the presence of pleural effusion (Q857279)

A. A-1, B-4, C-3, D-2

B. A-4, B-2, C-3, D-1

C. A-3, B-4, C-2, D-1

D. A-2, B-4, C-3, D-1

See Answer in Part B → Q50

@Neet_pg_bot

Q51: Which membrane channel is mainly affected in Cystic fibrosis? (Q857260)

A. Sodium

B. Chloride

C. Calcium

D. Potassium

See Answer in Part B → Q51

@Neet_pg_bot

Q52: A 45-year-old woman with obstructive lung disease is currently using salmeterol and tiotropium but continues to experience breathlessness and frequent exacerbations. Given her current situation, which of the following treatments would be most appropriate? (Q860154)

A. Nebulization with LAMA-LABA

B. Long-Term Oxygen Therapy (LTOT)

C. Positive Pressure Ventilation (PPV)

D. Pneumococcal Vaccine

See Answer in Part B → Q52

@Neet_pg_bot

Q53: A 60-year-old man with chronic cough and weight loss presents with increasing breathlessness. Chest X-ray shown below. Which of the following is the most likely cause ? (Q860464)

A. Right-sided pneumothorax

B. Right lung consolidation

C. Right lung collapse

D. Massive pleural effusion due to pulmonary malignancy

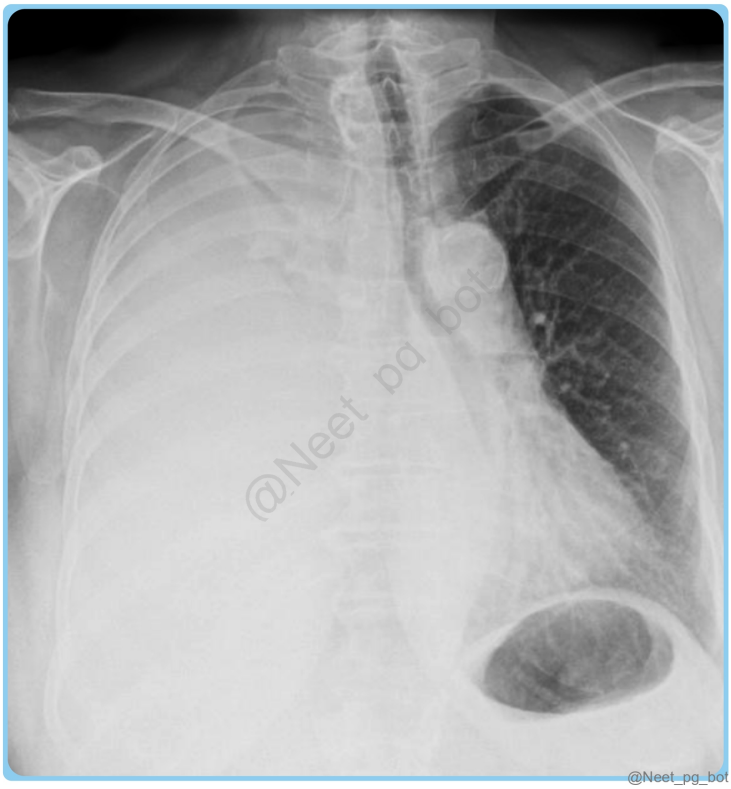

See Answer in Part B → Q53

@Neet_pg_bot

Q54: Which of the following conditions will have an FEV■/FVC ratio < 0.7 and FEV■ < 80% of the predicted value along with wheezing in the morning hours and shortness

of breath? (Q860397)

A. Asthma

B. Interstitial Lung Disease

C. Idiopathic Pulmonary Fibrosis

D. Silicosis

See Answer in Part B → Q54

@Neet_pg_bot

Q55: Criterion that differentiates exudative from transudative pleural effusion? (Q860390)

A. Low protein in pleural fluid

B. High protein in pleural fluid

C. Low sugar in pleural fluid

D. High sugar in pleural fluid

See Answer in Part B → Q55

@Neet_pg_bot

Q56: Most common cause of death in idiopathic pulmonary fibrosis? (Q844287)

A. Respiratory failure

B. Pulmonary edema

C. Cancer

D. PAH

See Answer in Part B → Q56

@Neet_pg_bot

Q57: A patient presents with acute epigastric pain and an increase in serum lipase levels. Three days after stabilization, a chest X-ray is obtained. What is the most common pathology behind the chest X-ray findings? (Q844274)

A. Increased PCWP

B. Pulmonary thromboembolism

C. Non cardiogenic pulmonary edema

D. Aspiration pneumonitis

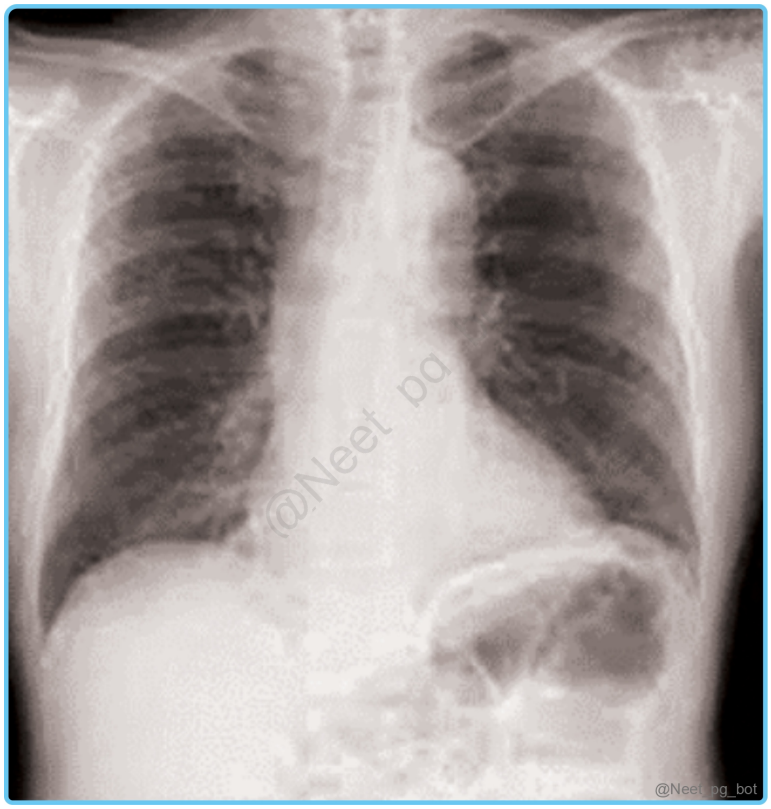

See Answer in Part B → Q57

@Neet_pg_bot

Q58: What is the expected finding in a patient with the following CXR? (Q844270)

A. Kussmaul breathing

B. Paradoxical breathing

C. Apneustic breathing

D. Bronchial breathing

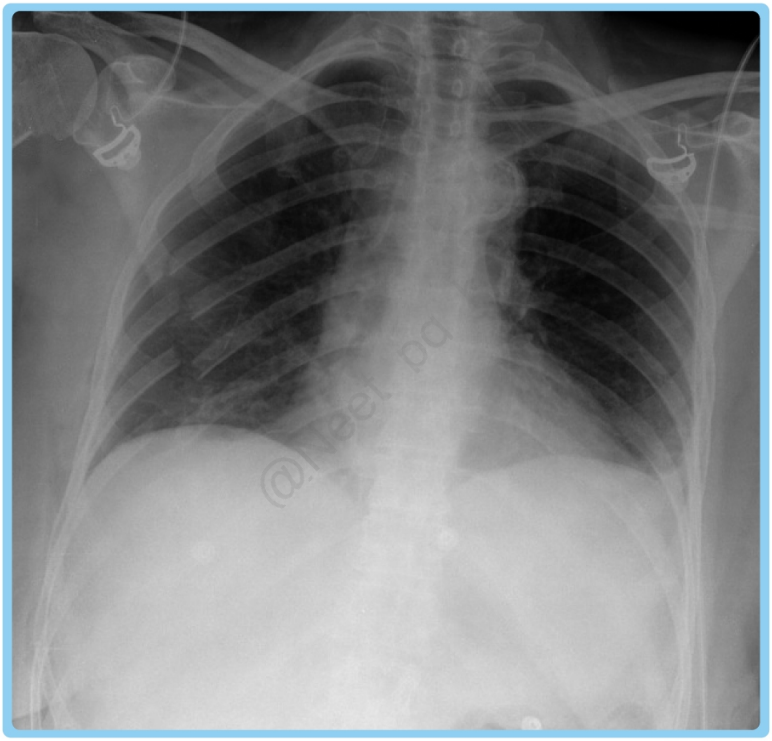

See Answer in Part B → Q58

@Neet_pg_bot

Q59: A 60-year-old bedridden patient develops sudden onset breathlessness and chest pain . CTPA was done. Which of the following non-invasive investigations will be useful to confirm the etiology of this presentation? (Q820451)

A. D dimer

B. MRI

C. Coagulogram

D. Doppler

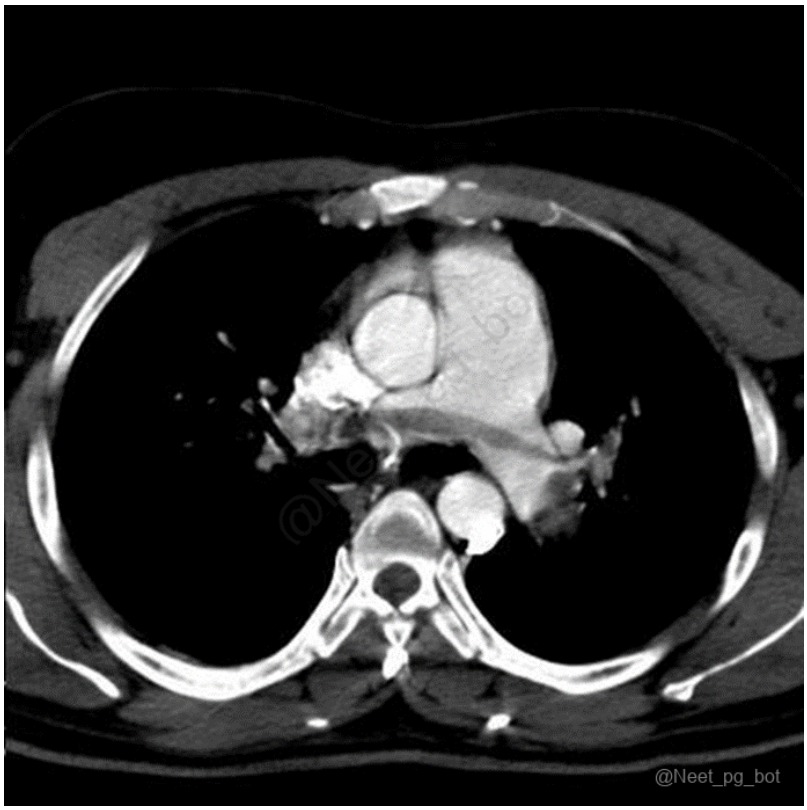

See Answer in Part B → Q59

@Neet_pg_bot

Q60: A patient presents with wheezing that improves with as-needed use of albuterol. Spirometry shows FEV1 ranging from 70% to 83%, and the patient experiences nighttime chest tightening twice a week. What is the most appropriate treatment? (Q844179)

A. Continue with albuterol

B. Replace with salmeterol twice daily

C. Start Tab prednisolone

D. Add an inhaled corticosteroid

See Answer in Part B → Q60

@Neet_pg_bot

Q61: A 62-year-old woman with a history of chronic obstructive pulmonary disease (COPD) presents with increased breathlessness, cough, and sputum production over the last two days. She appears distressed and has a respiratory rate of 28 breaths per minute. Her oxygen saturation is 88% on room air. Which of the following management strategies is most appropriate for her immediate treatment? (Q852751)

A. Initiate high-flow oxygen therapy to maintain oxygen saturation above 95%

B. Start nebulised bronchodilator therapy with salbutamol and ipratropium

C. Begin intravenous glucocorticoids immediately

D. Order a chest X-ray before any treatment is provided

See Answer in Part B → Q61

@Neet_pg_bot

Q62: A patient with a history of pneumonia develops pleural effusion. What is the expected finding in the pleural analysis for parapneumonic effusion? (Q852740)

A. Pleural protein/plasma protein ratio less than 0.5

B. Pleural LDH less than 2/3rd of plasma LDH

C. Pleural pH less than 7.2

D. Pleural LDH less than 0.6 of plasma LDH

See Answer in Part B → Q62

@Neet_pg_bot

Q63: A 46-year-old diabetic patient presented with fever, malaise, and a productive cough. His chest X-ray is given below. Which of the following statements is incorrect? {{caption_text}} (Q853358)

A. Patchy infiltrates as seen in pyogenic pneumonia

B. Interstitial infiltrates as seen in Mycoplasma pneumonia

C. Hilar lymphadenopathy with infiltrates as seen in malignancy

D. Aspiration pneumonia is more common in the upper segment of the lower lobe and posterior segment of the upper lobe

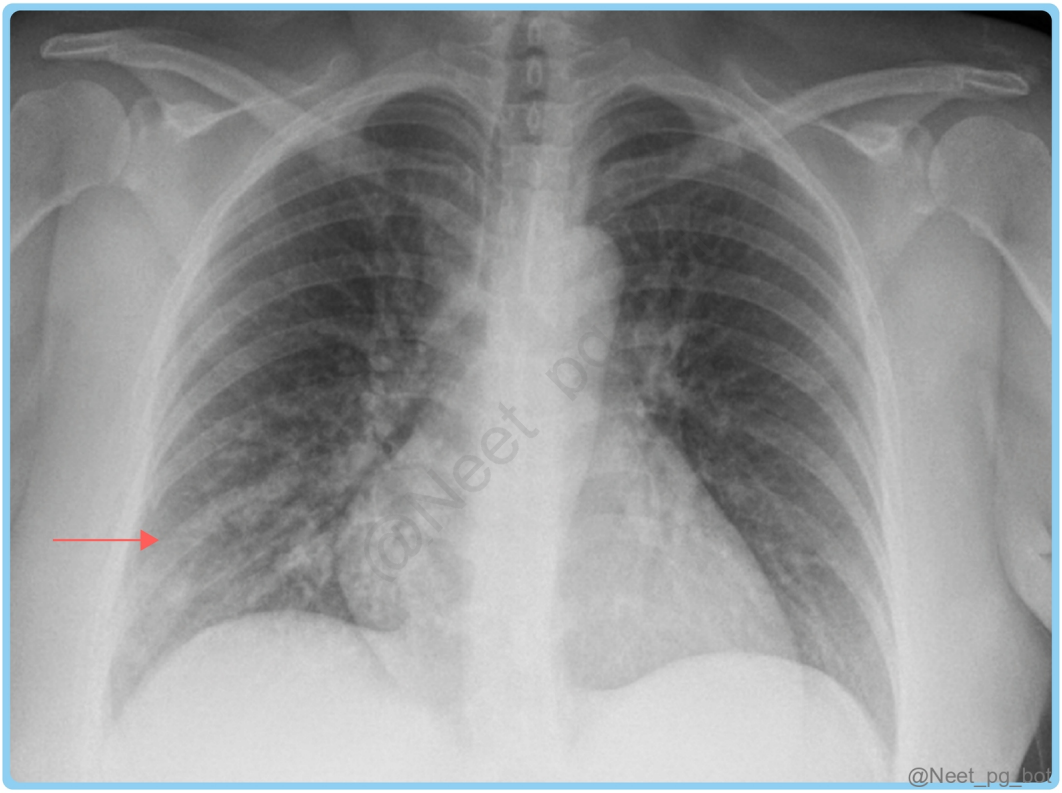

See Answer in Part B → Q63

@Neet_pg_bot

Q64: Old man underwent joint replacement surgery 3 days ago. Today he develops SOB with chest pain. O/E : pulse 100/min, BP 100/70 mm Hg, RR28/min and sp02: 85% room air. D-dimer is elevated. Which is the next best test (Q866499)

A. V/Q scan

B. ECG

C. CXR

D. CTPA

See Answer in Part B → Q64

@Neet_pg_bot

Q65: A patient with COVID-19 pneumonia is admitted with severe respiratory distress and their PaO■/FiO■ is < 100. What is the most appropriate ventilatory strategy in this case? (Q866498)

A. Low PEEP, high tidal volume

B. High PEEP, low tidal volume

C. Low tidal volume, low PEEP

D. High tidal volume, high PEEP

See Answer in Part B → Q65

@Neet_pg_bot

Q66: A 45-year-old chronic smoker presents with complaints of dyspnea. Pulmonary function tests reveal an FEV1/FVC ratio of 65% and an RV/TLC ratio of 141%. Which of the following best describes the underlying pathophysiology? (Q865365)

A. Air trapping with hyperinflation of lungs

B. Decreased lung compliance

C. Restrictive lung disease

D. Increased lung compliance

See Answer in Part B → Q66

@Neet_pg_bot

Q67: A patient presents with progressive shortness of breath for the last 6 months, accompanied by dry cough. Auscultation reveals bilateral basal end-inspiratory crepitations. There is no history of fever, joint pain, or occupational exposure. What is the diagnosis? (Q866819)

A. Cor-pulmonale

B. Sarcoidosis

C. IPF

D. Hypersensitivity pneumonitis

See Answer in Part B → Q67

@Neet_pg_bot

Q68: A patient presents with SOB and fatigue. CXR was done. What is the diagnosis? (Q866818)

A. TB

B. Asbestosis

C. Silicosis

D. Byssinosis



See Answer in Part B → Q68

@Neet_pg_bot

Q69: A patient is in ICU and there is a failed attempt of subclavian catheterization. Shortly after, BP drops and the pulse rises. What is the diagnosis? (Q866813)

A. Pneumothorax

B. Displacement of endotracheal tube (ET)

C. Air embolism

D. Dislodgement of ET

See Answer in Part B → Q69

@Neet_pg_bot

Q70: A 45-year-old patient with a history of smoking a pack of cigarettes for the past 15 years presents with hemoptysis. Chest X-ray shows a 3cm upper lobe mass near the apex of the lung. What is the next best step for managing this patient? (Q858025)

A. Bronchoscopy

B. CT-guided biopsy

C. Sputum cytology

D. Sputum for AFB

See Answer in Part B → Q70

@Neet_pg_bot

Q71: Which of the following does not cause central cyanosis? (Q855700)

A. Methemoglobinemia

B. Pulmonary arteriovenous fistula

C. High altitude

D. Hypothermia

See Answer in Part B → Q71

@Neet_pg_bot

Q72: A chronic cigarette smoker has now joined a construction company. His pulmonary function test results are given below. What is the most likely diagnosis for this patient? Initial lung volumes were: FEV1-0.9L FVC-1.9L FEV1/FVC-0.4 After bronchodilation: FEV1-1.9L FVC-3.9L FEV1/FVC-0.4 (Q855598)

A. Vascular disease with bronchodilator reversibility

B. Restrictive lung disease with bronchodilator reversibility

C. Restrictive lung disease without bronchodilator reversibility

D. Obstructive disease with bronchodilator reversibility

See Answer in Part B → Q72

@Neet_pg_bot

Q73: A 65-year-old female patient weighing 60 kg is on mechanical ventilation for ARDS secondary to urosepsis. The respiratory parameters are as follows: tidal volume – 360 mL; frequency – 30 breaths/min; PEEP - 5 cm of H2O; and FiO2-90%. The arterial blood gas findings are as follows; paO2-50 mmHg; paCO2-38 mmHg; and pH-7.38. What is the next step? (Q855351)

A. Reduce FiO2

B. Increase tidal volume

C. Increase respiratory rate

D. Increase PEEP

See Answer in Part B → Q73

@Neet_pg_bot

Q74: A 72-year-old man presented with weight loss, decreased appetite, and iron deficiency anemia. Chest x-ray was done and given below. What is the diagnosis? (Q856976)

A. Lung metastasis

B. Bronchogenic carcinoma

C. Miliary tuberculosis

D. Mesothelioma



See Answer in Part B → Q74

@Neet_pg_bot

Q75: A 55 year old shipbuilding worker presents with dyspnea. He has been working in this industry for the past 25 years. Which is the most specific malignancy that we can expect in this patient? (Q856984)

A. Bronchogenic carcinoma

B. Malignant mesothelioma

C. Small cell carcinoma of lung

D. Squamous cell carcinoma of lung

See Answer in Part B → Q75

@Neet_pg_bot

Q76: A 60-year-old male patient comes to your clinic with an 8-month history of shortness of breath and non-productive cough. He has smoked half a pack of cigarettes for the past 30 years. On physical examination, clubbing is seen and fine crackles are heard on both sides during inspiration. You perform pulmonary function tests and it shows an FEV1/FVC ratio of 92%. The CT scan of the chest is shown below. What is the most probable diagnosis? (Q856989)

A. Bronchial asthma

B. Pulmonary fibrosis

C. Pulmonary tuberculosis

D. Chronic obstructive pulmonary disease

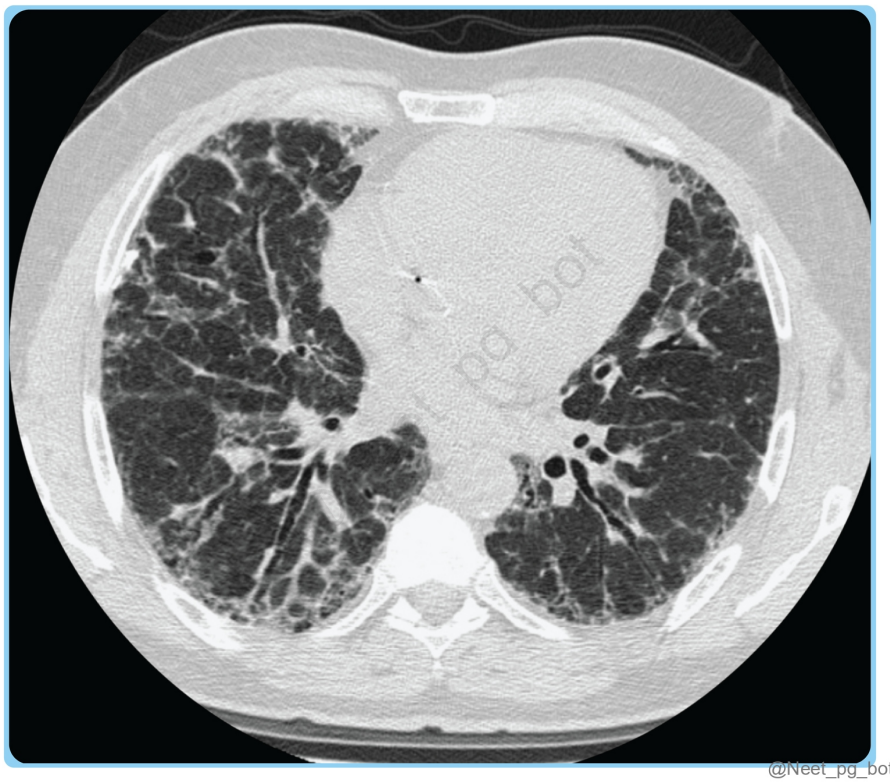

See Answer in Part B → Q76

@Neet_pg_bot

Q77: On examination, a person has distended neck veins, absent breath sounds, hyperresonance, and a shift of the trachea. What is the management? (Q866805)

A. Bedside CXR in casualty followed by chest tube insertion

B. Wide bore needle in 2 nd ICS

C. Pericardiocentesis

D. Pleurodesis with doxycycline

See Answer in Part B → Q77

@Neet_pg_bot

Q78: A 5-year-old child presented with recurrent respiratory infections with thickened sputum. Chest X-ray showed bronchial wall thickening. He has been suffering from steatorrhea since birth. Which of the following is the first differential diagnosis? (Q858033)

A. Hyaline membrane disease

B. Cystic fibrosis

C. Alpha 1 anti-trypsin deficiency

D. Malabsorption syndrome

See Answer in Part B → Q78

@Neet_pg_bot

Q79: Which of the following is a cause of exudative pleural effusion? (Q858016)

A. Heart failure

B. Rheumatic arthritis

C. Dressler syndrome

D. Nephrotic syndrome

See Answer in Part B → Q79

@Neet_pg_bot

Q80: In which medical condition is a ground-glass appearance observed on high-resolution computed tomography (HRCT)? (Q858009)

A. Asbestosis

B. Silicosis

C. Anthracosis

D. Bagassosis

See Answer in Part B → Q80

@Neet_pg_bot

Q81: A 65-year-old chronic smoker came to the medicine outpatient department with complaints of upper chest discomfort and drooping of an eyelid. He also complained of pain radiating to the upper arm and a tingling sensation in the 4th and 5th digits of his right hand. The chest X-ray is given below. Which of the following is the most likely diagnosis? (Q855501)

A. Pancoast tumor

B. Superior vena cava obstruction

C. Upper lobe pneumonia

D. Aspergilloma



See Answer in Part B → Q81

@Neet_pg_bot

Q82: Comment on the lung disease? (Q854721)

A. Hypersensitivity pneumonitis

B. Sarcoidosis

C. Acute respiratory distress syndrome

D. Bronchiectasis

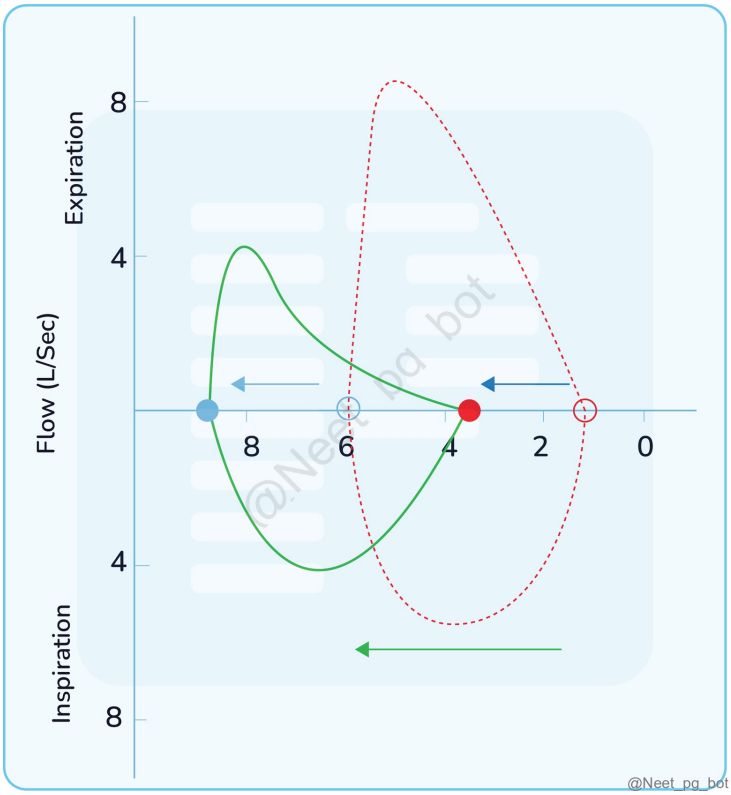

See Answer in Part B → Q82

@Neet_pg_bot

Q83: A male patient who is a known case of COPD presents to the emergency department with dyspnea. The arterial blood gas report is as follows: pH: 7.28 pCO 2 : 60 mmHg HCO 3 : 28 meq/L Which of the following is the most likely diagnosis? (Q854712)

A. Inadequately compensated respiratory acidosis

B. Fully compensated respiratory acidosis

C. Fully compensated respiratory alkalosis

D. Inadequately compensated metabolic alkalosis

See Answer in Part B → Q83

@Neet_pg_bot

Q84: A 70-year-old diabetic man presents after a fall. He is having a high fever, cough and breathing difficulty and appears confused. CXR shows lobar consolidation. Labs show elevated BUN and creatinine. Which is the most appropriate management? (Q854678)

A. Inpatient management with levofloxacin

B. Inpatient management with ceftriaxone

C. Discharge home on Amoxicillin with Clavulanic acid

D. Discharge home on Azithromycin

See Answer in Part B → Q84

@Neet_pg_bot

Q85: A 30-year-old man came with complaints of fever and cough for 3 days. On examination, creatinine is 1.5 and BUN is 45. Chest-x ray shows infiltrates in the right lung and patchy infiltrates in the left lung. A nasopharyngeal swab shows only Rhinovirus. The patient is shifted to the ICU. Which antibiotics are suitable for this patient? (Q854657)

A. Amoxicillin + Clavulanic acid

B. Azithromycin

C. Ceftriaxone + Azithromycin

D. Piptaz + Ciprofloxacin

See Answer in Part B → Q85

@Neet_pg_bot

Q86: In patients affected by COVID-19, which of the following patterns is frequently observed in chest CT scans? (Q856993)

A. Interlobular septal thickening

B. Air bronchograms

C. Ground glass opacity

D. Crazy paving pattern

See Answer in Part B → Q86

@Neet_pg_bot

Q87: A male patient with a history of chronic smoking presents with the complaint of dysphagia . Out of the following, which type of lung cancer is most likely to be found in this patient? (Q793827)

A. Squamous cell carcinoma

B. Adenocarcinoma

C. Large cell carcinoma

D. Bronchogenic carcinoma

See Answer in Part B → Q87

@Neet_pg_bot

Q88: What is the diagnosis based on the image given below ? (Q793956)

A. Pulmonary tuberculosis

B. Chronic obstructive pulmonary disease

C. Bronchial asthma

D. Bronchiectasis



See Answer in Part B → Q88

@Neet_pg_bot

Q89: A young man presents with a sudden onset of severe headache, dizziness, breathlessness, and blurring of vision while trekking on a mountain at an altitude of 5000 meters . He is unable to climb any further. Which of the following develops at high-altitude? (Q793881)

A. Metabolic alkalosis

B. Respiratory alkalosis

C. Respiratory acidosis

D. Metabolic acidosis

See Answer in Part B → Q89

@Neet_pg_bot

Q90: A patient presents with chronic complaints of a productive cough in the morning . The expectoration is yellow, foul smelling and increases on turning from left to right side. Which of the following lung diseases is likely to be present ? (Q793834)

A. Lung cancer

B. Bronchiectasis

C. Bronchial asthma

D. Pulmonary embolism

See Answer in Part B → Q90

@Neet_pg_bot

Q91: Kartagener syndrome is associated with defects in which of the following structures? (Q820676)

A. Microvilli

B. Microtubules

C. Cilia

D. Microfilaments

See Answer in Part B → Q91

@Neet_pg_bot

• [11_Infections] 085 Puo Dengue Nipah Zika And Pneumocystis Jirovecii

« Back to Folder Directory

[11_Infections] 085 Puo Dengue Nipah Zika And Pneumocystis Jirovecii — Quick Jump

Q1 (p. 1028) *Q2 (p. 1028)* *Q3 (p. 1029)* *Q4 (p. 1029)* *Q5 (p. 1029)* *Q6 (p. 1030)*
Q7 (p. 1030) *Q8 (p. 1031)* *Q9 (p. 1031)* *Q10 (p. 1031)* *Q11 (p. 1032)* *Q12 (p. 1032)*
Q13 (p. 1033) *Q14 (p. 1033)* *Q15 (p. 1033)*

Q1: Relative bradycardia is seen in which of the following infections? (Q850949)

A. Brucellosis

B. Influenza

C. Streptococcal Pharyngitis

D. Tuberculosis

See Answer in Part B → Q1

@Neet_pg_bot

Q2: A 28-year-old male presents with a history of fever, malaise, and abdominal discomfort for last one week. Physical examination reveals coated tongue, relative bradycardia and a hepatomegaly. NS-1 antigen is negative. What is the most likely fever pattern seen in this case? (Q850950)

A. Intermittent fever

B. Remittent fever

C. Saddle back fever

D. Sustained fever

See Answer in Part B → Q2

@Neet_pg_bot

Q3: Quotidian fever is seen with which of the following species of Plasmodium? (Q850951)

A. Falciparum

B. Malariae

C. Ovale

D. Vivax

See Answer in Part B → Q3

@Neet_pg_bot

Q4: A 55-year-old male presents with a fever of 38.5°C (101.3°F) that has persisted for three weeks. He reports significant weight loss, night sweats, and fatigue. His medical history is unremarkable. On physical examination, he has splenomegaly and cervical lymphadenopathy. Which investigation would be the most appropriate next step in this patient's management? (Q850952)

A. Chest X-ray

B. Blood culture

C. CT scan of the abdomen and pelvis

D. HIV test

See Answer in Part B → Q4

@Neet_pg_bot

Q5: Which of the following is not considered an autoinflammatory syndrome? (Q850953)

A. Familial Mediterranean fever

B. Adult-onset Still's disease

C. Rheumatoid arthritis

D. Cryopyrin-associated periodic syndromes

See Answer in Part B → Q5

@Neet_pg_bot

Q6: A 30-year-old female presents with a fever of 39°C that has persisted for the past five days. She reports severe muscle pain, nausea, and retroorbital pain. On examination, she has mild dehydration and a negative tourniquet test. Which of the following investigations would be most appropriate to confirm the diagnosis? (Q850954)

A. Hematocrit

B. NS-1 Antigen test

C. MAC ELISA for Dengue virus antibody

D. Platelet count

See Answer in Part B → Q6

@Neet_pg_bot

Q7: What is the most common neurological complication during the course of dengue fever illness? (Q850955)

A. Encephalopathy

B. Guillain-Barré Syndrome

C. Stroke

D. Encephalitis

See Answer in Part B → Q7

@Neet_pg_bot

Q8: A 30-year-old farmer presents with high-grade fever, retro-orbital pain, and severe calf muscle tenderness for the past 3 days. What is the most likely diagnosis? (Q850956)

A. Dengue fever

B. Leptospirosis

C. Zika virus

D. Typhoid / Enteric fever

See Answer in Part B → Q8

@Neet_pg_bot

Q9: Following a sudden outbreak of mystery fever in a South Indian village, several individuals from the same locality developed fever, headache, altered sensorium, and seizures. Which of the following is not true regarding this likely condition? (Q850957)

A. The disease has been linked to Pteropus species as natural reservoirs

B. The condition often presents as rapidly progressive viral encephalitis

C. Case fatality rate below 10%

D. Human-to-human transmission has been documented in prior outbreaks

See Answer in Part B → Q9

@Neet_pg_bot

Q10: A 28-year-old woman presents with fever, conjunctivitis, and a maculopapular rash after returning from a trip to Central America. Local health authorities comfirm antibodies to Zika virus infection. Which of the following is correct about this infection? (Q850958)

A. Transmitted only through infected bodily fluids.

B. Incubation period is 4 weeks

C. Complications include microcephaly and Guillain–Barré syndrome.

D. Reliable diagnosis via serology in the first week.

See Answer in Part B → Q10

@Neet_pg_bot

Q11: A 32-year-old male presents with progressive bilateral lower limb weakness over the past 10 days after recovery from zika virus infection. On examination, he has flaccid paralysis and absent deep tendon reflexes in the affected limbs. CSF analysis shows cytoalbuminological dissociation. NCV test confirms a demyelinating pattern. Which diagnostic criteria are used to diagnose this presentation? (Q850959)

A. Brighton

B. Macdonald

C. Hakim's

D. Adam and Victor

See Answer in Part B → Q11

@Neet_pg_bot

Q12: A 40-year-old HIV-positive patient presents with fever, dry cough, and progressive shortness of breath. His CD4+ count is 150 cells/mm³. Chest X-ray shows bilateral interstitial infiltrates. Which of the following is the most likely mechanism of infection in this patient? (Q850960)

A. Primary infection acquired from a contaminated water source

B. Airborne transmission from an infected individual

C. Ingestion of fungal spores from environmental reservoirs

D. Reactivation of a previously dormant infection acquired during childhood

See Answer in Part B → Q12

@Neet_pg_bot

Q13: A 45-year-old male with HIV presents with low-grade fever, nonproductive cough, and progressive shortness of breath over the past month. His HRCT shows bilateral ground-glass opacities. Which of the following is not correct about the suspected oppurtunisitic infection? (Q850961)

A. Increased Alveolar arteriolar gradient

B. Use of steroids during treatment of this oppurtunistic infection

C. Crushed ping pong ball appearance on Gomori methamine stain

D. Cultured on Sabaroud dextrose agar

See Answer in Part B → Q13

@Neet_pg_bot

Q14: Which of the following diagnostic methods provides the highest sensitivity for confirming the presence of Pneumocystis jirovecii ? (Q850962)

A. Induced sputum and staining with gomori methamine stain

B. Sputum immunofluuroscence

C. Polymerase Chain Reaction

D. β-D-glucan assay

See Answer in Part B → Q14

@Neet_pg_bot

Q15: A 35 year old truck driver with AIDS is having CD4 count of 150 cells/ cu.mm. He has sulfa drug allergy. Which of the following drugs can be used in this patient by nebulization route for prevention of this opportunisticinfection? (Q850963)

A. Pentamidine

B. Trimethoprim and Sulfamethoxazole

C. Atovaquone

D. Clindamycin with Primaquine

See Answer in Part B → Q15

@Neet_pg_bot

• [11_Infections] 086 Aspergillosis Aids And Covid-19

« Back to Folder Directory

[11_Infections] 086 Aspergillosis Aids And Covid-19 — Quick Jump

Q1 (p. 1035)	*Q2 (p. 1035)*	*Q3 (p. 1036)*	*Q4 (p. 1036)*	*Q5 (p. 1037)*	*Q6 (p. 1038)*
Q7 (p. 1039)	*Q8 (p. 1039)*	*Q9 (p. 1039)*	*Q10 (p. 1040)*	*Q11 (p. 1040)*	*Q12 (p. 1040)*
Q13 (p. 1041)	*Q14 (p. 1042)*	*Q15 (p. 1042)*	*Q16 (p. 1043)*	*Q17 (p. 1043)*	*Q18 (p. 1043)*
Q19 (p. 1044)	*Q20 (p. 1044)*	*Q21 (p. 1045)*			

Q1: A 42-year-old HIV-positive male with a history of disseminated Mycobacterium avium complex (MAC) infection presents for a routine check-up. He is compliant with antiretroviral therapy (ART) and has a CD4+ count of 46 cells/μL. Which prophylactic therapy is recommended in this patient to prevent Mycobacterium avium complex? (Q850974)

A. Monotherapy with azithromycin

B. Trimethoprim-sulfamethoxazole

C. Clarithromycin + ethambutol

D. Isoniazid + pyridoxine

See Answer in Part B → Q1

@Neet_pg_bot

Q2: An HIV positive patient presented with a whitish plaque in the mouth and esophagus as shown in the image below. Most likely diagnosis is: (Q882169)

A. Oral leukoplokia

B. Hairy cell leukemia

C. Oral candidiasis

D. Oral cancer



See Answer in Part B → Q2

@Neet_pg_bot

Q3: A 55-year-old man with triple vessel disease presents with a persistent cough, fever, and shortness of breath. On admission he has respiratory rate 26 /minute and an sp02 92% on room air. His RT-PCR for SARS-COV2 is positive. What is the preferred oxygen delivery device for this patient? (Q850983)

A. Non invasive ventilation with tight fitting face mask

B. Nasal cannula and flow rate of 6L/min

C. CPAP mask

D. Non-rebreathing face mask

See Answer in Part B → Q3

@Neet_pg_bot

Q4: A 60-year-old woman with obesity and hypertension presents with a cough, fever and shortness of breath for the past four days. Her SpO2 is 90% on room air and her respiratory rate is 34/min. Her RT-PCR for SARS COV2 is positive. Which of the following is correct about laboratory findings seen in this case? (Q850982)

A. Reduced D-dimer

B. Reduced IL-6

C. Elevated platelet count

D. Elevated NLR

See Answer in Part B → Q4

@Neet_pg_bot

Q5: A 55-year-old man with a history of asthma presents with a persistent cough, fever, and shortness of breath that started three days ago after attending a family gathering. His examination shows a SpO 2 of 92% on room air and a respiratory rate of 26 breaths per minute, with the accompanying X-ray. What is the investigation of choice for this condition? (Q850981)

A. HRCT chest

B. C-reactive protein

C. RT-PCR

D. Rapid antigen test

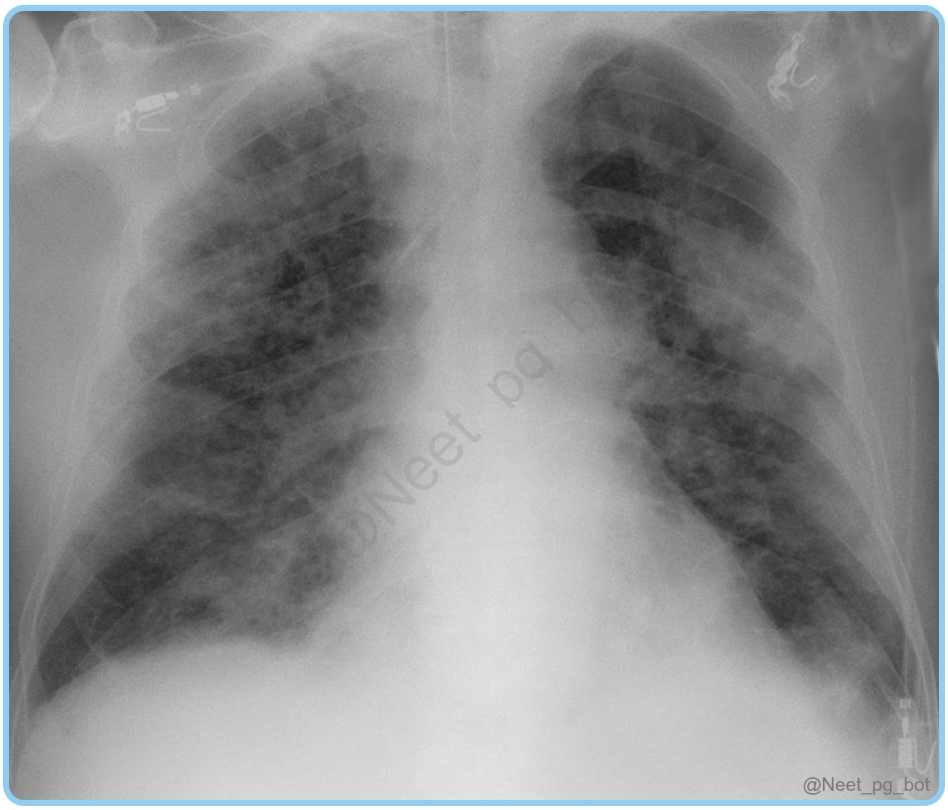

See Answer in Part B → Q5

@Neet_pg_bot

Q6: A 35-year-old HIV-positive man with a CD4 count of 80 cells/mm³ presents with chronic watery diarrhea and significant weight loss. Stool examination reveals oval-shaped oocysts measuring 20–30 microns, which appear pink to red on modified Kinyoun stain, showing a characteristic sporoblast. Which of the following is the best treatment? (Q850980)

A. Metronidazole

B. Nitazoxanide

C. TMP-SMX

D. Albendazole

See Answer in Part B → Q6

@Neet_pg_bot

Q7: A 36-year-old man with AIDS with CD4 count of 74 cells/μL presents with acute onset of odynophagia and retrosternal chest pain. Upper GI endoscopy reveals well-circumscribed, "volcano-like" ulcers in the mid-esophagus. Which of the following is the most likely diagnosis? (Q850979)

A. Cytomegalovirus esophagitis

B. Herpes simplex virus esophagitis

C. Candida esophagitis

D. ART induced esophagitis

See Answer in Part B → Q7

@Neet_pg_bot

Q8: A medical intern sustains a needle-stick injury from a known HIV-positive patient. What is the ideal time frame to initiate post-exposure prophylaxis for maximum efficacy? (Q850978)

A. Within 2 hours

B. Within 24 hours

C. Within 48 hours

D. After 72 hours

See Answer in Part B → Q8

@Neet_pg_bot

Q9: You have started fluconazole for secondary prevention of cryptococcus neoformans meningitis. Which of the following is correct statement about it? (Q850977)

A. Continue till CD4 count > 100 cells for one year and HIV RNA suppressed for >3 months

B. Continue till CD4 count > 200 cells for one year and HIV RNA suppressed for > 3 months

C. Continue till CD4 count < 200 cells for one year and HIV RNA suppressed for < 3 months

D. Continue till CD4 count > 200 cells and HIV RNA < 5000 copies/ ml

See Answer in Part B → Q9

@Neet_pg_bot

Q10: Which of the following drugs is effective against both HIV and hepatitis B? (Q850976)

A. Efavirenz

B. Tenofovir

C. Abacavir

D. Ritonavir

See Answer in Part B → Q10

@Neet_pg_bot

Q11: A 38 -year-old man is newly diagnosed with HIV. He is asymptomatic with a CD4 count of 650 cells/mm^3. Based on WHO recommendations, which of the following combinations would be best suited for treatment of this case? (Q850975)

A. Zidovudine + Lamivudine + Raltegravir

B. Abacavir + Lamivudine + Lopinavir

C. Tenofovir + Lamivudine + Efavirenz

D. Tenofovir + Lamivudine + Dolutegravir

See Answer in Part B → Q11

@Neet_pg_bot

Q12: A 55-year-old immunocompromised patient presents with fever, cough, and respiratory distress. CT chest is perfomed. Which of the following investigations would be most specific to confirm the diagnosis? (Q850930)

A. Lung histology shows fungal septate hyphae with branching at 45 degrees

B. BACTEC MGIT 960

C. Galactomannan antigen on sputum

D. Beta 1,3 D- glucan test



See Answer in Part B → Q12

@Neet_pg_bot

Q13: AIDS Patient is having a CD4 count of 200 cells/cu.mm. He has had fever, cough and shortness of breath for the past week. Auscultation reveals scattered bronchial breathing in the left infra-axillary and infrascapular areas. CXR reveals air bronchograms in the left lower lobe. Which opportunistic infection is present in this patient? (Q850973)

A. Pneumococcus

B. Mycobacterium avium intracellulare

C. Mycobacterium tuberculosis

D. Pneumocystis jirovecii

See Answer in Part B → Q13

@Neet_pg_bot

Q14: A truck driver with AIDS is brought in with fever and altered mental status. His family reports a week-long history of worsening headache, fever, projectile vomiting, and confusion. Neuroimaging shows a soapy bubble appearance, and CSF shows 50 lymphocytes/cu.mm with low sugar and a mild increase in protein. Which of the following is the most accurate test for confirmation of the diagnosis of this condition? (Q850972)

A. CSF Lateral flow assay

B. CSF gram staining

C. CSF India ink preparation

D. CSF staining with mucicarmine

See Answer in Part B → Q14

@Neet_pg_bot

Q15: A 3-week-old infant born to an HIV-positive mother is brought to OPD. The baby was delivered vaginally and was not breastfed. The mother has been on antiretroviral therapy throughout pregnancy. Which of the following is the most appropriate test to diagnose HIV infection in this neonate? (Q850971)

A. PCR HIV RNA

B. PCR HIV DNA

C. Serum ELISA for HIV

D. p24 antigen

See Answer in Part B → Q15

@Neet_pg_bot

Q16: A 28-year-old lab technician presents 10 days after sustaining a needle-stick injury while drawing blood from an HIV-positive patient. He did not receive post-exposure prophylaxis He is currently asymptomatic and anxious about possible seroconversion. Which of the following test will help in early detection of possible transmission of infection? (Q850970)

A. HIV PCR RNA

B. Western Blot

C. HIV PCR DNA

D. ELISA for HIV-1 and HIV-2

See Answer in Part B → Q16

@Neet_pg_bot

Q17: Which is correct about definiton of AIDS? (Q850969)

A. ELISA positive for HIV plus any WHO clinical stage 4 condition that includes AIDS-defining illnesses

B. ELISA positive for HIV plus CD4 count less than 350 cells /cu.mm

C. ELISA positive for HIV plus CD4 count less than 500 cells /cu.mm

D. ELISA positive for HIV plus persistent generalized lymphadenopathy involving > 2 groups

See Answer in Part B → Q17

@Neet_pg_bot

Q18: A 53-year-old man visits the clinic with recurring respiratory infections and oral candidiasis. Lab tests show a CD4 count of 150 cells/mm³, raising suspicion for HIV. Which structure allows the HIV virus to attach to CD4 cells initially? (Q850934)

A. CCR5

B. gp41

C. p17

D. gp120

See Answer in Part B → Q18

@Neet_pg_bot

Q19: A 31-year-old woman diagnosed with HIV is in her third trimester of pregnancy. Which of the following statements is not true regarding vertical transmission of HIV? (Q850933)

A. ART greatly lowers the risk of vertical transmission.

B. Transmission can occur through breast milk.

C. Prolonged membrane rupture increases transmission risk.

D. Viral transmission does not occur in the first trimester.

See Answer in Part B → Q19

@Neet_pg_bot

Q20: A 30-year-old asthmatic patient presents with worsening respiratory symptoms and is diagnosed with Allergic Bronchopulmonary Aspergillosis . Which of the following is the most appropriate initial treatment strategy? (Q850932)

A. Voriconazole

B. Itraconazole with low-dose corticosteroids

C. Fluconazole with corticosteroids

D. Posaconazole

See Answer in Part B → Q20

@Neet_pg_bot

Q21: Which of the following findings is not seen with allergic bronchopulmonary aspergillosis? (Q850931)

A. Elevated total serum IgE

B. Central bronchiectasis on HRCT

C. Presence of hyper-attenuated mucus on imaging

D. Halo sign on HRCT chest

See Answer in Part B → Q21

@Neet_pg_bot

• [11_Infections] 087 Previous Year Questions

« Back to Folder Directory

[11_Infections] 087 Previous Year Questions — Quick Jump

Q1 (p. 1046)	*Q2 (p. 1046)*	*Q3 (p. 1047)*	*Q4 (p. 1047)*	*Q5 (p. 1047)*	*Q6 (p. 1048)*
Q7 (p. 1049)	*Q8 (p. 1049)*	*Q9 (p. 1050)*	*Q10 (p. 1050)*	*Q11 (p. 1051)*	*Q12 (p. 1051)*
Q13 (p. 1051)	*Q14 (p. 1052)*	*Q15 (p. 1053)*	*Q16 (p. 1053)*	*Q17 (p. 1054)*	*Q18 (p. 1055)*
Q19 (p. 1055)	*Q20 (p. 1055)*	*Q21 (p. 1056)*	*Q22 (p. 1056)*	*Q23 (p. 1057)*	*Q24 (p. 1057)*
Q25 (p. 1057)	*Q26 (p. 1058)*	*Q27 (p. 1058)*	*Q28 (p. 1059)*	*Q29 (p. 1059)*	*Q30 (p. 1059)*
Q31 (p. 1060)	*Q32 (p. 1061)*	*Q33 (p. 1062)*	*Q34 (p. 1062)*	*Q35 (p. 1062)*	*Q36 (p. 1063)*

Q1: The blood investigation of a patient is given below. What is the probable diagnosis? HBsAg- Nonreactive HBeAg- Nonreactive IgG anti-HbcAg – Reactive IgM anti-HbcAg – Nonreactive (Q855717)

A. Acute hepatitis B

B. Chronic hepatitis B

C. Remote infection of hepatitis B

D. Core window period

See Answer in Part B → Q1

@Neet_pg_bot

Q2: A patient arrives at the hospital with symptoms of fever and chills. A fever profile test is conducted, which rules out malaria and dengue as the cause. However, the rK39 test comes back positive. What is the preferred treatment for this condition? (Q855608)

A. Amphotericin B

B. Griseofulvin

C. Dapsone

D. Hydroxychloroquine

See Answer in Part B → Q2

@Neet_pg_bot

Q3: A patient, who is a known case of HIV with a CD4 count of 200 cells/cu.mm, presents with 5 days of cough and high-grade fever without chills and rigors. There is no history of diarrhoea, vomiting, or nuchal rigidity. The chest x-ray is normal. What treatment will you give? (Q855704)

A. Amoxicillin-clavulanic acid + Azithromycin

B. Amphotericin B

C. Co-trimoxazole only

D. Antitubercular treatment

See Answer in Part B → Q3

@Neet_pg_bot

Q4: Which of the following is NOT a potential complication in a 40-year-old man who presents with a 15-day history of fever and a 1-day history of altered sensorium and is diagnosed with Plasmodium falciparum through a rapid diagnostic test? (Q855326)

A. Blood glucose <40 mg/dL

B. Arterial pH >7.2

C. Serum creatinine -5.2

D. Unarousable coma

See Answer in Part B → Q4

@Neet_pg_bot

Q5: A 25-year-old immunocompromised man presents with fever, headache, and altered sensorium. Examination shows neck rigidity and positive Kernig's sign. CSF reveals lymphocytic predominance, high protein, low glucose, and encapsulated yeast cells on India ink staining. What is the most appropriate treatment regimen for this patient? (Q855355)

A. Piperacillin + Tazobactam

B. Vancomycin + Ceftriaxone

C. Amphotericin B + Flucytosine

D. Ceftriaxone + Ampicillin

See Answer in Part B → Q5

@Neet_pg_bot

Q6: A patient presents with cough, cold, fever and malaise associated with weight loss and ascites. A radiograph of the chest is shown below. Ascitic fluid analysis showed elevated adenosine deaminase. Which of the following is the next step in management? (Q855357)

A. Biopsy

B. Start ATT after laparotomy stricture removal

C. Start anti-tubercular therapy

D. Symptomatic management

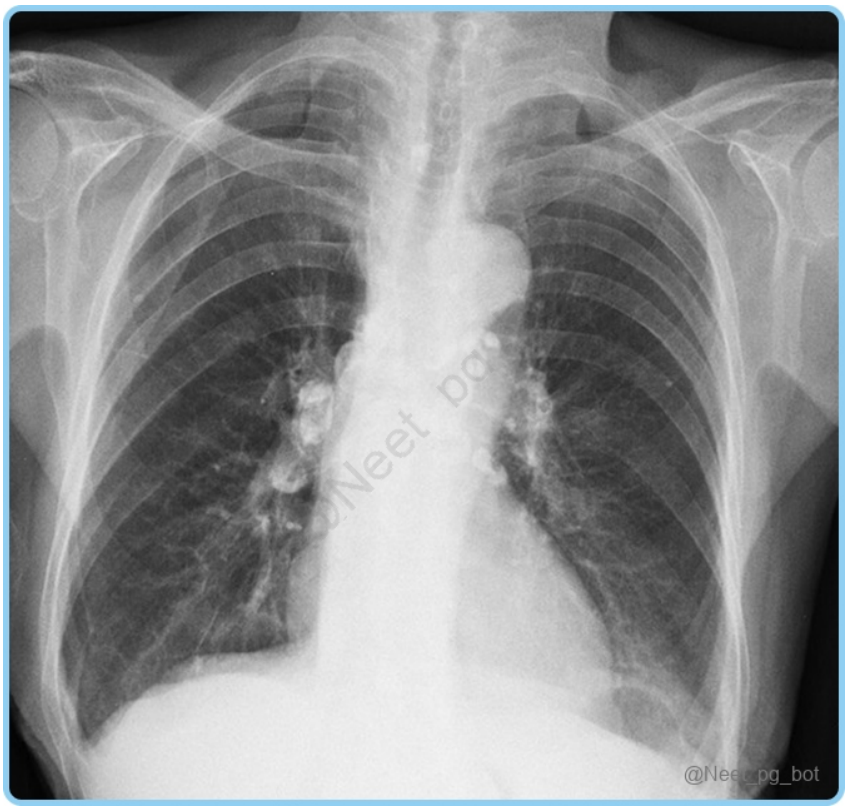

See Answer in Part B → Q6

@Neet_pg_bot

Q7: What is the association of Rhino-cerebral Mucor mycosis? (Q857049)

A. Diabetic ketoacidosis

B. Pregnancy

C. Antibiotics

D. Inhaled steroids

See Answer in Part B → Q7

@Neet_pg_bot

Q8: A 7-year-old boy presents with fever, painful swelling in front of both ears, and difficulty chewing or talking. On examination, he also complains of mild testicular

pain. What is the most likely diagnosis? (Q857613)

A. Cervical tuberculosis

B. Diphtheria

C. Mumps

D. Lymphoma

See Answer in Part B → Q8

@Neet_pg_bot

Q9: A newly diagnosed HIV patient presented with fever, cough and haemoptysis. His sputum sample showed acid-fast bacilli. What is the appropriate management for this patient? (Q855702)

A. Start ART if CD4<200

B. Start ART and then ATT after 2 weeks

C. Start ATT and then ART after 2 weeks

D. Start ATT and ART simultaneously

See Answer in Part B → Q9

@Neet_pg_bot

Q10: A patient presents with fever and altered sensorium. Peripheral smear shows multiple ring stages. Best treatment is? (Q866815)

A. Primaquine

B. Quinine

C. Chloroquine

D. Artesunate

See Answer in Part B → Q10

@Neet_pg_bot

Q11: Identify the correct ‘organism-drug to which it is intrinsically resistant’ pair: (Q856588)

A. Aspergillus niger - Voriconazole

B. Aspergillus fumigatus - Micafungin

C. Candida albicans - Amphotericin B

D. Candida Krusei - Fluconazole

See Answer in Part B → Q11

@Neet_pg_bot

Q12: A 23-year-old medical student with fever had developed epistaxis which had resolved on its own and on evaluation his platelet counts are 14,000/µL and BP is 110/70 mmHg and there is a 28% rise in haematocrit. Then he has been afebrile for the last 24 hours now, what should be the next steps of management of this patient? Give 4 units of platelets Give plenty of oral fluids Give IV fluids Keep under observation Discharge the patient (Q856966)

A. 1 and 2

B. 1,2 and 4

C. 2,3 and 4

D. 2 and 5

See Answer in Part B → Q12

@Neet_pg_bot

Q13: Following is a graphic representation of a patient admitted in the medicine ward with a fever. What could be the possible diagnosis? (Q856270)

A. Cerebral malaria

B. Brucellosis

C. Leptospirosis

D. Typhoid

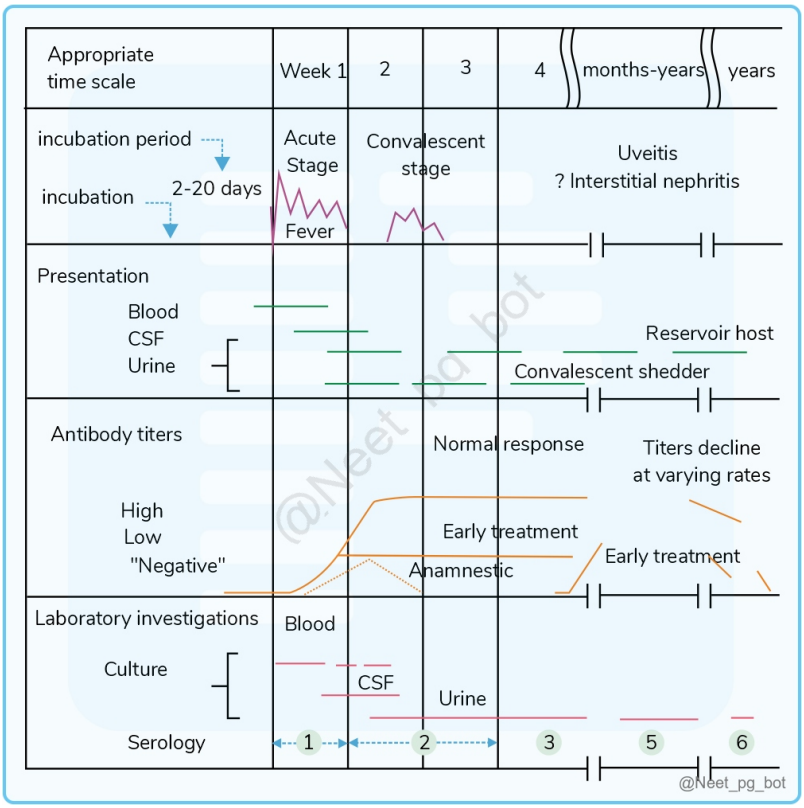

See Answer in Part B → Q13

@Neet_pg_bot

Q14: Which of the following is false about Mycoplasma pneumoniae? (Q856293)

A. Responds well to Amoxiclav

B. Antibodies are useful in diagnosis

C. Chest X-ray shows bilateral infiltrates

D. Can be cultured in a cell-free medium

See Answer in Part B → Q14

@Neet_pg_bot

Q15: An HIV-positive patient presents with the following finding. What is the diagnosis & WHO clinical stage of HIV? (Q859754)

A. Oral candidiasis & WHO stage 2

B. Oral hairy leukoplakia & WHO Stage 3

C. Oral candidiasis & WHO stage 3

D. Oral hairy leukoplakia & WHO stage 2



See Answer in Part B → Q15

@Neet_pg_bot

Q16: As seen below, a 49-year-old man presents with flu-like symptoms and a palmoplantar rash. On examination, he has epitrochlear lymphadenopathy. Which of the following is the likely diagnosis? (Q859759)

A. Primary syphilis

B. Secondary syphilis

C. Pyoderma gangrenosum

D. Steven Johnson syndrome



See Answer in Part B → Q16

@Neet_pg_bot

Q17: A patient diagnosed to be retro-positive was started on highly active antiretroviral therapy (HAART). Which of the following can be used to monitor treatment efficacy? (Q855853)

A. CD4+ T cell count

B. Viral load

C. p24 antigen

D. Viral serotype

See Answer in Part B → Q17

@Neet_pg_bot

Q18: A patient presents with a fever for 4 days. There are no bleeding manifestations, and vitals are stable. Workup shows Hb = 9 g/dl, platelet count - 20,000/mm³. What is the next appropriate step in management in 1st hour PCM Antibiotic Platelets transfusion Steroids (Q879177)

A. 1,2,3,4

B. 1,2,3

C. 1,2

D. 1

See Answer in Part B → Q18

@Neet_pg_bot

Q19: What immunological abnormality is observed due to the absence of CD40 in B cells? (Q857281)

A. Total lack of NK cells

B. Lack of CD8-mediated cytotoxicity

C. Decreased IgG and increase in IgM

D. Inability of neutrophils to act against infections

See Answer in Part B → Q19

@Neet_pg_bot

Q20: A HIV-positive patient presents with chronic diarrhoea for 4 weeks. Stool microscopy shows oval/ elliptical cysts measuring 16 X 20 µm. Diagnosis is? (Q866800)

A. Cryptosporidium

B. Cryptococcus

C. Cyclospora

D. Cystoisospora

See Answer in Part B → Q20

@Neet_pg_bot

Q21: A 35-year-old farmer presents with intermittent fever, profuse sweating, fatigue, and arthralgia for 3 weeks. He reports handling livestock and consuming unpasteurized dairy products. Mild hepatosplenomegaly is noted. Blood cultures reveal Brucella species. Which of the following is the most appropriate antimicrobial therapy? (Q866824)

A. Doxycycline alone

B. Doxycycline plus rifampicin

C. Doxycycline with azithromycin

D. Doxycycline plus ceftriaxone

See Answer in Part B → Q21

@Neet_pg_bot

Q22: 30 year old man presents with severe headache, fever for one day with altered sensorium. Nuchal rigidity is absent. Guarded LP was done and CSF shows 50 cells with 20% neutrophils and 80% lymphocytes with CSF sugar of 70 mg and RBS 100 mg/dl with protein= 90 mg/dl. Diagnosis is? (Q866829)

A. Viral encephalitis

B. Acute bacterial meningitis

C. Tubercular Meningitis

D. Viral meningitis

See Answer in Part B → Q22

@Neet_pg_bot

Q23: A patient underwent cardiac surgery and was admitted to the ICU. He later developed ventilator-associated pneumonia (VAP) and was started on empirical antibiotics. A few hours later, the patient developed acute kidney injury (AKI). Serum procalcitonin was sent. Which of the following statements regarding procalcitonin is correct? (Q865372)

A. It helps in determining the duration of antibiotic therapy

B. It helps in identifying which empirical antibiotics to be given

C. It can be used to confirm source of infection

D. It is used to differentiate bacterial from fungal cause

See Answer in Part B → Q23

@Neet_pg_bot

Q24: A 38-year-old male presents with a one-week history of fever, headache, retro-orbital pain, and myalgia. Skin examination reveals multiple purpura and petechiae on the left shoulder, trunk, and legs. Similar cases have been reported linked to increased incidence of mosquito breeding. What is the most common neurological complication associated with this condition? (Q852755)

A. Encephalopathy

B. Guillain-Barré Syndrome

C. Stroke

D. Encephalitis

See Answer in Part B → Q24

@Neet_pg_bot

Q25: A patient has pleural fluid with an LDH level greater than 0.6 times the serum LDH and protein greater than 0.5 times the serum protein. What is the most likely diagnosis? (Q844266)

A. Tuberculosis (TB)

B. Heart failure

C. Hepatic failure

D. Renal failure

See Answer in Part B → Q25

@Neet_pg_bot

Q26: What is the investigation of choice for detecting enteric fever in the first week? (Q860128)

A. Blood culture

B. Urine culture

C. Stool culture

D. Antibody detection

See Answer in Part B → Q26

@Neet_pg_bot

Q27: Which of the microorganisms listed below will exhibit intrinsic resistance to meropenem and aminoglycosides, but have sensitivity to cotrimoxazole? (Q857273)

A. Burkholderia cepacia

B. Acinetobacter

C. Pseudomonas

D. Stenotrophomonas

See Answer in Part B → Q27

@Neet_pg_bot

Q28: In a patient with HIV, the incorrect statement regarding prophylaxis for various organisms is: (PCP-Pneumocystis pneumonia, MAC-Mycobacterium avium complex) (Q854659)

A. Prophylaxis for PCP is indicated when CD4 count is <200 cells/µL

B. Stop prophylaxis for Coccidioides if CD4 count is >250 cells/µL for 6 months

C. Prophylaxis for MAC is indicated when CD4 count is <50 cells /µL

D. Prophylaxis for cryptococcus is indicated when the CD4 count is >150 cells/µL

See Answer in Part B → Q28

@Neet_pg_bot

Q29: A 30-year-old HIV-positive man presents with neck rigidity and papilledema. His CSF sample showed a capsulated organism positive for India ink staining. Which of the following statements is true? (Q854680)

A. Intracranial pressure remains normal

B. Delay antiretroviral therapy by 4-6 weeks after the initiation of antifungal treatment

C. Initiate treatment with oral fluconazole

D. Brain imaging shows changes in > 80 % of patients

See Answer in Part B → Q29

@Neet_pg_bot

Q30: A 30-year-old farmer from Tamil Nadu presented with fever, myalgia, headache and cough. On physical examination, a lesion is seen on the chest. Lung auscultation shows extensive bilateral rales. Blood investigation showed positive IgM for scrub

typhus. What would be the appropriate treatment? (Q854699)

A. Doxycycline

B. Doxycycline with Ceftriaxone

C. Ceftriaxone with Azithromycin

D. Doxycycline with Azithromycin



See Answer in Part B → Q30

@Neet_pg_bot

Q31: A 50-year-old HIV patient presented with a painful lesion, as shown in the image. What is the most likely diagnosis? (Q855448)

A. Basal cell carcinoma

B. Kaposi sarcoma

C. Malignant melanoma

D. Squamous cell carcinoma

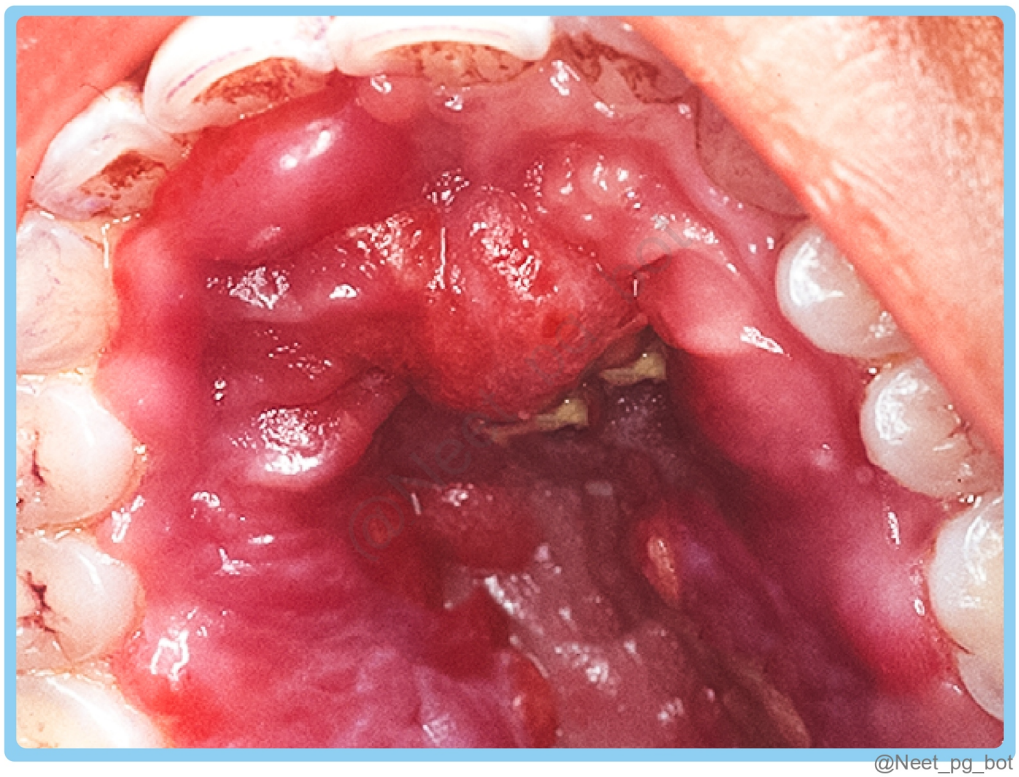

See Answer in Part B → Q31

@Neet_pg_bot

Q32: A 45-year-old HIV-positive male came with complaints of persistent cough and weight loss. He has skin lesions that appear as umbilicated papules and nodules predominantly on the face, trunk, and upper extremities. Chest x-ray showed multiple bilateral nodular infiltrates. His sputum CBNAAT for tuberculosis was negative and he has a low CD4 count. What is the probable diagnosis? (Q855461)

A. HIV with disseminated histoplasmosis

B. HIV with disseminated cryptococcosis

C. HIV with molluscum contagiosum

D. HIV with tuberculosis

See Answer in Part B → Q32

@Neet_pg_bot

Q33: An HIV-positive man presents with a high-grade fever. Examination reveals a positive Kernig's sign. CSF shows reduced glucose, increased protein, and increased leukocytes. A diagnosis of cryptococcal meningitis is made. What is the appropriate management for this patient? (Q858018)

A. Vancomycin

B. High dose fluconazole with flucytosine

C. Voriconazole

D. Liposomal amphotericin B

See Answer in Part B → Q33

@Neet_pg_bot

Q34: A 70-year-old patient with a smoking history presents with high-grade fever, cough, confusion, and diarrhea. Chest X-ray shows bilateral infiltrates in bilateral lower lung fields. On sputum gram stain, no organisms were detected. Laboratory results reveal Na: 126mEq/L, AST:62, ALT:56, RBS:112 mg/dl, serum bilirubin of 0.8mg%, and a positive HIV test. Which of the following organisms is responsible? (Q858022)

A. Streptococcus

B. Legionella

C. Pneumocystis jiroveci

D. Klebsiella

See Answer in Part B → Q34

@Neet_pg_bot

Q35: A 65-year-old male presented with unexplained fever and prolonged respiratory distress despite appropriate treatment. A diagnosis of cryptic tuberculosis was made. Which of the following is the correct statement related to this condition? (Q858030)

A. Positive skin tuberculin test and negative chest X-ray

B. Positive skin tuberculin test and positive chest X-ray

C. Negative skin tuberculin test and negative chest X-ray

D. Negative skin tuberculin test and positive chest X-ray

See Answer in Part B → Q35

@Neet_pg_bot

Q36: What is the drug of choice for Legionnaire's disease? (Q793967)

A. Vancomycin

B. Azithromycin

C. Streptomycin

D. Erythromycin

See Answer in Part B → Q36

@Neet_pg_bot

• [12_Oncology] 088 Previous Year Questions

« Back to Folder Directory

[12_Oncology] 088 Previous Year Questions — Quick Jump

Q1 (p. 1064) *Q2 (p. 1064)* *Q3 (p. 1064)* *Q4 (p. 1065)* *Q5 (p. 1065)* *Q6 (p. 1065)*

Q1: Which of the following is not used in management of tumor lysis syndrome? (Q793977)

A. Urine acidification

B. IV fluids

C. Dialysis

D. Rasburicase

See Answer in Part B → Q1

@Neet_pg_bot

Q2: Most common cause of hypercalcemia in a hospitalized patient is: (Q857290)

A. Malignancy

B. Parathyroid Adenoma

C. Parathyroid hyperplasia

D. Follicular thyroid CA

See Answer in Part B → Q2

@Neet_pg_bot

Q3: What is the most frequently observed delayed symptom of radiation therapy for the head and neck? (Q859545)

A. Dysphagia

B. Xerostomia

C. Myelopathy

D. Dysgeusia

See Answer in Part B → Q3

@Neet_pg_bot

Q4: For which of the following cancers is prophylactic cranial irradiation (PCI) routinely recommended as part of standard management (Q859648)

A. Lung cancer

B. Liver cancer

C. Prostate cancer

D. Breast cancer

See Answer in Part B → Q4

@Neet_pg_bot

Q5: A lung cancer patient has hyperpigmentation of palmar and sole creases. Which of the following is responsible for this presentation? (Q860465)

A. Melanocyte Stimulating Hormone (MSH)

B. C-peptide

C. Neuropeptide Y

D. Melanin

See Answer in Part B → Q5

@Neet_pg_bot

Q6: Which of the following mutations is associated with the Philadelphia chromosome? (Q860473)

A. Inversion

B. Insertion

C. Reciprocal translocation

D. Deletion

See Answer in Part B → Q6

@Neet_pg_bot

• [13_Miscellaneous Topics] 089 Previous Year Questions

« Back to Folder Directory

[13_Miscellaneous Topics] 089 Previous Year Questions — Quick Jump

Q1 (p. 1067) *Q2 (p. 1067)* *Q3 (p. 1067)* *Q4 (p. 1068)* *Q5 (p. 1068)* *Q6 (p. 1069)* *Q7 (p. 1069)*

Q1: What vitamin deficiency is responsible for the following symptoms in a patient: tingling sensation in the hands and feet, generalized weakness, easy fatigability, pallor, and ataxia? (Q793810)

A. Vitamin B1

B. Vitamin B12

C. Vitamin B2

D. Vitamin B3

See Answer in Part B → Q1

@Neet_pg_bot

Q2: Cat scratch disease is caused by? (Q793845)

A. Bartonella henselae

B. Bartonella quintana

C. Bartonella bacilliformis

D. Borrelia burgdorferi

See Answer in Part B → Q2

@Neet_pg_bot

Q3: A man brings his father who became unconscious while working in a field in the host sun at 42 degrees Celsius in May. One examination, there were no physical signs of dehydration. His serum electrolyte values were normal. The physician found that the body temperature was 106 F. Which of the following symptoms is least likely to be seen in this patient? (Q793895)

A. Nausea

B. Hypotension

C. Sweating

D. Headache

See Answer in Part B → Q3

@Neet_pg_bot

Q4: What is the most likely diagnosis for a tall male with a lack of pubic and axillary hair, underdeveloped genitalia, elevated levels of LH and FSH, and a karyotype of XXY? (Q793914)

A. Vanishing testis syndrome

B. Klinefelter’s syndrome

C. Noonan syndrome

D. Adrenal hyperplasia

See Answer in Part B → Q4

@Neet_pg_bot

Q5: How much sodium deficit needs to be corrected in a 40 kg female with a serum sodium level of 120 mEq/L to achieve a desired sodium concentration of 140 mEq/L? (Q830815)

A. 400 mEq

B. 300 mEq

C. 200 mEq

D. 100 mEq

See Answer in Part B → Q5

@Neet_pg_bot

Q6: During the medication review of an elderly male patient with a history of COPD, hypertension, and diabetes, what criteria should the physician consider? (Q830826)

A. Duke’s criteria

B. Light criteria

C. Beer’s criteria

D. Jones criteria

See Answer in Part B → Q6

@Neet_pg_bot

Q7: Match the following? a. Trisomy 13 1. Huntington's disease b. Trisomy 18 2. Patau syndrome c. Trinucleotide repeat sequence 3. Sickle disease d. Hb point mutation of glutamate to valine 4. Edward syndrome (Q857256)

A. a-2, b-4, c-1, d-3

B. b-1, a-3, d-2, c-4

C. a-2, b-1, c-4, d-3

D. a-4, b-1, c-3, d-2

See Answer in Part B → Q7

@Neet_pg_bot

• [14_Miscellaneous] 090 Previous Year Questions

« Back to Folder Directory

[14_Miscellaneous] 090 Previous Year Questions — Quick Jump

Q1 (p. 1070) *Q2 (p. 1070)* *Q3 (p. 1071)* *Q4 (p. 1071)* *Q5 (p. 1071)* *Q6 (p. 1072)*
Q7 (p. 1072) *Q8 (p. 1073)* *Q9 (p. 1074)*

Q1: A patient has a long arm span, hypermobile joints and hypermobile lens. What is the defective protein? (Q866820)

A. Fibrillin-1

B. Collagen

C. Elastin

D. Keratin

See Answer in Part B → Q1

@Neet_pg_bot

Q2: A skin graft was performed on a immunocompromised patient, using tissue from a immunocompetent donor. After a few weeks, the recipient developed skin contractures along with systemic symptoms such as fever, rash, and diarrhea. What is the most likely diagnosis? (Q866831)

A. Graft-versus-host disease

B. Graft failure

C. Rejection due to recipient T8 cells

D. Delayed wound healing

See Answer in Part B → Q2

@Neet_pg_bot

Q3: What is the enzyme deficiency in Pompe’s disease? (Q857265)

A. Lysosomal acid alpha-glucosidase

B. Glucose 6 phosphatase

C. Muscle phosphorylase

D. Phosphofructokinase

See Answer in Part B → Q3

@Neet_pg_bot

Q4: All of the following tests are done for screening in patients with Turner’s syndrome, except? (Q857282)

A. ANA

B. Audiometry

C. Echocardiography

D. Fasting blood glucose

See Answer in Part B → Q4

@Neet_pg_bot

Q5: Which is the best confirmatory method to ensure the central line is in the jugular vein? (Q859533)

A. Chest X-ray

B. Blood pH

C. Blood color

D. ETCO 2

See Answer in Part B → Q5

@Neet_pg_bot

Q6: What is the most likely diagnosis for an adult patient with a pulsatile swelling in the neck below the jaw angle that causes an outward expansile impulse, based on the findings of an MRI angiography? (Q859536)

A. Grave's disease

B. Branchial cyst

C. Thymic cyst

D. Carotid body tumour



See Answer in Part B → Q6

@Neet_pg_bot

Q7: A 32-year-old Mount Everest tour guide presents with blisters on her hand, severe pain, and erythema after prolonged exposure to extreme cold. Which of the following

is the most appropriate initial management for this patient? (Q859647)

A. Administer oxygen

B. Rapidly rewarm in warm water and protect

C. Pentoxyphylline

D. NSAID’s



See Answer in Part B → Q7

@Neet_pg_bot

Q8: A 30-year-old man presented the findings shown in the given image. What is this physical finding called? (Q859760)

A. Spoon-shaped nails

B. Raynaud's phenomenon

C. Pallor

D. Clubbing

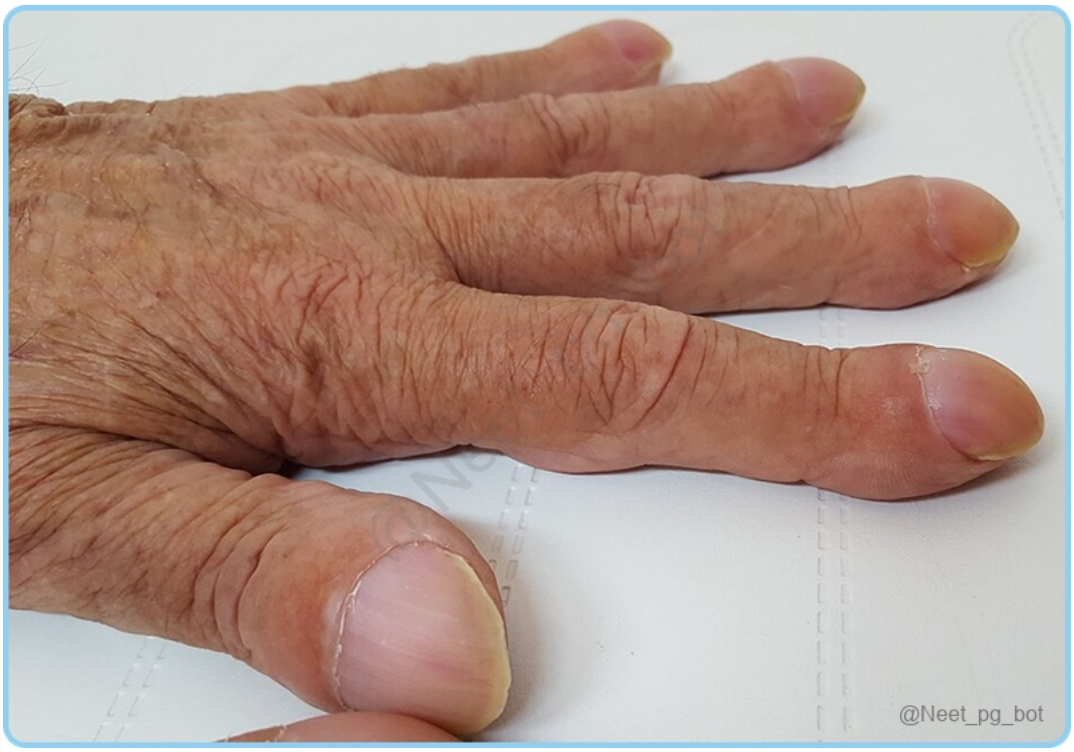

See Answer in Part B → Q8

@Neet_pg_bot

Q9: Which of the following animals is most likely responsible for biting a 10-year-old child who presented with symptoms of tachycardia, hypertension, tongue fasciculation, hypersalivation, dilated pupils, and mild erythema at the site of the wound? The child recalls that the animal had a curved tail pointing upwards. (Q859779)

A. Sea urchin

B. Caterpillar

C. Scorpion

D. Shellfish

See Answer in Part B → Q9

@Neet_pg_bot

Part B — All Answers & Explanations

• [01_Cardiology] 001 Valvular Heart Disease

« Back to Folder Directory

[01_Cardiology] 001 Valvular Heart Disease — Quick Jump

Q1 (p. 1075)	*Q2 (p. 1076)*	*Q3 (p. 1082)*	*Q4 (p. 1083)*	*Q5 (p. 1084)*	*Q6 (p. 1085)*
Q7 (p. 1085)	*Q8 (p. 1086)*	*Q9 (p. 1088)*	*Q10 (p. 1089)*	*Q11 (p. 1090)*	*Q12 (p. 1091)*
Q13 (p. 1091)	*Q14 (p. 1092)*	*Q15 (p. 1093)*	*Q16 (p. 1093)*	*Q17 (p. 1094)*	*Q18 (p. 1095)*
Q19 (p. 1097)	*Q20 (p. 1099)*	*Q21 (p. 1099)*	*Q22 (p. 1100)*	*Q23 (p. 1101)*	*Q24 (p. 1102)*

Q1: A 52-year-old male presents with worsening shortness of breath and fatigue. An echocardiogram shows left ventricular dilation and significant aortic regurgitation. Which of the following are the possible conditions causing Aortic regurgitation? Ankylosing Spondylitis Aortic Dissection Marfan's Syndrome Syphilis (Q850418)

A. 1,2,3

B. 2,3,4

C. 1,3,4

D. 1,2,3,4

Correct Answer: D. 1,2,3,4

■ *Listen (English)*

■ *Listen (Hindi)*

Explanation: All of the above are potential causes of aortic regurgitation but through different mechanisms. Aortic Regurgitation Aetiology Conditions affecting the valve structure and its functions Conditions causing valve root dilatation Bicuspid Aortic valve (Congenital) Infective Endocarditis Rheumatic fever Myxomatous prolapse of the valve Scarring of the valve by Syphilis (statement 4) Ankylosing spondylitis (statement 1) Radiation Trauma Aortic Dissection (statement 2) Aortitis (Takayasu arteritis or GCA) Hypertension Marfan syndrome (statement 3) Medial Degeneration Nonsyndromic familial aneurysm Pathophysiology Clinical symptoms Usually, it starts appearing only after 10 to 15 years. Symptoms specific to AR : Palpitations (more in the supine position) Head pounding sensation Other symptoms: Paroxysmal Nocturnal dyspnea(sometimes the early one to appear) Angina on rest or exertion & breathlessness on exertion Orthopnea and diaphoresis Peripheral edema

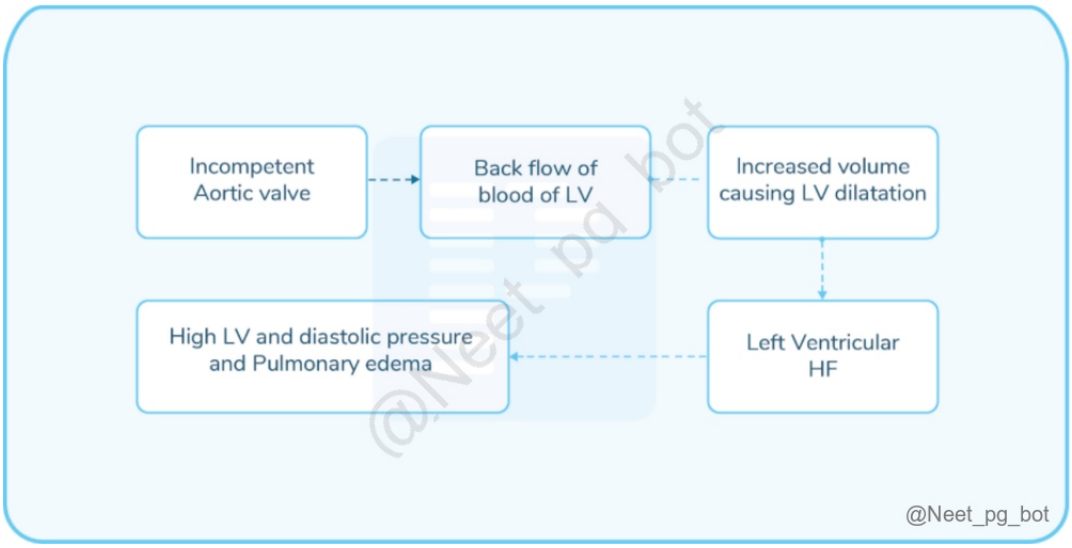

References:

Harrison's Principles of Internal Medicine, 22nd Edition, Page 2043-2044.

↑ *Back to this question in Part A*

@Neet_pg_bot

Q2: Match the following murmurs with the respective conditions. S.No Murmur Condition 1) a) Mitral Stenosis 2) b) Aortic Stenosis 3) c) Mitral Regurgitation 4) d) Aortic Regurgitation (Q850444)

A. 1-a, 2-b, 3-c, 4-d

B. 1-c, 2-a, 3-d, 4-b

C. 1-a, 2-c, 3-b, 4-d

D. 1-d, 2-b, 3-c, 4-a

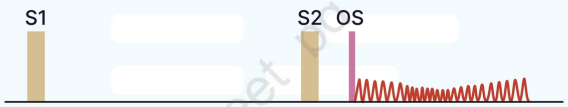

@Neet_pg_bot

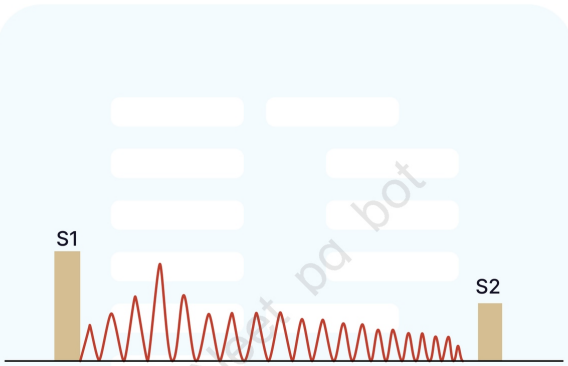

@Neet_pg_bot



@Neet_pg_bot

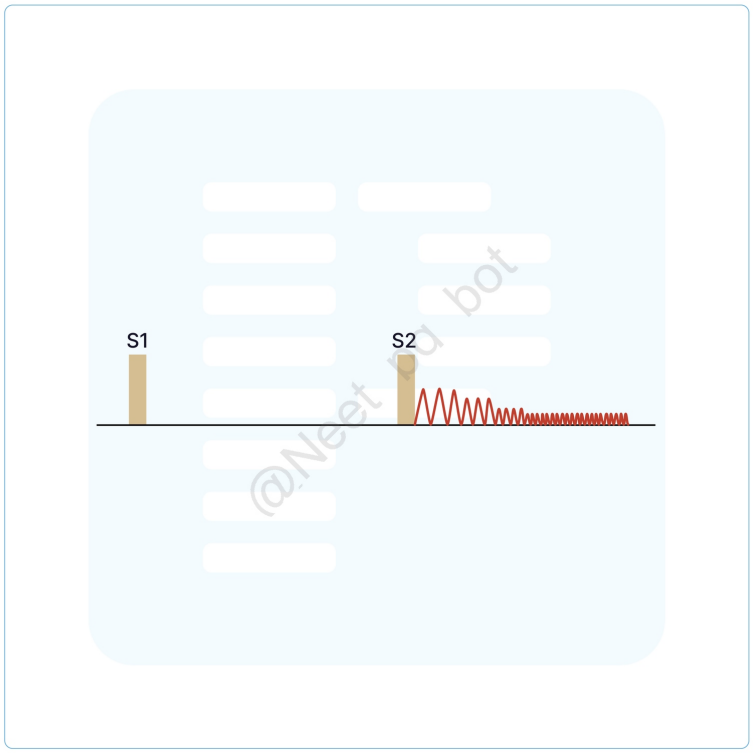

@Neet_pg_bot

Correct Answer: A. 1-a, 2-b, 3-c, 4-d

Explanation: Aortic Stenosis: Crescendo-decrescendo ejection murmur Mitral/Tricuspid Regurgitation: Holosystolic, high-pitched “blowing” murmur Aortic Regurgitation: Early diastolic, decrescendo, high-pitched “blowing” murmur Mitral Stenosis: Delayed rumbling mid-to-late diastolic murmur with opening snap Mitral valve prolapse: Late crescendo murmur with mid systolic click (MC) that occurs after carotid pulse Ventricular septal defect: Holosystolic, harsh-sounding murmur

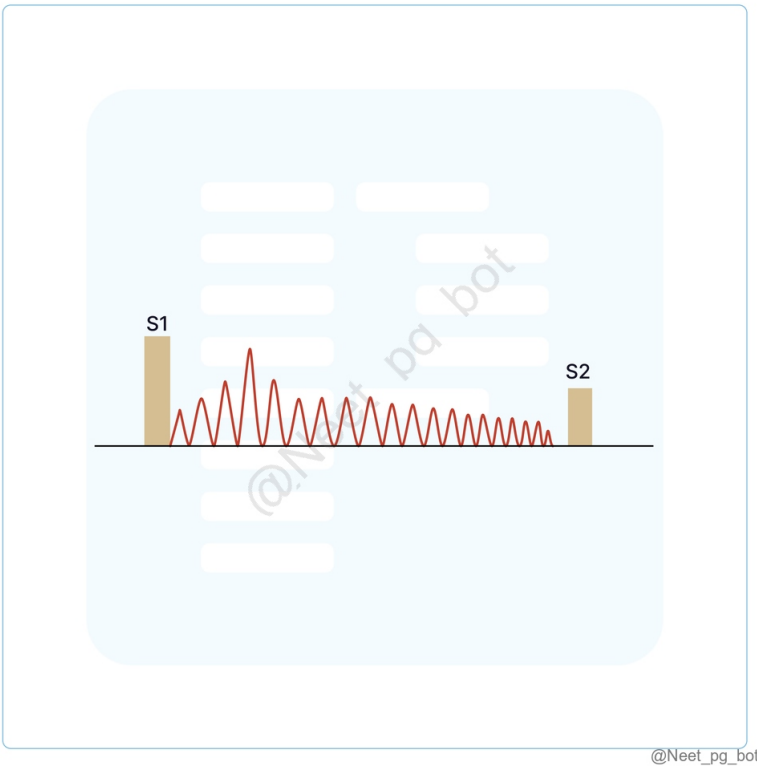

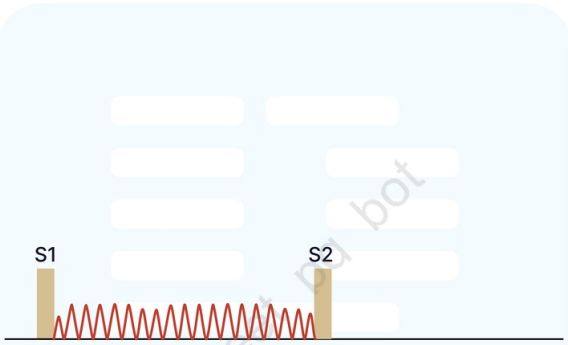

@Neet_pg_bot

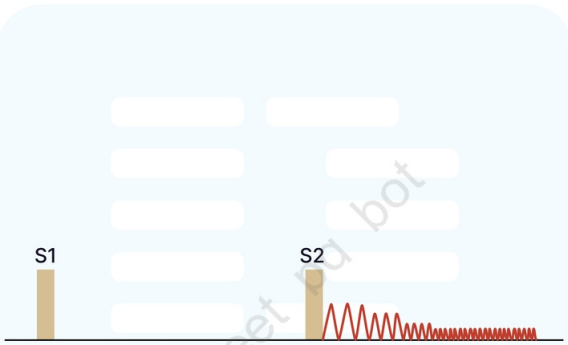

@Neet_pg_bot

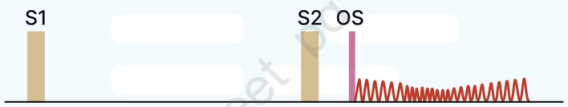

@Neet_pg_bot

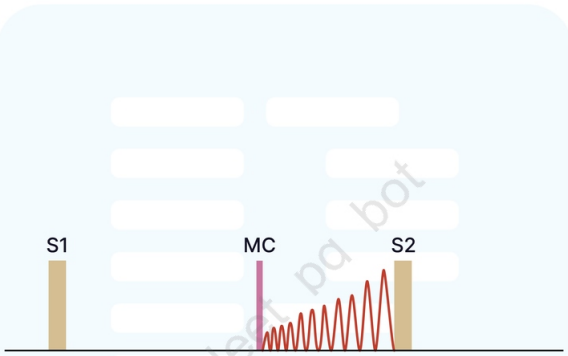

@Neet_pg_bot



@Neet_pg_bot

References:

Harrison's Principles of Internal Medicine, 22nd Edition, Page 283, 286-289. Davidson’s Principles and Practice of Medicine, 24th Edition, Page 460

↑ *Back to this question in Part A*

@Neet_pg_bot

Q3: A 25 year old woman diagnosed with scleroderma presents with exertional dyspnea. You auscultate a high-pitched, decrescendo diastolic murmur at the second left intercostal space, radiating along the left sternal border that increases with inspiration. Which of the following is correct about this case? (Q850440)

A. Graham Steell murmur

B. Austin Flint murmur

C. Carey-Coombs murmur

D. Gibson’s murmur

Correct Answer: A. Graham Steell murmur

■ *Listen (English)*

■ *Listen (Hindi)*

Explanation: This clinical scenario indicates a Graham steel murmur. Graham Steel Murmur Features: High-pitched, decrescendo diastolic murmur is best heard at the second left intercostal space and radiates along the left sternal border. Occurs due to pulmonary regurgitation due to pulmonary artery hypertension . It can become louder with inspiration Causes of pulmonary regurgitation: Pulmonary artery hypertension Severe PAH - annular dilatation of pulmonic valve Tetralogy of Fallot repair Over correction of sub-pulmonic stenosis Post balloon valvotomy Over correction of pulmonic stenosis Marfan syndrome Fibrillin gene defect on chromosome 15 Austin Flint Murmur (Option B): Low-pitched mid-to-late diastolic murmur from severe aortic regurgitation. Carey-Coombs Murmur (Option C): Mid-diastolic murmur of acute rheumatic fever due to inflamed mitral valve. Gibson murmur (Option D): Continuous machine-like murmur of PDA , not a diastolic murmur.

References:

Harrison's Principles of Internal Medicine, 22nd Edition, Page 2049.

↑ *Back to this question in Part A*

@Neet_pg_bot

Q4: A 65-year-old male presents to the clinic with complaints of left arm pain and intermittent dizziness. O/E, you find a notable difference in blood pressure readings: 150/90 mmHg in the right arm and 100/60 mmHg in the left arm. Which condition is least likely to cause this variation? (Q850438)

A. Coarctation of the aorta

B. Aortic dissection

C. Supravalvular aortic stenosis

D. Takayasu arteritis

Correct Answer: C. Supravalvular aortic stenosis

■ *Listen (English)*

■ *Listen (Hindi)*

Explanation: Supravalvular aortic stenosis is at sinotubular junction , meaning just before the aortic arch branches. Hence blood supply to both right brachiocephalic trunk and left common carotid artery will be reduced equally. Supravalvular aortic stenosis occurs above the aortic valve and affects blood flow from the root , not the branches. It does NOT typically cause a large difference between right and left arm blood pressures , because both subclavian arteries receive blood after the narrowed segment without asymmetrical involvement. Coarctation of the Aorta (CoA) (Option A) typically causes lower blood pressure in the lower extremities compared to the upper extremities, but can also lead to differences between arms due to collateral circulation. Aortic Dissection (Option

B) can cause differences in blood pressure between arms if the dissection extends into the subclavian arteries or affects the branches that supply the arms. Takayasu Arteritis (Option D) is an inflammatory condition that often affects the aorta and its branches and may cause stenosis or occlusion leading to differences in blood pressure between the arms.

References:

Harrison's Principles of Internal Medicine, 22nd Edition, Page 1862.

↑ *Back to this question in Part A*

@Neet_pg_bot

Q5: Match the following cardiac valvular disorders with their specific murmur type: Valvular defect Murmur 1. Aortic stenosis a. Pansystolic murmur increasing with inspiration 2. Mitral regurgitation b. Mid-diastolic rumble with opening snap 3. Mitral stenosis c. Harsh systolic murmur radiating to the carotids 4. Tricuspid regurgitation d. Holosystolic murmur radiating to the axilla (Q850436)

A. 1-b, 2-a, 3-d, 4-c

B. 1-c, 2-b, 3-a, 4-d

C. 1-c, 2-d, 3-b, 4-a

D. 1-d, 2-a, 3-c, 4-b

Correct Answer: C. 1-c, 2-d, 3-b, 4-a

■ *Listen (English)*

■ *Listen (Hindi)*

Explanation: Valvular disease Type of murmur Mitral regurgitation Holosystolic murmur radiating to the axilla. Mitral stenosis Mid-diastolic rumble with an opening snap. Tricuspid stenosis Mid-diastolic murmur Tricuspid regurgitation Blowing holosystolic murmur Aortic regurgitation Decrescendo diastolic murmur Aortic stenosis Crescendo-decrescendo ejection murmur . Pulmonary regurgitation End–diastolic murmur (Graham Steel murmur) Pulmonary stenosis Systolic ejection murmur

References:

Harrison's Principles of Internal Medicine, 22nd Edition, Page 2037-2039, 2044-2045, 2048-2050, 2052-2054, 2063-2064.

↑ *Back to this question in Part A*

@Neet_pg_bot

Q6: A 6-year-old girl with a history of Tetralogy of Fallot repair 12 months ago presents with abdominal swelling and pedal oedema. Cardiac auscultation reveals an early diastolic murmur, and ECG shows right ventricular and atrial enlargement. Considering the suspicion of pulmonary regurgitation, which investigation is most appropriate for further evaluation? (Q850433)

A. Transthoracic echocardiography

B. Cardiac magnetic resonance imaging

C. Transesophageal echocardiography

D. Cardiac catheterisation

Correct Answer: B. Cardiac magnetic resonance imaging

■ *Listen (English)*

■ *Listen (Hindi)*

Explanation: Cardiac MRI is the investigation of choice to diagnose pulmonary regurgitation , especially in patients with repaired congenital heart defects , as it provides more anatomical details and helps precisely access the Right ventricular volume and function. PULMONARY REGURGITATION Investigations Chest X-ray: Enlarged right atrium and ventricular shadow Cardiac MRI: Investigation of choice, especially in patients with repaired congenital heart defects. Echocardiography (transthoracic): It helps assess pulmonary valve morphology and the direction of blood flow. (Option A and C) Cardiac catheterisation is not usually done but can be done during transcatheter pulmonary valve procedures. (Option D) In a patient with pulmonary regurgitation, the MRI specifically identifies: Regurgitant Fraction (RF): It directly measures the volume of blood leaking back into the right ventricle (RV). An RF >30-40% is typically considered severe. RV Volumes and Function: It is the most accurate way to measure Right Ventricular End-Diastolic Volume (RVEDV) and End-Systolic Volume (RVESV) . This helps clinicians decide if the RV is becoming dangerously dilated. Flow Quantification: Using "phase-contrast" imaging, it calculates the net forward flow versus the backward flow across the pulmonary valve. Myocardial Fibrosis: Through Late Gadolinium Enhancement (LGE), MRI can identify scarring in the RV muscle, which is a predictor of arrhythmias and poor outcomes.

References:

Harrison's Principles of Internal Medicine, 22nd Edition, Page 2063-2064.

↑ *Back to this question in Part A*

@Neet_pg_bot

Q7: A 10-year-old girl presents with exercise intolerance and occasional chest pain. Examination reveals a systolic ejection murmur at the left upper sternal border and

elevated jugular venous pressure. An echocardiogram shows a peak systolic gradient of 70 mmHg across the pulmonary valve, raising suspicion for pulmonary valve stenosis. Which of the following set of statements is true regarding this condition? Pulmonic stenosis is always congenital. Dysplastic valves leading to pulmonary stenosis are seen in Noonan syndrome. Severe PS is defined by peak systolic gradient across the PV>64 mmHg Percutaneous balloon valvuloplasty is indicated for all patients. Pulmonic stenosis usually leads to right ventricular hypertrophy. (Q850431)

A. 2 and 5

B. 3 and 4

C. 2,3 and 5

D. 1,2 and 5

Correct Answer: C. 2,3 and 5

■ *Listen (English)*

■ *Listen (Hindi)*

Explanation: Pulmonary stenosis can involve dysplastic valves in Noonan syndrome. It is considered severe when the peak systolic gradient exceeds 64 mmHg and typically leads to right ventricular hypertrophy due to pressure overload. PULMONARY STENOSIS Aetiology It is essentially a congenital disease, but it may be acquired (Statement 1 ruled out) Noonan syndrome (dysplastic pulmonary valve) (Statement 2) Tetralogy of Fallot Carcinoids Bulky vegetation or tumours Pathophysiology Pulmonary stenosis obstructs blood flow from the right ventricle, resulting in increased chamber pressure and subsequent right ventricular hypertrophy. (Statement 5) Right ventricular dysfunction occurs early and at lower pressures due to its reduced adaptability to hemodynamic burden compared to the left ventricle. Severity Defined by the systolic pressure gradient between the RV and PA Severe: Peak systolic gradient >64 mm hg (Statement 3) Moderate: Peak systolic gradient 36-64 mm hg Mild: Peak systolic gradient <36 hh mg Management Medical: Diuretics for symptoms of right-sided heart failure Surgical: Percutaneous pulmonary balloon valvuloplasty (Statement 4 ruled out) is done when Symptomatic patients with moderate to severe PS Asymptomatic patients with peak gradient >64 mmHg or mean gradient > 35 mmHg.

References:

Harrison's Principles of Internal Medicine, 22nd Edition, Page 2063.

↑ *Back to this question in Part A*

@Neet_pg_bot

Q8: A 75-year-old male with a history of long-standing hypertension and atrial fibrillation presents with progressive fatigue & bilateral leg swelling. O/E, the patient

has distended neck veins with the following waveform with a blowing holosystolic murmur that increases with inspiration and radiating to epigastrium. What is the most likely diagnosis? (Q850429)

A. Pulmonary hypertension

B. Tricuspid regurgitation

C. Pulmonary stenosis

D. Mitral regurgitation



Correct Answer: B. Tricuspid regurgitation

■ *Listen (English)*

■ *Listen (Hindi)*

Explanation: This is likely tricuspid regurgitation , as the patient presents with jugular venous distension (prominent C-V waves, rapid Y descent) , ascites, and hepatomegaly. The characteristic finding is a blowing holosystolic murmur at the lower left sternal border, which increases with inspiration. Carvallo’s Sign): The murmur intensifies with inspiration . This occurs because the drop in intrathoracic pressure increases venous return to the right heart, increasing the regurgitant volume. Pulmonary hypertension (Option A): While pulmonary hypertension can eventually lead to right-sided heart failure and secondary TR, it has distinct clinical markers: It features a loud P2 (forceful pulmonary valve closure) rather than a holosystolic murmur. In the JVP, PH is more likely to show a giant "a" wave due to the right atrium contracting against a stiff, non-compliant right ventricle.

Pulmonary Stenosis (PS) (Option C): Pulmonary stenosis involves an obstruction of blood flow from the right ventricle to the pulmonary artery. PS presents with an ejection systolic murmur (crescendo-decrescendo) heard best over the pulmonic area (left upper sternal border), not a holosystolic murmur. Unlike TR, this murmur does not typically intensify with inspiration. Characterized by a prominent "a" wave due to right ventricular hypertrophy. Mitral Regurgitation (MR) (Option D): Mitral regurgitation is a left-sided heart pathology that differs in location and physiology: It causes a holosystolic murmur best heard at the apex with radiation to the axilla . As a left-sided murmur, it does not intensify with inspiration (blood pools in the lungs, reducing left-sided flow). JVP findings are usually normal in isolated MR, as the JVP reflects right-sided pressures.

References:

Harrison's Principles of Internal Medicine, 22nd Edition, Page 2060-2062.

↑ *Back to this question in Part A*

@Neet_pg_bot

Q9: A 66-year-old female presents with fatigue, abdominal discomfort, and swelling in her legs. On examination, she has jugular venous distention with giant ‘a’ waves, hepatomegaly, and ascites. Auscultation reveals a diastolic murmur at the lower left sternal border, which increases in intensity with inspiration. What’s the most likely diagnosis? (Q850426)

A. Mitral stenosis

B. Tricuspid stenosis

C. Constrictive pericarditis

D. Aortic stenosis

Correct Answer: B. Tricuspid stenosis

■ *Listen (English)*

■ *Listen (Hindi)*

Explanation: Tricuspid stenosis Explantion: The diastolic murmur at the lower left sternal border that increases with inspiration, along with jugular venous distention with giant ‘a’ waves , hepatomegaly , and ascites, is suggestive of Tricuspid stenosis. This condition is characterised by restricted blood flow from the right atrium to the right ventricle, often leading to right-sided heart failure symptoms like swelling in the legs, abdominal discomfort, and hepatomegaly. The presence of a diastolic murmur at the lower left sternal border further supports the diagnosis. Primary Causes: Rheumatic Heart Disease: Most common cause Carcinoid Syndrome Infective Endocarditis Congenital: Rare Mitral stenosis (MS) (Option A) causes left atrial pressure overload , leading to pulmonary congestion and dyspnea, often with orthopnea and paroxysmal nocturnal dyspnea . This patient’s presentation is dominated by right-sided heart failure symptoms (ascites, hepatomegaly, oedema) without the significant pulmonary congestion typically seen in MS. Primary Causes: Rheumatic Fever Congenital: "Parachute"

mitral valve. Severe Mitral Annular Calcification Constrictive pericarditis (Option C) causes a thickened, non-compliant pericardium, limiting diastolic filling and leading to systemic venous congestion (jugular venous distension, hepatomegaly, ascites). Heart sounds may be muffled, and a pericardial knock can be present. Unlike tricuspid stenosis, constrictive pericarditis lacks a diastolic murmur. Primary Causes: Idiopathic/Viral: Following an undiagnosed pericarditis. Post-Surgical: Common after cardiac surgery (scarring). Radiation Therapy Tuberculosis Aortic stenosis (Option D) causes left ventricular outflow obstruction, leading to exertional dyspnea, angina, and syncope, with a systolic ejection murmur radiating to the carotids. This patient's right-sided heart failure and diastolic murmur are more consistent with tricuspid stenosis, not aortic stenosis. Primary Causes: Age-related Calcification Bicuspid Aortic Valve Rheumatic Heart Disease:

References:

Harrison's Principles of Internal Medicine, 22nd Edition, Page 2059.

↑ *Back to this question in Part A*

@Neet_pg_bot

Q10: A 69-year-old man presents with severe aortic regurgitation. He reports increasing fatigue, breathlessness, and episodes of dizziness. On auscultation, a diastolic murmur is heard along with a water-hammer pulse, and an echocardiogram shows significant left ventricular dilation and an ejection fraction of 55%. What is the most appropriate management for this patient? (Q850425)

A. Medical management

B. Transcatheter aortic valve implantation

C. Intra-aortic balloon counterpulsation

D. Aortic valve replacement

Correct Answer: D. Aortic valve replacement

■ *Listen (English)*

■ *Listen (Hindi)*

Explanation: Aortic valve replacement is the ideal management for severe aortic regurgitation patients who are symptomatic, irrespective of their LV function. In asymptomatic progressive aortic regurgitation , AVR is advisable if LV dysfunction is evident. Regular non-invasive follow-up, once in 6-12 months, is necessary to monitor the development of myocardial dysfunction , as surgery delayed long after its development has minimal chances of completing LV recovery. Management Type Acute AR Chronic AR Medical (Option A) IV Diuretics (Furosemide) and Vasodilators (Sodium Nitroprusside) are used to stabilise the patient. Beta Blockers are contraindicated as they worsen the symptoms and reduce the cardiac output. Diuretics and Vasodilators like ACEi, CCB, Hydralazine, ARBs (can be used in chronic AR) to manage HTN; Target SBP <140 mm/Hg. For Angina: Nitrates For Syphilis: Benzathine Penicillin, 2.4 million units IM, three doses given with one week gap. Surgical

Aortic valve replacement (AVR) is the treatment of choice, usually within 24 hours of diagnosis. Intra-Aortic Balloon pum p is contraindicated as it worsens the regurgitant flow. (Option C) AVR is indicated when developing LV dysfunction or symptoms . Transcatheter aortic valve implantation (Option B) is not suggeste d due to its limited success in chronic conditions.

References:

Harrison's Principles of Internal Medicine, 22nd Edition, Page 2044-2046.

↑ *Back to this question in Part A*

@Neet_pg_bot

Q11: Match the following signs with specific features Signs Features 1. Muller Sign a) Systolic pulsations of the Spleen 2. Rosenbach sign b) Visible systolic pulsation of the uvula 3. Gerhardt's sign c) Jarring motion of the head with each heartbeat 4. De-Musset sign d) Systolic pulsations of the Liver (Q850421)

A. 1-b, 2-d, 3-a, 4-c

B. 1-a, 2-c, 3-b, 4-d

C. 1-c, 2-a, 3-d, 4-b

D. 1-d, 2-b, 3-c, 4-a

Correct Answer: A. 1-b, 2-d, 3-a, 4-c

■ *Listen (English)*

■ *Listen (Hindi)*

Explanation: Signs of Aortic Regurgitation Muller Sign It is a visible systolic pulsation of the uvula Rosenbach sign Systolic pulsations of the Liver Gerhardt's sign Systolic pulsations of the Spleen Quincke's sign Repeatedly alternating blushing and blanching of capillaries in the nail folds upon palpation (Capillary Pulsations) Landolphi sign Alternating systolic constriction and diastolic dilatation of pupils Traube Sign It is pistol shot sounds that are heard while auscultating over the femoral artery. Water-Hammer pulse Strong pulse that rises quickly and then drops off suddenly. Duroziez Sign It is a to-and-fro murmur heard while auscultating the femoral artery. De-Musset sign The jarring motion of the head with each heartbeat

References:

Harrison's Principles of Internal Medicine, 22nd Edition, Page 2044-2045.

↑ *Back to this question in Part A*

@Neet_pg_bot

Q12: A 72-year-old male presents with complaints of worsening dyspnea, angina and orthopnea. Physical examination reveals a loud diastolic murmur at the left sternal border and a widened pulse pressure. An echocardiogram indicates significant left ventricular dilation. What is the likely estimated regurgitant volume in this condition to label as severe valvular dysfunction? (Q850419)

A. < 35 ml/beat

B. > 35 ml/beat

C. < 60 ml/beat

D. > 60 ml/beat

Correct Answer: D. > 60 ml/beat

■ *Listen (English)*

■ *Listen (Hindi)*

Explanation: Widened pulse pressure with diastolic murmur with the given symptom profile points to Aortic regurgitation. The regurgitant volume in a patient with severe aortic regurgitation exceeds 60 mL per beat. Aortic regurgitation severity: Degree of regurgitant Regurgitant volume Regurgitant fraction Mild <30 ml/beat <30 % Moderate 30-59 ml/beat 30-50 % Severe ≥60 ml/beat >50 %

References:

Harrison's Principles of Internal Medicine, 22nd Edition, Page 2044-2045.

↑ *Back to this question in Part A*

@Neet_pg_bot

Q13: A 32-year-old female presents with palpitations, chest discomfort, and fatigue. A mid-systolic click and late systolic murmur are heard at the apex. Echocardiography shows mitral valve leaflets billowing into the left atrium during systole. Which of the following is leading cause of this presentation? (Q850397)

A. Inflammation of the mitral valve due to rheumatic fever

B. Fibrotic changes affecting the mitral valves

C. Rupture of the tendinae of the mitral valve

D. Myxomatous degeneration of mitral valve apparatus.

Correct Answer: D. Myxomatous degeneration of mitral valve apparatus.

■ *Listen (English)*

■ *Listen (Hindi)*

Explanation: Myxomatous degeneration of the mitral valve apparatus leads to mitral valve leaflets billowing into the left atrium during systole, thus causing Mitral valve prolapse. Inflammation of the mitral valve due to rheumatic fever (Option A) occurs in Rheumatic heart disease, which can result in fibrotic changes in the mitral valve (Option B), leading to mitral stenosis, which produces a low-pitched diastolic rumble. Rupture of the tendinae of the mitral valve (Option C) leads to acute severe mitral regurgitation, which can be a complication of mitral valve prolapse but is not the cause.

References:

Harrison's Principles of Internal Medicine, 22nd Edition, Page 2057.

↑ *Back to this question in Part A*

@Neet_pg_bot

Q14: A 65-year-old woman reports experiencing mild chest pain and shortness of breath on exertion. On examination, harsh ejection- systolic murmur is noted, best heard at the right second intercostal space and radiating to the carotids. An Echocardiogram shows an aortic valve area of 0.9 cm^2. Which stage of aortic stenosis is present and what is the ideal management? (Q850417)

A. Stage B and TAVR

B. Stage D and Statins

C. Stage B and Statins

D. Stage D and TAVR

Correct Answer: D. Stage D and TAVR

■ *Listen (English)*

■ *Listen (Hindi)*

Explanation: Aortic Valve area of < 1 cm^2 (Severe Stenosis) along with symptoms are categorized into Stage D and is managed by Transcatheter Aortic Valve Replacement (TAVR). Stage Aortic Valve area

References:

Harrison's Principles of Internal Medicine, 22nd Edition, Page 2039.

↑ *Back to this question in Part A*

@Neet_pg_bot

Q15: A 72-year-old patient presents with angina and shortness of breath on exertion. Physical examination reveals a slow-rising carotid pulse and a systolic ejection murmur. Which of the following is most likely to be observed in this patient? (Q850415)

A. Triple vessel disease

B. Right atrial enlargement

C. Medial displacement of heaving apex

D. Junctional Tacycardia

Correct Answer: A. Triple vessel disease

■ *Listen (English)*

■ *Listen (Hindi)*

Explanation: Aortic stenosis has slow rising anacortic pulse with ejection systolic murmur. It is seen in geriatric population and hence these patients have co-existent triple vessel disease. Left atrial hypertrophy causing double apical impulse will be seen in these patients. Note that hypertrophy causes lateral displacement of apex beat and not medial.

References:

Harrison's Principles of Internal Medicine, 22nd Edition, Page 2037-2038.

↑ *Back to this question in Part A*

@Neet_pg_bot

Q16: A 65-year-old patient presents to the clinic with increasing fatigue and shortness of breath on exertion. O/E a harsh, systolic crescendo-decrescendo ejection murmur is noted at the right second intercostal space. Which of the following is not seen in this condition ? (Q850413)

A. Left axis deviation

B. Angina pectoris

C. Syncope on exertion

D. Water Hammer pulse

Correct Answer: D. Water Hammer pulse

■ *Listen (English)*

■ *Listen (Hindi)*

Explanation: The clinical scenario described indicates case of Aortic stenosis, characterized by a harsh systolic crescendo-decrescendo ejection murmur typically heard at the right second intercostal space. Water hammer pulse is seen in Aortic regurgitation while Aortic stenosis has anacrotic pulse. Left axis deviation is seen in AS due to concentric left ventricular hypertrophy.

References:

Harrison's Principles of Internal Medicine, 22nd Edition, Page 2037-2038.

↑ *Back to this question in Part A*

@Neet_pg_bot

Q17: A 72-year-old woman presents with fatigue and progressive shortness of breath, particularly when climbing stairs. During the physical examination, a harsh, systolic ejection murmur is heard at the right second intercostal space, radiating to the carotids. Which of the following factors is least likely to be associated with the development of the condition? (Q850412)

A. Mediastinal irradiation

B. Mutation in NOTCH1

C. Prior rheumatic inflammation

D. Systemic lupus erythematosus

Correct Answer: D. Systemic lupus erythematosus

■ *Listen (English)*

■ *Listen (Hindi)*

Explanation: The given clinical scenario with systolic ejection murmur heard at the right second intercostal space radiating to the carotids suggests Aortic Stenosis . While mediastinal irradiation, mutation in NOTCH1, and prior rheumatic inflammation are all factors associated with aortic valve dysfunction. Systemic lupus erythematosus is less directly linked to the development of Aortic Stenosis. Etiology of Aortic stenosis (AS): Degenerative Calcification The primary cause of aortic stenosis (AS) in adults, often due to: Congenital Bicuspid Aortic Valve

(BAV) : Approximately 53% of cases. Trileaflet Valve Deterioration Previous Rheumatic Fever (Option C ruled out) : Inflammation can lead to scarring and calcification. Mediastinal Radiation (Option A ruled out) Cause late scarring and calcification of the aortic leaflets. Bicuspid Aortic Valve Disease Most common congenital heart valve defect, with a male predominance (2–4:1) . Genetic Factors : Mutations in NOTCH1 (Option B ruled out) , GATA5 , and GATA4 have been noted

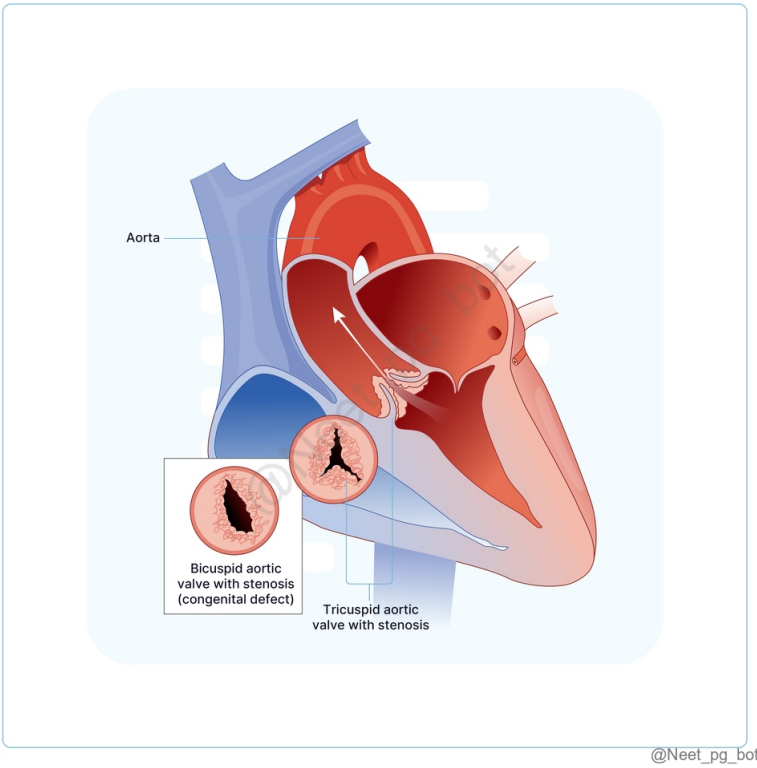

References:

Harrison's Principles of Internal Medicine, 22nd Edition, Page 2035-2037.

↑ *Back to this question in Part A*

@Neet_pg_bot

Q18: A 65-year-old male presents with recurrent syncopal episodes. Auscultation reveals an ejection systolic murmur heard at the right 2 nd intercostal space and radiates to the carotids. The murmur also becomes higher-pitched when heard at the apex. ECG shows left axis deviation with a normal sinus rhythm. Which condition is most likely in this patient? (Q850410)

A. Sick Sinus syndrome

B. Aortic stenosis

C. Complete heart block

D. Pulmonary stenosis

Correct Answer: B. Aortic stenosis

■ *Listen (English)*

■ *Listen (Hindi)*

Explanation: Aortic Stenosis Explantion : The given clinical presentation of Syncopal episodes with an Ejection systolic murmur in the geriatric age group points to valvular aortic stenosis. The ejection systolic murmur of aortic stenosis has two components: Low-frequency, harsh component – heard at right upper sternal border High-frequency musical component – transmitted to the apex = Gallavardin phenomenon/effect Gallavardin Effect: It refers to the phenomenon where a murmur of aortic stenosis (AS) becomes higher-pitched and more acoustically pure when auscultated at the apex of the heart despite originating from the aortic region. The ejection (mid) systolic (Crescendo-decrescendo) murmur of AS typically starts shortly after S1, increases in intensity, peaks during ejection, and ends just before aortic valve closure. Sick Sinus Syndrome (Option A): Causes bradycardia and syncope but no systolic murmur . Complete Heart Block (Option C): Syncope with AV dissociation , not normal sinus rhythm; no AS-type murmur . Pulmonary Stenosis (Option D): Murmur at left upper sternal border, no carotid radiation , no Gallavardin effect.

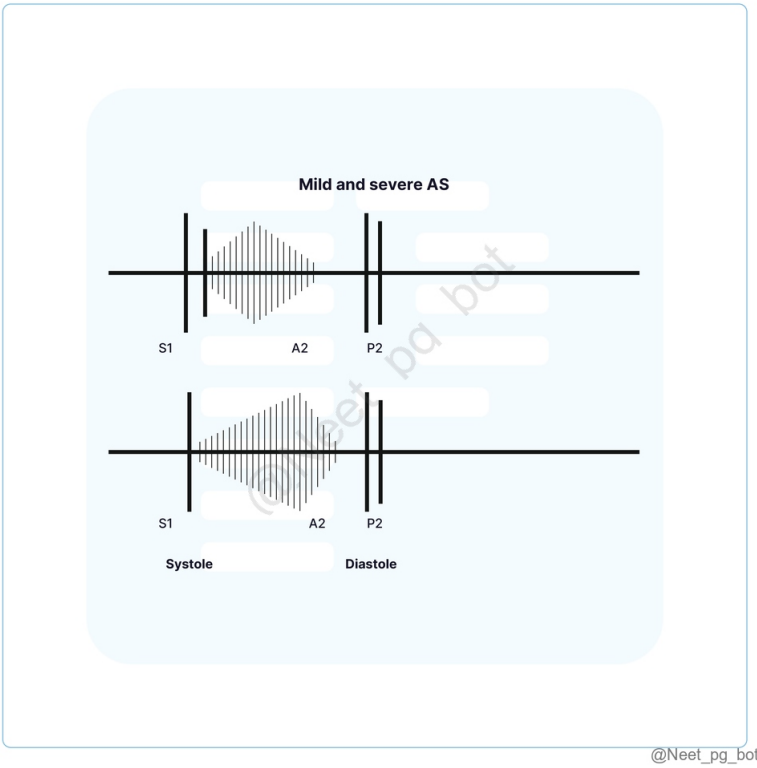

@Neet_pg_bot

References:

Harrison's Principles of Internal Medicine, 22nd Edition, Page 2037.

↑ *Back to this question in Part A*

@Neet_pg_bot

Q19: A 50-year-old female patient presents with exertional dyspnea and a history of rheumatic fever. Echocardiogram shows severe mitral stenosis with calcification. Which of the following is the most appropriate management strategy for her condition? (Q850408)

A. Initiate warfarin therapy

B. Percutaneous mitral balloon commissurotomy (PMBC)

C. Schedule for mitral valve replacement

D. Start beta-blockers and diuretics

Correct Answer: C. Schedule for mitral valve replacement

■ *Listen (English)*

■ *Listen (Hindi)*

Explanation: Mitral valve replacement is indicated for significant symptoms in patients with calcified severe mitral stenosis, particularly when heavy calcification makes the valve unsuitable for balloon valvuloplasty. Management of Mitral Stenosis: Medical Management: Patients with mild symptoms may be managed medically. Penicillin Prophylaxis : Essential for preventing rheumatic fever in risk patients. Symptomatic Relief : Sodium restriction, diuretics, beta-blockers (Option D ruled out), and Calcium channel blockers help manage symptoms and control heart rate in atrial fibrillation (AF). Anticoagulation : Warfarin for patients with AF, history of thromboembolism, or left atrial thrombus; INR target 2–3. (Option A ruled out) Cardioversion : For recent-onset AF, ensure anticoagulation for at least three weeks. Infective Endocarditis Prophylaxis : Routine antibiotic prophylaxis is no longer recommended. Interventional: Considered if patients remain symptomatic despite medical management or if pulmonary hypertension develops/Severe MS (<1.5 cm^2) Balloon valvuloplasty Mitral valvotomy/Mitral valve replacement Procedure Indications / Requirements Mitral Balloon Valvuloplasty (PMBC) (Option B ruled out) Significant symptoms present Isolated mitral stenosis (no or trivial mitral regurgitation) Mobile, non-calcified valve/sub valve apparatus on echocardiogram Left atrium free of thrombus Mitral Valve Replacement (Option C) Substantial mitral regurgitation Rigid and calcified valve Presence of thrombus formation Mitral Balloon Valvuloplasty/Percutaneous Mitral Balloon Commissurotomy:

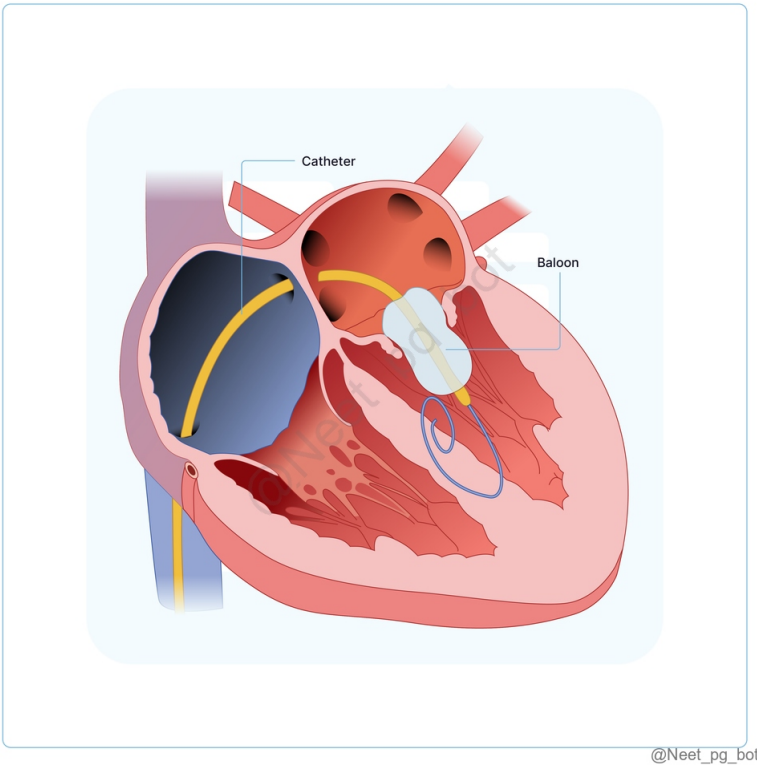

References:

Harrison's Principles of Internal Medicine, 22nd Edition, Page 2051-2052.

↑ *Back to this question in Part A*

@Neet_pg_bot

Q20: A 48-year-old female presents with worsening exertional dyspnea and fatigue. She has a history of rheumatic fever during her childhood. Examination shows diastolic murmur at the cardiac apex with pronounced opening snap. Which of the following findings is least likely to be present in this case? (Q850406)

A. Left atrial enlargement

B. Reduced mitral valve area

C. Right ventricular hypertrophy

D. Heaving apex beat

Correct Answer: D. Heaving apex beat

■ *Listen (English)*

■ *Listen (Hindi)*

Explanation: The presentation is classic for rheumatic mitral stenosis (diastolic murmur at apex with opening snap, history of rheumatic fever). MS leads to reduced mitral valve area , left atrial enlargement , and, in advanced disease, pulmonary hypertension with right ventricular hypertrophy . A heaving apex beat suggests left ventricular pressure overload (e.g., aortic stenosis), which is not typical of isolated mitral stenosis , where the apex is usually tapping or normal. Left atrial enlargement (Option A) is expected due to chronic pressure overload from obstructed mitral inflow. Reduced mitral valve area (Option B) is the hallmark anatomical change in mitral stenosis. Right ventricular hypertrophy (Option C) can occur secondary to pulmonary hypertension from long-standing mitral stenosis.

References:

Harrison's Principles of Internal Medicine, 22nd Edition, Page 2049

↑ *Back to this question in Part A*

@Neet_pg_bot

Q21: A 40-year-old female with a history of rheumatic heart disease comes to the OPD for a regular follow-up. Echocardiography confirmed the presence of severe mitral regurgitation . When considering her treatment options, which of the following interventions should not be included in her management plan? (Q850404)

A. Use of Apixaban if her CHA2DS2-VASc score ≥2

B. Cardiac resynchronization therapy, when indicated

C. Mitral valve repair if EF < 60%

D. Vitamin K antagonists

Correct Answer: A. Use of Apixaban if her CHA2DS2-VASc score ≥2

■ *Listen (English)*

■ *Listen (Hindi)*

Explanation: In patients with rheumatic heart disease (RHD) and mitral valve involvement —especially rheumatic mitral stenosis or regurgitation with atrial fibrillation —the recommended anticoagulant is a Vitamin K antagonist (Warfarin) . NOACs (e.g., Apixaban) are not recommended because major trials excluded patients with significant rheumatic valvular disease, and their safety/effectiveness is not established in this group. Cardiac resynchronization therap y (Option B): Appropriate if standard CRT criteria are met (EF ≤ 35%, LBBB). RHD is not a contraindication , so this should be included. Mitral valve repair if EF < 60% (Option C): Correct recommendation in severe chronic MR; EF < 60% indicates early LV dysfunction. Vitamin K antagonists (Option D): Preferred anticoagulants in rheumatic mitral valve disease, especially with AF; should be included.

References:

Harrison’s Principles of Internal Medicine, 22nd Edition, Page 3450.

↑ *Back to this question in Part A*

@Neet_pg_bot

Q22: A 65-year-old female presents to the clinic with complaints of fatigue, shortness of breath on exertion, and palpitations. On physical examination, a systolic thrill is palpable at the cardiac apex. Echocardiography showed severe backflow of blood from the left ventricle to the left atrium during ventricular systole. What kind of murmur is most likely to be heard during cardiac auscultation of this patient? (Q850401)

A. Continuous murmur

B. An opening snap followed by a diastolic murmur

C. Holosystolic murmur, best heard at the apex

D. Crescendo decrescendo systolic murmur best heard at the base

Correct Answer: C. Holosystolic murmur, best heard at the apex

■ *Listen (English)*

■ *Listen (Hindi)*

Explanation: The clinical presentation and echocardiography show features of severe mitral regurgitation , so on cardiac auscultation, a holosystolic murmur will most likely be heard at the cardiac apex. Continuous murmurs (Option A) occur during both systole and diastole, which is not characteristic of mitral regurgitation. They are typically associated with conditions that involve persistent blood flow between high- and low-pressure areas, such as in patent ductus arteriosus (PDA), where there is a constant flow of blood between the aorta and pulmonary artery. An opening snap followed by a diastolic murmur (Option B) is heard in mitral stenosis . It occurs due to the narrowed mitral valve opening during diastole, resulting in an opening snap followed by a low-pitched diastolic rumble. Crescendo-decrescendo systolic murmur (Option C) is typical of aortic stenosis . It is heard best at the base of the heart and radiates to the carotids. This murmur reflects the turbulent flow of blood through the narrowing of the aortic valve.

References:

Harrison’s Principle of Internal Medicine, 22nd Edition, Page 2053.

↑ *Back to this question in Part A*

@Neet_pg_bot

Q23: Which of the following is not a cause of primary chronic mitral regurgitation? (Q850400)

A. Ischemic cardiomyopathy

B. Rheumatic fever

C. Infective endocarditis

D. Radiation

Correct Answer: A. Ischemic cardiomyopathy

■ *Listen (English)*

■ *Listen (Hindi)*

Explanation: Ischemic cardiomyopathy causes secondary (functional) MR due to LV dilation or papillary muscle displacement , leading to poor leaflet coaptation. Primary MR occurs due to intrinsic structural abnormalities of the mitral valve (leaflets, chordae, papillary muscles). Rheumatic fever , infective endocarditis , and radiation (Option B,C & D) : all directly damage the mitral valve apparatus , making them causes of primary MR.

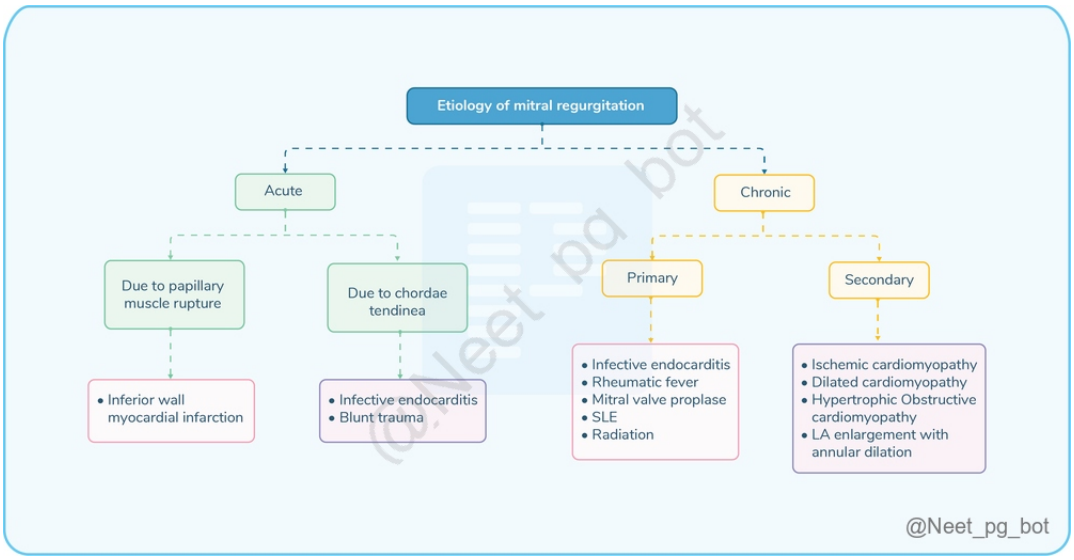

References:

Harrison's Principles of Internal Medicine, 22nd Edition, Page 2052.

↑ *Back to this question in Part A*

@Neet_pg_bot

Q24: A 65-year-old diabetic male with mitral valve prolapse presents with palpitations. Pulse 130/min irregular, BP on admission is 160/100 mmHg. He also has a history of infective endocarditis. Which of the following statements regarding his management is not true? (Q850398)

A. Anticoagulation therapy should be avoided due to low CHADS2Vasc score

B. Beta-blockers should be initiated for his palpitations

C. Mitral valve repair is preferred over mitral valve replacement

D. Prophylactic antibiotics should be initiated

Correct Answer: A. Anticoagulation therapy should be avoided due to low CHADS2Vasc score

■ *Listen (English)*

■ *Listen (Hindi)*

Explanation: As the patient has a CHA2DS2-VASc score of 3. (Age, DM and HTN) anticoagulation therapy should be initiated to reduce the risk of cerebrovascular accident . Prophylactic Antibiotics are given if patient has previous history of infective endocarditis. (Option D) Beta blockers will be useful for palpitations and patient should be scheduled for mitral valve prolapse repair to prevent further damage to left atria. (Option B) Repair

preserves the native valve, improves outcomes, and decreases postoperative complications. (Option C)

References:

Harrison’s Principles of Internal Medicine, 22nd Edition, Page 1950.

↑ *Back to this question in Part A*

@Neet_pg_bot

• [01_Cardiology] 002 Heart Sounds And Murmurs

« Back to Folder Directory

[01_Cardiology] 002 Heart Sounds And Murmurs — Quick Jump

Q1 (p. 1104)	*Q2 (p. 1105)*	*Q3 (p. 1106)*	*Q4 (p. 1107)*	*Q5 (p. 1107)*	*Q6 (p. 1108)*
Q7 (p. 1109)	*Q8 (p. 1110)*	*Q9 (p. 1111)*	*Q10 (p. 1113)*	*Q11 (p. 1114)*	*Q12 (p. 1115)*
Q13 (p. 1116)	*Q14 (p. 1118)*	*Q15 (p. 1119)*	*Q16 (p. 1120)*	*Q17 (p. 1121)*	*Q18 (p. 1122)*
Q19 (p. 1123)	*Q20 (p. 1124)*	*Q21 (p. 1125)*	*Q22 (p. 1125)*	*Q23 (p. 1126)*	*Q24 (p. 1127)*
Q25 (p. 1128)					

Q1: A 55-year-old man presents with gradually worsening shortness of breath and fatigue. He has a history of tuberculosis treated 10 years ago. Physical examination reveals elevated jugular venous pressure (JVP) that rises paradoxically with inspiration. Which of the following is the most likely diagnosis? (Q850497)

A. Pulmonary embolism

B. Restrictive cardiomyopathy

C. TB pericardial effusion

D. Constrictive pericarditis

Correct Answer: D. Constrictive pericarditis

■ *Listen (English)*

■ *Listen (Hindi)*

Explanation: A history of tuberculosis with progressive dyspnea , elevated JVP, and Kussmaul’s sign (JVP rising with inspiration) strongly suggests constrictive pericarditis . TB is a leading cause of constrictive pericarditis in endemic regions. Rigid, calcified pericardium restricts ventricular filling → right-sided heart failure signs + Kussmaul’s sign. Pulmonary embolism (Option A) Does not cause Kussmaul’s sign; presents with acute dyspnea, chest pain, and tachycardia. Restrictive cardiomyopathy (Option B) May mimic constriction but Kussmaul’s sign is less prominent , and TB history more strongly favors constrictive pericarditis. TB pericardial effusion (Option C) Tamponade physiology shows pulsus paradoxus , not Kussmaul’s sign; JVP falls on inspiration.

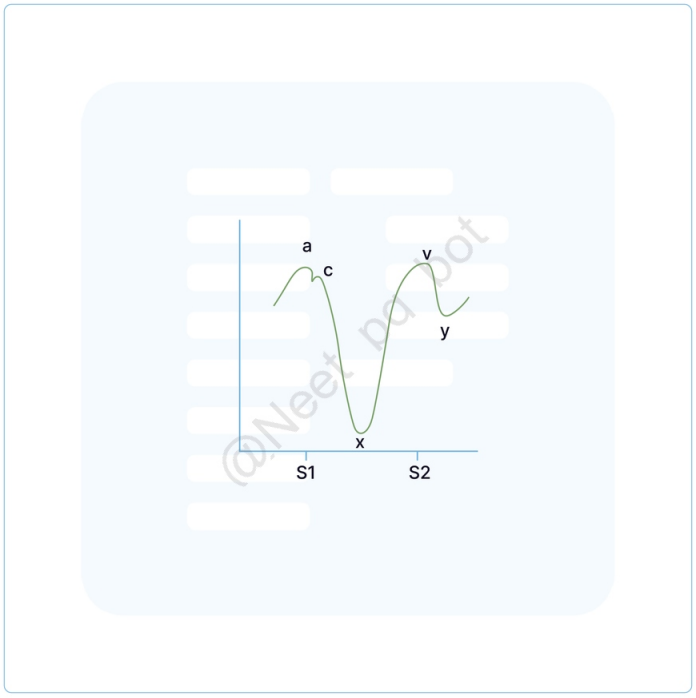

@Neet_pg_bot

References:

Harrison's Principles of Internal Medicine, 22nd Edition, Page 1906, 2081.

↑ *Back to this question in Part A*

@Neet_pg_bot

Q2: Which of the following statements is correct about grades of murmurs? (Q850755)

A. Grade 1 murmur is very loud and audible even without a stethoscope

B. Grade 2 murmur is faint but audible with a stethoscope

C. Grade 4 murmur has a loud intensity without thrill

D. Grade 6 murmur is very faint and heard with difficulty

Correct Answer: B. Grade 2 murmur is faint but audible with a stethoscope

■ *Listen (English)*

■ *Listen (Hindi)*

Explanation: Grading of Heart Murmurs - Levine scale (commonly used scale): Grade 1 Very faint, heard only with difficulty. Grade 2 Faint but audible with a stethoscope. Grade 3 Moderately loud, easily audible. Grade 4 Loud, with a palpable thrill. Grade 5 Very loud, with a palpable thrill, heard with the edge of the stethoscope. Grade 6 Extremely loud, audible without a stethoscope, with a palpable thrill.

References:

Harrison's Principles of Internal Medicine, 22nd Edition, Page 283.

↑ *Back to this question in Part A*

@Neet_pg_bot

Q3: Match the following murmurs to their characteristics Murmurs Characteristics 1. Mitral Stenosis A. High-pitched, crescendo-decrescendo murmur best heard at the right upper sternal border. 2. Aortic Stenosis B. Holosystolic murmur radiating to the axilla, often with a displaced apical impulse. 3. Patent Ductus Arteriosus C. Early diastolic decrescendo murmur best heard along the left sternal border. 4. Hypertrophic Cardiomyopathy D. "Machine-like" continuous murmur heard best at the left infraclavicular area. 5. Mitral Regurgitation E. Loud S1, opening snap, and low-pitched diastolic murmur heard best at the apex. 6. Aortic Regurgitation F. Systolic ejection murmur, often with a crescendo-decrescendo pattern, best heard at the right upper sternal border, radiating to the carotids. (Q850756)

A. 1 - E, 2 - F, 3 - D, 4 - A, 5 - B, 6 - C

B. 1 - E, 2 - F, 3 - A, 4 - D, 5 - C, 6 - B

C. 1 - F, 2 - E, 3 - D, 4 - A, 5 - C, 6 - B

D. 1 - F, 2 - E, 3 - A, 4 - D, 5 - B, 6 - C

Correct Answer: A. 1 - E, 2 - F, 3 - D, 4 - A, 5 - B, 6 - C

■ *Listen (English)*

■ *Listen (Hindi)*

Explanation: Mitral Stenosis Low-pitched diastolic murmur with opening snap, best at the apex. Accentuated by exercise or Valsalva's maneuver. Aortic Stenosis Systolic ejection murmur, crescendo-decrescendo pattern, radiating to carotids Patent Ductus Arteriosus A continuous, machine-like murmur, heard at the left infraclavicular area Hypertrophic Cardiomyopathy Harsh systolic murmur, crescendo-decrescendo pattern Mitral Regurgitation Holosystolic murmur radiating to the axilla Aortic Regurgitation Early diastolic decrescendo murmur, best heard at the left sternal border Graham Steell Murmur Early diastolic decrescendo murmur due to pulmonary regurgitation, heard best at the left upper sternal border. Austin Flint Murmur Low-pitched, rumbling diastolic

murmur due to severe aortic regurgitation causing turbulent flow in the left ventricle.

References:

Harrison's Principles of Internal Medicine, 22nd Edition, Page 285, 2037-2038, 2044, 2049, 2053, 2072.

↑ *Back to this question in Part A*

@Neet_pg_bot

Q4: A 35-year-old male presents with exertional chest pain and dyspnea. On physical examination, you note a harsh mid systolic murmur that is loudest at the left sternal border and increases in intensity with the Valsalva maneuver. Which of the following is the most likely cause? (Q850752)

A. Hypertrophic Cardiomyopathy

B. Aortic Stenosis

C. Pulmonary Stenosis

D. Atrial Septal Defect

Correct Answer: A. Hypertrophic Cardiomyopathy

■ *Listen (English)*

■ *Listen (Hindi)*

Explanation: Hypertrophic cardiomyopathy causes a harsh mid-systolic murmur at the left sternal border that increases with Valsalva due to dynamic left ventricular outflow tract obstruction becoming more pronounced as preload decreases. Aortic and pulmonary stenosis (Option B and C) have ejection systolic murmurs that will decrease with Valsalva. Atrial Septal Defect (Option D) does not have shunt murmur.

References:

Harrison's Principles of Internal Medicine, 22nd Edition, Page 2006-2007.

↑ *Back to this question in Part A*

@Neet_pg_bot

Q5: A 45-year-old male presents shortness of breath on exertion. Examination reveals a pansystolic murmur heard best at the apex of the heart, radiating to the axilla. The intensity of the murmur does not change with inspiration. Which of the following is

the most likely diagnosis? (Q850753)

A. Chronic Mitral Regurgitation

B. Chronic Tricuspid Regurgitation

C. Aortic Stenosis

D. Acute Mitral Regurgitation

Correct Answer: A. Chronic Mitral Regurgitation

■ *Listen (English)*

■ *Listen (Hindi)*

Explanation: Mitral Regurgitation (MR) is characterized by a high-pitched holosystolic murmur that is best heard at the apex of the heart and radiates to the axilla. It does not change with inspiration. Causes of Chronic Mitral Regurgitation: Primary Secondary (Annulus dilatation: Mitral valve prolapse Rheumatic fever (children) Infective endocarditis Atrial septal defect (Ostium primum) Ostium primum - cleft mitral valve Dilated cardiomyopathy Cause - Alcohol Hypertrophic cardiomyopathy Systolic anterior movement of mitral valve → leakage of blood Long standing Atrial fibrillation with left atrial enlargement On Auscultation in Chronic Mitral Regurgitation: Pansystolic murmur (Uniform intensity throughout systole) Flow murmur (mid-diastolic murmur) S3 is heard in chronic mitral regurgitation. Treatment of Chronic Mitral Regurgitation: MVRP (Mitral Valve Repair) MVR (Mitral Valve Replacement) Transcatheter based approach - Mitra-clip: Removes redundant/damaged mitral valve tissue Mitra-clip squeeze valve → valve leaflets function appropriately → leakage of blood minimized Chronic tricuspid regurgitation (Option B) becomes louder on inspiration. Best heard in the lower left sternal edge. Aortic Stenosis (Option C) presents with ejection systolic murmur. Best heard in the right second intercostal space, may radiate to the carotid arteries. Acute mitral Regurgitation (Option D) causes early murmur due to rapid rise in left atrial pressure. Best heard in the apex, may radiate to the axilla.

References:

Harrison's Principles of Internal Medicine, 22nd Edition, Page 2053-2054.

↑ *Back to this question in Part A*

@Neet_pg_bot

Q6: A 7-year-old child is brought to the clinic for evaluation of high blood pressure detected during a routine check-up. On physical examination, the blood pressure is higher in the arms compared to the legs. A continuous murmur is heard over the back, near the left scapula. Which of the following is the most likely diagnosis? (Q850754)

A. Takayau Arteritis

B. Coarctation of the Aorta

C. Atrial Septal Defect

D. Aortic Dissection

Correct Answer: B. Coarctation of the Aorta

■ *Listen (English)*

■ *Listen (Hindi)*

Explanation: Coarctation of the aorta is the narrowing of the aortic arch, typically distal to the left subclavian artery, leading to higher blood pressure in the arms than in the legs and a continuous murmur over the back. Clinical features: Can cause cardiac failure in newborns but may be asymptomatic in older children or adults. Hypertension above narrowing may cause headaches; reduced blood flow below may lead to leg cramps or weakness. Radio-femoral delay. A continuous murmur is typically heard over the back near the left scapula. Additional sound (ejection click) may be heard in the aortic area if a bicuspid aortic valve is present. Collateral circulation develops through periscapular, internal mammary, and intercostal arteries, sometimes causing localized bruits. Takayasu arteritis (Option A) is a large-vessel vasculitis that can cause pulse discrepancies and limb claudication, and does not typically present with a continuous murmur or blood pressure gradient between limbs. Atrial septal defect (Option C) causes a fixed split of the second heart sound and a systolic murmur due to increased flow across the pulmonary valve, but it does not cause blood pressure differences between the arms and legs. Aortic dissection (Option D presents with sudden, severe chest or back pain and may cause unequal blood pressures in the arms and not associated with a continuous murmur.

References:

Harrison's Principles of Internal Medicine, 22nd Edition, Page 2076-2077.

↑ *Back to this question in Part A*

@Neet_pg_bot

Q7: In aortic regurgitation, capillary pulsations can be seen in the nail beds. What is this sign called? (Q850751)

A. Quincke’s sign

B. Duroziez’s sign

C. de Musset’s sign

D. Hill sign

Correct Answer: A. Quincke’s sign

■ *Listen (English)*

■ *Listen (Hindi)*

Explanation: Quincke’s sign is capillary pulsation visible in the nail beds and is a classic peripheral sign of aortic regurgitation due to wide pulse pressure . Other signs of Aortic Regurgitation: deMusset's sign (Option C ruled out) A head bob occurring with each cardiac cycle Duroziez's sign (Option B ruled out) A systolic and diastolic bruit heard when the femoral artery is partially compressed. Hill's sign (option D) Popliteal cuff systolic pressure exceeds brachial pressure by more than 20 mmHg. Rosenbach's sign Systolic pulsations of the liver. Gerhard's sign Systolic pulsations of the spleen. Mueller's sign Systolic pulsations of the uvula. Becker's sign Visible pulsations of the retinal arteries and pupils. Quincke's pulses Visible Capillary pulsations in the nailbeds after holding the tip of the nail. Traube's sign A pistol shot murmur (systolic and diastolic sounds) heard over the femoral arteries. Mayne's sign More than a 15 mmHg decrease in DBP with arm elevation from the value obtained with the arm in the standard position.

References:

Harrison's Principles of Internal Medicine, 22nd Edition, Page 2044-2045.

↑ *Back to this question in Part A*

@Neet_pg_bot

Q8: From the list of ECG findings given below which will not be seen in mitral stenosis? (Q850749)

A. Tall R waves in V1-V3

B. Bifid P wave

C. Atrial fibrillation

D. Tall tented T-waves

Correct Answer: D. Tall tented T-waves

■ *Listen (English)*

■ *Listen (Hindi)*

Explanation: Tall tented T waves are seen in Hyperkalemia and not in mitral stenosis. Tall R waves in V1–V3 (Option A) can be seen in mitral stenosis due to right ventricular hypertrophy secondary to pulmonary hypertension. Bifid P wave (Option B) (also called P mitrale) is a classic sign of left atrial enlargement, commonly seen in mitral stenosis. Atrial fibrillation (Option C) frequently occurs in mitral stenosis due to left atrial dilation and increased pressure.

References:

Harrison's Principles of Internal Medicine, 22nd Edition, Page 2049.

↑ *Back to this question in Part A*

Q9: Which of the following schematic represents murmur of mitral stenosis? (Q850748)

Correct Answer: Unknown

- *Listen (English)*
- *Listen (Hindi)*

Explanation: Mitral stenosis presents with a mid-diastolic murmur with presystolic accentuation.

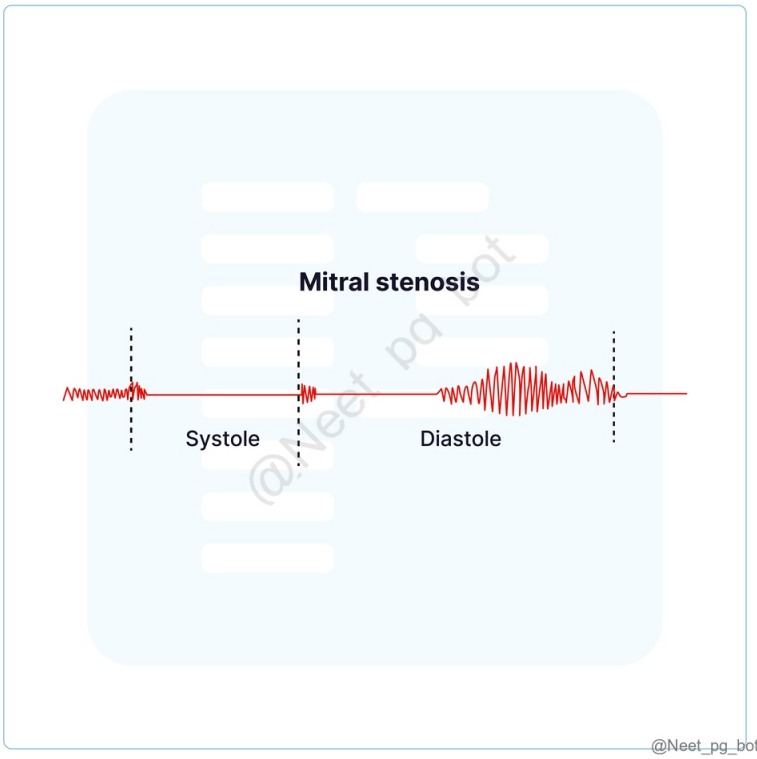

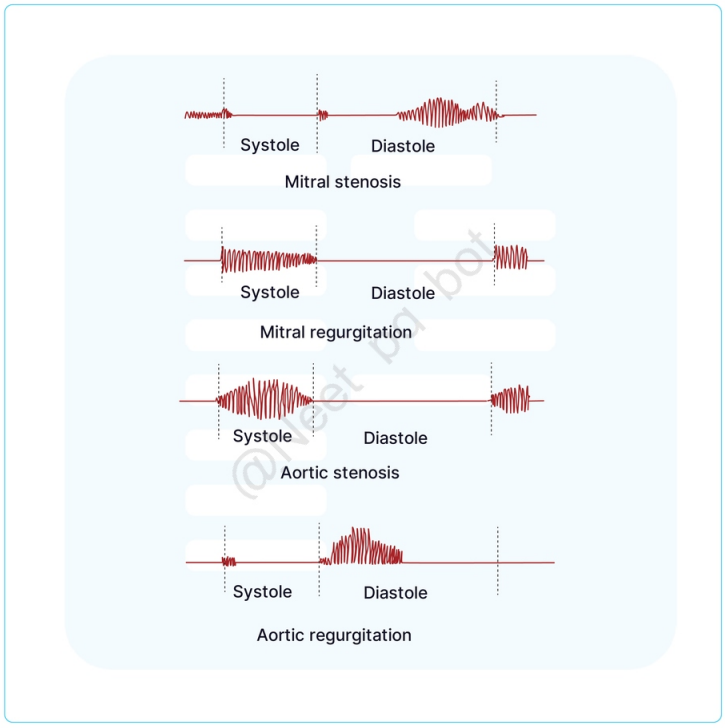

@Neet_pg_bot

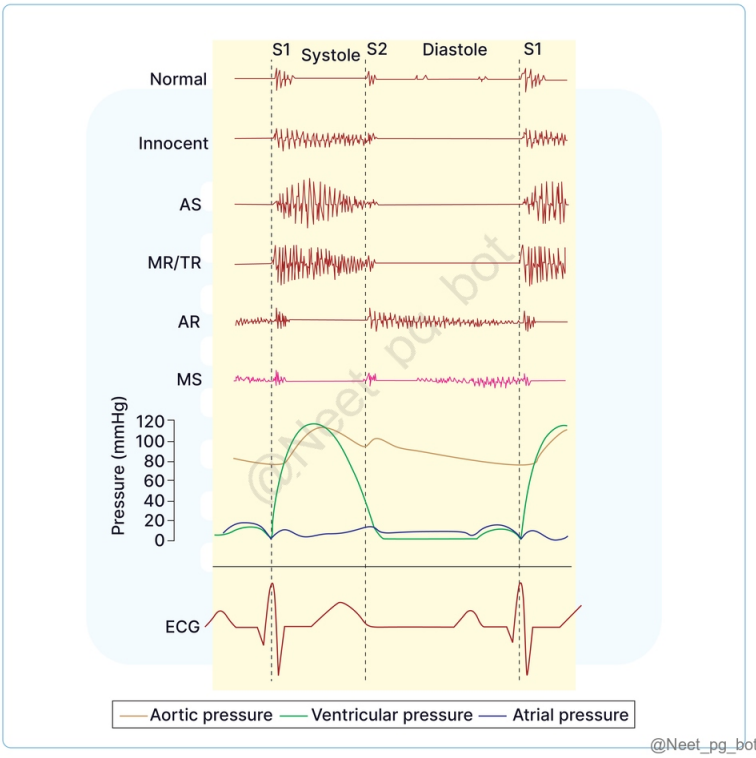

@Neet_pg_bot

References:

Harrison's Principles of Internal Medicine, 22nd Edition, Page 2048-2049.

↑ *Back to this question in Part A*

@Neet_pg_bot

Q10: A 60-year-old male with presents with shortness of breath and pedal edema. Auscultation reveals a loud diastolic sound. Chest X-ray is given below. What is the treatment? (Q850746)

A. Diuretics

B. Pericardiocentesis

C. Beta-blockers

D. Glyceryl trinitrate

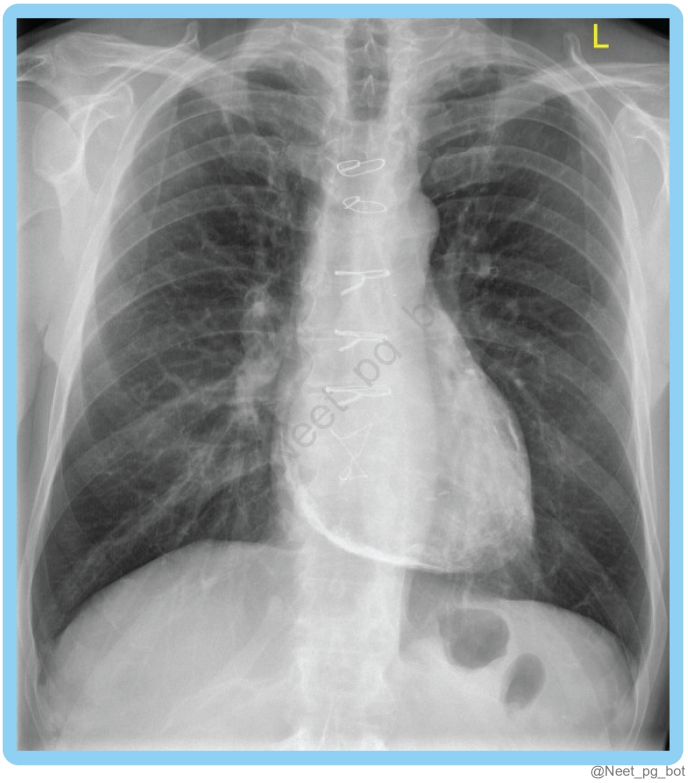

Correct Answer: A. Diuretics

■ *Listen (English)*

■ *Listen (Hindi)*

Explanation: The X-ray shows diffuse pericardial calcification along the left lateral and inferior wall of the heart. Loud pericardial sound indicates pericardial shudder. Diagnosis is constrictive pericarditis , and loop diuretics and

aldosterone antagonists are used for treatment. {{caption_text}} Pericardiocentesis (Option B) is indicated for pericardial effusion or cardiac tamponade , not for constrictive pericarditis where the pericardium is thickened and fibrotic rather than fluid-filled. Beta-blockers (Option C) are generally not helpful in constrictive pericarditis and may worsen symptoms by reducing heart rate and cardiac output. Glyceryl trinitrate (Option D) (nitroglycerin) is a vasodilator used in angina and heart failure but can worsen hypotension in constrictive pericarditis without improving the mechanical constraint.

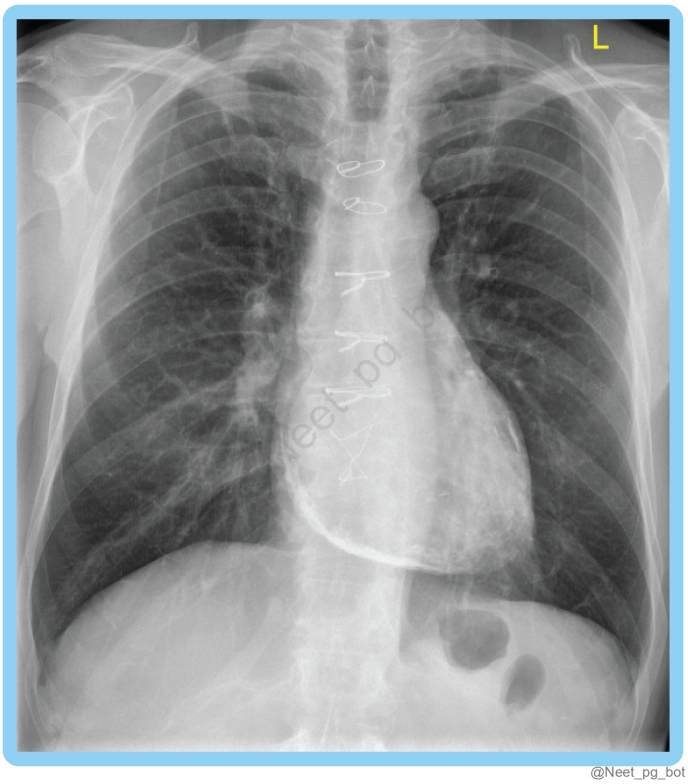

References:

Harrison's Principles of Internal Medicine, 22nd Edition, Page 2083-2084.

↑ *Back to this question in Part A*

@Neet_pg_bot

Q11: A 45-year-old woman recently diagnosed with adenocarcinoma lung presents with sudden dyspnoea, tachycardia, and hypotension. Examination reveals elevated JVP and an abnormal drop of 15mm Hg in systolic blood pressure during inspiration. An ECG was performed and is given below. What is the most appropriate next step in management? (Q850745)

A. Intravenous diuretics

B. Pericardiocentesis

C. Start vasopressors

D. Schedule elective cardiac surgery

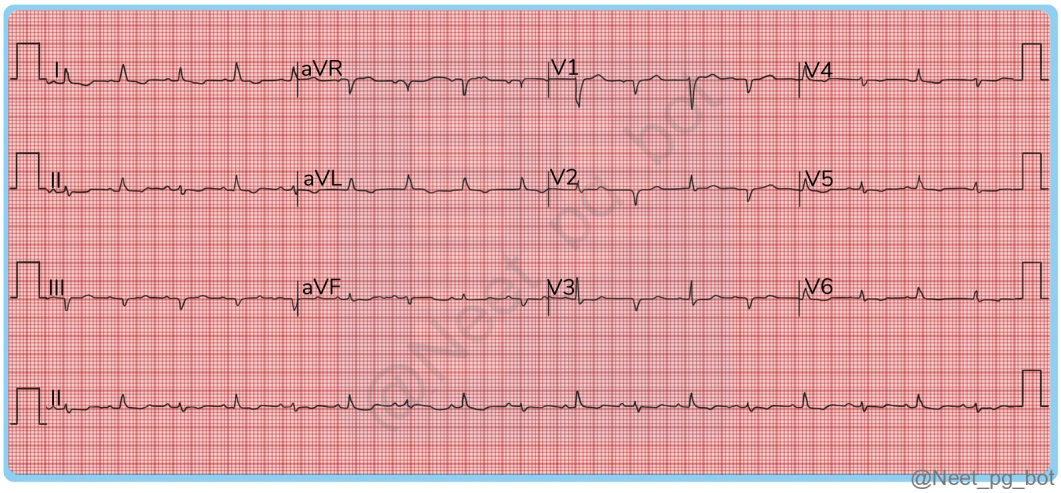

Correct Answer: B. Pericardiocentesis

■ *Listen (English)*

■ *Listen (Hindi)*

Explanation: Patient shows signs of cardiac tamponade, including hypotension , elevated JVP and pulsus paradoxus (drop in systolic BP >10–15 mmHg on inspiration). ECG shows electrical alternans. Urgent drainage of the pericardial fluid is required to relieve pressure on the cardiac chambers and restore cardiac output. Intravenous diuretics (Option A) are not helpful in tamponade, as reducing preload can worsen hypotension and cardiac output. Start vasopressors (Option C) may temporarily support blood pressure, but do not address the underlying mechanical compression , and delaying definitive treatment can be fatal. Schedule elective cardiac surgery (Option D) is inappropriate for an emergency like tamponade; pericardiocentesis is the immediate life-saving measure.

References:

Harrison's Principles of Internal Medicine, 22nd Edition, Page 2082.

↑ *Back to this question in Part A*

@Neet_pg_bot

Q12: A 60-year-old man with a history of heart failure presents with worsening edema and jugular venous distention. You observe a steep x and steep y descent in the jugular venous waveform. Which of the following conditions is most likely responsible for these findings? (Q850500)

A. Constrictive pericarditis

B. Tricuspid regurgitation

C. Pericardial tamponade

D. Acute Pericarditis

Correct Answer: A. Constrictive pericarditis

■ *Listen (English)*

■ *Listen (Hindi)*

Explanation: Constrictive pericarditis typically causes a steep y descent to maximise ventricular filling before the calcified pericardial sac limits the diastole. Steep x is explained by atrial dilatation because of having to work against the resistance of stiff ventricles. Causes: Post-Viral/Infectious: Often follows a bout of acute pericarditis. Tuberculosis Cardiac Surgery Radiation Therapy: Particularly in patients treated for chest malignancies (like Hodgkin lymphoma or breast cancer). Connective Tissue Disorders: Conditions like Rheumatoid Arthritis or SLE (Lupus). Clinical signs: Kussmaul's Sign Pericardial Knock Right-Sided Heart Failure Symptoms: Ascites Peripheral edema Hepatomegaly Pulsus Paradoxus Management: Medical Management Diuretics to reduce fluid overload and NSAIDs/Colchicine if there is active inflammation. Pericardiectomy The definitive "cure." This is the surgical removal of the scarred pericardium. It's a major surgery but releases the heart from its cage. Addressing Underlyings Treating TB with antitubercular therapy or managing autoimmune flares.

References:

Harrison's Principles of Internal Medicine, 22nd Edition, Page 1906, 2081.

↑ *Back to this question in Part A*

@Neet_pg_bot

Q13: A 65-year-old man presents with palpitations and lightheadedness. His ECG shows an unequal number of P waves and R waves and his jugular venous pressure tracing is shown below. Which of the following conditions is responsible for this finding? (Q850498)

A. Atrial fibrillation

B. Complete heart block

C. Tricuspid stenosis

D. Electromechanical dissociation

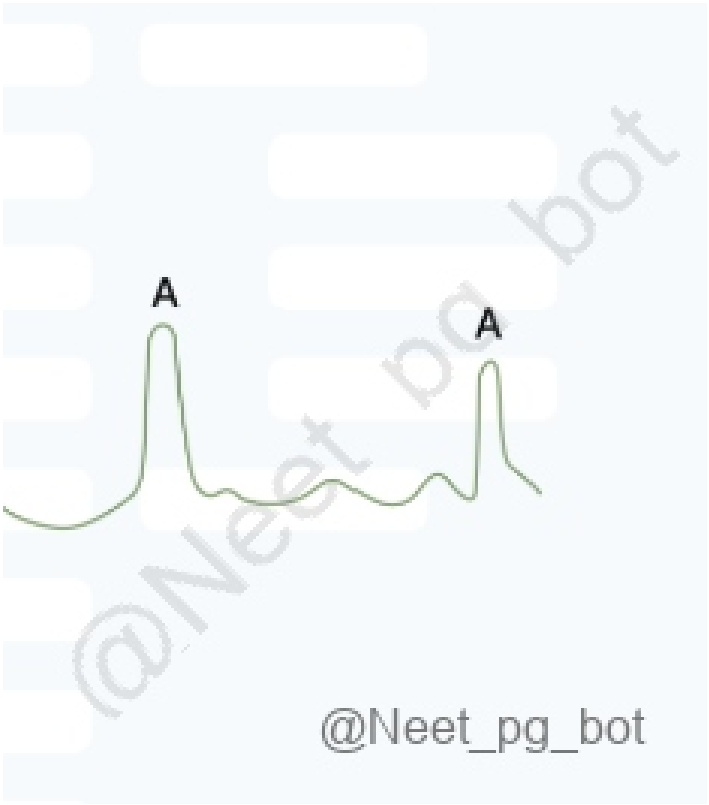

@Neet_pg_bot

Correct Answer: B. Complete heart block

- *Listen (English)*
- *Listen (Hindi)*

Explanation: Unequal R waves and P waves indicate AV dissociation. Cannon "a" waves occur when the atria contract against a closed tricuspid valve. Diagnosis is complete heart block. Atrial fibrillation (Option A) will have absent waves. Tricuspid stenosis (Option C) will cause large ‘a’ waves in JVP. Electromechanical dissociation (Option D) occurs after transmural MI causes the ventricular chamber to rupture.

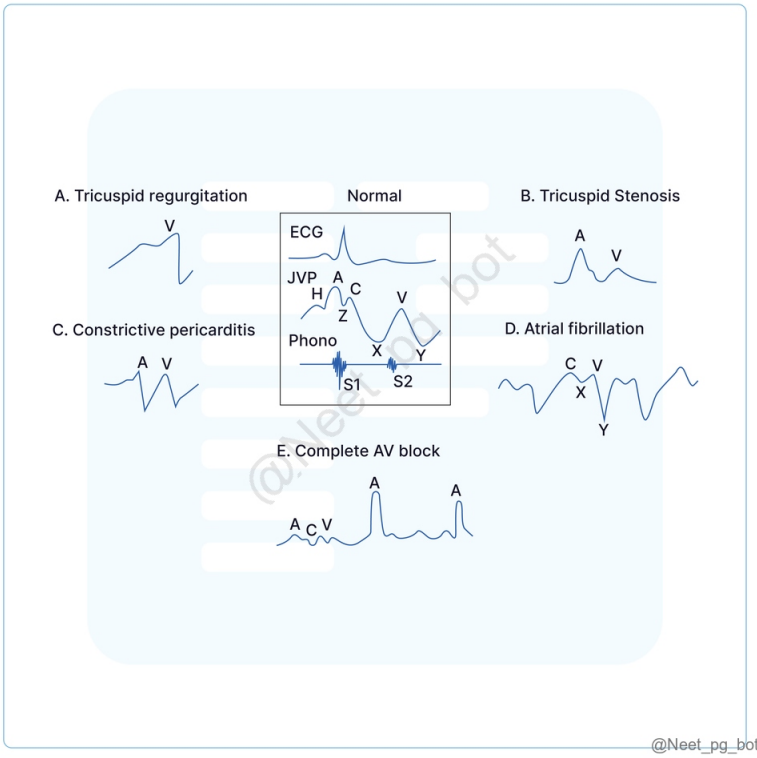

References:

Harrison's Principles of Internal Medicine, 22nd Edition, Page 1925-1926.

↑ *Back to this question in Part A*

@Neet_pg_bot

Q14: Loud first heart sound (S1) in mitral stenosis indicates? (Q850476)

A. Reduced LV compliance

B. Increased left atrial pressure

C. Severe calcified mitral stenosis

D. Hypertrophy of the right ventricle

Correct Answer: B. Increased left atrial pressure

■ *Listen (English)*

■ *Listen (Hindi)*

Explanation: Loud S1 is indicative of increased left atrial pressure, causing faster, abrupt closure of AV valves and, hence, a loud first heart sound. First heart sound (S1): The first heart sound is due to the closing of the AV valves. It occurs at the beginning of the isovolumetric contraction as lub sound. The intensity of S1 is determined by the distance over which the anterior leaflet of the mitral valve must travel to return to its annular plane, leaflet mobility, LV contractility, and PR interval. S1 is loud in rheumatic MS, hyperkinetic circulatory states and short PR interval. Severe calcified mitral stenosis (Option C) leads to immobile, stiff valve leaflets , which reduce the intensity of S1, making it soft or absent , not loud. Reduced LV compliance (Option A) typically affects diastolic filling but does not directly cause a loud S1; it may even reduce it in some conditions. Hypertrophy of the right ventricle (Option D) may be a consequence of pulmonary hypertension due to mitral stenosis, but it does not directly affect the loudness of S1 .

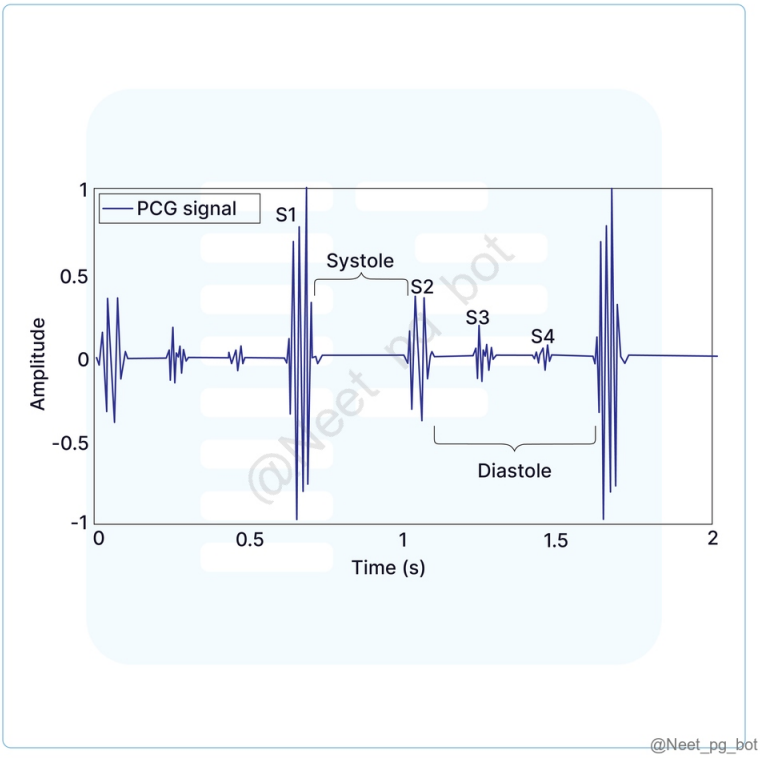

References:

Harrison's Principles of Internal Medicine, 22nd Edition, Page 1864, 2049.

↑ *Back to this question in Part A*

@Neet_pg_bot

Q15: A 70-year-old woman with a history of ischemic cardiomyopathy, hypertension, and diabetes presents with worsening shortness of breath and fatigue. On physical examination, you hear both an S3 and an S4 heart sound. Which of the following best explains the presence of both heart sounds in this patient? (Q850495)

A. Atrial fibrillation with mitral stenosis

B. Acute mitral regurgitation

C. Combined systolic and diastolic heart failure

D. Severe aortic stenosis

Correct Answer: C. Combined systolic and diastolic heart failure

■ *Listen (English)*

■ *Listen (Hindi)*

Explanation: The presence of both S3 and S4 heart sounds strongly suggests that this patient has combined systolic and diastolic dysfunction , which is common in elderly patients with long-standing hypertension, diabetes, and ischemic cardiomyopathy. S3 (ventricular gallop): Marker of Systolic Dysfunction S3 occurs just after S2 during rapid passive filling of the ventricle. It is produced when the ventricle is dilated and has reduced contractility. This patient has ischemic cardiomyopathy, which leads to a weak, dilated LV, causing an S3. S3 is strongly associated with reduced ejection fraction (HFrEF). S4 (atrial gallop): Marker of Diastolic Dysfunction S4 occurs just before S1, when the atria contract against a stiff ventricle. Long-standing hypertension and diabetes cause LV hypertrophy, making the ventricle non-compliant, resulting in S4. S4 is associated with HFpEF, diastolic dysfunction, and stiff ventricles. Together The coexistence of S3 and S4 implies: A dilated, poorly contracting ventricle (S3) A stiff, hypertrophied, non-compliant ventricle (S4) This combination occurs most commonly in advanced mixed heart failure , especially in older patients with multiple comorbidities—exactly the profile in this case. Atrial fibrillation with mitral stenosis (Option A) : An S4 is absent in atrial fibrillation because atrial contraction is ineffective. Mitral stenosis typically causes a loud S1 and an opening snap, not an S3 or S4. Acute mitral regurgitation (Option B): Acute mitral regurgitation can cause an S3 due to rapid ventricular filling, but an S4 would be uncommon unless there is concurrent diastolic dysfunction, which is less likely in an acute setting. Severe aortic stenosis (Option D): Aortic stenosis can cause an S4 due to the stiff left ventricle. However, an S3 is less likely unless there is concurrent left ventricular failure. Isolated aortic stenosis would not explain both sounds.

References:

Harrison's Principles of Internal Medicine, 22nd Edition, Page 270, 1984.

↑ *Back to this question in Part A*

@Neet_pg_bot

Q16: A 35-year-old woman presents with palpitations. On examination, hyperdynamic precordium is noted with soft S1 and pansystolic murmur. Which of the following is the most likely cause? (Q850494)

A. Hyperthyroidism

B. Mitral stenosis

C. Mitral regurgitation

D. Myxedema heart

Correct Answer: C. Mitral regurgitation

■ *Listen (English)*

■ *Listen (Hindi)*

Explanation: A pansystolic (holosystolic) murmur with a soft S1 and a hyperdynamic precordium is classic for mitral regurgitation: the mitral leaflets fail to coapt, producing a continuous systolic leak (murmur) and a soft/absent S1. The hyperdynamic impulse reflects increased volume load on the left ventricle. The closest option of Hyperthyroidism is ruled out as it has a loud S1 with ejection systolic murmur with hyperdynamic precordium. Hyperthyroidism (Option A): Produces a hyperdynamic circulation and systolic flow murmurs, but not a pansystolic murmur with soft S1. Mitral stenosis (Option B): Gives a loud, tapping S1 and a diastolic rumbling murmur with opening snap — opposite to findings here. Myxedema (hypothyroidism) (Option D): Associated with a low-output, sluggish precordium and bradycardia, not a hyperdynamic impulse or pansystolic murmur.

References:

Harrison's Principles of Internal Medicine, 22nd Edition, Page 2053.

↑ *Back to this question in Part A*

@Neet_pg_bot

Q17: A 25-year-old man presents to the ER with recurrent episodes of palpitations, dizziness, and occasional chest discomfort. Auscultation shows loud S1 and normal split S2. An ECG of the condition is given below. What is the most likely diagnosis for this patient's condition? (Q850491)

A. Atrial Fibrillation

B. Wolff-Parkinson-White (WPW) Syndrome

C. Myocardial Infarction

D. Brugada syndrome

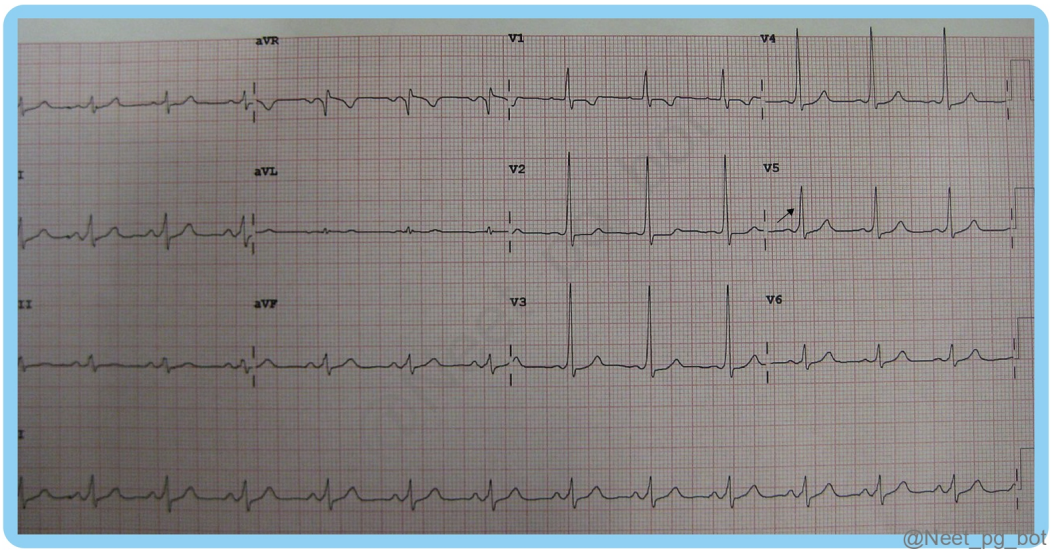

Correct Answer: B. Wolff-Parkinson-White (WPW) Syndrome

■ *Listen (English)*

■ *Listen (Hindi)*

Explanation: ECG shows short PR interval, delta wave (red marking) , and wide QRS complex, diagnostic of Wolff-Parkinson-White (WPW) Syndrome. Loud S1 is explained by tachycardia due to fast conduction via the bundle of kent. Atrial Fibrillation (Option A): AF can occur in WPW but does not cause a delta wave and presents with irregular rhythm rather than the specific findings in WPW. Myocardial Infarction (Option C): rMI causes ischemic changes on ECG, such as ST elevation or Q waves, but not the delta wave or short PR interval seen in WPW. Brugada syndrome (Option D) has coved or saddleback ST segment elevation.

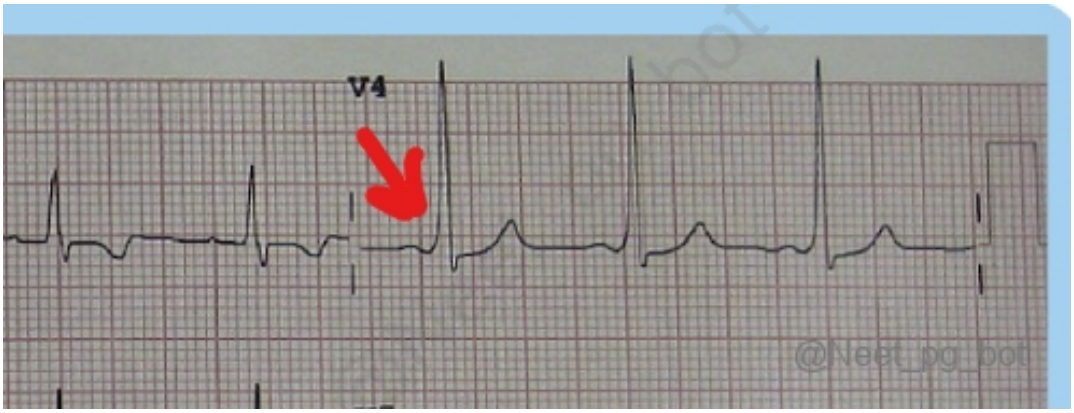

References:

Harrison's Principles of Internal Medicine, 22nd Edition, Page 1940-1941

↑ *Back to this question in Part A*

@Neet_pg_bot

Q18: A 6-year-old boy is brought my mother as he gets very breathless during physical activities and had hospitalization for recurrent pneumonia episodes. Inspection shows a right parasternal heave, no cyanosis and auscultation reveals a systolic ejection murmur. Which is correct auscultatory finding seen in this case? (Q850488)

A. Narrow split S2

B. Paradoxical split S2

C. Wide split fixed S2

D. Wide split variable S2

Correct Answer: C. Wide split fixed S2

■ *Listen (English)*

■ *Listen (Hindi)*

Explanation: A 6-year-old with exertional breathlessness, recurrent respiratory infections, right parasternal heave (RV hypertrophy), and a systolic ejection murmur suggests Atrial Septal Defect (ASD – ostium secundum type) . The classic auscultatory finding in ASD is a wide, fixed split S2 due to constant increased RV stroke volume and delayed pulmonic valve closure. Narrow split S2 (Option A): Occurs with conditions causing early P2, not seen in ASD. Paradoxical split S2 (Option B): Occurs when A2 is delayed (e.g., LBBB, aortic stenosis), opposite of ASD physiology. Wide split variable S2 (Option D): Seen in right bundle branch block or pulmonary stenosis, but variable , not fixed like in ASD.

References:

Harrison's Principles of Internal Medicine, 22nd Edition, Page 1864.

↑ *Back to this question in Part A*

@Neet_pg_bot

Q19: A 3-year-old girl presents to the clinic with a history of recurrent respiratory infections and exercise intolerance. On physical examination, a holosystolic murmur is noted at the left lower sternal border. Which of the following is correct about heart sound finding in this case? (Q850487)

A. Wide Fixed split S2

B. Paradoxical split S2

C. Narrow split S2

D. Wide split variable S2

Correct Answer: D. Wide split variable S2

■ *Listen (English)*

■ *Listen (Hindi)*

Explanation: The given clinical features are of Ventricular Septal Defect (VSD) which presents with a wide split variable S2. Wide Fixed split S2 (Option A) occurs in conditions like atrial septal defect (ASD), where the split remains constant during respiration due to continuous right heart volume overload, which is not seen in VSD. Paradoxical split S2 (Option B) happens when A2 occurs after P2, often due to conditions like HOCM with severe LV obstruction or severe aortic stenosis. It is not typical for VSD. Narrow split S2 (Option C) indicates a delayed closure of the aortic valve but is not characteristic of VSD, where increased right-sided volume typically causes a wider split.

References:

www.ncbi.nlm.nih.gov/books/NBK341/

↑ *Back to this question in Part A*

@Neet_pg_bot

Q20: A 45-year-old man presents with progressive dyspnea and occasional dizziness. On auscultation, a harsh crescendo-decrescendo systolic murmur is noted at the left sternal border, which increases with the Valsalva maneuver. There is also evidence of a jerky carotid pulse. Which of the following will be heard on auscultation in this case? (Q850485)

A. Wide split S2

B. Fixed split S2

C. Paradoxical split S2

D. Physiological split S2

Correct Answer: C. Paradoxical split S2

■ *Listen (English)*

■ *Listen (Hindi)*

Explanation: The clinical features suggest Hypertrophic Obstructive Cardiomyopathy (HOCM) with severe left ventricular outflow tract obstruction. It can delay the closure of the aortic valve (A2). This leads to the paradoxical splitting of S2, where A2 occurs after P2, causing the split to be heard during expiration. Wide split S2 (Option A):

This occurs when there is a delayed closure of the pulmonic valve (P2), causing an exaggerated split that increases during inspiration. Common in conditions like right bundle branch block (RBBB) or pulmonic stenosis. Fixed split S2 (Option B): The split remains constant throughout the respiratory cycle, typically seen in atrial septal defect (ASD), due to continuous right heart volume overload. Physiological split S2 (Option D): A normal finding where the split between A2 and P2 increases during inspiration and disappears during expiration due to increased venous return delaying P2.

References:

Harrison's Principles of Internal Medicine, 22nd Edition, Page 1864.

↑ *Back to this question in Part A*

@Neet_pg_bot

Q21: Narrow split S2 heart sound is heard in which of the following conditions? (Q850484)

A. Mitral regurgitation

B. Aortic stenosis

C. Atrial septal defect

D. Pulmonary hypertension

Correct Answer: B. Aortic stenosis

■ *Listen (English)*

■ *Listen (Hindi)*

Explanation: Narrow split S2 occurs in aortic stenosis because delayed closure of the aortic valve brings the A2 (aortic component) closer to P2 (pulmonic component). Mitral regurgitation (Option A): In mitral regurgitation, the S2 sound is typically unaffected. However, an S3 sound (due to volume overload) may be heard. Atrial septal defect (ASD) (Option C): In ASD, a wide and fixed split S2 is heard due to increased right-sided volume, which delays the closure of the pulmonic valve (P2). Pulmonary hypertension (Option D): This can lead to a delayed P2, causing a wide split S2, not a narrow split.

References:

Harrison's Principles of Internal Medicine, 22nd Edition, Page 1864, 2037.

↑ *Back to this question in Part A*

@Neet_pg_bot

Q22: Match the following Heart sound Condition seen 1) Wide Split S2 a) RBBB 2) Paradoxical Splitting S2 b) Mitral regurgitation 3) Fixed Splitting S2 c) LBBB 4) Narrow Split S2 d) Hypertrophic cardiomyopathy e) ASD (Q850482)

A. 1-b, 2-c, 3-e, 4-d

B. 1-a, 2-e, 3-b, 4-c

C. 1-b, 2-d, 3-b, 4-e

D. 1-c, 2-a, 3-b, 4-e

Correct Answer: A. 1-b, 2-c, 3-e, 4-d

■ *Listen (English)*

■ *Listen (Hindi)*

Explanation: Condition Type of Split Wide split Mitral regurgitation due to early A2 Paradoxical split LBBB due to delayed closure of A2 Fixed Splitting ASD Narrow splitting Dynamic out flow tract obstruction will cause more time for blood to exit from left side. This causes delayed closure of A2 causing narrow split S2

References:

Harrison's Principles of Internal Medicine, 22nd Edition, Page 1864.

↑ *Back to this question in Part A*

@Neet_pg_bot

Q23: A 28-year-old woman comes with a history of fever, chest pain, weight loss, and night sweats. During cardiac auscultation, the physician notes a characteristic sound that persists on breath holding. ECG shows global ST segment elevation with concavity upwards. What is this finding called on auscultation known as? (Q850481)

A. Opening snap

B. Pericardial friction rub

C. Pericardial knock

D. Pleural rub

Correct Answer: B. Pericardial friction rub

■ *Listen (English)*

■ *Listen (Hindi)*

Explanation: Auscultatory finding is pericardial friction rub as it persists on breath holding that differentiates it from pleural rub. ECG finding of global ST segment elevation indicates acute pericarditis. Possible etiology is Tuberculosis that will require more workup. Tuberculous pericarditis is a form of extrapulmonary tuberculosis . There is a serofibrinous exudate outside the heart which causes inflammation and irritation of the phrenic nerve, causing pain to radiate to the shoulders. Presents with chest pain at rest. On examination: Pericardial friction rub (scratchy sound on auscultation) present even when patient holds his breath. Investigation of choice: CBNAAT or Gene Expert testing of pericardial fluid. Treatment: ATT for 6 months. Opening snap (Option A) is a high pitch sound heard in cases of mitral stenosis, follows S2, occurring in early diastole. Pericardial knock (Option C) also known as pericardial shudder is seen in cases of calcification around the heart in patients after treatment with ATT. Pleural rub(Option D) is best heard in the phase of deep inspiration and disappears on breath holding.

References:

Harrison's Principles of Internal Medicine, 22nd Edition, Page 1389, 1867.

↑ *Back to this question in Part A*

@Neet_pg_bot

Q24: Which of the following features would raise suspicion for a diagnosis of Carney complex? (Q850480)

A. Association with tuberous sclerosis

B. Presence of skin pigmentation abnormalities

C. Restrictive cardiomyopathy

D. A-V nodal block

Correct Answer: B. Presence of skin pigmentation abnormalities

■ *Listen (English)*

■ *Listen (Hindi)*

Explanation: The Carney complex is familial cause of Atrial myxomas + skin lesions (pigmentation) + Endocrine abnormalities like Cushing syndrome, acromegaly, multinodular goiter and precocious puberty. Atrial Myxomas: Introduction Most common primary cardiac tumors in adults. Location Often found in the left atrium. Types Sporadic. Familial: Carney Complex (Myxomas + skin lesions + Endocrinopathies). Association with tuberous sclerosis (Option A): Not related; tuberous sclerosis is a separate genetic syndrome. Restrictive cardiomyopathy (Option C): Cardiac involvement is usually myxomas , not restrictive cardiomyopathy. A-V nodal block (Option D): Conduction defects are not a typical feature .

References:

Harrison's Principles of Internal Medicine, 22nd Edition, Page 2085, 3004.

↑ *Back to this question in Part A*

@Neet_pg_bot

Q25: During the cardiac cycle, the closing of the aortic valve takes place at ? (Q850478)

A. End of isovolumetric contraction

B. End of rapid filling phase

C. Start of isovolumetric relaxation

D. Start of ejection

Correct Answer: C. Start of isovolumetric relaxation

■ *Listen (English)*

■ *Listen (Hindi)*

Explanation: The aortic valve closes when the left ventricular pressure falls below aortic pressure — this marks the end of ejection and the beginning of isovolumetric relaxation . This event produces the second heart sound (S2) . End of isovolumetric contraction (Option A): This is when the aortic valve opens , not closes. End of rapid filling phase (Option B): This is a diastolic filling event , unrelated to aortic valve closure. Start of ejection (Option D): The aortic valve opens at the start of ejection, not closes.

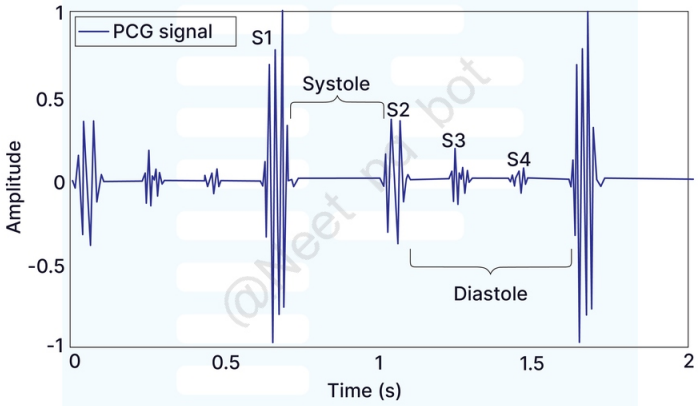

@Neet_pg_bot

References:

Guyton and Hall Textbook of Medical Physiology, 14th Edition, Page 122

Ganong's Review of Medical Physiology, 23rd Edition, Page 527-531

↑ *Back to this question in Part A*

@Neet_pg_bot

• [01_Cardiology] 003 Takotsubo Brugada Syndrome Rhd And Infective Endocarditis

« Back to Folder Directory

[01_Cardiology] 003 Takotsubo Brugada Syndrome Rhd And Infective Endocarditis — Quick Jump

Q1 (p. 1130)	*Q2 (p. 1131)*	*Q3 (p. 1131)*	*Q4 (p. 1132)*	*Q5 (p. 1133)*	*Q6 (p. 1134)*
Q7 (p. 1135)	*Q8 (p. 1136)*	*Q9 (p. 1137)*	*Q10 (p. 1139)*	*Q11 (p. 1140)*	*Q12 (p. 1141)*
Q13 (p. 1142)	*Q14 (p. 1142)*	*Q15 (p. 1143)*	*Q16 (p. 1144)*	*Q17 (p. 1144)*	*Q18 (p. 1145)*
Q19 (p. 1146)	*Q20 (p. 1147)*	*Q21 (p. 1148)*	*Q22 (p. 1149)*	*Q23 (p. 1149)*	*Q24 (p. 1150)*
Q25 (p. 1151)	*Q26 (p. 1151)*	*Q27 (p. 1152)*	*Q28 (p. 1153)*	*Q29 (p. 1153)*	*Q30 (p. 1155)*
Q31 (p. 1156)					

Q1: A 78 year old man, three months after undergoing transcatheter aortic valve replacement presents with high grade fever with chills and rigors. What is the most common causative organism in TAVR-associated infective endocarditis? (Q850454)

A. Streptococcus viridans

B. Enterococcus spp

C. Staphylococcus aureus

D. Candida spp.

Correct Answer: B. Enterococcus spp

■ *Listen (English)*

■ *Listen (Hindi)*

Explanation: Enterococcus spp. is the most common causative organism associated with TAVR-related infective endocarditis, followed by S. Aureus. Streptococcus viridans (Option A) is for community-acquired native valve -IE. For C.I.E.D. (Cardiac implantable electronic devices, such as pacemakers), the infective endocarditis leading organism is C.O.N.S.> Staph. Aureus

References:

Harrison's Principles of Internal Medicine, 22nd Edition, Page 1037.

↑ *Back to this question in Part A*

@Neet_pg_bot

Q2: Which of the following is a minor criterion for diagnosing infective endocarditis based on 2023 Duke-ISCVID criteria? (Q850473)

A. Two negative blood cultures

B. Echocardiogram showing valve perforation

C. PCR from a sterile body site identifying a typical pathogen

D. Two positive blood cultures

Correct Answer: C. PCR from a sterile body site identifying a typical pathogen

■ *Listen (English)*

■ *Listen (Hindi)*

Explanation: Positive Blood culture is a major criteria. (Option D ruled out) Echo showing valve perforation is a major criteria (Option B ruled out) Negative blood culture would not be considered for diagnosis.. (Option A ruled out) PCR, amplicon or metagenomic sequencing of typical pathogens from sterile sites other than cardiac tissue is now a minor criterion. The 2023 Duke-International Society for Cardiovascular Infectious Diseases (ISCVID) Criteria for Infective Endocarditis - Minor Criteria Updates Predisposing Conditions Expanded to include transcatheter valve procedures, endovascular leads of cardiac implantable devices, and a history of IE. Vascular Phenomenon Includes splenic and cerebral abscesses. Immunological Phenomena Clarifies immune complex-mediated glomerulonephritis, with a practical definition involving unexplained acute kidney injury, hematuria, proteinuria, or a renal biopsy showing immune complex disease. Microbiological Evidence PCR, amplicon or metagenomic sequencing of typical pathogens from sterile sites other than cardiac tissue is now a minor criterion Imaging Abnormal metabolic activity as detected by [18F]FDG PET/CT within 3 mo of implantation of prosthetic valve, ascending aortic graft (with concomitant evidence of valve involvement), intracardiac device leads or other prosthetic material Physical Exam A new regurgitant murmur on auscultation is considered a minor criterion when echocardiography is unavailable.

References:

Harrison's Principles of Internal Medicine, 22nd Edition, Page 1040. www.iscvid.org/wp-content/uploads/2023/07/2023-The-2023-Duke-ISCVID-Criteria-for-Infective-Endocarditis-Fowler-CID-May-4-2023-Final.pdf

↑ *Back to this question in Part A*

@Neet_pg_bot

Q3: Which of the following is a typical organism causing infective endocarditis based on 2023 Duke-ISCVID criteria? (Q850472)

A. Enterococcus faecalis

B. Streptococcus pneumoniae

C. Pseudomonas aeruginosa

D. Streptococcus pyogenes

Correct Answer: A. Enterococcus faecalis

■ *Listen (English)*

■ *Listen (Hindi)*

Explanation: 2023 Duke-ISCVID criteria for infective endocarditis (IE) - Typical and Non-typical Organisms Typical Non-Typical For General cases: Staphylococcus aureus, Staphylococcus lugdunensis Enterococcus faecalis (Option A) All streptococci (except Streptococcus pneumoniae and Streptococcus pyogenes) Granulicatella, Abiotrophia, Gemella species HACEK group (e.g., Haemophilus, Aggregatibacter, Cardiobacterium, Eikenella, Kingella) For cases involving intracardiac prosthetic material , additional typical organisms include: Coagulase-negative staphylococci Corynebacterium striatum, Corynebacterium jeikeium Serratia marcescens, Cutibacterium acnes Pseudomonas aeruginosa (Option C ruled out) Non-tuberculous mycobacteria (e.g., Mycobacterium chimaera) Candida species Organisms classified as non-typical are less frequently associated with IE and require three or more positive blood cultures for diagnosis. Streptococcus pneumoniae (Option B ruled out) Streptococcus pyogenes (Option D ruled out) Non-faecalis enterococci

References:

Harrison's Principles of Internal Medicine, 22nd Edition, Page 1040.

Davidson’s Principles and Practice of Medicine, 24th Edition, Page 529.

The 2023 Duke-ISVD Criteria

↑ *Back to this question in Part A*

@Neet_pg_bot

Q4: A 70 year old man with a prosthetic aortic valve has a fever, positive blood cultures for Enterococcus faecalis, valve vegetations visualized on echocardiography. Cardiac Computed Tomography shows a valve abscess. Which finding is a new major criterion for infective endocarditis in the 2023 Duke-ISCVID criteria? (Q850471)

A. Direct visual evidence of vegetations during surgery

B. Echocardiogram revealing vegetation

C. Positive blood cultures with Enterococcus faecalis

D. Development of a new onset murmur

Correct Answer: A. Direct visual evidence of vegetations during surgery

■ *Listen (English)*

■ *Listen (Hindi)*

Explanation: Findings like valvular vegetation, perforation, aneurysm, intracardiac fistula or abscesses on CCT are now considered major criteria according to the updated 2023 Duke-International Society for Cardiovascular Infectious Diseases (ISCVID) Criteria for Infective Endocarditis. The 2023 Duke-International Society for Cardiovascular Infectious Diseases (ISCVID) Criteria for Infective Endocarditis - Major Criteria Updates Microbiological Criteria Expanded "Typical" Pathogens : The list now includes Staphylococcus lugdunensis, Enterococcus faecalis, and other streptococci, excluding S. pneumoniae and S. pyogenes. Additionally, Granulicatella, Abiotrophia, and Gemella species are now recognised as typical IE pathogens. Prosthetic Material-Associated Pathogens : In intracardiac prosthetic devices, certain bacteria like coagulase-negative staphylococci and Corynebacterium species, as well as Pseudomonas aeruginosa, are considered typical. Simplified Blood Culture Protocol : Timing and separate venipuncture rules have been removed, though separate draws are still ideal. Fastidious Pathogens : New criteria account for hard-to-culture organisms like Coxiella burnetii, Bartonella, and Tropheryma whipplei, diagnosed via PCR or specific serology. Imaging Criteria Cardiac CT (CCT): Findings like valvular vegetation, perforation, aneurysm, intracardiac fistula or abscesses on CCT are now considered major criteria. (Option A) [18F]FDG PET/CT : Abnormal metabolic activity involving a native or prosthetic valve, ascending aortic graft (with concomitant evidence of valve involvement), intracardiac device leads or other prosthetic material. Surgical Evidence Intraoperative Findings : Direct visual evidence of IE during surgery, such as vegetations or abscesses, qualifies as a major criterion in cases without other definitive findings.

References:

Harrison's Principles of Internal Medicine, 22nd Edition, Page 1040.

Davidson’s Principles and Practice of Medicine, 24th Edition, Page 529

↑ *Back to this question in Part A*

@Neet_pg_bot

Q5: A 65 year old male patient with a history of rheumatic heart disease presents to the dental clinic for a tooth extraction. He has a prosthetic heart valve placed two years ago and reports a penicillin allergy. Which of the following prophylactic antibiotic regimens should be administered to this patient before his dental procedure to prevent infective endocarditis? (Q850470)

A. Amoxicillin 2g orally 1 hour before the procedure

B. Ampicillin 2g IV or IM within 1 hour before the procedure

C. Clarithromycin 500 mg orally 1 hour before the procedure

D. Cefazolin 1g IV or IM 30 minutes before the procedure

Correct Answer: C. Clarithromycin 500 mg orally 1 hour before the procedure

■ *Listen (English)*

■ *Listen (Hindi)*

Explanation: Clarithromycin is a suitable alternative for patients with penicillin allergies and is indicated for prophylaxis in patients with prosthetic heart valves. High-risk cardiac Lesions for endocarditis prophylaxis before dental procedures Prophylactic Antibiotic Regimens for endocarditis in adults with high-risk cardiac lesions Prosthetic heart valves or material Left ventricular assist devices. Prior endocarditis. Unrepaired cyanotic congenital heart disease, including palliative shunts or conduits. Completely repaired congenital heart defects during the 6 months after repair. Repaired congenital heart disease with residual defects adjacent to the prosthetic material. Surgical or transcatheter pulmonary artery valve or conduit placement Valvulopathy developed after cardiac transplantation. Standard oral regimen (Option A ruled out) Amoxicillin: 2g oral 1hr before procedure Inability to take oral medication (Option B ruled out) Ampicillin: 2g IV or IM within 1hr before procedure Penicillin allergy Clarithromycin or Azithromycin: 500 mg PO 1hr before procedure. Cephalexin: 2g oral 1hr before procedure (avoid if immediate hypersensitivity to penicillin). Doxycycline: 100 mg oral 1hr before procedure. Penicillin allergy, inability to take oral medication (Option D ruled out) Cefazolin or Ceftriaxone: 1g IV or IM 30 mins before the procedure.

References:

Harrison's Principles of Internal Medicine, 22nd Edition, Page 1048.

↑ *Back to this question in Part A*

@Neet_pg_bot

Q6: A 55 year old man with a history of prosthetic valve deployment presents with fever, chills, and fatigue. Blood cultures reveal methicillin-resistant Staphylococcus aureus. The patient has a prosthetic valve and shows evidence of vegetation on echocardiography. What is the appropriate antibiotic regimen for managing this patient’s infection? (Q850469)

A. Vancomycin + Gentamicin + Rifampin

B. Vancomycin + Daptomycin

C. Nafcillin + Gentamicin + Rifampin

D. Ampicillin + Gentamicin

Correct Answer: A. Vancomycin + Gentamicin + Rifampin

■ *Listen (English)*

■ *Listen (Hindi)*

Explanation: The patient has MRSA prosthetic valve endocarditis (PVE). The appropriate treatment includes Vancomycin + Rifampin and Gentamicin . Rifampin is crucial for targeting bacteria in biofilms which are formed on prosthetic valves. Treatment of Infective Endocarditis Based on Pathogen and Valve Type Methicillin-resistant Staphylococcus aureus (MRSA) NVE: Vancomycin or Daptomycin for 6 weeks. (Option B ruled out) PVE: Vancomycin + Rifampin+ Gentamicin Methicillin-sensitive Staphylococcus aureus (MSSA) PVE: Nafcillin + Rifampin (both for 6-8 weeks) + Gentamicin(for 2 weeks) (Option C ruled out)

References:

Harrison's Principles of Internal Medicine, 22nd Edition, Page 1041-1044.

↑ *Back to this question in Part A*

@Neet_pg_bot

Q7: Which of the following is a minor criterion under the Modified Duke's Criteria for infective endocarditis? (Q850468)

A. Positive echocardiographic findings of vegetation

B. Two positive blood cultures with a typical organism

C. Presence of a prosthetic valve

D. Abscess formation on echocardiogram

Correct Answer: C. Presence of a prosthetic valve

■ *Listen (English)*

■ *Listen (Hindi)*

Explanation: Positive echocardiographic findings of vegetation (Option A), Two positive blood cultures with a typical organism (Option B), Abscess formation on echocardiogram (Option D): All the given conditions form the major criteria for Infective Endocarditis in Modified Duke's criteria. Modified Duke's Criteria - Minor criteria Predisposing heart condition Any pre-existing valvular or cardiac abnormality, such as valvular disease, congenital heart defects, or prosthetic valves. (Option C) Intravenous drug use Recognised as a significant risk factor for IE. Fever ≥ 38°C Commonly seen in patients with IE. Vascular phenomena Such as embolic events (stroke, septic pulmonary infarcts), mycotic aneurysms, intracranial haemorrhages and Janeway lesions. Immunological phenomena Rheumatoid factor, Osler's nodes, Roth's spots or glomerulonephritis. Positive blood culture not meeting major criteria Isolation of organisms typical of IE in a single culture or other non-major findings. Suggestive echocardiography Abnormal findings that raise suspicion but do not meet the criteria for a major criterion. (D529)

References:

Harrison's Principles of Internal Medicine, 22nd Edition, Page 1040. Davidson’s Principles and Practice of Medicine, 24th Edition, Page 529

↑ *Back to this question in Part A*

@Neet_pg_bot

Q8: A 60 year-old man with a mechanical aortic valve presents with 2 weeks of fever, fatigue, and shortness of breath. He has a history of a dental procedure done 3 weeks back. Blood cultures are negative. FDG-PET/CT shows abnormal uptake around the valve. Which major criterion from the Modified Duke’s Criteria does this patient meet? (Q850467)

A. Negative blood culture for a typical organism

B. Evidence of endocardial involvement by FDG-PET/CT

C. Osler nodes and Janeway lesions

D. Recent history of dental procedure

Correct Answer: B. Evidence of endocardial involvement by FDG-PET/CT

■ *Listen to Audio 1*

Explanation: The FDG-PET/CT scan revealed abnormal uptake around the prosthetic valve, which is considered a major criterion under the Modified Duke’s Criteria. FDG-PET/CT is useful in cases involving prosthetic valves where traditional blood cultures might be negative, helping to detect inflammation around the valve, consistent with endocardial involvement. Modified Duke’s Criteria - Major criteria Positive blood cultures Identification of a typical organism from two cultures, or persistent positive cultures drawn more than 12 hours apart. Three or more positive cultures that have been taken over at least one hour apart. A single positive blood culture for Coxiella burnetii or a phase I IgG antibody titre > 1:800. Evidence of endocardial involvement Positive echocardiographic findings such as vegetations, abscesses, or new valvular regurgitation. Oscillating intracardiac masses or partial dehiscence of a prosthetic valve. Additional diagnostic tools like FDG-PET/CT or EKG-gated cardiac CT angiograms also meet major criteria for prosthetic valve endocarditis. (Added by the European Society of Cardiology)

References:

Harrison's Principles of Internal Medicine, 22nd Edition, Page 1040.

Davidson’s Principles and Practice of Medicine, 24th Edition, Page 529

↑ *Back to this question in Part A*

@Neet_pg_bot

Q9: A 30 year old woman who is known case of rheumatic heart disease and mitral regurgitation presents with complaints of fever for past 2 weeks.Echo showed vegetations on both surfaces of mitral valve.Blood cultures grew staphylococcus aureus. Which of the following would be immunological phenomenon seen in these patient? (Q850464)

A. Janeway lesions and Osler's nodes

B. Roth spots and Osler nodes

C. Carditis and Arthritis

D. Splinter hemorrhages in nails and clubbing

Correct Answer: B. Roth spots and Osler nodes

■ *Listen (English)*

■ *Listen (Hindi)*

Explanation: Immunological phenomena are ROG : R oth spots on fundus examination R A factor is positive (Suggests chronic immune activation) O sler nodes (Pea-shaped nodules in tips of fingers and occur due to immune complex deposition in dermal vessels) and G lomerulonephritis. Janeway lesions and Osler's nodes (Option A) is for vascular phenomenon seen in these patients. Carditis and Arthritis (Option C) is for rheumatic fever Manifestations: Cardiac manifestations: Perforation: Contributing to new onset murmur Paravalvular abscess Ring abscess Heart block CHF (Congestive Heart Failure) Intracardiac fistula Coronary embolization of vegetations Non-Cardiac manifestations: Janeway lesions Painless, erythematous macules on palms and soles. Related to septic microembolization Osler’s nodes Small painful pea-shaped nodules located at the tips of fingers and toes (Immune complex mediated). Subungual haemorrhages/Splinter haemorrhages More common in acute S. aureus IE. Haemorrhages below nails- multiple linear lesions, initially red then turning brown or black. Roth spots Pale-centred retinal haemorrhages that are seen in the fundus examination


@Neet_pg_bot

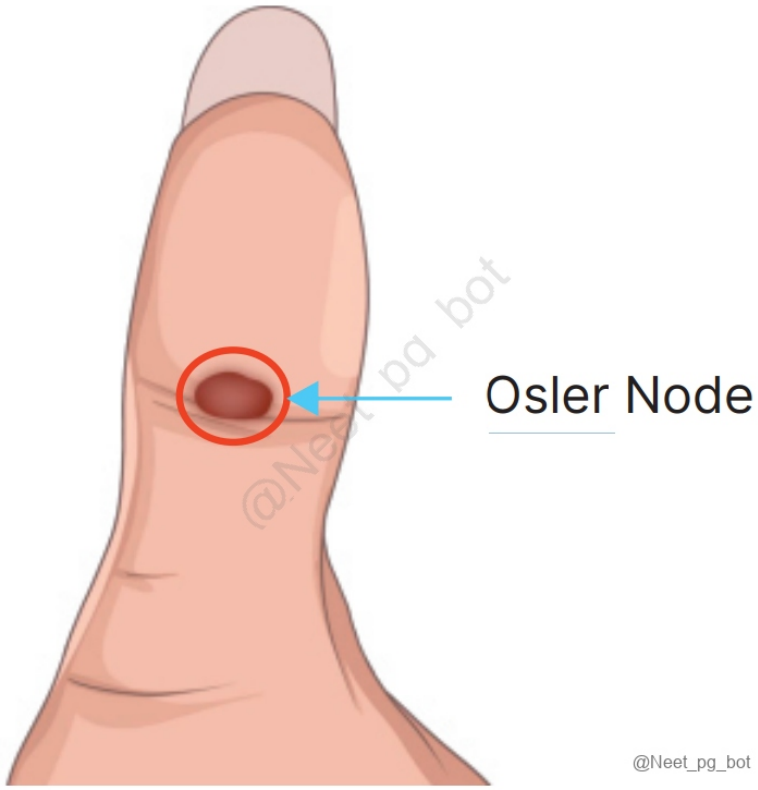
Osler Node
@Neet_pg_bot



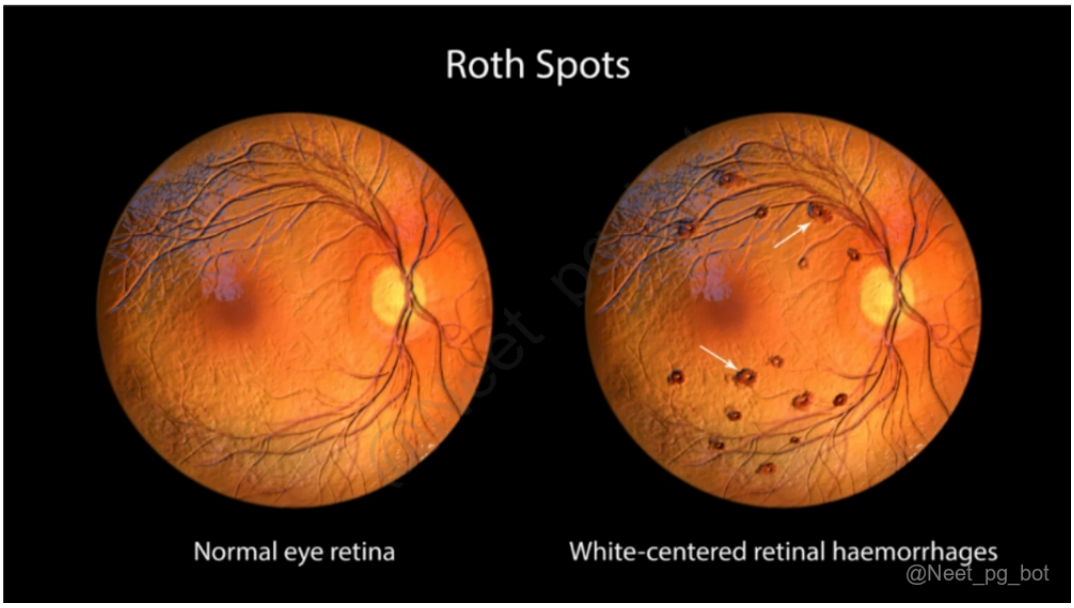

References:

Harrison's Principles of Internal Medicine, 22nd Edition, Page 1040.

↑ *Back to this question in Part A*

@Neet_pg_bot

Q10: In the context of infective endocarditis, what role do MSCRAMMs play in the disease process? (Q850463)

A. They enhance the immune response against pathogens during bacteremia.

B. They facilitate bacterial adherence to nonbacterial thrombotic endocarditis (NBTE) or injured endothelium.

C. They are responsible for the formation of emboli that lead to tissue infarction.

D. They promote the breakdown of vegetation formed in the heart.

Correct Answer: B. They facilitate bacterial adherence to nonbacterial thrombotic endocarditis (NBTE) or injured endothelium.

■ *Listen (English)*

■ *Listen (Hindi)*

Explanation: MSCRAMMs (Microbial Surface Components Recognising Adhesive Matrix Molecules) are adhesion proteins expressed by organisms like Staphylococcus aureus and Staphylococcus epidermidis . They allow bacteria to stick to exposed extracellular matrix and the sterile platelet–fibrin thrombus (NBTE), initiating vegetation formation in infective endocarditis. Enhance immune response (Option A): Incorrect; MSCRAMMs help bacteria evade immunity, not enhance it. Formation of emboli (Option C): Emboli occur due to friable vegetations, not MSCRAMMs. Breakdown of vegetation (Option D): MSCRAMMs promote adhesion, not degradation.

References:

Harrison's Principles of Internal Medicine, 22nd Edition, Page 1038.

↑ *Back to this question in Part A*

@Neet_pg_bot

Q11: A 65 year old male with ischemic cardiomyopathy and a history of benign prostatic hyperplasia presents with fever, malaise, and a new heart murmur. He recently underwent a urinary catheterisation for urinary retention. Blood cultures are positive for gram-positive cocci. What is the most likely causative organism of his infective endocarditis? (Q850461)

A. Staphylococcus aureus

B. Streptococcus gallolyticus

C. Enterococcus faecalis

D. Haemophilus species

Correct Answer: C. Enterococcus faecalis

■ *Listen (English)*

■ *Listen (Hindi)*

Explanation: Enterococcus faecalis is a gram-positive cocci and is frequently linked to infective endocarditis following genitourinary procedures, such as catheterization. Portals of entry Oral cavity: The entry point for viridans streptococci. Skin: Common entry point for staphylococci and S.epidermidis. Upper respiratory tract: Source for HACEK organisms (Haemophilus, Aggregatibacter, Cardiobacterium hominis, Eikenella corrodens, Kingella). (Option D ruled out) Gastrointestinal tract: Streptococcus gallolyticus (formerly S. bovis) is associated with colonic polyps and tumours. (Option B ruled out) Genitourinary tract and GI tract procedures (catheterization, colonoscopy): Source for enterococci. Nosocomial (hospital-acquired) sources: S. aureus, coagulase-negative staphylococci (CoNS), and enterococci are often linked to healthcare-associated infective endocarditis. (Option A ruled out) Prosthetic valve infections (PVE): Intraoperative contamination or postoperative infection, especially with S. aureus, CoNS, and gram-negative bacilli. Intravenous drug use: Primary portal for S. aureus infections, especially in tricuspid valve involvement. (Option A ruled out)

References:

Harrison's Principles of Internal Medicine, 22nd Edition, Page 1038.

↑ *Back to this question in Part A*

@Neet_pg_bot

Q12: A 68 year old farmer with a prosthetic valve presents with fever, night sweats, and fatigue 6 months post-surgery. Blood cultures are negative. He has goats and cows on his farm . Which organism is most likely responsible for his prosthetic valve endocarditis? (Q850460)

A. Staphylococcus epidermidis

B. Coxiella burnetii

C. Mycobacterium chimaera

D. Enterococcus faecalis

Correct Answer: B. Coxiella burnetii

■ *Listen (English)*

■ *Listen (Hindi)*

Explanation: Culture-Negative Infective Endocarditis (IE) Coxiella burnetii, and Bartonella species are due to exposure to animals. Common Cause : One-third to one-half of culture-negative cases are due to prior antibiotic exposure. Fastidious Organisms : Streptococci, Granulicatella, and Abiotrophia species. HACEK organisms - Haemophilus, Aggregatibacter, Cardiobacterium, Eikenella, and Kingella

References:

Harrison's Principles of Internal Medicine, 22nd Edition, Page 1354.

↑ *Back to this question in Part A*

@Neet_pg_bot

Q13: A 3 year girl with a history of patent ductus arteriosus presents with high grade fever. Her recent echocardiogram shows vegetations along the inner lining of her aorta. Which of the following conditions is the most likely diagnosis for this patient based on her symptoms and history? (Q850459)

A. Acute bacterial endocarditis

B. Subacute bacterial endocarditis

C. Infective endarteritis

D. Fungal endocarditis

Correct Answer: C. Infective endarteritis

■ *Listen (English)*

■ *Listen (Hindi)*

Explanation: The key-words are vegetations along the wall of the aorta in case of patent ductus arteriosus, which point more towards infective endarteritis. Infective endarteritis is an infection of the inner layer of arteries, often affecting shunts (arteriovenous, arterio-arterial like PDA) or coarctation of the aorta. Acute bacterial endocarditis (Option A): Involves rapid infection of normal valves, usually by Staphylococcus aureus , not arterial walls. Subacute bacterial endocarditis (Option B): Affects abnormal valves with slower progression, not the aorta. Fungal endocarditis (Option D): Involves large friable vegetations on valves, typically in immunocompromised or IV drug users.

References:

Harrison's Principles of Internal Medicine, 22nd Edition, Page 1036.

↑ *Back to this question in Part A*

@Neet_pg_bot

Q14: A 72 year female with a history of mitral valve prolapse presents with a fever and fatigue for last > 2 weeks. Physical examination reveals a new heart murmur and petechiae on her extremities. Blood cultures are sent. What is the leading organism

associated with this patient's probable condition? (Q850458)

A. Staphylococcus aureus

B. Streptococcus viridans

C. Enterococcus faecalis

D. HACEK organisms

Correct Answer: B. Streptococcus viridans

■ *Listen (English)*

■ *Listen (Hindi)*

Explanation: The patient's symptoms have persisted for > 2weeks aligning with the gradual onset characteristic of subacute bacterial endocarditis. Additionally, her history of mitral valve prolapse suggests a predisposing condition for the development of endocarditis. Streptococcus viridans is the most common organism associated with subacute bacterial endocarditis. Acute Bacterial Endocarditis Subacute Bacterial Endocarditis -Presentation as Fever, fatigue, and malaise within <2 weeks of infection Slow progression compared to Acute endocarditis. Signs : Changing heart murmur , Janeway lesions (hemorrhagic macules on palms/soles), petechiae, Roth's spots, splinter haemorrhages Signs : Gradual onset presentation over weeks to months (>2 weeks) but can be life-threatening if untreated Causative organisms : S. aureus Causative organism: Streptococcus viridans (Most common cause)

References:

Harrison's Principles of Internal Medicine, 22nd Edition, Page 1206, 2417.

↑ *Back to this question in Part A*

@Neet_pg_bot

Q15: Which of the following lists the valves in order of frequency of involvement in infective endocarditis, from most to least commonly affected? (Q850456)

A. Mitral valve > Aortic valve > Tricuspid valve > Pulmonic valve

B. Aortic valve > Mitral valve > Pulmonic valve > Tricuspid valve

C. Tricuspid valve > Mitral valve > Aortic valve > Pulmonic valve

D. Pulmonic valve > Aortic valve > Tricuspid valve > Mitral valve

Correct Answer: A. Mitral valve > Aortic valve > Tricuspid valve > Pulmonic valve

■ *Listen (English)*

■ *Listen (Hindi)*

Explanation: The Rationale is that mitral valve operates at the highest pressure gradient in the heart followed by the aortic valve. On the right side it is tricuspid followed by the pulmonic valve.

References:

emedicine.medscape.com/article/216650-overview

↑ *Back to this question in Part A*

@Neet_pg_bot

Q16: Which of the following statements is false regarding right-sided infective endocarditis (IE)? (Q850455)

A. Right-sided infective endocarditis is more commonly associated with enterococci than left-sided infective endocarditis.

B. Staphylococcus aureus is the most common pathogen in right-sided infective endocarditis

C. Injecting particles are more likely to reach the right-sided valves compared to the left-sided valves

D. Right-sided infective endocarditis has a better long-term prognosis compared to left-sided infective endocarditis

Correct Answer: A. Right-sided infective endocarditis is more commonly associated with enterococci than left-sided infective endocarditis.

■ *Listen (English)*

■ *Listen (Hindi)*

Explanation: Enterococci are more common in left-sided infective endocarditis than in right-sided IE. Staphylococcus aureus is responsible for IE in IVDU due to poor injection hygiene. (Option B) Injected particles damage right-sided valves. (Option C) Right-sided infective endocarditis has a better long-term prognosis (Option D)

References:

Harrison's Principles of Internal Medicine, 22nd Edition, Page 1037.

↑ *Back to this question in Part A*

@Neet_pg_bot

Q17: A 72 year old woman presents with severe chest pain and shortness of breath after the death of her husband. She has no history of heart disease. ECG shows STE of 2 mm in lead I , aVL, V2-V4. Bedside echocardiogram shows left ventricular ballooning and cardiac biomarkers are elevated. What is the most likely diagnosis? (Q850403)

A. Anterior wall MI

B. Takotsubo Cardiomyopathy

C. Inferior wall MI

D. Pulmonary Embolism

Correct Answer: B. Takotsubo Cardiomyopathy

■ *Listen (English)*

■ *Listen (Hindi)*

Explanation: Takotsubo cardiomyopathy, also known as broken heart syndrome, is characterized by left ventricular dysfunction often triggered by emotional stress. The patient's recent stressful event, ballooning of the left ventricle, and elevation of cardiac enzymes align perfectly with this diagnosis Anterior wall MI (Option A): Presents with similar ECG changes but has obstructive LAD lesion on angiography. Inferior wall MI (Option C): Causes ST elevation in leads II, III, and aVF, not V2–V4. Pulmonary embolism (Option D): Shows sinus tachycardia or S1Q3T3 pattern, not diffuse ST elevation.

References:

Harrison's Principles of Internal Medicine, 22nd Edition, Page 2019, 3164.

↑ *Back to this question in Part A*

@Neet_pg_bot

Q18: Which of the following is the most common echocardiographic finding associated with rheumatic carditis in children? (Q850453)

A. Aortic regurgitation

B. Mitral regurgitation

C. Aortic stenosis

D. Mitral stenosis

Correct Answer: B. Mitral regurgitation

■ *Listen (English)*

■ *Listen (Hindi)*

Explanation: The most common valvular lesion seen in Rheumatic carditis in children is mitral regurgitation. The same patient, after 18 years of age will have Mitral stenosis (predominant lesion) with mitral regurgitation.

References:

Harrison's Principles of Internal Medicine, 22nd Edition, Page 2855.

↑ *Back to this question in Part A*

@Neet_pg_bot

Q19: A 12 year old girl presents with involuntary, jerky movements in her hands and feet, worsening with stress or purposeful tasks and does not interferes with eating. Her mother tells that for 3 months she had developed arthritis that caused her to limp for a week with swelling of knee and ankle joints. Work up shows increased PR interval, What is the most appropriate initial treatment? (Q850451)

A. Penicillin prophylaxis

B. Haloperidol

C. Intravenous immunoglobulin (IVIG)

D. Carbamazepine

Correct Answer: A. Penicillin prophylaxis

■ *Listen (English)*

■ *Listen (Hindi)*

Explanation: The patient has Sydenham's chorea , a delayed complication of acute rheumatic fever following untreated streptococcal pharyngitis. Penicillin prophylaxis is the initial step to prevent further streptococcal infection and recurrent episodes of rheumatic fever, even if no active infection is present. Clinical features of Sydenham's chorea: Darting tongue / Harlequin tongue Pronator sign Hung up reflexes Emotional lability Signs seen in Sydenham's chorea: Tongue fasciculations (" Bag of worms ") Motor impersistence, for example, the "Milkmaid sign" (grip strength fluctuates, as if hand milking a cow), Inability to sustain tongue protrusion (called Jack-in-the-box tongue or Serpentine tongue , as the tongue slides in and out of the mouth) Treatment for Sydenham’s Chorea: Moderate to severe chorea Category Medications Purpose Initial Antibiotic Prophylaxis Benzathine penicillin G Prevent the recurrence of rheumatic fever Additional Treatment Neuroleptics : Pimozide, haloperidol, risperidone, olanzapine (Option B ruled out) Control chorea symptoms Anticonvulsants : Valproate, carbamazepine (Option D ruled out) Off-label use for symptom management Immunomodulatory Therapy

Corticosteroids, Intravenous immunoglobulin (IVIG), Plasma exchange (Option C ruled out) For severe/persistent symptoms Mild chorea does not need any treatment

References:

Harrison's Principles of Internal Medicine, 22nd Edition, Page 2858.

↑ *Back to this question in Part A*

@Neet_pg_bot

Q20: A 25 year woman presents with a history of exertional dyspnea, palpitations, and episodes of syncope. She recalls experiencing multiple episodes of sore throat as a child, followed by joint pains, for which she received no definitive treatment. On auscultation, there is a diastolic murmur at the apex and a loud S1. An echocardiogram reveals mitral valve orifice < 1.5 cm 2 with left atrial enlargement. What is the next most appropriate step in management? (Q850450)

A. Mitral balloon valvotomy

B. Mitral valve repair

C. ACE Inhibitors and rate control drugs

D. Immediate mitral valve replacement

Correct Answer: A. Mitral balloon valvotomy

■ *Listen (English)*

■ *Listen (Hindi)*

Explanation: The patient has rheumatic mitral stenosis secondary to untreated rheumatic fever in childhood, leading to significant narrowing of the mitral valve and left atrial enlargement. Mitral balloon valvotomy is the treatment of choice for symptomatic patients with mitral stenosis who do not have significant mitral regurgitation or left atrial thrombus. It is a minimally invasive procedure that can significantly improve valve function and relieve symptoms. Mitral valve repair (Option B): It is standard for regurgitation but rarely first line for mitral stenosis. In MS, thickened leaflets and fused commissures make repair harder than valvotomy. ACE Inhibitors and rate control drugs (Option C): Medical therapy eases symptoms but does not relieve the mechanical obstruction. ACE inhibitors help HFrEF, not MS, where the problem is filling; rate-control drugs can lengthen diastole but are not the next step once the patient has syncope and already needs mechanical intervention. Immediate mitral valve replacement (Option D): It is an invasive open-heart surgery using a prosthetic valve. It is reserved for patients unsuitable for balloon valvotomy (heavy calcification, major MR, or atrial thrombus); in a young adult, we prefer valve preservation to avoid lifelong anticoagulation or early prosthetic failure.

References:

Harrison's Principles of Internal Medicine, 22nd Edition, Page 1893, 2050. Davidson’s Principles and Practice of Medicine, 24th Edition, Page 465, 467, 517, 519, 521, 524, 525

↑ *Back to this question in Part A*

@Neet_pg_bot

Q21: A 35-year-old woman presents with progressive exertional dyspnea, fatigue, and occasional palpitations. O/E, she has an irregular pulse, a loud S1, an opening snap, and a low-pitched diastolic rumble at the apex. She recalls a childhood illness with fever and joint pain requiring hospitalization. Which of the following investigations is NOT primarily used in diagnosing her condition? (Q850449)

A. Echocardiography

B. Electrocardiogram

C. Blood cultures

D. Chest X-ray

Correct Answer: C. Blood cultures

■ *Listen (English)*

■ *Listen (Hindi)*

Explanation: The hallmark auscultatory findings of mitral stenosis is loud S1, opening snap, and diastolic rumble. Echo will tell you about the severity of Mitral stenosis. ECG will inform about cardiac chamber enlargement and PR interval prolongation which is a minor diagnostic criteria. Blood cultures are primarily used in diagnosing infective endocarditis, not for diagnosing RHD itself. They help identify pathogens when infection is suspected, particularly in patients with fever and valvular vegetation. Diagnosis of RHD: Blood Tests Leukocytosis, ESR, CRP Indicators of systemic illness. Raised ESR and CRP are common inflammatory markers. Throat Swab Culture Used to identify group A β-haemolytic streptococci . Cultures may also be taken from family members and contacts to confirm the source of infection. Antistreptolysin O (ASO) titres Elevated ASO levels (> 200 U in adults, > 300 U in children) or rising titres support the diagnosis of acute rheumatic fever. Normal ASO titres do not rule out the disease. Investigations Electrocardiogram (ECG) (Option B ruled out) Shows first-degree, and rarely, second-degree atrioventricular block. Pericarditis features. T-wave inversion. QRS voltage reduction. Chest X-ray (Option D ruled out) Identifies cardiomegaly and pulmonary congestion. Echocardiography (Option A ruled out) Reveals cardiac dilatation. Detects valve abnormalities: Commonly mitral regurgitation with mitral annulus dilatation and anterior mitral leaflet prolapse. Shows aortic regurgitation. Identifies pericardial effusion.

References:

Harrison's Principles of Internal Medicine, 22nd Edition, Page 2857. Davidson’s Principles and Practice of Medicine, 24th Edition, Page 488, 517, 530, 536, 538, 542, 620

↑ *Back to this question in Part A*

@Neet_pg_bot

Q22: Which of the following is not a part of the major criteria for a low-risk population? (Q850445)

A. Carditis

B. Polyarthritis

C. Chorea

D. Polyarthralgia

Correct Answer: D. Polyarthralgia

■ *Listen (English)*

■ *Listen (Hindi)*

Explanation: Polyarthralgia is not part of the major criteria; it is a minor criterion for low-risk populations but is a major criterion for high-risk populations. Carditis, Polyarthritis and Chorea (Option A,B and C): Major Jones criteria in both low- and high-risk populations. Modified Jones Criteria for Rheumatic Fever: Criteria Low-Risk Population High-Risk Population Major Criteria Carditis (clinical or subclinical) (Option A ruled out) Polyarthritis (Option B ruled out) Chorea (Option C ruled out) Erythema marginatum Subcutaneous nodules Carditis (clinical or subclinical) Monoarthritis or Polyarthritis Chorea Erythema marginatum Subcutaneous nodules Polyarthralgia (Option D) Minor Criteria Polyarthralgia (Option D) Hyperpyrexia (≥ 38.5ºC) ESR ≥ 60 mm/h and/or CRP ≥ 3.0 mg/dl Prolonged PR interval (if no there is no carditis in major criterion) Monoarthralgia Hyperpyrexia (≥ 38.0ºC) ESR ≥ 30 mm/h and/or CRP ≥ 3.0 mg/dl Prolonged PR interval (if no there is no carditis in major criterion)

References:

Harrison's Principles of Internal Medicine, 22nd Edition, Page 2857

Davidson’s Principles and Practice of Medicine, 24th Edition, Page 515

↑ *Back to this question in Part A*

@Neet_pg_bot

Q23: Which of the following is correct about St Vitus's dance? (Q850443)

A. It is an early manifestation of rheumatic fever

B. It occurs in all patients with rheumatic fever

C. It is associated with emotional lability

D. It is a minor diagnostic criteria

Correct Answer: C. It is associated with emotional lability

■ *Listen (English)*

■ *Listen (Hindi)*

Explanation: St Vitus's dance is another name for Sydenham's chorea. Sydenham's chorea is characterized by involuntary, purposeless movements, and significant emotional instability , often presenting as mood swings and obsessive-compulsive traits. It is more common in females. These features highlight its distinctive neurological profile as a complication of rheumatic fever.

References:

Harrison's Principles of Internal Medicine, 22nd Edition, Page 2856.

Davidson’s Principles and Practice of Medicine, 24th Edition, Page 516

↑ *Back to this question in Part A*

@Neet_pg_bot

Q24: A 5 year old boy presents with fever and migratory joint pain. On auscultation, a soft mid-diastolic murmur is heard at the apex. Echocardiography reveals mitral valve inflammation. Which of the following is most likely present in this patient? (Q850442)

A. Mitral stenosis murmur

B. Austin Flint murmur

C. Carey Coombs murmur

D. Graham Steele Murmur

Correct Answer: C. Carey Coombs murmur

■ *Listen (English)*

■ *Listen (Hindi)*

Explanation: Characterstic murmur of RHD is Carey Coombs murmur. It is a soft mid-diastolic apical murmur due to inflammation of the mitral valve leaflets (valvulitis) in acute rheumatic fever (ARF). It is a Flow murmur that occurs due to increased blood flow across thickened leaflets of mitral valve. This is specifically associated with ARF and reflects early mitral valve involvement. Mitral stenosis murmur (Option A): Mitral stenosis is seen after 18 years of age in RHD. It does not have valvulitis but has commisural fusion. Austin Flint (Option B) is seen in

Severe AR Graham Steel (Option D) is seen in PAH causing mild pulmonic regurgitation.

References:

Harrison's Principles of Internal Medicine, 22nd Edition, Page 288.

Davidson’s Principles and Practice of Medicine, 24th Edition, Page 515, 516, 517

↑ *Back to this question in Part A*

@Neet_pg_bot

Q25: Which of the following clinical features is most commonly associated with Acute Rheumatic fever in the Indian population? (Q850437)

A. Polyarthritis

B. Erythema Marginatum

C. Subcutaneous Nodules

D. Pulmonary Hypertension

Correct Answer: A. Polyarthritis

■ *Listen (English)*

■ *Listen (Hindi)*

Explanation: Polyarthritis is the most common symptom in ARF , seen in 60-75% of cases. In India, polyarthritis remains a prominent early manifestation of ARF. India has a high incidence of rheumatic heart disease, ranging from 13 to 150 cases per 100,000 population annually.

References:

Harrison's Principles of Internal Medicine, 22nd Edition, Page 2855-2856. Davidson’s Principles and Practice of Medicine, 24th Edition, Page 515

↑ *Back to this question in Part A*

@Neet_pg_bot

Q26: A 10 y/o boy presents with fever, joint pain, and a recent history of sore throat. Examination reveals a heart murmur suggestive of mitral regurgitation. Laboratory tests show elevated antistreptolysin O titers. Which of the following best explains the pathogenesis of his condition? (Q850435)

A. Direct invasion of heart valves by Streptococcus bacteria

B. Immune response triggered by molecular mimicry between bacterial antigens and heart tissue

C. Autoimmune destruction of heart valves due to viral infection

D. Genetic mutations in heart muscle proteins

Correct Answer: B. Immune response triggered by molecular mimicry between bacterial antigens and heart tissue

■ *Listen (English)*

■ *Listen (Hindi)*

Explanation: RF is an autoimmune process with ASO antibody causing damage to self cardiac tissues. It is an example of type 2 hypersensitivity/ molecular mimicry.

References:

Harrison's Principles of Internal Medicine, 22nd Edition, Page 2854-2855.

↑ *Back to this question in Part A*

@Neet_pg_bot

Q27: A 11 year boy with a history of acute rheumatic fever without carditis presents for follow-up. Based on the AHA guidelines, what is the recommended duration for continuing secondary prophylaxis in this patient? (Q850432)

A. Continue prophylaxis for 1 more year

B. Continue prophylaxis until the age of 25

C. Continue prophylaxis on lifelong basis

D. Continue prophylaxis until the age of 21

Correct Answer: D. Continue prophylaxis until the age of 21

■ *Listen (English)*

■ *Listen (Hindi)*

Explanation: Secondary Prevention in Acute Rheumatic Fever Duration of Prophylaxis Determined by the presence and severity of carditis, age, and time since the last ARF episode No Carditis 5 years or until 21 years of age, whichever is longer. Carditis without Valvular Disease 10 years or until 21 years of age, whichever is longer. Persistent Valvular Disease 10 years or until 40 years of age, whichever is longer. Lifelong prophylaxis may be needed in severe cases.

References:

Harrison's Principles of Internal Medicine, 22nd Edition, Page 2858.

↑ *Back to this question in Part A*

@Neet_pg_bot

Q28: Which of the following is not an indication for ICD implantation? (Q850430)

A. Chagas disease

B. Wolff-Parkinson-White syndrome

C. Hypertrophic cardiomyopathy

D. Long QT syndrome

Correct Answer: B. Wolff-Parkinson-White syndrome

■ *Listen (English)*

■ *Listen (Hindi)*

Explanation: While Wolff-Parkinson-White syndrome can lead to arrhythmias, it is typically amenable to catheter ablation, making ICD implantation unnecessary in the absence of other risk factors. Indication for ICD implantation Ischemic, Non-ischemic, Hypertrophic (Option C ruled out) , and Familial cardiomyopathy Arrhythmogenic right ventricular dysplasia Cardiac sarcoidosis Brugada syndrome Long-QT syndrome (Option D ruled out) Catecholaminergic polymorphic VT (CPVT) LV noncompaction Chagas disease (dilated cardiomyopathy due to infection) (Option A ruled out)

References:

Harrison's Principles of Internal Medicine, 22nd Edition, Page 2339-2340.

↑ *Back to this question in Part A*

@Neet_pg_bot

Q29: A 13 year old male is brought to ER by his father who noticed agonal breathing at 5 am in morning. He is the only child in family. Urgent ECG is done. What finding is noted? (Q850423)

A. Delta waves

B. Deep Q waves

C. Coved ST elevation

D. Epsilon waves

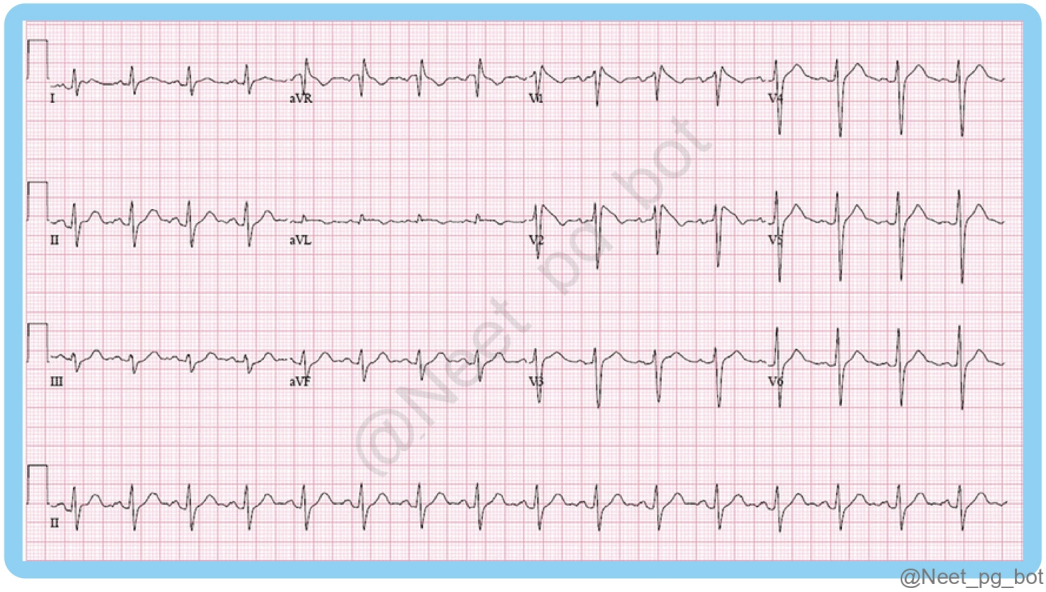

Correct Answer: C. Coved ST elevation

- *Listen (English)*
- *Listen (Hindi)*

Explanation: Notice the Coved ST elevation in V1-V3 which is seen in Brugada syndrome. It is a SCN5A defect and causes sudden nocturnal death in South east asian males. Epsilon waves are seen in ARVD and Deep Q waves in Hypertrophic cardiomyopathy and MI. Saddleback ST elevation (check out the arrow drawn at lead V2) is seen in Type 2 Brugada syndrome



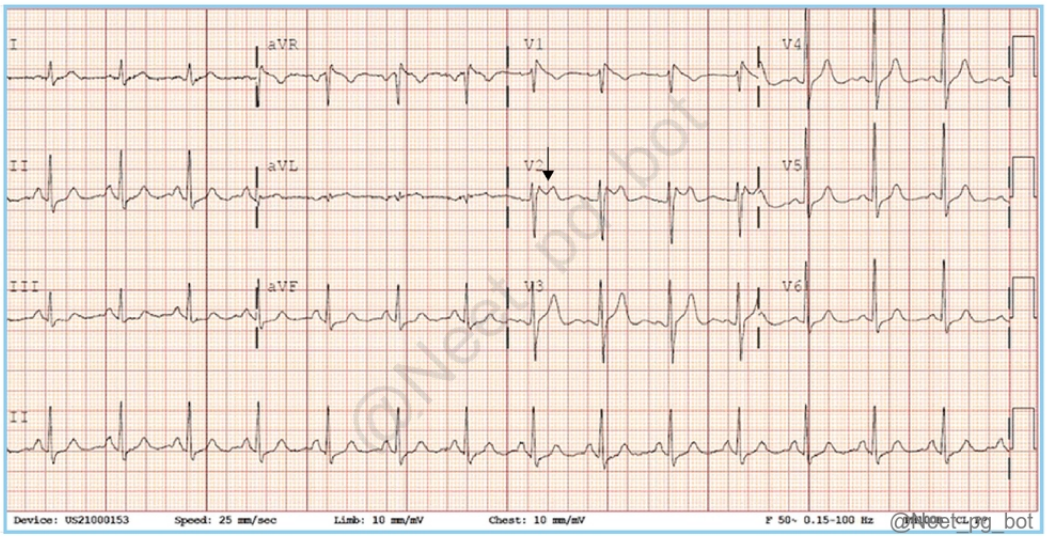

References:

Harrison's Principles of Internal Medicine, 22nd Edition, Page 1970.

↑ *Back to this question in Part A*

@Neet_pg_bot

Q30: A 15-year-old male presents to the ED after experiencing a brief episode of syncope. He reports occasional palpitations and dizziness. His family history is significant for sudden cardiac death at a young age. An ECG of leads V1-V3 is given below. Which of the following management options is most appropriate for this patient, given the findings? (Q850411)

A. Prescribe a beta-blocker and advise lifestyle modifications

B. Perform Troponin I levels

C. It is also called Broken heart syndrome

D. Deploy implantable cardioverter-defibrillator.

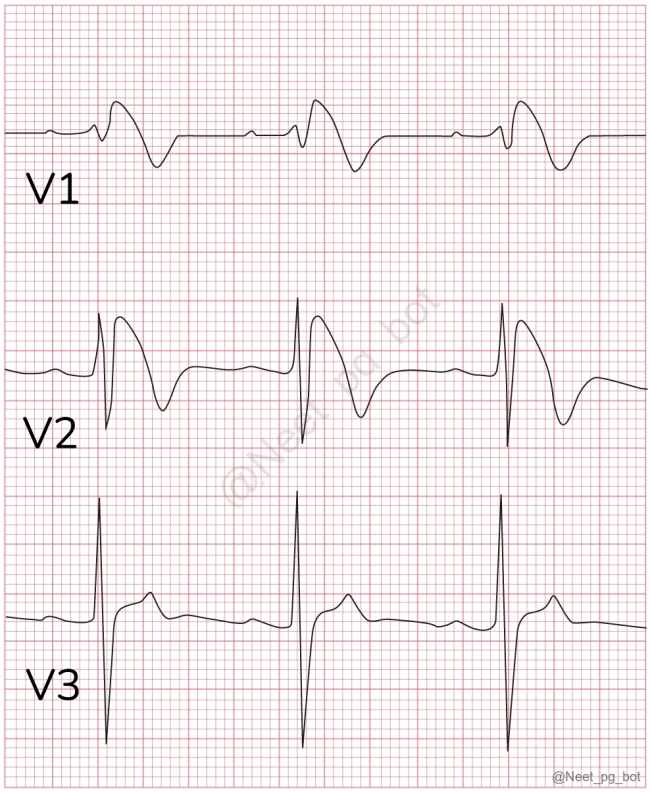

Correct Answer: D. Deploy implantable cardioverter-defibrillator.

■ *Listen (English)*

■ *Listen (Hindi)*

Explanation: ECG shows coved-type ST elevation >2 mm in V1–V3, characteristic of Brugada syndrome , which carries a high risk of sudden cardiac death. An ICD is the definitive management to prevent fatal arrhythmias. Prescribe a beta-blocker and advise lifestyle modifications (Option A): Beta-blockers are not effective and may worsen arrhythmias. Perform Troponin I levels (Option B): This is used for myocardial infarction, not Brugada syndrome. It is also called Broken heart syndrome (Option C): Refers to Takotsubo cardiomyopathy, not Brugada.

References:

Harrison's Principles of Internal Medicine, 22nd Edition, Page 1970.

↑ *Back to this question in Part A*

@Neet_pg_bot

Q31: A 68 year old postmenopausal woman presents to the emergency department with chest pain and dyspnea after a recent stressful event. Her ECG shows ST-segment elevation and cardiac biomarkers are elevated. What is the most appropriate next step in management of this patient? (Q850407)

A. Administer intravenous anticoagulation therapy

B. Implant an implantable cardioverter-defibrillator.

C. Initiate inotropic support immediately.

D. Perform coronary angiography

Correct Answer: D. Perform coronary angiography

■ *Listen (English)*

■ *Listen (Hindi)*

Explanation: The patient's symptoms, ST-segment elevation on ECG, and troponin elevation suggest Takotsubo cardiomyopathy, especially given her postmenopausal status and recent stress. The initial management focuses on ruling out obstructive coronary disease through coronary angiography while addressing acute symptoms. Administer intravenous anticoagulation therapy (Option A): Indicated for true MI or thromboembolism, not diagnostic here. Implant an implantable cardioverter-defibrillator (Option B): Not needed in transient, reversible stress cardiomyopathy. Initiate inotropic support immediately (Option C): Can worsen LV outflow obstruction; supportive care is preferred.

References:

Harrison's Principles of Internal Medicine, 22nd Edition, Page 2019

Davidson’s Principles and Practice of Medicine, 24th Edition, Page 541

↑ *Back to this question in Part A*

@Neet_pg_bot

• [01_Cardiology] 004 Ecg And Arrhythmias

« Back to Folder Directory

[01_Cardiology] 004 Ecg And Arrhythmias — Quick Jump

Q1 (p. 1158)	*Q2 (p. 1159)*	*Q3 (p. 1160)*	*Q4 (p. 1161)*	*Q5 (p. 1162)*	*Q6 (p. 1163)*
Q7 (p. 1165)	*Q8 (p. 1165)*	*Q9 (p. 1167)*	*Q10 (p. 1168)*	*Q11 (p. 1169)*	*Q12 (p. 1170)*
Q13 (p. 1171)	*Q14 (p. 1173)*	*Q15 (p. 1174)*	*Q16 (p. 1176)*	*Q17 (p. 1177)*	*Q18 (p. 1179)*
Q19 (p. 1180)	*Q20 (p. 1181)*	*Q21 (p. 1182)*			

Q1: A 68-year-old smoker man with a history of hypertension presents to the ER with complaints of palpitations and shortness of breath for the past 2 hours. On examination, his pulse is irregularly irregular with a rate of 140 beats per minute. An ECG of the patient is given below. He has poorly controlled COPD. Which of the following statements about his condition is incorrect? (Q850694)

A. Multiple ectopic foci due to structural damage to heart

B. Start beta blockers followed by warfarin

C. CHADS2VASc score is used to decide the need for anticoagulation

D. Amiodarone is used for chemical cardioversion

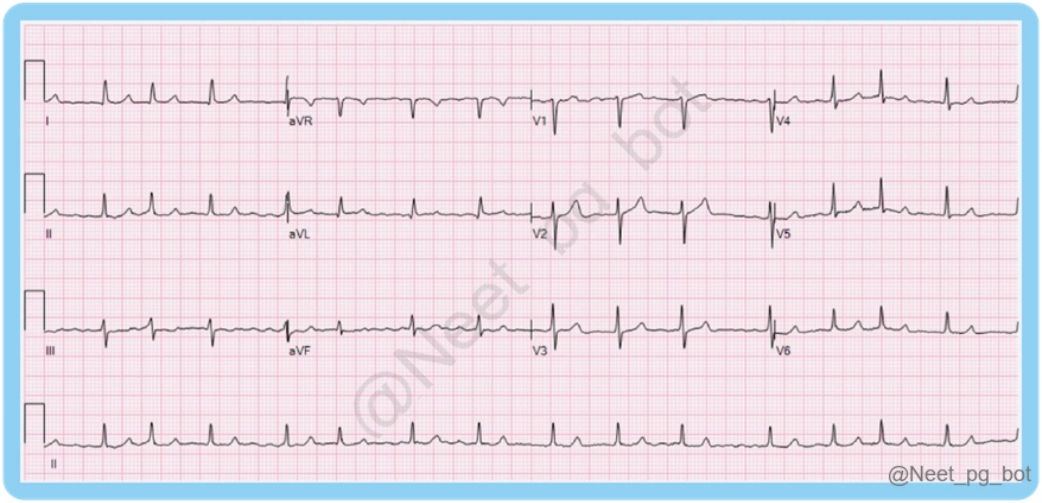

Correct Answer: B. Start beta blockers followed by warfarin

■ *Listen (English)*

■ *Listen (Hindi)*

Explanation: The patient's clinical presentation of irregularly irregular pulse and ECG findings indicate atrial fibrillation. Beta blockers are contraindicated in asthma /COPD patients. For anticoagulation in non valvular causes start apixaban or dabigatran. Warfarin is used for RHD with mitral stenosis causing atrial fibrillation. CHA2DS2-VASc stroke risk scoring system for AF Points Parameters Score C Congestive heart failure 1 H Hypertension history 1 A2 Age (≥75 years) 2 D Diabetes mellitus 1 S2 Previous stroke or transient ischemic attack (TIA) 2 V Vascular disease 1 A Age (65-74 years) 1 Sc Sex category (female) 1 Maximum total score 9 points Management option for AF as per CHA2DS2-VASc score 0: need not anticoagulate 1: Give aspirin >=2: Warfarin/Dabigatran/Rivaroxaban

References:

Harrison's Principles of Internal Medicine, 22nd Edition, Page 1949-1951 Davidson’s Principles and Practice of Medicine, 24th Edition, Page 470, 471, 472

↑ *Back to this question in Part A*

@Neet_pg_bot

Q2: A 68-year-old male patient with a history of hypertension presents to the emergency department in acute distress. He is diaphoretic, tachycardic, and complains of severe chest pain. BP is 90/60 mm Hg. His ECG is given below. Given the patient's condition, what is the most appropriate immediate management for this patient? (Q850728)

A. Amiodarone

B. Radiofrequency catheter ablation

C. Digoxin

D. Synchronized cardioversion



Correct Answer: D. Synchronized cardioversion

■ *Listen (English)*

■ *Listen (Hindi)*

Explanation: The patient's clinical presentation of acute distress, diaphoresis, tachycardia, and severe chest pain, along with the ECG showing saw-tooth flutter waves indicative of atrial flutter , suggests he is hemodynamically unstable. This necessitates immediate synchronized cardioversion to restore normal sinus rhythm and stabilize his condition. Atrial Flutter Management 1. Rhythm Control: Acute Management: Hemodynamically Unstable Patients: Synchronized cardioversion. Stable Patients: Electrical cardioversion (if no intracardiac thrombus). Pharmacological cardioversion: Antiarrhythmic drugs: Amiodarone Class IA: Procainamide, Quinidine, Disopyramide Class IC: Flecainide, Propafenone Calcium Channel Blockers: Verapamil, Diltiazem Beta-Blockers: Metoprolol, Carvedilol, Esmolol Long-Term Management: Radiofrequency catheter ablation of the cavotricuspid isthmus. 2. Rate Control: First-Line Agents: Calcium Channel Blockers (e.g., Verapamil, Diltiazem) Beta-Blockers (e.g., Metoprolol, Carvedilol, Esmolol) Digoxin (use cautiously due to toxicity). Goal: Heart rate < 110 beats per minute. 3. Anticoagulation: Assess stroke risk using the CHADS2-VASC score: Anticoagulation Recommendations: 2 or more points: Strong recommendation for anticoagulation. 1 point: Consider either aspirin or full anticoagulation.

References:

Harrison's Principles of Internal Medicine, 22nd Edition, Page 1944-1946.

Davidson’s Principles and Practice of Medicine, 24th Edition, Page 470

↑ *Back to this question in Part A*

@Neet_pg_bot

Q3: A 42-year-old woman diagnosed with stage IV breast cancer presents to the emergency department with confusion and breathing difficulty. BP on admission is 80/60 mm Hg. The ECG is attached below. Which of the following would be the most likely diagnosis in this patient? (Q850726)

A. Malignant pericardial effusion

B. Cardiac tamponade

C. Acute pericarditis

D. Constrictive pericarditis

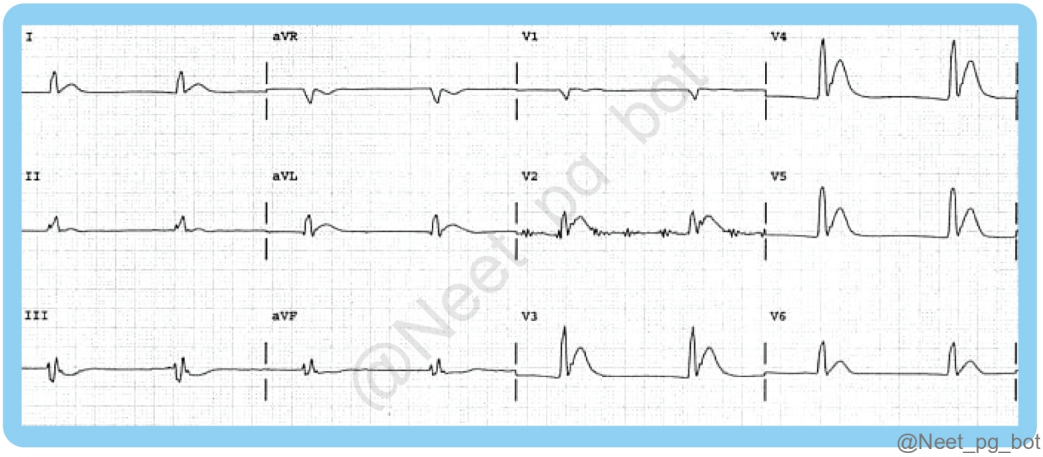

Correct Answer: B. Cardiac tamponade

■ *Listen (English)*

■ *Listen (Hindi)*

Explanation: ECG shows low voltage with electrical alternans in V3–V6, II, III, aVF. BP is low, indicating cardiac tamponade. Precordial leads show J point elevation / Osborn waves that can be explained by hypercalcemia caused by breast carcinoma. All the remaining options will have normal to low BP, but hemodynamic instability favours the diagnosis as cardiac tamponade.

References:

Harrison's Principles of Internal Medicine, 22nd Edition, Page 1905-1906.

↑ *Back to this question in Part A*

@Neet_pg_bot

Q4: A 45-year-old man is brought to the emergency department with confusion and muscle weakness. His laboratory results show a serum potassium level of 7.2 mEq/L.Which of the following T-wave morphologies is most likely to be seen on this patient's ECG? (Q850722)

Correct Answer: Unknown

■ *Listen (English)*

■ *Listen (Hindi)*

Explanation: In the setting of severe hyperkalemia (serum potassium > 7.0 mEq/L), the ECG typically shows peaked/tall T-waves, which is represented in Option C. T-wave abnormalities: {{caption_text}} T-wave Abnormality Associated Conditions and Characteristics Peaked T-waves Hyperkalemia: Narrow, pointed, called tall tented T-waves Myocardial infarction: Broad-based, asymmetric T-waves Left ventricular hypertrophy: Tall

T-waves in precordial leads Prinzmetal angina: Tall, pointed T-waves during chest pain Inverted T-waves Myocardial ischemia: Symmetrically inverted T-waves Wellens syndrome Cerebrovascular injury: cerebral T-waves Hypertrophic cardiomyopathy Pulmonary embolism in S1Q3T3

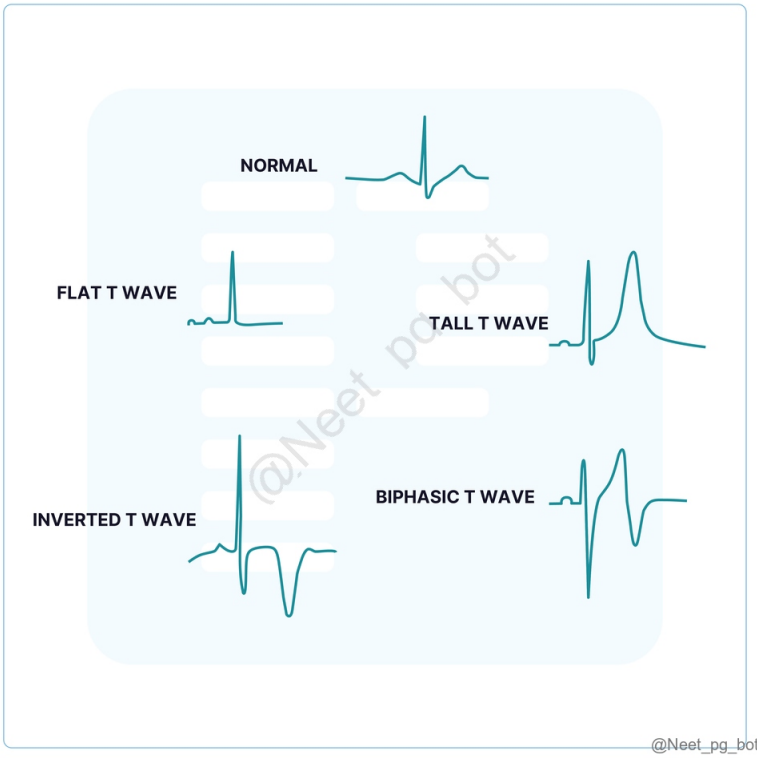

References:

Harrison's Principles of Internal Medicine, 22nd Edition, Page 359, 1874.

↑ *Back to this question in Part A*

@Neet_pg_bot

Q5: A 55-year-old alcoholic presents to the emergency department with sweating and palpitations. He is a known case of T2DM on metformin and Glipizide. Labs show plasma glucose 65 mg/dl, serum creatinine 2.0 mg/dl, BUN 70 mg/dl and serum potassium of 5.8 meq/dl. ECG is shown below. What is the next best step in the management of this patient? (Q850714)

A. Call nephrology for urgent hemodialysis

B. Stop metformin

C. Give IV dextrose with thiamine

D. Send to cath lab

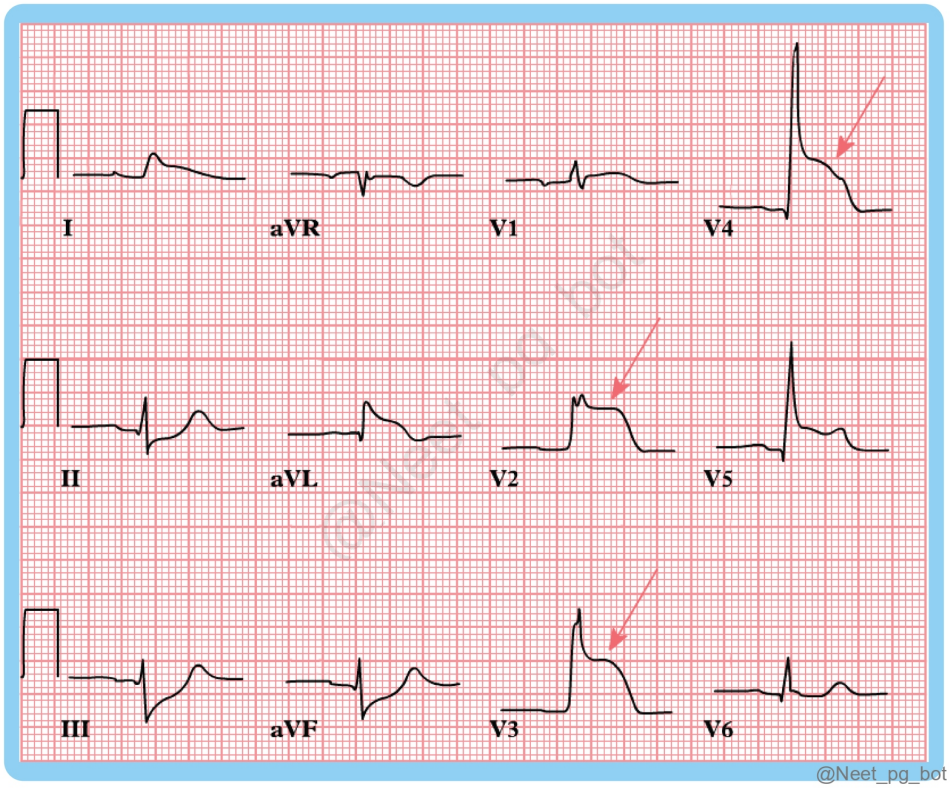

Correct Answer: D. Send to cath lab

■ *Listen (English)*

■ *Listen (Hindi)*

Explanation: The ECG shows ST elevation in leads I, AVL, and V2-V5 & reciprocal depressions in the inferior leads (II, III, AVF). This is a case of anterior wall STEMI, and PCI should be done within 90 minutes of arrival at the hospital. Call nephrology for urgent hemodialysis (Option A): Because: K■ 5.8 mEq/L is elevated but not at dialysis threshold, and STEMI management takes priority. Stop metformin (Option B): Metformin should be stopped in AKI, but this is not the immediate step in a STEMI emergency. Give IV dextrose with thiamine (Option D): Patient has no features of Wernicke encephalopathy and mild hypoglycemia can be corrected after stabilizing STEMI; not the first step.

References:

Harrison's Principles of Internal Medicine, 22nd Edition, Page 2119.

↑ *Back to this question in Part A*

@Neet_pg_bot

Q6: A 62-year-old man presents to the emergency department with palpitations and lightheadedness. His ECG shows a rapid, regular rhythm with a rate of 150 beats per minute, as shown below Which of the following conditions is most likely to be associated with this ECG finding? (Q850708)

A. Ventricular tachycardia

B. AV nodal re-entrant tachycardia

C. Wolf-Parkinson-White syndrome

D. Hypothermia

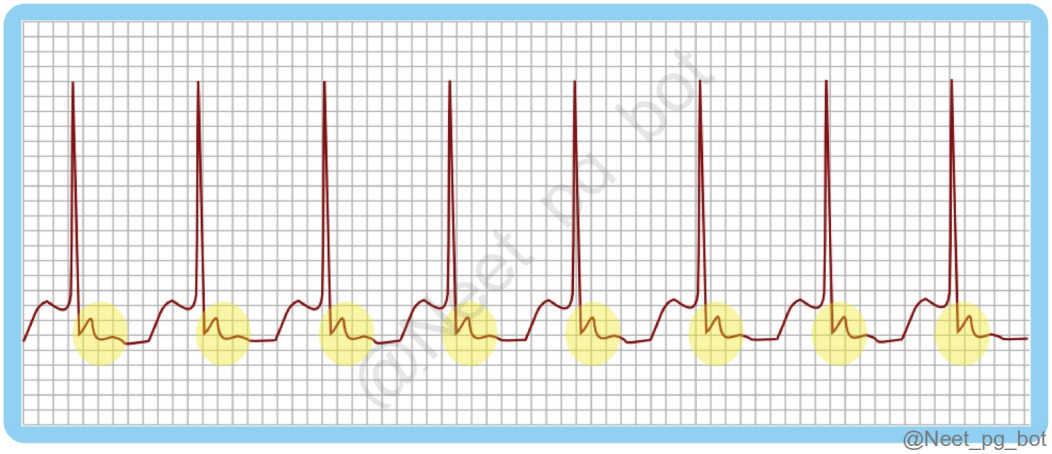

Correct Answer: B. AV nodal re-entrant tachycardia

■ *Listen (English)*

■ *Listen (Hindi)*

Explanation: The ECG shows a narrow qRS complex tachycardia seen in PSVT / AV nodal re-entrant tachycardia. The highlighted section in the ECG shows ST depression with P waves occurring after the RS complex. Rationale would be activation of atria after ventricles due to re-entry current. In most cases, these P waves may also not be seen. Ventricular tachycardia (Option A) will have broad QRS tachycardia. Wolf-Parkinson-White syndrome (Option C) has delta waves. Hypothermia (Option D) has osborn waves. Types of QRS Complex Abnormalities: Type of QRS Complex Associated Conditions Narrow QRS complex Tachycardia AV nodal re-entrant tachycardia, AV reentrant tachycardia (Orthodromic) Broad QRS complex Tachycardia Ventricular tachycardia, Torsades de Pointes Delta Wave Wolf-Parkinson-White syndrome J wave/Osbourne wave Hypothermia Epsilon wave Arrhythmogenic right ventricular dysplasia

References:

Harrison's Principles of Internal Medicine, 22nd Edition, Page 1940. Davidson’s Principle and Practice of Medicine Edition 24th Page 473, 474, 475

↑ *Back to this question in Part A*

@Neet_pg_bot

Q7: Match the following tachyarrhythmias with their respective pharmacological interventions Tachyarrhythmia Treatment 1. Atrial Fibrillation in Hypertension A. Adenosine 2. Stable Monomorphic Ventricular Tachycardia B. Esmolol followed by Anticoagulation 3. Torsades de Pointes C. Magnesium Sulfate 4. AV nodal re-entrant tachycardia D. Amiodarone (Q850706)

A. 1-B, 2-D, 3-C, 4-A

B. 1-B, 2-A, 3-D, 4-C

C. 1-D, 2-B, 3-A, 4-C

D. 1-A, 2-C, 3-B, 4-D

Correct Answer: A. 1-B, 2-D, 3-C, 4-A

■ *Listen (English)*

■ *Listen (Hindi)*

Explanation: 1 → B. Esmolol followed by Anticoagulation (Atrial fibrillation with hypertension → rate control with a β-blocker such as esmolol) 2 → D. Amiodarone (Stable monomorphic VT → amiodarone is the preferred antiarrhythmic) 3 → C. Magnesium sulfate (Torsades de pointes → first-line therapy is IV magnesium) 4 → A. Adenosine (AVNRT → adenosine is the drug of choice for acute termination)

References:

Harrison's Principles of Internal Medicine, 22nd Edition, Page 1938, 1942-1943, 1974. Goldberger’s Clinical Electrocardiography, A Simplified Approach, 9th Edition, Page. 139, 154, 167.

↑ *Back to this question in Part A*

@Neet_pg_bot

Q8: A 62-year-old woman presents to the ER with palpitations and lightheadedness. She is on azithromycin and cough syrup by her GP. BP on admission is 100/60 mm Hg. Her ECG is given below: Which of the following is the most appropriate immediate management for this patient? (Q850703)

A. Administer intravenous amiodarone

B. Perform immediate electrical cardioversion

C. Administer intravenous magnesium sulfate

D. Start oral beta-blocker therapy

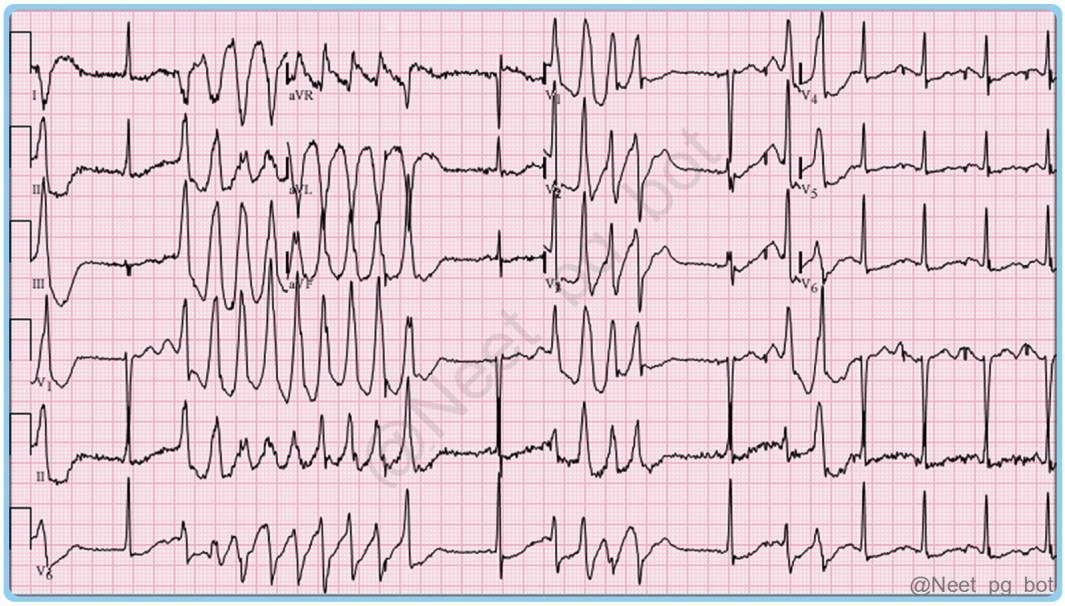

Correct Answer: C. Administer intravenous magnesium sulfate

■ *Listen (English)*

■ *Listen (Hindi)*

Explanation: The ECG is suggestive of Torsades de Pointes (TdP) , a specific form of polymorphic ventricular tachycardia occurring in the setting of QT interval prolongation. Key trigger is macrolides with over the counter cough syrups that may contain anti-histaminics like astemizole or terfenadine. This combination causes QT prolongation and triggers polymorphic ventricular tachycardia. Intravenous magnesium sulfate is the first-line treatment for TdP, as it helps suppress the triggering PVCs and can shorten the QT interval. Spindle-shaped pattern: The QRS complexes form a twisting or spindle-shaped "envelope." {{caption_text}} Treatment : Immediate management: Intravenous magnesium sulfate (even if serum magnesium is normal) Discontinue potential QT-prolonging medications Correct electrolyte abnormalities, especially hypokalemia Consider temporary pacing or isoproterenol infusion to increase heart rate and shorten QT interval Amiodarone (Option A) should be avoided as it can further prolong the QT interval. Immediate electrical cardioversion (Option B) is usually reserved for hemodynamically unstable patients. Oral beta-blockers (Option D) are not the immediate management, although they may be considered later in the treatment course.

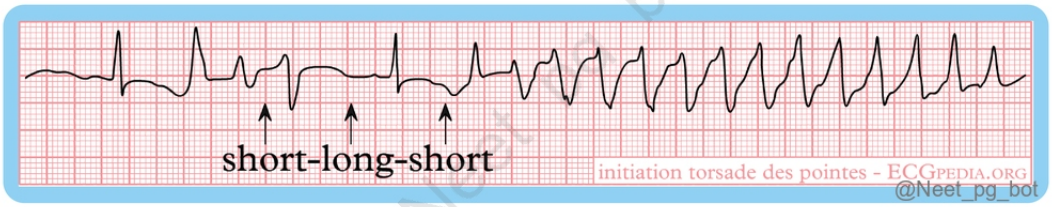

References:

Harrison's Principles of Internal Medicine, 22nd Edition, Page 1974-1975. Goldberger's Clinical Electrocardiography, A Simplified Approach, 9th Edition, Page. 166, 167.

↑ *Back to this question in Part A*

@Neet_pg_bot

Q9: A 65-year-old male with a history of prior myocardial infarction presents to the emergency department with severe palpitations, dizziness, and chest pain. He suddenly becomes pulseless and BP is unrecordable. An ECG shows wide QRS complexes, a regular rhythm, and a ventricular rate of 160 bpm. What is the most appropriate initial treatment for this patient? (Q850701)

A. Intravenous Adenosine

B. Intravenous Magnesium Sulfate

C. Defibrillation

D. Intravenous Procainamide

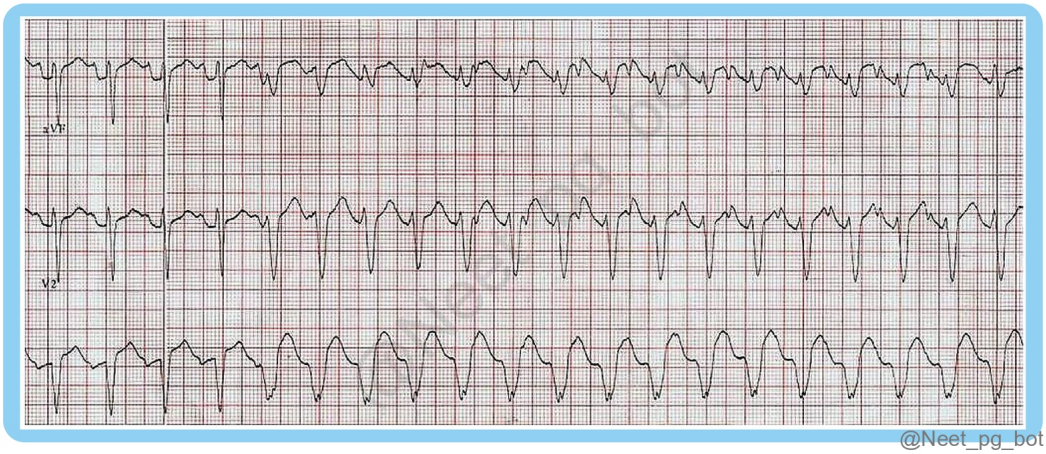

Correct Answer: C. Defibrillation

■ *Listen (English)*

■ *Listen (Hindi)*

Explanation: This patient has pulseless/ unstable monomorphic ventricular tachycardia (VT) as indicated by the wide QRS complexes, regular rhythm, and associated symptoms (hypotension, chest pain, altered mental status). Hemodynamic instability in VT requ ires immediate defibrillation. Treatment: Stable Monomorphic VT : Intravenous procainamide or amiodarone can be used. (Options A & D ruled out) Unstable Monomorphic VT : Immediate synchronized cardioversion is required. (Option C) Polymorphic VT (Torsades de Pointes) : IV magnesium sulfate and correction of underlying electrolyte abnormalities (e.g., hypokalemia) are crucial, along

with discontinuation of QT-prolonging drugs. (Option B ruled out)

References:

Harrison's Principles of Internal Medicine, 22nd Edition, Page 1964. Goldberger’s Clinical Electrocardiography, A Simplified Approach, 9th Edition, Page 167.

↑ *Back to this question in Part A*

@Neet_pg_bot

Q10: Which of the following is correct about Wolff-Parkinson-White syndrome? Accessory pathway between the atria and ventricles that lacks the decremental property Prolonged PR interval, delta waves, and narrow QRS complexes. Short PJ interval The drug of choice for an acute episode of palpitations is procainamide (Q850699)

A. 1 and 4 only

B. 2 and 3 only

C. 4 only

D. 1, 2, 3, and 4

Correct Answer: A. 1 and 4 only

■ *Listen (English)*

■ *Listen (Hindi)*

Explanation: Wolff-Parkinson-White (WPW) syndrome has an accessory electrical pathway between the atria and ventricles, bypassing the AV node. This accessory pathway, also known as the Bundle of Kent. PR interval is short (Option B is ruled out) PJ interval is normal (O ption C is ruled out) Procainamide is used for acute management of WPW ECG features of WPW Short PR interval (<120 ms) due to rapid conduction through the accessory pathway Delta wave: a slurred upstroke of the QRS complex Widened QRS complex (>110 ms) due to the fusion of early (preexcited) and normal ventricular activation The PJ interval is normal {{caption_text}} Fig: ECG in WPW Syndrome

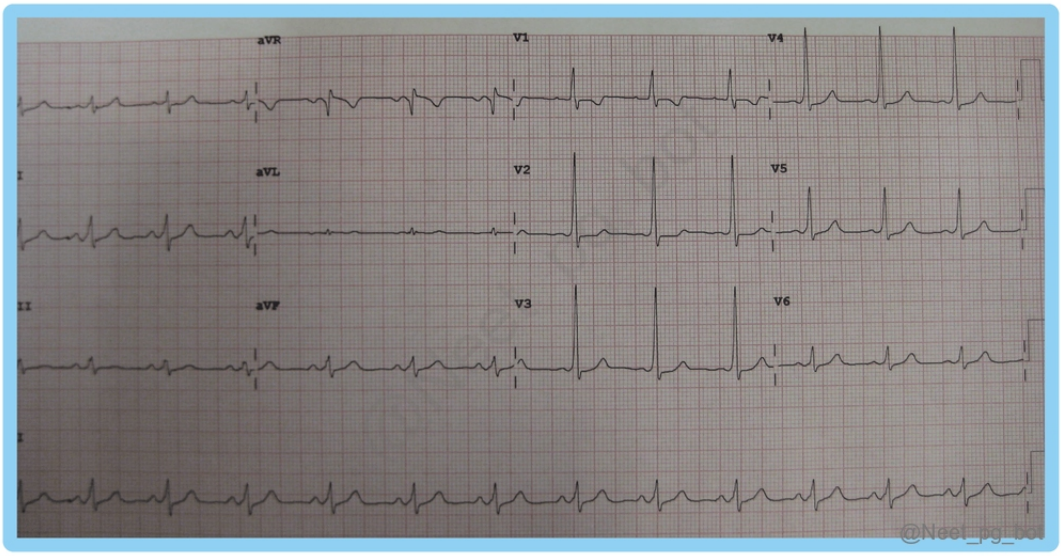

References:

Harrison's Principles of Internal Medicine, 22nd Edition, Page 1940-1941. Davidson’s Principles and Practice of Medicine 24 th Edition, Page 473, 474.

↑ *Back to this question in Part A*

@Neet_pg_bot

Q11: A 25-year-old female presents with sudden onset palpitations. ECG is shown below. You successfully terminated the arrhythmia using the Valsalva maneuver. Which of the following best describes the primary mechanism by which this maneuver terminates the arrhythmia? (Q850697)

A. Vagus induced decreased firing of the sinoatrial node

B. Vagus induced an increased sympathetic tone to the heart

C. Transient block in AV node conduction

D. Mechanical disruption of accessory pathways

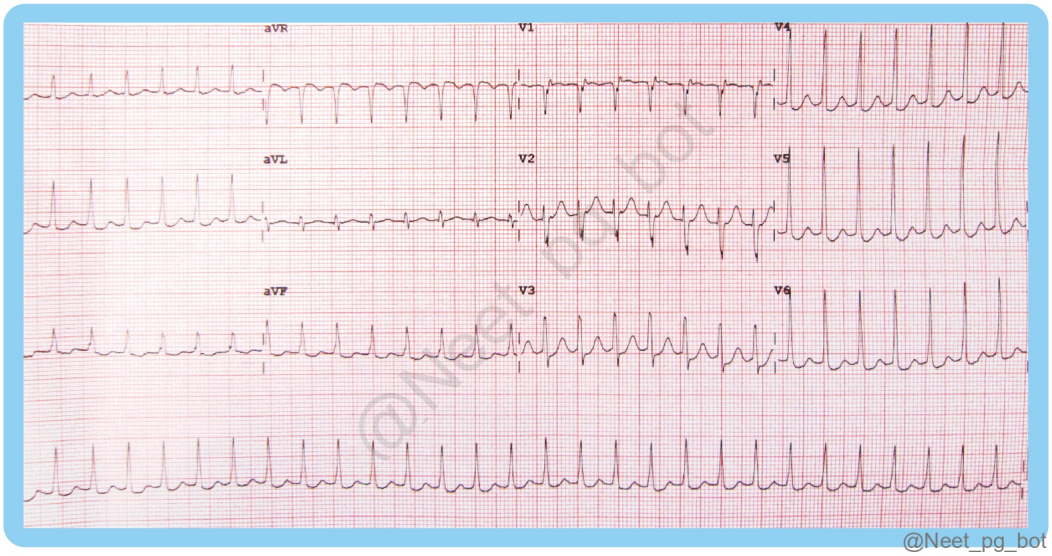

Correct Answer: C. Transient block in AV node conduction

■ *Listen (English)*

■ *Listen (Hindi)*

Explanation: The Valsalva maneuver transiently increases intrathoracic pressure. This leads to a reflex increase in vagal tone (parasympathetic activity). Increased vagal tone affects the AV node, potentially causing a transient block in conduction of re-entry current responsible for PSVT. Effect on the arrhythmia: Many supraventricular tachycardias involve a reentry circuit that includes the AV node. A transient block in AV node conduction can disrupt this circuit. This disruption can terminate the tachyarrhythmia, often restoring normal sinus rhythm. Management: Acute termination: Vagal maneuvers (e.g., Valsalva, carotid sinus massage) If vagal maneuvers fail, IV adenosine is the first-line pharmacological treatment: 6 mg - 12mg fast iv push. Alternative drugs: verapamil, diltiazem, or beta-blockers Synchronized cardioversion for hemodynamically unstable patients Long-term management: Catheter ablation: Often curative, especially for AVNRT and AVRT Pharmacological therapy: Beta-blockers or calcium channel blockers for prevention Class IC or III antiarrhythmic drugs in selected cases Patient education on performing vagal maneuvers Lifestyle modifications: Avoid triggers (e.g., caffeine, alcohol, stress) Regular exercise Adequate sleep Direct stimulation of the sinoatrial node (Option A): Vagal maneuvers actually slow the SA node; they do not stimulate it to terminate re-entry. Increased sympathetic tone of the heart (Option B): Sympathetic tone increases heart rate and would worsen the tachycardia. Vagal maneuvers aim for the opposite (parasympathetic). Mechanical disruption of accessory pathways (Option D): Accessory pathways are physical structures of heart tissue; they cannot be mechanically disrupted by a breathing maneuver.

References:

Harrison's Principles of Internal Medicine, 22nd Edition, Page 3541-3542.

Goldberger’s Clinical Electrocardiography, A Simplified Approach, 9th Edition, Page. 142, 143.

↑ *Back to this question in Part A*

@Neet_pg_bot

Q12: A 50-year-old man comes to your clinic for a annual medical check-up. He has Hypertension and takes Ramipril and Amlodipine. Office BP recording is 124/ 80 mm Hg. What is the ECG findings shown below? What is the most likely finding based on this ECG? (Q850534)

A. Left ventricular hypertrophy

B. Normal sinus rhythm

C. Second-degree AV block

D. Right bundle branch block

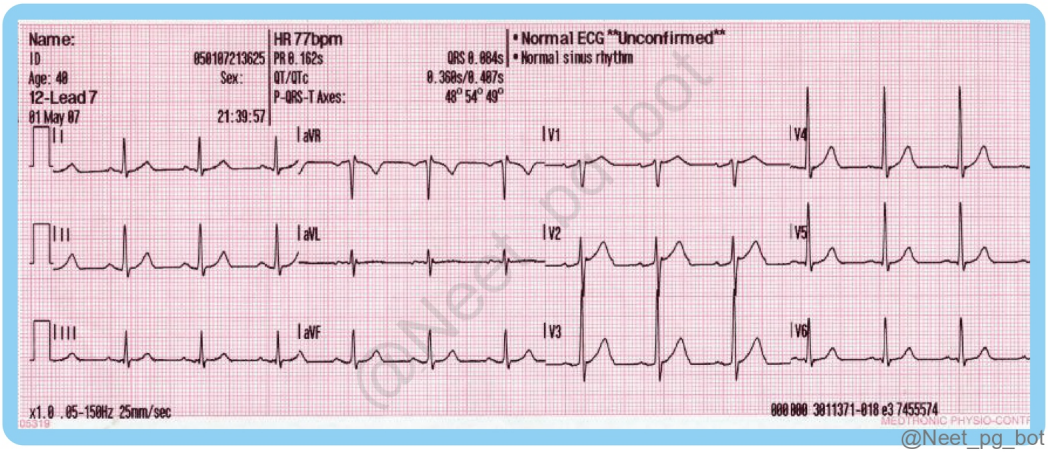

Correct Answer: B. Normal sinus rhythm

■ *Listen (English)*

■ *Listen (Hindi)*

Explanation: LVH requires SV1 + RV5 > 35 mm which is not present. (Option A) Second degree AV block has missed beats which are not present. (Option C) RBBB has rSR pattern in lead V1 which is not seen. (Option D) The interpretation by exclusion is normal sinus rhythm.

References:

Harrison's Principles of Internal Medicine, 22nd Edition, Page 1935. Goldberger’s Clinical Electrocardiography, A Simplified Approach, 9th Edition, Page. 11-20.

↑ *Back to this question in Part A*

@Neet_pg_bot

Q13: A 70-year-old patient is diagnosed with stokes adam syndrome. Which is correct about management of this patient? (Q850692)

A. Dual chamber pacemaker

B. Triple chamber pacemaker

C. Transcutaneous pacemaker

D. Transvenous pacemaker

Correct Answer: A. Dual chamber pacemaker

- *Listen (English)*
- *Listen (Hindi)*

Explanation: Stokes-Adams syndrome has AV dissociation that leads to low cardiac output and increased risk of sudden cardiac death. Dual-chamber pacemaker will restore AV synchrony and improve cardiac output. It will ensure atrial contraction is followed by ventricular contraction to ensure normal hemodynamics. Management: 1. Definitive/Long-term Management: Dual Chamber Pacemaker: It coordinates the contraction of both the atria and the ventricles, maintaining the "atrial kick" and improving cardiac output. The triple chamber pacemaker (Option B) is called CRT (cardiac resynchronization therapy) and are specifically used for heart failure with a reduced ejection fraction and bundle branch blocks to synchronize the two ventricles. It is not the standard first-line for isolated Stokes-Adams. 2. Acute/Emergency Management: If the patient is currently unstable or in active distress, the "step-up" approach for pacing is used: Atropine: Often the first medication tried, though frequently ineffective in high-degree blocks. Transcutaneous Pacing (Option C): This is an emergency, temporary measure using external pads (Zoll pads). It is painful and not a long-term solution. Transvenous Pacing (Option D): An interim step where a wire is threaded through a vein into the heart. This is used to stabilize the patient while they wait for the "permanent" pacemaker to be surgically implanted. {{caption_text}}

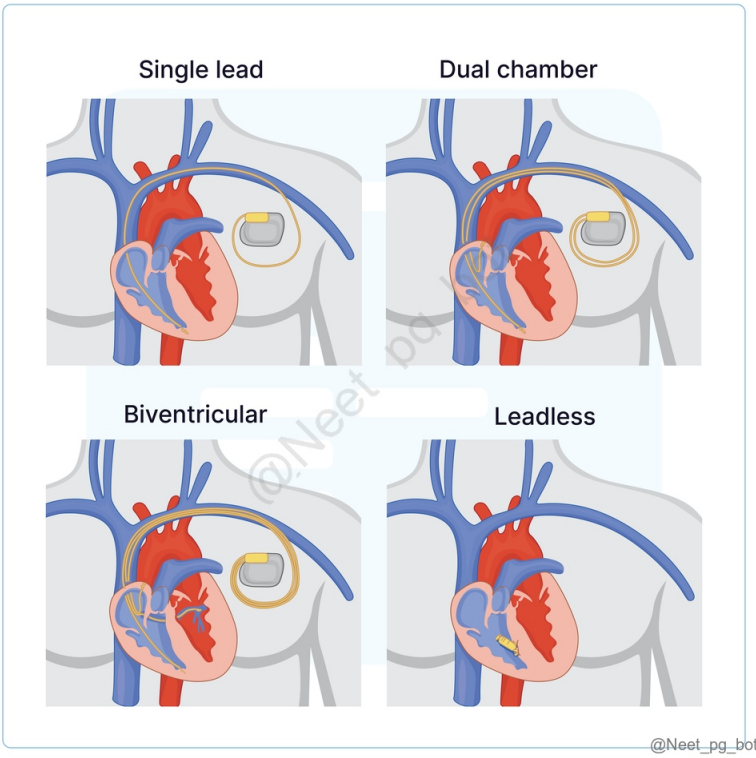

References:

Harrison's Principles of Internal Medicine, 22nd Edition, Page 1931. Davidson’s Principles and Practice of Medicine, 24th Edition, Page 482, 483

↑ *Back to this question in Part A*

@Neet_pg_bot

Q14: A 74-year-old patient comes to the emergency department with complaints of intermittent dizziness and lightheadedness. An electrocardiogram (ECG) is performed, as shown below. Based on the ECG findings and the clinical scenario, what type of atrioventricular block is most likely present in this patient? (Q850687)

A. Mobitz Type I - Wenckebach

B. Infranodal conduction defect

C. First-degree AV block

D. Third-degree AV block

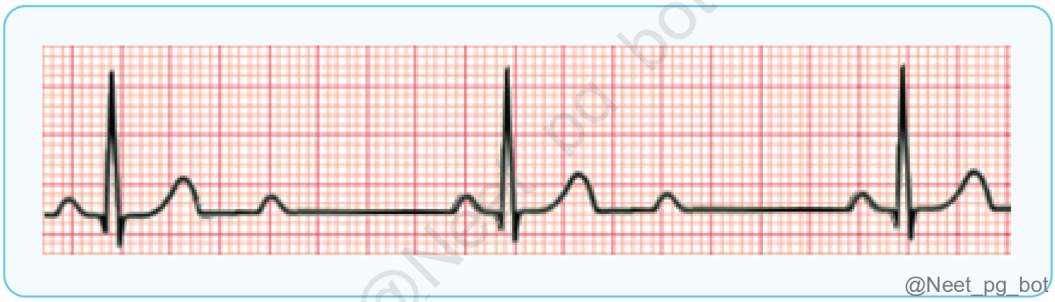

Correct Answer: B. Infranodal conduction defect

- *Listen (English)*
- *Listen (Hindi)*

Explanation: Notice a dropped beat after the second qRS complex. The P wave prior to it is visible, but QRS is missing. Now measure the PR interval after and before the missed beat, which is equal, and this indicates infranodal conduction defect. Also notice that each alternate P wave is not conducted down to ventricles indicating 2:1 block Mobitz I heart block (Option A) shows serial prolongation of PR interval. Third-degree AV Block (Option D) shows complete dissociation between P waves and QRS complexes, with no correlation between the two. First-degree heart block (Option C) has a PR interval > 200 msec

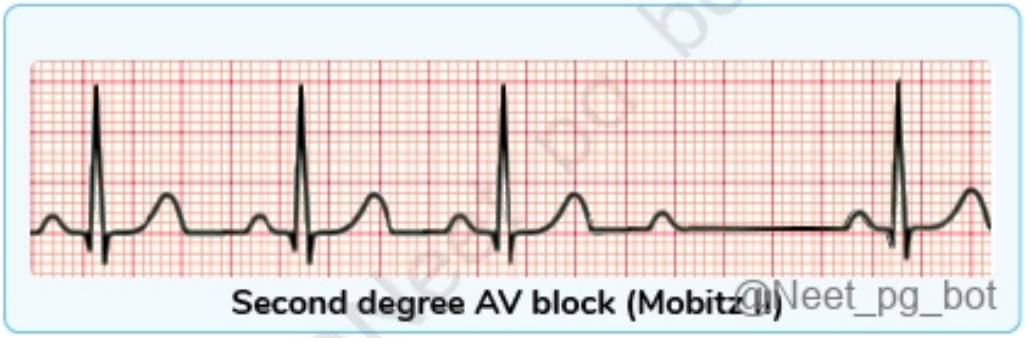

References:

Harrison's Principles of Internal Medicine, 22nd Edition, Page 1927.

↑ *Back to this question in Part A*

@Neet_pg_bot

Q15: A 72-year-old man is brought to the ER due to sudden onset syncope in the bathroom. His medical history includes hypertension and a prior myocardial infarction. ECG of the patient is given below. What is the most appropriate initial management for this patient? (Q850685)

A. Oral beta-blockers

B. Temporary pacing

C. Permanent pacemaker placement

D. IV atropine 0.4 mg

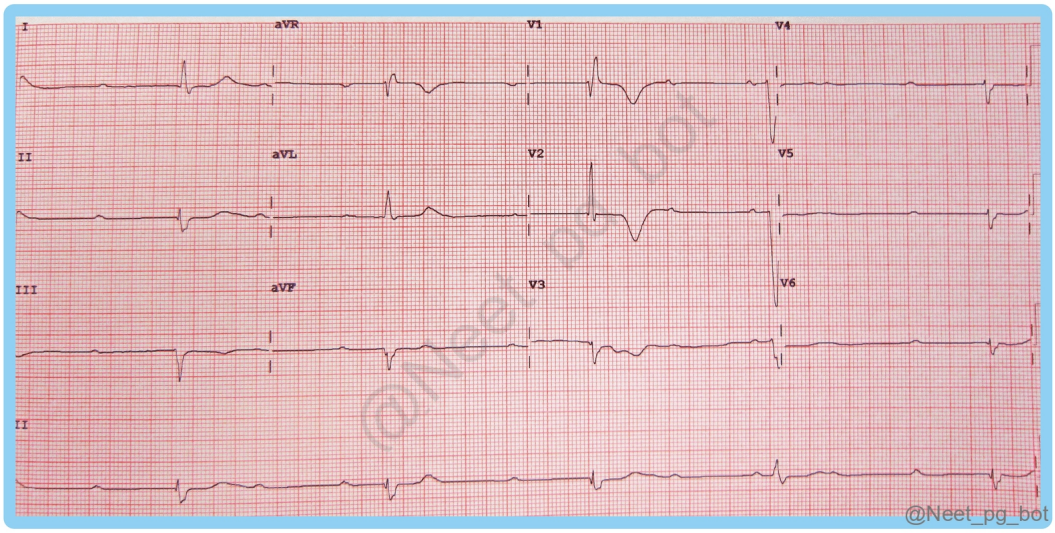

Correct Answer: B. Temporary pacing

■ *Listen (English)*

■ *Listen (Hindi)*

Explanation: The ECG shows third-degree (complete) AV block, where the atria and ventricles beat independently, causing slow heart rate and syncope. The initial management for symptomatic bradycardia is Atropine. But atropine does not work if the lesion is below the level of the AV node. So temporary pacing is the initial treatment to be started. ECG shows a huge difference between RR interval (black arrows) and PP interval (orange arrows). Ventricular rate is < 30 per min. There is complete dissociation between P waves and QRS complexes and the diagnosis is a third-degree atrioventricular block. Why Atropine Fails: Atropine speeds up the top chamber but can't fix a block deep in the wiring system below the AV node. It might even make things worse by speeding atria without helping ventricles. Best Treatment Steps: Start temporary pacing right away for stability in ER. Later, consider permanent pacemaker if block persists.

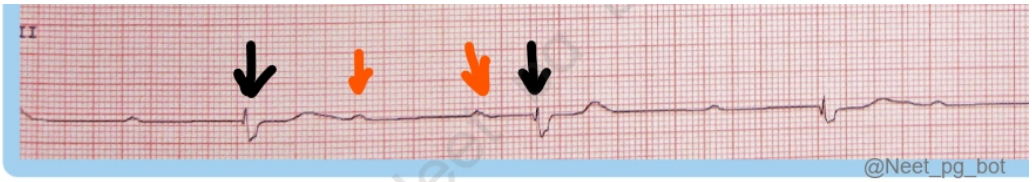

References:

Harrison's Principles of Internal Medicine, 22nd Edition, Page 1925-1926.

↑ *Back to this question in Part A*

Q16: A 68-year-old male patient presents to the ER with complaints of fatigue and occasional lightheadedness. He has a history of hypertension and coronary artery disease. During the examination, he describes episodes of near-syncope. The physician performs an ECG to evaluate his symptoms. What is the most likely diagnosis based on the ECG findings? (Q850668)

A. First-degree heart block

B. Mobitz Type I

C. Mobitz Type II

D. Complete heart block



Correct Answer: C. Mobitz Type II

■ *Listen (English)*

■ *Listen (Hindi)*

Explanation: ECG shows a normal PR interval followed by a non-conducted P wave, leading to dropped beats. This type is often associated with structural heart disease and can progress to complete heart block, which aligns with the patient's symptoms and history. First-degree heart block (Option A): PR interval is prolonged but every P is followed by a QRS . Mobitz Type I – Wenckebach (Option B): Progressive PR lengthening until a beat drops. Complete heart block (Option D): No relation between P waves and QRS complexes (AV dissociation).

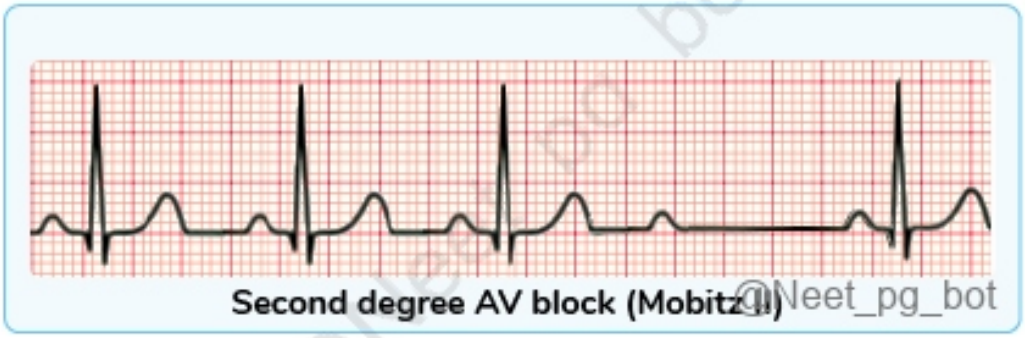

References:

Harrison's Principles of Internal Medicine, 22nd Edition, Page 1929.

↑ *Back to this question in Part A*

@Neet_pg_bot

Q17: A 58-year-old woman comes to the clinic for an annual medical check up. She has a history of mild hypertension, which is well-controlled with medication. She reports no symptoms such as palpitations, dizziness, or chest pain. An ECG of the patient is given below. What is the most likely diagnosis based on the ECG findings? (Q850631)

A. Second-Degree AV Block

B. First-Degree AV Block

C. Third-Degree AV Block

D. Bundle Branch Block

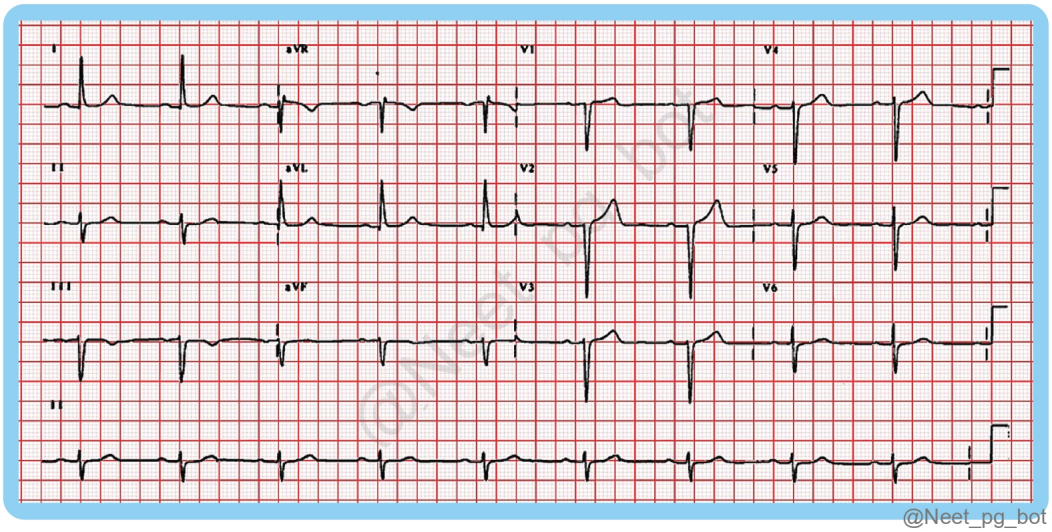

Correct Answer: B. First-Degree AV Block

- *Listen (English)*
- *Listen (Hindi)*

Explanation: There are no dropped beats, so a second-degree heart block is ruled out. Number of P waves is equal to the number of R waves, so a third-degree heart block is ruled out. BBB will have broad qRS complexes and ST segment changes that are not seen. So the answer is first-degree heart block that can be physiological. The PR interval in this ECG is 6 small squares, making it 240 msec. {{caption_text}}

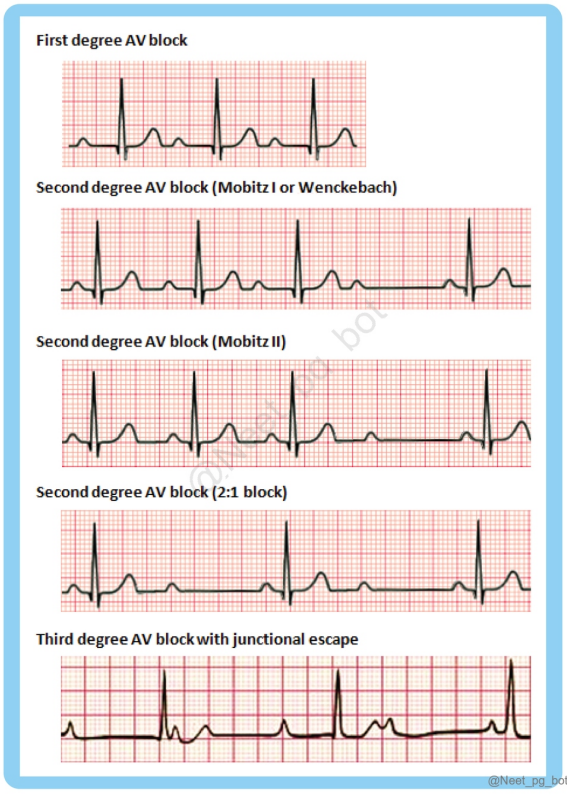

References:

Harrison's Principles of Internal Medicine, 22nd Edition, Page 1925.

↑ *Back to this question in Part A*

@Neet_pg_bot

Q18: A 25-year-old male presents with recurrent palpitations and dizziness. An ECG of the patient is given below. Which of the following statements is true regarding this patient's diagnosis? (Q850625)

A. He is at risk for pre-excited atrial fibrillation leading to dangerously fast ventricular rates

B. The accessory pathway is the Bundle of James, facilitating rapid conduction.

C. ECG shows prolonged PR interval with delta waves

D. Adenosine is drug of choice for this condition

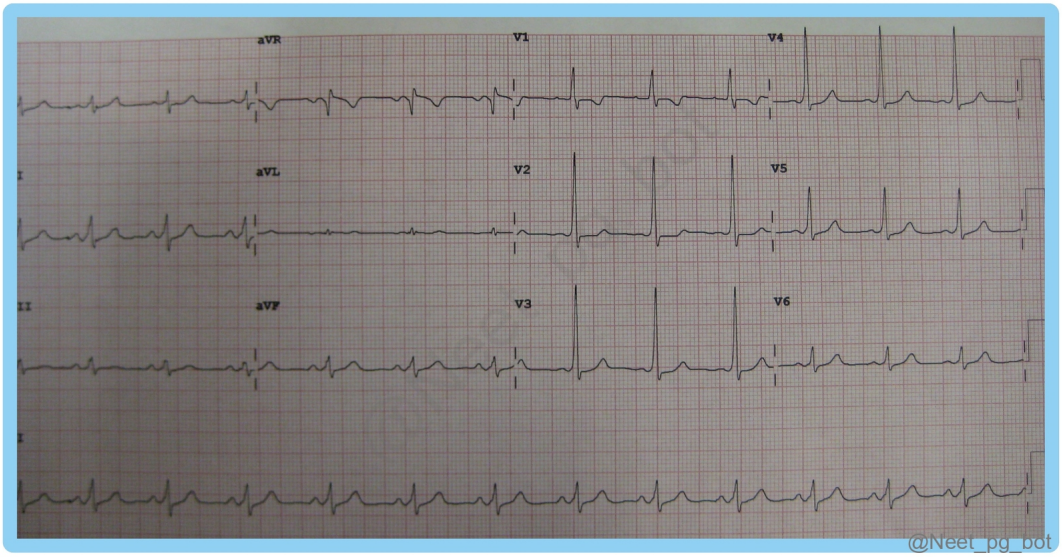

Correct Answer: A. He is at risk for pre-excited atrial fibrillation leading to dangerously fast ventricular rates

■ *Listen (English)*

■ *Listen (Hindi)*

Explanation: The ECG shows short PR interval + delta wave → Wolff–Parkinson–White (WPW) syndrome . In WPW, the accessory pathway (Bundle of Kent) can conduct impulses very rapidly , especially during atrial fibrillation , causing extremely fast ventricular rates and risk of ventricular fibrillation —a medical emergency. The accessory pathway is the Bundle of James, facilitating rapid conduction(Option B): Bundle of James is seen in

Lown–Ganong–Levine (LGL) syndrome , not WPW. ECG shows prolonged PR interval with delta waves(Option C): WPW has a short , not prolonged, PR interval. ■■■■■■■Adenosine is drug of choice for this condition■■■■■■■(Option D): Adenosine is contraindicated in WPW because AV nodal blockade can worsen conduction through the accessory pathway. Procainamide is preferred in acute episodes; flecainide for prevention.

References:

Harrison's Principles of Internal Medicine, 22nd Edition, Page 1941. Davidson’s Principles and Practice of Medicine, 24th Edition, Page 473, 474

↑ *Back to this question in Part A*

@Neet_pg_bot

Q19: A 28-year-old male presents to the emergency department with palpitations and lightheadedness. He has no significant past medical history and is otherwise healthy. After a thorough examination, an ECG is obtained. Based on the patient’s presentation and the findings of the ECG, what is the most likely diagnosis? (Q850619)

A. Atrial Fibrillation

B. Wolff-Parkinson-White (WPW) Syndrome

C. First-degree AV Block

D. Second degree heart block

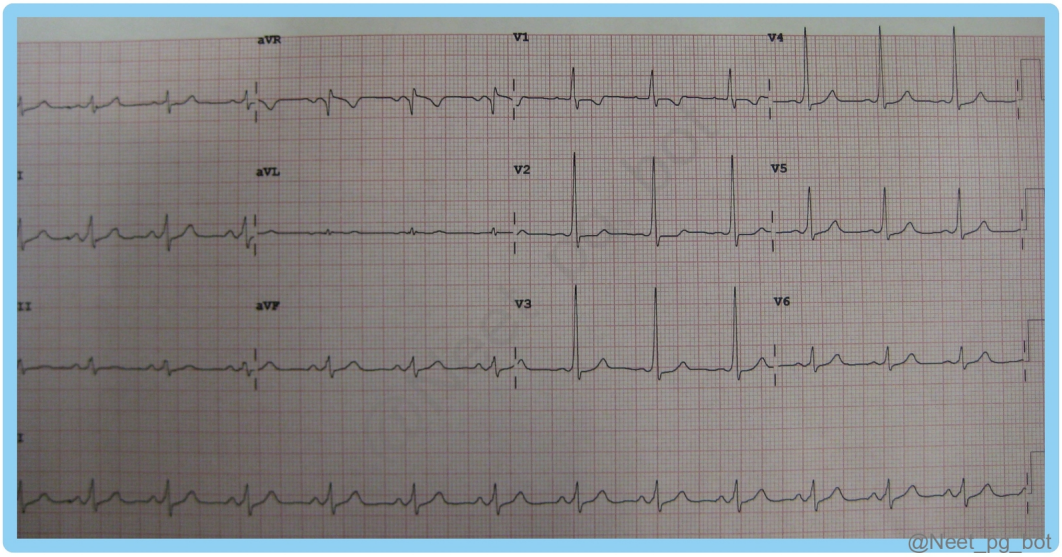

Correct Answer: B. Wolff-Parkinson-White (WPW) Syndrome

■ *Listen (English)*

■ *Listen (Hindi)*

Explanation: The PR interval is short (0.12 seconds). A delta wave (marked in the red arrows) is present in all leads, but it is particularly well seen in leads I, II, and V1-V6. Total QRS duration is prolonged (0.14 seconds). There is a tall R wave in the right-sided precordial leads, and non-specific ST segment/T wave changes accompany this. First-degree AV Block and second-degree heart block (Option C and D) cause bradycardia and are ruled out. Presence of P waves rules out atrial fibrillation (Option A) .

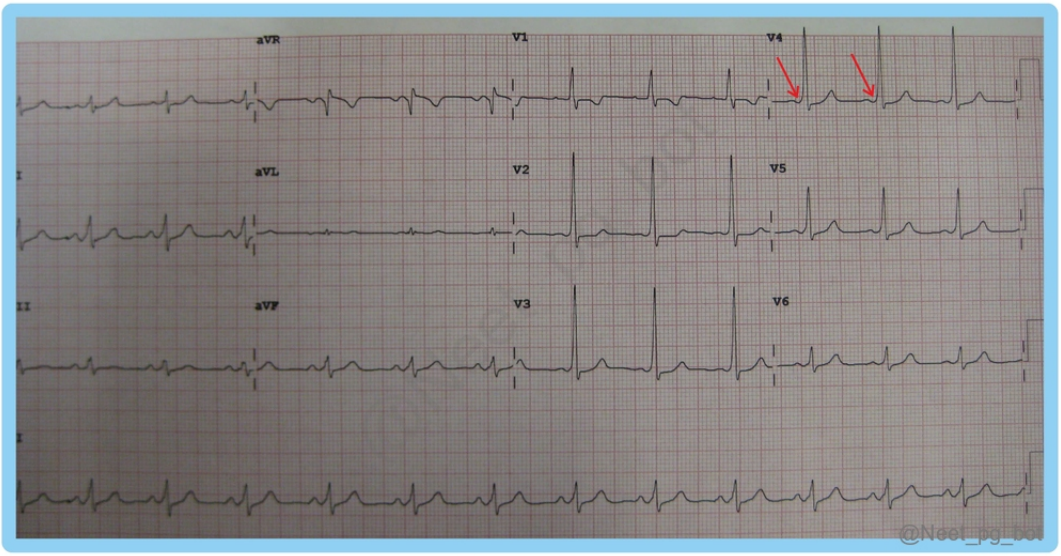

References:

Harrison's Principles of Internal Medicine, 22nd Edition, Page 1941. Goldberger’s Clinical Electrocardiography, A Simplified Approach, 9th Edition, Page. 242.

↑ *Back to this question in Part A*

@Neet_pg_bot

Q20: A 2-year-old child is referred to your hospital for a suspected congenital heart condition due to central cyanosis. On examination, there is a prominent jugular venous pulsation and a pansystolic murmur at the left lower sternal border. ECG shows Himalayan P waves. Which condition will you suspect? (Q850611)

A. Ebstein’s Anomaly

B. Atrial septal defect

C. Ventricular septal defect

D. Tetralogy of Fallot

Correct Answer: A. Ebstein’s Anomaly

■ *Listen (English)*

■ *Listen (Hindi)*

Explanation: Key word is himalayan P waves/ Peaked P waves that indicate Right atrial enlargement. The presence of pansystolic murmur indicates regurgitation across the tricuspid valve. This is seen in Ebstein anomaly which has an inferior displacement of the tricuspid valve. The cyanosis is explained by R to L shunting across ASD or patent foramen ovale.. Atrial septal defect (Option B): Usually acyanotic with fixed split S2; does not produce Himalayan P waves or pansystolic murmur. Ventricular septal defect (Option C): Causes a pansystolic murmur but no prominent JVP and no giant P waves ; cyanosis only in late Eisenmenger stage. Tetralogy of Fallot (Option D): Cyanosis and murmur, but murmur is ejection systolic , not pansystolic; JVP and Himalayan P waves are not features.

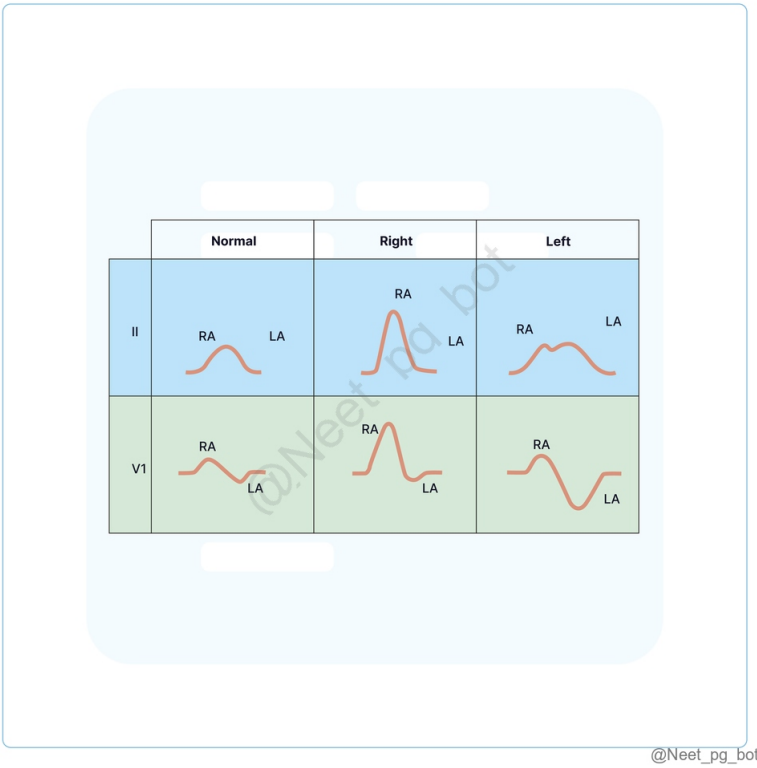

References:

Harrison's Principles of Internal Medicine, 22nd Edition, Page 2062. Goldberger’s Clinical Electrocardiography, A Simplified Approach, 9th Edition, Page. 50-53.

↑ *Back to this question in Part A*

@Neet_pg_bot

Q21: A 60-year-old woman with a history of hypertension and diabetes presents with a one-month history of mild exertional dyspnea. She denies chest pain but has noticed some occasional palpitations. Physical examination reveals a blood pressure of 140/90 mmHg and regular heart sounds. You order an ECG, which is shown below. What is the most likely diagnosis based on this ECG? (Q850602)

A. Normal axis

B. Right axis deviation

C. Left axis deviation

D. Extreme axis deviation

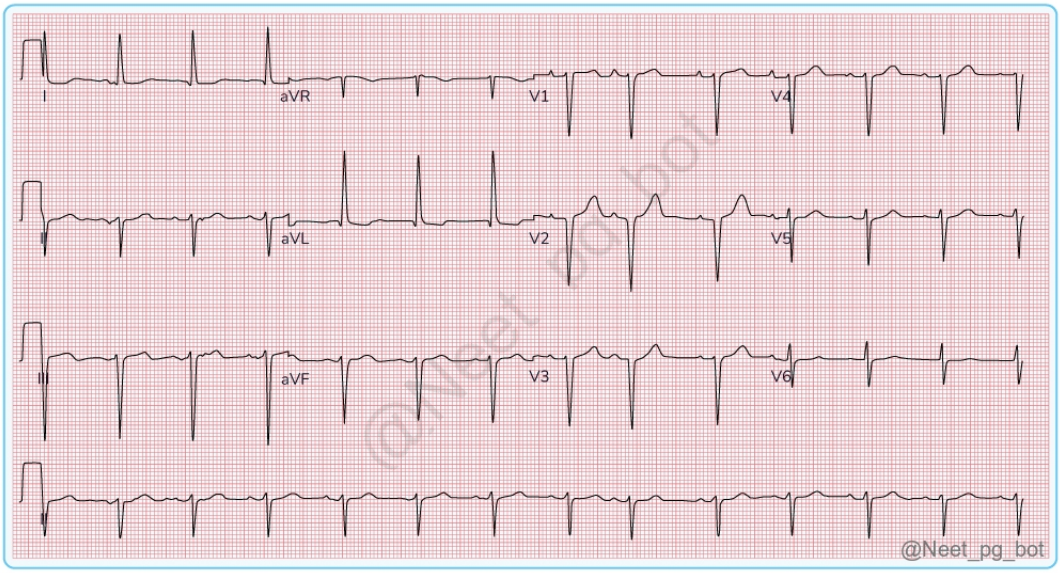

Correct Answer: C. Left axis deviation

■ *Listen (English)*

■ *Listen (Hindi)*

Explanation: The ECG in question shows left axis deviation when the vectors are plotted for the following data: QRS is POSITIVE (dominant R wave) in Lead I QRS is NEGATIVE (dominant S wave) in leads II, III and aVF Normal Axis : QRS axis between -30° and +90°, points downward and slightly left. Abnormal Axis Deviations: Left Axis Deviation : QRS axis less than -30°. Right Axis Deviation : QRS axis greater than +90°. Extreme Axis Deviation : QRS axis between -90° and 180°.

	Normal Axis 0 to 90	Left Axis Physiological 0 to -30	Left Axis Pathological -30 to -90	Right Axis 90 to 180	Extreme Axis -90 to -180	Indeterminate Axis ?
Lead I						
Lead II						
Lead III						

@Neet_pg_bot

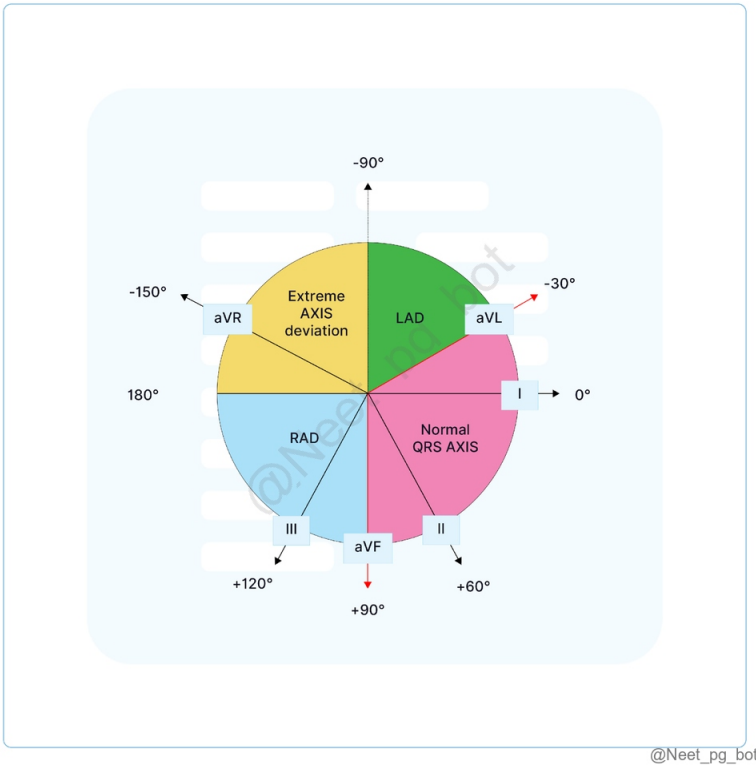

@Neet_pg_bot

References:

Harrison's Principles of Internal Medicine, 22nd Edition, Page 1869. Goldberger’s Clinical Electrocardiography, A Simplified Approach, 9th Edition, Page 46-49.

↑ *Back to this question in Part A*

@Neet_pg_bot

• [01_Cardiology] 005 Ischemic Heart Disease

« Back to Folder Directory

[01_Cardiology] 005 Ischemic Heart Disease — Quick Jump

Q1 (p. 1185)	*Q2 (p. 1186)*	*Q3 (p. 1186)*	*Q4 (p. 1187)*	*Q5 (p. 1188)*	*Q6 (p. 1189)*
Q7 (p. 1190)	*Q8 (p. 1191)*	*Q9 (p. 1193)*	*Q10 (p. 1194)*	*Q11 (p. 1195)*	*Q12 (p. 1196)*
Q13 (p. 1197)	*Q14 (p. 1198)*	*Q15 (p. 1199)*	*Q16 (p. 1200)*	*Q17 (p. 1201)*	*Q18 (p. 1202)*
Q19 (p. 1205)	*Q20 (p. 1206)*	*Q21 (p. 1207)*	*Q22 (p. 1208)*	*Q23 (p. 1209)*	*Q24 (p. 1210)*
Q25 (p. 1210)	*Q26 (p. 1211)*	*Q27 (p. 1212)*	*Q28 (p. 1213)*		

Q1: A 35-year-old woman comes at 8 am to the ER with chest pain that started last evening and has progressively worsened. She describes the pain as a burning sensation accompanied by a sour taste in her mouth, which began shortly after dinner. She has had similar experiences previously. This morning she passed a black stool. ECG and Echocardiography shows normal results. What is next investigation to be performed in this patient? (Q850457)

A. 24 hour pH monitoring

B. Endoscopy

C. hs-CTn

D. Coronary CT angiography

Correct Answer: B. Endoscopy

■ *Listen (English)*

■ *Listen (Hindi)*

Explanation: The patient is having chest pain due to reflux esophagitis . The first investigation to be done will be an Upper GI endoscopy, which will show mucosal erythema and friability. Passage of black stool is a red flag, and endoscopy will help in determining whether it is bleeding due to mucosal erosions or peptic ulceration that has caused this presentation. 24-hour pH monitoring (Option A) is the gold standard investigation and may not be available readily. hs-CTn (Option C) is a high-sensitivity troponin assay that would be done if presentation was of acute coronary syndrome. Coronary CT angiography (Option D) is done for ch ronic stable angina.

References:

Harrison's Principles of Internal Medicine, 22nd Edition, Page 103, 2504.

↑ *Back to this question in Part A*

@Neet_pg_bot

Q2: A 70-year-old male presents with an acute onset of severe dyspnea and shock 5 days after receiving fibrinolysis for STEMI. On examination, an early systolic murmur is heard at the apex. Echocardiography reveals valvular dysfunction. What is the most likely cause of his condition? (Q850499)

A. Ventricular septal rupture

B. Papillary muscle rupture

C. Ventricular aneurysm

D. Ventricular rupture

Correct Answer: B. Papillary muscle rupture

■ *Listen (English)*

■ *Listen (Hindi)*

Explanation: The buzzword in question is the Echo report of valvular dysfunction, implying Papillary muscle rupture . This occurs after a STEMI due to ischemia of the papillary muscles, leading to acute mitral valve insufficiency. Auscultation finding of acute MR is an early systolic murmur. VSD (Option A) will cause a pansystolic murmur. LV aneurysm (Option C) will cause clot formation and increased risk of stroke. Ventricular rupture (Option D) will cause cardiac tamponade.

References:

Harrison's Principles of Internal Medicine, 22nd Edition, Page 2122.

↑ *Back to this question in Part A*

@Neet_pg_bot

Q3: A 65-year-old male patient presents 6 weeks after experiencing an ST-elevation myocardial infarction . He reports malaise, fever, and chest discomfort that worsens with deep breathing. On examination, a pericardial friction rub is heard. Laboratory tests reveal leukocytosis and an elevated ESR. What is the most appropriate initial treatment for this condition? (Q850496)

A. Glucocorticosteroids

B. Aspirin

C. Colchicine

D. Rescue PCI

Correct Answer: B. Aspirin

■ *Listen (English)*

■ *Listen (Hindi)*

Explanation: The scenario indicates Dressler syndrome due to fever, malaise, and pericardial effusion occurring 6 weeks post-myocardial infarction, reflecting a delayed inflammatory response . Elevated inflammatory markers confirm this autoimmune reaction to myocardial injury. Aspirin (650 mg every 4 hours) is the initial treatment as it reduces inflammation and relieves symptoms without risking complications associated with NSAIDs or glucocorticoids, which can impair healing after an MI. Glucocorticoids and NSAIDs should be avoided within 4 weeks of STEMI due to risks of impaired infarct healing, ventricular rupture. (Option A & C) Rescue PCI (Option D) is done in case of failure of Fibrinolysis.

References:

Robbins & Cotran's Pathologic Basis of Diseases, 10th Edition, Page 552.

↑ *Back to this question in Part A*

@Neet_pg_bot

Q4: A 60-year-old female with a history of hypertension and hyperlipidemia presents with severe chest pain for 3 hours. She has a blood pressure of 180/110 mmHg and a history of active peptic ulcer disease. Her ECG shows ST-elevation in leads V2-V4. What is the most appropriate treatment option for this patient? (Q850493)

A. Streptokinase

B. Tissue plasminogen activator

C. Coronary artery bypass surgery

D. Percutaneous coronary intervention

Correct Answer: D. Percutaneous coronary intervention

■ *Listen (English)*

■ *Listen (Hindi)*

Explanation: Percutaneous coronary intervention (PCI): This patient has an acute anterior wall STEMI (ST elevation in V2–V4) presenting within 3 hours. She has active peptic ulcer disease, which is an absolute

contraindication to thrombolytic therapy due to the high risk of life-threatening bleeding. In such patients, primary PCI is the treatment of choice, as it achieves rapid reperfusion without systemic fibrinolysis. Fibrinolysis: Absolute contraindications: History of cerebrovascular hemorrhage. Nonhemorrhagic stroke or cerebrovascular event in the past year. Marked hypertension (>180/110 mmHg) at presentation. Suspected aortic dissection. Active internal bleeding (excluding menses). Relative contraindications: Use of anticoagulants (INR >2). Recent (<2 weeks) invasive procedure or prolonged (>10 min) CPR. Bleeding diathesis Pregnancy Hemorrhagic ophthalmic conditions (e.g., hemorrhagic diabetic retinopathy) Active peptic ulcer disease. Streptokinase and Allergy Risk: Patients should not receive streptokinase if they have already received it within the preceding 5 days to 2 years due to the risk of allergic reactions. Streptokinase (Option A): Streptokinase is contraindicated in patients with active internal bleeding, including peptic ulcer disease, due to high hemorrhagic risk. Tissue plasminogen activator (tPA) (Option B): tPA is also a fibrinolytic agent and shares the same absolute contraindication in active peptic ulcer disease. Coronary artery bypass surgery (CABG) (Option C): CABG is not the first-line emergency reperfusion strategy in acute STEMI unless PCI fails or there is a mechanical complication.

References:

Harrison's Principles of Internal Medicine, 22nd Edition, Page2129-2130.

↑ *Back to this question in Part A*

@Neet_pg_bot

Q5: A 60-year-old male with a history of hypertension and hyperlipidemia presents with chest pain lasting 45 minutes. His ECG shows STE in lead I, avL, V5, V6. Which of the following statements about his management is correct? (Q850490)

A. Beta blockers should be avoided in all patients with STEMI.

B. First line drug for the management of STEMI is Streptokinase

C. LMWH provides more reliable anticoagulation than UFH.

D. Leading cause of death after 24 hours of hospitalization is cardiac rupture

Correct Answer: C. LMWH provides more reliable anticoagulation than UFH.

■ *Listen (English)*

■ *Listen (Hindi)*

Explanation: LMWH provides a more predictable and reliable anticoagulant effect than unfractionated heparin (UFH) with fewer bleeding complications and no need for frequent monitoring, making it preferred in STEMI management. Low-Molecular-Weight Heparins (LMWH): Advantages: Higher bioavailability Subcutaneous administration Reliable anticoagulation without monitoring Geater anti-Xa:IIa activity Enoxaparin reduces death/nonfatal reinfarction and urgent revascularization compared with unfractionated heparin (UFH), but has higher bleeding rates. Beta blockers should be avoided in all patients with STEMI (Option A): Beta blockers reduce the size of the infarct by reducing oxygen consumption of the heart. So they are given to all patients unless

some contraindication, like acute pulmonary edema or bradycardia, is present. First-line drug for the management of STEMI is Streptokinase (Option B): The first drug given to patients with STEMI is aspirin chewable 325mg with Ticagrelor. The leading cause of death after 24 hours of hospitalization is cardiac rupture (Option D): The leading cause of death after 24 hours of hospitalization is Cardiogenic shock or pump failure.

References:

Harrison's Principles of Internal Medicine, 22nd Edition, Page 2121.

https://ars.els-cdn.com/content/image/1-s2.0-S1470211824015240-gr0001_lrg.jpg

↑ *Back to this question in Part A*

@Neet_pg_bot

Q6: A 65-year-old male presents with central chest pain for the last 3 hours radiating to the left shoulder. On admission, blood pressure is 150/100 mmHg, and his oxygen saturation is 95% on room air. Which of the following drugs should be avoided in this patient? (Q850486)

A. Administer morphine IV for pain relief

B. Administer nifedipine to relieve chest pain

C. Administer clopidogrel loading dose for platelet inhibition

D. Administer sublingual nitroglycerin (0.4 mg) to reduce myocardial oxygen demand

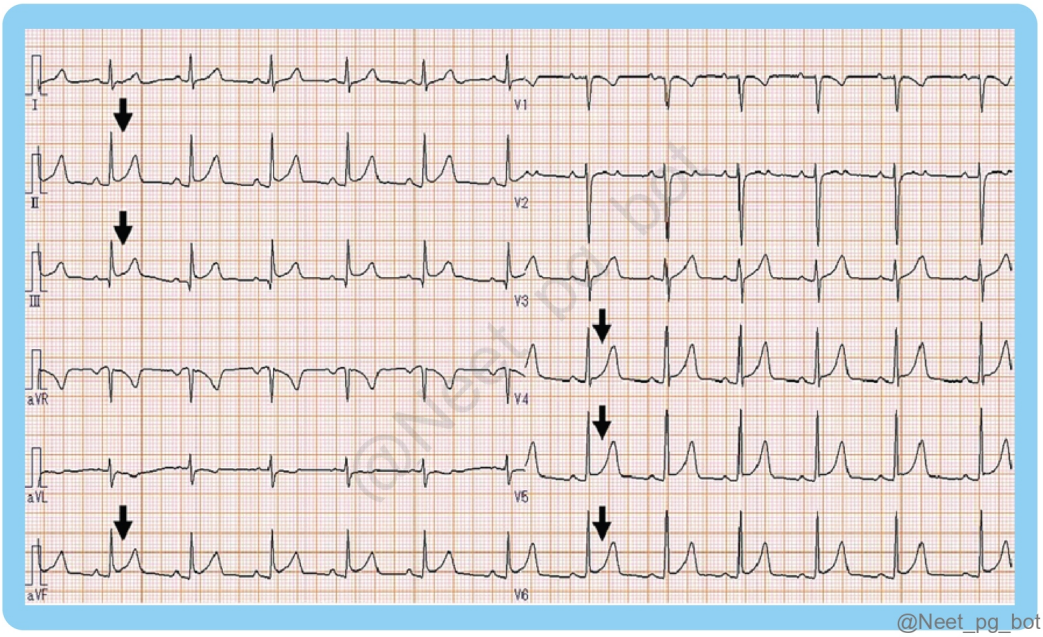

Correct Answer: B. Administer nifedipine to relieve chest pain

■ *Listen (English)*

■ *Listen (Hindi)*

Explanation: ECG shows ST elevations in leads II, III, aVF, V4-V6, indicating infero-lateral MI. Calcium channel blockers, particularly short-acting dihydropyridines like nifedipine, will cause reflex tachycardia and increase myocardial oxygen demand. This can worsen the patient, and hence is the wrong statement Morphine IV for pain relief (Option A) is appropriate for pain control and reducing sympathetic stress. Clopidogrel loading dose for platelet inhibition (Option C) is indicated to reduce thrombus formation in ACS. Sublingual nitroglycerin (0.4 mg) to reduce myocardial oxygen demand (Option D) is safe and effective for symptom relief.

References:

Harrison's Principles of Internal Medicine, 22nd Edition, Page 2102.

↑ *Back to this question in Part A*

@Neet_pg_bot

Q7: Which of the following would provide the least accurate diagnosis of Myocardial infarction? (Q850483)

A. Echocardiography

B. Coronary angiography

C. High sensitivity Troponin I

D. Radionuclide ventriculography

Correct Answer: D. Radionuclide ventriculography

■ *Listen (English)*

■ *Listen (Hindi)*

Explanation: Radionuclide ventriculography primarily assesses ventricular function and wall motion but is not specific for diagnosing myocardial infarction. Echocardiography (Option A): This provides functional evidence . It identifies Regional Wall Motion Abnormalities (RWMA) that occur almost instantly when a coronary artery is blocked, making it a highly accurate bedside tool. Coronary angiography (Option B): This is the anatomic gold standard . It uses fluoroscopy to directly visualize the "culprit" vessel occlusion, allowing for immediate therapeutic intervention (stenting). High sensitivity Troponin I (Option C): This is the biochemical gold standard . These assays detect minute amounts of myocardial necrosis within 1–3 hours of injury with near-perfect specificity for cardiac tissue.

References:

Harrison's Principles of Internal Medicine, 22nd Edition, Page 2106, 2098.

↑ *Back to this question in Part A*

@Neet_pg_bot

Q8: A 58-year-old male smoker was managed with primary PCI for STEMI 4 days ago. On the day of planned discharge he again develops central chest pain. Which of the following should be done in this patient to identify a reinfarction? (Q850479)

A. Troponin T

B. Creatine Kinase-MB

C. Lactate Dehydrogenase

D. Heart fatty acid-binding Protein

Correct Answer: B. Creatine Kinase-MB

■ *Listen (English)*

■ *Listen (Hindi)*

Explanation: In this scenario, CK-MB is the most useful marker for confirming reinfarction, as its levels normalize within 72 hours after an initial infarction. Troponin T (Option A) remains elevated for 7–10 days after the initial MI, so it is not reliable for detecting reinfarction. Lactate Dehydrogenase (Option C) rises late and is nonspecific for reinfarction. Heart fatty acid-binding protein (Option D) is sensitive but less commonly used in routine clinical practice for reinfarction detection. {{caption_text}} Cardiac Biomarkers for Acute Myocardial Infarction (AMI): {{caption_text}}

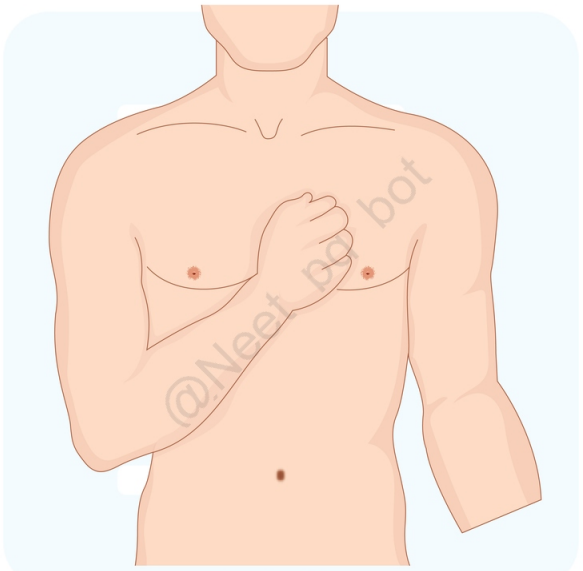

Levine Sign

@Neet_pg_bot

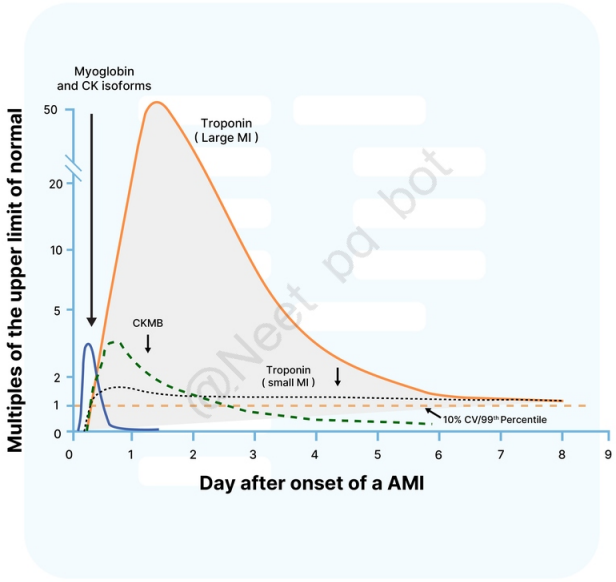

@Neet_pg_bot

References:

Harrison's Principles of Internal Medicine, 22nd Edition, Page 2116.

↑ *Back to this question in Part A*

@Neet_pg_bot

Q9: A 58-year-old male presents with chest pain, and an ECG reveals the following changes Based on these findings, which coronary artery is most likely affected? (Q850477)

A. Left Circumflex Artery

B. Right Coronary Artery

C. Anterior Interventricular Artery

D. Posterior Descending Artery

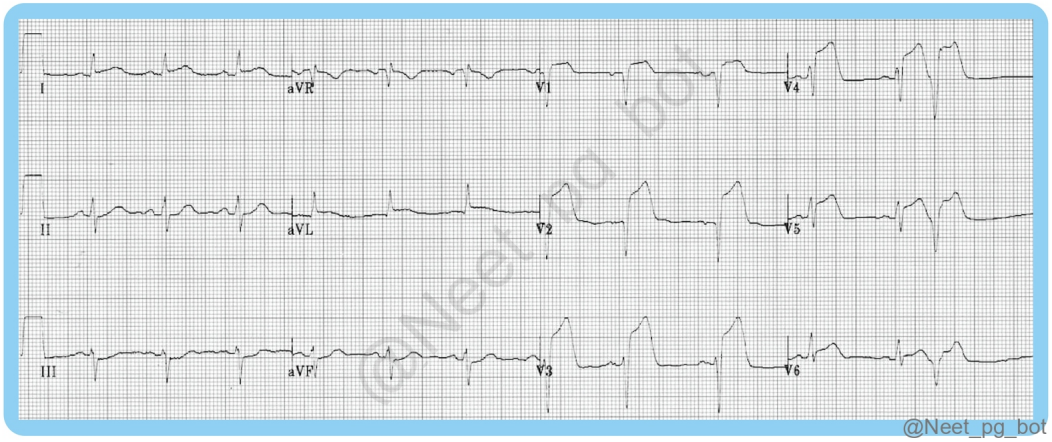

Correct Answer: C. Anterior Interventricular Artery

■ *Listen (English)*

■ *Listen (Hindi)*

Explanation: ECG shows ST elevation in leads V1–V6, I, and aVL, implying anterolateral MI. The blood vessel involved is the proximal LAD, also called the anterior interventricular artery. Left Circumflex Artery (Option A) will cause lateral wall MI Right Coronary Artery (Option B) will cause inferior wall MI Posterior Descending Artery (Option D) will cause posterior wall MI.

References:

Harrison's Principles of Internal Medicine, 22nd Edition, Page 1873.

↑ *Back to this question in Part A*

@Neet_pg_bot

Q10: A 65-year-old male patient with a history of coronary artery disease undergoes angiography, which reveals a thrombus in the right coronary artery (RCA). Based on this finding, which area of the heart is most likely to be affected by an infarct? (Q850475)

A. Anterior wall

B. Lateral wall

C. Inferior wall

D. Septal wall

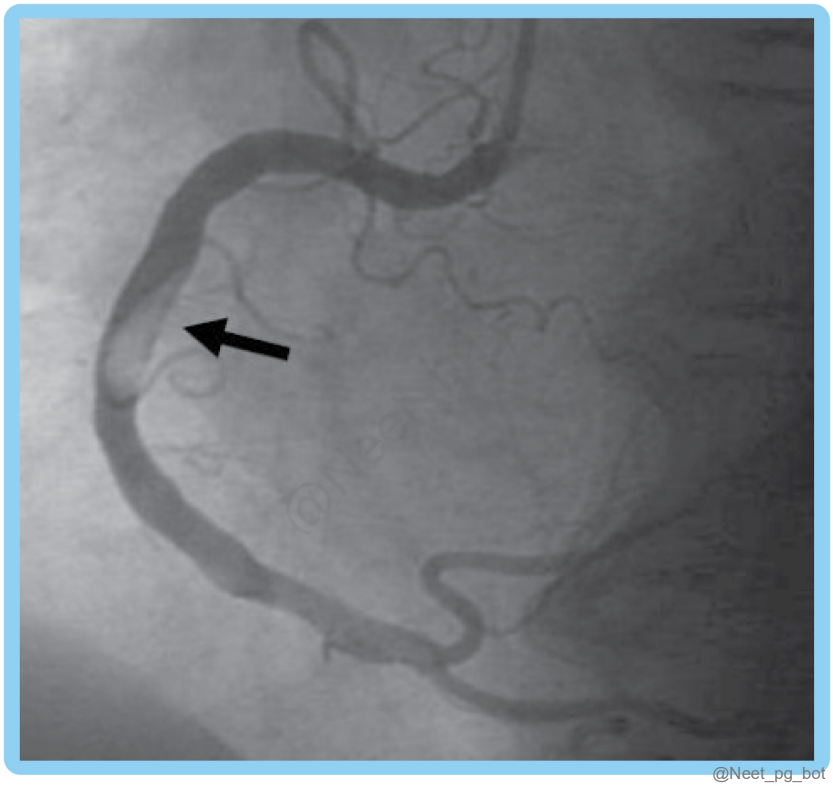

Correct Answer: C. Inferior wall

■ *Listen (English)*

■ *Listen (Hindi)*

Explanation: In a patient with a thrombus in the right coronary artery, the area of the heart to be affected by an infarct is the inferior wall. Coronary Artery Affected Location of Infarct Left Coronary Artery (LCA) Extensive Anterior Wall MI Left Circumflex Artery (LCX) Lateral Wall MI Left Anterior Descending (LAD) Anterior Wall MI Right Coronary Artery (RCA) Inferior Wall MI Posterior Descending Artery (PDA) Posterior Wall MI Coronary Circulation: {{caption_text}}

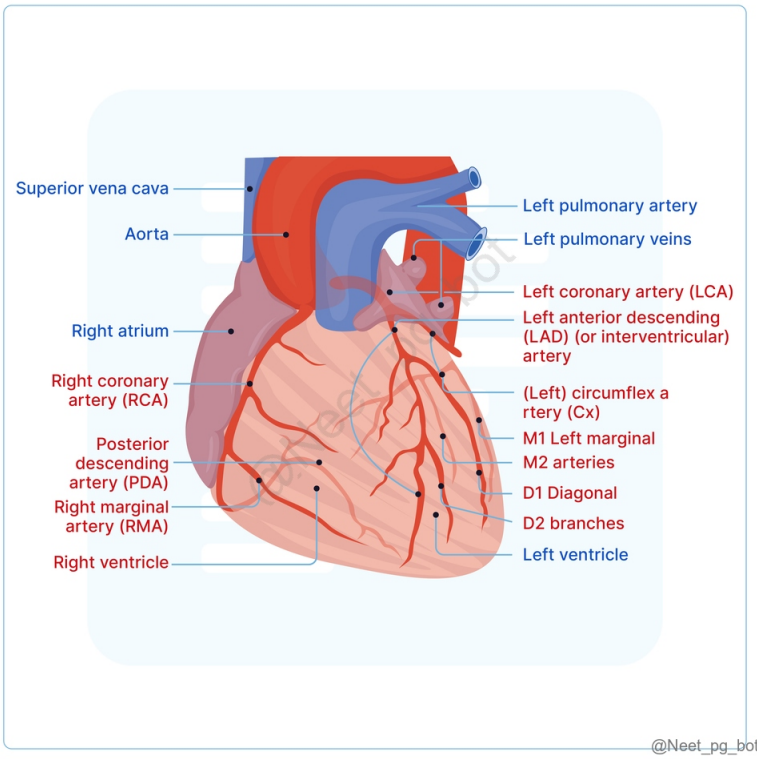

References:

Harrison's Principles of Internal Medicine, 22nd Edition, Page 1896, 1908.

Davidson's principles and practice of medicine, 24th Edition, Page: 444,445.

Guyton and Hall Textbook of Medical Physiology, 14th Edition, Page: 262

↑ *Back to this question in Part A*

@Neet_pg_bot

Q11: Which of the following is correct placement for Lead II on the ECG? (Q850474)

A. Left arm (+) to Left arm (–)

B. Right arm (+) to Left arm (–)

C. Left arm (–) to Left leg (+)

D. Right arm (–) to Left leg (+)

Correct Answer: D. Right arm (–) to Left leg (+)

■ *Listen (English)*

■ *Listen (Hindi)*

Explanation: In an ECG, the correct configuration for Lead II involves placing the positive electrode on the Left Leg (LL) and the negative electrode on the Right Arm (RA). This configuration allows the ECG to capture the electrical activity of the heart as it flows from the right atrium to the left ventricle. 12-Lead ECG System for Cardiac Monitoring Limb Leads forming einthoven's Triangle The concept of Einthoven's triangle is crucial for understanding lead placement in ECGs. It is an imaginary triangle formed by connecting the three limb electrodes (Right Arm, Left Arm, and Left Leg). The triangle represents the standard limb leads, which are as follows: Lead I: Left Arm (+) to Right Arm (–) Lead II: Left Leg (+) to Right Arm (–) Lead III: Left Leg (+) to Left Arm (–)

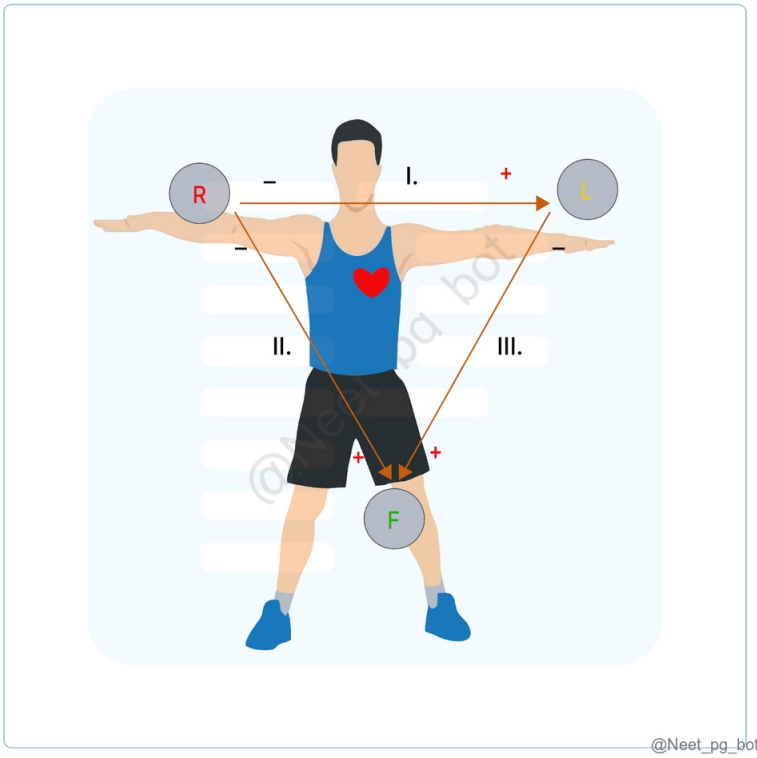

References:

Harrison's Principles of Internal Medicine, 22nd Edition, Page 1869.

↑ *Back to this question in Part A*

@Neet_pg_bot

Q12: A 56-year-old smoker male presented to the emergency department with chest pain radiating to interscapular area. On examination unequal radial artery pulse is palpated with BP of 180/110 mm Hg. Clinical diagnosis is: (Q850466)

A. Aortic dissection

B. Preductal coarctation of aorta

C. Aortic transection

D. Postductal coarctation of aorta

Correct Answer: A. Aortic dissection

■ *Listen (English)*

■ *Listen (Hindi)*

Explanation: Correct Option A - Aortic dissection: This patient presents with sudden severe chest pain radiating to the interscapular region, severe hypertension, and unequal radial pulses, which are classic features of acute aortic dissection. Smoking and hypertension are major risk factors. Pulse deficit and differential blood pressure between limbs are hallmark clinical signs. Preductal coarctation of aorta (Option B): Preductal coarctation presents in infancy or childhood with heart failure and differential cyanosis. It does not present acutely in a 56-year-old. Aortic transection (Option C): Aortic transection is usually due to severe blunt trauma (e.g., road traffic accident) and presents with shock, not isolated hypertension. Postductal coarctation of aorta (Option D): Postductal coarctation presents in younger patients with upper limb hypertension and weak femoral pulses, not acute tearing chest pain.

References:

Harrison's Principles of Internal Medicine, 22nd Edition, Page 1872, 2115.

↑ *Back to this question in Part A*

@Neet_pg_bot

Q13: A 60-year-old male presents with a sudden onset of severe chest pain that radiates to his left arm. This pain started about 60 minutes ago while he was having his breakfast. His medical history includes hypertension and hyperlipidemia. An ECG has been performed and cardiac biomarkers are significantly elevated. What is the most likely cause of his presentation? (Q850465)

A. Coronary artery spasm

B. Coronary artery embolism

C. Spontaneous coronary artery dissection

D. Plaque rupture

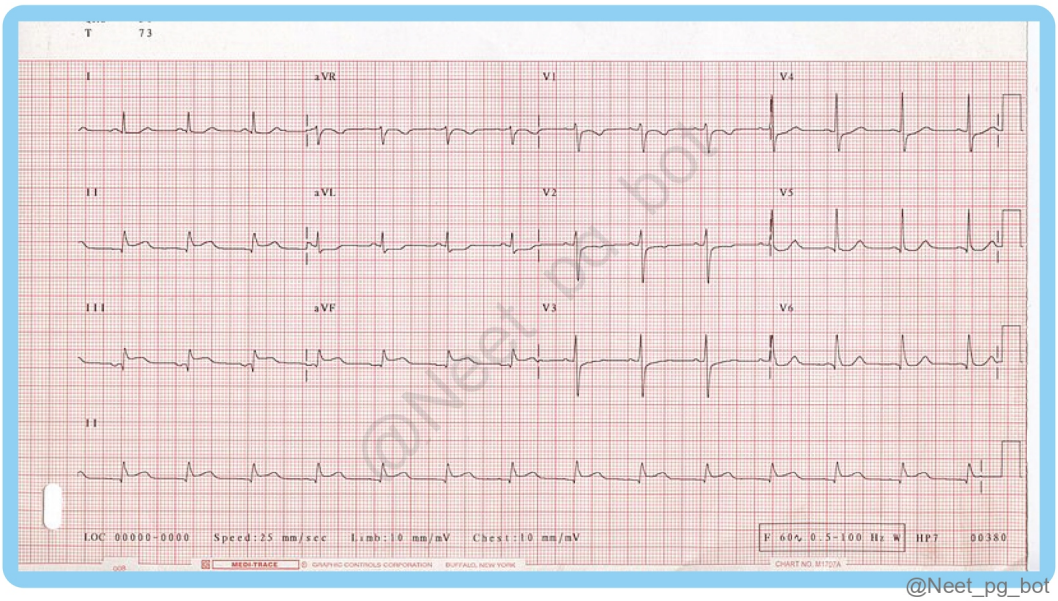

Correct Answer: D. Plaque rupture

■ *Listen (English)*

■ *Listen (Hindi)*

Explanation: The 12-lead ECG reveals ST-segment elevation in leads II, III, and aVF, accompanied by reciprocal ST-segment depression in leads I and aVL, indicating an inferior wall ST-segment elevation myocardial infarction. The primary underlying cause of this STEMI is often the rupture of an atherosclerotic plaque, which results in thrombus formation and subsequent myocardial ischemia. Coronary artery spasm (Prinzmetal's angina) (Option A): This causes transient ST-segment elevation due to vasospasm but does not typically lead to the same pattern of ischemia or cardiac marker elevation seen in this patient. Coronary artery embolism (Option B): Although a possible cause of myocardial infarction, it is much rarer compared to plaque rupture. Coronary emboli can result from conditions like atrial fibrillation or endocarditis but generally present differently. Spontaneous coronary artery dissection (Option C): SCAD is a rare cause of myocardial infarction, seen mostly in younger women and often associated with pregnancy or connective tissue disorders. The presentation may differ from classic STEMI.

References:

Harrison's Principles of Internal Medicine, 22nd Edition, Page 2113-2116.

↑ *Back to this question in Part A*

@Neet_pg_bot

Q14: A 72-year-old man underwent PCI with drug-eluting stents for double vessel disease yesterday. Today he develops chest pain with ECG showing ST-segment depression and cTn levels rising to five times the 99th percentile of the upper limit. What type of MI is seen in this case? (Q850462)

A. Type 1

B. Type 2

C. Type 3

D. Type 4

Correct Answer: D. Type 4

■ *Listen (English)*

■ *Listen (Hindi)*

Explanation: Post PCI myocardial infarction is classified as Type 4a MI. It has Troponin I values rising to 5x or more of normal. Types of MI Type 1 MI Occurs due to Plaque rupture/ Ulceration/ coronary dissection with thrombus Type 2 MI Occurs due to supply demand mismatch Fixed coronary atherosclerosis Coronary spasm or Coronary embolism Coronary artery dissection without thrombus Sustained tachyarrhythmia, Severe bradyarrhythmia Severe anemia or hypotension Type 3 MI When sudden cardiac death occurs due to MI before biomarkers values could be drawn and sent to lab Type 4a MI related to percutaneous coronary intervention Requires a fivefold increase in cTn values if initial values are normal. If initial cTn values are above the 99th percentile URL, a 20% rise is needed, with final values exceeding five times the 99th percentile. Type 4b MI This is associated with a stent thrombosis. Type 4c MI Associated with focal or diffuse restenosis after PCI Type 5 MI related to coronary artery bypass grafting Requires a tenfold increase in cTn values if initial values are normal. If initial cTn values are above the 99th percentile URL, a 20% rise is needed, with final values exceeding ten times the 99th percentile.

References:

Harrison's Principles of Internal Medicine, 22nd Edition, Page 2118.

↑ *Back to this question in Part A*

@Neet_pg_bot

Q15: Which of the following is correct about predisposition to atherosclerosis in these vessels? (Q850396)

A. Popliteal arteries > Coronary arteries > Circle of Willis > Abdominal aorta

B. Coronary arteries > Abdominal aorta > Circle of Willis > Popliteal arteries

C. Abdominal aorta > Coronary arteries > Popliteal arteries > Circle of Willis

D. Coronary arteries > Circle of Willis > Abdominal aorta > Popliteal arteries

Correct Answer: C. Abdominal aorta > Coronary arteries > Popliteal arteries > Circle of Willis

■ *Listen (English)*

■ *Listen (Hindi)*

Explanation: Arteries Involved in Atherosclerosis in decreasing order of involvement (mnemonic: ACP-Willis) A bdominal Aorta: Formation of an abdominal aortic aneurysm in infrarenal abdominal aorta C oronary Arteries ST-Elevation Myocardial Infarction Non-ST Elevation Myocardial Infarction / Unstable Angina P opliteal Arteries: Atherosclerosis in these arteries leads to peripheral artery disease (PAD), causing intermittent claudication Circle of Willis : Atherosclerotic plaques in the cerebral arteries can result in transient ischemic attacks (TIA) or strokes. {{caption_text}}

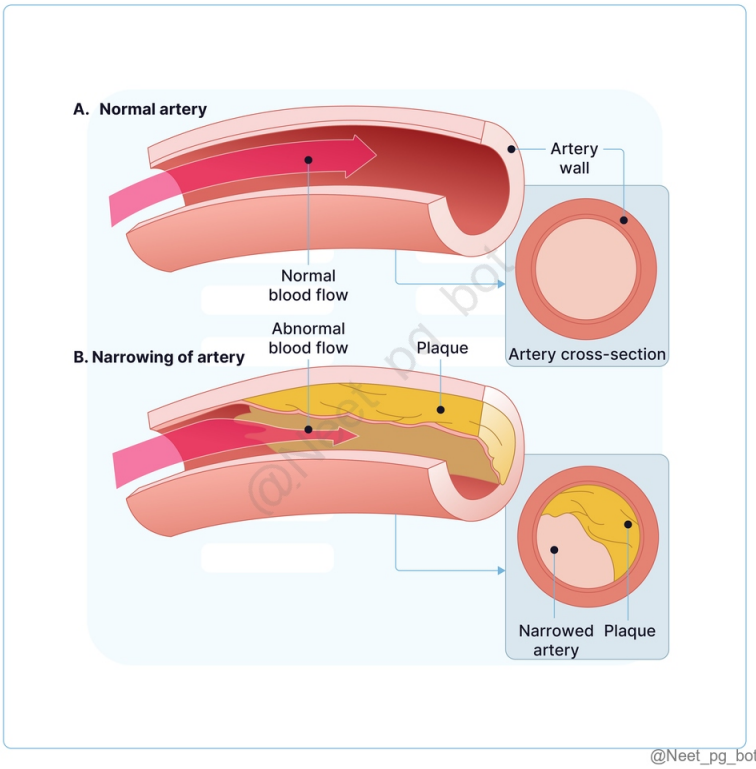

References:

Harrison's Principles of Internal Medicine, 22nd Edition, Page 2170.

↑ *Back to this question in Part A*

@Neet_pg_bot

Q16: A 58-year-old man presents with chest pain at rest for the past 4 hours. He has a history of hypertension and hyperlipidemia. ECG shows ST-segment depression in lead II, III, aVF and his cardiac troponin levels are elevated. What is the most appropriate next step in managing this patient's condition? (Q850452)

A. Immediate coronary artery bypass grafting

B. Thrombolysis

C. High-intensity Atorvastatin and ACEI

D. Aspirin and Ticagrelor

Correct Answer: D. Aspirin and Ticagrelor

■ *Listen (English)*

■ *Listen (Hindi)*

Explanation: The patient has NSTEMI (ST depression and elevated troponins)- inferior wall MI. The initial management includes dual antiplatelet therapy with aspirin and a P2Y12 inhibitor (e.g., ticagrelor) along with anticoagulation and risk stratification. Immediate coronary artery bypass grafting (Option A) is not first-line; CABG is reserved for high-risk anatomy or failed PCI. Thrombolysis (Option B) is used for STEMI, not NSTEMI. High-intensity Atorvastatin and ACEI (Option C) are part of secondary prevention, not immediate acute management.

References:

Harrison's Principles of Internal Medicine, 22nd Edition, Page 2110.

↑ *Back to this question in Part A*

@Neet_pg_bot

Q17: A 59-year-old woman with T2DM presents to ER with chest discomfort at rest radiationg to jaw and nausea for past 2 hours. ECG shows T wave inversion and ST depression in lead II, III, aVF. Trop I value is greater than 99th centile of upper reference limit. Which of the following is the most likely diagnosis? (Q850448)

A. Stable angina

B. Unstable angina

C. Non-ST elevation MI

D. ST elevation MI

Correct Answer: C. Non-ST elevation MI

■ *Listen (English)*

■ *Listen (Hindi)*

Explanation: The scenario here points to NSTEMI which is diagnosed by raised serum troponin levels, ECG changes of T-wave inversion, and clinical symptoms of chest pain. {{caption_text}} Stable angina (Option A) is a type of ischemic heart disease that occurs when the heart muscle does not receive adequate oxygen due to reduced blood flow through the coronary arteries, especially during physical exertion or emotional stress and presents with chest pain that lasts 2-10 minutes and is relieved on rest . Unstable angina (Option B) is ruled out as it has normal biomarkers. ST-Elevation MI (Option D) is caused by prolonged obstruction of blood supply to a part of the heart muscle, leading to tissue damage or necrosis, and has significant ST elevation in the ECG.

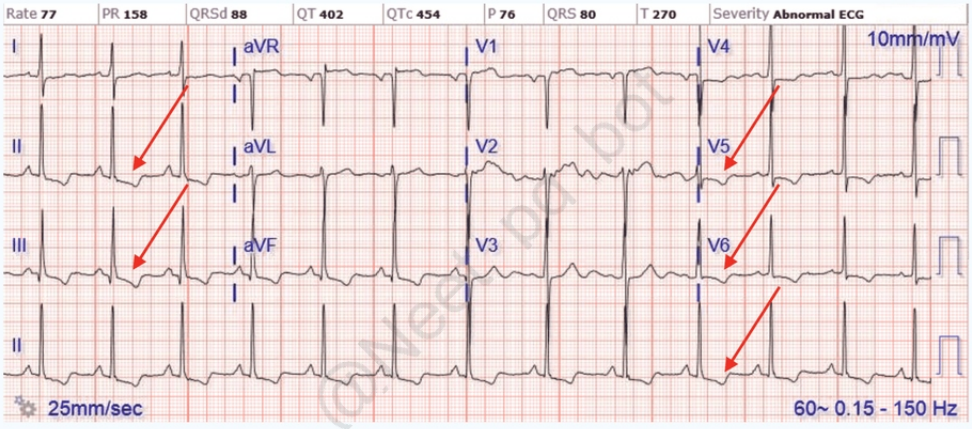

ECG of initial NSTEMI showing T wave inversion in leads II, III, aVF, and V4-6.
ECG, electrocardiogram : NSTEMI, non-ST segment elevation myocardial infraction

References:

Harrison's Principles of Internal Medicine, 22nd Edition, Page 2107-2108.

↑ *Back to this question in Part A*

@Neet_pg_bot

Q18: Check out this ECG finding and select the condition(s) that can present with this change? Hyperkalemia Variant Angina Digoxin (Therapeutic doses) Left Ventricular Hypertrophy (LVH) Chronic Stable Angina (Q850441)

A. 1 and 3

B. 1 and 2

C. 2, 3, and 5

D. 1, 2 and 5

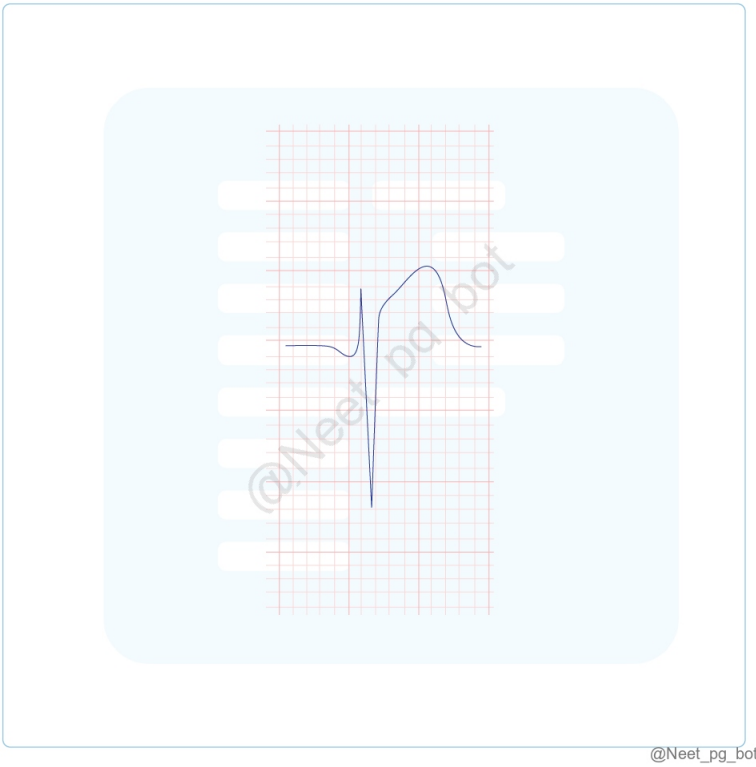

Correct Answer: B. 1 and 2

- *Listen (English)*
- *Listen (Hindi)*

Explanation: Conditions for ST elevation- Due to systolic current injury and ST depression ST Elevation ST Depression {{caption_text}} {{caption_text}} Acute Myocardial Infarction (STEMI) Prinzmetal Angina (statement 2) Left Bundle Branch Block (LBBB) Brugada syndrome Pericarditis (acute) Benign early repolarization Takotsubo Cardiomyopathy Aortic Dissection Hyperkalemia (Statement 1) Non-ST-Elevation Myocardial Infarction (NSTEMI) Digoxin (Therapeutic doses) (Statement 3) Chronic Stable Angina (Statement 5) Subendocardial ischemia (LV hypertrophy) (Statement 4) Hypokalemia

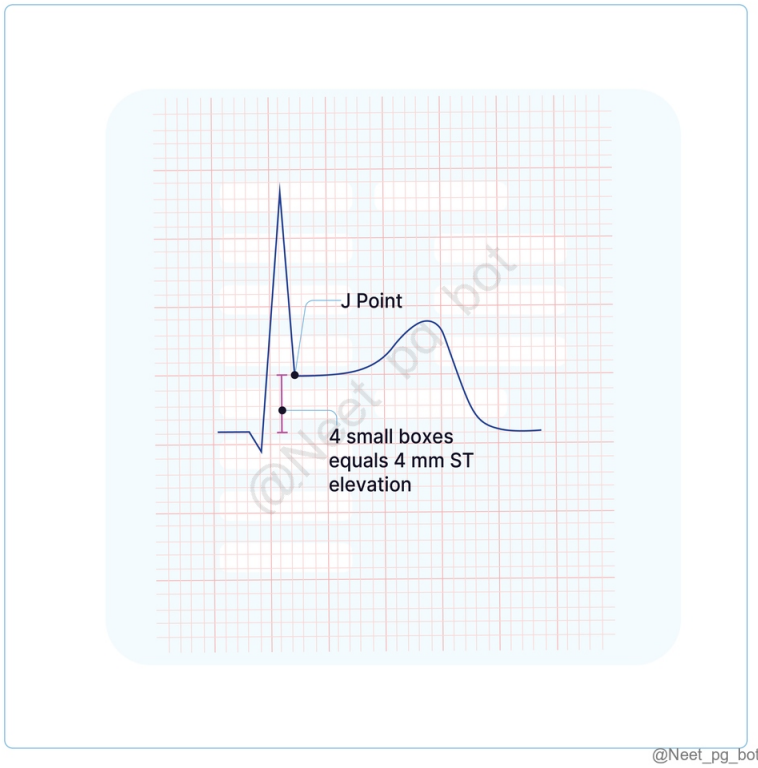

@Neet_pg_bot

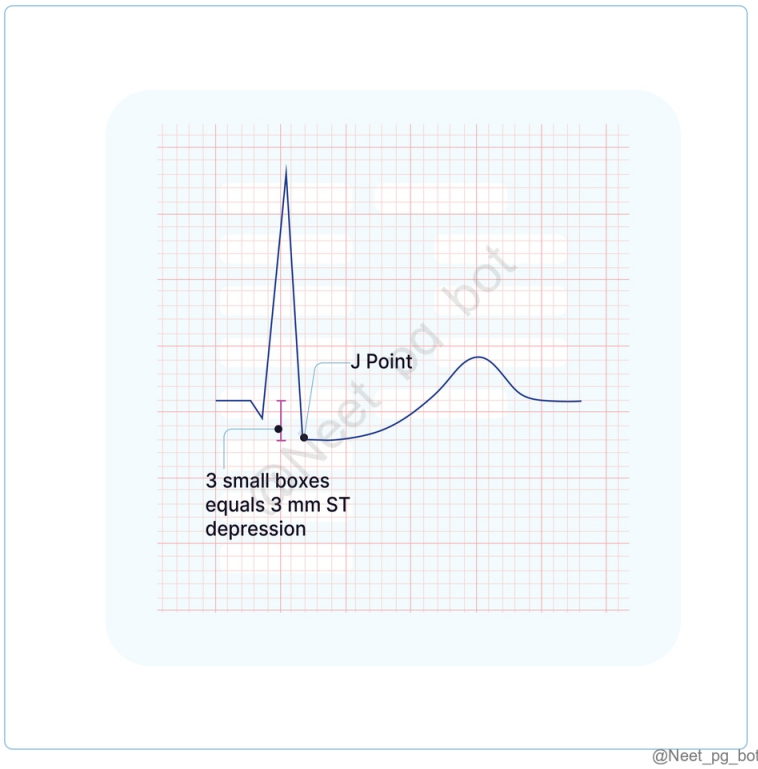

@Neet_pg_bot

References:

Harrison's Principles of Internal Medicine, 22nd Edition, Page 1873-1874.

↑ *Back to this question in Part A*

@Neet_pg_bot

Q19: A 65-year-old woman presents to the ER with early morning episode of chest pain lasting 15 minutes which is relieved by sublingual nitroglycerin. She has had similiar episodes in past and her husband says that metoprolol was started which worsend her chest pain episodes so they stopped the medication. Past medical history is significant for Raynaud phenomenon. ECG is given below. There is no elevation of cardiac markers on serial evaluation. Which of the following is the most likely diagnosis? (Q850434)

A. Stable angina

B. Unstable angina

C. Prinzmetal angina

D. Myocardial infarction

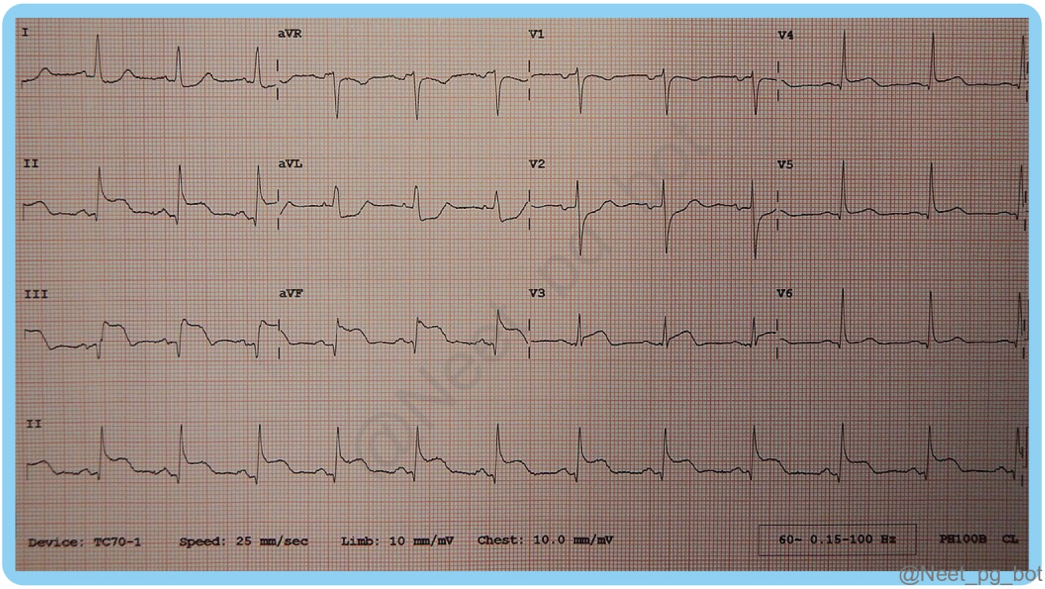

@Neet_pg_bot

Correct Answer: C. Prinzmetal angina

■ *Listen (English)*

■ *Listen (Hindi)*

Explanation: Based on the given scenario, the diagnosis is consistent with Prinzmetal angina, which is characterized by episodes of chest pain at rest, often relieved by nitroglycerin, and associated with transient ST-segment elevations on ECG. It is caused by coronary artery spasm rather than obstructive coronary artery

disease, and cardiac markers remain normal during these episodes. Stable angina (Option A): This type of angina is typically triggered by physical exertion or emotional stress and is characterized by predictable episodes of chest pain. It does not usually occur at rest and does not show transient ST-segment elevations during rest episodes. Unstable angina (Option B): This condition involves chest pain that occurs at rest, is more severe, and may last longer than stable angina. Myocardial infarction (Option D): MI typically presents with prolonged chest pain, elevated cardiac markers, and more significant ECG changes such as ST-segment elevation or depression that do not resolve with nitroglycerin.

References:

Harrison's Principles of Internal Medicine, 22nd Edition, Page 2112.

↑ *Back to this question in Part A*

@Neet_pg_bot

Q20: A 62-year-old male presents to ER central chest pain at rest and shortness of breath for last one hour. His medical history includes hypertension and hyperlipidemia. Troponin I is elevated. Which of the following is the most appropriate initial management for this patient's condition? (Q850428)

A. Send for PCI

B. Chewable Aspirin and Atorvastatin

C. Enoxaparin and Eptifibatide

D. IV atropine followed by temporary pacing

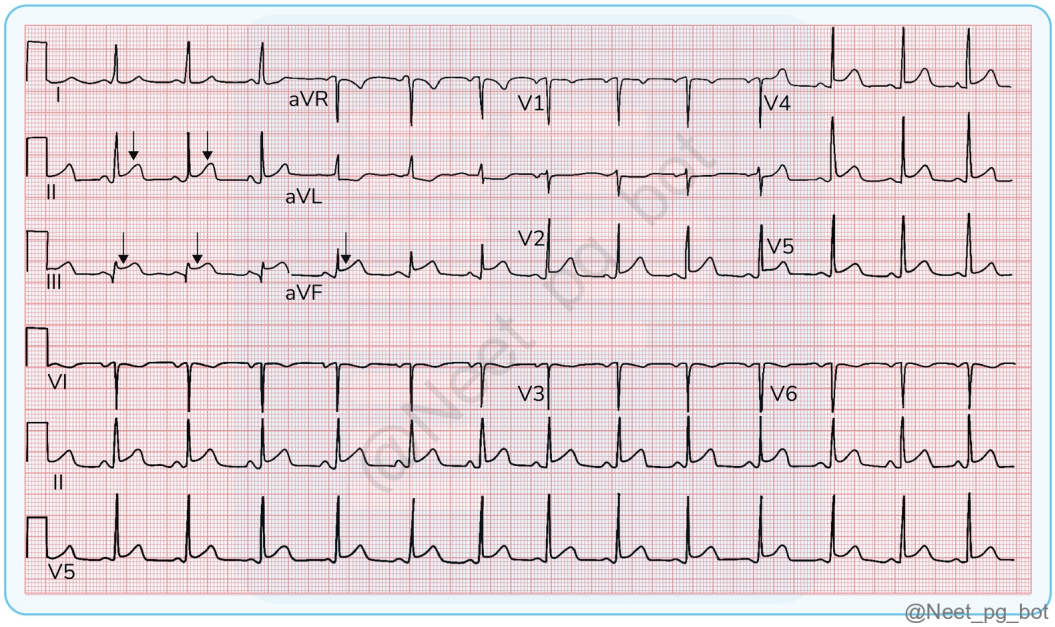

Correct Answer: B. Chewable Aspirin and Atorvastatin

■ *Listen (English)*

■ *Listen (Hindi)*

Explanation: This ECG shows inferior STEMI with ST elevation in leads II, III, aVF and reciprocal ST-depression in aVL . The most appropriate initial management step in the ER is to give: Chewable Aspirin (162–325 mg) for immediate platelet inhibition High-intensity Atorvastatin (80 mg) to stabilize plaque After these first-line measures, the patient should be sent for urgent PCI (door-to-balloon <90 min). Send for PCI (Option A) is not the initial step in NSTEMI; it is considered after risk stratification. Enoxaparin and Eptifibatide (Option C) are anticoagulant and GP IIb/IIIa inhibitors, used adjunctively, not as the very first action. IV atropine followed by temporary pacing (Option D) is for bradyarrhythmias, not ACS management.

References:

Harrison's Principles of Internal Medicine, 22nd Edition, Page 2117-2118.

↑ *Back to this question in Part A*

@Neet_pg_bot

Q21: A 65-year-old woman is known case of chronic stable angina and has undergone PCI with stenting last year. Today morning, she presents to the ER with a 60-minute episode of chest discomfort that occurred while she was watching television. She describes the pain as a tightness in his chest, radiating to her left arm. She has a history of T2DM and has deranged lipid profile. An ECG reveals inverted T-waves. Which of the following is the best next step in the management of this patient?

(Q850422)

A. Cardiac biomarkers

B. Send to Cath lab for PCI

C. Treadmill test

D. Myocardial perfusion imaging

Correct Answer: A. Cardiac biomarkers

■ *Listen (English)*

■ *Listen (Hindi)*

Explanation: The patient is known case of chronic stable angina and has already undergone a revascularization procedure. Due to T2DM and deranged lipids , atherosclerosis process is still ongoing and has today caused her to develop Acute coronary syndrome. Since ECG shows T wave inversion she is either is having unstable angina or NSTEMI. To differentiate between the two, Cardiac biomarkers must be done initially Send to Cath lab for PCI (Option B) is indicated after confirming NSTEMI or high-risk features, not immediately without biomarkers. Treadmill test (Option C) is not appropriate during acute chest pain. Myocardial perfusion imaging (Option D) is used for elective ischemia assessment, not in acute evaluation.

References:

Harrison's Principles of Internal Medicine, 22nd Edition, Page 2113.

↑ *Back to this question in Part A*

@Neet_pg_bot

Q22: What is the revascularization procedure of choice for two different cases, Patient A with triple vessel disease and Patient B with left anterior descending artery blockage with EF < 40%? (Q850420)

A. A: CABG; B: PCI with stenting

B. CABG for both A and B

C. A: PCI with stenting; B: CABG

D. A: PCI with Bare metal stenting ; B: PCI with drug eluting stenting

Correct Answer: B. CABG for both A and B

■ *Listen (English)*

■ *Listen (Hindi)*

Explanation: Coronary revascularization can be achieved either by Percutaneous Coronary Intervention (PCI) or Coronary Artery Bypass Grafting (CABG). The choice depends on the number of vessels involved, the location of the lesion, the complexity of coronary artery disease, and left ventricular function. Patient A: Triple Vessel Disease Patient B: LAD Blockage with EF < 40% In patients with triple-vessel coronary artery disease, CABG is the preferred revascularization strategy because it: Provides better long-term survival Achieves more complete revascularization Reduces the need for repeat revascularization procedures Therefore, CABG is the treatment of choice for triple-vessel disease, especially when there is associated left ventricular dysfunction or diabetes mellitus. In patients with significant LAD disease and reduced left ventricular ejection fraction (<40%), CABG is preferred over PCI because of surgical revascularization: Improves myocardial perfusion Provides better survival benefit in patients with LV dysfunction Reduces long-term mortality and major cardiac events Thus, CABG is the preferred revascularization strategy in patients with significant coronary artery disease associated with reduced ejection fraction.

References:

Harrison's Principles of Internal Medicine, 22nd Edition, Page 2103, 2105

↑ *Back to this question in Part A*

@Neet_pg_bot

Q23: A 65-year-old male with chronic stable angina presents with chest pain during routine activities. His current medications include aspirin, metoprolol, isosorbide mononitrate and atorvastatin, but his symptoms persist. Coronary angiography reveals 90% stenosis of the right coronary artery. and 70% in LCX. What is the most appropriate intervention? (Q850416)

A. Increase the dose of beta-blockers

B. Increase the dose of Long acting nitrates

C. PCI with drug-eluting stenting

D. Refer for coronary artery bypass grafting

Correct Answer: C. PCI with drug-eluting stenting

■ *Listen (English)*

■ *Listen (Hindi)*

Explanation: In a patient with chronic stable angina who remains symptomatic despite optimal medical therapy and has significant coronary stenosis (>70%) on angiography, PCI with drug-eluting stent placement is the appropriate next step to improve symptoms and prognosis. Increasing the dose of beta-blockers (Option A) may reduce heart rate and myocardial oxygen demand but will not correct the underlying mechanical obstruction.

Increasing the dose of long-acting nitrates (Option B) provides temporary symptomatic relief but is not definitive therapy once critical stenosis is documented. Coronary artery bypass grafting (Option D) is indicated in left main disease, triple-vessel disease, or diabetics with multivessel involvement — not in isolated RCA and LCX stenosis.

References:

Harrison's Principles of Internal Medicine, 22nd Edition, Page 2103.

↑ *Back to this question in Part A*

@Neet_pg_bot

Q24: A 60-year-old man with a history of CAD presents with recurrent syncope. Considering his intermediate to high risk for CAD, which imaging modality would be most appropriate for further evaluation? (Q850414)

A. Myocardial Perfusion Imaging

B. Stress Echocardiography

C. Multigated Acquisition (MUGA) Scanning

D. Treadmill test

Correct Answer: A. Myocardial Perfusion Imaging

■ *Listen (English)*

■ *Listen (Hindi)*

Explanation: Myocardial perfusion imaging is ideal for evaluating ischemia in patients with intermediate to high CAD risk, like this patient with a history of CAD and syncope . Thallium-201 imaging effectively detects areas of reduced blood flow , helping identify underlying ischemic disease. It's preferred when structural heart disease has been ruled out, as in this case, where echocardiography showed no abnormalities. Stress echocardiography (Option B) is useful but less sensitive than MPI in patients with known CAD and baseline ECG abnormalities. Multigated Acquisition (MUGA) scanning (Option C) assesses left ventricular ejection fraction but does not evaluate myocardial ischemia. Treadmill test (Option D) is contraindicated in high-risk CAD patients and may be unreliable or unsafe in those with recurrent syncope.

References:

Harrison's Principles of Internal Medicine, 22nd Edition, Page 1885-1886.

↑ *Back to this question in Part A*

@Neet_pg_bot

Q25: A 60-year-old male smoker presents with chest pain on climbing stairs. He is started on low-dose aspirin, statins and metoprolol by his GP. His symptoms have worsened despite medical therapy. What is the next best step in diagnosing the extent of his coronary artery disease? (Q850409)

A. Stress echocardiography

B. Myocardial perfusion imaging

C. Coronary angiography

D. Coronary computed tomography angiography

Correct Answer: D. Coronary computed tomography angiography

■ *Listen (English)*

■ *Listen (Hindi)*

Explanation: Coronary CT angiography (CCTA) is the next best step to evaluate the extent and severity of coronary artery disease in a stable patient whose symptoms have worsened despite optimal medical therapy. It is a non-invasive imaging modality that provides detailed visualization of coronary anatomy and plaque burden before considering invasive procedures. Stress echocardiography (Option A) is mainly used for initial diagnosis in stable angina, not for further evaluation when symptoms worsen despite therapy. Myocardial perfusion imaging (Option B) detects reversible ischemia but does not define coronary anatomy precisely. Coronary angiography (Option C) is invasive and reserved for patients with high-risk findings or those being considered for revascularization after non-invasive assessment.

References:

Harrison's Principles of Internal Medicine, 22nd Edition, Page 1880, 2097, 3907.

↑ *Back to this question in Part A*

@Neet_pg_bot

Q26: A 60-year-old male undergoes a treadmill ECG stress test and develops 2 mm of horizontal ST-segment depression after 12 minutes of exercise. He reports non-limiting chest pain (angina index = 1). What is his Duke Treadmill Score (DTS) and his risk category? (Q850405)

A. DTS = 0; Intermediate risk

B. DTS = 5; Low risk

C. DTS = -2; Intermediate risk

D. DTS = -8; High risk

Correct Answer: C. DTS = -2; Intermediate risk

■ *Listen (English)*

■ *Listen (Hindi)*

Explanation: Duke Treadmill Score (DTS) is calculated using the formula: DTS = Exercise time (in minutes) – (5× ST-segment deviation (in mm)) – (4 × angina index) The patient exercised for 12 minutes . There was 2 mm of horizontal ST-segment depression, so multiply by 5 . 5×2=10 The patient reported non-limiting chest pain, so the angina index = 1 (non-limiting angina). 4×1=4 Therefore, the DTS calculation: DTS = 12 –10 – 4= –2DTS This places the patient in the intermediate-risk category . Risk Interpretation: Risk DTS Interpretation Low Risk ≥ 5 No need for further coronary angiography. Intermediate Risk (Option C) +4 to –10 May need further tests, such as myocardial perfusion scanning or coronary angiography. High Risk < –10 Requires further investigation with coronary angiography.

References:

pmc.ncbi.nlm.nih.gov/articles/PMC1123951/

↑ *Back to this question in Part A*

@Neet_pg_bot

Q27: An elderly male with a history of cigarette smoking and hypertension develops chest pain after an evening walk. The pain is relieved after lying down for a few minutes. A treadmill stress test reveals ST-segment depression. What is the most likely cause attributed to this clinical presentation? (Q850402)

A. Hypertrophic Cardiomyopathy

B. Prinzmetal Angina

C. Non-ST-Elevation Myocardial Infarction (NSTEMI)

D. Chronic Stable Angina

Correct Answer: D. Chronic Stable Angina

■ *Listen (English)*

■ *Listen (Hindi)*

Explanation: Chronic stable angina, or exertional angina, is a type of ischemic heart disease that occurs when the heart muscle does not receive adequate oxygen due to reduced blood flow through the coronary arteries, especially during physical exertion or emotional stress. Usually lasts 5-10 minutes and resolves with rest or with the use of sublingual nitroglycerin within a few minutes. ECG Findings: Symptomatic Phase (During Angina): ST-segment

depression (hallmark finding), indicating subendocardial ischemia due to insufficient blood flow to the inner layer of the heart muscle. Hypertrophic Cardiomyopathy (Option A): While this condition may cause ischemia, it is not typically associated with ST-segment depression on a treadmill test. Prinzmetal Angina (Option B): This type of angina typically occurs at rest, often during nighttime or early morning, and is associated with transient ST-segment elevation rather than depression. Non-ST-Elevation Myocardial Infarction (NSTEMI) (Option C): While NSTEMI can present with ST-segment depression, the chest pain is more persistent and not typically relieved by rest.

References:

Harrison's Principles of Internal Medicine, 22nd Edition, Page 2094-2097.

↑ *Back to this question in Part A*

@Neet_pg_bot

Q28: Arrange the following structures of an atherosclerotic plaque inside a blood vessel from the innermost to the outermost layer: Fibrous cap Necrotic core Foam cell layer Media (Q850399)

A. Fibrous cap → Foam cell layer→ Necrotic core → Media

B. Necrotic core → Media → Foam cell layer → Fibrous cap

C. Foam cell layer → Fibrous cap → Media→ Necrotic core

D. Foam cell layer → Necrotic core → Fibrous cap → Media

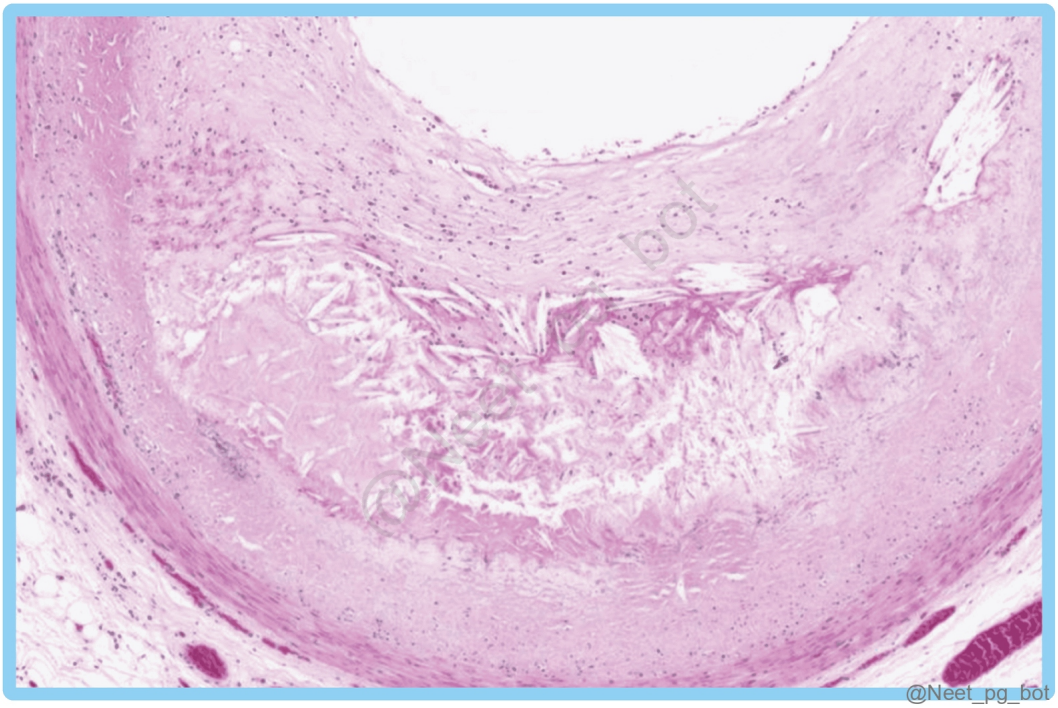

Correct Answer: A. Fibrous cap → Foam cell layer→ Necrotic core → Media

Explanation: Sequence of Atherosclerosis Development Endothelium (injury from HTN, hyperlipidemia, smoking) → LDL accumulation & macrophage engulfment → Foamy cell layer (fatty streaks) → Foam cell death → Necrotic core (dead cells + cholesterol) → Smooth muscle migration → Fibrous cap formation → Media thinning & weakening → Plaque formation and vulnerability {{caption_text}} {{caption_text}}

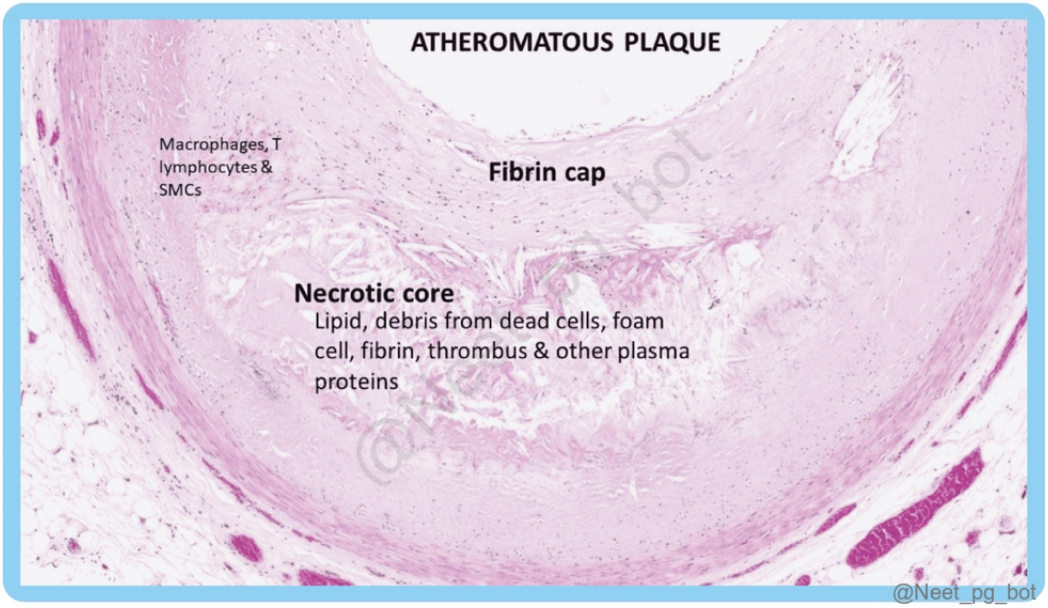

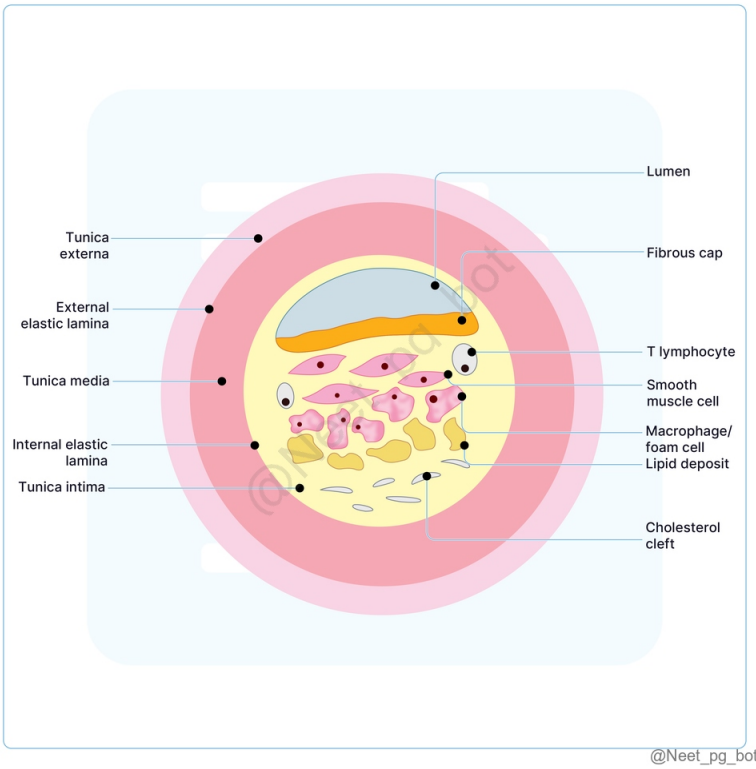

References:

Robbins & Cotran Pathologic Basis of Disease, 10th Edition, Page 493-502.

↑ *Back to this question in Part A*

@Neet_pg_bot

• [01_Cardiology] 006 Systemic Htn Pulmonary Htn

« Back to Folder Directory

[01_Cardiology] 006 Systemic Htn Pulmonary Htn — Quick Jump

Q1 (p. 1216) *Q2 (p. 1216)* *Q3 (p. 1217)* *Q4 (p. 1218)* *Q5 (p. 1219)* *Q6 (p. 1220)*
Q7 (p. 1221) *Q8 (p. 1221)* *Q9 (p. 1222)* *Q10 (p. 1223)*

Q1: A 55-year-old male presented to the clinic for a routine check-up last week. Automated Office Blood Pressure (AoBP) readings of 142/94, 138/86, and 138/90 mmHg. Ambulatory blood pressure monitoring (ABPM) was advised and the average 24-hour blood pressure is 138/86 mmHg. According to the ACC/AHA hypertension classification, what category does his blood pressure fall into? (Q850501)

A. Normal blood pressure

B. Elevated blood pressure

C. Stage 1 hypertension

D. Stage 2 hypertension

Correct Answer: C. Stage 1 hypertension

■ *Listen (English)*

■ *Listen (Hindi)*

Explanation: Stage 1 hypertension is a systolic blood pressure between 130-139 mmHg or diastolic blood pressure between 80-89 mmHg. The patient’s ABPM shows systolic readings between 138-142 mmHg and diastolic values between 86-90 mmHg. Hypertension category based on the American College of Cardiology (ACC) Blood pressure category Systolic (mm Hg) Diastolic (mm Hg) Normal < 120 < 80 Elevated 120-129 <80 Stage 1 hypertension 130 – 139 80 – 89 Stage 2 hypertension ≥140 ≥90 Hypertensive crisis >180 >120

References:

Harrison's Principles of Internal Medicine, 22nd Edition, Page 2134.

↑ *Back to this question in Part A*

@Neet_pg_bot

Q2: A 60-year-old male with a BMI of 30 presents with frequent headaches and dizziness. His office blood pressure is recorded as 126/74 mmHg, but home readings range between 150/94 mmHg and 156/90 mmHg. Ambulatory blood pressure monitoring confirms these findings with higher readings outside the office. Which of the following is the most appropriate management plan for this patient? (Q850503)

A. Lifestyle modifications alone is sufficient

B. Initiate antihypertensive therapy

C. Increase clinic visit frequency to monitor blood pressure

D. Diagnosis to be reconfirmed in 3 to 6 months

Correct Answer: B. Initiate antihypertensive therapy

■ *Listen (English)*

■ *Listen (Hindi)*

Explanation: The person in question most likely has masked hypertension. Lifestyle measures plus antihypertensive drug therapy are recommended. ACC/AHA White coat hypertension Masked hypertension Definition Elevated clinic or office BP and normal out-of-office BP (on ABPM or HBPM) in individuals not receiving antihypertensive therapy Normal BP on clinic or office BP readings and elevated out-of-office BP readings in individuals not receiving antihypertensive therapy Diagnosis Cutoff for Office Blood Pressure: ≥130/80 mmHg Cutoff for Out-of-Office Blood Pressure (Daytime ABPM or HBPM): <130/80 mmHg Cutoff for Office Blood Pressure: 120–129/<80 mmHg Cutoff for Out-of-Office Blood Pressure (Daytime ABPM or HBPM): ≥130/80 mmHg Management Lifestyle measures Diagnosis to be reconfirmed in 3 to 6 months (Option D ruled out) Yearly follow-ups with ABPM to detect progression to sustained hypertension Antihypertensive treatment: Estimated 10-year atherosclerotic cardiovascular disease risk of ≥10% Hypertension-related target organ damage Lifestyle measures + antihypertensive drug therapy recommended (Option B)(Option A ruled out) Long-term out-of-office BP monitoring (Option C ruled out) Abbreviations: HBPM - Home BP monitoring ABPM - Ambulatory BP monitoring

References:

Harrison's Principles of Internal Medicine, 22nd Edition, Page 1862, 2135.

↑ *Back to this question in Part A*

@Neet_pg_bot

Q3: During a lecture on cardiovascular physiology, a professor explained that conditions causing unequal arm blood pressure often involve branches of the aortic arch. Which of the following conditions is not likely to cause a difference in blood pressure between the arms? (Q850504)

A. Aortic dissection involving the ascending aorta

B. Coarctation of the aorta distal to the left subclavian artery

C. Takayasu arteritis affecting the aortic arch

D. Subclavian artery stenosis

Correct Answer: B. Coarctation of the aorta distal to the left subclavian artery

■ *Listen (English)*

■ *Listen (Hindi)*

Explanation: Coarctation of the aorta that occurs distal to the left subclavian artery does not cause a difference in blood pressure between the arms because the left subclavian and right brachiocephalic artery originates from the aorta before the point of coarctation. As a result, blood flow to the arms remains relatively equal. It will rather cause unequal BP between upper limbs and lower limbs. Conditions causing unequal left and right arm blood pressures Pathophysiology Aortic Dissection (Option A) Dissection occurring at the site of arterial branching from the aorta Subclavian Artery Stenosis (Option D ruled out) Atherosclerosis or other causes of stenosis (Thoracic Outlet Syndrome) in the subclavian artery reduce blood flow to the affected arm Takayasu Arteritis (Option C) Chronic vasculitis that affects large arteries, particularly the aorta and its branches

References:

Harrison's Principles of Internal Medicine, 22nd Edition, Page 1862.

↑ *Back to this question in Part A*

@Neet_pg_bot

Q4: A 28-year-old male with a history of resistant hypertension and periodic muscle cramps is being investigated. Lab tests show hypokalemia, low plasma renin activity, and low aldosterone levels. Genetic testing reveals a mutation in the epithelial sodium channel (ENaC). What is the most likely diagnosis? (Q850505)

A. Gordan syndrome

B. Liddle syndrome

C. Congenital adrenal hyperplasia (CAH)

D. Pheochromocytoma

Correct Answer: B. Liddle syndrome

■ *Listen (English)*

■ *Listen (Hindi)*

Explanation: Liddle syndrome is characterized by a mutation in the ENaC , leading to increased sodium reabsorption, volume expansion, and hypertension. The presence of hypokalemia, low renin, and low aldosterone levels is consistent with this diagnosis. Mendelian causes of HTN Disease Mode of inheritance Pathophysiology Key Features Gordon syndrome (Pseudohypoaldosteronism type II) (Option A ruled out) Autosomal dominant Mutations in regulatory proteins for the NCC (sodium chloride cotransporter) channel allow for unchecked activity, causing subsequent electrolyte and fluid overabsorption Hyperkalemia Normal glomerular filtration rate Pheochromocytoma (Option D ruled out) Autosomal dominant Neoplasia of the adrenal medulla generates heightened levels of norepinephrine and epinephrine Associated with MEN-2A (Sipple syndrome) MEN-2B VHL syndrome NF-1 Congenital Adrenal Hyperplasia (CAH) (Option C ruled out) Autosomal recessive Defects in steroid synthesis lead to buildup of intermediate metabolites with mineralocorticoid receptor activity 17-α hydroxylase deficiency: ↑ in aldosterone and thus HTN 11-β hydroxylase deficiency: ↑ in deoxycortisol which stimulates ENaC and causes HTN

References:

Harrison's Principles of Internal Medicine, 22nd Edition, Page 355.

↑ *Back to this question in Part A*

@Neet_pg_bot

Q5: A 65-year-old man with a long-standing history of hypertension presents with occasional episodes of dizziness and transient visual disturbances. Neurological examination and fundoscopy are normal. A carotid doppler is performed to visualize the carotid arteries. Which of the following findings is not expected to be seen in this patient? (Q850507)

A. Increased peak systolic velocity

B. Normal intima-media thickness

C. String sign

D. Turbulent blood flow in the carotid arteries

Correct Answer: B. Normal intima-media thickness

■ *Listen (English)*

■ *Listen (Hindi)*

Explanation: In patients with long-standing hypertension, there would likely be increased intima-media thickness due to vascular changes. Narrowing of the carotid artery lumen explains the string sign, increased velocity and resultant turbulence. Increased peak systolic velocity (Option A): Seen due to stenosis and narrowing of carotid lumen. String sign (Option C): Thread-like residual lumen in severe (>95%) carotid artery stenosis, seen on

Doppler/angiography. Turbulent blood flow (Option D): Occurs because of irregular lumen narrowing and velocity changes.

References:

Robbins & Cotran's Pathologic Basis of Diseases, 10th Edition, Page 497.

↑ *Back to this question in Part A*

@Neet_pg_bot

Q6: A 70-year-old male with a history of hypertension and not on medications has chronic kidney disease . His laboratory tests indicate an estimated glomerular filtration rate of 60 mL/min and elevated protein in his urine. His present blood pressure is 142/90 mmHg. Considering his condition, which of the following antihypertensive medications is most appropriate to initiate? (Q850508)

A. Amlodipine

B. Lisinopril

C. Hydrochlorothiazide

D. Metoprolol

Correct Answer: B. Lisinopril

■ *Listen (English)*

■ *Listen (Hindi)*

Explanation: In patients with hypertension and chronic kidney disease, ACE inhibitors like Lisinopril and ARBs are preferred first-line agents for hypertension (unless contraindicated). They help control blood pressure and provide renal protection. ACC/AHA Guidelines for Hypertension Management Indications for Use of antihypertensives Secondary prevention of recurrent CVD events in patients with clinical CVD (defined as CHD, CHF, stroke) and BP ≥130/≥80 mmHg Primary prevention in patients with an estimated 10-year ASCVD risk ≥10% and BP ≥130/≥80 mmHg Primary prevention of CVD and low CVD risk in patients with BP ≥140/ ≥90 mmHg Blood Pressure Goal in Treating Hypertension BP target < 130/80 mmHg for adults with confirmed hypertension and known CVD or 10-year ASCVD event risk ≥10% Exceptions to Therapeutic Target of <130/80 mmHg Age >80 years Blood pressure <140/90 mmHg in previously untreated hypertensive patients who experience an ischemic stroke or TIA Acute therapy for most hypertensive urgencies and emergencies Abbreviations: ASCVD - atherosclerotic cardiovascular disease CHD - coronary heart disease CHF - congestive heart failure CVD - cardiovascular disease Amlodipine (Option A): Useful add-on, but does not reduce proteinuria or provide renal protection like ACE inhibitors. Hydrochlorothiazide (Option C): Less effective when eGFR < 30–40 mL/min; also does not reduce proteinuria . Metoprolol (Option D): Beta-blockers are not first-line in CKD unless there is another indication (e.g., CAD, arrhythmia).

References:

Harrison's Principles of Internal Medicine, 22nd Edition, Page 2144.

↑ *Back to this question in Part A*

@Neet_pg_bot

Q7: Which of the following is most appropriate step cabout management of poorly controlled asthmatic on daily Formoterol and medium dose inhaled steroids and is still having nocturnal attacks daily? (Q850509)

A. Start Oral corticosteroids

B. Add LAMA

C. Start high dose inhaled corticosteroids

D. Start IV steroids

Correct Answer: B. Add LAMA

■ *Listen (English)*

■ *Listen (Hindi)*

Explanation: : The patient has poorly controlled asthma despite medium-dose ICS + LABA, with daily nocturnal symptoms, which classifies as step 4–5 asthma per GINA guidelines. Adding a LAMA (e.g., tiotropium) is the recommended next step before escalating to high-dose ICS or systemic steroids, as it improves lung function and reduces exacerbations. Start oral corticosteroids (Option A): Oral steroids are reserved for acute exacerbations or severe uncontrolled asthma, not as the first escalation step due to systemic side effects. Start high dose inhaled corticosteroids (Option C): High-dose ICS can be considered later if adding LAMA or other controllers fails, because LAMA addition is preferred first to minimize steroid side effects. Start IV steroids (Option D): IV steroids are indicated only in severe acute exacerbations, not for step-up management in stable, poorly controlled asthma.

References:

Harrison's Principles of Internal Medicine, 22nd Edition, Page 2137.

↑ *Back to this question in Part A*

@Neet_pg_bot

Q8: A 55-year-old male presents with severe headache, nausea, and confusion. His blood pressure is recorded at 190/130 mmHg. Neurological examination reveals

altered mental status, and the patient appears distressed. A fundoscopic exam shows retinal haemorrhages. What is the most appropriate classification of this patient's condition? (Q850510)

A. Hypertensive urgency

B. Hypertensive emergency

C. Malignant hypertension

D. Essential hypertension

Correct Answer: B. Hypertensive emergency

■ *Listen (English)*

■ *Listen (Hindi)*

Explanation: This patient exhibits signs of end-organ damage (altered mental status and retinal haemorrhages) classifying his condition as a hypertensive emergency. Condition Features Treatment Approach Hypertensive Urgency (Option A) Systolic BP > 180 mmHg and/or Diastolic BP > 120 mmHg without end-organ damage Reinstitution or increase of oral antihypertensives No hospitalization required Gradual BP reduction over hours/days Hypertensive Emergency The same BP values as urgency but with end-organ damage like Encephalopathy, stroke Retinal haemorrhages Aortic dissection Micronagiopathic hemolytic anemia Target 25% reduction in MAP over next 1-2 hours using IV agents (e.g., Nicardipine, labetalol and sodium nitroprusside) Malignant Hypertension (Option C) Abrupt increase in BP in previously hypertensive or normotensive patients to > 180 /120 mm Hg with papilledema. Renal impairment may coexist Fibrinoid necrosis in wall of blood vessels Intensive management often requires hospitalization and aggressive therapy with Labetaolol or nicardipine

References:

Harrison's Principles of Internal Medicine, 22nd Edition, Page 2148.

↑ *Back to this question in Part A*

@Neet_pg_bot

Q9: A 65-year-old man with a history of type 2 diabetes and hypertension presents to his primary care physician for a follow-up appointment. His blood pressure is 160/95 mmHg. The physician wants to start an antihypertensive medication. What is the target blood pressure for this patient? (Q850512)

A. < 140/90 mmHg

B. < 135/85 mmHg

C. < 130/80 mmHg

D. < 150/90 mmHg

Correct Answer: C. < 130/80 mmHg

■ *Listen (English)*

■ *Listen (Hindi)*

Explanation: For patients with diabetes, the target blood pressure is set at < 130/80 mmHg. This target is aimed at reducing the risk of complications associated with diabetes, including cardiovascular disease and kidney damage. Condition Target Blood Pressure Recommended Medications General Hypertension < 135-140/85-90 mmHg Initial: Thiazide diuretic, CCB, ACEI, or ARB (non-black) ; Thiazide or CCB (black) Hypertension with Diabetic Nephropathy < 130/80 mmHg ACEI/ARB End-Stage Renal Disease (ESRD) < 130/80 mmHg CCB (e.g., Amlodipine) Alpha blocker like prazosin Chronic Kidney Disease (CKD) Grade I-III < 130/80 mmHg ACEI/ARB + Thiazide + CCB eGFR < 30 ml/min < 130/80 mmHg Metolazone is only thiazide that can be given below eGFR of 30 ml / min

References:

Harrison's Principles of Internal Medicine, 22nd Edition, Page 2145-2147.

↑ *Back to this question in Part A*

@Neet_pg_bot

Q10: Which of the following is incorrect regarding the image given? (Q850513)

A. Can help identify the white-coat effect in patients

B. Continuous readings for a full 24-hour period

C. Measures both awake and sleep averages

D. Used to investigate hypertension only

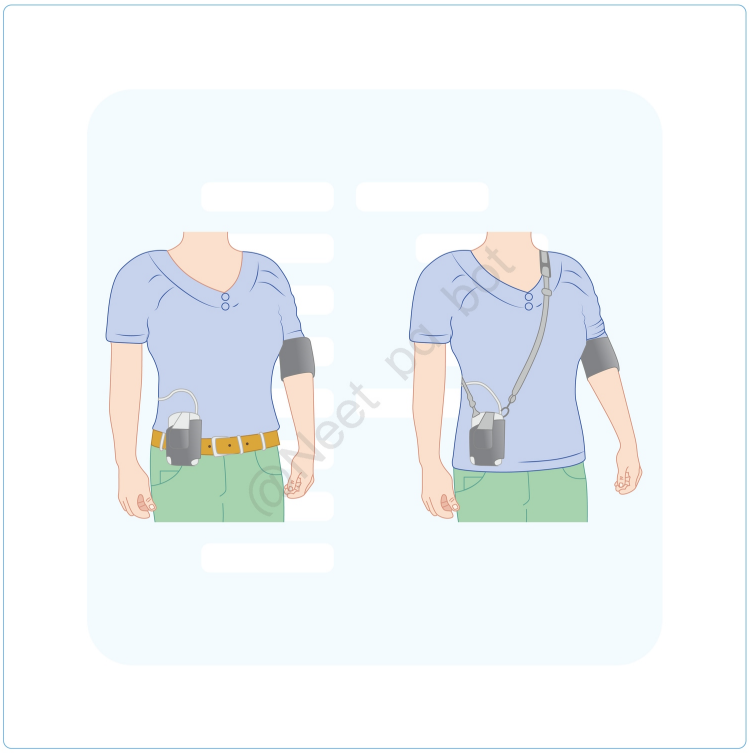

@Neet_pg_bot

Correct Answer: D. Used to investigate hypertension only

- *Listen (English)*
- *Listen (Hindi)*

Explanation: The image depicts Ambulatory BP Monitoring (ABPM). ABPM is used to investigate hypotensive episodes along with hypertension. These hypotensive episodes can occur due to autonomic dysfunction. Parameter Ambulatory BP Monitoring (ABPM) Home Blood Pressure Monitoring (HBPM) Device Type Oscillometric Oscillometric Operation Worn by patient, preprogrammed, fully automatic Self-administered by the patient Monitoring Duration 24 hours (Option B) 7 days (morning and evening) Mean Overall BP Present in report Average of 6 days if > 135/85 mmHg Mean Awake BP Present in report Average of readings during the day Mean Sleep BP Present in the report (Option C ruled out) Not typically calculated Clinical Applications White-coat hypertension (Option A ruled out) Confirm hypertension in children Resistant hypertension Labile hypertension Hypotensive episodes (Option D) Self-monitoring for hypertension management

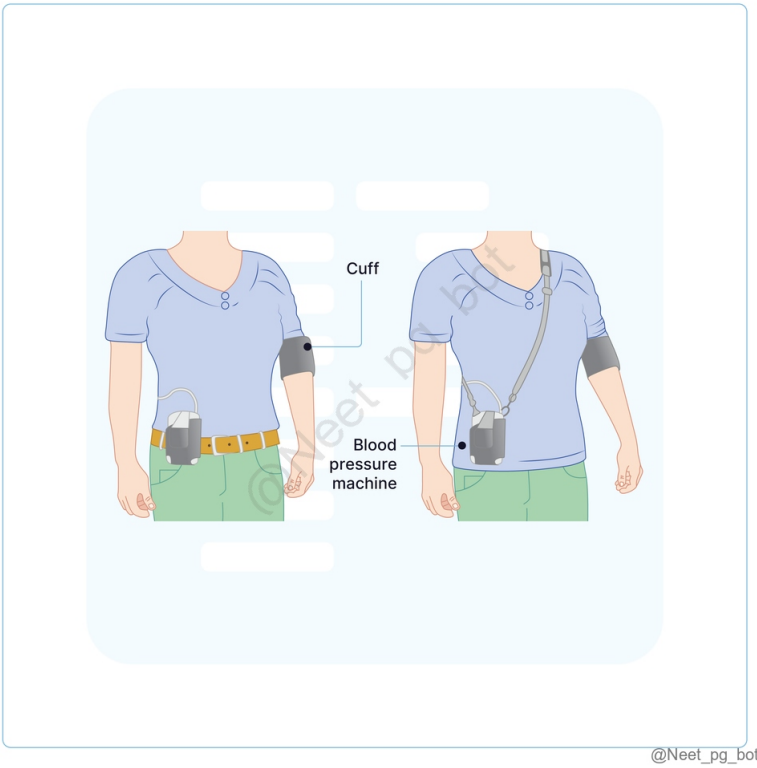

@Neet_pg_bot

References:

Harrison's Principles of Internal Medicine, 22nd Edition, Page 2135. Ambulatory Blood Pressure Monitoring (ABPM) as the reference standard for diagnosis of hypertension and assessment of vascular risk in adults - PubMed

↑ *Back to this question in Part A*

@Neet_pg_bot

• [01_Cardiology] 007 Chf Bbb Tachycardia Bradycardia And Heart Block

« Back to Folder Directory

[01_Cardiology] 007 Chf Bbb Tachycardia Bradycardia And Heart Block — Quick Jump

Q1 (p. 1226)	*Q2 (p. 1227)*	*Q3 (p. 1228)*	*Q4 (p. 1229)*	*Q5 (p. 1230)*	*Q6 (p. 1231)*
Q7 (p. 1232)	*Q8 (p. 1233)*	*Q9 (p. 1234)*	*Q10 (p. 1235)*	*Q11 (p. 1236)*	*Q12 (p. 1238)*
Q13 (p. 1239)	*Q14 (p. 1240)*	*Q15 (p. 1241)*	*Q16 (p. 1241)*	*Q17 (p. 1243)*	*Q18 (p. 1245)*

Q1: Which of the following statements is false about first-degree atrioventricular block? (Q850536)

A. Minor Jones criteria in Rheumatic fever

B. Serial prolongation of PR interval

C. Can be physiological

D. Consistent PR interval with no missed beats

Correct Answer: B. Serial prolongation of PR interval

■ *Listen (English)*

■ *Listen (Hindi)*

Explanation: n first-degree AV block , the PR interval is prolonged (>200 ms) but remains constant , and every P wave is followed by a QRS complex with no dropped beats. Aschoff nodules can involve the conduction system of the heart leading to PR prolongation and is a minor Jones criteria. It can be physiological due to high vagal tone in athletes.

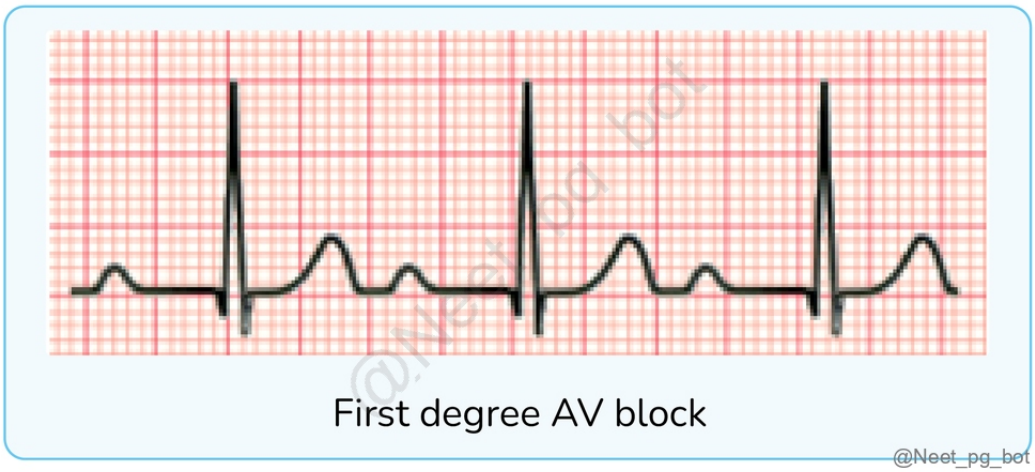

References:

Harrison's Principles of Internal Medicine, 22nd Edition, Page 1925.

↑ *Back to this question in Part A*

@Neet_pg_bot

Q2: A 65-year-old man treated with PCI for STEMI develops syncope and is found to have a 2:1 AV block with broad QRS on his ECG. Which of the following is the most likely mechanism behind his AV block, and how would atropine administration affect his condition? (Q850573)

A. The block is most likely in the AV node, and atropine will improve AV conduction.

B. The block is most likely in the His-Purkinje system, and atropine will improve AV conduction.

C. The block is most likely in the AV node, and atropine may increase the degree of AV block.

D. The block is most likely in the His-Purkinje system, and atropine may increase the degree of AV block.

Correct Answer: D. The block is most likely in the His-Purkinje system, and atropine may increase the degree of AV block.

■ *Listen (English)*

■ *Listen (Hindi)*

Explanation: 2:1 block is the differential diagnosis of Mobitz II and has lesion at the Bundle of his. The widened QRS complex is suggestive of a block in the His-Purkinje system rather than the AV node. Atropine works at AV node by reducing AV block and enhances conduction through the AV node But here the lesion is in His-Purkinje

system, so atropine has no effect or it may increase the block. Atropine will increase sinus firing rate causing increase in AV nodal conduction delay which will add to fixed conduction delay explaining the worsening of this block 2:1 Heart block: It is a condition where there is intermittent failure of conduction between the atrium and ventricle, resulting in every alternate atrial impulse being conducted to the ventricles. This means for every two P waves on an ECG, there is only one QRS complex. {{caption_text}}

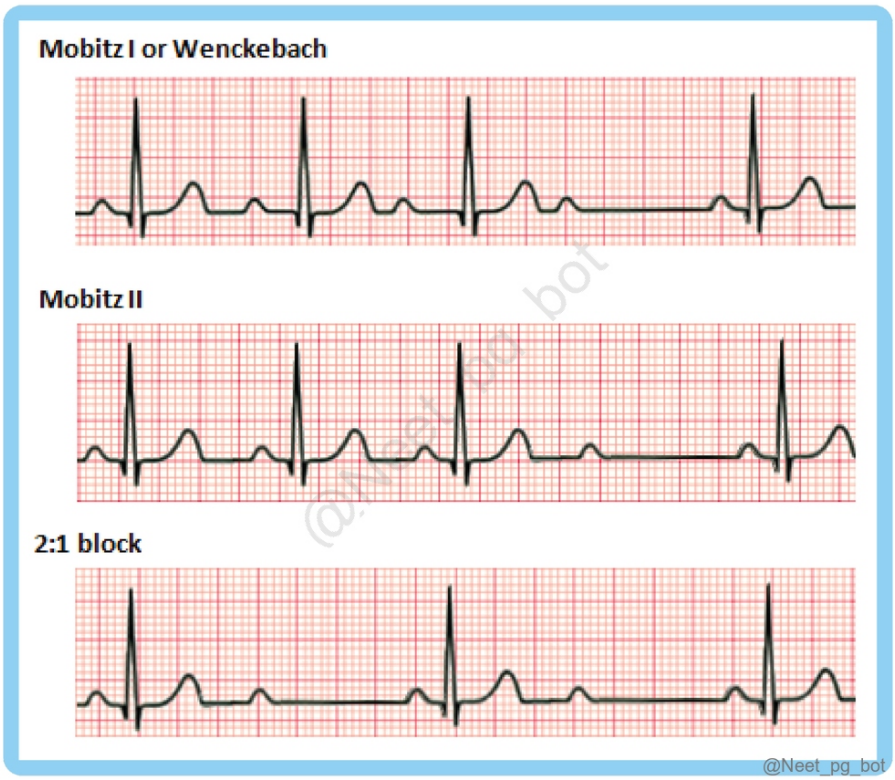

References:

Harrison's Principles of Internal Medicine, 22nd Edition, Page 1925.

↑ *Back to this question in Part A*

@Neet_pg_bot

Q3: Which among the following are included in the criteria for Metabolic syndrome 1) Waist circumference > 102 cm in men 2) Waist circumference > 88 cm in women 3) HDL > 50 mg/dL in men 4) BP 115/80 mm Hg 5) Fasting plasma glucose > 100 mg/dL 6) LDL > 200 mg/dL (Q850570)

A. 1, 2, 3, 4, 5

B. 1, 4, 5, 6

C. 1, 2, 5

D. 2, 4, 5, 6

Correct Answer: C. 1, 2, 5

■ *Listen (English)*

■ *Listen (Hindi)*

Explanation: LDL is not a part of the criteria. HDL > 50 will be protective rather. BP is normal. Only Waist circumference > 102 cms (men) & > 88 cms (women) and Fasting plasma glucose > 100 mg/dL among the given options are part of Metabolic syndrome (Syndrome-X) criteria. Metabolic syndrome/Syndrome-X criteria: 1) Waist circumference > 102 cm in Men > 88 cmin Women 2) HDL levels < 40 mg/dL in Men < 50 mg/dL in Women 3) Triglyceride levels > 150 mg/dL 4) BP (Blood Pressure) > 130/85 mmHg 5) Fasting plasma glucose > 100 mg/dL Extra mile Syndrome-Z: Syndrome-X +Obstructive Sleep Apnoea

References:

Harrison's Principles of Internal Medicine, 22nd Edition, Page 3253.

↑ *Back to this question in Part A*

@Neet_pg_bot

Q4: Drug causing maximum mortality reduction in a patient with HFrEF? (Q850564)

A. Ramipril

B. Carvedilol

C. Spironolactone

D. Canagliflozin

Correct Answer: A. Ramipril

■ *Listen (English)*

■ *Listen (Hindi)*

Explanation: Ramipril (an ACE inhibitor) provides the greatest mortality reduction in HFrEF . ACE inhibitors are first-line, foundational therapy and have been proven to: Reduce all-cause mortality Reduce HF hospitalization Slow disease progression Improve symptoms Drugs causing mortality reduction in Heart Failure β-blockers (Carvedilol / Metoprolol succinate / Bisoprolol) Aldosterone antagonists (Spironolactone) ACE inhibitors (Ramipril) SGLT2 inhibitors (e.g., Canagliflozin)

References:

Harrison's Principles of Internal Medicine, 22nd Edition, Page 1994.

↑ *Back to this question in Part A*

@Neet_pg_bot

Q5: A patient presents with sudden onset breathlessness. On arrival his vitals were, PR- 130 bpm, BP- 180/110 mmHg and spO 2 - 82% in room air. X-ray done is as shown below.What is the most appropriate next step in managing this patient? (Q850562)

A. Furosemide and Esmolol

B. Furosemide and NTG

C. Furosemide and Diltizaem

D. Furosemide and Digoxin

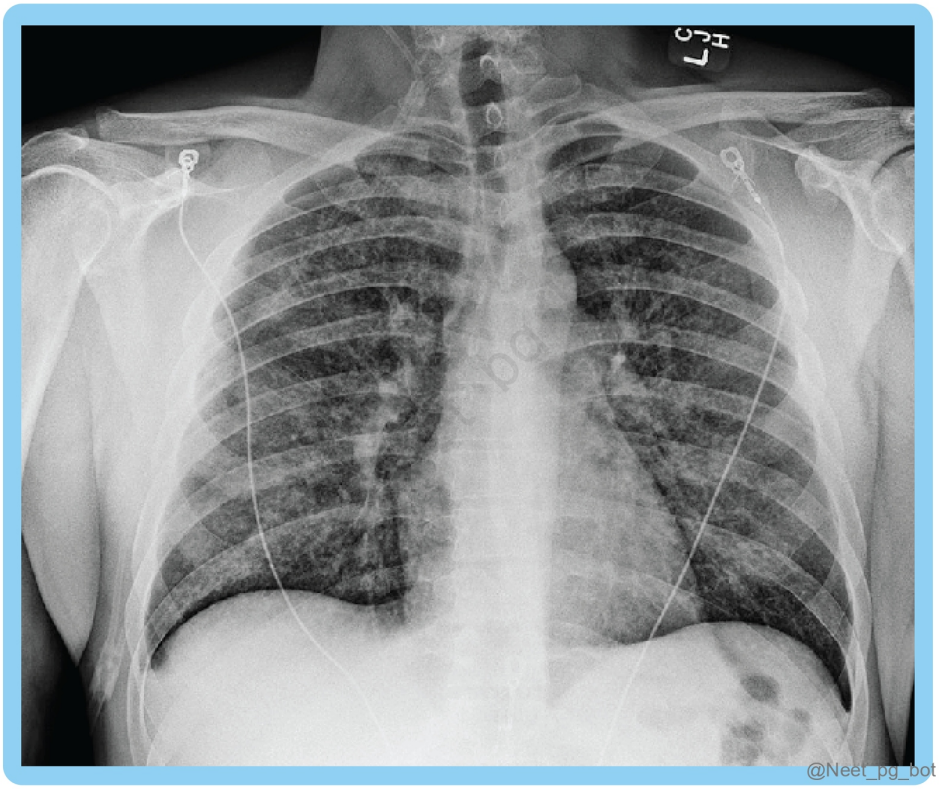

Correct Answer: B. Furosemide and NTG

■ *Listen (English)*

■ *Listen (Hindi)*

Explanation: X-ray shows perihilar infiltrates with increased interstitial markings due to an increase in hydrostatic pressure in vessels. Due to a hypertensive crisis, this patient is developing acute pulmonary edema due to LV failure . Prompt administration of Furosemide will reduce pulmonary edema. NTG is the drug of choice for Hypertensive crisis in LVF as it lowers BP and also reduces pulmonary edema. Beta blockers (Option A) are contraindicated in Acute Heart failure. Negative inotropic effects of diltiazem (Option C) will worsen this patient. Digoxin (Option D) is not used nowadays due to safer alternatives.

References:

Harrison's Principles of Internal Medicine, 22nd Edition, Page 1990.

↑ *Back to this question in Part A*

@Neet_pg_bot

Q6: A 75-year-old man is a known case of triple vessel disease, presented with fatigue. Echocardiography done showed global reduction in contractility and reduced ejection fraction. What is the most likely electrolyte disturbance seen in this patient? (Q850555)

A. Hyponatremia and Hypokalemia

B. Hypernatremia and Hyperkalemia

C. Hyponatremia and Hyperkalemia

D. Hypernatremia and Hypokalemia

Correct Answer: A. Hyponatremia and Hypokalemia

■ *Listen (English)*

■ *Listen (Hindi)*

Explanation: The patient has developed ischemic cardiomyopathy due to triple vessel disease and going into biventricular heart failure (global hypokinesia on Echocardiography) Due to RAAS activation potassium will be low . Another reason can be the use of diuretics in these patients Due to low BP, increased release of ADH will cause dilutional hyponatremia . Though RAAS is activated , excess of water as compared to sodium will worsen this hyponatremia. CHF has Hypervolemic Hyponatremia.

References:

Harrison's Principles of Internal Medicine, 22nd Edition, Page 1984.

↑ *Back to this question in Part A*

@Neet_pg_bot

Q7: A 50-year-old male comes with complaints of shortness of breath that worsens upon lying down for the past 1 week. On examination, pulse-130 bpm, BP-150/90 mmHg, neck veins are distended, S3+ on cardiac auscultation. He had developed MI last year and was treated. CXR is shown below. Which among the following is not part of the major Framingham's criteria? (Q850549)

A. Dyspnoea worse upon lying down

B. Neck vein distention

C. HR-130 bpm

D. S3

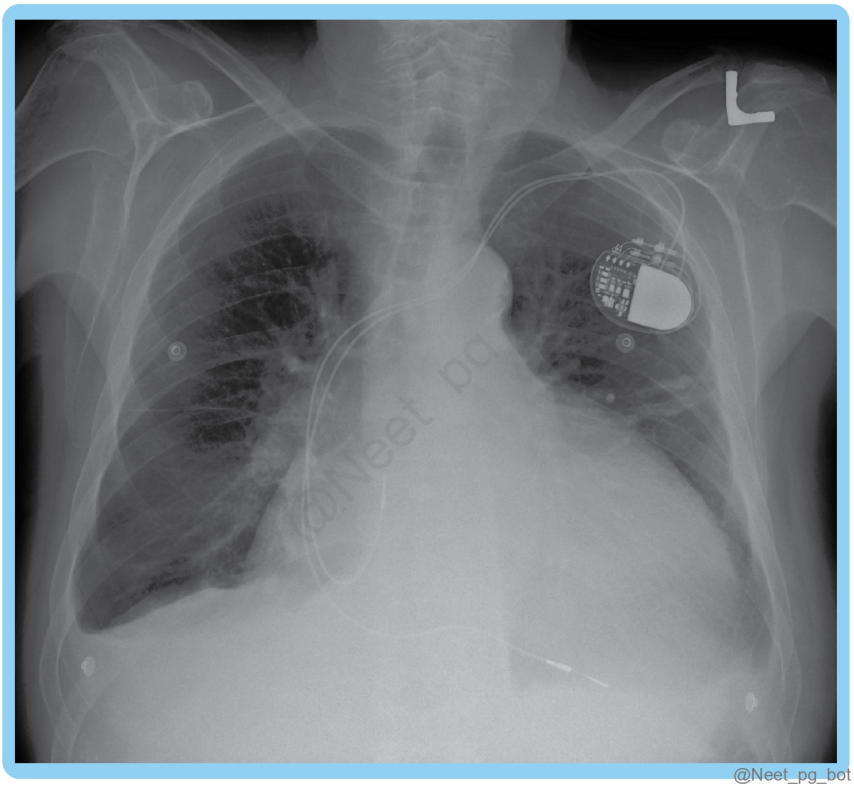

Correct Answer: C. HR-130 bpm

■ *Listen (English)*

■ *Listen (Hindi)*

Explanation: Tachycardia can occur in even anxiety or panic attacks and is a minor framingham criteria . S3, Orthopnea and distended neck veins are major diagnostic criteria for heart failure. CXR shows a pacemaker with two leads. The patient could have developed a heart block after his last cardiac event. Framingham diagnostic criteria for Heart Failure: Major criteria Minor criteria Acute pulmonary edema (crepitations/rales) Cardiomegaly

PND/Orthopnoea Elevated JVP, positive abdominojugular reflex S3 gallop rhythm Weight loss of > 4.5 kg in last 5 days Ankle edema (pitting pedal edema) Dyspnoea on exertion Hepatomegaly Nocturnal cough Pleural effusion Tachycardia (HR>120 bpm)

References:

https://pmc.ncbi.nlm.nih.gov/articles/PMC3756692/

↑ *Back to this question in Part A*

@Neet_pg_bot

Q8: A 68-year-old male is presented with sudden loss of consciousness and collapses. ECG on arrival at ER is shown below and significant perioral pallor was noted while tracing was being done. What is the diagnosis? (Q850544)

A. Third-degree atrioventricular block

B. Mobitz II heart block

C. Mobitz I block

D. First degree heart block



Correct Answer: A. Third-degree atrioventricular block

■ *Listen (English)*

■ *Listen (Hindi)*

Explanation: The ECG shows complete AV dissociation , where P waves and QRS complexes occur independently at their own intrinsic rates. This results in profound bradycardia , reduced cardiac output, and can cause sudden loss of consciousness and perioral pallor due to poor perfusion. This presentation is classic for Third-degree Atrioventricular Block. Mobitz II Block (Option B): Dropped QRS complexes without PR prolongation, but not complete dissociation . Mobitz I (Wenckebach) (Option C): Progressive PR lengthening with a dropped beat; usually not severe enough to cause collapse. First-degree Block (Option D): Prolonged PR interval only, usually asymptomatic.

References:

Harrison’s Principles of Internal Medicine, 22nd Edition, Page 1925, 1926, 1930.

↑ *Back to this question in Part A*

@Neet_pg_bot

Q9: Identify the type of heart block from the ECG given below. (Q850539)

A. First-degree AV block

B. 2nd degree heart block, intra nodal conduction delay

C. 2nd degree heart block, Infra nodal conduction delay

D. Third-degree atrioventricular block



@Neet_pg_bot

Correct Answer: B. 2nd degree heart block, intra nodal conduction delay

■ *Listen (English)*

■ *Listen (Hindi)*

Explanation: The ECG shows progressive prolongation of the PR interval until a dropped QRS complex occurs, characteristic of Mobitz Type I second-degree AV block (Wenckebach phenomenon). This reflects an intranodal conduction delay in the AV node. Second-degree heart block Dropped beats occur because some impulses from the atria fail to be transmitted to the ventricles. Types Mobitz Type I (Wenckebach) Mobitz Type II Description Progressive lengthening of PR intervals until a dropped beat occurs. {{caption_text}} PR interval remains constant until a dropped beat occurs {{caption_text}} Clinical Features Often physiological; can occur in young athletes. May not cause symptoms. Caused by His–Purkinje system disease. Higher risk of asystole. Management Typically does not require treatment. Monitor for changes; consider underlying heart disease. May require treatment if symptomatic. Consider temporary pacing. Monitor closely due to the risk of progression.



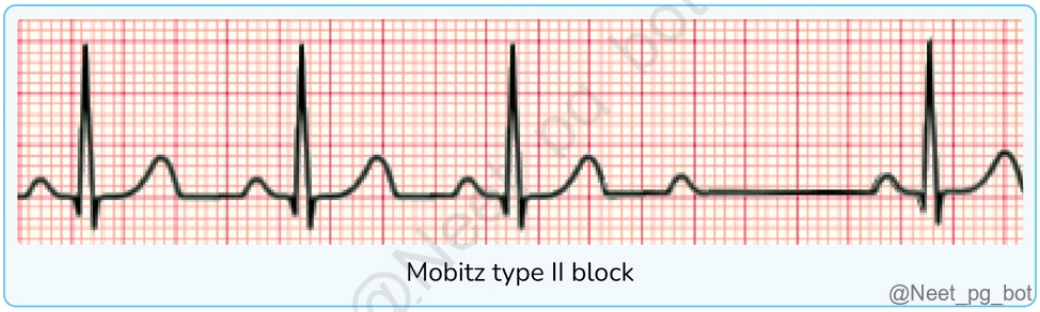

References:

Harrison's Principles of Internal Medicine, 22nd Edition, Page 1925.

↑ *Back to this question in Part A*

@Neet_pg_bot

Q10: A 68-year-old smoker presents with breathing trouble and sudden onset palpitations. The ECG is given below and has an irregular rhythm with an average heart rate of 150 beats per minute. What is the most likely diagnosis based on the ECG findings? (Q850516)

A. Atrial Fibrillation

B. Multifocal Atrial Tachycardia

C. Atrial Flutter

D. Sinus Tachycardia

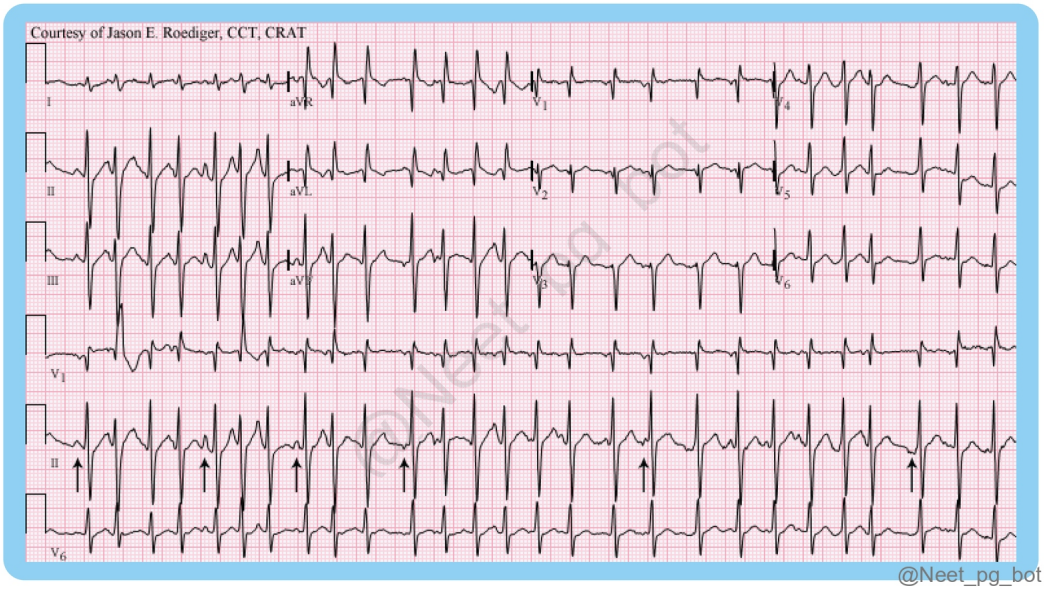

Correct Answer: B. Multifocal Atrial Tachycardia

■ *Listen (English)*

■ *Listen (Hindi)*

Explanation: ECG Shows variable RR interval with P waves that rules out atrial fibrillation. On close observation P waves (vertical arrows) are having variable morphology. The diagnosis is MAT. Smokers develop COPD and resultant hypoxia is the trigger for development of this arrhythmia. Atrial fibrillation (Option A): No distinct P waves; baseline is fibrillatory. Atrial flutter (Option C) has saw-tooth waves. Sinus tachycardia (Option D) has reduced RR interval with T wave and P wave visible independently.

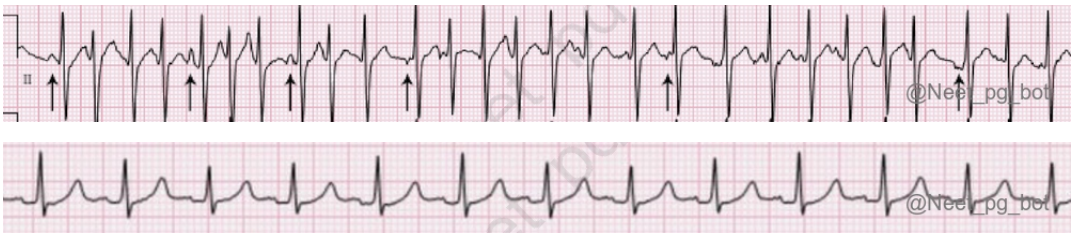

References:

Harrison's Principles of Internal Medicine, 22nd Edition, Page 1946.

↑ *Back to this question in Part A*

@Neet_pg_bot

Q11: Which of the following statements on transvenous pacing is wrong? (Q850532)

A. Central venous access is needed

B. Intracardiac lead placement is done

C. Permanent method of pacing

D. Required in inferior wall MI

Correct Answer: C. Permanent method of pacing

■ *Listen (English)*

■ *Listen (Hindi)*

Explanation: Transvenous pacing is a temporary pacing method for symptomatic bradycardia. Inferior wall MI leads to vagus nerve irritation and severe bradycardia that may not respond to atropine. (Option D) Aspect Transcutaneous Pacing Transvenous Pacing Purpose Temporary, fast initiation for symptomatic bradyarrhythmias or cardiac arrest. Longer-term temporary pacing for evaluation of permanent pacemaker need. Initiation Time Fastest method, used in emergencies (e.g., bradycardia, asystole). Requires more time due to the need for central venous access. (Option A) Electrode Placement Anterior pad: cardiac apex or lead V3 position. Posterior pad: inferior to scapula or between scapula and spine. Intracardiac lead placement through a central vein (e.g., femoral, subclavian). (Option B)

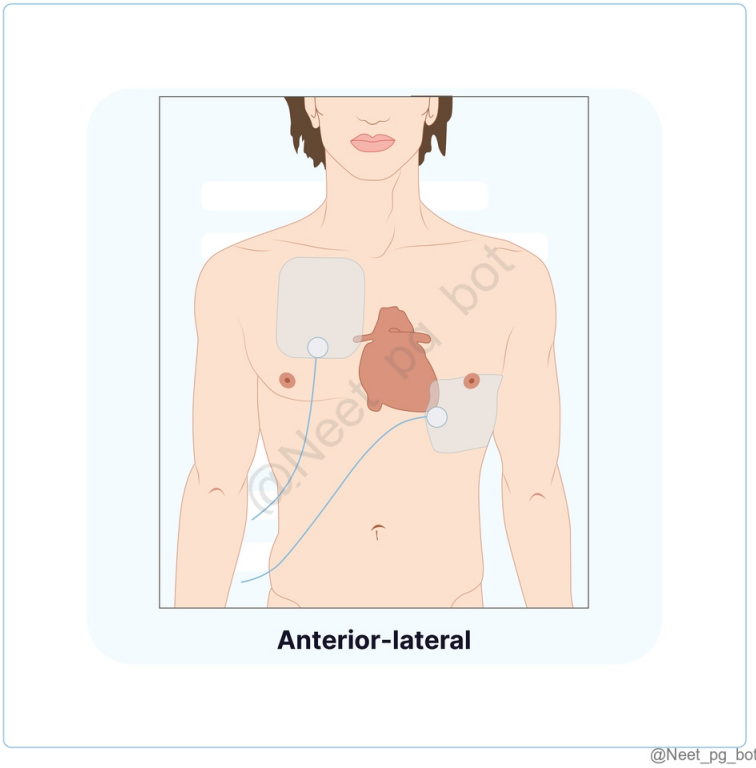

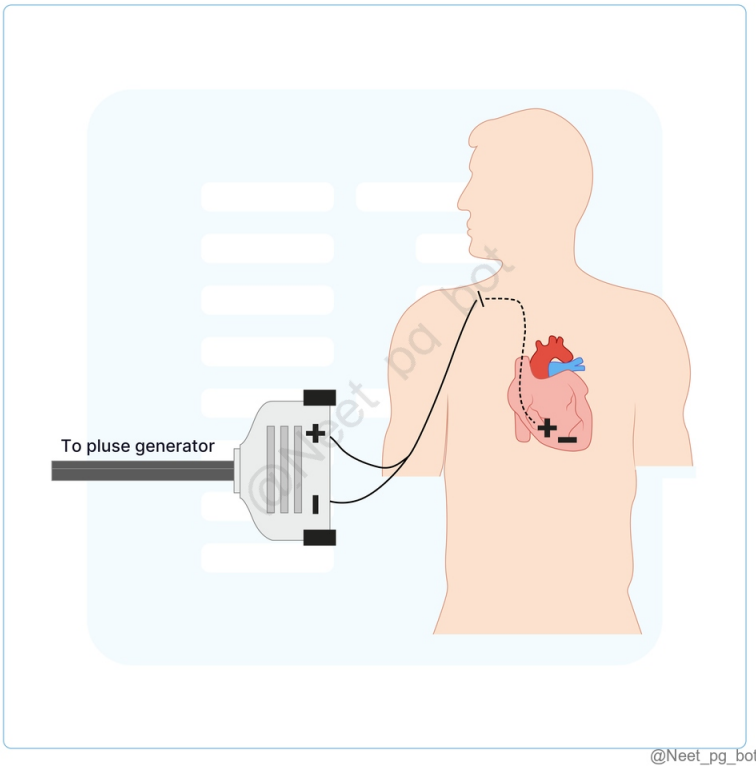

@Neet_pg_bot

References:

Harrison's Principles of Internal Medicine, 22nd Edition, Page 1929.

↑ *Back to this question in Part A*

@Neet_pg_bot

Q12: A 72-year-old male presents with an inferior wall STEMI. He starts developing altered mental status and heart rate is 38 bpm, blood pressure 80/50 mmHg. Which of the following will be used to manage his bradycadia? (Q850530)

A. IV atropine 1 mg every 3-5 minutes

B. IV atropine 2 mg every 3-5 minutes

C. IV atropine 0.5 mg every 3-5 minutes

D. IV atropine 0.6 mg every 3-5 minutes

Correct Answer: A. IV atropine 1 mg every 3-5 minutes

■ *Listen (English)*

■ *Listen (Hindi)*

Explanation: Altered mental status implies the patient has hemodynamically unstable bradycardia and the treatment is IV atropine 1 mg every 3-5 minutes. In older guidelines the dose was 0.5 mg for a maximum of 6 doses and now it is 1 mg per dose to maximum of 3 doses. The total maximum dose of 3 mg remains the same.

References:

Harrison's Principles of Internal Medicine, 22nd Edition, Page 2124, 2125.

↑ *Back to this question in Part A*

@Neet_pg_bot

Q13: A 38-year-old man with a history of fatigue and daily headaches is found to have a blood pressure 150/100 mmHg on multiple occasions. His chest X-ray shows cardiomegaly and echocardiography shows reduced mitral inflow with concentric hypertrophy of heart. Which of the following is correct about this patient? (Q850529)

A. Systolic malfunction of left ventricle

B. Mitral stenosis

C. Diastolic dysfunction of Left ventricle

D. Mitral regurgitation

Correct Answer: C. Diastolic dysfunction of Left ventricle

■ *Listen (English)*

■ *Listen (Hindi)*

Explanation: The key words in question are reduced mitral inflow and concentric hypertrophy of heart that indicates diastolic malfunction of LV due to hypertension of long standing duration. The increased LV end diastolic pressure explains why mitral inflow is reduced. Mitral stenosis (Option B) is ruled out as it does not have hypertrophy of LV and neither has hypertension. It causes left atria dilation. Mitral regurgitation (Option D) will cause eccentric hypertrophy. Wall thickness Chamber size Causes Concentric hypertrophy increased Normal to reduced Hypertension Eccentric hypertrophy Normal Dilated Mitral regurgitation Aortic regurgitation

References:

Harrison's Principles of Internal Medicine, 22nd Edition, Page 1882, 1978.

↑ *Back to this question in Part A*

@Neet_pg_bot

Q14: You are performing an annual medical check up of a 48-year-old man corporate executive. What is the most likely diagnosis based on the ECG findings? {{caption_text}} (Q850526)

A. Brugada Syndrome

B. Ventricular Tachycardia

C. Left Bundle Branch Block (LBBB)

D. Right Bundle Branch Block (RBBB)

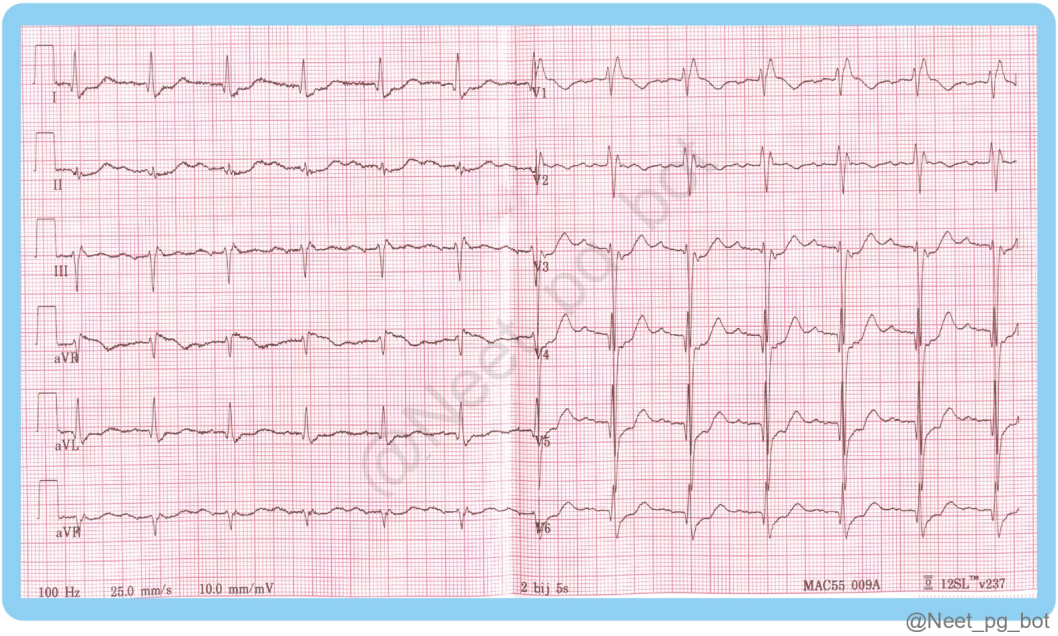

@Neet_pg_bot

Correct Answer: D. Right Bundle Branch Block (RBBB)

■ *Listen (English)*

■ *Listen (Hindi)*

Explanation: The patient is asymptomatic and ECG shows rsR' pattern (rabbit ears) in lead V1, a wide QRS (>120 ms), and a broad S wave in leads I and V6. These are classic features for RBBB. Brugada (Option A) is ruled out as it has Coved or saddle back ST segment elevation. VT (Option B) is ruled as the heart rate is normal. LBBB (Option C) occurs commonly after MI has deep S is lead V1 and notched R showing rabbit ear pattern in V5, V6.

References:

Harrison's Principles of Internal Medicine, 22nd Edition, Page 1871, 1872.

↑ *Back to this question in Part A*

@Neet_pg_bot

Q15: A 60 year old man presents with central chest pain and breathing difficulty for the last 6 hours. He had tested positive for RT-PCR SARS COV-2 yesterday. Auscultation shows bilateral basal crepitations. ECG shows non-specific ST segment changes. Both NT pro-BNP levels and Troponin I levels are elevated. In cath lab coronary angiography is normal. Diagnosis is? (Q850524)

A. Myocarditis

B. Anterior wall Myocardial infarction

C. Broken heart syndrome

D. Acute pericarditis

Correct Answer: A. Myocarditis

■ *Listen (English)*

■ *Listen (Hindi)*

Explanation: Presence of non specific ST segment changes with elevated NT-ProBNP and troponin I indicates myocardial damage by COVID 19. Myocarditis is causing chest pain and features of pulmonary edema. Anterior wall Myocardial infarction (Option B): Normal coronary angiography that rules out MI. Broken heart syndrome (Option C) requires intense emotional trauma and catecholamine excess. Acute pericarditis (Option D) is ruled out as it has global ST-segment elevation with concavity upwards.

References:

Harrison's Principles of Internal Medicine, 22nd Edition, Page 2011, 2012.

↑ *Back to this question in Part A*

@Neet_pg_bot

Q16: A 65-year-old diabetic male develops MI and is taken up for thrombolysis in the district hospital. ECG shows which of the following? (Q850523)

A. Ventricular tachycardia

B. Premature Ventricular Contractions (PVCs)

C. Right Bundle Branch Block (RBBB)

D. Left Bundle Branch Block (LBBB)

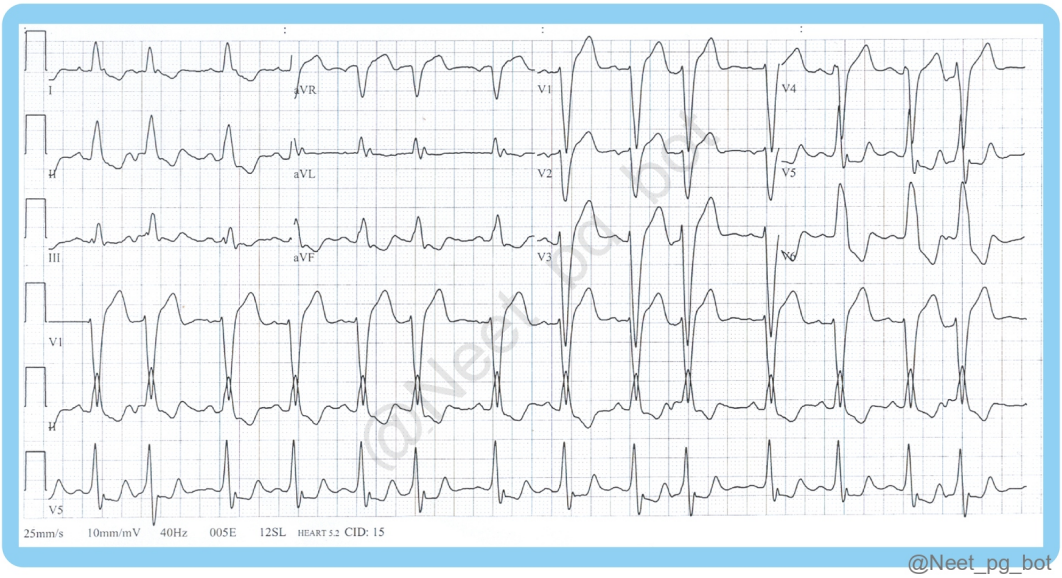

Correct Answer: D. Left Bundle Branch Block (LBBB)

■ *Listen (English)*

■ *Listen (Hindi)*

Explanation: Post MI the patient has developed LBBB . ECG shows a widened QRS complex (>120 ms), a broad and notched R wave in leads I, aVL, V5, and V6 (lateral leads), and a deep S wave in V1 and V2. The lack of Q waves in the lateral leads is also typical. In the context of acute MI, a new-onset LBBB is considered equivalent to STEMI and is an indication for urgent reperfusion (thrombolysis or PCI). This matches the description given: diabetic patient with MI undergoing thrombolysis → ECG showing LBBB. Clinical Significance in Acute MI In the context of an acute myocardial infarction (MI), a newly developed LBBB is a critical finding because: It is often associated with a large MI, as the block is located high up in the conducting system. It can obscure or mimic the typical ST-segment elevation seen in an acute STEMI (ST-Elevation Myocardial Infarction), making diagnosis challenging. When an LBBB is present, the diagnosis of MI is often made using the Sgarbossa criteria or the modified Smith criteria (also known as the modified Sgarbossa criteria). Therefore, an ECG of a patient who develops an LBBB will show the features of LBBB. {{caption_text}} Ventricular tachycardia (Option A): Would show rapid wide-complex tachycardia without organized P waves. Not consistent with the described morphology of lateral R-wave notching. PVCs (Option B): Premature, wide, bizarre QRS complexes occurring early, isolated events, not a sustained pattern across multiple leads. RBBB (Option C): Shows rsR' in V1 ("M-shaped"), and wide S waves in lateral leads, not the broad notched R waves in V5-V6 seen here.

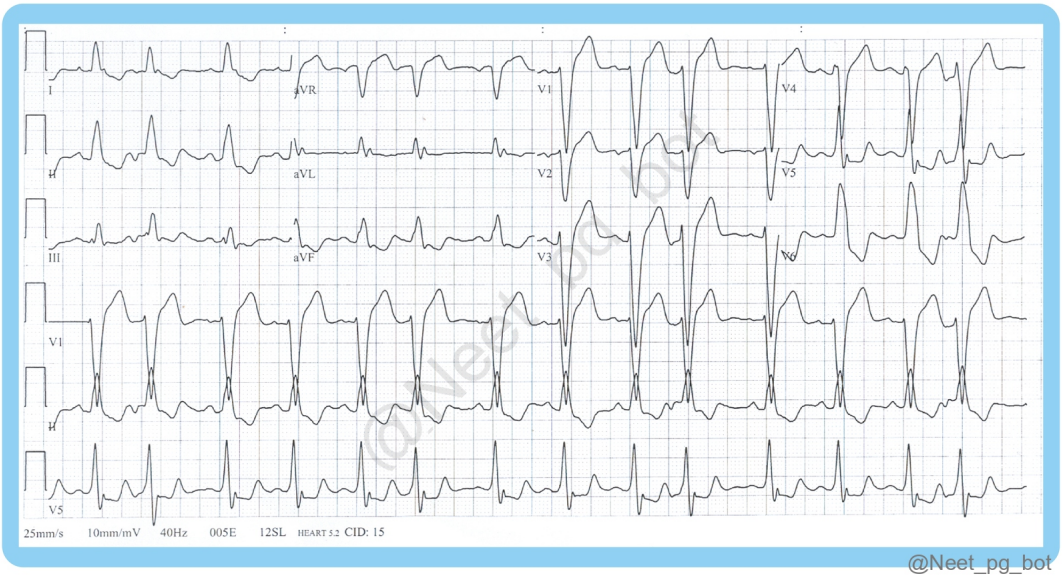

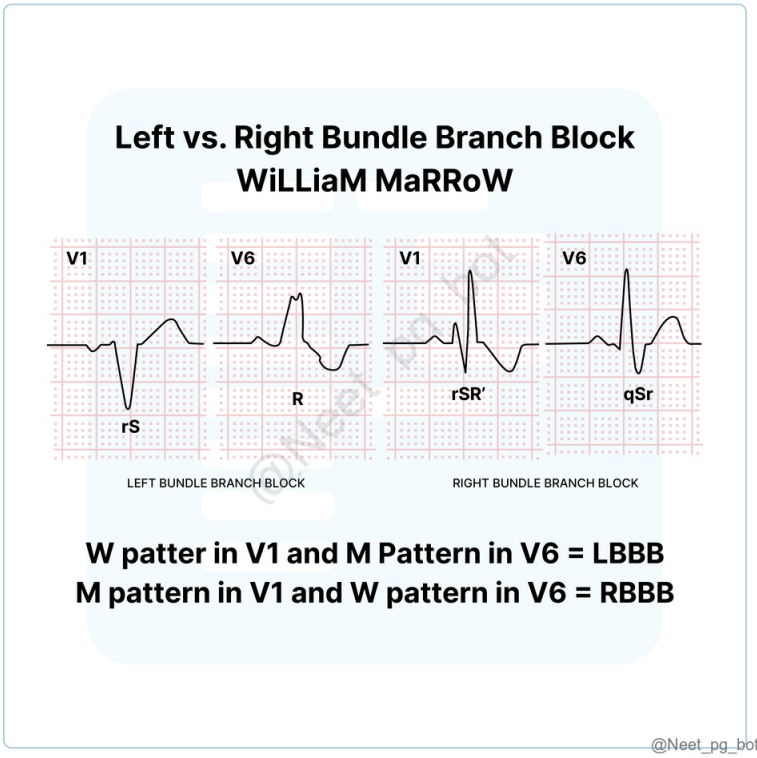

References:

Harrison's Principles of Internal Medicine, 22nd Edition, Page 1871, 1872.

↑ *Back to this question in Part A*

@Neet_pg_bot

Q17: Calculate the heart rate of the ECG shown below (Q850522)

A. 60 beats per minute

B. 75 beats per minute

C. 100 beats per minute

D. 50 beats per minute



Correct Answer: A. 60 beats per minute

■ *Listen (English)*

■ *Listen (Hindi)*

Explanation: There are 5 large boxes separating peaks of R waves. Heart Rate = 300/Number of Large Boxes between R-R interval or 1500/ Number of small boxes between R-R interval Heart rate = 300/5=60 beats per minute

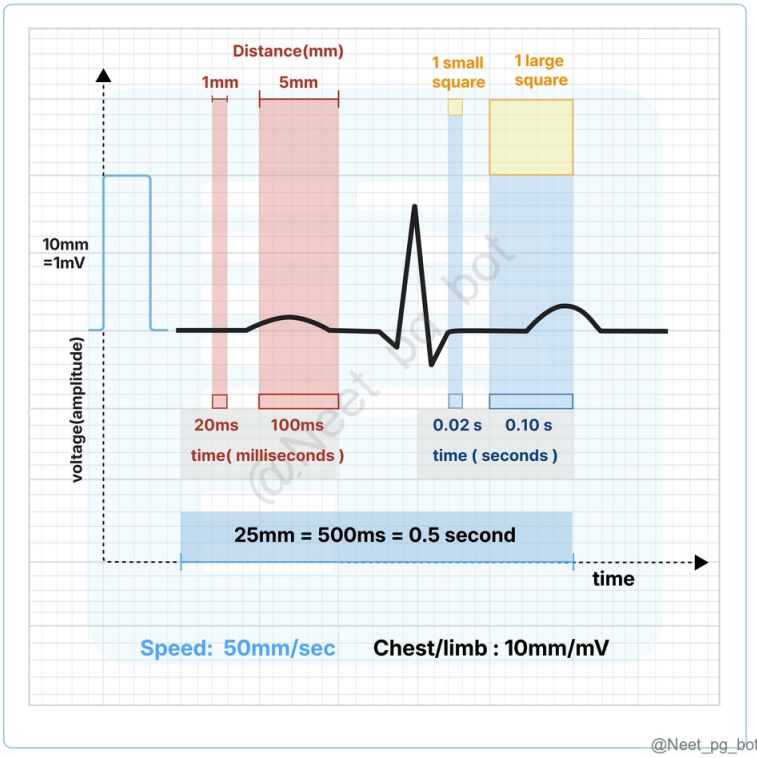

References:

Harrison's Principles of Internal Medicine, 22nd Edition, Page 1868

↑ *Back to this question in Part A*

@Neet_pg_bot

Q18: A 65-year-old smoker with COPD presents to the ER with palpitations and shortness of breath. His ECG shows an irregular rhythm with at least three distinct P-wave morphologies and a heart rate of 120 beats per minute. BP 100/60 mm Hg. Which of the following is the most appropriate management to prevent recurrence of this rythm disorder (Q850520)

A. Electrical cardioversion

B. Intravenous Diltiazem

C. LTOT with LAMA and LABA

D. IV amiodarone

Correct Answer: C. LTOT with LAMA and LABA

■ *Listen (English)*

■ *Listen (Hindi)*

Explanation: Multifocal atrial tachycardia is often triggered by acute illnesses and hypoxia in patients with COPD. Long term oxygen therapy using oxygen concentrator LAMA and LABA will address hypoxia that is the trigger for development of this dysrhythmia.

References:

Harrison's Principles of Internal Medicine, 22nd Edition, Page 1946, 2256.

↑ *Back to this question in Part A*

@Neet_pg_bot

• [01_Cardiology] 008 Diseases Of The Pericardium And Cardiomyopathies

« Back to Folder Directory

[01_Cardiology] 008 Diseases Of The Pericardium And Cardiomyopathies — Quick Jump

Q1 (p. 1246)	*Q2 (p. 1247)*	*Q3 (p. 1247)*	*Q4 (p. 1248)*	*Q5 (p. 1249)*	*Q6 (p. 1251)*
Q7 (p. 1253)	*Q8 (p. 1254)*	*Q9 (p. 1256)*	*Q10 (p. 1259)*	*Q11 (p. 1259)*	*Q12 (p. 1260)*
Q13 (p. 1261)	*Q14 (p. 1263)*	*Q15 (p. 1265)*	*Q16 (p. 1266)*	*Q17 (p. 1268)*	*Q18 (p. 1269)*
Q19 (p. 1271)	*Q20 (p. 1271)*	*Q21 (p. 1273)*	*Q22 (p. 1273)*	*Q23 (p. 1275)*	

Q1: A 25 year old male presents with exertional dyspnea and chest pain while playing table tennis. Echocardiography shows systolic anterior movement of mitral valve with LV free wall thickness of 30 mm. He informs you about the sudden death of his elder brother while dancing at a marriage party. Which of the following is the best intervention for management of this patient? (Q850596)

A. Mitral valvotomy

B. Implantable cardioverter defibrillator

C. Propranolol with Disopyramide

D. Surgical myomectomy

Correct Answer: B. Implantable cardioverter defibrillator

■ *Listen (English)*

■ *Listen (Hindi)*

Explanation: The diagnosis based on clinical and echo findings is hypertrophic cardiomyopathy. In lieu of significant ventricular hypertrophy of 30 mm thickness and SCD in sibling, implantable cardioverter defibrillator is best intervention in this patient. I mplantable Cardioverter-Defibrillator indications in HCM Unexplained syncope Abnormal blood pressure response during exercise Significant ventricular hypertrophy (>30mm thickness) Family history of SCD Multiple episodes of non-sustained ventricular tachycardia (NSVT)

References:

Harrison's Principles of Internal Medicine, 22nd Edition, Page 2008.

↑ *Back to this question in Part A*

@Neet_pg_bot

Q2: A 55 year old woman presents with acute chest pain and difficulty breathing after learning of the death of her daughter in an air crash. Her ECG shows ST-segment elevation in lead I, aVL, V2-V4. Cardiac biomarkers are elevated. Bed side echocardiography reveals ballooning of the left ventricular apex. What is the most likely diagnosis? (Q850637)

A. Myocardial Infarction

B. Takotsubo Cardiomyopathy

C. Aortic Dissection

D. Brudaga syndrome

Correct Answer: B. Takotsubo Cardiomyopathy

■ *Listen (English)*

■ *Listen (Hindi)*

Explanation: In the setting of intense emotional trauma causing catecholamine excess and Echo findings of LV apex ballooning , the diagnosis is Takotsubo cardiomyopathy. Myocardial Infarction (Option A) is the first differential diagnosis of this presentation in case the echo findings were not given. Aortic dissection (Option C) will cause unequal BP between both arms and coronary artery dissection. Brugada syndrome (Option D) occurs in young males and causes Sudden nocturnal death.

References:

Harrison's Principles of Internal Medicine, 22nd Edition, Page 2019.

↑ *Back to this question in Part A*

@Neet_pg_bot

Q3: A 55-year-old patient presents with sharp chest pain, fever, and inspiratory catch on taking deep breath 3 weeks after undergoing coronary artery bypass surgery. Which of the following is the most likely underlying mechanism? (Q850635)

A. Constrictive pericarditis

B. Post cardiac injury syndrome

C. Electro-mechanical dissociation

D. Autoimmune myocarditis

Correct Answer: B. Post cardiac injury syndrome

■ *Listen (English)*

■ *Listen (Hindi)*

Explanation: This patient’s presentation is consistent with postcardiac injury syndrome, often resulting from an autoimmune response to antigens from the injured myocardium following surgery. The resultant autoimmune pericarditis explains chest pain and pleuritis explains the inspiratory catch in breath. Causes can be Post-MI (Dressler syndrome) Post Surgery (open heart surgery, CABG, Valve replacement) Post trauma (pacemaker lead placement , blunt trauma to chest) Constrictive pericarditis (Option A) has Kussmaul sign, pericardial shock and visible calcification around the heart on CT chest. Electro-mechanical dissociation (Option C) will cause the heart to burst after transmural MI and causes death. Autoimmune myocarditis (Option D) is seen with SLE or vasculitis.

References:

Harrison's Principles of Internal Medicine, 22nd Edition, Page 2082.

↑ *Back to this question in Part A*

@Neet_pg_bot

Q4: A post-mortem study reveals deposits between the pericardial layers with a “bread and butter” appearance. Which of the following is most consistent with this form of pericarditis? (Q850633)

A. Hemorrhagic pericarditis

B. Purulent pericarditis

C. Fibrinous pericarditis

D. Caseous pericarditis

Correct Answer: C. Fibrinous pericarditis

■ *Listen (English)*

■ *Listen (Hindi)*

Explanation: The “bread and butter” appearance is characteristic of fibrinous pericarditis, marked by fibrin and leukocytic exudate on the pericardium. {{caption_text}} Bread and butter appearance seen in fibrinous pericarditis Types of Pericarditis Fibrinous pericarditis Often called "bread and butter" pericarditis due to fibrin deposits creating a rough appearance on the pericardium. Caused by conditions like myocardial infarction, infections, trauma, or systemic diseases. Purulent pericarditis (Option C) Caused by bacterial infections, leading to a

pus-filled pericardial sac. Haemorrhagic pericarditis (Option A) Involves blood within the pericardium, often due to trauma, malignancy (lung cancer) or uremia. Caseous pericarditis (Option D) Rare and typically associated with tuberculosis.



References:

Harrison's Principles of Internal Medicine, 22nd Edition, Page 2079
https://www.ncbi.nlm.nih.gov/books/NBK538254/

↑ *Back to this question in Part A*

@Neet_pg_bot

Q5: A 50 year old alcoholic presents with worsening fatigue, shortness of breath, and leg swelling. The Chest X-ray and Cardiac MRI of the patient are given below. Which of the following statements regarding the treatment of her condition is false? (Q850624)

A. Low dose diuretics should be administered to maintain an euvolemic state.

B. ACE inhibitors are recommended for heart failure with reduced ejection fraction.

C. Beta-blockers should not be used in patients with chronic heart failure.

D. Cardiac resynchronization will reduce symptoms

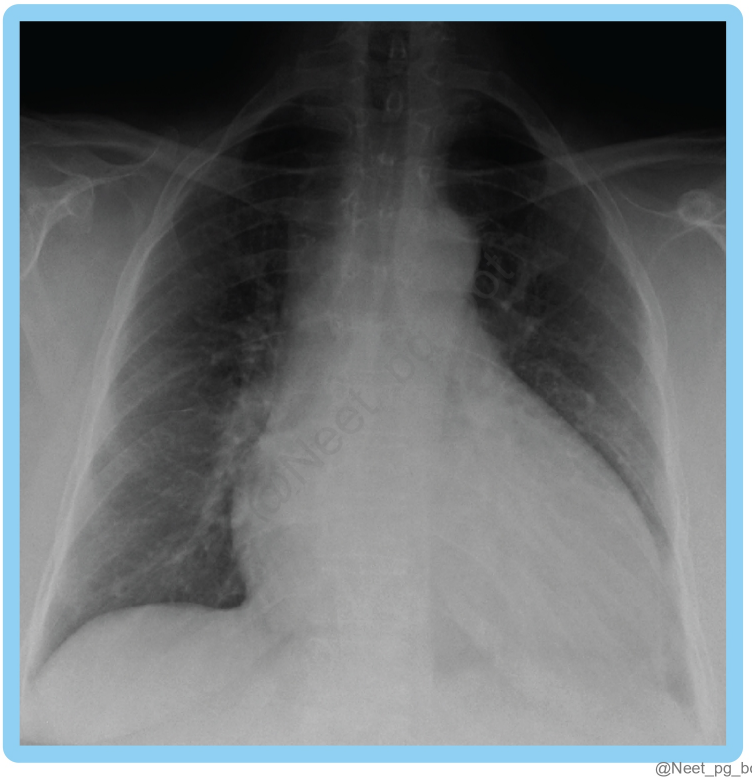

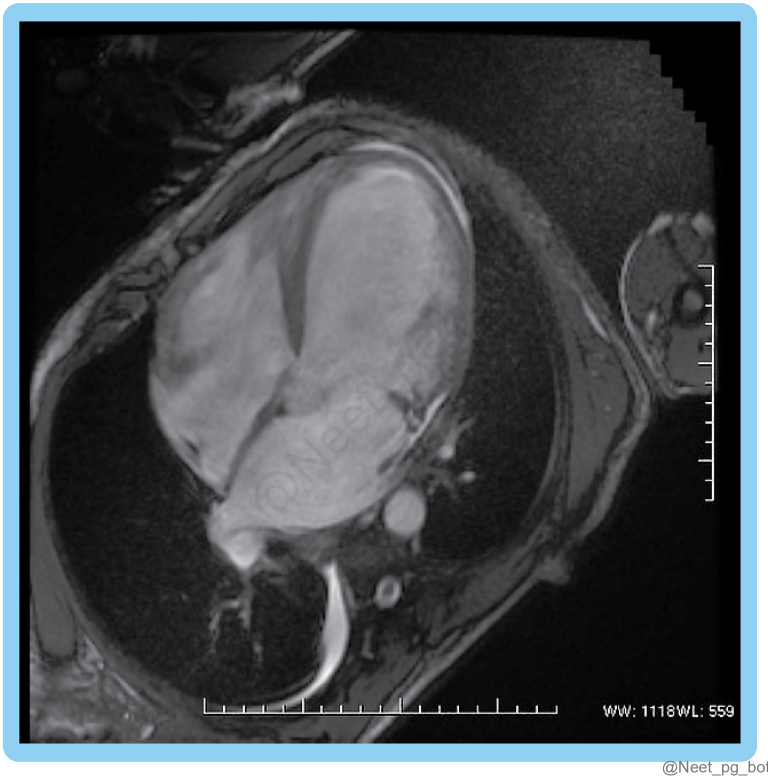

Correct Answer: C. Beta-blockers should not be used in patients with chronic heart failure.

■ *Listen (English)*

■ *Listen (Hindi)*

Explanation: CXR shows an increased CT ratio. Cardiac MRI shows reduced thickness of all chambers of the heart.. This implies the patient is having alcohol induced dilated cardiomyopathy , causing symptoms of heart failure. Beta blockers reduce mortality in chronic heart failure. Cardiac resynchronisation therapy is done to ensure both ventricles contract simultaneously and helps in reducing symptoms in DCM.

References:

Harrison's Principles of Internal Medicine, 22nd Edition, Page 1992.

↑ *Back to this question in Part A*

@Neet_pg_bot

Q6: A 50 year old alcoholic presents with shortness of breath and finding shown in the image. Auscultation reveals pan-systolic murmur. Which of the following findings is most consistent with the diagnosis of this patient? (Q850622)

A. Increased dynamic LV outflow tract obstruction

B. Increased Left ventricular diastolic dimension

C. Double Apical impulse

D. Point of maximum impulse displaced medially



Correct Answer: B. Increased Left ventricular diastolic dimension

- *Listen (English)*
- *Listen (Hindi)*

Explanation: The patient is having alcohol induced dilated cardiomyopathy. LV malfunction is causing pulmonary edema, and RV malfunction is causing pitting edema shown in the image. DCM will cause displaced hypokinetic apex with dilated, thinned-out cardiac chambers with functional Mitral regurgitation and tricuspid regurgitation, which explains the pansystolic murmur heard in this case. Increased dynamic LV outflow tract obstruction (Option A) and Double Apical impulse (Option C) are seen in HCM. Displacement of the apex beat (Option D) is seen in multiple conditions and hence ruled out.

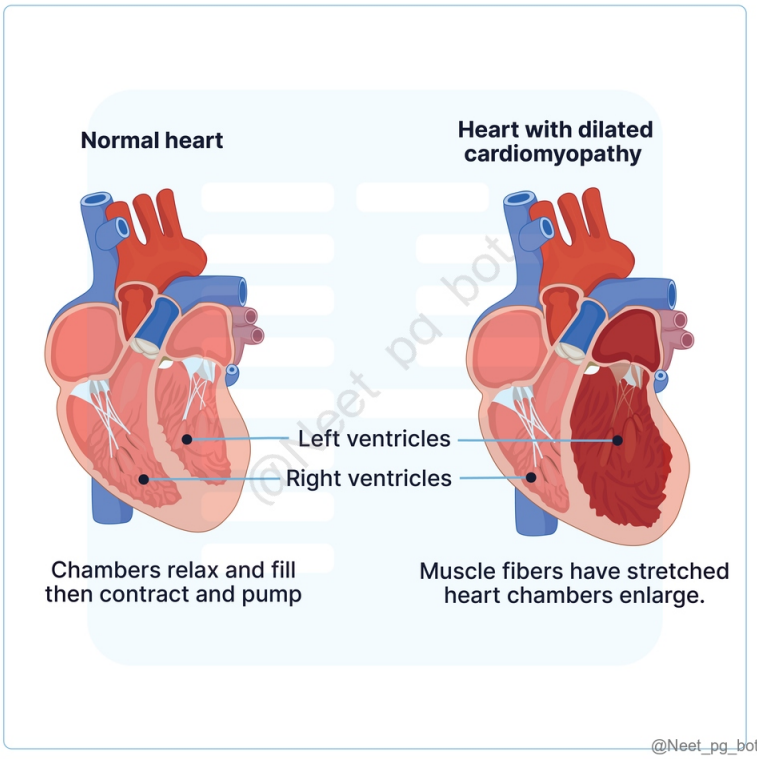

References:

Harrison's Principles of Internal Medicine, 22nd Edition, Page 2015.

Davidson's Principles and Practice of Medicine, 24th Edition, Page 539.

↑ *Back to this question in Part A*

@Neet_pg_bot

Q7: A 55 year old male presents to the emergency department with fatigue, shortness of breath, and swollen legs. CXR is shown below. Echocardiography shows global hypokinesia with reduced thickness of cardiac chambers. Which of the following is NOT a recognised cause of this patient's diagnosis? (Q850620)

A. Sarcoidosis

B. Chagas disease

C. Scleroderma

D. Heavy metal exposure to lead

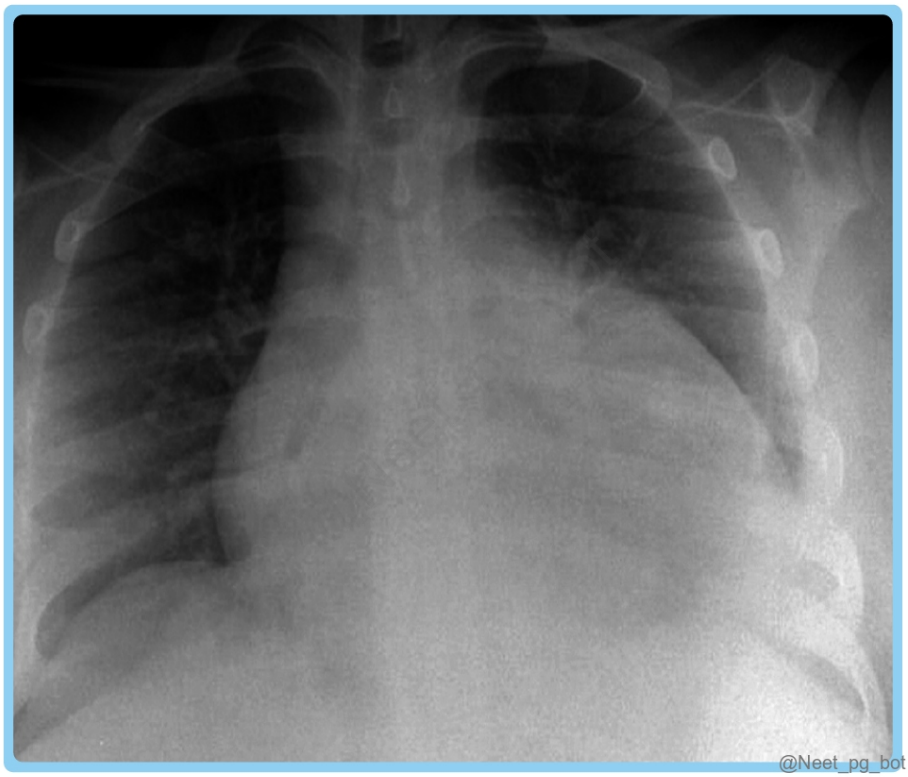

Correct Answer: C. Scleroderma

■ *Listen (English)*

■ *Listen (Hindi)*

Explanation: CXR shows an increased CT ratio. The echo shows global hypokinesia with thinned-out cardiac chambers, indicating dilated cardiomyopathy. Scleroderma causes restrictive cardiomyopathy. Must know causes of Dilated Cardiomyopathy Infective Viral (coxsackievirus, adenovirus, HIV) Parasitic (Chagas' disease, trypanosomiasis, toxoplasmosis) (Option B ruled out) Bacterial (diphtheria) Spirochetal (Lyme disease) Rickettsial (Q fever) Noninfective Granulomatous inflammatory disease Sarcoidosis Giant cell myocarditis Eosinophilic myocarditis Polymyositis, dermatomyositis Collagen vascular disease Toxic Alcohol Catecholamines (amphetamines, cocaine) Chemotherapeutic agents (anthracyclines, trastuzumab) Other therapeutic agents (hydroxychloroquine, chloroquine) Drugs of misuse (emetine, anabolic steroids) Heavy metals (lead, mercury) Metabolic Nutritional deficiencies (thiamine, selenium , carnitine) Endocrinopathy (thyroid disease, pheochromocytoma, diabetes, obesity, hemochromatosis) Dystrophin-related dystrophy (Duchenne's, Becker's) Mitochondrial myopathies (e.g., Kearns-Sayre syndrome)

References:

Harrison's Principles of Internal Medicine, 22nd Edition, Page 2016, 2020.

↑ *Back to this question in Part A*

@Neet_pg_bot

Q8: All of the following are correct about restrictive cardiomyopathy except? (Q850616)

A. Echo shows dilated atria with normal size ventricles and increased LV and RV end diastolic pressures

B. Cardiac MRI shows starry sky appearance due to amyloidosis

C. Absent y descent and steep x descent

D. Endomyocardial biopsy is the gold standard for diagnosing cardiac amyloidosis.

Correct Answer: C. Absent y descent and steep x descent

- *Listen (English)*
- *Listen (Hindi)*

Explanation: Restrictive cardiomyopathy (RCM): x descent: normal or mildly blunted y descent: prominent (steep) due to rapid early diastolic filling that abruptly stops Cardiac tamponade: x descent: prominent (steep) because atrial relaxation still occurs y descent: blunted or absent because ventricular filling is restricted by pericardial pressure Echocardiography in RCM typically reveals biatrial enlargement , normal or near-normal ventricular dimensions , and elevated diastolic pressures . (Option A) Cardiac MRI shows a starry sky pattern in amyloidosis, which is overall the most common cause of this rarest type of cardiomyopathy. (Option B) The gold standard test to demonstrate fibrosis is endomyocardial biopsy, which is now being replaced by Cardiac MRI since it is non-invasive and has better sensitivity. (Option D) {{caption_text}} Echocardiography showing enlarged atria and speckled appearance of ventricles.

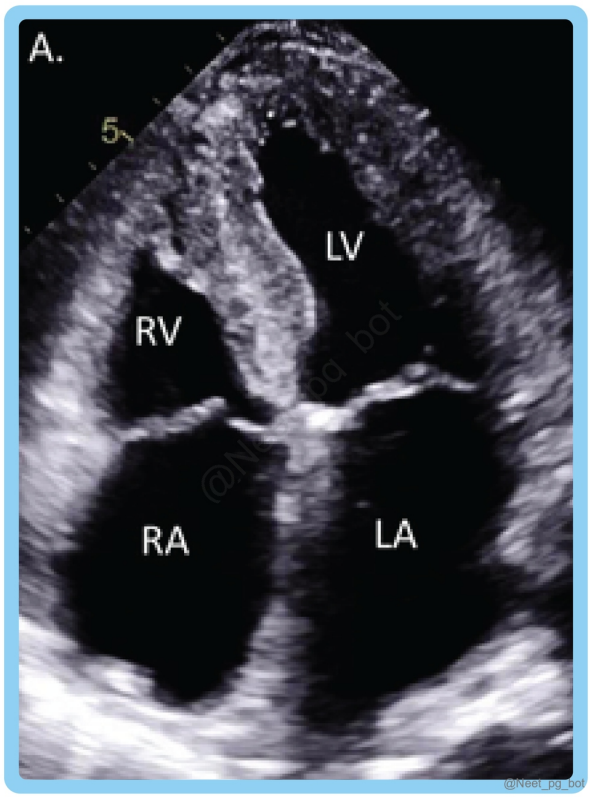

References:

Harrison's Principles of Internal Medicine, 22nd Edition, Page 2020, 2081.

↑ *Back to this question in Part A*

@Neet_pg_bot

Q9: A 60-year-old male presents with ascites, shortness of breath, and bilateral ankle edema. Kussmaul's sign is noted. An echocardiogram shows normal systolic function but diastolic dysfunction with a speckled pattern in the ventricular wall. The chest X-ray of the patient is given below. Which of the following statements is correct about the diagnosis of this patient? (Q850610)

A. Thinned out, small-size atria

B. Rapid y descent in JVP

C. Atrial fibrillation is rare in these patients.

D. Endomyocardial Fibroelastosis is the leading cause



Correct Answer: B. Rapid y descent in JVP

- *Listen (English)*
- *Listen (Hindi)*

Explanation: The echocardiogram showing normal systolic function with evidence of diastolic dysfunction and speckled appearance of ventricles implies RCM. That explains pedal edema and pulmonary edema. Atria are enlarged in RCM (Option A rules out) CXR shows a straight left heart border due to atrial enlargement RCM shows Prominent y descent : Due to elevated atrial pressures, there is rapid early ventricular filling in the diastole, creating a pronounced y descent on atrial pressure curves. RCM shows blunted x descent : Poor atrial relaxation and limited annular descent toward the apex result in a reduced x descent, as the atrium does not effectively empty or relax Atrial fibrillation is very common (Option C ruled out) ; ventricular arrhythmias are rare. Kussmaul's sign is absent in cardiac tamponade and is seen in RCM

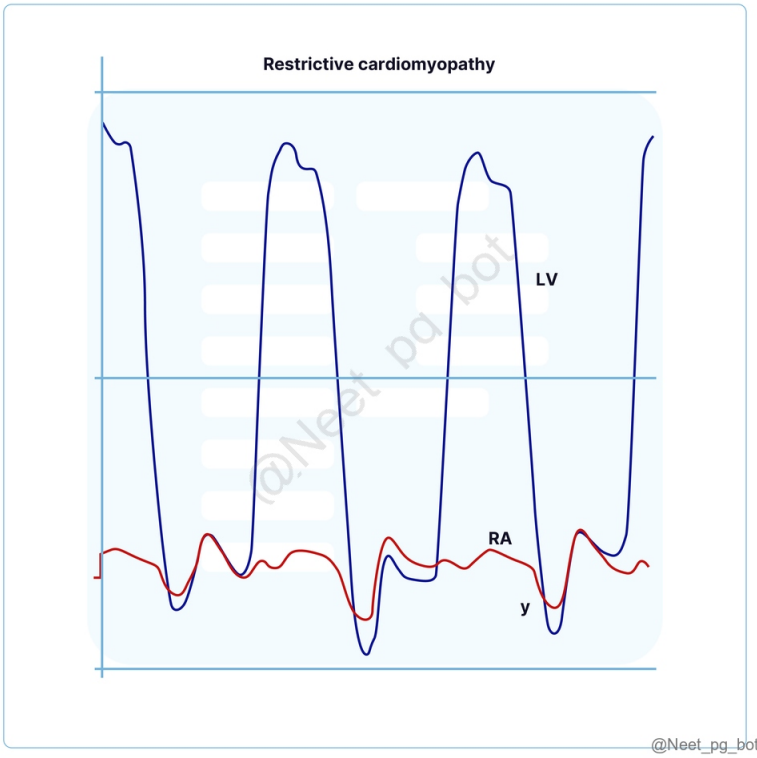

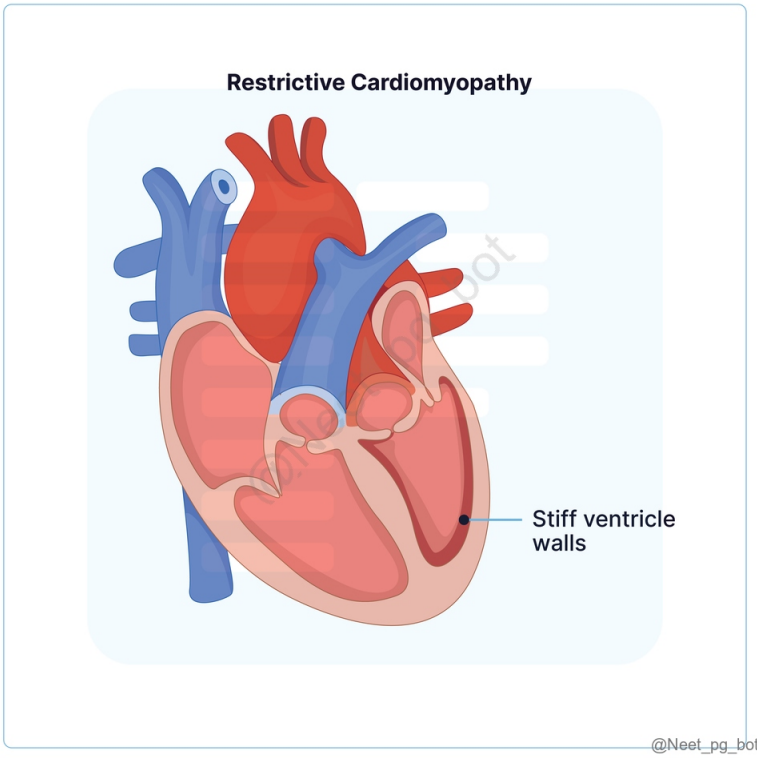

References:

Harrison's Principles of Internal Medicine, 22nd Edition, Page 2020.

↑ *Back to this question in Part A*

@Neet_pg_bot

Q10: A 45-year-old man presents with worsening fatigue, shortness of breath, and ankle swelling. His medical history includes joint pain, elevated liver enzymes, hyperpigmentation, and diabetes. He has recently been diagnosed with a metabolic disorder. An echocardiogram reveals elevated filling pressures and bilateral atrial enlargement. Which of the following best explains the underlying pathophysiology of this patient's condition? (Q850607)

A. Increased contractility due to myocardial hypertrophy

B. Impaired diastolic filling due to stiffened ventricular walls

C. Dilated ventricular chambers leading to heart failure

D. Obstruction of blood flow through the left ventricle

Correct Answer: B. Impaired diastolic filling due to stiffened ventricular walls

■ *Listen (English)*

■ *Listen (Hindi)*

Explanation: The combination of diabetes, liver dysfunction, arthropathy, and hyperpigmentation suggests hemochromatosis , a condition causing iron overload . Excess iron deposition in the myocardium leads to restrictive cardiomyopathy , characterized by stiff, noncompliant ventricles that impair diastolic filling while maintaining normal systolic function. This results in elevated filling pressures, atrial enlargement , and signs of right-sided heart failure . Increased contractility due to myocardial hypertrophy (Option A): Seen in hypertrophic cardiomyopathy , where there is asymmetric septal hypertrophy and dynamic LVOT obstruction — not in restrictive cardiomyopathy. Dilated ventricular chambers leading to heart failure (Option C): Typical of dilated cardiomyopathy , which presents with systolic dysfunction (reduced ejection fraction), not the preserved systolic function of restrictive cardiomyopathy. Obstruction of blood flow through the left ventricle (Option D): Occurs in hypertrophic obstructive cardiomyopathy (HOCM) due to septal hypertrophy and systolic anterior motion of the mitral valve — absent in this case.

References:

Harrison's Principles of Internal Medicine, 22nd Edition, Page 2020.

↑ *Back to this question in Part A*

@Neet_pg_bot

Q11: A 30-year-old female marathon runner collapses and is found unresponsive during a race. Despite attempts at resuscitation, she is pronounced dead in the ER. Her family reports that she had previously experienced episodes of dizziness and palpitations during training. You re-evaluate her ECG done at time of admission which shows epsilon waves. Which of the following conditions is most likely to contribute to sudden cardiac death in this young athlete? (Q850603)

A. Arrhythmogenic RV dysplasia

B. Commotio cordis

C. HCM

D. Atherosclerotic coronary artery disease

Correct Answer: A. Arrhythmogenic RV dysplasia

■ *Listen (English)*

■ *Listen (Hindi)*

Explanation: The keyword is epsilon wave in ECG that indicates a diagnosis of Arrhythmogenic RV dysplasia (ARVD). These are small positive deflections (notches) found at the end of the QRS complex, typically in the right precordial leads (V1–V3). They represent delayed ventricular activation in the scarred or fatty tissue of the right ventricle. Commotio cordis (Option B): This is a sudden cardiac arrest caused by a blunt, non-penetrating blow to the chest (like a baseball) during a specific phase of the cardiac cycle. It is an impact-related event, not a chronic structural/electrical disease. HCM (Option C): It is a genetic condition characterized by inappropriate thickening (hypertrophy) of the heart muscle, most commonly the interventricular septum. While HCM is the most common cause of sudden cardiac death (SCD) in young athletes, it does not present with epsilon waves. It typically shows LV hypertrophy, deep Q-waves, or T-wave inversions. Atherosclerotic coronary artery disease (Option D): It is the buildup of plaque (cholesterol and calcium) in the arteries that supply blood to the heart muscle, leading to narrowing or blockage. While CAD is the leading cause of exercise-related death in adults over age 35 , it is much rarer in a 30-year-old female athlete without a significant medical history. CAD would present on an ECG as ST-segment changes or T-wave inversions, not epsilon waves.

References:

Harrison's Principles of Internal Medicine, 22nd Edition, Page 1966.

↑ *Back to this question in Part A*

@Neet_pg_bot

Q12: Which of the following medications is not contraindicated in patients with hypertrophic cardiomyopathy? (Q850601)

A. Amlodipine

B. Verapamil

C. Furosemide

D. Digoxin

Correct Answer: B. Verapamil

■ *Listen to Audio 1*

Explanation: Amlodipine (Option A) reduces afterload , causes vasodilation worsens LVOT obstruction in HCM by: ↓ afterload → ↑ pressure gradient → Reflex ↑ HR → worsens obstruction Furosemide (Option C) reduce preload and reduce inflow to the right ventricle. Less inflow to RV implies less inflow to the left ventricle, which is already small in size in HCM. This causes BP to fall Verapamil does not affect preload. It can be used in patients with hypertrophic cardiomyopathy when beta blockers are contraindicated or not tolerated. It will act on the AV node, reduce heart rate and reduce oxygen consumption of this enlarged heart. Digoxin (Option D) will increase oxygen consumption and worsen pre-existing subendocardial ischemia that is present in these patients.

References:

Harrison's Principles of Internal Medicine, 22nd Edition, Page 2007, 2008.

↑ *Back to this question in Part A*

@Neet_pg_bot

Q13: A 45-year-old male presents with sharp chest pain worsened by lying down and relieved by sitting up. He had a recent viral illness. A friction rub is heard on cardiac auscultation, and the ECG shows the following. What is the most likely diagnosis? (Q850515)

A. Myocardial infarction

B. Pulmonary embolism

C. Acute pericarditis

D. Aortic dissection

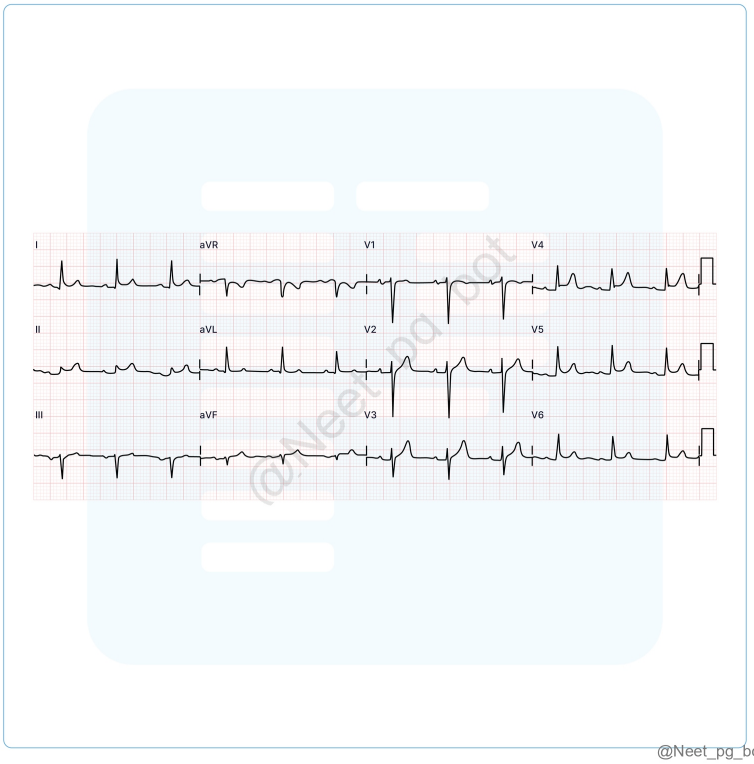

Correct Answer: C. Acute pericarditis

- *Listen (English)*
- *Listen (Hindi)*

Explanation: The clinical presentation and ECG findings of diffuse ST-segment elevation with PR-segment depression point to acute pericarditis. Auscultation shows pericardial friction rub, and relief of chest pain on sitting up adds to the ECG diagnosis. Myocardial infarction (Option A): Presents with localized ST elevation confined to leads representing the affected area and reciprocal ST depression in opposite leads. Pain is not positional and typically crushing in nature. Pulmonary embolism (Option B): Typically causes sudden pleuritic chest pain , dyspnea , and tachycardia , with ECG showing S1Q3T3 pattern or sinus tachycardia — not diffuse ST elevation. Aortic dissection (Option D): Causes tearing chest pain radiating to the back , often with unequal pulses or blood pressure between limbs. ECG may be normal or show ischemic changes if coronary involvement occurs, but PR depression and friction rub are absent .

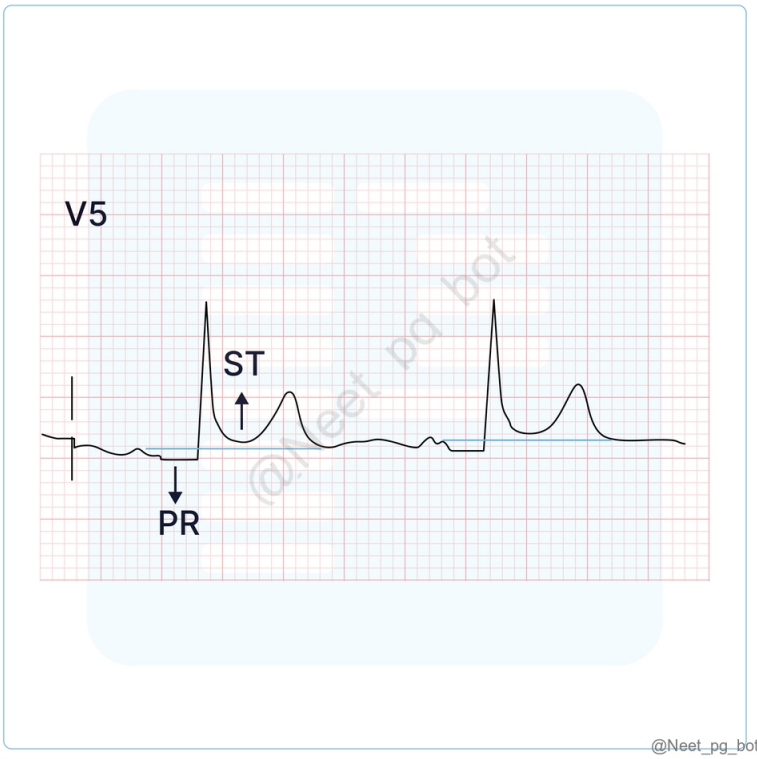

References:

Harrison's Principles of Internal Medicine, 22nd Edition, Page 2079.

↑ *Back to this question in Part A*

@Neet_pg_bot

Q14: A 30-year-old male presents with exertional chest pain and occasional fainting spells. His family history includes a relative who experienced sudden cardiac death. An echocardiogram reveals asymmetric septal hypertrophy. Which of the following is not a characteristic investigatory finding in this condition? (Q850592)

A. Brockenbrough-Braunwald-Morrow sign

B. Deep, narrow Q waves in the lateral leads

C. Left ventricle free wall thickness >10 mm

D. Increased precordial voltages

Correct Answer: C. Left ventricle free wall thickness >10 mm

■ *Listen (English)*

■ *Listen (Hindi)*

Explanation: The clinical scenario suggests hypertrophic obstructive cardiomyopathy (HOCM) due to the athlete's exertional syncope and family history of sudden cardiac death, alongside echocardiographic findings of asymmetric septal hypertrophy, which are characteristic of HOCM. However, left ventricle free wall thickness >10 mm is incorrect as HOCM is characterized by left ventricle thickness >15 mm (typically >30 mm in severe cases) The Brockenbrough–Morrow sign is a paradoxical fall in aortic pulse pressure after a PVC, seen in HOCM, due to worsening dynamic LVOT obstruction. ECG will show increased voltage in precordial leads due to hypertrophy of LV . ECG features of HOCM : Left ventricular hypertrophy (Sokolow-Lyon criteria: S wave depth in V1 + tallest R wave height in V5 or V6 > 35 mm) with increased precordial voltages and non-specific ST segment and T-wave abnormalities (Option D ruled out) Deep, narrow (“dagger-like”) Q waves in lateral (I, aVL, V5-6) +/- inferior (II, III, aVF) leads (Option B ruled out) due to septal hypertrophy. Cardiac catheterization: Brockenbrough–Braunwald–Morrow sign, (Option A ruled out) Trigger: Post-PVC beat. Finding: ↑ LV pressure but ↓ Aortic pulse pressure. Mechanism: Increased contractility worsens outflow obstruction. Constrictive/Restrictive (Square Root Sign) The Dip: Rapid early diastolic filling (sudden pressure drop). The Plateau: Filling hits a "wall" (stiff pericardium/myocardium), causing pressure to flatten abruptly.

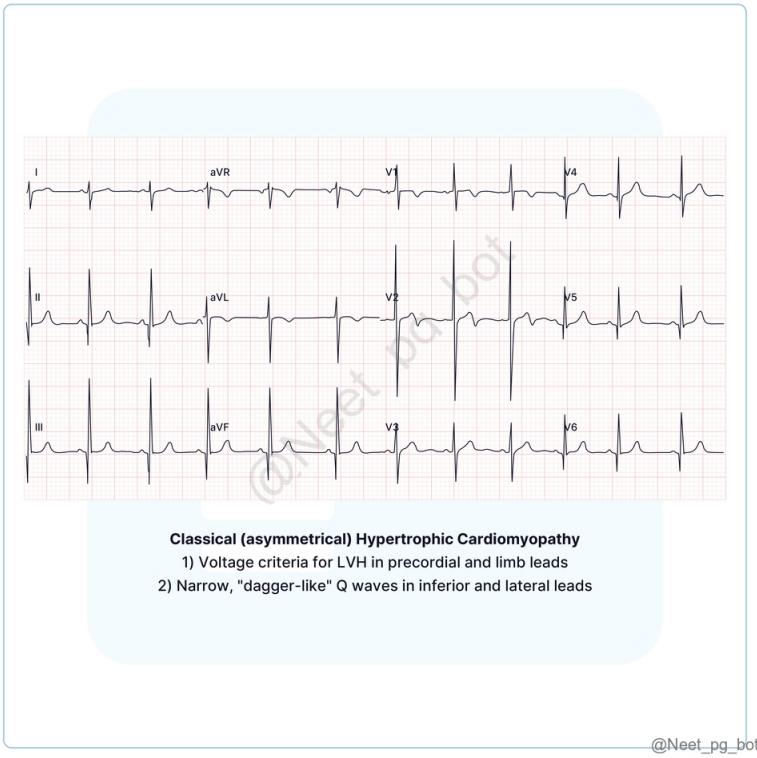

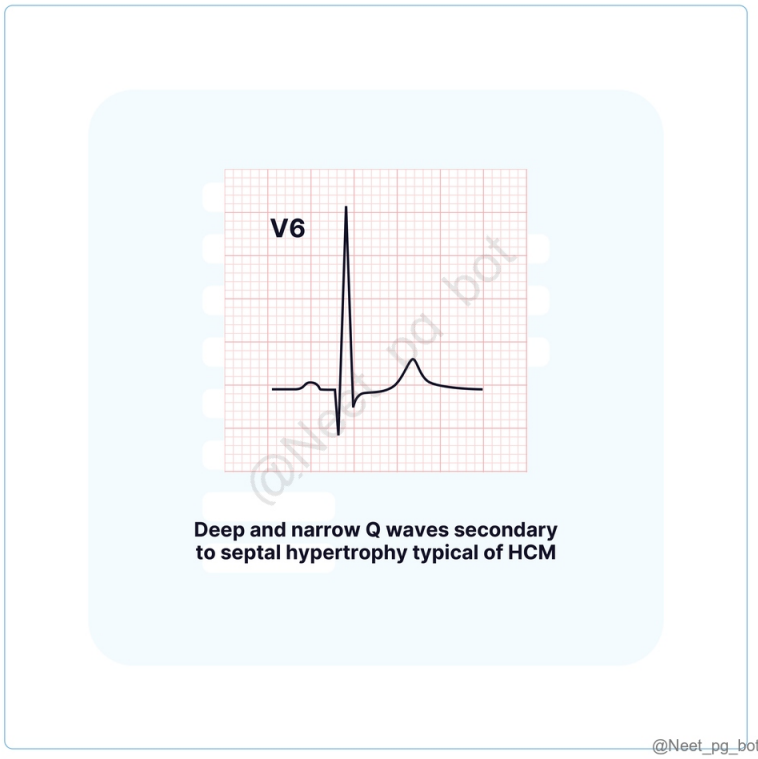

References:

Harrison's Principles of Internal Medicine, 22nd Edition, Page 2008.

https://pmc.ncbi.nlm.nih.gov/articles/PMC4676455/

↑ *Back to this question in Part A*

@Neet_pg_bot

Q15: A 15-year-old male presents to the ED after experiencing syncope while playing basketball. He has a palpable double impulse at the apex, and an ECG shows signs of left ventricular hypertrophy. An echocardiogram reveals asymmetric septal thickening with left ventricular outflow tract obstruction. Which of the following examination findings would not be expected in this patient? (Q850589)

A. Palpable double impulse at the apex

B. Late-peaking ejection systolic murmur best heard at the left sternal border

C. Pulsus bisferiens on peripheral pulse examination

D. Prominent y descent in jugular venous pressure (JVP)

Correct Answer: D. Prominent y descent in jugular venous pressure (JVP)

■ *Listen (English)*

■ *Listen (Hindi)*

Explanation: The patient's symptoms of syncope during exertion, left ventricular hypertrophy, and asymmetric septal thickening with outflow tract obstruction strongly suggest hypertrophic cardiomyopathy (HCM) , specifically hypertrophic obstructive cardiomyopathy (HOCM) . Prominent y descent in jugular venous pressure (JVP) is more typical of constrictive pericarditis rather than HOCM. Palpable double impulse at the apex (Option A): Due to forceful atrial contraction against a stiff hypertrophied ventricle. Late-peaking ejection systolic murmur (Option B): Caused by dynamic LV outflow tract obstruction, best heard at the left sternal border. Pulsus bisferiens (Option C): Bifid pulse due to rapid ejection followed by dynamic obstruction, typical in HOCM.

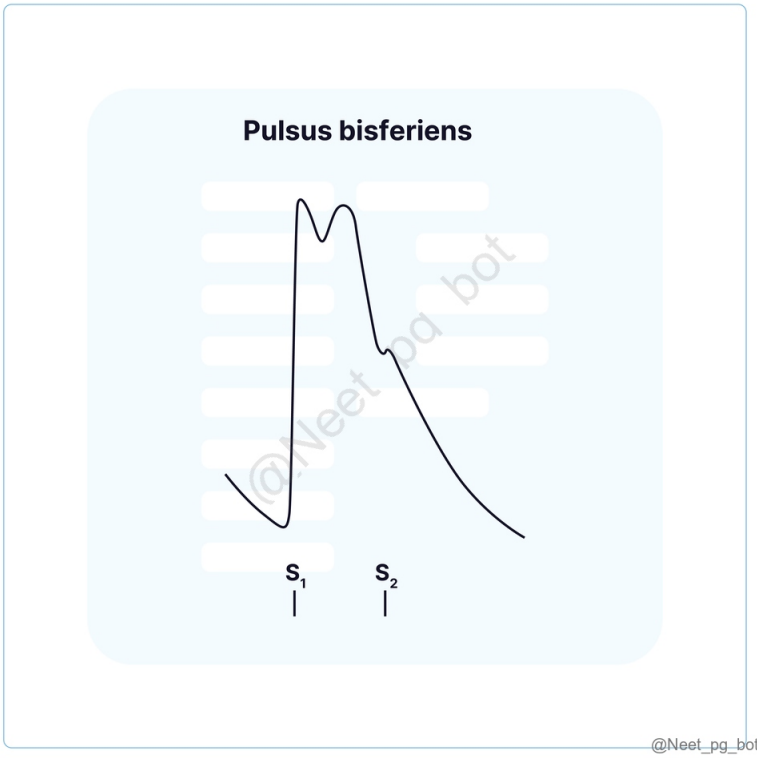

References:

Harrison's Principles of Internal Medicine, 22nd Edition, Page 2006, 2081.

↑ *Back to this question in Part A*

@Neet_pg_bot

Q16: A 30-year-old athlete presents with recurrent syncope and exertional chest pain. Exam shows a hyperdynamic apex beat and a mid-systolic murmur at the left lower

sternal border. Echocardiography reveals asymmetric septal hypertrophy and systolic anterior motion of the mitral valve. What is the most likely mechanism of his symptoms? (Q850584)

A. Diastolic heart failure due to a dilated left ventricle

B. Mitral valve prolapse

C. Left ventricular outflow tract obstruction

D. Aortic stenosis

Correct Answer: C. Left ventricular outflow tract obstruction

■ *Listen (English)*

■ *Listen (Hindi)*

Explanation: The patient has hypertrophic obstructive cardiomyopathy (HOCM) . Asymmetric septal hypertrophy and systolic anterior motion (SAM) of the mitral valve create a dynamic obstruction of the left ventricular outflow tract (LVOT) during systole. This obstruction worsens with exercise, standing, or Valsalva , explaining syncope, exertional chest pain, and a murmur that increases in intensity . The hyperdynamic apex beat reflects forceful contraction against the obstructed outflow tract. Coronary artery obstruction (Option A) : Causes ischemic chest pain but does not explain the dynamic murmur or hyperdynamic apex in a young athlete. Aortic stenosis (Option A) : Murmur is mid-systolic at the right 2nd intercostal space radiating to the carotids, not left lower sternal border. Mitral regurgitation(Option D) : Murmur is holosystolic at the apex radiating to the axilla , not mid-systolic at left lower sternal border.

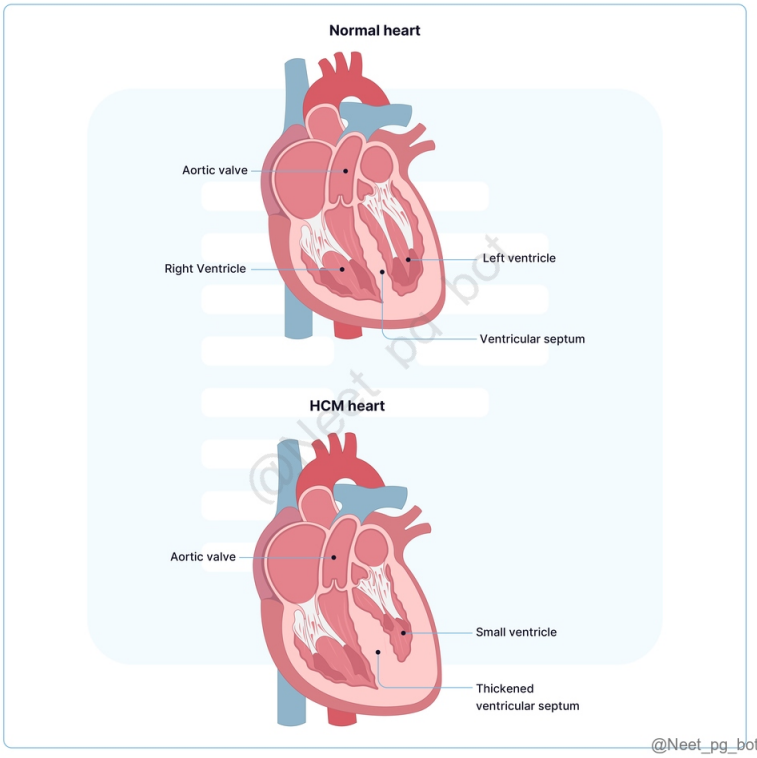

References:

Harrison's Principles of Internal Medicine, 22nd Edition, Page 2006.

↑ *Back to this question in Part A*

@Neet_pg_bot

Q17: A 60-year-old male presents with signs of peripheral oedema and ascites. A chest X-ray reveals the following, and echocardiography confirms a thickened pericardium. Which of the following is not correct regarding his likely condition? (Q850580)

A. Diastolic collapse of the ventricles

B. JVP shows a prominent “y” descent

C. Commonly caused by tuberculosis in endemic regions

D. CT scan can assist in visualizing pericardial calcification

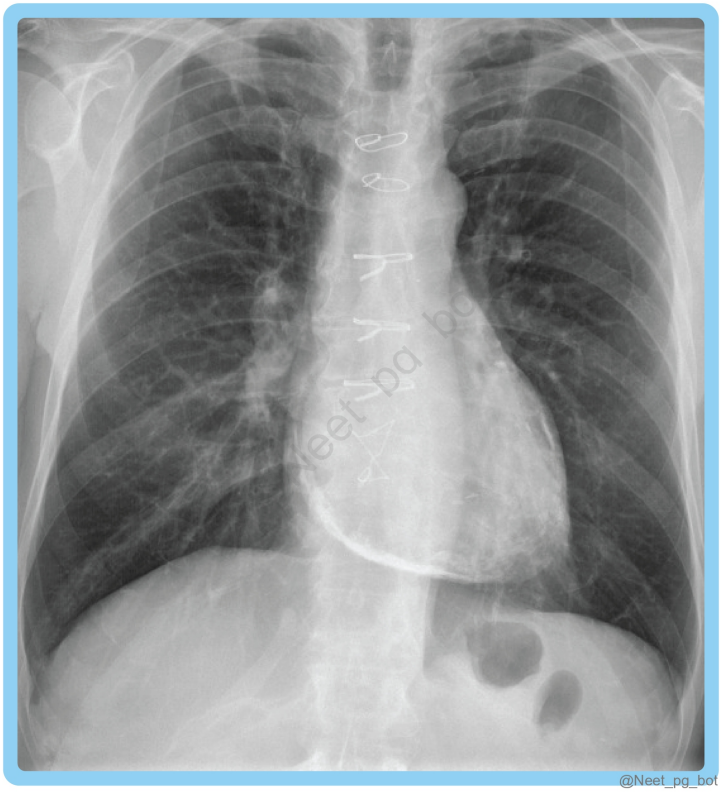

Correct Answer: A. Diastolic collapse of the ventricles

■ *Listen (English)*

■ *Listen (Hindi)*

Explanation: The patient’s presentation with peripheral oedema, ascites, elevated JVP, pericardial calcification visible on chest X-ray, and a thickened pericardium on echocardiography is suggestive of constrictive pericarditis . This condition is associated with diastolic dysfunction and signs of right-sided heart failure due to a rigid pericardium restricting heart filling. Diastolic collapse of the ventricles is seen in cardiac tamponade and not constrictive pericarditis. JVP shows a prominent “y” descent (Option B): Due to rapid early diastolic filling followed by an abrupt halt. Commonly caused by tuberculosis (Option C): TB is a frequent cause in developing countries. CT scan visualizing pericardial calcification (Option D): Helps confirm diagnosis and assess extent of calcification.

References:

Harrison's Principles of Internal Medicine, 22nd Edition, Page 2082.

↑ *Back to this question in Part A*

@Neet_pg_bot

Q18: A 45-year-old male presents with fatigue, abdominal swelling, and peripheral oedema. On examination, he has elevated jugular venous pressure, hepatomegaly, and

a loud diastolic sound. There is also a rise in JVP during inspiration. Which of the following is the most likely diagnosis? (Q850579)

A. Cardiac Tamponade

B. Constrictive pericarditis

C. Dilated cardiomyopathy

D. Restrictive cardiomyopathy

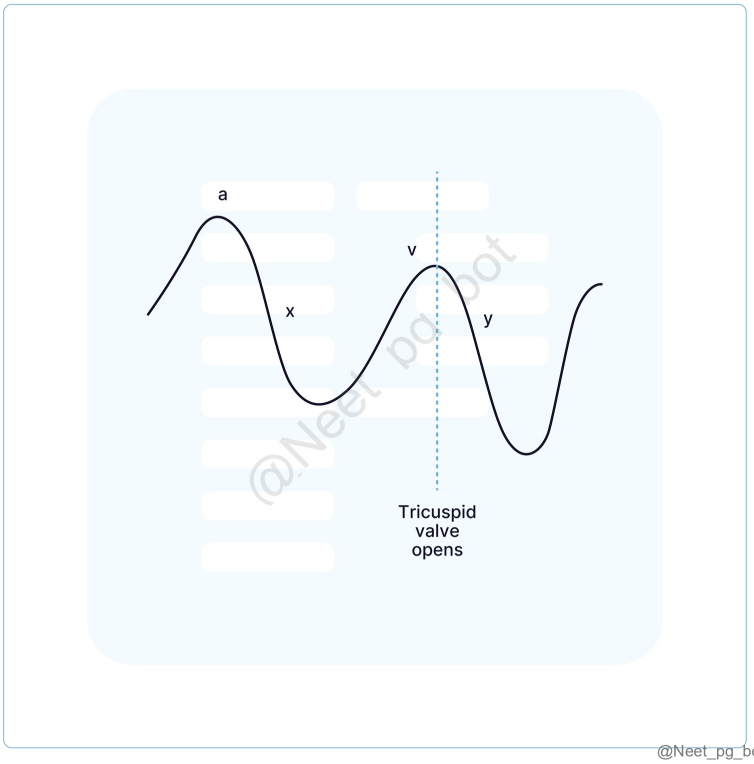

Correct Answer: B. Constrictive pericarditis

■ *Listen (English)*

■ *Listen (Hindi)*

Explanation: Elevated JVP with a rapid y descent , presence of a pericardial knock , Kussmaul’s sign (rise in JVP during inspiration), hepatomegaly, and peripheral edema are characteristic features of constrictive pericarditis caused by a rigid, fibrotic pericardium restricting diastolic filling. Cardiac tamponade (Option A): Shows absent y descent and pulsus paradoxus , not a pericardial knock. Dilated cardiomyopathy (Option C): Presents with systolic dysfunction and displaced apex beat, without pericardial signs. Restrictive cardiomyopathy (Option D): Mimics constriction but lacks pericardial thickening or knock; myocardial compliance is the issue.

References:

Harrison's Principles of Internal Medicine, 22nd Edition, Page 2081.

↑ *Back to this question in Part A*

@Neet_pg_bot

Q19: A 25-year-old male is brought to the emergency department after a high-speed car accident. His vitals are heart rate of 120 bpm, blood pressure of 80/50 mmHg, and he is pale with cold, clammy skin. He has a deep laceration on his lower thigh and is actively bleeding. Which of the following is the most appropriate initial management step? (Q850578)

A. Echocardiography guided pericardiocentesis

B. Emergency resuscitative thoracotomy

C. Start intravenous fluid resuscitation

D. Apply a tourniquet to the thigh

Correct Answer: D. Apply a tourniquet to the thigh

■ *Listen (English)*

■ *Listen (Hindi)*

Explanation: In cases of life-threatening external hemorrhage , such as active arterial bleeding from a limb injury, immediate application of a tourniquet is the first and most critical step — it prevents exsanguination before fluid resuscitation or definitive care. Echocardiography-guided pericardiocentesis (Option A): Indicated for cardiac tamponade , not external limb bleeding. Emergency resuscitative thoracotomy (Option B): Used in penetrating chest trauma with cardiac arrest , not extremity hemorrhage. Start intravenous fluid resuscitation (Option C): Important but secondary to hemorrhage control in active external bleeding.

References:

Harrison's Principles of Internal Medicine, 22nd Edition, Page 2293.

↑ *Back to this question in Part A*

@Neet_pg_bot

Q20: A 60 year old woman with stage 4 carcinoma breast presents to the ED with severe shortness of breath. On examination, she is hypotensive with a blood pressure of 80/60 mmHg, has distended neck veins with a jugular venous pressure of 12 cm H2O, and her heart sounds are muffled. An echocardiogram shows the following: What is the most appropriate immediate and definitive treatment for this patient?

(Q850572)

A. Intravenous saline infusion

B. Pericardiocentesis

C. Diuretics

D. Surgical drainage (pericardiotomy)

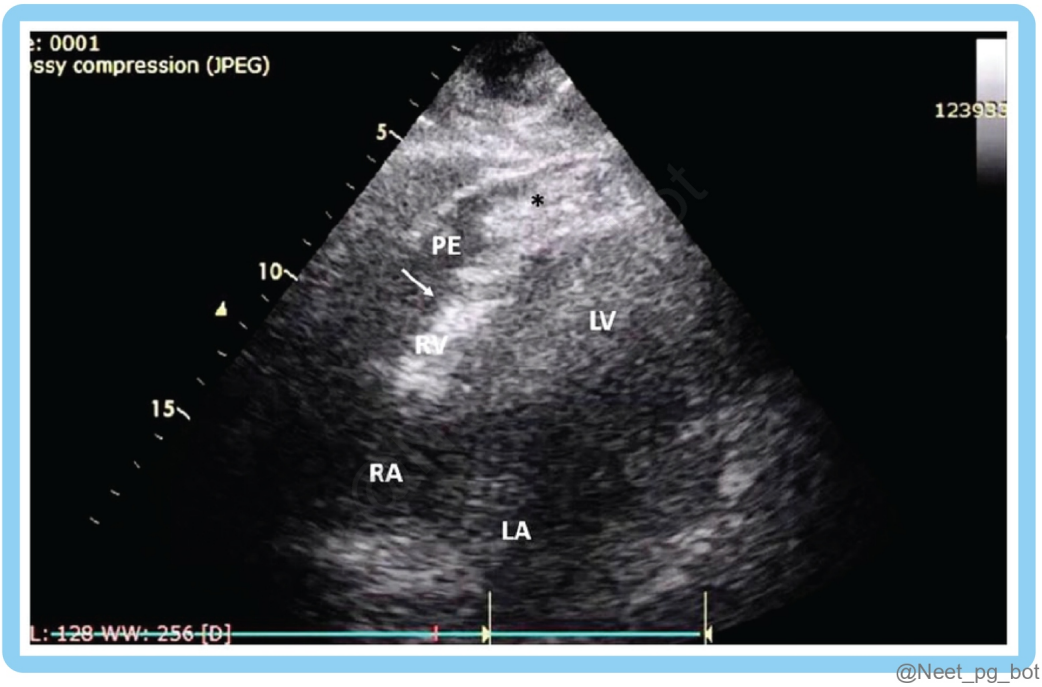

Correct Answer: B. Pericardiocentesis

■ *Listen (English)*

■ *Listen (Hindi)*

Explanation: The triad of hypotension, elevated jugular venous pressure, and muffled heart sounds (Beck's triad), along with echocardiographic evidence of right ventricular diastolic collapse, confirms cardiac tamponade . In such cases, immediate pericardiocentesis is both diagnostic and therapeutic—it relieves pericardial pressure, restores ventricular filling, and improves cardiac output. In malignancy-related tamponade, fluid may reaccumulate, and pericardial window or sclerotherapy can be considered later, but the first-line emergency management remains pericardiocentesis . Intravenous saline infusion (Option A): May temporarily improve preload and venous return, but it does not relieve pericardial pressure . It can only serve as a short-term supportive measure before pericardiocentesis. Diuretics (Option C): Reduce venous return and can exacerbate hypotension , worsening cardiac output. Contraindicated in tamponade. Surgical drainage (pericardiotomy) (Option D): Indicated for recurrent or loculated pericardial effusions , but not the immediate emergency treatment in this setting.

References:

Harrison's Principles of Internal Medicine, 22nd Edition, Page 2082.

↑ *Back to this question in Part A*

@Neet_pg_bot

Q21: Which of the following is a classic finding in cardiac tamponade? (Q850571)

A. Pulsus paradoxus

B. S3 heart sound

C. Pulsus alternans

D. High-pitched systolic murmur

Correct Answer: A. Pulsus paradoxus

■ *Listen (English)*

■ *Listen (Hindi)*

Explanation: Pulsus paradoxus is a hallmark finding in cardiac tamponade, characterized by a significant drop in systolic blood pressure during inspiration (greater than 10 mm Hg). It occurs due to the impaired filling of the heart chambers caused by pericardial fluid compression, limiting cardiac output during inspiration. This phenomenon is commonly observed in cardiac tamponade and serves as a key diagnostic feature in such cases. S3 heart sound (Option B): An S3 heart sound, also known as a ventricular gallop, is typically associated with heart failure or conditions causing rapid filling of the ventricles, such as dilated cardiomyopathy. It is not a classic finding in cardiac tamponade, which is more characterized by restricted ventricular filling and muffled heart sounds rather than additional heart sounds like S3. Pulsus alternans (Option C): Pulsus alternans refers to alternating strong and weak pulse beats, typically seen in left ventricular dysfunction, not cardiac tamponade. High-pitched systolic murmur (Option D): A high-pitched systolic murmur is usually associated with valvular heart diseases, such as aortic stenosis or mitral regurgitation, not cardiac tamponade

References:

Harrison's Principles of Internal Medicine, 22nd Edition, Page 2081.

↑ *Back to this question in Part A*

@Neet_pg_bot

Q22: A 65-year-old man presents to the emergency department with complaints of shortness of breath, fatigue, and mild chest discomfort. On examination, his blood pressure is low, and his heart sounds are faint on auscultation. The physician orders

an echocardiogram, which shows the following Based on these findings, which of the following ECG pattern would you most likely expect to see? (Q850557)

A. High-voltage QRS complexes

B. ST-segment elevation in all leads

C. Prolonged PR interval

D. Electrical alternans

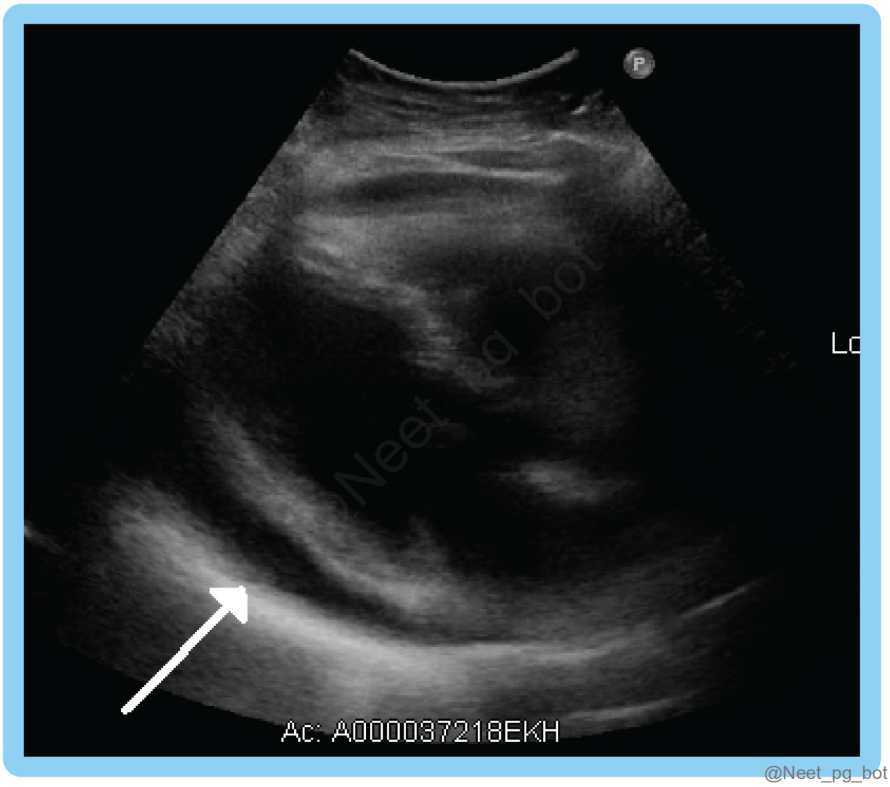

Correct Answer: D. Electrical alternans

■ *Listen (English)*

■ *Listen (Hindi)*

Explanation: This patient’s symptoms, vitals and echocardiographic findings which reveal a large fluid collection around the heart , with evidence of impaired filling of the right-sided chambers are suggestive of cardiac tamponade, likely due to a large pericardial effusion. Electrical alternans is a classic ECG finding in pericardial effusion , particularly when it leads to cardiac tamponade. It manifests as beat-to-beat variations in the amplitude of the QRS complexes, reflecting the heart's movement within the fluid-filled pericardial space. This finding is indicative of significant fluid accumulation and increased intrapericardial pressure, which impedes the heart's ability to fill properly during diastole. ECG showing Electrical alternans Red arrows showing variations in the amplitude of QRS complexes High-voltage QRS complexes (Option A): High-voltage QRS complexes suggest an increased electrical activity due to conditions like left ventricular hypertrophy or other myocardial adaptations.

However, in pericardial effusion, there are low-voltage QRS complexes. ST-segment elevation in all leads (Option B): This finding is more characteristic of acute pericarditis, where widespread ST-segment elevations occur due to inflammation of the pericardial sac. In pericardial effusion or tamponade, ST-segment changes are not the defining features. Prolonged PR interval (Option C): A prolonged PR interval typically indicates delayed conduction through the atrioventricular node. Although PR segment depression can occur in acute pericarditis, a prolonged PR interval is not a hallmark of pericardial effusion or tamponade.

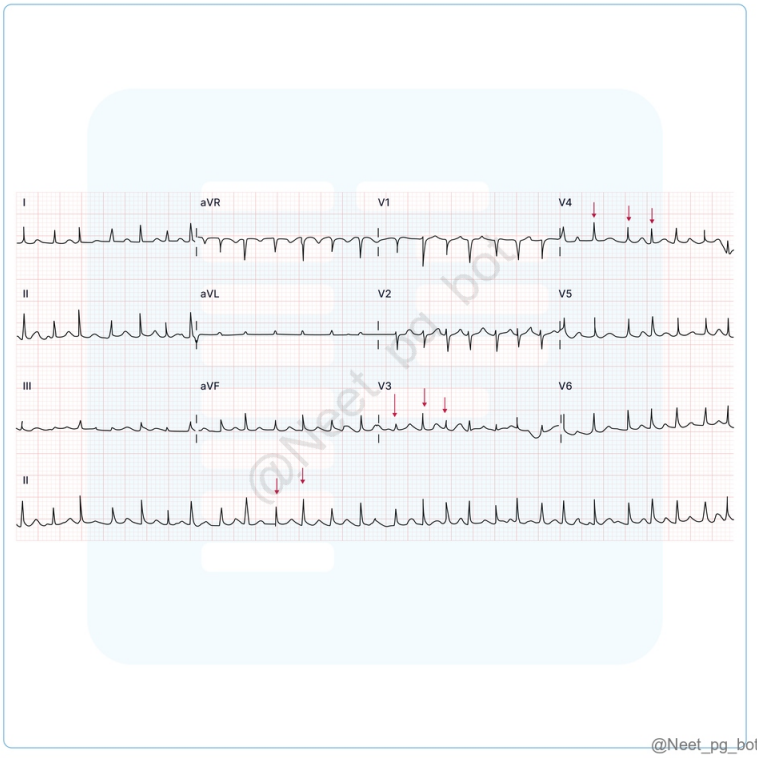

References:

Harrison's Principles of Internal Medicine, 22nd Edition, Page 2081.

↑ *Back to this question in Part A*

@Neet_pg_bot

Q23: A 60 y/o male with acute pericarditis who has not responded to NSAIDs and colchicine is now experiencing frequent recurrences. He does not tolerate glucocorticoids well. What additional treatment can be considered? (Q850553)

A. Increase the dose of NSAIDs

B. Start azathioprine

C. Begin a higher dose of colchicine

D. Stop all medications and monitor

Correct Answer: B. Start azathioprine

■ *Listen (English)*

■ *Listen (Hindi)*

Explanation: In cases where NSAIDs, colchicine, and glucocorticoids have failed, immunosuppressive therapy such as azathioprine can be considered. Azathioprine is used for patients with recurrent, refractory pericarditis who have multiple episodes lasting for extended periods. Increase the dose of NSAIDs (Option A): NSAIDs are effective for inflammation control in the short term, but increasing the dosage does not provide additional benefit once recurrences occur. Begin a higher dose of colchicine (Option C): Increasing the dose beyond the recommended levels is not advisable, as colchicine has a narrow therapeutic window . Higher doses increase the risk of gastrointestinal side effects, such as diarrhoea, and can be toxic, especially in patients with liver or kidney problems. Stop all medications and monitor (Option D): Stopping all medications without an alternative treatment plan is not appropriate in recurrent pericarditis cases. It can lead to persistent discomfort and potential complications.

References:

Harrison's Principles of Internal Medicine, 22nd Edition, Page 2080.

↑ *Back to this question in Part A*

@Neet_pg_bot

• [01_Cardiology] 009 Previous Year Questions

« Back to Folder Directory

[01_Cardiology] 009 Previous Year Questions — Quick Jump

Q1 (p. 1277)	*Q2 (p. 1279)*	*Q3 (p. 1281)*	*Q4 (p. 1281)*	*Q5 (p. 1282)*	*Q6 (p. 1283)*
Q7 (p. 1284)	*Q8 (p. 1285)*	*Q9 (p. 1286)*	*Q10 (p. 1287)*	*Q11 (p. 1289)*	*Q12 (p. 1290)*
Q13 (p. 1291)	*Q14 (p. 1292)*	*Q15 (p. 1293)*	*Q16 (p. 1294)*	*Q17 (p. 1295)*	*Q18 (p. 1297)*
Q19 (p. 1298)	*Q20 (p. 1299)*	*Q21 (p. 1300)*	*Q22 (p. 1300)*	*Q23 (p. 1301)*	*Q24 (p. 1302)*
Q25 (p. 1302)	*Q26 (p. 1303)*	*Q27 (p. 1304)*	*Q28 (p. 1305)*	*Q29 (p. 1306)*	*Q30 (p. 1308)*
Q31 (p. 1309)	*Q32 (p. 1310)*	*Q33 (p. 1311)*	*Q34 (p. 1312)*	*Q35 (p. 1313)*	*Q36 (p. 1316)*
Q37 (p. 1317)	*Q38 (p. 1319)*	*Q39 (p. 1320)*	*Q40 (p. 1320)*	*Q41 (p. 1321)*	*Q42 (p. 1323)*
Q43 (p. 1324)	*Q44 (p. 1325)*	*Q45 (p. 1326)*	*Q46 (p. 1326)*	*Q47 (p. 1327)*	*Q48 (p. 1329)*
Q49 (p. 1330)	*Q50 (p. 1332)*	*Q51 (p. 1335)*	*Q52 (p. 1336)*	*Q53 (p. 1337)*	*Q54 (p. 1338)*
Q55 (p. 1339)	*Q56 (p. 1341)*	*Q57 (p. 1342)*	*Q58 (p. 1343)*	*Q59 (p. 1344)*	*Q60 (p. 1345)*
Q61 (p. 1346)	*Q62 (p. 1347)*	*Q63 (p. 1348)*	*Q64 (p. 1349)*	*Q65 (p. 1350)*	*Q66 (p. 1351)*
Q67 (p. 1351)	*Q68 (p. 1352)*	*Q69 (p. 1353)*	*Q70 (p. 1354)*	*Q71 (p. 1355)*	*Q72 (p. 1356)*
Q73 (p. 1357)	*Q74 (p. 1359)*	*Q75 (p. 1361)*	*Q76 (p. 1363)*	*Q77 (p. 1364)*	*Q78 (p. 1365)*
Q79 (p. 1367)	*Q80 (p. 1368)*	*Q81 (p. 1369)*	*Q82 (p. 1371)*	*Q83 (p. 1372)*	*Q84 (p. 1374)*
Q85 (p. 1375)	*Q86 (p. 1377)*	*Q87 (p. 1377)*	*Q88 (p. 1379)*	*Q89 (p. 1381)*	*Q90 (p. 1382)*
Q91 (p. 1385)	*Q92 (p. 1385)*	*Q93 (p. 1387)*	*Q94 (p. 1388)*	*Q95 (p. 1389)*	*Q96 (p. 1390)*
Q97 (p. 1391)	*Q98 (p. 1392)*	*Q99 (p. 1394)*	*Q100 (p. 1395)*	*Q101 (p. 1396)*	*Q102 (p. 1397)*
Q103 (p. 1398)	*Q104 (p. 1400)*	*Q105 (p. 1400)*	*Q106 (p. 1402)*	*Q107 (p. 1403)*	*Q108 (p. 1404)*
Q109 (p. 1405)	*Q110 (p. 1407)*	*Q111 (p. 1409)*	*Q112 (p. 1410)*	*Q113 (p. 1411)*	*Q114 (p. 1412)*
Q115 (p. 1415)	*Q116 (p. 1416)*	*Q117 (p. 1418)*	*Q118 (p. 1419)*	*Q119 (p. 1420)*	*Q120 (p. 1421)*
Q121 (p. 1425)	*Q122 (p. 1426)*	*Q123 (p. 1428)*	*Q124 (p. 1429)*	*Q125 (p. 1430)*	*Q126 (p. 1432)*
Q127 (p. 1433)	*Q128 (p. 1435)*	*Q129 (p. 1437)*	*Q130 (p. 1438)*	*Q131 (p. 1440)*	*Q132 (p. 1441)*
Q133 (p. 1441)	*Q134 (p. 1443)*	*Q135 (p. 1446)*	*Q136 (p. 1446)*	*Q137 (p. 1447)*	*Q138 (p. 1448)*
Q139 (p. 1449)	*Q140 (p. 1451)*	*Q141 (p. 1452)*	*Q142 (p. 1453)*	*Q143 (p. 1453)*	*Q144 (p. 1454)*
Q145 (p. 1455)	*Q146 (p. 1456)*	*Q147 (p. 1457)*	*Q148 (p. 1458)*		

Q1: An alcoholic patient presents with palpitations, dizziness, and syncopal attacks. On examination, irregularly irregular pulse is seen. What will be seen on JVP? (Q866781)

A. Absent a wave

B. Large a wave

C. Canon a wave

D. Steep y descent

Correct Answer: A. Absent a wave

Explanation: The patient’s irregularly irregular pulse suggests atrial fibrillation (AF), which is common in chronic alcoholics (so-called holiday heart syndrome). In AF, the atria do not contract effectively → no coordinated atrial systole → no a wave is produced in the jugular venous pulse (JVP). Therefore, the finding will be absent a wave. Jugular Venous Pulse (JVP) reflects right atrial pressure changes during the cardiac cycle. The a wave corresponds to atrial contraction (just before S1). In AF, there is complete loss of organized atrial contraction → a wave disappears. Chronic alcoholics are prone to AF due to atrial dilation, electrolyte imbalance, and direct myocardial effects. Atrial fibrillation: Feature Details ECG Irregularly irregular RR intervals, absent P waves, fibrillatory baseline Causes Hypertension, valvular heart disease (esp. mitral), alcohol (holiday heart), thyrotoxicosis Complications Stroke, heart failure, tachycardia-induced cardiomyopathy Management Rate control (β-blockers, CCBs), rhythm control (amiodarone, cardioversion), anticoagulation (CHA■DS■-VASc score) JVP Waveform: Positive waves in JVP: a, c and v a wave - Atrium Contraction (Lat Rapid Filling Phase) c wave - Cusp bulging (tricuspid valve cusp bulging towards the atrium) v wave - Venous return Negative waves in JVP: x wave - Atrium relaxation x' wave - Tricuspid valve pulling towards the ventricle y descend - Opening of tricuspid valve JVP finding Cause Absent a wave Atrial fibrillation Large a wave Tricuspid stenosis, pulmonary hypertension Cannon a wave Complete heart block, VT (atria contracting against closed tricuspid valve) Steep y descent Constrictive pericarditis Incorrect Options: Large a wave (Option B) – Seen when the right atrium contracts against high resistance, e.g., tricuspid stenosis or pulmonary hypertension. Canon a wave (Option C) – Occurs when atria contract against a closed tricuspid valve, e.g., complete heart block, VT. Steep y descent (Option D) – Seen in constrictive pericarditis and severe tricuspid regurgitation.

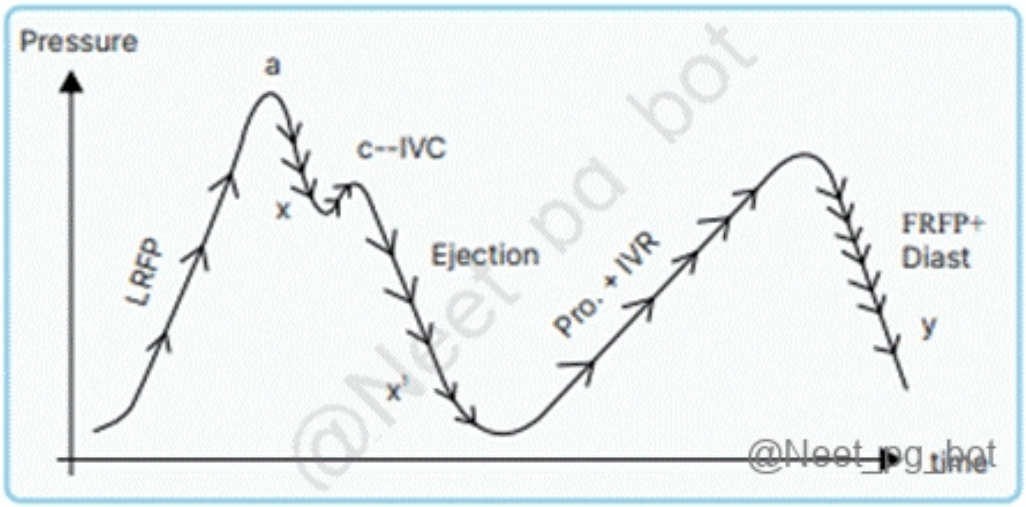

↑ *Back to this question in Part A*

@Neet_pg_bot

Q2: A 25-year-old female with a previous history of rheumatic fever. Examination shows a loud S1 and mid-diastolic murmur is having which of the following valvular heart disease? (Q866784)

A. TS

B. MR

C. MS

D. AR

Correct Answer: C. MS

Explanation: The patient has a history of rheumatic fever and presents with a loud S1 and mid-diastolic murmur, which are classic findings of mitral stenosis. Rheumatic fever is the most common cause of MS worldwide. Mitral stenosis results from thickening and fusion of the mitral valve leaflets, most often due to rheumatic heart disease. The loud S1 occurs because the stiff valve closes forcefully, and the mid-diastolic murmur is due to turbulent flow across the narrowed mitral orifice during diastole. Other features may include an opening snap and signs of pulmonary congestion. Mitral stenosis: Cause: Rheumatic fever (most common), congenital, calcific degeneration (elderly). Pathophysiology: Narrowed mitral orifice → ↑ left atrial pressure → pulmonary venous hypertension → right heart strain. Clinical features: Dyspnea, orthopnea, hemoptysis, atrial fibrillation. Auscultation: Loud S1, opening snap after S2, low-pitched mid-diastolic murmur at the apex (best heard with the patient in the left lateral position). Complications: Pulmonary hypertension, right heart failure, thromboembolism. Treatment: Medical (diuretics, rate control for AF) or surgical (percutaneous balloon mitral valvotomy, valve replacement). Incorrect Options: Tricuspid Stenosis (TS) (Option A) – Mid-diastolic murmur increases with inspiration; usually occurs with MS but isolated TS is rare. Mitral Regurgitation (MR) (Option B) – Produces a pansystolic murmur at the apex radiating to the axilla, not a mid-diastolic murmur. Aortic Regurgitation (AR) (Option D) – Produces an early diastolic decrescendo murmur at the left sternal border, not associated with loud S1.

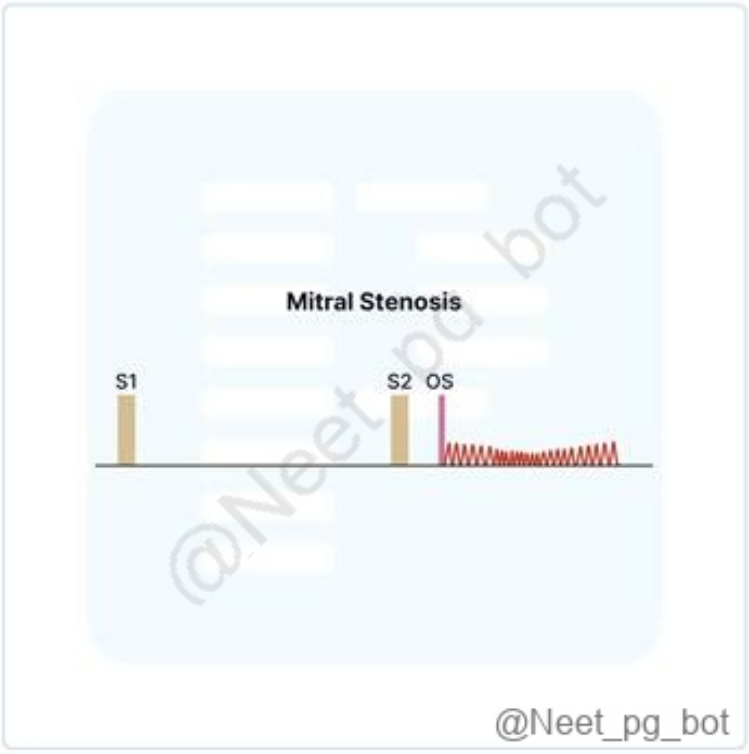

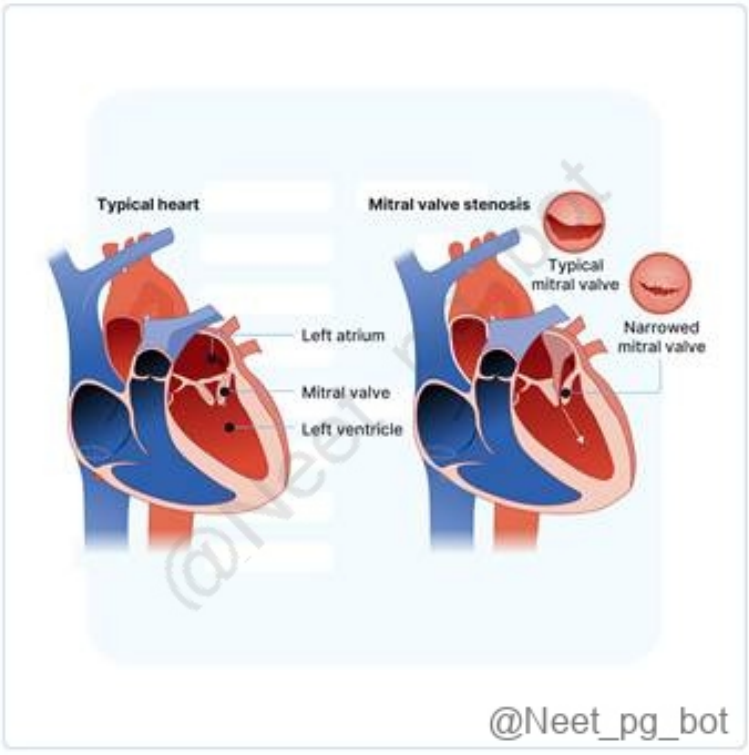

↑ *Back to this question in Part A*

@Neet_pg_bot

Q3: A female patient complains of chest pain while waking up in the morning. Pain is more in winter months. Which of the following best describes this patient? (Q866827)

A. Fixed plaque obstruction

B. Ach-induced coronary vasoconstriction

C. Subendocardial ischemia due to increased demand of myocardium

D. Increased sympathomimetic drive in morning hours

Correct Answer: B. Ach-induced coronary vasoconstriction

Explanation: This presentation is classic for Prinzmetal's (variant) angina , which is due to transient vasospasm of coronary arteries often occurring at rest, particularly in the early morning hours and more frequently in cold weather. Acetylcholine and other vasoconstrictors can trigger the spasm. ECG during pain may show transient ST-segment elevation. Incorrect Options: Fixed plaque obstruction (Option A): Seen in stable angina due to atherosclerosis; pain is usually exertional, not at rest. Subendocardial ischemia due to increased demand of myocardium (Option C): Describes the mechanism in stable angina during exercise or stress, not rest-related vasospasm. Increased sympathomimetic drive in morning hours (Option D): Plays a role in acute coronary syndromes but doesn't fully explain the cold-weather, early-morning, rest-related pain due to vasospasm.

↑ *Back to this question in Part A*

@Neet_pg_bot

Q4: Which type of pulse is based on the Frank-Starling law? (Q865309)

A. Pulsus bisferiens

B. Pulsus paradoxus

C. Pulsus alternans

D. Pulsus parvus

Correct Answer: C. Pulsus alternans

Explanation: Pulsus alternans shows alternating strong and weak pulse beats, often seen in severe left ventricular dysfunction. One proposed mechanism involves the Frank-Starling law , where a weak contraction leads to increased end-diastolic volume, boosting the next beat's strength. This cycle repeats, causing alternating pulse amplitudes. Another theory involves abnormal calcium cycling in cardiac myocytes. The Frank-Starling law of the heart describes the relationship between the volume of blood filling the heart (end-diastolic volume) and the force

of contraction during the next heartbeat (stroke volume) . Mechanism: Preload: Increased venous return leads to increased end-diastolic volume. Myocardial Stretch: Greater end-diastolic volume stretches the myocardial fibers. Force of Contraction: The stretched fibers generate a more forceful contraction due to the optimal overlap of actin and myosin filaments (length-tension relationship). Incorrect Options: Pulsus bisferiens (Option A): Characterised by a double systolic peak; seen in aortic regurgitation or hypertrophic cardiomyopathy—not related to Frank-Starling. Pulsus paradoxus (Option B): An exaggerated decrease in systolic BP during inspiration, typically seen in cardiac tamponade or severe asthma, not explained by Frank-Starling law. Pulsus parvus (Option D): A small, weak pulse seen in aortic stenosis; related to obstruction , not preload or contractility.

References:

Pulsus Alternans - StatPearls - NCBI Bookshelf

Guyton Textbook of Physiology, 14th Edition, Page 123, 124, 245

↑ *Back to this question in Part A*

@Neet_pg_bot

Q5: Mitral stenosis murmur corresponds to which wave of ECG? (Q865310)

A. QRS complex

B. T wave

C. P wave

D. ST segment

Correct Answer: C. P wave

Explanation: ■The murmur of mitral stenosis is a diastolic rumbling murmur that follows the opening snap of the mitral valve. It is best heard at the apex and is associated with left atrial contraction . The P wave on ECG represents atrial depolarization . Since mitral stenosis involves obstruction to left ventricular filling during atrial contraction , the murmur is timed with and follows the P wave . In severe mitral stenosis, a loud first heart sound and presystolic accentuation of the murmur (due to atrial contraction) are commonly observed, directly relating to the P wave . Mitral stenosis (MS) causes left atrial enlargement , which typically appears on ECG as Broad, bifid P waves , especially in lead II → “P mitrale.” P Wave in ECG: Feature Normal P Wave Right Atrial Enlargement (P Pulmonale) Left Atrial Enlargement (P Mitrale) Cause Normal atrial depolarization Pulmonary disease Congenital heart disease Tricuspid valve disorders Mitral valve disease Left ventricular failure Amplitude < 2.5 mm > 2.5 mm (in leads II, III, aVF, sometimes V1) May be increased but less prominent than in RAA Duration < 0.12 sec (120 ms) Normal (< 0.12 sec) Prolonged > 0.12 sec (broad P wave) Shape Smooth, upright Tall, peaked, narrow Notched/bifid ("M"-shaped) in lead II Lead II Appearance Smooth and positive Tall, peaked P wave Notched/bifid P wave Lead V1 Appearance Biphasic (small negative) Deep P wave Biphasic with prominent, prolonged negative terminal

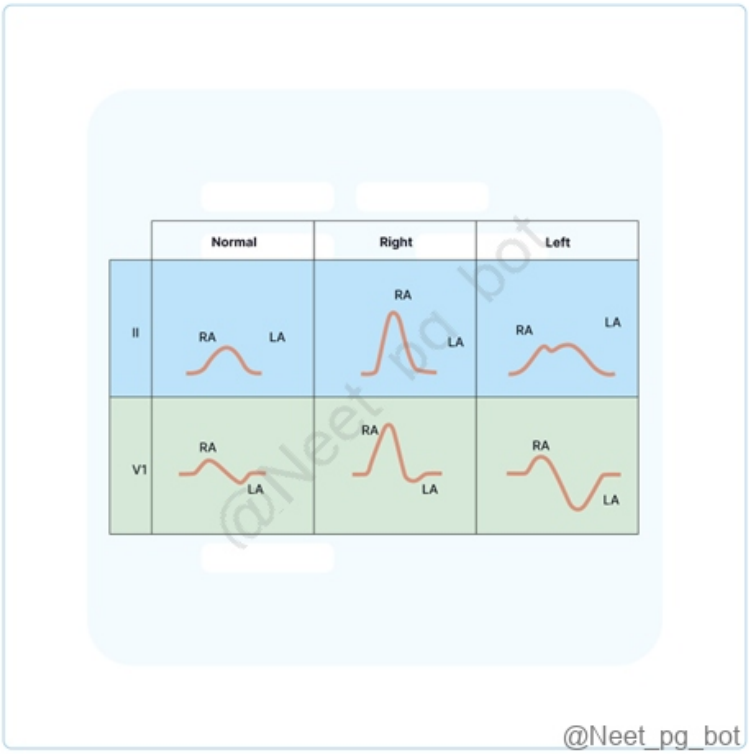

References:

Goldberger's Clinical Electrocardiography, A Simplified Approach, 9th Edition, Page. 50-53.

↑ *Back to this question in Part A*

@Neet_pg_bot

Q6: A 62-year-old male presents with sudden onset of shortness of breath and B/L pedal edema. He is compliant with his antihypertensive medications, and blood pressure is well controlled. ECG reveals an ejection fraction of 60%, concentric left ventricular hypertrophy, left atrial enlargement, and grade 2 diastolic dysfunction. Which of the following is the most appropriate next step to improve his condition? (Q865331)

A. Perform coronary angiography to rule out ischemic cardiomyopathy

B. Initiate loop diuretics and SGLT2 inhibitors for management of HFpEF

C. Start digoxin to enhance myocardial contractility

D. Initiate ivabradine to reduce heart rate and improve diastolic filling

Correct Answer: B. Initiate loop diuretics and SGLT2 inhibitors for management of HFpEF

Explanation: This 62-year-old man presents with sudden shortness of breath and bilateral pedal edema, classic signs of heart failure. His echocardiogram findings show: Ejection fraction (EF) of 60% → Preserved systolic function Concentric left ventricular hypertrophy Left atrial enlargement Grade 2 diastolic dysfunction These findings support a diagnosis of Heart Failure with Preserved Ejection Fraction (HFpEF), which is often related to diastolic dysfunction, especially in older adults with hypertension-induced hypertrophy. Loop diuretics (e.g., furosemide) help relieve volume overload symptoms like dyspnea and edema. SGLT2 inhibitors (e.g., empagliflozin, dapagliflozin) have been shown in recent trials to reduce hospitalization and improve quality of life in HFpEF , regardless of diabetes status . This is the most appropriate and guideline-recommended management . Types of heart failure: HFrEF: Systolic dysfunction, may present acutely. HFpEF: Diastolic dysfunction, usually present as chronic heart failure. Management of CHF: First line drugs used in chronic Heart failure: (mortality-reducing drugs) ARBs/ACE-Inhibitors Beta blockers (2nd gen- cardioselective) SGLT-2 inhibitors (Dapagliflozin, Empagliflozin) Anti-aldosterone (Spironolactone) Acute cases with Pulmonary edema: Oxygen: Secure airway and supplement O2 Loop diuretics: IV Furosemide 20-80 mg , reduces preload and systemic venous congestion IV Morphine: if patient is in severe pain/distress, can cause respiratory depression IV Nitroglycerin infusion: reduce afterload Acute decompensated with cardiogenic shock: (low BP) Vasopressors: Norepinephrine, Dobutamine, Dopamine Inodilators: Milrinone & Amrinone Levosimendan: Ca2+ channel sensitizer Omecamtiv mecarbil: Direct myosin activator Non-pharmacological treatment: Implantable cardioverter defibrillators (ICD) Coronary revascularisation: in Coronary artery disease patients Ventricular assist devices Cardiac transplantation Incorrect Options: Perform coronary angiography to rule out ischemic cardiomyopathy (Option A): Coronary angiography is appropriate if ischemic heart disease is strongly suspected. However, this patient has preserved EF and concentric LVH , which more strongly points toward hypertensive heart disease and HFpEF , not ischemic cardiomyopathy. This is not the most appropriate first step . Start digoxin to enhance myocardial contractility (Option C): Digoxin is not indicated in HFpEF, especially when EF is preserved and there is no indication of systolic dysfunction or atrial fibrillation needing rate control. It is not helpful here. Initiate ivabradine to reduce heart rate and improve diastolic filling (Option D): Ivabradine is indicated in HFrEF with EF ≤35% and sinus rhythm with heart rate ≥70 bpm , despite beta-blockers. It does not have a proven role in HFpEF .

References:

Davidson’s Principles & Practice of Medicine, 24th Edition, Pages- 464-468

↑ *Back to this question in Part A*

@Neet_pg_bot

Q7: Which of the following is not a symptom of cardiac failure? (Q865338)

A. Right hypochondriac pain

B. Non-pulsatile elevation of JVP

C. Orthopnea

D. Paroxysmal nocturnal dyspnea

Correct Answer: B. Non-pulsatile elevation of JVP

Explanation: Cardiac failure (heart failure) presents with a range of symptoms depending on whether it is right-sided, left-sided, or both. Elevated JVP is a feature of right-sided heart failure , but it is typically pulsatile , reflecting right atrial pressure transmitted through the jugular vein. Non-pulsatile JVP elevation suggests an alternative cause like superior vena cava (SVC) obstruction , not heart failure. Congestive Heart Failure - Clinical Features Cardiac output decreased Stroke volume decreased Heart rate increased Increased sympathetic drive leading to palpitations and diaphoresis Orthopnea Paroxysmal nocturnal dyspnea Clinical Features of Left-Sided vs. Right-Sided Congestive Heart Failure (CHF) Left-Sided Heart Failure Right-Sided Heart Failure Causes : Ischemic heart disease (myocardial infarction). Hypertension Dilated cardiomyopathy. Aortic or mitral valve disease. Causes : Left-sided heart failure (most common cause). Chronic lung diseases (COPD, pulmonary hypertension). Pulmonary embolism. Right ventricular infarction. In left-sided heart failure, the left ventricle cannot effectively pump blood to the body, leading to a backup of blood into the lungs. Clinical features: This primarily results in pulmonary symptoms. Dyspnea Exertional dyspnea). Orthopnea Paroxysmal nocturnal dyspnea Pulmonary Congestion: Crackles (rales) heard on auscultation due to fluid in the alveoli. Cough Wheezing (cardiac asthma). Fatigue and Weakness Decreased Exercise Tolerance Limited physical activity due to breathlessness and fatigue. S3 Gallop Cool Extremities: Reduced cardiac output may cause poor peripheral circulation, leading to cold, pale skin. In right-sided heart failure, the right ventricle fails to pump blood effectively into the pulmonary circulation, leading to systemic venous congestion. It is often secondary to left-sided heart failure or conditions affecting the lungs (cor pulmonale). Clinical Features: Peripheral Edema Jugular Venous Distension (JVD) Hepatomegaly B/L pitting pedal edema Kussmaul sign: JVP elevation on inspiration Ascites Nocturia Weight Gain Anorexia and Nausea Incorrect Options: Right hypochondriac pain (Option A) is a symptom of right-sided heart failure due to liver congestion. Orthopnea (Option C) is a classic symptom of left-sided heart failure, caused by pulmonary congestion when lying flat. Paroxysmal nocturnal dyspnea (PND) (Option D) is a common symptom of left-sided heart failure, due to fluid redistribution at night causing sudden breathlessness.

References:

www.ncbi.nlm.nih.gov/books/NBK430873/

↑ *Back to this question in Part A*

@Neet_pg_bot

Q8: A 45-year-old male presents to a PHC for a routine check-up. His blood pressure readings on two separate occasions are 148/90 mmHg and 152/96 mmHg. He is asymptomatic and has no known comorbidities. What is the most appropriate next step in management according to current hypertension guidelines? (Q865381)

A. Initiate treatment only if BP exceeds 160/100 mmHg

B. Start Amlodipine 5 mg once daily and advise follow-up in 1 month

C. Refer to a higher center for further evaluation

D. Start the patient on IV anti-hypertensive drugs

Correct Answer: B. Start Amlodipine 5 mg once daily and advise follow-up in 1 month

Explanation: The patient is in Stage 1 Hypertension (140–159/90–99 mmHg) confirmed on two occasions , and since no compelling comorbidities are present, monotherapy with a calcium channel blocker (e.g., Amlodipine) is an appropriate first-line treatment. Follow-up in 1 month is standard to assess BP response and adherence. ACC/AHA Guidelines for Hypertension Management Indications for Use of antihypertensives Secondary prevention of recurrent CVD events in patients with clinical CVD (defined as CHD, CHF, stroke) and BP ≥130/≥80 mmHg Primary prevention in patients with an estimated 10-year ASCVD risk ≥10% and BP ≥130/≥80 mmHg Primary prevention of CVD and low CVD risk in patients with BP ≥140/ ≥90 mmHg Blood Pressure Goal in Treating Hypertension BP target < 130/80 mmHg for adults with confirmed hypertension and known CVD or 10-year ASCVD event risk ≥10% Exceptions to Therapeutic Target of <130/80 mmHg Age >80 years Blood pressure <140/90 mmHg in previously untreated hypertensive patients who experience an ischemic stroke or TIA Acute therapy for most hypertensive urgencies and emergencies Abbreviations: ASCVD - atherosclerotic cardiovascular disease CHD - coronary heart disease CHF - congestive heart failure CVD - cardiovascular disease Patient type First Drug Add a Second Drug If Needed to Achieve the target BP If a Third Drug is Needed to Achieve the target BP Black patients (African ancestry): All ages CCB or thiazide diuretic ARB or ACE inhibitor Combination of CCB + ACE inhibitor or ARB + thiazide diuretic White and other non-black Patients: Younger than 60 years ARB or ACE inhibitor CCB or thiazide diuretic White and other non-black patients: 60 years and older CCB or thiazide diuretic ARB or ACE inhibitor Abbreviations: CCB - Calcium channel blocker ACE - Angiotensin converting enzyme ARB - Angiotensin receptor blocker Hypertension with other associated conditions Initial drug of choice Hypertension and diabetes ARB or ACE inhibitor Hypertension and chronic kidney disease ARB or ACE inhibitor Note: in black patients, good evidence for the renal protective effects of ACE inhibitors Hypertension and clinical coronary artery disease β-Blocker plus ARB or ACE inhibitor Hypertension and stroke history ARB or ACE inhibitor Hypertension and heart failure Regardless of blood pressure, ARB or ACE inhibitor + β-blocker + diuretic + spironolactone. A dihydropyridine CCB can be added if needed for BP control. Pneumonic: ABDS Incorrect Options: Initiate treatment only if BP exceeds 160/100 mmHg (Option A): Older guidelines used this threshold for initiating therapy in asymptomatic patients without comorbidities, but current guidelines recommend starting antihypertensive therapy at ≥140/90 mmHg if confirmed on two separate occasions, even in low-risk individuals. Lifestyle changes + medications are appropriate here. Refer to a higher center for further evaluation (Option C): There is no need for referral at this point. The patient has uncomplicated hypertension and can be managed at the primary health center (PHC) level with basic antihypertensive therapy and lifestyle advice. Start the patient on IV anti-hypertensive drugs (Option D): IV antihypertensives are used for hypertensive emergencies (e.g., BP >180/120 mmHg with end-organ damage). This patient is stable and asymptomatic, with no signs of acute target organ damage — oral therapy is appropriate.

References:

Harrison’s Principle of Internal Medicine, Edition 21st- Page 2082

↑ *Back to this question in Part A*

@Neet_pg_bot

Q9: A 30 year old man with 6 month past history of PND and SOB. On examination, JVP is elevated with irregularly irregular pulse and tender hepatomegaly and MDM. past medical history of ARF. Which of the following is not seen in this patient? (Q866488)

A. Presystolic accentuation of mid-diastolic murmur is hallmark feature

B. Patient has increased risk of embolic stroke

C. Absent a wave in JVP

D. Right heart failure

Correct Answer: A. Presystolic accentuation of mid-diastolic murmur is hallmark feature

Explanation: Presystolic accentuation of a mid-diastolic murmur occurs in mitral stenosis with sinus rhythm due to atrial contraction just before systole. This patient has atrial fibrillation (irregularly irregular pulse and absent a wave in JVP), which abolishes the presystolic accentuation because there is no coordinated atrial contraction . Patient has increased risk of embolic stroke (Option B): AF increases the risk of left atrial thrombus and systemic embolism. Absent a wave in JVP (Option C): AF abolishes the a wave due to loss of organized atrial contraction. Right heart failure (Option D): Long-standing MS → pulmonary venous hypertension → pulmonary arterial hypertension → RV hypertrophy/dilatation → systemic venous congestion and signs of right-sided failure (tender hepatomegaly, elevated JVP, peripheral edema).

↑ *Back to this question in Part A*

@Neet_pg_bot

Q10: A patient presents with palpitations and an irregularly irregular pulse. He presents within 2 hours of symptom onset, and has no history of diabetes or other comorbidities. What is the most appropriate initial management? (Q866489)

A. TEE for starting anticoagulation

B. Cardioversion

C. Control ventricular rate with verapamil

D. Wait and watch

Correct Answer: C. Control ventricular rate with verapamil

Explanation: In symptomatic atrial fibrillation, initial priority is to control the ventricular rate to improve hemodynamics and relieve symptoms Even though AF is of recent onset (<48 hours) and cardioversion could be

considered, rate control is often performed first unless the patient is unstable (hypotension, shock, ongoing ischemia, severe heart failure). Verapamil , a non-dihydropyridine calcium channel blocker, slows AV nodal conduction, reducing ventricular rate and improving cardiac output. Atrial Fibrillation Features Characterized by abnormal automatic firing and multiple re-entry circuits. Atria beat rapidly and ineffectively; ventricles activated irregularly Produces an "irregularly irregular" pulse Palpitations, syncope, and breathlessness can be present Asymptomatic AF: Can present as systemic embolism and stroke ECG Features QRS Complexes: Irregular but normal P Waves: Absent; baseline may show irregular fibrillation waves Ventricular Rate: Fast at onset (120-160 beats/min) Slower in chronic AF due to medication effects and AV nodal fatigue Management Paroxysmal Atrial Fibrillation First-line Therapy: Beta-blockers are effective in patients with CAD, hypertension, and heart failure. Class Ic Drugs: Propafenone or flecainide to prevent episodes (not for patients with CAD or LV dysfunction). Class III Drugs: Amiodarone : Most effective but with significant side effects; used when other treatments fail. Dronedarone : Alternative to amiodarone; contraindicated in heart failure. Rate Control: Digoxin and verapamil for AV node conduction slowing, but not for AF prevention. Catheter Ablation: Considered for patients with drug-resistant AF; prevents AF in ~75% of cases but may have complications. Persistent Atrial Fibrillation Rhythm Control : Cardioversion : Electrical or pharmacological (e.g., intravenous flecainide or amiodarone). Timing: Immediate if AF <48 hours; anticoagulation required if AF ≥48 hours. Prophylactic Amiodarone : To reduce recurrence risk. Rate Control : Medications: Digoxin, β-blockers, or rate-limiting calcium antagonists (verapamil, diltiazem) . Combination Therapy: Digoxin with β-blockers ; avoid combining calcium antagonists with β-blockers. Pace and Ablate: Permanent pacemaker with AV nodal block for symptomatic AF. Thromboprophylaxis Anticoagulation: Required for stroke prevention due to blood stasis in the left atrium. Warfarin : INR target of 2.0–3.0; start 4 weeks prior to cardioversion. DOACs: Rivaroxaban, apixaban, edoxaban, and dabigatran as alternatives to warfarin; no monitoring needed. Risk Assessment: CHA2DS2-VASc Score : For stroke risk; anticoagulate if score ≥2 . HAS-BLED Score: For bleeding risk; monitor patients with score ≥3. Aspirin: Not recommended due to low efficacy in preventing embolic stroke. CHA2DS2-VASc stroke risk scoring system for AF Points Parameters Score C Congestive heart failure 1 H Hypertension history 1 A2 Age (≥75 years) 2 D Diabetes mellitus 1 S2 Previous stroke or transient ischemic attack (TIA) 2 V Vascular disease 1 A Age (65-74 years) 1 Sc Sex category (female) 1 Maximum total score 9 points TEE for starting anticoagulation (Option A): This is indicated if AF duration is >48 hours or unknown, to exclude thrombus before starting anticoagulation. Cardioversion (Option B): Rhythm control is generally attempted after rate control and stabilization, unless there’s severe instability. Wait and watch (Option D): Passive observation is inappropriate in symptomatic AF; early intervention to control rate is required.

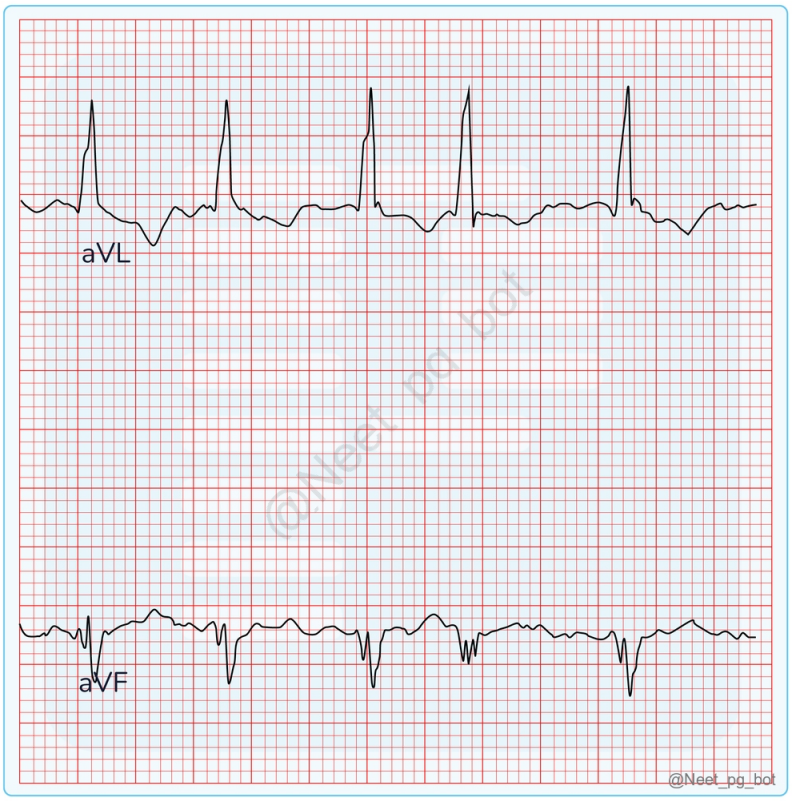

References:

.

↑ *Back to this question in Part A*

@Neet_pg_bot

Q11: A patient presents with frothy sputum, dyspnea, and paroxysmal nocturnal dyspnea (PND) and subsequently dies. Autopsy lung histopathology shows hemosiderin-laden macrophages. Which of the following is least likely to occur in this patient? (Q866493)

A. Volume overload

B. RV failure

C. Pulmonary vein obstruction

D. Protein losing enteropathy

Correct Answer: D. Protein losing enteropathy

Explanation: The clinical features of frothy sputum, dyspnea, and PND , along with hemosiderin-laden macrophages on lung histopathology, are classical for chronic passive pulmonary congestion due to left-sided heart failure . The macrophages (also called “heart failure cells”) contain hemosiderin derived from repeated alveolar hemorrhage secondary to chronically elevated pulmonary venous pressure. Protein-losing enteropathy (PLE) is caused by chronic intestinal lymphatic congestion , most commonly seen in: Constrictive pericarditis Severe chronic right-sided heart failure Intestinal lymphangiectasia PLE is not a direct or typical consequence of isolated left-sided heart failure with pulmonary congestion , and it does not explain the lung pathology described. Therefore, it is the least likely finding in this patient. Volume overload (Option A): Left-sided heart failure leads to reduced cardiac output and activation of the renin–angiotensin–aldosterone system (RAAS) , resulting in sodium and water retention . Hence, volume overload is a common and expected finding. Right ventricular failure (Option B): Chronic elevation of pulmonary venous pressure causes pulmonary arterial hypertension , leading to right ventricular hypertrophy and eventual right ventricular failure (secondary cor pulmonale) . Thus, RV failure can occur as a downstream consequence of chronic left-sided heart failure. Pulmonary venous obstruction (Option C): Although not a mechanical obstruction, elevated left atrial pressure (as seen in LV dysfunction or mitral valve disease) produces a functional pulmonary venous outflow obstruction , resulting in pulmonary congestion and hemosiderin-laden macrophages.

References:

↑ *Back to this question in Part A*

@Neet_pg_bot

Q12: A female patient comes to the ER with palpitations and syncopal attacks following exercise. She has had similar episodes in the past. An ECG was performed as follows. What is the most probable diagnosis? {{caption_text}} (Q853362)

A. Uhl's disease

B. Arrhythmogenic Right Ventricular Dysplasia

C. Hypertrophic Cardiomyopathy

D. Brugada's syndrome

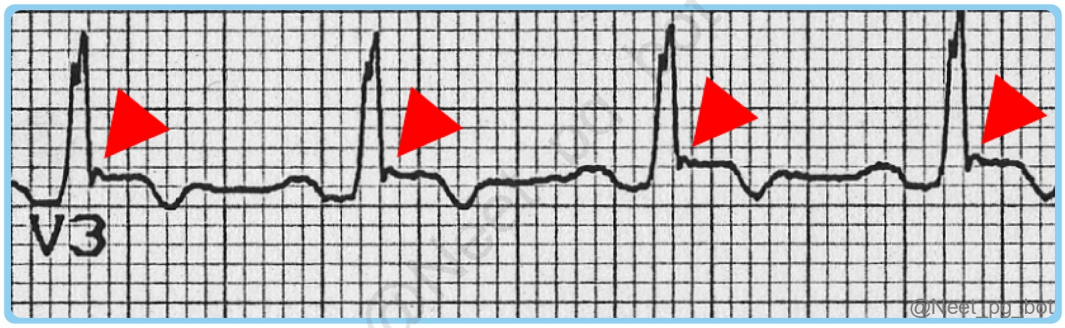

Correct Answer: B. Arrhythmogenic Right Ventricular Dysplasia

Explanation: The patient's symptoms of palpitations, syncope following exercise, and a suggestive ECG pattern are characteristic of Arrhythmogenic Right Ventricular Dysplasia (ARVD) , a condition that often leads to arrhythmias and sudden cardiac death, particularly in young, athletic individuals. Arrhythmogenic Right Ventricular Dysplasia (ARVD) is an inherited cardiac disorder characterized by the progressive replacement of the right ventricular myocardium with fibrofatty tissue, leading to arrhythmias, particularly ventricular tachycardia and sudden cardiac death. It primarily affects the right ventricle but can involve the left ventricle as well. Etiology Mutations in genes encoding desmosomal proteins (e.g., PKP2, DSP, DSG2, JUP). Clinical Features Palpitations Syncope Exercise-induced arrhythmias Sudden cardiac death, Particularly in young, athletic individuals. Diagnostic Findings Electrocardiogram (ECG): Ventricular arrhythmias, especially ventricular tachycardia. Epsilon waves on ECG (specific to ARVD). Echocardiography: May show right ventricular dilation and dysfunction. Cardiac MRI: Shows fibrofatty infiltration of the right ventricle. Family history: Key in diagnosing genetic basis. Diagnostic Criteria Based on the Task Force Criteria, which include: ECG abnormalities, arrhythmias, imaging findings, and histological evidence. Pathological criteria: Fibrofatty infiltration of the right ventricle. Management Antiarrhythmic drugs Implantable cardioverter-defibrillator (ICD): For preventing sudden cardiac death in high-risk patients. Heart transplantation: In severe cases with progressive heart failure. Uhl's disease (Option A): Also affects the right ventricle but lacks the hallmark epsilon waves and T-wave inversions. Hypertrophic Cardiomyopathy (Option C): More commonly presents with asymmetric septal hypertrophy and deep Q waves, not epsilon waves. Brugada’s Syndrome (Option D): Characterized by ST-segment elevation in V1–V3, not epsilon waves.

References:

Harrison's Principles of Internal Medicine, 21st Edition, Page 1916.

↑ *Back to this question in Part A*

@Neet_pg_bot

Q13: Which of the following is associated with a Graham-Steel murmur? (Q852672)

A. Ventricular septal defect (VSD)

B. Hypertrophic obstructive cardiomyopathy (HOCM)

C. Pulmonary regurgitation

D. Aortic regurgitation

Correct Answer: C. Pulmonary regurgitation

Explanation: The Graham-Steel murmur indicates pulmonary regurgitation secondary to pulmonary hypertension. This early diastolic decrescendo murmur is heard best at the left upper sternal border (pulmonic area) and is caused by the backward flow of blood from the pulmonary artery into the right ventricle during diastole. It is specifically associated with pulmonary hypertension, which causes dilation of the pulmonary artery and subsequent incompetence of the pulmonary valve. Cardiac Murmurs and Their Characteristics Common Pathological Murmurs Condition Murmur Characteristics Mitral Stenosis Low-pitched diastolic murmur with an opening snap,

best heard at the apex Aortic Stenosis Crescendo-decrescendo systolic ejection murmur, radiates to carotids, best heard at the right upper sternal border Patent Ductus Arteriosus (PDA) Continuous, machine-like murmur, best heard at the left infraclavicular area Hypertrophic Cardiomyopathy (HOCM) (Option B) Harsh systolic murmur with a crescendo-decrescendo pattern, best heard at the left sternal border, increases with Valsalva maneuver Mitral Regurgitation (MR) Holosystolic murmur, best heard at the apex, radiates to the axilla Aortic Regurgitation (AR) Early diastolic decrescendo murmur, best heard at the left sternal border Ventricular Septal Defect (VSD) (Option A) Harsh holosystolic murmur, best heard at the left lower sternal border (LLSB) Atrial Septal Defect (ASD) Systolic ejection murmur, best heard at the left upper sternal border (LUSB), with fixed, widely split S2 Tricuspid Regurgitation (TR) Holosystolic murmur, best heard at the left lower sternal border, increases with inspiration (Carvallo's sign) Special Murmurs & Their Associations Murmur Cause & Characteristics Graham-Steel Murmur (Pulmonary Regurgitation due to Pulmonary Hypertension) Early diastolic decrescendo murmur, best heard at the left upper sternal border, caused by pulmonary valve incompetence due to pulmonary hypertension Austin Flint Murmur (Severe Aortic Regurgitation) (Option D) Low-pitched, rumbling diastolic murmur, best heard at the apex, due to turbulent flow in the left ventricle compressing the mitral valve Mammary Murmur (Physiologic in Pregnancy) Continuous hissing murmur, heard over the left second and third intercostal spaces, caused by increased blood flow through internal mammary vessels

References:

Harrison's Principles of Internal Medicine, 21st Edition, Page 1992

↑ *Back to this question in Part A*

@Neet_pg_bot

Q14: A 65-year-old male with chronic stable angina presents with worsening chest pain during routine activities. His current medications include aspirin, clopidogrel, metoprolol, and atorvastatin, but his symptoms persist. ECG shows ST-segment depression in V5-V6, and coronary angiography reveals 80% stenosis of the left anterior descending (LAD) artery. What is the most appropriate intervention? (Q852747)

A. Increase the dose of beta-blockers

B. Add Ranolazine

C. Percutaneous coronary intervention (PCI) with drug-eluting stent (DES)

D. Refer for coronary artery bypass grafting (CABG)

Correct Answer: C. Percutaneous coronary intervention (PCI) with drug-eluting stent (DES)

Explanation: The patient has: Significant LAD stenosis (80%) Persistent angina despite optimal medical therapy Evidence of ischemia (ST depression) This fulfills the indication for revascularization . For isolated, proximal LAD stenosis with persistent symptoms, PCI with DES is the preferred intervention because: It relieves symptoms

Improves quality of life DES has a lower restenosis rate than bare-metal stents Increase the dose of beta-blockers (Option A): Already on optimal therapy; dose change won't fix an 80% LAD block. Add Ranolazine (Option B): Add-on drug only; angiography already shows severe LAD stenosis → needs PCI. Refer for coronary artery bypass grafting (CABG) (Option D): Reserved for left main or multivessel disease; this is isolated LAD → PCI preferred.

References:

Harrison's Principles of Internal Medicine, 21st Edition, Pages 2041-2045

↑ *Back to this question in Part A*

@Neet_pg_bot

Q15: A 72 y/o woman presents with severe chest pain and shortness of breath after a stressful argument. She is post-menopausal with no history of heart disease. O/E, she is slightly tachycardic with normal blood pressure. An echocardiogram shows left ventricular ballooning during systole, and cardiac enzymes are minimally elevated. What is the most likely diagnosis? (Q852748)

A. Hypertensive Heart Disease

B. Takotsubo Cardiomyopathy

C. Coronary Artery Disease

D. Pulmonary Embolism

Correct Answer: B. Takotsubo Cardiomyopathy

Explanation: Takotsubo cardiomyopathy, also known as broken heart syndrome, is characterized by transient left ventricular dysfunction often triggered by emotional or physical stress . The patient's recent stressful event, post-menopausal status, ballooning of the left ventricle, and minimal elevation of cardiac enzymes align perfectly with this diagnosis. Takotsubo cardiomyopathy (Gebrochenes-Herz syndrome) About Takotsubo cardiomyopathy, also known as broken-heart syndrome or stress-induced cardiomyopathy, is a non-ischemic condition primarily affecting post-menopausal women. It features temporary left ventricular dysfunction that resembles a heart attack but with minimal cardiac enzyme release and no significant obstructive coronary artery disease. The name "Takotsubo" is derived from Japanese, meaning octopus trap, reflecting the ballooning shape of the left ventricle during contraction. Pathophysiology Catecholamine Hypothesis: Elevated catecholamines (norepinephrine, epinephrine, dopamine) indicate stress-induced sympathetic overdrive, leading to microvascular spasms and myocardial injury. Microvascular Dysfunction: Impaired function is suggested by abnormalities in coronary flow reserve and microvascular resistance. Inflammation: Imaging may show myocardial oedema, necrosis, and fibrosis, with conditions like myocarditis and autoimmune diseases potentially triggering TC. Estrogen Deficiency: Exaggerated vasoconstriction and increased sympathetic activity in post-menopausal women contribute to TC. Clinical features Takotsubo cardiomyopathy often mimics acute coronary syndrome.(MI)

Common Triggers: Emotional Stress: Events like the unexpected death of a loved one, domestic abuse, or financial loss. Physical Stress: Serious medical diagnoses or natural disasters. Symptoms: Chest pain, dyspnea, and syncope. Some patients may have signs of heart failure, such as tachyarrhythmias or bradyarrhythmias. A late-peaking systolic murmur may be present due to LVOTO. About 10% of patients may develop cardiogenic shock. Hypertensive Heart Disease (Option A): Caused by chronic high blood pressure, leading to left ventricular hypertrophy. This patient's history does not indicate long-standing hypertension. Coronary Artery Disease (Option C): Involves plaque buildup in coronary arteries, causing reduced blood flow. The absence of obstructive disease on angiography and minimal enzyme release suggests this is unlikely. Pulmonary Embolism (Option D): Occurs when a blood clot blocks a pulmonary artery, leading to sudden shortness of breath and chest pain. History of long term immobilization/ DVT is present. The patient's findings indicate a cardiac issue, not a pulmonary one.

References:

Harrison’s Principles of Internal Medicine, 21st Edition, Page 1966

Takotsubo Cardiomyopathy - StatPearls - NCBI Bookshelf

↑ *Back to this question in Part A*

@Neet_pg_bot

Q16: A 68-year-old man with long-standing hypertension presents to the emergency department with severe chest pain, profuse sweating, and marked tachycardia. He appears acutely ill and hypotensive. His ECG finding is given below. What is the most appropriate immediate management? (Q852749)

A. Amiodarone

B. Radiofrequency catheter ablation

C. Digoxin

D. Synchronized cardioversion



Correct Answer: D. Synchronized cardioversion

Explanation: The patient's clinical presentation with the ECG showing saw-tooth flutter waves indicative of atrial flutter He is hemodynamically unstable which necessitates immediate synchronized cardioversion . Cardioversion restores sinus rhythm rapidly and prevents further hemodynamic collapse Amiodarone (Option A) : Slow-acting antiarrhythmic; not suitable for immediate stabilization in an unstable patient. Radiofrequency catheter ablation (Option B): Definitive long-term treatment for atrial flutter, but not done in emergencies. Digoxin (Option C): Used for rate control in stable patients; acts slowly and cannot stabilize an unstable rhythm

References:

Harrison’s Principles of Internal Medicine, 21st Edition, Page 1899-1902

Davidson’s Principles and Practice of Medicine, 24th Edition, Page 470

Atrial Flutter - StatPearls - NCBI Bookshelf

↑ *Back to this question in Part A*

@Neet_pg_bot

Q17: A 58-year-old woman comes to the clinic for a routine follow-up. She has a history of mild hypertension, which is well-controlled with medication. She reports no symptoms such as palpitations, dizziness, or chest pain. An ECG of the patient is given below. What is the most likely diagnosis based on the ECG findings? {{caption_text}} (Q852750)

A. Second-Degree AV Block

B. First-Degree AV Block

C. Third-Degree AV Block

D. Bundle Branch Block

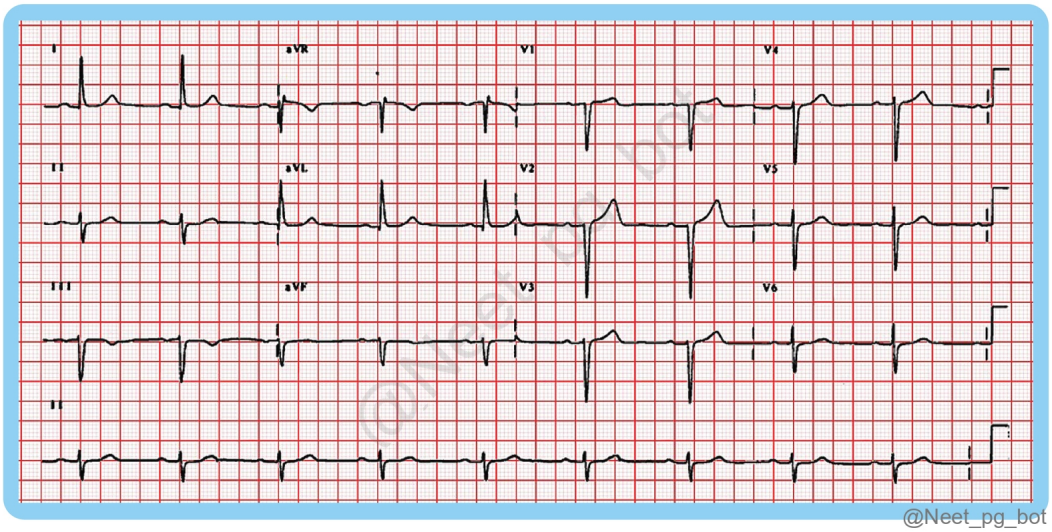

Correct Answer: B. First-Degree AV Block

Explanation: The ECG shows a prolonged PR interval (>0.20 seconds) but consistently conducts P waves to QRS complexes, indicating first-degree AV block. There are no dropped beats, ruling out higher-degree blocks. Second-Degree AV Block (Option A): This block features progressive lengthening of the PR interval followed by a dropped QRS complex, which is absent in this ECG as there are no dropped beats. Third-Degree AV Block (Option C): Here, there is complete dissociation between P waves and QRS complexes. This is absent in the ECG since P waves are consistently followed by QRS complexes. {{caption_text}} Bundle Branch Block (Option D): This condition shows a wide QRS complex with characteristic morphology. This feature is absent in the ECG, where the QRS complexes are normal in width and shape

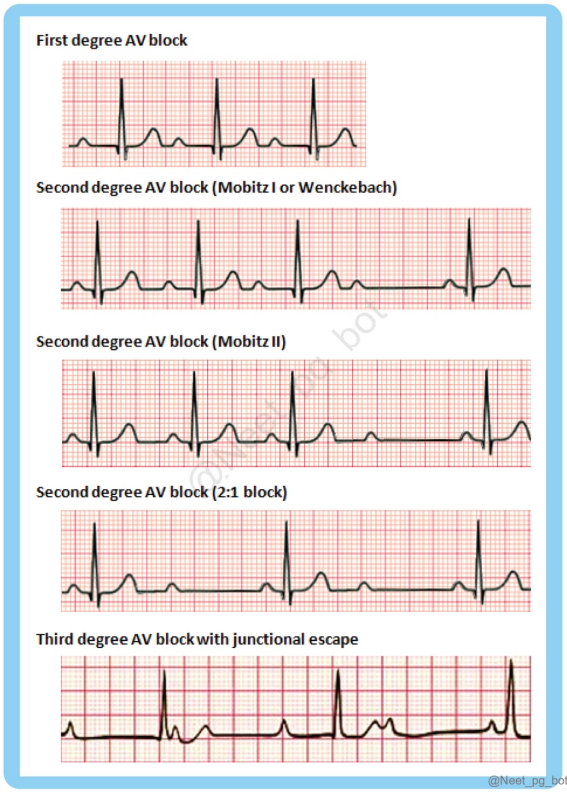

References:

Harrison's Principles of Internal Medicine, 21st Edition, Page 1881

First-Degree Heart Block - StatPearls - NCBI Bookshelf

1st degree heart block: Causes, symptoms, and treatment

↑ *Back to this question in Part A*

@Neet_pg_bot

Q18: A patient of CKD has tachycardia. An ECG is taken and shown below. What's the most likely diagnosis? (Q844166)

A. Hyperkalemia

B. Hypokalemia

C. Hypercalcemia

D. Hypocalcemia

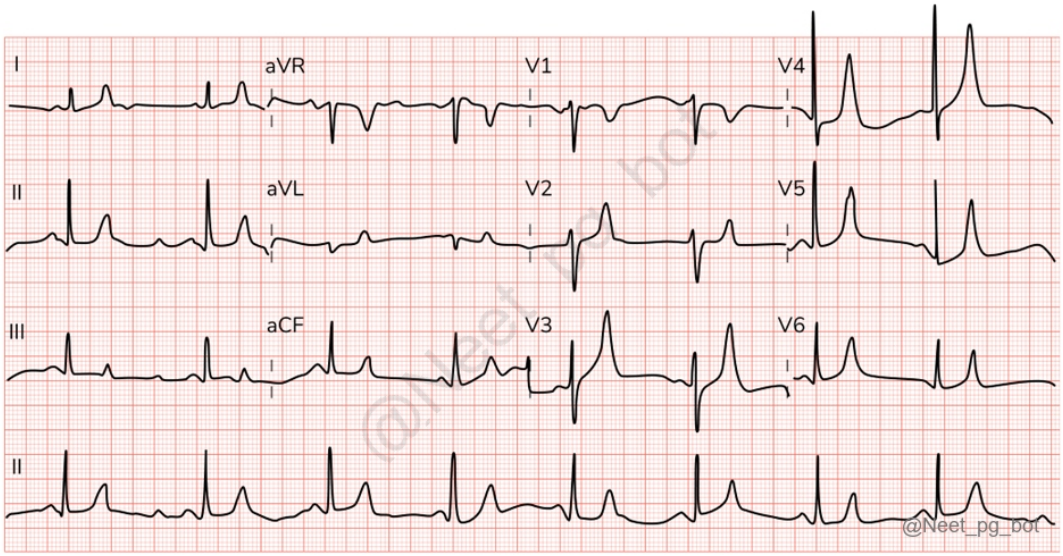

Correct Answer: A. Hyperkalemia

Explanation: Correct Option A - Hyperkalemia: C hronic kidney disease (CKD) often leads to electrolyte imbalances due to impaired kidney function. Hyperkalemia is one such common imbalance, which can have significant effects on cardiac function. ECG Findings in Hyperkalemia: Tall, peaked T waves Widened QRS complexes Prolonged PR interval Flattening or absence of P waves Eventually, this can lead to a sine-wave pattern and ventricular fibrillation if untreated. These ECG changes are characteristic of hyperkalemia, particularly in the setting of CKD, where the kidneys are unable to excrete potassium effectively. Incorrect Options: Option B - Hypokalemia: ECG findings typically include U waves, flattened or inverted T waves, and prolonged QT interval. Option C - Hypercalcemia: ECG may show a shortened QT interval. Option D - Hypocalcemia: ECG may show a prolonged QT interval.

References:

.

↑ *Back to this question in Part A*

@Neet_pg_bot

Q19: A 60-year-old lady presents with SOB and angina pectoris episodes. Work up shows aortic stenosis. Which of the following is the reason behind these chest pain episodes? (Q844172)

A. Increased pressure in aorta

B. Decreased pressure in aorta

C. Increased oxygen consumption in heart

D. Increase in volume overload of heart

Correct Answer: C. Increased oxygen consumption in heart

Explanation: Correct Option C - Increased oxygen consumption in the heart: Aortic Stenosis and Angina: In aortic stenosis, the narrowed aortic valve obstructs blood flow from the left ventricle to the aorta. This obstruction increases the left ventricular pressure as the heart must work harder to overcome the resistance, leading to left ventricular hypertrophy (LVH). The hypertrophied myocardium increases oxygen demand but, due to the narrowed valve, coronary perfusion is compromised, especially during diastole. This imbalance between increased oxygen demand and reduced supply leads to myocardial ischemia and angina. Incorrect Options: Option A - Increased pressure in the aorta: This is not the primary cause of angina. The pressure increases in the left ventricle, not in the aorta. Option B - Decreased pressure in the aorta: While aortic pressure may be lower during ejection, this is not the direct cause of angina. Option D - Increase in volume overload of the heart: Volume overload is more associated with conditions like mitral regurgitation or heart failure, not typically with the chest pain in aortic stenosis.

↑ *Back to this question in Part A*

@Neet_pg_bot

Q20: Patient presents with features of right heart failure and exhibits a rapid Y descent on cardiac examination. What is the most likely diagnosis? (Q844245)

A. Constrictive pericarditis

B. Cardiac tamponade

C. Pulmonary hypertension

D. Right ventricular infarction

Correct Answer: A. Constrictive pericarditis

Explanation: Correct Option A - Constrictive Pericarditis: Constrictive pericarditis is a condition where the pericardium becomes thickened and fibrotic, leading to impaired filling of the heart, particularly the right side. A rapid Y descent on jugular venous pressure (JVP) is a classic finding in constrictive pericarditis, reflecting rapid early diastolic filling of the ventricle due to the rigid pericardium. The patient may present with signs of right heart failure, such as peripheral edema, ascites, and hepatomegaly. Incorrect Options: Option B - Cardiac Tamponade: Cardiac tamponade typically presents with a blunted or absent Y descent on JVP tracing due to the equalization of pressures during diastole, which restricts ventricular filling. The presence of a rapid Y descent makes cardiac tamponade less likely. Option C - Pulmonary Hypertension: Pulmonary hypertension can cause right heart failure, but it is not associated with a rapid Y descent on JVP. The JVP findings in pulmonary hypertension are usually more related to elevated pressure rather than specific waveforms like a rapid Y descent. Option D - Right Ventricular Infarction: Right ventricular infarction can present with signs of right heart failure. However, the JVP typically shows an elevated a-wave or a prominent X descent, not a rapid Y descent.

↑ *Back to this question in Part A*

@Neet_pg_bot

Q21: A pulmonary artery hypertension patient presented with an irregularly irregular pulse with loud P2 on auscultation. Which JVP finding will be seen in this patient? (Q844316)

A. Absent a waves

B. Cannon a waves

C. Rapid x descent

D. Rapid y descent

Correct Answer: A. Absent a waves

Explanation: Correct Option A - Absent a waves: Clinical Context: The patient has pulmonary artery hypertension (PAH) and presents with an irregularly irregular pulse and a loud P2 (second heart sound). The irregularly irregular pulse suggests the presence of atrial fibrillation, which is often associated with PAH due to right atrial enlargement from increased pressure. JVP Findings in Atrial Fibrillation: Absent a Waves: In atrial fibrillation, the irregular and often rapid contractions of the atria lead to ineffective atrial contraction. As a result, the a waves, which represent atrial contractions, are absent in the JVP waveform. This is consistent with the finding in atrial fibrillation where the rhythm is irregular and there is no coordinated atrial contraction. Incorrect Options: Option B - Cannon a Waves: Cannon a waves are seen in conditions where there are atrial contractions against a closed tricuspid valve, as in cases of complete heart block or atrial fibrillation with discordance between atrial and ventricular contractions. However, this finding is not as specific as the absence of a waves in atrial fibrillation. Option C - Rapid x Descent: Rapid x descent is more associated with conditions like constrictive pericarditis rather than atrial fibrillation, which is the primary condition described here. Option D - Rapid y Descent: Rapid y descent is indicative of constrictive pericarditis or other conditions where there is rapid filling of the ventricles. It is not typically associated with atrial fibrillation.

↑ *Back to this question in Part A*

@Neet_pg_bot

Q22: A young athlete underwent testing for a competition and was found to have hypertrophic cardiomyopathy. Which of the following will increase the murmur in this condition? (Q844250)

A. Handgrip

B. Valsalva maneuver

C. Squatting

D. Leaning forward

Correct Answer: B. Valsalva maneuver

Explanation: Correct Option B - Valsalva Maneuver: Hypertrophic cardiomyopathy (HCM) is a condition characterized by the thickening of the heart muscle, particularly the interventricular septum, which can obstruct blood flow out of the left ventricle, leading to a systolic murmur. The murmur associated with HCM is dynamic and can change in intensity with different maneuvers that affect the volume of blood in the left ventricle. The Valsalva maneuver decreases venous return to the heart, leading to reduced left ventricular filling. In HCM, this reduction in ventricular volume increases the obstruction to blood flow, making the murmur louder. This maneuver accentuates the outflow tract obstruction by bringing the hypertrophied septum closer to the anterior mitral valve leaflet. Incorrect Options: Option A - Handgrip: The handgrip maneuver increases systemic vascular resistance, which typically increases murmurs of regurgitant lesions like mitral regurgitation but decreases the murmur in HCM because the increased afterload reduces the degree of outflow tract obstruction. Option C - Squatting: Squatting increases venous return and systemic vascular resistance, leading to increased left ventricular filling and a reduction in the outflow tract obstruction. This typically softens the murmur in HCM. Option D - Leaning Forward: Leaning forward can accentuate murmurs of aortic regurgitation but does not have a significant effect on the murmur of HCM.

↑ *Back to this question in Part A*

@Neet_pg_bot

Q23: Which of the following drugs will cause Torsades de pointes if given with erythromycin? (Q844254)

A. Astemizole

B. Levofloxacin

C. Amoxicillin

D. Ceftriaxone

Correct Answer: A. Astemizole

Explanation: Correct Option A - Astemizole: Astemizole is an antihistamine that has been associated with QT interval prolongation, a risk factor for Torsades de pointes, a type of life-threatening ventricular tachycardia. Erythromycin, a macrolide antibiotic, is known to inhibit the cytochrome P450 3A4 (CYP3A4) enzyme. Astemizole is metabolized by CYP3A4, and when given together, erythromycin can increase the levels of astemizole, leading to significant QT prolongation and a high risk of Torsades de pointes. Due to this risk, astemizole has been withdrawn from the market in many countries. Incorrect Options Option B - Levofloxacin:

Levofloxacin is a fluoroquinolone antibiotic that can also cause QT interval prolongation. However, when given with erythromycin, the risk of Torsades de pointes is lower compared to astemizole because levofloxacin is not as strongly influenced by CYP3A4 interactions. Option C - Amoxicillin: Amoxicillin is a beta-lactam antibiotic that does not prolong the QT interval and is not associated with Torsades de pointes, either alone or in combination with erythromycin. Option D - Ceftriaxone: Ceftriaxone is a third-generation cephalosporin that also does not prolong the QT interval or interact with erythromycin to increase the risk of Torsades de pointes.

↑ *Back to this question in Part A*

@Neet_pg_bot

Q24: A patient presents with shortness of breath. Vitals are HR= 120/min, BP= 90/60. Echo shows diastolic collapse of ventricles. CT showed money bag appearance. Which is best for management of this patient? (Q844256)

A. Start diuretic with BP monitoring

B. Intra aortic balloon pump

C. Pericardiocentesis

D. Ventricular assist device

Correct Answer: C. Pericardiocentesis

Explanation: The patient has tachycardia, hypotension, shortness of breath , and imaging consistent with pericardial tamponade : Echo: diastolic collapse of ventricles → hallmark of tamponade CT: “money bag” appearance → large pericardial effusion Pericardial tamponade requires urgent pericardiocentesis to relieve pressure on the heart. Start diuretic with BP monitoring (Option A) Incorrect because diuretics reduce preload and can worsen tamponade by causing cardiovascular collapse. Intra-aortic balloon pump (Option B) Incorrect; used in cardiogenic shock and severe LV failure, not tamponade. Ventricular assist device (Option D) Incorrect; used for advanced heart failure, not acute pericardial tamponade

↑ *Back to this question in Part A*

@Neet_pg_bot

Q25: What is the next best step in management of a pulseless patient with the following rhythm? (Q844260)

A. Defibrillate and continue chest compression

B. Defibrillate and check pulse

C. Check pulse and give synchronized DC

D. Give synchronized DC and continue chest compression



Correct Answer: A. Defibrillate and continue chest compression

Explanation: Correct Option A - Defibrillate and continue chest compression: Management of Pulseless Monomorphic Ventricular Tachycardia: Pulseless monomorphic ventricular tachycardia (VT) is a type of ventricular arrhythmia that requires immediate treatment. The absence of a pulse indicates that the patient is in cardiac arrest and effective treatment is critical to restore circulation and potentially save the patient's life. Recommended Steps: Defibrillate: For pulseless VT (or pulseless ventricular fibrillation), immediate defibrillation is indicated. Defibrillation provides an electric shock to the heart to reset the electrical activity and restore a normal rhythm. Continue Chest Compressions: While defibrillation is being administered, chest compressions should continue as they are essential for maintaining blood flow to vital organs until normal rhythm is restored. Incorrect Options: Option B - Defibrillate and check pulse: After defibrillation, checking for a pulse is important, but it should not delay the immediate administration of another shock if the patient remains pulseless. Compressions should continue uninterrupted during this process. Option C - Check pulse and give synchronized DC: Checking for a pulse before defibrillation is inappropriate in the context of pulseless cardiac arrest. Synchronized direct current (DC) cardioversion is used for certain arrhythmias like atrial fibrillation or atrial flutter with a pulse, not for pulseless VT. Option D - Give synchronized DC and continue chest compression: Synchronized DC cardioversion is not the appropriate treatment for pulseless VT. Defibrillation (not synchronized cardioversion) is required in this case.

References:

.

↑ *Back to this question in Part A*

@Neet_pg_bot

Q26: A patient with a history of hypertension presents with atrial fibrillation, shortness of breath and Bilateral basal crackles on auscultation. Least important in management would be: (Q844277)

A. Start on anticoagulants like warf or Doac

B. Start beta blocker

C. Cardioversion to correct rhythm if hemodynamically remain unstable even after medical management

D. Iv Digoxin to control rate

Correct Answer: B. Start beta blocker

Explanation: Correct Option B - Start beta blocker: Beta blockers are used to control heart rate and manage symptoms related to atrial fibrillation. However, in acute settings with symptoms like shortness of breath and bilateral crackles, especially if heart failure is suspected, other treatments might take precedence. In cases of acute heart failure or unstable hemodynamics, immediate rate control might be achieved using other agents. Incorrect Options: Option A - Start on anticoagulants like warfarin or DOAC: Anticoagulants are crucial in the management of atrial fibrillation to prevent thromboembolic events such as stroke. Given the patient's symptoms and history, anticoagulation should be considered unless contraindicated. Option C - Cardioversion to correct rhythm if hemodynamically unstable even after medical management: If the patient remains hemodynamically unstable despite medical management, cardioversion is necessary to restore normal sinus rhythm and stabilize the patient. This is crucial in managing acute atrial fibrillation. Option D - IV Digoxin to control rate: IV digoxin is used for rapid rate control in atrial fibrillation, especially when accompanied by heart failure. It can be beneficial in acute settings for managing symptoms and controlling the ventricular rate.

↑ *Back to this question in Part A*

@Neet_pg_bot

Q27: The PR interval was measured at 0.21 seconds in a routine ECG of the patient. What is the correct Interpretation? (Q844281)

A. Second degree HB

B. First degree HB

C. Normal rhythm

D. Complete HB

Correct Answer: B. First degree HB

Explanation: Correct Option B - First degree HB: First-degree heart block is defined by a prolonged PR interval greater than 0.20 seconds (200 milliseconds). In this case, a PR interval of 0.21 seconds indicates a prolonged PR interval, which is characteristic of first-degree heart block. Incorrect Options: Option A - Second degree HB: Second-degree heart block (HB) is characterized by intermittent failure of some atrial impulses to be conducted to the ventricles. This is usually identified by a pattern of dropped beats or a varying PR interval. The PR interval in second-degree HB can be normal or prolonged, but it does not specifically represent a fixed interval as seen in first-degree HB. Option C - Normal rhythm: A normal PR interval ranges from 0.12 to 0.20 seconds. A PR interval of 0.21 seconds exceeds this range, indicating that the rhythm is not normal. Option D - Complete HB: Complete heart block (also known as third-degree heart block) is characterized by a complete dissociation between atrial and

ventricular activity, with no correlation between P waves and QRS complexes. The PR interval is not applicable in this context as the atrial impulses do not conduct to the ventricles.

References:

.

↑ *Back to this question in Part A*

@Neet_pg_bot

Q28: A 70 year old male patient presents to the OPD with multiple, recurrent fainting episodes. An ECG was taken and it shows P waves at a rate of 75 bpm and qrs complexes at a rate of 35 bpm. What is the diagnosis? (Q860467)

A. Mobitz type II heart block

B. Stokes adams syndrome

C. First degree heart block

D. Wolf parkinson white syndrome

Correct Answer: B. Stokes adams syndrome

Explanation: The clinical manifestations indicate Stokes Adams syndrome , characterized by complete heart block with recurrent syncope . The ECG findings show P waves at 75 bpm with QRS complexes at 35 bpm , demonstrating AV dissociation typical of complete heart block or IIIrd degree heart block . This indicates a complete interruption of electrical conduction between the atria and ventricles, leading to independent atrial and ventricular rhythms. Third-degree atrioventricular block / Stokes-Adams Syndrome Definition Complete failure of conduction between atria and ventricles, resulting in independent beating (AV dissociation). {{caption_text}} Ventricular Activity Maintained by an escape rhythm from: The AV node or bundle of His (narrow QRS complexes). Distal Purkinje tissues (broad QRS complexes). ECG Findings Prolonged PR interval Broad QRS complex Number of P waves will not be equal to the number of R waves P-R interval (atrial rate) will not match the R-R interval (ventricular rate) Clinical Features Recurrent syncope or 'Stokes–Adams' attacks- sudden loss of consciousness and collapse. Brief anoxic seizure. Pallor and a death-like appearance during the attack; characteristic flush upon recovery. Rapid recovery distinguishes it from epilepsy. Management Depends on clinical circumstances. Transient AV block in acute inferior myocardial infarction- no treatment if the patient remains stable. Symptomatic third-degree AV block- intravenous atropine or intravenous isoprenaline to maintain circulation until temporary pacing is inserted. Permanent pacemaker. Mobitz type II heart block (Option A) presents with intermittent failure of AV conduction with normal PR intervals 200ms. Unlike complete heart block, some P waves still conduct to the ventricles, and the pattern is not consistent with the current ECG findings. First degree heart block (Option C) shows prolonged PR interval >200ms with 1:1 AV conduction. This is typically asymptomatic and would not cause the presenting symptoms of recurrent syncope. Wolf parkinson white syndrome (Option D) presents with a short PR interval <120ms and delta waves. This represents pre-excitation through an accessory pathway and does not cause the AV dissociation seen in this case.



References:

Davidson's Principles and Practice of Medicine, 24th edition, Pages 477-478

↑ *Back to this question in Part A*

@Neet_pg_bot

Q29: A 48-year-old man presents with progressive fatigue and breathlessness. On examination, he has distended neck veins, hepatomegaly, ascites, and peripheral edema. Chest X-ray is shown below. Which of the following is the most likely diagnosis? (Q860471)

A. Acute pericarditis

B. Bronchial asthma

C. Constrictive pericarditis

D. Atrial myxoma

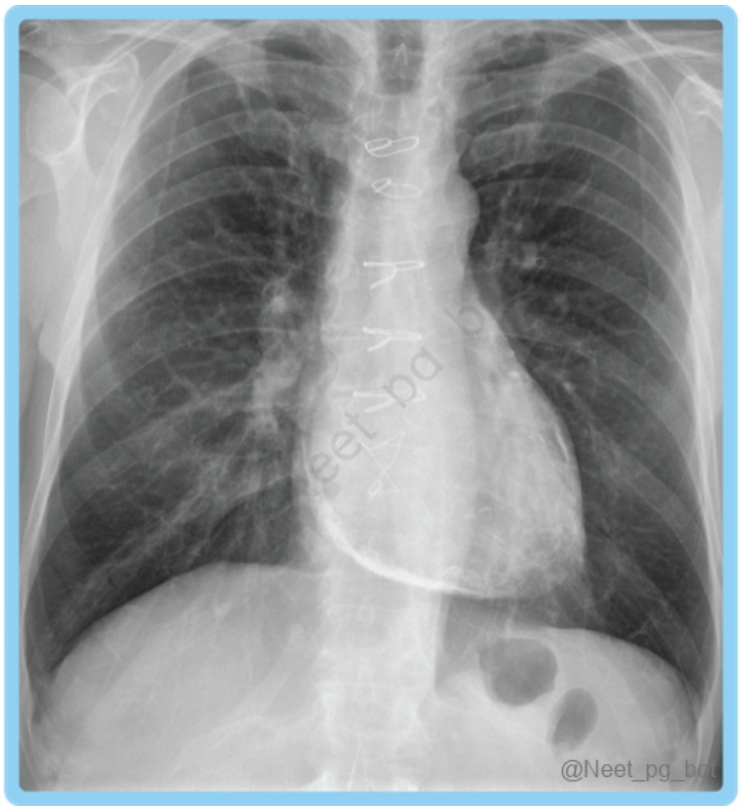

Correct Answer: C. Constrictive pericarditis

Explanation: Constrictive pericarditis is caused by fibrosis and calcification of the pericardium , leading to restricted ventricular filling during diastole . Key Clinical Features: Raised JVP with prominent y descent Systemic venous congestion → hepatomegaly, ascites, pedal edema Pericardial knock (early diastolic sound) Kussmaul's sign (JVP rises on inspiration) Chest X-ray findings: Normal-sized heart Pericardial calcification ("egg-in-cup" appearance) {{caption_text}} Acute pericarditis (Option A) presents with a flask-shaped, enlarged cardiac silhouette while in constrictive pericarditis, the heart is normal sized. Bronchial asthma (Option B) shows pulmonary hyperinflation with bronchial wall thickening. Atrial myxoma (Option D) typically presents with cardiomegaly, left atrial enlargement, and vascular redistribution.

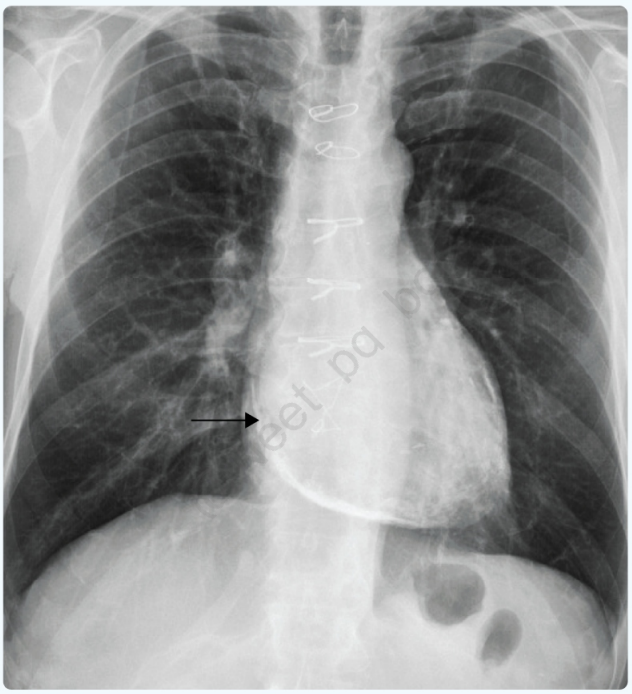

Diffuse pericardial calcification seen along the right lateral and inferior wall of heart

@Neet_pg_bot

References:

Davidson's Principles and Practice of Medicine, 24th Edition, Page 543, 544

↑ *Back to this question in Part A*

@Neet_pg_bot

Q30: A patient has muffled heart sounds with low blood pressure. What is the correct JVP finding? (Q860477)

A. Steep x descent

B. Absent y descent

C. Steep y descent

D. Blunted x descent

Correct Answer: B. Absent y descent

Explanation: The clinical manifestations such as muffled heart sounds with low blood pressure indicate cardiac tamponade , which is characterized by the accumulation of fluid in the pericardial space, leading to compromised

cardiac filling and subsequent hemodynamic compromise. In cardiac tamponade, the characteristic finding is absent y descent and non-pulsatile elevated JVP due to impaired right ventricular filling during diastole. The condition presents with Beck's triad , which includes muffled heart sounds, hypotension, and elevated JVP. Cardiac Tamponade Definition A condition where the cardiac chambers are compressed by a tense pericardial effusion, limiting cardiac inflow. Fluid accumulation of as little as 200 ml to upwards of 2L may lead to cardiac tamponade development. Clinical Features Beck's triad Jugular Venous Distension : Due to increased central venous pressure. Prominent x descent and an absent y descent. Hypotension : Resulting from impaired cardiac output. Muffled Heart Sounds : Caused by fluid accumulation in the pericardial space, dampening heart sounds. Other features Pulsus Paradoxus : A drop in systolic BP during inspiration, greater than 10 mm Hg. Causes of Pulsus paradoxus: Lung Conditions: Acute asthma, COPD, tension pneumothorax, pleural effusion, pulmonary embolism. Heart Conditions: Cardiac tamponade, constrictive pericarditis. Steep x descent (Option A): Steep x descent is typically seen in constrictive pericarditis. Although prominent x descent is also seen in cardiac tamponade, absent y descent is a more highlighting feature typical of cardiac tamponade. Steep y descent (Option C): Steep y descent is observed in exaggerated tricuspid regurgitation, which allows for rapid right atrial emptying during diastole. Blunted x descent (Option D): Blunted x descent is seen in restrictive cardiomyopathy where there is impaired ventricular relaxation. The clinical presentation of muffled heart sounds and hypotension is more consistent with cardiac tamponade rather than restrictive cardiomyopathy.

References:

Harrison’s Principles of Internal Medicine, 21st Edition, Page 1853, 2021, 2022

↑ *Back to this question in Part A*

@Neet_pg_bot

Q31: A young male patient presents with sudden onset chest pain for one hour with ECG showing STE in lead 2,3 and aVF. Which is the best treatment for this case of inferior wall MI in a multispecialty hospital? (Q860480)

A. Alteplase

B. Streptokinase

C. Primary angioplasty

D. Dabigatran

Correct Answer: C. Primary angioplasty

Explanation: The clinical manifestations (sudden onset chest pain) with characteristic ECG findings (ST elevation in lead 2,3 and aVF) indicate an acute inferior wall ST-elevation myocardial infarction (STEMI) . Primary angioplasty , also known as Primary Percutaneous Coronary Intervention (PCI) , is the gold standard treatment for STEMI when performed at a capable facility within 120 minutes of first medical contact. Immediate Goals: Control cardiac discomfort. Rapidly identify patients for reperfusion therapy. Proper triage of lower-risk patients. Avoid inappropriate discharge of STEMI patients. Overall Aim: Initiate percutaneous coronary intervention (PCI)

within 120 minutes of first medical contact, including transfer to a PCI-capable facility if necessary. Alteplase (Option A): Alteplase, a tissue plasminogen activator, is only preferred in non-PCI-capable hospitals, where patients are further to be transferred to a PCI capable hospital. In a multispecialty hospital with PCI capabilities, primary angioplasty offers better outcomes with lower bleeding risk. Streptokinase (Option B): Streptokinase is no longer the treatment of choice according to current guidelines due to its risk of anaphylaxis and inferior outcomes compared to primary PCI. Dabigatran (Option D): Dabigatran is an anticoagulant and is not indicated for the treatment of STEMI. While anticoagulation is part of STEMI management, direct oral anticoagulants like dabigatran are not the primary treatment strategy in acute STEMI. PIM050

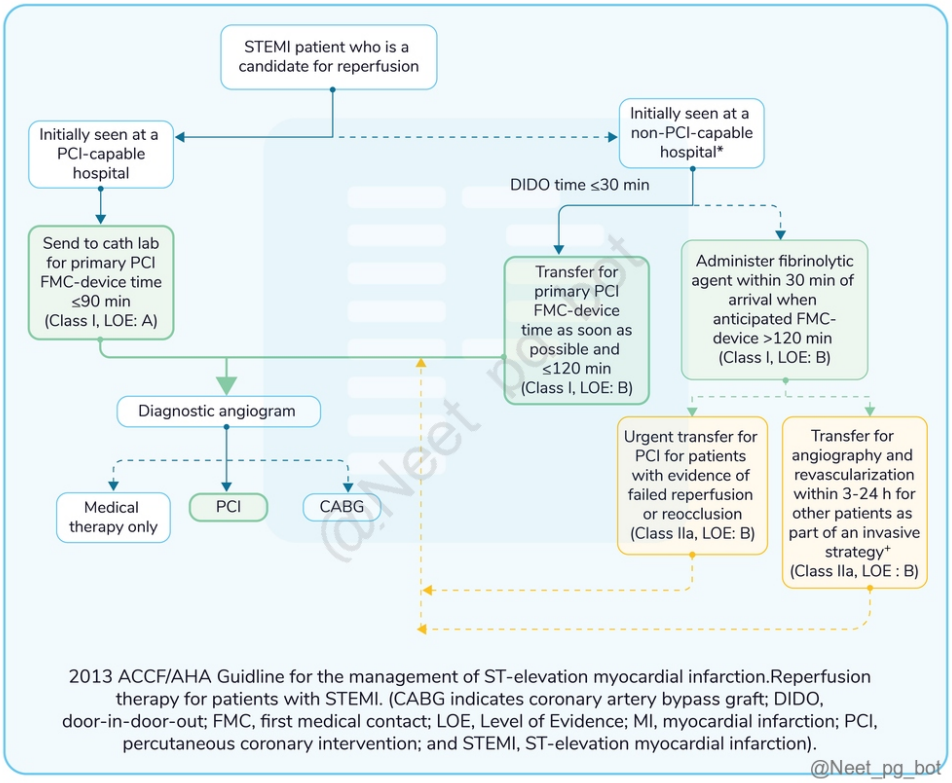

2013 ACCF/AHA Guidline for the management of ST-elevation myocardial infarction.Reperfusion therapy for patients with STEMI. (CABG indicates coronary artery bypass graft; DIDO, door-in-door-out; FMC, first medical contact; LOE, Level of Evidence; MI, myocardial infarction; PCI, percutaneous coronary intervention; and STEMI, ST-elevation myocardial infarction).

References:

Harrison's Principles of Internal Medicine, 21st Edition, Page 1828, 1829, 2056, 2057

Davidson’s Principles and Practice of Medicine, 24th Edition, Page 497-501

↑ *Back to this question in Part A*

@Neet_pg_bot

Q32: "A 45-year-old female presents to the emergency department with breathlessness. She has a history of a viral infection and chest pain from 7 days ago. A chest X-ray reveals a "water bottle" heart. All of the following statements are true except:" (Q840110)

A. Pulsus paradoxus is observed

B. Loud S1

C. Emergency pericardiocentesis may be required

D. ECG showing RA and RV collapse requires immediate intervention

Correct Answer: B. Loud S1

Explanation: Correct Option B - Loud S1: In the described scenario, viral pericarditis initially occurred, progressing to pericardial effusion and subsequent diastolic collapse of the ventricles, resulting in cardiac tamponade. Due to the presence of fluid surrounding the heart, muffled heart sounds are expected rather than a loud S1. Incorrect Options: Option A - Pulsus paradoxus is observed: Pulsus paradoxus, characterized by a drop in blood pressure of more than 12 mmHg during inspiration, is a feature of cardiac tamponade. Option C - Emergency pericardiocentesis may be required: This statement is true as pericardiocentesis is performed as an emergency measure as there is diastolic collapse of the ventricles. Option D - ECG showing RA and RV collapse requires immediate intervention: This statement is true as there is diastolic collapse of ventricles in cardiac tamponade.

References:

.

↑ *Back to this question in Part A*

@Neet_pg_bot

Q33: Which of the following conditions is indicated by the symptoms of chest pain and breathlessness in a 55-year-old male, as revealed by the provided ECG? (Q840116)

A. Unstable angina

B. Non-ST elevation myocardial infarction (NSTEMI)

C. Acute myocarditis

D. Posterior wall myocardial infarction (MI)

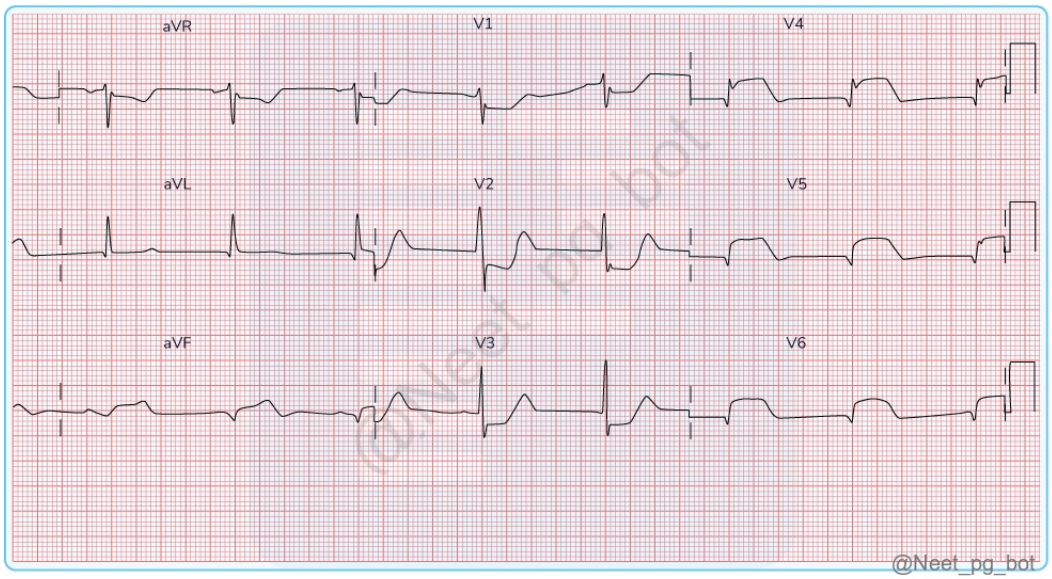

Correct Answer: D. Posterior wall myocardial infarction (MI)

Explanation: Correct Option: D) Posterior wall myocardial infarction (MI) ST depression is evident in leads V2, V3, and V4, displaying a predominantly horizontal configuration, with upright T waves. Moreover, the R/S ratio in anterior chest leads is greater than 1. These combined observations suggest the likelihood of a posterior wall myocardial infarction. Options A & B - Unstable angina & NSTEMI: The ECG changes observed in both unstable angina and NSTEMI display similarities and show T wave inversion accompanying ST depression. Option C - Acute myocarditis: There are no pathognomic findings in acute myocarditis as it shows non-specific ST segment changes.

References:

.

↑ *Back to this question in Part A*

@Neet_pg_bot

Q34: Which of the following statements is false regarding a 35-year-old male presenting to the emergency department with unconsciousness and the given ECG findings? (Q840119)

A. Atrial fibrillation can occur in structurally normal hearts

B. Direct current cardioversion should always be performed immediately

C. IV digoxin can be used when AF is associated with heart failure

D. Pulse deficit is a useful clinical clue in AF

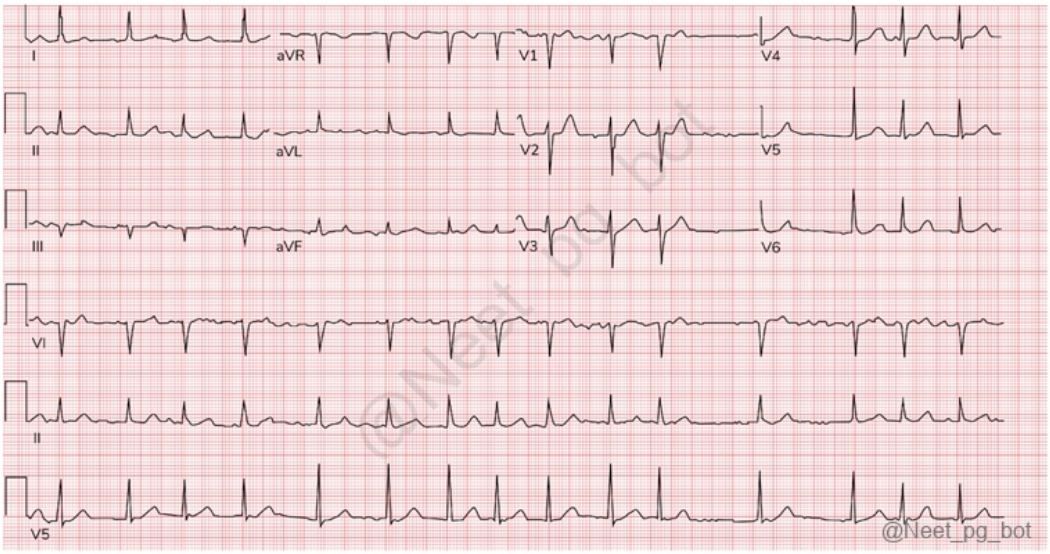

Correct Answer: B. Direct current cardioversion should always be performed immediately

Explanation: Correct Option: B) Direct current cardioversion should always be performed immediately
Explantion: The ECG shows atrial fibrillation (AF) , characterized by an irregularly irregular rhythm with absent P waves. DC cardioversion is not universally performed in all patients with AF. It is indicated only when AF causes hemodynamic instability (shock, pulmonary edema, severe hypotension). In stable patients, immediate cardioversion is avoided because it can dislodge atrial thrombi and trigger a stroke unless anticoagulation is ensured. Atrial fibrillation can occur in structurally normal hearts (Option A): AF can occur even in a structurally normal heart called "lone AFib," can be triggered by factors like age, genetics, or lifestyle, and can also happen for no obvious reason. While AF often develops in hearts with underlying issues, it is not limited to those with heart disease. IV digoxin can be used when AF is associated with heart failure (Option C): IV digoxin is helpful for rate control , particularly when AF is accompanied by heart failure. Pulse deficit is a useful clinical clue in AF(Option D): Pulse deficit (difference between heart rate and pulse rate) is a classic bedside clue to AF, due to weak ventricular contractions not producing palpable pulses

References:

.

↑ *Back to this question in Part A*

@Neet_pg_bot

Q35: A 21-year-old man presents with episodes of chest pain. Physical examination reveals a bisferiens pulse and a heaving apex. What is the most likely diagnosis? (Q860218)

A. Dilated Cardiomyopathy (DCM)

B. Hypertrophic Cardiomyopathy (HCM)

C. Mitral Stenosis

D. Aortic Stenosis

Correct Answer: B. Hypertrophic Cardiomyopathy (HCM)

Explanation: The presence of a bisferiens pulse (double-peaked pulse) and a heaving apex are characteristic physical findings of Hypertrophic Cardiomyopathy (HCM) . This condition is characterized by asymmetric hypertrophy of the ventricular septum, which can cause dynamic obstruction of the left ventricular outflow tract. Hypertrophic Cardiomyopathy (HCM) Feature Characteristics Pathophysiology Autosomal dominant genetic disorder Mutations in beta-myosin heavy-chain, troponin, and myosin-binding protein C Inappropriate left ventricular hypertrophy Key Physical Findings Bisferiens (jerky arterial) pulse Heaving apex Mid-systolic murmur Dynamic LVOT obstruction Common Symptoms Angina (chest pain) Dyspnea Syncope MC cause of sudden death Pathological Features Misaligned myocardial fibers Myocardial fibrosis Rigid left ventricle Impaired diastolic filling Examination Findings Clinical Finding Description Palpable Left Ventricular Hypertrophy An enlarged left ventricle can be felt during physical examination, indicating hypertrophy. Double Impulse at the Apex A palpable fourth heart sound suggests forceful atrial contraction against a non-compliant ventricle. Mid-Systolic Murmur at the Base Turbulent blood flow through the obstructed left ventricular outflow tract produces a mid-systolic murmur. Pansystolic Murmur at the Apex Indicates mitral regurgitation caused by abnormal systolic anterior motion of the mitral valve. Jerky Arterial Pulse Characteristic of HOCM, contrasts with the slow-rising pulse seen in aortic stenosis. Pulsus bisferiens A double pulse noticed during systole in the peripheral pulse is called pulsus bisferiens. It is associated with severe aortic disease accompanied by aortic regurgitation and HOCM. Dilated Cardiomyopathy (Option A) is characterized by left ventricular dilation and impaired systolic function. Physical exam findings typically include signs of heart failure, such as elevated jugular venous pressure and displaced apex beat, but bisferiens pulse and heaving apex are not typical features. Mitral Stenosis (Option C) presents with obstruction of blood flow from the left atrium to the left ventricle. Physical exam findings typically include a diastolic murmur best heard at the apex and possible signs of left atrial enlargement, but bisferiens pulse is not a characteristic finding. Aortic Stenosis (Option D) causes obstruction of blood flow from the left ventricle into the aorta. While it can present with chest pain, the classic physical findings include a systolic ejection murmur and a reduced or delayed carotid pulse, not a bisferiens pulse.

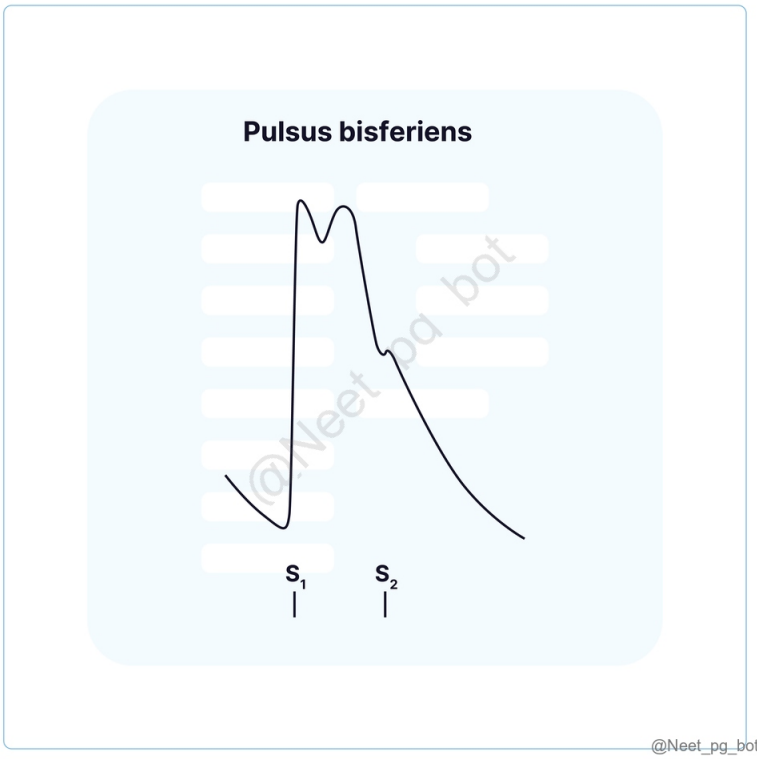

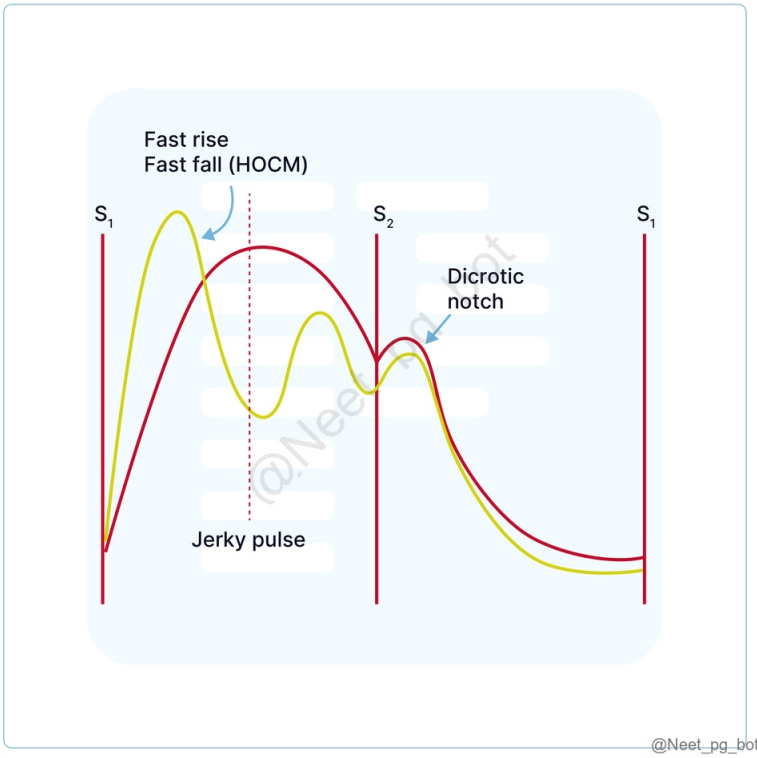

References:

Davidson’s Principles and Practice of Medicine, 24th Edition, Page 540

Dynamic Auscultation in HOCM

Auscultatory Findings in HOCM

Reverse splitting

↑ *Back to this question in Part A*

@Neet_pg_bot

Q36: Based on the given ECG, identify which wall of the myocardium was affected in this patient? (Q860223)

A. Inferior wall

B. Anterior wall

C. Posterior wall

D. Lateral wall

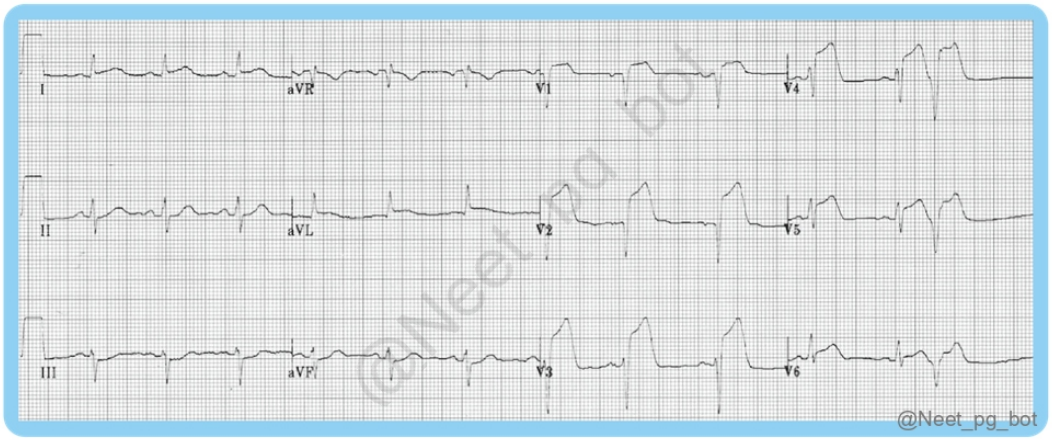

Correct Answer: B. Anterior wall

Explanation: The ECG demonstrates ST elevation in leads V2, V3, and V4 is indicative of an anterior wall myocardial infarction (MI) The ECG shows ST segment elevation with a convex upward shape (Pardee sign) in the precordial leads, which is characteristic of acute anterior wall myocardial infarction supplied by the left anterior descending artery. Infarct Localization based on ECG Infarct Location Affected Coronary Artery Leads Lateral Wall MI (Option D) Left Circumflex Artery (LCx) V5, V6, I, aVL Septal Wall MI Septal Branch of Left Anterior Descending Artery (LAD) V1, V2 Anterior Wall MI (Option A) Left Anterior Descending Artery (LAD) V1-V4, I, aVL Extensive Anterior Wall MI Left Main Coronary Artery (LMCA) V1-V6, I, aVL Posterior Wall MI (Option C) Posterior Descending Artery (PDA) V1-V4 (ST depression), V7, V8, V9 (ST elevation) Inferior Wall MI (Option A) Right Coronary Artery (RCA) Leads II, III, aVF NSTEMI (Anterior Wall) Left Anterior Descending Artery (LAD) Often subtle changes in V1-V4 Inferior wall (Option A) involvement typically shows

ST elevation in leads II, III, and aVF, which is not present in this ECG tracing. The absence of these changes rules out inferior wall MI. Posterior wall (Option C) involvement would show ST depression in leads V1-V4 and ST elevation in leads V7, V8, and V9. This pattern is not seen in the current ECG. Lateral wall (Option D) involvement would show changes in leads V5, V6, I, and aVL. While there may be some changes in these leads, they are not the predominant finding, and the primary area of involvement is clearly anterior.

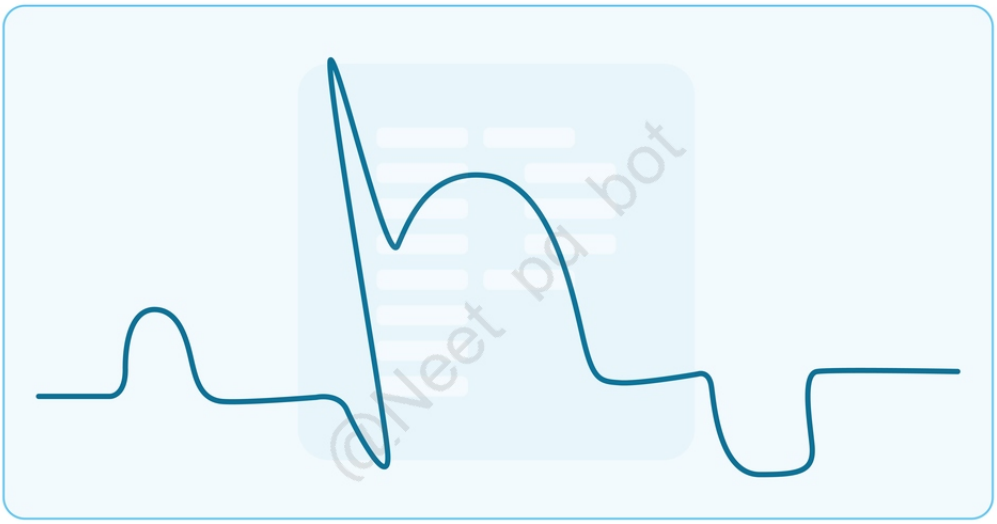

Pardee Sign- ST segment elevation with a convex upward shape

@Neet_pg_bot

References:

Harrison's principles of internal medicine, 21st Edition, Page: 1828,1829.

Davidson's principles and practice of medicine, 24th Edition, Page: 449.

https://www.cardiologymedjournal.com/articles/jccm-aid1082.php

↑ *Back to this question in Part A*

@Neet_pg_bot

Q37: In which of the following scenarios is Rescue Percutaneous Coronary Intervention (PCI) indicated? (Q860242)

A. Failed thrombolysis

B. Chronic stable angina

C. Prinzmetal's angina

D. NSTEMI

Correct Answer: A. Failed thrombolysis

Explanation: Rescue PCI is specifically indicated when thrombolytic therapy fails to restore coronary blood flow in acute myocardial infarction. This intervention becomes necessary when initial thrombolytic treatment is unsuccessful in dissolving the occluding blood clot, as evidenced by persistent symptoms, ongoing ST-segment elevation, or hemodynamic instability . The procedure serves as a secondary intervention to mechanically reestablish coronary perfusion when pharmacological reperfusion has failed. 2013 ACCF/AHA Guideline for the management of ST-elevation myocardial infarction. Reperfusion therapy for patients with STEMI. (CABG indicates coronary artery bypass graft; DIDO, door-in–door-out; FMC, first medical contact; LOE, Level of Evidence; MI, myocardial infarction; PCI, percutaneous coronary intervention; and STEMI, ST-elevation myocardial infarction) Chronic stable angina (Option B) is characterized by predictable chest pain occurring with exertion or stress. While PCI may be performed for relief in cases where medical management has failed, it is not classified as rescue PCI. The intervention in stable angina is planned and elective rather than emergent. Prinzmetal's angina (Option C) is caused by coronary artery spasm and typically responds to medical management with calcium channel blockers and nitrates. PCI is not usually indicated unless there is a significant fixed obstruction. The primary treatment focuses on managing vasospasm rather than mechanical intervention. NSTEMI (Option D) management follows a different protocol where initial medical therapy is the standard approach, with PCI timing based on risk stratification and response to treatment. While PCI may be indicated in NSTEMI, it is not considered rescue PCI as it is part of the planned treatment strategy rather than a rescue measure after failed therapy.

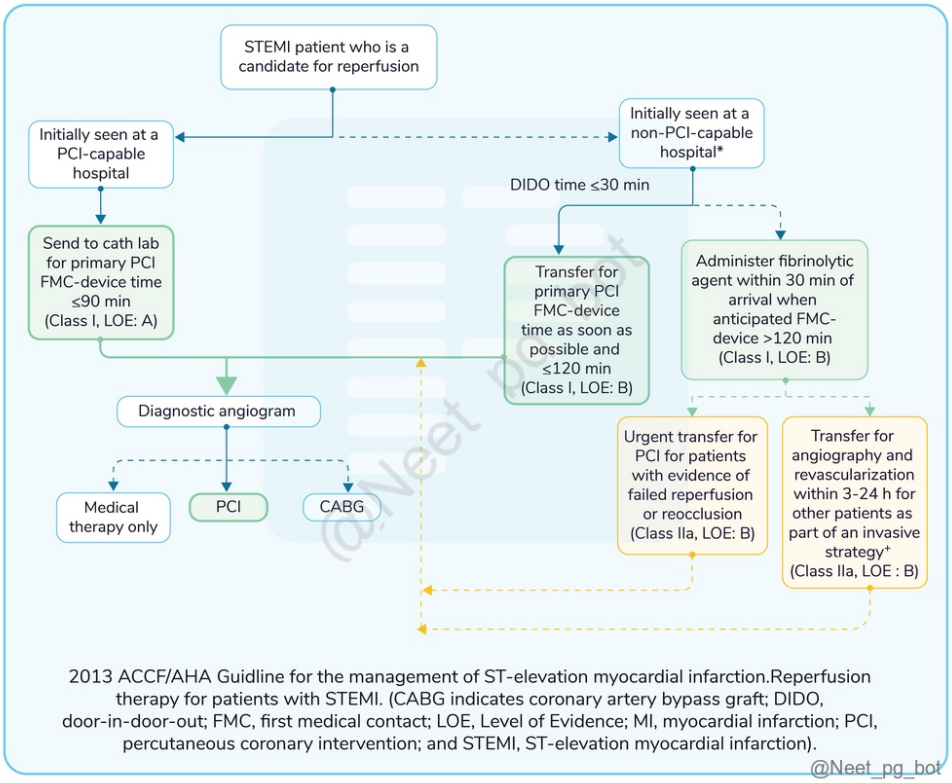

2013 ACCF/AHA Guidline for the management of ST-elevation myocardial infarction.Reperfusion therapy for patients with STEMI. (CABG indicates coronary artery bypass graft; DIDO, door-in-door-out; FMC, first medical contact; LOE, Level of Evidence; MI, myocardial infarction; PCI, percutaneous coronary intervention; and STEMI, ST-elevation myocardial infarction).

@Neet_pg_bot

References:

Harrison's Principles of Internal Medicine, 21st Edition, Page: 2047-2049, 2051, 2053

↑ *Back to this question in Part A*

Q38: A 30-year-old man with a past history of tuberculosis now complains of abdominal distension and pedal edema. On examination, his neck veins are prominent. His chest x-ray is given below. Which of the following findings will be seen in this patient? (Q860246)

A. Pulsus bisferiens

B. Kussmaul sign

C. Non pulsatile elevated JVP

D. SBP rises from 80 mmHg to 60 mmHg

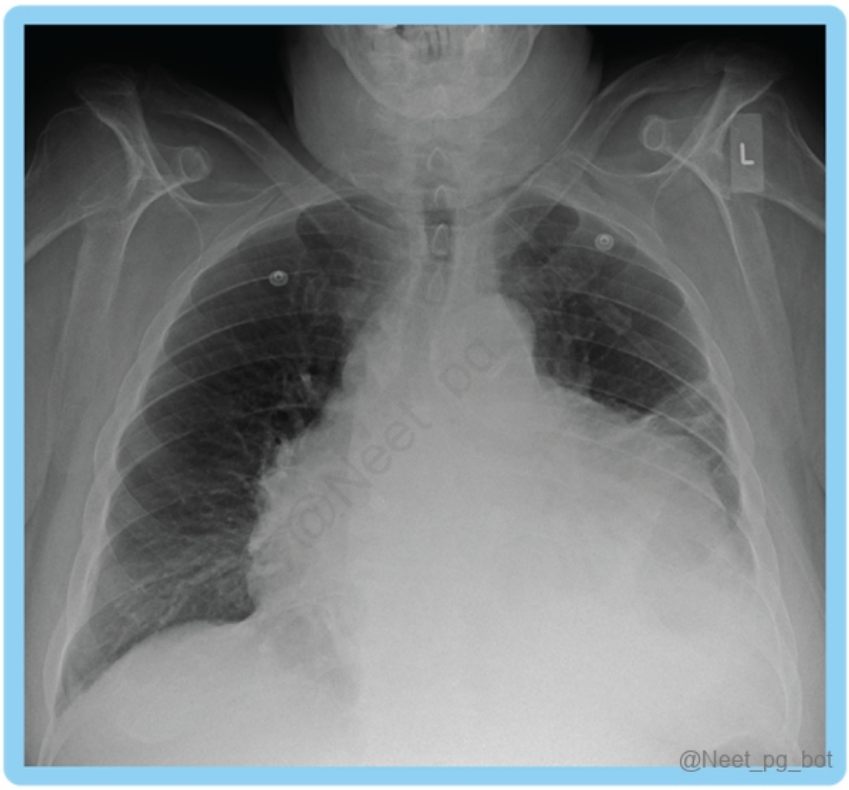

Correct Answer: C. Non pulsatile elevated JVP

Explanation: Correct Option C - Non-pulsatile elevated JVP: This patient likely has constrictive pericarditis as a post-tuberculosis complication. Clinical features include ascites, pedal edema, raised non-pulsatile JVP, and prominent neck veins, with pericardial calcification often seen on chest X-ray. The elevated JVP is non-pulsatile due to the rigid pericardium limiting right atrial filling. Incorrect Options: Option A - Pulsus bisferiens: Pulsus bisferiens is seen in hypertrophic obstructive cardiomyopathy or severe aortic regurgitation, not in constrictive

pericarditis Option B - Kussmaul sign: Kussmaul sign (JVP rises on inspiration) may be present in constrictive pericarditis, but it is not universally seen, and the key finding here is non-pulsatile JVP. Option D - SBP rises from 80 mmHg to 60 mmHg: This describes pulsus paradoxus, which is more characteristic of cardiac tamponade, not constrictive pericarditis.

References:

Harrison's Principles of Internal Medicine, 21st Edition, Page 1853, 2021, 2022

Low-Pressure Cardiac Tamponade | Circulation

Fluid amount

Pulsus paradoxus

↑ *Back to this question in Part A*

@Neet_pg_bot

Q39: Which of the following is seen in subclinical acute myocarditis? (Q857252)

A. Palpitations

B. Elevated pro-BNP, Trop T

C. Low LVEF on 2D ECHO

D. Elevated creatinine levels

Correct Answer: B. Elevated pro-BNP, Trop T

Explanation: iomarkers of cardiac injury raised ECG findings suggestive of cardiac injury Abnormal cardiac function on echocardiogram or cardiac MRI Absent Needed Probable acute myocarditis In the clinical context of possible myocardial injury with cardiovascular symptoms and at least one of the following: Biomarkers of cardiac injury raised ECG findings suggestive of cardiac injury Abnormal cardiac function on echocardiogram or cardiac MRI Absent Needed Definite myocarditis Histological or immunohistological evidence of myocarditis Histological or immunohistological evidence of myocarditis Not Needed Options C and D are incorrect as they are not found in subclinical acute myocarditis.

References:

https://pmc.ncbi.nlm.nih.gov/articles/PMC5814111/

↑ *Back to this question in Part A*

@Neet_pg_bot

Q40: Which of the following describes an aortic regurgitation murmur? (Q857263)

A. Ventricular contraction

B. Ejection systolic murmur

C. Diastolic murmur

D. Systolic murmur

Correct Answer: C. Diastolic murmur

Explanation: S .

References:

Harrison's Principles of Internal Medicine, 21st Edition, page 1821, 1822, 1823, 1988

BMJ JournalLink

NIH websiteLink

↑ *Back to this question in Part A*

@Neet_pg_bot

Q41: What does the ECG in the following image depict? (Q857267)

A. Pericarditis

B. Viral myocarditis

C. Torsades de pointes

D. Cardiac tamponade

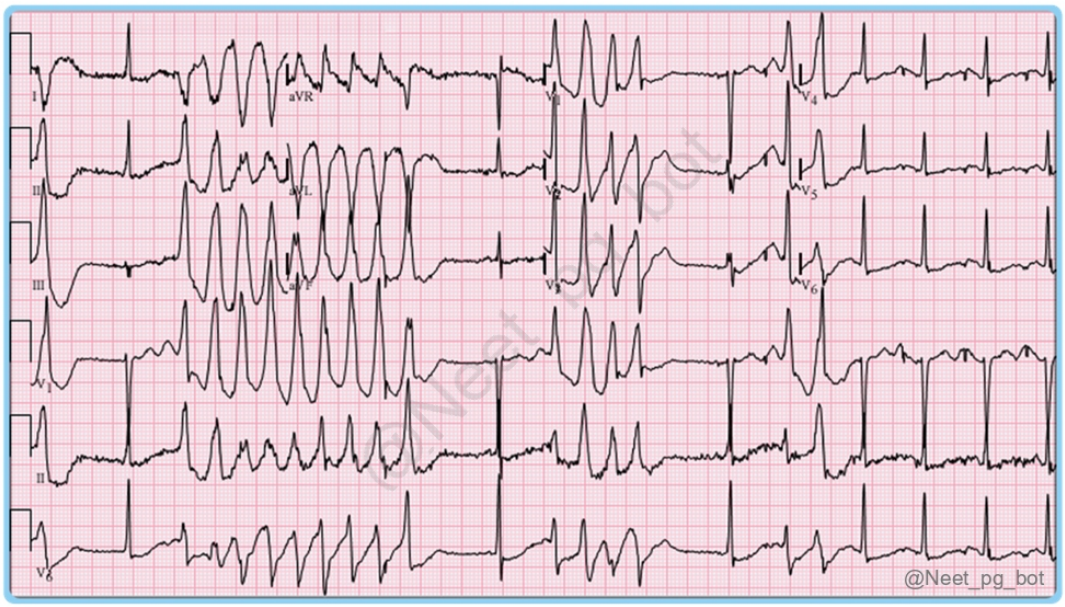

Correct Answer: C. Torsades de pointes

Explanation: - Torsades de pointes: The polymorphic VT, spindle-shaped pattern, and prolonged QT interval seen in the ECG show the diagnosis of Torsades de Pointes. Torsades de Pointes ECG features : Polymorphic VT : Characterized by variation in QRS direction and amplitude. Spindle-shaped pattern : The QRS complexes form a twisting or spindle-shaped "envelope". {{caption_text}} Prolonged QT interval PVC initiation : Often triggered by a premature ventricular contraction (PVC) on a prolonged T-U wave, creating an "R on T" phenomenon. {{caption_text}} Postectopic pause : A pause following the PVC, further prolonging repolarization. Causes : Mnemonic: "A TIGERS BITE" A - Antiarrhythmics (Class IA and III) T - Tricyclic antidepressants I - Ischemia (myocardial) G - Genetics (congenital long QT syndrome) E - Electrolyte abnormalities (hypokalemia, hypomagnesemia, hypocalcemia) R - Restrictive cardiomyopathy S - Stroke (especially subarachnoid haemorrhage) B - Bradycardia I - Interactions (drug-drug interactions that prolong QT) T - Toxins (organophosphates, arsenic, etc.) E - Endocrine disorders (hypothyroidism, pheochromocytoma) Treatment : Immediate management: Intravenous magnesium sulfate (even if serum magnesium is normal) Discontinue potential QT-prolonging medications Correct electrolyte abnormalities, especially hypokalemia Consider temporary pacing or isoproterenol infusion to increase heart rate and shorten QT interval Acute pericarditis (Option A) shows T-wave inversion following ST-segment elevation in the ECG. Viral myocarditis (Option B) shows prolonged QRS, QT prolongation, diffuse T wave inversion, ventricular arrhythmias, and AV conduction defects in the ECG. Cardiac tamponade (Option D) shows consecutive normally-conducted QRS complexes that alternate in height (electrical alternans) and low QRS voltage with tachycardia in the ECG.

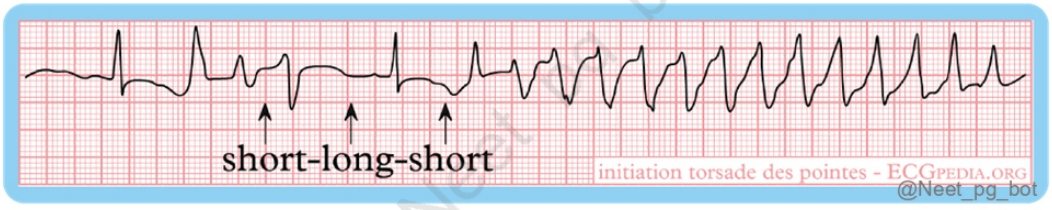

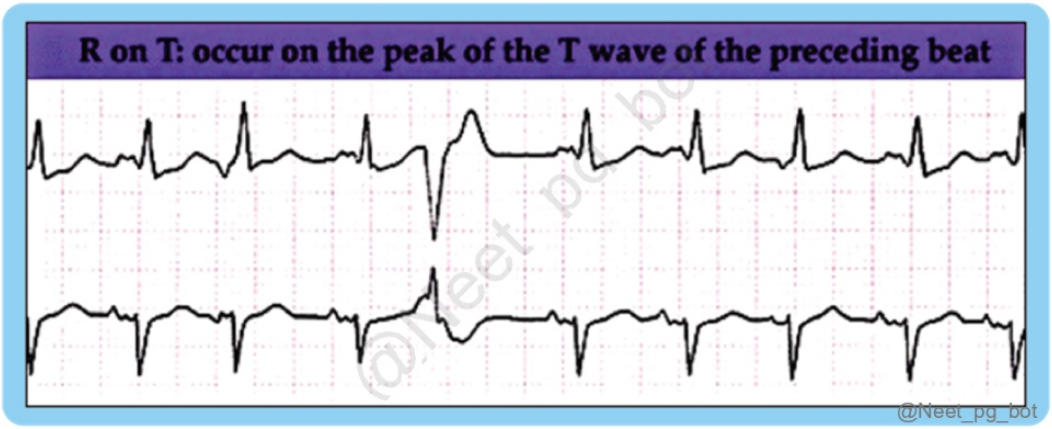

References:

Goldberger's Clinical Electrocardiography, A Simplified Approach, 9th Edition, Page: 166, 167.

↑ *Back to this question in Part A*

@Neet_pg_bot

Q42: What is the correct order for cardiac auscultation, from superior to inferior? a. Pulmonary b. Tricuspid c. Mitral (Q857280)

A. a > b > c

B. b > a > c

C. c > a > b

D. c > b > a

Correct Answer: A. a > b > c

Explanation: PE to Man) "APE to Man" refers to: Aortic Valve: To listen to the aortic valve closing , place the stethoscope on the right side of the sternum at the 2nd intercostal space . Pulmonary Valve: To listen to the pulmonic valve closing , place the stethoscope on the left side of the sternum at the 2nd intercostal space . Erb's Point (where S2 sound is best heard): Located on the left side at the 3rd intercostal space .

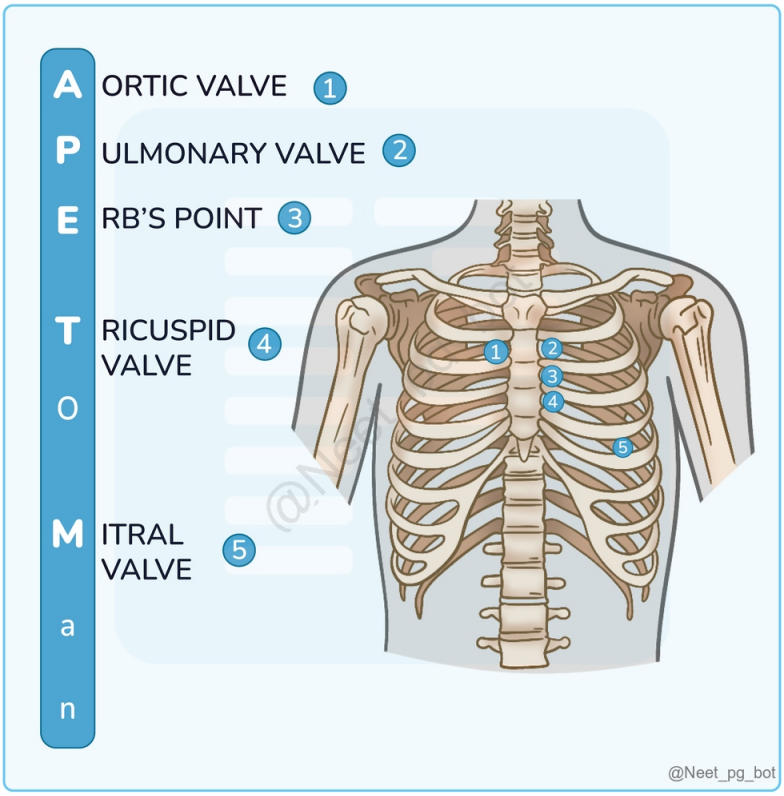

References:

https://www.osmosis.org/answers/ape-to-man-heart-sounds-mnemonic

↑ *Back to this question in Part A*

@Neet_pg_bot

Q43: Which of the following jvp findings seen in a patient with muffled heart sounds, hypotension and raised JVP? (Q820395)

A. Absent x descent

B. Absent y descent

C. C waves are enlarged

D. A waves are absent

Correct Answer: B. Absent y descent

Explanation: Correct Option B - Absent y descent: Y descent is the drop in JVP during early diastole when the tricuspid valve opens and blood flows from the right atrium to the right ventricle. In cardiac tamponade, the

elevated pressure in the right atrium due to compression prevents normal descent of the JVP during diastole, leading to an absent y descent. This is the correct finding for the given scenario. Incorrect Options: Option A - Absent x descent: X descent is the drop in JVP during ventricular systole. It's seen in conditions where the right atrium is not excessively obstructed or compressed. In cardiac tamponade, the x descent can actually be exaggerated, not absent. Option C - C waves are enlarged: C waves on the JVP waveform represent the bulging of the tricuspid valve into the right atrium during ventricular contraction. Enlarged C waves are often seen in conditions like tricuspid regurgitation, but they are not specifically associated with the given symptoms of muffled heart sounds, hypotension, and raised JVP. Option D - A waves are absent: A waves correspond to atrial contraction, which occurs just before the tricuspid valve closes. Absent A waves can be seen in conditions like atrial fibrillation or complete heart block, where the atria are not contracting in a coordinated manner. However, absent A waves would not directly explain the combination of symptoms mentioned in the scenario.

References:

.

↑ *Back to this question in Part A*

@Neet_pg_bot

Q44: Which of the following is correct regarding Wolf Parkinson's white syndrome? (Q820427)

A. Short PJ Interval

B. Broad QRS interval

C. Tall Tented T waves

D. Prolonged PR interval

Correct Answer: B. Broad QRS interval

Explanation: Correct Option B - Broad QRS interval: Wolf-Parkinson-White (WPW) syndrome is a condition in which an abnormal electrical pathway known as an accessory pathway exists between the atria and ventricles of the heart. ECG finding associated with Wolf-Parkinson-White syndrome is a short PR interval and a characteristic broad QRS complex due to the abnormal electrical pathway. The presence of the accessory pathway can lead to a delta wave, which is an initial slurring of the QRS complex, causing it to appear broader than normal. Incorrect Options: Option A - Short PJ Interval: In WPW syndrome, the characteristic finding is a shortened PR interval rather than a short PJ interval. The PR interval represents the time it takes for the electrical signal to travel from the atria to the ventricles. In WPW syndrome, due to the presence of the accessory pathway, the signal bypasses part of the normal conduction system, resulting in a shorter PR interval on an electrocardiogram (ECG). Option C - Tall Tented T Waves: Tall tented T waves are not a typical feature of WPW syndrome. Tall tented T waves are associated with conditions like hyperkalemia (high levels of potassium in the blood) and can be seen in ECGs in those scenarios. Option D - Prolonged PR interval: As mentioned earlier, the PR interval is actually shortened in WPW syndrome due to the accessory pathway bypassing the normal conduction system. A prolonged PR interval

could be indicative of other conditions like first-degree heart block.

↑ *Back to this question in Part A*

@Neet_pg_bot

Q45: The patient presented with pedal oedema, raised JVP till mandible and ascites. What is the most likely diagnosis? (Q820445)

A. Cardiac failure

B. Renal failure

C. Liver failure

D. Brain injury

Correct Answer: A. Cardiac failure

Explanation: Correct Option A - Cardiac failure: The symptoms mentioned - pedal edema, raised jugular venous pressure (JVP) up to the mandible, and ascites - are indicative of congestive heart failure (cardiac failure). Let's go through each option and explain why: Congestive heart failure occurs when the heart's pumping ability is compromised, leading to fluid accumulation in various parts of the body. Pedal edema (swelling in the feet and ankles) occurs due to fluid retention in the lower extremities. Raised JVP is a sign of increased pressure in the veins returning blood to the heart, often observed in heart failure due to the inefficient pumping of blood. Ascites, the accumulation of fluid in the abdominal cavity, can also result from the increased venous pressure caused by heart failure. Incorrect Options: Option B - Renal failure: While renal failure can lead to fluid retention and edema, it typically doesn't cause the specific pattern of JVP elevation and ascites seen in the case. Renal failure might lead to edema and fluid overload, but these symptoms are more directly associated with heart failure in this context. Option C - Liver failure: Liver failure can lead to ascites due to disruptions in fluid balance and decreased production of proteins responsible for maintaining proper fluid distribution. However, the elevated JVP up to the mandible is less likely to be caused by liver failure alone. This sign is more indicative of heart failure. Option D - Brain injury: Brain injury, unless involving specific areas of the brain that control fluid balance, is not a likely cause of the symptoms described. Brain injury might lead to other neurological symptoms, but it wouldn't explain the combination of pedal edema, raised JVP, and ascites.

↑ *Back to this question in Part A*

@Neet_pg_bot

Q46: A 20 year old male who is an IV drug user. on examination, a temperature of 38.5 C, and some spots can be noted over the fundus. CBC showed a leukocyte count of 20,000/cu mm. Blood has been sent for culture. Infective endocarditis is suspected.

How many minor duke's criteria are satisfied for the diagnosis? (Q830821)

A. 1

B. 2

C. 3

D. 4

Correct Answer: C. 3

Explanation: Correct Option C - 3: Duke's criteria satisfied for the diagnosis of infective endocarditis is 3. Minor Duke's criteria include: Injection drug use Temperature > 38.0°C Phenomena (such as fundus spots)

References:

.

↑ *Back to this question in Part A*

@Neet_pg_bot

Q47: A 10-year-old boy's father noticed agonal respiration at 5 AM while he was asleep. He was rushed to the ER where an ECG was performed as given. What could be the diagnosis? (Q854656)

A. Early repolarization syndrome

B. Brugada Syndrome

C. Hypertrophic cardiomyopathy

D. Atrial fibrillation

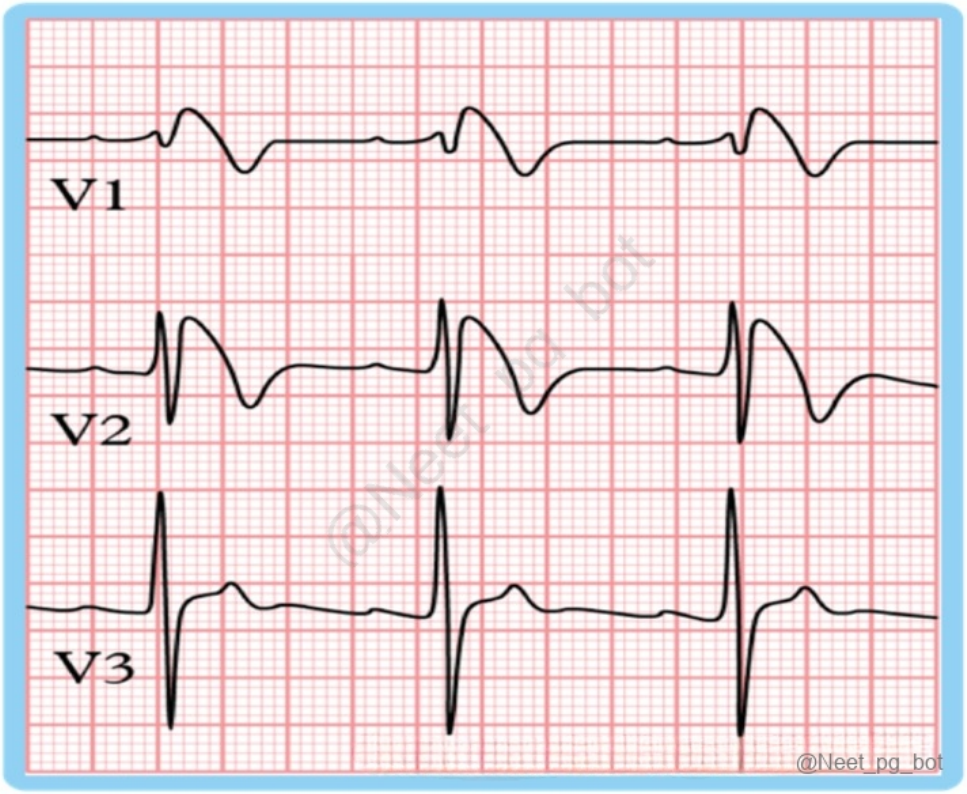

Correct Answer: B. Brugada Syndrome

Explanation: Based on the given scenario and ECG findings (ST elevation in V1-V3), the diagnosis is Brugada Syndrome - a rare, inherited cardiac disorder that predisposes individuals to life-threatening arrhythmias, often occurring during sleep. The presence of agonal respiration at night strongly suggests a ventricular arrhythmia, a hallmark of Brugada Syndrome. Brugada Syndrome About A rare, inherited disease that predisposes patients to potentially fatal cardiac arrhythmias, characterised by right bundle branch block and ST-segment elevations in the right precordial leads (V1-V3) on ECG. Clinical features Symptoms range from asymptomatic to sudden cardiac death, often during sleep. Syncope in 80% of patients with ventricular tachycardia or fibrillation. Other symptoms: Palpitations, dizziness, and fever history may trigger symptoms. ECG findings Type I: Coved ST elevations >2 mm with inverted T wave. Type II: Saddleback-shaped ST elevation >2 mm. Type III: Saddleback-shaped ST elevations <2 mm. Patients with a normal ECG and high-risk factors may need a drug challenge test to reveal ST elevations in leads V1 to V3. {{caption_text}} Drug challenge test Drugs used in the challenge test: Class IA antiarrhythmics (Procainamide, Ajmaline). IC antiarrhythmics (Flecainide, Propafenone). Brugada ECG findings can also emerge from Cocaine use or Tricyclic antidepressant toxicity. Electrolyte abnormalities like Hyperkalemia and Hypercalcemia can reveal ST elevations in the right precordial leads. A normal drug challenge test in pediatric patients may need to be repeated after puberty due to hormonal influences. The "Full Stomach Test" can also help expose ST elevations by increasing vagal tone. Additional diagnostic options include genetic testing for SCN5A mutations and invasive electrophysiology. Treatment Implantable Cardioverter-Defibrillator (ICD) for high-risk patients. Incorrect Options: Early repolarization syndrome (Option A) is a genetic condition presenting with life-threatening arrhythmias and J-point elevation in ECG. This is not the given scenario here. Hypertrophic cardiomyopathy (Option C) is an autosomal dominant cardiac myocyte disease and presents with shortness of breath and chest discomfort. It does not present with agonal respiration at night and is not the given scenario. Atrial fibrillation (Option D) is a type of cardiac arrhythmia that presents with an irregularly irregular rhythm in the ECG. This is not the given ECG picture.

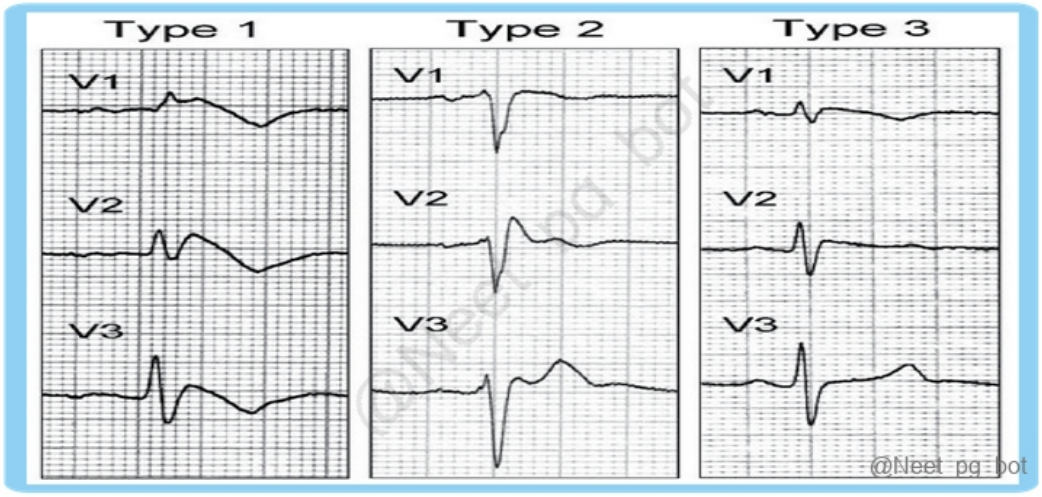

References:

Brugada Syndrome - StatPearls - NCBI Bookshelf

Brugada Syndrome - GeneReviews® - NCBI Bookshelf

Harrison’s Principles of Internal Medicine, 21st Edition, Page: 1925.

↑ *Back to this question in Part A*

@Neet_pg_bot

Q48: All of the following are the causes of high-output cardiac failure, except? (Q854694)

A. Cor pulmonale

B. Beri Beri

C. Anemia

D. Systemic AV shunt

Correct Answer: A. Cor pulmonale

Explanation: Cor pulmonale is a change in the structure and function of the right ventricle developing as a result of a pulmonary disorder leading to pulmonary hypertension. This is not associated with high-output cardiac failure but with right ventricular hypertrophy. Causes of high-output cardiac failure Category Aetiology Pathophysiology Metabolic Hyperthyroidism Increased thyroid hormone increases contractility, heart rate, and systemic metabolism, causing reduced systemic vascular resistance and eventually cardiomyopathy. Myeloproliferative disorders Increased cellular metabolism and turnover, leading to higher metabolic demand and decreased systemic vascular resistance. Myocardial Sepsis Inflammatory response leads to vasodilation and high cardiac output;

initially hyperdynamic phase with low systemic vascular resistance. Thiamine deficiency (Beriberi) (Option B) Thiamine deficiency causes systemic vasodilation and direct myocardial effects, resulting in high venous return and cardiomyopathy. Chronic lung disease Chronic hypoxia and hypercapnia reduce systemic arterial resistance, causing chronic volume overload and right-sided heart failure. Peripheral vascular Arteriovenous fistulas (AVF) (Option D) Shunt from artery to vein bypasses the arteriolar and capillary bed, increasing venous return to the heart, and requiring increased cardiac output. Liver cirrhosis Impaired clearance of vasoactive substances and bacterial translocation lead to decreased systemic vascular resistance and high-output failure. Obesity Excessive vasodilation due to adipokines and altered myocardial metabolism contribute to high-output cardiac failure. Other Erythroderma Vasoactive changes that may lead to high-output cardiac failure (less defined). Carcinoid syndrome Tumor secretion of vasoactive substances can cause vasodilation and reduced systemic vascular resistance. Mitochondrial disorders Altered cellular metabolism and energy production lead to increased demand and potential high-output failure. Acromegaly Increased growth hormone can lead to increased tissue demand and altered vascular resistance. Paget disease of bone Increased bone turnover leads to AVF formation, contributing to high-output cardiac failure. Conditions Stress, exercise, fever, pregnancy Temporary increases in metabolic demand or vasodilation, though not direct causes of high-output cardiac failure. Anemia (Option C) The attempt to compensate for reduced oxygen delivery by increasing cardiac output leads to high-output cardiac failure later on.

References:

https://www.ncbi.nlm.nih.gov/books/NBK499994/

https://www.ncbi.nlm.nih.gov/books/NBK513337/

Davidson’s Principles of and Practice of Medicine, 24th Edition, Page: 463.

↑ *Back to this question in Part A*

@Neet_pg_bot

Q49: What does the ECG depict in the following image? (Q854707)

A. First-degree heart block

B. Second-degree intra-nodal heart block

C. Complete heart block

D. AV dissociation



Correct Answer: B. Second-degree intra-nodal heart block

Explanation: Given ECG shows progressive lengthening of PR intervals until a dropped beat occurs, which indicates Mobitz type I block, which is a type of second-degree heart block. Second-degree heart block Dropped beats occur because some impulses from the atria fail to be transmitted to the ventricles. Types Mobitz Type I (Wenckebach) Mobitz Type II Description Progressive lengthening of PR intervals until a dropped beat occurs. Cycle repeats itself. {{caption_text}} PR interval remains constant. Some P waves are not conducted. {{caption_text}} Clinical Features Often physiological; can occur in young athletes. May not cause symptoms. Caused by His-Purkinje system disease. Higher risk of asystole. Management Typically does not require treatment. Monitor for changes; consider underlying heart disease. May require treatment if symptomatic. Consider temporary pacing. Monitor closely due to the risk of progression. First-degree heart block (Option A): The PR interval is prolonged but typically not greater than 0.50 seconds, i.e. > 0.20 seconds but < 0.50 seconds. ECG does not show any dropped beat. {{caption_text}} AV dissociation (Option D) is seen in third-degree heart blocks (complete heart block) (Option C) due to complete failure of the conduction between atria and ventricles. {{caption_text}}



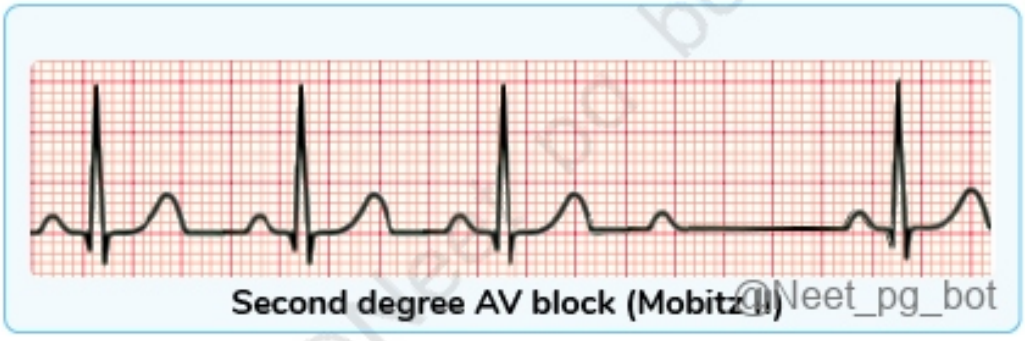

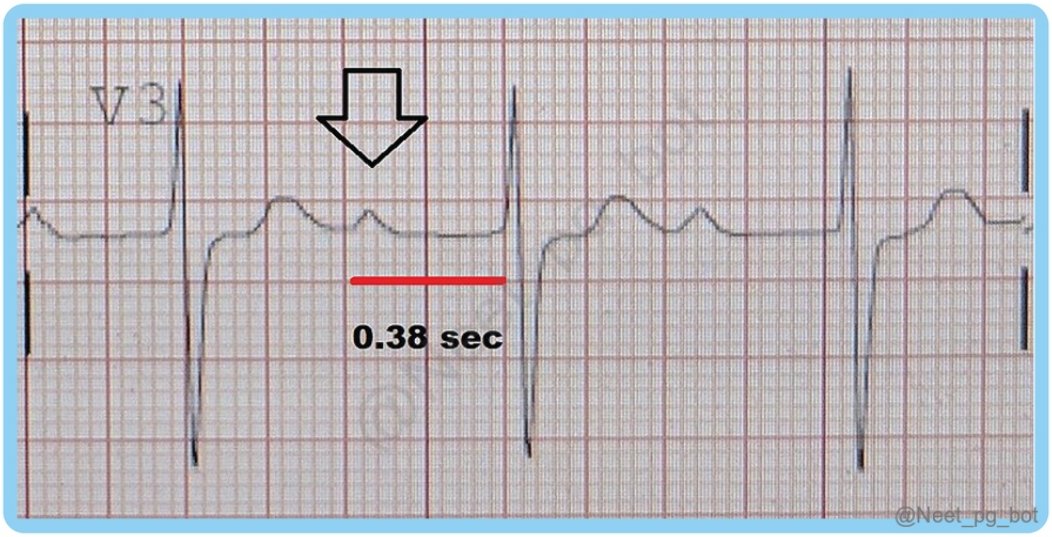

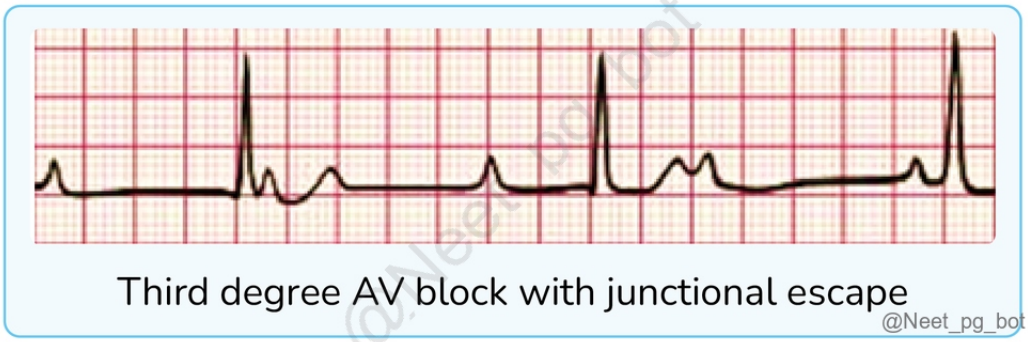

References:

Davidson's Principles and Practice of Medicine, 24th Edition, Page: 477, 478.

↑ *Back to this question in Part A*

@Neet_pg_bot

Q50: A 75-year-old woman with Type 2 diabetes mellitus and hypertension, developed features of heart failure and expired. The post-mortem cardiac biopsy slide is given below. What is the likely diagnosis? (Q854713)

A. Dilated Cardiomyopathy

B. Restrictive cardiomyopathy

C. Hypertrophic cardiomyopathy

D. Takotsubo cardiomyopathy

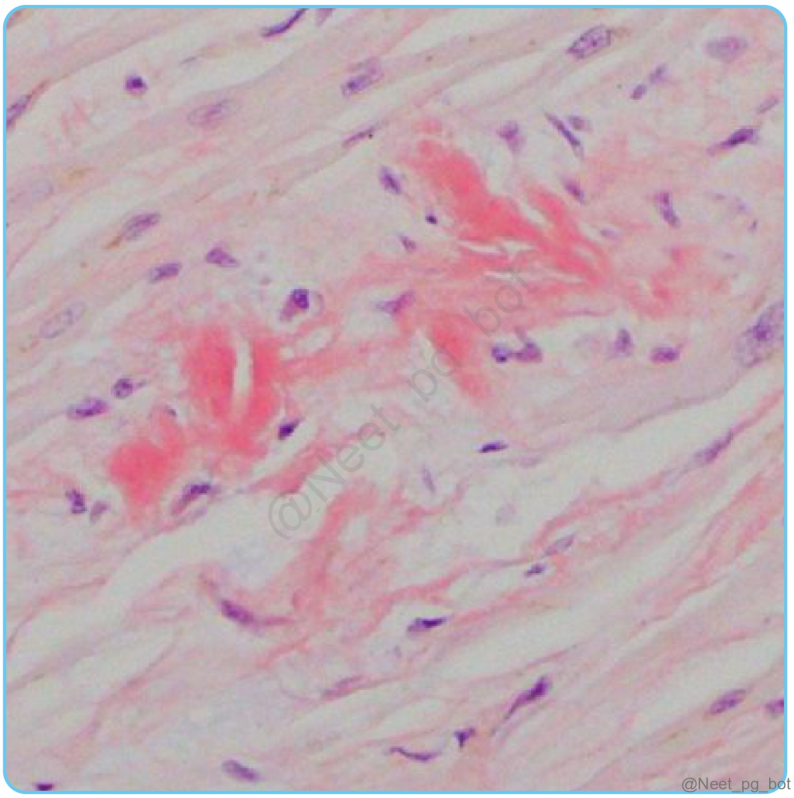

Correct Answer: B. Restrictive cardiomyopathy

Explanation: The image given here is of amyloid deposits (pink hyaline) in the myocardium causing myocardial stiffening and restriction leading to restrictive cardiomyopathy. Restrictive Cardiomyopathy Characterized by abnormal diastolic function, often with mildly reduced contractility and ejection fraction (usually 30–50%). Causes Infiltrative diseases : Amyloidosis (Most common cause) Sarcoidosis Hemochromatosis Fibrotic conditions : Radiation therapy Scleroderma Endomyocardial fibrosis Storage diseases : Glycogen storage diseases (types II, III) Fabry's disease Pathophysiology Abnormal Diastolic Function The primary abnormality in restrictive cardiomyopathy is impaired diastolic filling due to the stiffened ventricular walls. Elevated end-diastolic pressures in both ventricles without significant chamber dilation. Bilateral Atrial Enlargement The non-compliant ventricles lead to increased pressures, resulting in dilation of both atria. Right-Sided Heart Failure The stiff ventricles result in increased filling pressures, particularly affecting the right side, causing peripheral oedema, ascites, and jugular venous distention. Amyloid Infiltration (in amyloidosis) Amyloid fibrils (pink hyaline deposits) accumulate between myocytes, leading to myocardial stiffening and restrictive physiology. {{caption_text}} Cardiac amyloidosis (Congo red stain) Fibrosis In conditions like radiation-induced cardiomyopathy or endomyocardial fibrosis, stiffening of the myocardium occurs due to scarring, further impairing ventricular filling. Dilated cardiomyopathy (Option A) can be due to many causes broadly classified as infective, noninfective, toxic, and metabolic causes. The biopsy shows myocyte shape variation, inflammation, interstitial fibrosis, signs of cardiotoxicity (depending on the cause), etc. This is however not the given scenario. {{caption_text}} Hypertrophic cardiomyopathy (Option C) is a genetic disorder and the histological examination shows enlarged cardiomyocytes with eosinophilic cytoplasm and box-shaped nuclei, normal myocardium in patches, interstitial fibrosis, microvascular ischemia, intercalated discs and desmosomes. {{caption_text}} Takotsubo cardiomyopathy (Option D), or stress cardiomyopathy, is a transient condition characterized by left ventricular apical ballooning often triggered by emotional or physical stress, mimicking acute coronary syndrome without coronary obstruction. The given image does not represent Takotsubo cardiomyopathy.

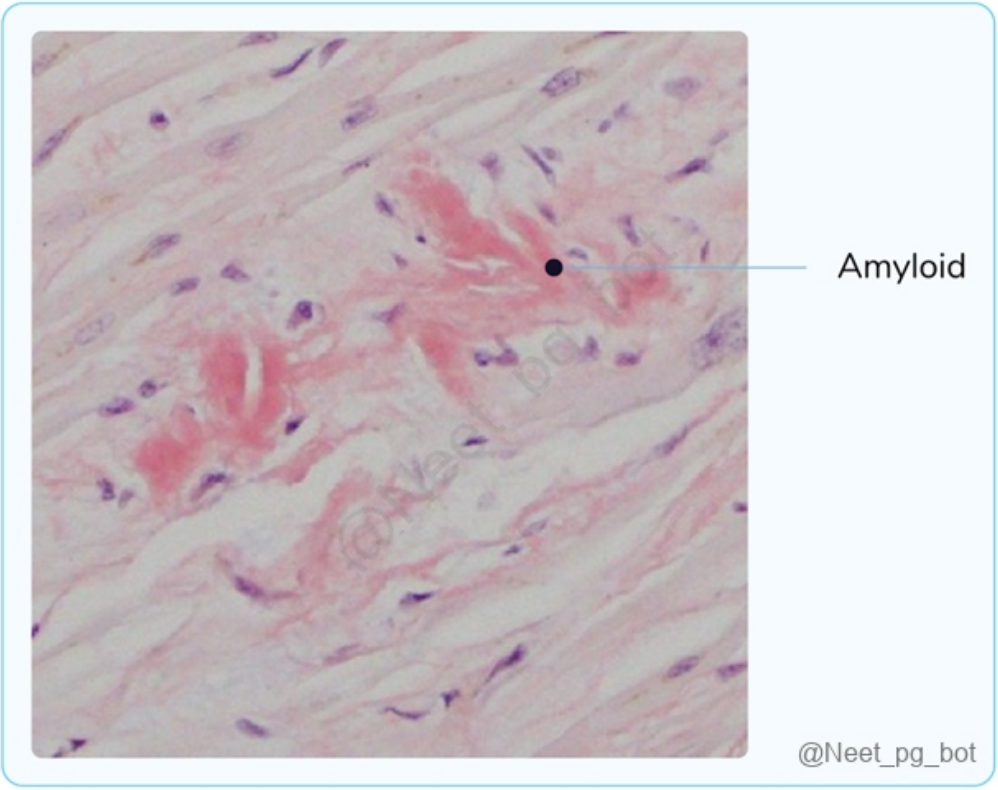
Amyloid
@Neet_pg_bot

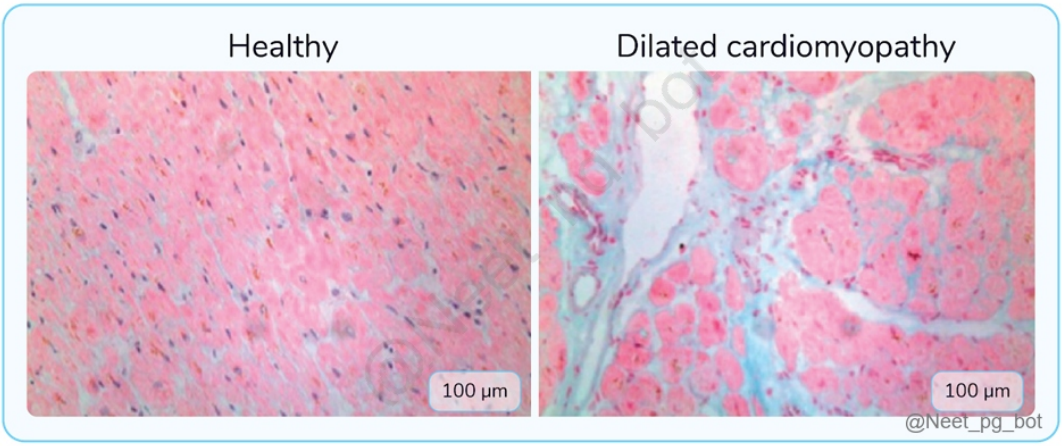
Healthy
Dilated cardiomyopathy
100 µm
100 µm
@Neet_pg_bot

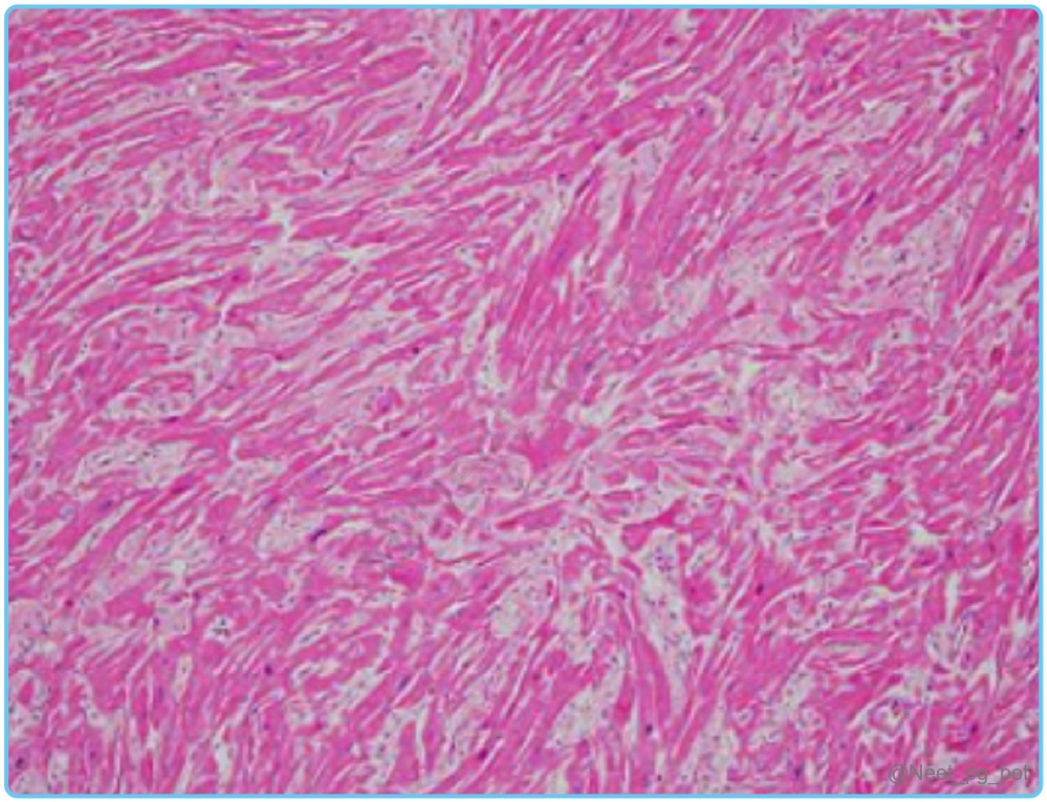

References:

Harrison’s Principles of Internal Medicine, 21st Edition, Page 1967,1968,1969

Pink hyaline

Radiation

Atrial dilatation

↑ *Back to this question in Part A*

@Neet_pg_bot

Q51: A 60-year-old diabetic male with central chest pain, shortness of breath and palpitations came to the emergency department. An ECG was taken, which showed NSTEMI. Which of the following is the right treatment? (Q854724)

A. Aspirin + Clopidogrel

B. Aspirin + Statin

C. Aspirin + Clopidogrel + LMWH

D. Aspirin + LMWH

Correct Answer: C. Aspirin + Clopidogrel + LMWH

Explanation: NSTEMI is a form of Non-ST Elevation Acute Coronary Syndrome (NSTE-ACS) caused by partial occlusion of a coronary artery due to a platelet-rich thrombus . Management includes antithrombotic therapy , which consists of: 1. Dual Antiplatelet Therapy (DAPT) Aspirin P2Y12 inhibitor (Clopidogrel / Ticagrelor / Prasugrel) 2. Anticoagulation Low Molecular Weight Heparin (Enoxaparin) or UFH / Fondaparinux ■■■■■■■ Important: Thrombolysis is not indicated in NSTEMI because there is no complete coronary occlusion. ■■■■■■■Aspirin + Clopidogrel (Option A) is incorrect as anticoagulation is also required. Aspirin + Statin (Option B) : Statins are used, but antiplatelet + anticoagulation therapy is essential and prefereed over use of statins. Aspirin + LMWH (Option D) is incorrect as it does not involve a P2Y12 inhibitor (dual antiplatelet therapy required).

References:

Harrison's Principles of Internal Medicine, 21st Edition, Pages 2047, 2048, 2049, 2051, 2053

↑ *Back to this question in Part A*

@Neet_pg_bot

Q52: Which of the following statements about the culture taken in a suspected case of infective endocarditis is correct? (Q854726)

A. Two samples from peripheral lines 30 minutes apart

B. Three samples from peripheral lines 1 hour apart

C. One sample only from the peripheral line

D. Two peripheral samples, two days apart

Correct Answer: B. Three samples from peripheral lines 1 hour apart

Explanation: The culture taken in a suspected case of infective endocarditis must be by at least 3 blood cultures drawn from separate venipuncture sites over ≥1 hour. Modified Duke’s Criteria - Major criteria Positive blood cultures Identification of a typical organism from two cultures, or persistent positive cultures drawn more than 12 hours apart. At least 3 blood cultures drawn from separate venipuncture sites over ≥1 hour. (Option B) A single positive blood culture for Coxiella burnetii or a phase I IgG antibody titre > 1:800 . Evidence of endocardial involvement Positive echocardiographic findings such as vegetations, abscesses, or new valvular regurgitation. Oscillating intracardiac masses or partial dehiscence of a prosthetic valve. Additional diagnostic tools like FDG-PET/CT or EKG-gated cardiac CT angiograms also meet major criteria for prosthetic valve endocarditis. (Added by the European Society of Cardiology)

References:

Harrison’s Principles of Internal Medicine, 21st Edition, Page: 1026.

Davidson’s Principles and Practice of Medicine, 24th Edition, Page: 529.

↑ *Back to this question in Part A*

@Neet_pg_bot

Q53: Identify the condition associated with the murmur depicted in the image below. (Q855412)

A. Mitral Regurgitation

B. Aortic Regurgitation

C. Aortic Stenosis

D. Mitral Stenosis

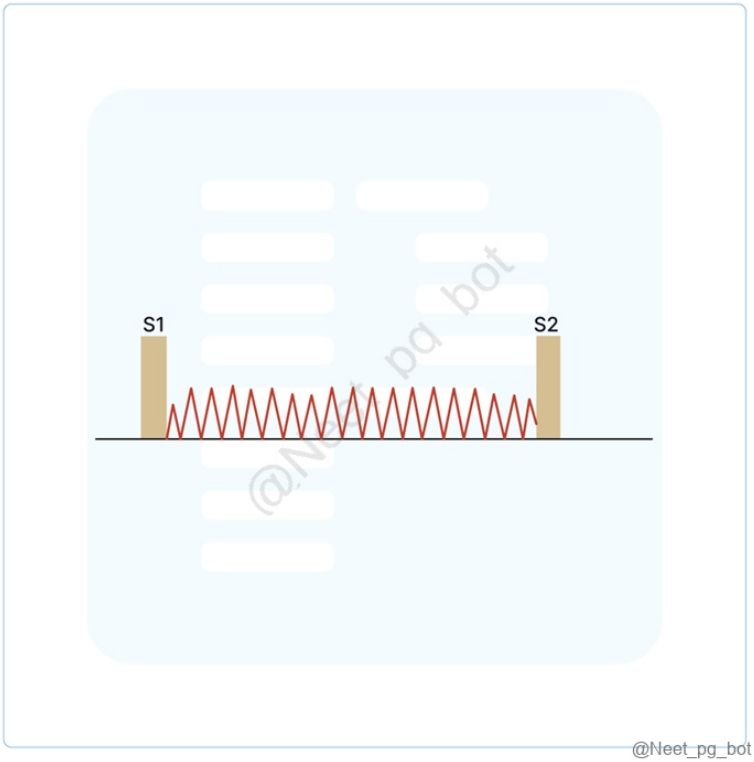

Correct Answer: A. Mitral Regurgitation

Explanation: Type: Pansystolic murmur. Location: Best heard at the apex, radiates to the axilla. Intensity: Grade II-IV, soft/absent S1 in chronic cases. Dyspnea, fatigue, orthopnea, atrial fibrillation. Aortic Regurgitation (AR) (Option B) Incomplete closure of the aortic valve, causing retrograde flow into LV. Type: Diastolic decrescendo

murmur. Location: Best heard at left sternal border (3rd-4th ICS). Features: High-pitched, decrescendo. Bounding pulses, wide pulse pressure, Water-Hammer pulse, heart failure symptoms. Aortic Stenosis (AS) (Option C) Narrowing of the aortic valve, obstructing LV outflow. Type: Systolic ejection murmur. Location: Best heard at right upper sternal border (2nd ICS), radiates to carotids. Features: Crescendo-decrescendo. Angina, syncope, left ventricular hypertrophy, paradoxical S2 splitting. Mitral Stenosis (MS) (Option D) Narrowing of the mitral valve, obstructing flow from LA to LV. Type: Diastolic rumbling murmur. Location: Best heard at apex in left lateral decubitus position. Features: Low-pitched, with an opening snap after S2. Dyspnea, pulmonary hypertension, right-sided heart failure, atrial fibrillation. Heart Murmurs Definition Abnormal heart sounds caused by turbulent blood flow through valves or cardiac chambers. Classification Systolic Murmurs: Occur between S1 and S2 (e.g., MR, AS). Diastolic Murmurs: Occur between S2 and S1 (e.g., MS, AR). Continuous Murmurs: Occur throughout the cardiac cycle (e.g., PDA). Clinical Assessment Includes murmur timing, intensity, location, radiation, and associated cardiac or systemic features. Grading System (Intensity) Grade I: Barely audible. Grade II: Soft but easily audible. Grade III: Loud without thrill. Grade IV: Loud with a palpable thrill. Grade V: Very loud, audible with edge of stethoscope. Grade VI: Audible without a stethoscope.

References:

Harrison's Principles of Internal Medicine, 21st Edition, Page: 1821, 1822, 1823, 1981, 1988, 1991, 1992, 1996, 1997.

↑ *Back to this question in Part A*

@Neet_pg_bot

Q54: A 40-year-old female patient came with complaints of chest pain, palpitation, and shortness of breath. On examination, a mid-diastolic murmur was heard, and a prominent 'a' wave was found on JVP. What is the most likely diagnosis? (Q855479)

A. Mitral stenosis

B. Tricuspid stenosis

C. Mitral regurgitation

D. Tricuspid regurgitation

Correct Answer: B. Tricuspid stenosis

Explanation: The combination of a mid-diastolic murmur and a prominent 'a' wave in the jugular venous pressure (JVP) suggests tricuspid stenosis (TS). The mid-diastolic murmur, which can also occur in mitral stenosis, is best heard along the left sternal border and over the xiphoid process, increasing during inspiration due to enhanced venous return. The prominent 'a' wave in JVP is a result of increased right atrial pressure, which impedes right atrial emptying during diastole, creating a giant 'a' wave. ECG findings typically show right atrial enlargement, with tall, peaked P waves in leads II, III, and aVF. Type Cause Features of Murmur Associated Symptoms JVP Findings Aortic Regurgitation (AR) Incomplete closure of the aortic valve, causing retrograde flow into LV. Type: Diastolic decrescendo murmur. Location: Best heard at left sternal border (3rd-4th ICS). Features: High-pitched,

decrescendo. Bounding pulses Wide pulse pressure Water-Hammer pulse Heart failure symptoms. Normal or minimally elevated JVP unless associated with heart failure. Aortic Stenosis (AS) Narrowing of the aortic valve, obstructing LV outflow. Type: Systolic ejection murmur. Location: Best heard at right upper sternal border (2nd ICS), radiates to carotids. Features: Crescendo-decrescendo. Angina Syncope Left ventricular hypertrophy Paradoxical S2 splitting. Normal JVP unless severe. Mitral Regurgitation (MR) (Option C) Incomplete closure of the mitral valve, causing backflow from LV to LA. Type: Pansystolic murmur. Location: Best heard at the apex, radiates to the axilla. Intensity: Grade II-IV, soft/absent S1 in chronic cases. Dyspnea Fatigue Orthopnea Atrial fibrillation. Elevated JVP, prominent V wave due to regurgitant flow. Mitral Stenosis (MS) (Option A) Narrowing of the mitral valve, obstructing flow from LA to LV. Type: Diastolic rumbling murmur. Location: Best heard at apex in left lateral decubitus position. Features: Low-pitched, with an opening snap after S2. Dyspnea Pulmonary hypertension Right-sided heart failure Atrial fibrillation. Elevated JVP with prominent "a" wave due to increased atrial pressure. Tricuspid Regurgitation (TR) (Option D) Incomplete closure of the tricuspid valve, causing backflow into the right atrium. Type: Pansystolic murmur. Location: Best heard at the lower left sternal border. Features: Holosystolic, blowing murmur. Hepatomegaly Ascites Edema Right-sided heart failure. Elevated JVP with prominent "v" wave due to backflow into the right atrium. Tricuspid Stenosis (TS) Narrowing of the tricuspid valve, obstructing flow from RA to RV. Type: Diastolic murmur. Location: Best heard at the lower left sternal border. Features: Low-pitched rumbling murmur. Fatigue Hepatomegaly Ascites Peripheral edema. Elevated JVP with prominent "a" wave due to increased atrial pressure.

References:

Harrison's Principles of Internal Medicine, 21st Edition, Page: 279, 283, 284, 1991, 1992, 1995-1997, 2001-2004.

↑ *Back to this question in Part A*

@Neet_pg_bot

Q55: A patient who is a known case of hypertension on multiple antihypertensive medications came to the OPD. His ECG finding is given below. Which of the following drugs is responsible for the ECG finding? (Q855489)

A. Prazosin

B. Metoprolol

C. Hydrochlorothiazide

D. Spironolactone



Correct Answer: D. Spironolactone

Explanation: The ECG finding of tall, peaked T waves suggests hyperkalemia. Among the listed medications, spironolactone is the drug most likely to cause hyperkalemia. Mechanism of Spironolactone: Spironolactone is a potassium-sparing diuretic. It works by blocking the mineralocorticoid receptor in the distal tubule and collecting duct of the kidneys, which inhibits sodium reabsorption and potassium excretion. As a result, it promotes sodium diuresis but retains potassium, potentially leading to hyperkalemia. ECG Changes in Hyperkalemia: Tall, peaked T waves are a classic ECG finding in hyperkalemia. As the potassium level rises, it affects the ST-T segments and can lead to changes in repolarization. Serum Potassium Level (mEq/L) ECG Changes 5.5–6.5 Tall, peaked T waves 6.5–7.5 Loss of P waves 7.0–8.0 Widened QRS complex > 8.0 Sine wave pattern {{caption_text}} Prazosin (Option A): This is an alpha-1 antagonist used in the treatment of hypertension and does not commonly cause hyperkalemia. Metoprolol (Option B): This is a beta-blocker used for hypertension and cardiovascular issues. It does not typically cause hyperkalemia. Hydrochlorothiazide (Option C): This is a thiazide diuretic, which actually promotes potassium loss and would more likely cause hypokalemia rather than hyperkalemia.

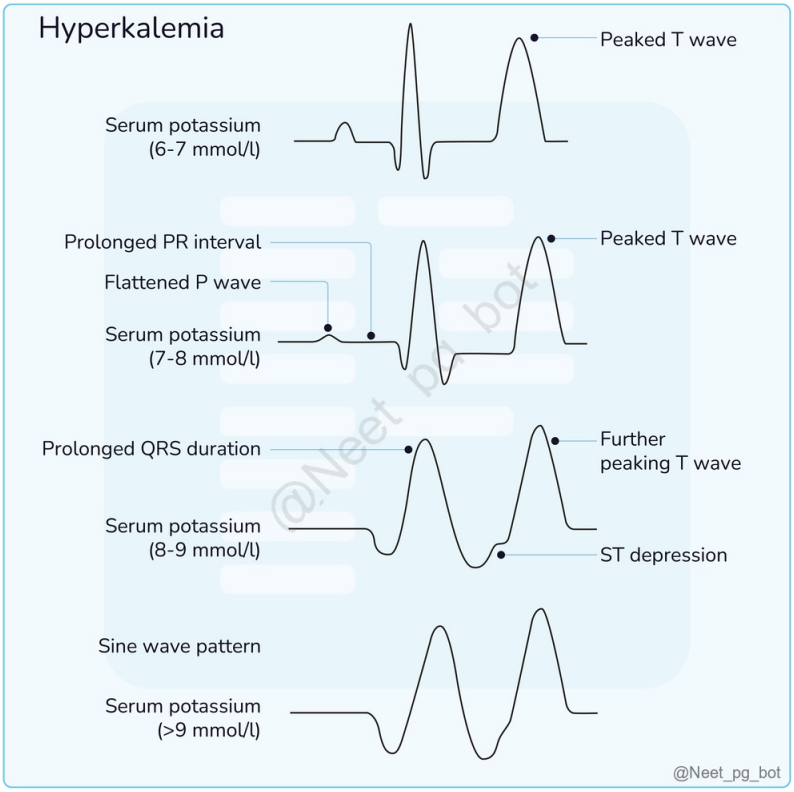

References:

Harrison's Principles of Internal Medicine, 21st Edition, Page: 348, 350-355. Goodman & Gilman's The Pharmacological Basis of Therapeutics, 13th Edition, Page: 209, 454-456. https://www.ncbi.nlm.nih.gov/pmc/articles/PMC6205312/

↑ *Back to this question in Part A*

@Neet_pg_bot

Q56: A patient presents with dyspnea and distended neck veins that increase on inspiration. There is no murmur. What is the diagnosis? (Q858032)

A. Constrictive pericarditis

B. Aortic regurgitation

C. Tricuspid stenosis

D. Pulmonary arterial hypertension

Correct Answer: A. Constrictive pericarditis

Explanation: onstrictive Pericarditis: Pathophysiology: Progressive thickening, fibrosis, and calcification of the pericardium restrict heart filling. Calcification can extend into the myocardium, impairing myocardial contraction. Restricted ventricular filling leads to elevated atrial pressures, causing: Atrial hypertrophy Atrial dilation Atrial fibrillation (common). Primarily manifests as systemic venous congestion (lung congestion is rare). Examination Findings: Finding Description Elevated JVP with rapid y descent Reflects rapid early diastolic filling of the right ventricle due to pressure gradient. atigue Caused by the heart's inability to meet circulatory demands. Rapid, low-volume pulse Restricted filling limits stroke volume, weakening the pulse. Pericardial knock A loud early S3 from the thickened pericardium during diastolic filling. Kussmaul's sign Paradoxical rise in JVP during inspiration. Hepatomegaly Liver enlargement due to i ncreased venous pressure. Ascites Abdominal fluid accumulation due to systemic venous congestion. Peripheral oedema Swelling in the extremities from fluid retention. Pulsus paradoxus A fall in systolic BP (10mm Hg) during inspiration, potentially impalpable pulse. Atrial fibrillation Common due to atrial hypertrophy and dilation. Aortic regurgitation (Option B) typically presents with a characteristic diastolic murmur, which is absent in this case. Additionally, aortic regurgitation does not cause increased neck vein distention with inspiration. Tricuspid stenosis (Option C) presents with elevated jugular venous pressure, but also includes a diastolic murmur and does not demonstrate Kussmaul's sign. The jugular venous pressure in tricuspid stenosis remains constant or decreases with inspiration. Pulmonary arterial hypertension (Option D) can cause increased jugular venous pressure but does not demonstrate Kussmaul's sign. While it can cause right-sided heart failure symptoms, the characteristic inspiratory increase in neck vein distention is not a typical feature.

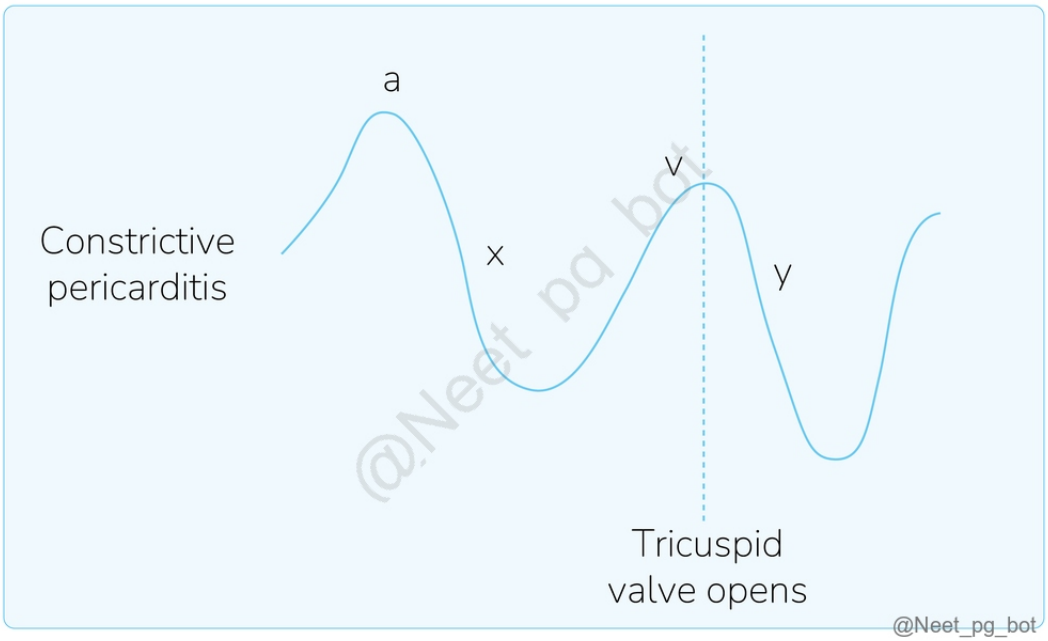

References:

Davidson's Principles and Practice of Medicine, 24th Edition, Page 543

↑ *Back to this question in Part A*

@Neet_pg_bot

Q57: Which of the following drugs reduce mortality in a patient with heart failure? (Q858361)

A. Metoprolol

B. Furosemide

C. Prazosin

D. Torsemide

Correct Answer: A. Metoprolol

Explanation: aptopril, Enalapril ARBs: Telmisartan, Olmesartan ARNI: ARB+Neprilysin inhibitor - Valsartan-Sacubitril (most preferred 1st line drug) ADR: Cough, angioedema Beta-blockers Cardioselective (2nd gen): Metoprolol, Bisoprolol 3rd gen: Carvedilol (both α- & β- blocking action) - Best beta blocker for heart failure ADR: Bradycardia, Hypotension SGLT-2 Inhibitors Dapagliflozin, Empagliflozin ADR: UTI, Forunier gangrene, Euglycemic DKA Aldosterone antagonists Spironolactone ADR: Gynaecomastia Furosemide (Option B): While furosemide is commonly used in heart failure for symptom relief and fluid management, it has not been shown to reduce mortality in heart failure patients. It primarily helps manage congestion and improve symptoms but does not affect the underlying disease progression or survival. Prazosin (Option C) : Although prazosin is an alpha-blocker that can reduce afterload, clinical trials have not demonstrated mortality benefit in heart failure patients. In fact, alpha-blockers may increase the risk of heart failure worsening due to their vasodilatory effects and reflex sympathetic activation. Torsemide (Option D) : Similar to furosemide, torsemide is a loop diuretic that helps manage fluid overload and symptoms in heart failure but has not been proven to reduce mortality. While it may have better bioavailability than furosemide, neither medication has shown a survival benefit in clinical trials.

References:

Davidson’s Principles & Practice of Medicine, 24th Edition, Pages- 464-468

↑ *Back to this question in Part A*

@Neet_pg_bot

Q58: A 65-year-old man with known lung cancer presents with acute shortness of breath and chest discomfort. On examination, percussion over the left infrascapular area is dull, and breath sounds are markedly decreased. He has hypotension, tachycardia, elevated JVP, and muffled heart sounds. What is the most likely diagnosis? (Q793802)

A. Cardiac tamponade

B. Chronic constrictive pericarditis

C. Pulmonary embolism

D. Left-sided pleural effusion

Correct Answer: A. Cardiac tamponade

Explanation: Correct answer : A) Cardiac tamponade Cardiac tamponade occurs when rapid accumulation of pericardial fluid compresses the heart and leads to obstructive shock . Key clinical signs: Beck's triad: Hypotension Elevated JVP (non-pulsatile) Muffled heart sounds Pulsus paradoxus (>10 mmHg fall in SBP during inspiration) Dullness + decreased breath sounds (left infrascapular area): Pericardial effusion from tumor encroachment can cause adjacent lung compression → basal dullness. This combination of respiratory distress + shock + muffled heart sounds strongly suggests tamponade . Chronic constrictive pericarditis (Option B): Chronic, stable condition with Kussmaul's sign, not acute shock. Pulmonary embolism (Option C): Lungs usually clear, percussion normal, and no Beck's triad → not tamponade. Left-sided pleural effusion (Option D): Causes dullness and ↓ breath sounds, but no hypotension, no muffled heart sounds, no JVP rise → not tamponade.

References:

Harrison's Principles of Internal Medicine, 21e

↑ *Back to this question in Part A*

@Neet_pg_bot

Q59: Identify the conduction abnormality from the ECG given below? (Q855705)

A. First degree heart block

B. Ventricular tachycardia

C. Third degree heart block

D. Second degree heart block



Correct Answer: D. Second degree heart block

Explanation: Given ECG shows progressive lengthening of PR intervals until a dropped beat occurs, which indicates Mobitz type I block . It can be further classified into two types: Mobitz Type I (Wenckebach) - is characterized by a progressive prolongation of the PR interval until a beat is dropped Mobitz Type II - involves intermittent blocked beats without progressive PR interval prolongation. First-degree heart block (Option A) is characterized by a prolonged PR interval on the ECG. It indicates a delay in the electrical conduction between the atria and ventricles. Ventricular tachycardia (Option B) is a rapid heart rhythm originating from the ventricles. On the ECG, it appears as a wide QRS complex with a heart rate exceeding 100 beats per minute. Third-degree heart block (complete heart block) (Option C) is a severe conduction abnormality characterised by atrioventricular dissociation.

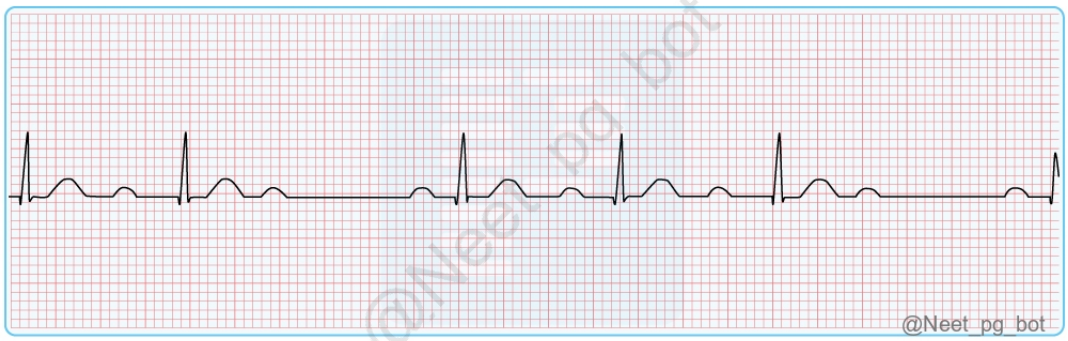

References:

Harrison's Principles of Internal Medicine, 21st Edition, Page 1877, 1878, 1881, 1882

Davidson's Principles and Practice of Medicine, 24th Edition, Page 477-478

↑ *Back to this question in Part A*

@Neet_pg_bot

Q60: A 45-year-old patient with suspected mitral stenosis is found to have a soft or absent first heart sound on auscultation. Which of the following conditions is least likely to cause a soft or absent S1? (Q855710)

A. Severe mitral valve calcification

B. Aortic regurgitation

C. First degree heart block

D. Advanced mitral stenosis

Correct Answer: B. Aortic regurgitation

Explanation: : Prolonged PR interval delays ventricular contraction, allowing mitral leaflets to drift partially closed, producing a softer S1. Advanced mitral stenosis (Option D): In severe disease, leaflet stiffness can decrease mobility and soften or abolish S1 ; mild disease usually produces a loud S1.

References:

Harrison's Principles of Internal Medicine, 21st Edition, Page 1987, 1988

↑ *Back to this question in Part A*

@Neet_pg_bot

Q61: Which of the following is the initial treatment of choice for managing the condition in a female patient who comes to the hospital with palpitations, having stable vital signs and an ECG showing the following? (Q855330)

A. Amiodarone

B. Adenosine

C. DC cardioversion

D. Primary PCI

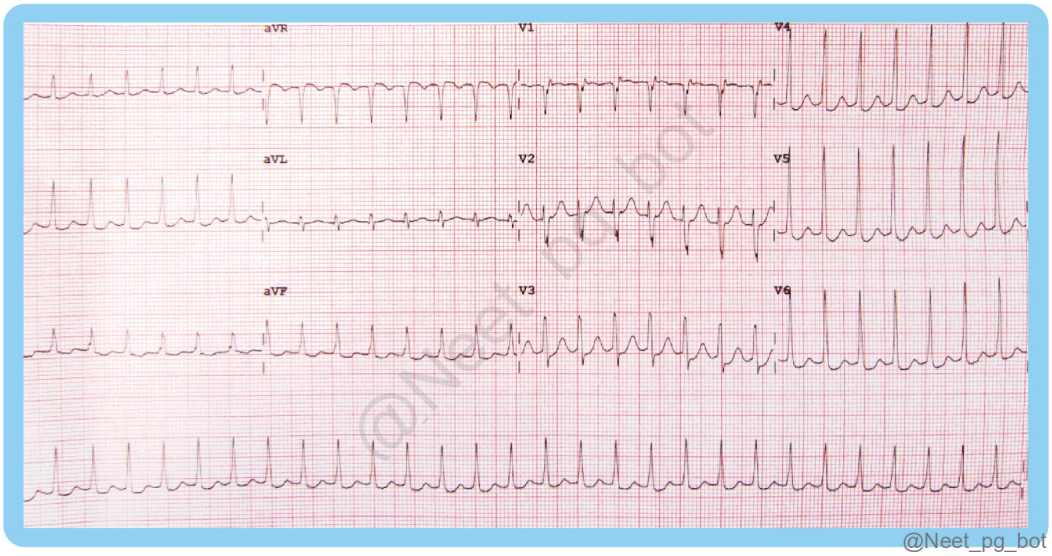

Correct Answer: B. Adenosine

Explanation: Adenosine is the first-line management of the presented condition. The ECG pattern shown suggests Paroxysmal SupraVentricular Tachycardia (PSVT) , a common arrhythmia characterized by rapid heart rates originating above the ventricles. Adenosin e is a potent vasodilator and affects the electrical conduction system of the heart. It activates specific receptors in the heart, particularly the adenosine A1 receptors, which help to slow

down the conduction through the AV node. This interruption of the abnormal electrical pathway in SVT can restore normal sinus rhythm. Paroxysmal Supraventricular Tachycardia (PSVT): Signs and Symptoms: Sudden onset of rapid, regular palpitations Dizziness or lightheadedness Shortness of breath Chest discomfort or pressure Anxiety Fatigue In severe cases: syncope, hypotension, or heart failure symptoms ECG Findings: Regular, narrow-complex tachycardia (QRS duration <120 ms) Reduced R-R interval Heart rate between 150-250 bpm P waves often not visible or buried in T waves {{caption_text}} Common types include: a) AV Nodal Reentrant Tachycardia (AVNRT): Retrograde P waves may appear as pseudo R' in V1 or pseudo S in inferior leads b) AV Reentrant Tachycardia (AVRT): Retrograde P waves may be visible after the QRS complex Management: Acute termination: Vagal maneuvers (e.g., Valsalva, carotid sinus massage) If vagal maneuvers fail, IV adenosine is the first-line pharmacological treatment: 6 mg - 12mg fast iv push. Alternative drugs: verapamil, diltiazem, or beta-blockers Synchronized cardioversion for hemodynamically unstable patients Long-term management: Catheter ablation: Often curative, especially for AVNRT and AVRT Pharmacological therapy: Beta-blockers or calcium channel blockers for prevention Class IC or III antiarrhythmic drugs in selected cases Patient education on performing vagal maneuvers Lifestyle modifications Avoid triggers (e.g., caffeine, alcohol, stress) Regular exercise Adequate sleep Amiodarone (Option A) is used to treat Stable Monomorphic Ventricular tachycardia. DC Cardioversion (Option C) is used to treat Atrial flutter, Atrial fibrillatio.n Primary PCI (Option D) is used to treat acute myocardial infarctio.n



References:

Goldberger’s Clinical Electrocardiography, A Simplified Approach, 9th edition, Page 142, 143.

↑ *Back to this question in Part A*

@Neet_pg_bot

Q62: A patient with heart disease has breathlessness when going to the bathroom. What grade does he belong to? (Q855360)

A. NYHA 3

B. NYHA 4

C. mMRC 4

D. mMRC 5

Correct Answer: A. NYHA 3

Explanation: NYHA 3 indicates moderate symptoms. Patients classified as NYHA 3 experience symptoms such as marked limitation of physical activity, becoming symptomatic with less than ordinary activity (such as going to the bathroom) and having no symptoms at rest. NYHA functional classification assesses the impact of heart disease on a patient's daily activities. NYHA 4 (Option B) indicates severe symptoms. Patients classified as NYHA 4 experience symptoms even at rest and are unable to carry out any physical activity without discomfort. The mMRC (Option C) dyspnea scale is used to assess dyspnea (shortness of breath) in patients with respiratory conditions. mMRC 4 indicates severe dyspnea, where patients become too breathless to leave the house or experience significant discomfort even while at rest. mMRC 5 (Option D) is not a standard category in the MMRC dyspnea scale. The scale typically ranges from 0 to 4, with 0 indicating no dyspnea and 4 indicating the most severe dyspnea.

References:

Harrison's Principles of Internal Medicine, Twenty-First Edition 1798, 2186

↑ *Back to this question in Part A*

@Neet_pg_bot

Q63: Based on the ECG given below, which of the following is not used in the management of the condition? (Q855364)

A. Verapamil

B. Metoprolol

C. Amiodarone

D. Non-synchronised DC shock

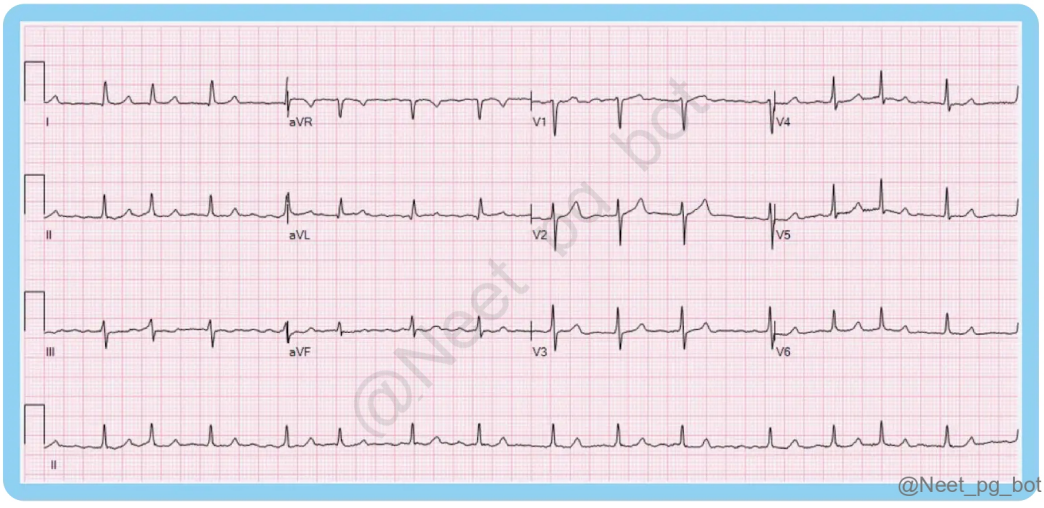

Correct Answer: D. Non-synchronised DC shock

Explanation: ECG is suggestive of atrial fibrillation a s there is an irregularly irregular rhythm and absent P waves with narrow QRS complexes are present. In atrial fibrillation, synchronised DC shock/cardioversion can be used. Nonsynchronised DC shock (Defibrillation) is not used in the management of these patients. Verapamil (Option A) can be used in the management of patients with atrial fibrillation. Metoprolol (Option B) can be used in the management of patients with atrial fibrillation. Amiodarone (Option C) can be used in the management of patients with atrial fibrillation.

References:

Harrison's Principles of Internal Medicine, Twenty-First Edition Page 1817, 1874, 1903, 1904, 1905, 1906

↑ *Back to this question in Part A*

@Neet_pg_bot

Q64: Which of the following foods is not included in the DASH diet? (Q857042)

A. Rich in potassium

B. Rich in calcium

C. Rich in sodium

D. Rich in magnesium

Correct Answer: C. Rich in sodium

Explanation: The DASH diet (Dietary Approaches to Stop Hypertension) recommends limiting the intake of sodium, as high sodium consumption is associated with increased blood pressure. The DASH diet suggests reducing the use of table salt and avoiding processed foods that are typically high in sodium, such as fast food, canned soups, and salty snacks. DASH-type dietary plan: A diet rich in fruits, vegetables, and low-fat dairy products with reduced saturated and total fat content. Diet is also rich in potassium (Option A), calcium (Option B), and magnesium (Option D) . DASH Diet Originated in the 1990s through NIH-funded research, found to lower systolic BP by 6-11 mm Hg. It promotes fruits, vegetables, lean meats, and low sodium (~1500 mg/day) and encourages fresh, minimally processed food. Key Nutrients in DASH diet: Carbohydrates: Whole grains, legumes, leafy greens. Fats: Healthy fats (olive oil, nuts, omega-3 fish), avoid trans fats. Proteins: Plant-based proteins preferred, lean meats, low-fat dairy. Electrolytes: Potassium: Helps lower BP, prevents muscle cramps, and supports heart function. Sources: bananas, oranges, spinach, beans. Sodium: DASH limits sodium to ~1500 mg/day to reduce hypertension risk. Calcium: Essential for bone health and muscle function. Sources: dairy, leafy greens. Magnesium: Aids blood vessel relaxation and BP control. Sources: whole grains, nuts, seeds. Clinical Significance of DASH diet: Lowers BP, blood glucose, LDL, triglycerides, and insulin resistance. Helps with metabolic syndrome, diabetes, and heart failure. Linked to reduced risk of colorectal cancer, liver disease, and celiac disease. Reduces hospitalization and mortality in heart failure patients. Meets ADA recommendations for diabetes management.

References:

Harrison’s Principle of Internal Medicine, 21st edition, Page 2082

https://www.ncbi.nlm.nih.gov/books/NBK482514/

↑ *Back to this question in Part A*

@Neet_pg_bot

Q65: A patient has presented with features of cardiac tamponade. Which of the following is correct regarding this condition? (Q857043)

A. Pulsus Paradoxus is always present

B. Kussmaul sign is always present

C. Tall A wave is present

D. Jugular veins column is visibly distended without pulsations

Correct Answer: D. Jugular veins column is visibly distended without pulsations

Explanation: Cardiac tamponade refers to the accumulation of fluid in the pericardial sac, which puts pressure on the heart and impairs its ability to pump effectively. Jugular veins column distending without pulsations is a characteristic finding in cardiac tamponade. Due to the increased pressure in the pericardial sac, the jugular veins become visibly distended, but the normal pulsations with each heartbeat are diminished or absent. Cardiac Tamponade Definition A condition where the cardiac chambers are compressed by a tense pericardial effusion, limiting cardiac inflow. Fluid accumulation of as little as 200 ml to upwards of 2L may lead to cardiac tamponade development. Beck's triad Jugular Venous Distension: Due to increased central venous pressure. Prominent x descent and an absent y descent. Hypotension : Resulting from impaired cardiac output. Muffled Heart Sounds : Caused by fluid accumulation in the pericardial space, dampening heart sounds. Other Clinical features Pulsus Paradoxus : A drop in systolic BP during inspiration, greater than 10 mm Hg. It is present in most of the conditions but not always (Option A) and can vary depending on the severity of tamponade and other factors. Causes of Pulsus paradoxus: Lung Conditions: Acute asthma, COPD, tension pneumothorax, pleural effusion, pulmonary embolism. Heart Conditions: Cardiac tamponade, constrictive pericarditis. Kussmaul sign refers to an abnormal rise in jugular venous pressure during inspiration. It is not specific to cardiac tamponade (Option B) and can be seen in various cardiac and respiratory conditions. It is not always present in cardiac tamponade. The A wave represents atrial contraction on the jugular venous pulse waveform. In cardiac tamponade, the elevated pressure in the pericardial sac can impair atrial filling, leading to a reduced or absent A wave rather than a tall A wave (Option C).

References:

Harrison’s Principles of Internal Medicine, 21st edition, Page 1853, 2021, 2022

Low-Pressure Cardiac Tamponade | Circulation

Fluid amount

Pulsus paradoxus

↑ *Back to this question in Part A*

@Neet_pg_bot

Q66: What is the clinical diagnosis for a young male who has no symptoms but is found to have a wide fixed split S2 during auscultation? (Q857046)

A. ASD

B. VSD

C. TOF

D. BAV

Correct Answer: A. ASD

Explanation: A wide fixed split S2 on auscultation is a characteristic finding in atrial septal defects (ASD), where there is abnormal communication between the atria. It allows increased blood flow from the left atrium to the right atrium, causing a delay in the closure of the pulmonic valve, resulting in a wide fixed split S2. Types of S2 split Conditions causing split Narrow split S2 Mild Left Ventricular Failure Early Aortic Stenosis wide split fixed S2 Atrial Septal Defect (ASD) Wide split variable S2 Ventricular Septal Defect (VSD) Right Bundle Branch Block (RBBB) Paradoxical split S2 Left Bundle Branch Block Severe Aortic Stenosis Atrial Septal Defect: Congenital, low-pressure, left to right shunt. The right ventricle will have volume overloading. Types of ASD: Ostium Secundum (most common), Ostium Primum, Sinus Venosus On auscultation: Wide fixed split S2 sound Chest x-ray: May show enlarged right atrial and right ventricular enlargement and increased pulmonary markings Transthoracic echocardiogram: Gold standard imaging modality, helps to detect size and assess the direction of blood flow. A ventricular septal defect (Option A) is another type of congenital heart defect where there is an abnormal opening in the septum between the two ventricles. It typically produces a harsh holosystolic murmur, rather than a wide fixed split S2 heard on auscultation. Tetralogy of Fallot (Option C) is a congenital heart condition characterized by a combination of four heart defects: ventricular septal defect, pulmonary stenosis, right ventricular hypertrophy, and overriding aorta. The characteristic murmur in TOF is a systolic ejection murmur and not specifically associated with a wide fixed split S2. Bicuspid Aortic Valve (Option D) can be associated with aortic stenosis or regurgitation, it is not specifically associated with a wide fixed split S2.

References:

ASD

↑ *Back to this question in Part A*

@Neet_pg_bot

Q67: Which of the following is contraindicated in a patient with Wolff–Parkinson–White (WPW) syndrome presenting with atrial fibrillation? (Q857052)

A. Treadmill test

B. Electrophysiological studies

C. Oral beta blocker

D. Procainamide

Correct Answer: A. Treadmill test

Explanation: Wolff–Parkinson–White (WPW) syndrome is a ventricular pre-excitation syndrome caused by an accessory pathway (Bundle of Kent) that bypasses the AV node, allowing rapid conduction from atria to ventricles. In WPW with atrial fibrillation , impulses can be conducted rapidly to the ventricles through the accessory pathway, predisposing to ventricular fibrillation and sudden cardiac death . Beta blockers are AV nodal–blocking agents . In WPW with atrial fibrillation, AV nodal blockade: Slows AV node conduction Favors rapid conduction via the accessory pathway Increases the risk of ventricular fibrillation Hence, beta blockers are contraindicated in this setting. Option-wise

References:

Harrison’s Principles of Internal Medicine, 21st Edition, Page 1896,1897

https://www.sciencedirect.com/science/article/abs/pii/0002914980901162

https://www.ncbi.nlm.nih.gov/books/NBK554437/#

↑ *Back to this question in Part A*

@Neet_pg_bot

Q68: Which of the following is not correct about Defibrillation? (Q857055)

A. Only be used by a trained person

B. Decrease in success rate with delay in initiation

C. Improve prognosis

D. 1 minute gap between 2 shocks

Correct Answer: D. 1 minute gap between 2 shocks

Explanation: A 1-minute gap between 2 shocks is incorrect, as defibrillation should be delivered without delay to maximize the chances of successful resuscitation. Defibrillation: Indications: Ventricular fibrillation (VF) Pulseless ventricular tachycardia (VT) Personnel Involved: Defibrillation is typically performed by medical personnel trained in Advanced Cardiac Life Support (ACLS) or Pediatric Advanced Life Support (PALS). (Option A) Preparation: Resuscitation (CPR) continues while preparing the defibrillator. Once available, the defibrillator should be used immediately , taking precedence over other measures. Defibrillation Technique: Manual defibrillator paddles or hands-free defibrillator pads are placed on the chest (right sternal border and cardiac apex, or in anteroposterior configuration). The defibrillator is charged and set to the manufacturer's recommended initial energy level (120-200 joules for biphasic defibrillators, 360 joules for monophasic). A shock is delivered after confirming no one is in contact with the patient. Post-Defibrillation: CPR is resumed immediately for 2 minutes after the shock. The pulse and rhythm are checked to assess if VF or pulseless VT has been terminated. If VF or VT persists, defibrillation is repeated, with increasing energy as per guidelines. Medications During Resuscitation: Epinephrine (1 mg IV every 3-5 minutes) should be given after the first unsuccessful shock. Amiodarone (300 mg IV bolus) may be administered if VT or VF persists, with additional doses (150 mg) as needed. Lidocaine can be used in place of amiodarone in some cases, but epinephrine and amiodarone are preferred. Clinical Significance: Early defibrillation increases the chances of survival in VF . After 10 minutes of VF, the chances of successful resuscitation decrease significantly. (Option B & C) Contraindications: There are no contraindications for defibrillation in the presence of VF or pulseless VT.

References:

https://www.ncbi.nlm.nih.gov/books/NBK499899/

↑ *Back to this question in Part A*

@Neet_pg_bot

Q69: Modified duke criteria are used for diagnosis of? (Q857066)

A. Infective endarteritis

B. Infectious mononucleosis

C. Inflammatory myopathy

D. Infective endocarditis

Correct Answer: D. Infective endocarditis

Explanation: Modified duke criteria are used for diagnosis of infective endocarditis. Modified Duke Criteria (2023 update): I. Definite Endocarditis: A. Pathologic Criteria 1. Microorganisms identified in the context of clinical signs of active endocarditis in a vegetation from cardiac tissue; from explanted prosthetic valve or sewing ring; from ascending aortic graft (with concomitant evidence of valve involvement); from an endovascular intra cardiac implantable electronic device (CIED) or from an arterial embolus OR 2. Active endocarditis in the same above mentioned locations. Microorganisms identified in appropriate sample by PCR, amplicon or metagenomic sequencing, or in situ hybridization B. Clinical Criteria (mentioned below) 1. 2 Major Criteria OR 2. 1 Major and 3

Minor Criteria OR 3. 5 Minor Criteria II. Possible Endocarditis: A. 1 Major Criterion and 1 Minor Criterion OR B. 3 Minor Criteria III. Rejected Endocarditis: A. Firm alternate diagnosis explaining signs/symptoms OR B. Lack of recurrence despite antibiotic therapy for only < 4 days OR C. No pathologic/macroscopic evidence of IE at surgery or autopsy with antibiotic therapy for less than 4 days OR D. Does not meet criteria of possible IE Clinical Criteria I. Major Criteria A. Microbiologic Major Criteria (i) Positive blood cultures Microorganisms that commonly cause IE isolated from 2 or more separate blood culture sets OR Microorganisms that occasionally or rarely cause IE isolated from 3 or more separate blood culture sets (ii) Positive laboratory tests Positive polymerase chain reaction (PCR) or other nucleic acid-based technique for Coxiella burnetii , Bartonella species, or Tropheryma whipplei from blood OR Coxiella burnetii antiphase I immunoglobulin G (IgG) antibody titer > 1:800 or isolated from a single blood culture OR Indirect immunofluorescence assays (IFA) for IgM and IgG antibodies to Bartonella henselae or Bartonella quintana with IgG titer ≥ 1:800 B. Imaging Major Criteria (i) Echocardiography and cardiac computed tomography (CT) imaging Echocardiography and cardiac CT showing vegetation, valve/leaflet perforation, valve/leaflet aneurysm, abscess, pseudoaneurysm, or intracardiac fistula OR Significant new valvular regurgitation on echocardiography as compared with previous imaging. Worsening or changing of preexisting regurgitation is not sufficient OR New partial dehiscence of prosthetic valve as compared with previous imaging. (ii) 18F-FDG PET/CT imaging Abnormal metabolic activity involving a native or prosthetic valve, ascending aortic graft (with concomitant evidence of valve involvement), intracardiac device leads, or other prosthetic material C. Surgical Major Criteria Evidence of IE documented by direct inspection during heart surgery neither Major Imaging Criteria nor subsequent histologic or microbiologic confirmation II. MINOR CRITERIA A. Predisposition Previous history of IE Prosthetic valve Previous valve repair Congenital heart disease More than mild regurgitation or stenosis of any etiology Endovascular intracardiac implantable electronic device (CIED) Hypertrophic obstructive cardiomyopathy Intravenous drug use B. Fever Temperature greater than 38.0°C C. Vascular Phenomena Clinical or radiological evidence of arterial emboli, septic pulmonary infarcts, cerebral or splenic abscess, mycotic aneurysm, intracranial hemorrhage, conjunctival hemorrhages, Janeway lesions, purulent pericardium D. Immunologic Phenomena Positive rheumatoid factor, Osler nodes, Roth spots, or immune complex-mediated glomerulonephritis E. Microbiologic Evidence (Falling Short of Major Criterion) Positive blood cultures for a microorganism consistent with IE but not meeting the requirements for Major Criterion OR Positive culture, PCR, or other nucleic acid-based test (amplicon or shotgun sequencing, in situ hybridization) for organisms consistent with IE from a sterile body site other than cardiac tissue, cardiac prosthesis, or arterial embolus F. Imaging Criteria Abnormal 18F-FDG PET/CT within 3 months of implantation of prosthetic valve G. Physical Examination Criteria New valvular regurgitation identified on auscultation if echocardiography is not available.

References:

https://www.researchgate.net/publication/370520403_The_2023_Duke-ISCVID_Criteria_for_Infective_Endocarditis_Updating_the_Modified_Duke_Criteria

↑ *Back to this question in Part A*

@Neet_pg_bot

Q70: Which of the following indicators shall be seen with use of a small-sized BP cuff? (Q857069)

A. False elevation of BP

B. Falsely low value of BP

C. Cancels the effects of calcified arteries

D. Increases trans arm impedance

Correct Answer: A. False elevation of BP

Explanation: False elevation of BP is observed when using a small-sized blood pressure cuff. Errors in Blood Pressure Measurement Due to Improper Cuff Size: Cuff Too Narrow: Overestimates blood pressure. Applies excessive pressure to a smaller area, leading to falsely high readings. Cuff Too Wide: Underestimates blood pressure. (Option B) Distributes pressure over a larger area, resulting in falsely low readings. Importance of Proper Cuff Size: Ensures accurate blood pressure measurement. Avoids misdiagnosis of hypertension or hypotension. Cancels the effects of calcified arteries (Option C): A small-sized BP cuff does not negate the effects of calcified arteries. While arterial calcification can lead to inaccurate BP measurements, using the correct cuff size is essential for obtaining accurate readings. Increases trans-arm impedance (Option C): A small-sized BP cuff does not directly increase trans-arm impedance. Trans-arm impedance refers to resistance encountered in certain BP measurement techniques, but it is not specifically affected by cuff size.

References:

https://www.sciencedirect.com/science/article/abs/pii/0002870378901199

https://pmc.ncbi.nlm.nih.gov/articles/PMC10407761/

↑ *Back to this question in Part A*

@Neet_pg_bot

Q71: Elderly male patient has presented with recurrent falls. Which of the following medicines is responsible? (Q857070)

A. Prazocin

B. Metformin

C. Acarbose

D. Thiazide

Correct Answer: A. Prazocin

Explanation: Prazosin is an alpha-1 adrenergic antagonist that can cause orthostatic hypotension and syncope, leading to an increased risk of falls, particularly in elderly patients. Prazosin: Quinazoline derivative that acts as competitive alpha-1 adrenergic receptor antagonist Mechanism of Action: Alpha-1 adrenergic receptor antagonist

Smooth muscle relaxation → ↓ systemic vascular resistance → ↓ blood pressure Affects various tissues (blood vessels, prostate, urethra, iris dilator muscle, brain) Crosses the blood-brain barrier → contributes to cognitive effects (basis for PTSD use) Metabolism: Hepatic (via CYP450 enzymes) Half-life: ~2.5 hours (prolonged in chronic renal failure and congestive heart failure) Uses: FDA-approved Indication: Hypertension (alone or in combination with other antihypertensives) but not a first-line agent. Non-FDA-approved Indication: Benign prostatic hyperplasia (BPH) Post-traumatic stress disorder (PTSD)-associated nightmares Raynaud phenomenon Pheochromocytoma Scorpion envenomation Adverse Effects: Serious Adverse Effects: First-dose hypotension (recommend initial dose at bedtime) Orthostatic hypotension Syncope Intraoperative Floppy Iris Syndrome (IFIS) Priapism Common Adverse Effects: Dizziness Headache Drowsiness Lack of energy Weakness Palpitations Nausea Metformin (Option B) is used for managing type 2 diabetes. While it may cause gastrointestinal side effects like nausea and diarrhea, it does not directly contribute to falls. Acarbose (Option C) is an alpha-glucosidase inhibitor used to manage diabetes by delaying carbohydrate absorption. It can cause gastrointestinal issues but does not lead to falls. Thiazide (Option D) diuretics can sometimes cause orthostatic hypotension, especially in elderly patients, but this side effect is less common and less pronounced compared to prazosin, which is more strongly associated with orthostatic hypotension and falls.

References:

https://www.ncbi.nlm.nih.gov/books/NBK555959/

https://pmc.ncbi.nlm.nih.gov/articles/PMC7138342/

↑ *Back to this question in Part A*

@Neet_pg_bot

Q72: What is the waist to hip ratio that is associated with an increased risk of heart disease? (Q857072)

A. > 0.80 in males

B. > 0.80 in females

C. > 0.85 in males

D. > 0.85 in females

Correct Answer: D. > 0.85 in females

Explanation: The waist to hip ratio that is associated with an increased risk of heart disease is > 0.85 in females. Waist-to-Hip Ratio: Waist-to-hip ratio is a more accurate measure of obesity-related cardiovascular risk than BMI, with specific cut-offs of 0.83 for women and 0.9 for men significantly increasing the risk for myocardial infarction. Physicians should prioritize measuring waist-to-hip ratio, along with waist circumference, to assess cardiovascular risk, particularly in specific ethnic groups. Reducing abdominal obesity and increasing hip circumference, potentially through muscle mass development, may reduce cardiovascular risk.

References:

https://pmc.ncbi.nlm.nih.gov/articles/PMC1373709/#

↑ *Back to this question in Part A*

@Neet_pg_bot

Q73: Best management of a hemodynamically stable patient with ECG showing Broad QRS complex with antidromic tachycardia is? (Q857074)

A. Oral verapamil

B. Oral Beta-blocker

C. Cardioversion

D. Intravenous Procainamide

Correct Answer: D. Intravenous Procainamide

Explanation: Intravenous procainamide is the best management for a hemodynamically stable patient with broad QRS complex antidromic tachycardia, as it terminates the arrhythmia by slowing conduction through the accessory pathway. Atrioventricular Reentrant Tachycardia (AVRT): AVRT is a type of supraventricular tachycardia that occurs in patients with an accessory pathway, such as in Wolff-Parkinson-White (WPW) syndrome. Pathology: AVRT involves a reentrant circuit that includes the normal AV conduction system and the accessory pathway. Two types exist: Orthodromic AVRT (more common): Conduction travels down the AV node and up the accessory pathway. Antidromic AVRT (less common): Conduction travels down the accessory pathway and up the AV node. ECG Features: Orthodromic AVRT: Narrow QRS complex tachycardia (QRS < 120 ms) Regular rhythm with heart rates typically 150-250 bpm Retrograde P waves often visible in the ST segment or early T wave Antidromic AVRT: Wide QRS complex tachycardia (QRS > 120 ms) Regular rhythm with heart rates typically 170-240 bpm Retrograde P waves may be obscured by the wide QRS AVRT can be initiated by premature atrial or ventricular complexes that block one pathway and conduct through the other, setting up the reentrant circuit. Management: Acute Termination of Orthodromic AVRT: Stable patients: Start with vagal maneuvers (Valsalva or carotid sinus massage). If unsuccessful: IV adenosine (first-line pharmacologic treatment), IV verapamil, IV procainamide or IV beta-blockers. Acute Termination of Antidromic AVRT: If confirmed, avoid AV nodal blockers (adenosine, beta-blockers , verapamil , digoxin). (Option A & B) IV procainamide is the preferred treatment. Cardioversion (Option D): Reserved for hemodynamically unstable patients; unnecessary in a stable patient where pharmacologic management with IV procainamide is effective.

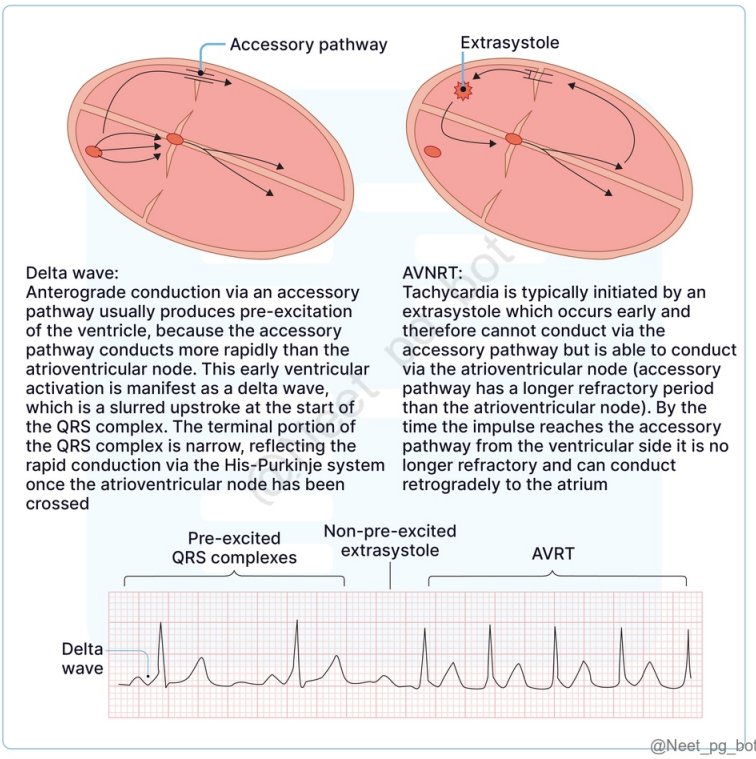

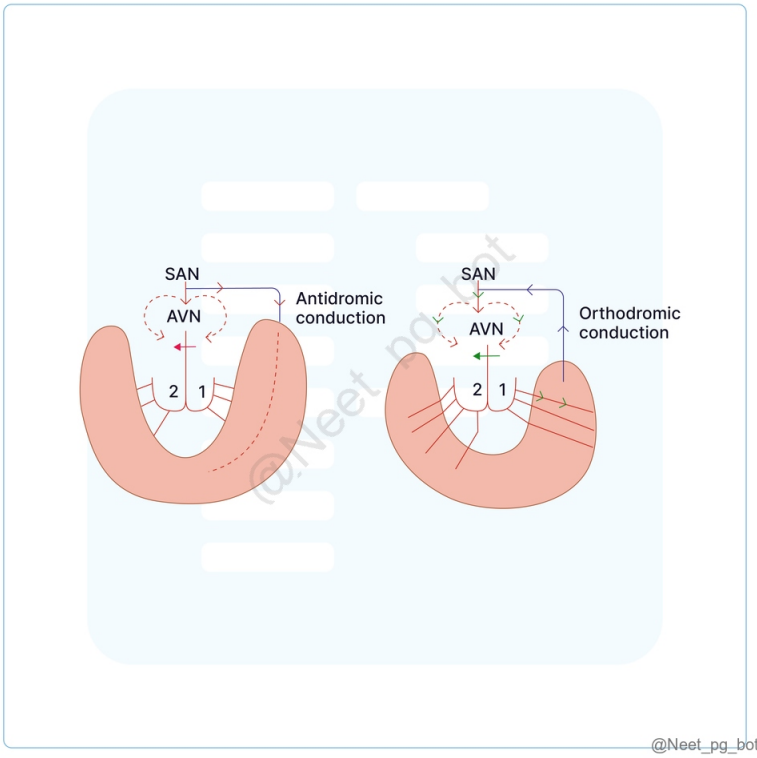

References:

Goldberger’s Clinical Electrocardiography, A Simplified Approach, 9th Edition, Page 139, 140

https://www.ncbi.nlm.nih.gov/books/NBK557788/#

↑ *Back to this question in Part A*

@Neet_pg_bot

Q74: What is the diagnosis for a 23-year-old female who has been experiencing fever for the past week and displays the following rhythm on the monitor? {{caption_text}} (Q857095)

A. Atrial fibrillation

B. Atrial flutter

C. Supra ventricular tachyarrhythmia

D. Ventricular tachyarrhythmia



Correct Answer: A. Atrial fibrillation

Explanation: The given image shows Atrial fibrillation Atrial fibrillation is a cardiac rhythm disorder characterized by rapid, irregular electrical impulses in the atria. This results in a rapid and irregular ventricular response, leading to an irregular heart rate on the monitor. {{caption_text}} Atrial flutter (Option B): typically appears as a regular, sawtooth pattern on the monitor, rather than the irregular pattern seen in this case. {{caption_text}} Supraventricular tachyarrhythmia (Option C): is a broad term that encompasses various rapid heart rhythms originating from above the ventricles. It includes conditions like atrial fibrillation, atrial flutter, and other supraventricular tachycardias. While atrial fibrillation is a type of supraventricular tachyarrhythmia, it is more specific than the general term used in this option. {{caption_text}} Ventricular tachyarrhythmia (Option D): refers to abnormal rapid rhythms that originate in the ventricles. This rhythm disorder is characterized by a wide QRS complex on the monitor, unlike the narrow QRS complex typically seen in atrial fibrillation.

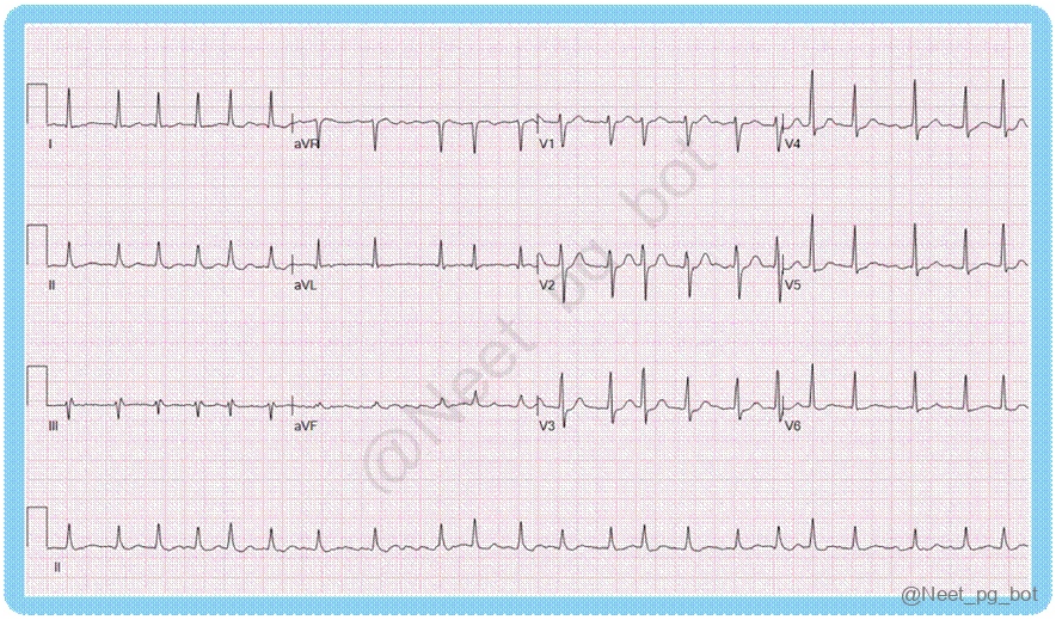
I
aVR
V1
V4
II
aVL
V2
V5
III
aVF
V3
V6
II
@Neet_pg_bot

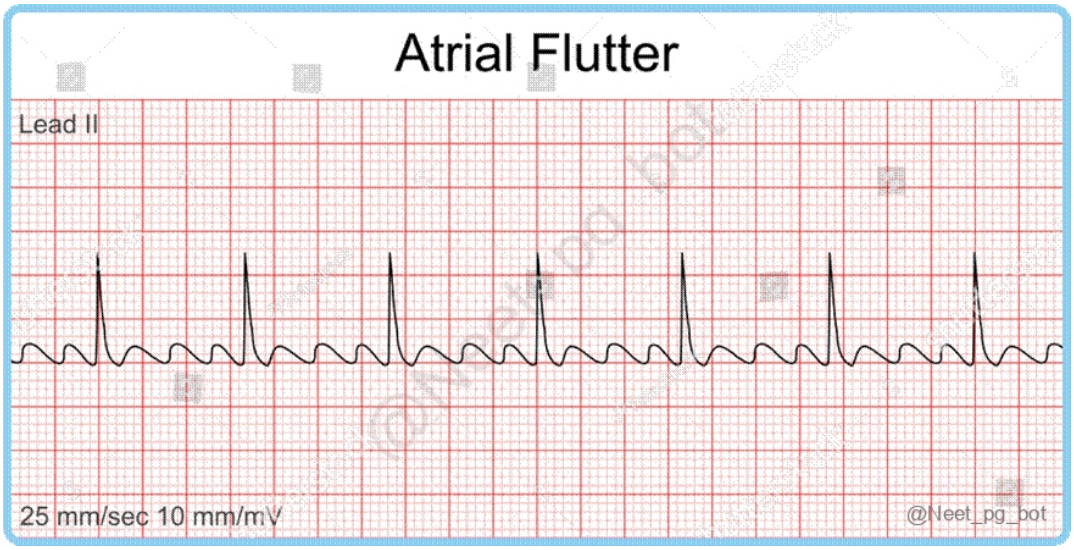
Atrial Flutter
Lead II
25 mm/sec 10 mm/mV
@Neet_pg_bot

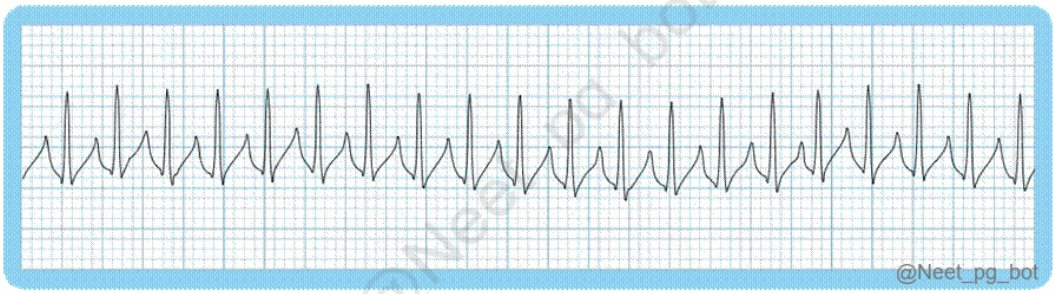
@Neet_pg_bot

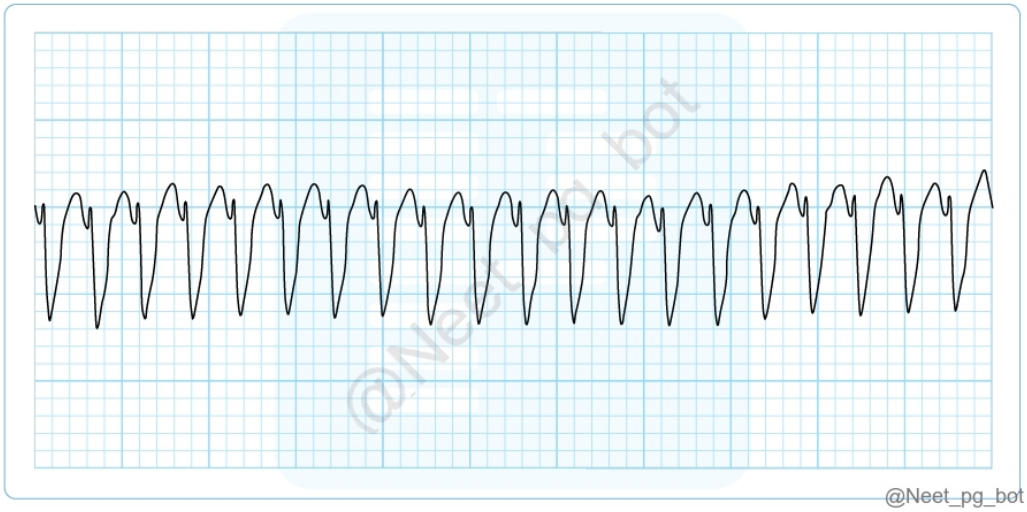

References:

https://cpr.heart.org/-/media/CPR-Files/CPR-Guidelines-Files/Algorithms/AlgorithmACLS_Tachycardia_200612.pdf?sc_lang=en

Harrison's Principle of Internal Medicine, Edition 21st- Pg No. 1888, 1889, 1904-07

↑ *Back to this question in Part A*

@Neet_pg_bot

Q75: An intern observed that a patient in the ward was unresponsive, and an ECG which was performed urgently showed a rhythm as depicted below. DC shock was delivered but the arrhythmia persisted and the patient is still unresponsive. What is the next best step in the management of this patient? (Q857615)

A. Synchronized cardioversion

B. Start CPR

C. Deliver another DC shock

D. 1 mg epinephrine



Correct Answer: B. Start CPR

Explanation: The ECG shows ventricular fibrillation (VF) —a shockable cardiac arrest rhythm. The patient is unresponsive and persistent VF continues even after a defibrillation attempt. According to ACLS guidelines , after a shock: Immediate next step is to start CPR for 2 minutes. Defibrillation must always be followed by CPR , because coronary and cerebral perfusion must be restored while the myocardium recovers. Synchronized cardioversion (Option A): Not used for VF. Cardioversion requires an organized QRS, which VF does not have. Deliver another DC shock (Option C): Shocks must be alternated with 2-minute CPR cycles, not delivered back-to-back. 1 mg epinephrine (Option D): Epinephrine is given after 2 minutes of CPR following the second shock , not immediately after the first shock. ■■■■■■■Management of Shockable (VT/ V Fib) Conditions: Immediate Recognition Identify Shockable Rhythm: Recognize VF or pulseless VT. Activate Emergency Response: Call for advanced life support. ↓ Initiate CPR Start High-Quality CPR: Perform chest compressions at a rate of 100-120/min, with a depth of 5-6 cm. Continue CPR for 2 minutes. ↓ Defibrillation After 2 minutes of CPR, deliver a Non-Synchronized DC Shock to restore normal rhythm. If no change, administer a second shock immediately. ↓ Continue CPR Resume CPR for 2 Minutes Place an intravenous or intraosseous line for drug administration. ↓ Administer Epinephrine Epinephrine 1 mg (1:10,000): Given IV/IO after 2 minutes of CPR to enhance coronary perfusion pressure. ↓ Advanced Airway Management Secure Airway: Perform endotracheal intubation if necessary. Capnography: Monitor end-tidal CO2 levels. Ventilation: Provide 1 breath every 6 seconds post-intubation. ↓ Further Defibrillation Third Shock: If VF or pulseless VT persists, deliver a third non-synchronized shock. Continue CPR for 2 More Minutes: Follow with additional CPR. ↓ Administer Antiarrhythmic Medication Amiodarone 300 mg IV: Administer for shock-refractory VT to stabilize heart rhythm. ↓ Identify and Treat Reversible Causes

References:

Harrison's principles of internal medicine, 21st edition, Page 2063, 2262, 2263

Davidson's principles and practice of medicine, 24th edition, Page 481, 482

↑ *Back to this question in Part A*

@Neet_pg_bot

Q76: Pulsus paradoxus is seen in: (Q857626)

A. Coronary artery disease

B. Severe Asthma or Chronic Obstructive Pulmonary Disease

C. Atrial Fibrillation

D. Right ventricular myocardial infarction

Correct Answer: B. Severe Asthma or Chronic Obstructive Pulmonary Disease

Explanation: Pulsus paradoxus is an ominous sign in a patient with obstructive lung disease, as it is associated with significant negative intrathoracic (pleural) pressures, affecting venous return to the heart and causing a drop in systolic blood pressure during inspiration. During severe asthma attacks or exacerbations of COPD, airway resistance increases significantly during inspiration and significant rise in negative intrathoracic pressure. Pulsus Paradoxus Definition: A fall in systolic blood pressure >10 mmHg during inspiration. Pathophysiology: Exaggerated interventricular dependence → Increased right ventricular filling during inspiration shifts the septum leftward, reducing left ventricular output and causing a more pronounced drop in systolic pressure. Associated Conditions: Pericardial tamponade (classic association) External pressure on the heart limits filling Inspiration compresses the RV, preventing normal inspiratory RV filling Interventricular septum shifts left, restricting LV filling and output → Marked fall in BP Massive pulmonary embolism Hemorrhagic shock Severe obstructive lung disease (e.g., asthma, COPD) Tension pneumothorax Effusive Constrictive Pericarditis Restrictive Cardiomyopathy Measurement: Auscultatory method: Identify the systolic pressure during expiration and independent of respiration. The difference between these two is the pulsus paradoxus . If the difference exceeds 15 mmHg, pulsus paradoxus may be palpable at the brachial or femoral artery. Tachycardia, atrial fibrillation, tachypnea will make it difficult to measure. Respiratory Changes in Cardiac Output, Blood Pressure, and Pulse Rate: Physiological Changes with Respiration: Inspiration: ↓ Intrathoracic pressure → ↑ Venous return to the right heart ↑ Right ventricular (RV) output ↑ Pulmonary vascular capacitance → Blood is sequestered in the lungs, reducing flow to the left heart ↓ Left ventricular (LV) output → ↓ Blood pressure (BP) Expiration: ↓ Venous return to the right heart → ↓ RV output ↑ Venous return to the left heart → ↑ LV output → ↑ BP

References:

Harrison's principles of internal medicine, 21st edition, Page 2132, 1818, 2022

Davidson's principles and practice of medicine, 24th edition, Page 180, 462, 447, 448

↑ *Back to this question in Part A*

@Neet_pg_bot

Q77: A 64-year-old man presents with complaints of palpitations and syncope. He has a history of inferior-wall myocardial infarction a year ago. Holter study was done and his 24 hour ECG strip obtained is given below. What is the long-term treatment for this condition? (Q857641)

A. Amiodarone

B. Atropine only

C. Permanent pacemaker

D. Atropine and isoproterenol

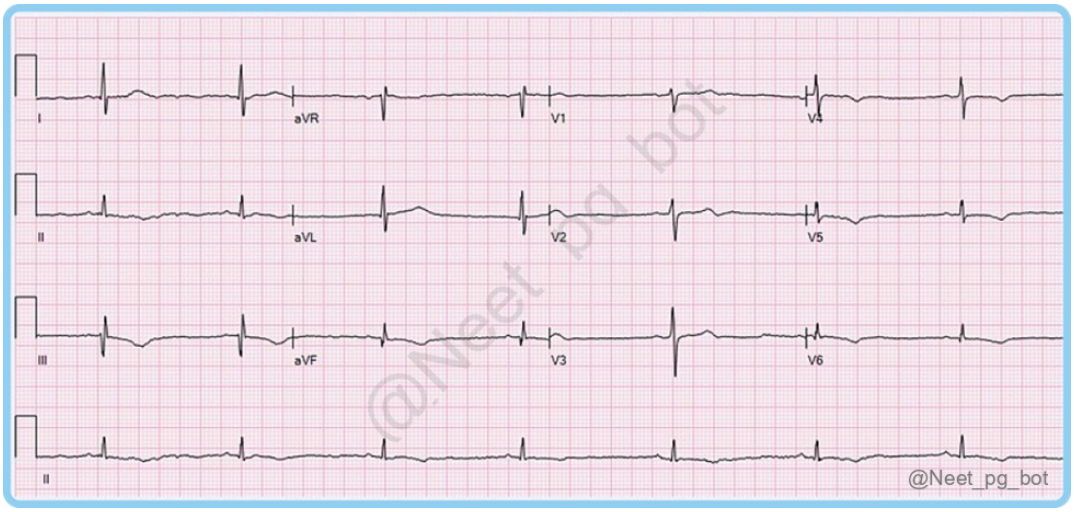

Correct Answer: C. Permanent pacemaker

Explanation: The 24-hour ECG strip suggests the presence of sinus node dysfunction (sick sinus syndrome) characterized by bradycardia (slow heart rate), pauses, and sinus arrests. This condition is commonly seen in individuals who have had a previous myocardial infarction. Long-term treatment for this would be a "Permanent pacemaker." Sinus bradycardia Definition Sinus bradycardia is a cardiac rhythm with normal sinus node depolarization but a rate < 60 bpm. Diagnostic Criteria ECG showing sinus rhythm at a rate lower than 60 bpm. Common Etiologies Normal in athletes Medications (beta-blockers, calcium channel blockers, digoxin) Hypothyroidism, hypothermia Sick sinus syndrome, myocardial infarction Vagal stimulation (e.g., vasovagal syncope) Clinical Features Asymptomatic (in many patients) Fatigue Dizziness or lightheadedness Exercise intolerance Syncope or presyncope Cognitive slowing Worsening angina or heart failure symptoms Evaluation Assess hemodynamic stability ECG to confirm sinus rhythm Review medication list for bradycardic agents Evaluate for comorbidities (e.g., hypothyroidism, myocardial infarction) Management If Hemodynamically Unstable: IV atropine 0.5 mg every 3-5 minutes (max 3 mg) If there is no improvement, consider a temporary pacemaker If Stable, for long term mamagement: Treat underlying causes Withdraw bradycardia-inducing medications Permanent pacemaker Amiodarone (Option A) is an antiarrhythmic medication used to treat various

cardiac arrhythmias. However, it is not the primary treatment for sinus node dysfunction. Atropine only (Option B) is a medication used for acute management of symptomatic bradycardia. It is used only in emergency situations or as a temporary measure before definitive treatment such as a pacemake r is implemented. Isoproterenol is a medication that acts as a cardiac stimulant and can increase heart rate. While it may be used in certain acute situations , it is not an appropriate long-term treatment for sinus node dysfunction. Additionally, combining atropine and isoproterenol (Option D) is not a typical approach for managing this condition.

References:

Davidson’s Principles and Practice of Medicine, 24th edition, Page 482, 483

https://www.ncbi.nlm.nih.gov/books/NBK493201/

↑ *Back to this question in Part A*

@Neet_pg_bot

Q78: A 5 year old child has flexible fingers and can even touch the back of his hand with his wrist extended. The child also demonstrates the sign shown in the image below. On auscultation, a click is heard after S1, followed by a late systolic murmur. What is the probable diagnosis? (Q857653)

A. Ehlers-Danlos syndrome

B. Marfan’s syndrome

C. Loeys-Dietz syndrome

D. Osteogenesis imperfecta

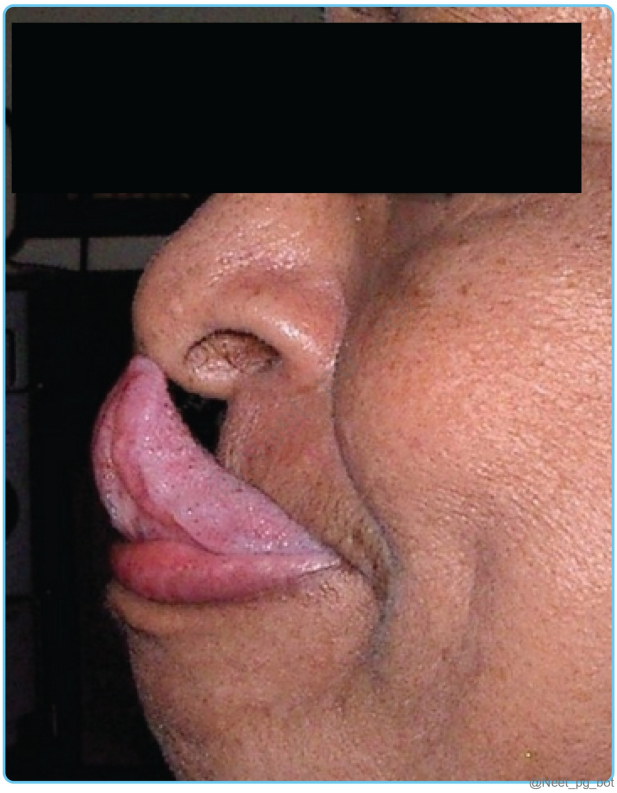

Correct Answer: A. Ehlers-Danlos syndrome

Explanation: Hypermobility of joint, the ability to touch the back of the hand with the wrist extended, tongue to nose sign (Gorlin's sign) and auscultatory findings of mitral valve prolapse suggests that this could be Ehlers-Danlos syndrome (EDS) which is a genetic disorders that affects the connective tissues and shows various systemic manifestations, primarily involving the skin, joints, and blood vessels. Ehlers-Danlos Syndrome (EDS): Genetically heterogeneous connective tissue disorders Common features: Skin: Soft, hyperextensible , fragile, slow healing, atrophic scars Joints: Hypermobility, subluxations, chronic pain Vascular fragility: Risk of arterial & organ rupture in some types Gorlin's sign is seen Classification: 13 clinical types (linked to 20 genes) Common mutations: COL1A1, COL1A2, COL3A1, COL5A1, COL5A2 Major EDS Types & Features: Type Gene Key Features Classical (cEDS) COL5A1, COL5A2 Hyperextensible skin, atrophic scars, joint hypermobility Vascular (vEDS) COL3A1 Thin skin, visible veins, arterial/organ rupture, Hypermobile (hEDS) Unknown Joint hypermobility , chronic pain, POTS, mitral valve prolapse Kyphoscoliotic PLOD1, FKBP14 Severe scoliosis, hypotonia, vascular rupture Arthrochalasia COL1A1, COL1A2 Congenital hip dislocation, severe joint hypermobility Dermatosparaxis ADAMTS2 Severe skin fragility, sagging skin, large hernias Periodontal C1R, C1S Severe gum disease, tooth loss, vascular fragility Diagnosis: Clinical criteria + genetic testing (except hEDS) hEDS diagnosed using: Modified Beighton Score ≥4 Arthralgia in ≥4 joints Differential diagnoses: Marfan syndrome Osteogenesis Imperfecta Loeys-Dietz syndrome Management: EDS is a diverse group of connective tissue disorders with no cure, requiring symptom-based management and specialized care. Multidisciplinary care Musculoskeletal: Physiotherapy, braces, joint protection Vascular monitoring (for vEDS) Low-impact exercise (swimming, walking) Avoid high-impact sports (gymnastics, weightlifting) Emergency preparedness (MedicAlert, ER protocol for vEDS) Psychological support for chronic pain & genetic diagnosis

References:

Harrison's Principles of Internal Medicine, 21st edition, Page 2000, 3224 - 3228

https://en.wikipedia.org/wiki/Gorlin_sign

↑ *Back to this question in Part A*

@Neet_pg_bot

Q79: Which of the following is the most appropriate position for placement of single lead pacemaker ? (Q857654)

A. Right ventricle

B. Left atrium

C. Left ventricle

D. Superior vena cava

Correct Answer: A. Right ventricle

Explanation: The pacemaker lead is typically placed in the right ventricle for most pacemaker implantations. This positioning allows the electrical impulses generated by the pacemaker to be delivered to the right ventricle, which then stimulates the heart muscle to contract and maintain an appropriate heart rhythm. Pacemakers of the Heart: Natural Pacemaker sites and their depolarization rates: Sinoatrial node: 60 to 100 beats per minute Atria: less than 60 beats per minute Atrioventricular node: 40 to 60 beats per minute Ventricles: 20 to 40 beats per minute Artificial Pacemaker: An artificial pacemaker is a small battery-operated device that helps regulate the heart's rhythm by producing electrical impulses. It typically consists of three parts: a generator, leads (wires), and sensors (electrodes). Traditional pacemakers are implanted under the skin, usually on the chest just below the collarbone or in the stomach area, and they connect to the heart through tiny wires. There are several types of traditional pacemakers: Single-lead pacemakers: One lead is placed in the right ventricle. Dual-lead pacemakers: One lead is placed in the right atrium and one in the right ventricle. Biventricular pacemakers (CRT): Three leads are used, placed in the right atrium, right ventricle, and left ventricle. Wireless pacemakers are smaller and consist of a pulse generator and electrodes in one device. They are implanted inside the heart through a catheter inserted via internal jugular or femoral or subclavian vein, sending impulses to the right ventricle without the need for traditional surgery. {{caption_text}}

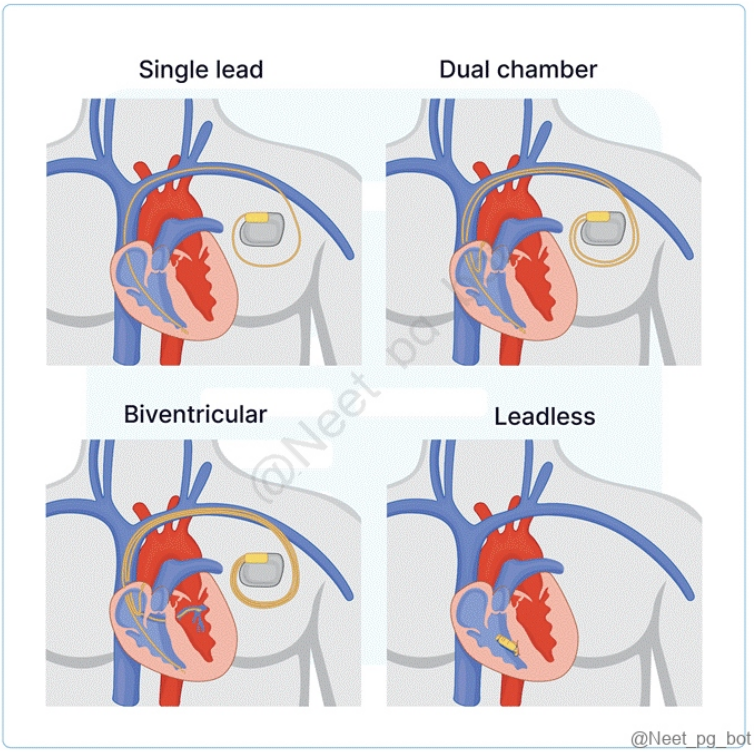

References:

Davidson’s Principles and Practice of Medicine, 24th edition, Page 482, 483

Pacemaker | American Heart Association

Junctional Rhythm - StatPearls - NCBI Bookshelf

↑ *Back to this question in Part A*

@Neet_pg_bot

Q80: What is the most probable diagnosis for a female patient, aged 65, who visits the outpatient department with symptoms of breathlessness and fatigue? During examination, the patient's neck veins were engorged, and her jugular venous pulse displayed a swift X and Y descent. (Q857667)

A. Constrictive pericarditis

B. Cardiac tamponade

C. Dilated cardiomyopathy

D. Restricted cardiomyopathy

Correct Answer: A. Constrictive pericarditis

Explanation: The most likely diagnosis is constrictive pericarditis. Constrictive pericarditis is a condition characterized by inflammation and fibrosis of the pericardium, the sac-like structure surrounding the heart. It leads to the stiffening of the pericardium, impairing the normal filling and functioning of the heart. Constrictive Pericarditis: Progressive inflammation, thickening, fibrosis, and calcification of the pericardium restrict heart filling. Calcification can extend into the myocardium, impairing myocardial contraction. Restricted ventricular filling leads to elevated atrial pressures, causing: Atrial hypertrophy Atrial dilation Atrial fibrillation (common). Primarily manifests as systemic venous congestion (lung congestion is rare). Examination Findings: Finding Description Elevated JVP with rapid y descent Reflects rapid early diastolic filling of the right ventricle due to pressure gradient. Fatigue Caused by the heart's inability to meet circulatory demands. Rapid, low-volume pulse Restricted filling limits stroke volume, weakening the pulse. Pericardial knock A loud early S3 from the thickened pericardium during diastolic filling. Kussmaul's sign Paradoxical rise in JVP during inspiration. Hepatomegaly Liver enlargement due to i ncreased venous pressure. Ascites Abdominal fluid accumulation due to systemic venous congestion. Peripheral oedema Swelling in the extremities from fluid retention. Pulsus paradoxus A fall in systolic BP (10mm Hg) during inspiration, potentially impalpable pulse. Atrial fibrillation Common due to atrial hypertrophy and dilation. Cardiac tamponade (Option B): Typically presents with elevated JVP, but it shows a prominent X descent and an absent Y descent (due to impaired filling), not rapid X and Y descents. Dilated cardiomyopathy (Option C): This condition generally presents with signs of heart failure and an elevated JVP, but the JVP waveform does not typically show rapid X and Y descents. Restrictive cardiomyopathy (Option D): This condition can present with symptoms similar to constrictive pericarditis, but it usually has a slow Y descent in the JVP rather than a rapid one.

References:

Davidson's Principles and Practice of Medicine, 24th edition, Page 543

↑ *Back to this question in Part A*

@Neet_pg_bot

Q81: A 35 year old female patient with fever and malar rashes was found to have vegetations on either side of the heart valves. What can be the diagnosis of the patient? (Q857674)

A. Infective endocarditis

B. Libman sacks endocarditis

C. Rheumatic Heart Disease

D. None of the above

Correct Answer: B. Libman sacks endocarditis

Explanation: A 35 year old female presents with fever and malar rashes suggests that this could be systemic lupus erythematosus (SLE) and the cardiac involvement of SLE shows Libman-Sacks endocarditis (LSE) . Libman-Sacks endocarditis is a form of nonbacterial endocarditis (also known as nonbacterial thrombotic endocarditis) that is commonly associated with systemic lupus erythematosus (SLE). It is characterized by the presence of small, sterile vegetations on both sides of the heart valves, particularly the mitral and aortic valves. Systemic Involvement in SLE System Manifestations Pulmonary system Pleuritis (most common): Prevalence (30 - 50%) Pneumonitis Atelectasis Reduced lung volume and Pulmonary ■brosis Shrinking lung syndrome, (< 5%) Intra-alveolar hemorrhage Pulmonary HTN (< 5 %) (Option C) Acute Respiratory Distress Syndrome (ARDS) (< 5%) Musculoskeletal system It is the most commonly involved system Polyarthritis (symmetrical) Polyarthralgia Rheumatoid arthritis Myositis Jaccoud arthropathy is a reversible deformity caused by ligament laxity, capsule fibrosis, and muscular imbalance. Axial skeletal involvement is uncommon. {{caption_text}} Renal system Lupus nephritis (most common) Proteinuria Nephrotic syndrome Rarely End-stage Renal Disease (ESRD) Nervous system Headache, Seizures, Stroke, Polyneuropathy, TIA, Acute confusional state, Movement disorder, Aseptic meningitis, Myelopathy, Psychosis and Mood disorders. Cardiovascular system Coronary artery disease - common cause of death Pericarditis Coronary vasculitis Myocarditis Libman sacks endocarditis Accelerated atherosclerosis Hematological manifestations Anemia of chronic disease Leucopenia Lymphopenia Thrombocytopenia Autoimmune Hemolytic anemia-MCC of anemia in SLE Splenomegaly GI involvement Abdominal pain Nausea, diarrhoea Abnormal liver enzymes Ocular manifestation Sicca syndrome: Dry eyes (keratoconjunctivitis sicca) and dry mouth (xerostomia). Conjunctivitis Episcleritis Vasculitis While infective endocarditis (Option A) can also cause vegetations on the heart valves, the presence of malar rashes suggests an autoimmune condition like SLE rather than an infectious etiology.



References:

Harrison’s Principles of Internal Medicine, 21st Edition, Page 2740, 2741, 2742, 2743.

↑ *Back to this question in Part A*

@Neet_pg_bot

Q82: PR segment in ECG indicates: (Q857686)

A. Atrial depolarization

B. Atrioventricular nodal conduction

C. Ventricular depolarization

D. Ventricular repolarization

Correct Answer: B. Atrioventricular nodal conduction

Explanation: The PR segment represents the period of atrioventricular nodal conduction in the cardiac cycle. Component Cause Normal Duration and Size P wave Atrial depolarization is initiated by the SA node. (Option A Ruled Out) 0.08–0.11 seconds 2–2.75 small boxes <2.5 mm (0.25 mV) in amplitude/ height <0.12 sec (120 msec or 3 small boxes) in width PR interval Time from onset of atrial depolarization (P wave) to onset of ventricular depolarization (electrical impulse passing through AV node) (Option B) 0.12–0.20 seconds 3–5 small boxes Q wave Initial depolarization of the interventricular septum, directed from left to right. <0.04 seconds <1 small box Depth: <1/4 of R wave or ~1–2 mm (<0.5 small boxes) QRS complex Ventricular depolarization - the time taken for the electrical impulse to spread through the ventricles. (Option C Ruled Out) <0.10 seconds <2.5 small boxes in width Height: 5–30 mm (1–6 big boxes) QT interval Time from the start of ventricular depolarization to the end of ventricular repolarization. Duration depends on HR. HR inversely proportional QT length. Rate-corrected (QTc) 330–350 msec ~11 small boxes ST segment Represents the early part of ventricular repolarization. It is isoelectric (flat). (Option D Ruled Out) 0.08–0.12 seconds 2–3 small boxes Normally isoelectric (flat), deviations >1 small box indicate pathology T wave Represents the later stage of ventricular repolarization. <0.04 seconds 2.5–6.25 small boxes Height: Varies. Normally <5 mm (1 big box) in limb leads, <10 mm (2 big boxes) in precordial leads U wave Unknown origin; possibly related to repolarization of Purkinje fibers or ventricular walls. Not always measurable {{caption_text}}

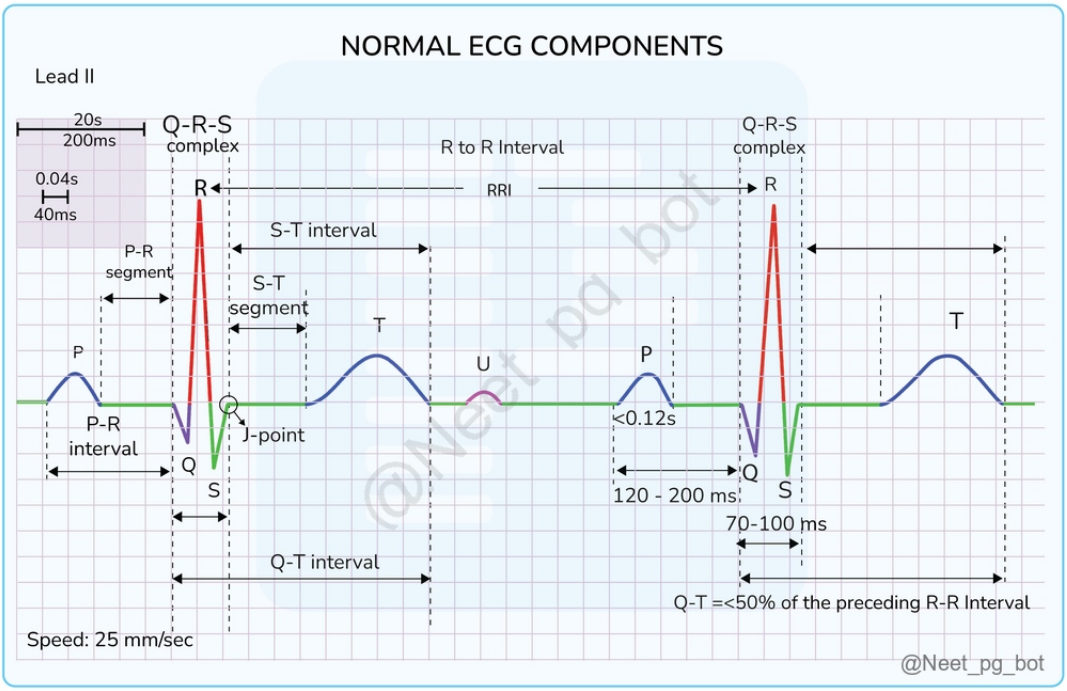

References:

Goldberger's Clinical Electrocardiography, A Simplified Approach, 9th Edition, Page. 11-20.

↑ *Back to this question in Part A*

@Neet_pg_bot

Q83: Most sensitive and specific marker for MI is? (Q857691)

A. Troponin

B. Cytokeratin

C. Myoglobin

D. CPK-MM

Correct Answer: A. Troponin

Explanation: Troponin as the most sensitive and specific biomarker for myocardial infarction (MI). Troponin is a regulatory protein complex found specifically in cardiac muscle tissue. It begins to rise within 3-6 hours of injury, peaks at 24-48 hours, and can remain elevated for 7-10 days, providing a wide diagnostic window. Cardiac troponins (cTnI and cTnT) have nearly absolute myocardial tissue specificity and high clinical sensitivity. Cardiac Biomarkers for Acute Myocardial Infarction (AMI): {{caption_text}} 1. Cardiac Troponin: Preferred biochemical markers due to their sensitivity and specificity. Criteria for ACS: Requires rise and/or fall in biomarker values, with at least one value above the 99th percentile upper reference limit. Troponin T (cTnT) and Troponin I (cTnI)

increase significantly after STEMI. Can detect concentrations <1 ng/L in non-ischemic conditions. Troponin levels: Increase within 3-6 hours. Peak at around 36 hours. Remains elevated for 7-10 days after STEMI. Troponin should be measured at presentation and repeated at 1-3 hours (high-sensitivity assays) or 3-6 hours (conventional assays). Further troponin tests are advised beyond 3-6 hours if AMI remains a possibility or there is diagnostic uncertainty. Causes of elevated Serum Troponin other than MI Cardiorespiratory Causes Non-Cardiorespiratory Causes Pulmonary embolism Aortic dissection Acute pulmonary edema Tachyarrhythmias Myocarditis/Myopericarditis Cardiac trauma Cardiac surgery/ablation Prolonged hypotension Severe sepsis Severe burns Stroke Subarachnoid hemorrhage End-stage renal failure Cardiac troponin levels remain elevated for several days after an acute myocardial infarction (AMI), making them unreliable for detecting reinfarction. 2. Creatine Phosphokinase (CK) and CK-MB: CK rises within 4-8 hours. Peaks by 24 hours. Returns to normal within 48-72 hours. CK lacks specificity for STEMI since it can be elevated in skeletal muscle disease, trauma, or injections. CK-MB isoenzyme is more specific for the heart CK-MB elevated: Cardiac surgery Myocarditis Electrical cardioversion CK-MB/CK ratio >2.5 suggests a myocardial source, though it's not diagnostic. CK-MB levels normalize within 48 to 72 hours , so a subsequent rise can confirm reinfarction. 3. Lactate Dehydrogenase (LDH): Increase in the blood 6 to 12 hours after ACS. Peak within 24 to 72 hours. Normalize within 8 to 14 days. LDH is no longer used to diagnose myocardial infarction because it is not specific to cardiac myocytes. 4. Heart-type Fatty Acid-Binding Protein (H-FABP): Sensitivity of H-FABP in detecting AMI within 4 hours of symptom onset was 60%, significantly higher than troponin (18.8%) and CK-MB (12.5%). But the specificity of H-FABP in detecting AMI was less than that of troponin and CK-MB. Cytokeratin (Option B): Cytokeratin is a protein found in epithelial cells and has no role in cardiac injury detection. It is primarily used as a tumor marker for certain types of cancers and has no relevance in diagnosing myocardial infarction. Myoglobin (Option C): While myoglobin is released during muscle injury and rises earlier than troponin (2-3 hours after injury), it lacks cardiac specificity as it is found in both cardiac and skeletal muscle. CPK-MM (Option D): Creatine Phosphokinase-MM is the skeletal muscle isoform of CPK. It is predominantly found in skeletal muscle. Its elevation can occur in condition causing skeletal muscle damage, making it a poor choice for specific MI diagnosis.

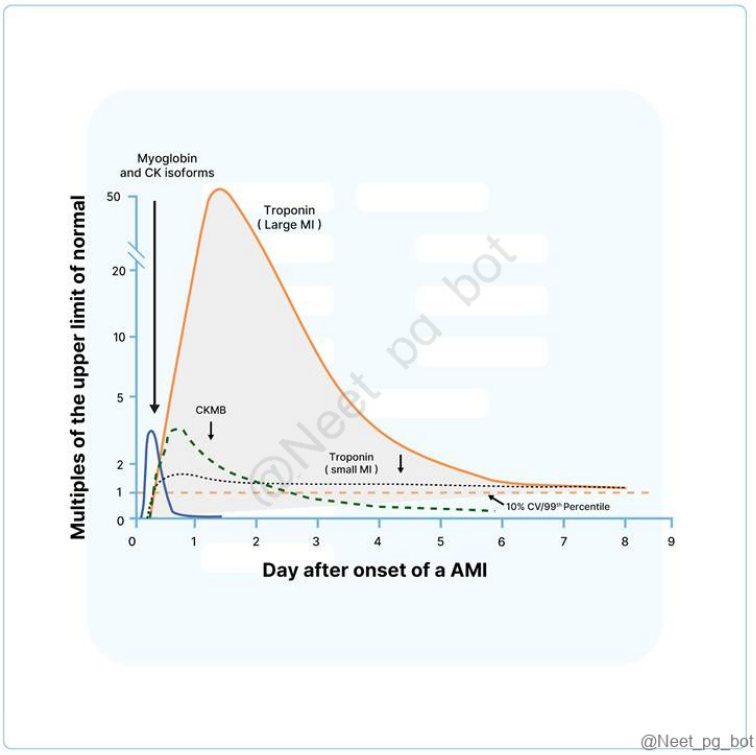

References:

Harrison’s Principles of Internal Medicine, 21st Edition, Page 106,2055,2056

Davidson’s Principles and Practice of Medicine, 24th Edition, Page 179,497

Cardiac Biomarkers - StatPearls - NCBI Bookshelf

↑ *Back to this question in Part A*

@Neet_pg_bot

Q84: Which of the following is given lifelong for patient receiving prosthetic mitral valve replacement? (Q857693)

A. Aspirin

B. Clopidogrel

C. Atorvastatin

D. Warfarin

Correct Answer: D. Warfarin

Explanation: Warfarin is given as the lifelong medication for patients with prosthetic mitral valve replacement . All mechanical valves require long-term anticoagulation because they can cause systemic thromboembolism or may develop valve thrombosis or obstruction . Warfarin, a v itamin K antagonist , works by inhibiting the clotting proteins in the blood, providing necessary anticoagulation to prevent thromboembolic complications in patients with mechanical heart valves. For patients with mechanical heart valve replacements, warfarin therapy requires a higher target INR range of 3.0 to 3.5 . This higher intensity of anticoagulation is necessary to prevent thromboembolic complications associated with mechanical valves. Warfarin Use Target INR Range Atrial Fibrillation 2.0 - 2.5 Venous Thromboembolism (VTE) Prophylaxis Bioprosthetic Heart Valves (first 3 months) Post-Myocardial Infarction Treatment of DCT, PE, TIA 2.5 - 3.0 Mechanical Prosthetic Heart Valves 3.0 - 3.5 Recurrent Thromboembolism Aspirin (Option A): While aspirin is an antiplatelet agent that acts on blood platelets, it alone is insufficient for mechanical valve anticoagulation. Unlike warfarin, which inhibits the circulating blood clotting proteins, aspirin's antiplatelet action is not potent enough to prevent valve thrombosis in mechanical valves. Clopidogrel (Option B): Clopidogrel, like aspirin, has anti-platelet action and is not adequate for mechanical valve anticoagulation. Both these drugs act on platelets and not on clotting proteins, making them insufficient for preventing mechanical valve thrombosis. Atorvastatin (Option C): Atorvastatin is an anti-dyslipidemic drug that has no anticoagulant properties. While patients with prosthetic valves may require statins for other cardiovascular indications, the primary requirement is anticoagulation, not lipid management.

References:

Harrison's Principles of Internal Medicine, 21st Edition, Page 933

K D Tripathi, Essentials of Medical Pharmacology, 8th edition, Page 669

↑ *Back to this question in Part A*

@Neet_pg_bot

Q85: A 68-year-old male presents with palpitations and shortness of breath. His medical history includes hypertension, diabetes, and coronary artery disease. On examination, irregularly irregular heartbeats are noted. An electrocardiogram (ECG) reveals irregularly irregular rhythm , no P waves, and absence of an isoelectric baseline. His blood pressure is 132/84 mmHg, heart rate 130 bpm, and oxygen saturation 94% on room air. Given the patient's clinical presentation and history, which of the following treatment options should be considered as a first-line approach for managing this case? (Q855706)

A. Amiodarone

B. Metoprolol

C. Electrical cardioversion

D. Direct oral anticoagulant (DOAC) therapy

Correct Answer: B. Metoprolol

Explanation: The clinical scenario of a patient with a history of hypertension, diabetes, and coronary artery disease, irregularly irregular heartbeats on examination, along with an ECG showing irregularly irregular rhythm, no P waves, and absence of an isoelectric baseline, points towards a diagnosis of atrial fibrillation. The first-line approach for managing this case is beta blockers , such as metoprolol , to achieve rate control. Atrial Fibrillation Features Characterized by abnormal automatic firing and multiple re-entry circuits. Atria beat rapidly and ineffectively; ventricles activated irregularly Produces an "irregularly irregular" pulse Palpitations, syncope, and breathlessness can be present Asymptomatic AF: Can present as systemic embolism and stroke ECG Features QRS Complexes: Irregular but normal P Waves: Absent; baseline may show irregular fibrillation waves Ventricular Rate: Fast at onset (120-160 beats/min) Slower in chronic AF due to medication effects and AV nodal fatigue {{caption_text}} Management Paroxysmal Atrial Fibrillation First-line Therapy: Beta-blockers are effective in patients with CAD, hypertension, and heart failure. Class Ic Drugs: Propafenone or flecainide to prevent episodes (not for patients with CAD or LV dysfunction). Class III Drugs: Amiodarone : Most effective but with significant side effects; used when other treatments fail. (Option A) Dronedarone : Alternative to amiodarone; contraindicated in heart failure. Rate Control: Digoxin and verapamil for AV node conduction slowing, but not for AF prevention. Catheter Ablation: Considered for patients with drug-resistant AF; prevents AF in ~75% of cases but may have complications. Persistent Atrial Fibrillation Rhythm Control : Cardioversion : Electrical or pharmacological (e.g., intravenous flecainide or amiodarone). Timing: Immediate if AF <48 hours in unstable patients. (Option C) Anticoagulation is required if AF ≥48 hours to prevent thromboembolic events. (Option D) Prophylactic Amiodarone : To reduce recurrence risk. Rate Control : Medications: Digoxin, β-blockers, or rate-limiting calcium antagonists (verapamil, diltiazem) . Combination Therapy: Digoxin with β-blockers ; avoid combining calcium antagonists with β-blockers. Pace and Ablate: Permanent pacemaker with AV nodal block for symptomatic AF.

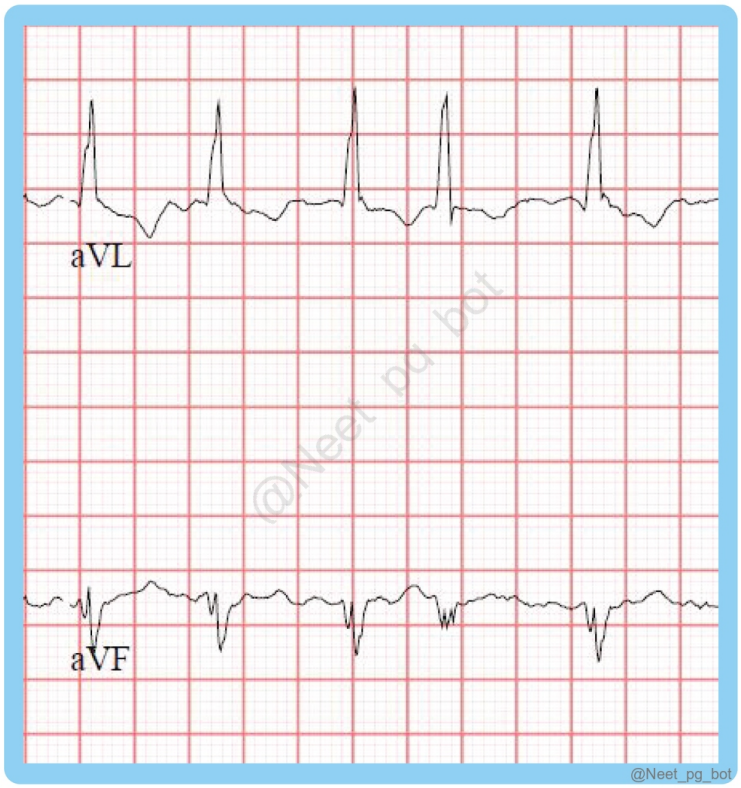

References:

Harrison’s Principles of Internal Medicine, 21st Edition, Page 1903- 1907 Davidson’s Principles and Practice of Medicine, 24th Edition, Page 470, 471, 472

↑ *Back to this question in Part A*

@Neet_pg_bot

Q86: All are true regarding heart failure except: (Q855713)

A. Regardless of ejection fraction and the type of heart failure, the 5-year mortality rate is around 50%

B. Non-cardiovascular death is more in HFrEF-30-40% as compared to HFpEF-15%

C. Angiotensin converting enzyme (ACE) inhibitors cause cough in 15% and angioedema in 1%

D. Atrial fibrillation is common in elderly and is the cause of stroke in quarter of the stroke cases

Correct Answer: B. Non-cardiovascular death is more in HFrEF-30-40% as compared to HFpEF-15%

Explanation: Noncardiac causes account for a significant proportion of deaths, with 62% in HFpEF , 54% in HFmrEF, and 35% in HFrEF. Classification of Heart Failure by Left Ventricular Ejection Fraction: Type of Heart Failure Definition Heart failure with reduced ejection fraction (HFrEF) LVEF ≤40% Heart failure with improved ejection fraction (HFimpEF) Previous LVEF ≤40% and a follow-up LVEF >40% Heart failure with mildly reduced ejection fraction (HFmrEF) LVEF 41%–49% Heart failure with preserved ejection fraction (HFpEF) LVEF ≥50% Regardless of ejection fraction and the type of heart failure, the 5-year mortality rate is around 50% (Option A) : The 5-year mortality rate for heart failure patients, regardless of ejection fraction, is approximately 50%. The development of symptomatic heart failure carries a poor prognosis, with around 30-40% of patients dying within 1 year of diagnosis, and 60-70% dying within 5 years, which is correct. Angiotensin converting enzyme (ACE) inhibitors cause cough in 15% and angioedema in 1% (Option C) : ACE inhibitors are known to cause a cough in 15% of patients and rarely cause rashes or angioedema in 1% due to the accumulation of bradykinin and substance P, which is true. Atrial fibrillation is common in elderly and is the cause of stroke in quarter of the stroke cases (Option D) : Atrial fibrillation is common in elderly patients, with more than 95% of patients being over 60 years old. It increases the risk of stroke by five-fold and is responsible for around 25% of strokes, which is accurate.

References:

https://www.ncbi.nlm.nih.gov/books/NBK553115/ https://pmc.ncbi.nlm.nih.gov/articles/PMC6818034/#

↑ *Back to this question in Part A*

@Neet_pg_bot

Q87: In atrial fibrillation, choose the correct statements: Novel oral anticoagulants (NOACs) used in the treatment of moderate to severe MS Anticoagulants should be given in patients with ischemic stroke due to atrial fibrillation NOACs are contraindicated in prosthetic valves All patients with atrial fibrillation who are not candidates for cardiac surgery can be started on beta-blockers (Q855730)

A. 1,2,3 and 4 correct

B. 1,2 and 3 correct

C. 2 and 3 correct

D. 1 and 4 correct

Correct Answer: C. 2 and 3 correct

Explanation: The correct statements are 2 and 3. Atrial Fibrillation Features Characterized by abnormal automatic firing and multiple re-entry circuits. Atria beat rapidly and ineffectively; ventricles activated irregularly Produces an "irregularly irregular" pulse Palpitations, syncope, and breathlessness can be present Asymptomatic AF: Can present as systemic embolism and stroke ECG Features QRS Complexes: Irregular but normal P Waves: Absent; baseline may show irregular fibrillation waves Ventricular Rate: Fast at onset (120-160 beats/min) Slower in chronic AF due to medication effects and AV nodal fatigue {{caption_text}} Management Paroxysmal Atrial Fibrillation: First-line Therapy: Beta-blockers are effective in patients with CAD, hypertension, and heart failure. (4) Class Ic Drugs: Propafenone or flecainide to prevent episodes (not for patients with CAD or LV dysfunction). Class III Drugs: Amiodarone : Most effective but with significant side effects; used when other treatments fail. Dronedarone : Alternative to amiodarone; contraindicated in heart failure. Rate Control: Digoxin and verapamil for AV node conduction slowing, but not for AF prevention. Catheter Ablation: Considered for patients with drug-resistant AF; prevents AF in ~75% of cases but may have complications. Persistent Atrial Fibrillation: Rhythm Control : Cardioversion : Electrical or pharmacological (e.g., intravenous flecainide or amiodarone). Timing: Immediate if AF <48 hours in unstable patients. Anticoagulation is required if AF ≥48 hours to prevent thromboembolic events. Prophylactic Amiodarone : To reduce recurrence risk. Rate Control : Medications: Digoxin, β-blockers, or rate-limiting calcium antagonists (verapamil, diltiazem) . Combination Therapy: Digoxin with β-blockers ; avoid combining calcium antagonists with β-blockers. Pace and Ablate: Permanent pacemaker with AV nodal block for symptomatic AF. Thromboprophylaxis: Anticoagulation: Required for ischemic stroke prevention due to blood stasis in the left atrium. (2) Warfarin : INR target of 2.0–3.0; start 4 weeks prior to cardioversion. DOACs/NOACs: Rivaroxaban, apixaban, edoxaban, and dabigatran as alternatives to warfarin; no monitoring needed; contraindicated in atrial fibrillation with rheumatic mitral stenosis (1) or mechanical heart valves due to insufficient evidence supporting their safety and efficacy in these conditions. (3) Risk Assessment: CHA2DS2-VASc Score : For stroke risk; anticoagulate if score ≥2 . HAS-BLED Score: For bleeding risk; monitor patients with score ≥3. Aspirin: Not recommended due to low efficacy in preventing embolic stroke.

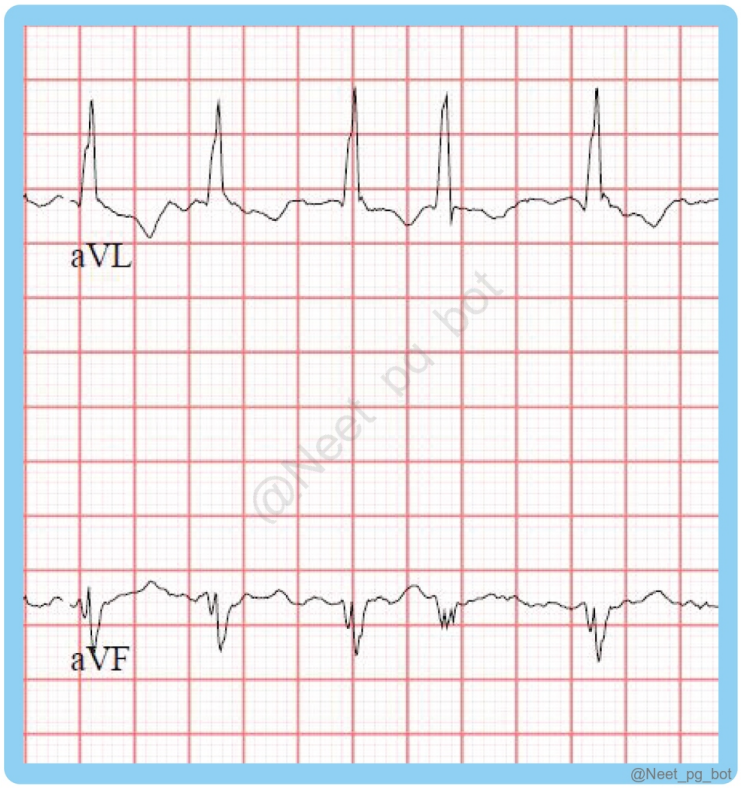

References:

Harrison’s Principles of Internal Medicine, 21st Edition, Page 1903- 1907 Davidson’s Principles and Practice of Medicine, 24th Edition, Page 470, 471, 472 https://svn.bmj.com/content/9/1/30

↑ *Back to this question in Part A*

@Neet_pg_bot

Q88: A 60 year old male patient with critical mitral stenosis presented with atrial fibrillation. He has a history of multiple episodes of transient ischemic attacks. Which of the following are true regarding the prevention of stroke in this patient? Only aspirin is given Warfarin is given Direct oral anticoagulants are not indicated Mitral valvotomy should be recommended (Q855731)

A. 1 only

B. 2 and 3

C. 2,3 and 4

D. 1,2,3 and 4

Correct Answer: B. 2 and 3

Explanation: The true statements regarding the prevention of stroke in this patient are 2 and 3. Atrial Fibrillation Features Characterized by abnormal automatic firing and multiple re-entry circuits. Atria beat rapidly and ineffectively; ventricles activated irregularly Produces an "irregularly irregular" pulse Palpitations, syncope, and breathlessness can be present Asymptomatic AF: Can present as systemic embolism and stroke ECG Features QRS Complexes: Irregular but normal P Waves: Absent; baseline may show irregular fibrillation waves Ventricular Rate: Fast at onset (120-160 beats/min) Slower in chronic AF due to medication effects and AV nodal fatigue {{caption_text}} Management Paroxysmal Atrial Fibrillation: First-line Therapy: Beta-blockers are effective in patients with CAD, hypertension, and heart failure. Class Ic Drugs: Propafenone or flecainide to prevent episodes (not for patients with CAD or LV dysfunction). Class III Drugs: Amiodarone : Most effective but with significant side effects; used when other treatments fail. Dronedarone : Alternative to amiodarone; contraindicated in heart failure. Rate Control: Digoxin and verapamil for AV node conduction slowing, but not for AF prevention. Catheter Ablation: Considered for patients with drug-resistant AF; prevents AF in ~75% of cases but may have complications. Persistent Atrial Fibrillation: Rhythm Control : Cardioversion : Electrical or pharmacological (e.g., intravenous flecainide or amiodarone). Timing: Immediate if AF <48 hours in unstable patients. Anticoagulation is required if AF ≥48 hours to prevent thromboembolic events. Prophylactic Amiodarone : To reduce recurrence risk. Rate Control : Medications: Digoxin, β-blockers, or rate-limiting calcium antagonists (verapamil, diltiazem) . Combination Therapy: Digoxin with β-blockers ; avoid combining calcium antagonists with β-blockers. Pace and Ablate: Permanent pacemaker with AV nodal block for symptomatic AF. Thromboprophylaxis: Anticoagulation: Required for ischemic stroke prevention due to blood stasis in the left atrium. Warfarin : INR target of 2.0–3.0; start 4 weeks prior to cardioversion; recommended in patients with moderate to severe mitral stenosis or mechanical valves. (2) DOACs/NOACs : Rivaroxaban, apixaban, edoxaban, and dabigatran as alternatives to warfarin; no monitoring needed; contraindicated in atrial fibrillation with rheumatic mitral stenosis or mechanical heart valves due to insufficient evidence supporting their safety and efficacy in these conditions. (3) Risk Assessment: CHA2DS2-VASc Score : For stroke risk; anticoagulate if score ≥2 . HAS-BLED Score: For bleeding risk; monitor patients with score ≥3. Aspirin: Not recommended due to low efficacy in preventing embolic stroke. (1) Mitral valvotomy should be recommended (Option 1) : Mitral valvotomy is not recommended for stroke prevention in this patient as it is indicated for symptomatic patients with isolated severe mitral stenosis and a valve area < 1.5 cm^2. It is contraindicated in the presence of left atrial thrombus, which is a common concern in atrial fibrillation.

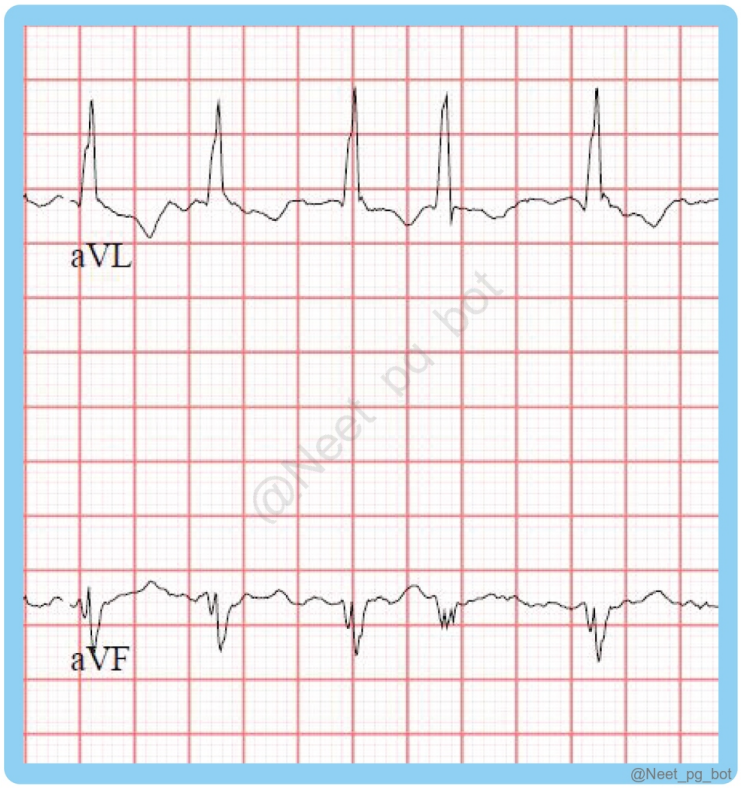

References:

Harrison’s Principles of Internal Medicine, 21st Edition, Page 1903- 1907 Davidson’s Principles and Practice of Medicine, 24th Edition, Page 470, 471, 472 https://svn.bmj.com/content/9/1/30 https://pmc.ncbi.nlm.nih.gov/articles/PMC6490374/

↑ *Back to this question in Part A*

@Neet_pg_bot

Q89: For the diagnosis of resistant hypertension, the patient should have uncontrolled hypertension despite taking three antihypertensive drugs. This should include at least one: (Q856598)

A. Calcium channel blocker

B. Beta blocker

C. Alpha blocker

D. Diuretic

Correct Answer: D. Diuretic

Explanation: iuretic For the diagnosis of resistant hypertension, the patient must have uncontrolled hypertension despite taking three antihypertensive drugs, including at least one diuretic. While calcium channel blockers , beta blockers , or alpha blockers can be part of the treatment regimen, the inclusion of a diuretic is essential to confirm the diagnosis of resistant hypertension. Resistant Hypertension: Refers to blood pressure persistently greater than 140/90 mmHg despite using three or more antihypertensive agents, including a diuretic. Population at Risk: It is more common in individuals over 60 years old and those at higher cardiovascular risk. Causes: Nonadherence to therapy. Secondary causes such as obesity, primary aldosteronism, and excessive alcohol intake. Use of certain nonprescription or prescription drugs. Evaluation: Home blood pressure monitoring can help determine if office readings are accurate. Secondary hypertension evaluation is recommended if no apparent cause of resistance is found. Management: Mineralocorticoid receptor antagonists, particularly spironolactone , are effective as add-on therapies.

References:

Harrison’s Principles of Internal Medicine, 21st Edition, Page 2086

↑ *Back to this question in Part A*

@Neet_pg_bot

Q90: Identify the disease? (Q856617)

A. Tricuspid stenosis

B. Mitral stenosis

C. Dilated cardiomyopathy

D. Hypertrophic obstructive cardiomyopathy

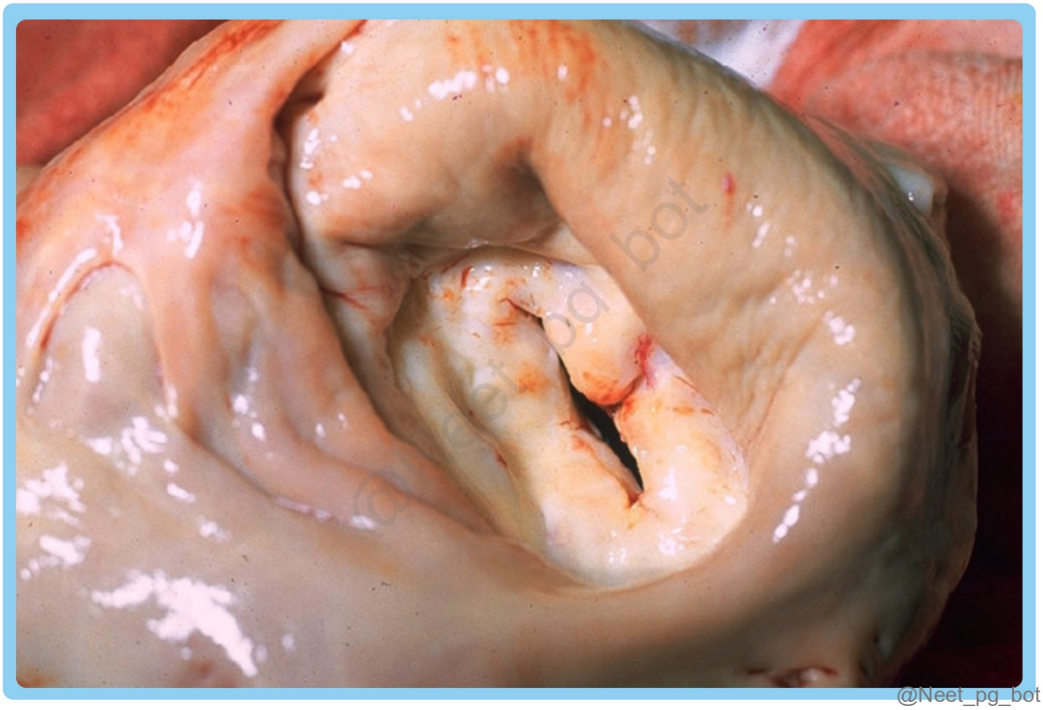

Correct Answer: B. Mitral stenosis

Explanation: - Mitral stenosis: The reduced area of the mitral valve with a "fish mouth" appearance is a hallmark feature of mitral stenosis. Mitral Stenosis (MS): Aetiology: Primary Cause : Rheumatic fever is the leading cause of mitral stenosis, accounting for about 40% of cases in patients with a history of rheumatic heart disease. Congenital abnormalities (e.g., parachute valve, cor triatriatum) Mitral annular calcification with involvement of leaflets Autoimmune diseases (e.g., systemic lupus erythematosus, rheumatoid arthritis) Left atrial myxoma Infective endocarditis with large vegetation Pathology : Chronic inflammation leads to thickening of the valve leaflets, fibrous tissue formation, calcific deposits, and fusion of the mitral commissures and chordae tendinae. This process results in a narrowed, funnel-shaped valve. (Fish-mouth Appearance) Normal mitral valve area : 4-6 cm^2; significant obstruction of <2 cm^2. Hemodynamics : In severe MS (<1.5 cm^2), a left atrial (LA) pressure of ~25 mmHg is needed to maintain normal cardiac output (CO). Effects of Heart Rate : Increased heart rate diminishes diastolic filling time, raising the LA pressure and transvalvular gradient Symptoms : Exertional dyspnea, cough, and progressive limitation of daily activities. Orthopnea and paroxysmal nocturnal dyspnea can develop as MS worsens. Atrial fibrillation (AF) often accelerates symptom progression. Complications: Pulmonary Hypertension (Leading to RVH & RHF) Atrial Fibrillation (Due to Left atrial enlargement) Thrombus Formation: Stasis of blood in the enlarged left atrium, increases the risk of thrombus formation, especially in patients with atrial fibrillation. Hemoptysis (Elevated pulmonary venous pressure - rupture of small veins) Infective Endocarditis Pulmonary Infections Findings: Inspection : Malar flush, jugular venous distension, and right ventricular (RV) enlargement. Auscultation : A loud S1, an opening snap (OS) after S2, and a low-pitched, rumbling mid-diastolic murmur with presystolic accentuation- heard best at the apex. Characteristics of a murmur in severe MS: Decreased interval between A2 & OS. Wide splitting of S2. Palpable systolic thrill. The duration of the murmur increases. Investigations: ECG : Often shows LA enlargement, right axis deviation, and RV hypertrophy. Echocardiogram : Measures mitral inflow velocity and transvalvular gradients and evaluates for associated mitral regurgitation (MR) or other valvular lesions. Chest X-ray : Shows LA enlargement, pulmonary vein dilation, and Kerley B lines indicating pulmonary congestion.

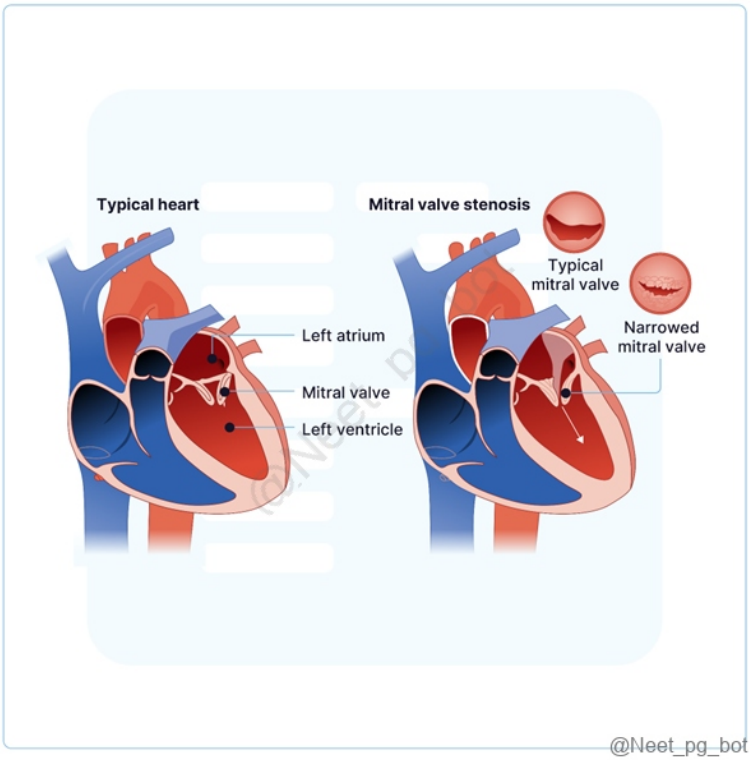

@Neet_pg_bot

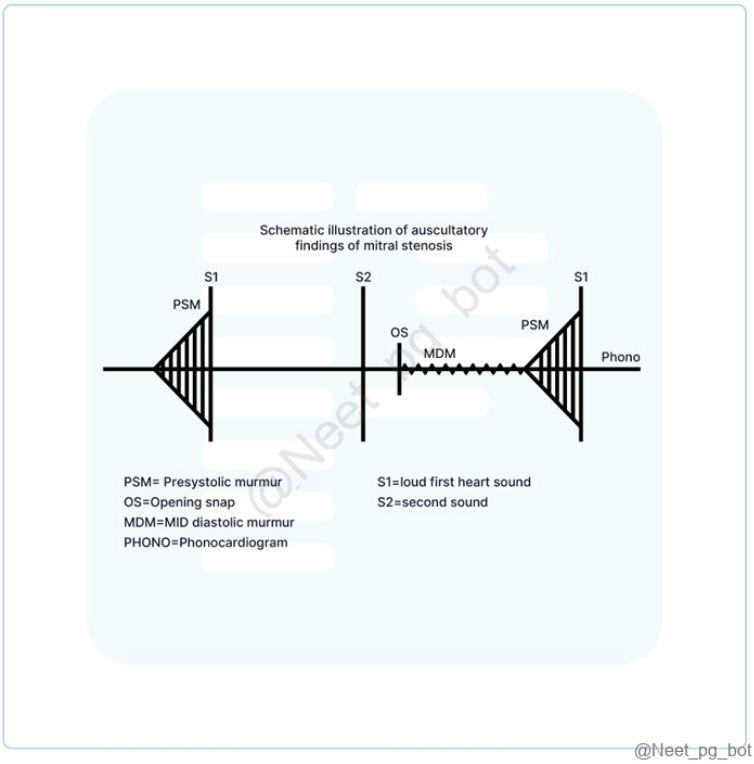

@Neet_pg_bot

References:

Harrison’s Principles of Internal Medicine, 21st Edition, Page 1991-1994

↑ *Back to this question in Part A*

@Neet_pg_bot

Q91: A patient who is a known case of atherosclerosis underwent a circumflex artery bypass. The stent is now placed successfully. He's already taking lisinopril, verapamil, and metoprolol. Which drug should be added? (Q856117)

A. PDE 3 inhibitor

B. Direct oral anticoagulant

C. P2Y12 receptor blocker

D. PDE 5 inhibitor

Correct Answer: C. P2Y12 receptor blocker

Explanation: P2Y12 receptor blockers , such as clopidogrel, ticagrelor, and prasugrel, are antiplatelet medications commonly used in patients undergoing percutaneous coronary intervention (PCI), including the placement of stents. Percutaneous Coronary Intervention (PCI) PCI involves balloon dilatation and stenting for symptomatic IHD with suitable stenoses in epicardial coronary arteries. Indications : Symptom-limiting angina despite optimal medical therapy. Evidence of ischemia during stress tests. Post-PCI Management : Aspirin is administered indefinitely, and P2Y12 antagonists for 1-3 months. P2Y12 receptor antagonists are used with aspirin for up to 12 months. Clopidogrel (300mg, followed by 75 mg daily) with aspirin reduces death, reinfarction, and stroke risks in STEMI patients. Newer drugs like ticagrelor (180 mg, followed by 90 mg twice daily) and prasugrel (60 mg, followed by 10 mg daily) are more effective than clopidogrel for ischemic complication prevention in STEMI patients undergoing PCI but have a higher bleeding risk. Current-generation drug-eluting stents reduce restenosis but require prolonged dual antiplatelet therapy (DAPT). Incorrect Options: Phosphodiesterase-3 (PDE 3) inhibitors (Option A) are commonly used in the treatment of heart failure and peripheral vascular disease. Direct oral anticoagulants (DOACs) (Option B) may be considered in some patients with certain indications, such as atrial fibrillation or mechanical heart valves. The routine use of DOACs may not be necessary in all patients who undergo a circumflex artery bypass for atherosclerosis. Phosphodiesterase-5 (PDE 5) inhibitors (Option D) , such as sildenafil, tadalafil, and vardenafil, are primarily used for the treatment of erectile dysfunction and pulmonary arterial hypertension.

References:

Davidson's Principles and Practice of Medicine, 24th edition, Page: 491.

↑ *Back to this question in Part A*

@Neet_pg_bot

Q92: A male patient had feeble femoral pulses with an upper-limb blood pressure of 186/90 mmHg. Chest x-ray showed enlarged intercostal arteries. What is the likely diagnosis? (Q856118)

A. Coarctation of aorta

B. Atrial septal defect

C. Bicuspid aortic valve

D. Patent ductus arteriosus

Correct Answer: A. Coarctation of aorta

Explanation: The feeble femoral pulses and raised upper limb blood pressure indicate the diagnosis of coarctation of the aorta. The enlarged intercostal vessels indicate collaterals. Coarctation of the Aorta: It is a congenital condition leading to the narrowing of the aortic arch. This narrowing causes a shelf-like obstruction in the descending aorta, typically near the junction of the main and left pulmonary arteries. Less commonly affects the transverse aortic arch. Physical Examination Findings: Characteristic features: Elevated blood pressure in the upper limbs. Brachiofemoral delay: Diminished or delayed femoral pulses compared to brachial or radial pulses. Lower extremity blood pressure and pulses are lower and delayed than upper extremities (systolic pressure gradient > 20 mmHg between upper & lower extremities) unless significant aortic collaterals have developed. A continuous murmur may be heard over the scapula due to collateral blood flow. Hemodynamic Effects: Increased afterload on structures receiving oxygenated blood, including the left ventricle, coronary arteries, ascending/transverse aorta, cerebral and arm vessels, and proximal descending aorta. Associations: A bicuspid aortic valve (typically with right-left commissural fusion) is commonly seen. Turner syndrome should be considered, especially in women with short stature, webbed neck, lymphedema, and primary amenorrhea. Turner syndrome often indicates a more severe condition with increased risks. Prognosis and Risks Post-Surgical Repair: Generally good prognosis after surgical repair. However, patients remain at risk for: Systemic hypertension Premature atherosclerosis Left ventricular failure Aortic aneurysm, dissection, and recurrent coarctation. Incorrect Options: Atrial septal defect (Option B) typically causes right heart volume overload, with a fixed split S2 and a systolic ejection murmur at the pulmonary area, reflecting increased pulmonary flow. It does not produce a blood pressure difference between the upper and lower limbs or weak femoral pulses. The bicuspid aortic valve (Option C) has a varied presentation and has findings of low-pitched systolic ejection murmur and ejection click. Patent ductus arteriosus (Option D) is a congenital anomaly of the heart where the ductus arteriosus fails to completely close and leads to a continuous machinery murmur below the clavicle, prominent precordial impulse, tachycardia, and bounding peripheral pulses.

References:

Harrison’s Principles of Internal Medicine, 21st Edition, Page: 2015.

https://www.ncbi.nlm.nih.gov/books/NBK430913/

↑ *Back to this question in Part A*

@Neet_pg_bot

Q93: A 45-year-old woman with a history of hypertension presented to the emergency room with loss of consciousness, chest pain, and diaphoresis. On examination, she was grossly unstable, and the bilateral pulses were unequal. ECG showed nonspecific ST-T changes. What is the next best investigation? (Q856130)

A. MRI

B. Transoesophageal echocardiography

C. Cardiac enzymes

D. X-ray

Correct Answer: B. Transoesophageal echocardiography

Explanation: The clinical features here point to the diagnosis of aortic dissection, and the most sensitive and specific investigation for this is transesophageal endoscopy. Transesophageal Echocardiography (TEE) TEE uses a transducer at the tip of an endoscope inserted into the oesophagus for clearer views of the heart. Provides better image quality and spatial resolution, especially for posterior structures. Preferred for assessing small cardiac lesions like valvular vegetations, intracardiac thrombi, and congenital abnormalities. Requires topical and systemic anaesthesia, usually conscious sedation. Risks include oesophagal damage, perforation, aspiration, and anaesthesia complications. Used in intubated patients and for intraoperative monitoring during cardiac surgeries. Clinical Features of Aortic Dissection: Pain: Sudden onset, severe, tearing chest pain , often associated with diaphoresis . Pain location: Can be anterior or posterior chest, commonly in the interscapular region, and may migrate as the dissection progresses. Associated Symptoms: Syncope , dyspnea, and weakness. Neurological symptoms (e.g., hemiplegia, hemianesthesia due to carotid artery obstruction, paraplegia due to spinal cord ischemia). Bowel ischemia, hematuria, and myocardial ischemia. Physical Findings: Hypertension or hypotension, loss of pulses, aortic regurgitation, pulmonary oedema. Horner's syndrome, superior vena cava syndrome, hoarseness, dysphagia, and airway compromise (from adjacent structure compression). Complications: Acute aortic regurgitation (in >50% of proximal dissections), often causing bounding pulses, wide pulse pressure, and diastolic murmur. Hemopericardium and cardiac tamponade, especially in type A lesions with retrograde dissection. Investigations/Diagnosis of Aortic Dissection: Chest X-ray: (Option D) Widened superior mediastinum, left-sided pleural effusion in ascending aorta dissection. Widened mediastinum and potentially wider descending aorta in descending aorta dissection. Not highly specific, especially in cases suspecting cardiovascular events. Electrocardiogram (ECG): No myocardial ischemia on ECG helps differentiate aortic dissection from myocardial infarction. Transthoracic Echocardiography: Simple and rapid, with a sensitivity of 60-85% for aortic dissection. Most effective for proximal ascending aorta dissections. Transesophageal Echocardiography: Highly sensitive (98%) and specific (~90%) for detecting dissections of the ascending and descending aorta. Less effective for diagnosing arch dissections. CT and MRI : (Option A) Highly accurate (>90% sensitivity and specificity) for identifying intimal flaps, dissection extent, and involvement of major arteries. Useful for detecting intramural haemorrhage and penetrating ulcers. Selection between CT, MRI, and echocardiography depends on institutional resources and patient hemodynamic stability. Cardiac enzymes (Option C) , such as troponin and creatine kinase-MB elevation, indicate injury or infarction of the heart muscle, which can occur in conditions like a heart attack. While cardiac enzymes are essential in the evaluation of chest pain and suspected myocardial injury, they do not provide immediate information about the current hemodynamic instability and the cause of the patient's

symptoms.

References:

Harrison’s Principles of Internal Medicine, 21st Edition, Page: 102, 1833, 1834.

↑ *Back to this question in Part A*

@Neet_pg_bot

Q94: A 50-year-old man presents with a history of recurrent retrosternal chest pain, with each episode lasting for 3-5 min and subsiding with sublingual nitrate. ECG shows left ventricular hypertrophy and flat T-wave. He has a known case of hypertension, diabetes mellitus, and hypercholesterolemia and is currently on aspirin, atenolol, metformin, and lovastatin. What is the next best step in management? (Q856171)

A. IV glyceryl trinitrate infusion

B. Injection enoxaparin

C. Add clopidogrel

D. Increase the dose of beta blocker

Correct Answer: B. Injection enoxaparin

Explanation: The patient's clinical presentation, history of recurrent chest pain, and ECG findings of left ventricular hypertrophy and flat T-waves raise concerns for NSTEMI-acute coronary syndrome. Injection enoxaparin , a low molecular weight heparin, is often used as an initial treatment to prevent clot formation and progression of coronary artery disease. Management of NSTEMI-ACS Management of NSTEMI involves evaluating patients with a low likelihood of ischemia in emergency settings, continuous ECG monitoring, stress testing, and serum troponin assessments, while those who meet criteria for NSTE-ACS are admitted for further monitoring and medical treatment aimed at stabilizing their condition and preventing future events. Medical management Anti-ischemic therapy: Sublingual glyceryl trinitrate/nitroglycerin: DOC for unstable angina For ischemic discomfort IV beta-blockers (Atenolol, Metoprolol): They reduce the oxygen demand of the myocardium They relieve pain, reduce arrhythmias, and reduce short-term mortality Verapamil and diltiazem: Given if symptoms are not relieved by full dose beta blockers and nitrates They decrease the heart rate IV morphine sulfate or diamorphine: For analgesia Antiemetics like metoclopramide (For symptomatic relief) Nifedipine or amlodipine (If chest discomfort persists) Atorvastatin and other HMG-CoA reductase inhibitors: Reduces occurrence of MI and recurrences of acute coronary syndrome Ezetimibe or alirocumab, evolocumab: Given if unresponsive to full dose statins They reduce LDL cholesterol and prevent further cardiovascular events Antithrombotic therapy: Antiplatelet drugs: Cyclooxygenase inhibitor: aspirin Platelet P2Y12 receptor inhibitor: clopidogrel Anticoagulants: Unfractionated heparin. Low molecular heparin: Enoxaparin. Direct thrombin inhibitor: bivalirudin. Synthetic factor Xa inhibitor: fondaparinux. Invasive management Done if the medical management

fails and symptoms do not improve. Coronary arteriography must be done within 48 hours of presentation. Coronary revascularisation includes PCI (percutaneous coronary intervention) or coronary artery bypass grafting (CABG) . IV glyceryl trinitrate infusion (Option A) is given in case of patients presenting with ongoing chest pain. The given scenario here gives a history of recurrent chest pains but does not specify that the patient suffers from it at presentation. Hence, it is not the best step for management. Add clopidogrel (Option C): Clopidogrel is an antiplatelet drug that has antithrombotic action, however, enoxaparin is a better agent than clopidogrel and hence not preferred. Increase the dose of beta-blocker (Option D) : This step is not preferred over anticoagulation therapy using enoxparin.

References:

Davidson's principles and practice of medicine, 24th Edition, Page: 493, 500.

Harrison's Principles of Internal Medicine, 21st Edition, Page: 2046, 2047.

https://www.ncbi.nlm.nih.gov/books/NBK442000/

https://pubmed.ncbi.nlm.nih.gov/9790281/

https://www.ncbi.nlm.nih.gov/books/NBK557814/

↑ *Back to this question in Part A*

@Neet_pg_bot

Q95: Evaluation of a patient revealed the presence of a mid-diastolic murmur. JVP showed prominent a-waves. What is the likely diagnosis? (Q856199)

A. Mitral stenosis

B. Tricuspid stenosis

C. Mitral regurgitation

D. Tricuspid regurgitation

Correct Answer: B. Tricuspid stenosis

Explanation: The mid-diastolic murmur and the prominent a-waves on the JVP suggest the narrowing of the tricuspid valve, called tricuspid stenosis . Tricuspid Stenosis Aetiology Congenital Rheumatic origin (often coexists with mitral stenosis) Pathophysiology RA pressure ↑ , due to the diastolic pressure gradient between RA and RV, results in systemic venous congestion. Restricted forward flow of blood leads to ↓ cardiac output. Clinical features Fatigue Mild dyspnea Venous congestion (right-side heart failure): Hepatomegaly, ascites, oedema and may lead to cardiac cirrhosis. Physical examination: Jugular venous distension with prominent ‘a’ waves Auscultation: Mid-diastolic murmur at left lower sternal border Murmur increases with inspiration (Carvallo's sign). If mitral stenosis coexist Pulmonary artery hypertension Orthopnea due to pulmonary oedema Investigations Chest X-ray and ECG show features of RA enlargement Echocardiogram: Thickened tricuspid valve with diastolic

doming and increased pressure gradient between RV and RA. Management Medical management: To reduce systemic venous congestion symptoms Dietary salt restriction Loop diuretics Surgical intervention: Valvular repair or Prosthetic valve replacement. Incorrect Options: Mitral stenosis (MS) (Option A) causes left atrial pressure overload, leading to pulmonary congestion and dyspnea, often with orthopnea and paroxysmal nocturnal dyspnea. It is associated with a low-pitched rumbling mid-diastolic murmur with an opening snap but no prominent a-waves in JVP unless it is a severe case. Mitral regurgitation (Option C) presents with a holosystolic murmur radiating to the axilla, which is not the given scenario. The JVP changes are seen only in severe cases. Tricuspid regurgitation (Option D) is associated with a 'C-v' wave and steep 'y' descent in the JVP and has a blowing holosystolic murmur.

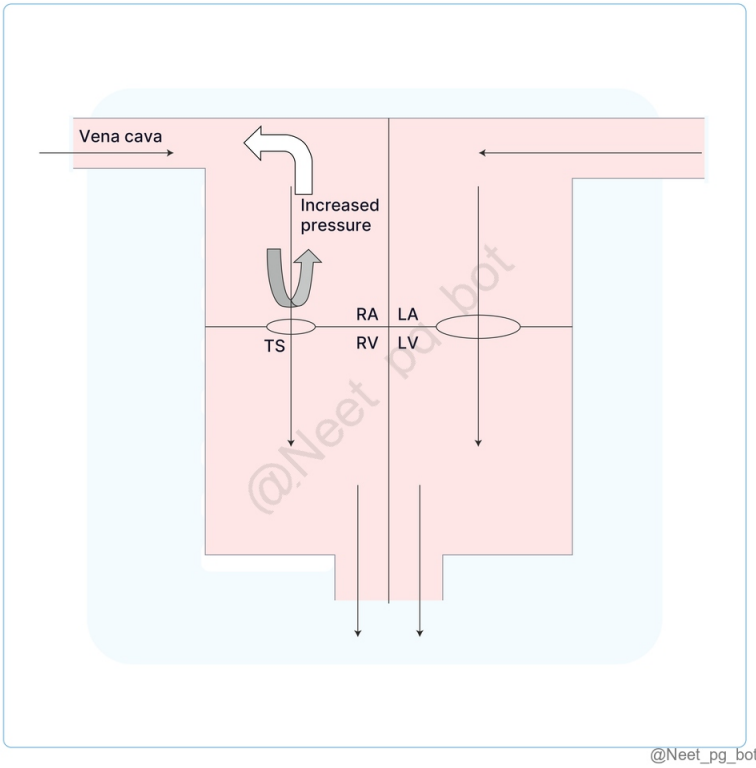

References:

Harrison's Principles of Internal Medicine, 21st Edition, Page: 2001, 2002

↑ *Back to this question in Part A*

@Neet_pg_bot

Q96: A 20-year-old woman presents with breathlessness and chest pain. She is a known case of mitral stenosis. Her pulse is irregularly irregular. No thrombus is seen on echocardiography. What is the best agent to prevent future thrombotic events? (Q856202)

A. Dabigatran

B. Aspirin 150mg

C. Oral warfarin

D. Aspirin + Clopidogrel

Correct Answer: C. Oral warfarin

Explanation: Oral warfarin is the best agent to prevent thrombotic events in case of mitral stenosis. Mitral Stenosis (MS): Aetiology: Primary Cause : Rheumatic fever is the leading cause of mitral stenosis, accounting for about 40% of cases in patients with a history of rheumatic heart disease. Congenital abnormalities (e.g., parachute valve, cor triatriatum) Mitral annular calcification with involvement of leaflets Autoimmune diseases (e.g., systemic lupus erythematosus, rheumatoid arthritis) Left atrial myxoma Infective endocarditis with large vegetation Symptoms : Exertional dyspnea, cough, and progressive limitation of daily activities. Orthopnea and paroxysmal nocturnal dyspnea can develop as MS worsens. Atrial fibrillation (AF) often accelerates symptom progression. Complications: Pulmonary Hypertension (Leading to RVH & RHF) Atrial Fibrillation (Due to Left atrial enlargement) Thrombus Formation: Stasis of blood in the enlarged left atrium, increases the risk of thrombus formation, especially in patients with atrial fibrillation. Hemoptysis (Elevated pulmonary venous pressure - rupture of small veins) Infective Endocarditis Pulmonary Infections Management of Mitral Stenosis: Medical Management: Patients with mild symptoms may be managed medically. Penicillin Prophylaxis : Essential for preventing rheumatic fever in risk patients. Symptomatic Relief : Sodium restriction, diuretics, beta-blockers, and Calcium channel blockers help manage symptoms and control heart rate in atrial fibrillation (AF). Anticoagulation : Warfarin is for patients with AF, a history of thromboembolism , or left atrial thrombus; INR target 2–3. Cardioversion : For recent-onset AF, ensure anticoagulation for at least three weeks. Infective Endocarditis Prophylaxis : Routine antibiotic prophylaxis is no longer recommended. Interventional: Considered if patients remain symptomatic despite medical management or if pulmonary hypertension develops/Severe MS (<1.5 cm^2) Balloon valvuloplasty Mitral valvotomy/Mitral valve replacement Incorrect Options: Dabigatran (Option A) is an alternative anticoagulant but is not preferred as the first-line treatment as it has an increased risk of causing thromboembolic events. Aspirin + Clopidogrel (Option B & D) is not approved for use in mitral stenosis to prevent thrombotic events.

References:

Harrison’s Principles of Internal Medicine, 21st Edition, Page: 1991-1994.

↑ *Back to this question in Part A*

@Neet_pg_bot

Q97: Resistant hypertension is defined as? (Q856945)

A. BP >160/90 mmHg with one antihypertensive

B. BP >140/90 mmHg with one antihypertensive

C. BP >160/90 mmHg with three or more antihypertensive

D. BP >140/90 mmHg with three or more antihypertensive

Correct Answer: D. BP >140/90 mmHg with three or more antihypertensive

Explanation: Resistant hypertension is defined as persistently elevated blood pressure (BP) that remains >140/90 mmHg despite the use of three or more antihypertensive medications, being one of them is diuretic, and at optimal doses. Hypertension Diagnosis Based on ABPM (ambulatory blood pressure monitoring) 24-h Average ≥130/80 mm Hg Awake (daytime) average ≥135/85 mm Hg Asleep (night-time) average ≥120/70 mm Hg Hypertension category based on the American College of Cardiology (ACC) Blood pressure category Systolic (mm Hg) Diastolic (mm Hg) Normal < 120 < 80 Elevated 120-129 <80 Stage 1 hypertension 130 – 139 80 – 89 Stage 2 hypertension ≥140 ≥90 Hypertensive crisis >180 >120 Measurement of automated office Blood Pressure (AoBP) : 3 readings to be taken Discard 1st reading The next 2 readings need to be averaged HTN if BP> 135/85 mmHg

References:

Harrison's Principle of Internal Medicine, 21st edition, Page 2076

Blood pressure readings

Ambulatory Blood Pressure Measurement | Hypertension (ahajournals.org)

Measurement of Blood Pressure in Humans: A Scientific Statement From the American Heart Association | Hypertension (ahajournals.org)

↑ *Back to this question in Part A*

@Neet_pg_bot

Q98: Which among the following investigations is the most suitable for diagnosing myocardial infarction (MI) within a timeframe of 2-4 hours of onset of chest pain? (Q856953)

A. LDH

B. CKMB

C. Troponin-T

D. BNP

Correct Answer: C. Troponin-T

Explanation: Troponin-T is a cardiac biomarker that is highly specific to cardiac muscle injury. It typically starts to rise within 3-4 hours after the onset of myocardial injury and remains elevated for several days. Therefore, it is considered the best investigation for diagnosing MI within 2-4 hours of symptom onset. Cardiac Biomarkers for

Acute Myocardial Infarction (AMI): 1. Cardiac Troponin Preferred biochemical markers due to their sensitivity and specificity. Criteria for ACS: Requires rise and/or fall in biomarker values, with at least one value above the 99th percentile upper reference limit. Troponin T (cTnT) and Troponin I (cTnI) increase significantly after STEMI. Can detect concentrations <1 ng/L in non-ischemic conditions. Troponin levels: Increase within 3-6 hours Peak at around 36 hours Remains elevated for 7-10 days after STEMI. Troponin should be measured at presentation and repeated at 1-3 hours (high-sensitivity assays) or 3-6 hours (conventional assays). Further troponin tests are advised beyond 3-6 hours if AMI remains a possibility or there is diagnostic uncertainty. Causes of elevated Serum Troponin other AMI Cardiorespiratory Causes Non-Cardiorespiratory Causes Pulmonary embolism Aortic dissection Acute pulmonary edema Tachyarrhythmias Myocarditis/Myopericarditis Cardiac trauma Cardiac surgery/ablation Prolonged hypotension Severe sepsis Severe burns Stroke Subarachnoid hemorrhage End-stage renal failure Cardiac troponin levels remain elevated for several days after an acute myocardial infarction (AMI), making them unreliable for detecting reinfarction. 2. Creatine Phosphokinase (CK) and CK-MB (Option B): CK rises within 4-8 hours. Peaks by 24 hours. Returns to normal within 48-72 hours. CK lacks specificity for STEMI since it can be elevated in skeletal muscle disease, trauma, or injections. CK-MB isoenzyme is more specific for the heart CK-MB elevated: Cardiac surgery Myocarditis Electrical cardioversion CK-MB/CK ratio >2.5 suggests a myocardial source, though it's not diagnostic. CK-MB levels normalize within 48 to 72 hours , so a subsequent rise can confirm reinfarction. 3. Lactate Dehydrogenase (LDH) (Option A): Increase in the blood 6 to 12 hours after ACS. Peak within 24 to 72 hours. Normalize within 8 to 14 days. LDH is no longer used to diagnose myocardial infarction because it is not specific to cardiac myocytes. 4. Heart-type Fatty Acid-Binding Protein (H-FABP): Sensitivity of H-FABP in detecting AMI within 4 hours of symptom onset was 60%, significantly higher than troponin (18.8%) and CK-MB (12.5%). But the specificity of H-FABP in detecting AMI was less than that of troponin and CK-MB. 5. BNP (B-type natriuretic peptide) (Option D): BNP is a hormone released by the ventricles of the heart in response to increased stretching of cardiac muscle cells. It is primarily used for diagnosing and assessing the severity of heart failure. BNP levels are not specific to myocardial infarction and do not provide timely diagnosis within 2-4 hours

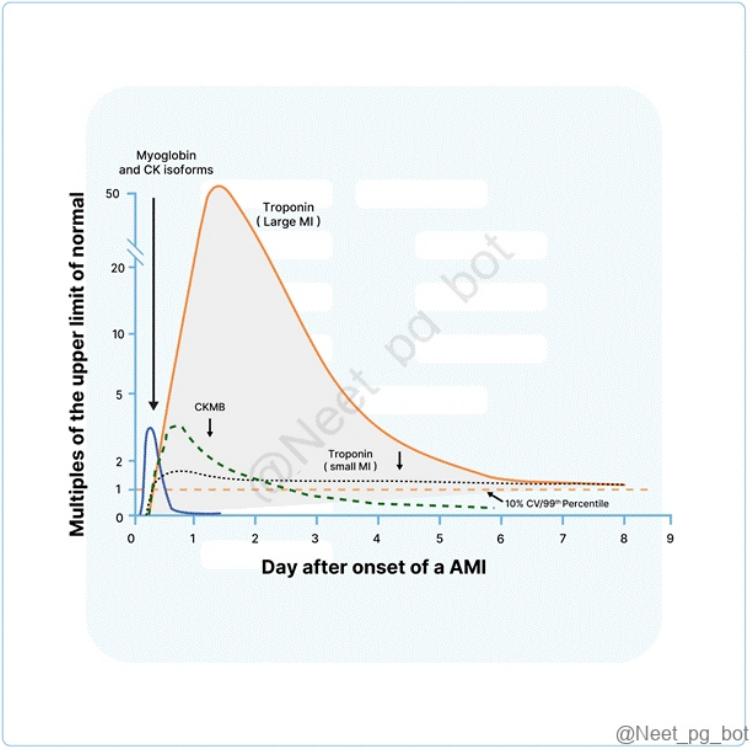

References:

Harrison’s Principles of Internal Medicine, 21st edition, Page 106, 2055, 2056

Davidson’s Principles and Practice of Medicine, 24th edition, Page 179, 497

Cardiac Biomarkers - StatPearls - NCBI Bookshelf

https://www.ncbi.nlm.nih.gov/pmc/articles/PMC9186000/#

↑ *Back to this question in Part A*

@Neet_pg_bot

Q99: Which of the following treatment options is not suitable for managing a patient with non-ST-elevation myocardial infarction (NSTEMI)? (Q856335)

A. Aspirin

B. Clopidogrel

C. Streptokinase

D. Prasugrel

Correct Answer: C. Streptokinase

Explanation: In a patient with Non-ST-elevation myocardial infarction (NSTEMI) , streptokinase is not typically used for treatment. Streptokinase belongs to the class of fibrinolytic agents and is commonly used for the management of ST-elevation myocardial infarction (STEMI) to dissolve blood clots causing the blockage in the coronary arteries. However, in NSTEMI, the underlying mechanism is often different, and the management approach focuses on antiplatelet therapy and anticoagulation rather than fibrinolysis. Management of NSTEMI-ACS: Management of NSTEMI involves evaluating patients with a low likelihood of ischemia in emergency settings, continuous ECG monitoring, stress testing, and serum troponin assessments, while those who meet criteria for NSTE-ACS are admitted for further monitoring and medical treatment aimed at stabilizing their condition and preventing future events. Medical management Anti-ischemic therapy: Sublingual glyceryl trinitrate/nitroglycerin: DOC for unstable angina For ischemic discomfort IV beta-blockers (Atenolol, Metoprolol): They reduce the oxygen demand of the myocardium They relieve pain, reduce arrhythmias, and reduce short-term mortality Verapamil and diltiazem: Given if symptoms are not relieved by full dose beta blockers and nitrates They decrease the heart rate IV morphine sulfate or diamorphine: For analgesia Antiemetics like metoclopramide (For symptomatic relief) Nifedipine or amlodipine (If chest discomfort persists) Atorvastatin and other HMG-CoA reductase inhibitors: Reduces occurrence of MI and recurrences of acute coronary syndrome Ezetimibe or alirocumab, evolocumab: Given if unresponsive to full dose statins They reduce LDL cholesterol and prevent further cardiovascular events Antithrombotic therapy: Antiplatelet drugs: Cyclooxygenase inhibitor: aspirin (Option A) Platelet P2Y12 receptor inhibitor: clopidogrel, Prasugrel (Option B, D) Anticoagulants: Unfractionated heparin. Low molecular heparin: enoxaparin. Direct thrombin inhibitor: bivalirudin. Synthetic

factor Xa inhibitor: fondaparinux. Invasive management Done if the medical management fails and symptoms do not improve. Coronary arteriography must be done within 48 hours of presentation. Coronary revascularization includes PCI (percutaneous coronary intervention) or coronary artery bypass grafting (CABG) .

References:

Harrison's Principles of Internal Medicine, 21st edition, Page 2047-2049, 2051, 2053

↑ *Back to this question in Part A*

@Neet_pg_bot

Q100: A 65 year old male patient presented to the emergency room with symptoms of palpitation, dizziness. On examination pulse is 180 beats per minute and his blood pressure is 70 mmHg systolic. The electrocardiogram (ECG) reveals a narrow QRS complex tachycardia with a regular heart rate. What should be the next course of action in managing this patient? (Q856342)

A. DC cardioversion

B. Adenosine

C. Valsalva Maneuver

D. Verapamil

Correct Answer: A. DC cardioversion

Explanation: In this patient, immediate cardioversion is the most appropriate next step in the management. DC cardioversion Electrical cardioversion (DC cardioversion) is used to terminate organized arrhythmias such as atrial fibrillation (AF) or ventricular tachycardia (VT). It is the treatment of choice for unstable tachyarrhythmias . The electric current interrupts the arrhythmia, causing a brief asystole , usually followed by the return of sinus rhythm . It is usually performed as an elective procedure under general anesthesia . The shock is delivered immediately after the R wave to avoid triggering ventricular fibrillation (VF) , which may occur if applied during ventricular repolarization (T wave) . High-energy shocks may cause chest wall pain post-procedure . If there is no urgency , it is best to start with a lower-energy shock (around 50 joules) and increase if necessary. Adenosine (Option B) is commonly used for the acute termination of supraventricular tachycardia (SVT) episodes. However, it is not the preferred initial treatment for a patient with signs of hemodynamic instability and low blood pressure. Adenosine can cause a transient period of asystole when administered, which can further compromise the patient's blood pressure. Valsalva Maneuver (Option C) involves straining against a closed glottis, can be attempted as a non-invasive method to terminate certain types of supraventricular tachycardias. Verapamil (Option D) is a calcium channel blocker that can be effective in terminating certain types of supraventricular tachycardias, such as atrioventricular nodal reentrant tachycardia.

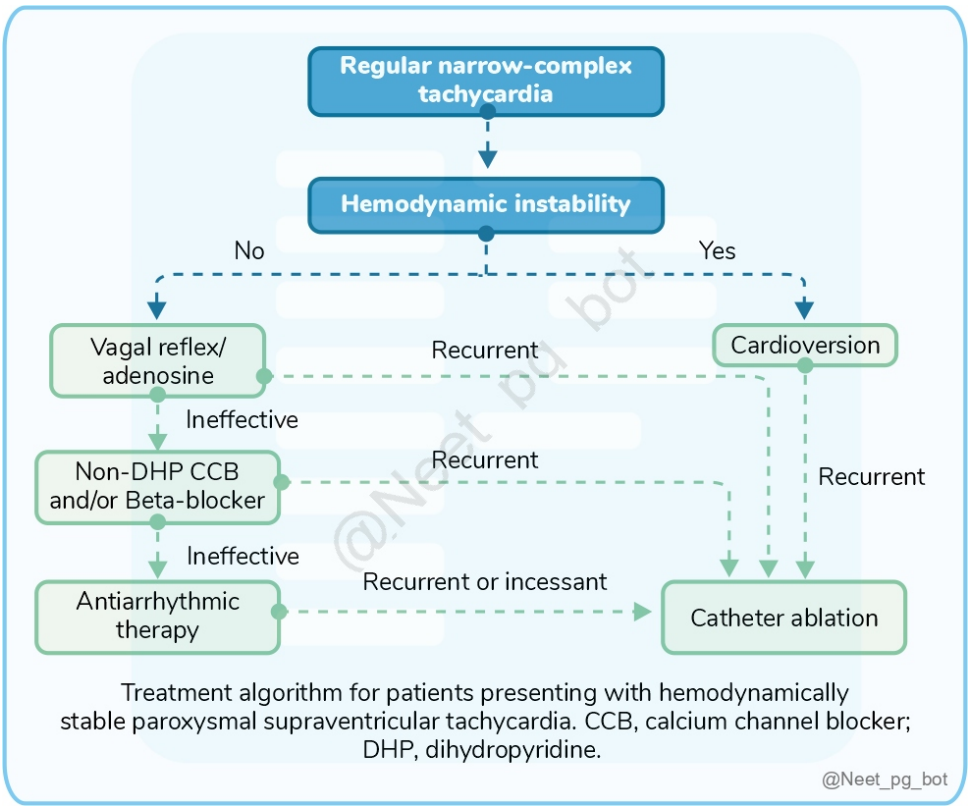

↑ *Back to this question in Part A*

@Neet_pg_bot

Q101: What would be the most appropriate approach for a patient experiencing chest pain for the past 3 hours, where an ECG shows ST depression in anterior chest leads and T wave inversion? (Q856351)

A. Intra aortic balloon pump(IABP)

B. Thrombolysis with alteplase

C. Prophylaxis for arrhythmia

D. Aspirin with heparin

Correct Answer: D. Aspirin with heparin

Explanation: As the patient presented within 3 hours of the onset of chest pain, which suggests an acute coronary syndrome (ACS) and the ECG findings of ST depression in anterior chest leads and T wave inversion are consistent with myocardial ischemia.. Aspirin is an antiplatelet agent that inhibits platelet aggregation and Heparin is an anticoagulant that prevents the formation and propagation of blood clots. It is administered promptly to patients suspected of having ACS to minimize ongoing thrombosis. Management of NSTEMI-ACS: Management

of NSTEMI involves evaluating patients with a low likelihood of ischemia in emergency settings, continuous ECG monitoring, stress testing, and serum troponin assessments, while those who meet criteria for NSTE-ACS are admitted for further monitoring and medical treatment aimed at stabilizing their condition and preventing future events. Medical management Anti-ischemic therapy: Sublingual glyceryl trinitrate/nitroglycerin: DOC for unstable angina For ischemic discomfort IV beta-blockers (Atenolol, Metoprolol): They reduce the oxygen demand of the myocardium They relieve pain, reduce arrhythmias, and reduce short-term mortality Verapamil and diltiazem: Given if symptoms are not relieved by full dose beta blockers and nitrates They decrease the heart rate IV morphine sulfate or diamorphine: For analgesia Antiemetics like metoclopramide (For symptomatic relief) Nifedipine or amlodipine (If chest discomfort persists) Atorvastatin and other HMG-CoA reductase inhibitors: Reduces occurrence of MI and recurrences of acute coronary syndrome Ezetimibe or alirocumab, evolocumab: Given if unresponsive to full dose statins They reduce LDL cholesterol and prevent further cardiovascular events Antithrombotic therapy: Antiplatelet drugs: Cyclooxygenase inhibitor: aspirin Platelet P2Y12 receptor inhibitor: clopidogrel Anticoagulants: Unfractionated heparin. Low molecular heparin: enoxaparin. Direct thrombin inhibitor: bivalirudin. Synthetic factor Xa inhibitor: fondaparinux. Invasive management Done if the medical management fails and symptoms do not improve. Coronary arteriography must be done within 48 hours of presentation. Coronary revascularization includes PCI (percutaneous coronary intervention) or coronary artery bypass grafting (CABG) . PCI (percutaneous coronary intervention) (Option A) is a preferred treatment option for patients with ST-segment elevation myocardial infarction (STEMI). Thrombolysis with alteplase (Option B) is primarily indicated for patients with STEMI who present within a specific time window and are not candidates for primary PCI. While arrhythmias can be a complication of ACS, prophylactic treatment for arrhythmias (Option C) is not the primary management strategy in the acute phase. The focus initially is on addressing the underlying ischemia and preventing further thrombosis through antiplatelet and anticoagulant therapy.

References:

Harrison's Principles of Internal Medicine, 21st edition, Page 100, 101, 2047-2049, 2051, 2053

↑ *Back to this question in Part A*

@Neet_pg_bot

Q102: A 45-year-old female patient presents to the clinic with complaints of increasing fatigue and shortness of breath. Upon auscultation, the physician detects a pan systolic murmur that is best heard at the right side of the heart. The murmur radiates to the axilla and is louder during inspiration. The patient denies any history of fever, chest pain, or recent infections. What is the most probable diagnosis for this patient's condition based on the described findings? (Q856358)

A. Aortic stenosis

B. Mitral valve prolapse

C. Ventricular septal defect

D. Tricuspid regurgitation

Correct Answer: D. Tricuspid regurgitation

Explanation: Tricuspid regurgitation is characterized by a pan systolic murmur heard best along the right side of the heart and it radiates to the right of the sternum. Additionally, tricuspid regurgitation is often secondary to other conditions affecting the right side of the heart, such as pulmonary hypertension or right heart failure. The characteristics of a pan systolic murmur heard at the right side of the heart and radiating to the axilla, along with the absence of signs of aortic stenosis, mitral valve prolapse, and ventricular septal defect, point toward tricuspid regurgitation as the most likely diagnosis in this case. It's important to consider the entire clinical picture and potentially perform further tests (e.g., echocardiography) to confirm the diagnosis and assess the severity of the condition. Aortic Stenosis (Option A) Systolic ejection murmur, crescendo-decrescendo pattern, radiating to carotids, best heard at the right upper sternal border Mitral Valve Prolapse (Option B) Late systolic murmur is best heard at the apex, not a pan systolic murmur. Typically preceded by a non-ejection click, and intensity and duration increases with maneuvers that decrease ventricular volume. Ventricular Septal Defect (Option C) Harsh, holosystolic murmur heard, best at the left lower sternal border , as blood flows from the higher-pressure left ventricle to the lower-pressure right ventricle.

References:

Harrison's Principles of Internal Medicine, 21st edition, Page 281-286, 1821-1823, 1969

Davidson's Principles and Practice of Medicine, 24th edition, Page 517-519,526

↑ *Back to this question in Part A*

@Neet_pg_bot

Q103: Correct sequence after p wave: A - ‘a’ wave B - 1 st heart sound C - Rapid filling of ventricles D - ‘t’ wave (Q856377)

A. ABCD

B. ABDC

C. CABD

D. ACBD

Correct Answer: B. ABDC

Explanation: ABDC The correct sequence after the P wave is as follows: A. The 'a' wave represents atrial contraction. It occurs during atrial systole when the atria contract to push blood into the ventricles. B. The 1st heart sound, also known as S1, is the closure of the atrioventricular (AV) valves (mitral and tricuspid valves) at the beginning of ventricular systole. It marks the onset of ventricular contraction. D. The 't' wave is a repolarization phase of the ventricles. It represents the relaxation and resetting of the ventricles after contraction. C. After the 't' wave, the ventricles enter the diastole phase, during which they passively fill with blood from the atria. This is known as rapid ventricular filling. Jugular Venous Pressure (JVP) Waveform a wave Caused by atrial systole.

Atrial contraction results in a temporary halt in venous inflow. Some blood flows back into the veins, causing a rise in venous pressure. c wave Arises from the increase in atrial pressure during isovolumetric ventricular contraction. Pressure is transmitted through the closed and bulging tricuspid valve. x descent Ventricular systole pulls the tricuspid valve down v wave Corresponds to the rise in atrial pressure as blood fills the atria. Occurs during diastole while the tricuspid valve is still closed. y descent Opening of tricuspid valve causing emptying of right atrium into ventricle Respiration Influence : Venous pressure decreases during inspiration due to negative intrathoracic pressure, and rises during expiration.

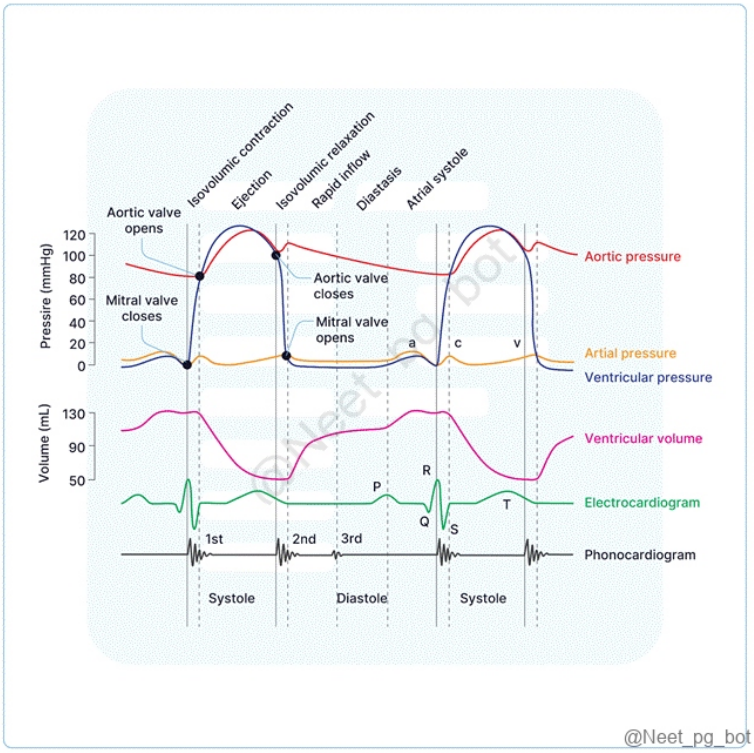

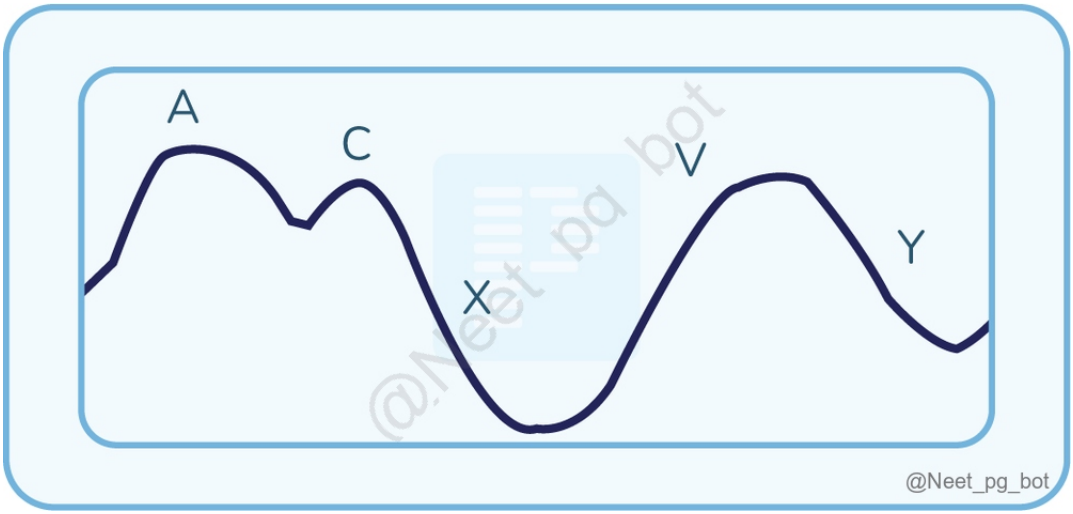

References:

Ganong’s Review of Medical Physiology, 26th edition, Page 529, 530 531

↑ *Back to this question in Part A*

@Neet_pg_bot

Q104: Water hammer pulse is seen in which of the following conditions? (Q855002)

A. Aortic stenosis

B. Aortic regurgitation

C. Aortic stenosis and aortic regurgitation

D. Mitral regurgitation

Correct Answer: B. Aortic regurgitation

Explanation: Water hammer pulse is seen in Aortic regurgitation. Signs of Aortic Regurgitation Muller Sign It is a visible systolic pulsation of the uvula Rosenbach sign Systolic pulsations of the Liver Gerhardt's sign Systolic pulsations of the Spleen Quincke's sign Repeatedly alternating blushing and blanching of capillaries in the nail folds upon palpation (Capillary Pulsations) Landolphi sign Alternating systolic constriction and diastolic dilatation of pupils Traube Sign It is pistol shot sounds that are heard while auscultating over the femoral artery. Water-Hammer pulse/ Corrigan's pulse Strong pulse that rises quickly and then drops off suddenly. Duroziez Sign It is a to-and-fro murmur heard while auscultating the femoral artery. De-Musset sign The jarring motion of the head with each heartbeat Aortic stenosis (Option A): Severe aortic stenosis is associated with pulsus parvus et tardus, characterized by a carotid pulse that rises slowly and peaks late due to restricted blood flow through the narrowed valve, which is distinct from the bounding water hammer pulse seen in aortic regurgitation. Aortic stenosis and aortic regurgitation (Option C): In cases where aortic stenosis and aortic regurgitation coexist, the stenosis reduces the stroke volume ejected into the aorta, limiting the high-amplitude and rapid upstroke typical of a water hammer pulse seen in isolated aortic regurgitation. Mitral regurgitation (Option D): Chronic mitral regurgitation shows a sharp, low-volume pulse due to reduced forward cardiac output, while acute mitral regurgitation may present with a narrow pulse pressure. Neither scenario produces the rapid upstroke and collapse characteristic of a water hammer pulse.

References:

Harrison’s Principles of Internal Medicine, 21st Edition, Page 1988

↑ *Back to this question in Part A*

@Neet_pg_bot

Q105: A 70-year-old man with a known history of DM and HTN on regular medications presents with a history of progressively worsening dyspnoea on exertion. On examination, there’s elevated JVP, positive hepatojugular reflux, crackles at the

lung bases, hepatomegaly, ascites and pedal oedema. What is your provisional diagnosis? (Q855008)

A. Heart failure

B. Hypertrophic cardiomyopathy

C. Mitral regurgitation

D. Portal hypertension

Correct Answer: A. Heart failure

Explanation: The patient’s symptoms, including progressively worsening dyspnea on exertion, elevated jugular venous pressure (JVP), positive hepatojugular reflux, crackles at the lung bases, hepatomegaly, ascites, and pedal edema, are indicative of heart failure. Clinical features of Congestive Heart Failure: Cardiac output decreased Stroke volume decreased Heart rate increased Increased sympathetic drive leading to palpitations and diaphoresis Orthopnea Paroxysmal nocturnal dyspnea Clinical Features of Left-Sided vs. Right-Sided Congestive Heart Failure (CHF) Left-Sided Heart Failure Right-Sided Heart Failure Causes : Ischemic heart disease (myocardial infarction). Hypertension Dilated cardiomyopathy. Aortic or mitral valve disease. Causes : Left-sided heart failure (most common cause). Chronic lung diseases (COPD, pulmonary hypertension). Pulmonary embolism. Right ventricular infarction. In left-sided heart failure, the left ventricle cannot effectively pump blood to the body, leading to a backup of blood into the lungs. Clinical features: This primarily results in pulmonary symptoms. Exertional dyspnea Orthopnea Paroxysmal nocturnal dyspnea Pulmonary Congestion: Crackles (rales) heard on auscultation due to fluid in the alveoli. Cough Wheezing (cardiac asthma). Fatigue and Weakness Decreased Exercise Tolerance Limited physical activity due to breathlessness and fatigue. S3 Gallop Cool Extremities: Reduced cardiac output may cause poor peripheral circulation, leading to cold, pale skin. In right-sided heart failure, the right ventricle fails to pump blood effectively into the pulmonary circulation, leading to systemic venous congestion. It is often secondary to left-sided heart failure or conditions affecting the lungs (cor pulmonale). Clinical Features: Peripheral Edema Jugular Venous Distension (JVD) Hepatomegaly B/L pitting pedal edema Kussmaul sign: JVP elevation on inspiration Ascites Nocturia Weight Gain Anorexia and Nausea Hypertrophic cardiomyopathy (Option B): While hypertrophic cardiomyopathy can cause dyspnea, the patient’s clinical signs of elevated JVP, hepatojugular reflux, crackles, hepatomegaly, ascites, and pedal edema are more indicative of heart failure due to volume overload, which is not a characteristic feature of hypertrophic cardiomyopathy. Mitral regurgitation (Option C) : Although mitral regurgitation can lead to heart failure, the signs observed here (e.g., ascites, pedal edema, crackles) indicate a more generalized failure of the heart to pump blood effectively, which is more consistent with heart failure (particularly congestive heart failure) rather than isolated mitral regurgitation. Portal hypertension (Option D) can occur secondary to right heart failure, but the progressive dyspnea, along with the extensive signs of systemic congestion (e.g., elevated JVP, ascites, hepatojugular reflux), points toward a primary cardiac condition like heart failure.

References:

https://www.ncbi.nlm.nih.gov/books/NBK430873/

↑ *Back to this question in Part A*

@Neet_pg_bot

Q106: Which of the following is not a radiological finding in a patient with left heart failure? (Q855046)

A. Kerley B lines

B. Focal oligemia

C. Increased venous blood in lung

D. Change in upper lobe circulation

Correct Answer: B. Focal oligemia

Explanation: hanges in Left Heart Failure: Pulmonary venous dilation and congestion (Option C) Cephalization of pulmonary veins: Upper lobe vessels become more prominent due to redistribution of blood flow (Option D) Kerley B (septal) lines: Horizontal lines caused by interstitial edema (Option A) Thickened interlobar fissures Pulmonary interstitial edema: Blurring of vascular margins and peribronchial cuffing Pulmonary alveolar edema: Bat-wing or butterfly pattern of opacities Pleural effusion Cardiomegaly (increased cardiothoracic ratio) {{caption_text}}

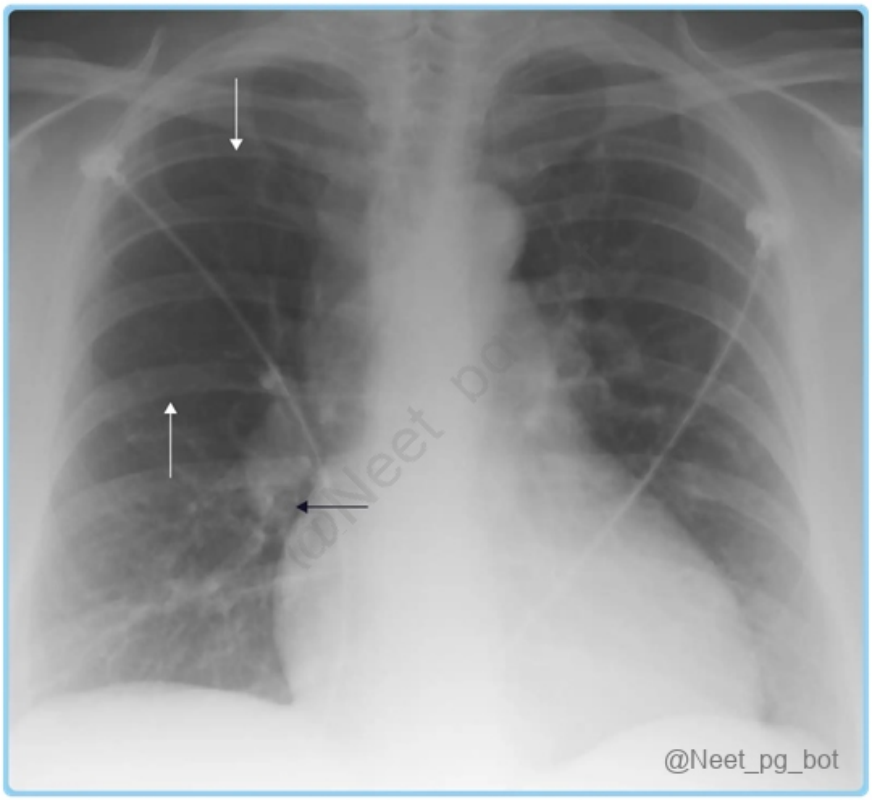

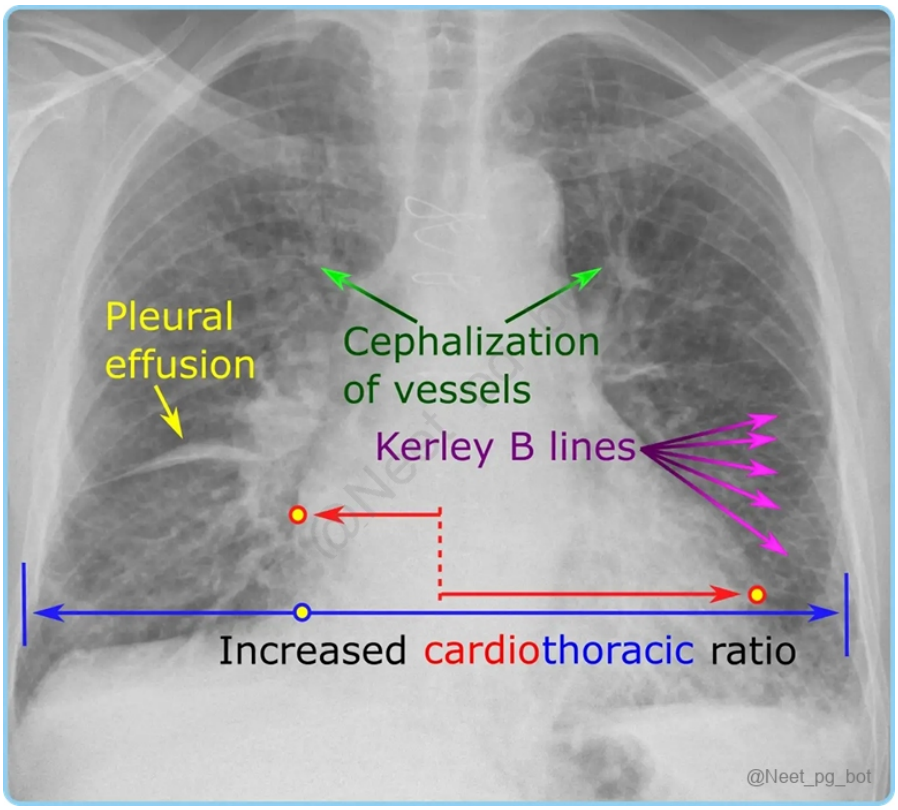

References:

https://www.sciencedirect.com/science/article/abs/pii/0002870363900966
https://radiopaedia.org/articles/congestive-cardiac-failure#:~:text=Plain%20radiograph,pleural%20effusion
https://onlinelibrary.wiley.com/doi/abs/10.1111/j.0954-6820.1972.tb04801.x

↑ *Back to this question in Part A*

@Neet_pg_bot

Q107: A 60-year-old man presented with an episode of acute onset dizziness and loss of consciousness, which lasted for a few seconds, followed by a regain of full consciousness. There were no similar episodes in the past. Which of the following is a true statement regarding this scenario? (Q855052)

A. ECG to rule out atrial fibrillation

B. If ECG is normal, CT scan should be done

C. Tilt-table testing

D. Vestibular neuritis is a possible condition that can cause these symptoms

Correct Answer: A. ECG to rule out atrial fibrillation

Explanation: The patient’s presentation of acute onset dizziness and loss of consciousness, which lasted only a few seconds and was followed by full recovery, suggests a transient loss of consciousness episode, likely syncope . This could be due to arrhythmias (atrial fibrillation , sinus node dysfunction, atrioventricular block, ventricular tachyarrhythmia) or structural cardiac abnormalities, making an ECG crucial in this case to rule out cardiac causes. Syncope: Transient, self-limited loss of consciousness due to acute global impairment of cerebral blood flow. Rapid onset, brief duration, and spontaneous, complete recovery. Categories of Syncope Causes: Neurally mediated syncope (reflex or vasovagal syncope) Orthostatic hypotension Cardiac syncope Initial Evaluation of Syncope: Detailed history and thorough questioning of eyewitnesses. Complete physical and neurologic examination. Measure blood pressure and heart rate in the supine position and after 3 minutes of standing to assess for orthostatic hypotension. ECG Indications: If there is suspicion of syncope due to arrhythmia or underlying cardiac disease. Relevant electrocardiographic abnormalities include bradyarrhythmias, tachyarrhythmias, AV block, acute myocardial ischemia, old myocardial infarction, long QT, and bundle branch block. If ECG is normal, CT scan should be done (Option B): A CT scan would only be required if a seizure or transient ischemic attack (TIA) is suspected. Given that the episode lasted only a few seconds, the patient has no history of similar events, and there are no lasting neurological deficits, a CT scan is not typically needed at this point. Tilt-table testing (Option C) is generally reserved for patients with recurrent or unexplained syncope. It is not typically used for a single isolated episode of syncope, especially in the absence of a history of similar events. Vestibular neuritis (Option D) typically causes dizziness and a sense of spinning (vertigo), but it does not generally lead to loss of consciousness. Since the patient’s primary symptom is syncope (brief loss of consciousness), vestibular neuritis is not the most likely diagnosis in this case.

References:

Harrison's Principles of Internal Medicine, 21st Edition, Page 152,157,158

↑ *Back to this question in Part A*

@Neet_pg_bot

Q108: A 58-year-old male patient has been diagnosed with hypertension. On examination, there is no existing cardiovascular disease, no hypertension-mediated organ damage (HMOD), and renal function is normal. He should be immediately started on pharmacological management if his blood pressure is more than (Q855064)

A. >130/80 mmHg

B. >160/100 mmHg

C. >150/100 mmHg

D. >140/90 mmHg

Correct Answer: D. >140/90 mmHg

Explanation: guidelines for hypertension management: Indications for Immediate Pharmacological Treatment: Adults aged 18-79 years with: Systolic Blood Pressure (SBP): ≥140 mmHg Diastolic Blood Pressure (DBP): ≥90 mmHg In patients with no cardiovascular disease, no hypertension-mediated organ damage (HMOD), and normal renal function, immediate pharmacological therapy is initiated if the BP is ≥140/90 mmHg. AHA Hypertension Grading Category Systolic BP (mmHg) Diastolic BP (mmHg) Normal <120 <80 Elevated 120–129 <80 Hypertension Stage 1 130–139 80–89 Hypertension Stage 2 ≥140 ≥90 Hypertensive Crisis >180 >120 ACC/AHA Guidelines for Hypertension Management Indications for Use of antihypertensives Secondary prevention of recurrent CVD events in patients with clinical CVD (defined as CHD, CHF, stroke) and BP ≥130/≥80 mmHg Primary prevention in patients with an estimated 10-year ASCVD risk ≥10% and BP ≥130/≥80 mmHg Primary prevention of CVD and low CVD risk in patients with BP ≥140/ ≥90 mmHg Blood Pressure Goal in Treating Hypertension BP target < 130/80 mmHg for adults with confirmed hypertension and known CVD or 10-year ASCVD event risk ≥10% Exceptions to Therapeutic Target of <130/80 mmHg Age >80 years Blood pressure <140/90 mmHg in previously untreated hypertensive patients who experience an ischemic stroke or TIA Acute therapy for most hypertensive urgencies and emergencies Abbreviations : ASCVD - atherosclerotic cardiovascular disease CHD - coronary heart disease CHF - congestive heart failure CVD - cardiovascular disease Patient type First Drug Add a Second Drug If Needed to Achieve the target BP If a Third Drug is Needed to Achieve the target BP Black patients (African ancestry): All ages CCB or thiazide diuretic ARB or ACE inhibitor Combination of CCB + ACE inhibitor or ARB + thiazide diuretic White and other non-black Patients: Younger than 60 years ARB or ACE inhibitor CCB or thiazide diuretic White and other non-black patients: 60 years and older CCB or thiazide diuretic ARB or ACE inhibitor Abbreviations : CCB - Calcium channel blocker ACE - Angiotensin converting enzyme ARB - Angiotensin receptor blocker Hypertension with other associated conditions Initial drug of choice Hypertension and diabetes ARB or ACE inhibitor Hypertension and chronic kidney disease ARB or ACE inhibitor Note: in black patients, good evidence for the renal protective effects of ACE inhibitors Hypertension and clinical coronary artery disease β-Blocker plus ARB or ACE inhibitor Hypertension and stroke history ARB or ACE inhibitor Hypertension and heart failure Regardless of blood pressure, ARB or ACE inhibitor + β-blocker + diuretic + spironolactone. A dihydropyridine CCB can be added if needed for BP control. Pneumonic: ABDS

References:

Harrison's Principles of Internal Medicine, 21st Edition, Page: 2082.
https://onlinelibrary.wiley.com/doi/10.1111/jch.12237 American Heart Association (AHA) Guidelines for Hypertension Clinical Establishments Guidelines

↑ *Back to this question in Part A*

@Neet_pg_bot

Q109: A 65-year-old male patient presented with chest pain, exertional dyspnea and syncope. He was diagnosed with a case of aortic stenosis and his chest x-ray was taken which is shown below. What is the most likely diagnosis? (Q859523)

A. Dilated aortic root

B. Widening of aortic knob

C. Widening of the vascular pedicle

D. Post stenotic dilatation of aorta

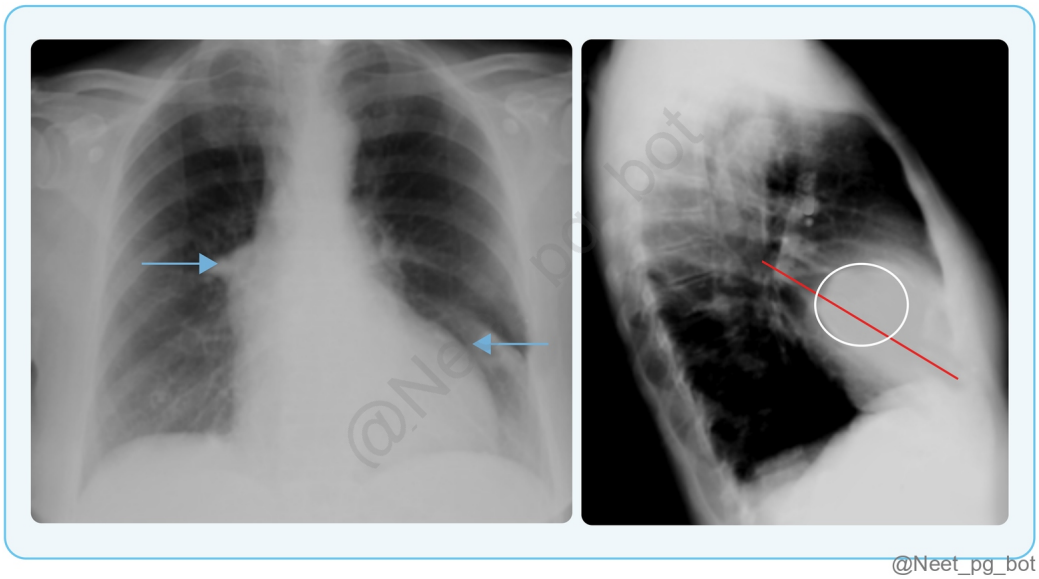

Correct Answer: D. Post stenotic dilatation of aorta

Explanation: Based on the given clinical presentation of chest pain, exertional dyspnea, and syncope, along with the diagnosis of aortic stenosis and chest x-ray findings, the most likely diagnosis in this case is post-stenotic dilatation of the aorta . Aortic Stenosis Symptom onset: AS is clinically significant when the aortic valve orifice narrows to ~1 cm^2. Severe AS can remain asymptomatic for years due to LV compensation. Symptom progression: Often develops in the sixth to eighth decades; patients with bicuspid aortic valves may experience symptoms 10-20 years earlier. Clinical Manifestations of Aortic Stenosis: Triad: Exertional dyspnea, Angina pectoris, Syncope on exertion Early symptoms : Fatigue and reduced exercise tolerance. Advanced stages: Orthopnea Paroxysmal nocturnal dyspnea Pulmonary edema. Late Findings: RV failure Systemic venous hypertension Hepatomegaly Atrial fibrillation Tricuspid regurgitation Post-Stenotic Aortic Dilatation (PSAD) Definition : Post-stenotic aortic dilatation refers to the enlargement of the aortic vessel wall distal to a stenotic or malformed aortic valve. It typically involves the ascending aorta, with a diameter greater than 4.0 cm, and is characterized by a progressive increase in size of more than 0.3 cm per year. Risk : It is considered a precursor to serious conditions like aortic dissection and rupture, which can be fatal. Aetiology : PSAD can occur in patients with aortic stenosis (AS) or aortic regurgitation (AR), and even in those with a normal aortic valve (e.g., in the case of a bicuspid aortic valve, BAV), or after aortic valve replacement (AVR). PSAD is not solely related to the severity of AS but may have a genetic basis, alongside mechanical stresses placed on the aortic wall. The bicuspid aortic valve is an independent risk factor for both AS and progressive aortic dilatation. Imaging findings: Dilatation of the aorta immediately distal to the stenosis. Normal or narrowed aortic segment proximal to stenosis. Additional findings depend on aetiology. Incorrect Options: Aortic root dilatation (Option A) is typically asymptomatic and discovered incidentally, but in rare cases, it can lead to severe complications like aortic dissection, rupture, or congestive heart failure due to aortic insufficiency. This is not the given scenario. Widening of the aortic knob (Option B) is seen in congenital heart diseases, aortic dissection, systemic hypertension, post-stenotic dilatation, etc. However, the location of the given lesion is not of the aortic knob. Widening of the vascular pedicle (Option C) : The vascular pedicle is measured between parallel lines drawn from the point at which the superior vena cava intersects the right main bronchus and a line drawn at the takeoff of the left subclavian artery from the aorta. This is not the given

radiograph.

References:

Harrison’s Principles of Internal Medicine, 21st Edition, Page: 1980,1981.

https://pmc.ncbi.nlm.nih.gov/articles/PMC1464384/

↑ *Back to this question in Part A*

@Neet_pg_bot

Q110: The device seen in the following image is? (Q859525)

A. Cardiac pacemaker

B. Chemo port device

C. Travel tract for accessory

D. Chest X-ray artefact

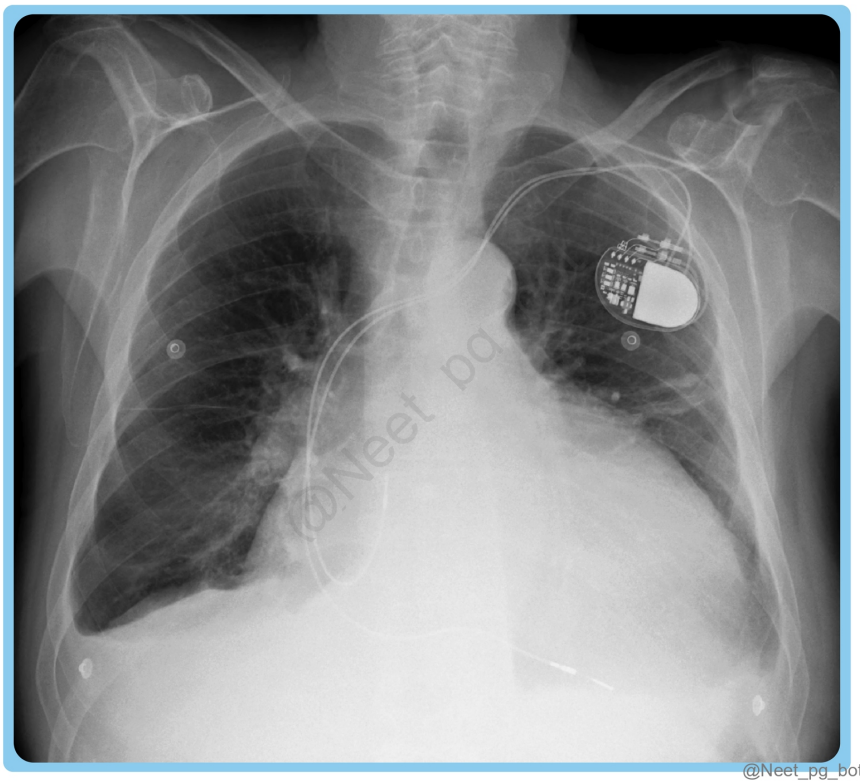

Correct Answer: A. Cardiac pacemaker

Explanation: The device shown in the x-ray is a cardiac pacemaker . Cardiac Conduction Devices (CCDs) Implantable Cardioverter Defibrillators (ICD): Function: Delivers electrical shocks to treat dysrhythmias and restore normal sinus rhythm. Types: Transvenous ICDs (T-ICD): Leads placed at the junction of the brachiocephalic vein/superior vena cava and right ventricle (RV). Can be combined with biventricular pacemakers for Cardiac Resynchronization Therapy (CRT). Subcutaneous ICDs (S-ICD): No transvenous lead insertion. The pulse generator is placed subcutaneously, and the shock is delivered via a left parasternal subcutaneous lead. Components of CCDs: Pulse Generator: Provides the electrical signals. Electrode: Sends electrical impulses to the heart. Lead Wires: Connect the electrode to the pulse generator, with different tips for attachment to the heart. Active Fixation: Leads with helical tips screw into the myocardium. Passive Fixation: Leads anchor onto heart trabeculae through fibrosis. Chest Radiography for CCD Evaluation: Preferred imaging modality for assessing CCD location, lead integrity, and complications. Two Views Required: Posterior-Anterior (PA) View : Provides a 2D view for lead integrity. Lateral (LAT) View: Essential for evaluating lead tip location and distinguishing between leads in the right or left ventricle. {{caption_text}} Purpose of Imaging: To ensure correct positioning of leads, diagnose complications, and confirm device functionality for maximal therapeutic benefit. Chemoport device (Option B) Implantable ports, commonly referred to as chemoports, totally implantable central venous access ports, or Port-A-Caths, are a type of central venous catheter designed for patients needing extended venous access. These devices provide a long-term solution for central venous access, offering a distinct advantage over peripherally inserted central catheters (PICC). {{caption_text}} Options C and D are incorrect .

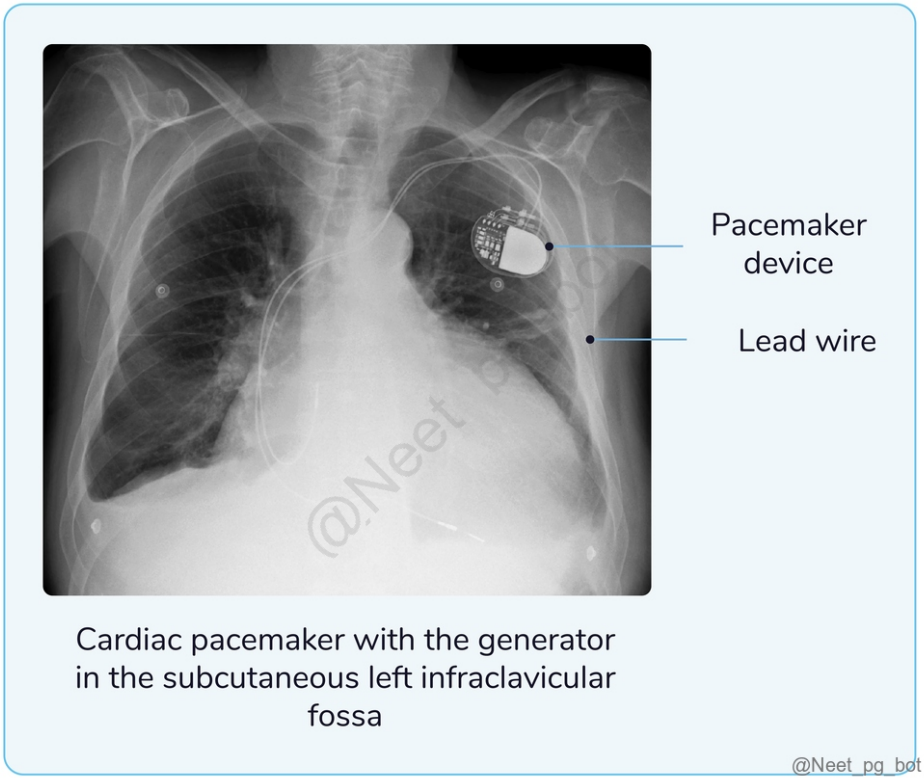

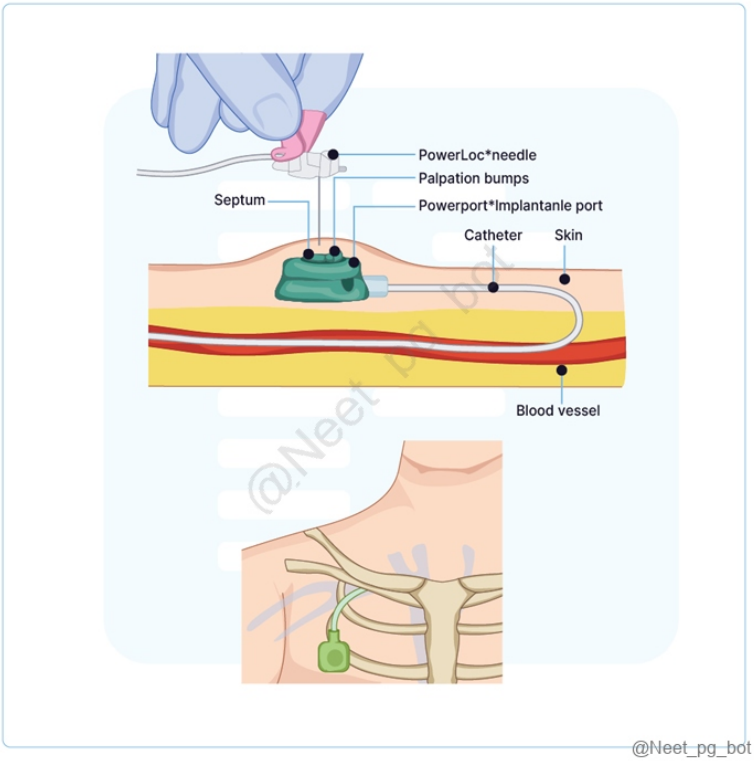

References:

https://pmc.ncbi.nlm.nih.gov/articles/PMC4286824/

https://radiopaedia.org/articles/implantable-port

↑ *Back to this question in Part A*

@Neet_pg_bot

Q111: A 55-year-old male patient came to the hospital complaining of palpitations. During the examination, a diastolic murmur is detected in the left third intercostal space, along with the presence of a pistol shot sound over the femoral arteries. What is the diagnosis here? (Q859528)

A. Aortic regurgitation

B. Aortic stenosis

C. Tricuspid regurgitation

D. Mitral regurgitation

Correct Answer: A. Aortic regurgitation

Explanation: The diastolic murmur and the pistol shot sound over the femoral artery along with palpitations signify the diagnosis of aortic regurgitation . Signs of Aortic Regurgitation Muller Sign It is a visible systolic pulsation of the uvula Rosenbach sign Systolic pulsations of the Liver Gerhardt's sign Systolic pulsations of the Spleen Quincke's sign Repeatedly alternating blushing and blanching of capillaries in the nail folds upon palpation (Capillary Pulsations) Landolphi sign Alternating systolic constriction and diastolic dilatation of pupils Traube Sign It is pistol shot sounds that are heard while auscultating over the femoral artery. Water-Hammer pulse Strong pulse that rises quickly and then drops off suddenly. Duroziez Sign It is a to-and-fro murmur heard while auscultating the femoral artery. De-Musset sign The jarring motion of the head with each heartbeat Blood Pressure Elevated systolic pressure and decreased diastolic pressure result in increased arterial pulse pressure . Atrio-ventricular malformation and Atrio-ventricular ■stula also show low diastolic BP due to continuous Korotko■ sounds. Positive Hill’s sign is an abnormal difference in BP in the upper limb and lower limb. On Palpation Heaving LV impulse is noted, which is displaced laterally and inferiorly Diastolic and Systolic Thrills were noticed at the left lower sternal border and suprasternal notch, respectively. On Auscultation Heart Sounds A2 is absent In the Bicuspid aortic valve, systolic ejection sound is present Sometimes, A4 is also heard Murmurs A decrescendo diastolic murmur , best heard when sitting up and leaning forward, is an early diastolic murmur that becomes holo-diastolic as the condition progresses to a severe stage. Musical diastolic murmur is aortic cusp fluttering in the regurgitant flow. Mid-diastolic murmur Austin Flint murmur is a soft, low-pitched, mid- to end-diastolic murmur caused by mitral valve displacement due to AR. Ejection systolic murmur is commonly heard in AR along with AS . Incorrect Options: Aortic stenosis (Option B) presents with a midsystolic ejection murmur at the upper sternal border. Tricuspid regurgitation (Option C) presents with a holosystolic murmur at the lower left sternal border. Mitral regurgitation (Option D) presents with a systolic murmur at the apex of the heart with radiation to the left axilla.

References:

Harrison’s Principles of Internal Medicine, 21st Edition, Page 1988

BMJ JournalLink

NIH websiteLink

↑ *Back to this question in Part A*

@Neet_pg_bot

Q112: A person with dyspnea has a slight limitation in physical activity and doing ordinary activity causes symptoms but he is asymptomatic at rest. To which class does he belong, based on the New York Heart Association functional classification? (Q859529)

A. Class I

B. Class II

C. Class III

D. Class IV

Correct Answer: B. Class II

Explanation: The given scenario belongs to Class II in the New York Heart Association classification for heart failure. New York Heart Association (NYHA) Classification Class Symptoms I (Option A) No limitation of physical activity. No symptoms with ordinary exertion (e.g. shortness of breath when walking, climbing stairs etc). II Slight limitation of physical activity. Ordinary activity causes symptoms. III (Option C) Marked limitation of physical activity. Less than ordinary activity causes symptoms. Asymptomatic at rest. IV (Option D) Inability to carry out any physical activity without discomfort. Symptoms at rest.

References:

Harrison's Principles of Internal Medicine, 21st Edition, Page: 1798.

↑ *Back to this question in Part A*

@Neet_pg_bot

Q113: A 56-year-old woman who had a heart attack 2 years ago is currently experiencing a cough and difficulty breathing while walking short distances. Physical examination revealed dullness upon percussion and reduced breath sounds on the right side. A chest x-ray indicated the presence of moderate pleural effusion. Thoracocentesis, guided by ultrasound, was performed and the laboratory results are provided below. Pleural fluid findings: Appearance: turbid pH: 7.1 Protein: 3.2 g/dL Lactate dehydrogenase: 80 U/L (normal serum LDH- 50-150 U/L) Pleural fluid protein/serum protein ratio: 0.34 Pleural fluid LDH /serum LDH: 0.3 Glucose: 54 mg/dL WBC count: 4000 cells/µL with >50% lymphocytes Adenosine deaminase: 30 U/L AFB smear microscopy: Negative Gram staining and microscopy: No organisms, no pus cells (Q859532)

A. Parapneumonic pleural effusion

B. Malignant pleural effusion

C. Congestive heart failure

D. Tubercular pleural effusion

Correct Answer: C. Congestive heart failure

Explanation: The above case with the given clinical findings is suggestive of the diagnosis of congestive heart failure . The effusion is transudative in nature here according to Light’s criteria. Congestive Heart Failure: Clinical features Cardiac output decreased Stroke volume decreased Heart rate increased Increased sympathetic drive leading to palpitations and diaphoresis Orthopnea Paroxysmal nocturnal dyspnea Clinical Features of Left-Sided vs. Right-Sided Congestive Heart Failure (CHF) Left-Sided Heart Failure Right-Sided Heart Failure Causes : Ischemic heart disease (myocardial infarction). Hypertension Dilated cardiomyopathy. Aortic or mitral valve disease. Causes : Left-sided heart failure (most common cause). Chronic lung diseases (COPD, pulmonary hypertension). Pulmonary embolism. Right ventricular infarction. In left-sided heart failure, the left ventricle cannot effectively pump blood to the body, leading to a backup of blood into the lungs. Clinical features: This primarily results in pulmonary symptoms. Dyspnea Exertional dyspnea). Orthopnea Paroxysmal nocturnal dyspnea Pulmonary Congestion: Crackles (rales) heard on auscultation due to fluid in the alveoli. Cough Wheezing (cardiac asthma). Fatigue and Weakness Decreased Exercise Tolerance Limited physical activity due to breathlessness and fatigue. S3 Gallop Cool Extremities: Reduced cardiac output may cause poor peripheral circulation, leading to cold, pale skin. In right-sided heart failure, the right ventricle fails to pump blood effectively into the pulmonary circulation, leading to systemic venous congestion. It is often secondary to left-sided heart failure or conditions affecting the lungs (cor pulmonale). Clinical Features: Peripheral Edema Jugular Venous Distension (JVD) Hepatomegaly B/L pitting pedal oedema Kussmaul sign: JVP elevation on inspiration Ascites Nocturia Weight Gain Anorexia and Nausea Pleural fluid Analysis Light's Criteria Differentiates transudative from exudative pleural effusions based on LDH and protein levels in pleural fluid. An exudative pleural effusion meets at least one of the following: Pleural fluid protein/serum protein > 0.5 Pleural fluid LDH/serum LDH > 0.6 Pleural fluid LDH exceeds two-thirds of the normal upper limit for serum. ~25% of transudates may be misidentified as exudates. If exudative criteria are met but a transudative condition is suspected, measure protein difference; if >31 g/L (3.1 g/dL), likely transudative. Parapneumonic pleural effusion (Option A) has increased in WBCs, especially neutrophils and the appearance is cloudy. Malignant pleural effusion (Option B) and tubercular pleural effusion (Option D) are exudative in nature

References:

Harrison’s Principles of Internal Medicine 21st edition Page 2198, 2199.

://pmc.ncbi.nlm.nih.gov/articles/PMC4753987/#sec4

CHF

↑ *Back to this question in Part A*

@Neet_pg_bot

Q114: What is the most likely diagnosis for a 45-year-old man who experiences chest pain and difficulty breathing that worsens when lying down but improves when sitting upright, and has muffled heart sounds during examination? (Q859534)

A. Pericardial effusion

B. Tetralogy of Fallot

C. Transposition of great arteries

D. Pulmonary hypertension

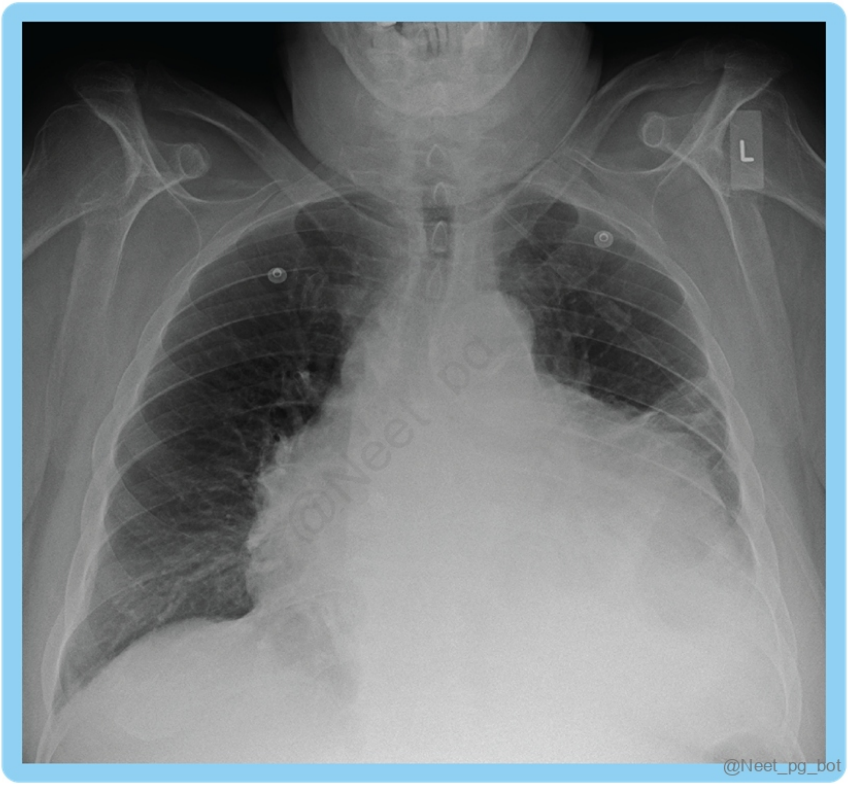

Correct Answer: A. Pericardial effusion

Explanation: The above presentation of breathlessness on lying down and it being relieved on sitting, and the X-ray given which shows an enlarged cardiac silhouette is suggestive of a probable diagnosis of pericardial effusion. Pericardial effusion: Pericardial effusion can lead to cardiac tamponade if rapid. Faint heart sounds and a large cardiac silhouette on X-ray. Chest X-ray showing waterbottle configuration in Pericardial effusion {{caption_text}} Electrical alternans is a classic ECG finding in pericardial effusion, particularly when it leads to cardiac tamponade. It manifests as beat-to-beat variations in the amplitude of the QRS complexes, reflecting the heart's movement within the fluid-filled pericardial space. This finding is indicative of significant fluid accumulation and increased intrapericardial pressure, which impedes the heart's ability to fill properly during diastole. {{caption_text}} ECG showing Electrical alternans White arrows showing variations in the amplitude of QRS complexes Incorrect Options: Tetralogy of Fallot (Option B) shows a boot-shaped heart on an x-ray. Transposition of great arteries (Option C) shows an egg-on-string appearance on x-ray. Pulmonary hypertension (Option D) shows a pruned tree appearance of the pulmonary vasculature.

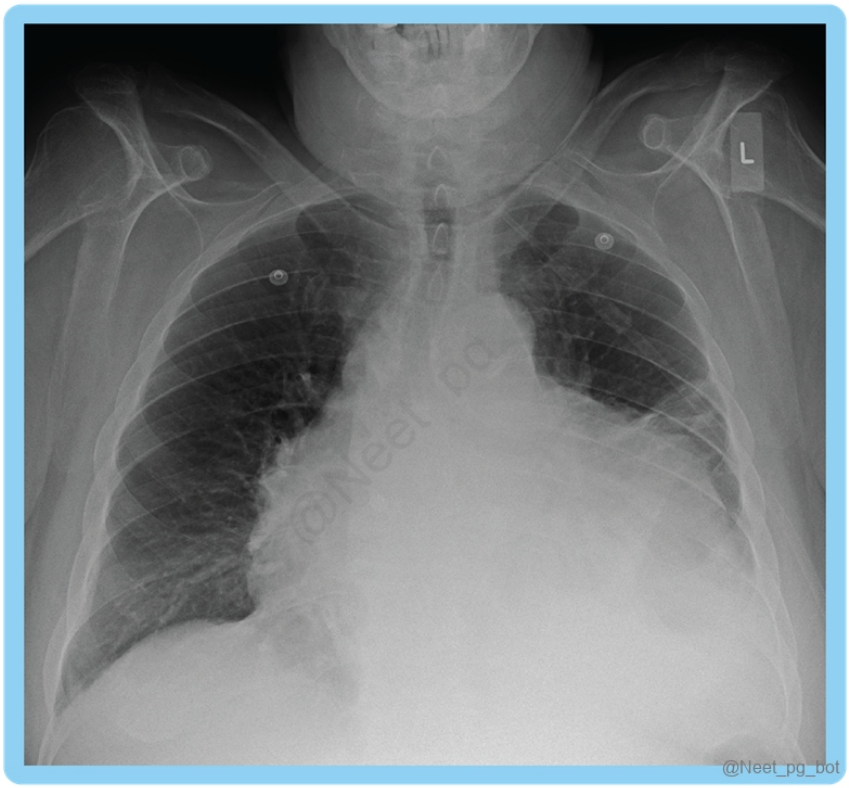



References:

Harrison’s Principles of Internal Medicine, 21st Edition, Page: 1830, 1853, 2020, 2028.

↑ *Back to this question in Part A*

@Neet_pg_bot

Q115: A 62-year-old man with a history of coronary artery disease presents with sudden onset palpitations, dizziness, and mild chest discomfort. His blood pressure is 90/60 mmHg and ECG is given below. What is the most likely diagnosis? (Q859535)

A. Atrial fibrillation

B. Atrial flutter

C. Ventricular tachycardia

D. Ventricular fibrillation

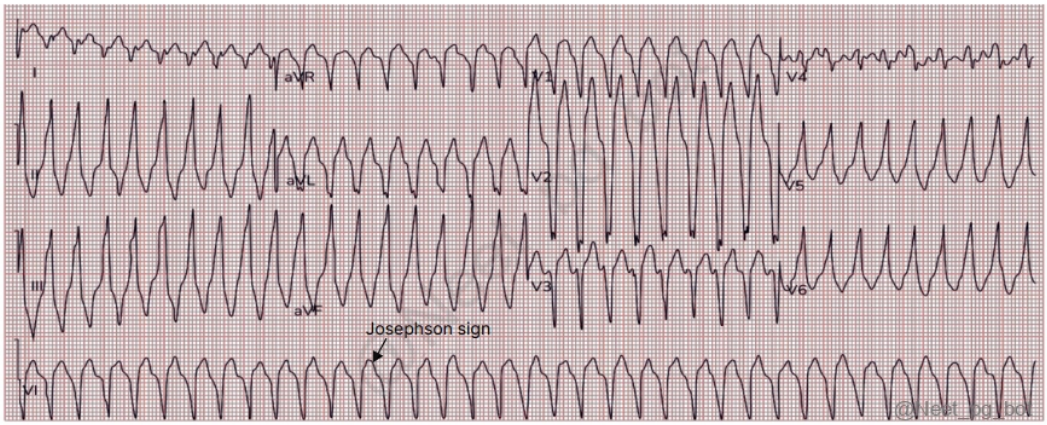

Correct Answer: C. Ventricular tachycardia

Explanation: ECG shows broad QRS tachycardia (>100/min) with classic VT features such as wide complexes , extreme axis deviation , and possible capture/fusion beats , strongly suggesting ventricular tachycardia Key Features of Ventricular Tachycardia Tachycardia: HR > 100/min (short R-R interval) Broad QRS complexes due to slower myocyte-to-myocyte conduction Josephson sign: Notch on the downslope of the S-wave Capture beats: Normal QRS amidst VT Fusion beats: Mixed SVT + VT impulse → intermediate QRS Extreme axis deviation Treatment of VT Pulseless VT: Defibrillation (unsynchronized shock) Stable VT: IV Amiodarone Post-MI VT (DOC): Amiodarone If BP unrecordable: Defibrillation Cardioversion: Synchronized DC shock Defibrillation: Unsynchronized DC shock Atrial fibrillation (Option A): Irregularly irregular rhythm, no P waves, variable R-R, usually narrow QRS. Not compatible with a regular wide-complex tachycardia. Atrial flutter (Option B): Saw-tooth waves, atrial rate ~300/min, usually narrow QRS. Ventricular fibrillation (Option D): Completely chaotic rhythm, no QRS, no pulse. Patient would be pulseless, unlike in this case.

References:

Harrison’s Principles of Internal Medicine, 21st Edition, Page: 1899-1902.

Davidson’s Principles and Practice of Medicine, 24th Edition, Page: 470.

Atrial Flutter - StatPearls - NCBI Bookshelf

↑ *Back to this question in Part A*

@Neet_pg_bot

Q116: Based on the ECG given below, what is the most likely diagnosis? (Q859537)

A. Normal ECG

B. Ventricular fibrillation

C. Ventricular tachycardia

D. Misplaced leads

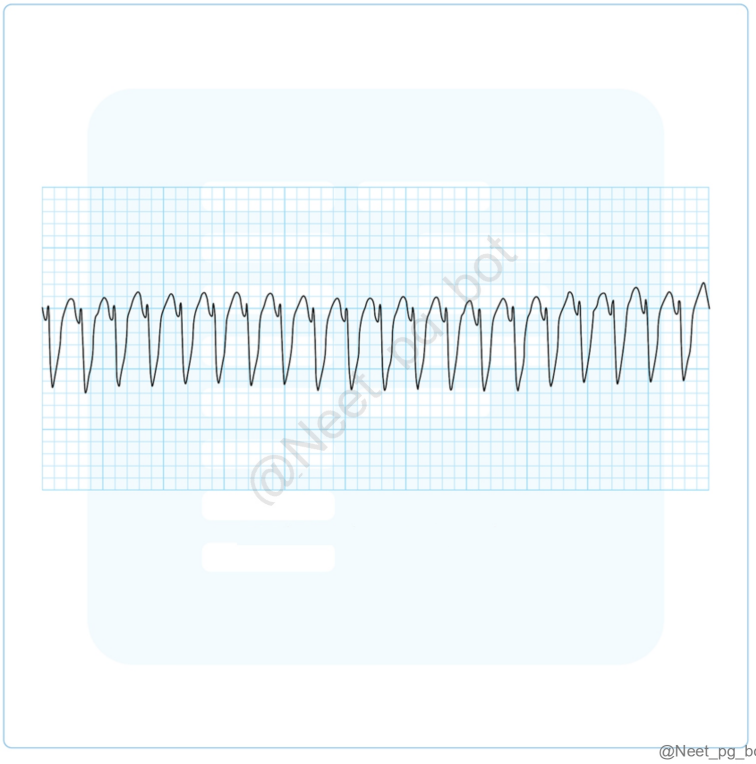

Correct Answer: C. Ventricular tachycardia

Explanation: The given ECG shows ventricular tachycardia with wide, regular QRS complexes and a rate typically over 100 bpm. Ventricular tachycardia Pathology: VT is defined as three or more consecutive premature ventricular contractions (PVCs) with a heart rate of over 100 bpm. It can be either monomorphic (all QRS complexes appear similar) or polymorphic (QRS complexes vary in shape). Monomorphic VT is often related to a

reentry circuit around a myocardial scar, typically after myocardial infarction, while polymorphic VT, especially Torsades de Pointes, is related to prolonged QT intervals, ischemia, or electrolyte imbalances. ECG Findings: Monomorphic VT : Wide QRS complexes (>120 ms), regular rhythm, and consistent morphology across leads. The QRS axis may vary depending on the site of origin (e.g., LBBB or RBBB-like morphology). {{caption_text}} Polymorphic VT : Continuously changing QRS morphology, often associated with prolonged QT intervals (in Torsades de Pointes). {{caption_text}} Treatment: Stable Monomorphic VT : Intravenous procainamide or amiodarone can be used. Unstable Monomorphic VT : Immediate synchronized cardioversion is required. Polymorphic VT (Torsades de Pointes) : IV magnesium sulfate and correction of underlying electrolyte abnormalities (e.g., hypokalemia) are crucial, along with discontinuation of QT-prolonging drugs. Incorrect Options: The above is not a normal ECG (Option A) as it has tachycardia, absent P wave, and vast QRS complexes. Ventricular fibrillation (Option B) usually has no identifiable QRS complex hence the given ECG does not show ventricular fibrillation. Misplaced leads (Option D) do not produce the given ECG.

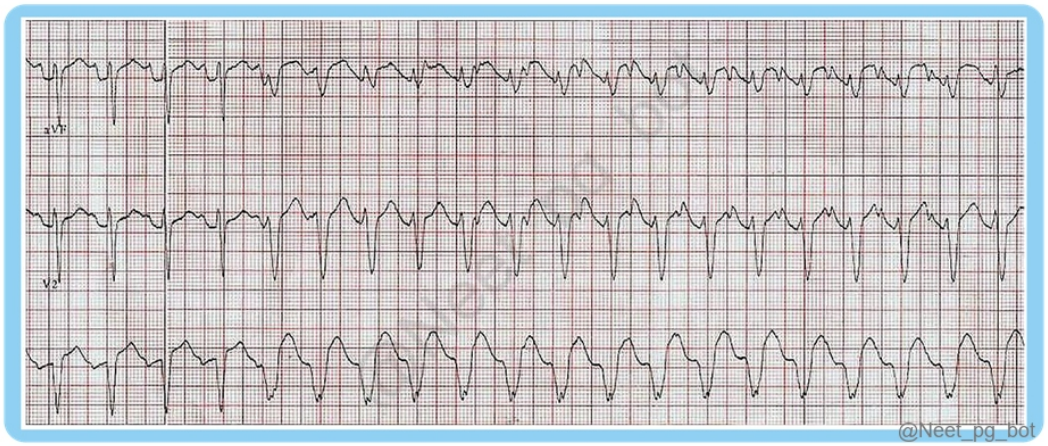

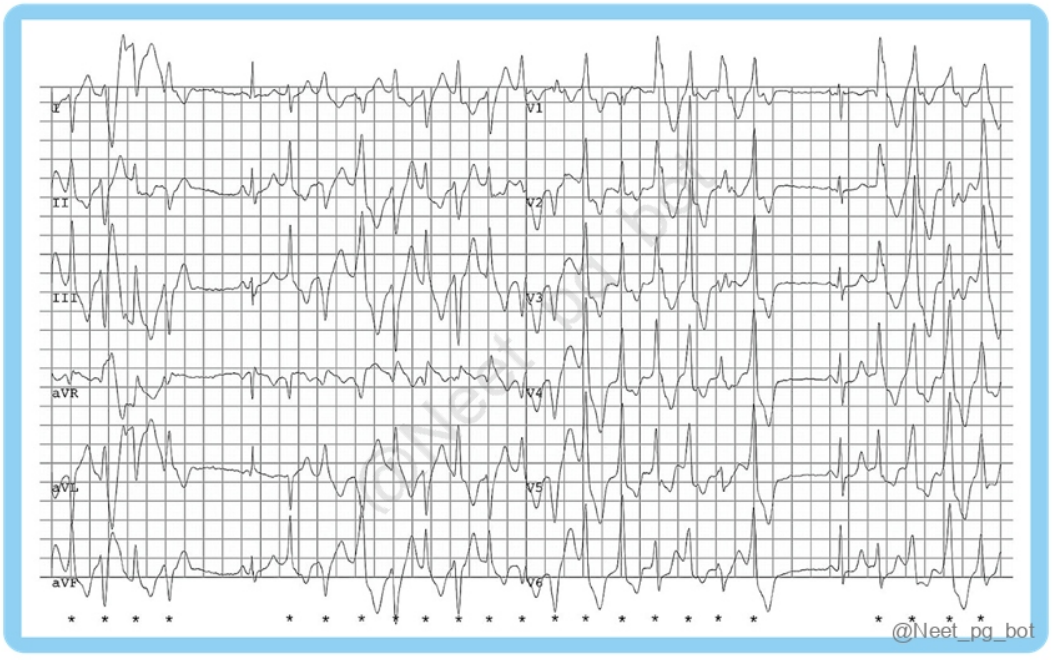

References:

Goldberger’s Clinical Electrocardiography, A Simplified Approach, 9th Edition, Page: 167.

↑ *Back to this question in Part A*

@Neet_pg_bot

Q117: HV interval in the below given His bundle electrogram is for conduction: (Q859559)

A. Through the His-Purkinje system

B. From AV node to bundle of His

C. Purkinje to ventricular fibres

D. From a bundle of His and bundle branches to ventricles

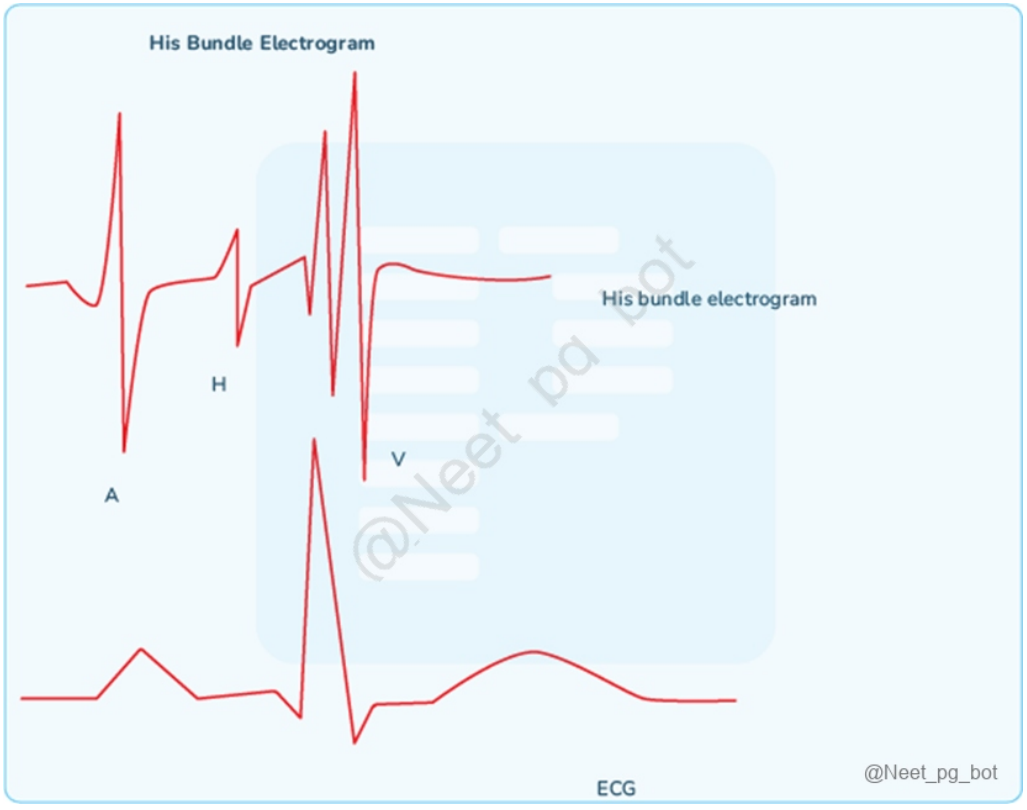

Correct Answer: D. From a bundle of His and bundle branches to ventricles

Explanation: The HV interval represents the time it takes for electrical conduction to occur from the His bundle and bundle branches to the ventricles of the heart. A typical His bundle electrogram includes the following components: A: Atrial deflection H: His deflection QRS: Ventricular depolarization The intervals measured are as follows: P-H: The interval from the start of the P wave (either from a standard lead ECG or high atrial lead) to the initial rapid deflection of the His bundle spike . (Option B) A-H: The interval from the onset of the atrial deflection on the His bundle electrogram (low RA) to the His bundle deflection . (Option A) H-V : The interval from the first

rapid deflection of the His bundle to the onset of ventricular depolarization, measured either from the His bundle electrogram or standard leads. Option C is incorrect.

References:

https://www.ahajournals.org/doi/pdf/10.1161/01.cir.47.4.897

↑ *Back to this question in Part A*

@Neet_pg_bot

Q118: A 50-year-old man presents with recurrent episodes of chest pain which is seen only on exertion or exercise and lasts 2-5 minutes. He was assessed and was diagnosed with a case of stable angina however his BP was consistently elevated. What is the most appropriate antihypertensive for this patient (Q859560)

A. Atenolol

B. Thiazides

C. Enalapril

D. Amlodipine

Correct Answer: D. Amlodipine

Explanation: The most appropriate antihypertensive for a patient with stable angina and consistently elevated blood pressure would be Amlodipine . It is particularly beneficial in patients with stable angina, as it can improve coronary blood flow by reducing vasospasm and decreasing myocardial oxygen demand. Additionally, amlodipine has a favourable effect on blood pressure control, which makes it suitable for patients with both stable angina and hypertension. Medical management of stable angina Medication Class Function/Mechanism Indications Nitrates Sublingual nitroglycerin (0.4 or 0.6 mg) Long-acting forms (oral, transdermal) Systemic venodilation Reduces LV end-diastolic volume and pressure Releases nitric oxide (NO) to relax vascular smooth muscle Angina relief Preemptive use before activities Improves exercise tolerance Beta-Blocker (Option A) Reduces heart rate, arterial pressure, and myocardial contractility Improves survival post-MI Angina relief Reduces mortality and reinfarction rates Calcium Channel Blockers Coronary vasodilators Reduces myocardial oxygen demand and arterial pressure Dihydropyridines (e.g., amlodipine) and non-dihydropyridines (e.g., verapamil) Angina treatment when beta-blockers are ineffective Variant angina Antiplatelet Drugs Aspirin : inhibits platelet activation Clopidogrel 75mg : blocks platelet aggregation Reduces coronary events in high-risk populations Stent placement Thiazide (Option B) diuretics are a class of medications used to treat hypertension. They help reduce blood pressure by promoting diuresis and decreasing fluid volume. However, they may not be the most appropriate choice in this case since the patient already has stable angina, and thiazides are not specifically indicated for the treatment of angina. Enalapril (Option C) is an angiotensin-converting enzyme (ACE) inhibitor that is commonly used in the management of hypertension and are effective antihypertensive agent, they may not be the initial choice in this case, considering the patient's primary symptom of stable angina

References:

Harrison’s Principles of Internal Medicine 21st edition Page: 2041-2045.

↑ *Back to this question in Part A*

@Neet_pg_bot

Q119: A postoperative cardiac surgery patient developed sudden hypotension, raised central venous pressure, and pulsus paradoxus at the 4 th postoperative hour. The most probable diagnosis is. (Q859565)

A. Ventricular dysfunction

B. Cardiac tamponade

C. CHF

D. Excessive mediastinal effusion

Correct Answer: B. Cardiac tamponade

Explanation: Based on the symptoms described in the postoperative cardiac surgical patient, the most probable diagnosis is cardiac tamponade which is a medical emergency characterized by the accumulation of fluid or blood in the pericardial sac, which leads to compression of the heart and impaired cardiac function. Cardiac Tamponade Definition A condition where the cardiac chambers are compressed by a tense pericardial effusion, limiting cardiac inflow. Fluid accumulation of as little as 200 ml to upwards of 2 L may lead to cardiac tamponade development. Clinical Features Beck's triad Jugular Venous Distension : Due to increased central venous pressure. Prominent x descent and an absent y descent. Hypotension : Resulting from impaired cardiac output. Muffled Heart Sounds : Caused by fluid accumulation in the pericardial space, dampening heart sounds. Other features Pulsus paradoxus : A drop in systolic BP during inspiration, greater than 10 mm Hg. Causes of Pulsus paradoxus: Lung Conditions: Acute asthma, COPD, tension pneumothorax, pleural effusion, pulmonary embolism. Heart Conditions: Cardiac tamponade, constrictive pericarditis. Low-Pressure Cardiac Tamponade Definition This occurs when lower pericardial pressure leads to tamponade, often in cases of intravascular fluid depletion (e.g., hypovolemia). Features Jugular Venous Distension: Often absent Pulsus Paradoxus: Rare Requires a high degree of suspicion due to the absence of typical signs like jugular venous distension and pulsus paradoxus. Incorrect Options: While ventricular dysfunction (Option A) can cause hypotension and cardiac symptoms, it does not typically present with raised central venous pressure or pulsus paradoxus. Additionally, the sudden onset of symptoms in this case suggests a more acute problem like cardiac tamponade rather than chronic ventricular dysfunction. CHF (Option C) can cause fluid retention, leading to increased venous pressure and symptoms such as dyspnea and oedema. However, it does not typically present with sudden hypotension, raised central venous pressure, or pulsus paradoxus. Excessive mediastinal effusion (Option D) can potentially cause compression of the heart and lead to symptoms similar to cardiac tamponade. However, the specific mention of raised central venous pressure and pulsus paradoxus points more towards cardiac tamponade as the likely diagnosis.

References:

Harrison’s Principles of Internal Medicine, 21st Edition, Page: 1853, 2021, 2022.

Low-Pressure Cardiac Tamponade | Circulation

Fluid amount

Pulsus paradoxus

↑ *Back to this question in Part A*

@Neet_pg_bot

Q120: A male patient in his youth comes to the clinic complaining of a persistent high fever over the past 5 days. During the examination of his hands, painless lesions are observed, and a new regurgitant murmur is detected. The echocardiogram reveals the existence of a mass on the mitral valve. Based on these findings, which of the following abdominal findings would be expected in this case? (Q859791)

A. Ascites

B. Splenomegaly

C. Hepatomegaly

D. Portal hypertension



Correct Answer: B. Splenomegaly

Explanation: The presence of high-grade fever, painless lesions on the hands (Janeway lesions), and a new regurgitant murmur suggests the possibility of infective endocarditis. The most likely abdomen finding in this case would be splenomegaly . Acute Bacterial Endocarditis Aggressive course compared to subacute endocarditis. Causative organisms : S. aureus (Most common cause) (including MRSA), S. pneumoniae, L. monocytogenes, Haemophilus species, streptococci (groups A, B, G). Risk factors : Comorbid conditions like malignancy, diabetes mellitus, IV drug use, or alcoholism. Presentation : Fever, fatigue, and malaise within <2 weeks of infection. Changing heart murmur, potential congestive heart failure. Possible signs: Janeway lesions (hemorrhagic macules on palms/soles), petechiae Roth's spots Splinter haemorrhages Splenomegaly (rare). (Option B) Peripheral manifestations : Janeway lesions: Painless, erythematous macules on palms and soles. Related to septic microembolization, {{caption_text}} Osler's nodes: Small painful pea-shaped nodules located at the tips of fingers and toes (Immune complex-mediated). {{caption_text}} Subungual haemorrhages/Splinter haemorrhages; More common in acute S. aureus IE. Haemorrhages below nails- multiple linear lesions, initially red then turning brown or black. {{caption_text}} Roth spots: Pale-centred retinal haemorrhages that are seen in the fundus examination {{caption_text}} Arterial emboli : Occur in up to 50% of patients, often preceding IE diagnosis, causing organ dysfunction (e.g., stroke, kidney, spleen , or limb ischemia). Neurologic complications : Strokes complicate 15-35% of cases; also include encephalopathy, seizures, meningitis, intracranial haemorrhage, mycotic aneurysms, and brain abscesses. Renal complications : Hypocomplementemic glomerulonephritis due to immune complex deposition, often improving with antimicrobial therapy; renal infarcts may cause flank pain and hematuria. Ascites (Option A) occurs due to portal hypertension, chronic liver disease, nephrotic syndrome, or severe right-sided heart failure , and it is not a typical abdominal manifestation of infective endocarditis. Hepatomegaly (Option C) is usually seen in congestive hepatopathy due to right-sided heart failure, viral hepatitis, or infiltrative liver diseases , whereas infective endocarditis primarily produces splenic enlargement rather than liver enlargement . Portal hypertension (Option D) results from increased resistance to portal blood

flow , most commonly due to cirrhosis or portal vein obstruction , and is not associated with infective endocarditis
.



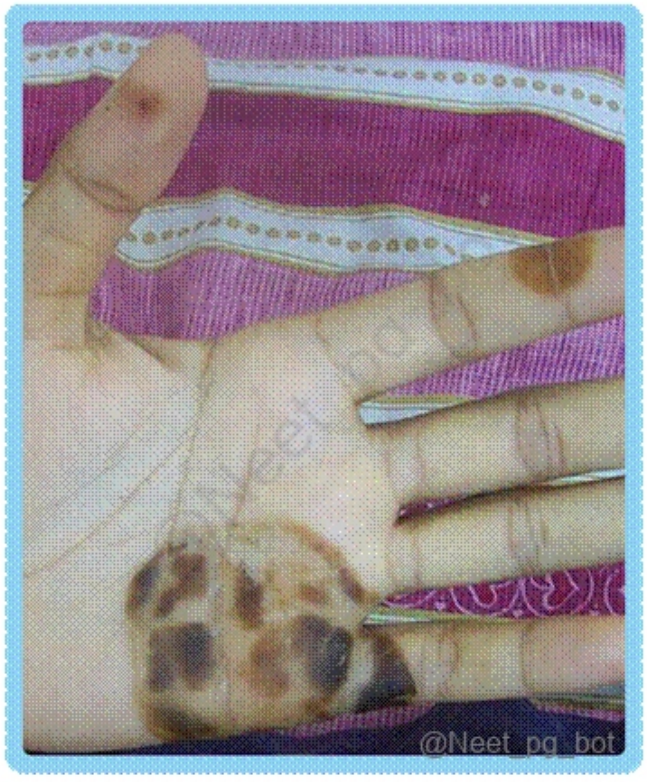



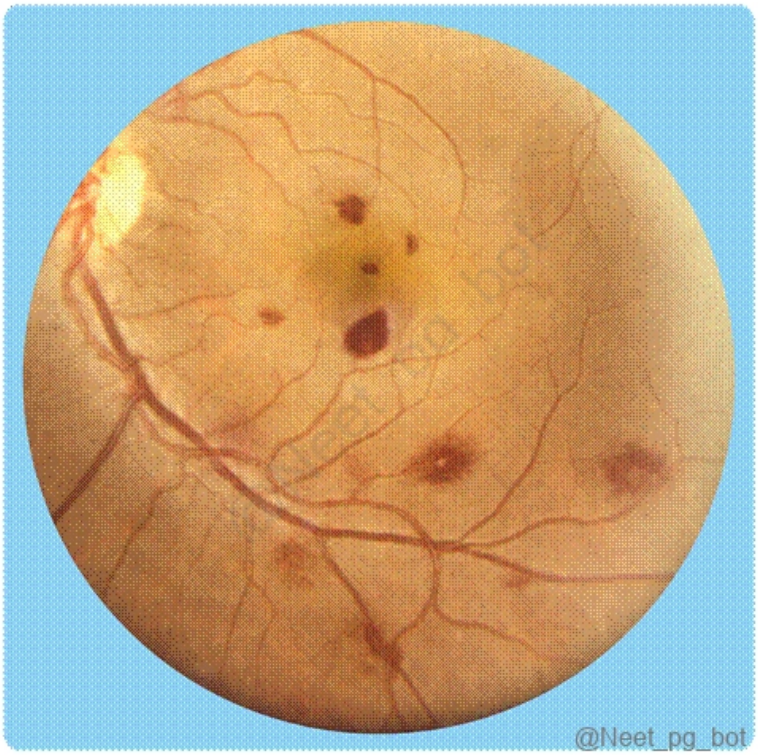

References:

Harrison’s Principles of Internal Medicine, 21st Edition, Page: 979, 1189, 1024, 1025.

www.healthline.com/health/subacute-bacterial-endocarditis#outlook

www.msdmanuals.com/home/heart-and-blood-vessel-disorders/endocarditis/infective-endocarditis

www.researchgate.net/publication/258857573_Splinter_haemorrhages_Osler's_nodes_Janeway_lesions_and_Roth_spots_the_peripheral_stigmata_of_endocarditis

↑ *Back to this question in Part A*

@Neet_pg_bot

Q121: Which of the following leads to a continuous murmur? (Q859800)

A. Peripheral Pulmonic stenosis

B. Severe Pulmonary artery hypertension

C. Type A aortic dissection

D. Rupture of cardiac chamber

Correct Answer: A. Peripheral Pulmonic stenosis

Explanation: Peripheral Pulmonic stenosis produces a characteristic continuous murmur due to persistent turbulent blood flow through narrowed pulmonary artery branches. This congenital condition creates turbulence in blood flow that begins in systole, peaks near the second heart sound, and continues through diastole. The continuous nature of the murmur occurs because the pressure gradient between the pulmonary artery and its branches remains throughout the cardiac cycle, maintaining constant turbulent flow. Continuous murmur Definition Murmur that persists across systole and diastole Begins in at S1, continues through second heart sound (S2) and tapers at next S1 Causes Patent Ductus Arteriosus (PDA) Peripheral Pulmonic stenosis Valsalva aneurysm Aortopulmonary window Great vessel arteriovenous fistula Coronary to pulmonic fistula Severe Pulmonary artery hypertension (Option B) typically causes leakage of blood into the RV during the diastole due to the high pressure in the pulmonary arteries, characteristically producing a diastolic murmur. Type A aortic dissection (Option C) is a medical emergency and the presentation mainly accompanies classical signs like blood pressure discrepancies between the upper extremities, pulse deficits & hypotension. Murmur is rarely seen and if seen its mostly diastolic murmur. Rupture of cardiac chamber (Option D) is a medical emergency. The hemodynamic compromise would be severe and acute, leading to cardiogenic shock and unrecordable BP. No murmur will be heard.

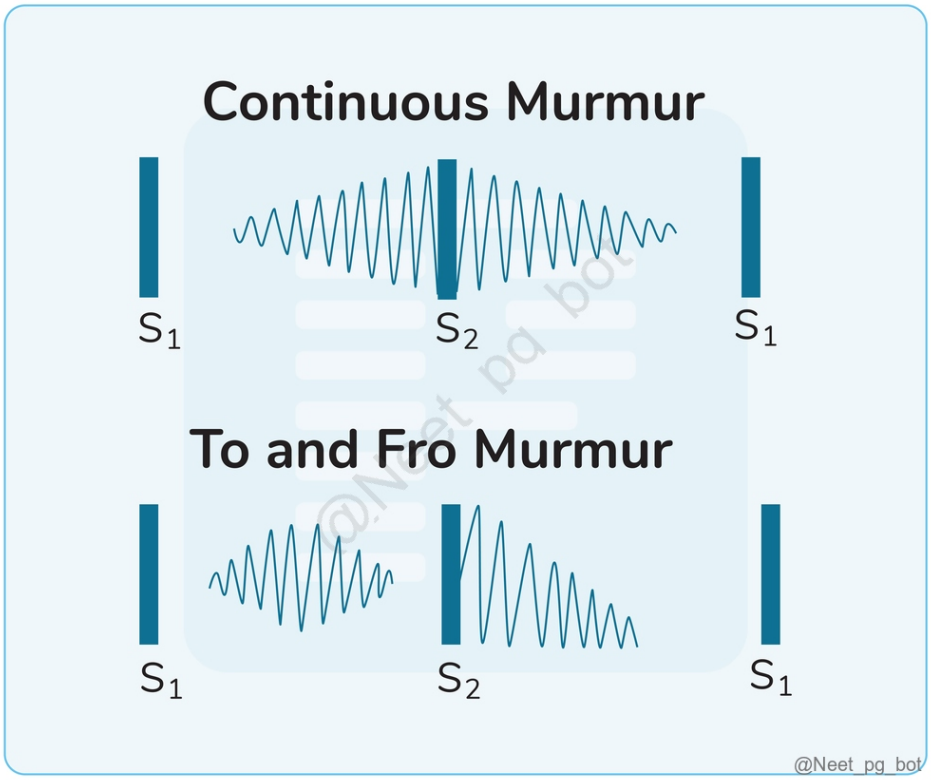

References:

Harrison's Principles of Internal Medicine, 21st Edition, Page 281-286, 1821-1823, 1969

↑ *Back to this question in Part A*

@Neet_pg_bot

Q122: A hypertensive patient who is non-compliant with medication presents with sudden-onset breathlessness. A chest X-ray reveals findings consistent with pulmonary edema. How will you manage this patient? (Q855894)

A. Intravenous salbutamol

B. Intravenous nitroglycerin

C. Nebulization with salbutamol

D. Oxygen and antibiotics

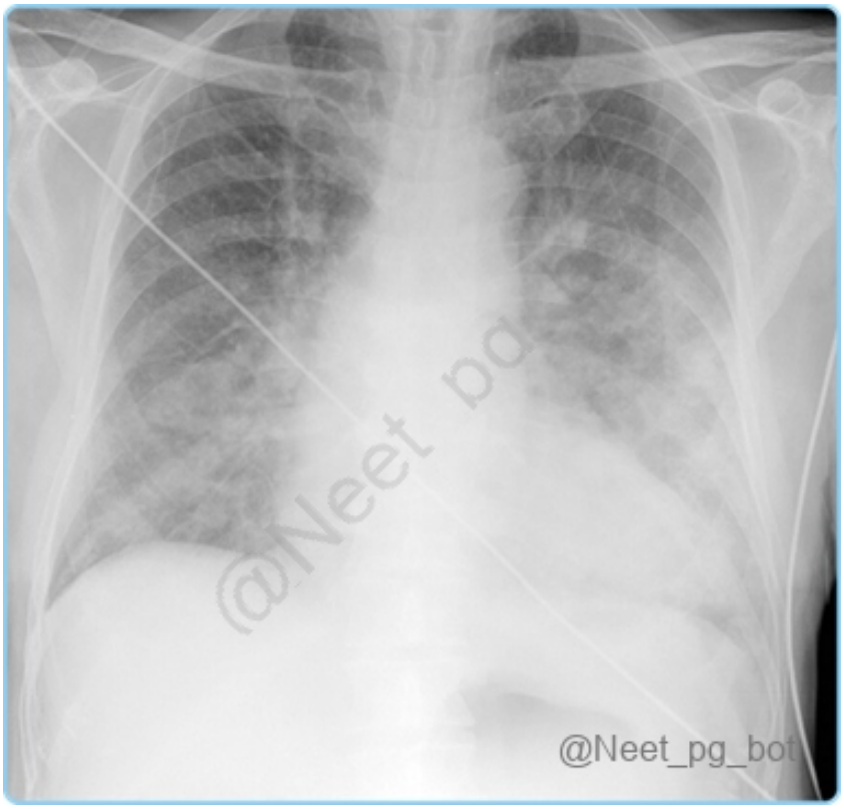

Correct Answer: B. Intravenous nitroglycerin

Explanation: The clinical scenario suggests acute cardiogenic pulmonary edema (ACPE). Precipitating factors: Severe hypertension Acute myocardial infarction Chronic heart failure exacerbation Medication non-compliance Excessive salt intake Symptoms: Sudden severe dyspnea Pink frothy sputum Cyanosis Rales and rhonchi heard on auscultation Chest X-ray findings: Interstitial edema Alveolar edema in a butterfly pattern Possible cardiomegaly Management of Cardiogenic Pulmonary Edema: IV Nitroglycerin Mechanism: Reduces preload and afterload by causing venodilation, lowering pulmonary venous pressure. Indication: Rapid relief of pulmonary edema symptoms without causing hypotension. Administration: Start with sublingual nitroglycerin; escalate to intravenous if symptoms persist. Oxygen Therapy: Maintain oxygen saturation >92%. Use non-invasive positive pressure ventilation (NIPPV) or intubation if oxygenation fails. Diuretics (e.g., Furosemide): Used to remove excess fluid but only after stabilizing the patient's hemodynamics. Morphine: Provides venodilation and reduces anxiety, but use is controversial due to the risk of respiratory depression. Positioning: Sitting upright with legs dependent to reduce venous return in patients without hypotension. Intravenous salbutamol (Option A): Salbutamol is a β2-agonist used for acute severe asthma or hyperkalemia, not pulmonary edema. Nebulization with salbutamol (Option C): Similar to Option A, it is used in asthma management, not for ACPE. Oxygen and antibiotics (Option D): Oxygen therapy is indicated, but antibiotics are not used in cardiogenic pulmonary edema unless there is an underlying infection like pneumonia.

References:

Harrison's Principles of Internal Medicine, 21st Edition, Page: 355, 1930, 1931, 1932, 1935, 1936, 2155, 2255, 2256.

Goodman & Gillman's The Pharmacological Basis of Therapeutics, 13th Edition, Page: 731, 732.

AHA Journals

PubMed Article

↑ *Back to this question in Part A*

@Neet_pg_bot

Q123: A patient on antidepressants presents with hypotension. An ECG reveals wide QRS complexes and right axis deviation. How will you manage this patient? (Q855897)

A. Antiarrhythmics

B. Intravenous sodium bicarbonate

C. Propranolol

D. Phenytoin

Correct Answer: B. Intravenous sodium bicarbonate

Explanation: The clinical scenario indicates tricyclic antidepressant (TCA) toxicity, characterized by: Hypotension Wide QRS complexes Right axis deviation QT prolongation on ECG TCAs block sodium channels in the myocardium, leading to arrhythmias and conduction delays. Side effects of Tricyclic antidepressants: Mechanism of side effect Side effect H1 receptor blockade Sedation, weight gain Anticholinergic action on muscarinic receptors Hyperthermia Dry eyes/mouth Mydriasis (C/I in glaucoma) Urinary retention Constipation Tachycardia Increase in serotonin in the brain Seizure threshold reduction Alpha 1 adrenergic receptor antagonism Postural hypotension Sodium channel block Arrhythmia/ QT prolongation Bradycardia in heart block due to overdose Management of TCA Toxicity: Intravenous Sodium Bicarbonate Mechanism: Reverses the sodium channel blockade by alkalinizing the serum, stabilizing myocardial membranes. Indication: For QRS widening (>100 ms), hypotension, or arrhythmias due to TCA toxicity. Dose: Bolus of 50–100 mEq; repeat as necessary until QRS duration normalizes. Activated Charcoal: If ingestion is recent (within 2 hours), it helps reduce absorption of the drug. Other Measures for Complications: Seizures: Benzodiazepines are preferred. Polymorphic ventricular tachycardia (Torsades de Pointes): Use intravenous magnesium sulfate. Antiarrhythmics (Option A): Class IA, IC, and III antiarrhythmics (e.g., quinidine, flecainide, amiodarone) are contraindicated as they exacerbate sodium channel blockade. Propranolol (Option C): A beta-blocker, it is not effective in treating TCA-induced arrhythmias or QRS widening. It can worsen hypotension and bradycardia caused by TCA toxicity. Phenytoin (Option D): An antiepileptic drug, it has no role in TCA toxicity. It can displace TCAs from protein-binding sites, worsening toxicity symptoms.

References:

Harrison's Principles of Internal Medicine, 21st Edition, Page: 1924, 3587.

Goodman & Gillman's The Pharmacological Basis of Therapeutics, 13th Edition, Page: 62, 158, 271, 273, 276, 304, 307, 570, 571.

K.D. Tripathi - Essentials of Medical Pharmacology, 8th Edition, Page: 180, 483, 485, 487.

https://www.ncbi.nlm.nih.gov/books/NBK557791/

https://www.uptodate.com/contents/tricyclic-antidepressant-poisoning

https://pubmed.ncbi.nlm.nih.gov/15728327/

https://www.ncbi.nlm.nih.gov/books/NBK430931/

↑ *Back to this question in Part A*

@Neet_pg_bot

Q124: A 25-year-old patient is undergoing tooth extraction for dental caries. Which of the following does not require prophylaxis against infective endocarditis? (Q855912)

A. Prior history of endocarditis

B. Atrial septal defect

C. Unrepaired cyanotic heart disease

D. Prosthetic heart valves

Correct Answer: B. Atrial septal defect

Explanation: Atrial septal defect (ASD) is a congenital heart defect; however, it is generally not considered a high-risk condition for infective endocarditis unless there are other complicating factors, such as a significant shunt or right-sided heart failure. Infective Endocarditis (IE) Infective endocarditis (IE) is a bacterial or fungal infection of the endocardial surface of the heart, typically affecting the heart valves. Prophylaxis against infective endocarditis is recommended before certain invasive procedures (like dental extractions) for patients at high risk of developing this condition. Indications for Prophylaxis in Infective Endocarditis: High-Risk Patients: Prosthetic heart valves (mechanical/bioprosthetic) (Option D) History of infective endocarditis (Option A) Congenital heart disease (CHD): Unrepaired cyanotic CHD (Option C) Repaired CHD with prosthetic material (first 6 months) Repaired CHD with residual defects Cardiac transplantation recipients with valvulopathy Procedures Requiring Prophylaxis: Dental: Extractions, periodontal surgery, root canal, dental implants Respiratory: Tonsillectomy, adenoidectomy, bronchoscopy with biopsy GI/GU: Endoscopy with biopsy, colonoscopy, cystoscopy (high-risk patients) Prophylaxis Regimen: Amoxicillin: 2 grams orally, 30–60 minutes before Alternative (Penicillin allergic): Clindamycin: 600 mg orally Azithromycin: 500 mg orally Causes of Infective endocarditis Condition Most Common Organism Community-acquired native valve endocarditis Staphylococcus aureus Healthcare-associated native valve endocarditis Streptococci Endocarditis in injection drug users (Right side) Staphylococcus aureus Endocarditis in injection drug users (Left side) Staphylococcus aureus Most common organism causing prosthetic valve endocarditis Enterococci and Staphylococcus aureus Most common group of

organisms causing early prosthetic valve endocarditis (<12 months after surgery) Coagulase-negative staphylococci (CoNS) Late prosthetic valve endocarditis (>12 months after surgery) Streptococci Acute infective endocarditis Staphylococcus aureus Subacute infective endocarditis Streptococcus viridans Cardiovascular implantable electronic device (CIED)-associated endocarditis Enterococci and Coagulase-negative Staphylococci (CoNS) Culture-negative endocarditis HACEK organisms Coxiella burnetii Bartonella

References:

Harrison's Principles of Internal Medicine, 21st Edition, Page: 1023, 1025, 1027, 1031, 1033, 1034.

Robbins and Cotran Pathologic Basis of Disease, 10th Edition, Page: 563, 564.

↑ *Back to this question in Part A*

@Neet_pg_bot

Q125: A patient presents to you with an irregularly irregular pulse of 120/minute and a pulse deficit of 20. Which of the following would be the jugular venous pressure (JVP) finding? (Q855932)

A. Absent p wave

B. Absent a wave

C. Cannon a wave

D. Raised JVP with normal waveform

Correct Answer: B. Absent a wave

Explanation: The clinical scenario suggests atrial fibrillation (AF), a common arrhythmia with an irregularly irregular heartbeat, often accompanied by a fast heart rate (e.g., 120 beats/min). The pulse deficit of 20 indicates that not every atrial contraction is passed to the ventricles due to irregular conduction through the atrioventricular (AV) node, meaning some atrial beats are not followed by ventricular contractions. Atrial Fibrillation Features Characterized by abnormal automatic firing and multiple re-entry circuits. Atria beat rapidly and ineffectively; ventricles activated irregularly Produces an "irregularly irregular" pulse Palpitations, syncope, and breathlessness can be present Asymptomatic AF: Can present as systemic embolism and stroke ECG Features QRS Complexes: Irregular but normal P Waves: Absent; baseline may show irregular fibrillation waves Ventricular Rate: Fast at onset (120-160 beats/min) Slower in chronic AF due to medication effects and AV nodal fatigue {{caption_text}} JVP Absent a wave Management Paroxysmal Atrial Fibrillation First-line Therapy: Beta-blockers are effective in patients with CAD, hypertension, and heart failure. Class Ic Drugs: Propafenone or flecainide to prevent episodes (not for patients with CAD or LV dysfunction). Class III Drugs: Amiodarone : Most effective but with significant side effects; used when other treatments fail. Dronedarone : Alternative to amiodarone; contraindicated in heart failure. Rate Control: Digoxin and verapamil for AV node conduction slowing, but not for AF prevention. Catheter Ablation: Considered for patients with drug-resistant AF; prevents AF in ~75% of cases but may have complications. Persistent Atrial Fibrillation Rhythm Control : Cardioversion : Electrical or pharmacological (e.g.,

intravenous flecainide or amiodarone). Timing: Immediate if AF <48 hours; anticoagulation required if AF ≥48 hours. Prophylactic Amiodarone : To reduce recurrence risk. Rate Control : Medications: Digoxin, β-blockers, or rate-limiting calcium antagonists (verapamil, diltiazem) . Combination Therapy: Digoxin with β-blockers ; avoid combining calcium antagonists with β-blockers. Pace and Ablate: Permanent pacemaker with AV nodal block for symptomatic AF. Thromboprophylaxis Anticoagulation: Required for stroke prevention due to blood stasis in the left atrium. Warfarin : INR target of 2.0–3.0; start 4 weeks prior to cardioversion. DOACs: Rivaroxaban, apixaban, edoxaban, and dabigatran as alternatives to warfarin; no monitoring needed. Risk Assessment: CHA2DS2-VASc Score : For stroke risk; anticoagulate if score ≥2 . HAS-BLED Score: For bleeding risk; monitor patients with score ≥3. Aspirin: Not recommended due to low efficacy in preventing embolic stroke. CHA2DS2-VASc stroke risk scoring system for AF Points Parameters Score C Congestive heart failure 1 H Hypertension history 1 A2 Age (≥75 years) 2 D Diabetes mellitus 1 S2 Previous stroke or transient ischemic attack (TIA) 2 V Vascular disease 1 A Age (65-74 years) 1 Sc Sex category (female) 1 Maximum total score 9 points Management option for AF as per CHA2DS2-VASc score 0: need not anticoagulate 1: Give aspirin >=2: Warfarin/Dabigatran/Rivaroxaban Absent p wave (Option A): This is a characteristic ECG finding in atrial fibrillation. The absence of the P wave on ECG signifies that there is no organized atrial contraction, which leads to the irregularly irregular ventricular rhythm. Cannon a wave (Option C): Cannon a waves occur in atrioventricular (AV) dissociation, where the atria contract against a closed tricuspid valve, leading to a large, prominent a wave. Raised JVP with normal waveform (Option D): A raised JVP with a normal waveform is typically seen in conditions like congestive heart failure, right ventricular infarction, or superior vena cava obstruction. In atrial fibrillation, the JVP may be raised, but the waveform will not be normal.

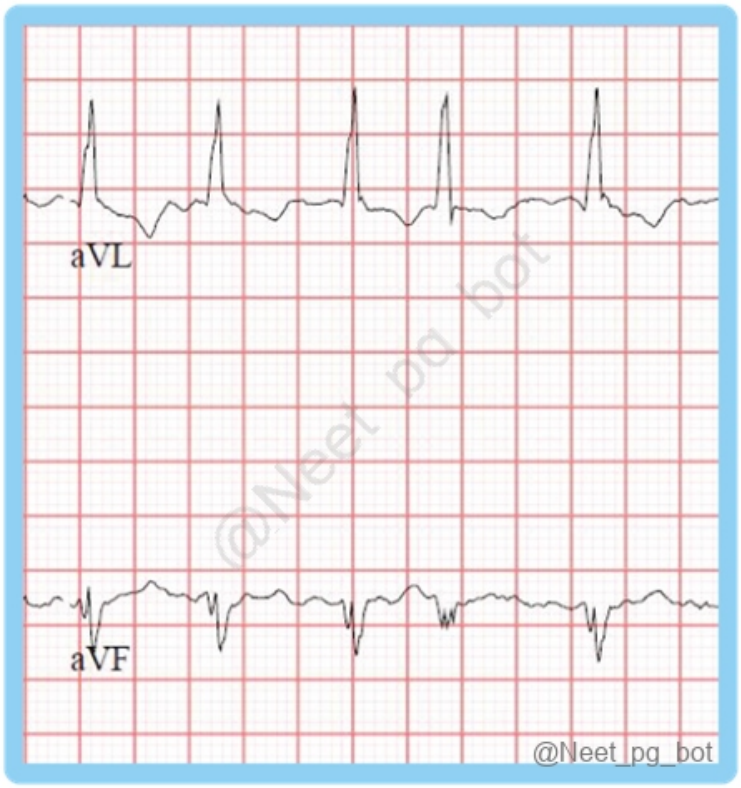

References:

Harrison's Principles of Internal Medicine, 21st Edition, Page: 1816-1818, 1903- 1907, 1991, 2007.

Davidson’s Principles and Practice of Medicine, 24th Edition, Page 470, 471, 472.

PMC Article: PubMed 34506629

PMC Article: PubMed 3221309

↑ *Back to this question in Part A*

@Neet_pg_bot

Q126: An 11-year-old child with a history of streptococcal pharyngitis presents with fever and arthralgia. There is no past history of rheumatic heart disease or carditis. How often is 600,000 IU of benzathine penicillin recommended for prophylaxis of rheumatic heart disease? (Q856007)

A. Immediately

B. Thrice weekly lifelong

C. Once in three weeks for 5 years or till the age of 18, whichever is longer

D. Once in three weeks for 10 years or till the age of 25, whichever is longer

Correct Answer: C. Once in three weeks for 5 years or till the age of 18, whichever is longer

Explanation: The clinical scenario describes acute rheumatic fever (ARF) in a child, which follows a group A streptococcal (GAS) pharyngitis infection. Secondary prophylaxis is essential to prevent recurrent episodes of ARF, which increases the risk of developing rheumatic heart disease (RHD). Secondary prophylaxis for Rheumatic Fever: Dose and Frequency: Patients weighing <27 kg: 600,000 IU benzathine penicillin every 3 weeks. Patients ≥27 kg: 1.2 million IU benzathine penicillin every 3 weeks. Condition Recommended Duration Without Carditis 5 years after the last attack or until 18 years of age, whichever is longer With Carditis but No Residual Valvular Disease 10 years or until 21–25 years of age, whichever is longer With Persistent Valvular Disease At least 10 years or until 40 years of age; lifelong prophylaxis may be required Revised Jones Criteria for the diagnosis of Acute Rheumatic Fever (ARF) Criteria Low-risk Populations Moderate- and High-risk Populations Major Criteria Carditis Clinical or subclinical Clinical or subclinical Arthritis Polyarthritis only Polyarthritis, polyarthralgia, or monoarthritis Chorea Yes Yes Erythema Marginatum Yes Yes Subcutaneous Nodules Yes Yes Minor Criteria Carditis Clinical or subclinical Clinical or subclinical Arthritis Polyarthritis only Polyarthritis, polyarthralgia, or monoarthritis Polyarthralgia Not applicable Yes Fever ≥38.5°C ≥38.0°C ESR ≥60 mm in the first hour ≥30 mm/hr and/or CRP ≥3.0 mg/dL Prolonged PR Interval Yes, after age variability Yes, after age variability Monoarthralgia Not applicable Yes For All Patient Populations Evidence of Preceding Group A Streptococcal Infection Increased ASLO/anti-DNAse B titer or positive throat culture or positive rapid strep test Diagnosis of Initial ARF 2 Major criteria or 1 Major + 2 Minor criteria Diagnosis of Recurrent ARF 2 Major criteria or 1 Major + 2 Minor or 3 Minor criteria

References:

Harrison's Principles of Internal Medicine, 21st Edition, Page: 2766, 2767, 2768, 2770.

Robbins and Cotran Pathologic Basis of Disease, 10th Edition, Page: 560, 561, 562.

Ghai Essential Pediatrics, 9th Edition, Page: 434.

↑ *Back to this question in Part A*

@Neet_pg_bot

Q127: A man on diuretics presents with weakness. An ECG shows flat T waves and prominent U waves. What is the most likely diagnosis? (Q856009)

A. Hypocalcemia

B. Hypomagnesemia

C. Hyperkalemia

D. Hypokalemia

Correct Answer: D. Hypokalemia

Explanation: The clinical presentation and ECG findings strongly suggest hypokalemia, a condition defined as a serum potassium level <3.5 mEq/L. Symptoms: Muscle weakness, cramps, or paralysis. Fatigue and lethargy. Constipation or ileus (due to smooth muscle dysfunction). Severe cases may lead to cardiac arrhythmias. Causes of Hypokalemia: Diuretic Use (Loop and Thiazide Diuretics): Increased renal excretion of potassium. Metabolic Alkalosis: Intracellular shift of potassium due to increased extracellular pH. Excessive β-agonist Activity: Intracellular potassium shift (e.g., in asthma treatment with salbutamol). Gastrointestinal Losses: Vomiting or diarrhea leading to potassium depletion. Other Causes: Insulin administration (drives potassium into cells). Magnesium deficiency (worsens renal potassium loss). Hyperaldosteronism (increased potassium excretion). ECG Changes in Hypokalemia: Flattened T waves. Prominent U waves. ST depression. Prolonged QT interval. Severe cases: Risk of ventricular tachycardia or fibrillation. Management: Potassium Replacement: Oral potassium chloride for mild cases. Intravenous potassium for severe or symptomatic cases (administer cautiously to avoid hyperkalemia). Correct Underlying Cause Hypocalcemia (Option A): Presents with muscle cramps, tetany, or paresthesias. ECG: Prolonged QT interval but no prominent U waves. Hypomagnesemia (Option B): Causes muscle weakness and arrhythmias. ECG: Torsades de Pointes (polymorphic ventricular tachycardia). Hyperkalemia (Option C): Presents with muscle weakness or paralysis. ECG: Tall, peaked T waves, shortened QT interval, and widened QRS complex.

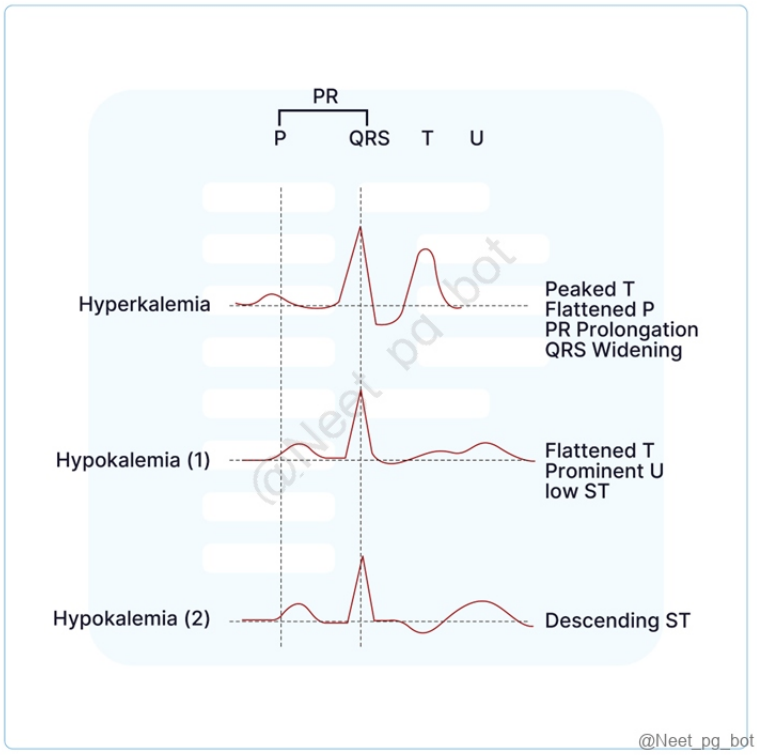

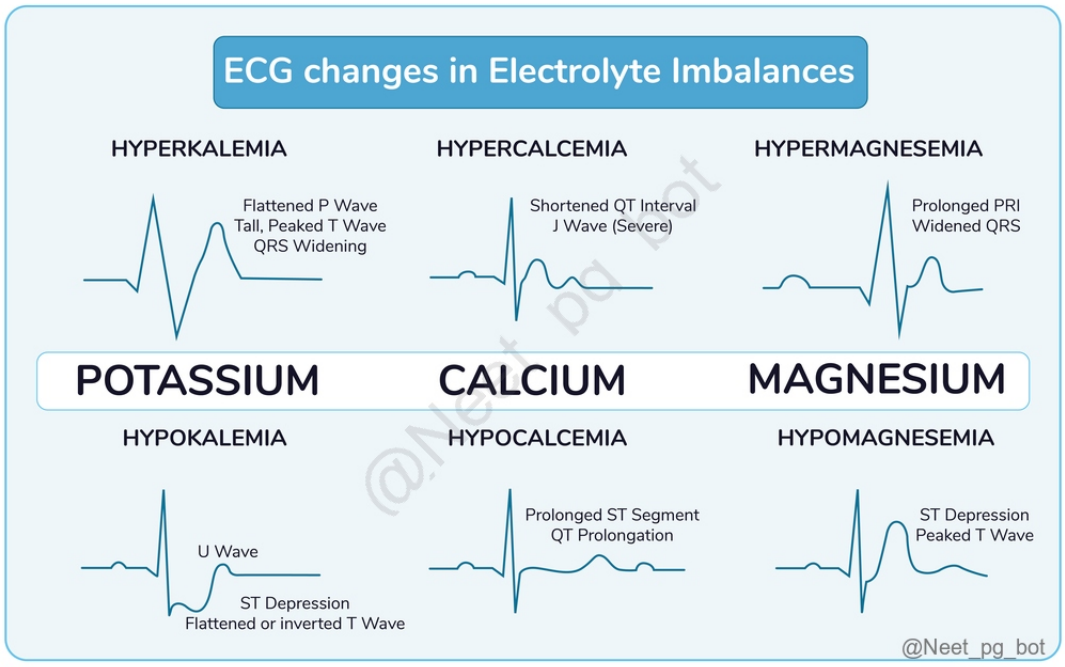

References:

Harrison's Principles of Internal Medicine, 21st Edition, Page: 168, 181, 296, 346, 348, 350, 351, 352, 358

↑ *Back to this question in Part A*

@Neet_pg_bot

Q128: A patient with coronary artery disease presents to you with chest pain and palpitations. The ECG is shown below. Which of the following can be used in the management? (Q856017)

A. Oral metoprolol

B. Oral amiodarone

C. Intravenous amiodarone

D. Intravenous metoprolol

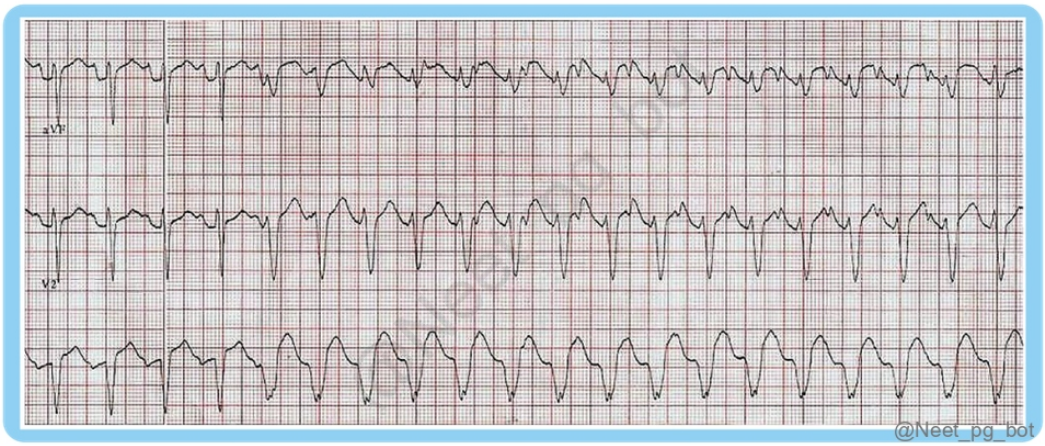

Correct Answer: C. Intravenous amiodarone

Explanation: The clinical scenario and ECG findings suggest ventricular tachycardia (VT) in a patient with coronary artery disease. ECG Findings: Wide QRS complexes (>120 ms). Absence of P waves or atrioventricular dissociation. Ventricular rate >100 bpm. Symptoms: Palpitations, chest pain, syncope, and dyspnea. Management Hemodynamically Stable VT: Drug of Choice: Intravenous amiodarone. Mechanism: Class III antiarrhythmic, prolongs action potential duration and refractory period. Hemodynamically Unstable VT: Immediate Electrical Cardioversion. Torsades de Pointes (Polymorphic VT): Treat with intravenous magnesium sulfate. Resuscitation Steps for Shockable & Non-Shockable Conditions Shockable Conditions Non-Shockable Conditions Ventricular Fibrillation Asystole Ventricular Tachycardia Pulseless Electrical Activity Shockable Conditions Non-Shockable Conditions Immediate Recognition Identify Shockable Rhythm: Recognize VF or pulseless VT. Activate Emergency Response: Call for advanced life support. ↓ Initiate CPR Start High-Quality CPR: Perform chest compressions at a rate of 100-120/min, with a depth of 5-6 cm. Continue CPR for 2 minutes. ↓ Defibrillation After 2 minutes of CPR, deliver a Non-Synchronized DC Shock to restore normal rhythm. If no change, administer a second shock immediately. ↓ Continue CPR Resume CPR for 2 Minutes Place an intravenous or intraosseous line for drug administration. ↓ Administer Epinephrine Epinephrine 1 mg (1:10,000): Given IV/IO after 2 minutes of CPR to enhance coronary perfusion pressure. ↓ Advanced Airway Management Secure Airway: Perform endotracheal intubation if necessary. Capnography: Monitor end-tidal CO2 levels. Ventilation: Provide 1 breath every 6 seconds post-intubation. ↓ Further Defibrillation Third Shock: If VF or pulseless VT persists, deliver a

third non-synchronized shock. Continue CPR for 2 More Minutes: Follow with additional CPR. ↓ Administer Antiarrhythmic Medication Amiodarone 300 mg IV: Administer for shock-refractory VT to stabilize heart rhythm. ↓ Identify and Treat Reversible Causes Immediate Recognition Identify Non-Shockable Rhythm: Recognize asystole or pulseless electrical activity (PEA). Activate Emergency Response: Call for advanced life support. ↓ Initiate CPR Start High-Quality CPR: Perform chest compressions at a rate of 100-120/min, with a depth of 5-6 cm. Continue CPR for 2 minutes. ↓ Establish intravenous or intraosseous line for medication administration. ↓ Administer Epinephrine Epinephrine 1 mg (1:10,000): Administer IV/IO after the first 2 minutes of CPR. ↓ Identify Rhythm Non-Shockable Rhythm: Continue CPR and administer epinephrine every 3-5 minutes. Goal: To increase the likelihood of developing a shockable rhythm, such as ventricular fibrillation (VF), which is necessary for effective defibrillation. Shockable Rhythm: Administer a Non-Synchronized DC Shock to restore normal rhythm. ↓ Advanced Airway Management Airway: Secure the airway with endotracheal intubation if necessary. Capnography: Monitor end-tidal CO2 levels. Ventilation: Provide 1 breath every 6 seconds post-intubation for adequate oxygenation. ↓ Continue CPR Resume chest compressions for 2 minutes. ↓ Identify and Treat Reversible Causes Primary Focus: Address reversible causes, especially hypothermia. ↓ Repeat CPR and Epinephrine Cycle: Continue repeating CPR and epinephrine administration every 3-5 minutes. Oral Metoprolol (Option A): Selective β1-antagonist used in angina, hypertension, and chronic heart failure; not indicated for acute ventricular tachycardia management, especially when rapid control is needed. Oral Amiodarone (Option B): Used for chronic treatment of VT, atrial fibrillation, and ventricular fibrillation; delayed onset makes it unsuitable for acute management. Intravenous Metoprolol (Option D): Used in acute myocardial infarction to reduce heart rate and myocardial oxygen demand; not a first-line treatment for ventricular tachycardia.

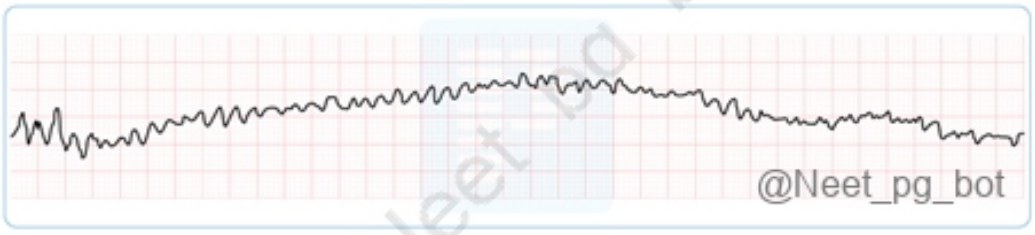

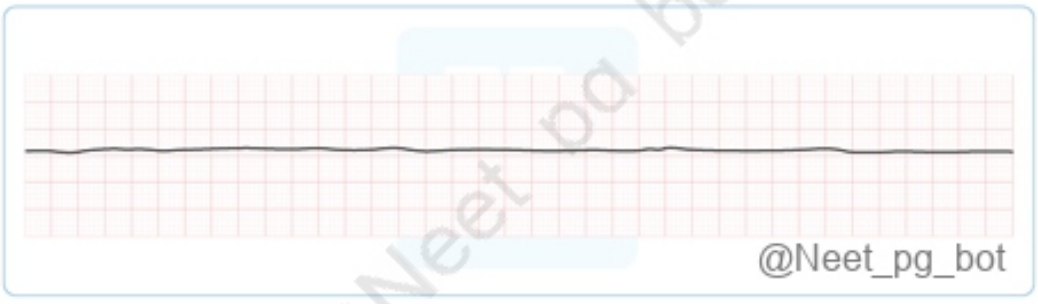

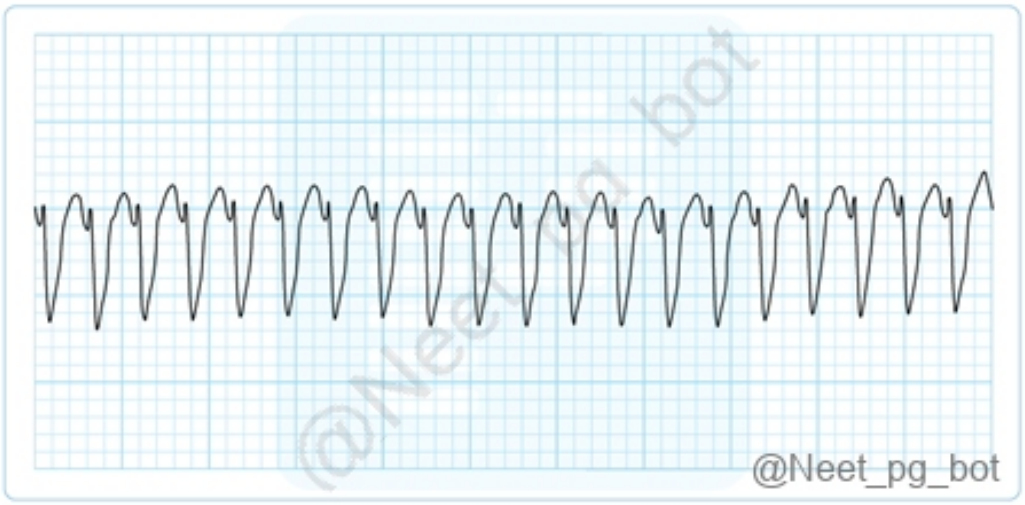



References:

Harrison's principles of internal medicine, 21st Edition, Page: 2063,2262,2263.

Davidson's principles and practice of medicine, 24th Edition, Page: 481482.

Asystole

↑ *Back to this question in Part A*

@Neet_pg_bot

Q129: A 20-year-old female presents with septic shock, blood pressure 58/30 mmHg, and MAP 58 mmHg. She has received 30 mL/kg of crystalloid fluid, but her MAP remains <65 mmHg. What is the next best step in management? (Q865315)

A. Start dopamine

B. Start noradrenaline

C. Repeat crystalloid fluid

D. Start vasopressin

Correct Answer: B. Start noradrenaline

Explanation: Noradrenaline (norepinephrine) is the vasopressor of choice in septic shock due to its potent alpha-1 effects (vasoconstriction) and minimal beta effects, improving MAP without excessive tachycardia. Septic Shock Management: 1. Source Control Start broad-spectrum antibiotics within 1 hour. Remove infected/ necrotic tissue or devices if they are the source. 2. Shock Management (within 6 hours) Fluids: Crystalloids (NS/albumin) up to 80 mL/kg. Target: CVP 8–12 mmHg, MAP ≥65 mmHg, ScvO■ ≥70%. Use norepinephrine (warm shock) or epinephrine (cold shock) as first-line vasopressors if fluid therapy fails. Dopamine is no longer preferred due to adverse hormonal effects. 3. Enhancing Host Response Steroids if shock is vasopressor-refractory or cortisol is low. Vasopressin can be added in refractory shock. Start dopamine (Option A) Less preferred due to higher risk of arrhythmias and worse outcomes compared to noradrenaline. Repeat crystalloid fluid (Option C) Already received appropriate volume; additional fluid may cause fluid overload without improving perfusion. Start vasopressin (Option D) Vasopressin is used as an adjunct to noradrenaline in refractory cases, not as initial therapy.

References:

Septic Shock - StatPearls - NCBI Bookshelf

↑ *Back to this question in Part A*

@Neet_pg_bot

Q130: A patient presents to the ER with central chest pain. He has a past medical history of heart disease. ECG is shown below. What is the diagnosis? (Q866785)

A. Anterolateral MI

B. Inferolateral MI

C. Acute pericarditis

D. Constrictive pericarditis

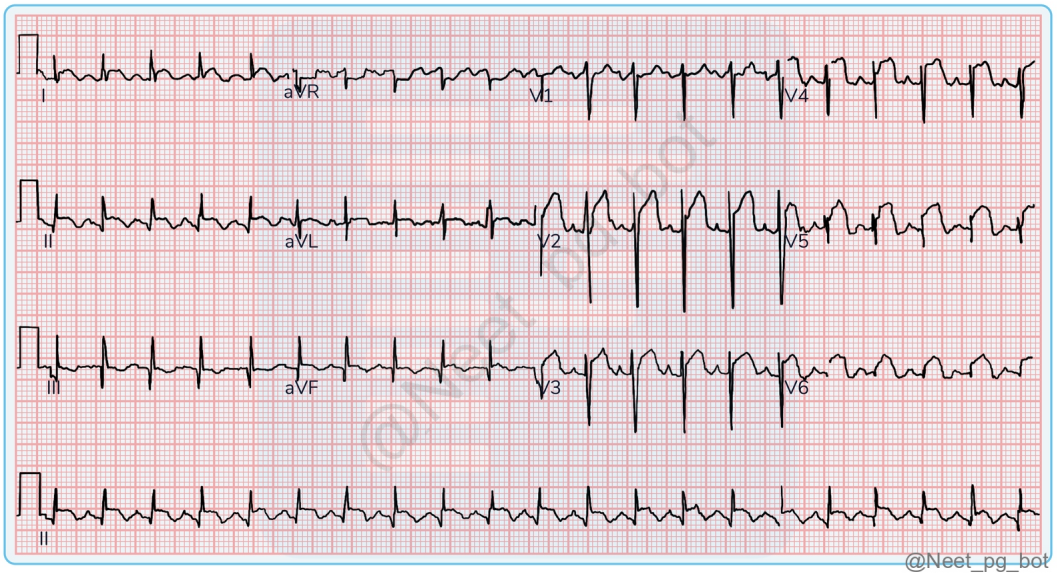

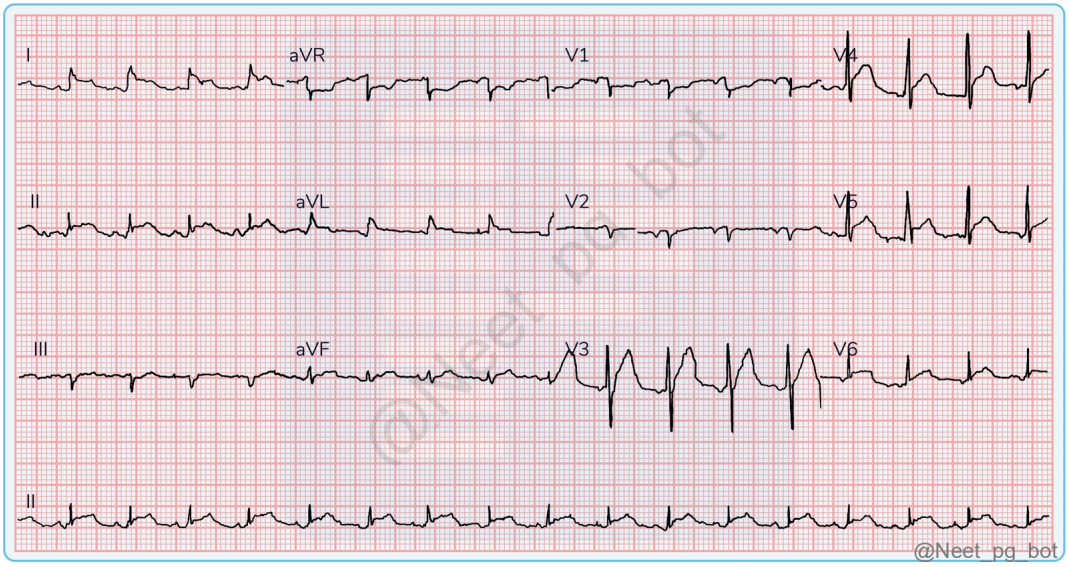

Correct Answer: A. Anterolateral MI

Explanation: ECG Findings: ST-segment elevation: Anterior leads: V2–V4 Lateral leads: I, aVL, V5, V6 Reciprocal ST-segment depression: leads III and aVF (inferior leads) Interpretation: This combination indicates acute injury involving both the anterior wall (supplied by the LAD) and the lateral wall (supplied by the LCX or diagonal branches of LAD) — hence, anterolateral MI. Reciprocal changes (ST depression in inferior leads) strengthen the diagnosis of acute MI and help differentiate from pericarditis. MI location vs. ECG leads MI Location Leads with ST Elevation Likely Artery Anterior V1–V4 LAD Lateral I, aVL, V5, V6 LCX or diagonal branch Anterolateral V2–V6, I, aVL LAD + LCX/diagonal branch Inferior II, III, aVF RCA or LCX Inferolateral II, III, aVF, I, aVL, V5, V6 RCA + LCX Posterior V7–V9 (or tall R in V1–V2) RCA or LCX Incorrect Options: Inferolateral MI (Option B): Inferolateral MI would have ST elevation in inferior leads (II, III, aVF) plus lateral leads (I, aVL, V5, V6). Here, inferior leads show ST depression, not elevation → rules out this option. Acute pericarditis (Option C): Pericarditis usually has diffuse ST elevation across almost all leads without reciprocal ST depression (except in aVR/V1) and PR segment depression. This ECG shows localized ST elevation with clear

reciprocal changes — typical of MI, not pericarditis. Constrictive pericarditis (Option D): Constrictive pericarditis is a chronic condition; ECG may show low voltage QRS or nonspecific changes, not acute ST elevation patterns. It presents with signs like Kussmaul's sign, pericardial knock, and right heart failure — not acute chest pain + STEMI pattern.

References:

.

↑ *Back to this question in Part A*

@Neet_pg_bot

Q131: A patient after MI develops a broad QRS complex tachycardia. His BP is 120/85 mm Hg. ECG is given below. Best management? (Q866787)

A. Amiodarone iv

B. Labetalol iv

C. Metoprolol iv

D. Nitroglycerin iv

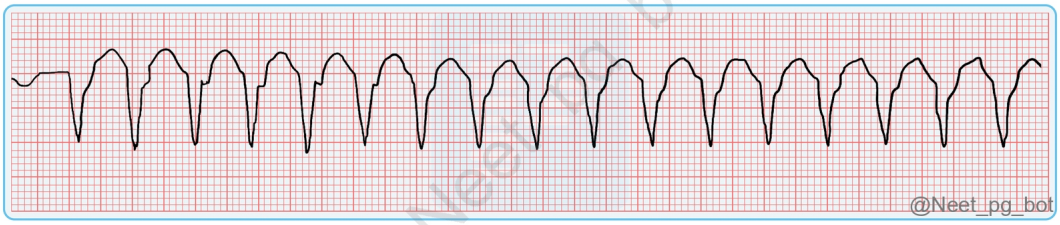

Correct Answer: A. Amiodarone iv

Explanation: Step 1: Recognising the rhythm Broad QRS (>120 ms) Regular tachycardia Monomorphic appearance Post-MI patient → high risk of ventricular tachycardia (VT) Diagnosis: Sustained monomorphic VT Step 2: Assessing stability BP = 120/85 mm Hg → patient is hemodynamically stable (no shock, syncope, severe hypotension, or heart failure). In stable VT, first-line pharmacologic management = IV amiodarone (or procainamide in some guidelines). Class III antiarrhythmic that prolongs repolarisation and suppresses ventricular ectopy. Preferred in structural heart disease post-MI because other agents (like some beta-blockers) may worsen VT in the acute setting. Stable vs. unstable broad complex tachycardia (VT) Status First-line management Stable VT IV amiodarone (or procainamide) Unstable VT Immediate synchronized DC cardioversion Pulseless VT / VF Immediate defibrillation + CPR Incorrect Options: Labetalol IV (Option B): Labetalol is an alpha- and beta-blocker used for hypertension, not for acute VT management. Giving it here will not terminate VT and can worsen instability. Metoprolol IV (Option C): While beta-blockers are used post-MI for arrhythmia prevention, they are not the first choice for terminating sustained VT in the acute phase. Risk of worsening hypotension or bradyarrhythmia once VT resolves. Nitroglycerin IV (Option D) Used for angina or heart failure due to ischemia.

Has no role in terminating VT. May cause hypotension in this context.

References:

.

↑ *Back to this question in Part A*

@Neet_pg_bot

Q132: A man presents to the emergency department unconscious and hypotensive. His ECG reveals narrow complex tachycardia. What is the next best step in management? (Q840106)

A. Synchronized DC cardioversion

B. Carotid massage

C. IV adenosine 6 mg

D. IV amiodarone

Correct Answer: A. Synchronized DC cardioversion

Explanation: Correct Option A - Synchronized DC cardioversion: The patient is unconscious and hypotensive , indicating hemodynamic instability . His ECG shows a narrow-complex tachycardia , most consistent with paroxysmal supraventricular tachycardia (PSVT) . In any patient with tachyarrhythmia + hemodynamic instability , the immediate management is synchronized DC cardioversion (except for AF) , regardless of the specific narrow-complex rhythm (except polymorphic VT where unsynchronized shock is used). Incorrect Options: Options B, C & D: They are usually administered in a hemodynamically stable patient. Additionally, amiodarone is given to patients with broad QRS complex tachycardia.

References:

.

↑ *Back to this question in Part A*

@Neet_pg_bot

Q133: A 70-year-old man collapsed in his house and was rushed to the hospital. On arrival, his ECG tracing was as shown below. Which of the following is the best intervention for this patient? (Q859568)

A. Use of automated external defibrillator

B. Injection of vasopressin 40 IU

C. Injection of Adrenaline 1mg IV

D. Injection of Atropine 0.5mg IV

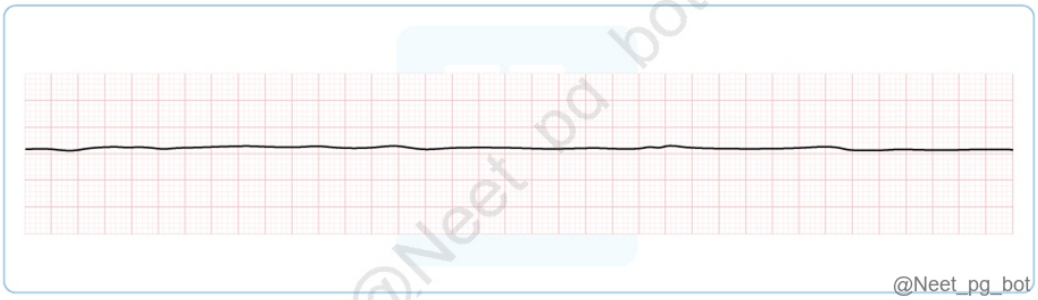

Correct Answer: C. Injection of Adrenaline 1mg IV

Explanation: The ECG here is starting to show asystole and the best treatment modality is CPR and injection of Adrenaline 1mg IV. Resuscitation Steps for Asystole {{caption_text}} Options A, B, and D are incorrect.

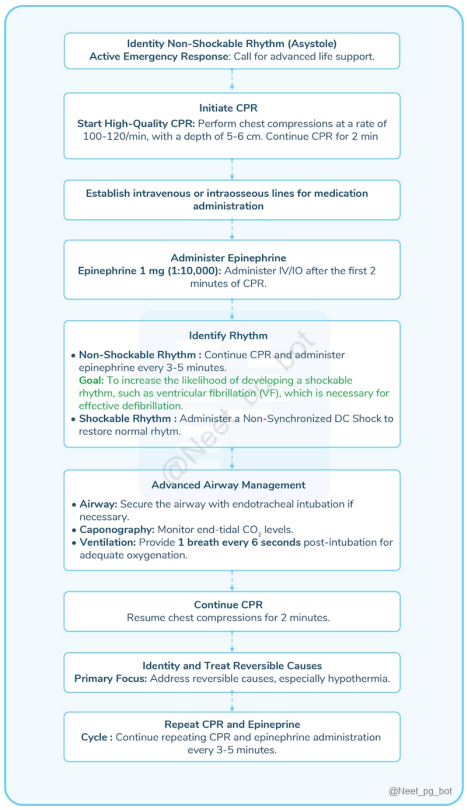

References:

Harrison's principles of internal medicine, 21st Edition, Page: 2262,2263.

Davidson's principles and practice of medicine, 24th Edition, Page: 482.

Asystole

↑ *Back to this question in Part A*

@Neet_pg_bot

Q134: Which of these conditions will cause a large ‘P’ wave in ECG? (Q879158)

A. Mitral stenosis

B. Aortic stenosi

C. Aortic regurgitation

D. Tricuspid stenosis

Correct Answer: D. Tricuspid stenosis

Explanation: The P wave represents atrial depolarisation, and the size of the wave reflects atrial muscle mass. The initial part of the P wave is due to depolarisation of the right atrium (RA) and the terminal part is due to left atrial (LA) depolarisation. Right atrial enlargement → tall, peaked P wave Left atrial enlargement → broad, notched P wave Tricuspid stenosis obstructs the flow from RA to RV, which results in: Increased RA pressure Chronic RA volume overload Right atrial enlargement (hypertrophy and dilation) More muscle to depolarise, resulting in a larger P wave amplitude. On ECG, right atrial enlargement produces P pulmonale (height >2.5 mm in lead II, peaked P waves in III, aVF and prominent first part of P wave in V1). This pattern is characteristic of right-sided pathology such as COPD, pulmonary hypertension, tricuspid stenosis and regurgitation. Mitral stenosis (Option A): It obstructs LA to LV, causing left atrial enlargement, resulting in P mitrale (broad, notched P wave) on ECG. Aortic stenosis (Option B): It causes LV pressure overload, leading to concentric LV hypertrophy, seen as tall R waves in V5-V6, deep S waves in V1-V3, increased Sokolow–Lyon index (S in V1 + R in V5 or V6 > 35 mm) on ECG. In later stages, LV diastolic dysfunction can lead to increased LA pressure, causing left atrial enlargement (P mitrale). Aortic regurgitation (Option C): It causes LV volume overload, leading to left ventricular dilatation and later LA enlargement.

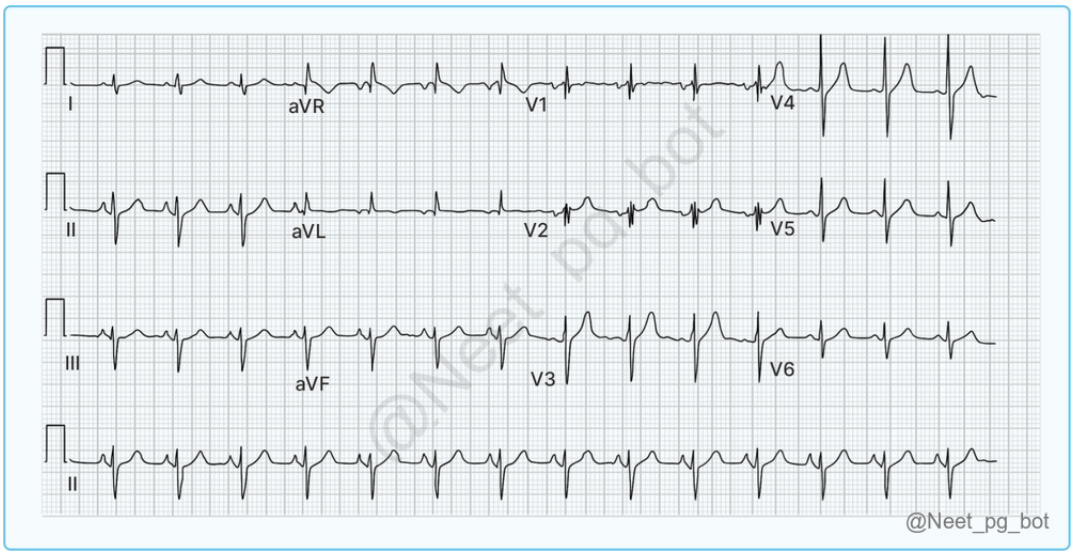
I
aVR
V1
V4
II
aVL
V2
V5
III
aVF
V3
V6
II
@Neet_pg_bot

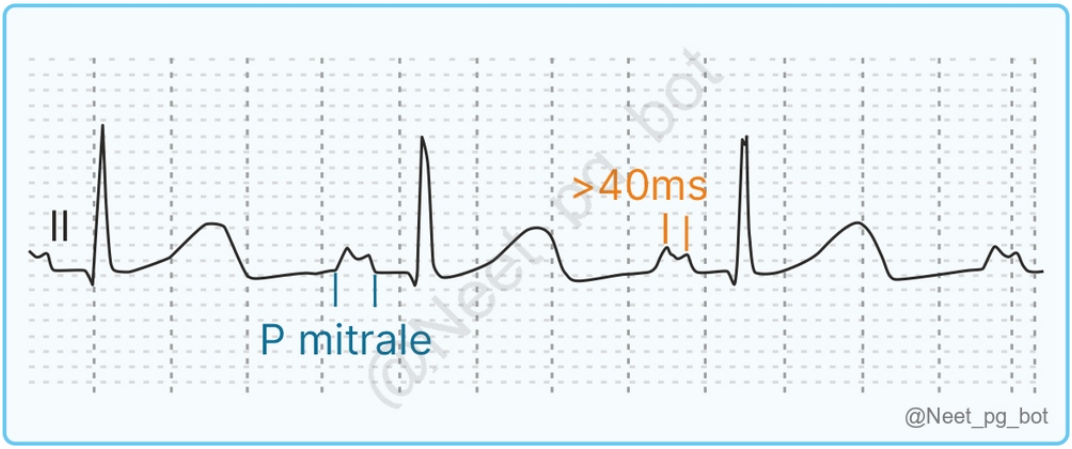
II
>40ms
P mitrale
@Neet_pg_bot

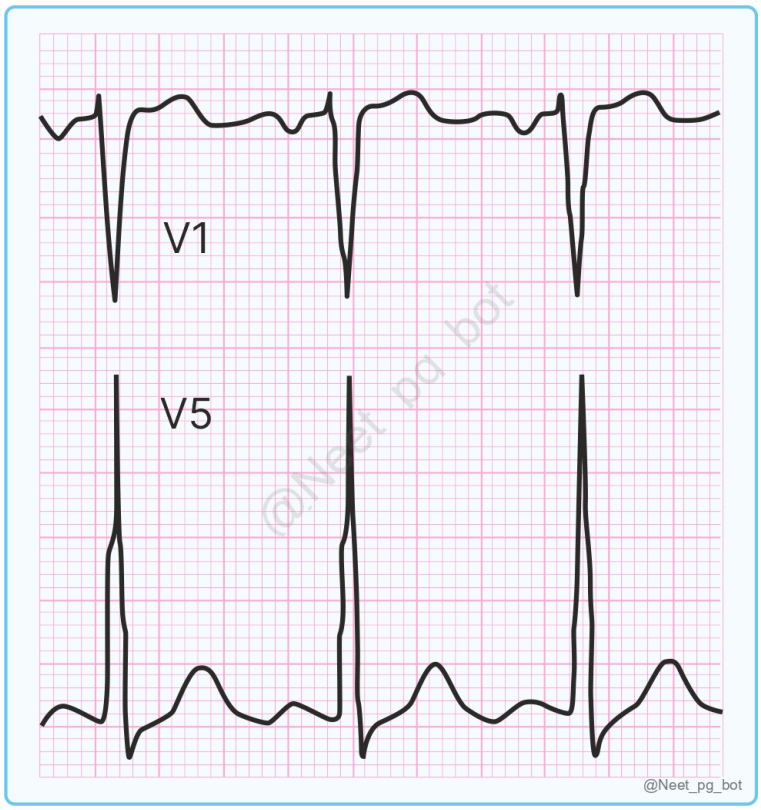

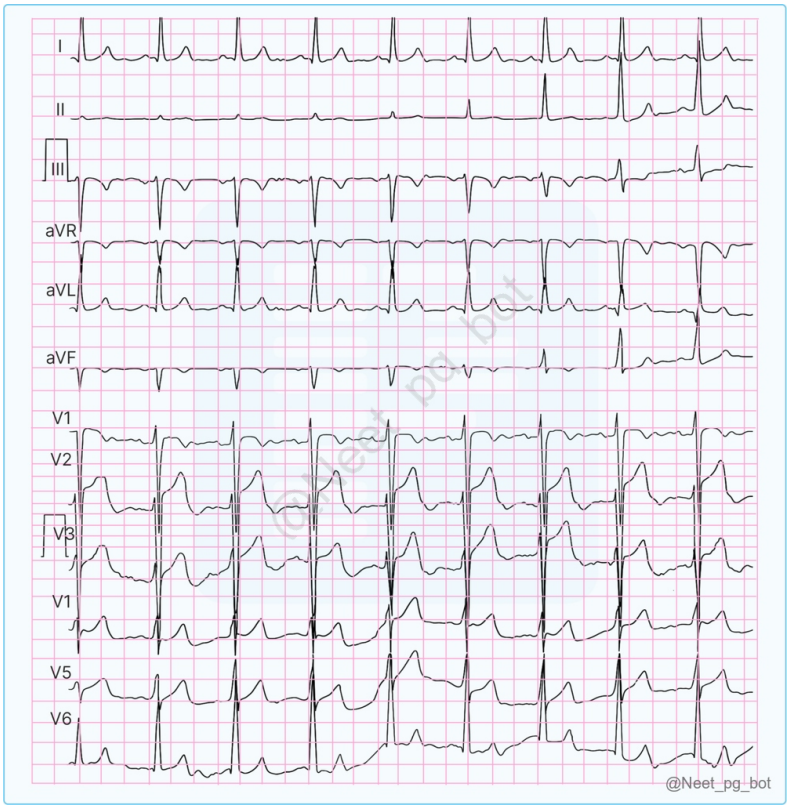

References:

Harrison’s Principles of Internal Medicine, 21st Edition, Page 2064-2065. Tricuspid Stenosis - StatPearls - NCBI Bookshelf

↑ *Back to this question in Part A*

@Neet_pg_bot

Q135: Which of the following conditions does NOT share the same initial mechanism leading to heart failure as the others? (Q879211)

A. High salt intake

B. Anemia

C. Fever

D. Thyrotoxicosis

Correct Answer: A. High salt intake

Explanation: Anemia, fever, and thyrotoxicosis all cause high-output heart failure, where the primary mechanism is an increase in cardiac output due to elevated metabolic demand or decreased systemic vascular resistance. In contrast, high salt intake leads to volume overload, causing low-output (congestive) heart failure through increased preload rather than increased metabolic demand.

References:

Harrison’s Principles of Internal Medicine, 21st Edition, Pages 1651-1653.

↑ *Back to this question in Part A*

@Neet_pg_bot

Q136: A 20-year-old athlete died during a practice session, and the attending doctor declared him dead on arrival and sent for an autopsy. The gross specimen of his heart is shown below. What is the plausible cause and advice to the family? (Q879215)

A. Cardiac arrest, check cholesterol in family members

B. Cardiac arrest due to hypertrophic cardiomyopathy, screen family members

C. Sudden cardiac death due to valvular pathology caused by rheumatic etiology

D. Cardiac arrest due to arrhythmias and heart blockwith no significant lesion on cardiac autopsy



Correct Answer: B. Cardiac arrest due to hypertrophic cardiomyopathy, screen family members

Explanation: In a young athlete who dies suddenly during exertion, the most likely cause is hypertrophic cardiomyopathy (HCM), typically showing asymmetric septal hypertrophy and a banana-shaped left ventricular cavity on gross pathology. HCM is a genetic (autosomal dominant) disorder involving mutations in sarcomeric proteins, predisposing to ventricular arrhythmias and sudden cardiac death. Hence, first-degree relatives should be screened by echocardiography and genetic testing.

References:

Harrison's Principles of Internal Medicine, 21st Edition, Pages 1600-1603.

↑ *Back to this question in Part A*

@Neet_pg_bot

Q137: A patient presents with exertional dyspnea and pedal oedema. His echocardiogram shows a dilated left ventricle with reduced systolic function. Which of the following statements regarding this condition is false? (Q879444)

A. Pulmonary hypertension may develop in this patient

B. Ejection fraction will be reduced in this condition

C. Long-term anticoagulation is not needed for this patient

D. Beta blockers are indicated in chronic management

Correct Answer: C. Long-term anticoagulation is not needed for this patient

Explanation: The patient is a classic case of Heart Failure with Reduced Ejection Fraction (HFrEF). Option C is false because patients with HFrEF (NYHA II-III) have a significant risk of LV thrombus and embolic events due to low-flow dilated ventricles. Hence, anticoagulation is recommended in such patients. Incorrect Options: Pulmonary hypertension may develop in this patient (Option A): This is true because patients with left ventricular heart failure have a risk of developing right heart failure, which in turn is associated with pulmonary hypertension. Moreover, class II Pulmonary hypertension occurs due to an ↑ in LAP, which in turn is due to an ↑ in LVDEP. Ejection fraction will be reduced in this condition (Option B): By definition of HFrEF, EF < 40% , so this is true. Beta blockers are indicated in chronic management (Option D): Evidence-based beta blockers (carvedilol, metoprolol succinate, bisoprolol) improve survival in chronic HFrEF.

References:

Harrison's Principles of Internal Medicine, 22nd Edition, Pages 1987-1995, 1997.

↑ *Back to this question in Part A*

@Neet_pg_bot

Q138: Which of the following conditions is characterized by the absence of P waves? (Q793825)

A. Ventricular tachycardia

B. Focal atrial tachycardia

C. Ventricular fibrillation

D. Atrial fibrillation

Correct Answer: D. Atrial fibrillation

Explanation: Correct Option D - Atrial Fibrillation: The P wave on an electrocardiogram (ECG) represents the depolarization of the atria. Atrial fibrillation (AF) is a common cardiac arrhythmia characterized by a fast and irregular heartbeat originating from multiple areas in the atria. Absent P waves are a feature of AF because the atria are not depolarizing in a coordinated fashion. Instead of a regular P wave preceding each QRS complex, there are rapid, irregular fibrillatory waves with no discernible P waves. Incorrect Options: Options A, B and C are incorrect.

References:

Harrison's Principles of Internal Medicine, 21e

↑ *Back to this question in Part A*

@Neet_pg_bot

Q139: Interpret the ECG given below. (Q793832)

A. Ventricular fibrillation

B. Atrial fibrillation

C. Supra ventricular tachycardia

D. Ventricular tachycardia

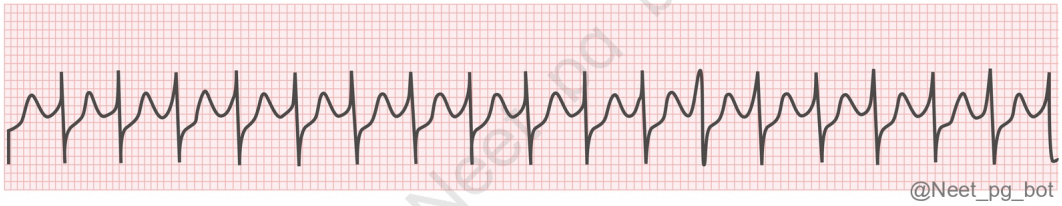

Correct Answer: C. Supra ventricular tachycardia

Explanation: Correct Option C - Supra ventricular tachycardia: The ECG in the question shows a narrow QRS complex with an increased heart rate. Supraventricular tachycardia (SVT) is a type of arrhythmia that originates above the ventricles and can cause a rapid heartbeat. The ECG tracing for SVT shows a regular rhythm with a narrow QRS complex, often with a sudden onset and termination. Thus, the above ECG indicates supraventricular tachycardia. Incorrect Options: Option A - Ventricular fibrillation: Ventricular fibrillation is a life-threatening arrhythmia that occurs when the ventricles (lower chambers) of the heart quiver instead of contracting properly, leading to a lack of blood flow to the body's vital organs. The ECG tracing for ventricular fibrillation shows a rapid and chaotic pattern with no identifiable P, QRS, or T waves. Option B - Atrial fibrillation: Atrial fibrillation is a common arrhythmia that occurs when the atria (upper chambers) of the heartbeat irregularly and often rapidly, leading to inefficient blood flow to the ventricles. The ECG tracing for atrial fibrillation shows an irregular rhythm with no discernible P waves and an irregularly spaced QRS complex Option D - Ventricular tachycardia: Ventricular tachycardia is a type of arrhythmia that originates in the ventricles and can lead to a fast and potentially life-threatening heart rate. The ECG tracing for ventricular tachycardia shows a regular or irregular rhythm with a wide QRS complex, often with a repeating pattern.

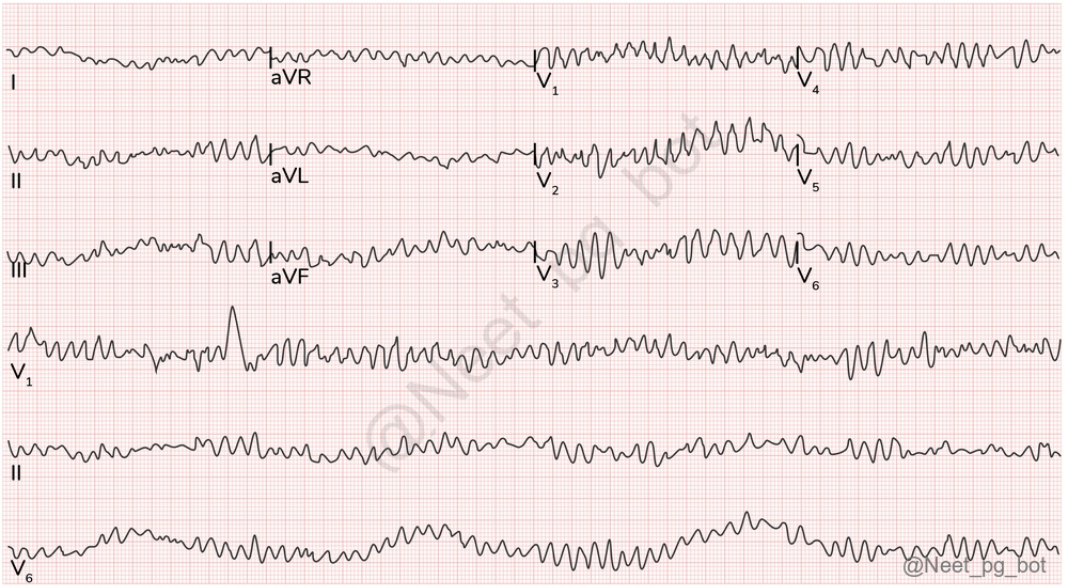
I
aVR
V1
V4
II
aVL
V2
V5
III
aVF
V3
V6
V1
II
V6
@Neet_pg_bot

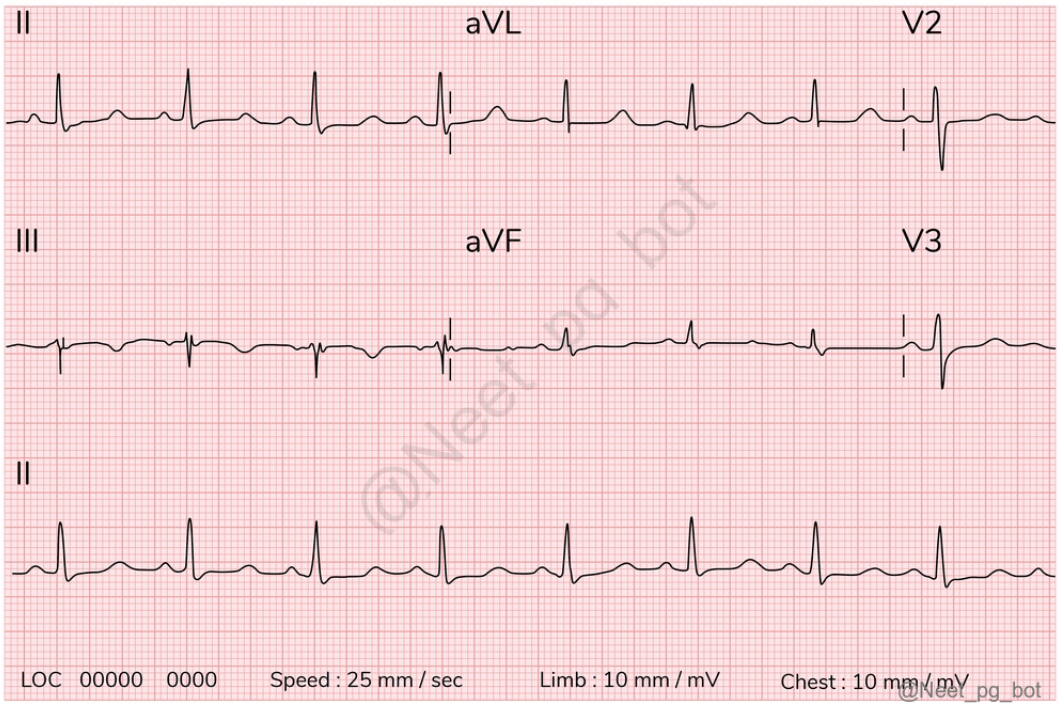
II
aVL
V2
III
aVF
V3
II
LOC 00000 0000
Speed : 25 mm / sec
Limb : 10 mm / mV
Chest : 10 mm / mV
@Neet_pg_bot

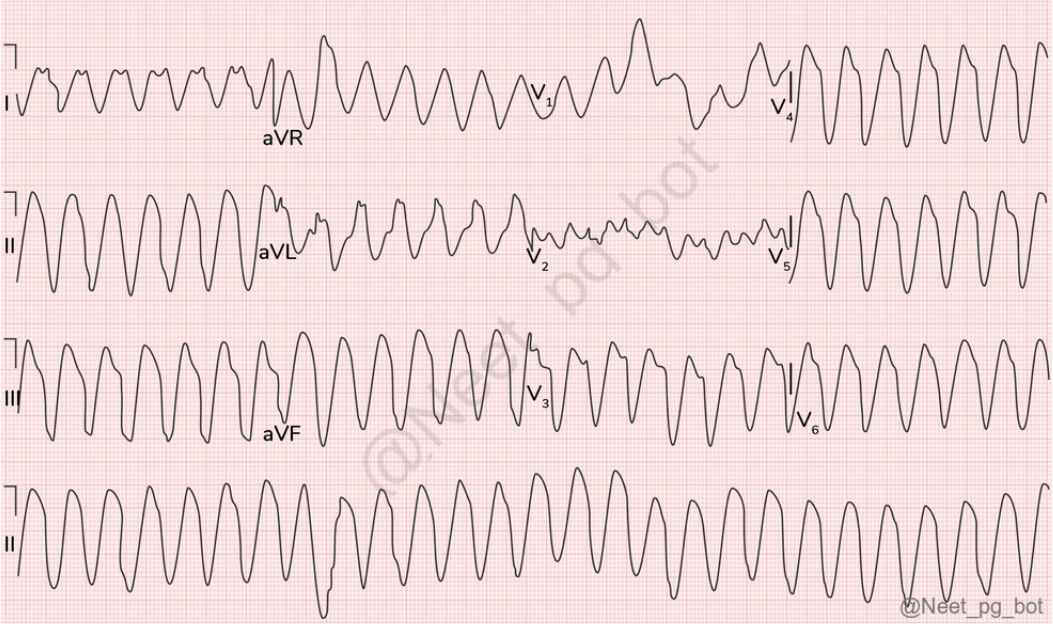

References:

.

↑ *Back to this question in Part A*

@Neet_pg_bot

Q140: J-wave is seen in? (Q793859)

A. Hypothermia

B. Heat stroke

C. High-altitude pulmonary edema

D. Drowning

Correct Answer: A. Hypothermia

Explanation: Correct Option A - Hypothermia: J wave, also known as an Osborn wave, is a small hump or notch that appears on the QRS complex of an electrocardiogram (ECG) in certain conditions. It is most commonly associated with hypothermia, a condition in which the body temperature drops below normal. The exact mechanism by which J waves develop in hypothermia is not fully understood, but it is believed to be related to changes in the electrical properties of the heart caused by cold temperatures. Specifically, hypothermia can cause a decrease in the speed of electrical conduction in the heart, which can lead to the development of the J wave. Incorrect Options: Options B, C, and D are not associated with J waves.

References:

HARRISON'S PRINCIPLES OF INTERNAL MEDICINE 20TH EDITION

↑ *Back to this question in Part A*

@Neet_pg_bot

Q141: A 26-year-old male patient, an accident victim started developing difficulty in breathing . On examination, his BP as 80/40 mmHg and pulses were feeble, JVP was found to be elevated with an absent Y descent, and heart sounds were muffled . What is the most likely diagnosis? (Q793863)

A. Constrictive pericarditis

B. Cardiac tamponade

C. Acute pericarditis

D. Cardiac failure

Correct Answer: B. Cardiac tamponade

Explanation: Correct Option B - Cardiac tamponade: The given scenario describes a young male patient who has developed difficulty in breathing and has signs of hemodynamic compromise, including hypotension and weak pulses, elevated jugular venous pressure with absent Y descent, and muffled heart sounds. Based on these findings, the most likely diagnosis is cardiac tamponade. Cardiac tamponade is a medical emergency that occurs when there is an accumulation of fluid in the pericardial sac surrounding the heart, leading to compression of the cardiac chambers and impaired filling during diastole. This can result in decreased cardiac output and hemodynamic compromise, which may manifest as hypotension, tachycardia, elevated jugular venous pressure, and muffled heart sounds. Cardiac tamponade can be caused by a variety of conditions, including trauma, infection, malignancy, and autoimmune disorders. Incorrect Options: Option A - Constrictive pericarditis: Constrictive pericarditis is a chronic condition that results from the thickening and fibrosis of the pericardial sac, leading to impaired diastolic filling of the heart chambers. This can result in similar symptoms to those seen in cardiac tamponade, including elevated jugular venous pressure and muffled heart sounds, but the onset is typically more gradual, and the symptoms are not as severe. Constrictive pericarditis is also associated with other signs, such as Kussmaul's sign and pericardial knock. Option C - Acute pericarditis: Acute pericarditis is an inflammatory condition of the pericardial sac, which can lead to chest pain, fever, and pericardial friction rub on auscultation. However, the signs and symptoms are not typically as severe as those seen in cardiac tamponade, and there is no significant hemodynamic compromise. Option D - Cardiac failure: Cardiac failure is incorrect because while cardiac tamponade can lead to heart failure, it is not the primary diagnosis in this case. Furthermore, cardiac failure typically presents with different symptoms such as shortness of breath, fatigue, and fluid accumulation in the legs.

References:

Prepladder Notes

↑ *Back to this question in Part A*

@Neet_pg_bot

Q142: A known hypertensive patient is brought to the ER with palpitations and breathlessness. On examination, his BP was 220/140 with signs of encephalopathy. All of the following can be used to treat this condition except? (Q793876)

A. IV Nicardipine

B. IV Mannitol

C. IV Esmolol

D. IV Sodium Nitroprusside

Correct Answer: B. IV Mannitol

Explanation: IV Mannitol does not play a role in the management of patients with hypertensive encephalopathy. caution must be exercised to avoid precipitous drops in blood pressure, which can exacerbate cerebral ischemia. V Mannitol is not typically used to lower blood pressure in hypertensive emergencies. Instead, it is used to reduce intracranial pressure in conditions such as cerebral edema or increased intracranial pressure due to trauma, tumors, or cerebral hemorrhage. It can indirectly lower blood pressure by reducing intracranial pressure and improving cerebral perfusion, it is not a primary agent for managing hypertensive emergencies. IV Nicardipine (Option A): A first-line IV antihypertensive for hypertensive emergency; safely reduces BP. IV Esmolol (Option C): Short-acting β-blocker used in hypertensive emergencies, especially with tachycardia. IV Sodium Nitroprusside (Option D): Potent arterial + venous vasodilator; rapidly reduces BP in severe hypertensive encephalopathy.

References:

.

↑ *Back to this question in Part A*

@Neet_pg_bot

Q143: A patient with chronic stable angina is having signs of heart failure. The use of which of the following drugs can decrease mortality? (Q793889)

A. Nifedipine

B. Digoxin

C. Lisinopril

D. Torsemide

Correct Answer: C. Lisinopril

Explanation: Correct Option C - Lisinopril: The patient has chronic stable angina + signs of heart failure , which indicates left ventricular dysfunction . ACE inhibitors (like Lisinopril) are proven to reduce mortality in: Heart failure with reduced ejection fraction (HFrEF) Post-myocardial infarction patients Patients with LV dysfunction, even if asymptomatic They prevent remodeling, reduce afterload, improve symptoms, and significantly improve survival . Digoxin improves symptoms but does NOT reduce mortality. Incorrect Options: Options A, B and D are incorrect.

References:

.

↑ *Back to this question in Part A*

@Neet_pg_bot

Q144: A person collapses following a road traffic accident, and you begin performing CPR. The rescue team arrives with an automated external defibrillator (AED). Which of the following is the most appropriate next step? (Q793901)

A. Continue 5 rounds of CPR @ 30:2 followed by application of AED

B. Continue CPR while the team applies the AED paddles

C. Stop CPR and let them apply paddles

D. Handover the patient and leave

Correct Answer: B. Continue CPR while the team applies the AED paddles

Explanation: Correct Option B) Continue CPR while the team applies the AED paddles CPR should be continued without interruption until the AED is ready to analyze rhythm or deliver a shock. Continuous chest compressions maintain blood flow to vital organs. Pause CPR only when the AED instructs for rhythm analysis or shock delivery. Incorrect Options: Option A - Continue 5 rounds of CPR @ 30:2 followed by application of AED: Do not wait to finish 5 cycles before using AED. Option C - Stop CPR and let them apply paddles: Stopping CPR delays perfusion. Option D - Handover the patient and leave: You must assist and continue CPR until the team takes over.

References:

Prepladder Notes

↑ *Back to this question in Part A*

Q145: What is the probable diagnosis based on the ECG given below? (Q793909)

A. Hypokalemia

B. Hyperkalemia

C. Hypothermia

D. Hypocalcemia

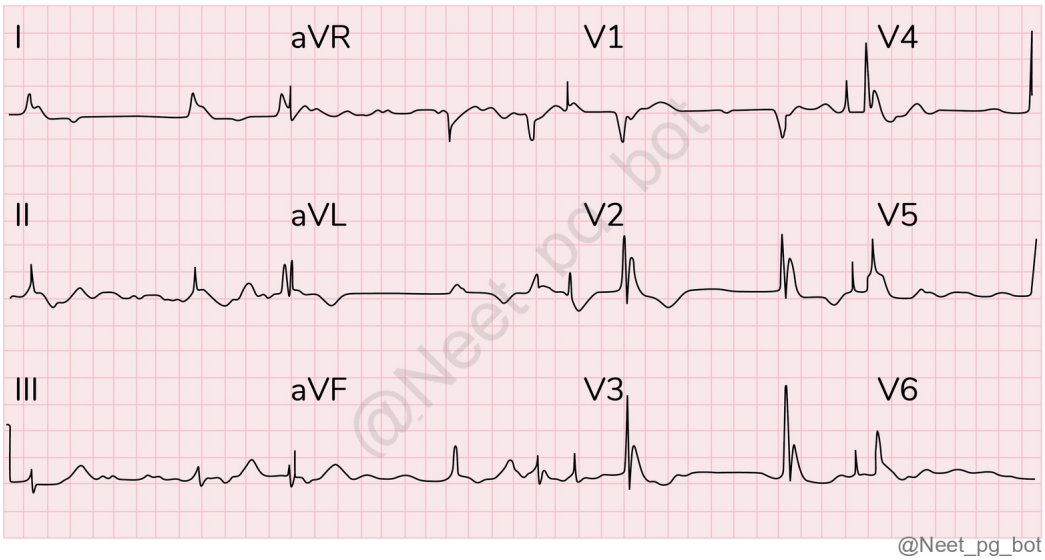

Correct Answer: C. Hypothermia

Explanation: Hypothermia is a medical emergency that occurs when the body temperature drops below 35°C (95°F). As the body temperature drops, various physiological functions are affected, including heart function. The ECG changes seen in hypothermia are due to alterations in the electrical conduction system of the heart and are often reversible with rewarming. The ECG findings shown above indicate it to be hypothermia; it includes bradycardia, prolonged PR interval, widened QRS complex, and J waves/Osborn waves (shown with red arrows on the ECG). Osborn waves/J waves are positive deflections at the end of the QRS complex in the leads V3-V6 and are sometimes referred to as the "camel hump" sign. Option A - Hypokalemia: Hypokalemia is an electrolyte imbalance that can also affect the heart and cause ECG changes. Hypokalemia can cause flattened or inverted T waves, ST segment depression, and U waves. However, in this ECG, the findings are not consistent with either hypokalemia or hyperkalemia. Option B - Hyperkalemia: Hyperkalemia is also an electrolyte imbalance that can affect the heart and cause ECG changes. Hyperkalemia can cause peaked T waves, widened QRS complex, and a sine wave pattern. Option D - Hypocalcemia: Hypocalcemia can also cause ECG changes, such as QT prolongation and ST segment depression. However, these changes are not seen in the given ECG, making hypocalcemia an unlikely diagnosis.

ECG Changes with Potassium Imbalance

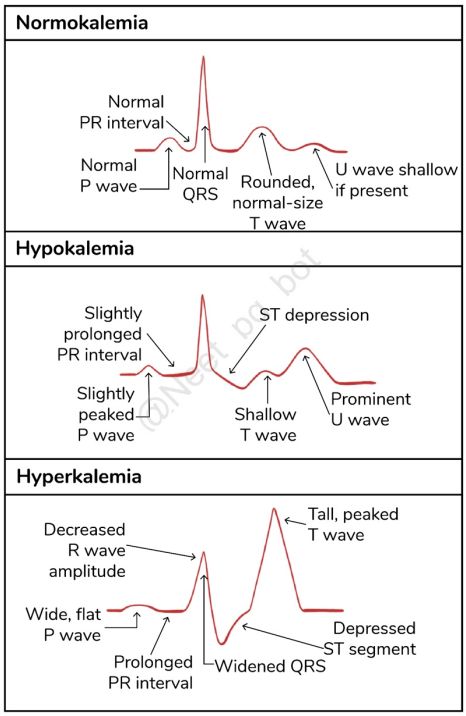

References:

.

↑ *Back to this question in Part A*

@Neet_pg_bot

Q146: A 19-year-old woman with no comorbidities presented with numbness and paraesthesia of the fingers along with the characteristic finding shown in the image below. She has no other illnesses, and she says these episodes occur when she is under excess stress or during cold temperatures . What is the most likely diagnosis ? (Q793945)

A. Primary Raynaud’s phenomenon

B. Secondary Raynaud’s phenomenon

C. Cold sores

D. Scleredema



Correct Answer: A. Primary Raynaud’s phenomenon

Explanation: Correct Option A - Primary Raynaud’s phenomenon: Primary Raynaud’s phenomenon is a condition in which the blood vessels in the fingers and toes narrow in response to cold temperatures or emotional stress. As a result, the fingers and toes may feel numb or cold and may turn white or blue. This condition occurs without any underlying disease and is more common in women than men. The patient in this case has no other comorbidities and has symptoms that are typical of Primary Raynaud's phenomenon. Incorrect Options: Options B, C, and D are incorrect.

References:

.

↑ *Back to this question in Part A*

@Neet_pg_bot

Q147: Identify the false statement regarding management of NSTEMI (Q793962)

A. Aspirin loading dose should be initated immediately

B. ACC/AHA guidelines call for either a P2Y12 inhibitor (clopidogrel, prasugrel or ticagrelor) as a class I recommendation

C. Glycoprotein IIB/IIIA inhibitors are useful adjuncts

D. Fibrinolytic therapy is useful in acute coronary syndrome without ST-segment elevation

Correct Answer: D. Fibrinolytic therapy is useful in acute coronary syndrome without ST-segment elevation

Explanation: Correct Option D - Fibrinolytic therapy is useful in acute coronary syndrome without ST-segment elevation: Fibrinolytic therapy is not recommended for NSTEMI because the underlying cause of the condition is not a complete occlusion of a coronary artery by a blood clot. Fibrinolytic therapy is typically reserved for patients with STEMI (ST-segment elevation myocardial infarction) who have evidence of a complete occlusion of a coronary artery. Incorrect Options: Option A - Aspirin loading dose should be initiated immediately: True. Aspirin is a cornerstone of the treatment of NSTEMI, and a loading dose of 162-325 mg should be given immediately upon diagnosis. Option B - ACC/AHA guidelines call for either a P2Y12 inhibitor (clopidogrel, prasugrel, or ticagrelor) as a class I recommendation: True. P2Y12 inhibitors are recommended as part of the standard treatment for NSTEMI, as they help to prevent platelet aggregation and reduce the risk of further cardiac events. Option C - Glycoprotein IIB/IIIA inhibitors are useful adjuncts: True. Glycoprotein IIB/IIIA inhibitors are potent antiplatelet agents that can be used as adjunctive therapy in patients with NSTEMI who are at high risk for adverse cardiac events.

References:

.

↑ *Back to this question in Part A*

@Neet_pg_bot

Q148: A 16-year-old female presents with recent episodes of palpitations and shortness of breath. On examination, she has a systolic murmur at the cardiac apex. Laboratory evaluation shows elevated anti-streptolysin O titers and erythrocyte sedimentation rate. An echocardiogram reveals moderate regurgitation in the mitral valve. A biopsy of her heart tissue is performed, and a pathology image is provided below. Which of the following statements about this pathology is not true? (Q828964)

A. Present in myocardium and endocardium only

B. Fibrinoid necrosis in the center

C. Uncommon in chronic stages

D. Anitschkow cells

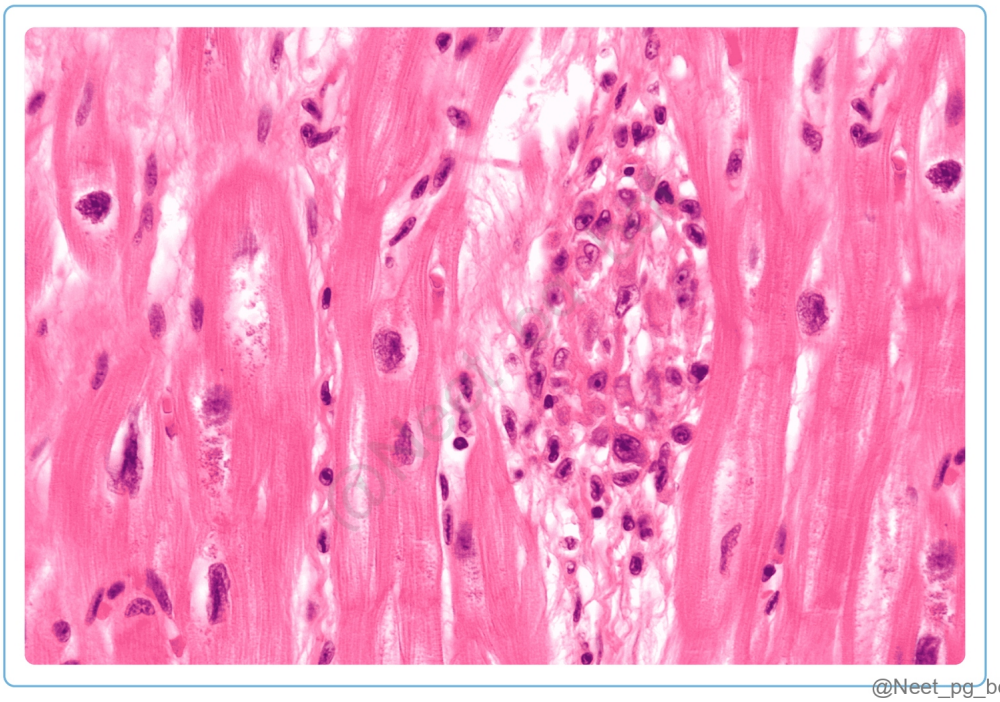

Correct Answer: A. Present in myocardium and endocardium only

Explanation: Correct Option A - Present in myocardium and endocardium only: This patient's presentation, including elevated anti-streptolysin O titers and elevated ESR with heart valve involvement, suggests the diagnosis of acute rheumatic fever. The mitral and aortic valves are mostly involved, with resultant regurgitations in the acute stages of the disease. The pathology image shows a microscopic view of cardiac tissue stained with H&E (Hematoxylin and Eosin). Within the myocardium, there are characteristic Aschoff bodies, which appear as granulomatous nodules containing central fibrinoid necrosis, foci of T lymphocytes, occasional plasma cells, and plump activated macrophages. During acute RF, Aschoff bodies may be found in any of the three layers of the heart, resulting in pericarditis , myocarditis, or endocarditis (pancarditis). {{caption_text}} Incorrect Options: Option B - Fibrinoid necrosis in the center: Aschoff bodies typically show fibrinoid necrosis in the center. Option C - Uncommon in chronic stages: Aschoff bodies are rarely seen in patients with chronic RHD because of the long intervals between the initial insult and the development of valve deformity. They are most often seen only in patients with acute RF. Option D - Anitschkow cells: Aschoff bodies are indeed surrounded by Anitschkow cells, the plump activated macrophages that have abundant cytoplasm and central round-to-ovoid nuclei (occasionally binucleate) in which the chromatin condenses into a central, slender, wavy ribbon (hence the designation “caterpillar cells”).

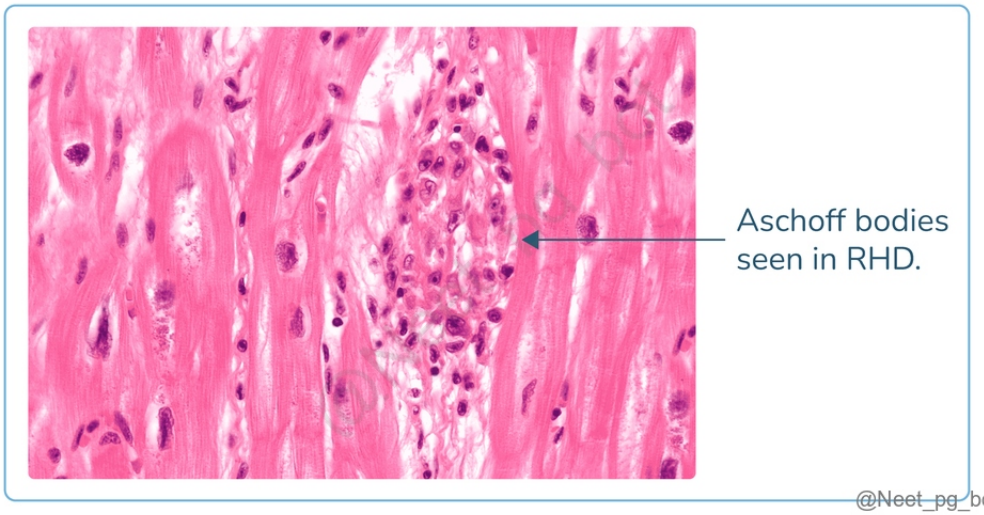

References:

Harrison's Textbook of Internal Medicine

↑ *Back to this question in Part A*

@Neet_pg_bot

• [02_Emergency Medicine] 010 Emergency Cardiovascular Care Protocols Bcls Acls Mechanical Ventilation And Causes Of Pulseless Electrical Activity

« Back to Folder Directory

[02_Emergency Medicine] 010 Emergency Cardiovascular Care Protocols Bcls Acls Mechanical Ventilation And Causes Of Pulseless Electrical Activity — Quick Jump

Q1 (p. 1461) *Q2 (p. 1462)* *Q3 (p. 1463)* *Q4 (p. 1464)* *Q5 (p. 1466)* *Q6 (p. 1467)*
Q7 (p. 1468) *Q8 (p. 1469)* *Q9 (p. 1470)* *Q10 (p. 1471)* *Q11 (p. 1472)* *Q12 (p. 1473)*
Q13 (p. 1473)

Q1: You are walking in a park when you notice an elderly person collapse in front of you. Which of the following is the first step in managment of this patient? (Q850935)

A. Initiate chest compressions

B. Check for scene safety

C. Call for help

D. Check carotid pulse

Correct Answer: B. Check for scene safety

■ *Listen (English)*

■ *Listen (Hindi)*

Explanation: Ensure scene safety: Before starting any BLS, ensure the environment is safe. Remove the victim from any immediate danger, such as standing water or traffic.

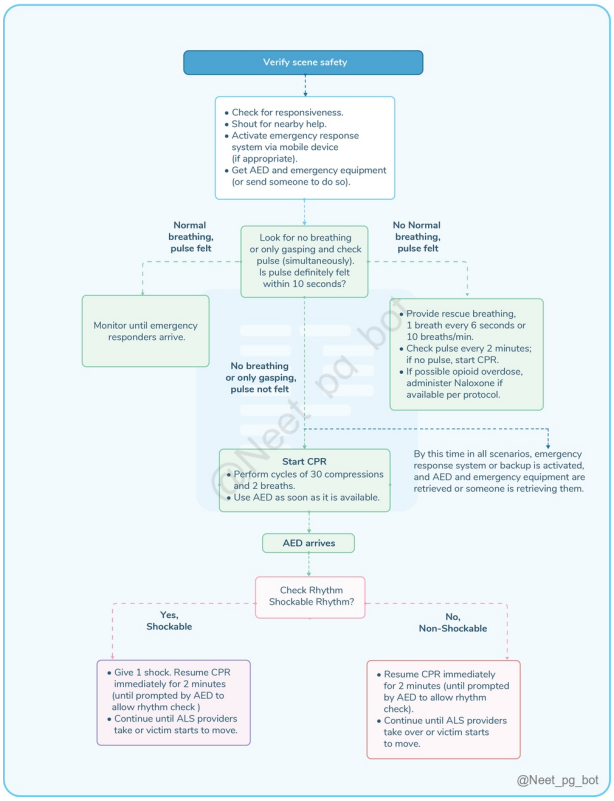

References:

Davidson's Principles and Practice of Medicine, 24th edition, Page 456, 457.

pmc.ncbi.nlm.nih.gov/articles/PMC5703000/

↑ *Back to this question in Part A*

@Neet_pg_bot

Q2: You are intern posted in ICU. Nurse calls you to assist for a sepsis patient whose ECG monitor is showing the following display and she has started chest compressions. Which of the following is the first step in managment of this patient? (Q850936)

A. Intubate the patient

B. Defibrillation

C. Cardioversion

D. Amiodarone

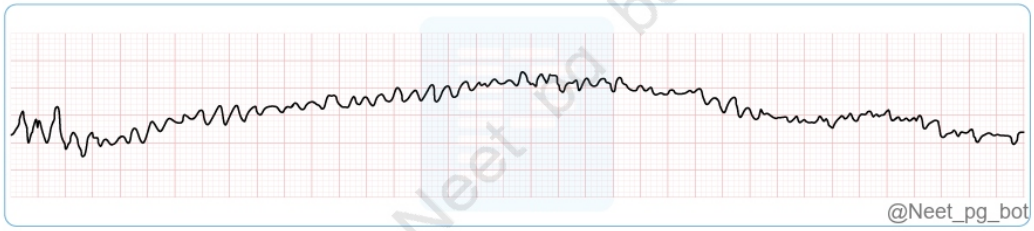

Correct Answer: B. Defibrillation

■ *Listen (English)*

■ *Listen (Hindi)*

Explanation: ECG shows chaotic, irregular waveforms without distinct QRS complexes or P waves seen in ventricular fibrillation. This is a shockable rhythm Immediate defibrillation is the primary treatment to restore a normal heart rhythm

References:

Harrison's principles of internal medicine, 21st Edition, Page 2258,2259.

Davidson's principles and practice of medicine, 24th Edition, Page 456.

www.ncbi.nlm.nih.gov/books/NBK513349/

↑ *Back to this question in Part A*

@Neet_pg_bot

Q3: 65 year old patient with anterior wall MI develops asystole. Which of the following is the first step in management of this patient? (Q850937)

A. Asses for reversible causes

B. Check pulse

C. Chest compressions @30:2

D. 10 ml of 1:10,000 Epinephrine

Correct Answer: C. Chest compressions @30:2

■ *Listen (English)*

■ *Listen (Hindi)*

Explanation: hest compressions @30:2: Asystole is a non-shockable cardiac arrest rhythm. According to ACLS guidelines, once asystole is identified and cardiac arrest is confirmed, the first immediate step is to start high-quality CPR with chest compressions (30:2 if no advanced airway). Early, effective chest compressions

maintain cerebral and coronary perfusion while further management is organized. Assess for reversible causes (Option A): Reversible causes (5 H's and 5 T's) are evaluated after CPR has been initiated, not before starting life-saving measures. Check pulse (Option B): A pulse check is done before diagnosing cardiac arrest. Once asystole is identified, CPR should be started immediately. 10 ml of 1:10,000 Epinephrine (Option D): Epinephrine is indicated in asystole but is given after CPR has been started, not as the first step.

References:

Davidson's principles and practice of medicine, 24th Edition, Page 458.

www.ncbi.nlm.nih.gov/books/NBK513349/

↑ *Back to this question in Part A*

@Neet_pg_bot

Q4: Assertion: Cardioversion is the preferred treatment for hemodynamic compromise caused by supraventricular tachycardia Reason: Synchronized direct current (DC) shock is administered at the peak of the R wave to avoid R on T phenomenon (Q850938)

A. Both assertion and reason are true, and the reason is a correct explanation of the assertion.

B. Both assertion and reason are true, but the reason is not a correct explanation of the assertion.

C. The assertion is true, but the reason is false.

D. The assertion is false, but the reason is true.

Correct Answer: A. Both assertion and reason are true, and the reason is a correct explanation of the assertion.

■ *Listen (English)*

■ *Listen (Hindi)*

Explanation: of the assertion.

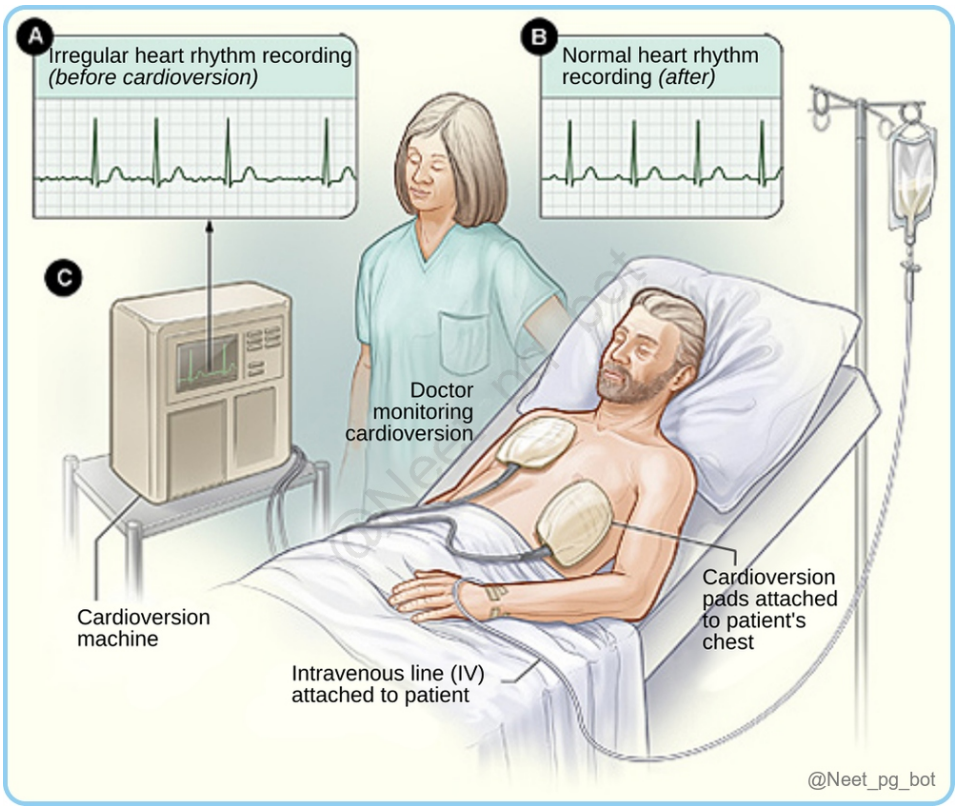

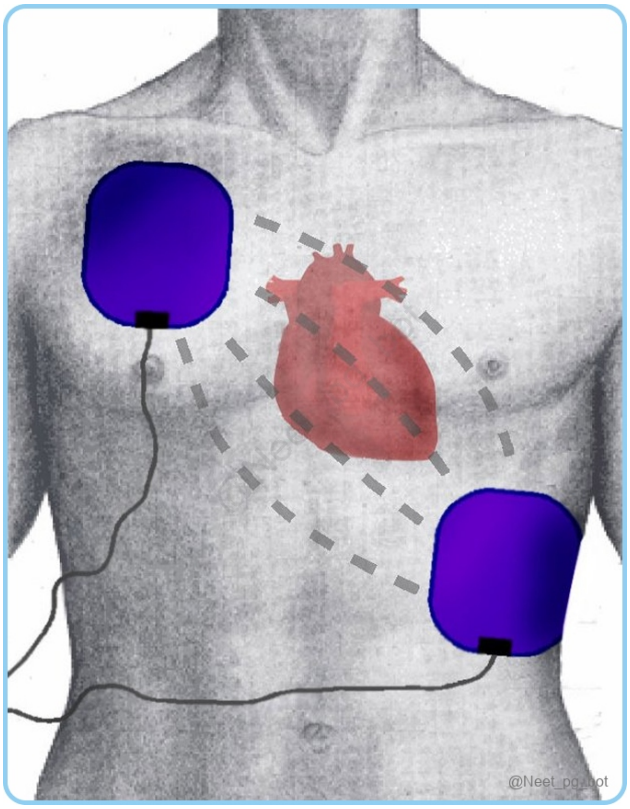

References:

Davidson's principles and practice of medicine, 24th Edition, Page: 482.

www.ncbi.nlm.nih.gov/books/NBK482173/

www.ncbi.nlm.nih.gov/books/NBK499899/

www.ncbi.nlm.nih.gov/pmc/articles/PMC2813644/

↑ *Back to this question in Part A*

@Neet_pg_bot

Q5: You are resuscitating a patient with following ECG tracing in ER. CPR is given @30:2 and 10 ml of 1: 10,000 adrenaline is given twice at interval of 3 minutes but the tracing is still the same. What is next best step in management of this patient? (Q850939)

A. Repeat 10 ml of 1: 10,000 adrenaline iv

B. Repeat 1 ml of 1: 10,000 adrenaline iv

C. Give DC shock 200J biphasic

D. Give DC shock 360J monophasic

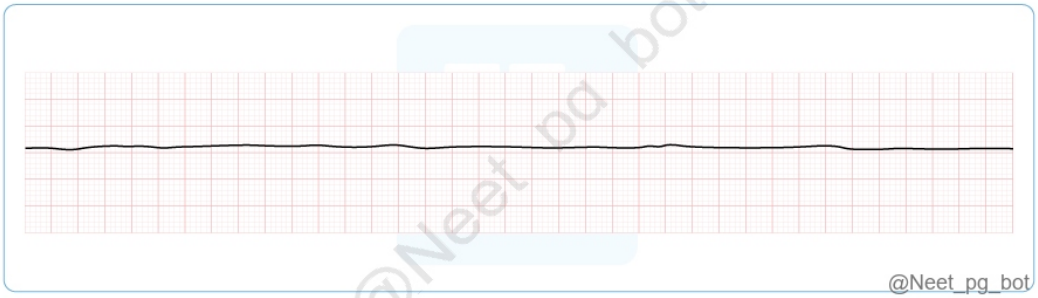

Correct Answer: A. Repeat 10 ml of 1: 10,000 adrenaline iv

■ *Listen (English)*

■ *Listen (Hindi)*

Explanation: Repeated adrenaline administration in asytole may convert this flat line ECG into ventricular fibrillation which can then be given defibrillation to restore normal sinus rhythm.

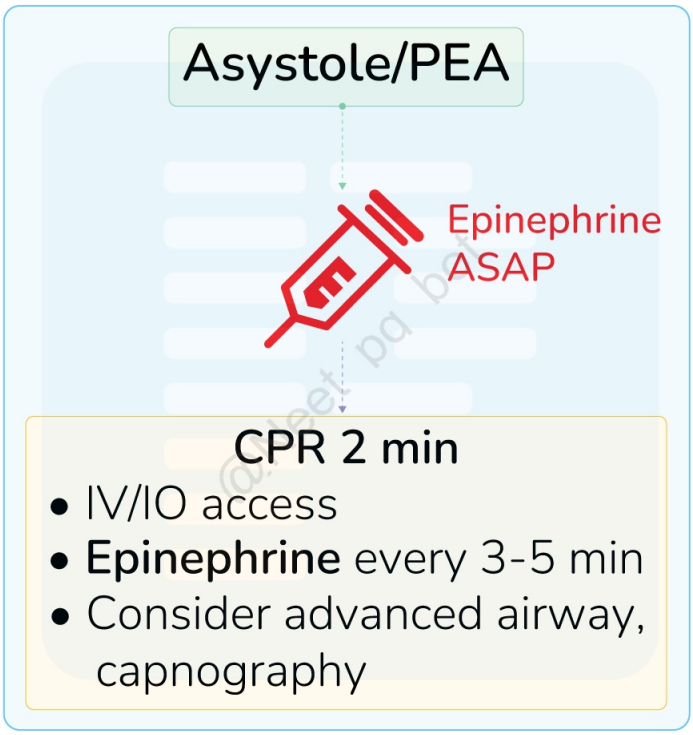

References:

Harrison's principles of internal medicine, 21st Edition, Page: 2262,2263.

Davidson's principles and practice of medicine, 24th Edition, Page: 482.

www.ncbi.nlm.nih.gov/books/NBK430866/

↑ *Back to this question in Part A*

@Neet_pg_bot

Q6: Blood pressure of a 65-year-old male in the ICU crashes. ECG tracing shows Ventricular fibrillation. 200 J biphasic shock is given to patient. Which of the following is next best step for management of this patient? (Q850940)

A. Amiodarone

B. Start CPR

C. Secure advanced airway

D. Epinephrine

Correct Answer: B. Start CPR

■ *Listen (English)*

■ *Listen (Hindi)*

Explanation: Immediately after defibrillation, the rhythm takes some time to reset to normal. During this time, chest compressions must continue @30:2. Amiodarone (Option A): Given after CPR and defibrillation if VF persists. Secure advanced airway (Option C): Done during ongoing CPR if needed, but not the immediate next step. Epinephrine (Option D): Administered after the first CPR cycle, not immediately after shock.

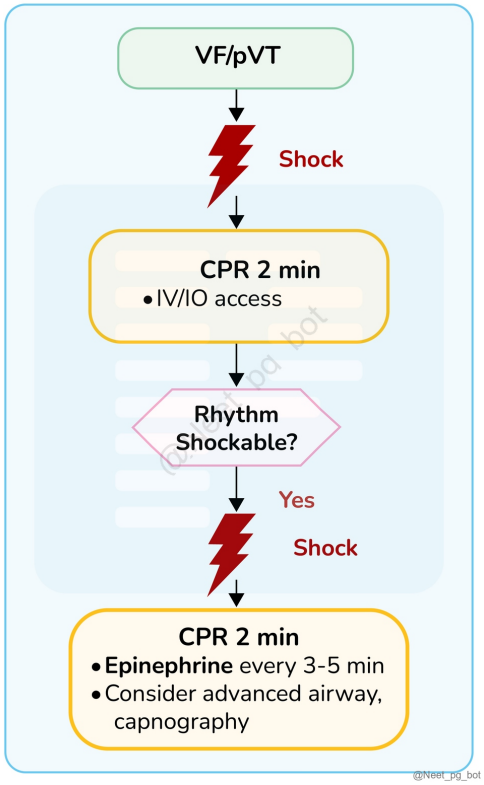

References:

Harrison's principles of internal medicine, 21st Edition, Page 2063, 2262, 2263

Davidson's principles and practice of medicine, 24th Edition, Page 481, 482

www.ncbi.nlm.nih.gov/books/NBK430866/

↑ *Back to this question in Part A*

@Neet_pg_bot

Q7: An alcoholic is admitted with diagnosis acute pancreatitis. On day 2 evening, he is shifted to ICU for Ventilator assistance for ARDS. Which of the following statements

is not correct regarding the management of this patient? (Q850941)

A. Set tidal volume of 12 mL/kg lean body weight

B. Prone positioning

C. Set FiO2 at 1.0 and then titrate down to maintain pO2 55- 80 mm Hg

D. Adjust Respiratory rate to keep pH > 7.3

Correct Answer: A. Set tidal volume of 12 mL/kg lean body weight

■ *Listen (English)*

■ *Listen (Hindi)*

Explanation: Tidal volume should be kept at 6 ml per kg of lean body weight to enable. FiO2 (Fraction of Inspired Oxygen) is initially set at 1.0 (100% oxygen) and then reduced to the lowest level needed to maintain adequate oxygenation. Permissive hypercapnia is allowed, so keeping a pH of >7.3 is fine while adjusting the respiratory rate. Ventilator Settings for ARDS Parameter Recommended Setting Mode Volume Assist-Control (AC) or Pressure-Control Ventilation Tidal Volume (VT) 4-6 mL/kg of predicted body weight (PBW) - Prevents barotrauma/volutrauma Plateau Pressure ≤ 30 cm H 2 O - to reduce lung injury PEEP use PEEP -FiO 2 titration table (typically 5 -15 cm H 2 O, can go up to 20 in severe ARDS) FiO2 Strat with 100% (1.0), then titrate down to maintain SpO 2 88-95% or PaO 2 55-80 mmHg Respiratory Rate Adjust to maintain pH ≥ 7.30 (can be up to 35/min); permissive hypercapnia is allowed Driving Rate Keep <15 cm H 2 O - (Driving pressure = Plateau pressure - PEEP) I:E Ratio Typically 1:1 to 1:2 (can prolong expiration if needed) Prone Positioning Consider if PaO 2 /FiO 2 < 150 despite optimal settings

References:

Harrison’s Principles of Internal Medicine, 21st Edition, Page 2230

↑ *Back to this question in Part A*

@Neet_pg_bot

Q8: A 58-year-old male patient with chronic obstructive pulmonary disease (COPD) is admitted to the hospital and placed on mechanical ventilation. His arterial blood gas analysis shows the following values: PaO2: 86 mmHg, PaCO2: 50 mmHg and pH: 7.32. Which of the following management strategies should be prioritized for this patient? (Q850942)

A. Decrease the tidal volume to improve ventilation.

B. Increase the FiO2 immediately to avoid oxygen toxicity.

C. Increase PEEP to improve oxygenation and maintain lung recruitment.

D. Increase the expiratory time to promote CO2 washout

Correct Answer: D. Increase the expiratory time to promote CO2 washout

■ *Listen (English)*

■ *Listen (Hindi)*

Explanation: In a mechanically ventilated COPD patient, the most appropriate strategy is to increase expiratory time to enhance CO■ washout and prevent air trapping . These patients have prolonged airway resistance, and allowing insufficient expiratory time can lead to dynamic hyperinflation and auto-PEEP , worsening ventilation. Decreasing tidal volume (Option A) would reduce minute ventilation and worsen hypercapnia. Increasing FiO■ (Option B) is unnecessary as the patient's PaO■ is adequate, and excessive oxygen may depress respiratory drive in COPD. While increasing PEEP (Option C) may help alveolar recruitment in restrictive lung diseases, it must be used cautiously in COPD due to the risk of worsening air trapping. Therefore, optimizing expiratory time by reducing respiratory rate and adjusting the I: E ratio is the safest and most effective intervention in this scenario.

References:

https://www.ncbi.nlm.nih.gov/books/NBK606131/

https://www.ncbi.nlm.nih.gov/books/NBK448186/#

https://www.ncbi.nlm.nih.gov/books/NBK536919/#

↑ *Back to this question in Part A*

@Neet_pg_bot

Q9: A 35-year-old male with Guillain-Barré Syndrome develops progressive respiratory muscle weakness and is placed on mechanical ventilation. Which of the following ventilator modes is most appropriate in this setting? (Q850943)

A. Pressure Support Ventilation

B. Synchronized Intermittent Mandatory Ventilation

C. Assist-Control Mechanical Ventilation

D. Continuous Positive Airway Pressure

Correct Answer: C. Assist-Control Mechanical Ventilation

■ *Listen (English)*

■ *Listen (Hindi)*

Explanation: In Guillain-Barré syndrome with respiratory failure, Assist-Control ventilation provides full ventilatory support, ensuring adequate tidal volume and respiratory rate for patients with progressive muscle weakness . Pressure Support Ventilation (Option A): Requires spontaneous breathing, not suitable for severe weakness. Synchronized Intermittent Mandatory Ventilation (Option B): Provides partial support; may be insufficient in rapidly worsening paralysis. Continuous Positive Airway Pressure (Option D): Only maintains airway pressure in spontaneously breathing patients, not for full ventilation support.

References:

www.ncbi.nlm.nih.gov/books/NBK539742/

www.ncbi.nlm.nih.gov/books/NBK441856/#

www.ncbi.nlm.nih.gov/books/NBK448186/

link.springer.com/article/10.1007/s10877-023-01019-z

pmc.ncbi.nlm.nih.gov/articles/PMC6284234/#

pubmed.ncbi.nlm.nih.gov/16079905/

www.sciencedirect.com/topics/nursing-and-health-professions/intermittent-mandatory-ventilation

↑ *Back to this question in Part A*

@Neet_pg_bot

Q10: A 60-year-old male is on mechanical ventilation for acute hypoxemic respiratory failure (Type 1). His latest ABG shows: pH: 7.43, PaCO■: 38 mmHg, PaO■: 54 mmHg, HCO■■: 24 mEq/L. Which of the following changes should be made to improve his oxygenation? (Q850944)

A. Increase tidal volume

B. Increase FiO■

C. Decrease respiratory rate

D. Increase minute ventilation

Correct Answer: B. Increase FiO■

■ *Listen (English)*

■ *Listen (Hindi)*

Explanation: The patient has Type 1 respiratory failure (low PaO■ with normal PaCO■), indicating a pure oxygenation problem . Increasing FiO■ is the most direct and effective way to raise PaO■. It is also the latest and simplest way to improve oxygenation. It provides an immediate increase in alveolar oxygen concentration and thus

raises PaO■ quickly. Always titrate FiO■ up to 60% (0.6) before increasing PEEP. Increasing tidal volume (A) or minute ventilation (D) would reduce CO■, not help oxygenation. Decreasing RR (C) would worsen oxygenation by lowering minute ventilation and overall alveolar exposure to oxygen.

References:

pmc.ncbi.nlm.nih.gov/articles/PMC7782574/#

↑ *Back to this question in Part A*

@Neet_pg_bot

Q11: A 28-year-old male is admitted to the ICU after sustaining blunt chest trauma in a motor vehicle accident. Chest imaging reveals pulmonary contusions. After 48 hours, he develops severe hypoxemia with PaO■/FiO■ ratio of 110, bilateral infiltrates on chest X-ray, and no signs of left heart failure. What is the most appropriate next step in management? (Q850945)

A. Insert a wide-bore needle in the fifth intercostal space

B. Start intravenous furosemide to reduce pulmonary edema

C. Begin low tidal volume mechanical ventilation

D. Initiate high-flow nasal cannula oxygen therapy

Correct Answer: C. Begin low tidal volume mechanical ventilation

■ *Listen (English)*

■ *Listen (Hindi)*

Explanation: This patient has developed ARDS, likely secondary to pulmonary contusion, confirmed by bilateral infiltrates and low PaO■/FiO■ ratio. The cornerstone of ARDS management is lung-protective ventilation using low tidal volumes (4–6 mL/kg of predicted body weight) to prevent volutrauma and barotrauma. Wide-bore needle (Option A) is used for tension pneumothorax, which would present with absent breath sounds and hemodynamic compromise, not diffuse infiltrates. Lasix (Option B) may be harmful here, as ARDS is due to inflammatory alveolar damage, not fluid overload. HFNC (Option D) is insufficient in moderate-to-severe ARDS, where invasive ventilation is required to maintain oxygenation and protect lungs.

References:

Harrison’s Principles of Internal Medicine, 21st Edition, Page 2231,2232

↑ *Back to this question in Part A*

@Neet_pg_bot

Q12: A 45-year-old male presents with acute shortness of breath, orthopnea, and bilateral pulmonary crackles. Work up shows elevated Pro-NT- BNP levels and ABG shows type 1 respiratory failure with pO2=60 mm Hg. Which of the following is best to improve his oxygenation status? (Q850946)

A. High-flow nasal cannula

B. Urgent intubation

C. Non-rebreather mask

D. NIV using Bi-PAP

Correct Answer: D. NIV using Bi-PAP

■ *Listen (English)*

■ *Listen (Hindi)*

Explanation: The patient has acute decompensated heart failure (orthopnea, crackles, elevated NT-proBNP) with Type 1 respiratory failure (hypoxemia without hypercapnia). BiPAP (Bilevel Positive Airway Pressure) helps by: Providing positive pressure during inspiration (IPAP) and expiration (EPAP) , improving oxygenation and offloading the failing left ventricle. Reducing preload and afterload , thus relieving pulmonary edema and improving gas exchange. HFNC (Option A) improves oxygenation but lacks the positive pressure support needed in pulmonary edema. Invasive ventilation (Option B) is reserved for severe respiratory distress, altered mental status, or failure of NIV. Non-rebreather mask (Option C): Delivers oxygen but offers no positive pressure support, less effective in pulmonary edema.

References:

https://www.ncbi.nlm.nih.gov/books/NBK482178/#

https://www.ncbi.nlm.nih.gov/books/NBK470429/

↑ *Back to this question in Part A*

@Neet_pg_bot

Q13: A 68-year-old male with a history of COPD presents with increasing dyspnea, productive cough, and confusion. Arterial blood gas (ABG) shows pH 7.30, pCO■ 58 mmHg, and pO■ 55 mmHg. He is hemodynamically stable. What is the next best step in management? (Q850947)

A. Immediate endotracheal intubation

B. Noninvasive positive-pressure ventilation

C. Intravenous antibiotics only

D. High-flow nasal cannula oxygen therapy

Correct Answer: B. Noninvasive positive-pressure ventilation

■ *Listen (English)*

■ *Listen (Hindi)*

Explanation: This patient with COPD exacerbation shows moderate hypercarbia (pH 7.30, pCO■ 58 mmHg) and respiratory acidosis , which is an indication of NIV . NIV, such as BiPAP, can reduce the work of breathing, improve gas exchange, and prevent the need for intubation. Since the patient is hemodynamically stable and able to protect his airway, NIV is the appropriate next step. Immediate endotracheal intubation (Option A) : Reserved for severe respiratory acidosis (pH < 7.2) or failed NIV. This patient's pH is 7.30, indicating moderate acidosis. Intravenous antibiotics only (Option C) : While antibiotics may be needed, they do not address acute respiratory failure or hypercarbia. High-flow nasal cannula oxygen therapy (Option D) : Helps with oxygenation but does not manage hypercapnia or improve ventilation as NIV does in COPD exacerbations.

References:

Harrison's Principles of Internal Medicine 21st edition Page 2231

↑ *Back to this question in Part A*

@Neet_pg_bot

• [02_Emergency Medicine] 011 Massive Transfusion Protocol Ards Snakebite Aha Updates Altitude Sickness

« Back to Folder Directory

[02_Emergency Medicine] 011 Massive Transfusion Protocol Ards Snakebite Aha Updates Altitude Sickness — Quick Jump

Q1 (p. 1475)	*Q2 (p. 1476)*	*Q3 (p. 1477)*	*Q4 (p. 1477)*	*Q5 (p. 1479)*	*Q6 (p. 1480)*
Q7 (p. 1480)	*Q8 (p. 1481)*	*Q9 (p. 1482)*	*Q10 (p. 1483)*	*Q11 (p. 1484)*	*Q12 (p. 1485)*
Q13 (p. 1486)	*Q14 (p. 1487)*	*Q15 (p. 1488)*	*Q16 (p. 1488)*	*Q17 (p. 1489)*	*Q18 (p. 1490)*

Q1: A 60-year-old man collapses at a shopping mall. Bystanders start CPR and activate EMS. On arrival, paramedics find the patient unresponsive, pulseless, and in ventricular fibrillation on the monitor. What is the next best step for his managment? (Q850671)

A. Begin chest compressions and administer 1 mg epinephrine immediately, then attempt defibrillation

B. Deliver one shock with a biphasic defibrillator followed by immediate chest compressions, then secure airway

C. Deliver three stacked shocks followed by pulse check and atropine administration

D. Perform synchronized cardioversion followed by amiodarone if rhythm persists

Correct Answer: B. Deliver one shock with a biphasic defibrillator followed by immediate chest compressions, then secure airway

■ *Listen (English)*

■ *Listen (Hindi)*

Explanation: This patient is in cardiac arrest with ventricular fibrillation (a shockable rhythm) . According to ACLS guidelines , the immediate next step is: Immediate defibrillation (one shock) Resume CPR for 2 minutes without pulse check Then consider airway and medications Chest compressions and administer 1 mg epinephrine immediately, then attempt defibrillation (Option A): Epinephrine is not first-line in shockable rhythms and should be given after the second defibrillation cycle. Stacked shocks followed by pulse check and atropine administration (Option C) refers to an outdated practice; stacked shocks are no longer recommended. Synchronized cardioversion followed by amiodarone if rhythm persists (Option D): Synchronized cardioversion is used for organized rhythms like SVT or VT with a pulse, not VF. Prompt defibrillation + CPR is the foundation of VF management in current guidelines.

References:

www.ncbi.nlm.nih.gov/books/NBK544231/

resident360.nejm.org/content-items/defibrillation-strategies-for-refractory-ventricular-fibrillation

www.nejm.org/doi/full/10.1056/NEJMoa2207304

↑ *Back to this question in Part A*

@Neet_pg_bot

Q2: A 35-year-old male mountaineer plans a rapid ascent to an altitude of 4500 meters for a climbing expedition. He has a history of experiencing symptoms like fatigue, non-productive cough, and difficulty breathing during previous high-altitude trips. Based on the scenario, which of the following strategies should the mountaineer implement to effectively prevent symptoms, and what is the main treatment he should consider if symptoms develop? (Q850690)

A. Maintain an average altitude gain exceeding 300 m per day, and begin immediate treatment with acetazolamide

B. Ascend rapidly without acclimatization, and use supplemental oxygen if symptoms develop

C. Ascend slowly with a maximum altitude gain of 300 m per day, and prioritize descent of 1000 meters if symptoms occur

D. Use alcohol to relax during the ascent, and rely solely on portable hyperbaric chambers if symptoms arise

Correct Answer: C. Ascend slowly with a maximum altitude gain of 300 m per day, and prioritize descent of 1000 meters if symptoms occur

■ *Listen (English)*

■ *Listen (Hindi)*

Explanation: The mountaineer is at risk of High Altitude Pulmonary Edema (HAPE) due to rapid ascent and previous symptoms, which include fatigue, cough, and dyspnea. Effective prevention involves a slow ascent with a maximum altitude gain of 300 m per day and the primary treatment for symptoms is immediate descent of 1000 meters to alleviate hypoxia and reduce pulmonary edema. Maintain an average altitude gain exceeding 300 m per day, and begin immediate treatment with acetazolamide. (Option A): This contradicts the recommendation to limit altitude gain to 300 m per day for prevention, and acetazolamide is not effective for HAPE treatment. Ascend rapidly without acclimatization, and use supplemental oxygen if symptoms develop. (Option B): Rapid ascent increases the risk of HAPE. While supplemental oxygen may help, it is not the primary treatment; immediate descent is crucial. Use alcohol to relax during the ascent, and rely solely on portable hyperbaric chambers if symptoms arise. (Option D): Alcohol should be avoided as it can worsen symptoms. Relying solely on hyperbaric chambers is not recommended without descent as a primary intervention.

References:

www.ncbi.nlm.nih.gov/books/NBK430819/

pubmed.ncbi.nlm.nih.gov/20417343/

pmc.ncbi.nlm.nih.gov/articles/PMC3617508/

↑ *Back to this question in Part A*

@Neet_pg_bot

Q3: A 28-year-old male skier is found unresponsive in the snow with a core body temperature of 27°C (81°F). Which of the following is NOT a treatment approach for managing his hypothermia? (Q850682)

A. Administer warm intravenous fluids at 40-42°C

B. Utilize extracorporeal membrane oxygenation to provide rewarming and circulatory support

C. Use passive external rewarming by layering him with wet clothing

D. Perform active internal rewarming using warm saline lavage of body cavities

Correct Answer: C. Use passive external rewarming by layering him with wet clothing

■ *Listen (English)*

■ *Listen (Hindi)*

Explanation: The skier's unresponsiveness and core body temperature of 27°C (81°F) indicate severe hypothermia, defined as a drop in core body temperature below 28°C. This condition disrupts the body's ability to maintain homeostasis, leading to potential organ failure and life-threatening complications. Layering with wet clothing can exacerbate heat loss, as wet materials conduct heat away from the body more efficiently than dry materials. Effective treatment for hypothermia requires removing wet clothing and using dry insulation to help retain body heat. Warm intravenous fluids at 40–42°C (Option A): Standard method for active internal rewarming. Extracorporeal membrane oxygenation (Option B): Used in severe hypothermia with cardiac instability. Active internal rewarming using warm saline lavage of body cavities (Option D): Effective core rewarming technique in severe cases.

References:

www.ncbi.nlm.nih.gov/books/NBK545239/

↑ *Back to this question in Part A*

@Neet_pg_bot

Q4: A 40-year-old male fisherman is rescued after being exposed to cold water for several hours. Upon examination, his core body temperature is 29°C (84°F). He shows signs of lethargy, dilated pupils, and a slow heart rate. Which of the following statements about his condition is false? (Q850680)

A. Mild hypothermia typically presents with symptoms like shivering and increased muscle tone.

B. In moderate hypothermia shivering generally stops as the body temperature approaches 30°C.

C. Severe hypothermia can lead to unresponsiveness and increased risk of cardiac dysrhythmias.

D. Osborn waves are typically absent in hypothermic patients with temperatures below 28°C.

Correct Answer: D. Osborn waves are typically absent in hypothermic patients with temperatures below 28°C.

■ *Listen (English)*

■ *Listen (Hindi)*

Explanation: This patient has hypothermia , characterized by a core body temperature of 29°C, leading to symptoms such as lethargy, dilated pupils, and bradycardia. This condition results from prolonged exposure to cold, affecting the body's ability to maintain normal temperature and function. Osborn (J) waves are often present in hypothermic patients and can indicate the severity of the condition. Mild hypothermia (32–35°C / 90–95°F) (Option A): Hunger, nausea, fatigue, shivering, pale/dry skin, ↑BP, HR, respiration, and muscle tone. Cognitive decline, memory impairment, ataxia, dysarthria. Shivering may stop if energy stores are low. Cold-induced diuresis. Moderate hypothermia (28–32°C / 82–90°F) (Option B): Lethargy, CNS depression (hyporeflexia, dilated pupils), shivering stops at 30–32°C, paradoxical undressing. ↑Risk of atrial fibrillation, hypotension, bradycardia, bradypnea. Severe hypothermia (<28°C / <82°F) (Option C): Unresponsiveness, ↓cerebral blood flow, hypotension, bradycardia, ↓cardiac output. Atrial/junctional dysrhythmias, pulmonary congestion, oliguria, areflexia. Risk of cardiorespiratory failure and death. {{caption_text}}

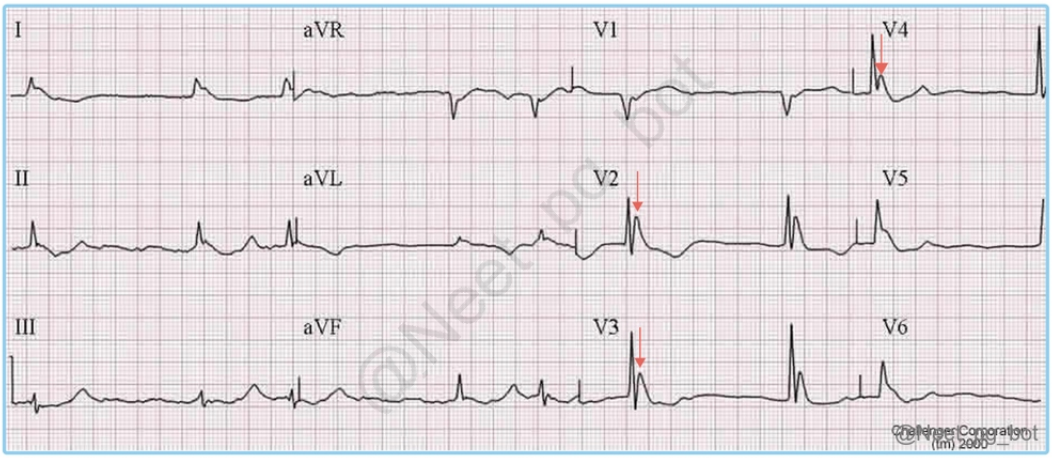

References:

www.ncbi.nlm.nih.gov/books/NBK545239/

↑ *Back to this question in Part A*

@Neet_pg_bot

Q5: A 30-year-old male hiker ascends rapidly from sea level to an altitude of 4500 meters over 24 hours. Two days after his arrival, he begins to experience increasing fatigue, a non-productive cough, and difficulty breathing during physical activity. His oxygen saturation is 60% on examination, and he exhibits tachypnea and cyanosis. Based on the scenario, which factors do not contribute to the patient's clinical features? (Q850677)

A. Low hypoxic ventilatory response (HVR)

B. Use of sleep medications during ascent

C. Recent heavy physical exertion prior to ascent

D. Extended acclimatization period before ascent

Correct Answer: D. Extended acclimatization period before ascent

■ *Listen (English)*

■ *Listen (Hindi)*

Explanation: The patient’s symptoms, including fatigue, cough, tachypnea, and low oxygen saturation, are characteristic of acute HAPE, a severe form of altitude sickness resulting from hypoxia and noncardiogenic pulmonary edema. An extended acclimatization period is protective against altitude sickness. It allows the body to adjust to lower oxygen levels gradually, thereby reducing the risk of developing HAPE (High altitude pulmonary edema). Low hypoxic ventilatory response (Option A) : A low HVR is a significant risk factor for developing altitude-related illnesses, including HAPE. It impairs the body's ability to respond to low oxygen levels, making it more likely for the patient to experience severe hypoxia and associated symptoms. Use of sleep medications during ascent (Option B) : Sleep medications can depress the respiratory drive, leading to a reduced HVR. This can worsen hypoxia at high altitudes, increasing the risk of HAPE and contributing to the patient's clinical features. Recent heavy physical exertion prior to ascent (Option C) : Engaging in heavy physical exertion can lead to fatigue and increased susceptibility to altitude sickness, including HAPE. This factor can contribute to the worsening of symptoms once at high altitude.

References:

www.ncbi.nlm.nih.gov/books/NBK430819/

↑ *Back to this question in Part A*

@Neet_pg_bot

Q6: A 34-year-old woman, 36 weeks pregnant, is brought to the emergency department after collapsing at home. Upon arrival, she is unresponsive and in cardiac arrest. CPR is initiated immediately. The team begins advanced cardiac life support for pregnancy. Which of the following is the correct to optimize maternal and fetal outcomes? (Q850676)

A. Delay chest compressions to position the patient for cesarean section.

B. Perform left uterine displacement.

C. Administer 2 mg epinephrine IV every 5 minutes.

D. Delay defibrillation to avoid harm to the fetus.

Correct Answer: B. Perform left uterine displacement.

■ *Listen (English)*

■ *Listen (Hindi)*

Explanation: Relieving aortocaval compression is essential to improve venous return and cardiac output. Left uterine displacement (LUD) is crucial in pregnancy to optimize maternal resuscitation efforts. In cardiac arrest, CPR replaces the heart's pumping . CPR works only if enough blood returns to the chest . Pregnancy causes the uterus to compress the IVC , reducing venous return. Left uterine displacement relieves this compression. This improves venous return , making CPR more effective . Cardiac Arrest in Pregnancy Position: Full left lateral decubitus to relieve aortocaval compression. Oxygen: 100% via face mask. IV Access: Above diaphragm. Treat Causes: Identify and address precipitating factors. Location: Do not transport for cesarean ; manage on site. (Option A) CPR: ≥100/min, depth ≥5 cm, full recoil; limit interruptions. Uterus: Continuous manual LUD if ≥umbilicus. Defibrillation: Same as nonpregnant, biphasic 120–200 J. (Option D) Drugs: Amiodarone 300 mg IV for refractory VF/VT; repeat 150 mg as needed. Epinephrine 1 mg IV/IO q3–5 min preferred over vasopressin. (Option C) Cesarean: If resuscitation fails and GA >23 weeks, deliver within 4 min. Fetal survival: Best if delivery within 5 min of arrest.

References:

www.ahajournals.org/doi/full/10.1161/cir.0000000000000300

pmc.ncbi.nlm.nih.gov/articles/PMC2700584/

↑ *Back to this question in Part A*

@Neet_pg_bot

Q7: A 58-year-old man suffers a witnessed cardiac arrest in the emergency room. After 3 cycles of CPR , iv epinephrine, 2 defibrillation shocks, he achieves return of

spontaneous circulation (ROSC). He is now unresponsive, with a blood pressure of 88/50 mmHg and SpO■ of 92% on 10 L/min oxygen by face mask. Which of the following is the most appropriate next step in management? (Q850674)

A. Administer 1 mg epinephrine IV every 3–5 minutes and continue chest compressions

B. Perform immediate coronary angiography and stenting regardless of ECG findings

C. Optimize oxygenation and ventilation, and assess for need of vasopressors and targeted temperature management

D. Discontinue resuscitation efforts and observe, as ROSC has been achieved

Correct Answer: C. Optimize oxygenation and ventilation, and assess for need of vasopressors and targeted temperature management

■ *Listen (English)*

■ *Listen (Hindi)*

Explanation: Once ROSC is achieved, the next priority is post-cardiac arrest care, which includes ensuring adequate oxygenation (SpO■ >94%), avoiding hyperoxia, supporting blood pressure (e.g., fluids, vasopressors if MAP <65 mmHg), and considering targeted temperature management (TTM) if the patient is comatose. The American Heart Association (AHA)–compliant post-ROSC bundle includes optimizing oxygenation and ventilation, assessing the need for vasopressors, and implementing targeted temperature management. Epinephrine administrations and chest compressions (Option A) is incorrect because epinephrine and CPR are no longer indicated after ROSC. Immediate coronary angiography and stenting (Option B) is premature unless STEMI is evident on ECG. Discontinue resuscitation efforts and observe, as ROSC has been achieved (Option D) ignores the fact that ROSC patients remain critically ill and need intensive support.

References:

pubmed.ncbi.nlm.nih.gov/36949360/

↑ *Back to this question in Part A*

@Neet_pg_bot

Q8: A 55-year-old man experiences a sudden cardiac arrest while jogging in a park. A bystander witnesses the collapse. According to the Adult OHCA Chain of Survival, what is the correct sequence of actions performed by the emergency responders in this scenario? (Q850673)

A. Early recognition and Prevention → Activation of Emergency Response → Defibrillation → High-Quality CPR → Recovery→ Post-Cardiac Arrest Care

B. Activation of Emergency Response → High-Quality CPR → Defibrillation → Advanced Resuscitation → Post-Cardiac Arrest Care → Recovery

C. High-Quality CPR → Activation of Emergency Response → Advanced Resuscitation → Defibrillation → Post-Cardiac Arrest Care → Recovery

D. High-Quality CPR → Activation of Emergency Response → Defibrillation → Advanced Resuscitation → Post-Cardiac Arrest Care → Recovery

Correct Answer: B. Activation of Emergency Response → High-Quality CPR → Defibrillation → Advanced Resuscitation → Post-Cardiac Arrest Care → Recovery

■ *Listen (English)*

■ *Listen (Hindi)*

Explanation: The Adult OHCA (Out-of-Hospital Cardiac Arrest) Chain of Survival Mnemonic : All Cool Doctors Are Perfect Rescuers {{caption_text}}



@Neet_pg_bot

References:

cpr.heart.org/en/resuscitation-science/cpr-and-ecc-guidelines/algorithms#pediatrics

↑ *Back to this question in Part A*

@Neet_pg_bot

Q9: 4-year-old child is found unresponsive at home. The parents initiate CPR, and the child is transported to the emergency department. Upon arrival, the medical team begins CPR and attaches a defibrillator. The rhythm check shows asystole. What is the next step in managing this child according to the Pediatric cardiac arrest Algorithm? (Q850672)

A. Deliver a shock immediately

B. Administer Amiodarone IV/IO

C. Administer Epinephrine and continue CPR

D. Administer Lidocaine IV/IO

Correct Answer: C. Administer Epinephrine and continue CPR

■ *Listen (English)*

■ *Listen (Hindi)*

Explanation: In the pediatric cardiac arrest algorithm, asystole is a non-shockable rhythm. The appropriate treatment involves continuing CPR and administering Epinephrine as soon as possible. Defibrillation (shock) (Option A) is not indicated for asystole or pulseless electrical activity (PEA), which are non-shockable rhythms. Amiodarone (Option B) : Used in VF/pVT. Begin with 300 mg IV/IO; a follow-up dose of 150 mg IV/IO may be administered if needed. An alternative dose is 5 mg/kg IV. Lidocaine (Option D) : Used in VF/pVT. Start with 1-1.5 mg/kg IV. If ventricular fibrillation (VF) or pulseless ventricular tachycardia (VT) persists, administer 0.5-0.75 mg/kg IV every 5-10 minutes, up to a maximum of 3 mg/kg.

References:

cpr.heart.org/en/resuscitation-science/cpr-and-ecc-guidelines/algorithms#pediatrics

↑ *Back to this question in Part A*

@Neet_pg_bot

Q10: Which of the following statements about massive transfusion is not correct? (Q850645)

A. PRBC should be administered first to address hypoxia and acidosis in bleeding patient

B. 1:1:0.25 ratio of PRBC: FFP: SDP

C. Blood products should be warmed before infusion to prevent coaguloapthy

D. ABO grouping is not required for platelet transfusion

Correct Answer: D. ABO grouping is not required for platelet transfusion

■ *Listen (English)*

■ *Listen (Hindi)*

Explanation: Even in massive transfusion, ABO grouping for platelets is relevant and preferred. The statement "ABO matching is not required" is still incorrect, although relaxed in emergencies under strict protocols. In the massive transfusion protocol, PRBC must be administered first (Option A) because, in a bleeding patient, blood loss causes hypoxia and acidosis. PRBC carries oxygen and helps neutralize the acidosis component.. Platelets should not be given first, as their function would be impaired by acidosis. The ratio of PRBC:FFP: PRP should be maintained at 1:1:1 (Option B), but for SDP is 1:1:0.25. Warming of blood products (Option C) is essential during rapid transfusion to prevent hypothermia, which is a significant risk in trauma patients receiving large volumes of cold blood products. Hypothermia can lead to coagulopathy, worsening the bleeding.

References:

www.uptodate.com/contents/massive-blood-transfusion

www.hematology.org/education/clinicians/guidelines-and-quality-care/clinical-practice-guidelines/guidelines-for-massive-transfusion

↑ *Back to this question in Part A*

@Neet_pg_bot

Q11: A 35-year-old farmer is brought to ER 2 hours after being bitten by a snake on his left ankle. He has severe swelling of the left leg, gingival bleeding, and incoagulable blood on the 20-minute whole blood clotting time test. You decide to administer ASV . Twenty minutes after starting the ASV infusion, the patient develops urticaria, cough, and abdominal pain. His blood pressure drops to 85/50 mmHg. Which of the following is the most appropriate next step in management? (Q850669)

A. Discontinue ASV infusion permanently

B. Continue ASV infusion and administer corticosteroids

C. Stop ASV infusion temporarily and treat with epinephrine

D. Administer heparin to counteract coagulopathy

Correct Answer: C. Stop ASV infusion temporarily and treat with epinephrine

■ *Listen (English)*

■ *Listen (Hindi)*

Explanation: In this case, the patient is developing an early (anaphylactic) reaction to the ASV , which occurs within 10-180 minutes of starting treatment. The symptoms presented (urticaria, cough, abdominal pain, and hypotension) are typical of this reaction. The correct management for an early ASV reaction is as follows: Stop the ASV infusion immediately. Administer epinephrine (adrenaline) intramuscularly or subcutaneously. Give antihistamines and corticosteroids. Treat shock if present (IV fluids, oxygen). Once symptoms have subsided, resume ASV administration at a slower rate. Discontinue ASV infusion permanently (Option A) is incorrect because ASV is crucial for treating severe envenomation. After managing the reaction, ASV should be restarted. Continuing ASV infusion and administering corticosteroids (Option B) is incorrect because continuing the infusion during an anaphylactic reaction can worsen the patient's condition. The infusion should be stopped first. Administer heparin (Option D) is incorrect and potentially dangerous. Heparin is contraindicated in snake bite-induced coagulopathy and would not address the anaphylactic reaction.

References:

pmc.ncbi.nlm.nih.gov/articles/PMC4925324/

↑ *Back to this question in Part A*

@Neet_pg_bot

Q12: A 28-year-old farmer is brought to the ER 30 minutes after being bitten by a snake on his right leg. He presents with severe pain and swelling at the bite site, and examination reveals two puncture wounds. His blood pressure is 90/60 mmHg and he has gingival bleeding. The 20-minute whole blood clotting time test shows that the blood is incoagulable. Which of the following is the most appropriate next step in management? (Q850666)

A. Administer crypoprecipitate

B. Administer 150-200 ml of polyvalent antivenom

C. Apply a tight tourniquet above the bite site

D. Administer heparin to manage coagulopathy

Correct Answer: B. Administer 150-200 ml of polyvalent antivenom

■ *Listen (English)*

■ *Listen (Hindi)*

Explanation: In this case, the patient shows signs of severe envenomation: Severe pain and swelling at the bite site Hypotension (BP 90/60 mmHg) Gingival bleeding Incoagulable blood on the 20-minute whole blood clotting time test These symptoms strongly suggest a viper bite with significant systemic effects. According to the management guide, for severe poisoning with rapidly progressive or overt hemolysis or coagulopathy, the recommended antivenom dose is 150-200 ml. Administer cryoprecipitate (Option A): Supportive, but antivenom is needed first to

stop ongoing venom-induced coagulopathy. Apply a tight tourniquet above the bite site (Option C): Not recommended as it can worsen local tissue damage. Administer heparin to manage coagulopathy (Option D): Contraindicated as coagulopathy is due to venom, not thrombosis.

References:

pmc.ncbi.nlm.nih.gov/articles/PMC4925324/

snakehelpline.com/snake-bite/first-aid/

↑ *Back to this question in Part A*

@Neet_pg_bot

Q13: A 32-year-old farmer is brought to the emergency department after being bitten by a snake while working in his field in rural India. He presents with severe local pain, swelling, and gum bleeding. Within 2 hours, he develops diplopia, dysphagia, and progressive weakness in his limbs. Laboratory tests show prolonged prothrombin time and decreased fibrinogen levels. Which of the following snakes is most likely responsible for this envenomation? (Q850661)

A. Cobra

B. Russell's viper

C. Saw-scaled viper

D. Krait

Correct Answer: B. Russell's viper

■ *Listen (English)*

■ *Listen (Hindi)*

Explanation: The patient's symptoms and laboratory findings suggest a combination of hemotoxic and neurotoxic effects: Hemotoxic: Severe local pain and swelling, gum bleeding, prolonged prothrombin time, and decreased fibrinogen levels. Neurotoxic: Diplopia, dysphagia, and progressive limb weakness. This combination of hemotoxic and neurotoxic effects is characteristic of Russell's viper envenomation . Cobra (Option A): Mainly neurotoxic, rarely causes coagulopathy. Saw-scaled viper (Option C): Typically causes local tissue damage and mild coagulopathy, not prominent neurotoxicity. Krait (Option D): Neurotoxic only, minimal local swelling or coagulopathy.

References:

1. Davidson’s Principle and Practice of Medicine, 24th Edition, Page 152, 153, 154, 155, 156, 157, 158 2. pmc.ncbi.nlm.nih.gov/articles/PMC9278408/

↑ *Back to this question in Part A*

@Neet_pg_bot

Q14: A 60-year-old woman is admitted to the ICU with sepsis secondary to a urinary tract infection. After 48 hours, she develops acute hypoxemic respiratory failure. Her chest X-ray shows bilateral infiltrates, and her PaO2/FiO2 ratio is 180 mmHg on PEEP of 8 cm H2O. An echocardiogram shows normal cardiac function. Which of the following is the most appropriate next step in management? (Q850660)

A. Initiate high-frequency oscillatory ventilation

B. Start inhaled nitric oxide therapy

C. Begin low tidal volume ventilation with 6 mL/kg lean body weight

D. Administer high-dose corticosteroids

Correct Answer: C. Begin low tidal volume ventilation with 6 mL/kg lean body weight

■ *Listen (English)*

■ *Listen (Hindi)*

Explanation: The patient meets the Berlin criteria for ARDS: Timing: Within 1 week of known clinical insult (sepsis) Chest imaging: Bilateral infiltrates Origin of edema: Not due to cardiac failure (confirmed by echocardiogram) Oxygenation: PaO2/FiO2 ratio of 180 mmHg (indicating moderate ARDS: 100 mmHg < PaO2/FiO2 ≤ 200 mmHg) For moderate ARDS, the next best management option is low tidal volume ventilation with a predicted body weight of 6 mL/kg. ARDS: Management Grade Severity (PaO■/FiO■) Key Management Strategies Grade A (Mild) 200 mmHg < PaO■/FiO■ ≤ 300 mmHg (with PEEP or CPAP ≥ 5 cm H■O) Low tidal volume ventilation (4–8 ml/kg predicted body weight) and lower inspiratory pressures (plateau pressure < 30 cm H■O) Grade B (Moderate) 100 mmHg < PaO■/FiO■ ≤ 200 mmHg Minimized plateau and driving pressures; High PEEP (35–50 cmH■O for 20–40 s); Prone positioning; Recruitment maneuvers; ECMO in selected patients Grade C (Severe) PaO■/FiO■ ≤ 100 mmHg Neuromuscular blockade in early ARDS; Conservative fluid management; Inhaled vasodilators as rescue therapy; Avoid routine use of pulmonary artery catheter Grade D (Severe) PaO■/FiO■ ≤ 100 mmHg Avoid high-frequency oscillatory ventilation; Avoid β■-agonists for improving outcomes

References:

Harrison’s Principles of Internal Medicine, 21st Edition, Page 2227, 2228, 2229

pmc.ncbi.nlm.nih.gov/articles/PMC7997862/

↑ *Back to this question in Part A*

@Neet_pg_bot

Q15: A 45-year-old man is admitted to the ICU with severe pneumonia. He develops worsening respiratory symptoms and bilateral infiltrates on chest X-ray within 5 days. Which of the following best describes the pathophysiological mechanism occurring in the alveoli during the early phase of this patient's condition? (Q850655)

A. Increased surfactant production

B. Thickening of the alveolar basement membrane

C. Accumulation of protein-rich edema fluid

D. Fibrosis of the alveolar walls

Correct Answer: C. Accumulation of protein-rich edema fluid

■ *Listen (English)*

■ *Listen (Hindi)*

Explanation: Rapid deterioration in a case of pneumonia indicates development of acute respiratory distress syndrome. The key pathophysiological mechanism in the early exudative phase of ARDS accumulation of protein-rich edema fluid. This occurs due to increased capillary permeability resulting from injury to the alveolar-capillary membrane. Increased surfactant production (Option A): ARDS leads to reduced surfactant dysfunction, not increased production. Thickening of the alveolar basement membrane (Option B): While this may occur later in ARDS, it's not a primary mechanism in the early phase. This is also seen in bronchial asthma. Fibrosis of the alveolar walls (Option D): This is a feature of the late (fibrotic) phase of ARDS, not the early phase.

References:

Harrison’s Principles of Internal Medicine Edition 21st Page 2225, 2226, 2227

↑ *Back to this question in Part A*

@Neet_pg_bot

Q16: A 55 year-old male presents to the emergency department with fever, tachypnea, and altered mental status. BP is 100/60 mm Hg Laboratory results show: WBC: 14,000/μL Serum lactate: 1.8 mmol/L Creatinine: 1.8 mg/dL (baseline 0.9 mg/dL) Chest X-ray reveals a right lower lobe infiltrate. The patient requires 6 L/min of oxygen to maintain pO2 of 90 mm Hg. Which of the following is the most accurate diagnosis for this patient? (Q850652)

A. Systemic Inflammatory Response Syndrome

B. Sepsis

C. Acute Tubular necrosis

D. Septic shock

Correct Answer: B. Sepsis

■ *Listen (English)*

■ *Listen (Hindi)*

Explanation: According to Sepsis-3 , sepsis is life-threatening organ dysfunction caused by a dysregulated host response to infection. This patient has pneumonia (infection) with organ dysfunction: Respiratory: PaO■/FiO■ = 90/0.45 = 200 → indicates hypoxemia Renal: Creatinine rise from 0.9 to 1.8 mg/dL → acute kidney injury → Thus, SOFA score ≥2 , confirming sepsis . Systemic Inflammatory Response Syndrome (SIRS) (Option A): Infection or organ dysfunction not mandatory by criteria. Acute Tubular Necrosis (Option C): Explains renal injury only, not systemic infection or multi-organ dysfunction. Septic shock (Option D): Requires hypotension despite fluids and lactate ≥2 mmol/L, which are absent here.

References:

Harrison's Principles of Internal Medicine, 21st Edition, Volume I, Page.2241, 2242.

↑ *Back to this question in Part A*

@Neet_pg_bot

Q17: A 30-year-old trauma patient underwent massive transfusion protocol after a road traffic accident. Six hours later, he develops acute onset dyspnea, hypoxia, and bilateral pulmonary infiltrates on chest X-ray. He is afebrile, Pulse 100/min with BP 124/ 80 mm Hg. JVP is normal and pro NT BNP levels are normal. What is the most likely diagnosis? (Q850648)

A. Transfusion-associated circulatory overload

B. Transfusion-related acute lung injury

C. Mismatched blood transfusion

D. Laryngospasm due to citrate induced hypocalcemia

Correct Answer: B. Transfusion-related acute lung injury

■ *Listen (English)*

■ *Listen (Hindi)*

Explanation: Since BP is normal, neck veins are not distended, and Pro-NT-BNP levels are normal, it indicates TRALI developing after blood transfusion. TRALI presents within 6 hours of transfusion with acute hypoxemia and bilateral pulmonary infiltrates due to donor anti-leukocyte antibodies causing non-cardiogenic pulmonary edema. Transfusion-associated circulatory overload (TACO) (Option A): Shows elevated JVP and raised pro-BNP, unlike this case. Mismatched blood transfusion (Option C): Causes fever, chills, back pain, and hemoglobinuria, not isolated respiratory distress. Laryngospasm due to citrate-induced hypocalcemia (Option D): Leads to tetany or arrhythmias, not bilateral pulmonary infiltrates.

References:

Harrison's Principles of Internal Medicine,21st Edition, Volume I, Page. 894, 895.

↑ *Back to this question in Part A*

@Neet_pg_bot

Q18: A 28-year-old male is brought to the trauma center following a motorcycle accident. He is unconscious BP 70/40 mmHg and shows signs of active bleeding. Massive transfusion protocol is initiated. After receiving 4 units of PRBCs rapidly, he develops muscle twitching. ABG shows metabolic alkalosis. ECG shows normal sinus rythm with QT prolongation. What is the most appropriate immediate next step in his management? (Q850646)

A. Administer intravenous calcium gluconate to correct citrate-induced hypocalcemia, which is causing neuromuscular irritability and QT prolongation.

B. Start platelet transfusion immediately to correct dilutional thrombocytopenia, as prolonged transfusion leads to bleeding due to thrombocytopenia.

C. Give sodium bicarbonate to treat the developing metabolic alkalosis resulting from massive transfusion.

D. Transfuse cryoprecipitate to correct fibrinogen deficiency and prevent DIC-like picture often seen after >10 units of PRBC.

Correct Answer: A. Administer intravenous calcium gluconate to correct citrate-induced hypocalcemia, which is causing neuromuscular irritability and QT prolongation.

■ *Listen (English)*

■ *Listen (Hindi)*

Explanation: After rapid transfusion of multiple units of PRBCs, citrate toxicity can occur, leading to hypocalcemia , which presents with muscle twitching, paresthesia and prolonged QT interval . Hence, IV calcium gluconate is the most immediate and appropriate step . Platelet transfusion (Option B) is important later in MTP, but not the priority here, as the clinical picture suggests an electrolyte imbalance, not active coagulopathy. Sodium

bicarbonate (Option C) is incorrect because metabolic alkalosis seen post-transfusion is usually mild and self-limiting due to metabolism of citrate to bicarbonate; treating it with sodium bicarbonate can worsen alkalosis and is not first-line. Cryoprecipitate (Option D) , while relevant in ongoing transfusions, is not the immediate response to the described ECG

References:

www.who.int/publications/i/item/clinical-transfusion-practice-guidelines-for-medical-interns

↑ *Back to this question in Part A*

@Neet_pg_bot

• [02_Emergency Medicine] 012 Previous Year Questions

« Back to Folder Directory

[02_Emergency Medicine] 012 Previous Year Questions — Quick Jump

Q1 (p. 1492) *Q2 (p. 1492)* *Q3 (p. 1493)* *Q4 (p. 1494)* *Q5 (p. 1494)* *Q6 (p. 1495)*
Q7 (p. 1496) *Q8 (p. 1497)* *Q9 (p. 1497)* *Q10 (p. 1498)* *Q11 (p. 1499)* *Q12 (p. 1499)*
Q13 (p. 1500)

Q1: An RTA patient has received 4 packed RBC within a few hours. Which of the following will be seen? (Q866789)

A. Hypernatremia

B. Hyponatremia

C. Hypocalcemia

D. Hyperkalemia

Correct Answer: C. Hypocalcemia

Explanation: Stored packed RBCs contain citrate as an anticoagulant. Rapid transfusion leads to citrate binding ionized calcium in the recipient's blood, causing acute hypocalcemia. Citrate toxicity is more likely when large volumes of blood are transfused rapidly, as in massive transfusion protocols. The liver normally metabolizes citrate, but in shock or hypothermia this clearance is impaired. Clinical signs: Perioral numbness, paresthesia, muscle cramps, tetany, hypotension, and prolonged QT interval on ECG. Massive Blood Transfusion: Definition: Replacement of blood volume exceeding patient's total blood volume within 24 hrs (or >10 units of PRBC). Acute complications: Metabolic: Hypocalcemia (citrate toxicity), hypomagnesemia, hyperkalemia (from hemolysis), hypothermia, metabolic alkalosis. Coagulopathy: Due to dilution of platelets and clotting factors. Volume overload & ARDS. Prevention: Warm blood before transfusion, monitor electrolytes, give calcium gluconate if needed, replace platelets & FFP in balanced ratios. Key electrolyte changes in massive transfusion: Electrolyte Cause Change Calcium Citrate binding ↓ (Hypocalcemia) Potassium Leakage from stored RBCs ↑ (Hyperkalemia) Magnesium Citrate binding ↓ (Hypomagnesemia) Sodium Usually normal; slight ↑ if using older preservatives — Incorrect Options: Hypernatremia (Option A) – Not a major finding; sodium content in stored blood is minimal. Hyponatremia (Option B) – Not typically caused by transfusion. Hyperkalemia (Option D) – Possible in prolonged storage, but acute citrate-induced hypocalcemia is more characteristic in rapid large transfusions.

↑ *Back to this question in Part A*

@Neet_pg_bot

Q2: Which is the best confirmatory method to ensure the central line is in the jugular vein? (Q866816)

A. Chest x-ray

B. Blood pH

C. Blood color

D. ETCO2

Correct Answer: A. Chest x-ray

Explanation: Importance of Chest X-ray in Central Line Placement Initial Assessment: A chest X-ray should be performed immediately after internal jugular and subclavian line placement to confirm correct catheter placement and rule out iatrogenic pneumothorax. Post-Procedure Verification: It is crucial to verify catheter placement and ensure no complications, like pneumothorax, following the procedure. Ipsilateral Side Approach: If the internal jugular central venous line (CVL) insertion fails, move to the ipsilateral subclavian vein. A chest X-ray or ultrasound should be performed before attempting the opposite side to prevent bilateral pneumothoraces. Options B, C, and D are incorrect.

↑ *Back to this question in Part A*

@Neet_pg_bot

Q3: Young male has sustained Femur shaft fracture after RTA and internal fixation was done. 2 days later he develops shortness of breath with confusion and petechial rash. Diagnosis is? (Q866513)

A. FES

B. ARDS

C. Pulmonary embolism

D. Pleural effusion

Correct Answer: A. FES

Explanation: This patient has the classic triad of Fat Embolism Syndrome following a long bone fracture and orthopedic surgery: Respiratory distress (shortness of breath) Neurological symptoms (confusion, altered sensorium) Petechial rash (typically on upper chest, axillae, and conjunctiva) Fat emboli enter the circulation from bone marrow after trauma or fixation and lodge in pulmonary and systemic microvasculature, producing respiratory compromise, brain dysfunction, and a petechial rash due to dermal capillary occlusion. ARDS (Option B) : Can occur after trauma but doesn’t present with the petechial rash; onset is usually a bit later and is related to

widespread inflammatory lung injury. Pulmonary embolism (Option C) : Causes acute dyspnea and hypoxia but usually lacks neurologic signs and rash; most often from DVT. Pleural effusion (Option D) : Would present with unilateral decreased breath sounds, not acute neuro changes or rash.

↑ *Back to this question in Part A*

@Neet_pg_bot

Q4: Which of the following is not part of the clinical criteria for anaphylaxis? Urticaria, lip/tongue edema Wheeze and respiratory distress Abdominal cramps and vomiting Hypertension (Q840144)

A. 1, 2, and 3

B. 1 and 2

C. 2 and 3

D. 4

Correct Answer: D. 4

Explanation: While urticaria, respiratory distress, and GI symptoms are common, hypertension is not a feature of anaphylaxis. Anaphylaxis causes hypotension due to vasodilation and increased vascular permeability . Anaphylaxis is a severe, rapid-onset, multisystem allergic reaction . The clinical criteria include: Skin/Mucosal: Urticaria, angioedema, lip/tongue swelling, rash Respiratory: Wheezing, stridor, dyspnea Cardiovascular: Hypotension or shock , not hypertension Gastrointestinal: Abdominal cramps, vomiting, diarrhea

References:

.

↑ *Back to this question in Part A*

@Neet_pg_bot

Q5: A 65-year-old patient with type 2 diabetes mellitus experiences hypoglycemia and falls, resulting in incoherent speech. CT scan reveals a large acute subdural hematoma (SDH) >30 cc. What is the most appropriate immediate management? (Q860237)

A. Administer intravenous mannitol and observe

B. Start dual antiplatelet therapy (aspirin + clopidogrel)

C. Emergent surgical evacuation (craniotomy or burr hole)

D. Stabilize the patient and schedule routine neurosurgical consultation

Correct Answer: C. Emergent surgical evacuation (craniotomy or burr hole)

Explanation: Large acute SDH (>30 cc) with neurological deficits is a surgical emergency . Immediate evacuation relieves mass effect, prevents herniation, and improves outcomes. Administer intravenous mannitol and observe (Option A): Temporarily reduces ICP but does not remove the hematoma → insufficient. Start dual antiplatelet therapy (aspirin + clopidogrel) (Option B): Antiplatelets increase bleeding risk and are contraindicated in acute SDH. Stabilize the patient and schedule routine neurosurgical consultation(Option D): While stabilization is important (airway, breathing, circulation), delaying surgery for routine consultation is dangerous. Large symptomatic SDH needs urgent neurosurgical intervention , not a routine referral.

References:

Harrison's Principle of Internal Medicine 21st Edition Page 3457, 3458

↑ *Back to this question in Part A*

@Neet_pg_bot

Q6: What medication can be administered to a patient who experiences altered consciousness, sweating, rapid heartbeat, persistent erection, and increased saliva production, with a blood pressure reading of 150/90 mm Hg after visiting a temple with their grandmother? (Q854658)

A. ASV

B. Adrenaline

C. Steroid

D. Prazosin

Correct Answer: D. Prazosin

Explanation: The patient might be suffering from a scorpion sting cardiotoxicity as per his symptoms and the best choice of medication here is Prazosin . Treatment of scorpion sting: Identification of the scorpion species is essential for determining treatment, as stings from non-lethal species typically only require basic care. Non-lethal stings : Most stings cause local discomfort and can be managed at home with ice packs, analgesics, or antihistamines. Patients should return to the emergency department if cranial-nerve or neuromuscular symptoms develop. Severe envenomations : Aggressive supportive care and careful use of antivenom can prevent deaths from more dangerous stings. Initial measures : Keeping the patient calm, applying pressure dressings, and using cold packs can reduce venom absorption. Treatment for symptoms : Continuous IV infusion of midazolam can control agitation and muscle movements, but close monitoring is needed due to the risk of respiratory arrest,

especially when sedatives or narcotics are used. Management of complications : Hypertension and Pulmonary oedema : Managed with Nifedipine, Nitroprusside, Hydralazine, or Prazosin . Bradycardia : Managed with atropine. Antivenin : FDA-approved antivenin (C. sculpturatus IgG F(ab')2 in horse serum) is available in some countries and can rapidly reverse cranial-nerve dysfunction and muscular symptoms when administered intravenously. Incorrect Options: Anti-snake venom (Option A) is a specific treatment used for snakebite envenomation and is not indicated in the given scenario. Adrenaline (Option B) is commonly used in emergencies to treat severe allergic reactions and cardiac arrest. Steroids (Option C) , such as corticosteroids have anti-inflammatory and immunosuppressive effects. They are generally used in allergic reactions, autoimmune disorders, and asthma. However, these are not preferred in the given scenario.

References:

Harrison's Principles of Internal Medicine, 21st Edition, Page: 3613.

↑ *Back to this question in Part A*

@Neet_pg_bot

Q7: A patient was being treated in ICU for sepsis. The initial ABG shows pH= 6.9, pO 2 = 80 mm Hg. pCO 2 = 55 mmHg, HCO 3 = 10 meq/L. A repeat ABG after 2 hours shows pH=7.1, pCO 2 = 20 mmHg, pO 2 = 140 mm Hg, and HCO 3 = 10 meq/L. Which is most plausible to explain the change seen in the ABG report? (Q854662)

A. Excessive air and less heparin in the ABG sample

B. Excess air and more heparin in the ABG sample

C. Less air and more heparin in the ABG sample

D. Less air and less heparin in the ABG sample

Correct Answer: B. Excess air and more heparin in the ABG sample

Explanation: The change in the pH without a change in the bicarbonate level indicates excess heparinization . The increased pO 2 shows excess air . Effects of excess heparin: Heparin is a sulfated mucopolysaccharide with acidic properties. The excess of heparin in the ABG syringe can have the following effects: Effect on pH: If the pH is normal or alkaline (high) to begin with, acidemia increases i.e., the pH will fall on contact with the acidic heparin. If the pH is very acidic to begin with, acidemia decreases i.e., the pH will rise as the mildly acidic heparin reduces the greater acidity of the blood. Delusional effect: The PaO 2 and PaCO 2 can also be falsely lowered by dilution.

References:

https://pubmed.ncbi.nlm.nih.gov/3919622/

↑ *Back to this question in Part A*

@Neet_pg_bot

Q8: Which of the following statements regarding the management of frostbite is incorrect? (Q855609)

A. Amputation in severe cases

B. Rewarming is done

C. Antibiotics and analgesics not used

D. The area is dried and cleaned

Correct Answer: C. Antibiotics and analgesics not used

Explanation: Antibiotics are commonly prescribed in the management of frostbite to prevent or treat secondary bacterial infections that can occur as a result of damaged tissue. Analgesics, such as nonsteroidal anti-inflammatory drugs (NSAIDs) or opioids, may be used to manage pain. In severe cases of frostbite where tissue damage is extensive and irreversible, amputation may be necessary to remove dead or gangrenous tissue (Option A) and prevent the spread of infection. Therefore, amputation can be a part of the management in severe cases. Rewarming the affected area (Option B) is a critical step in the management of frostbite. It should be done using warm water (not hot) or by placing the affected area in a warm environment. Rewarming helps to restore blood flow and prevent further tissue damage. After rewarming, the affected area should be gently dried and cleaned to prevent infection. (Option D) Cleaning helps remove any debris or contaminants from the damaged tissue.

References:

Harrison Principles of Internal Medicine, 21stEdition, Page 783, 790

Goutam Biswas Review of Forensic Medicine and Toxicology, 3rd Edition, Page 264-265

↑ *Back to this question in Part A*

@Neet_pg_bot

Q9: During a scorching summer afternoon, a man, who had been toiling in a field, unexpectedly collapsed. Upon examination, there were no apparent physical indications of dehydration, although his radial pulse was detectable. The doctor determined that the man's serum electrolyte levels were within the normal range. Shockingly, the man's body temperature measured 106 degrees Fahrenheit. Considering these circumstances, which of the following should be administered as an initial form of immediate assistance? (Q857001)

A. Inject epinephrine immediately

B. Cover with hot damp sheets

C. Cover with cool damp sheets

D. Start CPR

Correct Answer: C. Cover with cool damp sheets

Explanation: The above patient seems to be suffering from a heat stroke. There are no signs of dehydration and the body temperature is quite high and the radial pulse is present. The next best step is to cover the body with cool damp sheets. Epinephrine injection (Option A) can be fatal for the patient. CPR (Option D) is not required as a steady radial pulse is perceived and the patient is not in shock.

References:

Davidson's Principles and Practice of Medicine, 24th edition, Page 168

Goutam Biswas Review of Forensic Medicine and Toxicology, 3rd edition, Page 265-266

↑ *Back to this question in Part A*

@Neet_pg_bot

Q10: According to the ABCD2 scoring, which factors indicate a greater likelihood of a patient with TIA experiencing a future stroke? (Q856931)

A. Age <60 years

B. SBP>140 mm Hg and DBP <90 mmHg

C. Duration of TIA >5 mins

D. Diabetes

Correct Answer: D. Diabetes

Explanation: Presence of diabetes indicates higher risk of stroke following TIA. ABCD2 Score for TIA (Transient Ischemic Attack): The Risk of Stroke Parameter Criteria Points Age > 60 years (Option A) 1 point Blood Pressure BP ≥ 140/90 (Option B) 1 point Clinical Features Speech disturbance without weakness 1 point Unilateral leg weakness 2 points Duration 10–59 minutes (Option C) 1 point ≥ 60 minutes 2 points Diabetes Presence of diabetes 1 point Stroke Risk Based on Score: Score Stroke Risk Day 2 Day 7 Day 90 0–3 1% 1.2% 3.1% 4–5 4.1% 5.9% 9.8% 6–7 8.1% 11.7% 17.8%

References:

https://www.ncbi.nlm.nih.gov/books/NBK459143/

↑ *Back to this question in Part A*

@Neet_pg_bot

Q11: The recommended temperature of a water bath for a patient with frostbite is (Q858462)

A. 37 degree C

B. 42 degree C

C. 32 degree C

D. 30 degree C

Correct Answer: A. 37 degree C

Explanation: The recommended temperature of a water bath for a patient with frostbite is 37 degree C. Frostbite: Pathophysiology: Tissue freezes below 0°C (32°F), leading to the ice-crystal formation that destroys the cellular structure. Vascular endothelial damage causes stasis, microvascular thrombosis, and progressive dermal ischemia. Thrombosis, ischemia, and necrosis lead to mummification and demarcation over weeks to months. Clinical Presentation: Symptoms: Sensory deficits (light touch, pain, or temperature perception); "chunk of wood" sensation in extremities. Signs: Superficial frostbite: Anesthesia, erythema, pliable subcutaneous tissue, and no tissue loss. Deep frostbite: Waxy, mottled, violaceous-white tissue; hemorrhagic vesicles indicate severe injury. Treatment: Rewarming: Immerse frozen tissue in circulating water at 37°- 40°C (99°-104°F) for 30-60 minutes. Avoid premature termination of thawing despite the pain. Medical Management: Prostacyclin analogs (e.g., iloprost) within 48 hours. Thrombolysis (rt-PA) and heparin for deep frostbite within 24 hours to reduce amputation risk. Surgical Considerations: Delay debridement or amputation until demarcation.

References:

Harrison’s Principles of Internal Medicine, 21st Edition, Page 3633,3634

↑ *Back to this question in Part A*

@Neet_pg_bot

Q12: All of the following is used in the management of breathless patients at a high altitude of 3000 mts except. (Q858463)

A. Intravenous digoxin

B. Oxygen supplementation

C. Immediate descent

D. Acetazolamide

Correct Answer: A. Intravenous digoxin

Explanation: A breathless patient at a high altitude of 3000 meters suggests High-Altitude Pulmonary Edema (HAPE) , and intravenous digoxin is not used in its management. High-Altitude Pulmonary Edema (HAPE): Risk Factors: Rapid ascent, history of HAPE, respiratory infections, cold temperatures. Cardiopulmonary abnormalities (e.g., mitral stenosis, primary pulmonary hypertension) increase risk, even at moderate altitudes. Clinical Features: Reduced exercise tolerance greater than expected at altitude. Dry cough may precede, followed by blood-tinged sputum. Tachypnea, tachycardia, crackles on auscultation. Hypoxemia and respiratory alkalosis are present unless on acetazolamide (which may cause metabolic acidosis). Investigation: Chest X-ray: Patchy or streaky interstitial edema. Electrocardiograms: Right ventricular strain or hypertrophy. Prevention: Gradual ascent is key to acclimatization. Sustained-release nifedipine (30 mg twice daily) prevents HAPE in those ascending rapidly or with a history of HAPE. Acetazolamide (Option D) and dexamethasone are potential options, though their roles require careful monitoring. Treatment: Immediate descent (Option C) and supplemental oxygen (Option B) (targeting >90% saturation) are the most effective treatments. Maintain rest, warmth, and limit exertion. Hyperbaric therapy (portable altitude chamber) may be lifesaving if descent is not possible. Oral nifedipine as adjunctive therapy.

References:

Harrison’s Principle of Internal Medicine, 21st Edition, Page 3619,3620

↑ *Back to this question in Part A*

@Neet_pg_bot

Q13: A 47-year-old woman was brought to the casualty in an unconscious state after having suddenly collapsed. As there was no pulse, cardiopulmonary resuscitation was started and the monitor showed the following rhythm. What is the next step? (Q859792)

A. Defibrillation

B. Synchronized cardioversion

C. 1mg epinephrine

D. 0.5mg atropine

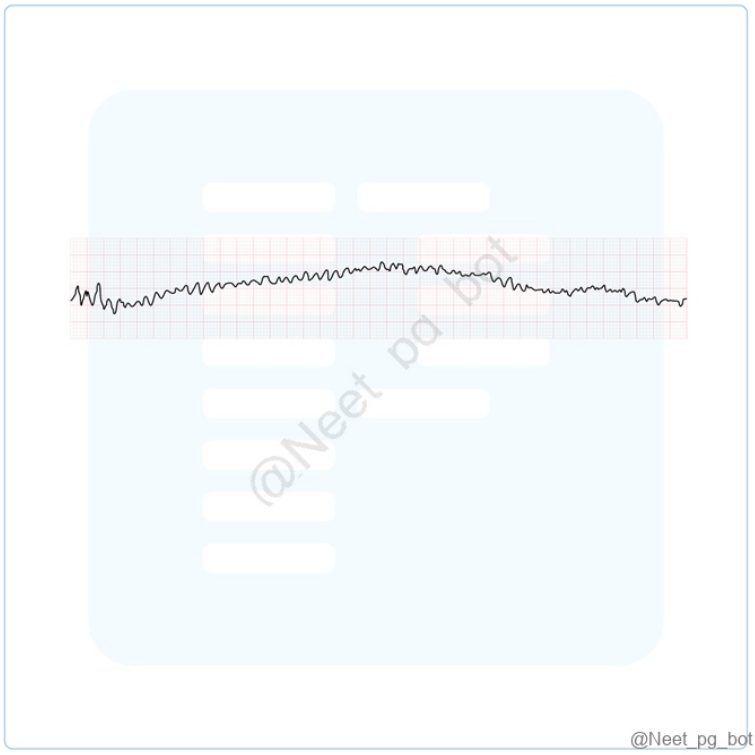

Correct Answer: A. Defibrillation

Explanation: The given ECG shows ventricular fibrillation and the next step of management is defibrillation since this is a shockable rhythm. Shockable Conditions Non-Shockable Conditions Ventricular Fibrillation Asystole Ventricular Tachycardia Pulseless Electrical Activity Shockable Conditions Non-Shockable Conditions Immediate Recognition Identify Shockable Rhythm: Recognize VF or pulseless VT. Activate Emergency Response: Call for advanced life support. ↓ Initiate CPR Start High-Quality CPR: Perform chest compressions at a rate of 100-120/min, with a depth of 5-6 cm. Continue CPR for 2 minutes. ↓ Defibrillation (Option A) After 2 minutes of CPR, deliver a Non-Synchronized DC Shock to restore normal rhythm. If no change, administer a second shock immediately. ↓ Continue CPR Resume CPR for 2 Minutes Place an intravenous or intraosseous line for drug administration. ↓ Administer Epinephrine Epinephrine 1 mg (Option C) (1:10,000): Given IV/IO after 2 minutes of CPR to enhance coronary perfusion pressure. ↓ Advanced Airway Management Secure Airway: Perform endotracheal intubation if necessary. Capnography: Monitor end-tidal CO2 levels. Ventilation: Provide 1 breath every 6 seconds post-intubation. ↓ Further Defibrillation Third Shock: If VF or pulseless VT persists, deliver a third non-synchronized shock. Continue CPR for 2 More Minutes: Follow with additional CPR. ↓ Administer Antiarrhythmic Medication Amiodarone 300 mg IV: Administer for shock-refractory VT to stabilize heart rhythm. ↓ Identify and Treat Reversible Causes Immediate Recognition Identify Non-Shockable Rhythm: Recognize asystole or pulseless electrical activity (PEA). Activate Emergency Response: Call for advanced life support. ↓ Initiate CPR Start High-Quality CPR: Perform chest compressions at a rate of 100-120/min, with a depth of 5-6 cm. Continue CPR for 2 minutes. ↓ Establish intravenous or intraosseous lines for medication administration. ↓ Administer Epinephrine Epinephrine 1 mg (1:10,000): Administer IV/IO after the first 2 minutes of CPR. ↓ Identify Rhythm Non-Shockable Rhythm: Continue CPR and administer epinephrine every 3-5 minutes. Goal: To increase the likelihood of developing a shockable rhythm, such as ventricular fibrillation (VF), which is necessary for effective defibrillation. Shockable Rhythm: Administer a Non-Synchronized DC Shock to restore normal rhythm. ↓ Advanced Airway Management Airway: Secure the airway with endotracheal intubation if necessary.

Capnography: Monitor end-tidal CO2 levels. Ventilation: Provide 1 breath every 6 seconds post-intubation for adequate oxygenation. ↓ Continue CPR Resume chest compressions for 2 minutes. ↓ Identify and Treat Reversible Causes Primary Focus: Address reversible causes, especially hypothermia. ↓ Repeat CPR and Epinephrine Cycle: Continue repeating CPR and epinephrine administration every 3-5 minutes. Synchronized cardioversion (Option B) is used to reset the abnormal heart rhythm and is given in synchronisation with the R wave in the ECG (delivered at the peak of the R wave). It is performed in arrhythmias where the heart is still contracting but irregularly, such as Paroxysmal Supraventricular Tachycardia (PSVT), Atrial Fibrillation (AF), and Atrial Flutter. 0.5 mg atropine (Option D) is indicated for symptomatic bradycardia and not in a pulseless patient.





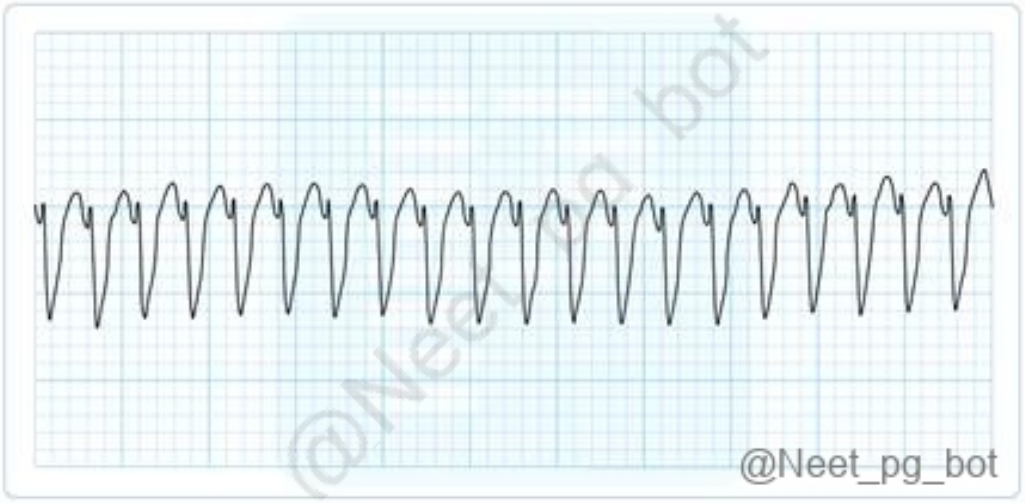



References:

Harrison's principles of internal medicine, 21st Edition, Page: 2063, 2262, 2263

Davidson's principles and practice of medicine, 24th Edition, Page: 481, 482

www.ncbi.nlm.nih.gov/books/NBK430866/

↑ *Back to this question in Part A*

@Neet_pg_bot

• [03_Endocrinology] 013 Diabetes Mellitus-I

« Back to Folder Directory

[03_Endocrinology] 013 Diabetes Mellitus-I — Quick Jump

Q1 (p. 1504) *Q2 (p. 1504)* *Q3 (p. 1505)* *Q4 (p. 1506)* *Q5 (p. 1507)* *Q6 (p. 1508)*
Q7 (p. 1509) *Q8 (p. 1510)* *Q9 (p. 1511)* *Q10 (p. 1511)* *Q11 (p. 1512)* *Q12 (p. 1513)*
Q13 (p. 1514) *Q14 (p. 1514)* *Q15 (p. 1515)* *Q16 (p. 1515)* *Q17 (p. 1516)* *Q18 (p. 1517)*
Q19 (p. 1518)

Q1: You are a doctor in armed forces and are tasked with doing medical examination of new recruits. Your next candidate has a blood report that mentions a FBS of 116 mg/dl. Which of the following terms will you use to describe this blood report? (Q850583)

A. Impaired fasting glucose

B. Impaired glucose tolerance

C. Diabetes mellitus

D. Secondary diabetes

Correct Answer: A. Impaired fasting glucose

■ *Listen (English)*

■ *Listen (Hindi)*

Explanation: Impaired Fasting Glucose (IFG) term is used when FBS is 100-125 mg/dl Impaired Glucose Tolerance (IGT) (Option B) is used when the 2-hour value is between 140-199 mg/dl Diabetes mellitus (Option C): Requires FBS ≥126 mg/dL or other diagnostic criteria. Secondary diabetes (Option D): Occurs due to underlying conditions like pancreatitis or Cushing's syndrome.

References:

Davidson's Principles and Practice of Medicine, 24th Edition, Page 722, 726, 727, 728, 743, 744, 745

↑ *Back to this question in Part A*

@Neet_pg_bot

Q2: In type 1 DM, stage III of beta cell destruction presents as which of the following? (Q850609)

A. Autoimmune - , Symptomatic, Dysglycemia

B. ■■■■Autoimmune +, Symptomatic, Hyperglycemia

C. Autoimmune - , Asymptomatic, Normoglycemia

D. Autoimmune + , Asymptomatic, Normoglycemia

Correct Answer: B. ■■■■Autoimmune +, Symptomatic, Hyperglycemia

■ *Listen (English)*

■ *Listen (Hindi)*

Explanation: Type 1 diabetes mellitus is autoimmune in etiology due to islet cell antibodies. The stages of evolution of disease are as follows: Stage 1: Asymptomatic, Normoglycemia Stage 2 : Asymptomatic, Dysglycemia (progressive beta cell dysfunction) Stage 3: Symptomatic, Hyperglycemia



References:

JDRF–Endocrine Society–ADA consensus and published in Lancet Diabetes & Endocrinology and Diabetes Care.

↑ *Back to this question in Part A*

@Neet_pg_bot

Q3: Which of the following insulin preparations need to given once a week? (Q850608)

A. Icodec

B. Glargine

C. Degludec

D. Determir

Correct Answer: A. Icodec

■ *Listen (English)*

■ *Listen (Hindi)*

Explanation: Icodec is a once-weekly basal insulin with the longest duration (~7 days) among all insulins. It binds reversibly to albumin and is gradually released into the circulation. Among the given options, Icodec is the only insulin approved for once-weekly injection. Glargine (Option B) is a long-acting insulin (24 hours) used once daily for basal coverage. Degludec (Option C) is an ultra-long-acting insulin (>42 hours) that allows flexible dosing. Detemir (Option D) lasts 16–20 hours and often requires twice-daily dosing.

References:

https://pmc.ncbi.nlm.nih.gov/articles/PMC10258611/

https://pmc.ncbi.nlm.nih.gov/articles/PMC12048741/

↑ *Back to this question in Part A*

@Neet_pg_bot

Q4: Which of the following dermatological diseases is most specific to a patient of diabetes mellitus with RBS of 220 mg/dl and RIA showing low fasting insulin levels? (Q850604)

A. Necrobiosis lipoidica diabeticorum

B. Acanthosis nigricans

C. Diabetic dermopathy

D. Intertriginous candidiasis

Correct Answer: A. Necrobiosis lipoidica diabeticorum

■ *Listen (English)*

■ *Listen (Hindi)*

Explanation: Necrobiosis lipoidica diabeticorum (NLD) is a rare, specific skin manifestation of diabetes, often seen in patients with long-standing or poorly controlled diabetes. It presents as well-defined, shiny plaques on the shins. Low fasting insulin and hyperglycemia suggest insulin deficiency rather than resistance , which correlates with NLD. Acanthosis nigricans (Option B): Associated with insulin resistance and hyperinsulinemia, not low insulin. Diabetic dermopathy (Option C): Common, but nonspecific “shin spots” seen in many diabetic patients. Intertriginous candidiasis (Option D): Opportunistic infection, not specific to diabetes.

References:

.

↑ *Back to this question in Part A*

@Neet_pg_bot

Q5: A 17-year-old male with thalassemia major presents with fatigue, hyperpigmented skin, and recently diagnosed diabetes mellitus. He has been receiving regular blood transfusions since early childhood. On examination, he has discoloration of the skin shown below, mild hepatomegaly, and lab reports show elevated serum ferritin and fasting blood glucose of 180 mg/dL.Which of the following should not be done in the initial management of this patient? (Q850597)

A. Start basal bolus insulin

B. Start iron chelation therapy

C. Phlebotomy

D. Monitor for cardiac iron overload with MRI T2



@Neet_pg_bot

Correct Answer: C. Phlebotomy

■ *Listen (English)*

■ *Listen (Hindi)*

Explanation: The patient has Bronze Diabetes, a form of diabetes associated with iron overload due to repeated blood transfusions in thalassemia major. This condition leads to impaired insulin secretion, resulting in hyperglycemia and characteristic skin changes. In a thalassemia major patient with bronze diabetes, insulin therapy is essential to control hyperglycemia due to iron-induced β-cell damage. Iron chelation with agents like deferasirox is the appropriate method to reduce iron overload, as phlebotomy is contraindicated in such anemic patients. Monitoring for cardiac iron overload with MRI T2* is crucial due to the risk of siderotic cardiomyopathy. Start basal bolus insulin (Option A): Required to control hyperglycemia due to pancreatic iron deposition. Start iron chelation therapy (Option B): Essential to reduce iron overload and prevent organ damage. Monitor for cardiac iron overload with MRI T2 (Option D): Important to assess for cardiac siderosis and guide chelation therapy.

References:

https://pmc.ncbi.nlm.nih.gov/articles/PMC4437060/

↑ *Back to this question in Part A*

@Neet_pg_bot

Q6: Which of the following genetic factors is most strongly associated with an increased risk of developing Type 1 Diabetes Mellitus? (Q850595)

A. HLA-B27

B. HLA-DR3 DR4

C. HLA DR2

D. HLA DR 5

Correct Answer: B. HLA-DR3 DR4

■ *Listen (English)*

■ *Listen (Hindi)*

Explanation: HLA- DR3/DR4 haplotypes are strongly linked to increased susceptibility to T1DM. Mechanism: Loss of immune tolerance and progressive β-cell apoptosis in the pancreas by self-CD4 cells. HLA-B27 (Option A): Associated with ankylosing spondylitis and other spondyloarthropathies, not T1DM. HLA-DR2 (Option C): Associated with multiple sclerosis and protection against T1DM. HLA-DR5 (Option D): Less commonly associated; not a major risk factor for T1DM.

References:

Davidson’s Principles and Practice of Medicine, 24th Edition, Page 728, 729

↑ *Back to this question in Part A*

@Neet_pg_bot

Q7: 25-year-old thin asymptomatic male is found to have fasting hyperglycemia during a routine checkup. His father and grandmother were diabetics.Genetic testing confirms a glucokinase mutation, consistent with MODY type 2. Which is correct management? (Q850593)

A. Start insulin

B. Start Metformin

C. Start semaglutide

D. No treatment required

Correct Answer: D. No treatment required

■ *Listen (English)*

■ *Listen (Hindi)*

Explanation: MODY2 is characterized by mutations in the GCK gene, leading to stable mild hyperglycemia without requiring treatment. Patients with this subtype typically maintain normal renal function and do not experience significant progression of diabetes. In contrast in MC subtype MODY 3 that occurs due to HNF1A mutation, treatment is given with glipizide. Insulin (Option A): Not required; hyperglycemia is mild and stable. Metformin (Option B): Usually ineffective in GCK-MODY. Semaglutide (Option C): Not indicated; MODY2 rarely benefits from pharmacotherapy.

References:

Davidson's Principles and Practice of Medicine, 24th Edition, Page 733

↑ *Back to this question in Part A*

@Neet_pg_bot

Q8: Which of the following is most important intervention to reduce the progression of macrovascular complications of diabetes mellitus (Q850591)

A. Tight glycaemic control with HbA1c < 7%

B. Tight BP control and statins

C. Cessation of smoking

D. Limitation of sedentary activities

Correct Answer: B. Tight BP control and statins

■ *Listen (English)*

■ *Listen (Hindi)*

Explanation: Strict BP control and control of dyslipidemia are main interventions to reduce macrovascular complications in diabetes, such as myocardial infarction and stroke. Statin therapy is essential to lower LDL cholesterol. Target BP is <130/80 mm Hg and Target LDL is < 70 mg/dl. Macrovascular Complications of Diabetes Mellitus: Coronary circulation: Myocardial ischemia/infarction. Cerebral circulation: Transient ischemic attack, stroke. Peripheral circulation: Claudication, ischemia. Tight glycemic control with HbA1c <7% (Option A): Primarily reduces microvascular complications, less impact on macrovascular disease. Cessation of smoking (Option C): Important lifestyle measure, supportive but not as potent as BP/statin control. Limitation of sedentary activities (Option D): Helpful adjunct for overall cardiovascular health, but less direct impact on macrovascular outcomes.

References:

Davidson's Principles and Practice of Medicine, 24th Edition, Page 743, 755, 756, 757

↑ *Back to this question in Part A*

@Neet_pg_bot

Q9: Which of the following is not a microvascular complication of diabetes mellitus? (Q850587)

A. Diabetic retinopathy

B. Diabetic neuropathy

C. Diabetic foot

D. Diabetic nephropathy

Correct Answer: C. Diabetic foot

■ *Listen (English)*

■ *Listen (Hindi)*

Explanation: Diabetic foot is primarily a macrovascular complication resulting from peripheral artery disease and neuropathy. Diabetic Microvascular Complications Diabetic retinopathy Diabetic nephropathy Diabetic neuropathy (overall most common complication of DM)

References:

Davidson’s Principles and Practice of Medicine, 24th Edition, Page 756- 762

↑ *Back to this question in Part A*

@Neet_pg_bot

Q10: Which of the following is most important intervention for a newly diagnosed type 2 diabetes mellitus patient with HbA1c of 7%? (Q850586)

A. Hypocaloric diet

B. Carbohydrate counting

C. Light aerobic activity

D. Start cereals with low glycemic index

Correct Answer: A. Hypocaloric diet

■ *Listen (English)*

■ *Listen (Hindi)*

Explanation: Lifestyle modifications like hypocaloric diet(500 Kcal restriction per day) is single most important intervention in newly diagnosed type 2DM. Carbohydrate counting is done for T1DM. Consumption of cereals with low glycemic index is universal intervention in all diabetics to prevent post prandial spikes. Even a 5–10% weight loss through calorie restriction can dramatically improve insulin sensitivity, reduce HbA1c, and potentially lead to diabetes remission in early T2DM. Carbohydrate counting (Option B): Mainly used in Type 1 DM for insulin dose adjustment. Light aerobic activity (Option C): Helpful adjunct but dietary control is the most crucial first intervention. Start cereals with low glycemic index (Option D): Supportive dietary advice, not the primary intervention.

References:

Davidson’s Principles and Practice of Medicine, 24th Edition, Page 722, 726, 727, 728, 743, 744, 745.

↑ *Back to this question in Part A*

@Neet_pg_bot

Q11: A 12-year-old girl presents with abdominal pain, vomitting and prostration for past one day. O/E: pulse:100/min, BP: 100/60 mm Hg and RR=20/min with a fruity-smelling breath. Work up shows plasma glucose level of 350 mg/dL and a positive urine ketone test. Which of the following is next step for managment of this patient? (Q850540)

A. Start regular insulin drip at 0.05–0.1 U/kg/hr

B. Give normal saline bolus

C. Perform ABG

D. Check serum electrolytes

Correct Answer: C. Perform ABG

■ *Listen (English)*

■ *Listen (Hindi)*

Explanation: This child is having presentation of diabetic ketoacidosis on clinical grounds. However, the triad of DKA is not satisfied. Without a complete diagnosis we don't start treatment. RBS is > 200 mg/dl with symptoms, Urine ketones are present Acidosis report is not given in case presentation. We should first perform ABG to demonstrate low bicarbonate and low pH. It would take not more than few minutes and hence delay in treatment would not change the course of illness. Also note that vitals are decent and patient does not need bolus IV fluids. If this patient was having crashing vitals then giving fluid bolus would have given been preference over all others. The sequence in management of this patient will be Perform ABG (check lactate levels for possibility of lactic acidosis or sepsis and check potassium levels) IV Fluid saline over 1 hour to correct dehydration + KCL added to

IV fluid bottle Once K+ is ≥3.3 mEq/L and at least 1–2 hours of fluid therapy has been given, start regular insulin infusion at 0.05–0.1 U/kg/hr If blood sugar falls to below 250 mg/dl change IV fluid to N/2 in 5%D Transition to subcutaneous insulin once patient is alert, eating, and metabolic parameters (AG, pH, bicarb) normalize

References:

Harrison's Principle of Internal Medicine, 21st Edition, Page 3095

↑ *Back to this question in Part A*

@Neet_pg_bot

Q12: A 50-year-old woman presents for a routine check-up. She has no family history of diabetes or hypertension. According to the American Diabetes Association (ADA) guidelines, what is the most appropriate screening recommendation for her? (Q850568)

A. No screening is necessary until age 60

B. Screen now and re-screen every 3 years if normal

C. Screen every year regardless of results

D. Screen only if symptoms of diabetes appear

Correct Answer: B. Screen now and re-screen every 3 years if normal

■ *Listen (English)*

■ *Listen (Hindi)*

Explanation: The American Diabetes Association recommends that adults aged 45 and older undergo screening for diabetes, regardless of risk factors. Since the patient is 50 years old, she should be screened now, with re-screening every 3 years if the results are normal, ensuring early detection and intervention if necessary. Summary of Screening Guidelines Population First Screening Age Rescreening Frequency General Adults 45 years Every 3 years, if normal Overweight/Obese Adults Any age Based on individual risk factors Individuals with Prediabetes N/A Annually High-Risk Ethnic Groups <45 years Every 3 years, if normal Pregnant Women During pregnancy As needed, based on risk factors

References:

https://www.ncbi.nlm.nih.gov/books/NBK574060/

https://www.ncbi.nlm.nih.gov/books/NBK554615/

↑ *Back to this question in Part A*

@Neet_pg_bot

Q13: Which of the following is best for monitoring of diabetes mellitus? (Q850566)

A. Continous glucose monitoring

B. HbA1c

C. Post prandial blood glucose

D. Self monitoring of blood glucose

Correct Answer: A. Continous glucose monitoring

■ *Listen (English)*

■ *Listen (Hindi)*

Explanation: Continuous glucose monitoring measures real-time glucose trends. It can detect nocturnal and silent hypoglycemia. It is unaffected by hemoglobinopathy and anemia. The biggest advantage is, it gives an immediate therapy adjustment opportunity. HbA1c (Option B) can be affected by hemoglobinopathies, anemia and does not detect hypoglycemic episodes that occur in diabetics. Postprandial blood glucose (Option C) is too variable-dependent on meal timing and composition Self-monitoring of blood (Option D) glucose is usually avoided by diabetics due to the hassle of pricking self.

References:

Davidson's Principles and Practice of Medicine, 24th Edition, Page 724, 727

↑ *Back to this question in Part A*

@Neet_pg_bot

Q14: Which of the following tests is the most appropriate for short-term monitoring of glycemic control in a diabetic patient ? (Q850563)

A. HbA1c

B. Fructosamine

C. Fasting Blood Glucose

D. Oral Glucose Tolerance Test (OGTT)

Correct Answer: B. Fructosamine

■ *Listen (English)*

■ *Listen (Hindi)*

Explanation: Fructosamine is the best choice for short-term glycemic control monitoring because it reflects average blood glucose levels over the past 2-3 weeks , allowing for timely adjustments in diabetes management. This is crucial when monitoring changes after medication adjustments, unlike HbA1c (Option A), which indicates longer-term control over 2-3 months. Fasting, Postprandial Plasma Glucose and OGTT (Options C & D) provide only single-time-point results.

References:

www.ncbi.nlm.nih.gov/pmc/articles/PMC4604592/

↑ *Back to this question in Part A*

@Neet_pg_bot

Q15: Glycosylated Hemoglobin is not reliable in diagnosis of which of the following types of diabetes mellitus? (Q850560)

A. Bronze diabetes

B. Type 1 Diabetes mellitus

C. Type 1.5 Diabetes mellitus

D. Type 2 Diabetes mellitus

Correct Answer: A. Bronze diabetes

■ *Listen (English)*

■ *Listen (Hindi)*

Explanation: Glycated Hemoglobin (HbA1c) effectively assesses overall glycemic control and is suitable for diagnosing diabetes in asymptomatic individuals. Bronze diabetes is seen in transfusion-dependent thalassemia patients. They develop hemochromatosis, and iron excess damages the beta cells of the pancreas, leading to insulinopenia. Thalassemia patients have low HbA, which will cause falsely low HbA1c. Causes of falsely low or normal HbA1c (due to decreased RBC turnover) Causes of falsely elevated HbA1c Hemolytic anemia Acute blood loss Chronic liver disease Reticulocytosis B-12/Folate deficiency Iron deficiency anemia

References:

Davidson’s Principles and Practice of Medicine, 24th Edition, Pages 722, 726, 727, 728

↑ *Back to this question in Part A*

@Neet_pg_bot

Q16: Which of the following values is not used for diagnosis of diabetes mellitus? (Q850556)

A. Random Blood sugar of 250 mg/dl with classic symptoms

B. Post prandial value of 200 mg/dl

C. Fasting blood sugar of 140 mg/dl in an asymptomatic patient

D. HbA1c value of 7.8% in asymptomatic patient

Correct Answer: B. Post prandial value of 200 mg/dl

■ *Listen (English)*

■ *Listen (Hindi)*

Explanation: Post-prandial value is used for monitoring and follow-up, and not for diagnosis. In the ADA diagnosis table, is 2-hour value > 200 mg/dl is used for diagnosis. The 2-hour value is taken after a glucose challenge of 75gm glucose and is not the same as the post-prandial value. PP value can be influenced by the type of meal taken. Random blood sugar> 200 mg/dl with classic symptoms, fasting blood sugar of 140 mg/dl in an asymptomatic patient, and HbA1c value of 7.8% in an asymptomatic patient are all used for the diagnosis of diabetes mellitus.

References:

Davidson’s Principles and Practice of Medicine, 24th Edition, Page 722, 726, 727, 728.

↑ *Back to this question in Part A*

@Neet_pg_bot

Q17: Which of the following drugs is most likely to cause drug-induced diabetes by impairing insulin secretion from the pancreas? (Q850550)

A. Glucocorticoids

B. Thiazide diuretics

C. Phenytoin

D. β-lactam antibiotics

Correct Answer: B. Thiazide diuretics

■ *Listen (English)*

■ *Listen (Hindi)*

Explanation: Thiazide diuretics are known to impair insulin secretion from the pancreas (possibly secondary to the hypokalemia induced by the thiazide diuretics), leading to increased blood glucose levels and a higher risk of developing diabetes. Drugs Causing Diabetes Drugs Affecting Glucose levels (Not Causing DM) Glucocorticoids – Increase insulin resistance (Option A); can cause temporary or type 2 diabetes β-lactam antibiotics – Interfere with urine glucose tests (Option D) Thiazide diuretics – Impair insulin secretion (Option B); used for hypertension Levodopa – May cause false-positive glucose results Phenytoin – Possible liver-related mechanism (Option C); anticonvulsant Salicylates – Affect glucose measurements in urine

References:

Davidson's Principles and Practice of Medicine, 24th Edition, Page 725, 728, 733

KD Tripathi, Essentials of Medical Pharmacology, 8th edition, Page 606.

↑ *Back to this question in Part A*

@Neet_pg_bot

Q18: An 8-year-old boy is brought to ER with a 2-day history of vomiting, abdominal pain and prostration. On examination, he is drowsy, with sunken eyes, dry tongue, cold extremities, a thready pulse of 140/min, BP of 80/50 mmHg and RR =30/min. His RBS : 460 mg/dL, urine shows 4+ ketones and ABG shows pH= 7.2 , pC02 =20 mm Hg and HCO3 = 5 meq/L. What is the most appropriate next step in management? (Q850548)

A. Start IV insulin infusion at 0.1 U/kg/hr

B. Start normal saline with insulin drip

C. Give bolus of normal saline

D. Normal saline with insulin bolus followed insulin drip

Correct Answer: C. Give bolus of normal saline

■ *Listen (English)*

■ *Listen (Hindi)*

Explanation: This child has severe DKA with hypovolemic shock. In DKA with shock, the FIRST and most urgent step is fluid resuscitation. Administer 10–20 mL/kg of 0.9% normal saline over 30–60 minutes , repeating as needed until perfusion improves. This restores circulating volume, improves tissue perfusion, and helps correct acidosis. Start IV insulin immediately (Option A): Insulin before fluids can cause cerebral edema and worsen hypokalemia. Bolus of insulin has been discontinued as per the latest ISPAD guidelines Start bicarbonate infusion (Option B): Bicarbonate is avoided unless pH < 6.9. Raises risk of cerebral edema and offers no benefit here. Start maintenance IV fluids (Option D): Too slow for a child in shock. Must give rapid NS bolus, not maintenance rates.

References:

ISPAD guidelines

↑ *Back to this question in Part A*

@Neet_pg_bot

Q19: Which of the following statements about Type 1.5 Diabetes Mellitus is incorrect? (Q850545)

A. Characterized by autoimmune destruction of beta cells

B. Start basal bolus insulin if C- peptide > 0.8 ng/ml

C. It is often misdiagnosed as Type 2 DM

D. Avoid use of sulfonlyureas

Correct Answer: B. Start basal bolus insulin if C- peptide > 0.8 ng/ml

■ *Listen (English)*

■ *Listen (Hindi)*

Explanation: Type 1.5 DM or Latent Autoimmune Diabetes in Adults (LADA) is usually diagnosed in adults, often in their 20s to 30s, distinguishing it from Type 1 DM which commonly presents in childhood. If C-peptide > 0.8 ng/mL (Preserved Function): Start metformin or DPP-4 inhibitors or GLP-1 agonists. Avoid sulfonylureas as they deplete beta cells faster If C-peptide = 0.3–0.8 ng/mL (Moderate dysfunction): Use Basal insulin + metformin or DPP-4i If C-peptide < 0.3 ng/mL (Severe deficiency):Start basal-bolus or basal + mealtime insulin Autoimmune β-cell destruction (Option A): True; LADA is an autoimmune diabetes similar to Type 1 but with slower progression. Often misdiagnosed as Type 2 DM (Option C): True; adults initially appear like T2DM but progressively lose β-cell function. Avoid sulfonylureas (Option D): True; they accelerate β-cell exhaustion and worsen progression in LADA.

References:

www.ncbi.nlm.nih.gov/books/NBK557897/

↑ *Back to this question in Part A*

@Neet_pg_bot

• [03_Endocrinology] 014 Diabetes Mellitus-Ii

« Back to Folder Directory

[03_Endocrinology] 014 Diabetes Mellitus-Ii — Quick Jump

Q1 (p. 1519) *Q2 (p. 1519)* *Q3 (p. 1520)* *Q4 (p. 1521)* *Q5 (p. 1522)* *Q6 (p. 1522)*
Q7 (p. 1523) *Q8 (p. 1524)* *Q9 (p. 1524)* *Q10 (p. 1525)* *Q11 (p. 1526)* *Q12 (p. 1527)*
Q13 (p. 1528) *Q14 (p. 1529)* *Q15 (p. 1529)* *Q16 (p. 1530)* *Q17 (p. 1531)* *Q18 (p. 1531)*
Q19 (p. 1532)

Q1: A 22-year-old female with newly diagnosed Type 1 Diabetes Mellitus is struggling to maintain postprandial glucose levels despite basal-bolus insulin therapy. Her endocrinologist decides to add an adjunctive medication approved for both type 1 and type 2 diabetes mellitus. Which of the following drugs fits this indication? (Q850634)

A. Empagliflozin

B. Linagliptin

C. Pramlintide

D. Semaglutide

Correct Answer: C. Pramlintide

■ *Listen (English)*

■ *Listen (Hindi)*

Explanation: Pramlintide is an amylin analog, approved for use in both type 1 and type 2 diabetes mellitus, in patients already on insulin. It slows gastric emptying, suppresses postprandial glucagon, and promotes satiety, helping improve postprandial glucose control. Empagliflozin (Option A) (SGLT2 inhibitor) is used only in type 2 DM, not type 1 due to DKA risk. Linagliptin (Option B) is a DPP-4 inhibitor. Semagutide (Option D) is not approved for use in type 1 DM as it needs some beta cell reserve to be able to produce insulin by incretin effect

References:

Harrison’s Principle of Internal Medicine, 21st Edition, Page 3111

↑ *Back to this question in Part A*

@Neet_pg_bot

Q2: A 65-year-old woman with poorly controlled diabetes mellitus presents to the emergency department with fever, facial pain, and a black necrotic eschar on her nasal turbinates. A CT scan shows sinus involvement and extension to the brain. What is the most appropriate initial management for this patient? (Q850781)

A. Fluconazole

B. Immediate surgical debridement and intravenous amphotericin B

C. Doxycyline and Azithromycin

D. Piperacillin Tazobactum

Correct Answer: B. Immediate surgical debridement and intravenous amphotericin B

■ *Listen (English)*

■ *Listen (Hindi)*

Explanation: In cases of rhino-cerebral mucormycosis, especially with signs of significant tissue necrosis and possible central nervous system involvement, immediate surgical debridement is essential to remove necrotic tissue and control the infection. Intravenous amphotericin B is the first-line antifungal treatment that targets the causative organisms, significantly improving the patient's chances of survival.

References:

https://www.ncbi.nlm.nih.gov/books/NBK557429/

↑ *Back to this question in Part A*

@Neet_pg_bot

Q3: A 55-year-old woman with a 10-year history of type 2 diabetes presents for a routine eye examination with compliants of visual loss. On examination, she is found to have microaneurysms, retinal haemorrhages, cotton wool spots and macular edema. What is the most effective management option for her symptomatic foveal oedema? (Q850780)

A. Pan-retinal laser photocoagulation

B. Intravitreal anti-VEGF injections

C. Corticosteroid injections

D. Routine observation and follow-up

Correct Answer: B. Intravitreal anti-VEGF injections

■ *Listen (English)*

■ *Listen (Hindi)*

Explanation: The patient likely has diabetic macular oedema, a complication of diabetic retinopathy characterized by retinal thickening and fluid accumulation in the macula. This condition can lead to visual impairment and requires prompt treatment to preserve vision. Anti-VEGF therapy has been shown to be more effective than laser treatment for symptomatic foveal oedema in diabetic macular oedema. Pan-retinal laser photocoagulation (Option A) : While effective for proliferative diabetic retinopathy, it is not the first-line treatment for symptomatic foveal oedema. Corticosteroid injections (Option C) : While they may have some benefit, anti-VEGF injections are typically preferred in current clinical practice for treating diabetic macular oedema. Routine observation and follow-up (Option D) : This option is not appropriate for symptomatic foveal oedema, as timely intervention is necessary to prevent vision loss.

References:

Davidson's Principles and Practice of Medicine, 24th Edition, Page 1174- 1177

↑ *Back to this question in Part A*

@Neet_pg_bot

Q4: Best screening test for evaluation of diabetic nephropathy is (Q850779)

A. HbA1c

B. BUN: Creatinine ratio

C. Creatinine clearance

D. Urinary protein to creatinine ratio

Correct Answer: D. Urinary protein to creatinine ratio

■ *Listen (English)*

■ *Listen (Hindi)*

Explanation: Serum creatinine and creatinine clearance rise only after significant nephron loss (≥50%) , so they miss early kidney damage like microalbuminuria. They are late markers and poor indicators for early diabetic nephropathy screening . Diabetic nephropathy begins with microalbuminuria (30–300 mg/day). uPCR can detect even small increases in albumin accurately. Most important is that it is a quantitative test and not qualitative test. By using creatinine as a reference, uPCR corrects for variations in urine concentration. It r equires only a random spot urine sample, not cumbersome 24-hour urine collection. Improves patient compliance. More consistent and less expensive than repeated 24h urine collections. Useful for routine diabetic follow-up HbA1c (Option A): Reflects long-term glycemic control but does not assess kidney damage or albuminuria. BUN:Creatinine ratio (Option B): Useful for differentiating pre-renal vs intrinsic renal failure, not for screening diabetic nephropathy. Creatinine clearance (Option C): Detects later decline in GFR; not sensitive for early microalbuminuria in diabetic

nephropathy.

References:

Davidson’s Principles and Practice of Medicine, 24th Edition, Page 757-759

↑ *Back to this question in Part A*

@Neet_pg_bot

Q5: All of the following are correct about diabetic neuropathy except? (Q850778)

A. Affects unmyelinated type C fibers

B. Third nerve palsy presents with pupillary involvement

C. Orthostatic hypotension occurs due to involvement of type B fibers

D. Clonidine is used for management of diabetic diarrhea

Correct Answer: B. Third nerve palsy presents with pupillary involvement

■ *Listen (English)*

■ *Listen (Hindi)*

Explanation: Most common cranial nerve affected in DM is occulomotor nerve with pupillary sparing. Microvascular ischemia affects the central core of the nerve where the somatic motor fibers are located . Thus EOM palsy will occur causing ptosis and eye being down and out. Peripheral parasympathetic fibers are spared because they are supplied by pial blood vessels on the nerve’s surface. Diabetic neuropathy affects unmyelinated type C fibers, causing burning pain and autonomic symptoms because these fibers are most vulnerable to chronic hyperglycemia-induced oxidative stress. (Option A) Orthostatic hypotension arises from damage to lightly myelinated type B preganglionic fibers, as ischemia impairs sympathetic vasoconstriction needed to maintain BP upon standing. (Option C) Clonidine, an α2-agonist, helps in diabetic diarrhea by reducing intestinal secretions through inhibition of sympathetic outflow to the gut. (Option D)

References:

Davidson’s Principles and Practice of Medicine, 24th Edition, Page 758-761.

↑ *Back to this question in Part A*

@Neet_pg_bot

Q6: Which of the following is not correct about Type 2 diabetes mellitus? (Q850776)

A. Polygenic inheritance

B. Increased insulin levels

C. Beta cell exhaustion

D. Increased PPAR-γ activity

Correct Answer: D. Increased PPAR-γ activity

■ *Listen (English)*

■ *Listen (Hindi)*

Explanation: Type 2 diabetes mellitus is characterized by insulin resistance and β-cell dysfunction. PPAR-γ is a nuclear receptor that improves insulin sensitivity when activated. In T2DM, endogenous PPAR-γ activity is not increased; instead, insulin resistance predominates. Reduced or dysfunctional PPAR-γ signaling is more consistent with the metabolic state of T2DM. Drugs like Thiazolidinediones (TZDs) intentionally activate PPAR-γ to treat insulin resistance. Therefore, increased PPAR-γ activity is not a pathological feature of T2DM. Incorrect Options: Option A) Polygenic inheritance - Correct : T2DM has a strong genetic basis involving multiple genes . Shows familial clustering. Option B) Increased insulin levels - Correct (early phase) : Due to insulin resistance, the pancreas initially compensates with hyperinsulinemia . Insulin levels fall later as β-cells fail. Option C) Beta-cell exhaustion - Correct . Chronic overwork of β-cells leads to β-cell dysfunction and failure , producing sustained hyperglycemia.

References:

Davidson’s Principles and Practice of Medicine, 24th Edition, Page 730, 731, 743

↑ *Back to this question in Part A*

@Neet_pg_bot

Q7: Which of the following is correct about mechanism of action of Acarbose? (Q850774)

A. Increases insulin secretion from pancreatic beta cells

B. Inhibits α-glucosidase in intestinal brush border

C. Increases glucose uptake in peripheral tissues

D. Enhances insulin sensitivity in peripheral tissues

Correct Answer: B. Inhibits α-glucosidase in intestinal brush border

■ *Listen (English)*

■ *Listen (Hindi)*

Explanation: Acarbose inhibits alpha-glucosidase enzymes in the gut, slowing the digestion of carbohydrates and reducing post-meal glucose spikes. It is taken with each meal to reduce post-prandial blood glucose and modestly improve glycemic control.

References:

Davidson’s Principles and Practice of Medicine, 24th Edition, Page 747

↑ *Back to this question in Part A*

@Neet_pg_bot

Q8: Which of the following is not correct about complications seen in Diabetes mellitus? (Q850640)

A. Blindness incidence is increased by 25 times

B. Foot gangrene and amputation risk is increased by 100 times

C. Most common site of diabetic foot ulcer is heel

D. Diabetic nephropathy is leading cause of Chronic kidney disease

Correct Answer: C. Most common site of diabetic foot ulcer is heel

■ *Listen (English)*

■ *Listen (Hindi)*

Explanation: A diabetic foot ulcer is usually seen on the toes or metatarsal heads, not heels Risk of blindness in diabetics is up to 25 times higher than in the normal population due to neovascularization. It can lead to retinal detachment and vitreous hemorrhage. Diabetic nephropathy leads to diffuse glomerulosclerosis that causes progressive decline of eGFR. At values less < 30 ml /min, either Hemodialysis or kidney transplantation decision-making has to be done. Due to the combination of neuropathy and angiopathy, the risk of critical limb ischemia, non-healing ulcers, and ultimately digital gangrene or limb amputation is much higher, reaching up to 40-100x times more than the normal population.

References:

Harrison’s Principles of Internal Medicine, 21st Edition, Page 3113

↑ *Back to this question in Part A*

@Neet_pg_bot

Q9: Which of the following is not correct about SGLT2i (Q850638)

A. Lowering of SBP

B. Used in HFreEF in non diabetic population

C. Cause afferent arteriolar dilatation

D. Increased risk of mycotic genital infections

Correct Answer: C. Cause afferent arteriolar dilatation

■ *Listen (English)*

■ *Listen (Hindi)*

Explanation: SGLT2i will cause salt loss in urine. It will increase sodium at macula densa and cause afferent constriction. This reduces intraglomerular pressure. Thus it reduces progression of diabetic nephropathy Salt loss in urine also lowers SBP by 5 mm Hg and explains the cardiovascular benefit without causing orthostatic hypotension Increased sugar levels in urine explains the risk of mycotic genital infections and UTI.

References:

Harrison's Principle of Internal Medicine, 21st Edition, Page 3112

↑ *Back to this question in Part A*

@Neet_pg_bot

Q10: Which of the following is the earliest renal abnormality in diabetic nephropathy? (Q850636)

A. Microalbuminuria

B. Nodular glomerulosclerosis

C. Increased glomerular filtration rate

D. Proteinuria (>300 mg/day)

Correct Answer: C. Increased glomerular filtration rate

■ *Listen (English)*

■ *Listen (Hindi)*

Explanation: The earliest functional change in diabetic nephropathy is glomerular hyperfiltration, seen as an increased GFR due to afferent arteriolar dilation resulting from altered tubuloglomerular feedback. This precedes microalbuminuria, which marks the first clinical stage. Structural changes like Kimmelstiel–Wilson nodules occur much later.

References:

Brenner & Rector’s The Kidney (11th Ed)

↑ *Back to this question in Part A*

@Neet_pg_bot

Q11: 50-year-old man with T2DM presents with consistently elevated early morning blood glucose levels. His continous glucose monitoring does not show any noctural hypoglycemia. His current insulin regimen includes twice-daily intermediate-acting insulin. Which of the following is the most likely explanation for his fasting hyperglycaemia? (Q850615)

A. Excess dose of insulin given the day before

B. Increased insulin sensitivity between 4 am to 8 am

C. Inreased insulin resistance between 4 am to 8 am

D. Beta cell exhausation

Correct Answer: C. Inreased insulin resistance between 4 am to 8 am

■ *Listen (English)*

■ *Listen (Hindi)*

Explanation: The patient has dawn phenomenon , where early morning hyperglycemia results from increased insulin resistance between 4 am to 8 am. The lack of preceding nocturnal hypoglycemia rules out somogyi phenomenon. Somogyi phenomenon : Hormones involved are catecholamines, cortisol, glucagon and GH Dawn phenomenon : Hormones involved are cortisol and GH {{caption_text}}

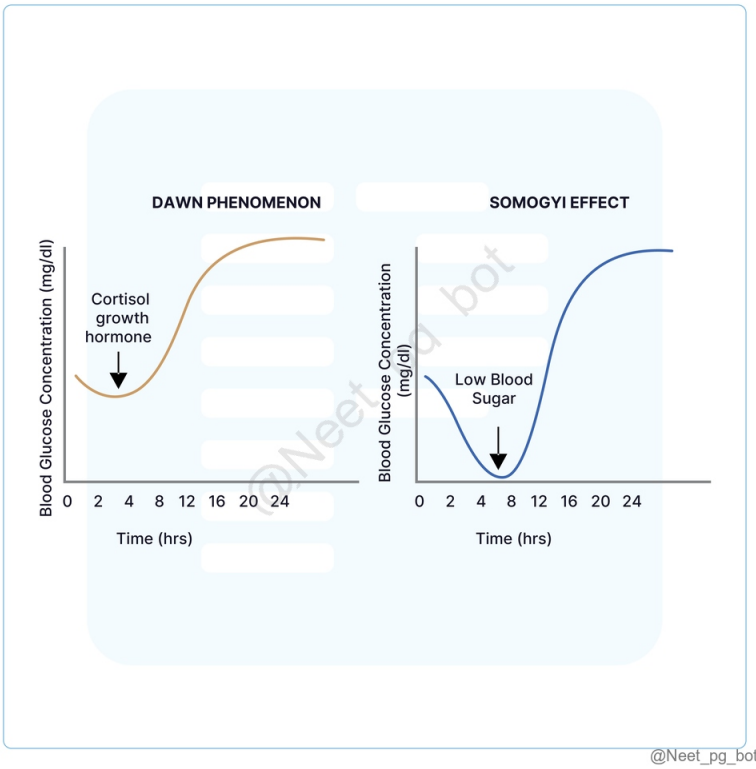

@Neet_pg_bot

References:

Davidson's Principles and Practice of Medicine, 24th Edition, Page 741, 750

https://www.ncbi.nlm.nih.gov/books/NBK551525/

↑ *Back to this question in Part A*

@Neet_pg_bot

Q12: Which of the following drugs slows the progression of diabetic nephropathy and is an aldosterone antagonist? (Q850632)

A. Finrenone

B. Empagliflozin

C. Linagliptin

D. ACEi

Correct Answer: A. Finrenone

■ *Listen (English)*

■ *Listen (Hindi)*

Explanation: Drugs that slow the progression of CKD in diabetic nephropathy ACEi or ARB Finrenone SGLT2i - Empagliflozin GLP1RA Drugs to avoid in diabetic nephropathy NSAIDS Metformin Dual RAAS blockade with ACEi and ARB

References:

Harrison's Principle of Internal Medicine, 21st Edition, Page 3111

↑ *Back to this question in Part A*

@Neet_pg_bot

Q13: A 52-year-old obese male with poorly controlled Type 2 Diabetes Mellitus is started on semaglutide. Which of the following statements is not true regarding this drug? (Q850629)

A. It acts via GLP-1 receptor agonism, enhancing glucose-dependent insulin secretion

B. It may cause abdominal pain and elevated serum amylase levels suggestive of pancreatitis

C. It can cause transient worsening of diabetic retinopathy, especially in patients with rapid glycemic improvement

D. It commonly causes fluid retention and weight gain due to PPAR-γ activation

Correct Answer: D. It commonly causes fluid retention and weight gain due to PPAR-γ activation

■ *Listen (English)*

■ *Listen (Hindi)*

Explanation: Fluid retention and weight gain are side effects of thiazolidinediones like pioglitazone which act via PPAR-γ – not seen with semaglutide. Semaglutide carries a black box warning for Risk of thyroid C-cell tumors, including medullary thyroid carcinoma (MTC) based on studies on rodents. So contraindicated in patients with MEN 2 Semaglutide is a GLP-1 receptor agonist, increases insulin release in a glucose-dependent manner. (Option A) Semaglutide is associated with pancreatitis; patients may show raised amylase/lipase. (Option B) Rapid correction of chronic hyperglycemia by semaglutide and even intensive insulin therapy causes sudden shift in retinal perfusion , altered retinal blood flow and endothelial function causing transient worsening of pre-existing microvascular damage. (Option C)

References:

Harrison's Principle of Internal Medicine, 21st Edition, Page 3110

↑ *Back to this question in Part A*

@Neet_pg_bot

Q14: A 50-year-old woman with Type 2 diabetes mellitus presents with extreme fatigue and thirst. She is non-compliant with her medications. Her blood pressure is 170/100 mmHg, and labs show: Random plasma glucose: 286 mg/dL HbA1c: 11.2% Urine glucose: +++ Serum creatinine: 2 mg/dL eGFR: 25 mL/min Serum potassium: 6.5 mEq/L Which of the following is NOT appropriate for managing this patient? (Q850628)

A. Monitor urine albumin creatinine ratio

B. Start Metformin with Sitagliptin

C. Start Amlodipine

D. Start Empagliflozin

Correct Answer: B. Start Metformin with Sitagliptin

■ *Listen (English)*

■ *Listen (Hindi)*

Explanation: Metformin is contraindicated in patients with eGFR <30 mL/min due to the risk of lactic acidosis . Sitagliptin is renally excreted and requires dose adjustment in CKD stage 4; starting standard doses is not appropriate . Monitor urine albumin-to-creatinine ratio (Option A): Essential for tracking progression of diabetic nephropathy. Start Amlodipine (Option C): Calcium channel blockers are safe for hypertension in CKD. Preferred when serum potassium is high , since ACE inhibitors/ARBs may worsen hyperkalemia. Start Empagliflozin (Option D) : SGLT2 inhibitors provide cardiorenal benefits : lower blood pressure, reduce proteinuria, and slow CKD progression. Can be used cautiously in patients with eGFR 25 mL/min , though glucose-lowering efficacy decreases at lower eGFR.

References:

Harrison’s Principle of Internal Medicine, 21st Edition, Page 3110

↑ *Back to this question in Part A*

@Neet_pg_bot

Q15: You are educating a mother of 8-year-old girl with type 1 Diabetes Mellitus about insulin administration techniques. Which of the following statements is incorrect regarding insulin delivery? (Q850626)

A. The preferred site for subcutaneous insulin injection is the anterior abdominal wall.

B. Insulin pens should be held at a 90° angle to the skin for optimal delivery

C. Repeated insulin injections at the same site can cause lipohypertrophy

D. Repeat the insulin injection spot after 5-7 days

Correct Answer: D. Repeat the insulin injection spot after 5-7 days

■ *Listen (English)*

■ *Listen (Hindi)*

Explanation: Repeating the same injection spot should be avoided for at least 2 weeks to allow tissue healing and reduce lipodystrophy risk. Repeated use of the same site may cause lipodystrophy. Lipohypertrophy is more common and is seen due to the anabolic effects of insulin. The anterior abdominal wall is the preferred site due to consistent absorption. 90° angle ensures proper SC delivery using insulin pens or syringes.

References:

Harrison's Principle of Internal Medicine, Edition 21st- Page 3108, 3106.

↑ *Back to this question in Part A*

@Neet_pg_bot

Q16: A 60-year-old diabetic patient collapsed in the bathroom in the morning and died. She was on metformin and glipizide for the last 10 years. Her latest HbA1c was 11%. What can be a possible cause of this event? (Q850623)

A. Autonomic neuropathy

B. Congestive chronic heart failure

C. Pericardial tamponade

D. Catastrophic CNS hemorrhage

Correct Answer: A. Autonomic neuropathy

■ *Listen (English)*

■ *Listen (Hindi)*

Explanation: Uncontrolled diabetes with a 10-year duration will have an increased risk of cardiac autonomic neuropathy. It can cause silent myocardial ischemia, arrhythmias, nocturnal bradycardia, or QT prolongation, leading to sudden death, especially overnight or early morning (bathroom collapse is classic). HbA1c: 11% indicates suboptimal control, further increasing microvascular and autonomic complications. Congestive chronic heart failure (Option B) causes gradual decompensation, not sudden collapse unless massive arrhythmia.

Pericardial tamponade (Option C) : There is no history suggestive of cardiac tamponade. CNS bleed (Option D) w ould present with headache, focal neuro deficits, and may not cause instant death unless massive

References:

Insulin- Pharmacology, Therapeutic Regimens and Principles of Intensive Insulin Therapy - Endotext - NCBI Bookshelf (nih.gov)

Harrison's Principle of Internal Medicine, 21st Edition, Page 3108, 3109

↑ *Back to this question in Part A*

@Neet_pg_bot

Q17: A 55-year-old man with T2DM is brought to ER in unconcious state. Work up shows ABG pH=7.38, pCO2 40 mm Hg HCO3 = 26 meq/L, Sodium 140 meq/L , K =5.5 meq/L urine ketostix is negative, RBS : 150 mg/dl and serum lactate is normal. Which of the following is correct about next step in managment of this patient? (Q850621)

A. NCCT head

B. Normal saline followed by insulin drip

C. Administer 50% dextrose

D. Draw blood culture and start empirical antimicrobials

Correct Answer: A. NCCT head

■ *Listen (English)*

■ *Listen (Hindi)*

Explanation: Presentation given is of a diabetic patient with normal glucose, no acidosis, no ketones, and normal lactate, the most likely cause of sudden unconsciousness should trigger an evaluation for neurological causes (e.g., stroke or seizure). Based on lab reports hypoglycemia, DKA, hyperosmolar hyperglycemic state and sepsis are ruled out. Hence we will perform NCCT head to evaluate for CNS event like stroke.

References:

Harrison's Principle of Internal Medicine, 21st Edition, Page 3134, 3135.

↑ *Back to this question in Part A*

@Neet_pg_bot

Q18: Which of the following drug will worsen cardiovascular mortality in a diabetic patient who underwent a CABG? (Q850618)

A. Semaglutide

B. Empagliflozin

C. Rosiglitazone

D. Tirzepatide

Correct Answer: C. Rosiglitazone

■ *Listen (English)*

■ *Listen (Hindi)*

Explanation: Rosiglitazone, a thiazolidinedione , has been associated with an increased risk of cardiovascular events, particularly myocardial infarction and heart failure, especially in patients with existing cardiovascular disease or those who have undergone procedures like CABG. Antidiabetic drugs proven to reduce cardiovascular mortality in T2DM: SGLT2 inhibitors Empagliflozin, Canagliflozin, Dapagliflozin Proven to reduce CV death , hospitalization for heart failure , and renal outcomes Especially useful in T2DM with HF or CKD GLP-1 receptor agonists Semaglutide, Liraglutide, Dulaglutide Reduce major adverse cardiovascular events (MACE) in atherosclerotic CV disease Tirzepatide A dual GLP-1 + GIP agonist

References:

Harrison’s Principle of Internal Medicine, 21st Edition, Page 3106

↑ *Back to this question in Part A*

@Neet_pg_bot

Q19: Which form of insulin is used for basal delivery in basal bolus regimen? (Q850617)

A. Lispro

B. N.P.H

C. Glargine

D. Glulisine

Correct Answer: C. Glargine

■ *Listen (English)*

■ *Listen (Hindi)*

Explanation: In the basal–bolus insulin regimen, basal insulin is used to provide a continuous, peakless insulin level to control fasting and between-meal glucose. Insulin glargine is a long-acting insulin analog with a duration of ~24 hours and no pronounced peak, making it ideal for basal delivery. This regimen closely mimics physiological insulin secretion. Lispro (Option A): Lispro is a rapid-acting insulin used for prandial (bolus) coverage, not for basal insulin requirements. N.P.H (Option B): NPH is an intermediate-acting insulin with a definite peak, increasing the risk of hypoglycemia, and is less preferred for basal–bolus regimens. Glulisine (Option D): Glulisine is a rapid-acting insulin analog used for mealtime glucose control, not basal insulin delivery.

References:

Type 1 Diabetes - StatPearls - NCBI Bookshelf (nih.gov)

Harrison’s Principle of Internal Medicine, 21st Edition, Page 3104 - 3107

↑ *Back to this question in Part A*

@Neet_pg_bot

• [03_Endocrinology] 015 Dka And Hyperosmolar Coma Pancreatic Neuroendocrine Tumors

« Back to Folder Directory

[03_Endocrinology] 015 Dka And Hyperosmolar Coma Pancreatic Neuroendocrine Tumors — Quick Jump

Q1 (p. 1534)	*Q2 (p. 1535)*	*Q3 (p. 1535)*	*Q4 (p. 1536)*	*Q5 (p. 1537)*	*Q6 (p. 1538)*
Q7 (p. 1539)	*Q8 (p. 1539)*	*Q9 (p. 1540)*	*Q10 (p. 1541)*	*Q11 (p. 1542)*	*Q12 (p. 1543)*
Q13 (p. 1544)	*Q14 (p. 1544)*	*Q15 (p. 1545)*	*Q16 (p. 1546)*	*Q17 (p. 1547)*	*Q18 (p. 1548)*

Q1: A 45-year-old man comes with recurrent episodes of loss of consciousness, tremors, excessive sweating, and confusion. A tumour of the pancreas is suspected, and the serum proinsulin level (on a 72-hour fasting test) is raised. Which of the following investigations would be most preferred? (Q850664)

A. Computed tomography

B. MRI

C. Manual Palpation and Intraoperative Ultrasound

D. Endoscopic Ultrasound (EUS)

Correct Answer: D. Endoscopic Ultrasound (EUS)

Explanation: The clinical scenario points to insulinoma for which the main investigation of choice to confirm the diagnosis is endoscopic ultrasound. EUS is highly sensitive for detecting small insulinomas in the pancreas and allows precise localization before surgery. It is highly sensitive for small pancreatic neuroendocrine tumors (<2 cm) and allows fine-needle aspiration if needed. CT scan (Option A): Useful for larger pancreatic masses but less sensitive for detecting small insulinomas (<2 cm). MRI (Option B): Good soft tissue resolution but less sensitive than EUS for tiny lesions. Manual palpation and intraoperative ultrasound (Option C): Used during surgery, not as an initial preferred diagnostic tool.

References:

Harrison’s Principles of Internal Medicine, 21st edition, Page: 665.

Diagnosis and management of insulinoma - PMC

Essentials of Insulinoma Localization with Selective Arterial Calcium Stimulation and Hepatic Venous Sampling

↑ *Back to this question in Part A*

@Neet_pg_bot

Q2: A 48-year-old woman presents with a 6-month history of recurrent diarrhoea, weight loss, and intermittent abdominal pain. She also reports flushing and has recently developed diabetes without prior risk factors. Examination shows steatorrhea and a mild erythematous rash. Blood tests reveal elevated fasting plasma glucose. A pancreatic somatostatinoma is suspected.Which of the following investigations is NOT routinely used in the initial diagnosis of this condition? (Q850691)

A. Measurement of fasting somatostatin levels

B. CT/MRI imaging

C. Somatostatin receptor imaging

D. Biopsy with immunohistochemistry

Correct Answer: C. Somatostatin receptor imaging

Explanation: Somatostatinoma is a rare pancreatic neuroendocrine tumour characterised by: Diabetes Steatorrhea Gallstones Abdominal pain, diarrhoea, and occasional flushing Sometimes a necrolytic erythema-like rash Somatostatin receptor imaging (SRI) such as Octreotide scans or Ga-68 DOTATATE PET is not required for the initial diagnosis . It is mainly used for: Staging Assessing tumour burden Detecting metastases Evaluating somatostatin receptor expression for therapeutic planning Elevated fasting plasma somatostatin levels (Option A): Essential for diagnosis. CT/MRI imaging (Option B): These are first-line imaging modalities used to localize the pancreatic tumour; hence, routinely required. Biopsy and immunohistochemistry (Option D): Confirms the tumor histologically.

References:

Harrison’s Principles of Internal Medicine, 21st edition, Page: 665, 2987.

Somatostatinoma - Endotext - NCBI Bookshelf

↑ *Back to this question in Part A*

@Neet_pg_bot

Q3: Assertion : In diabetic ketoacidosis (DKA), potassium levels can appear normal or even elevated initially despite a total body potassium deficiency. Reason : Potassium shifts from the intracellular to the extracellular space due to insulin deficiency and acidosis, temporarily raising serum potassium levels. (Q850688)

A. Both assertion and reason are correct, and the reason correctly explains the assertion.

B. Both assertion and reason are correct, but the reason does not correctly explain the assertion.

C. The assertion is correct, but the reason is incorrect.

D. The assertion is incorrect, but the reason is correct.

Correct Answer: A. Both assertion and reason are correct, and the reason correctly explains the assertion.

Explanation: In DKA , total body potassium is depleted due to osmotic diuresis, vomiting, and urinary losses. However, serum potassium may appear normal or elevated because insulin deficiency and acidosis cause potassium to shift from cells into the extracellular space , temporarily raising serum levels.

References:

Harrison’s Principles of Internal Medicine, 21st Edition, Page 3114,3115

Davidson’s Principles and Practice of Medicine, 24th Edition, Page 736

https://pmc.ncbi.nlm.nih.gov/articles/PMC7292523/

Profound hypokalemia associated with severe diabetic ketoacidosis - PMC

Hypernatremia in Diabetic Ketoacidosis: Rare Presentation and a Cautionary Tale - PMC

Hyperglycemic Crises: Diabetic Ketoacidosis and Hyperglycemic Hyperosmolar State

Resuscitation of Adult Diabetic Ketoacidosis | RECAPEM

Hyperosmolar Hyperglycemic Syndrome - StatPearls - NCBI Bookshelf

↑ *Back to this question in Part A*

@Neet_pg_bot

Q4: A 45-year-old male with type 1 diabetes presents with increased thirst, frequent urination, nausea, vomiting, and abdominal pain. On examination, he has dry mucous membranes, tachypnea, and a fruity odour to his breath. His blood pressure is 90/60 mmHg. Labs show blood glucose of 450 mg/dL, bicarbonate of 18 mEq/L, and pH of 7.28. Which of the following statements is FALSE? (Q850686)

A. Kussmaul breathing is deep, laboured, and rapid.

B. Fruity odour on the breath is caused by acetone.

C. Dehydration in DKA is associated with dry mucous membranes and poor capillary refill.

D. Fever is always present in DKA and indicates infection.

Correct Answer: D. Fever is always present in DKA and indicates infection.

Explanation: Fever is not always present in DKA ; its presence may suggest an underlying infection but is not a defining feature of DKA. Kussmaul breathing (Option A): It is deep, laboured, and rapid to compensate for metabolic acidosis. Fruity odour (Option B): Caused by acetone from ketone metabolism. Dehydration (Option C): Presents with dry mucous membranes and poor capillary refill .

References:

Harrison’s Principles of Internal Medicine, 21st Edition, Page 3114,3115

Davidson’s Principles and Practice of Medicine, 24th Edition, Page 736

www.ncbi.nlm.nih.gov/books/NBK560723/

↑ *Back to this question in Part A*

@Neet_pg_bot

Q5: A 23-year-old male with Type 1 Diabetes Mellitus presents to the emergency department with nausea, vomiting, and abdominal pain. He reports that he has not taken his insulin for the past two days. On examination, he appears dehydrated, with deep and rapid breathing. Laboratory tests reveal high blood glucose, ketonemia, and metabolic acidosis. Which of the following statements about the pathophysiology of the patient’s condition is TRUE? (Q850684)

A. Insulin deficiency leads to increased glucose utilization by the cells.

B. Elevated counterregulatory hormones increase glycogen synthesis, reducing blood glucose levels.

C. Lipolysis increases free fatty acids (FFA) in the liver, leading to ketogenesis.

D. Increased glucose utilization prevents hyperglycemia and osmotic diuresis.

Correct Answer: C. Lipolysis increases free fatty acids (FFA) in the liver, leading to ketogenesis.

Explanation: In diabetic ketoacidosis (DKA) , insulin deficiency and elevated counterregulatory hormones promote lipolysis , increasing FFAs, which the liver converts to ketone bodies , causing metabolic acidosis. A) Increased glucose utilization (Option A): Insulin deficiency actually reduces glucose uptake , causing hyperglycemia. B) Glycogen synthesis reduces glucose (Option B): Counterregulatory hormones increase glycogenolysis and gluconeogenesis , raising glucose. D) Increased glucose utilization prevents hyperglycemia (Option D): Hyperglycemia occurs due to reduced utilization and increased production .

References:

Harrison’s Principles of Internal Medicine, 21st Edition, Page 3115

Davidson’s Principles and Practice of Medicine, 24th Edition, Page 736

Recurrent Concurrent Diabetic Ketoacidosis and Thyroid Storm - PMC

↑ *Back to this question in Part A*

@Neet_pg_bot

Q6: A 35-year-old patient presents to the clinic with persistent diarrhoea, which has led to significant dehydration. After evaluation, it is determined that the diarrhoea is secretory. The patient has a history of diabetes, which is uncontrolled. Which of the following statements best describes the management and mechanisms associated with secretory diarrhoea in this patient? (Q850683)

A. Secretory diarrhoea primarily results from the malabsorption of nutrients

B. The main goal of management is reducing intestinal secretion

C. Antisecretory agents like Racecadotril and Crofelemer may help reduce fluid loss

D. Secretory diarrhoea shows a high osmotic gap that is not related to food intake

Correct Answer: C. Antisecretory agents like Racecadotril and Crofelemer may help reduce fluid loss

Explanation: The clinical scenario is of secretory diarrhoea associated with uncontrolled diabetes mellitus, and antisecretory agents like Racecadotril and Crofelemer help reduce fluid loss. Malabsorption of nutrients (Option A): This causes osmotic diarrhea , not secretory diarrhea. Main goal is reducing intestinal secretion (Option B): Supportive care with fluid and electrolyte replacement is the priority; secretion control is adjunctive. High osmotic gap unrelated to food (Option D): Secretory diarrhea actually has a low osmotic gap and occurs even during fasting .

References:

Harrison’s Principles of Internal Medicine, 21st edition, Page: 302.

Secretory diarrhoea: mechanisms and emerging therapies - PMC

Consensus statement: octreotide dose titration in secretory diarrhoea - PubMed

Diabetic diarrhoea. Pathophysiology, diagnosis, and management - PubMed

↑ *Back to this question in Part A*

@Neet_pg_bot

Q7: Which of the following toxin-producing bacteria does a VIPoma mimic? (Q850679)

A. Shigella dysenteriae

B. Vibrio cholerae

C. Corynebacterium diphtheriae

D. Bordetella pertussis

Correct Answer: B. Vibrio cholerae

Explanation: VIPoma secretes vasoactive intestinal peptide (VIP) , causing profuse watery diarrhea, hypokalemia, and dehydration , similar to the cholera toxin effect . Shigella dysenteriae (Option A): Causes dysentery with bloody diarrhea, not watery diarrhea. Corynebacterium diphtheriae (Option C): Causes respiratory diphtheria , not secretory diarrhea. Bordetella pertussis (Option D): Causes whooping cough , unrelated to VIP effects.

References:

Harrison’s Principles of Internal Medicine, 21st edition, Page: 665.

Vasoactive Intestinal Peptide-Secreting Tumor (VIPoma) - Endotext - NCBI Bookshelf

Clinically Important Toxins in Bacterial Infection: Utility of Laboratory Detection - PMC

↑ *Back to this question in Part A*

@Neet_pg_bot

Q8: Identify the true statement about the condition where the patient presents with high plasma somatostatin levels, steatorrhea, hypochlorhydria, and diabetes mellitus due to a tumour. (Q850675)

A. The tumour primarily occurs in the stomach

B. This is usually a small tumour that often goes unnoticed

C. This is rarely associated with MEN 1 syndrome

D. Metastasis is rare and is treated using chemotherapy for localized disease

Correct Answer: C. This is rarely associated with MEN 1 syndrome

Explanation: Somatostatinomas are rare pancreatic or duodenal neuroendocrine tumors, and unlike other pancreatic NETs, they are infrequently associated with MEN 1 syndrome . Tumor primarily in the stomach (Option A): Usually occurs in the duodenum or pancreas , not stomach. Small tumor often goes unnoticed (Option B): They are often large at diagnosis due to nonspecific symptoms. Metastasis rare / treated with chemo (Option D): Many are malignant and may metastasize , requiring surgical management.

References:

Harrison's Principles of Internal Medicine, 21st edition, Page: 665, 2987.

www.ncbi.nlm.nih.gov/books/NBK279034/

↑ *Back to this question in Part A*

@Neet_pg_bot

Q9: A 54-year-old female presents with significant weight loss and a characteristic rash as in the image. Blood tests reveal elevated plasma glucagon levels exceeding 1000 pg/mL. A CT scan shows a large mass in the tail of the pancreas. Which of the following statements regarding her condition is correct? (Q850667)

A. The mass is commonly found in the head of the pancreas

B. The initial treatment includes antibiotics and steroids

C. The rash seen is necrolytic migratory erythema

D. Surgical resection is the treatment option for this condition

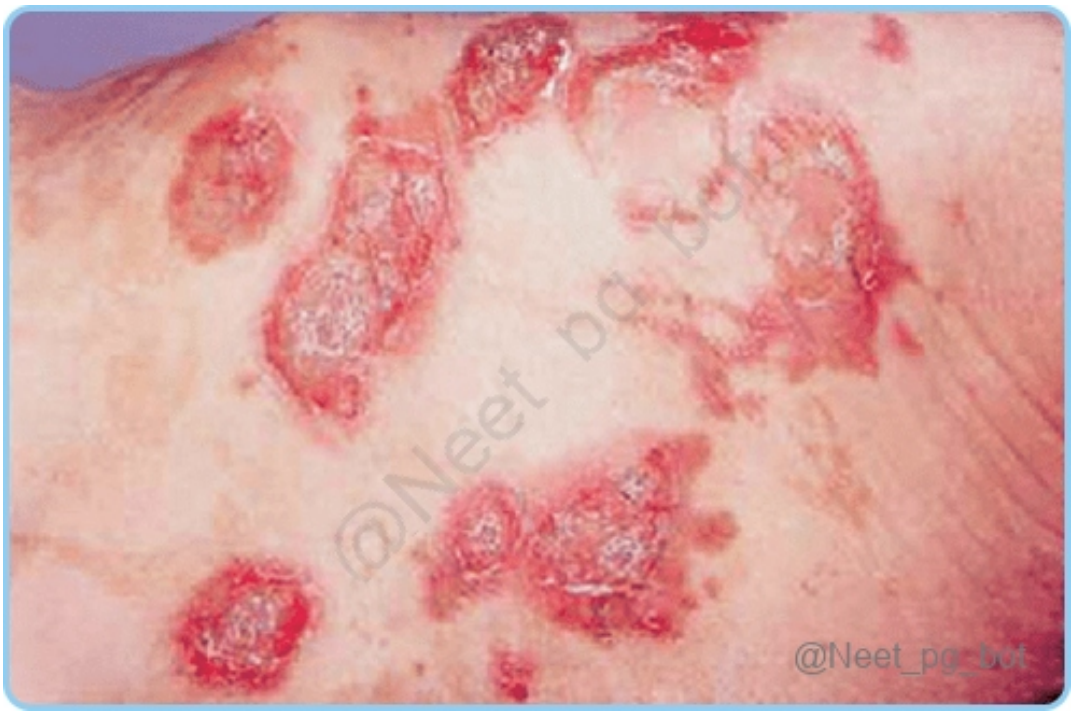

Correct Answer: C. The rash seen is necrolytic migratory erythema

Explanation: The scenario here is of the diagnosis of glucagonoma, which is characterized by elevated plasma glucagon levels exceeding 1000 pg/mL and the typical rash found in this condition called necrolytic migratory erythema. Mass in the head of the pancreas (Option A): Glucagonomas are most commonly found in the tail . Antibiotics and steroids (Option B): Do not treat the tumor or associated syndrome. Surgical resection (Option D): Curative option for a small percentage of patients with localized tumors.

References:

Harrison's Principles of Internal Medicine, 21st edition, Page: 3129, 3130.

www.ncbi.nlm.nih.gov/books/NBK519500/

www.ncbi.nlm.nih.gov/books/NBK481900/

↑ *Back to this question in Part A*

@Neet_pg_bot

Q10: A 65-year-old female with type 2 diabetes on SGLT2 inhibitors is brought to the emergency department unconscious. Lab results show pH 7.2, $HCO3^-$ 15 mEq/L, RBS 210 mg/dl, and plasma beta-hydroxybutyrate 2.8 mmol/L with normal lactate. Urine analysis reveals the presence of ketones. What condition is most consistent with these findings? (Q850639)

A. Lactic Acidosis

B. Diabetic Ketoacidosis

C. Euglycemic Diabetic Ketoacidosis

D. Hyperglycemic Hyperosmolar State

Correct Answer: C. Euglycemic Diabetic Ketoacidosis

Explanation: SGLT2 inhibitors can cause ketoacidosis with only mildly elevated or normal glucose levels; here, metabolic acidosis with ketones and glucose 210 mg/dl fits Euglycemic Diabetic Ketoacidosis (EDKA). Lactic Acidosis (Option A): Ruled out as lactate is normal. Diabetic Ketoacidosis (Option B): Typical DKA presents with marked hyperglycemia (>250–300 mg/dl). Hyperglycemic Hyperosmolar State (Option D): Characterized by severe hyperglycemia (>600 mg/dl), absent here.

References:

Harrison’s Principles of Internal Medicine, 21st Edition, Page 3114,3115

Lactic Acidosis - StatPearls - NCBI Bookshelf

empendium.com/mcmtextbook-sae/chapter/B78.II.13.3.3.?rfmcm

www.sciencedirect.com/topics/nursing-and-health-professions/acetoacetic-acid

pmc.ncbi.nlm.nih.gov/articles/PMC4497494/#sec3

pmc.ncbi.nlm.nih.gov/articles/PMC4497494/#sec3

glycemic Syndrome - StatPearls - NCBI Bookshelf

https://www.ncbi.nlm.nih.gov/books/NBK554570/#

pmc.ncbi.nlm.nih.gov/articles/PMC6553675/

↑ *Back to this question in Part A*

@Neet_pg_bot

Q11: A 40-year-old male comes to the clinic with recurrent episodes of hypoglycemia and loss of consciousness. On further evaluation, he is found to have a tumour on the pancreas. Which of the following is not a component of Whipple’s triad to suspect insulinoma? (Q850662)

A. Symptoms of hypoglycemia

B. Low plasma glucose concentration

C. Subsequent improvement of symptoms with the use of glucose treatment

D. Elevated fasting insulin levels

Correct Answer: D. Elevated fasting insulin levels

Explanation: Whipple's triad includes: Symptoms of hypoglycemia (Emotional outburst) Low plasma glucose measured during symptoms <45 mg/dl Relief of symptoms after glucose administration.

References:

Harrison's Principles of Internal Medicine, 21st edition, Page: 664, 665.

www.ncbi.nlm.nih.gov/books/NBK544299/

↑ *Back to this question in Part A*

@Neet_pg_bot

Q12: A 45-year-old woman with diabetes presents to the emergency department with confusion, fatigue, dizziness, palpitations, sweating, and tremors. Her blood glucose is 48 mg/dL. Which of the following is least likely to cause hypoglycemia in this patient? (Q850658)

A. Insulin

B. Sulfonylureas

C. Metformin

D. Meglitinides

Correct Answer: C. Metformin

Explanation: Metformin rarely causes hypoglycemia when used alone. Its primary action is to reduce hepatic glucose production and improve peripheral glucose uptake , without directly stimulating insulin secretion , which is why blood glucose rarely drops below normal . Insulin (Option A) directly lowers blood glucose and is a common cause of hypoglycemia. Sulfonylureas (Option B) stimulate insulin release , increasing the risk of hypoglycemia. Meglitinide s (Option D) also stimulate insulin secretion , so hypoglycemia is a potential complication.

References:

Harrison's Principles of Internal Medicine, 21st edition, Page: 3129, 3130.

www.ncbi.nlm.nih.gov/books/NBK534841/

www.endocrine.org/patient-engagement/endocrine-library/severe-hypoglycemia

↑ *Back to this question in Part A*

@Neet_pg_bot

Q13: A 55-year-old man presents with persistent abdominal pain and unintentional weight loss over the past 3 months. He reports no significant past medical history and denies any changes in bowel habits. A CT scan of the abdomen reveals a well-circumscribed mass in the pancreas. Laboratory tests show elevated serum glucose levels but normal levels of other pancreatic hormones. Which of the following is the most likely diagnosis for this patient? (Q850654)

A. Insulinoma

B. Gastrinoma

C. Non-functioning pancreatic NET

D. Glucagonoma

Correct Answer: C. Non-functioning pancreatic NET

Explanation: The patient has a pancreatic mass with hyperglycemia but no hormone-related symptoms , which is typical for non-functioning NETs that present due to mass effect or incidental findings. Insulinoma (Option A): Causes hypoglycemia , not high glucose. Symptoms: confusion, sweating, tremors, Whipple's triad. Not consistent. Gastrinoma (Option B): Causes refractory peptic ulcers, diarrhea , and high gastrin. CT may show tumors in the gastrinoma triangle. No ulcers, no gastrin elevation. Glucagonoma (Option D): Causes severe hyperglycemia + classic rash (necrolytic migratory erythema. Also, weight loss and anemia. Rash is absent; hormone levels are normal.

References:

Harrison's Principles of Internal Medicine 21st edition Page 664.

↑ *Back to this question in Part A*

@Neet_pg_bot

Q14: A 75-year-old man with poorly controlled type 2 diabetes presents to the emergency department with confusion and increased thirst over the past week. On examination, he has dry mucous membranes, a weak pulse, and a blood pressure of 85/50 mmHg. Laboratory tests show: (Plasma glucose: 1000 mg/dL, Serum osmolality: 360 mOsm/kg, Serum sodium: 130 mEq/L, Arterial blood gas: pH 7.38, bicarbonate

18 mEq/L). Which of the following is the most appropriate initial treatment for this patient? (Q850653)

A. Administer IV Ringer Lactate

B. Administer IV 0.9% normal saline

C. Start IV insulin bolus of 1 unit/kg with IV Potassium

D. Administer oral hypoglycemic agents

Correct Answer: B. Administer IV 0.9% normal saline

Explanation: This patient has Hyperglycemic Hyperosmolar State (HHS) : very high plasma glucose (>600 mg/dL), elevated osmolality, dehydration, and no significant acidosis (pH normal, HCO■■ >18). The initial and most critical step is aggressive fluid resuscitation with isotonic saline (0.9% NaCl) to restore intravascular volume and perfusion before starting insulin. Ringer Lactate (Option A) Contains lactate and is not the first-choice fluid for HHS; normal saline is preferred. IV insulin bolus with potassium (Option C) Insulin is started only after initial fluid resuscitation; otherwise, it can worsen shock and electrolyte shifts. Oral hypoglycemic agents (Option D) Ineffective and unsafe in this acute emergency.

References:

Harrison’s Principles of Internal Medicine 21st edition Page 3117

recapem.com/resuscitation-of-adult-diabetic-ketoacidosis/

↑ *Back to this question in Part A*

@Neet_pg_bot

Q15: A 70-year-old woman with type 2 diabetes is admitted for confusion and severe dehydration. Her blood glucose is 900 mg/dL, and serum osmolality is elevated. Arterial blood gas reveals a normal pH and bicarbonate. Which of the following clinical signs would NOT be expected in this patient? (Q850650)

A. Hypotension

B. Tachycardia

C. Kussmaul breathing

D. Fever

Correct Answer: C. Kussmaul breathing

Explanation: This patient has Hyperglycemic Hyperosmolar State (HHS) : severe hyperglycemia, high osmolality, dehydration, but no ketoacidosis (normal pH and bicarbonate). Kussmaul breathing is characteristic of DKA , not HHS. Hypotension (Option A): Expected due to severe dehydration. Tachycardia (Option B): Common compensatory response to volume loss. Fever (Option D): May occur if infection precipitated HHS.

References:

Harrison's Principles of Internal Medicine 21st edition Page 3117

↑ *Back to this question in Part A*

@Neet_pg_bot

Q16: A 28-year-old female with type 1 diabetes presents to the emergency department with increased thirst, frequent urination, nausea, abdominal pain, and signs of dehydration, including dry mucous membranes, tachycardia, and hypotension (BP: 98/60 mmHg). On examination, her vital signs include a heart rate of 110 bpm, respiratory rate of 22 breaths/min, and a blood pressure of 98/60 mmHg. Laboratory results show a blood glucose level of 350 mg/dL, serum bicarbonate of 18 mEq/L, and a pH of 7.30. What is the next step in management based on the ISPAD 2022 guidelines? (Q850647)

A. Start intravenous fluids and initiate insulin therapy

B. Administer subcutaneous insulin and monitor glucose

C. Provide oral hydration and adjust the diet accordingly

D. Ensure airway patency and consider nasogastric tube insertion

Correct Answer: A. Start intravenous fluids and initiate insulin therapy

Explanation: According to ISPAD 2022 guidelines , this patient has mild DKA (pH 7.25–7.30, HCO■■ 15–18, glucose >250 mg/dl, dehydration). The first step in management is IV fluid resuscitation to restore intravascular volume, followed by insulin infusion after initial fluid replacement. Subcutaneous insulin (Option B) Used only in selected mild/moderate DKA cases when IV insulin is not feasible. Oral hydration/diet (Option C) Inadequate for DKA, as patient has dehydration and acidosis. Airway patency/NG tube (Option D) Not indicated unless patient is comatose or vomiting with risk of aspiration.

References:

Harrison's Principles of Internal Medicine, 21st Edition, Page 3116,3117

pmc.ncbi.nlm.nih.gov/articles/PMC5871863/#

pubmed.ncbi.nlm.nih.gov/21871759/#

pmc.ncbi.nlm.nih.gov/articles/PMC4085289/

turkjemergmed.com/full-text/841

Adult Diabetic Ketoacidosis - StatPearls - NCBI Bookshelf

↑ *Back to this question in Part A*

@Neet_pg_bot

Q17: A 28-year-old male presents with tachycardia, hypotension, and drowsiness. He has a sweet smell of acetone on his breath. Laboratory results show a random blood sugar of 400 mg/dL, serum bicarbonate level of 12 mEq/L, arterial pH of 7.1, and serum β-hydroxybutyrate level of 6 mmol/L. What diagnosis is most consistent with this patient's condition? (Q850644)

A. Mild Diabetic Ketoacidosis

B. Moderate Diabetic Ketoacidosis

C. Severe Diabetic Ketoacidosis

D. Hyperglycemic Hyperosmolar State

Correct Answer: B. Moderate Diabetic Ketoacidosis

Explanation: The patient has pH 7.1 , serum bicarbonate 12 mEq/L , and is drowsy , which fall into the criteria for moderate DKA (pH 7.00–7.24, HCO■■ 10–15, altered sensorium) . Mild DKA (Option A): pH 7.25–7.30 and HCO■■ 15–18 with patient alert; not seen here. Severe DKA (Option C): pH <7.0 and HCO■■ <10 with stupor/coma; criteria not met. Hyperglycemic Hyperosmolar State (Option D): Glucose usually >600 mg/dL with little/no ketosis; does not match this case.

References:

Harrison’s Principles of Internal Medicine, 21st Edition, Page 3114,3115

Davidson’s Principles and Practice of Medicine, 24th Edition, Page 736

https://pmc.ncbi.nlm.nih.gov/articles/PMC7292523/

Profound hypokalemia associated with severe diabetic ketoacidosis - PMC

Hypernatremia in Diabetic Ketoacidosis: Rare Presentation and a Cautionary Tale - PMC

Hyperglycemic Crises: Diabetic Ketoacidosis and Hyperglycemic Hyperosmolar State

Resuscitation of Adult Diabetic Ketoacidosis | RECAPEM

Hyperosmolar Hyperglycemic Syndrome - StatPearls - NCBI Bookshelf

↑ *Back to this question in Part A*

@Neet_pg_bot

Q18: A 40-year-old male with poorly controlled type 1 diabetes presents with vomiting and shortness of breath. He appears dehydrated and tachycardic, with a fruity odour on his breath. His lab results show elevated blood glucose and ketones. Which of the following is not a risk factor for his condition? (Q850642)

A. Infection

B. Pancreatitis

C. Hypothyroidism

D. Inadequate insulin administration

Correct Answer: C. Hypothyroidism

Explanation: Diabetic ketoacidosis (DKA) is commonly precipitated by infection, pancreatitis, myocardial infarction, and inadequate insulin administration . Hypothyroidism is not a recognized risk factor. Precipitating Factors: Inadequate insulin administration (Option D) Infection (pneumonia/UTI/gastroenteritis/sepsis) (Option A) Infarction (cerebral, coronary, mesenteric, peripheral) Pancreatitis (Option B) Drugs (cocaine) Pregnancy

References:

Harrison’s Principles of Internal Medicine, 21st Edition, Page 3115

Davidson’s Principles and Practice of Medicine, 24th Edition, Page 736

Recurrent Concurrent Diabetic Ketoacidosis and Thyroid Storm - PMC

↑ *Back to this question in Part A*

@Neet_pg_bot

• [03_Endocrinology] 016 Disorders Of Adrenal Gland And Cushing Syndrome - I

« Back to Folder Directory

[03_Endocrinology] 016 Disorders Of Adrenal Gland And Cushing Syndrome - I — Quick Jump

Q1 (p. 1549)	*Q2 (p. 1550)*	*Q3 (p. 1551)*	*Q4 (p. 1552)*	*Q5 (p. 1553)*	*Q6 (p. 1554)*
Q7 (p. 1555)	*Q8 (p. 1556)*	*Q9 (p. 1557)*	*Q10 (p. 1557)*	*Q11 (p. 1558)*	*Q12 (p. 1559)*
Q13 (p. 1559)	*Q14 (p. 1560)*	*Q15 (p. 1561)*	*Q16 (p. 1561)*	*Q17 (p. 1562)*	*Q18 (p. 1563)*
Q19 (p. 1563)	*Q20 (p. 1564)*	*Q21 (p. 1565)*			

Q1: 16-year-old boy is brought to the ER due to fever, vomiting, and irritability for 2 days. Vitals are thready pulse 120/min, BP is 80/60 mm Hg with cold clammy extremities. General physical examination shows petechiae on extremities, CNS examination shows nuchal rigidity and kernig sign. CBC show TLC of 25000 cells/ cu.mm and platelet count of 15,000/cu.mm Gram stain of CSF is shown and rest of the lab report is awaited. Which of the following is not correct about managment of this patient? {{caption_text}} (Q850558)

A. Normal saline bolus

B. Hydrocortisone

C. Ceftriaxone and Vancomycin

D. Fludrocortisone

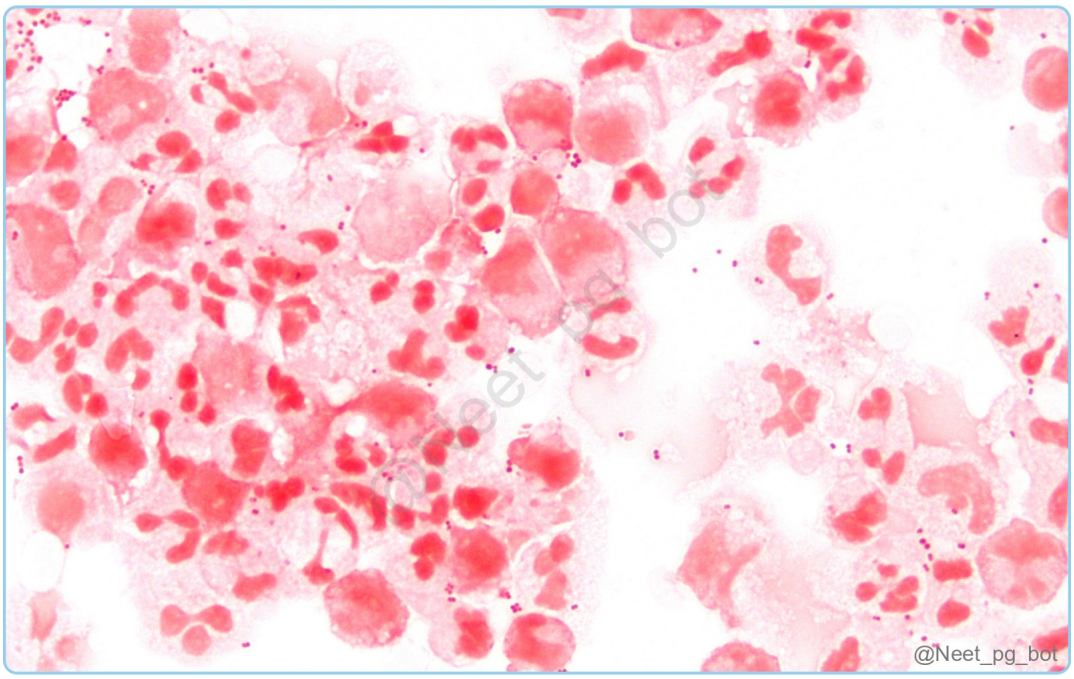

Correct Answer: D. Fludrocortisone

■ *Listen (English)*

■ *Listen (Hindi)*

Explanation: The patient is criticially sick and going into addisonian crisis due to Waterhouse-Friderichsen Syndrome Gram stain reveals gram negative diploccoci which is neisseria meningitidis. The ongoing sepsis has caused DIC as suggested by low platelet count Give Fluid boluses till pulse comes back to normal followed by 1L over next 1-2 hours which will restore the circulation of this patient. IV hydrocortisone is DOC for addisonian crisis. IV ceftriaxone and vancomycin will be given to treat the sepsis Fludrocortisone is an oral tablet used in primary chronic adrenal insufficiency . Management: Management Aspect Clinical Action & Details Duration Fluid Resuscitation Normal saline boluses (Aggressive resuscitation to maintain cardiac output). If shock persists after 40 mL/kg, elective intubation is recommended. Acute Phase (until hemodynamically stable). Empirical Antibiotics Ceftriaxone (75 - 100 mg/kg/d) + Vancomycin (40 - 60 mg/kg/d) to cover resistant bacteria. 7 days (Standard); 3–5 days may be effective. Adjunctive Steroids Hydrocortisone (Replacement doses for refractory shock with impaired adrenal responsiveness). During Refractory Shock period. Metabolic Support Correct hypoglycemia, acidosis, and electrolyte imbalances (K, Ca, Mg, PO 4). Continuous monitoring until resolved. Post-Inflammatory NSAIDs for immune-complex inflammatory syndrome. Until spontaneous resolution .

References:

https://www.ncbi.nlm.nih.gov/books/NBK551510/

Harrison’s Principle of Internal Medicine, 21st Edition, Page 1249-1250

↑ *Back to this question in Part A*

@Neet_pg_bot

Q2: A 30-year-old male presents to the clinic with complaints of hyperpigmented skin, lethargy, and abdominal pain occasionally. His vitals are blood pressure of 158/90mmHg, heart rate of 102/min, and a temperature of 98 ° F (37 ° C). Keeping in view the suspicion of primary hyperaldosteronism, which of the following set of metabolic findings correlates with this diagnosis? (Q876269)

A. Hyperkalaemia, hyponatremia, and normal renin

B. Hyponatremia only

C. Hypernatremia, hypokalaemia, and low renin

D. Hypercalcemia only

Correct Answer: C. Hypernatremia, hypokalaemia, and low renin

Explanation: Correct Option C - Hypernatremia, hypokalaemia, and low renin: Primary hyperaldosteronism (also known as Conn's syndrome) is caused by a benign tumour (adenoma) in one of the adrenal glands. Secondary hyperaldosteronism, on the other hand, is usually caused by an underlying condition that stimulates the adrenal glands to produce more aldosterone, such as renal artery stenosis, heart failure, or cirrhosis. Clinical findings of hyperaldosteronism may include: Hypertension (high blood pressure) Hypokalemia (low levels of potassium in the blood) Muscle weakness and fatigue Polyuria (increased urine production) Polydipsia (increased thirst) Headaches Visual disturbances Palpitations Numbness or tingling in the extremities Diagnosis Screening for mineralocorticoid excess is not currently recommended for all patients with hypertension, but drug-resistive hypertensive patients should be screened for mineralocorticoid excess. For this, different levels of hormones should be monitored. Detect Plasma renin level. Detect Plasma aldosterone Measure Aldosterone renin ratio Lab findings Hypernatremia Hypokalaemia Low renin Treatment The goal of treatment is to manage hypokalaemia and hypertension. Calcium channel blockers, particularly nifedipine, have been administered to treat hypertension. Spironolactone and other mineralocorticoid antagonists may also be used to treat this condition. A combination of diuretics, such as thiazide and spironolactone, may also alleviate the hypertensive crisis. Other therapeutic possibilities include ARBs and ACE inhibitors. Incorrect Options: Option A - Hyperkalaemia, hyponatremia, normal renin: These are the findings of adrenal insufficiency Low aldosterone levels are characterized by hyperkalemia and hyponatremia. Option B - Hyponatremia only: Hyponatremia does not occur in the primary aldosteronism Hyponatremia occurs in various medical disorders, such as Syndrome of inappropriate anti-diuretic hormone Chronic vomiting Heart failure Option D - Hypercalcemia only: In primary aldosteronism, hypercalcemia does not occur It is of the excess parathyroid hormone secretion

References:

Harrison's principle of internal medicine, 21st edition, Page no. 2731-2734

↑ *Back to this question in Part A*

@Neet_pg_bot

Q3: 40-year-old woman diagnosed with cushing syndrome presents with headaches and increased skin pigmentation over the past few months. She underwent a bilateral adrenalectomy six months ago. Which of the following is false about her condition? (Q850612)

A. Rapid expansion of pituitary tumor

B. Low ACTH level

C. Prevented by prophylactic radiation therapy before adrenalectomy

D. Occurs due to lack of negative feedback

Correct Answer: B. Low ACTH level

■ *Listen (English)*

■ *Listen (Hindi)*

Explanation: ACTH levels are very high in Nelson syndrome since both adrenal glands have been resected leading to loss of negative feedback control. It can occur in patient with cushing disease refractory to surgery. The pre-existing corticotrope adenoma will expand in size to loss of check mechanism and will produce mass effects explaining the presenting complaints of this patient.

References:

Harrison's Principles of Internal Medicine, 21st edition, Page 2916

https://www.ncbi.nlm.nih.gov/books/NBK560755/

↑ *Back to this question in Part A*

@Neet_pg_bot

Q4: Which of the following is first investigation to be performed in patient with ACTH dependant cushing syndrome? (Q850606)

A. MRI Pituitary

B. High dose dexamethasone suppression test

C. Low dose dexamethasone suppression test

D. Inferior petrosal sinus sampling

Correct Answer: A. MRI Pituitary

■ *Listen (English)*

■ *Listen (Hindi)*

Explanation: First investigation to be done in ACTH dependant cushing syndrome is MRI pituitary Elevated ACTH and elevated cortisol implies either endogenous cause or ectopic cause. MRI pituitary along with CRH test will help in identifying a pituitary adenoma High dose dexamethasone suppression test helps to differentiate endogenous or ectopic cause. Failure to suppress cortisol production will imply ectopic source (Option B) Low dose dexamethasone is a screening test for cushing syndrome (Option C) Inferior petrosal sinus sampling petrosal/ peripheral ratio > 2 indicates endogenous cause (Option D) First investigation to be done in ACTH independant cushing syndrome is CT abdomen

References:

Harrison's Principles of Internal Medicine, 21st Edition, Page 2962

↑ *Back to this question in Part A*

@Neet_pg_bot

Q5: Which of the following is not a clinical feature of Cushing syndrome? (Q850600)

A. Hypokalemia

B. Increased susceptibility to infections

C. Menorrhagia

D. Wasting of gluteal musculature

Correct Answer: C. Menorrhagia

■ *Listen (English)*

■ *Listen (Hindi)*

Explanation: ushing syndrome results from chronic excess glucocorticoids and is characterized by catabolic effects, immunosuppression, and mineralocorticoid activity. Typical features include hypokalemia (due to mineralocorticoid action), increased susceptibility to infections, and proximal muscle wasting, including gluteal muscle wasting. Menstrual irregularities are common, but they usually present as amenorrhea or oligomenorrhea, not menorrhagia. Incorrect Options: Option A – Hypokalemia: Excess cortisol can activate mineralocorticoid receptors, leading to renal potassium loss and hypokalemia, especially in ectopic ACTH syndrome. Option B - Increased susceptibility to infections: Glucocorticoids cause immunosuppression, predisposing patients to bacterial, fungal, and opportunistic infections. Option D - Wasting of gluteal musculature: Cortisol causes protein catabolism, leading to proximal muscle weakness and wasting, particularly involving the pelvic girdle and gluteal muscles.

References:

Harrison's principles of internal medicine, 21st Edition, Page 2961

↑ *Back to this question in Part A*

@Neet_pg_bot

Q6: 50-year-old man presents with severe cough for 3 months and hemoptysis episodes for past 3 days. Physical examination shows hypertension, purple abdominal wall striae, changes in hands as shown. Endobronchial lung biopsy is shown below. Which of the following is the most likely cause in this patient? (Q850594)

A. Carcinoid tumor

B. Oat cell cancer of lung

C. Squamous cell cancer of lung

D. Large cell cancer of lung

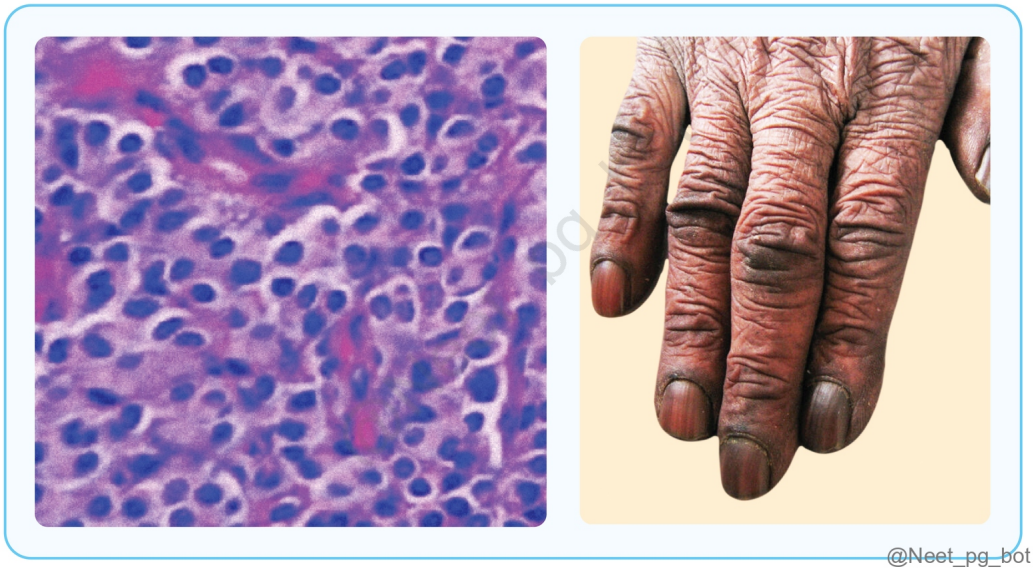

Correct Answer: A. Carcinoid tumor

■ *Listen (English)*

■ *Listen (Hindi)*

Explanation: Carcinoid tumor Clinical history points to diagnosis of cushing syndrome due to ectopic source. Cushing features are hyperpigmentation of knuckes and IP joints with purpule striae on anterior abdominal wall, hypertension and centripetal obesity. Endobronchial biopsy report shows organoid nests of uniform cells and the nuclei with “salt and pepper” chromatin. Oat cell cancer cells will be disorganised mass of cells with nuclei that will always looked crushed and squeezed. Carcinoid Tumor (Left Slide) Uniform cells with abundant cytoplasm , round nuclei , and “salt and pepper” chromatin pattern. Cells arranged in nesting or trabecular pattern with minimal mitosis and necrosis. Oat Cell Cancer / Small Cell Lung Carcinoma (Right Slide) Small round cells with

scant cytoplasm , hyperchromatic nuclei , and nuclear molding . Shows high mitotic activity , frequent necrosis , and crush artifacts due to fragile cells.

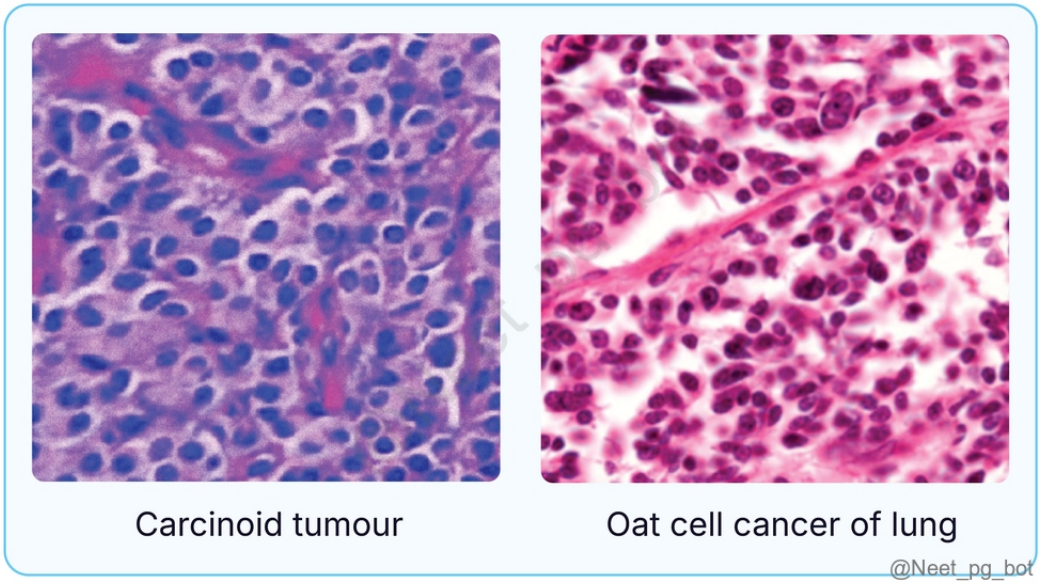

References:

Harrison's Principles of Internal Medicine, 21st Edition, Page 3000- 3008

↑ *Back to this question in Part A*

@Neet_pg_bot

Q7: 35 year old bollywood actor develops flushing episodes, asthma like symptoms and frequent episodes of watery diarrhea . 24 hour urinary 5 HIAA levels are elevated. Which of the following drugs will be suitable for managment of GI complaints of this patient? (Q850588)

A. Loperamide

B. Telotristat ethyl

C. Somatostatin analogues

D. Racecadotril

Correct Answer: C. Somatostatin analogues

■ *Listen (English)*

■ *Listen (Hindi)*

Explanation: Somatostatin analogues are the first-line treatment for carcinoid syndrome. They inhibit secretion of serotonin and other vasoactive peptides , thereby controlling flushing, diarrhea, and wheezing Telotristat ethyl (Option A) blocks serotonin production by inhibiting tryptophan hydroxylase ; used as adjunctive therapy for patients who don't fully respond to somatostatin analogues Loperamide (Option B) acts on μ-opioid receptors in gut → ↓ motility, ↑ transit time. It works well in motility-driven diarrhea like IBS-D and travelers' diarrhea. Racecadotril (Option D) is an enkephalinase inhibitor → ↑ endogenous enkephalins → ↓ cAMP-mediated secretion. It is useful in acute infectious diarrhea , but serotonin-mediated secretion in carcinoid is too strong , so inhibition is inadequate.

References:

Harrison's principles of internal medicine 21st Edition, Page 663- 668, 2987.

↑ *Back to this question in Part A*

@Neet_pg_bot

Q8: 30 year old patient with pheochromocytoma is undergoing surgery for tumor resection. Which drug should be prepared by anaesthesiologist as a standy infusion and will not cause post operative hypotension? (Q850585)

A. Labetalol

B. Phenoxybenzamine

C. Nitroprusside

D. Phentolamine

Correct Answer: C. Nitroprusside

■ *Listen (English)*

■ *Listen (Hindi)*

Explanation: During pheochromocytoma surgery, a short-acting, easily titratable IV agent is needed to manage sudden hypertensive surges. Nitroprusside acts within seconds and stops acting within minutes, so it provides excellent intraoperative control without causing postoperative hypotension . Phenoxybenzamine (Option A): long-acting; causes prolonged postoperative hypotension. Phentolamine (Option B): alpha-blocker; may cause postoperative hypotension. Labetalol (Option D): not ideal for acute hypertensive crises; beta-blockade can worsen BP if unopposed.

References:

Harrison's principles of internal medicine, 21st Edition, Page 2979

↑ *Back to this question in Part A*

@Neet_pg_bot

Q9: Which of the following is the most sensitive and specific diagnostic test for detecting pheochromocytoma? (Q850581)

A. Plasma free metanephrine

B. Plasma-fractionated metanephrine

C. 24 hr urinary total metanephrine

D. 24 hr urinary catecholamines

Correct Answer: A. Plasma free metanephrine

■ *Listen (English)*

■ *Listen (Hindi)*

Explanation: Plasma free metanephrine has been described a sensitivty of 4+ and specificity of 3+ 24 hour urinary fractionated metanephrine has sensitivity of 4+ and specificty of 2+ 4+ means > 95% and 3+ means 85-95% and 2+ is < 85% Hack to remember when use word Free vs fractionated in work up of pheochromocytoma: Plasma is "free flowing" so we use free metanephrine values In contrast urine is filtered and has metabolically "fragmented or broken down products", so Fractionated metanephrine values Diagnostic Method Sensitivity Specificity 24-h urinary tests Catecholamines Fractioned metanephrines Total metanephrines +++ ++++ +++ +++ ++ ++++ Plasma Tests Catecholamines Free metanephrines +++ ++++ ++ +++

References:

Harrison’s Principles of Internal Medicine, 21st edition, Pages 2977

↑ *Back to this question in Part A*

@Neet_pg_bot

Q10: Which of the following drugs is used for managment of pre-operative hypertension in pheochromocytoma (Q850575)

A. Selective beta-blocker alone before surgery

B. Phenoxybenzamine + Phentolamine

C. Phenoxybenzamine + Propranolol

D. Propranolol and Phentolamine

Correct Answer: C. Phenoxybenzamine + Propranolol

■ *Listen (English)*

■ *Listen (Hindi)*

Explanation: Managing pheochromocytoma before surgery is critical to prevent life-threatening hypertensive crises during tumor manipulation. The standard approach includes: 1. Alpha-Blockade (FIRST and MANDATORY) Drug: Phenoxybenzamine (non-selective, irreversible α-blocker) Start: 10–14 days before surgery 2. Volume Expansion Liberal salt and fluid intake (especially after adequate α-blockade) Prevents postoperative hypotension 3. Beta-Blockade (Never give before α-blockade – may precipitate hypertensive crisis by unopposed α-adrenergic action) Indication: If patient has persistent tachycardia or arrhythmias Drug: Propranolol or atenolol

References:

Harrison's Principles of Internal Medicine, 21st edition, Pages 2976-2979.

↑ *Back to this question in Part A*

@Neet_pg_bot

Q11: Which of the following is imaging modality of choice for pheochromocytoma? (Q850567)

A. MRI abdomen

B. Gallium 68 dotatate PET/CT

C. MIBG scan

D. Somatostatin receptor Scinitgraphy

Correct Answer: B. Gallium 68 dotatate PET/CT

■ *Listen (English)*

■ *Listen (Hindi)*

Explanation: Imaging modality with > 95% diagnostic sensitivity and specificity for pheochromocytoma is Gallium 68 dotatate PET/CT. Another test with similar diagnostic accuracy is 18Fluoro-DOPA PET/CT. The remaining options are stars of older years.

References:

Harrison's Principles of Internal Medicine, 21st edition, Pages 2977

↑ *Back to this question in Part A*

@Neet_pg_bot

Q12: A 45-year-old woman presents with persistent hypertension, weight gain, and muscle weakness. Lab results reveal elevated cortisol levels and suppressed ACTH. Which of the following is the next best investigation for work up of this patient? (Q850525)

A. High dose dexamethasone suppresion test

B. Low dose dexamethasone suppression test

C. CT abdomen

D. MRI pituitary

Correct Answer: C. CT abdomen

■ *Listen (English)*

■ *Listen (Hindi)*

Explanation: The patient's clinical presentation, including elevated cortisol, suppressed ACTH, indicates an autonomous source of cortisol. Since we are suspecting adrenal adenoma / ACTH independant cushing syndrome , CT abdomen will be done. MRI pituitary and High dose dexamethasone suppression test is done in ACTH dependant cushing syndome. Low dose dexamethasone is done for confirmation of diagnosis but in this case the diagnosis is already made.

References:

Davidson's Principles and Practice of Medicine, 24th edition, Page 665, 666, 675.

Physiology, Adrenal Gland - StatPearls - NCBI Bookshelf.

↑ *Back to this question in Part A*

@Neet_pg_bot

Q13: Which of the following statements is incorrect regarding a patient with mineralocorticoid excess? (Q850552)

A. Excess aldosterone causes hypokalemic metabolic alkalosis

B. Serum sodium may remain normal despite total body sodium overload

C. Long-standing hypokalemia can lead to proximal muscle weakness

D. ACE inhibitors can falsely elevate aldosterone levels

Correct Answer: D. ACE inhibitors can falsely elevate aldosterone levels

■ *Listen (English)*

■ *Listen (Hindi)*

Explanation: ACE inhibitors actually suppress aldosterone , leading to falsely low aldosterone levels and low aldosterone-to-renin ratio (ARR) . They do not elevate aldosterone , so they must be stopped before testing. Excess aldosterone causes hypokalemic metabolic alkalosis (Option A) : Excess aldosterone increases renal excretion of potassium and hydrogen ions , causing hypokalemic metabolic alkalosis Serum sodium may remain normal despite total body sodium overload■■■■■■■ (Option B) : Although total body sodium is high, serum sodium may appear normal due to dilution from fluid retention ■■■■■■■Long-standing hypokalemia can lead to proximal muscle weakness (Option C) : Chronic hypokalemia can impair muscle function, leading to proximal myopathy

References:

Harrison’s Principles of Internal Medicine, 21st edition, Page 2966-65

↑ *Back to this question in Part A*

@Neet_pg_bot

Q14: Which of the following is not correct about primary addison disease? (Q850546)

A. Increased Serum creatinine

B. Orthostatic hypotension

C. Skin color changes to pale alabaster

D. Hyperkalemia

Correct Answer: C. Skin color changes to pale alabaster

■ *Listen (English)*

■ *Listen (Hindi)*

Explanation: Addison disease has salt wasting and volume depletion. This can lead to incresed serum creatinine (Option A) Salt wasting explains orthostatic hypotension (Option B) Low aldosterone explains hyponatermia with hyperkalemia. Remember aldosterone and potassium have inverse relation (Option D) In primary addison disease, ACTH will rise due to feedback mechanism and will cause hyperpigmentation of skin. In contrast pale alabaster skin is seen in secondary addison disease.

References:

Davidson's Principles and Practice of Medicine 24th edition, pages 672-673

↑ *Back to this question in Part A*

@Neet_pg_bot

Q15: Which of the following is not a clinical feature of glucocorticoid deficiency (Q850543)

A. Hypoglycemia

B. Eosinopenia

C. Orthostatic hypotension

D. Hyponatremia

Correct Answer: B. Eosinopenia

■ *Listen (English)*

■ *Listen (Hindi)*

Explanation: Low glucocorticoids will cause hypoglycemia attacks. Cortisol values and eosinophil count has inverse relation. Low cortisol is associated with high eosinophil count and vice versa. Lack of cortisol causes loss of feedback inhibition of ADH release . This causes more ADH and resultant dilutional hyponatermia. Cortisol has partial aldosterone like activity. Less cortisol will cause low BP

References:

Davidson's Principles and Practice of Medicine, 24th edition, pages 671-672

↑ *Back to this question in Part A*

@Neet_pg_bot

Q16: Which part of the nephron is affected in Gordon syndrome? (Q850541)

A. Distal convoluted tubule

B. Proximal nephron

C. Ascending limb of the loop of Henle

D. Descending limb of the loop of Henle

Correct Answer: A. Distal convoluted tubule

■ *Listen (English)*

■ *Listen (Hindi)*

Explanation: Gordon syndrome affects DCT. It is caused by mutations that increase sodium-chloride reabsorption via the NCC (Na■/Cl■ cotransporter) in the DCT. this leads to low alosterone levels and hence it is also called Pseudohypoaldosteronism type IIA. It leads to: 1. Hypertension (due to volume expansion) 2. Hyperkalemia (due to reduced potassium excretion) 3. Metabolic acidosis 4. Low renin and aldosterone levels It is the opposite phenotype of Gitelman syndrome , which also involves the DCT but causes hypokalemia and metabolic alkalosis. Inheritance Autosomal dominant (mostly) Pathogenesis Mutations in the WNK1, WNK4, CUL3, or KLHL3 genes result in abnormalities in serine/threonine kinases that dysregulate the thiazide-sensitive sodium-chloride cotransporter (NCC) in the distal nephron (Option A). This leads to increased sodium and chloride reabsorption, causing extracellular volume expansion and subsequent hypertension. Clinical Presentation Non-specific symptoms like muscle weakness, fatigue, hypertension (not always) Laboratory Findings Hyperkalemia Hyperchloremic metabolic acidosis Hypercalciuria Low or low-normal plasma renin activity Low serum aldosterone levels (relative to hyperkalemia) Normal kidney function/normal glomerular filtration Management Correction of electrolyte abnormalities Salt restriction Thiazide diuretics

References:

https://www.ncbi.nlm.nih.gov/pmc/articles/PMC10874887/

↑ *Back to this question in Part A*

@Neet_pg_bot

Q17: All of the following are clinical manifestations of Liddle’s syndrome except? (Q850537)

A. Hypokalemia

B. Hyporeninemia

C. Hypertension

D. Hyperaldosteronism

Correct Answer: D. Hyperaldosteronism

■ *Listen (English)*

■ *Listen (Hindi)*

Explanation: Aldosterone levels are suppressed in Liddle’s syndrome. Liddle’s syndrome (pseudohyperaldosteronism): Definition An autosomal dominant genetic disorder characterized by hypertension with hypokalemic metabolic alkalosis, hyporeninemia, and suppressed aldosterone secretion Pathophysiology Mutations in SCNN1A, SCNN1B, and SCNN1G genes → α, β, and γ subunits of ENaC (Epithelial Sodium Channel) altered → Increased Epithelial Sodium Channel activity→Elevated sodium reabsorption in the distal nephron → Sodium retention Clinical features Early-onset hypertension (as early as 2 years of age) (Option C ruled out) Hypokalemia (Option A ruled out) and metabolic alkalosis Suppressed plasma renin (Option B ruled

out) and aldosterone levels (Option D) Fatigue, muscle weakness, dizziness, and vision changes Management Potassium-sparing diuretics: Amiloride or Triamterene Salt restriction

References:

https://www.ncbi.nlm.nih.gov/pmc/articles/PMC6731958/

↑ *Back to this question in Part A*

@Neet_pg_bot

Q18: 45-year-old woman presents to the clinic with complaints of persistent high blood pressure despite medication and muscle weakness. On examination BP is 170/100 mmHg. Work up shows results pH= 7.46, serum potassium: 3.2 mEq/L, serum sodium: 142 mEq/L and increased aldosterone levels. CT abdomen shows adrenal mass size of 2cm. Which of the following test is used to confirm the diagnosis? (Q850535)

A. Plasma renin activity

B. Saline infusion test

C. ACTH stimulation test

D. Petrosal sinus sampling

Correct Answer: B. Saline infusion test

■ *Listen (English)*

■ *Listen (Hindi)*

Explanation: Diagnosis based on hypertension with hypokalemic alkalosis is primary hyperaldosteronism. Since CT shows an adrenal mass, it would be conn syndrome. ARR is the correct initial test to screen for hyperaldosteronism and saline infusion test is a confirmatory test for diagnosis of Primary Hyperaldosteronism. ACTH stimulation test (Option C) is used for adrenal insufficiency/ Addison disease. Dexamethasone suppression test evaluates cortisol excess (Cushing’s syndrome).

References:

Davidson's Principles and Practice of Medicine, 24th edition, pages 673-674

↑ *Back to this question in Part A*

@Neet_pg_bot

Q19: 50-year-old hypertensive male presents with muscle weakness and frequent headaches. Work up shows hypokalemic metabolic alkalosis with low plasma aldosterone and low renin. Which of the following is the most likely diagnosis? (Q850531)

A. Liddle syndrome

B. Conn syndrome

C. Addison disease

D. Bilateral adrenal hyperplasia

Correct Answer: A. Liddle syndrome

■ *Listen (English)*

■ *Listen (Hindi)*

Explanation: Liddle syndrome This patient has hypertension, hypokalemia, and metabolic alkalosis — a triad suggesting mineralocorticoid excess. However, both plasma aldosterone and renin are low, ruling out primary (Conn syndrome) and secondary hyperaldosteronism . (Option B and D ruled out) . This points toward a condition that mimics aldosterone's action despite its suppression. Liddle syndrome fits this profile: it is a genetic disorder where mutated ENaC channels in the distal nephron stay overactive, causing sodium retention and potassium loss, independent of aldosterone. Addison disease has hypotension and salt wasting and hence is ruled out. (Option C)

References:

Harrison's Principles of Internal Medicine, 21st Edition, Page 2078-79

↑ *Back to this question in Part A*

@Neet_pg_bot

Q20: 30 year old patient presents with hypertension and hypokalemic metabolic alkalosis. CT scan shows mass over the kidney of size 1.5 cm with elevated ARR. What is the next best step for management of this patient? (Q850528)

A. Spironolactone on life-long basis

B. Adrenalectomy

C. Adrenal venous sampling

D. Dexamethasone suppression test

Correct Answer: C. Adrenal venous sampling

■ *Listen (English)*

■ *Listen (Hindi)*

Explanation: Adrenal venous sampling Diagnosis is Conn syndrome as elevated aldosterone renin ratio is given in patient with adrenal mass with Hypertension Even if a CT scan shows an adrenal mass, AVS (adrenal venous sampling) is needed to confirm lateralization of aldosterone production before surgery because: Coexistent non-functioning adrenal adenomas (incidentalomas) are common, especially in older adults. The CT might show a mass, but it may not be the one producing aldosterone — and sometimes both glands are involved (bilateral hyperplasia). AVS helps to differentiate between Unilateral disease → candidate for adrenalectomy Bilateral disease → treated medically (e.g. with mineralocorticoid receptor antagonists like spironolactone or eplerenone)

References:

Harrison's Principles of Internal Medicine, 21st Edition, Page 349, 350, 365, 2078, 2079, 2965, 2987, 3162, 3165.

↑ *Back to this question in Part A*

@Neet_pg_bot

Q21: A 35-year-old man presents with episodic headaches, palpitations, and excessive sweating. He is found to have labile hypertension and an adrenal mass on testing. Genetic testing confirms a ret proto-oncogene mutation, and ultrasound shows bilateral thyroid nodules. Which of the following is the major catecholamine produced by this tumor? (Q850527)

A. Epinephrine

B. Nor epinephrine

C. Dopamine

D. Metanephrine

Correct Answer: A. Epinephrine

■ *Listen (English)*

■ *Listen (Hindi)*

Explanation: Majority of pheochromocytoma are NE producing (80%) but in this question due to association with MEN 2/ Sipple syndrome the answer is epinephrine producing . The presence of ret gene and thyoid masses indictate a medullary carcinoma of thyroid that could be present. Pheochromocytomas arise from chromaffin cells of the adrenal medulla (or extra-adrenal paraganglia). These tumors lack cortisol exposure needed to activate the enzyme phenylethanolamine N-methyltransferase (PNMT) , which converts norepinephrine to epinephrine. Hence, overall norepinephrine is the predominant secretion in ~80% of pheochromocytomas. Norepinephrine (Option B):

Predominant in noradrenergic pheochromocytomas (e.g., VHL syndrome or sporadic extra-adrenal paragangliomas), where PNMT is absent. In MEN2, norepinephrine is mostly converted to epinephrine, so it's not the major product. Dopamine (Option C): This is rarely the major product and is more commonly seen in rare, malignant paragangliomas. Metanephrine (Option D): This is the O-methylated metabolite of epinephrine (via COMT), not a catecholamine itself. Plasma free metanephrines are key for diagnosis, but the tumor primarily produces epinephrine.

References:

Davidson's Principles and Practice of Medicine, 24th edition, Page 665, 666, 675.

Physiology, Adrenal Gland - StatPearls - NCBI Bookshelf.

↑ *Back to this question in Part A*

@Neet_pg_bot

• [03_Endocrinology] 017 Diseases Of Thyroid

« Back to Folder Directory

[03_Endocrinology] 017 Diseases Of Thyroid — Quick Jump

Q1 (p. 1567)	*Q2 (p. 1568)*	*Q3 (p. 1568)*	*Q4 (p. 1570)*	*Q5 (p. 1571)*	*Q6 (p. 1572)*
Q7 (p. 1573)	*Q8 (p. 1573)*	*Q9 (p. 1574)*	*Q10 (p. 1575)*	*Q11 (p. 1575)*	*Q12 (p. 1576)*
Q13 (p. 1577)	*Q14 (p. 1578)*	*Q15 (p. 1579)*	*Q16 (p. 1580)*	*Q17 (p. 1581)*	*Q18 (p. 1582)*
Q19 (p. 1582)	*Q20 (p. 1583)*	*Q21 (p. 1584)*	*Q22 (p. 1585)*	*Q23 (p. 1586)*	*Q24 (p. 1587)*
Q25 (p. 1588)	*Q26 (p. 1588)*	*Q27 (p. 1590)*	*Q28 (p. 1591)*	*Q29 (p. 1592)*	*Q30 (p. 1592)*
Q31 (p. 1593)	*Q32 (p. 1594)*	*Q33 (p. 1594)*	*Q34 (p. 1595)*	*Q35 (p. 1596)*	*Q36 (p. 1597)*

Q1: An elderly woman is brought to the emergency department with altered behavior after a week of poor oral intake. She has a known history of hypothyroidism and has been irregular with her medications. On examination, she is bradycardic and hypotensive. Arterial blood gas analysis reveals respiratory acidosis, and serum sodium levels are low. Which of the following findings is least likely to be present in this patient? (Q884031)

A. Hypoglycemia

B. Hyperthermia

C. Rhabdomyolysis

D. Hypercapnia

Correct Answer: B. Hyperthermia

Explanation: Myxedema coma is the life-threatening extreme of hypothyroidism and carries a 20-40% mortality rate , even with intensive treatment. Importantly, clinical outcomes are independent of serum T4 and TSH levels. Clinical manifestations include: Reduced level of consciousness ranging from confusion → somnolence → coma Seizures and other abnormal CNS signs Profound hypothermia (may reach 23°C) Hypoventilation leading to hypercapnia (Option D) and hypoxemia Hyponatremia Hypoglycemia (Option A) due to impaired gluconeogenesis and cortisol deficiency Bradycardia and hypotension Rhabdomyolysis (Option C) and acute kidney injury

References:

Harrison’s Principles of Internal Medicine, 22nd Edition, Page 3032

↑ *Back to this question in Part A*

@Neet_pg_bot

Q2: A 64-year-old woman from an iodine-deficient region has had a slowly progressive multinodular thyroid enlargement for 18 years. She was asymptomatic and euthyroid until recently. She now presents with palpitations, weight loss, and tremors. Investigations show: TSH - Suppressed Free T4 - Normal T3 - Disproportionately elevated Thyroid scintigraphy - Heterogeneous uptake with multiple hot and cold areas FNAC from different nodules shows mixed polyclonal and monoclonal populations Which of the following represents the most important pathophysiological change responsible for her current disease state? (Q884023)

A. Development of autoimmune TSH-receptor antibodies

B. Emergence of nodules with functional autonomy

C. Progressive iodine deficiency causing diffuse hyperplasia

D. Malignant transformation of polyclonal nodules

Correct Answer: B. Emergence of nodules with functional autonomy

Explanation: Initially, she had Nontoxic Multinodular Goitre (NT-MNG) presenting as euthyroid, predominantly polyclonal hyperplastic nodules with normal TSH, which represents a hyperplastic response to growth factors & cytokines. But over time, some nodules acquire functional autonomy, and they begin secreting thyroid hormone independent of TSH. This converts NT-MNG to Toxic MNG, whose defining pathophysiologic feature is functional autonomy. This explains the low TSH, T3-predominant thyrotoxicosis, heterogeneous uptake and clinical symptoms of AF, palpitations, and weight loss; precipitated by iodine exposure (Jod-Basedow phenomenon). Autoimmune TSH-receptor antibodies (Option A): This is the mechanism of Graves' disease, causing diffuse toxic goitre, not toxic multinodular goitre. Progressive iodine deficiency (Option C): Iodine deficiency causes diffuse or multinodular goitre formation, but does not explain the development of thyrotoxicosis in multinodular goitre. Malignant transformation of polyclonal nodules (Option D): Malignancy may cause rapid enlargement, hoarseness or lymphadenopathy, but it does not produce thyroid hormone excess and therefore does not cause thyrotoxicosis.

References:

Harrison's Principles of Internal Medicine, 22nd Edition, Page 3041, 3042.

↑ *Back to this question in Part A*

@Neet_pg_bot

Q3: A 32-year-old woman presents with a painless thyroid nodule. Ultrasound shows a hypoechoic solid lesion with microcalcifications and irregular margins. FNAC reveals nuclear grooves and intranuclear cytoplasmic inclusions. Which thyroid malignancy is most likely to account for the majority of thyroid cancers worldwide? (Q884024)

A. Follicular carcinoma

B. Papillary carcinoma

C. Medullary thyroid carcinoma

D. Anaplastic carcinoma

Correct Answer: B. Papillary carcinoma

Explanation: Papillary thyroid carcinoma (PTC) is the most common thyroid malignancy, accounting for ~80-90% of all thyroid cancers and 80-85% of well-differentiated thyroid malignancies. Microscopic PTC is found in up to 25% of thyroid glands at autopsy, but most are clinically insignificant microcarcinomas. Characteristic cytology: Orphan Annie eye nuclei Nuclear grooves Intranuclear cytoplasmic inclusions Spread: Predominantly lymphatic, but can metastasise hematogenously (lung, bone) Treatment: Total thyroidectomy (lobectomy only for low-risk microcarcinoma) with radioiodine ablation when indicated, followed by TSH-suppressive levothyroxine therapy. Follicular carcinoma (Option A): Accounts for only 5-10% of thyroid cancers and spreads mainly hematogenously. Medullary carcinoma (Option C): Comprises <10% of cases, arises from parafollicular C-cells, and is associated with MEN syndromes. Anaplastic carcinoma (Option D): Extremely aggressive but very rare (1-2%) and not the predominant thyroid malignancy.

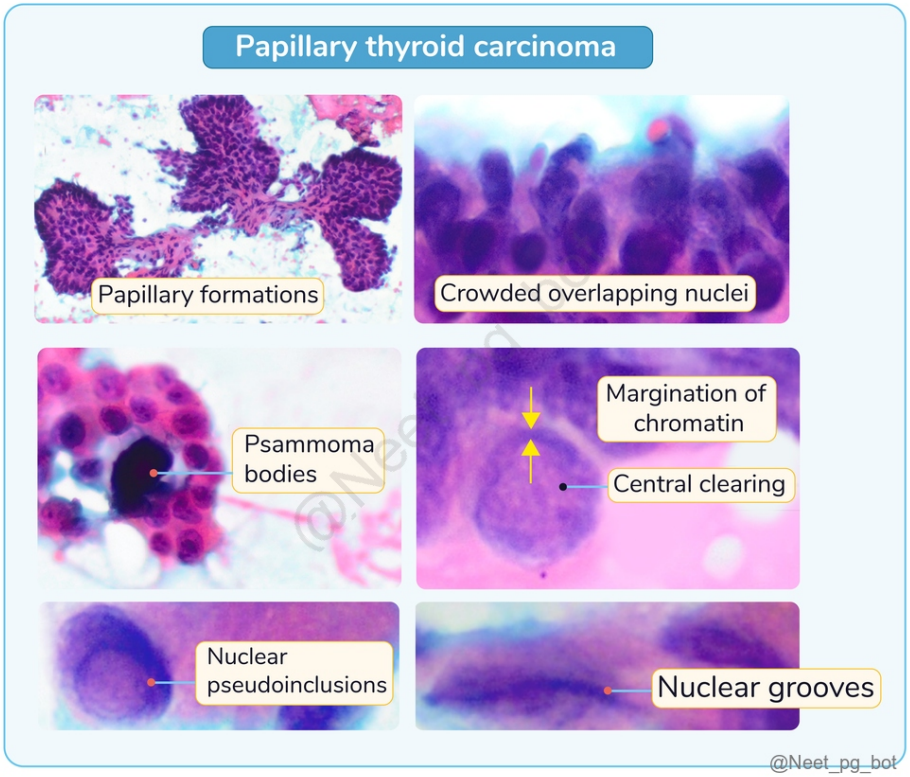

References:

Harrison's Principles of Internal Medicine, 22nd Edition, Page 3046.

↑ *Back to this question in Part A*

@Neet_pg_bot

Q4: Which of the following is/ are recognised risk factors for thyroid carcinoma in a patient presenting with a thyroid nodule? History of head and neck irradiation during childhood Male gender Slowly enlarging, mobile thyroid nodule in a middle-aged woman Hoarseness of voice or vocal cord paralysis PET-avid thyroid nodule on 18-FDG imaging (Q884025)

A. 1, 2, 4 and 5

B. 1 and 4 only

C. 1, 3 and 4

D. Only 1

Correct Answer: A. 1, 2, 4 and 5

Explanation: High-risk historical and examination features that increase malignancy probability include: Age <20 or >65 years Male gender (Statement 2) Nodule size >4 cm Rapidly enlarging or new neck mass Hoarseness / vocal cord paralysis (recurrent laryngeal nerve involvement) (Statement 4) Nodule fixed to adjacent structures Lateral cervical lymphadenopathy (ipsilateral nodes) Extrathyroidal extension Childhood head and neck irradiation (mantle radiation, cranial radiation, nuclear fallout exposure) (Statement 1) PET-avid nodules on 18-FDG or Ga-68 DOTATATE imaging Family history of papillary thyroid cancer in two or more first-degree relatives Genetic syndromes - MEN2, Cowden's, FAP, Carney complex, PTEN hamartoma tumour syndrome$f$ A slowly enlarging mobile thyroid nodule in a middle-aged woman is characteristic of benign disease and is not a malignancy risk factor. (Statement 3)

References:

Harrison's Principles of Internal Medicine, 22nd Edition, Page 3045.

↑ *Back to this question in Part A*

@Neet_pg_bot

Q5: A 19-year-old woman is evaluated for persistent biochemical thyrotoxicosis detected during routine screening. She has mild tachycardia but no weight loss, tremor, or ophthalmopathy. Her mother and maternal uncle are known to have "high thyroid hormone levels" but have never required treatment. Investigations show: Free T4 - High Free T3 - High TSH - Normal Which of the following best explains this patient's condition? (Q884026)

A. Activating mutation of the TSH receptor

B. Impaired feedback due to thyroid hormone receptor-β mutation

C. Autonomous hyperfunctioning thyroid nodules

D. TSH-secreting pituitary adenoma

Correct Answer: B. Impaired feedback due to thyroid hormone receptor-β mutation

Explanation: This is Resistance to Thyroid Hormone (RTH) . Key discriminator clues: Elevated T3 and T4 with non-suppressed TSH Minimal clinical hyperthyroidism Strong family history No ophthalmopathy No nodular goiter Classic RTH is caused by mutations in the TRβ gene , leading to impaired tissue sensitivity and loss of negative feedback at the pituitary , producing inappropriately normal or high TSH despite elevated thyroid hormones. Patients are often clinically euthyroid or mildly hyperthyroid and usually do not require antithyroid therapy Activating TSH receptor mutation (Option A): Produces true hyperthyroidism with suppressed TSH and overt symptoms. Autonomous nodules (Option C): TSH is suppressed due to intact pituitary feedback. TSH-secreting pituitary adenoma (Option D): TSH is frankly elevated, and patients have progressive

thyrotoxicosis, goitre, and mass-effect symptoms.

References:

Harrison’s Principles of Internal Medicine, 22nd Edition, Page 3025.

↑ *Back to this question in Part A*

@Neet_pg_bot

Q6: A 27-year-old woman presents with weight loss, tremors and palpitations for 2 months. She has no neck pain or fever. Examination shows no goiter or thyroid tenderness. Laboratory evaluation shows: TSH - Suppressed Free T4 - Elevated ESR - Normal Thyroid radionuclide uptake - Very low Serum thyroglobulin - Normal Which of the following is the most likely diagnosis? (Q884027)

A. Subacute granulomatous thyroiditis

B. Graves’ disease

C. Thyrotoxicosis factitia

D. Toxic multinodular goitre

Correct Answer: C. Thyrotoxicosis factitia

Explanation: Serum thyroglobulin remains normal in thyrotoxicosis factitia (Exogenous thyroid hormone ingestion) because the excess thyroid hormone is self-administered , and the thyroid gland is not actively synthesising or releasing hormone. In Thyrotoxicosis Factitia: RAIU is suppressed because the thyroid gland is not synthesizing hormone. TSH is suppressed , but T3:T4 ratio is low (T4 predominance), unlike Graves where T3 predominates. Thyroid gland is normal-sized and non-tender (no goitre, no pain). No ophthalmopathy or dermopathy (unlike Graves’ disease). Anti-TPO and TRAb antibodies are negative. Serum thyroglobulin is normal or low - key discriminator. Treatment is cessation of exogenous hormone ± beta blockers In contrast, thyroglobulin is elevated in all endogenous causes of thyrotoxicosis. It is particularly high in thyroiditis , where follicular destruction causes leakage of stored thyroglobulin. The primary clinical use of thyroglobulin is in follow-up of differentiated thyroid carcinoma - after total thyroidectomy and radioiodine ablation, thyroglobulin should be undetectable . Detectable thyroglobulin (without anti-Tg antibodies) indicates residual or recurrent disease. Subacute granulomatous thyroiditis (Option A): Follicular destruction causes marked thyroglobulin elevation . Graves’ disease (Option B): Diffuse gland hyperfunction causes elevated thyroglobulin . Toxic multinodular goitre (Option D): Autonomous nodules actively synthesise hormone → elevated thyroglobulin .

References:

Harrison’s Principles of Internal Medicine, 22nd Edition, Page 3026

↑ *Back to this question in Part A*

@Neet_pg_bot

Q7: A 38-year-old woman presents with weight gain, constipation, and cold intolerance. Laboratory evaluation shows low free T4 with elevated TSH. Which of the following conditions is least likely to produce this biochemical pattern? (Q884028)

A. Postpartum autoimmune thyroiditis

B. Lithium-induced thyroid dysfunction

C. Sheehan syndrome

D. Chronic autoimmune thyroiditis

Correct Answer: C. Sheehan syndrome

Explanation: The biochemical pattern shown is primary hypothyroidism (↓T4, ↑TSH). Causes of Primary Hypothyroidism Autoimmune destruction (Option D) - Hashimoto's thyroiditis, atrophic thyroiditis Iatrogenic - Post ^{131}I therapy, subtotal/total thyroidectomy, neck irradiation Drug-induced - Amiodarone, lithium (Option B), iodine excess (contrast), antithyroid drugs, interferon-α, tyrosine kinase inhibitors (e.g., sunitinib), immune checkpoint inhibitors (nivolumab, pembrolizumab, ipilimumab) Congenital - Thyroid dysgenesis, dyshormonogenesis, TSH-R mutation Iodine deficiency (most common cause worldwide) Infiltrative diseases - Amyloidosis, sarcoidosis, hemochromatosis, Riedel thyroiditis Transient forms - Postpartum thyroiditis (Option A) , subacute thyroiditis, withdrawal of excess thyroxine Sheehan syndrome is a cause of secondary hypothyroidism due to pituitary infarction. It causes low or inappropriately normal TSH with low T4 , not the elevated TSH seen in primary hypothyroidism - making it least consistent with the given biochemical pattern.

References:

Harrison's Principles of Internal Medicine, 22nd Edition, Page 3027

↑ *Back to this question in Part A*

@Neet_pg_bot

Q8: A 2-month-old infant presents with persistent constipation, poor feeding, prolonged jaundice and hypotonia. Examination reveals macroglossia and no palpable thyroid gland in the neck. Laboratory evaluation shows: TSH - markedly elevated Free T4 - very low Which of the following statements regarding this condition is true? (Q884029)

A. Most cases are caused by defects in thyroid hormone synthesis

B. High circulating T4 levels are required to normalize TSH in early life

C. The disorder is more common in males

D. Thyroid hormone replacement can be delayed until 1 year of age

Correct Answer: B. High circulating T4 levels are required to normalize TSH in early life

Explanation: This infant has congenital hypothyroidism , most commonly due to thyroid gland dysgenesis . ≈85% of neonatal hypothyroidism is due to thyroid dysgenesis (Option A) (agenesis, ectopy, hypoplasia) Remaining cases are due to dyshormonogenesis (defective hormone synthesis) Females are affected twice as often as males (Option C) Classic features include: Prolonged jaundice Macroglossia Hypotonia Constipation Umbilical hernia Neonates require relatively high circulating T4 levels to suppress TSH and normalise neurodevelopment. This is why early high-dose levothyroxine is essential. Delay in therapy leads to irreversible intellectual disability (Option D)

References:

Harrison's Principles of Internal Medicine, 22nd Edition, Page 3027, 3028

↑ *Back to this question in Part A*

@Neet_pg_bot

Q9: A patient with autoimmune thyroid disease is suspected to have autoimmune polyendocrine syndrome type 2 (APS-2). Which of the following pairs of additional diseases, when present together with autoimmune thyroid disease, would confirm the diagnosis of APS-2? (Q884030)

A. Hypoparathyroidism + Chronic mucocutaneous candidiasis

B. Addison's disease + Type 1 diabetes mellitus

C. Pernicious anemia + Vitiligo

D. Celiac disease + Sjögren syndrome

Correct Answer: B. Addison's disease + Type 1 diabetes mellitus

Explanation: Autoimmune Polyendocrine Syndrome Type 2 (APS-2) (Schmidt syndrome) is a polygenic autoimmune disorder characterized by a specific triad: Autoimmune thyroid disease - present in 70-75% of cases Type 1 diabetes mellitus - present in 40-60% of cases Addison disease - present in 40-50% of cases (mandatory component) Thus, in a patient who already has autoimmune thyroid disease, the coexistence of Addison disease and T1DM together confirms APS-2. Other associations of Autoimmune Hypothyroidism Vitiligo Pernicious anemia Alopecia areata Sjögren syndrome Myasthenia gravis Autoimmune hypoparathyroidism Primary hypogonadism Celiac disease Dermatitis herpetiformis Rheumatoid arthritis and SLE

References:

Harrison’s Principles of Internal Medicine, 22nd Edition, Page 3030

↑ *Back to this question in Part A*

@Neet_pg_bot

Q10: A 61-year-old woman from an iodine-deficient region presents with a gradually enlarging neck mass for 16 years. She is clinically euthyroid. On raising both arms above her head, she develops facial flushing and venous congestion. Her CT scan shows substernal extension with mild tracheal narrowing. Thyroid ultrasound reveals multiple nodules of varying size. Which of the following statements regarding her condition is correct? (Q884022)

A. Most nodules represent monoclonal neoplastic transformation

B. Sudden onset of neck pain most commonly indicates malignant change

C. Radioiodine can reduce goitre volume by nearly half and ablate autonomous nodules

D. Thyroxine suppression therapy is the preferred long-term treatment

Correct Answer: C. Radioiodine can reduce goitre volume by nearly half and ablate autonomous nodules

Explanation: Non-toxic multinodular goitre (MNG) is more common in women, increases with age and is frequent in iodine-deficient regions. Most nodules are polyclonal hyperplastic lesions (Option A) , and patients are usually euthyroid and asymptomatic. Pemberton’s sign indicates thoracic inlet compression. Radioiodine therapy is used when surgery is contraindicated; it can reduce goitre size by ~40-50% and selectively ablate autonomous nodules. Sudden neck pain (Option B): Usually due to intranodular haemorrhage, not malignancy. Thyroxine suppression (Option D): Rarely effective and increases the risk of inducing thyrotoxicosis.

References:

Harrison’s Principles of Internal Medicine, 22nd Edition, Page 3041, 3042, 3043.

↑ *Back to this question in Part A*

@Neet_pg_bot

Q11: An elderly woman is brought to the emergency department in winter with progressive drowsiness for 2 days. On examination, she is hypothermic, bradycardic,

hypotensive, and has non-pitting facial puffiness. She is hypoventilating. Laboratory evaluation reveals hyponatremia, hypoglycemia, and hypercapnia. What is the most likely diagnosis? (Q884032)

A. Septic shock

B. Cardiogenic shock

C. Myxedema coma

D. Acute adrenal crisis

Correct Answer: C. Myxedema coma

Explanation: This presentation is classic for myxedema coma , the most severe and life-threatening manifestation of hypothyroidism. Myxedema coma represents the extreme end of the myxedema crisis spectrum and has a 20-40% mortality rate even with treatment. Clinical features present here: Altered mental status (drowsiness → coma) Profound hypothermia (can fall to ~23°C) Bradycardia and hypotension Hypoventilation → hypercapnia and hypoxemia Hyponatremia and hypoglycemia Non-pitting edema (myxedema) Common precipitants include: sedatives, antidepressants, anesthetics, opioids, infection, cold exposure, MI, and stroke. Septic shock (Option A): Characterized by fever, tachycardia, leukocytosis and an identifiable infective focus. Myxedema coma instead presents with profound hypothermia, bradycardia, and hypoventilation. Cardiogenic shock (Option B): Would show signs of left heart failure such as pitting pedal edema, raised JVP, pulmonary edema and dyspnea , not non-pitting myxedematous edema and hypothermia. Acute adrenal crisis (Option D): Causes hypotension and hypoglycemia, but does not produce hypothermia, bradycardia, hypoventilation, or myxedematous facial puffiness.

References:

Harrison’s Principles of Internal Medicine, 22nd Edition, Page 3032

↑ *Back to this question in Part A*

@Neet_pg_bot

Q12: A 64-year-old man is admitted with severe community-acquired pneumonia requiring ICU care. He has no prior thyroid disease. Thyroid profile shows: Total T3 - Low Free T4 - Normal TSH - Normal Reverse T3 - Elevated What is the most appropriate interpretation of this thyroid profile? (Q884033)

A. Primary hypothyroidism

B. Secondary hypothyroidism

C. Sick euthyroid syndrome

D. Thyroid hormone resistance

Correct Answer: C. Sick euthyroid syndrome

Explanation: The most common hormone pattern seen in Sick Euthyroid Syndrome (SES) is a decrease in total and free T3 levels with normal T4 and TSH . This pattern is termed Low T3 syndrome . SES occurs in patients with acute or severe systemic illness without intrinsic thyroid disease . Acute severe illness suppresses peripheral 5′-deiodinase activity, leading to: Impaired conversion of T4 → T3 Increased conversion of T4 → rT3 Fall in biologically active T3 proportional to illness severity This represents an adaptive metabolic response to reduce energy expenditure. Thyroid hormone therapy is not indicated . In critically ill patients, both T4 and T3 may fall markedly - this is termed Low T4 syndrome , which is associated with poor prognosis . Primary hypothyroidism (Option A): Characterised by low T4 with elevated TSH due to failure of the thyroid gland. Reverse T3 is not elevated and the characteristic low-T3 pattern of SES is not seen. Secondary hypothyroidism (Option B) : Due to pituitary failure, showing low T4 with low or inappropriately normal TSH . This is a structural endocrine disorder, not a transient adaptive response to illness. Thyroid hormone resistance (Option D) : Shows elevated T3 and T4 with non-suppressed TSH due to impaired tissue sensitivity to thyroid hormone. It does not produce isolated low T3 levels.

References:

Harrison’s Principles of Internal Medicine, 22nd Edition, Page 3039

↑ *Back to this question in Part A*

@Neet_pg_bot

Q13: A neonate is born with a large scalp defect as shown. The mother had been treated for hyperthyroidism during early pregnancy. Which of the following drugs is most likely responsible for this congenital anomaly? (Q884034)

A. Propylthiouracil

B. Methimazole

C. Radioactive iodine

D. Levothyroxine

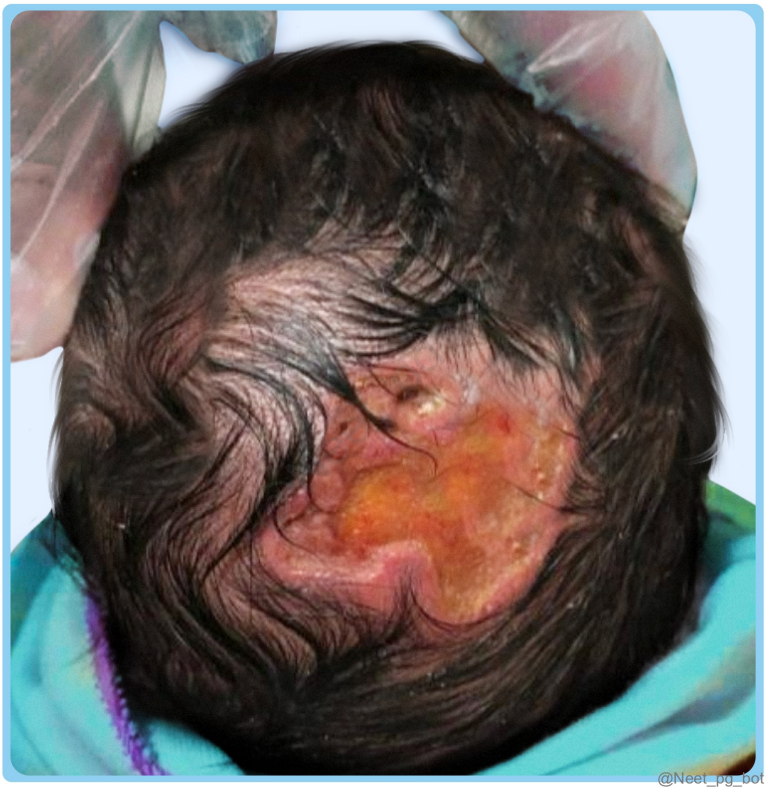

Correct Answer: B. Methimazole

Explanation: This neonate has aplasia cutis congenita , a scalp defect with absence of skin and underlying skull bone commonly over the vertex It is a characteristic teratogenic defect classically associated with methimazole / carbimazole exposure during the first trimester of pregnancy . Methimazole embryopathy includes: Aplasia cutis congenita Choanal atresia Tracheoesophageal fistula Esophageal atresia Facial anomalies Fetal goitre Because of this risk, propylthiouracil (PTU) is preferred in the first trimester , and methimazole is avoided. Propylthiouracil (Option A): Preferred antithyroid drug in the first trimester because it has much lower teratogenic risk . It is not associated with aplasia cutis congenita. Radioactive iodine (Option C): Causes fetal thyroid ablation leading to congenital hypothyroidism , not structural scalp defects like aplasia cutis. Levothyroxine (Option D): Synthetic thyroid hormone used to treat hypothyroidism and is safe in pregnancy . It does not cause any congenital malformations.

References:

Harrison’s Principles of Internal Medicine, 22nd Edition, Page 3036

↑ *Back to this question in Part A*

@Neet_pg_bot

Q14: A 32-year-old woman with Graves' disease has persistent hyperthyroidism despite 12 months of carbimazole therapy. She is a smoker and has mild

exophthalmos. She is not pregnant and is not breastfeeding. She wishes to conceive in the future. Which of the following is the most appropriate next step? (Q884035)

A. Radioiodine therapy without any additional medication

B. Radioiodine therapy with concurrent oral prednisone

C. Radioiodine therapy after immediate conception

D. Total thyroidectomy without further evaluation

Correct Answer: B. Radioiodine therapy with concurrent oral prednisone

Explanation: This patient has Graves disease with mild ophthalmopathy and is a smoker , which significantly increases the risk of worsening eye disease following radioiodine (RAI) therapy. Pregnancy and lactation are the only absolute contraindications to RAI - she has neither. RAI can be given in mild ophthalmopathy with steroid cover. Prednisone 0.2-0.5 mg/kg/day started at the time of RAI and tapered over 6-12 weeks reduces the risk of ophthalmopathy progression. Conception should be deferred for at least 6 months after RAI. Radioiodine therapy without steroid cover (Option A): Patients with Graves ophthalmopathy-especially smokers-have a high risk of worsening eye disease after radioiodine. Steroid prophylaxis is required to prevent progression. Radioiodine therapy followed by immediate conception (Option C): Conception is contraindicated for at least 6 months after radioiodine therapy due to risk of fetal thyroid ablation. Total thyroidectomy without further evaluation (Option D): Surgery is reserved for patients with large goiters, compressive symptoms, suspected malignancy, or moderate-to-severe ophthalmopathy. Mild ophthalmopathy can be safely managed with radioiodine plus steroid cover.

References:

Harrison’s Principles of Internal Medicine, 22nd Edition, Page 3036

↑ *Back to this question in Part A*

@Neet_pg_bot

Q15: A 25-year-old primigravida at 9 weeks of gestation presents with palpitations, tremors and excessive sweating. Thyroid function tests confirm hyperthyroidism. Which is the most appropriate initial drug of choice? (Q884036)

A. Methimazole

B. Carbimazole

C. Propylthiouracil

D. Propranolol

Correct Answer: C. Propylthiouracil

Explanation: This patient is in the first trimester of pregnancy with thyrotoxicosis. Propylthiouracil (PTU) is the drug of choice in the first trimester because it has lower teratogenic risk compared to methimazole and carbimazole. Methimazole and carbimazole (Option A and B) are associated with characteristic embryopathy, including: Aplasia cutis congenita Choanal atresia Tracheoesophageal fistula Fetal goiter Omphalocele Therefore, they are avoided in early pregnancy. However, PTU is used only in the first trimester because prolonged use is associated with severe hepatotoxicity . Hence, after completion of the first trimester, patients are shifted to methimazole or carbimazole . Throughout pregnancy, the lowest effective dose of antithyroid drug should be used to maintain maternal free T4 in the upper limit of the non-pregnant reference range . Propranolol (Option D): Provides only symptomatic control and does not reduce thyroid hormone synthesis.

References:

Harrison's Principles of Internal Medicine, 22nd Edition, Page 3036

↑ *Back to this question in Part A*

@Neet_pg_bot

Q16: A 42-year-old woman presents with a slowly progressive anterior neck swelling for 4 years. She has no palpitations, tremor, weight loss, or menstrual irregularities. Examination reveals a soft, symmetrically enlarged, non-tender thyroid gland with no palpable nodules. Thyroid function tests are normal. Which of the following best explains the pathogenesis of her condition? (Q884037)

A. Activating mutation of the TSH receptor

B. Chronic iodine deficiency causing diffuse follicular hyperplasia

C. Autoimmune destruction of thyroid follicles

D. Somatic mutations causing monoclonal nodular proliferation

Correct Answer: B. Chronic iodine deficiency causing diffuse follicular hyperplasia

Explanation: This patient has non-toxic diffuse (simple/colloid) goitre . It is most commonly caused by iodine deficiency Relative TSH stimulation due to impaired thyroid hormone synthesis → uniform follicular hyperplasia with colloid accumulation Gland is soft, symmetrical, non-tender, euthyroid and nodule-free Usually benign and asymptomatic TFTs are normal Surgery is rarely indicated - only for cosmetic reasons, tracheal compression, or thoracic inlet obstruction Large substernal goitres can show positive Pemberton's sign Early stages show diffuse hyperplasia; late stages may accumulate colloid. Activating mutation of the TSH receptor (Option A): Causes autonomous hormone production leading to toxic nodular goitre with suppressed TSH and clinical thyrotoxicosis - not a euthyroid diffuse enlargement. Autoimmune destruction of thyroid follicles (Option C): Represents Hashimoto's thyroiditis , which causes a firm irregular gland with hypothyroidism and positive anti-TPO antibodies - not a soft euthyroid diffuse goitre. Somatic mutations causing monoclonal nodular proliferation

(Option D): Seen in multinodular goitre , which produces nodular architecture rather than a uniform diffuse enlargement.

References:

Harrison’s Principles of Internal Medicine, 22nd Edition, Page 3040, 3041

↑ *Back to this question in Part A*

@Neet_pg_bot

Q17: A 29-year-old woman with no prior thyroid illness presents with intermittent tremors and heat intolerance for 10 days. She delivered her second child 5 months ago. There is no neck pain, fever, or sore throat. Examination shows a small, soft, non-tender thyroid gland. Investigations reveal: TSH - Suppressed Free T4 - Elevated ESR - Normal Anti-TPO antibodies - Positive 99mTc-pertechnetate uptake - Suppressed Which of the following best describes the expected course of this illness? (Q884038)

A. Progression to permanent thyrotoxicosis requiring radioiodine

B. Spontaneous resolution after a transient hypothyroid phase

C. Requirement of prolonged glucocorticoid therapy

D. Lifelong antithyroid drug therapy due to high relapse rate

Correct Answer: B. Spontaneous resolution after a transient hypothyroid phase

Explanation: This patient has silent (postpartum) thyroiditis , a painless autoimmune destructive thyroiditis occurring 3-6 months after delivery . Thyrotoxicosis results from release of preformed thyroid hormones , not increased synthesis-hence suppressed radionuclide uptake , normal ESR , and positive anti-TPO antibodies . The illness typically follows a self-limited course with a transient thyrotoxic phase , followed by a temporary hypothyroid phase , and then spontaneous recovery in most patients. Silent thyroiditis is an autoimmune destructive thyroiditis that: Occurs 3-6 months postpartum - Postpartum thyroiditis Is associated with positive TPO antibodies Has normal ESR Shows suppressed radionuclide uptake due to follicular destruction Is more common in women with autoimmune disease Clinical course: Transient thyrotoxic phase (2-4 weeks) Followed by hypothyroid phase (4-12 weeks) Then spontaneous recovery in most patients (Option A) ~20-30% may develop permanent hypothyroidism long-term Management: Only symptomatic therapy (β-blockers). Temporary thyroxine may be used during hypothyroid phase and withdrawn after 6-9 months. Annual follow-up is recommended as a proportion may develop permanent hypothyroidism and recurrence may occur in subsequent pregnancies. Prolonged glucocorticoids (Option C): Steroids are required in painful subacute thyroiditis, not in painless silent thyroiditis. Lifelong antithyroid therapy (Option D): Antithyroid drugs are ineffective because hormone excess is due to follicular destruction, not increased synthesis.

References:

Harrison’s Principles of Internal Medicine, 22nd Edition, Page 3038, 3039

↑ *Back to this question in Part A*

@Neet_pg_bot

Q18: A 29-year-old woman with known primary hypothyroidism is 11 weeks pregnant and is on regular levothyroxine therapy. She is clinically well. Which of the following is the recommended upper limit of serum TSH that should be maintained in her at this gestational age? (Q884039)

A. < 1.5 mIU/L

B. < 2.5 mIU/L

C. < 3.0 mIU/L

D. < 4.0 mIU/L

Correct Answer: B. < 2.5 mIU/L

Explanation: During the first trimester , maternal thyroxine is the sole source of thyroid hormone for fetal brain development. Even mild maternal hypothyroidism is associated with impaired fetal neurocognitive outcomes. Therefore, pregnancy-specific TSH targets are: 1st trimester: TSH < 2.5 mIU/L 2nd trimester: TSH < 3.0 mIU/L 3rd trimester: TSH < 3.0 mIU/L Thyroid function should be monitored by measuring TSH every 4 weeks in the first trimester , and less frequently after 20 weeks of gestation. Levothyroxine dose requirements increase during pregnancy due to increased thyroxine-binding globulin, placental deiodination, and increased maternal-fetal demand. → The dose often needs to be increased by up to 50% . Post-delivery levothyroxine doses are usually reduced back to pre-pregnancy levels , with repeat TSH monitoring to re-establish euthyroidism.

References:

Harrison’s Principles of Internal Medicine, 22nd Edition, Page 3031, 3032

↑ *Back to this question in Part A*

@Neet_pg_bot

Q19: Which of the following is not a feature of hypothyroidism? (Q850927)

A. Pericardial efffusion

B. Pleural efffusion

C. Carpal tunnel syndrome

D. Diarrhea

Correct Answer: D. Diarrhea

■ *Listen (English)*

■ *Listen (Hindi)*

Explanation: Hypothyroidism typically slows metabolism , leading to fluid accumulation (pericardial or pleural effusions) and neuropathies like carpal tunnel syndrome. Diarrhea is not a feature ; constipation is more common. Serous cavity effussions are seen in hypothyroidism due to myxedema. Myxedema reduces lymphatic outflow / drainage of Lymph that explains the development of both pericardial and pleural effusion (Options A and B) in these patients. Deposition of mucinous material of GAG in the transverse carpal ligament and surrounding soft tissues causes median nerve compression (Option C) and numbness, tingling, weakness in the hand.

References:

Harrison’s Principles of Internal Medicine, 21st Edition, Volume I, Page 2933

↑ *Back to this question in Part A*

@Neet_pg_bot

Q20: Which of the following is the most appropriate preoperative management to prevent thyroid storm in a pateint of grave's disease who is scheduled for total thyroidectomy? (Q850785)

A. Start propranolol 7 days before and perform surgery once heart rate normalizes

B. Start methimazole and wait till acheiving euthyroid status

C. Start methimazole, potassium iodide, propranolol and wait till achieving euthyroid status

D. Take consent for high risk emergency surgery with careful intraoperative monitoing

Correct Answer: C. Start methimazole, potassium iodide, propranolol and wait till achieving euthyroid status

■ *Listen (English)*

■ *Listen (Hindi)*

Explanation: To prevent thyroid storm during thyroidectomy in a patient with severe hyperthyroidism due to Grave's disease, it is essential to render the patient euthyroid preoperatively. Methimazole is started to inhibit thyroid hormone synthesis, and once hormone levels begin to fall (typically after a few days), potassium iodide is added 7–10 days before surgery to inhibit hormone release (the Wolff-Chaikoff effect) and reduce gland

vascularity. Propranolol is used to control adrenergic symptoms and also slightly inhibits peripheral T4 to T3 conversion. The Burch-Wartofsky scoring system is used to help diagnose thyroid storm: Interpretation of Burch-Wartofsky score: ≥45 points: Highly suggestive of thyroid storm 25-44 points: Impending thyroid storm <25 points: Unlikely to represent thyroid storm

References:

Harrison's Principles of Internal Medicine, 21st Edition, Page 2942..

www.ncbi.nlm.nih.gov/books/NBK278927/

↑ *Back to this question in Part A*

@Neet_pg_bot

Q21: A 45-year-old woman with a history of multinodular goitre undergoes a CT angiogram with iodinated contrast for suspected pulmonary embolism. Two weeks later, she presents with palpitations, heat intolerance, and weight loss. Her thyroid function tests show suppressed TSH and elevated T3 and T4. Which of the following best explains this patient's current condition? (Q850786)

A. Wolff-Chaikoff effect

B. Jod-Basedow effect

C. Thyroid storm

D. Hashitoxicosis

Correct Answer: B. Jod-Basedow effect

■ *Listen (English)*

■ *Listen (Hindi)*

Explanation: This patient developed iodine-induced hyperthyroidism (Jod-Basedow phenomenon) after exposure to iodinated contrast, especially in the setting of pre-existing multinodular goitre. The sudden iodine load triggers excessive thyroid hormone synthesis in autonomous thyroid tissue. Wolff-Chaikoff effect (Option A): This is the opposite of Jod-Basedow. It is a protective mechanism where a large dose of iodine causes the thyroid to shut down hormone production temporarily. This would lead to hypothyroidism (high TSH, low T4), not hyperthyroidism. Thyroid storm (Option C): This is a life-threatening, extreme manifestation of hyperthyroidism (fever, delirium, cardiac failure). While this patient is symptomatic, "Thyroid storm" describes the severity of the state rather than the underlying mechanism requested by the question. Hashitoxicosis (Option D): This is the transient hyperthyroid phase of Hashimoto’s thyroiditis caused by the "leaking" of preformed hormones as the gland is destroyed. It is not triggered by iodine contrast.

References:

Harrison’s Principle of Internal Medicine, 21st Edition, Page 2945

↑ *Back to this question in Part A*

@Neet_pg_bot

Q22: A 52-year-old woman presents with a 2-week history of palpitations, anxiety, and weight loss. On examination, her heart rate is 110 bpm and regular, and she has a painful goitre. Thyroid function tests show decreased TSH level and elevated free T3 & T4 levels. A thyroid scan shows very low uptake. Which of the following is the most likely diagnosis? (Q850787)

A. Graves' disease

B. Toxic multinodular goiter

C. Subacute thyroiditis

D. TSH-secreting pituitary adenoma

Correct Answer: C. Subacute thyroiditis

■ *Listen (English)*

■ *Listen (Hindi)*

Explanation: The patient presents with painful goitre, hyperthyroid symptoms, and low radioactive iodine uptake , which is characteristic of subacute (de Quervain) thyroiditis . The low uptake differentiates it from conditions caused by overproduction of hormone. {{caption_text}} Graves' disease (Option A) usually presents with diffuse, painless goitre and high radioactive iodine uptake. Toxic multinodular goiter (Option B) is typically painless with patchy increased uptake on scan. TSH-secreting pituitary adenoma (Option D) causes high TSH with high T3/T4, unlike the suppressed TSH seen here.

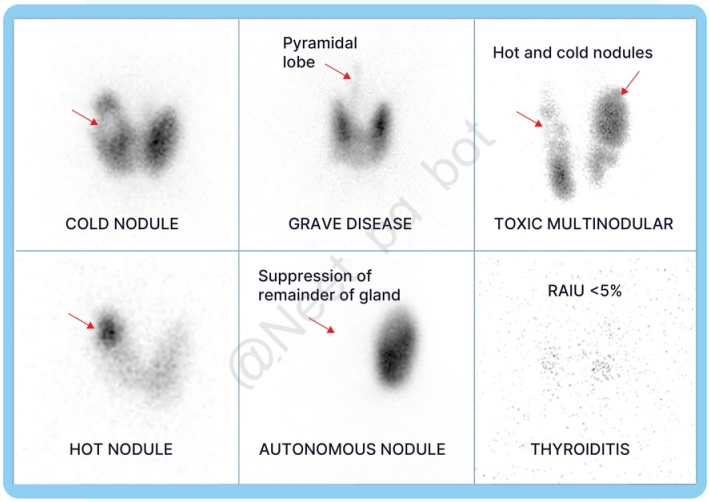

@Neet_pg_bot

References:

www.ncbi.nlm.nih.gov/books/NBK482216/

↑ *Back to this question in Part A*

@Neet_pg_bot

Q23: 35-year-old woman presents with a history of weight loss, palpitations and heat intolerance. On examination, she has a diffuse goitre, ophthalmopathy and fine tremors in her outstretched hands. Her thyroid function tests show: TSH: < 0.01 mIU/L (normal range: 0.4-4.0 mIU/L) Free T4: 35 pmol/L (normal range: 10-20 pmol/L) Free T3: 12 pmol/L (normal range: 3.5-6.5 pmol/L) Which of the following is the most likely cause of her hyperthyroidism? (Q850790)

A. Toxic multinodular goiter

B. Graves' disease

C. TSH-secreting pituitary adenoma

D. Jod Basedow effect

Correct Answer: B. Graves' disease

■ *Listen (English)*

■ *Listen (Hindi)*

Explanation: The patient has diffuse goitre, ophthalmopathy, tremors, and suppressed TSH with elevated T3/T4 , which is characteristic of Graves' disease , an autoimmune hyperthyroidism. Toxic multinodular goiter (Option A) usually presents with nodular, asymmetric goitre without ophthalmopathy. TSH-secreting pituitary adenoma (Option C) causes elevated TSH despite high T3/T4, unlike the suppressed TSH seen here. Jod-Basedow effect (Option D) occurs after iodine exposure in susceptible patients and is usually not associated with ophthalmopathy.

References:

Davidson's Principle and Practice of Medicine, 24th Edition, Page 634.

pmc.ncbi.nlm.nih.gov/articles/PMC5014602/

↑ *Back to this question in Part A*

@Neet_pg_bot

Q24: 50 year old patient was diagnosed with atrial fibrillation. Diagnostic work up showed high T4, high T3 and high TSH. Which of the following is next best investigation for this patient? (Q850795)

A. MRI Head

B. USG neck

C. TSH receptor antibody titer

D. Radioactive thyroid scan

Correct Answer: A. MRI Head

■ *Listen (English)*

■ *Listen (Hindi)*

Explanation: The patient has high T4, high T3, and inappropriately high TSH , suggesting secondary hyperthyroidism due to a TSH-secreting pituitary adenoma . MRI of the pituitary is the next best investigation to localize the adenoma. USG neck (Option B) is used to assess thyroid nodules but cannot detect a pituitary source. TSH receptor antibody titer (Option C) is for Graves' disease, which presents with suppressed TSH, not elevated. Radioactive thyroid scan (Option D) evaluates thyroid uptake but cannot identify a pituitary cause.

References:

Davidson's Principle and Practice of Medicine, 24th Edition, Page 637.

pmc.ncbi.nlm.nih.gov/articles/PMC5014602/

↑ *Back to this question in Part A*

@Neet_pg_bot

Q25: On the Thyroid function test, TSH is suppressed, Free T4 level is normal, and Free T3 is increased. Which of the following is the most likely diagnosis? (Q850796)

A. Subclinical hyperthyroidism

B. Euthyroid sick syndrome

C. Primary Hyperthyroidism

D. T3 thyrotoxicosis

Correct Answer: D. T3 thyrotoxicosis

■ *Listen (English)*

■ *Listen (Hindi)*

Explanation: T3 thyrotoxicosis is characterized by suppressed TSH, elevated T3, and normal T4 , often representing an early or mild form of hyperthyroidism where T3 rises first. Subclinical hyperthyroidism (Option A) shows suppressed TSH but normal T3 and T4. Euthyroid sick syndrome (Option B) usually shows low T3 with normal or low T4 and variable TSH. Primary hyperthyroidism (Option C) generally presents with suppressed TSH and elevated T4 (often T3 as well).

References:

Harrison’s Principles of Internal Medicine, 21st Edition, Volume I, Page 2931, 2932.

↑ *Back to this question in Part A*

@Neet_pg_bot

Q26: RAIU scan was performed for a 35 year old lady with hypertension and palpitations. Diagnosis is? (Q850925)

A. Toxic multinodular goiter

B. Graves' disease

C. Thyroiditis

D. Thyroid adenoma



Correct Answer: B. Graves' disease

- *Listen (English)*
- *Listen (Hindi)*

Explanation: Graves' disease typically shows diffusely increased uptake on a radioactive iodine uptake (RAIU) scan, correlating with hyperthyroidism and systemic symptoms like palpitations and hypertension. Toxic multinodular goiter (Option A) usually shows heterogeneous uptake with multiple “hot” nodules rather than diffuse uptake. Thyroiditis (Option C) shows low or negligible uptake due to release of preformed hormone rather than increased synthesis. Thyroid adenoma (Option D) presents as a single “hot” nodule on RAIU scan, not diffuse uptake.

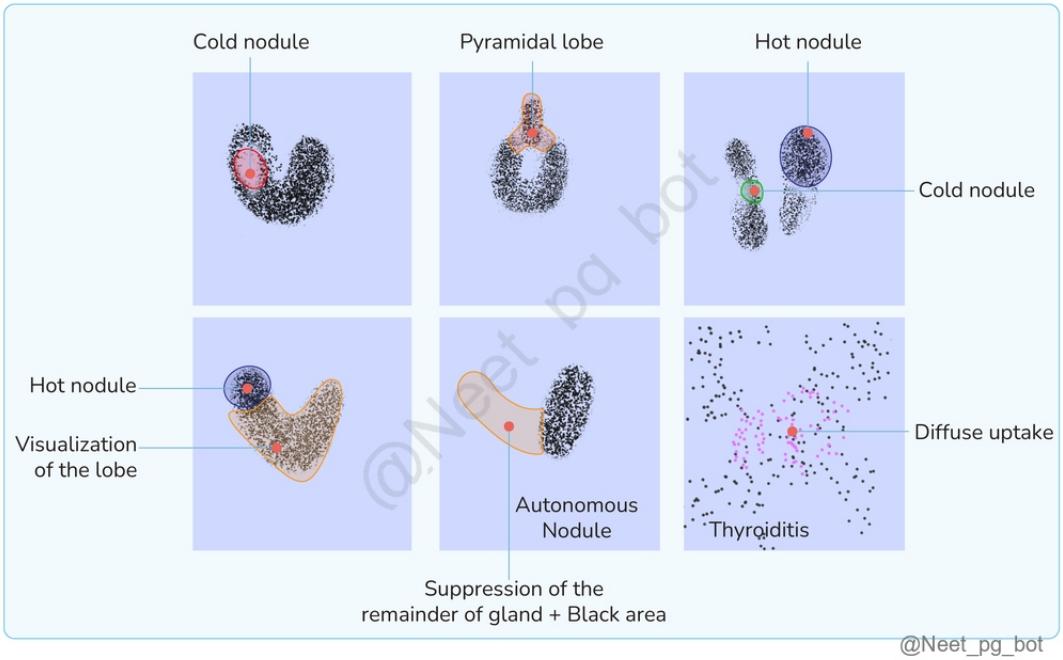

References:

Harrison's Principles of Internal Medicine, 21st Edition, Volume I, Page. 2932.

↑ *Back to this question in Part A*

@Neet_pg_bot

Q27: A 32-year-old woman presents with palpitations, weight loss, and heat intolerance for the past 3 months. On examination, she has a diffuse goitre and mild proptosis. Thyroid function tests show suppressed TSH and elevated free T4 and T3. Which of the following is the most appropriate next step in management? (Q850926)

A. Radioiodine ablation

B. Total thyroidectomy

C. Start propranolol and carbimazole

D. MRI Brain

Correct Answer: C. Start propranolol and carbimazole

■ *Listen (English)*

■ *Listen (Hindi)*

Explanation: This patient has new-onset Graves' disease with symptomatic hyperthyroidism. Initial management includes beta-blockers (like propranolol) for symptom control and antithyroid drugs (like carbimazole) to reduce hormone synthesis. Radioiodine ablation (Option A) is considered later for definitive therapy, not first-line in new-onset disease. Total thyroidectomy (Option B) is reserved for large goiters, suspicion of malignancy, or intolerance to medications. MRI Brain (Option D) is not indicated as this is a primary thyroid disorder, not a central cause of hyperthyroidism.

References:

Harrison's Principles of Internal Medicine, 21st Edition, Page 2938, 2941

↑ *Back to this question in Part A*

@Neet_pg_bot

Q28: A 45-year-old woman presents with palpitations, vomiting, diarrhea and marked agitation following an abrupt discontinuation of her antithyroid medication following a UTI. On examination, she is diaphoretic with proptosis and diffuse neck swelling with prominent jugular pulsations . Vitals are pulse: 120/min, BP 160/100 mm Hg, RR 24/min Temp: 39 C. Which of the following is best drug for managment of this patient? (Q850784)

A. Saturated solution of potassium iodide

B. Propylthiouracil

C. Liothyronine

D. Propranolol

Correct Answer: B. Propylthiouracil

■ *Listen (English)*

■ *Listen (Hindi)*

Explanation: Hyperadrenergic symptoms like palpitations, tremors, sweating with hyperthermia in a grave's disease patient (diffusely enlarged thyroid with proptosis), and abrupt discontinuation of medication and infection point to Thyroid storm. The drug of choice for thyroid storm and initial treatment to be given is Propylthiouracil, which reduces peripheral T4 to T3 conversion. Saturated solution of potassium iodide (Option A) is used to acutely block thyroid hormone release, but only after thionamides are started. Liothyronine (Option C) is T3 supplementation and would worsen thyroid storm. Propranolol (Option D) should be given with extreme caution, as the finding of heart failure (prominent neck veins is mentioned).

References:

Harrison's Principles of Internal Medicine, 21st Edition, Page 2942

↑ *Back to this question in Part A*

@Neet_pg_bot

Q29: Which of the following is correct description of myxedema seen in patients with hypothyroidism? (Q850928)

A. Increased dermal collagen deposition

B. Accumulation of dermal glycosaminoglycans

C. Dermal saponification of fat

D. Dermal fibrosis

Correct Answer: B. Accumulation of dermal glycosaminoglycans

■ *Listen (English)*

■ *Listen (Hindi)*

Explanation: The patient's symptoms, including fatigue , weight gain , dry skin , and non-pitting edema (myxedema) , points to hypothyroidism. In hypothyroidism, there is an accumulation of glycosaminoglycans in the dermis that binds to water, leading to non-pitting edema of skin. Increased dermal collagen deposition (Option A) is not the primary mechanism of myxedema. Dermal saponification of fat (Option C) occurs in pancreatic fat necrosis, not hypothyroidism. Dermal fibrosis (Option D) refers to chronic scarring, which is not characteristic of myxedema.

References:

Harrison’s Principles of Internal Medicine, 21st Edition, Volume I, Page 2935

↑ *Back to this question in Part A*

@Neet_pg_bot

Q30: A 45-year-old woman comes with complaints of extensive hair loss, menorrhagia and weight gain. Work up shows elevated TSH , low T3, low T4 levels and anti TPO antibody present status. She has no known cardiovascular disease. Which of the following is the most appropriate next step regarding this patient? (Q850929)

A. Start levothyroxine 25 µg daily

B. Start levothyroxine 100 µg daily

C. Start liothyronine (T3) 5 µg three times daily

D. Observe and repeat thyroid function tests in 3 months

Correct Answer: B. Start levothyroxine 100 µg daily

■ *Listen (English)*

■ *Listen (Hindi)*

Explanation: Start levothyroxine 100 µg daily is approximately the full replacement dose (1.6ug/kg) for a healthy adult without cardiovascular disease. Levothyroxine increases oxygen consumption of heart and giving full dose in patients with coexistent heart disease can trigger angina. Levothyroxine 25 µg daily (Option A) is too low and is used for elderly or patients with heart disease to avoid precipitating arrhythmias or angina. Liothyronine (T3) 5 µg TID (Option C) is used in myxedema coma Observe and repeat in 3 months (Option D): We have to be proactive in this case

References:

Davidson's Principle and Practice of Medicine, 24th Edition, Page 640, 641

↑ *Back to this question in Part A*

@Neet_pg_bot

Q31: A known case of autoimmune thyroiditis presents with confusion and seizures. EEG shows generalized slowing without epileptiform discharges. Vitals are pulse 60/min. BP 120/100 mm Hg and temp 37.2 C. Work up shows High TSH, low T4, low T3, blood counts and CRP is normal. Which of the following is correct about diagnosis and management? (Q851050)

A. Hashimoto's encephalopathy and Hydrocortisone

B. Myxedema coma and iv Liothyronine

C. Myxedema coma and iv Levothyroxine

D. Thyroid storm and NG tube Propylthiouracil

Correct Answer: A. Hashimoto's encephalopathy and Hydrocortisone

■ *Listen (English)*

■ *Listen (Hindi)*

Explanation: The patient presents with neurological symptoms (confusion, seizures) in the context of autoimmune thyroiditis . Normal blood counts and CRP, along with high TSH and low T4/T3, support Hashimoto's encephalopathy , which responds to corticosteroids . Myxedema coma (Options B and C) usually presents with hypotension, hypothermia, and more severe systemic compromise. Thyroid storm and NG tube Propylthiouracil

(Option D): Thyroid storm is a hyperthyroid emergency, not seen with high TSH and low T4/T3.

References:

Davidson’s Principle and Practice of Medicine, 24th Edition, Page 641

www.ncbi.nlm.nih.gov/books/NBK545193/

↑ *Back to this question in Part A*

@Neet_pg_bot

Q32: Most common cardiovascular finding in case of young female with Grave's disease is? (Q851051)

A. Sinus Tachycardia

B. Atrial fibrillation

C. Ejection systolic murmur

D. Widened pulse pressure

Correct Answer: A. Sinus Tachycardia

■ *Listen (English)*

■ *Listen (Hindi)*

Explanation: The increased sympathomimetic drive caused by an excess of thyroid hormones leads to sinus tachycardia as the most common feature. Atrial fibrillation is also seen, particularly in patients over 50 years of age, and resolves in more than 50% of cases when antithyroid medication is started. High cardiac output produces bounding pulses and widened pulse pressure , along with an aortic systolic murmur due to hyperdynamic circulation. This can worsen angina or heart failure in elderly patients.

References:

Harrison 21st edition, page 2939

Davidson’s Principle and Practice of Medicine, 24th Edition,Page 642

↑ *Back to this question in Part A*

@Neet_pg_bot

Q33: Which of the following is not correct about Grave's associated ophthalmopathy? (Q851052)

A. Occurs in the absence of hyperthyroidism in 10% of patients

B. Earliest manifestation is proptosis and diplopia

C. Can cause loss of vision and papilledema

D. Lid lag can occur in causes other than grave' disease

Correct Answer: B. Earliest manifestation is proptosis and diplopia

■ *Listen (English)*

■ *Listen (Hindi)*

Explanation: arliest manifestation is proptosis and diplopia: In Graves' ophthalmopathy (thyroid eye disease), the earliest and most common manifestation is lid retraction and lid lag, due to sympathetic overactivity and levator palpebrae involvement. Proptosis and diplopia occur later, as a result of orbital fibroblast activation, glycosaminoglycan deposition, and extraocular muscle enlargement. Hence, stating proptosis and diplopia as the earliest features is incorrect. Incorrect Options: Option A - Occurs in the absence of hyperthyroidism in 10% of patients: Graves' ophthalmopathy can occur in euthyroid or hypothyroid patients (euthyroid Graves' disease) in about 5–10% of cases. Option C - Can cause loss of vision and papilledema: Severe disease may lead to optic nerve compression, causing decreased vision, papilledema, or optic neuropathy. Option D - Lid lag can occur in causes other than Graves' disease: Lid lag is not specific to Graves' disease and may be seen in other causes of thyrotoxicosis and hyperadrenergic states.

References:

Harrison's Principles of Internal Medicine, 21st Edition, Volume I, Page 2938.

↑ *Back to this question in Part A*

@Neet_pg_bot

Q34: In a patient with suspected hyperthyroidism, what is the initial screening test to be considered? (Q851053)

A. TSH and free T4

B. TSH and unbound T3

C. TSH and ultrasound neck

D. TSH and RAIU

Correct Answer: A. TSH and free T4

■ *Listen (English)*

■ *Listen (Hindi)*

Explanation: TSH and free T4 are the initial screening tests for suspected hyperthyroidism. Suppressed TSH with elevated free T4 confirms the diagnosis, guiding further evaluation. TSH and unbound T3 (Option B) is not routinely used for initial screening, as T3 may be normal in early hyperthyroidism. TSH and ultrasound neck (Option C) is used later to assess nodules or structural abnormalities, not for initial screening. TSH and RAIU (Option D) is used to differentiate causes of hyperthyroidism, not for first-line screening.

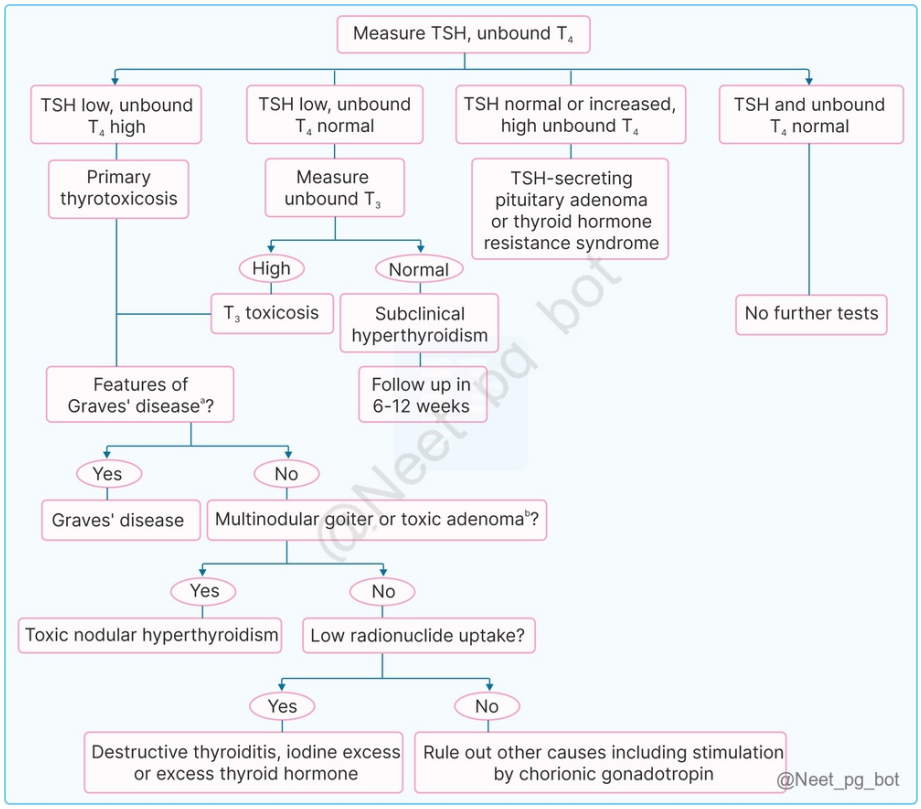

References:

Davidson’s Principle and Practice of Medicine, 24th Edition, Page 640, 641

↑ *Back to this question in Part A*

@Neet_pg_bot

Q35: A 68-year-old man with ischemic cardiomyopathy has been on amiodarone for 1 year. Routine screening reveals: TSH: 9.4 mIU/L (↑) Free T4: Low-normal Free T3: Normal He has no neck pain or thyroid tenderness. Which of the following thyroid disorders is least likely to be related to amiodarone therapy? (Q884019)

A. Failure to escape from the Wolff-Chaikoff effect

B. Iodine-induced hyperthyroidism due to autonomous nodules

C. Destructive thyroiditis-like thyrotoxicosis

D. Painless autoimmune thyroiditis (silent/postpartum)

Correct Answer: D. Painless autoimmune thyroiditis (silent/postpartum)

Explanation: Amiodarone, a type III antiarrhythmic agent, is structurally related to thyroid hormone and contains 39% iodine by weight. Thus, typical doses of amiodarone (200 mg/d) are associated with very high iodine intake, leading to greater than 40-fold increases in plasma and urinary iodine levels. Amiodarone has the following effects on thyroid function: Acute, transient suppression of thyroid function; Inhibition of T4 to T3 conversion causing either a euthyroid hyperthyroxinemia or increased dosage requirement in LT4-treated hypothyroid patients. Hypothyroidism in patients susceptible to the inhibitory effects of a high iodine load (Wolff-Chaikoff effect) (Option A) Thyrotoxicosis that may be caused by either a Jod-Basedow effect (Option B) from the iodine load, in the setting of MNG or incipient Graves' disease (Type 1 Amiodarone-induced Thyrotoxicosis (AIT)) , or a thyroiditis-like condition due to a toxic effect on thyroid follicular cells (Option C) (Type 2 Amiodarone-induced Thyrotoxicosis (AIT)). Painless autoimmune (Hashimoto-type) thyroiditis is an autoimmune thyroid disease and is not caused by amiodarone. Typically, patients have a brief phase of thyrotoxicosis lasting 2-4 weeks, followed by hypothyroidism for 4-12 weeks, and then resolution; often, however, only one phase is apparent The condition can occur in up to 5% of women 3-6 months after pregnancy and is then termed postpartum thyroiditis , and is usually associated with the presence of TPO antibodies in antepartum.

References:

Harrison's Principles of Internal Medicine, 22nd Edition, Page 3039, 3040.

↑ *Back to this question in Part A*

@Neet_pg_bot

Q36: A 61-year-old man with long-standing multinodular goitre has been on amiodarone for ventricular arrhythmia for the past 9 months. He presents with palpitations, weight loss and tremors. Thyroid function tests show suppressed TSH with elevated free T4 and T3. Colour Doppler ultrasound of the thyroid shows markedly increased vascularity. Which of the following statements is correct regarding his condition? (Q884020)

A. Thyrotoxicosis is due to drug-induced lysosomal destruction of thyroid follicles

B. Radioiodine uptake is typically very low due to follicular cell destruction

C. It results from iodine-induced autonomous hormone synthesis

D. First-line therapy is systemic glucocorticoids

Correct Answer: C. It results from iodine-induced autonomous hormone synthesis

Explanation: Type-1 Amiodarone-Induced Thyrotoxicosis (Type-1 AIT) occurs in patients with pre-existing thyroid disease such as multinodular goitre or latent Graves disease. The massive iodine load from amiodarone triggers the Jod-Basedow phenomenon , leading to excess autonomous thyroid hormone synthesis. It shows increased thyroid vascularity on colour Doppler. Feature Type-1 AIT Type-2 AIT Underlying thyroid disease Present Absent Mechanism Jod-Basedow hormone overproduction Lysosomal follicular destruction (Option A) Doppler flow Increased Decreased Primary treatment Thionamides ± perchlorate Glucocorticoids (Option D) Natural course Persistent May resolve spontaneously Low radioiodine uptake (Option B): Seen in Type-2 AIT because hormone excess is due to follicular destruction, not increased synthesis.

References:

Harrison’s Principles of Internal Medicine, 22nd Edition, Page 3039, 3040.

↑ *Back to this question in Part A*

@Neet_pg_bot

• [03_Endocrinology] 018 Disorders Of Parathyroid Gland And Men Syndromes

« Back to Folder Directory

[03_Endocrinology] 018 Disorders Of Parathyroid Gland And Men Syndromes — Quick Jump

Q1 (p. 1599)	*Q2 (p. 1600)*	*Q3 (p. 1600)*	*Q4 (p. 1603)*	*Q5 (p. 1603)*	*Q6 (p. 1604)*
Q7 (p. 1605)	*Q8 (p. 1605)*	*Q9 (p. 1606)*	*Q10 (p. 1609)*	*Q11 (p. 1610)*	*Q12 (p. 1612)*
Q13 (p. 1613)	*Q14 (p. 1614)*	*Q15 (p. 1614)*	*Q16 (p. 1615)*	*Q17 (p. 1616)*	*Q18 (p. 1617)*
Q19 (p. 1617)	*Q20 (p. 1618)*	*Q21 (p. 1619)*	*Q22 (p. 1620)*	*Q23 (p. 1621)*	*Q24 (p. 1622)*
Q25 (p. 1623)	*Q26 (p. 1624)*	*Q27 (p. 1624)*	*Q28 (p. 1625)*	*Q29 (p. 1626)*	*Q30 (p. 1627)*
Q31 (p. 1628)	*Q32 (p. 1629)*				

Q1: A 64 y/o man presents with 1 week of confusion, lethargy, constipation, and polydipsia. He also has unintentional weight loss. Examination shows cachexia. Laboratory investigations: Serum calcium: 16.8 mg/dL, Serum albumin: 3.8 g/dL, Serum phosphorus: 2.1 mg/dL If this patient had metabolic alkalosis and a history of consuming large quantities of over-the-counter heartburn relief tablets, which of the following would be the most likely diagnosis? (Q890423)

A. Primary hyperparathyroidism

B. Familial hypocalciuric hypercalcemia

C. Milk-alkali syndrome

D. Vitamin D intoxication

Correct Answer: C. Milk-alkali syndrome

Explanation: This patient has severe hypercalcemia with hypophosphatemia and metabolic alkalosis , along with a history of consuming large amounts of over-the-counter heartburn tablets (typically calcium carbonate). This is suggestive of milk-alkali syndrome. Milk-alkali syndrome (also known as calcium-alkali syndrome) is caused by the ingestion of large amounts of calcium and absorbable alkali (like calcium carbonate). Classic triad: Hypercalcemia Metabolic alkalosis Acute kidney injury Now, a common cause of hypercalcemic crisis is widespread OTC calcium use Hypercalcemic crisis is defined as severe hypercalcemia (usually >14 mg/dL) with neurologic dysfunction, dehydration, and acute kidney injury The major causes (from Harrison) include: Malignancy-associated hypercalcemia (PTHrP, osteolytic metastases) Primary hyperparathyroidism Milk-alkali syndrome Vitamin D-mediated causes (intoxication, granulomatous disease) High bone turnover states (immobilisation) Primary hyperparathyroidism (Option A): Causes hypercalcemia via ↑ PTH → bone resorption

& renal Ca reabsorption. Familial hypocalciuric hypercalcemia (Option B): Due to a CaSR mutation, produces mild, lifelong, asymptomatic hypercalcemia. Vitamin D intoxication (Option D) : Causes hypercalcemia via ↑ intestinal Ca absorption. Typically associated with hyperphosphatemia.

References:

Harrison's Principles of Internal Medicine, 22nd Edition, Pages 3282, 3283.

↑ *Back to this question in Part A*

@Neet_pg_bot

Q2: Which of the following interventions is the initial therapy for a patient with severe, acute symptomatic hypocalcemia with tetany, laryngeal spasm, and seizures? (Q890445)

A. Oral calcium carbonate

B. Intravenous calcium infusion

C. Subcutaneous teriparatide

D. Intravenous bisphosphonates

Correct Answer: B. Intravenous calcium infusion

Explanation: Severe, symptomatic hypocalcemia is a medical emergency requiring rapid restoration of serum calcium. IV calcium (calcium gluconate preferred): Provides immediate calcium availability Rapidly reverses neuromuscular irritability Stabilises cardiac and neuronal membranes Indications for IV calcium: Tetany Laryngospasm Seizures Prolonged QT interval Typical approach: Bolus followed by continuous infusion Cardiac monitoring recommended Complete treatment framework for hypocalcemia: Acute symptomatic → IV calcium gluconate Chronic or mild → Oral calcium supplementation Hypoparathyroidism → Oral calcium + calcitriol Vitamin D deficiency → Vitamin D replacement Refractory hypocalcemia → Always correct hypomagnesemia Goal of therapy: Relieve symptoms Maintain calcium in the low-normal range Avoid hypercalciuria Oral calcium carbonate (Option A): Too slow for acute, life-threatening symptoms. Subcutaneous Teriparatide (Option C) : Used in chronic hypoparathyroidism, not emergency rescue. Intravenous Bisphosphonates (Option D) : Lower calcium and worsen hypocalcemia.

References:

Harrison's Principles of Internal Medicine, 22nd Edition, Page 3279.

↑ *Back to this question in Part A*

@Neet_pg_bot

Q3: A physician taps the patient's face just anterior to the ear lobe, below the zygomatic arch. This produces the following characteristic finding. This physical sign is associated with which of the following electrolyte abnormalities? (Q890444)

A. Hypercalcemia

B. Hypocalcemia

C. Hypermagnesemia

D. Hypokalemia



Correct Answer: B. Hypocalcemia

Explanation: Tapping the face just anterior to the ear lobe below the zygomatic arch producing facial muscle twitching is Chvostek sign. This occurs due to increased neuromuscular excitability from low serum calcium levels, commonly seen in hypocalcemia (e.g., hypoparathyroidism). Hypocalcemia increases neuromuscular excitability, leading to facial muscle twitching when the facial nerve is stimulated (Chvostek sign) Chvostek sign: Elicited by tapping the facial nerve Indicates latent tetany Classic bedside sign of chronic hypocalcemia Pathophysiology: Low extracellular calcium lowers the threshold for neuronal depolarisation Results in involuntary muscle contractions Key signs & symptoms of hypocalcemia: Chvostek sign Trousseau sign Tetany and carpopedal spasm Perioral numbness and tingling Seizures in severe cases ECG: prolonged QT interval Hypercalcemia (Option A): Decreases neuromuscular excitability → weakness, not twitching. Hypermagnesemia (Option C) : Causes neuromuscular blockade and hyporeflexia. Hypokalemia (Option D) : Causes muscle weakness and U waves on ECG.



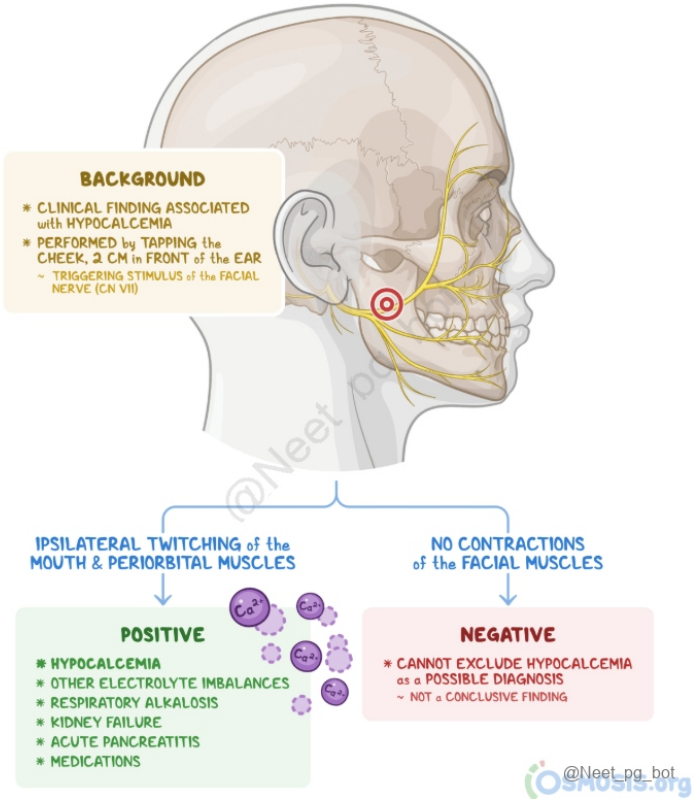

References:

Harrison’s Principles of Internal Medicine, 22nd Edition, Page 3286.

↑ *Back to this question in Part A*

@Neet_pg_bot

Q4: Which of the following ECG changes is characteristically associated with significant hypocalcemia? (Q890443)

A. Shortened QT interval

B. Prolonged QT interval

C. Prominent U waves

D. Peaked T waves

Correct Answer: B. Prolonged QT interval

Explanation: Hypocalcemia prolongs ventricular repolarisation, leading to ST-segment lengthening and a prolonged QT interval on ECG Pathophysiologic basis: Low serum calcium delays calcium-dependent phase 2 of the cardiac action potential Results in prolonged myocardial repolarisation ECG hallmark of hypocalcemia: Prolonged QT interval Opposite finding in hypercalcemia → shortened QT (Option A) Clinical features of hypocalcemia: Perioral numbness, tingling Tetany, carpopedal spasm Chvostek and Trousseau signs Seizures and arrhythmias in severe cases Common causes of hypocalcemia: Vitamin D deficiency (most common) Hypoparathyroidism Pseudohypoparathyroidism Chronic kidney disease Acute pancreatitis Hungry bone syndrome Prominent U waves (Option C): Prominent U waves are seen in hypokalemia. Peaked T waves (Option D) : Peaked T waves are characteristic of hyperkalemia.

References:

Harrison’s Principles of Internal Medicine, 22nd Edition, Pages 3285, 3286.

↑ *Back to this question in Part A*

@Neet_pg_bot

Q5: Which of the following is characteristic of a patient diagnosed with pseudopseudohypoparathyroidism (PPHP)? (Q890442)

A. Hypocalcemia, hyperphosphatemia, elevated PTH

B. Hypocalcemia, hypophosphatemia, elevated PTH

C. Hypercalcemia, hypophosphatemia, suppressed PTH

D. Normal calcium, normal phosphate, normal PTH

Correct Answer: D. Normal calcium, normal phosphate, normal PTH

Explanation: Pseudopseudohypoparathyroidism (PPHP) is defined by: Physical features of Albright hereditary osteodystrophy (AHO) Absence of parathyroid hormone resistance Biochemical hallmark of PPHP: Normal serum calcium (Option A, B, and C ruled out) Normal serum phosphate Normal PTH levels Pathophysiologic basis: Caused by paternal inheritance of a GNAS mutation PTH signalling in the kidney and bone is intact Therefore, no hypocalcemia or hyperphosphatemia Key contrast (high-yield): Maternal GNAS mutation → pseudohypoparathyroidism (PTH resistance) Paternal GNAS mutation → pseudopseudohypoparathyroidism (no resistance) Disorder AHO Ca PO■ PTH GNAS Inheritance PHP 1A Yes ↓ ↑ ↑ Maternal PHP 1B No ↓ ↑ ↑ Imprinting defect PHP 2 No ↓ ↑ ↑ Post-receptor PPHP Yes Normal Normal Normal Paternal PHP = Pseudohypoparathyroidism PPHP = Pseudopseudohypoparathyroidism

References:

Harrison's Principles of Internal Medicine, 22nd Edition, Pages 3288-3290.

↑ *Back to this question in Part A*

@Neet_pg_bot

Q6: Which of the following disorders is characterised by hypocalcemia with hyperphosphatemia in the absence of renal failure? (Q890440)

A. Vitamin D deficiency

B. Pseudohypoparathyroidism

C. Hungry bone syndrome

D. Malabsorption syndrome

Correct Answer: B. Pseudohypoparathyroidism

Explanation: Hypocalcemia with hyperphosphatemia indicates absent or ineffective PTH action In the absence of renal failure, this biochemical pattern most strongly points to: Hypoparathyroidism Pseudohypoparathyroidism (PTH resistance) Pseudohypoparathyroidism (PHP): Characterised by end-organ resistance to PTH PTH levels are elevated, but the kidneys fail to respond Results in: ↓ Renal calcium reabsorption and ↓ 1,25-(OH)■D production → hypocalcemia ↓ Renal phosphate excretion → hyperphosphatemia Low calcium with high phosphate in the absence of renal failure almost invariably indicates hypoparathyroidism or PHP Key differential framework for hypocalcemia + hyperphosphatemia: Low PTH → hypoparathyroidism High PTH with resistance → pseudohypoparathyroidism Renal failure → phosphate retention. Vitamin D deficiency (Option A): Causes secondary hyperparathyroidism → phosphaturia, not hyperphosphatemia. Hungry bone syndrome (Option C): Causes hypocalcemia with low phosphate due to rapid skeletal uptake. Malabsorption syndrome (Option D) : Leads to vitamin D deficiency and secondary HPT → low/normal phosphate.

References:

Harrison’s Principles of Internal Medicine, 22nd Edition, Pages 3290, 3291.

↑ *Back to this question in Part A*

@Neet_pg_bot

Q7: A 68 y/o woman with chronic kidney disease presents with progressive confusion, lethargy, polyuria, and polydipsia. Examination shows severe dehydration. Laboratory results reveal: Serum calcium: 16.2 mg/dL, BUN: 52 mg/dL, Creatinine: 2.4 mg/dL. Which of the following is the most appropriate initial step in management? (Q890439)

A. Intravenous zoledronic acid

B. Intravenous hydration with normal saline

C. Intravenous furosemide

D. Subcutaneous calcitonin

Correct Answer: B. Intravenous hydration with normal saline

Explanation: This patient meets criteria for hypercalcemic crisis: Serum calcium >14 mg/dL Neurologic symptoms (confusion, obtundation) Acute kidney injury and profound dehydration The most appropriate initial step in management is IV hydration with normal saline Hypercalcemic crisis: Pathophysiologic basis of crisis: Hypercalcemia → nephrogenic diabetes insipidus Polyuria → volume depletion ↓ GFR → impaired renal calcium excretion → worsening hypercalcemia First and most critical step in management: Aggressive IV isotonic saline Restores intravascular volume Improves renal perfusion and GFR Enhances renal calcium clearance This step is mandatory regardless of aetiology (malignancy, PTH-mediated, vitamin D - mediated) Intravenous Zoledronic acid (Option A): Essential for malignancy-associated hypercalcemia, but onset is 24-48 hours. Intravenous furosemide (Option C): Only after adequate hydration; premature use worsens dehydration. Subcutaneous calcitonin (Option D) : Rapid but temporary effect; does not correct volume depletion.

References:

Harrison’s Principles of Internal Medicine, 22nd Edition, Page 3284, 3285.

↑ *Back to this question in Part A*

@Neet_pg_bot

Q8: Which of the following is the treatment of hypercalcemia caused by vitamin D intoxication, often leading to normalisation of serum calcium over several days? (Q890437)

A. Thiazide diuretics

B. Glucocorticoids

C. Lithium

D. Calcimimetics

Correct Answer: B. Glucocorticoids

Explanation: The treatment of hypercalcemia caused by vitamin D intoxication is with glucocorticoids. Vitamin D intoxication causes hypercalcemia primarily by: Increased intestinal calcium absorption Increased vitamin D - mediated bone resorption Glucocorticoids are specifically effective in this setting because they: Reduce intestinal calcium absorption Suppress vitamin D - dependent gene transcription Decrease in the conversion and action of active vitamin D metabolites Typical response: Serum calcium falls gradually over several days Commonly used agents include prednisone Core management principles for vitamin D - mediated hypercalcemia: Stop vitamin D and calcium intake IV isotonic saline for hydration Glucocorticoids as targeted therapy Bisphosphonates if hypercalcemia is severe or persistent Thiazide diuretics (Option A): Increase renal calcium reabsorption and worsen hypercalcemia. Lithium (Option C): Raises the PTH set-point and can cause hypercalcemia. Calcimimetics (Option D) : Used in PTH-mediated hypercalcemia, not vitamin D toxicity.

References:

Harrison’s Principles of Internal Medicine, 22nd Edition, Page 3281.

↑ *Back to this question in Part A*

@Neet_pg_bot

Q9: The hand X-ray shown is most characteristic of which condition? (Q890435)

A. Rheumatoid arthritis

B. Acromegaly

C. Hyperparathyroidism

D. Osteoarthritis



Correct Answer: B. Acromegaly

Explanation: The image given shows widening, flattening, and tufting of distal phalanges referred to as "Spade phalanx sign". This is seen in Acromegaly. It results from: Chronic excess growth hormone (GH) GH → ↑ IGF-1 → periosteal bone formation This produces: Enlargement of terminal phalanges Characteristic spade-shaped appearance on X-ray It is a classic and high-yield radiologic feature of acromegaly Often associated with other imaging findings: Enlarged sella turcica Increased heel-pad thickness Rheumatoid arthritis (Option A): Causes marginal erosions and joint space narrowing. Hyperparathyroidism (Option C): Causes subperiosteal bone resorption, not widening. Osteoarthritis (Option D) : Shows osteophytes and cartilage loss, not tufting.

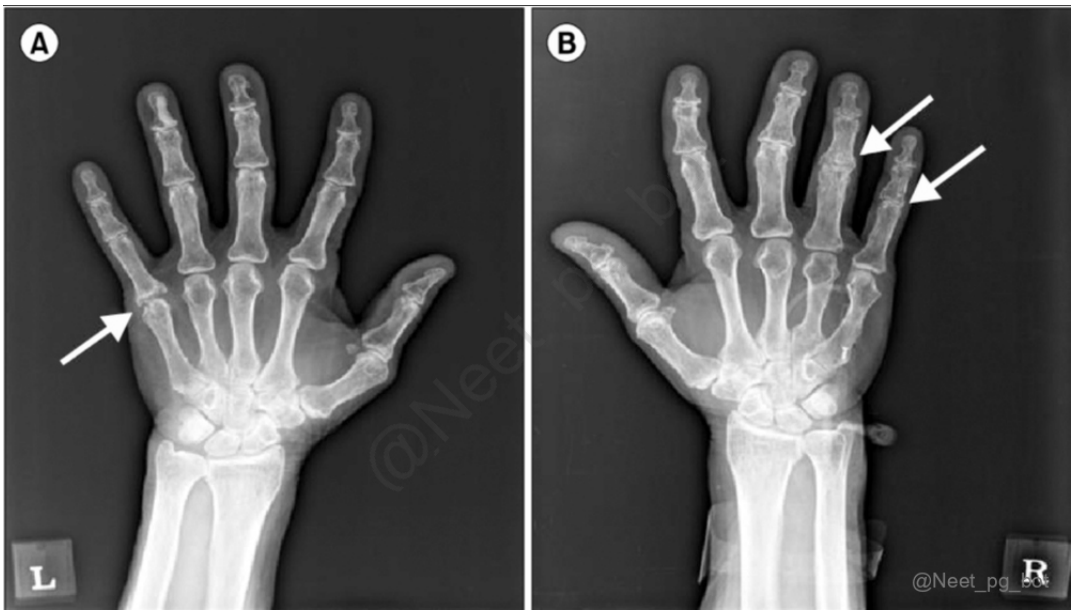
A
B
L
R
@Neet_pg_bot

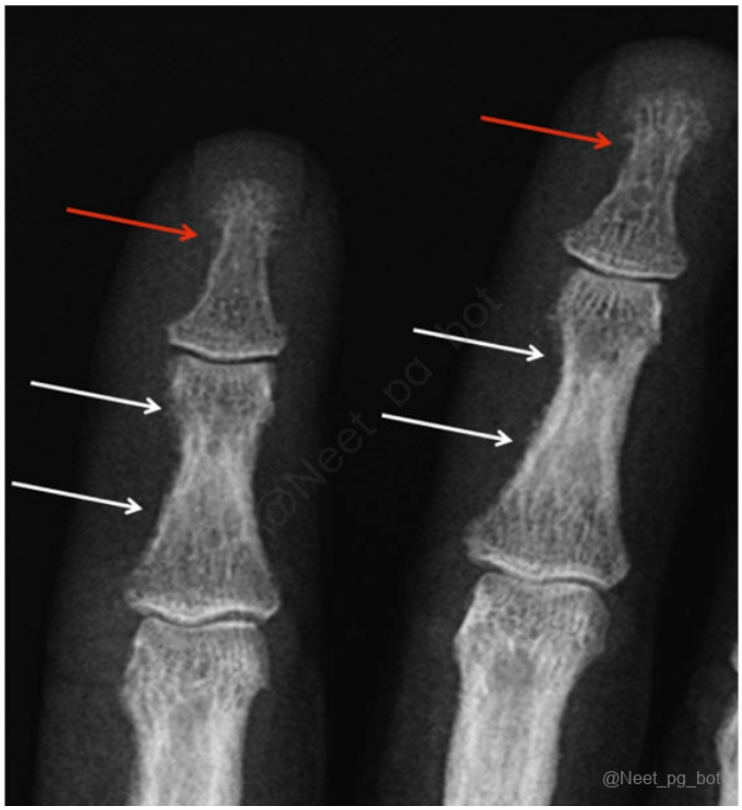
@Neet_pg_bot



References:

Harrison's Principles of Internal Medicine, 22nd Edition, Page 2966.

↑ *Back to this question in Part A*

@Neet_pg_bot

Q10: A 65 y/o man with untreated primary hyperparathyroidism presents with severe pain in his right thigh. An X-ray is as follows. Based on the described condition, which of the following histologic findings is most characteristic of this lesion? (Q890432)

A. Mosaic pattern of lamellar bone with cement lines

B. Replacement of marrow elements by fibrous tissue and giant multinucleated osteoclasts

C. Accumulation of unmineralized osteoid matrix

D. Malignant proliferation of plasma cells

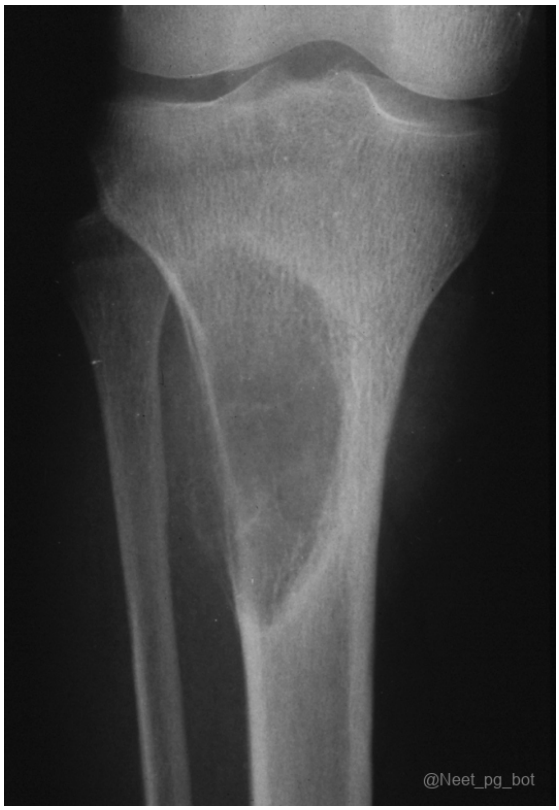

Correct Answer: B. Replacement of marrow elements by fibrous tissue and giant multinucleated osteoclasts

Explanation: In severe, untreated primary hyperparathyroidism , patients can develop “brown tumours” of bone. These are focal lytic lesions caused by excessive osteoclastic activity and fibroblastic proliferation. Osteitis fibrosa cystica is the classic skeletal manifestation of chronic, severe hyperparathyroidism Radiological features: Well-defined lytic lesions (“brown tumours”) Subperiosteal bone resorption Salt-and-pepper skull (in advanced disease) Pathophysiology: Excess PTH → marked osteoclastic activation Bone resorption exceeds formation Histologic hallmark: Giant multinucleated osteoclasts in Howship’s lacunae Replacement of normal marrow by fibrovascular tissue Brown tumours are reactive, non-neoplastic lesions, despite their aggressive radiographic appearance Mosaic pattern of lamellar bone with cement lines (Option A): Mosaic cement lines are characteristic of Paget disease of bone. Accumulation of unmineralized osteoid matrix (Option C): Unmineralized osteoid defines osteomalacia. Malignant proliferation of plasma cells (Option D) : Plasma cell proliferation suggests multiple myeloma.

References:

Harrison’s Principles of Internal Medicine, 22nd Edition, Pages 3277, 3278.

↑ *Back to this question in Part A*

@Neet_pg_bot

Q11: A patient presents with bone pain and an elevated alkaline phosphatase. A radiograph of the lumbar spine shows enlargement of a vertebral body with marked cortical thickening of the superior and inferior end plates, producing a "picture-frame" appearance. Which of the following is the most likely diagnosis? (Q890431)

A. Primary hyperparathyroidism

B. Paget's disease of bone

C. Fibrous dysplasia

D. Osteomalacia

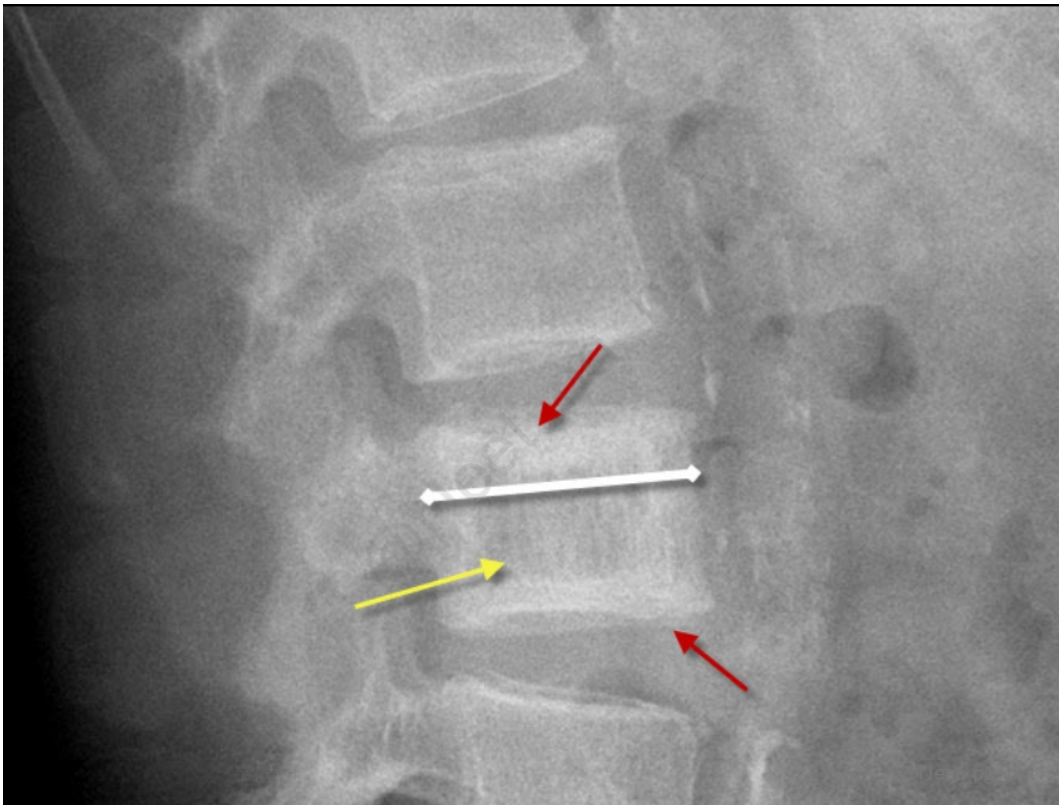

Correct Answer: B. Paget's disease of bone

Explanation: This patient presents with bone pain, elevated alkaline phosphatase , and radiographic changes of the spine showing an enlarged vertebral body with cortical thickening of the end plates , producing a "picture-frame" appearance . These findings are classic for Paget's disease of bone. Paget's disease of bone is characterised radiographically by: Cortical thickening and bony enlargement Sclerosis of vertebral margins Classic "picture-frame vertebra" This appearance must be distinguished from hyperparathyroidism-related spinal changes Rugger-jersey spine (hyperparathyroidism): Dense sclerosis of the superior and inferior vertebral endplates Relative central lucency Most commonly seen in secondary hyperparathyroidism due to chronic kidney disease Reflects high bone turnover from chronic PTH excess Key distinction: Paget's disease → enlarged vertebra +

picture-frame cortex Secondary HPT → band-like endplate sclerosis (rugger-jersey spine) Primary hyperparathyroidism (Option A): Causes osteopenia and subperiosteal bone resorption, not picture-frame sclerosis. Fibrous dysplasia (Option C): Produces expansile, radiolucent “ground-glass” lesions. Osteomalacia (Option D) : Shows osteopenia and Looser’s zones (pseudofractures).

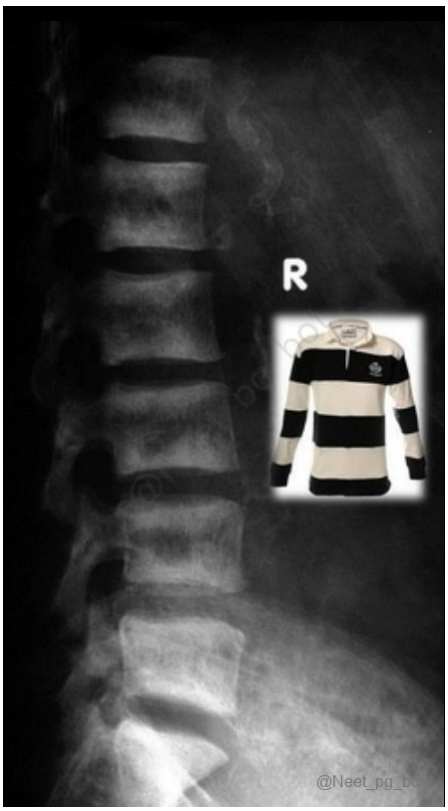

References:

Harrison’s Principles of Internal Medicine, 22nd Edition, Pages 3312-3314.

↑ *Back to this question in Part A*

@Neet_pg_bot

Q12: In differentiating Familial Hypocalciuric Hypercalcemia (FHH) from primary hyperparathyroidism, which of the following urinary biochemical findings most strongly supports a diagnosis of FHH? (Q890430)

A. 24-hour urinary calcium >300 mg

B. Calcium-to-creatinine clearance ratio (CCCR) >0.02

C. Calcium-to-creatinine clearance ratio (CCCR) <0.01

D. Frank hematuria

Correct Answer: C. Calcium-to-creatinine clearance ratio (CCCR) <0.01

Explanation: The calcium-to-creatinine clearance ratio (CCCR) is the most useful test to differentiate FHH from primary hyperparathyroidism (PHPT). Primary hyperparathyroidism (PHPT) is most commonly caused by: Solitary parathyroid adenoma (~80-85%) Parathyroid hyperplasia (~10-15%) Parathyroid carcinoma (<1%) A critical cause mimicking PHPT is Familial Hypocalciuric Hypercalcemia (FHH), which must be excluded before surgery FHH pathophysiology: Inactivating mutation of the calcium-sensing receptor (CaSR) The kidney perceives serum calcium as low Results in increased renal calcium reabsorption Key distinguishing biochemical feature: Low urinary calcium excretion CCCR <0.01 → FHH CCCR >0.02 → Primary hyperparathyroidism This distinction is essential because, PHPT is surgical FHH is benign and managed conservatively 24-hour urinary calcium >300 mg (Option A): Hypercalciuria favours primary hyperparathyroidism, not FHH. Calcium-to-creatinine clearance ratio (CCCR) >0.02 (Option B): CCCR >0.02 is typical of PHPT Frank hematuria (Option D) : Hematuria is not a diagnostic biochemical discriminator.

References:

Harrison's Principles of Internal Medicine, 22nd Edition, Pages 3279, 3280.

↑ *Back to this question in Part A*

@Neet_pg_bot

Q13: Which of the following biochemical patterns is most characteristic of primary hyperparathyroidism? (Q890429)

A. Low calcium, high phosphate, high PTH

B. High calcium, low phosphate, high PTH

C. High calcium, high phosphate, low PTH

D. Low calcium, low phosphate, low PTH

Correct Answer: B. High calcium, low phosphate, high PTH

Explanation: Primary hyperparathyroidism results from autonomous secretion of parathyroid hormone (PTH), most commonly due to a parathyroid adenoma Key biochemical effects of excess PTH: ↑ Serum calcium (Option A and D ruled out) Increased bone resorption Increased renal tubular calcium reabsorption ↓ Serum phosphate: PTH inhibits proximal tubular phosphate reabsorption → phosphaturia. (Option C ruled out) ↑ PTH levels despite hypercalcemia: Loss of normal calcium-mediated negative feedback. This biochemical triad (high Ca, low phosphate, high PTH) is the hallmark of primary hyperparathyroidism and distinguishes it from secondary and PTH-independent causes of hypercalcemia.

References:

Harrison’s Principles of Internal Medicine, 22nd Edition, Pages 3275, 3276.

↑ *Back to this question in Part A*

@Neet_pg_bot

Q14: Which of the following findings represents the most common underlying cause of primary hyperparathyroidism? (Q890428)

A. Parathyroid carcinoma

B. Diffuse hyperplasia of all four parathyroid glands

C. Solitary parathyroid adenoma

D. Multiple parathyroid adenomas

Correct Answer: C. Solitary parathyroid adenoma

Explanation: The most common cause of primary hyperparathyroidism is a solitary parathyroid adenoma , which autonomously secretes parathyroid hormone (PTH) , leading to hypercalcemia. Primary hyperparathyroidism results from autonomous overproduction of parathyroid hormone (PTH), leading to hypercalcemia The distribution of causes is: Solitary parathyroid adenoma → ~80-85% (most common) Parathyroid hyperplasia (all four glands) → ~10-15% Parathyroid carcinoma → <1% Solitary adenoma: Usually, a benign neoplasm of chief cells Produces unregulated PTH secretion Leads to classic biochemical findings: hypercalcemia, hypophosphatemia, increased bone resorption Parathyroid carcinoma (Option A): Hypercalcemia due to excess calcium intake + absorbable alkali, not bone turnover. Diffuse hyperplasia of all four parathyroid glands (Option B): Less common; classically associated with MEN 1. Multiple parathyroid adenomas (Option D) : Occur, but are far less frequent than a single adenoma.

References:

Harrison’s Principles of Internal Medicine, 22nd Edition, Pages 3275, 3276.

↑ *Back to this question in Part A*

@Neet_pg_bot

Q15: Which of the following conditions causes hypercalcemia primarily due to increased bone turnover, in which bone resorption exceeds bone formation? (Q890426)

A. Milk-alkali syndrome

B. Vitamin D intoxication

C. Hyperthyroidism

D. Sarcoidosis

Correct Answer: C. Hyperthyroidism

Explanation: Hypercalcemia results from increased calcium entry into the extracellular fluid, which can occur via: Increased bone resorption Increased intestinal calcium absorption Increased renal calcium reabsorption Hyperthyroidism causes hypercalcemia through: Thyroid hormone-mediated high bone turnover Bone resorption exceeds bone formation Occurs in up to 20% of hyperthyroid patients Resulting hypercalcemia is usually mild to moderate but reflects a bone-driven mechanism Common features of hypercalcemia across causes include: Neurologic: fatigue, lethargy, confusion Renal: polyuria, nephrogenic diabetes insipidus GI: constipation, nausea Musculoskeletal: proximal muscle weakness Cardiac: shortened QT interval Milk-alkali syndrome (Option A): Hypercalcemia due to excess calcium intake + absorbable alkali, not bone turnover. Vitamin D intoxication (Option B): Predominantly causes hypercalcemia via increased intestinal calcium absorption. Sarcoidosis (Option D) : Caused by unregulated extrarenal 1,25-(OH)■D production, increasing gut absorption.

References:

Harrison’s Principles of Internal Medicine, 22nd Edition, Pages 3274, 3275.

↑ *Back to this question in Part A*

@Neet_pg_bot

Q16: Which of the following gastrointestinal symptoms is most commonly associated with hypercalcemia? (Q890424)

A. Diarrhoea

B. Hyperactive bowel sounds

C. Constipation

D. Hematochezia

Correct Answer: C. Constipation

Explanation: The gastrointestinal symptom most commonly associated with hypercalcemia is constipation. Hypercalcemia causes depression of neuromuscular excitability by increasing the threshold for action potentials. This results in smooth muscle relaxation, particularly affecting the gastrointestinal tract System-wise clinical manifestations of hypercalcemia: System Clinical manifestation Gastrointestinal Constipation (most common) Anorexia Nausea and vomiting Abdominal pain Ileus in severe hypercalcemia Renal Polyuria and polydipsia Nephrogenic diabetes insipidus Dehydration → prerenal azotemia Nephrolithiasis Nephrocalcinosis (chronic cases) Neurologic / Psychiatric Fatigue Impaired concentration Confusion and lethargy Stupor and coma in severe

hypercalcemia Depression, apathy (“psychiatric overtones ”) Musculoskeletal Proximal muscle weakness Bone pain (if due to malignancy or hyperparathyroidism) Cardiovascular Shortened QT interval Arrhythmias in severe cases These findings are classically remembered as “stones, bones, groans, thrones, and psychiatric overtones.” Diarrhoea (Option A) and Hyperactive bowel sounds (Option B): Hypercalcemia causes decreased GI motility, not diarrhoea or hyperactive bowel sounds Hematochezia (Option D) : Hematochezia is unrelated to calcium homeostasis

References:

Harrison’s Principles of Internal Medicine, 22nd Edition, Pages 3274, 3275.

↑ *Back to this question in Part A*

@Neet_pg_bot

Q17: A 65-year-old patient presents with constipation, abdominal pain, nausea, vomiting, confusion, and bone pain. Laboratory tests reveal elevated calcium levels. Considering the role of the calcium-sensing receptor (CaSR) in calcium homeostasis, which of the following is regulated by CaSR? (Q850696)

A. PTH

B. FGF-23

C. Vitamin D3

D. Calcitonin

Correct Answer: A. PTH

Explanation: The parathyroid glands, located behind the thyroid, consist of four small glands that produce parathyroid hormone (PTH) , an 84-amino acid peptide. The calcium-sensing receptor (CaSR), a G-protein-coupled receptor (GPCR) regulates PTH secretion, which responds to changes in serum calcium levels. FGF-23 (Fibroblast growth factor 23) (Option B) is a phosphaturic hormone that suppresses parathyroid hormone (PTH). It regulates calcium and phosphate metabolism by reducing phosphate levels and increasing calcium levels in the blood, which can lead to nephrolithiasis. Vitamin D3 (Option C) promotes calcium absorption, bone mineralisation and tissue differentiation. Deficiency of this vitamin leads to hypocalcemia, rickets, and osteomalacia , while its excess can result in hypercalcemia. Calcitonin (Option D) is a peptide hormone secreted by the parafollicular C cells of the thyroid gland. It is a tumour marker in medullary thyroid carcinoma and can be used therapeutically for conditions such as osteoporosis and Paget’s disease of bone.

References:

Harrison’s Principles of Internal Medicine, 21st Edition, Volume I, Page 3169, 3170.

Davidson’s Principles and Practice of Medicine, 24th Edition, Page 661.

↑ *Back to this question in Part A*

@Neet_pg_bot

Q18: A 28-year-old woman presents with complaints of irregular menstrual cycles and infertility & reports increased headaches and visual changes over the past few months. An MRI reveals a large pituitary tumor. Family history is significant for several relatives with breast and thyroid cancers. Which syndrome is most likely associated with her condition? (Q850741)

A. McCune-Albright Syndrome

B. Von Hippel-Lindau (VHL) Disease

C. Cowden Syndrome

D. Carney Complex

Correct Answer: C. Cowden Syndrome

Explanation: The most likely diagnosis is Cowden Syndrome, characterized by a family history of breast and thyroid cancers and pituitary tumors. The patient's symptoms of irregular menstrual cycles, infertility, and the pituitary tumor on MRI are consistent with this syndrome. Cowden Syndrome: Cause: PTEN mutation (chr 10q23.31) Features: Multiple hamartomas (skin, mucosa, organs), ↑ risk of thyroid, breast, pituitary tumors Endocrine: Prolactin-secreting pituitary adenomas → irregular menses, infertility; requires monitoring McCune-Albright Syndrome (MAS) (Option A): GNAS1 mutation; polyostotic fibrous dysplasia, café-au-lait spots, precocious puberty Von Hippel-Lindau (VHL) Disease (Option B): VHL mutation (chr 3); hemangioblastomas, organ cysts, RCC, pheochromocytoma, possible pituitary tumors Carney Complex (CNC) (Option D): PRKAR1A mutation (chr 17q); myxomas, spotty pigmentation, endocrine tumors including GH-secreting pituitary adenomas → acromegaly

References:

Harrison’s Principles of Internal Medicine, 21st Edition, Page 2990, 2991, 2992

↑ *Back to this question in Part A*

@Neet_pg_bot

Q19: 40-year-old man presents with salt wasting, salt craving and postural hypotension. He has a family history of autoimmune disorders. Laboratory tests reveal elevated blood glucose levels and positive autoantibodies. Autoimmune

Polyendocrine Syndrome is suspected. Which of the following statements regarding the diagnosis is not true? (Q850736)

A. Associated with Addison disease

B. Associated with Autoimmune thyroiditis

C. Associated with Celiac disease

D. Associated with Hypoparathyroidism

Correct Answer: D. Associated with Hypoparathyroidism

Explanation: Presentation of diabetes mellitus and autoimmunity in a 40-year-old man is suggestive of Autoimmune polyendocrine syndrome type 2 . Hypoparathyroidism is a part of APS type 1. APS is a group of disorders characterized by the simultaneous occurrence of multiple autoimmune conditions affecting the endocrine system, which are also associated with non-endocrine conditions. Addison's disease (Option A), Autoimmune thyroiditis (Option B), and Celiac disease (Option C) are all associated with APS type 2

References:

Harrison’s principle of internal medicine, 22nd edition, Page 3089

↑ *Back to this question in Part A*

@Neet_pg_bot

Q20: A 35-year-old man presents with recurrent kidney stones, abdominal pain, and peptic ulcers. His blood pressure is elevated, and he has a family history of thyroid carcinoma. Laboratory tests reveal high serum calcium and parathyroid hormone levels. What is the most likely diagnosis? (Q850735)

A. MEN Type 1

B. MEN Type 4

C. MEN Type 2B

D. MEN Type 2A

Correct Answer: D. MEN Type 2A

Explanation: This patient features points toward multiple endocrine neoplasia type 2A (MEN2A) . Primary hyperparathyroidism → causes kidney stones and elevated calcium. Pheochromocytoma → explains hypertension . Medullary thyroid carcinoma → suggested by family history of thyroid cancer . MEN Type 1 (Option A)

involves the “3 Ps”: parathyroid, pancreatic endocrine tumors, and pituitary tumors , typically not associated with medullary thyroid carcinoma. MEN Type 4 (Option B) is rare, caused by CDKN1B mutations , and resembles MEN1 but usually without thyroid carcinoma. MEN Type 2B (Option C) Features medullary thyroid carcinoma, pheochromocytoma, mucosal neuromas, and Marfanoid habitus . Kidney stones and parathyroid hyperplasia are uncommon.

References:

Harrison’s principle of internal medicine, 21st edition, Page 2983 - 2990 Davidson’s Principles and Practice of Medicine, 24th Edition, Page 868, 869

↑ *Back to this question in Part A*

@Neet_pg_bot

Q21: A 3-year-old boy with growth delays and leg bowing has not improved after six months of vitamin D treatment. Labs show low calcium, low phosphate, and elevated alkaline phosphatase. Genetic testing indicates a Vitamin D gene mutation. What is the best management option? (Q850733)

A. Increase in vitamin D dosage

B. Initiate phosphate supplementation

C. Administer Calcium

D. Administer Calcitriol

Correct Answer: D. Administer Calcitriol

Explanation: The gene mutation of 25-hydroxyvitamin D 1α-hydroxylase (CYP27B1) enzyme, which helps in the conversion of inactive metabolites of Vitamin D to the active form (1,25 (OH) Vit D3), is called Type 1 Vitamin D dependent Rickets , and it is treated with supplementing the active form, Calcitriol. If rickets is resistant to treatment with vitamin D supplementation, it is most likely due to either type 1 or type 2 vitamin D-dependent rickets or hypophosphatemic rickets. An increase in vitamin D dosage (Option A) wouldn't help due to a defect in the enzyme needed to convert vitamin D into its active form in this type of rickets; therefore, it is managed by administering the active form directly. Initiate phosphate supplementation (Option B) alone does not correct the underlying defect. Administer Calcium (Option C) may help transiently but will not address the vitamin D activation deficiency.

References:

Harrison’s principle of internal medicine, 21st edition, Page 3168 Davidson’s Principles and Practice of Medicine, 24th Edition, Page 1052, 1053

↑ *Back to this question in Part A*

Q22: A 6-year-old boy presents with a history of recurrent fractures and pain in his lower limbs.He has a history of poor dietary intake, particularly low dairy consumption. Clinical examination leads to the findings similar to the images given below. Based on these observations, which of the following lab findings would be most consistent with his condition? (Q850731)

A. Low Parathyroid hormone, High Calcium

B. Low Calcium, High Phosphate

C. High Calcium, Low Phosphate

D. High Parathyroid hormone, Low Calcium

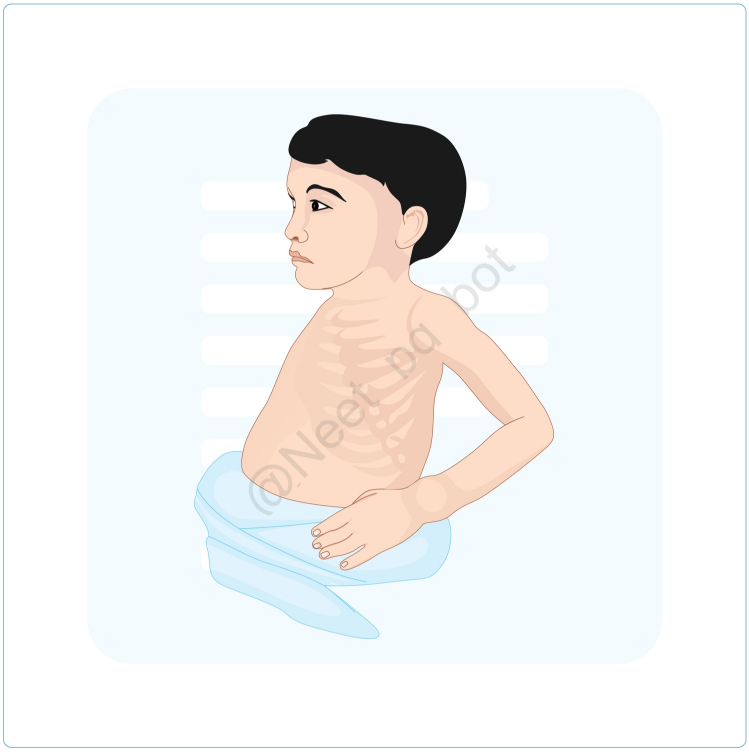

@Neet_pg_bot



Correct Answer: D. High Parathyroid hormone, Low Calcium

Explanation: The child appears to have nutritional rickets , which commonly results from vitamin D deficiency. This leads to secondary hyperparathyroidism (high PTH) . This condition is associated with low calcium and low phosphate levels (due to increased renal excretion), causing defective mineralisation of the bone matrix at the growth plate in children before the fusion of epiphysis. Low Parathyroid hormone, High Calcium (Option A) is not consistent, as PTH would rise in low calcium states. Low Calcium, High Phosphate (Option B) is seen in hypoparathyroidism, not nutritional rickets. High Calcium, Low Phosphate (Option C) occurs in primary hyperparathyroidism, not in dietary deficiency-induced rickets.

References:

Harrison’s principle of internal medicine, 21st edition, Page 3168 Davidson’s Principles and Practice of Medicine, 24th Edition, Page 1051, 1052

↑ *Back to this question in Part A*

@Neet_pg_bot

Q23: A 65-year-old woman with a history of chronic kidney disease secondary to hypertension presents with symptoms of nausea, vomiting, and confusion. On Investigating her Lab values are Serum calcium: 12.0 mg/dL (normal range: 8.5-10.5 mg/dL) Serum phosphate: 4.9 mg/dL (normal range: 2.5-4.5 mg/dL) Serum PTH: 200

pg/mL (normal range: 10-65 pg/mL) Which of the following is the most likely diagnosis of this patient? (Q850729)

A. Primary Hyperparathyroidism

B. Secondary Hyperparathyroidism

C. Pseudohypoparathyroidism

D. Tertiary Hyperparathyroidism

Correct Answer: D. Tertiary Hyperparathyroidism

Explanation: Tertiary hyperparathyroidism occurs in chronic kidney disease after prolonged secondary hyperparathyroidism, leading to autonomous PTH secretion and hypercalcemia despite persistent kidney disease. {{caption_text}} Primary Hyperparathyroidism (Option A) usually presents with elevated calcium and PTH but without underlying CKD. Secondary Hyperparathyroidism (Option B) presents with low or normal calcium and high PTH due to CKD, not hypercalcemia. Pseudohypoparathyroidism (Option C) presents with hypocalcemia and elevated PTH due to target organ resistance, not hypercalcemia.

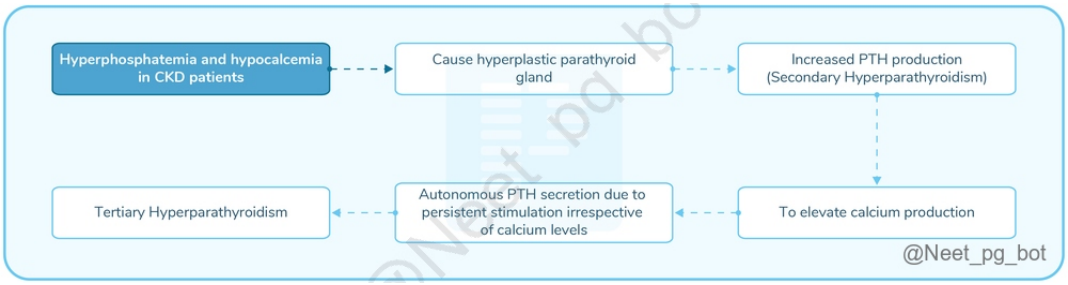

References:

Harrison’s principle of internal medicine, 21st edition, Page 3188. Davidson’s Principles and Practice of Medicine, 24th Edition, Page 663, 664.

↑ *Back to this question in Part A*

@Neet_pg_bot

Q24: An 8-year-old boy presents with characteristic skeletal and developmental defects, such as short stature and shortened 4th and 5th metacarpals. Laboratory findings show elevated PTH levels, hypocalcemia, and hyperphosphatemia. Genetic testing reveals a deficiency in the Gsα subunit. Based on these findings, what is the most likely diagnosis? (Q850727)

A. Pseudopseudohypoparathyroidism (PPHP)

B. Pseudohypoparathyroidism type 1a (PHP1A)

C. Pseudohypoparathyroidism type 1b (PHP1B)

D. Hypoparathyroidism

Correct Answer: B. Pseudohypoparathyroidism type 1a (PHP1A)

Explanation: PHP1A : Albright hereditary osteodystrophy (AHO): short stature, shortened 4th/5th metacarpals Biochemistry: ↑ PTH, ↓ calcium, ↑ phosphate Mechanism: Renal resistance to PTH due to defective Gsα subunit This combination is classic for PHP1A . Pseudopseudohypoparathyroidism (PPHP) (Option A) shows skeletal features but normal calcium, phosphate, and PTH levels. Pseudohypoparathyroidism type 1b (PHP1B) (Option C) lacks skeletal deformities but has renal PTH resistance. Hypoparathyroidism (Option D) presents with low PTH, hypocalcemia, and hyperphosphatemia but no skeletal defects.

References:

Harrison’s principle of internal medicine, 21st edition, Page 3188

↑ *Back to this question in Part A*

@Neet_pg_bot

Q25: A 45-year-old adult patient presents with symptoms of chronic hypocalcemia. Which of the following features is associated with this condition? (Q850723)

A. Extrapyramidal symptoms like dystonia

B. Tissue deposition of calcium due to hyperphosphatemia

C. Skin infections such as candidiasis

D. All of the above

Correct Answer: D. All of the above

Explanation: Chronic hypocalcemia, especially due to hypoparathyroidism, leads to basal ganglia calcification causing extrapyramidal symptoms, soft tissue calcium deposition due to hyperphosphatemia, and chronic mucocutaneous candidiasis due to immune dysfunction. Chronic Hypocalcemia In chronic hypocalcemia, often associated with conditions like chronic kidney disease, hyperphosphatemia (Option B) can lead to ectopic calcifications in tissues. Extrapyramidal symptoms like dystonia (Option A) occurs due to basal ganglia calcifications Ocular cataract Abnormal dentition Autoimmune polyglandular syndrome Cutaneous candidiasis (Option C) Salt wasting Postural hypotension

References:

Harrison’s principle of internal medicine, 21st edition, Page 3186-3187

↑ *Back to this question in Part A*

@Neet_pg_bot

Q26: A 65-year-old woman with primary hyperparathyroidism presents with nausea, vomiting, confusion, and dehydration. She shows signs of hypovolemia and altered mental status. Labs reveal high serum calcium, low phosphate, and elevated PTH. What is the first line of treatment? (Q850720)

A. Intravenous Bisphosphonates

B. Aggressive hydration with normal saline

C. Peritoneal dialysis

D. Calcitonin nasal spray

Correct Answer: B. Aggressive hydration with normal saline

Explanation: The first-line treatment for severe hypercalcemia in primary hyperparathyroidism is aggressive intravenous hydration with normal saline to correct hypovolemia and promote renal calcium excretion. Intravenous bisphosphonates (Option A) are used after hydration to inhibit bone resorption. Peritoneal dialysis (Option C) is reserved for refractory hypercalcemia with renal failure. Calcitonin nasal spray (Option D) has a rapid but short-lived effect and is not first-line therapy.

References:

Harrison’s principle of internal medicine, 21st edition, Page 3182-3183

↑ *Back to this question in Part A*

@Neet_pg_bot

Q27: A 52-year-old man diagnosed with hypoparathyroidism six months ago after neck surgery presents with tingling in his hands and feet, muscle cramps, and fatigue. His lab results indicate low serum calcium, elevated phosphate, and severely low parathyroid hormone (PTH) levels. What is the most appropriate treatment for his condition? (Q850717)

A. Initiate intravenous calcium gluconate therapy

B. Administration of Alendronate

C. Administration of Teriparatide

D. Start oral calcium and Vitamin D supplement

Correct Answer: C. Administration of Teriparatide

Explanation: Teriparatide, a recombinant PTH analog, is the most appropriate treatment for chronic hypoparathyroidism when calcium and Vitamin D supplements fail to maintain normal calcium levels. It helps restore calcium-phosphate balance and mimics natural PTH action. Initiate intravenous calcium gluconate (Option A) is used for acute, symptomatic hypocalcemia. Administration of Alendronate (Option B) is used for osteoporosis, not hypoparathyroidism. Start oral calcium and Vitamin D supplement (Option D) is the initial therapy but may not suffice in refractory cases.

References:

Harrison’s principle of internal medicine, 21st edition, Page 3187

↑ *Back to this question in Part A*

@Neet_pg_bot

Q28: A 45-year-old woman undergoes total thyroidectomy for a large goiter. Two days post-surgery, investigations reveal low serum calcium and low parathyroid hormone (PTH) levels. During clinical examination, the following observation is made. What is this sign known as ? (Q850712)

A. Trousseau sign

B. Chvostek sign

C. Hoffman's sign

D. Brudzinski's sign



Correct Answer: B. Chvostek sign

Explanation: Chvostek's sign is a clinical sign of hypocalcemia, where tapping over the facial nerve (at the parotid gland) causes twitching of the facial muscles. This occurs due to the increased neuromuscular excitability caused by l ow calcium levels , commonly seen in hypoparathyroidism. Trousseau sign (Option A) is carpopedal spasm induced by inflating a BP cuff in hypocalcemia. Hoffman's sign (Option C) indicates corticospinal tract lesion, not hypocalcemia. Brudzinski's sign (Option D) is seen in meningitis, not in postoperative hypocalcemia.

References:

Harrison's principle of internal medicine, 21st edition, Page 358, 3185-3186

↑ *Back to this question in Part A*

@Neet_pg_bot

Q29: A 45-year-old woman presents to the emergency department with muscle cramps, tingling in her fingers, and a tight sensation around her mouth. She has a history of thyroid surgery for papillary carcinoma. Examination revealed increased neuromuscular excitability. Lab results show low PTH, low calcium, and elevated phosphate levels. Which syndrome is most likely associated with this presentation? (Q850707)

A. Cushing’s syndrome

B. McCune-Albright Syndrome

C. Turner syndrome

D. DiGeorge syndrome

Correct Answer: D. DiGeorge syndrome

Explanation: The condition described, characterized by neuromuscular excitability, low calcium, low PTH, and elevated phosphate levels, is diagnosed as Hypoparathyroidism , which can be associated with DiGeorge syndrome . DiGeorge Syndrome : Failure of development of the 3rd and 4th pharyngeal pouches Features - CATTCH-22 Deletion of chromosome 22q11 C ongenital heart disease A bnormal facial features - Low set ears and hypertelorism T hymus gland abnormalities or absence and T racheo-esopahgeal fistulas C left platelet/lip H ypoparathyroidism and H ypocalcemia Cushing’s syndrome (Option A) is characterised by excess cortisol, which leads to symptoms such as weight gain (moon facies), tiredness, muscle weakness, hypertension, mood swings, hirsutism, osteoporosis, and elevated blood sugar. It is not associated with hypocalcemia, low PTH, or neuromuscular excitability. McCune-Albright Syndrome (Option B) is a genetic disorder caused by an active mutation in a G protein (mosaic pattern). It involves bone abnormalities (fibrous dysplasia), skin pigmentation, and endocrine issues (e.g., precocious puberty). It does not typically affect the parathyroid glands or cause hypocalcemia. Turner syndrome (Option C) is a genetic disorder affecting females, characterised by a 45XO karyotype. It presents with short stature, a fish-like mouth, a high-arched palate, a webbed neck, a broad chest, and underdeveloped ovaries, leading to primary amenorrhea and infertility . It is not associated with parathyroid dysfunction or abnormal calcium and phosphate levels.

References:

Harrison’s Principles of Internal Medicine, 21st Edition, Volume I, Page 358, 3187, Davidson’s Principles and Practice of Medicine, 24th Edition, Page 664.

↑ *Back to this question in Part A*

@Neet_pg_bot

Q30: A 58-year-old man with chronic kidney disease (CKD) returns for a follow-up, reporting fatigue, bone pain, and muscle weakness. Examination reveals bone tenderness, and lab tests show elevated parathyroid hormone (PTH) levels. Which of the following findings is not typically associated with this condition? (Q850704)

A. Elevated serum calcium levels

B. Raised serum alkaline phosphatase levels

C. Elevated serum phosphate levels

D. Raised urinary albumin creatinine ratio

Correct Answer: A. Elevated serum calcium levels

Explanation: The patient has secondary hyperparathyroidism due to CKD . In CKD, the kidneys fail to excrete phosphate and cannot activate vitamin D adequately. This leads to: Hyperphosphatemia → phosphate binds calcium → ↓ serum calcium Reduced 1,25-(OH)■ vitamin D → ↓ intestinal calcium absorption Hypocalcemia → stimulates ↑ PTH (secondary hyperparathyroidism) High PTH → increased bone turnover → bone pain, tenderness, ↑ alkaline phosphatase Therefore, Serum calcium is low , not high. Raised serum alkaline phosphatase (Option B): Seen due to high bone turnover from elevated PTH → typical in secondary hyperparathyroidism. Elevated serum phosphate (Option C): CKD reduces phosphate excretion → hyperphosphatemia is expected. Raised urinary albumin creatinine ratio (Option D): Reflects ongoing kidney damage and is commonly elevated in CKD.

References:

Harrison's Principles of Internal Medicine, 21st Edition, Volume I, Page 2313, 2314,

Davidson's Principles and Practice of Medicine, 24th Edition, Page 663.

↑ *Back to this question in Part A*

@Neet_pg_bot

Q31: A 39-year-old woman presents with persistent constipation, abdominal pain, and intermittent lower back pain. She has a history of recurrent kidney stones and reports fatigue. Lab tests reveal elevated calcium and decreased phosphate levels. She has been advised to undergo a sestamibi Tc-99 scan. Which of the following is not an indication for surgery in this condition? (Q850700)

A. Nephrolithiasis

B. Renal impairment

C. Age >50 years

D. Osteoporosis

Correct Answer: C. Age >50 years

Explanation: The given scenario indicates Primary Hyperparathyroidism , where the treatment of choice is surgical excision of the tumor . Age <50 years is an indication for surgery. The treatment of choice for parathyroid adenoma is surgical excision. Indications for surgery: Age <50 years Nephrolithiasis (Option A) confirmed by imaging Elevated serum calcium level (documented) Osteoporosis (Option D) confirmed by DEXA scan (T-score < -2.5 S.D.) Renal impairment (Option B) (creatinine clearance <60 ml/min) Elevated urinary calcium levels (24 hours) Vertebral fracture confirmed by imaging

References:

Harrison’s Principles of Internal Medicine, 21st Edition, Volume I, Page 31776-3178. Davidson’s Principles and Practice of Medicine, 24th Edition, Page 663, 664.

↑ *Back to this question in Part A*

@Neet_pg_bot

Q32: A 60-year-old female presents with complaints of abdominal pain, constipation, and recent episodes of confusion and depression. Laboratory tests reveal elevated serum calcium and alkaline phosphatase (SAP) levels and decreased phosphate levels. Which of the following clinical features is not typically associated with this condition? (Q850698)

A. Recurrent nephrolithiasis

B. Osteitis fibrosa cystica

C. Tetany

D. Urinary tract infection

Correct Answer: C. Tetany

Explanation: The scenario of constipation, abdominal pain, elevated calcium levels, increased bone turnover (indicated by elevated alkaline phosphatase), and decreased phosphate levels suggests Primary Hyperparathyroidism , where tetany is not observed; instead, it is typically seen in hypoparathyroidism. Tetany is characterized by muscle spasms resulting from increased excitability of peripheral nerves due to serum calcium levels falling below 7 mg/dl, as seen in hypoparathyroidism. Recurrent nephrolithiasis (Option A) is common due to hypercalciuria. Osteitis fibrosa cystica (Option B) is a classic skeletal manifestation of hyperparathyroidism. Urinary tract infection (Option D) can occur secondary to nephrolithiasis and urinary stasis.

References:

Harrison’s Principles of Internal Medicine, 21st Edition, Volume I, Page 3175, 3176. Davidson’s Principles and Practice of Medicine, 24th Edition, Page 663.

↑ *Back to this question in Part A*

@Neet_pg_bot

• [03_Endocrinology] 019 Diseases Of Anterior Pituitary

« Back to Folder Directory

[03_Endocrinology] 019 Diseases Of Anterior Pituitary — Quick Jump

Q1 (p. 1630)	*Q2 (p. 1631)*	*Q3 (p. 1632)*	*Q4 (p. 1634)*	*Q5 (p. 1634)*	*Q6 (p. 1635)*
Q7 (p. 1636)	*Q8 (p. 1636)*	*Q9 (p. 1637)*	*Q10 (p. 1638)*	*Q11 (p. 1639)*	*Q12 (p. 1640)*
Q13 (p. 1641)	*Q14 (p. 1641)*	*Q15 (p. 1642)*	*Q16 (p. 1643)*	*Q17 (p. 1644)*	*Q18 (p. 1645)*
Q19 (p. 1646)	*Q20 (p. 1647)*	*Q21 (p. 1648)*	*Q22 (p. 1649)*	*Q23 (p. 1650)*	*Q24 (p. 1651)*
Q25 (p. 1652)	*Q26 (p. 1652)*	*Q27 (p. 1654)*	*Q28 (p. 1655)*	*Q29 (p. 1656)*	*Q30 (p. 1656)*

Q1: Which of the following is the sequence of hormonal supplementation in a patient of Panhypopituitarism (Q850924)

A. Glucocorticoids → Thyroid hormones → Growth hormone → Sex hormones

B. Glucocorticoid → thyroid hormone → Sex hormones → Growth hormone

C. Thyroid hormones → Sex hormones → Glucocorticoids → Growth hormone

D. Sex hormones → Growth hormone → Glucocorticoids → Thyroid hormones

Correct Answer: B. Glucocorticoid → thyroid hormone → Sex hormones → Growth hormone

Explanation: For panhypopituitarism, the sequence of hormone replacement therapy is Glucocorticoid → thyroid hormone → Sex hormones → Growth hormone Hormonal therapy for Panhypopituitarism Hormone deficient Hormone replacement ACTH Corticosteroid replacement should be started first to reduce the risk of triggering an adrenal crisis. Hydrocortisone 10-20 mg/day in divided doses Cortisone acetate 15-25 mg/day in divided doses Prednisolone 5 mg/day TSH Thyroid hormone replacement is then added for hypothyroidism L-thyroxine 0.0075 - 0.15 mg/day FSH/LH After thyroid hormone replacement - sex hormone replacement is initiated Males - testosterone Females - estrogen / progesterone / gonadotropins GH Adults - Somatotropin (0.1 - 1.25 mg SC QID) Children - Somatotropin (0.02 - 0.05 mg/kg/day) Vasopressin Intranasal desmopressin (5–20 g BID/day) Oral 300–600 µg QID

References:

Harrison’s Principles of Internal Medicine, 21st Edition, Page 2899

www.ncbi.nlm.nih.gov/books/NBK430885/

Hypopituitarism - StatPearls - NCBI Bookshelf

↑ *Back to this question in Part A*

@Neet_pg_bot

Q2: A 38-year-old woman with a known pituitary adenoma presents with a sudden onset of severe headache, vomiting and rapidly progressive visual loss. MRI brain suggests an acute haemorrhage within the pituitary gland. Which of the following conditions is not associated with increased risk of developing this emergency? (Q890236)

A. Acute hypovolemic shock

B. Sickle cell anaemia

C. Poorly controlled diabetes mellitus

D. Graves' disease

Correct Answer: D. Graves' disease

Explanation: The given clinical scenario of a middle-aged woman with an acute onset of symptoms, along with her imaging, points towards the diagnosis of pituitary apoplexy and Graves' disease (hyperthyroidism) is not associated with it. Pituitary apoplexy is a life-threatening endocrine emergency caused by acute haemorrhage or infarction of the pituitary gland, most commonly occurring in patients with pituitary adenomas. It is precipitated by conditions that cause vascular instability, infarction, or haemorrhage, including: Pituitary adenoma (spontaneous) Acute shock Diabetes mellitus Hypertension Sickle cell anaemia Sheehan syndrome

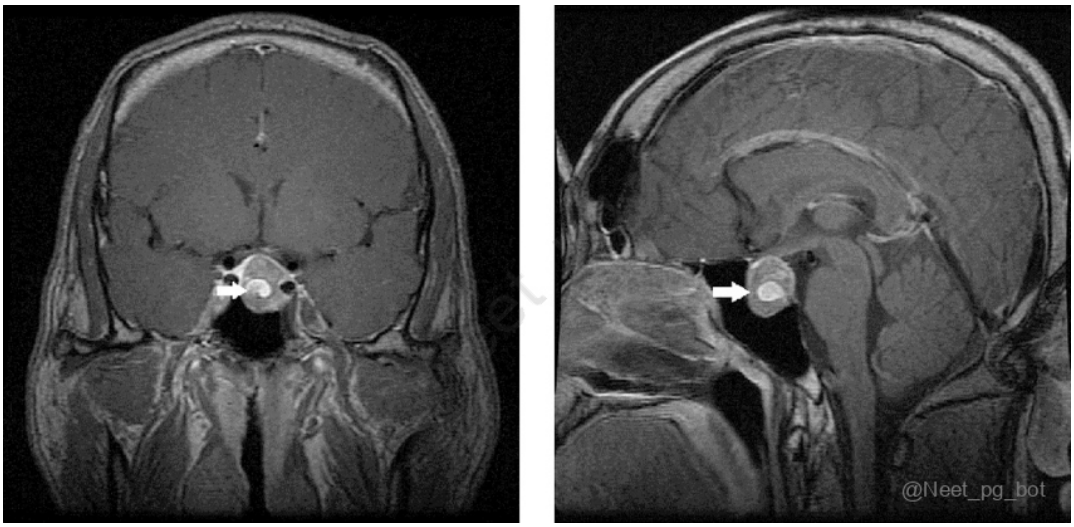

References:

Harrison's Principles of Internal Medicine, 22nd Edition, Page 2993.

↑ *Back to this question in Part A*

Q3: A 14-year-old boy presents with progressive headache, vomiting, declining school performance and polyuria. MRI brain reveals the following finding. Which of the following statements about this lesion is most accurate? (Q890235)

A. In the papillary variant, calcifications are commonly seen

B. In the adamantinomatous variant, calcifications are rare

C. Complete surgical excision is usually curative

D. Biopsy shows cholesterol crystals within the cyst

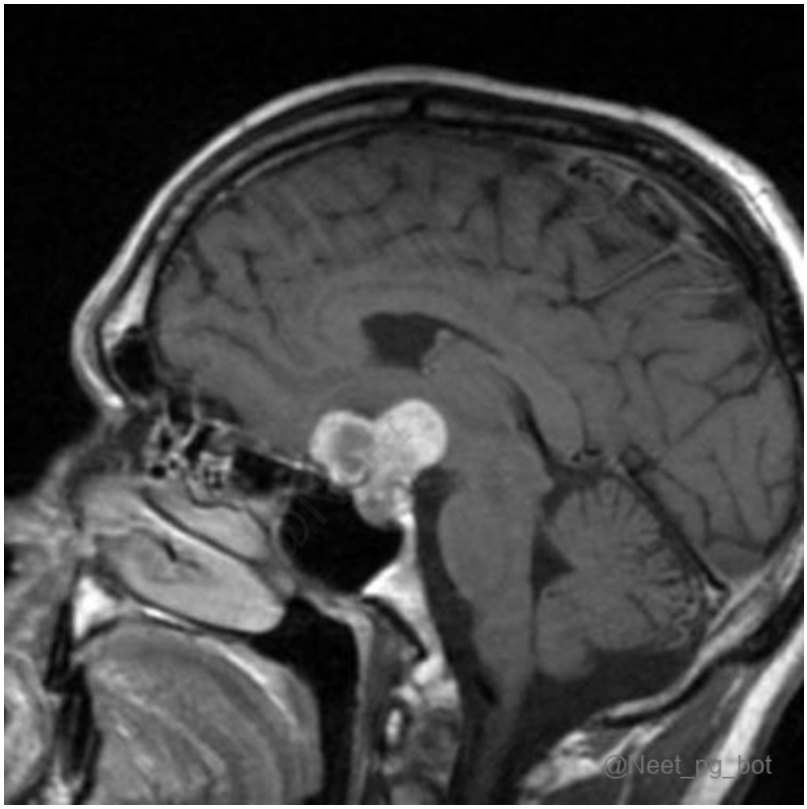

Correct Answer: D. Biopsy shows cholesterol crystals within the cyst

Explanation: Craniopharyngiomas are benign epithelial suprasellar tumors derived from Rathke's pouch remnants. They characteristically contain cholesterol-rich machine oil fluid, so a biopsy reveals cholesterol crystals within the cyst (Option D). Causes central diabetes insipidus, hypopituitarism, and bitemporal hemianopia. Bimodal age distribution (children & 50-65 yrs). They are locally adherent to surrounding hypothalamic and optic structures, so complete surgical excision is not curative in most patients and must be followed by post-operative radiotherapy to prevent recurrence. (Option C) Two pathological variants exist: Adamantinomatous (children) (Option B): cystic,

calcifications common , keratin nodules Papillary (adults) (Option A): solid, calcifications rare

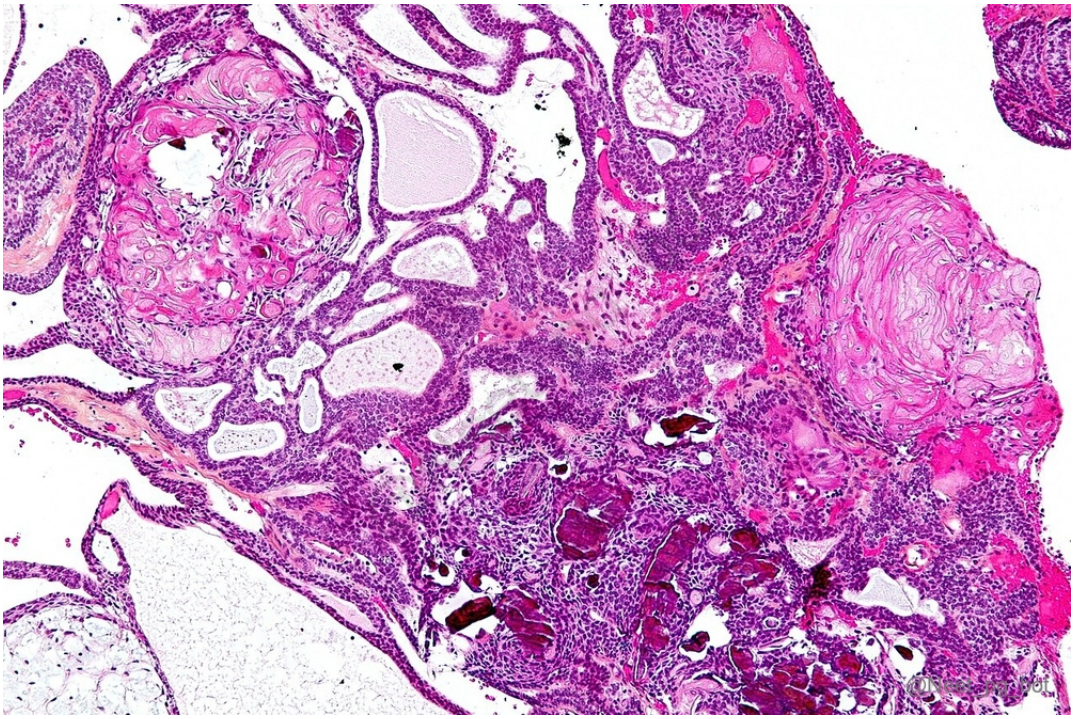

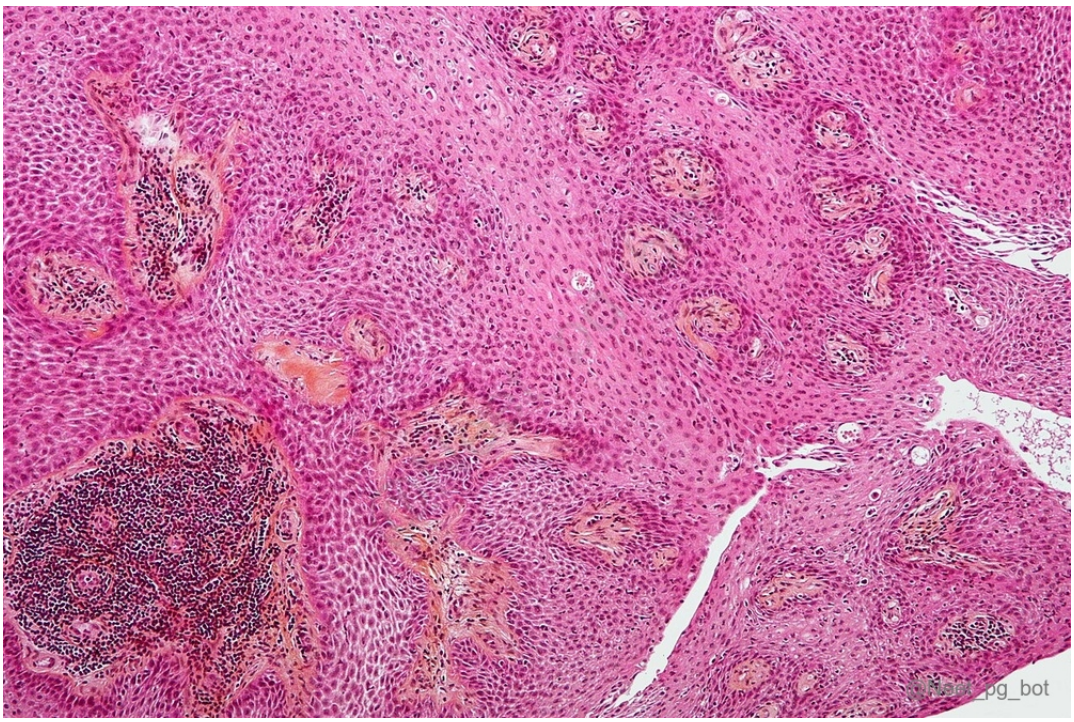

References:

Harrison’s Principles of Internal Medicine, 22nd Edition, Page 3002.

↑ *Back to this question in Part A*

@Neet_pg_bot

Q4: A 49-year-old man presents with gradually progressive lethargy, loss of appetite and intermittent vomiting for several months. He also reports excessive thirst and passing large volumes of urine. MRI brain shows a suprasellar mass with mixed cystic-solid components and areas of calcification. Which of the following is the most common initial clinical presentation of this condition? (Q890234)

A. Bitemporal hemianopia

B. Hypogonadotropic hypogonadism

C. Persistent headache

D. Central diabetes insipidus

Correct Answer: C. Persistent headache

Explanation: Craniopharyngiomas are benign suprasellar cystic tumors derived from Rathke's pouch remnants. They commonly cause early obstruction of CSF pathways and raised intracranial pressure, making headache the most common presenting symptom across both pediatric and adult age groups. Raised intracranial pressure also produces: Early-morning vomiting Papilledema Lethargy Hydrocephalus Craniopharyngiomas can present with: Headache - most common symptom Hypopituitarism - due to pituitary destruction Hypogonadotropic hypogonadism (Option B) - Results from pituitary stalk involvement and hypothalamic damage Central diabetes insipidus (Option D) - due to posterior pituitary involvement Bitemporal hemianopia (Option A) - due to optic chiasmal compression

References:

Harrison's Principles of Internal Medicine, 22nd Edition, Page 3002.

↑ *Back to this question in Part A*

@Neet_pg_bot

Q5: A 28-year-old man is diagnosed with a hereditary endocrine tumour syndrome and is being planned for surveillance imaging. In which of the following conditions is routine pituitary tumour screening not required? (Q890233)

A. MEN 1

B. MEN 4

C. Carney complex

D. MEN 2

Correct Answer: D. MEN 2

Explanation: MEN 2 is characterised by medullary thyroid carcinoma, pheochromocytoma, and hyperparathyroidism , but does not involve pituitary adenomas. Therefore, routine pituitary imaging and hormonal screening are not indicated in MEN 2. MEN 2 includes MEN-2A, MEN-2B (MEN-3), and familial medullary thyroid carcinoma variants - none of which involve pituitary tumours. The genetic syndromes associated with pituitary tumours include: MEN 1 (Option A): Caused by menin gene mutation; classically causes pituitary adenomas, pancreatic NETs, and parathyroid hyperplasia ("3 Ps"). MEN 4 (Option B): CDKN1B mutation syndrome; MEN-1-like disorder that includes pituitary adenomas . Carney complex (Option C): Associated with GH-secreting pituitary adenomas , leading to acromegaly, along with cardiac myxomas and skin pigmentation. McCune-Albright syndrome is another important genetic disorder associated with GH-secreting pituitary adenomas.

References:

Harrison's Principles of Internal Medicine, 22nd Edition, Pages 3004, 3080.

↑ *Back to this question in Part A*

@Neet_pg_bot

Q6: A 34-year-old woman presents with secondary amenorrhea and spontaneous galactorrhea for 6 months. She also complains of gradually worsening peripheral vision. MRI brain reveals a 16-mm pituitary lesion. Which of the following visual field defects is most likely in this patient? (Q890232)

A. Bitemporal superior quadrantanopia

B. Homonymous superior quadrantanopia

C. Central scotoma

D. Monocular temporal hemianopia

Correct Answer: A. Bitemporal superior quadrantanopia

Explanation: This patient has a pituitary macroprolactinoma causing early optic chiasmal compression. Pituitary macroadenomas (>10 mm) initially compress the ventral portion of the optic chiasm, which contains the inferior nasal retinal fibres. These fibres carry information from the superior temporal visual fields. Therefore, the earliest visual field defect is bitemporal (heteronymous) superior quadrantanopia. With further tumour growth, complete bitemporal hemianopia develops. Homonymous superior quadrantanopia (Option B): Occurs due to temporal lobe optic radiation lesions ("pie in the sky") , not chiasmal compression. Central scotoma (Option C): Seen in optic neuritis and macular disease . Monocular temporal hemianopia (Option D): Indicates pre-chiasmal optic nerve

compression , not chiasmal involvement.

References:

Harrison’s Principles of Internal Medicine, 22nd Edition, Page 222, 223.

↑ *Back to this question in Part A*

@Neet_pg_bot

Q7: A 55-year-old man presents with progressive fatigue and recent visual field defects. MRI shows a large sellar mass compressing the pituitary gland. Which of the following findings would be least likely to be present in this patient? (Q890231)

A. Increased adiponectin levels

B. Hypogonadotropic hypogonadism

C. Secondary hypothyroidism

D. Diffuse mucocutaneous hyperpigmentation

Correct Answer: D. Diffuse mucocutaneous hyperpigmentation

Explanation: The patient has a pituitary macroadenoma causing panhypopituitarism. Large pituitary macroadenomas destroy normal pituitary tissue, leading to panhypopituitarism: ↓ ACTH → Secondary adrenal insufficiency ↓ TSH → Secondary hypothyroidism (Option C) ↓ LH/FSH → Hypogonadotropic hypogonadism (Option B) ↓ GH → Growth failure and adult hyposomatotropism ↓ PRL→ Lactation failure Because ACTH levels are low, melanocyte-stimulating activity is reduced; therefore, mucocutaneous hyperpigmentation does not occur. Hyperpigmentation is seen only when ACTH is in excess (primary adrenal failure, ectopic ACTH). Cortisol deficiency also causes increased adiponectin → increased insulin sensitivity . (Option A)

References:

Harrison’s Principles of Internal Medicine, 22nd Edition, Page 3055.

↑ *Back to this question in Part A*

@Neet_pg_bot

Q8: A 28-year-old woman presents with oligomenorrhea and spontaneous galactorrhea. Serum prolactin is 78 ng/mL. MRI of the sellar region is planned. Which of the following lesion sizes would classify the pituitary tumour as a microadenoma? (Q890230)

A. < 5 mm

B. < 8 mm

C. < 10 mm

D. < 15 mm

Correct Answer: C. < 10 mm

Explanation: The patient has a prolactin-secreting pituitary adenoma (prolactinoma) with biochemical hyperprolactinemia. Pituitary adenomas are classified based on size: Microadenoma: < 10 mm Macroadenoma: ≥ 10 mm Pituitary adenomas may be detected incidentally on imaging or suspected in patients with features of hormone hypersecretion (e.g., galactorrhea, amenorrhea) or mass effect. MRI with contrast is the best investigation to detect pituitary tumours and assess suprasellar extension and optic chiasm involvement. In all patients with suspected pituitary adenoma, measurement of pituitary hormone levels is mandatory to evaluate both hypersecretion and hyposecretion syndromes. Microadenomas commonly cause endocrine symptoms, while macroadenomas commonly present with visual field defects and hypopituitarism.

References:

Harrison’s Principles of Internal Medicine, 22nd Edition, Page 3003.

↑ *Back to this question in Part A*

@Neet_pg_bot

Q9: A 46-year-old man presents with progressively worsening headache and difficulty seeing objects in the peripheral field of vision. MRI reveals a large sellar mass compressing the optic chiasm. Hormonal evaluation shows mildly elevated serum prolactin with low cortisol and low TSH levels. Which of the following cell types is the most likely origin of this tumour? (Q890229)

A. Lactotroph cells

B. Corticotroph cells

C. Gonadotroph cells

D. Thyrotroph cells

Correct Answer: C. Gonadotroph cells

Explanation: The patient has a non-functioning pituitary adenoma producing mass-effect manifestations and evolving hypopituitarism. Non-functioning pituitary adenomas do not produce clinically active hormone excess

and therefore typically present with mass-effect symptoms rather than endocrine syndromes. Nearly 80% of non-functioning pituitary adenomas arise from gonadotroph cells, making them the most common cell of origin. As these tumours enlarge, they produce: Headache and bitemporal hemianopia from optic chiasm compression Cranial nerve palsies causing diplopia and ptosis Mild hyperprolactinemia (stalk effect) due to loss of dopaminergic inhibition Progressive hypopituitarism in later stages from compression of normal pituitary tissue Lactotroph cells (Option A): Cause prolactinomas, which produce marked hyperprolactinemia with galactorrhea and amenorrhea. Corticotroph cells (Option B): Produce ACTH-secreting adenomas causing Cushing's disease. Thyrotroph cells (Option D): Produce TSH-secreting adenomas causing hyperthyroidism.

References:

Harrison’s Principles of Internal Medicine, 22nd Edition, Page 3013.

↑ *Back to this question in Part A*

@Neet_pg_bot

Q10: A 27-year-old woman presents with 6 months of amenorrhea, spontaneous galactorrhea and infertility. Serum prolactin is 120 ng/mL. Which of the following is the most appropriate next step in evaluation? (Q884050)

A. MRI of pituitary fossa

B. Serum free T4 and TSH levels

C. Serum LH and FSH levels

D. Start cabergoline therapy

Correct Answer: B. Serum free T4 and TSH levels

Explanation: The patient has hyperprolactinemia, causing hypogonadotropic hypogonadism. Primary hypothyroidism is a frequent, reversible cause of hyperprolactinemia. Primary hypothyroidism causes low circulating thyroid hormone, leading to elevated TRH. TRH directly stimulates pituitary lactotrophs, producing hyperprolactinemia, which suppresses GnRH → ↓ LH/FSH → amenorrhea, galactorrhea and infertility. Therefore, thyroid function testing must be done before pituitary imaging or dopamine-agonist therapy. Correction of hypothyroidism alone can normalise prolactin levels. Diagnostic algorithm of hyperprolactinemia. CKD = Chronic kidney disease; PRL = Prolactin; MPRL = Macroprolactin ; mPRL = Monomeric prolactin; HR: Hormonal replacement; DA = Dopamine agonists; RPCS = Progressive chiasmatic syndrome; PA = Pituitary apoplexy ; NFPA = Non-functioning pituitary adenoma; TSS = Transphenoidal surgery. MRI pituitary (Option A): Should be performed only after excluding reversible causes of hyperprolactinemia. LH & FSH (Option C): Will be suppressed, but do not identify the aetiology. Start cabergoline (Option D): May mask a reversible endocrine cause if started prematurely.

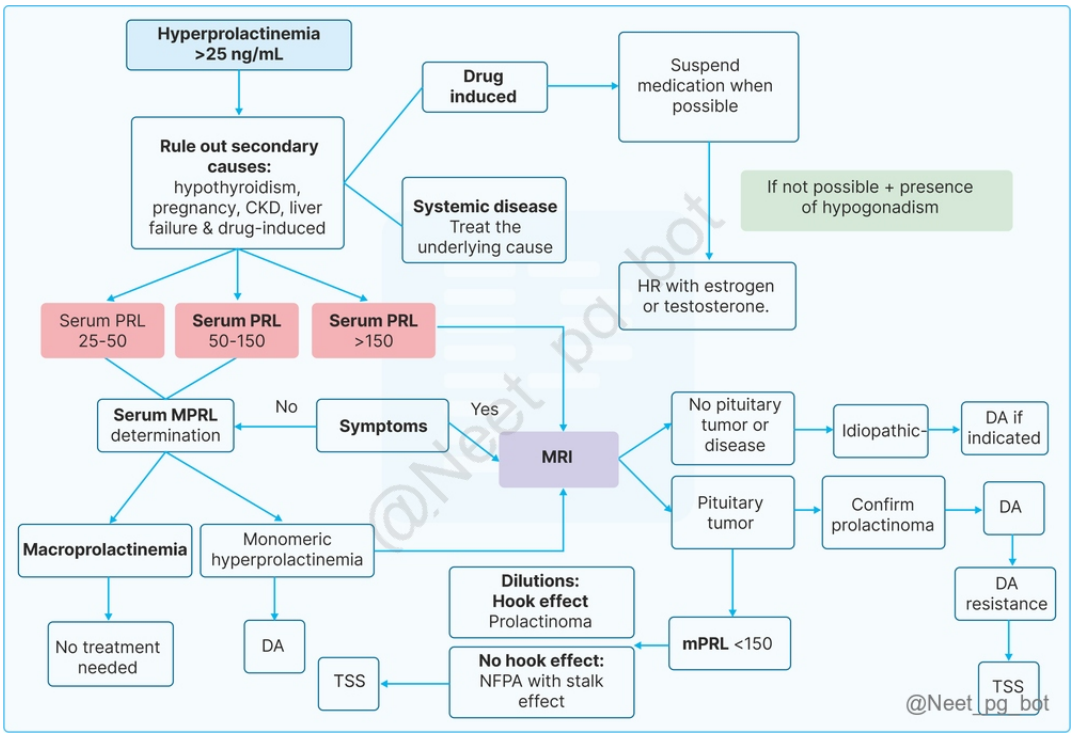

References:

Harrison's Principles of Internal Medicine, 22nd Edition, Page 3005.

↑ *Back to this question in Part A*

@Neet_pg_bot

Q11: A 29-year-old woman presents with secondary amenorrhea and milky nipple discharge for 6 months. She also reports an inability to conceive despite regular unprotected intercourse. Which of the following clinical features would be least likely to be part of her underlying disorder? (Q884049)

A. Galactorrhea

B. Infertility

C. Diminished libido

D. Visual field defect

Correct Answer: C. Diminished libido

Explanation: The patient is suffering from hyperprolactinemia, causing hypogonadotropic hypogonadism. Hyperprolactinemia suppresses pulsatile GnRH secretion, leading to decreased LH and FSH, producing:

Amenorrhea (secondary > primary) Galactorrhea (Option A): Due to prolactin-mediated milk secretion Infertility (Option B): Occurs due to suppression of gonadotropins and anovulation Visual field defects (Option D) due to optic chiasmal compression (in macroadenomas) Always rule out hypothyroidism (↑TRH → ↑PRL) and pregnancy before labelling idiopathic hyperprolactinemia. Diminished libido is not a typical presenting feature in women and is classically described in men with hyperprolactinemia.

References:

Harrison's Principles of Internal Medicine, 22nd Edition, Page 3004.

↑ *Back to this question in Part A*

@Neet_pg_bot

Q12: A 40-year-old man presents with progressive increase in ring and shoe size, coarse facial features, excessive sweating, arthralgia and new-onset diabetes mellitus. Serum IGF-1 is elevated, and growth hormone fails to suppress following an oral glucose tolerance test. MRI sella reveals a pituitary mass. What is the most common underlying aetiology of his condition? (Q884048)

A. Ectopic GHRH secretion from bronchial carcinoid

B. Pure somatotroph pituitary adenoma

C. Lactotroph adenoma with stalk effect

D. Hypothalamic hamartoma

Correct Answer: B. Pure somatotroph pituitary adenoma

Explanation: Acromegaly is caused by chronic excess growth hormone secretion after epiphyseal fusion, leading to elevated IGF-1 levels and progressive acral enlargement, arthropathy, hyperhidrosis and metabolic complications. In more than 95% of cases, acromegaly is pituitary in origin, and the most common cause is a pure somatotroph pituitary adenoma, making it the predominant etiology. Oral glucose suppression failure is diagnostic of acromegaly. Most patients present with macroadenomas. First-line treatment is transsphenoidal surgery. Causes of acromegaly are classified as: 1. Pituitary causes (~98%) Pure somatotroph adenoma - ~60% (most common) Mixed somatotroph-lactotroph adenoma Other plurihormonal pituitary tumours These are responsible for autonomous GH secretion and account for the vast majority of cases. 2. Extrapituitary causes (Rare) A. Ectopic GH-GH-secreting tumours Very rare Can be seen in neuroendocrine tumours B. Excess GHRH secretion Central: Hypothalamic hamartoma Peripheral: Bronchial carcinoid Pancreatic neuroendocrine (islet cell) tumours These cause secondary pituitary somatotroph hyperplasia rather than a discrete adenoma. Ectopic GHRH secretion (Option A): Causes secondary pituitary somatotroph hyperplasia; rare compared to pituitary adenoma. Lactotroph adenoma with stalk effect (Option C): May cause hyperprolactinemia but does not produce GH excess. Hypothalamic hamartoma (Option D): Can secrete GHRH, but is a very uncommon cause of acromegaly.

References:

Harrison’s Principles of Internal Medicine, 22nd Edition, Page 3008.

↑ *Back to this question in Part A*

@Neet_pg_bot

Q13: A 23-year-old woman undergoes dynamic pituitary testing. Following TRH administration, her serum growth hormone (GH) levels show a paradoxical rise. Which of the following clinical conditions is most likely to show this response? (Q884047)

A. Acromegaly

B. Simple protein-energy malnutrition

C. Cushing syndrome

D. Chronic kidney disease

Correct Answer: A. Acromegaly

Explanation: TRH physiologically stimulates TSH and prolactin secretion and does not stimulate GH. A rise in GH after TRH is abnormal and indicates pituitary or hypothalamic pathology with aberrant TRH receptor expression or dysregulated somatotroph control. In acromegaly, the somatotroph adenoma: Expresses ectopic TRH receptors Shows autonomous GH secretion Demonstrates abnormal pituitary receptor cross-reactivity This produces a classical paradoxical GH rise following TRH administration. Other conditions known to show paradoxical GH Rise after TRH: Prolactinoma/mixed GH-PRL adenoma: Aberrant lactotroph-somatotroph cross-talk Anorexia nervosa / chronic starvation: Central hypothalamic dysregulation Liver failure: ↓ IGF-1 feedback → ↑ GH with abnormal TRH sensitivity Simple protein-energy malnutrition (Option B): Peripheral nutritional deficiency without hypothalamic reprogramming does not cause paradoxical TRH-GH response. Cushing syndrome (Option C): Excess cortisol suppresses GH secretion. Chronic kidney disease (Option D): CKD produces GH resistance and altered clearance, but does not produce TRH-induced GH rise.

References:

https://pubmed.ncbi.nlm.nih.gov/2110409/

↑ *Back to this question in Part A*

@Neet_pg_bot

Q14: A 15-year-old boy receiving recombinant growth hormone therapy for constitutional short stature presents with progressive weight gain, facial puffiness and

new-onset impaired fasting glucose. Which of the following adverse effects is he least likely to develop due to growth hormone therapy? (Q884046)

A. Slipped capital femoral epiphysis

B. Tinnitus

C. Pseudotumor cerebri

D. Hypotension

Correct Answer: D. Hypotension

Explanation: Growth hormone is a potent counter-regulatory hormone to insulin and antagonises insulin action, leading to impaired glucose tolerance and hyperglycemia; hence, it is contraindicated in uncontrolled diabetes mellitus. GH also causes dose-related sodium, potassium and water retention, producing weight gain, oedema and hypertension. It stimulates linear bone growth and epiphyseal cartilage widening, predisposing to slipped capital femoral epiphysis (Option A), and increases intracranial pressure, causing headache and pseudotumor cerebri (Option C) . Other recognised adverse effects include: Tinnitus (Option B) , Carpal tunnel syndrome, Joint pains, Gynecomastia, Pituitary tumour regrowth, Progression of skin lesions, Acromegaloid changes.

References:

Harrison’s Principles of Internal Medicine, 22nd Edition, Page 2997.

↑ *Back to this question in Part A*

@Neet_pg_bot

Q15: A 4-year-old boy is brought in with proportionate short stature, frontal bossing and recurrent episodes of fasting hypoglycemia. His serum growth hormone levels are markedly elevated, but IGF-1 levels are very low. Which of the following is the most likely underlying abnormality? (Q884045)

A. Congenital GHRH deficiency

B. Inactivating mutation of the growth hormone receptor

C. Isolated pituitary somatotroph hypoplasia

D. Congenital absence of IGF-1 production

Correct Answer: B. Inactivating mutation of the growth hormone receptor

Explanation: Laron syndrome is an autosomal recessive disorder characterised by growth hormone receptor anomalies, resulting in failure of GH signalling despite elevated circulating GH levels. Because GH cannot act on its receptor, hepatic synthesis of IGF-1 is markedly reduced, leading to severe proportionate short stature, characteristic facies, and recurrent hypoglycemia (due to loss of GH's counter-regulatory effect on insulin). Treatment is by subcutaneous administration of recombinant IGF-1, not growth hormone, as GH therapy is ineffective in receptor-level resistance. GHRH deficiency (Option A): Causes secondary GH deficiency with low GH and low IGF-1, not elevated GH. Somatotroph hypoplasia (Option C): Produces primary pituitary GH deficiency , again associated with low GH levels , not GH resistance. Primary IGF-1 deficiency (Option D): Extremely rare; GH levels are not typically markedly elevated and the defect is post-receptor synthetic failure , not receptor insensitivity.

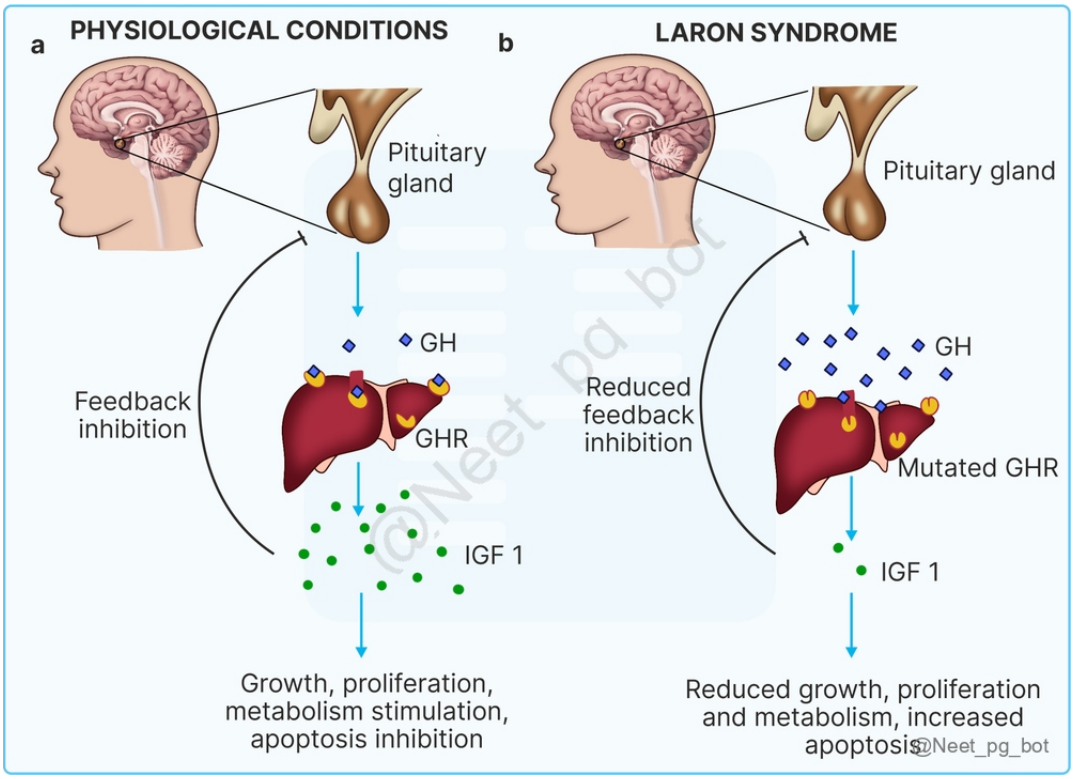

References:

Harrison's Principles of Internal Medicine, 22nd Edition, Page 2984, 2296.

↑ *Back to this question in Part A*

@Neet_pg_bot

Q16: A patient with acromegaly presents with large spade-like hands and impaired glucose tolerance. The pituitary MRI shows a somatotrope adenoma. Which of the following is the preferred medical therapy to shrink the tumor preoperatively? (Q850805)

A. Cabergoline

B. Lanreotide

C. Bromocriptine

D. Pegvisomant

Correct Answer: B. Lanreotide

■ *Listen (English)*

■ *Listen (Hindi)*

Explanation: Lanreotide , a long-acting somatostatin analog , is the preferred preoperative medical therapy for GH-secreting pituitary adenomas . It effectively reduces tumor size and controls GH/IGF-1 levels , improving acromegaly symptoms and metabolic complications like impaired glucose tolerance . Cabergoline (Option A) and Bromocriptine (Option C) are dopamine agonists . They are less effective in shrinking GH-secreting tumors and are usually reserved for mild cases or patients intolerant to somatostatin analogs. Pegvisomant (Option D) is a GH receptor antagonist that normalizes IGF-1 and improves metabolic complications but does not reduce tumor size , so it is not preferred preoperatively .

References:

Harrison’s Principles of Internal Medicine, 22nd Edition, Page 3009

↑ *Back to this question in Part A*

@Neet_pg_bot

Q17: Which of the following diseases is mismatched with its hormonal profile and management (Q850922)

A. Lymphocytic hypophysitis - variable deficiency in pituitary hormone Sheehan syndrome - treated with hormone replacement therapy Langerhans cell histiocytosis of pituitary - ADH deficiency present

B. Lymphocytic hypophysitis - Glucocorticoid to reduce inflammation Sheehan syndrome - Panhypopituitarism Langerhans cell histiocytosis of pituitary - surgical excision of the lesion

C. Lymphocytic hypophysitis - Glucocorticoid to reduce inflammation Sheehan syndrome - ADH deficiency present Langerhans cell histiocytosis of pituitary-thyroid hormone replacement is essential.

D. Lymphocytic hypophysitis - Surgical excision if vision is affected Sheehan syndrome - Thyroid hormone replacement after Corticosteroids are stabilized Langerhans cell histiocytosis of pituitary - Chemotherapy is systemic involvement present

Correct Answer: C. Lymphocytic hypophysitis - Glucocorticoid to reduce inflammation Sheehan syndrome - ADH deficiency present Langerhans cell histiocytosis of pituitary-thyroid hormone replacement is essential.

Explanation: Features Sheehan syndrome Lymphocytic hypophysitis LCH of pituitary Cause Occurs due to postpartum ischemic necrosis of the pituitary, commonly presenting with panhypopituitarism An autoimmune inflammation of the pituitary, causing variable hormone deficiencies Infiltration of the pituitary by Langerhans cells Hormone profile Panhypopituitarism, except for ADH Variable deficiencies : often low ACTH, TSH, LH, FSH, PRL, ADH deficiency presenting as central diabetes insipidus May have low or normal pituitary hormones depending on the degree of infiltration Treatment Hormone replacement Glucocorticoid replacement to manage adrenal insufficiency. Thyroid hormone replacement after corticosteroids are stabilized. Gonadal hormone replacement Corticosteroids to manage inflammation Hormone replacement as needed for any deficiencies. Surgery only if visual field compromise or other complications arise. Surgical resection of affected mass Chemotherapy may be needed if systemic involvement present Vinblastine Methotrexate-containing regimens Cytarabine

References:

Harrison’s Principles of Internal Medicine, 21st Edition, Pages 2897 and 2907

Sheehan Syndrome - StatPearls - NCBI Bookshelf

Lymphocytic Hypophysitis - StatPearls - NCBI Bookshelf

www.ncbi.nlm.nih.gov/books/NBK430885/

↑ *Back to this question in Part A*

@Neet_pg_bot

Q18: A 60-year-old male with a history of pituitary adenoma presents with sudden-onset severe headache, palpitations, excessive sweating, and hypotension. Lab results show severe hypoglycemia, and imaging reveals hemorrhage within the pituitary and deviation of the pituitary stalk. What is the initial management for this patient? (Q850921)

A. Urgent surgical decompression

B. High dose IV glucocorticoid

C. IV dextrose administration

D. Oral hydrocortisone

Correct Answer: B. High dose IV glucocorticoid

Explanation: Considering this patient’s history of pituitary adenoma and his current clinical presentation, he has most likely developed pituitary apoplexy. High-dose IV glucocorticoids are the first-line treatment that addresses adrenal insufficiency, stabilizes blood pressure, and corrects hypoglycemia. Pituitary apoplexy Management High-dose glucocorticoids is the first line of treatment to correct adrenal insufficiency, stabilize blood pressure, and correct hypoglycemia. Patients without evident visual loss or impaired consciousness can be managed conservatively with high-dose glucocorticoids. Urgent surgical decompression (Option A): Required for patients with significant or progressive visual loss, cranial nerve palsy, or loss of consciousness. Monitoring: Visual recovery is inversely correlated with the duration of time after the acute event, so timely intervention is crucial. IV dextrose administration (Option C) can temporarily address hypoglycemia but it does not address the underlying adrenal insufficiency which is a medical emergency. Oral hydrocortisone (Option D) is not preferred as this is an acute endocrine emergency, and oral corticosteroids are not fast acting thus only IV forms of corticosteroid are preferred.

References:

Harrison’s Principles of Internal Medicine, 21st Edition, Page 2897 and 2898

↑ *Back to this question in Part A*

@Neet_pg_bot

Q19: Match the following pituitary gland disorders with their respective serum hormone levels. Pituitary gland disorder Serum hormone levels 1. Hypopituitarism a) Severe ↓ ACTH and GH, other hormones maybe ↓ or normal 2. Sheehan syndrome b) GH, ACTH, TSH, LH, FSH, prolactin, ADH ↓ 3. Pituitary apoplexy c) GH, ACTH, TSH, LH, FSH normal or ↓; prolactin ↑ 4. Stalk effect d) GH, ACTH, TSH, LH, FSH, prolactin ↓ and ADH normal (Q850920)

A. 1-c, 2-b, 3-d, 4-a

B. 1-b, 2-d, 3-a , 4-c

C. 1-d, 2-a, 3-c, 4-b

D. 1-a, 2-c, 3-b, 4-d

Correct Answer: B. 1-b, 2-d, 3-a , 4-c

Explanation: Pituitary hormone levels in different pituitary gland disorders Hypopituitarism It occurs due to damage in the pituitary gland caused by tumors, surgery, trauma, or genetic conditions. GH, ACTH, TSH, LH, FSH, prolactin, ADH ↓ (deficiency varies based on which cells are affected). Sheehan syndrome Postpartum hypopituitarism caused by ischemic necrosis of the pituitary gland following severe blood loss during childbirth. GH, ACTH, TSH, LH, FSH, prolactin ↓ and ADH norma l Pituitary apoplexy A medical emergency involving sudden hemorrhage or infarction in the pituitary gland. Severe ↓ ACTH and GH, other hormones may be ↓ or normal Stalk effect Compression or disruption of the pituitary stalk causing a reduction in hypothalamic inhibition

of prolactin, resulting in elevated prolactin levels without other pituitary hormone abnormalities. GH, ACTH, TSH, LH, FSH normal or ↓, prolactin ↑

References:

Harrison's Principles of Internal Medicine, 21st Edition, Page 2898, 2906

Factors Influencing Disconnection Hyperprolactinemia and Reversal of Serum Prolactin after Pituitary Surgery in a Non-Functioning Pituitary Macroadenoma - PMC.

↑ *Back to this question in Part A*

@Neet_pg_bot

Q20: Which of the following is not true regarding the stalk effect of the pituitary? (Q850918)

A. Hyperprolactinemia occurs due to a hypersecreting macroadenoma

B. There is reduced secretion of dopamine in the pituitary stalk

C. Significant deficiencies in other pituitary hormones are not present

D. Prolactin level is usually less than 200 ng/ml

Correct Answer: A. Hyperprolactinemia occurs due to a hypersecreting macroadenoma

Explanation: Hyperprolactinemia in the stalk effect occurs due to compression of the pituitary stalk by a non-secreting pituitary macroadenoma and not due to a hypersecreting macroadenoma. Compression of the pituitary stalk results in reduced hypothalamic dopamine delivery to the pituitary due to stalk compression, which leads to unopposed prolactin secretion (Option B ruled out) A serum prolactin level below 200 ng/mL can be observed in cases with a "stalk effect". Serum prolactin level above 200 ng/mL typically indicates a prolactin-secreting macroadenoma. (Option D ruled out) Other pituitary hormones are usually normal initially , but large tumors may eventually cause hypopituitarism (Option C ruled out) Thus, the hormonal profile in the stalk effect GH, ACTH, TSH, LH, FSH normal or ↓ Prolactin ↑ but less than 200 ng/mL {{caption_text}}

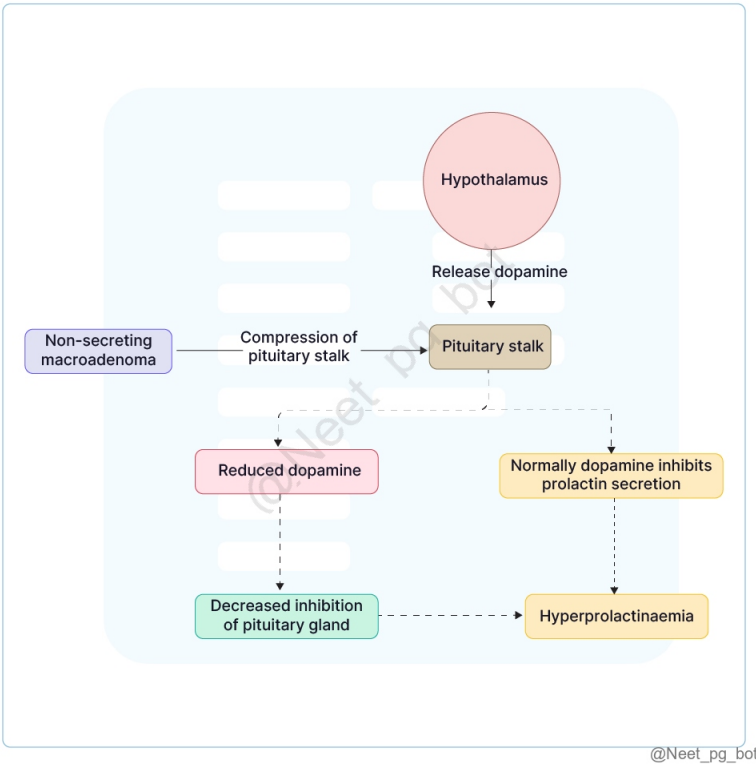

References:

Pituitary Adenoma - StatPearls - NCBI Bookshelf

Factors Influencing Disconnection Hyperprolactinemia and Reversal of Serum Prolactin after Pituitary Surgery in a Non-Functioning Pituitary Macroadenoma - PMC

↑ *Back to this question in Part A*

@Neet_pg_bot

Q21: A 32 year old nulliparous woman comes to the OB-GYN department for investigation of infertility. She also complains of occasional headaches and galactorrhoea. Lab tests and imaging lead to a diagnosis of prolactinoma. If we want to restore fertility in this patient, which of the following is the treatment of choice in this patient? (Q850917)

A. Cabergoline therapy till pregnancy is confirmed

B. Bromocriptine therapy till pregnancy is confirmed

C. Radiotherapy for mass reduction of tumor

D. Transsphenoidal resection of the mass

Correct Answer: B. Bromocriptine therapy till pregnancy is confirmed

Explanation: In order to restore fertility in this patient, Bromocriptine therapy can be used until pregnancy is confirmed Treatment of prolactinoma in pregnancy Desire for fertility DOC - Bromocriptine Bromocriptine therapy is initiated to restore fertility It is short-acting and has low teratogenic effects After pregnancy is confirmed - the drug is discontinued, and serial monitoring of prolactin levels Drug may be reintroduced if tumor growth is apparent Visual field defect If the tumor is very large and threatens the vision, surgical decompression may be done Cabergoline therapy (Option A), although it is the first line therapy for prolactinoma, is not preferred in those patients desiring fertility because it is long acting as it has a high affinity for D2-receptors. Radiotherapy for mass reduction of tumor (Option C) is reserved for aggressive tumors that do not respond to dopamine agonists or surgery; thus, it is not recommended for this patient.

References:

Harrison's Principles of Internal Medicine, 21st Edition, Pages 2911 and 2912

↑ *Back to this question in Part A*

@Neet_pg_bot

Q22: A 40-year-old man presents with erectile dysfunction and galactorrhea. Blood tests confirm elevated prolactin levels and an MRI reveals a macroadenoma. Which of the following management strategies is most appropriate for this patient? (Q850916)

A. Trans sphenoidal surgery

B. Start cabergoline

C. Observation & regular follow-up with MRI

D. Start Lanreotide

Correct Answer: B. Start cabergoline

■ *Listen (English)*

■ *Listen (Hindi)*

Explanation: For patients with macroadenomas and significant symptoms, initiation of dopamine agonist therapy (such as cabergoline or bromocriptine) is the first-line treatment to reduce prolactin levels and shrink the tumor. Lanreotide is used to shrink GH producing adenoma in case of acromegaly. Diagnosis of Prolactinoma: PRL levels > 200 µg/L most likely indicates prolactinoma PRL levels below 100 µg/L may indicate microadenomas MRI Head is recommended for all patients with hyperprolactinemia Shows suprasellar mass. Management: Asymptomatic microadenomas: No treatment if fertility is not desired. Regular monitoring and imaging are recommended. Symptomatic microadenomas: Use dopamine agonists, titrated for optimal PRL suppression. Normal PRL levels do not guarantee tumor shrinkage. Macroadenomas: Perform visual field testing before starting

dopamine agonists. Follow-up with MRI and visual field assessments every 6-12 months.

References:

Page 3004, Harrison’s Principles of Internal Medicine, 22 nd Edition,

↑ *Back to this question in Part A*

@Neet_pg_bot

Q23: A 28-year-old woman presents to her primary care physician with complaints of irregular menstrual cycles, galactorrhea, and difficulty conceiving. Laboratory tests reveal elevated serum prolactin levels. MRI of the patient is given below. Which of the following statements about the given condition is not true? (Q850915)

A. Female-to-Male ratio is approximately 20:1 for microadenomas

B. Men generally present with symptoms earlier than women

C. Macroadenoma may cause bitemporal hemianopia

D. Prolactin levels correlate with the size of the tumor



Correct Answer: B. Men generally present with symptoms earlier than women

Explanation: The given clinical scenario with elevated prolactin levels & MRI showing a mass in the sellar region suggests Prolactinoma , where men often present later with larger tumours due to less obvious signs of hormonal imbalance. Prolactin levels correlate with the size of the tumour (Option D ruled out) Classification of Tumors: Microadenomas : Tumors < 1 cm in diameter. Macroadenomas : Tumors greater than 1 cm in diameter & can be locally invasive and compress adjacent structures such as Optic Chaisma , resulting in Bitemporal Hemianopia) (Option C ruled out) Female-to-male ratio for micro prolactinomas is approximately 20:1 (Option A ruled out) For macroadenomas, the ratio is close to 1:1.

References:

Harrison's Principles of Internal Medicine, 21st Edition, Page 2908, 2909

Stress-Induced Hyperprolactinemia: Pathophysiology and Clinical Approach - PMC.

↑ *Back to this question in Part A*

@Neet_pg_bot

Q24: Which of the following is the most appropriate initial management for a patient with Sheehan syndrome? (Q850914)

A. Immediate thyroid hormone replacement

B. Hydrocortisone administration

C. Fludrocortisone administration

D. GH administration

Correct Answer: B. Hydrocortisone administration

Explanation: The clinical presentation, along with a history of PPH during delivery & low cortisol & thyroid hormone levels, suggests Sheehan Syndrome . The initial management for a patient with suspected Sheehan syndrome, particularly with evidence of adrenal insufficiency, is to start hydrocortisone to replace cortisol. Sheehan syndrome Management Hormone Replacement Therapies: Cortisol Replacement: Administer hydrocortisone (Initial treatment) if there is ACTH deficiency. Mineralocorticoid is not typically recommended. (Option C) Thyroid Hormone Replacement: Indication : Levothyroxine (50–150 μg) should be given once daily. Aim to maintain serum T4 in the upper range of normal. Thyroid hormone (Option A) should not be administered without glucocorticoid therapy in cases of adrenal insufficiency, as this can lead to an adrenal crisis. Sex Hormone Replacement: Recommended for women under 50 years with gonadotropin deficiency and for men to restore sexual function and prevent osteoporosis. Growth Hormone Replacement: Growth hormone (GH) is given via daily subcutaneous injections for children and adolescents with GH deficiency (Option D) Side Effects : The primary side effect is sodium retention, which may present as peripheral oedema or carpal tunnel syndrome GH replacement should start at a low dose, with regular monitoring of serum IGF-1 to assess response.

References:

Davidson’s Principles and Practice of Medicine, 24th Edition, Page 682 Speroff’s Clinical Gynecologic Endocrinology And Infertility, 9th Edition, Page 904

↑ *Back to this question in Part A*

@Neet_pg_bot

Q25: A 32-year-old woman experiences severe postpartum hemorrhage during delivery, requiring a blood transfusion. Two weeks later, she reports fatigue, weight loss and failure of lactation. Which of the following hormone replacement will not be required in this case? (Q850913)

A. Hydrocortisone

B. Melatonin

C. Thyroxine

D. Somatotropin

Correct Answer: B. Melatonin

■ *Listen (English)*

■ *Listen (Hindi)*

Explanation: The clinical presentation, along with a history of PPH during delivery, suggests sheehan syndrome. It refers to acute infarction and ischemic necrosis of the pituitary gland due to postpartum hemorrhage and subsequent hypovolemic hypotension. Melatonin is released from pineal gland and regulates circadian rhythm /sleep–wake cycle and does not need replacement in sheehan syndrome Lifelong hormone replacement is of 1. Glucocorticoids (Hydrocortisone / Prednisone) → always replace first to avoid adrenal crisis. 2. Levothyroxine (for secondary hypothyroidism) 3. Estrogen ± Progesterone (for women not desiring fertility) Or GnRH/gonadotropins if fertility desired. 4. Growth Hormone/ Somatotropin replacement may be considered in selected adults with hypopituitarism to improve metabolic function and quality of life, but is not required in all cases.

References:

Page 2996: Harrison 22nd edition

↑ *Back to this question in Part A*

@Neet_pg_bot

Q26: 45-year-old man presents with headaches, frequent change in shoe size and visual field defects. MRI head is shown below. IGF-1 is elevated and GH levels remain elevated on glucose challenge. Which of the following is the most appropriate management for this patient? (Q850912)

A. Initiate treatment with oral cabergoline

B. Start long-acting Octreotide

C. Perform transsphenoidal surgical resection

D. Initiate external beam radiation therapy

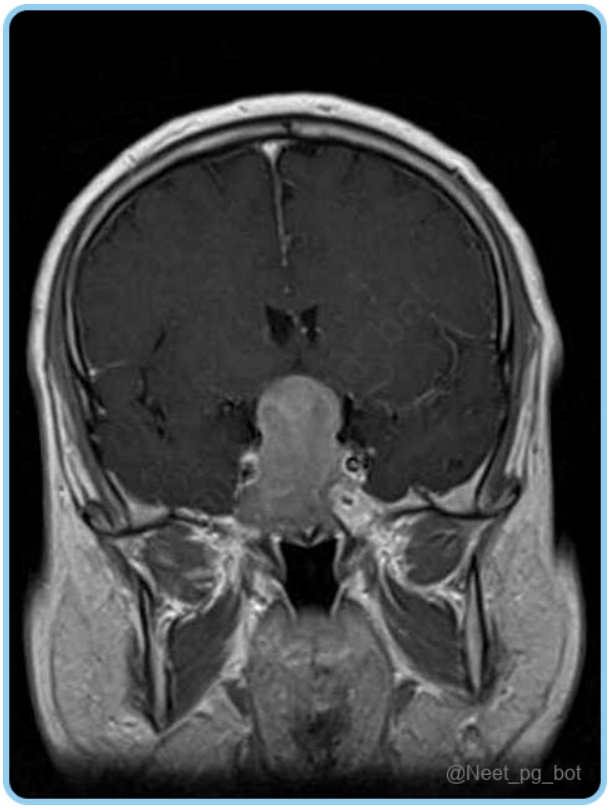

Correct Answer: C. Perform transsphenoidal surgical resection

■ *Listen (English)*

■ *Listen (Hindi)*

Explanation: The clinical signs of enlargement of feet, visual field defects likely from optic chiasma compression and biochemical evidence of excess of GH points to acromegaly. MRI head shows somatotroph pituitary macroadenoma with mass effect . Transsphenoidal surgical resection is the preferred treatment. Management of Acromegaly Surgical Treatment Transsphenoidal surgical resection is the preferred treatment, especially for those with GH-secreting adenomas. Post-Surgery: Improvement in soft tissue swelling and normalization of GH levels typically occur shortly after surgery IGF-1 levels normalize within 3-4 days. There is a 10% recurrence rate of acromegaly years later, and up to 15% of patients may develop hypopituitarism. Medical therapy Preferred in

medical therapy if curative surgery is not feasible or if GH fails to decrease post resection Somatostatin Receptor Ligands (SRLs): (Option B ruled out) Long-acting injectable forms (octreotide, lanreotide) . Normalizes GH and IGF-1 levels in about 50% of patients. Side Effects : GI disturbances, transient nausea, and gallbladder issues. GH receptor antagonist: Pegvisomant blocks peripheral GH receptors, normalizing IGF-1 levels in about 70% of patients, though GH levels remain elevated. It is administered through daily subcutaneous injections and is used for recurrences or poor responses to SRLs. Dopamine Agonists: (Option A ruled out) High doses of cabergoline can provide modest GH suppression. Radiation Therapy (Option D ruled out) External beam radiation therapy or stereotactic techniques are considered for patients not achieving biochemical control through surgery or medical therapy.

References:

Harrison's Principles of Internal Medicine, 22nd edition, Page 3010

↑ *Back to this question in Part A*

@Neet_pg_bot

Q27: 50-year-old woman presents with increase in size of hand and feet with voice changes and carpal tunnel syndrome. IGF -1 levels are increased. Which of the following findings will likely not be seen in this case? (Q850911)

A. Hypoglycemic attacks

B. Galactorrhea

C. Bitemporal Hemianopia

D. Colonic polyps

Correct Answer: A. Hypoglycemic attacks

■ *Listen (English)*

■ *Listen (Hindi)*

Explanation: Hypoglycemic attacks GH is counter regulatory hormone causing increase of blood glucose and impaired glucose tolerance in patients with acromegaly. Presence of Mammosomatotrope cell adenoma can explain galactorrhea Pituitary adenoma > 10 mm can press on optic chiasma leading to bitemporal hemianopia Acromegaly is associated with increased risk of colonic polyps and mortality from colonic malignancy

References:

Harrison's Principles of Internal Medicine, 22nd Edition, Page 3008

↑ *Back to this question in Part A*

@Neet_pg_bot

Q28: A 45-year-old man presents with spade like hands, coarse facies and increased spacing between his lower teeth. Which of the following is screening test for this case? (Q850910)

A. IGF-1 levels

B. IGF-2 levels

C. GH Levels

D. GH levels after 2 hour of glucose challenge test



Correct Answer: A. IGF-1 levels

■ *Listen (English)*

■ *Listen (Hindi)*

Explanation: The patient has classic features of acromegaly (spade-like hands, coarse facial features, increased interdental spacing). IGF-1 is the best screening test because: It reflects integrated GH secretion over the day It is elevated consistently in acromegaly It is not affected by pulsatile GH release IGF-2 levels (Option B): IGF-2 is not used in acromegaly screening . GH levels (Option C): GH secretion is pulsatile , making random GH levels unreliable. GH levels after 2-hour OGTT (Option D): This is the confirmatory (diagnostic) test . Failure of GH suppression after glucose load confirms acromegaly.

References:

Harrison’s Principles of Internal Medicine, 21st Edition, Page 2912

↑ *Back to this question in Part A*

@Neet_pg_bot

Q29: Prolactin levels can be increased in all of the following conditions except? (Q850909)

A. Acromegaly

B. Primary hypothyroidism

C. Secondary hypothyroidism

D. Prolactinoma

Correct Answer: C. Secondary hypothyroidism

■ *Listen (English)*

■ *Listen (Hindi)*

Explanation: Acromegaly can arise from Mammosomatotrope cell adenoma leading to excess GH as well as prolactin TRH stimulates the anterior pituitary to release TSH and prolactin. In primary hypothyroidism , T4 and T3 are low causing rise of TRH. (Option B) This increased TRH will cause both TSH and prolactin to rise contributing to galactorrhea. Secondary hypothyroidism has pituitary damage leading to low TSH and low or normal prolactin Prolactinoma will cause excess prolactin leading to galactorrhea and menstural abnormalities (Option D)

References:

Harrison’s Principles of Internal Medicine, 22nd Edition, Page 3008

↑ *Back to this question in Part A*

@Neet_pg_bot

Q30: Best test to confirm the diagnosis of acromegaly is? (Q850806)

A. IGF-1

B. IGF-2

C. Oral Glucose Tolerance Test

D. MRI pituitary

Correct Answer: C. Oral Glucose Tolerance Test

■ *Listen (English)*

■ *Listen (Hindi)*

Explanation: Diagnosis of acromegaly is confirmed by an Oral Glucose Tolerance Test (OGTT) using 75 g glucose. Glucose should suppress GH, but in acromegaly it fails to suppress . In acromegaly, GH fails to suppress to <0.4 µg/L within 1–2 hours , confirming the diagnosis. IGF-1 level(Option A): IGF-1 is the best screening test , not confirmatory. It reflects integrated GH secretion but cannot alone confirm acromegaly. IGF-2 (Option B): IGF-2 is involved mainly in fetal (prenatal) growth , not postnatal growth, and has no role in diagnosing acromegaly. MRI pituitary (Option D): MRI helps identify the pituitary adenoma , but it cannot confirm hormonal excess .

References:

,Page 3008, Harrison’s Principles of Internal Medicine, 22nd Edition,

↑ *Back to this question in Part A*

@Neet_pg_bot

• [03_Endocrinology] 020 Previous Year Questions

« Back to Folder Directory

[03_Endocrinology] 020 Previous Year Questions — Quick Jump

Q1 (p. 1658)	*Q2 (p. 1659)*	*Q3 (p. 1661)*	*Q4 (p. 1663)*	*Q5 (p. 1664)*	*Q6 (p. 1665)*
Q7 (p. 1665)	*Q8 (p. 1666)*	*Q9 (p. 1667)*	*Q10 (p. 1667)*	*Q11 (p. 1668)*	*Q12 (p. 1669)*
Q13 (p. 1670)	*Q14 (p. 1671)*	*Q15 (p. 1672)*	*Q16 (p. 1672)*	*Q17 (p. 1673)*	*Q18 (p. 1674)*
Q19 (p. 1675)	*Q20 (p. 1676)*	*Q21 (p. 1677)*	*Q22 (p. 1677)*	*Q23 (p. 1678)*	*Q24 (p. 1679)*
Q25 (p. 1680)	*Q26 (p. 1681)*	*Q27 (p. 1681)*	*Q28 (p. 1682)*	*Q29 (p. 1683)*	*Q30 (p. 1684)*
Q31 (p. 1685)	*Q32 (p. 1686)*	*Q33 (p. 1687)*	*Q34 (p. 1688)*	*Q35 (p. 1689)*	*Q36 (p. 1692)*
Q37 (p. 1693)	*Q38 (p. 1694)*	*Q39 (p. 1695)*	*Q40 (p. 1697)*	*Q41 (p. 1698)*	*Q42 (p. 1699)*
Q43 (p. 1699)	*Q44 (p. 1700)*	*Q45 (p. 1701)*	*Q46 (p. 1702)*	*Q47 (p. 1704)*	*Q48 (p. 1704)*
Q49 (p. 1705)	*Q50 (p. 1706)*	*Q51 (p. 1707)*	*Q52 (p. 1709)*	*Q53 (p. 1709)*	*Q54 (p. 1713)*
Q55 (p. 1713)	*Q56 (p. 1714)*	*Q57 (p. 1715)*	*Q58 (p. 1716)*	*Q59 (p. 1718)*	*Q60 (p. 1721)*
Q61 (p. 1724)	*Q62 (p. 1725)*	*Q63 (p. 1726)*	*Q64 (p. 1727)*	*Q65 (p. 1729)*	*Q66 (p. 1729)*
Q67 (p. 1730)	*Q68 (p. 1731)*	*Q69 (p. 1732)*	*Q70 (p. 1733)*	*Q71 (p. 1733)*	*Q72 (p. 1734)*
Q73 (p. 1736)	*Q74 (p. 1740)*	*Q75 (p. 1740)*	*Q76 (p. 1741)*	*Q77 (p. 1742)*	*Q78 (p. 1743)*
Q79 (p. 1744)	*Q80 (p. 1744)*	*Q81 (p. 1745)*	*Q82 (p. 1746)*	*Q83 (p. 1747)*	*Q84 (p. 1748)*
Q85 (p. 1749)	*Q86 (p. 1750)*	*Q87 (p. 1751)*	*Q88 (p. 1752)*	*Q89 (p. 1753)*	*Q90 (p. 1753)*
Q91 (p. 1754)	*Q92 (p. 1755)*	*Q93 (p. 1755)*	*Q94 (p. 1756)*	*Q95 (p. 1757)*	*Q96 (p. 1758)*
Q97 (p. 1758)	*Q98 (p. 1759)*	*Q99 (p. 1760)*	*Q100 (p. 1760)*	*Q101 (p. 1761)*	*Q102 (p. 1762)*
Q103 (p. 1762)					

Q1: A patient presents with weight gain, thinning of hair, and dry skin. Diagnosis is Hashimoto's thyroiditis. Which antibody is seen in this case? (Q866788)

A. Anti-TPO antibody

B. Anti TSH

C. Anti TBG

D. Long-acting thyroid-stimulating antibody

Correct Answer: A. Anti-TPO antibody

Explanation: Hashimoto's thyroiditis is the most common cause of hypothyroidism in iodine-sufficient areas, and it is strongly associated with anti-thyroid peroxidase (anti-TPO) antibodies. These antibodies cause autoimmune

destruction of the thyroid gland. Anti-TPO antibodies target the enzyme thyroid peroxidase, which is essential for thyroid hormone synthesis (oxidation and iodination of iodine, coupling of iodotyrosines). Their presence confirms autoimmune thyroid disease, especially Hashimoto's. Other antibodies, like anti-thyroglobulin, may also be present but anti-TPO has the highest diagnostic relevance. Hashimoto's thyroiditis: AKA Chronic autoimmune lymphocytic thyroiditis. Epidemiology: More common in women, especially middle-aged. Pathogenesis: Autoantibodies (anti-TPO, anti-thyroglobulin) → chronic inflammation → fibrosis → hypothyroidism. Clinical features: Weight gain, cold intolerance, dry skin, hair thinning, constipation, menstrual irregularities. Lab findings: High TSH, low free T4, positive anti-TPO antibodies. Histopathology : Diffuse lymphocytic infiltration Formation of germinal centers Hurthle cells (large oxyphilic epithelial cells with granular cytoplasm) replacing follicular epithelium Atrophic thyroid follicles with dense fibrosis in late stages Treatment: Lifelong levothyroxine replacement. Complications: Increased risk of thyroid lymphoma. Incorrect Options: Anti TSH (Option B) – Not seen in Hashimoto's; would interfere with TSH action, not a diagnostic marker. Anti TBG (Option C) – Antibodies against thyroxine-binding globulin are rare and not relevant for Hashimoto's diagnosis. Long-acting thyroid-stimulating antibody (Option D) – Seen in Graves' disease, causes hyperthyroidism, not hypothyroidism.

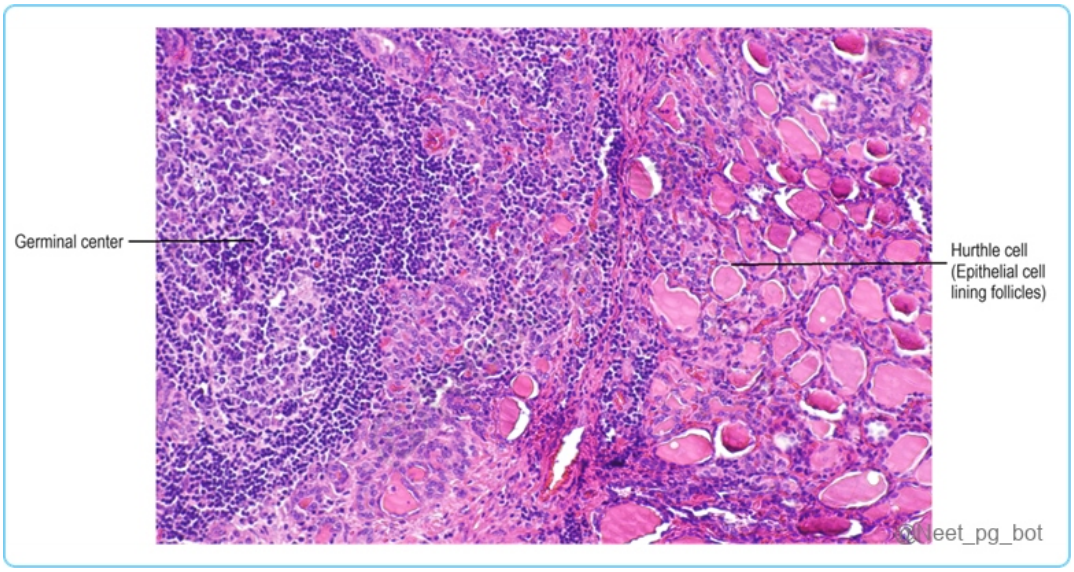

References:

.

↑ *Back to this question in Part A*

@Neet_pg_bot

Q2: A patient has developed a cough and weight loss for the last 3 months. Biopsy of lung mass shows expression of chromogranin and synaptophysin. Which paraneoplastic syndrome will most likely occur in this patient? (Q866793)

A. Hypercalcemia

B. Cushing syndrome

C. Gynaecomastia

D. SIADH

Correct Answer: D. SIADH

Explanation: Chromogranin and synaptophysin positivity suggests a neuroendocrine tumor , such as small cell carcinoma of the lung. These tumors often produce ectopic ADH, leading to syndrome of inappropriate antidiuretic hormone secretion (SIADH). In SIADH, excessive ADH secretion causes water retention without corresponding sodium retention, resulting in dilutional hyponatremia and low plasma osmolality. Small cell lung carcinoma is notorious for secreting ectopic hormones, particularly ADH and ACTH. The presence of neuroendocrine markers confirms the tumor's secretory nature. Small Cell Carcinoma: Origin: Neuroendocrine Kulchitsky cells in the lung. Markers: Chromogranin, synaptophysin, neuron-specific enolase (NSE). Paraneoplastic syndromes: SIADH (ADH), Cushing syndrome (ACTH), Lambert–Eaton myasthenic syndrome (autoantibodies against presynaptic calcium channels). Histology: Small cells with scant cytoplasm, nuclear molding, high mitotic count. Prognosis: Aggressive, early metastasis; often unresectable at diagnosis. Treatment: Combination chemotherapy ± radiotherapy; surgery rarely indicated. Salt and pepper chromatin (black arrows) Paraneoplastic Syndromes in Lung Cancers: Lung Cancer Type Paraneoplastic Syndromes Small cell carcinoma SIADH, Cushing syndrome, Lambert–Eaton Squamous cell carcinoma Hypercalcemia (PTHrP) Adenocarcinoma Hypertrophic osteoarthropathy Carcinoid tumor Carcinoid syndrome Paraneoplastic syndromes seen in other cancers: Cancer Type Paraneoplastic Syndrome Mechanism / Mediator Renal cell carcinoma Polycythemia Erythropoietin production Hepatocellular carcinoma Polycythemia Erythropoietin production Ovarian teratoma Anti–NMDA receptor encephalitis Autoantibodies to NMDA receptors Thymoma Myasthenia gravis Autoantibodies to postsynaptic AChRs Breast cancer Dermatomyositis / Polymyositis Immune-mediated Gastric carcinoma Acanthosis nigricans Growth factors stimulating melanocytes Pancreatic carcinoma Trousseau syndrome (migratory thrombophlebitis) Hypercoagulability (mucin) Lymphomas Hypercalcemia 1,25-(OH)■ vitamin D production Medullary thyroid carcinoma Diarrhea, flushing Calcitonin, VIP Incorrect Options: Hypercalcemia (Option A) – Classically associated with squamous cell carcinoma via PTHrP secretion. Cushing syndrome (Option B) – Possible in small cell carcinoma (ectopic ACTH), but SIADH is more common in this setting. Gynaecomastia (Option C) – Seen in some germ cell tumors or liver disease, not typical for small cell carcinoma.

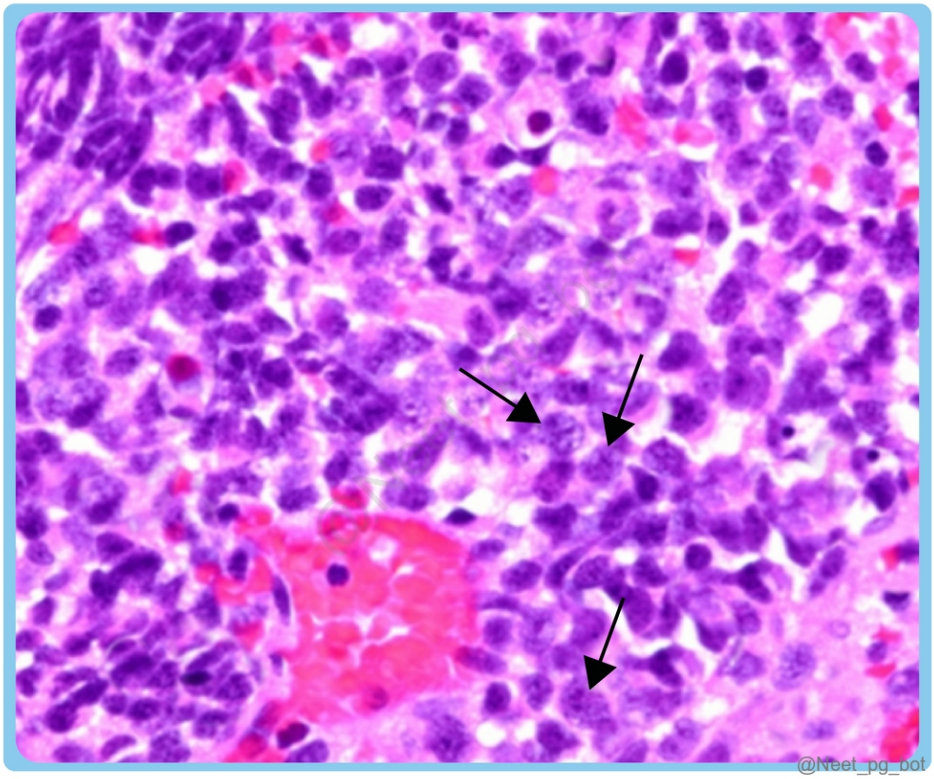

References:

.

↑ *Back to this question in Part A*

@Neet_pg_bot

Q3: A patient presents with palpitations, headache, and sweating. His BP is 180/100 mmHg. 24-hour urinary metanephrine values are elevated. What is the diagnosis? (Q866794)

A. Carcinoid tumor

B. Pheochromocytoma

C. Carcinoid crisis

D. Neuroblastoma

Correct Answer: B. Pheochromocytoma

Explanation: Pheochromocytoma is a catecholamine-secreting tumor of the adrenal medulla. Classic symptoms are episodic headache, sweating, and palpitations with hypertension. Elevated 24-hour urinary metanephrines confirm catecholamine excess. Pheochromocytomas arise from chromaffin cells derived from neural crest tissue. Excess secretion of epinephrine and norepinephrine causes paroxysmal hypertension and sympathetic overactivity. Metanephrines are catecholamine metabolites, and their measurement in a 24-hour urine sample or plasma is the most sensitive test for diagnosis. Pheochromocytoma: Origin: Chromaffin cells (adrenal medulla). Rule of 10s: ~10% bilateral, 10% malignant, 10% extra-adrenal (paraganglioma), 10% in children. Associations: MEN 2A, MEN 2B, von Hippel–Lindau disease, NF1. Treatment: α-blockade (phenoxybenzamine) before β-blockade, then surgical resection. Histology: Zellballen pattern (nests of cells with rich vascular stroma). Incorrect Options: Carcinoid tumor (Option A): Presents with flushing, diarrhea, and bronchospasm; diagnosis by urinary 5-HIAA, not metanephrines. Carcinoid crisis (Option C): Severe complication of carcinoid tumor with profound hypotension and bronchospasm; unrelated to catecholamines. Neuroblastoma (Option D): Pediatric tumor of adrenal medulla or sympathetic chain; elevated HVA/VMA (dopamine metabolites), not metanephrines in adults.

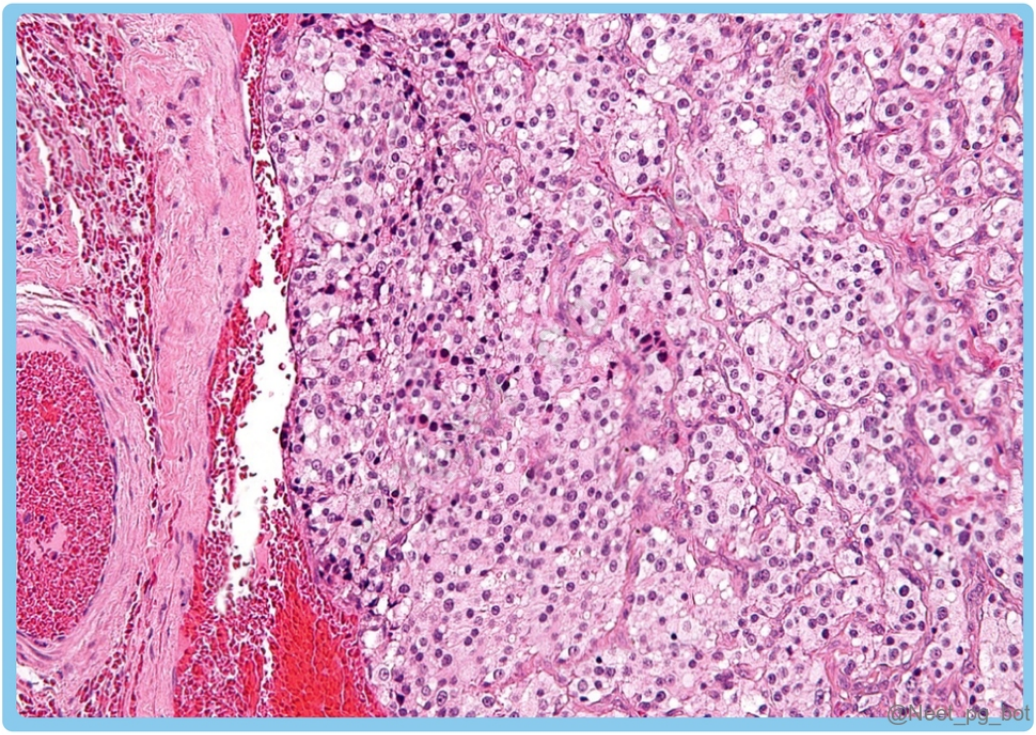



References:

.

↑ *Back to this question in Part A*

@Neet_pg_bot

Q4: A known case of hyperthyroidism, who is not on medication, is scheduled for total thyroidectomy. The PAC check was not done properly. What is the leading complication that can occur during surgery? (Q866801)

A. Hyperthermia

B. Hypothermia

C. Arrhythmia

D. Hypothyroidism

Correct Answer: C. Arrhythmia

Explanation: In uncontrolled hyperthyroidism, catecholamine sensitivity is increased, predisposing the patient to severe intraoperative arrhythmias, especially during surgical manipulation of the thyroid gland. A patient with untreated hyperthyroidism undergoing thyroidectomy is at high risk of thyroid storm, precipitated by surgical stress . This can manifest with tachyarrhythmias, hyperthermia, and hypertension. Arrhythmia (especially atrial fibrillation or supraventricular tachycardia) is the most immediate and dangerous intraoperative complication.

Proper preoperative control with antithyroid drugs, β-blockers, and adequate preparation is essential. Incorrect Options: Hyperthermia (Option A): Can occur in thyroid storm but is not the leading intraoperative danger; arrhythmia is more acutely life-threatening. Hypothermia (Option B): Not typically associated with hyperthyroidism; more a concern in prolonged surgeries in cold OR environments. Hypothyroidism (Option D): Develops postoperatively, not during surgery.

Page 2942: Harrison 21st

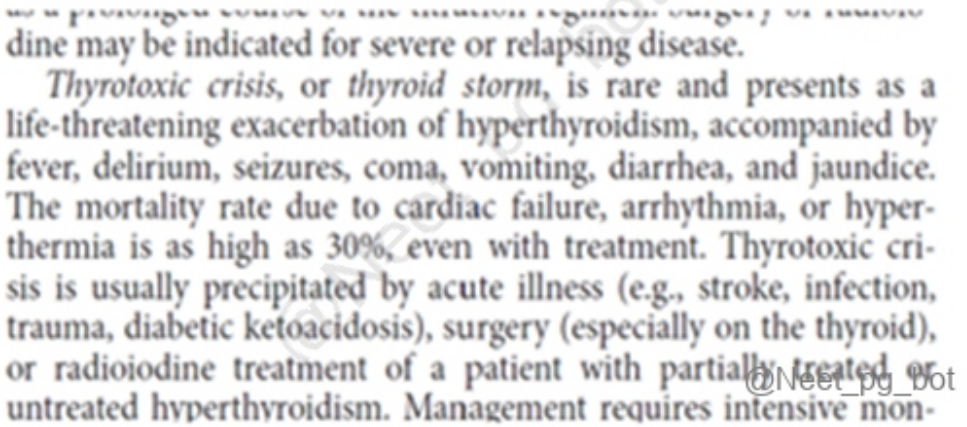

dine may be indicated for severe or relapsing disease.

Thyrotoxic crisis, or *thyroid storm*, is rare and presents as a life-threatening exacerbation of hyperthyroidism, accompanied by fever, delirium, seizures, coma, vomiting, diarrhea, and jaundice. The mortality rate due to cardiac failure, arrhythmia, or hyperthermia is as high as 30%, even with treatment. Thyrotoxic crisis is usually precipitated by acute illness (e.g., stroke, infection, trauma, diabetic ketoacidosis), surgery (especially on the thyroid), or radioiodine treatment of a patient with partially treated or untreated hyperthyroidism. Management requires intensive mon-

@Neet_pg_bot

↑ *Back to this question in Part A*

@Neet_pg_bot

Q5: Patient presents with hypertension and hypokalemic metabolic alkalosis. CT scan shows a mass over the kidney with elevated ARR. What is the next best step for the management of this patient? (Q866803)

A. Spironolactone on a lifelong basis

B. Adrenalectomy

C. ACTH stimulation test

D. Dexamethasone suppression test

Correct Answer: B. Adrenalectomy

Explanation: This patient likely has primary hyperaldosteronism (Conn's syndrome) due to an adrenal adenoma. In unilateral disease confirmed by imaging and biochemistry (elevated Aldosterone–Renin Ratio), surgical adrenalectomy is the treatment of choice. Hypertension + hypokalemic metabolic alkalosis + high ARR + adrenal mass suggests unilateral aldosterone-producing adenoma. After confirming lateralization (often with adrenal venous sampling in some protocols), the definitive treatment is laparoscopic adrenalectomy. Medical management with mineralocorticoid receptor antagonists (spironolactone/eplerenone) is reserved for bilateral adrenal

hyperplasia or non-surgical candidates. Primary Hyperaldosteronism: Feature Primary Hyperaldosteronism Common causes Adrenal adenoma (Conn's), bilateral adrenal hyperplasia Key features Hypertension, hypokalemia, metabolic alkalosis Screening Elevated ARR (Aldosterone–Renin Ratio) Confirmatory tests Saline suppression test, fludrocortisone suppression test Treatment – unilateral Surgical adrenalectomy Treatment – bilateral Spironolactone/eplerenone Incorrect Options: Spironolactone (Option A): First-line for bilateral hyperplasia or non-surgical patients, not preferred for unilateral adenoma in a surgical candidate. ACTH stimulation test (Option C): Used for adrenal insufficiency diagnosis, not hyperaldosteronism. Dexamethasone suppression test (Option D): Used for diagnosing Cushing's syndrome.

↑ *Back to this question in Part A*

@Neet_pg_bot

Q6: A female presents with amenorrhea and galactorrhea. Serum prolactin is elevated. MRI shows pituitary adenoma. Best management for this patient? (Q866806)

A. Bromocriptine

B. Letrozole

C. Tamoxifen

D. Goserelin

Correct Answer: A. Bromocriptine

Explanation: The patient has hyperprolactinemia due to a pituitary adenoma (prolactinoma). Hyperprolactinemia → suppresses GnRH → ↓ LH/FSH → menstrual irregularities and infertility. First-line treatment for prolactinomas is dopamine agonists (Bromocriptine or Cabergoline) as they inhibit prolactin secretion and can shrink the tumor. Bromocriptine is safe in women desiring pregnancy. Surgery (trans-sphenoidal resection) is reserved for drug-resistant or compressive symptoms (e.g., visual loss). Prolactinoma: Causes: Pituitary adenoma (most common) Drugs: antipsychotics, metoclopramide Hypothyroidism (↑ TRH → ↑ prolactin) Symptoms: Women: amenorrhea, galactorrhea, infertility Men: decreased libido, erectile dysfunction, gynecomastia Mass effect: headaches, bitemporal hemianopia if the optic chiasm is compressed Diagnosis: serum prolactin, MRI brain with pituitary protocol Treatment: dopamine agonists (Bromocriptine, Cabergoline) → surgery if not responsive Incorrect Options: Letrozole (Option B) – Aromatase inhibitor for estrogen-dependent breast cancer and infertility, not first-line for prolactinoma. Tamoxifen (Option C) – Selective estrogen receptor modulator (SERM) used in breast cancer, unrelated to prolactinomas. Goserelin (Option D) – GnRH agonist used in prostate/breast cancer and endometriosis, not for prolactinoma.

↑ *Back to this question in Part A*

@Neet_pg_bot

Q7: Hyperpigmentation in Addison’s disease is due to increased secretion of: (Q866480)

A. Cortisol

B. ACTH

C. Aldosterone

D. Renin

Correct Answer: B. ACTH

Explanation: ACTH In primary adrenal insufficiency (Addison’s disease) , destruction of the adrenal cortex leads to low cortisol and aldosterone . The pituitary compensates by secreting more ACTH from the precursor proopiomelanocortin (POMC) , which also produces melanocyte-stimulating hormone (MSH) . MSH stimulates melanin production, causing skin and mucosal hyperpigmentation . Addison's disease refers to primary adrenocortical failure : Etiology Autoimmune: M/C/C Worldwide Sporadic Polyglandular syndromes Tuberculosis: M/C/C in India Histoplasmosis HIV/AIDS Metastatic carcinoma Bilateral adrenalectomy Clinical features Glucocorticoid insufficiency Weight loss, anorexia, malaise, weakness, nausea, vomiting, diarrhea or constipation, postural hypotension, shock, hypoglycemia, hyponatremia (dilutional), hypercalcemia Mineralocorticoid insufficiency: Hypotension, shock, hyponatremia, hyperkalemia ACTH excess: Pigmentation Adrenal androgen insufficiency: Decreased body hair and loss of libido, especially in females Cortisol (Option A) : Deficient in Addison’s disease; low levels stimulate ACTH production but do not directly cause pigmentation. Aldosterone (Option C) : Deficient in Addison’s disease; loss leads to hyperkalemia and hypotension, not pigmentation. Renin (Option D) : Elevated due to hypovolemia, but has no role in pigmentation.

↑ *Back to this question in Part A*

@Neet_pg_bot

Q8: A patient presents with palpitations, headache and diaphoresis + elevated 24 hour urine metanephrine levels. Which of the following drugs can be used both preoperatively and intraoperatively for control of BP? (Q866494)

A. Phenoxybenzamine

B. Esmolol

C. Clonidine

D. Labetalol

Correct Answer: D. Labetalol

Explanation: Correct answer: D) Labetalol Labetalol is a combined α- and β-adrenergic blocker that can be used both preoperatively and intraoperatively in pheochromocytoma to control hypertension. While non-selective α-blockade (e.g., phenoxybenzamine) is preferred initially to prevent hypertensive crises, labetalol can be used when both α- and β-blockade are desired and during surgery to manage BP surges. Phenoxybenzamine (Option A): An irreversible α-blocker, used mainly preoperatively, but not ideal intraoperatively due to prolonged action and inability to titrate rapidly. Esmolol (Option B): A short-acting β1-blocker, used after adequate α-blockade if tachycardia persists; not used alone for BP control in pheochromocytoma. Clonidine (Option C): Central α2 agonist, not first-line for pheochromocytoma BP control; may reduce sympathetic outflow but less effective for catecholamine surges.

References:

.

↑ *Back to this question in Part A*

@Neet_pg_bot

Q9: A 56-year-old diabetic patient is currently on Metformin and Insulin Glargine. His HbA1c is 8.2%, indicating suboptimal glycemic control. Echocardiography reveals a reduced ejection fraction (EF) of 35%. Which of the following is the most appropriate agent to add to his current regimen? (Q866500)

A. Pioglitazone

B. Glimepiride

C. Sitagliptin

D. Empagliflozin

Correct Answer: D. Empagliflozin

Explanation: Empagliflozin is an SGLT2 inhibitor that not only lowers blood glucose but also has proven cardiovascular benefits , particularly in patients with heart failure with reduced ejection fraction (HFrEF) , irrespective of diabetes status. In this diabetic patient with suboptimal glycemic control and EF 35%, empagliflozin is the preferred add-on as it reduces hospitalizations for heart failure and improves survival. Pioglitazone (Option A): Causes fluid retention and can worsen heart failure — contraindicated in EF <40%. Glimepiride (Option B): A sulfonylurea that increases hypoglycemia risk and offers no cardiovascular benefit. Sitagliptin (Option C): A DPP-4 inhibitor with neutral cardiovascular effects; not first choice for HFrEF.

↑ *Back to this question in Part A*

@Neet_pg_bot

Q10: A patient presents with salt wasting, craving, hyperkalemia, metabolic acidosis, and skin pigmentation. What is the most likely diagnosis? (Q866509)

A. Addison’s disease

B. Cushing’s syndrome

C. Conn’s syndrome

D. Pheochromocytoma

Correct Answer: A. Addison’s disease

Explanation: The most likely diagnosis is Addison’s disease, Addison’s disease (primary adrenal insufficiency) is characterized by: Mineralocorticoid deficiency → salt wasting, salt craving, hyperkalemia, metabolic acidosis. Glucocorticoid deficiency → weakness, fatigue, weight loss. Increased ACTH due to loss of cortisol negative feedback → skin hyperpigmentation from excess melanocyte-stimulating hormone (MSH). Investigations Random plasma cortisol measurement (values >500 nmol/L exclude adrenal insufficiency) Short ACTH stimulation test- if random cortisol levels are between 100-500, 1 microgram ACTH, serum cortisol levels of <500 is considered confirmatory for adrenal insufficiency. Plasma renin and aldosterone (high renin with low/lower part of the reference range aldosterone in mineralocorticoid deficiency) Dehydroepiandrosterone sulfate (DHEAS) and androstenedione in women Adrenal autoantibodies for autoimmune causes; imaging (CT/MRI) if antibodies are negative. Management 1. Glucocorticoid Replacement: Oral hydrocortisone is preferred, and Prednisolone and dexamethasone may also be used. 2. Mineralocorticoid Replacement: Fludrocortisone Addisonian crisis An Addisonian crisis is a life-threatening medical emergency that occurs when there is a severe deficiency of cortisol and aldosterone. It is most commonly seen in people with Addison's disease (primary adrenal insufficiency), especially when their hormone replacement therapy is inadequate or missed or during periods of extreme stress (e.g., illness, trauma, or surgery). Management: IV Hydrocortisone Cushing’s syndrome (Option B): Due to cortisol excess; presents with central obesity, moon face, hypertension, hyperglycemia—not salt wasting or hyperkalemia. Conn’s syndrome (Option C): Primary hyperaldosteronism; causes sodium retention, hypertension, hypokalemia, metabolic alkalosis—not hyperkalemia or pigmentation. Pheochromocytoma (Option D): Catecholamine-secreting tumor; presents with episodic headache, sweating, tachycardia, hypertension—not salt wasting or hyperpigmentation.

↑ *Back to this question in Part A*

@Neet_pg_bot

Q11: A known type 1 diabetic presents with glucose 799 mg/dL, Na■ 128 mEq/L, Cl■ 88 mEq/L, and signs of dehydration. Which of the following is NOT used in the initial management? (Q866515)

A. 0.9% Normal saline

B. 3% Saline

C. IV infusion insulin

D. Potassium monitoring

Correct Answer: B. 3% Saline

Explanation: The clinical presentation points towards DKA In DKA, the initial management focuses on: Fluid resuscitation with isotonic saline (0.9% NaCl) to correct dehydration. Insulin infusion to correct hyperglycemia and ketosis. Potassium monitoring and replacement as insulin therapy and fluids can cause hypokalemia. Updated Management of Diabetic Ketoacidosis (ISPAD 2022): 3% hypertonic saline is not indicated unless there is severe symptomatic hyponatremia with neurological symptoms (usually Na■ < 120 mEq/L and acute onset). In this case, hyponatremia is dilutional and corrects with normal saline and DKA management.

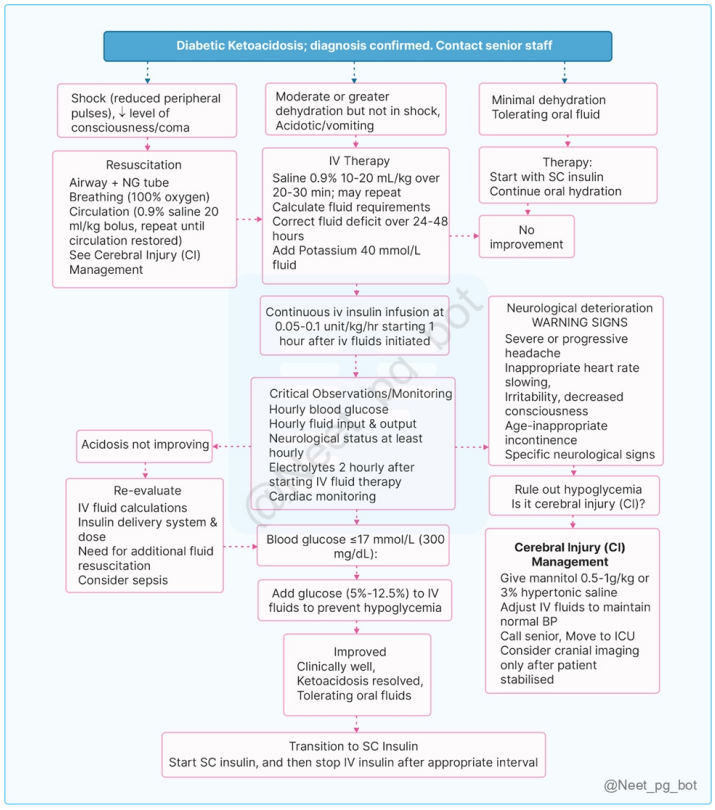

References:

.

↑ *Back to this question in Part A*

@Neet_pg_bot

Q12: A female patient with type 1 DM and hypothyroidism presented with chronic oral mucocutaneous candidiasis for 5 years. She is diagnosed with autoimmune polyendocrinopathy syndrome type 1. Which of the following is incorrect about this condition? (Q853349)

A. DM type-1 association is high

B. Starts in infancy

C. Hypoparathyroidism

D. High association with candidiasis

Correct Answer: A. DM type-1 association is high

Explanation: Type 1 diabetes mellitus (DM) is commonly associated with APS Type 2, it is less frequently seen in APS Type 1. Autoimmune Polyendocrinopathy Syndrome (APS) Type 1 is also known as APECED (Autoimmune Polyendocrinopathy, Candidiasis, and Ectodermal Dystrophy). APS Type 1 is more associated with conditions like hypoparathyroidism, adrenal insufficiency, and chronic mucocutaneous candidiasis. Autoimmune Polyendocrinopathy Syndrome (APS) Autoimmune Polyendocrinopathy Syndrome iis a group of autoimmune disorders characterized by the immune system mistakenly attacking multiple endocrine glands, leading to hormonal imbalances. It is classified into two main types Feature APS-1 (APECED - Autoimmune Polyendocrinopathy-Candidiasis-Ectodermal Dystrophy) APS-2 (Schmidt syndrome) Gene AIRE mutation HLA-DR3, DR4 Inheritance Autosomal recessive Polygenic Age Childhood (Option B ruled out) Adulthood Classic triad Candidiasis + Hypoparathyroidism + Addison disease (Options C & D ruled out) Addison + Thyroid disease + Type 1 DM Candidiasis Very common Rare Hypoparathyroidism Common Rare Type 1 DM Rare Common

References:

Robbins and Cotran Pathologic Basis of Disease, 10th Edition, Pages 1123

↑ *Back to this question in Part A*

@Neet_pg_bot

Q13: A patient presents with hypotension, hyponatremia and blackening of the knuckles and perioral area. Which of the following conditions is most likely associated with these symptoms? (Q844204)

A. Conn syndrome

B. Cushing's syndrome

C. Primary ACTH deficiency

D. Addison’s disease

Correct Answer: D. Addison’s disease

Explanation: Correct Option D - Addison’s Disease: Addison’s Disease : Symptoms : Hypotension : Due to insufficient cortisol production affecting blood pressure. Hyponatremia : Caused by low aldosterone levels, leading to reduced sodium reabsorption. Hyperpigmentation : Characterized by darkening of the skin, including knuckles and perioral areas, due to increased ACTH levels stimulating melanocytes. Incorrect Options: Option A - Conn Syndrome: Characterized by primary hyperaldosteronism, which typically leads to hypertension, hypokalemia (low potassium), and metabolic alkalosis, but not usually associated with hyperpigmentation or hyponatremia. Option B - Cushing’s Syndrome: Results from excess cortisol production and can present with hypertension, hyperglycemia, and hypokalemia. Hyperpigmentation is not a common feature; instead, you might see features such as easy bruising and a “moon facies.” Option C - Primary ACTH Deficiency: Leads to low cortisol levels but not usually associated with hyperpigmentation. Patients may experience symptoms of adrenal insufficiency, but hyperpigmentation is more characteristic of primary adrenal insufficiency (Addison’s disease) rather than ACTH deficiency.

↑ *Back to this question in Part A*

@Neet_pg_bot

Q14: A patient with a history of Wilson's disease presents with neurological manifestations. Which of the following is the best diagnostic modality? (Q844223)

A. Serum ceruloplasmin

B. Urinary copper excretion

C. Hepatic parenchymal demonstration of copper

D. Anti-tissue transglutaminase (Anti-tTG) antibody

Correct Answer: C. Hepatic parenchymal demonstration of copper

Explanation: Correct Option C - Hepatic parenchymal demonstration of copper: The gold standard for diagnosing Wilson’s disease—especially when neurological symptoms are present—is quantitative hepatic copper estimation via liver biopsy . A level >250 µg/g dry weight confirms the diagnosis with high specificity. Serum ceruloplasmin (Option A): While serum ceruloplasmin is often low in Wilson's disease, it is not the most reliable diagnostic tool, as ceruloplasmin levels can be low in other conditions and may be normal in some patients with Wilson's disease. Urinary copper excretion (Option B): This test measures 24-hour urinary copper excretion and is elevated in Wilson's disease, but it is not as definitive as hepatic copper measurement. It is useful as part of the diagnostic workup but not the best single test. Anti-tissue transglutaminase (Anti-tTG) antibody) (Option D): This antibody is associated with celiac disease and is not relevant to the diagnosis of Wilson's disease.

References:

.

↑ *Back to this question in Part A*

@Neet_pg_bot

Q15: A patient presents with large sweaty hands, macroglossia, and frontal bossing. Select the best test for confirmation of the diagnosis: (Q844227)

A. GHRH levels

B. IGF- 1

C. IGF- 2

D. GH levels after glucose suppression

Correct Answer: D. GH levels after glucose suppression

Explanation: Correct Option D - GH levels after glucose suppression: The best test for confirming a diagnosis of acromegaly (often caused by excess growth hormone) is GH suppression test. 75g of oral glucose is administered and blood GH levels are checked at 30, 60, 90, and 120 minutes. Normally, glucose suppressess GH, If GH > 1ng/ml, it is confirmatory of acromegaly. Incorrect Options: Option A - GHRH levels: Growth Hormone-Releasing Hormone (GHRH) levels are not typically used for the diagnosis of acromegaly. While GHRH can stimulate growth hormone release, its levels are not directly indicative of acromegaly. Option C - IGF-2: IGF-2 is not typically used for diagnosing acromegaly. It is more relevant in conditions like certain tumors and is not a primary diagnostic marker for acromegaly. Option B - Insulin-like Growth Factor 1 (IGF-1) . IGF-1 levels are elevated in acromegaly due to the increased secretion of growth hormone. IGF-1 is a stable marker that reflects chronic exposure to growth hormone and is therefore used as the screening test for acromegaly.

References:

.

↑ *Back to this question in Part A*

@Neet_pg_bot

Q16: In a patient with type 1 diabetes at the 3rd stage of beta cell damage, which of the following conditions is most likely to be observed? (Q844327)

A. Autoimmune positive + normoglycemia

B. Autoimmune negative + normoglycemia

C. Autoimmune positive + dysglycemia

D. Autoimmune negative + dysglycemia

Correct Answer: C. Autoimmune positive + dysglycemia

Explanation: Correct Option C - Autoimmune positive + dysglycemia: In Stage 3 of type 1 diabetes, there is significant beta cell damage due to an ongoing autoimmune process, leading to dysglycemia (impaired glucose levels). At this stage, there is insufficient insulin production to maintain normal glucose levels, causing hyperglycemia, which characterizes dysglycemia. Incorrect Options: Option A - Autoimmune positive + normoglycemia: This situation is typically seen in the early stages of type 1 diabetes (Stage 1), where there is an autoimmune response against beta cells, but blood glucose levels remain normal because there is still enough insulin production to maintain glucose homeostasis. Option B - Autoimmune negative + normoglycemia: This scenario is not associated with type 1 diabetes. In type 1 diabetes, the autoimmune process is the hallmark feature. If there are no autoimmune markers (autoantibodies), it suggests that type 1 diabetes is unlikely. Normoglycemia in such a context would also not indicate any beta cell damage typical of type 1 diabetes. Option D - Autoimmune negative + dysglycemia: This condition is more suggestive of type 2 diabetes or other forms of diabetes where autoimmune destruction of beta cells is not present. Dysglycemia without autoimmunity does not fit with the progression of type 1 diabetes, which is defined by the presence of autoimmune markers.

↑ *Back to this question in Part A*

@Neet_pg_bot

Q17: A patient presents with features of hyperthyroidism, characterized by decreased TSH levels and elevated free T3 and T4. Which of the following statements about this condition is NOT true? (Q844328)

A. The condition will improve simultaneously with improvement in the thyrotoxic state.

B. In 10% of cases, the condition is present without hyperthyroidism.

C. Severe disease can cause vision loss.

D. No specs criteria is used for this condition.



Correct Answer: A. The condition will improve simultaneously with improvement in the thyrotoxic state.

Explanation: Correct Option A - The condition will improve simultaneously with improvement in the thyrotoxic state: This statement is not true because the condition being referred to is likely Graves' ophthalmopathy (thyroid eye disease), which does not always improve simultaneously with the resolution of the thyrotoxic state. The eye manifestations can persist or even worsen independently of the thyroid hormone levels. Incorrect Options: Options B, C and D are true statements regarding hyperthyroidism and Graves' ophthalmopathy.

↑ *Back to this question in Part A*

@Neet_pg_bot

Q18: A young woman presents with weight loss, tachycardia, heat intolerance, and tremors. On examination, she has exophthalmos. What is the most likely diagnosis? (Q844329)

A. Parkinson's disease

B. Graves' disease

C. Addison's disease

D. Alzheimer's disease

Correct Answer: B. Graves' disease

Explanation: Correct Option B - Graves' disease: Graves' disease is an autoimmune disorder that leads to hyperthyroidism. Symptoms such as weight loss, tachycardia, heat intolerance, and tremors are all characteristic of an overactive thyroid. Exophthalmos (protrusion of the eyes) is a hallmark feature of Graves' disease, distinguishing it from other thyroid conditions. This makes Graves' disease the most likely diagnosis given the patient's symptoms and findings. Incorrect Options: Option A - Parkinson's disease: Parkinson's disease is a neurodegenerative disorder characterized by tremors, bradykinesia (slowness of movement), rigidity, and postural instability. It does not typically present with weight loss, heat intolerance, or exophthalmos, which are more suggestive of a hyperthyroid state. Option C - Addison's disease: Addison's disease is a disorder of adrenal insufficiency characterized by symptoms such as fatigue, weight loss, hyperpigmentation, hypotension, and salt cravings. It does not typically present with tachycardia, heat intolerance, tremors, or exophthalmos, which are indicative of hyperthyroidism rather than adrenal insufficiency. Option D - Alzheimer's disease: Alzheimer's disease is a neurodegenerative condition that primarily affects memory and cognitive function. It does not cause weight loss, tachycardia, heat intolerance, tremors, or exophthalmos, which are not associated with its clinical presentation.

↑ *Back to this question in Part A*

@Neet_pg_bot

Q19: In Type 1 Diabetes Mellitus, what characterizes stage 3 of beta-cell destruction? (Q844286)

A. Symptomatic hyperglycemia

B. Dysglycemic symptomatic

C. Normoglycemic symptomatic

D. Dysglycemic asymptomatic

Correct Answer: A. Symptomatic hyperglycemia

Explanation: Correct Option A - Symptomatic hyperglycemia : In Type 1 Diabetes Mellitus (DM), the progression of beta-cell destruction typically occurs in stages: Stage 1: Autoimmune destruction of beta cells, but no symptoms are present. Normal blood glucose levels. Stage 2: Progressive beta-cell destruction with dysglycemia (impaired glucose metabolism) but no symptoms of hyperglycemia yet. Stage 3: Significant beta-cell destruction leading to symptomatic hyperglycemia. Patients will present with symptoms such as polyuria, polydipsia, and weight loss due to elevated blood glucose levels. At Stage 3, the destruction is advanced enough that insulin production is insufficient to maintain normal glucose levels, resulting in symptomatic hyperglycemia. Incorrect Options: Option B - Dysglycemic symptomatic: Dysglycemia refers to abnormal glucose levels, which could be either high (hyperglycemia) or low (hypoglycemia). In Type 1 DM, Stage 3 is characterized specifically by symptomatic hyperglycemia, not just dysglycemia. Option C - Normoglycemic symptomatic: Normoglycemic means normal

blood glucose levels. In Stage 3 of Type 1 DM, the patient is not normoglycemic; instead, they are experiencing symptomatic hyperglycemia due to the loss of beta-cell function. Option D - Dysglycemic asymptomatic: Dysglycemia asymptomatic implies abnormal glucose levels without symptoms. In Stage 3 of Type 1 DM, patients are symptomatic due to hyperglycemia, so this option does not fit the stage described.

References:

.

↑ *Back to this question in Part A*

@Neet_pg_bot

Q20: Which of the following antidiabetic drugs can cause glucosuria? (Q860437)

A. Glimepiride

B. Exenatide

C. Acarbose

D. Empagliflozin

Correct Answer: D. Empagliflozin

Explanation: Empagliflozin belongs to the class of SGLT-2 inhibitors that work by blocking sodium-glucose cotransporter 2 in the proximal convoluted tubules of the nephron. This mechanism prevents the reabsorption of glucose and sodium back into the bloodstream, leading to glucosuria. The drug provides multiple benefits including reduced progression of chronic kidney disease, diuretic effects through sodium loss, and blood pressure reduction of 3-6 mmHg. However, these drugs are contraindicated in patients with eGFR <45 ml/min due to reduced efficacy and risk of urinary tract infections. Sodium-glucose co-transporter 2 (SGLT2) Inhibitors Examples Canagliflozin Dapagliflozin Empagliflozin Mechanism of Action Blocks reabsorption of glucose in the proximal convoluted tubule, promoting the excretion of sodium and glucose in urine Indications Reduce progression of chronic kidney disease (CKD) Diuretic effect, leading to sodium loss Reduces systolic blood pressure (SBP) by 3-6 mmHg Cardiorenal advantage CHF to decrease mortality with or without DM Side Effects Increased risk of urinary tract infections (UTIs) Glucosuria (leading to UTIs and vulvovaginal candidiasis) Dehydration (orthostatic hypotension) Weight loss Contraindications Not recommended if estimated glomerular filtration rate (eGFR) < 45 ml/min Use with caution in renal insufficiency (decreased efficacy with decreased GFR) Glimepiride (Option A) : This sulfonylurea medication works by stimulating insulin release from pancreatic beta cells, causing hypoglycemia and weight gain. It does not cause glucosuria as its mechanism of action is focused on increasing insulin secretion. Exenatide (Option B): This GLP-1 receptor agonist binds to GLP-1 receptor in pancreatic beta-cells in turn increasing insulin secretion and suppressing glucagon secretion. Its actions include delayed gastric emptying, induces early satiety (weight loss) & stabilizes atherosclerotic plaque (reduction in cardiovascular mortality). Its mechanism does not involve renal glucose reabsorption thus does not cause glucosuria. Acarbose (Option C) : This alpha-glucosidase inhibitor works by controlling post-prandial glucose spikes through reduced carbohydrate absorption in the intestine. It may cause abdominal bloating and diarrhea but

does not affect renal glucose handling or cause glucosuria.

References:

Harrison's Principles of Internal Medicine, 21st Edition, Page 3110- 3113

↑ *Back to this question in Part A*

@Neet_pg_bot

Q21: A diabetic patient came to the outpatient department with complaints of fatigue and frequent urination. On examination vitals are stable and an HbA1c is done. What is the cut-off percentage used for determining controlled diabetes? (Q860444)

A. 6.0

B. 6.5

C. 7.0

D. 7.5

Correct Answer: C. 7.0

Explanation: According to the American College of Physicians, the target HbA1c for determining controlled diabetes is <7.0% for adults with diabetes. This value represents optimal glycemic control, though it may be adjusted to <8.0% in elderly frail patients . Glycated Hemoglobin (HbA1c) effectively assesses overall glycemic control and is suitable for diagnosing diabetes in asymptomatic individuals. HbA1c prediction in undiagnosed individuals: < 5.7% : Normal 5.7% - 6.5% : Pre-diabetic > 6.5% : Diabetic For patients with existing diabetes, HbA1c is used to evaluate the degree of effective control on diabetes. The cutoffs recommended by ACP for monitoring effective control include: HbA1c < 7.0% Preprandial capillary plasma glucose between 80-130 mg/dL Postprandial capillary plasma glucose <180 mg/dL. 6.0 (Option A) , 6.5 (Option B) & 7.5 (Option D) are incorrect values according to ACP recommendation.

References:

https://www.acpjournals.org/doi/10.7326/M17-0939

↑ *Back to this question in Part A*

@Neet_pg_bot

Q22: Which of the following is associated with MEN-1 syndrome? (Q860448)

A. Parathyroid adenoma

B. Parotid tumor

C. Renal cell carcinoma

D. Pheochromocytoma

Correct Answer: A. Parathyroid adenoma

Explanation: MEN-1 syndrome, also known as Wermer syndrome , results from a mutation in the MEN-1 gene located on chromosome 11q13 . This gene mutation leads to uncontrolled mitosis in endocrine glands. The classic triad of MEN-1 includes parathyroid adenoma (the most common manifestation), pancreatic adenoma, and pituitary adenoma . Parathyroid involvement is typically the first and most frequent manifestation of this syndrome. Types of Multiple Endocrine Neoplasia MEN Type I MEN Type II MEN Type III MEN Type IV Cause Defect of chromosome 11q13 causing MEN 1 gene mutation Also called Wermer's syndrome Defect of chr.10 leading to mutation of RET gene Also called Sipple's syndrome Also called MEN II B , it is a variant of Type 2 MEN Defect of chr.12 causing CDKN1B gene Tumors Included Parathyroid adenoma (most common) It presents with primary hyperparathyroidism (↑ PTH and ↑ Ca) All the 4 glands can be included. Rx: Total/subtotal parathyroid resection Parathyroid adenoma (most common, and calcium can be normal) Medullary carcinoma thyroid (most common) Parathyroid adenoma (Presents as hypercalcemia) Pancreatic adenoma Presents as Gastrinoma or Zollinger-Ellison syndrome This leads to peptic ulcer disease in the duodenum, which is the leading cause of death in this type. Pheochromocytoma . Pheochromocytoma (Most important criterion for both MEN 2 and MEN 3): Presents with elevated blood pressure. Pituitary adenoma: Prolactinoma Pituitary adenoma: Prolactinoma, causing amenorrhea and Infertility Medullary thyroid carcinoma Calcitonin is the tumor marker present Cold nodules are seen on the thyroid scan Metastasis can be traced with PET scan Visible neck mass, causing dysphagia Rx - Prophylactic thyroidectomy Reproductive tract tumors Testicular tumors Neuroendocrine tumor (Cervix) Associated conditions Angio■broma Collagenoma Adrenocortical tumor Carcinoid tumors/Argenta■noma Pheochromocytoma (only in 1%) Congenital aganglionosis, Hirschsprung disease Marfanoid habitus Medullated corneal nerve ■bers Mucosal neuromas Megacolon and Multiple diverticulae Occasionally with Renal tumor Adrenal tumor Parotid tumor (Option B) : Parotid tumors are not part of the multiple endocrine neoplasia syndromes. These tumors affect the salivary glands and are not associated with endocrine disorders. Renal cell carcinoma (Option C) : While some renal manifestations may occur in MEN syndromes (such as in MEN IV), renal cell carcinoma is not a feature of MEN-1. It may be coincidentally present but is not a defining feature of the syndrome. Pheochromocytoma (Option D) : Pheochromocytoma is actually associated with MEN-II/Sipple syndrome & MEN-III, not MEN-1.

References:

Harrison's Principle of Internal Medicine, 21st Edition, Page 2983 - 2990

Davidson's Principles and Practice of Medicine, 24th Edition, Page 868, 869

↑ *Back to this question in Part A*

@Neet_pg_bot

Q23: All of the below are features of Conn's syndrome except? (Q860462)

A. Metabolic alkalosis

B. Metabolic acidosis

C. Hypertension

D. Muscle cramps

Correct Answer: B. Metabolic acidosis

Explanation: Metabolic acidosis is not a feature of Conn's syndrome. Conn’s syndrome (primary hyperaldosteronism) is caused by excess aldosterone , leading to increased Na■ reabsorption and increased K■ & H■ excretion in the distal nephron.This produces the classic triad: Hypertension (due to Na■ and water retention) Hypokalemia (→ muscle cramps, weakness) Metabolic alkalosis (due to loss of H■ ions) Conn Syndrome / Primary Hyperaldosteronism Definition Primary hyperaldosteronism characterized by excessive aldosterone secretion from adrenal glands with suppressed plasma renin Epidemiology Most common cause of secondary hypertension (6-20% of adult hypertensive patients) Higher prevalence in resistant hypertension (up to 30%) 2x more common in women Etiology Aldosterone-producing adenoma (50-60%) Bilateral idiopathic adrenal hyperplasia Aldosterone-producing adrenal carcinoma (1%) Familial hyperaldosteronism (Types 1-3) Pathophysiology ↑ Aldosterone → ↑ Na+ reabsorption → plasma volume expansion ↑ K+ excretion → hypokalemia Can lead to tissue inflammation and fibrosis in heart, kidneys, vasculature Clinical Features Resistant hypertension Muscle weakness/cramping Fatigue Headaches Polydipsia/polyuria NO edema (due to spontaneous natriuresis) Lab Findings ↓ K+ (can be normal in up to 38%) ↑ Na+ Metabolic alkalosis ↑ Urinary K+ excretion (>30 mmol/day) Suppressed plasma renin ↑ Aldosterone-to-renin ratio (ARR) Diagnostic Criteria Initial screening: ARR >40 Confirmatory tests: Salt loading test Fludrocortisone suppression test Captopril suppression test Imaging: CT scan for adenoma Adrenal venous sampling for lateralization Treatment Adenoma: Laparoscopic adrenalectomy Bilateral hyperplasia: Medical management Medical options: Spironolactone (first-line) Eplerenone Amiloride Prognosis Surgery: 30-60% cure rate for adenomas High morbidity/mortality if untreated May need long-term BP monitoring High-Yield Associations Normal K+ doesn't exclude diagnosis No edema despite hyperaldosteronism Screen all resistant hypertension cases

References:

Harrison's Principles of Internal Medicine, 21st Edition, Page 349, 350, 365, 2078, 2079, 2965, 2987, 3162, 3165.

↑ *Back to this question in Part A*

@Neet_pg_bot

Q24: A 45-year-old man presents to the outpatient department with symptoms of headache, renal stones, and abdominal pain. Serum calcium is low and PTH is high. Which of the following hormone and associated disease might be causing these symptoms? (Q840096)

A. Parathyroid and Primary hyperparathyroidism

B. Catecholamines and Pheochromocytoma

C. Thyroxine and Hypothyroidism

D. Mineral and bone disorders

Correct Answer: D. Mineral and bone disorders

Explanation: Correct Option: D) Mineral and bone disorders Low serum calcium with high PTH indicates secondary hyperparathyroidism , most commonly due to chronic kidney disease–related mineral and bone disorder (CKD-MBD) . This leads to bone pain, renal stones, abdominal discomfort, and headache due to disturbed calcium–phosphate metabolism and compensatory PTH rise. Parathyroid and Primary hyperparathyroidism (Option A): Primary hyperparathyroidism causes high calcium + high PTH , not low calcium + high PTH. Catecholamines and Pheochromocytoma (Option B): Causes episodic headache, hypertension, palpitations; not associated with low calcium or raised PTH . Thyroxine and Hypothyroidism (Option C): Hypothyroidism causes fatigue, weight gain, cold intolerance; does not cause high PTH or renal stones .

References:

.

↑ *Back to this question in Part A*

@Neet_pg_bot

Q25: A 45-year-old man presents to the outpatient department with proximal muscle weakness, purple stretch marks, obesity, and easy bruising. What is the underlying condition? (Q840099)

A. Hyperthyroidism

B. Hypercortisolism

C. Hyperparathyroidism

D. Hyperaldosteronism

Correct Answer: B. Hypercortisolism

Explanation: Correct Option B - Hypercortisolism: The presented scenario suggests Cushing syndrome with features like weight gain, purple striae, and proximal myopathy. Hypercortisolism is the underlying condition in Cushing syndrome. It's primarily caused by chronic over-production of cortisol by the adrenal glands, often due to adrenal or pituitary tumors. Pituitary-dependent cortisol excess, termed Cushing’s disease, accounts for about 80% of cases of Cushing syndrome. Incorrect Options: Options A, C & D are incorrect.

↑ *Back to this question in Part A*

@Neet_pg_bot

Q26: All of the following are criteria for diagnosis of diabetes ketoacidosis, except? (Q840103)

A. Serum glucose of more than 250 mg

B. Anion gap of more than 10-12

C. Serum bicarbonate less than 15 mmol

D. Serum potassium less than 3.5 mEq

Correct Answer: D. Serum potassium less than 3.5 mEq

Explanation: Correct Option D - Serum potassium less than 3.5 mEq: Serum potassium below 3.5 mEq can occur in diabetic ketoacidosis (DKA) but isn't part of diagnostic criteria. In DKA, patients are often potassium-depleted, yet plasma potassium levels may not fully indicate a total deficit. Initially, levels might even be elevated due to factors like water loss and potassium shifting. However, treatment can lead to a rapid drop in plasma potassium due to fluid dilution, insulin-induced movement into cells, and ongoing renal loss. Incorrect Options: Option A - Serum glucose of more than 250 mg: Serum glucose above 250 mg/dL is a diagnostic criterion for DKA. This leads to osmotic diuresis, causing dehydration and electrolyte loss, especially sodium and potassium. Option B - Anion gap of more than 10-12: An anion gap above 10-12 is a diagnostic criterion for DKA. It occurs because bicarbonate is replaced by β-hydroxybutyric acid and acetoacetic acid, reducing the sum of bicarbonate and chloride concentrations and raising the anion gap. Option C - Serum potassium less than 3.5 mEq: Serum bicarbonate below 15 mmol/L is a diagnostic criterion for DKA. Ketosis causes blood ketone accumulation, resulting in metabolic acidosis. This shift forces hydrogen ions into cells, displacing potassium ions.

↑ *Back to this question in Part A*

@Neet_pg_bot

Q27: Which of the following is the diagnostic test for carcinoid tumors? (Q860132)

A. 24-hour urinary catecholamines

B. Serum calcitonin levels

C. Serum chromogranin A

D. Urinary 5-hydroxyindoleacetic acid

Correct Answer: D. Urinary 5-hydroxyindoleacetic acid

Explanation: The clinical manifestations indicate that carcinoid tumors are neuroendocrine tumors that secrete serotonin, which is metabolized to 5-HIAA and excreted in urine. Diagnosis of Carcinoid Syndrome Diagnostic Method Details 5-HIAA Urine Test Primary diagnostic test 24-hour urine collection Measures serotonin metabolites Can be challenging if patient is consuming serotonin-rich foods (e.g., salmon, eggs) Somatostatin Scintigraphy Also known as OctreoScan Can confirm presence of somatostatin receptors Helps in tumor localization Used to predict response to somatostatin analogue therapy 68Ga-DOTATATE PET Scan More sensitive imaging technique Uses radioactive gallium-68 Helps predict response to treatment Particularly useful for NET imaging Chromogranin A Blood test biomarker Elevated in metastatic disease Should be interpreted with caution in patients with renal dysfunction, patients taking PPIs Not diagnostic alone, but helpful in monitoring Clinical Symptoms Flushing episodes (2-5 mins) Diarrhea Wheezing Heart valve problems Abdominal pain Telangiectasia 24-hour urinary catecholamines (Option A): This test is used to diagnose pheochromocytoma and other catecholamine-secreting tumors, not carcinoid tumors. Catecholamines are not characteristic of carcinoid syndrome. Serum calcitonin levels (Option B): This test is used to diagnose medullary thyroid carcinoma, which is a different type of neuroendocrine tumor. Calcitonin is unlikely to be elevated in carcinoid syndrome. Serum chromogranin A (Option C): While chromogranin A can be elevated in some neuroendocrine tumors, it is not specific for carcinoid tumors and is not the diagnostic test of choice. It may be used as a supplementary marker but not for primary diagnosis.

References:

Harrison's Principles of Internal Medicine, 21st Edition, Pages 668-669

↑ *Back to this question in Part A*

@Neet_pg_bot

Q28: Which of the following tests is the best for assessing long-term control of diabetes mellitus? (Q860233)

A. Glycosylated Hemoglobin

B. Glycated Albumin

C. Serum Fructosamine

D. Urine Sugar

Correct Answer: A. Glycosylated Hemoglobin

Explanation: Glycosylated Hemoglobin (HbA1c) is the gold standard for monitoring long-term glycemic control in diabetic patients . This test provides a reliable measure of average blood glucose levels over the preceding 2-3 months, corresponding to the lifespan of red blood cells. HbA1c testing is particularly valuable because it is not affected by daily fluctuations in blood glucose levels and does not require fasting . The test measures the percentage of hemoglobin molecules that have glucose attached to them, providing a more stable and accurate

reflection of overall glycemic control. It provides a more comprehensive view of glucose levels compared to other tests, with a diagnostic threshold of ≥ 48 mmol/mol (6.5%), making it ideal for early detection, particularly in patients with risk factors like obesity and family history. HbA1c evaluation: < 5.7% : Normal 5.7% - 6.5% : Pre-diabetic > 6.5% : Diabetic Other Investigations for Diabetes Mellitus: Blood Glucose Tests: Fasting Plasma Glucose (FPG) Measures glucose after an overnight fast. Diagnostic threshold: ≥ 126 mg/dL (7.0 mmol/L). Simple, cost-effective, and widely available. Random Plasma Glucose (RPG) Measures glucose at any time, irrespective of meals. Diagnostic threshold: ≥ 200 mg/dL (11.1 mmol/L). Useful for immediate diagnosis in symptomatic patients. Oral Glucose Tolerance Test (OGTT) Fasting glucose was measured, followed by a 75 g glucose drink, then re-measured after 2 hours. Diagnostic threshold: ≥ 200 mg/dL (11.1 mmol/L). More time-consuming; identifies impaired glucose tolerance. Glycated Albumin (Option B) measurement reflects average blood glucose levels over only 2-3 weeks due to albumin's shorter half-life of approximately 20 days. While useful for short-term monitoring, it doesn't provide the comprehensive long-term assessment that HbA1c offers. Serum Fructosamine (Option C) testing, similar to glycated albumin, provides information about glycemic control over the previous 2-3 weeks. This test measures glycated plasma proteins and is sometimes used when HbA1c results may be unreliable, such as in patients with hemoglobinopathies. Urine Sugar (Option D) testing is not reliable for assessing long-term glucose control as it is influenced by multiple factors including renal threshold, hydration status, and concurrent medications. Urine glucose appears only when blood glucose exceeds the renal threshold, making it an inadequate measure of overall glycemic control.

References:

Davidson’s Principles and Practice of Medicine, 24th Edition, Page 722, 726, 727, 728.

↑ *Back to this question in Part A*

@Neet_pg_bot

Q29: Which of the following anti-diabetic drug is recently approved to be used in patients with heart failure with low ejection fraction and reduced urine output? (Q857286)

A. Linagliptin

B. Empagliflozin

C. Pioglitazone

D. Degludec

Correct Answer: B. Empagliflozin

Explanation: : It is a DPP-4 inhibitor. The DPP 4 enzyme is responsible for the breakdown of incretins such as GLP-1. Pioglitazone (Option C): These drugs have been shown to cause dose-dependent fluid retention, hence this drug class is generally avoided in patients with heart failure. Degludec (Option D): Insulin degludec is a long-acting insulin used to treat hyperglycemia caused by type 1 and 2 diabetes mellitus.

References:

Harrison’s Principle of Internal Medicine, 21st Edition, Page: 3113.

↑ *Back to this question in Part A*

@Neet_pg_bot

Q30: A child is brought to the ER in an unconscious state after severe vomiting and abdominal pain episodes. HR = 100/min and BP=100/60 mm Hg. Work up shows: pH=7.2 Blood glucose 300 mg/dl Ketone 3+. What should be the best management? (Q857287)

A. Infusion of 0.05 – 0.1 U/kg dose insulin after 1 hour of IVF

B. 0.1 Unit/kg insulin stat followed infusion of 0.5 U- 0.1 U/kg dose insulin and IVF

C. 0.1 U/kg insulin subcutaneous stat followed by IVF

D. IVF followed by subcutaneous 0.1 U/kg insulin

Correct Answer: A. Infusion of 0.05 – 0.1 U/kg dose insulin after 1 hour of IVF

Explanation: - Infusion of 0.05 – 0.1 U/kg dose insulin after 1 hour of IVF: The clinical scenario here points to the diagnosis of diabetic ketoacidosis. Diagnostic parameters in an unconscious diabetic patient: Parameters Diabetic Ketoacidosis (DKA) pH (7.35-7.45) 6.8 - 7.3 $HCO3^{-}$ (22 to 26 meq/L) <18 Ketostix ++++ Plasma beta-hydroxybutyrate >2.5 RBS (mg/dL) 250 - 600 Plasma Osmolality (275 to 295 mOsm/kg) 300 - 320 Updated Management of Diabetic Ketoacidosis (ISPAD 2022): Contraindication of Insulin Drip: Insulin should be withheld if the serum potassium level is below 3.3 mmol/L. The target is to maintain serum potassium levels above 3.5 mmol/L (3.5 meq/L) to start the insulin drip. Hypokalemia can lead to diaphragmatic paralysis and potentially result in respiratory arrest.

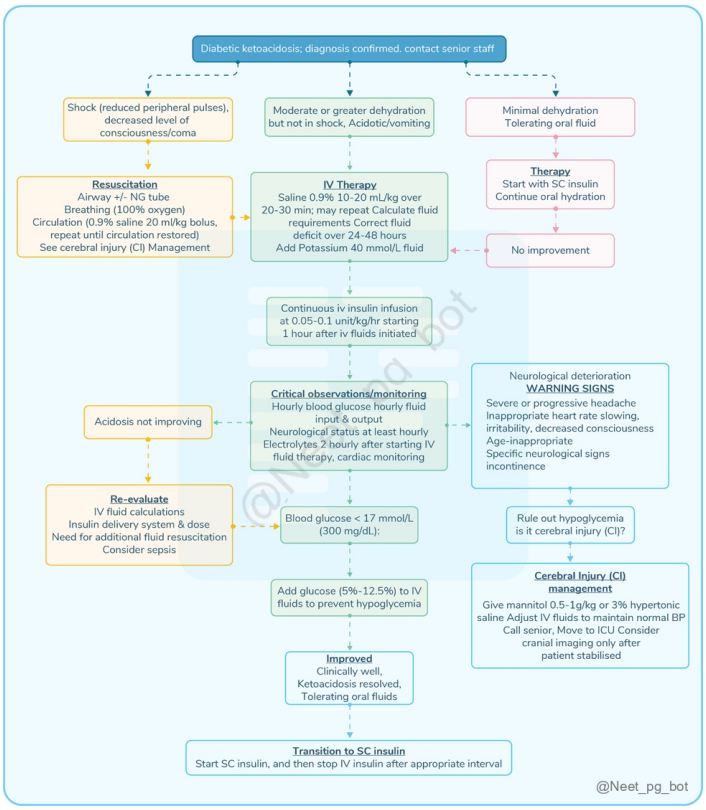

References:

Harrison’s Principles of Internal Medicine, 21st Edition, Page 3116,3117

Initial Potassium Replacement in Diabetic Ketoacidosis

Hypokalemic paralysis in a professional bodybuilder - PubMed

Management of adult diabetic ketoacidosis - PMC

Comparing the clinical effects of balanced electrolyte solutions versus normal saline in managing diabetic ketoacidosis

Adult Diabetic Ketoacidosis - StatPearls - NCBI Bookshelf

↑ *Back to this question in Part A*

@Neet_pg_bot

Q31: A 26-year-old female presents with palpitations, weight loss, tremors, sweating and diarrhoea. What is the next test that will help establish the diagnosis for this patient? (Q857288)

A. TSH and free T4

B. Anti Thyroid Peroxidase antibodies

C. Total T3

D. USG Neck

Correct Answer: A. TSH and free T4

Explanation: - TSH and free T4 The TSH and T4 are the primary screening tests for thyroid function, and low TSH and high free T4 levels indicate hyperthyroidism , which matches the symptoms described. Thyroid Function Test Workup: Initial Screening: TSH (Thyroid Stimulating Hormone) Normal range: 0.4-4.0 mIU/L Follow-up Tests (if TSH is abnormal): Free T4 (thyroxine) Free T3 (triiodothyronine) if T4 is normal but TSH is suppressed (Option C) Consider total T4 and T3 tests, but free hormone tests are preferred Interpretation of Results: Condition TSH Free T4 Free T3 Primary hypothyroidism ↑ ↓ ↓ Primary hyperthyroidism ↓ (<0.1 mIU/L) ↑ ↑ Subclinical hypothyroidism ↑ Normal Normal Subclinical hyperthyroidism ↓ Normal Normal Secondary hypothyroidism ↓ or Approximately normal ↓ ↓ T3 thyrotoxicosis ↓ Normal ↑ Additional Tests for Etiology: Anti-TPO (thyroid peroxidase) antibodies (Option B) Positive in 5-15% of euthyroid women, up to 2% of euthyroid men Present in almost all autoimmune hypothyroidism cases Present in up to 80% of Graves' disease cases TRAb (TSH receptor antibody) or TSI (Thyroid Stimulating Immunoglobulin) For Graves' disease diagnosis Used to predict remission after antithyroid drug treatment Important in pregnancy to assess the risk of fetal/neonatal thyrotoxicosis ■■■■■■■■■■■■■■■ Thyroglobulin (Tg) Elevated in all types of thyrotoxicosis except factitia Main use: follow-up of thyroid cancer patients post-treatment Imaging Studies: Thyroid Ultrasound (Option D) Indication: All patients with suspected thyroid nodules Evaluate nodule characteristics (size, composition, echogenicity, margins, calcifications) Fine Needle Aspiration (FNA) Biopsy: Indicated for suspicious nodules based on ultrasound criteria Ultrasound-guided FNA preferred for improved accuracy Radioactive iodine uptake scan: While useful in differentiating causes of hyperthyroidism (e.g., Graves' disease vs. thyroiditis), it is not the immediate next best step. It is the next step after TFT shows a hyperthyroid picture. Graves' disease: Enlarged gland, homogeneous increased uptake Toxic adenoma: Focal area of increased uptake, suppressed remainder Toxic multinodular goitre: Multiple areas of increased/decreased uptake Thyroiditis: Very low uptake Thyrotoxicosis factitia: Low uptake

References:

Harrison’s Principles of Internal Medicine, 21st Edition, Volume I, Page: 2931, 2932.

↑ *Back to this question in Part A*

@Neet_pg_bot

Q32: A patient with a history of rheumatoid arthritis (RA) presented to the ER with hypotension. She was on medication for RA but abruptly stopped them. On examination, her HR = 110 bpm, BP is 80/40 mm Hg, blood sugar = 50 mg/dl, Na = 130 meq/L and K = 6.0 meq/L. What should be the most appropriate management? (Q854674)

A. Fast IV fluids

B. Hydrocortisone

C. Dopamine infusion

D. Soda bicarbonate

Correct Answer: B. Hydrocortisone

Explanation: The scenario here is of Addisonian crisis (or adrenal crisis) that was triggered due to the abrupt cessation of medications for rheumatoid arthritis (glucocorticoids like prednisone). This is treated with intravenous hydrocortisone . Clinical features of adrenal crisis Circulatory shock Severe hypotension Hyponatremia Hyperkalemia Hypoglycemia Hypercalcemia Muscle cramps Nausea Vomiting Diarrhea Unexplained fever Precipitating factors: Other illnesses Surgery Infection Management of adrenal crisis: Correct volume depletion IV saline for correcting blood pressure and pulse Replace glucocorticoids IV hydrocortisone succinate 100 mg stat and 100 mg QID for first 12-24 hrs Parenteral hydrocortisone 50-100 mg IM QID till the patient can take it orally Correct metabolic abnormalities Acute hypoglycemia: IV 10% glucose Hyperkalemia: Usually corrected with volume replacement, otherwise needs specific treatment Identify and treat the underlying cause Acute precipitating factors like infection Adrenal or pituitary pathology Incorrect Options: Fast IV fluids (Option A) is one of the steps in management to correct the blood pressure and pulse but it is not the definitive treatment for Addisonian crisis which needs to be managed with IV hydrocortisone. Dopamine infusion (Option C) is not a definitive treatment for adrenal crisis and is used to treat low blood pressure, low heart rate, and cardiac arrest. Soda bicarbonate (Option D) is not indicated for adrenal crisis.

References:

Davidson’s Principles of and Practice of Medicine, 24th Edition, Page: 671, 672, 673.

↑ *Back to this question in Part A*

@Neet_pg_bot

Q33: Which of the following is not a component of metabolic syndrome? (Q854734)

A. LDL

B. Fasting glucose

C. Abdominal circumference

D. Blood pressure

Correct Answer: A. LDL

Explanation: HDL is the component of metabolic syndrome and not LDL . NCEP: ATPIII 2001 and Harmonizing Definition Criteria for the Metabolic Syndrome NCEP: ATP III 2001 Harmonizing Definition Three or more of the

following: Central obesity (Option C) : Waist circumference > 102 cm (males), > 88 cm (females) Hypertriglyceridemia: Triglyceride level ≥150 mg/dl or specific medication Low HDL cholesterol : <40 mg/dl for men and <50 mg/dl for women or specific medication Hypertension (Option D) : BP systolic ≥130 mmHg & diastolic ≥85 mmHg or specific medication Fasting plasma glucose level (Option B) ≥100 mg/dl or specific medication or previously diagnosed type II diabetes Three of the following: Men Waist circumference (cm) Women Waist circumference (cm) ≥94 (South Asian) ≥ 80 (South Asian) Fasting triglyceride level >150 mg/dL or specific medication HDL cholesterol level <40 mg/dL for men and <50 mg/dL for women or specific medication Blood pressure >130 mm systolic or >85 mm diastolic or previous diagnosis or specific medication Fasting plasma glucose level ≥100 mg/dL (alternative indication: drug treatment of elevated glucose levels)

References:

Harrison's Principles of Internal Medicine, 21st Edition, Page: 3151.

↑ *Back to this question in Part A*

@Neet_pg_bot

Q34: A female patient presents with severe restlessness, palpitations, and tremors to the emergency department. She is a known case of bronchial asthma. On examination, the neck looks swollen. Blood pressure is elevated, and tachycardia is noted. ECG shows atrial fibrillation. Which of the following drugs is used for immediate management in this patient? (Q855431)

A. Diltiazem

B. Propranolol

C. Esmolol

D. Propylthiouracil

Correct Answer: A. Diltiazem

Explanation: rrhythmias Precipitating factors Precipitating factors: Stress: Acute illnesses like stroke, trauma, diabetic ketoacidosis Surgery, commonly of the thyroid Infections Acute iodine load: Radioiodine treatment of a patient with partially or untreated hyperthyroidism Iodinated contrast agents Amiodarone administeration Treatment Management of the precipitating factors (digoxin, diuretics, & oxygen) IV fluids and ice pack Propylthiouracil (DOC) Methimazole/carbimazole Beta-blockers Corticosteroids Lugol's iodine/ sodium ipodate Propylthiouracil (PTU) (Option D): Propylthiouracil is used to inhibit the synthesis of thyroid hormones in thyroid storm and is the drug of choice for the management of thyroid storm. However, it should be given only after the rate of atrial fibrillation is controlled, as the primary goal in the acute setting is to stabilize the patient and manage the arrhythmia.

References:

Harrison's Principles of Internal Medicine, 21st Edition, Page: 2942. Goodman & Gillman's The Pharmacological Basis Of Therapeutics, 14th Edition, Page: 275. https://www.ncbi.nlm.nih.gov/pmc/articles/PMC1681414/ https://www.ncbi.nlm.nih.gov/books/NBK448095/

↑ *Back to this question in Part A*

@Neet_pg_bot

Q35: A 25-year-old male patient came with complaints of palpitations, sweating, and restlessness. He has a complaint of sweaty palms. Clinical findings are depicted in the image given below. What is the diagnostic finding seen in this patient? (Q855441)

A. Anti-thyroglobulin antibody

B. Anti-thyroid peroxidase antibody

C. Thyroid receptor antibody

D. Elevated ultrasensitive thyrotropin levels



@Neet_pg_bot

Correct Answer: C. Thyroid receptor antibody

Explanation: This patient's clinical presentation suggests Graves' disease, a form of hyperthyroidism. The symptoms, including palpitations, sweating, restlessness, and sweaty palms, are common in hyperthyroid states. The diagnostic finding in Graves' disease is elevated thyroid receptor antibodies. These antibodies, specifically thyroid-stimulating immunoglobulins (TSI), stimulate the thyroid gland, leading to excess production of thyroid hormones, resulting in hyperthyroid symptoms. Graves' Disease is an autoimmune disorder causing hyperthyroidism due to thyroid-stimulating immunoglobulins (TSI) that stimulate the thyroid gland, increasing

hormone production (T3 and T4). Clinical Features: Hyperthyroid symptoms: Palpitations, sweating, restlessness, weight loss, heat intolerance, tachycardia, hyperactivity, irritability. Graves' ophthalmopathy: Exophthalmos, lid retraction, lid lag, conjunctival injection, dry eyes, visual disturbances. Diagnosis: Elevated TSI and thyroid function tests showing elevated T3/T4 and suppressed TSH. Radioactive iodine uptake: Increased in Graves' disease. Management: Antithyroid drugs: Propylthiouracil (PTU) or methimazole to inhibit thyroid hormone production. Radioactive iodine (RAI): Ablates overactive thyroid tissue but does not treat ophthalmopathy. Surgical treatment: Thyroidectomy if needed for large goiters or refractory cases. Graves' ophthalmopathy: Managed with corticosteroids, radiotherapy, or orbital decompression surgery for severe cases. Signs in Grave’s ophthalmopathy Signs in Grave’s ophthalmopathy Dalrymple’s sign {{caption_text}} It is due to the contraction of Muller’s muscles Upper lid retraction M/C presenting sign Von Graefe’s sign/ Lid-lag/ Stare sign {{caption_text}} It is the inability to close the upper eyelid It is the earliest sign There is inadequate blinking leading to exposure keratitis Lid lag of the upper eyelid on downward gaze Enroth’s sign {{caption_text}} It is the fullness/ edema of the lower eyelids Gifford’s sign _ Difficulty in eversion of the upper eyelid Mobius sign _ Convergence weakness Griffith sign {{caption_text}} Lower lid lag on upward gaze Stellwag’s sign _ Incomplete and infrequent blinking Joffroy’s sign _ Lack of wrinkling of the forehead in superior gaze Gellineck sign _ Abnormal pigmentation of the upper eyelid Anti-thyroglobulin antibody (Option A) and Anti-thyroid peroxidase antibody (Option B): These antibodies are elevated in conditions such as autoimmune hypothyroidism (e.g., Hashimoto's thyroiditis). Elevated ultrasensitive thyrotropin (TSH) levels (Option D): TSH is typically low in hyperthyroid states like Graves' disease due to feedback inhibition, not elevated.

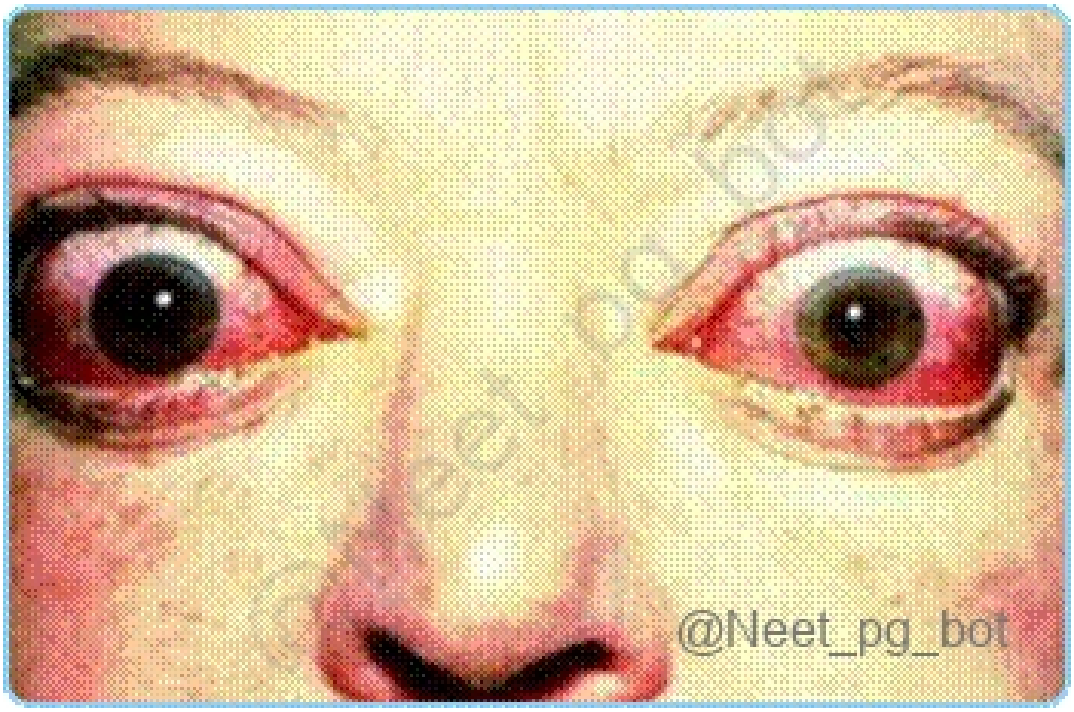







References:

Robbins and Cotran Pathologic Basis of Disease, 10th Edition, Page: 520, 521, 522. Davidson's Principle and Practice of Medicine, 24th Edition, Page: 634. Pubmed

https://www.ncbi.nlm.nih.gov/books/NBK582134/table/article-142674.table0/ https://eyewiki.org/Thyroid_Eye_Disease#:~:text=Eyelid%20retraction%20(Dalrymple's%20sign)%20is,bilateral%20axial%20proptosis%20(exophthalmos)

↑ *Back to this question in Part A*

@Neet_pg_bot

Q36: A patient came to medical OPD with complaints of polyuria. He has a history of undergoing total hypophysectomy. His Na + levels were found to be 155 mEq/L, and his urine osmolarity was 200 mOsm/L. What is the definitive management in this patient? (Q855498)

A. DDAVP for 2 weeks and then discontinue

B. DDAVP supplementation for lifelong

C. Upsetting of receptors, so no treatment required

D. Thiazides for 2 weeks

Correct Answer: B. DDAVP supplementation for lifelong

Explanation: DDAVP supplementation for lifelong This patient's clinical presentation and history are consistent with central diabetes insipidus (DI) , which results from insufficient vasopressin (antidiuretic hormone, ADH) secretion due to total hypophysectomy (removal of the pituitary gland). Key findings supporting this diagnosis include: Polyuria (excessive urination) and low urine osmolarity (200 mOsm/L) indicate dilute urine, characteristic of diabetes insipidus. Hypernatremia (Na■ = 155 mEq/L) suggests dehydration, commonly seen in DI due to impaired water retention. Definitive management for central diabetes insipidus due to total hypophysectomy is lifelong desmopressin (DDAVP) supplementation. DDAVP is a synthetic analogue of vasopressin that helps reduce urine output and prevent dehydration. This treatment is required for the patient to manage the symptoms of DI and maintain fluid balance. DDAVP for 2 weeks and then discontinue (Option A): This is not appropriate for complete hypophysectomy, where the deficiency of vasopressin is permanent. Short-term DDAVP would only be used in cases where the deficiency is transient (e.g., partial hypophysectomy). Upsetting of receptors, so no treatment required (Option C): In central diabetes insipidus, the issue is the lack of vasopressin, not receptor dysfunction. Without treatment, the patient would experience chronic dehydration and electrolyte imbalances. Thiazides for 2 weeks (Option D): Thiazide diuretics may be used in nephrogenic diabetes insipidus (due to kidney resistance to ADH), but they are not effective in central DI, where the problem lies in vasopressin production, not renal response.

References:

Harrison's Principles of Internal Medicine, 21st Edition, Page: 2920-2922.
https://www.ncbi.nlm.nih.gov/books/NBK470458/

↑ *Back to this question in Part A*

Q37: A 29-year-old male patient presents with coarse facial features and gradual enlargement of the hands and feet for the past decade. He has been diagnosed with acromegaly based on elevated levels of IGF-1 and growth hormone that did not suppress after a 75 g glucose challenge test. What drug is recommended for treatment? (Q858019)

A. Lanreotide depot formulation

B. Terlipressin

C. Ketoconazole

D. Leuprolide

Correct Answer: A. Lanreotide depot formulation

Explanation: cromegaly Surgical Treatment Transsphenoidal surgical resection is the preferred treatment, especially for those with GH-secreting adenomas. Post-Surgery: Improvement in soft tissue swelling and normalization of GH levels typically occur shortly after surgery IGF-1 levels normalize within 3-4 days. There is a 10% recurrence rate of acromegaly years later, and up to 15% of patients may develop hypopituitarism. Medical therapy Preferred in medical therapy if curative surgery is not feasible or if GH fails to decrease post resection Somatostatin Receptor Ligands (SRLs): Long-acting injectable forms (octreotide, lanreotide) . Normalizes GH and IGF-1 levels in about 50% of patients. Side Effects : GI disturbances, transient nausea, and gallbladder issues. GH receptor antagonist: Pegvisomant blocks peripheral GH receptors, normalizing IGF-1 levels in about 70% of patients, though GH levels remain elevated. It is administered through daily subcutaneous injections and is used for recurrences or poor responses to SRLs. Dopamine Agonists: High doses of cabergoline can provide modest GH suppression. Radiation Therapy External beam radiation therapy or stereotactic techniques are considered for patients not achieving biochemical control through surgery or medical therapy. Terlipressin (Option B): Terlipressin is a synthetic vasopressin analog used primarily for the treatment of hepatorenal syndrome and bleeding esophageal varices. It has no role in the treatment of acromegaly as it does not affect GH secretion or action. Ketoconazole (Option C): Ketoconazole is an antifungal medication. While it has been used off-label for some endocrine conditions (such as adrenal hypercortisolism), it is not indicated for acromegaly management as it does not affect GH or IGF-1 levels. Leuprolide (Option D) : Leuprolide is a gonadotropin-releasing hormone (GnRH) agonist commonly used for the treatment of conditions such as prostate cancer and endometriosis. It does not have any effect on GH secretion and is therefore not effective in treating acromegaly.

References:

Harrison’s Principles of Internal Medicine, 21st Edition, Page 2912, 2913, 2914

↑ *Back to this question in Part A*

Q38: A patient presents with complaints of sudden onset headache, palpitation, and profuse sweating. The patient has had multiple similar episodes in the past. During these episodes, the patient's blood pressure is elevated. A 24-hour urine metanephrine is elevated. What is the most likely diagnosis? (Q858021)

A. Addison's disease

B. Renal artery stenosis

C. Pheochromocytoma

D. Hyperthyroidism

Correct Answer: C. Pheochromocytoma

Explanation: T scan of the abdomen and pelvis to locate the tumor. {{caption_text}} 18F-FDG PET scanning is recommended for metastatic disease. MIBG scintigraphy Somatostatin receptor scintigraphy Gallium DOTATATE PET scanning {{caption_text}} Differential Diagnosis Hyperthyroidism Renal artery stenosis Hyperaldosteronism Cardiomyopathy Postural tachycardia syndrome (POTS) Addison's disease (Option A): Addison's disease is primary adrenocortical failure and presents with symptoms like fatigue, weight loss, low blood pressure, and skin hyperpigmentation. While adrenal crisis can cause symptoms such as headache and sweating, it does not cause an episodic elevation of blood pressure and is characterized by hypotension rather than hypertension. Also elevated metanephrines is not a finding in Addison’s disease. Renal artery stenosis (Option B): Renal artery stenosis can lead to high blood pressure but does not cause sudden onset headaches, palpitation, and profuse sweating. An elevated 24-hour urine metanephrine is not associated with renal artery stenosis as this condition affects the renovascular system rather than catecholamine production. Hyperthyroidism (Option D): Hyperthyroidism symptoms include weight loss, increased appetite, tremors, heat intolerance, palpitations, and sweating. However, an elevated 24-hour urinary metanephrine is not associated with hyperthyroidism, and the symptoms are typically continuous rather than episodic.



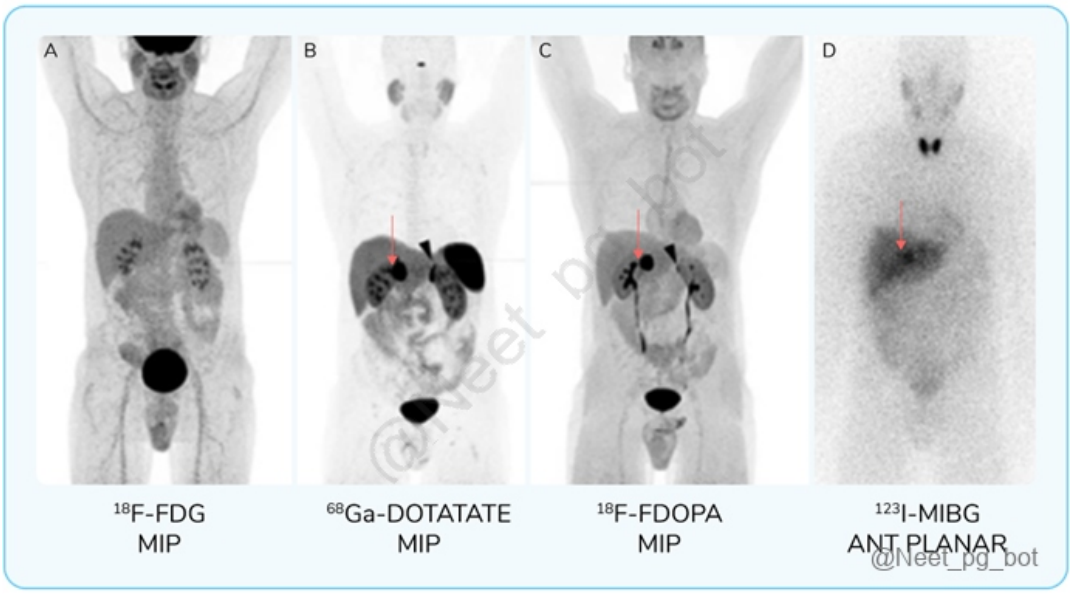

References:

Harrison's Principles of Internal Medicine, 21st Edition, Page 2976-2979.

↑ *Back to this question in Part A*

@Neet_pg_bot

Q39: In a 60-year-old male, what is the primary etiology typically associated with Cushing's disease? (Q858034)

A. Small-cell lung cancer

B. Adrenal tumor

C. Ectopic ACTH syndrome

D. Pituitary microadenoma

Correct Answer: D. Pituitary microadenoma

Explanation: ushing's syndrome is a collection of symptoms resulting from prolonged exposure to high levels of glucocorticoids. Cushing's disease specifically refers to Cushing's syndrome caused by a pituitary corticotrope adenoma. It is relatively rare, but mild cases may be more common, particularly among those with symptoms like central obesity, type 2 diabetes and osteoporosis. {{caption_text}} Causes: Cushing's syndrome can be caused by various factors, categorised as ACTH-dependent or ACTH-independent. I) ACTH-dependent Cushing's Syndrome accounts for approximately 90% of cases. Cushing's disease (ACTH-producing pituitary adenoma) is the most common cause. Ectopic ACTH syndrome occurs when a non-pituitary tumour secretes ACTH . II) ACTH-independent Cushing's Syndrome constitutes the remaining 10% of cases. Adrenocortical adenoma is the most prevalent cause, accounting for 5–10% of all cases. Rare causes include: Primary bilateral macronodular adrenal hyperplasia (PBMAH) Primary pigmented nodular adrenal disease (PPNAD) McCune-Albright syndrome Small-cell lung cancer (Option A) can produce ACTH or ACTH-like substances, resulting in paraneoplastic Cushing's syndrome. However, it is not the most common cause of Cushing's disease in an elderly patient. Small-cell lung cancer typically presents with additional respiratory symptoms and a more rapid onset of hypercortisolism features. Adrenal tumor (Option B) can cause Cushing's syndrome through autonomous cortisol production by either an adenoma or carcinoma. However, these tumors bypass the pituitary-adrenal axis and typically suppress ACTH levels, unlike the elevated ACTH seen in Cushing's disease caused by a pituitary microadenoma. Ectopic ACTH syndrome (Option C) occurs when non-pituitary tumors (such as lung, pancreas, or thymus) produce ACTH. While this is a recognized cause of Cushing's syndrome, it is less common than pituitary microadenomas as the primary cause of Cushing's disease in older adults. Ectopic ACTH syndrome typically presents with more rapid onset and severe metabolic derangements.



Clinical features of Cushing's syndrome. A. Note central and broad, purple stretch marks (B. close-up). C. Note thin and brittle skin in an elderly patient with Cushing's syndrome. D. Hyperpigmentation of the knuckles in a patient with ectopic adrenocorticotropioc hormone (ACTH) excess.

@Neet_pg_bot

References:

Harrison's Principles of Internal Medicine, 21st Edition, Page 3000- 3008

↑ *Back to this question in Part A*

@Neet_pg_bot

Q40: A 30-year-old female patient presented with bone pain and recurrent episodes of renal colic. Her family reported a history of abnormal behavior. Work up shows elevated serum calcium, low phosphate and elevated SAP. Which of the following is best for further work up of this patient? (Q858035)

A. MRI neck

B. Tc-99m MIBI stress test

C. Sestamibi SPECT /CT

D. CT scan of abdomen

Correct Answer: C. Sestamibi SPECT /CT

Explanation: T: This patient has features of primary hyperparathyroidism—bone pain (“bones”), renal colic (“stones”), neuropsychiatric symptoms (“psychiatric overtones”), with ↑ serum calcium, ↓ phosphate, and ↑ serum alkaline phosphatase. After biochemical confirmation, the best test for further work-up is the localization of the parathyroid adenoma. Tc-99m sestamibi SPECT/CT is the most sensitive and specific modality as it combines functional imaging with precise anatomical localization. Incorrect Options: Option A - MRI neck: MRI can identify parathyroid lesions, but it is less sensitive than sestamibi SPECT/CT and is usually reserved when sestamibi is negative or equivocal. Option B - Tc-99m MIBI stress test: This test is used for myocardial perfusion imaging in ischemic heart disease, not for parathyroid localization. Option D - CT scan of abdomen: CT abdomen may detect renal stones or nephrocalcinosis, which are complications, but it does not help localize parathyroid adenoma.

References:

Harrison’s Principles of Internal Medicine, 21st Edition, Volume I, Page 31776-3178.

Davidson’s Principles and Practice of Medicine, 24th Edition, Page 663, 664.

↑ *Back to this question in Part A*

@Neet_pg_bot

Q41: Which medication is recommended as the primary treatment for high blood sugar in a 19-year-old woman with a medical history of type 1 diabetes mellitus, who has been brought to the emergency room due to symptoms of confusion, vomiting, and abdominal pain, and subsequently diagnosed with diabetic ketoacidosis? (Q793941)

A. Regular insulin

B. Lente insulin

C. Glyburide

D. 70/30 insulin

Correct Answer: A. Regular insulin

Explanation: In the management of DKA (diabetic ketoacidosis), the main goal is to lower the blood glucose level and correct the acid-base and electrolyte imbalances. Regular insulin is the drug of choice for the management of hyperglycemia in DKA. It is a fast-acting insulin that is given intravenously and has a rapid onset of action, which helps to lower the blood glucose level quickly. Incorrect choices: Option b: Lente insulin is a combination of short-acting and long-acting insulin, which is used for the management of type 1 and type 2 diabetes mellitus. It has a delayed onset of action and is not effective for the rapid correction of hyperglycemia in DKA. Option c: 70/30 insulin is a combination of intermediate-acting and short-acting insulin, which is used for the management of type 1 and type 2 diabetes mellitus. It is not appropriate for the rapid correction of hyperglycemia in DKA. Option d: Glyburide is an oral hypoglycemic agent that is used for the management of type 2 diabetes mellitus. It works by stimulating the release of insulin from the pancreas. It is not appropriate for the management of DKA as

it does not lower the blood glucose level quickly enough to be effective in the treatment of this condition.

↑ *Back to this question in Part A*

@Neet_pg_bot

Q42: Which of the following is seen in MEN 2B syndrome? (Q855719)

A. Café au lait spot

B. Medullary thyroid carcinoma

C. Parathyroid adenoma

D. Optic nerve glioma

Correct Answer: B. Medullary thyroid carcinoma

Explanation: Multiple Endocrine Neoplasia (MEN) is a group of genetic syndromes (Autosomal Dominant) characterized by the development of tumors in multiple endocrine glands. Diagnostic criteria for MEN is Clinical features of 2 or more associated tumors Notable Family history Confirmation by genetic analysis. Types of Multiple Endocrine Neoplasia MEN Type I (Wermer's syndrome) MEN Type II (Sipple's syndrome) MEN Type III (MEN II B) MEN Type IV Cause Defect of chr.11q13 causing MEN 1 gene mutation Defect of chr.10 leading to mutation of RET gene Variant of Type 2 MEN Defect of chr.12 causing CDKN1B gene Tumors Included Parathyroid adenoma (m/c) Enteropancreatic adenoma Pituitary adenoma Medullary thyroid carcinoma (m/c) Pheochromocytoma Parathyroid adenoma (Option C) (Calcium can be normal) Medullary thyroid carcinoma (m/c) Pheochromocytoma (high blood pressure) Parathyroid adenoma (Presents as hypercalcemia) Pituitary adenoma Reproductive tract tumors Testicular tumors Neuroendocrine tumor (Cervix) Associated conditions Angio■broma Collagenoma Adrenocortical tumor Carcinoid tumors/ Argenta■noma Pheochromocytoma (only in 1%) Bronchopulmonary NET Thymic NET Gastric NET Lipomas Meningiomas Congenital aganglionosis, Hirschsprung disease Marfanoid habitus Medullated corneal nerve ■bers Mucosal neuromas Megacolon and Multiple diverticulae Renal tumor Adrenal tumor Café au lait spots (Option A) are light brown patches on the skin and are commonly seen in conditions such as neurofibromatosis. Optic nerve gliomas (Option D) are not typically associated with MEN 2B syndrome. They are more commonly seen in neurofibromatosis type 1.

References:

Harrison's principle of internal medicine, 21st Edition, Page 2983 - 2990

Davidson's Principles and Practice of Medicine, 24th Edition, Page 868, 869

↑ *Back to this question in Part A*

@Neet_pg_bot

Q43: Which of the following is a characteristic feature of Kallmann syndrome? (Q855313)

A. Anosmia

B. Syndactyly in males

C. Precocious puberty in females

D. White forelock

Correct Answer: A. Anosmia

Explanation: Kallmann syndrome results from defective hypothalamic gonadotropin-releasing hormone synthesis and is associated with anosmia or hyposmia due to olfactory bulb agenesis or hypoplasia. Pathophysiology: Kallmann syndrome results from defective synthesis of hypothalamic gonadotropin-releasing hormone (GnRH). It is often accompanied by anosmia or hyposmia due to agenesis or hypoplasia of the olfactory bulb. This defect occurs due to mutations that impair the embryonic migration of GnRH neurons from the olfactory placode to the hypothalamus. Associated Features: Neurological and Physical Abnormalities: Anosmia or hyposmia Color blindness Optic atrophy Nerve deafness Cleft palate Cryptorchidism Renal abnormalities Mirror movements (neurological) Genetic Basis: Initial discovery: X-linked KAL gene mutations. Other genetic mutations include autosomal recessive (e.g., GPR54, KISS1) and dominant (e.g., FGFR1) mutations. Additional genes: GNRH1, PROK2, PROKR2, CHD7, PCSK1, FGF8, NELF, WDR11, TAC3, TACR3, SEMA3E. Some cases involve oligogenic mutations where multiple gene mutations contribute to the phenotype. Clinical Presentation: Males: Delayed puberty, hypogonadal features (e.g., micropenis, due to low testosterone during infancy). Females: Primary amenorrhea and lack of secondary sexual development. Low levels of luteinizing hormone (LH), follicle-stimulating hormone (FSH), and sex steroids (testosterone or estradiol). Diagnosis: Typically, it is a diagnosis of exclusion after ruling out other causes of hypothalamic-pituitary dysfunction. Repetitive GnRH administration restores pituitary gonadotropin responses, indicating a hypothalamic defect. Treatment: Males: Long-term human chorionic gonadotropin (hCG) or testosterone therapy to induce pubertal development and secondary sex characteristics. Females: Cyclic estrogen and progestin therapy to induce secondary sexual development. Fertility Restoration: Administration of gonadotropins or pulsatile GnRH delivery via a portable infusion pump. Syndactyly in males (Option B): Associated with Apert or Poland syndromes, not Kallmann syndrome. Precocious puberty in females (Option C): Kallmann syndrome causes delayed puberty, not precocious puberty, due to deficient GnRH secretion. White forelock (Option D): A white forelock (poliosis) is a feature of Waardenburg syndrome, a genetic disorder associated with sensorineural hearing loss, pigmentary abnormalities, and dystopia canthorum but not Kallmann syndrome.

References:

Harrison's Principles of Internal Medicine, 21st edition, Page 2896, 2897

↑ *Back to this question in Part A*

@Neet_pg_bot

Q44: What would be the most suitable course of action for managing a 65-year-old male who presented with symptoms of weakness, lethargy, excessive cold intolerance, and slow ankle jerk? His thyroid function test (TFT) revealed a TSH level of 16 Mu/L (normal range: 0.4 - 4.0 mu / l), T4 level of 0.3 ng/dl (normal range: 0.6 - 1.6 ng / dl), and T3 level of 70 pg /dl. (Q857050)

A. Start levothyroxine at 100 micrograms and decrease the dose gradually

B. Start levothyroxine at 25 micrograms and increase the dose gradually

C. Start levothyroxine at 25 micrograms and decrease the dose gradually

D. Give T3 and T4 drugs simultaneously

Correct Answer: B. Start levothyroxine at 25 micrograms and increase the dose gradually

Explanation: Low T3 and T4 valves with high TSH and given clinical features suggests that this could be a case of hypothyroidism . The most appropriate management for primary hypothyroidism is to initiate treatment with levothyroxine , a synthetic form of thyroid hormone. The initial dose of levothyroxine should be low and gradually increased until the patient reaches the optimal replacement dose. Starting with a dose of 25 micrograms is a common practice in such cases. Clinical Features of Hypothyroidism: Fatigue, weakness and increased sleep Cold intolerance, Weight gain Dry, coarse skin, Hair loss Constipation Depression and cognitive impairment Menstrual irregularities and infertility Bradycardia Myxedema Hoarse voice Carpal tunnel syndrome, Slow reflexes Goiter, Anemia, Hypercholesterolemia Thyroid Function Test : TSH (Thyroid Stimulating Hormone) Normal range: 0.4-4.0 mIU/L Interpretation of Results: Condition TSH Free T4 Free T3 Primary hypothyroidism ↑ ↓ ↓ Primary hyperthyroidism ↓ (<0.1 mIU/L) ↑ ↑ Subclinical hypothyroidism ↑ Normal Normal Subclinical hyperthyroidism ↓ Normal Normal Secondary hypothyroidism ↓ or Approximately normal ↓ ↓ T3 thyrotoxicosis ↓ Normal ↑ Treatment of hypothyroidism: Levothyroxine - 1.6 µg/kg to be started Available as 25 µg / 50 µg / 88 µg / 100 µg If the dose is >100µg, it increases O2 consumption resulting in angina. Hence, careful titration of dose increments should be done.

References:

Harrison’s Principles of Internal Medicine, 21st edition, Page 2931- 2935

↑ *Back to this question in Part A*

@Neet_pg_bot

Q45: Fulminant diabetes mellitus is seen in? (Q857056)

A. Diabetic ketoacidosis

B. Coxsackie B virus

C. Non ketonic hyperosmolar coma

D. Autoimmune pancreatitis

Correct Answer: B. Coxsackie B virus

Explanation: Fulminant diabetes mellitus is associated with coxsackie B virus infection . Fulminant Diabetes: A rapidly progressing subtype of type 1 diabetes, leading to severe hyperglycemia and ketoacidosis within a short time. Pathogenesis: Exact cause unclear but likely involves genetic factors (HLA genes, especially DR4-DQ4) and viral infections (coxsackieviruses A4, A5, A6, B1 , rotavirus, cytomegalovirus, Epstein-Barr virus, human herpes virus (HHV)-6, and HHV-7) Clinical Features: Rapid onset: Average duration of hyperglycemic symptoms is 4 days. Preceding symptoms: Common-cold-like symptoms and gastrointestinal symptoms are frequent. Near-normal glycated hemoglobin (HbA1c): Despite severe hyperglycemia and ketoacidosis. Absent C-peptide levels: Indicating no residual insulin secretion. No autoantibodies against pancreatic β-cells: Unlike classic type 1 diabetes. Elevated pancreatic enzyme levels. Possible association with pregnancy. Diagnosis: Based on rapid progression of hyperglycemia, ketoacidosis, and the above clinical features. Treatment: Immediate management of diabetic ketoacidosis (DKA) with: Intravenous saline infusion. Regular insulin therapy. Long-term insulin therapy: Continuous subcutaneous insulin infusion (CSII) or multiple daily injections (MDI). Prognosis: Without immediate treatment, death can occur within 24 hours. Early recognition and prompt intervention are critical for survival. Diabetic ketoacidosis (Option A) (DKA) is a serious complication of diabetes, characterized by hyperglycemia, ketone production, and metabolic acidosis. However, it is a consequence rather than a cause of fulminant diabetes. Non-ketotic hyperosmolar coma (Option C) is a life-threatening complication of diabetes, marked by extremely high blood sugar and severe dehydration. Unlike fulminant diabetes, it is typically seen in type 2 diabetes. Autoimmune pancreatitis (Option D) is a rare form of chronic pancreatitis caused by an autoimmune reaction. While it can lead to endocrine dysfunction, it does not cause the rapid and severe destruction of β-cells seen in fulminant type 1 diabetes.

References:

Harrison’s Principles of Internal Medicine, 21st Edition, Page 3095

https://academic.oup.com/jcem/article/108/12/e1473/7194776

https://www.nature.com/articles/ncpendmet0351

↑ *Back to this question in Part A*

@Neet_pg_bot

Q46: A comatose elderly patient with a weight of approximately 70 kilograms is presented to the emergency department. During examination, it was determined that the patient's serum glucose levels were 500mg/dL, arterial pH is 7.30, and there is an elevation in plasma ketones levels. However, the serum potassium levels are within the normal range. In order to treat this patient, which of the following should be added to the saline solution? (Q857668)

A. Insulin

B. Bicarbonate

C. Potassium

D. 14 units of regular insulin intravenously

Correct Answer: A. Insulin

Explanation: The patient's clinical features suggest diabetic ketoacidosis (DKA), a potentially life-threatening complication of uncontrolled diabetes. Insulin is the mainstay of treatment in DKA as it helps lower blood glucose levels and suppresses ketone production. Updated Management of Diabetic Ketoacidosis (ISPAD 2022): {{caption_text}} Contraindication of Insulin Drip: Insulin should be withheld if the serum potassium level is below 3.3 mmol/L. The target is to maintain serum potassium levels above 3.5 mmol/L (3.5 meq/L) to start the insulin drip. Hypokalemia can lead to diaphragmatic paralysis and potentially result in respiratory arrest. Bicarbonate (Option B): It is not indicated in this patient because DKA treatment requires bicarbonate only if pH < 7.0 , and his pH is 7.33. Potassium (Option C) : S upplementation is not needed initially since his K■ is normal, but levels must be closely monitored , as insulin therapy can cause hypokalemia. 14 units of regular insulin intravenously (Option D) The exact insulin dose (e.g., 14 units IV) cannot be determined from the information provided; insulin in DKA is given as an IV bolus followed by continuous infusion , titrated to clinical response.

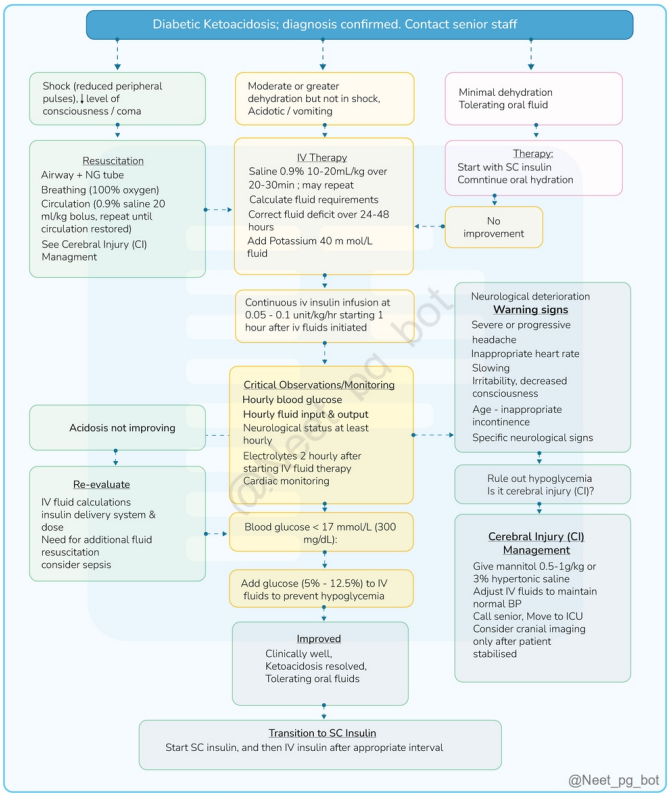

References:

Harrison’s Principles of Internal Medicine, 21st edition, Page 3116, 3117

Initial Potassium Replacement in Diabetic Ketoacidosis

Hypokalemic paralysis in a professional bodybuilder - PubMed

Management of adult diabetic ketoacidosis - PMC

Comparing the clinical effects of balanced electrolyte solutions versus normal saline in managing diabetic ketoacidosis

Adult Diabetic Ketoacidosis - StatPearls - NCBI Bookshelf

↑ *Back to this question in Part A*

@Neet_pg_bot

Q47: Addison's disease is characterized by all of the following symptoms except? (Q857672)

A. Hyperglycemia

B. Hyponatremia

C. Hyperkalemia

D. Hypotension

Correct Answer: A. Hyperglycemia

Explanation: Individuals with Addison's disease may experience hypoglycemia (Not Hyperglycemia) (low blood sugar) due to the inadequate production of cortisol, a hormone involved in regulating blood sugar levels. Addison's disease refers to primary adrenocortical failure . Etiology Autoimmune: M/C/C Worldwide Sporadic Polyglandular syndromes Tuberculosis: M/C/C in India Histoplasmosis HIV/AIDS Metastatic carcinoma Bilateral adrenalectomy Clinical features Glucocorticoid insufficiency: Weight loss, anorexia, malaise, weakness, nausea, vomiting, diarrhea or constipation, postural hypotension, shock, hypoglycemia, hyponatremia (Option B) (dilutional), hypercalcemia Mineralocorticoid insufficiency: Hypotension (Option D) , shock, hyponatremia, hyperkalemia (Option C) ACTH excess: Pigmentation Adrenal androgen insufficiency: Decreased body hair and loss of libido, especially in females

References:

Davidson's Principles and Practice of Medicine, 24th edition, pages 671-672

↑ *Back to this question in Part A*

@Neet_pg_bot

Q48: What is the preferred medication for treating Hyperthyroidism during the second trimester of pregnancy? (Q857684)

A. Propyl Thiouracil

B. Carbimazole

C. Sodium iodide

D. Radioactive iodine

Correct Answer: B. Carbimazole

Explanation: Carbimazole is the preferred medication for treating hyperthyroidism during the second trimester of pregnancy . Carbimazole is a thyroid peroxidase inhibitor that has higher potency and longer half life than propylthiouracil. However, it crosses the placenta easily, and can cause aplasia cutis in the fetus. For this reason, Carbimazole is not administered during the 1st trimester. Management of Hyperthyroidism in Pregnancy Medical Management First Trimester: Propylthiouracil 100-300mg/day (three times daily) Mechanism: Inhibits hormone synthesis + Thyroxine to Triiodothyronine conversion Second/Third Trimester: Methimazole 5-15mg/day (once daily) Monitoring: Thyroid Function Tests every 2-4 weeks Thyroid Stimulating Hormone Receptor Antibodies: 18-22 weeks, 30-34 weeks Target: Free Thyroxine upper normal, Thyroid Stimulating Hormone slightly low Thyroid Storm Protocol Propanolol Potassium Iodide/Lugol's solution (60 minutes post-antithyroid drugs) Propylthiouracil/Methimazole administration Glucocorticoids Intensive care support Mortality: 20-30% if untreated Teratogenicity Methimazole Embryopathy: Aplasia cutis Choanal/esophageal atresia Dysmorphic facies PTU Associated: Isolated anomalies Situs inversus Renal tract malformations Contraindications Radioactive iodine First trimester thyroidectomy Fetal Surveillance Ultrasound markers: Thyroid dimensions Fetal heart rate (>160/min significant) Growth parameters Hydrops features Bone maturation Propyl Thiouracil (Option A) : While propylthiouracil is the drug of choice during the first trimester of pregnancy due to lower risk of birth defects, it is not the preferred option during the second trimester. The switch to carbimazole is recommended after the first trimester due to its better efficacy and safety profile. Sodium iodide (Option C) : This medication is contraindicated during pregnancy as it can cross the placenta and affect fetal thyroid function. It can cause fetal hypothyroidism and goiter formation. Radioactive iodine (Option D) : Radioactive iodine is absolutely contraindicated during pregnancy as it readily crosses the placenta and can affect the fetal thyroid gland, potentially causing miscarriage or serious developmental issues. It should never be used during any stage of pregnancy.

References:

Harrison’s Principles of Internal Medicine, 21st Edition, Volume I, Page 2938.

↑ *Back to this question in Part A*

@Neet_pg_bot

Q49: A 30-year-old female patient came to the outpatient department with complaints of neck swelling. She gives a history of weight loss and palpitations. On examination,

she has exophthalmos and a diffusely enlarged thyroid gland. What are the essential investigations that should be done for the patient? Thyroid scan Fine needle aspiration cytology (FNAC) Thyroid function tests Ultrasound of neck Anti-thyroid antibody (Q855715)

A. 1,2,3,4 and 5

B. 1,3,5 only

C. 3,4,5 only

D. 1,3,4 and 5 only

Correct Answer: D. 1,3,4 and 5 only

Explanation: The patient presents with diffuse goiter, weight loss, palpitations, and exophthalmos —classic features of Graves' disease . Essential investigations include: Thyroid Function Tests → confirm hyperthyroidism (↓TSH, ↑T3/T4). Ultrasound neck → shows diffuse enlargement and increased vascularity ("thyroid inferno"). Thyroid scan → diffuse increased uptake, differentiates Graves from thyroiditis. Anti-thyroid antibodies → TRAb/TPO antibodies support autoimmune etiology. FNAC is not required unless a suspicious thyroid nodule is present. Grave's Disease Investigations: TFTs: ↓TSH, ↑T3/T4; may show T3 or T4 toxicosis. Antibodies: TRAb positive; TPO may be elevated. Thyroid scan: Diffuse uptake (Graves) vs. low uptake (thyroiditis). Ultrasound: Enlarged gland with increased vascular flow.

References:

Harrison's Principles of Internal Medicine, 21st Edition, Page 2938-2942

↑ *Back to this question in Part A*

@Neet_pg_bot

Q50: In a PHC, which of the following initial screening tests are used to diagnose diabetes? HbA1c >6.5 Fasting blood sugar >126mg/dl Random blood sugar >200mg/dl 2-hour post glucose load blood sugar (Q855721)

A. 1 and 2

B. 2 and 3

C. 2 and 4

D. 1,2 and 3

Correct Answer: C. 2 and 4

Explanation: The initial screening for diabetes in a PHC typically involves fasting blood sugar levels >126 mg/dL and a 2-hour post-glucose load blood sugar. The diagnosis of diabetes can be established using any of the following criteria: Fasting Plasma Glucose (FPG): ≥ 126 mg/dL (2) after an overnight fast. The result should be confirmed by repeating the test. Random Plasma Glucose (RPG) : > 200 mg/dL, done only if the patient presents with symptoms of diabetes such as polyuria, polydipsia, ketoacidosis, or unexplained weight loss. Oral Glucose Tolerance Test (OGTT) : A two-hour plasma glucose level ≥ 200 mg/dL after a 75-gram oral glucose challenge. For children, the test uses 1.75 gm/kg body weight. HbA1c >6.5 : HbA1c estimation is not typically used in primary health centers (PHC) in India due to limited resources, and it is usually only available in tertiary centers.

References:

https://www.nhm.gov.in/images/pdf/guidelines/nrhm-guidelines/stg/diabetes-mellitus.pdf

↑ *Back to this question in Part A*

@Neet_pg_bot

Q51: During her pregnancy, a woman who had Grave's disease was consistently taking. Consequently, the newborn suffered from aplasia cutis congenita. Which specific medication could be attributed to the occurrence of this condition? (Q856948)

A. Carbimazole

B. Levothyroxine

C. Methylthiouracil

D. Hydrouracil

Correct Answer: A. Carbimazole

Explanation: Carbimazole is the antithyroid medication which can cause aplasia cutis congenita , a rare condition characterized by the scalp formation defect, absence of skin in localized or widespread areas at birth. Hence it is contraindicated in the 1st trimester of pregnancy due to its teratogenic effects on the fetus. Carbimazole Carbimazole is a thyroid peroxidase inhibitor and is the prodrug of methimazole. Uses: DOC in hyperthyroidism and Graves disease. DOC in the second and third trimester of pregnancy. Used alongside I-131 in patients with severe hyperthyroidism to prevent flare-ups from stored T4. The adverse effects include Teratogenic- Cutis aplasia , Esophageal atresia, Choanal atresia. Maculopapular rash Arthralgia Cholestatic jaundice {{caption_text}} Differences between propylthiouracil and carbimazole: Propylthiouracil Carbimazole (Prodrug of Methimazole) Less potent 5 x more potent Highly plasma protein-bound Less plasma protein bound Less transferred across the placenta and in milk Large amounts transferred across the placenta and in milk Plasma t½ 1-2 hours; Acts for 4-8 hours Plasma t½ 6-10 hours; Acts for 12-24 hours Multiple (2-3) daily doses Single daily dose Inhibits peripheral T4 to T3 conversion Does not inhibit T4 to T3 conversion DOC in the first trimester of pregnancy. (less teratogenic) C/I in 2nd and 3rd trimesters. DOC in 2nd and 3rd trimester of pregnancy. (less hepatotoxic) C/I in the first trimester. Levothyroxine (Option B) is a synthetic thyroid hormone used to treat hypothyroidism. It is not associated with an increased risk of aplasia cutis congenita.



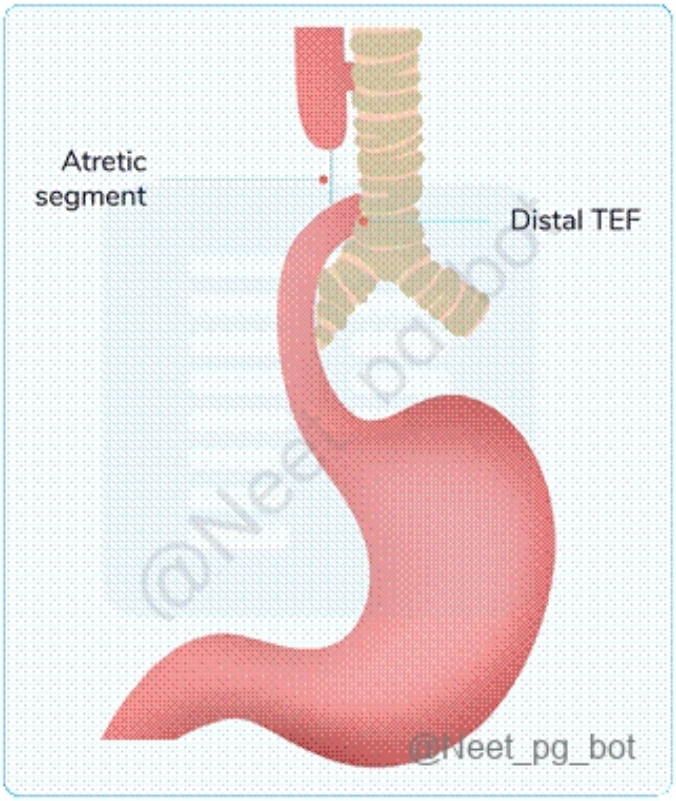

References:

KD Tripathi Essentials of medical pharmacology, 8th edition, Page 275, 276

↑ *Back to this question in Part A*

@Neet_pg_bot

Q52: Which of the following conditions are most commonly associated with elevated TSH levels and decreased T4 levels? (Q856970)

A. Hypoparathyroidism

B. Pituitary Adenoma

C. Grave's disease

D. Hashimoto's thyroiditis

Correct Answer: D. Hashimoto's thyroiditis

Explanation: Hashimoto's thyroiditis is an autoimmune disorder leading to chronic inflammation and destruction of thyroid tissue. This results in decreased production of T3 and T4 hormones. As a compensatory mechanism, the pituitary gland releases more TSH to stimulate the thyroid gland, causing increased TSH levels. Primary vs Secondary Hypothyroidism: Feature Primary Hypothyroidism Secondary Hypothyroidism Definition Thyroid gland dysfunction leads to inadequate thyroid hormone production Pituitary dysfunction leads to insufficient TSH secretion Causes Autoimmune (Hashimoto's thyroiditis) Iatrogenic (e.g., post-thyroidectomy, radiation) Iodine deficiency Medications (e.g., amiodarone, lithium) Infiltrative diseases (e.g., sarcoidosis) Food goitrogen → Cabbage, cassava. Pituitary tumors Pituitary surgery or radiation Sheehan’s syndrome Trauma Genetic pituitary hormone deficiencies Non-obstetric cause of pituitary damage called Simmonds's disease (AVM, tumor, HTN) Sarcoidosis Hemochromatosis Lab TSH - ↑; Free T3/T4 - ↓ TSH - Normal or ↓; Free T3/T4 - ↓ Clinical Features Fatigue, weight gain, cold intolerance Dry skin, hair loss Bradycardia, constipation Myxedema (puffy face, non-pitting edema) Similar to primary hypothyroidism Other pituitary hormone deficiencies (e.g., low cortisol, low LH/FSH) Treatment Levothyroxine (T4) replacement with dosage based on TSH levels Levothyroxine (T4) replacement, but monitored by free T4 levels (since TSH is unreliable) Hypoparathyroidism (Option A) is a condition characterized by inadequate production or secretion of parathyroid hormone (PTH) by the parathyroid glands. While Pituitary Adenoma (Option B) can cause various hormonal imbalances, such as excessive production of prolactin (leading to hyperprolactinemia), it does not typically result in increased TSH and low T4 levels. In Grave's disease (Option C), TSH levels are typically decreased due to the negative feedback mechanism resulting from high levels of thyroid hormones

References:

Harrison’s Principles of Internal Medicine, 21st edition, Page 2933

↑ *Back to this question in Part A*

@Neet_pg_bot

Q53: A diabetic patient walks into your clinic and does “namaste”. The image is given below. What could be the probable cause? (Q856286)

A. Flexor tenosynovitis

B. Cheiroarthropathy

C. Dupuytrens contracture

D. Ankyloses



Correct Answer: B. Cheiroarthropathy

Explanation: Cheiroarthropathy is related to long-standing poor glycemic control and the accumulation of advanced glycation end-products (AGEs) in the skin and soft tissues.This can cause difficulty in fully extending the fingers, leading to a characteristic hand posture resembling the "namaste" gesture. {{caption_text}} While flexor tenosynovitis (Option A) can occur in individuals with diabetes, it does not specifically explain the "namaste" gesture mentioned in the question. {{caption_text}} Although Dupuytren's contracture (Option C) is associated with certain risk factors, such as family history and alcoholism, it is not directly related to the "namaste" gesture. {{caption_text}} While ankylosis (Option D) can occur in various conditions, including certain forms of arthritis, trauma, or infection, it does not specifically explain the "namaste" gesture in the context of a diabetic patient. {{caption_text}}



@Neet_pg_bot



@Neet_pg_bot





References:

Harrison’s Principles of Internal Medicine, 21st edition, Page 3124, 3125

Davidson's Principles and Practice of Medicine, 24th edition, Page 755 - 762

https://www.researchgate.net/publication/361023593_Diabetic_Cheiroarthropathy

↑ *Back to this question in Part A*

@Neet_pg_bot

Q54: A 12-year-old child who is known to have type 1 diabetes mellitus presents with confusion and drowsiness. Her mother says that she seems to be breathing very fast. On examination, mucous membranes are dry, and blood pressure is 70/50 mmHg. Random blood glucose is 415 mg/d,l and urine ketones are 4+. What is the next best step in management? (Q855056)

A. 2-3 L of normal saline over 1-3 hours

B. Insulin infusion at 0.1 units/kg/hour

C. Arterial blood gas

D. Insulin bolus of 0.1 units/kg given

Correct Answer: A. 2-3 L of normal saline over 1-3 hours

Explanation: The child's presentation indicates diabetic ketoacidosis (DKA), characterized by confusion, drowsiness, Kussmaul breathing, hyperglycemia, positive urine ketones, dry mucous membranes, and hypotension indicating severe dehydration and shock . The next best step for management is to initiate 2-3 liters of normal saline over 1-3 hours . Initial treatment starts with careful fluid resuscitation to restore circulation and improve perfusion. Insulin infusion should begin 1–2 hours after fluid resuscitation to reduce cerebral edema risk, and insulin bolus is not recommended due to increased cerebral edema risk. (Option B, D ruled out). Arterial Blood Gas (ABG) (Option C) can be checked to assess acidosis, but it does not take priority over stabilizing circulation.

References:

Harrison's Principles of Internal Medicine, 21st Edition, Page 3114,3115 Davidson's Principles and Practice of Medicine, 24th Edition, Page 736 https://pmc.ncbi.nlm.nih.gov/articles/PMC7292523/ Profound hypokalemia associated with severe diabetic ketoacidosis - PMC Hypernatremia in Diabetic Ketoacidosis: Rare Presentation and a Cautionary Tale - PMC Hyperglycemic Crises: Diabetic Ketoacidosis and Hyperglycemic Hyperosmolar State Resuscitation of Adult Diabetic Ketoacidosis | RECAPEM Hyperosmolar Hyperglycemic Syndrome - StatPearls - NCBI Bookshelf

↑ *Back to this question in Part A*

@Neet_pg_bot

Q55: A patient came to the hospital with complaints of lethargy, increased sleep, and weight gain. Investigations revealed low plasma TSH concentration. However, on the administration of TRH, the TSH levels increased. Which of the conditions is likely in this patient? (Q858428)

A. Hyperthyroidism due to disease in the pituitary

B. Hypothyroidism due to disease in the pituitary

C. Hypothyroidism due to disease in the hypothalamus

D. Hyperthyroidism due to disease in the hypothalamus

Correct Answer: C. Hypothyroidism due to disease in the hypothalamus

Explanation: The patient's symptoms of lethargy, increased sleep, and weight gain point towards hypothyroidism. The increase in TSH levels upon TRH administration indicates a lack of proper stimulus for TSH secretion from the hypothalamus. Feature Primary Hypothyroidism Secondary Hypothyroidism Definition Thyroid gland dysfunction leads to inadequate thyroid hormone production Pituitary dysfunction leads to insufficient TSH secretion Causes Autoimmune (Hashimoto's thyroiditis) Iatrogenic (e.g., post-thyroidectomy, radiation) Iodine deficiency Medications (e.g., amiodarone, lithium) Infiltrative diseases (e.g., sarcoidosis) Food goitrogen → Cabbage, cassava. Pituitary tumors Pituitary surgery or radiation Sheehan’s syndrome Trauma Genetic pituitary hormone deficiencies Non-obstetric cause of pituitary damage called Simmonds's disease (AVM, tumor, HTN) Sarcoidosis Hemochromatosis Lab TSH - ↑ Free T3/T4 - ↓ TSH - Normal or ↓ Free T3/T4 - ↓ Clinical Features Fatigue, weight gain , cold intolerance Dry skin, hair loss Increased sleep Bradycardia, constipation Myxedema (puffy face, non-pitting edema) Similar to primary hypothyroidism Other pituitary hormone deficiencies (e.g., low cortisol, low LH/FSH) Treatment Levothyroxine (T4) replacement with dosage based on TSH levels Levothyroxine (T4) replacement, but monitored by free T4 levels (since TSH is unreliable) Hyperthyroidism due to disease in the pituitary (Option A) would result in elevated TSH and thyroid hormone levels, which is not consistent with the patient's low plasma TSH and hypothyroidism symptoms. Hypothyroidism due to disease in the pituitary (Option B): In pituitary hypothyroidism, TSH would be low due to the lack of pituitary secretion. However, unlike the hypothalamic case, TSH would not increase after TRH administration because the pituitary is unable to respond to TRH. Hyperthyroidism due to disease in the hypothalamus (Option D): In hypothalamic hyperthyroidism, there would be a lack of feedback inhibition on the hypothalamus and pituitary, leading to elevated TSH and thyroid hormones. This is not consistent with the patient's low TSH and hypothyroidism.

References:

Harrison’s Principles of Internal Medicine, 21st Edition, Volume I, Page 2933

↑ *Back to this question in Part A*

@Neet_pg_bot

Q56: A 55-year-old man with a known pituitary adenoma presents with sudden, severe headache, vomiting, and rapidly decreasing responsiveness. On examination, his blood pressure is 80/50 mmHg. Which of the following findings is most characteristic of pituitary apoplexy? (Q858432)

A. Hypertension

B. Shock

C. Unconsciousness

D. Fatigue

Correct Answer: B. Shock

Explanation: Pituitary apoplexy is an acute hemorrhage or infarction of the pituitary gland, usually occurring in a pituitary adenoma. Acute destruction of pituitary tissue causes sudden ACTH deficiency , leading to adrenal crisis , which manifests as: Hypotension and shock (most characteristic) Loss of consciousness due to decreased cerebral perfusion Severe headache, vomiting Visual impairment and ophthalmoplegia from compression Hypoglycemia Hypertension (Option A): Not seen; patients are typically hypotensive . Unconsciousness (Option C): Can occur but is secondary to shock , not the primary hallmark. Fatigue (Option D): Seen in chronic hypopituitarism, not acute apoplexy.

References:

Harrison’s Principles of Internal Medicine, 21st Edition, Page 2897,2898

↑ *Back to this question in Part A*

@Neet_pg_bot

Q57: What is a macrovascular complication that develops in the advanced stages of diabetes? (Q859745)

A. Coronary artery disease

B. Foot ulcer

C. Nephropathy

D. Retinopathy

Correct Answer: A. Coronary artery disease

Explanation: The macrovascular complication that develops in the advanced stages of diabetes is coronary artery disease. Macrovascular Complications of Diabetes Mellitus Major causes of morbidity and mortality in type 1 and type 2 diabetes. Involves large blood vessels, leading to: Coronary circulation: Myocardial ischaemia/infarction. Cerebral circulation: Transient ischaemic attack, stroke. Peripheral circulation: Claudication, ischaemia. Key Points: Excess mortality : Mainly due to myocardial infarction and stroke. Accelerated atherosclerosis : Earlier onset and more severe in diabetics. Amplified risk factors : Smoking, hypertension, dyslipidemia. Metabolic syndrome : Common in type 2 diabetes, with additional cardiovascular risk factors due to insulin resistance. Criteria for metabolic syndrome are Hypertension High Fasting glucose Elevated TG Low HDL Central obesity Statistics: Condition Increased Rate in Diabetics Cardiovascular death 1.7 times higher Myocardial infarction 1.8 times greater Stroke hospitalisation 1.5 times higher Non-traumatic amputations 60% occur in diabetics First cardiovascular event (type 1) 3 times higher in women, 2.3 times higher in men Mechanisms linking hyperglycemia to macrovascular disease: Increased vascular permeability : Due to high blood glucose. Lipoprotein deposition : Hyperinsulinemia and hypertension increase atherogenic lipoprotein deposits in large vessels. Risk Management: Glycaemic control : Reduces both microvascular and macrovascular complications. Blood pressure control : ACE inhibitors/ARBs are protective. Dyslipidemia management : Statins are recommended to lower cardiovascular risks. Lifestyle modifications : Smoking cessation, weight management, and regular physical activity are crucial. Diabetic Microvascular Complications Diabetic microangiopathy affects small blood vessels in diabetes, leading to significant morbidity and mortality. Key clinical syndromes include: Diabetic retinopathy (Option D) Diabetic nephropathy (Option C) Diabetic neuropathy Foot ulcer (Option B) is a microvascular complication of diabetes.

References:

Davidson’s Principles and Practice of Medicine, 24th Edition, Page 743, 755, 756, 757

↑ *Back to this question in Part A*

@Neet_pg_bot

Q58: What is the disease depicted in the image below? (Q859778)

A. Acromegaly

B. PCOS

C. Cushing’s syndrome

D. Advanced obesity

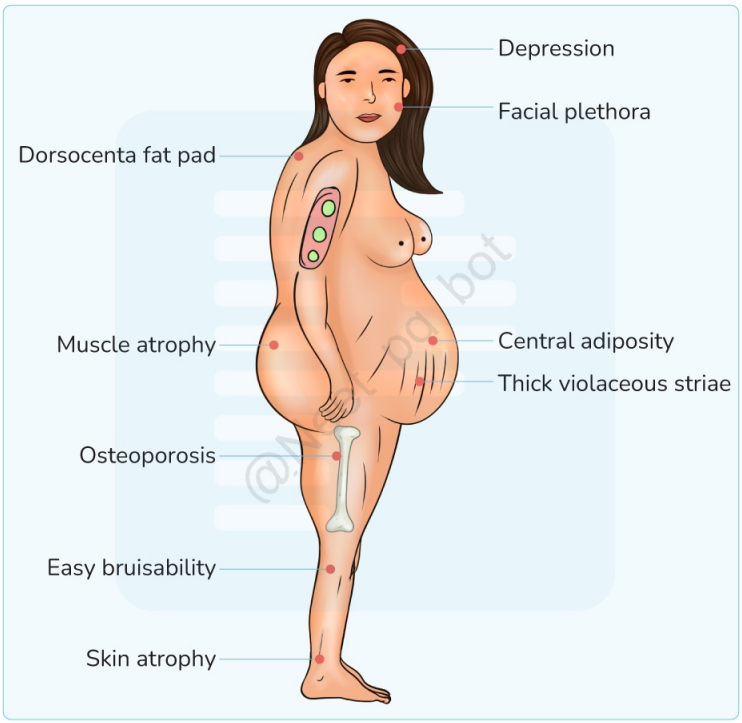

Correct Answer: C. Cushing’s syndrome

Explanation: The clinical manifestations in the image is of Cushing’s syndrome which is caused due to prolonged exposure to high levels of glucocorticoids. Cushing's syndrome Cushing's syndrome is a collection of symptoms resulting from prolonged exposure to high levels of glucocorticoids . Cushing's disease specifically refers to Cushing's syndrome caused by a pituitary corticotrope adenoma. It is relatively rare, but mild cases may be more common, particularly among those with symptoms like central obesity, type 2 diabetes and osteoporosis. {{caption_text}} Clinical Features of Cushing syndrome Physical: Weight gain and central obesity: Particularly around the face ("moon facies") and the back of the neck ("buffalo hump"). Skin changes: Thin and fragile skin prone to bruising, broad purple stretch marks, acne, and hirsutism. Musculoskeletal Issues: Osteoporosis (leading to fractures, especially in the spine) (Option B), muscle weakness, proximal myopathy (difficulty climbing stairs or rising from a chair), and decreased deep tendon reflexes. Metabolic: Glucose intolerance or diabetes and dyslipidemia (abnormal blood lipid levels). Cardiovascular: Hypertension, hypokalemia, and oedema. Reproductive: Decreased libido, and amenorrhea in women due to suppressed gonadotropin release. Psychological: Irritability, emotional instability, depression, cognitive impairment, and in severe cases, psychosis. Other features: Increased susceptibility to infections, elevated white blood cell count, eosinopenia Hypercoagulable state, increasing the risk of deep vein thrombosis and pulmonary embolism.



References:

Harrison's Principles of Internal Medicine, 21st Edition, Page: 3000-3008.

↑ *Back to this question in Part A*

@Neet_pg_bot

Q59: A 30-year-old man presents with sudden onset of a headache, palpitation, and profuse sweating. He had several such episodes in the past. During these episodes, his BP is found to be high. A 24-hour urinary metanephrine is elevated. What is the most likely aetiology? (Q859793)

A. Fibromuscular dysplasia

B. Renal artery stenosis

C. Pheochromocytoma

D. Hyperthyroidism

Correct Answer: C. Pheochromocytoma

Explanation: The elevated 24-hour urinary metanephrine with the given clinical features suggests phaeochromocytoma . Pheochromocytoma Description Pheochromocytomas are rare tumours arising from chromaffin cells of the adrenal medulla. The clinical features result from excessive secretion of catecholamines. Epidemiology Estimated to occur in 2 to 8 of 1 million persons per year. The mean age at diagnosis is 40 years, although the tumours can occur from early childhood until late in life. The classic ‘rule of tens’ is 10% bilateral, 10% extra-adrenal (Paragangliomas), and 10% metastatic. It is not used nowadays. Etiopathogenesis These tumors can be benign or malignant and are frequently associated with familial syndromes like Neurofibromatosis type 1, multiple endocrine neoplasia type II, and Von-Hippel Lindau disease. Catecholamines are produced in the chromaffin cells starting with the rate-limiting step of tyrosine hydroxylase (TH), regulating the conversion of tyrosine to dihydroxyphenylalanine (DOPA). Pheochromocytomas release these catecholamines in various patterns ranging from paroxysmal, continuous, and mixed patterns. Norepinephrine is released continuously and can result in persistent hypertension, while epinephrine is released in a paroxysmal pattern resulting in tachyarrhythmias. Ryanodine-2 receptors (RyR2). Beta-2 adrenoceptors Alpha(1)-adrenoreceptors Histopathology Histology of the lesion characteristically shows zellballen nests of chromaffin cells with strong positivity to chromogranin, synaptophysin, CD56, and focally to S100. {{caption_text}} The presence of chromaffin cells in the extra-adrenal tissue is the only pathognomonic characteristic of the malignant form of the entity. Clinical features Classical triad Episode of palpitation Headache Profuse sweating The dominant sign is Hypertension Tachycardia Anxiety Subcutaneous neurofibromas Cafe-au-lait macules Thyroid mass Axillary freckling Lisch nodules on the iris Retinal angiomas Abdominal mass Diagnosis Diagnosis of pheochromocytoma can be established by biochemical confirmation of hypersecretion of metanephrines and catecholamines. 24-hour urine test Catecholamines Fractionated metanephrines Total metanephrines Imaging : CT scan of the abdomen and pelvis to locate the tumour. {{caption_text}} 18F-FDG PET scanning is recommended for metastatic disease. MIBG scintigraphy Somatostatin receptor scintigraphy Gallium DOTATATE PET scanning {{caption_text}} Differential Diagnosis Hyperthyroidism Renal artery stenosis Hyperaldosteronism Cardiomyopathy Postural tachycardia syndrome (POTS) Treatment The definitive treatment of pheochromocytoma is surgical resection. Preoperative preparation of the patient has to be considered, and blood pressure should be consistently < 160/90 mm Hg. Blood pressure is controlled by alpha-adrenergic blockers(phenoxybenzamine 0.5-4 mg/kg of body weight) Oral Prazosin or IV phentolamine can be used to control paroxysm. Unilateral Pheochromocytoma: Minimally invasive adrenalectomy: Preferred treatment for most unilateral adrenal pheochromocytomas. Open adrenalectomy Bilateral pheochromocytomas: Bilateral total adrenalectomy is associated with a lifelong need for steroid replacement with long-term side effects. Bilateral partial or cortical sparing adrenalectomy (open or laparoscopic) Complications Myocardial infarction Cardiogenic shock Renal Failure Pulmonary edema Acute respiratory distress syndrome (ARDS) Lactic acidosis Hypertensive retinopathy Hypertensive encephalopathy Fibromuscular dysplasia (Option A) is a systemic vascular disease that is the cause of 10% to 20% of renal artery stenosis. This presents with resistant hypertension, hematuria, flank pain, renal infarct, hypokalemia, and abdominal bruit. Renal artery stenosis (Option C) can cause hypertension, but it does not typically present with sudden-onset headaches, palpitations, and profuse sweating. Hyperthyroidism (Option D) can cause symptoms such as palpitations and sweating. However, sudden-onset headaches and episodes of high blood pressure are not typical features of this condition.

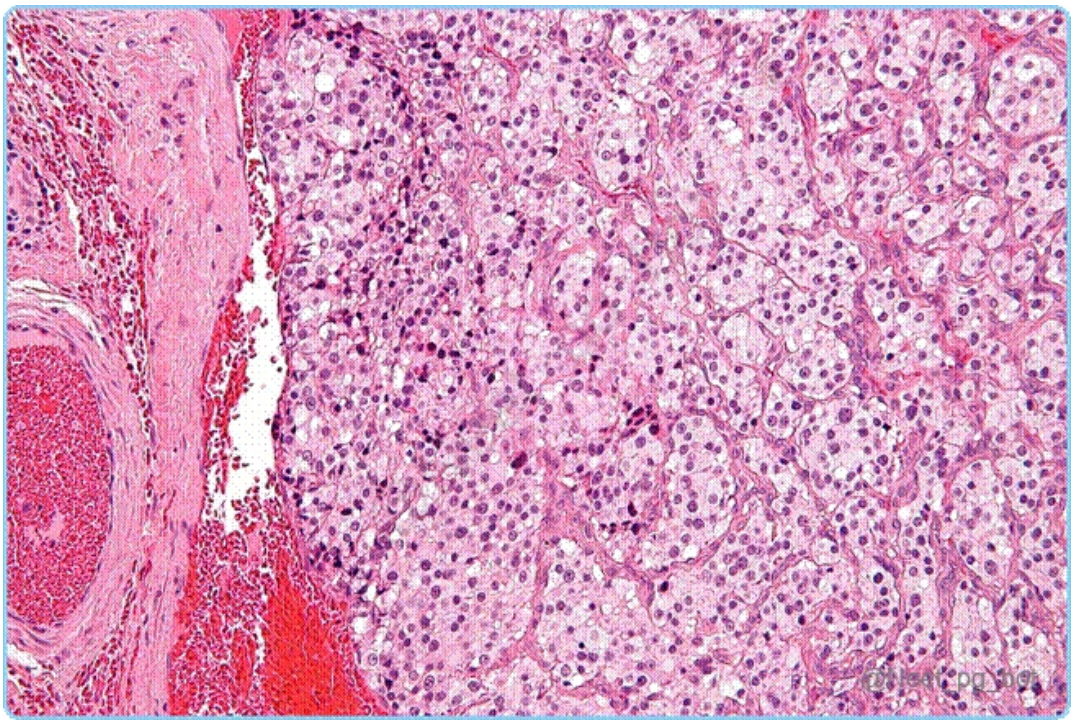
@Neet_pg_bot

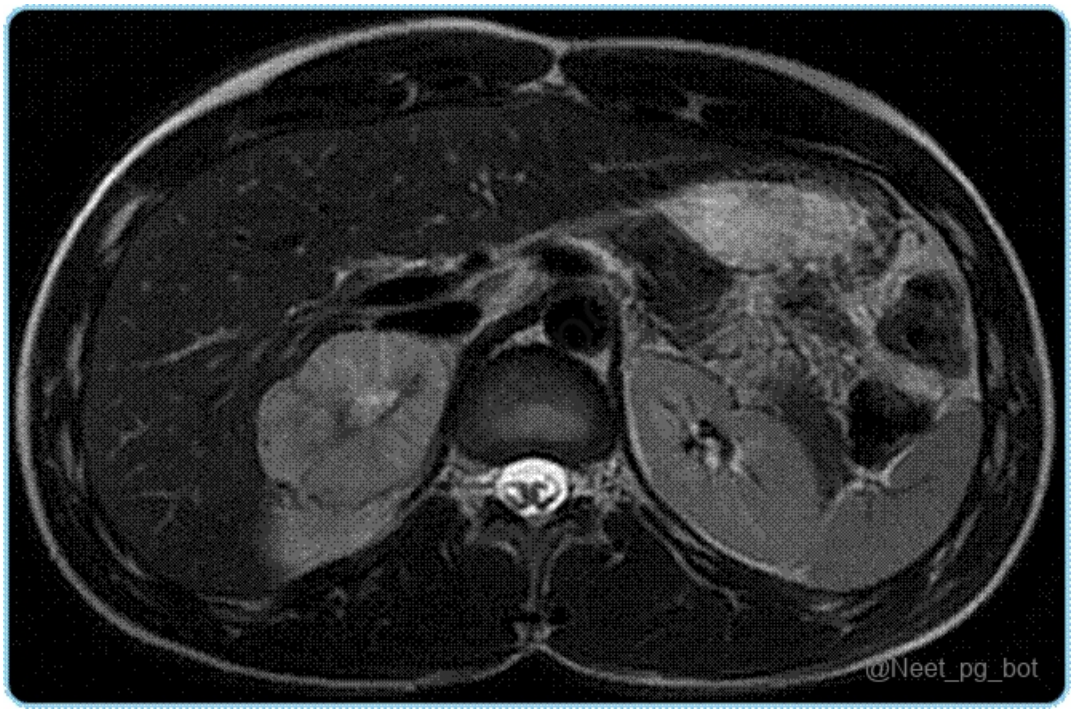
@Neet_pg_bot

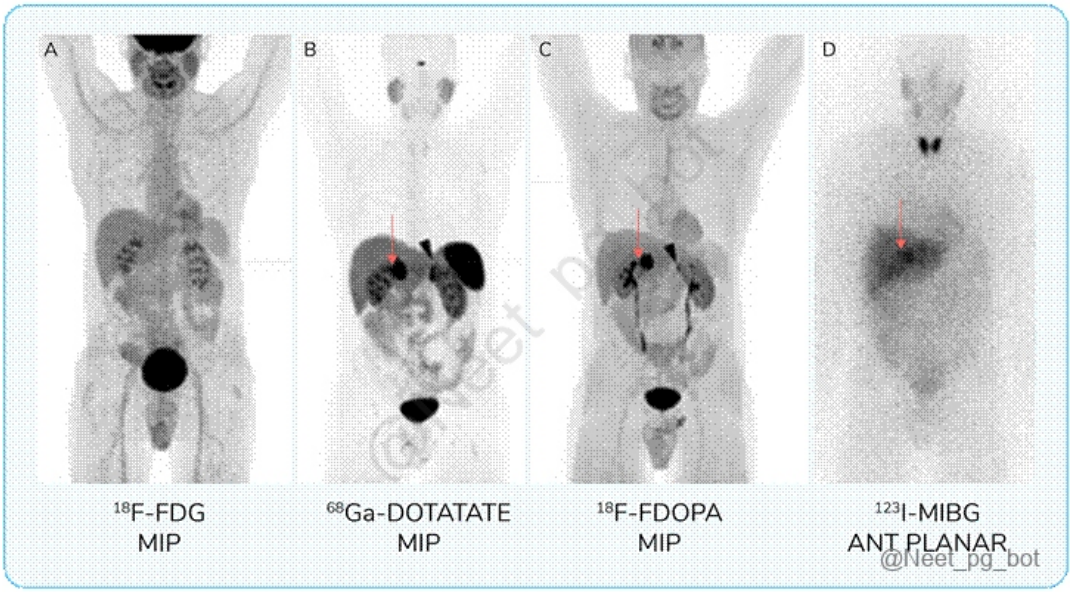

References:

Harrison's Principles of Internal Medicine, 21st edition, Page: 2976-2979.

↑ *Back to this question in Part A*

@Neet_pg_bot

Q60: A patient with diabetes mellitus for the past 5 years presents with vomiting and abdominal pain. She is non-compliant with medication and appears dehydrated. Investigations revealed a blood sugar value of 500 mg/dL and the presence of ketone bodies. What is the next best step in management? (Q855846)

A. Intravenous fluids with long-acting insulin

B. Intravenous fluids

C. Intravenous insulin

D. Intravenous fluids with regular insulin

Correct Answer: D. Intravenous fluids with regular insulin

Explanation: The patient with diabetes mellitus presents with abdominal pain, nausea, vomiting, dehydration, Kussmaul breathing, hyperglycemia, and metabolic acidosis, indicative of diabetic ketoacidosis (DKA); the next best step in management is intravenous fluids with regular insulin. Diabetic Ketoacidosis (DKA) It is a life-threatening complication of diabetes, primarily type 1 diabetes mellitus (T1DM), though it can occur in type 2 diabetes mellitus (T2DM) under stress. Precipitating Factors Inadequate Insulin Administration Infections

Infarctions Pancreatitis Pregnancy Drugs: Cocaine and other substances that impair glucose metabolism. Pathophysiology Insulin Deficiency: Leads to reduced glucose uptake and unopposed glucagon secretion, causing hyperglycemia and lipolysis. Ketogenesis: Increased fatty acid oxidation produces ketone bodies (ß-hydroxybutyrate, acetoacetate), resulting in ketosis. Acidosis: Accumulation of ketone bodies leads to high anion gap metabolic acidosis. Dehydration: Osmotic diuresis from hyperglycemia causes volume depletion, electrolyte imbalances, and renal impairment. Clinical Features Symptoms Signs Nausea and vomiting Abdominal pain Thirst, polyuria, and polydipsia Weight loss Weakness and fatigue Shortness of breath Dehydration (dry mucous membranes, poor skin turgor) Hypotension (postural or supine) Tachycardia Hypothermia Tachypnea Kussmaul respiration (deep, labored breathing) Fruity odor of acetone on the breath Abdominal tenderness resembling acute abdomen Lethargy, obtundation, possible cerebral edema, or coma Investigations Blood Glucose: Typically 250–600 mg/dL. Serum Ketones: ß-hydroxybutyrate preferred for accurate detection; urine ketostix detect acetoacetate and acetate. Arterial Blood Gas (ABG): pH: 6.8–7.3 (acidosis). pCO■: 20–30 mmHg. HCO■: <18 mEq/L. Electrolytes: Potassium: Total body deficiency (3–6 mEq/kg) due to osmotic diuresis; serum potassium may be high initially but drops rapidly with insulin therapy. Sodium: Dilutional hyponatremia due to hyperglycemia. Anion Gap: Elevated, indicating high anion gap metabolic acidosis. Renal Function: Elevated blood urea nitrogen (BUN) and creatinine due to dehydration. Management Follow ISPAD 2022 Guidelines: Ensure IV fluid resuscitation and appropriate insulin administration in patients with moderate dehydration. Initial Stabilization Intravenous Fluids: Start with isotonic saline (0.9%) to correct dehydration and improve circulation. Switch to 0.45% saline if sodium levels are elevated. Add 5% dextrose when blood glucose reaches 200 mg/dL to prevent hypoglycemia. Insulin Therapy Intravenous Regular Insulin: Initial bolus of 0.1 units/kg, followed by continuous infusion at 0.1 units/kg/hour. Continue until acidosis resolves (pH >7.3, bicarbonate >15 mEq/L, and anion gap normalizes). Potassium Correction: If potassium is <3.3 mEq/L, delay insulin and administer potassium chloride (KCl). Maintain potassium between 3.5–5.0 mEq/L. Intravenous fluids with long-acting insulin (Option A): Long-acting insulin is not used for acute management of DKA. It is started only after stabilization and when the patient resumes oral intake. Intravenous fluids (Option B): Although fluid resuscitation is critical, it must be combined with insulin therapy to address acidosis and hyperglycemia. Intravenous insulin (Option C): Insulin alone cannot correct the severe dehydration and electrolyte imbalances associated with DKA.

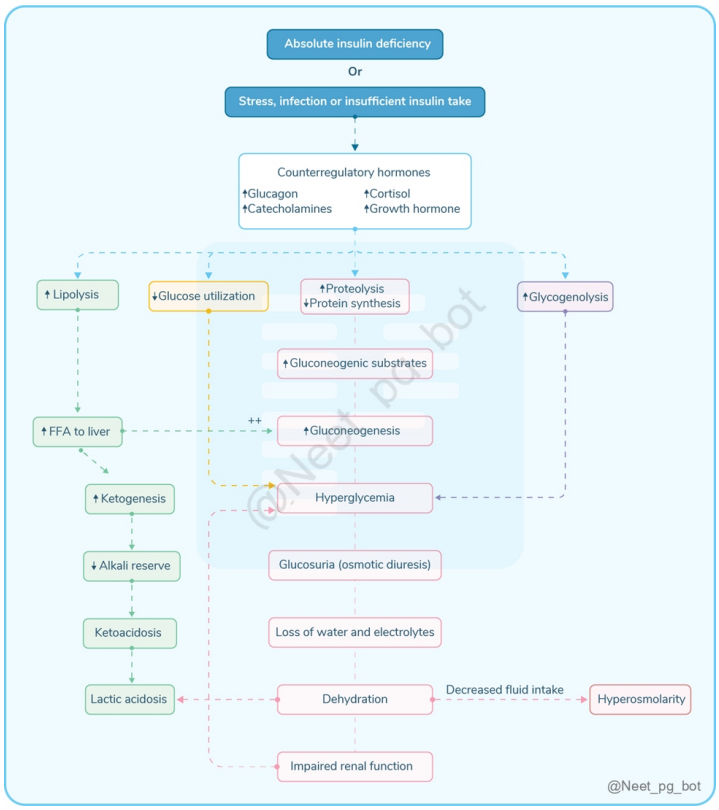

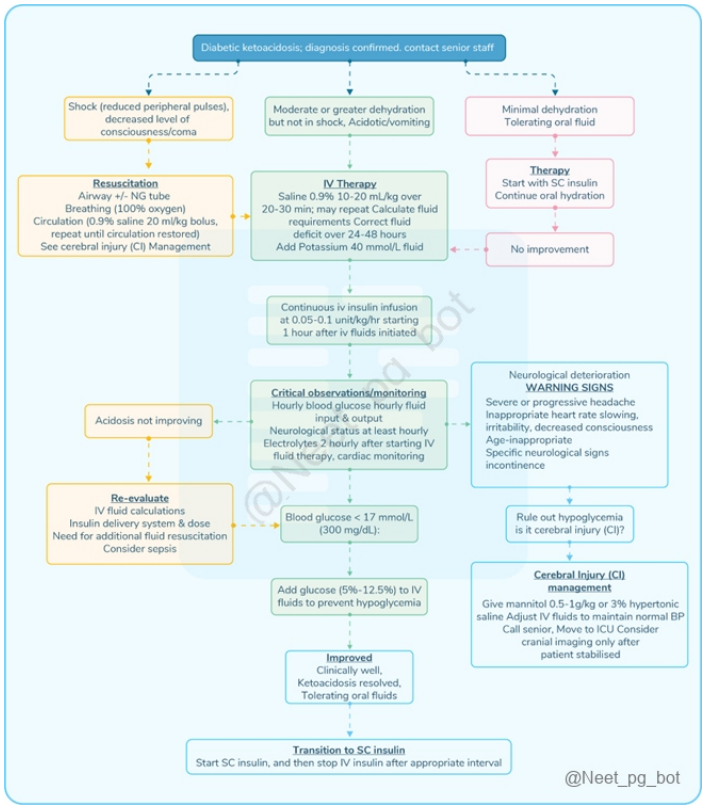

References:

Harrison’s Principles of Internal Medicine, 21st Edition, Page: 3114,3115.

Davidson’s Principles and Practice of Medicine, 24th Edition, Page: 736.

Recurrent Concurrent Diabetic Ketoacidosis and Thyroid Storm - PMC

https://pmc.ncbi.nlm.nih.gov/articles/PMC7292523/

Profound hypokalemia associated with severe diabetic ketoacidosis - PMC

Hypernatremia in Diabetic Ketoacidosis: Rare Presentation and a Cautionary Tale - PMC

Hyperglycemic Crises: Diabetic Ketoacidosis and Hyperglycemic Hyperosmolar State

Resuscitation of Adult Diabetic Ketoacidosis | RECAPEM

Hyperosmolar Hyperglycemic Syndrome - StatPearls - NCBI Bookshelf

↑ *Back to this question in Part A*

@Neet_pg_bot

Q61: A female patient with a negative urine pregnancy test presents to you with galactorrhea. An MRI was done, which revealed a large pituitary tumor. If the patient is not willing to undergo surgery, which of the following is the best drug for treatment? (Q855929)

A. Bromocriptine

B. Promethazine

C. Octreotide

D. Clozapine

Correct Answer: A. Bromocriptine

Explanation: The clinical scenario is indicative of a prolactinoma —a benign pituitary tumor that results in excessive prolactin production, leading to symptoms such as galactorrhea, amenorrhea, and infertility in women. The negative urine pregnancy test rules out pregnancy as a cause of galactorrhea. In patients who are unwilling to undergo surgery, the first-line treatment is medical management with dopamine agonists, such as Bromocriptine (or cabergoline), which effectively lower prolactin levels and reduce tumor size. Prolactinoma A benign pituitary tumor secreting excess prolactin. Cause Mostly idiopathic; can be associated with MEN 1 or RET gene mutations. Classification Microadenomas: <1 cm, often asymptomatic. Macroadenomas: >1 cm, may cause visual field defects, headaches, and neurological symptoms. Symptoms Galactorrhea, amenorrhea, infertility (women) Erectile dysfunction, reduced libido (men) Headaches, visual disturbances (e.g., bitemporal hemianopia, diplopia in large tumors). Diagnosis Elevated prolactin levels, MRI for tumor imaging. Treatment Dopamine agonists: Bromocriptine, Cabergoline (first-line) to reduce prolactin secretion and tumor size. Cabergoline: Preferred; fewer side effects. Surgical: If resistant to or intolerant of dopamine agonists, or with significant complications.

Radiotherapy: For resistant cases. Promethazine (Option B) is an antihistamine used for motion sickness, pruritus, and nausea. Octreotide (Option C) is a somatostatin analog primarily used for conditions like acromegaly, variceal bleeding, and hepatorenal syndrome. Clozapine (Option D) is an atypical antipsychotic used in the treatment of refractory schizophrenia and severe mania.

References:

Harrison's Principles of Internal Medicine, 21st Edition, Page: 2302, 2303, 2909, 2910, 2911.

Goodman & Gillman's The Pharmacological Basis Of Therapeutics - 13th Edition, Page: 237, 240, 292, 293, 299, 776.

PMC Article: PMC1116493

PMC Article: PMC3487282

↑ *Back to this question in Part A*

@Neet_pg_bot

Q62: Which of the following is not seen in MEN 2B syndrome? (Q856016)

A. Megacolon

B. Parathyroid adenoma

C. Mucosal neuroma

D. Marfanoid habitus

Correct Answer: B. Parathyroid adenoma

Explanation: Parathyroid adenomas are typically associated with MEN 2A and MEN 1, not MEN 2B. MEN 2B (also known as MEN 3) is a rare inherited condition caused by gain-of-function mutations in the RET proto-oncogene at chromosomal locus 10q11.2. Features of MEN 2B Medullary Thyroid Carcinoma (MTC): (Most common) often aggressive and presenting early. Pheochromocytoma: Frequently bilateral, causing palpitations, sweating, and headaches. Mucosal Neuromas: Present as bumpy, enlarged lips, tongue, and eyelids. (Option C ruled out) Marfanoid Habitus: Features include tall stature, long limbs, arachnodactyly, and joint hypermobility. (Option D ruled out) Megacolon: Results from intestinal autonomic ganglion dysfunction, often associated with diverticula. (Option A ruled out) Medullated corneal nerve fibers and delayed puberty. MEN 1 (Wermer Syndrome) MEN 2A (Sipple Syndrome) MEN 2B (MEN 3) MEN 4 Gene: MEN1 Gene: RET Gene: RET Gene: CDKN1B Pituitary Adenomas Pancreatic Neuroendocrine Tumors Primary Hyperparathyroidism Medullary Thyroid Carcinoma Phaeochromocytoma Primary Hyperparathyroidism Medullary Thyroid Carcinoma Phaeochromocytoma Mucosal Neuromas Marfanoid Habitus Pituitary Adenomas Pancreatic Neuroendocrine Tumors Primary Hyperparathyroidism Reproductive Tumors

References:

Harrison's Principles of Internal Medicine, 21st Edition, Page: 2983, 2988, 2989, 2990, 3229.

↑ *Back to this question in Part A*

@Neet_pg_bot

Q63: A lung cancer patient has hyperpigmentation of palmar and sole creases. Which of the following is responsible for this presentation? (Q860465)

A. Melanocyte Stimulating Hormone (MSH)

B. C-peptide

C. Neuropeptide Y

D. Melanin

Correct Answer: A. Melanocyte Stimulating Hormone (MSH)

Explanation: The clinical manifestations indicate Ectopic Cushing's syndrome , a paraneoplastic syndrome commonly associated with lung cancer. Proopiomelanocortin (POMC) produced by the tumor is cleaved to form Melanocyte Stimulating Hormone (MSH) and ACTH , leading to hyperpigmentation. This process represents one of the most common hormonally-induced paraneoplastic syndromes in small cell lung cancer (SCLC). Ectopic Cushing's Syndrome Definition ACTH production from non-pituitary sources leading to Cushing's syndrome Epidemiology Accounts for 10-20% of cases of Cushing's syndrome Common Sources Small cell lung cancer (most common) Bronchial and thymic carcinoids Islet tumors Pheochromocytomas Medullary thyroid carcinomas Pathophysiology Increased expression of POMC gene from non-pituitary sources Production of MSH , β-lipotropin, and other POMC-derived peptides Production of ACTH fragments Clinical Features Hyperglycemia Marked fluid retention Hyperpigmentation manifestations due to MSH Less marked weight gain compared to pituitary Cushing's Centripetal fat redistribution Hypertension Hypokalemia Metabolic alkalosis Glucose intolerance Diagnosis Very high ACTH levels (typically >2-3 times normal) No response to high-dose dexamethasone suppression Treatment Treatment of underlying malignancy Glucocorticoid receptor blockers Steroidogenesis inhibitors Management of complications (diabetes, hypokalemia) Key Distinctions from Pituitary Cushing's Higher ACTH levels No response to dexamethasone suppression More rapid onset More severe metabolic complications C-peptide (Option B) is a byproduct formed during the conversion of proinsulin to insulin. It has no role in the hyperpigmentation seen in paraneoplastic syndromes associated with lung cancer. Neuropeptide Y (Option C) is involved in appetite regulation through hypothalamic signaling. This peptide does not contribute to the hyperpigmentation observed in paraneoplastic syndromes. Melanin (Option D) is the end product of melanogenesis responsible for skin pigmentation. While it is the final pigment, the question asks about the hormone responsible for triggering the hyperpigmentation, which is MSH.

References:

Harrison’s Principles of Internal Medicine 21st edition Page 724

Davidson's Principles and Practice of Medicine, 24th Edition, Page: 600-603.

↑ *Back to this question in Part A*

@Neet_pg_bot

Q64: Which of the following mutations is associated with the Philadelphia chromosome? (Q860473)

A. Inversion

B. Insertion

C. Reciprocal translocation

D. Deletion

Correct Answer: C. Reciprocal translocation

Explanation: The Philadelphia chromosome is a balanced translocation between the long arm of chromosomes 9 and 22 [t(9;22)(q34.1;q11.2)] . It is present in the majority of patients with chronic myeloid leukaemia (CML). Formation of Philadelphia chromosome: A balanced translocation is a type of chromosomal rearrangement in which segments of two different chromosomes break and exchange places without any loss of genetic material. In the case of CML, a segment of chromosome 9 containing the ABL gene (Abelson Leukemia) , located at the q34 region, moves to chromosome 22. Similarly, the segment of chromosome 22 containing the BCR gene (breakpoint cluster region) , located at the q11 region, moves to chromosome 9. This exchange results in the formation of two derivative chromosomes: one with the truncated chromosome 9 segment and the BCR-ABL fusion gene and the other with the truncated chromosome 22 segment. The chromosome containing the BCR-ABL fusion gene is known as the Philadelphia chromosome. {{caption_text}} The BCR-ABL fusion forms a novel oncoprotein called p210 bcr-abl-1 (210 = molecular weight in kiloDalton—210 kDa). Inversion (Option A) occurs when a segment of DNA breaks away from the chromosome, flips around, and reattaches in the reverse orientation. This is not the mechanism involved in Philadelphia chromosome formation. Insertion (Option B) involves the addition of extra nucleotides into a DNA sequence. This type of mutation can cause frameshift mutations but is not responsible for the Philadelphia chromosome. Deletion (Option D) results in the loss of a segment of DNA from a chromosome. While deletions are important mutations, they do not cause the formation of the Philadelphia chromosome, which involves an exchange of genetic material between chromosomes.

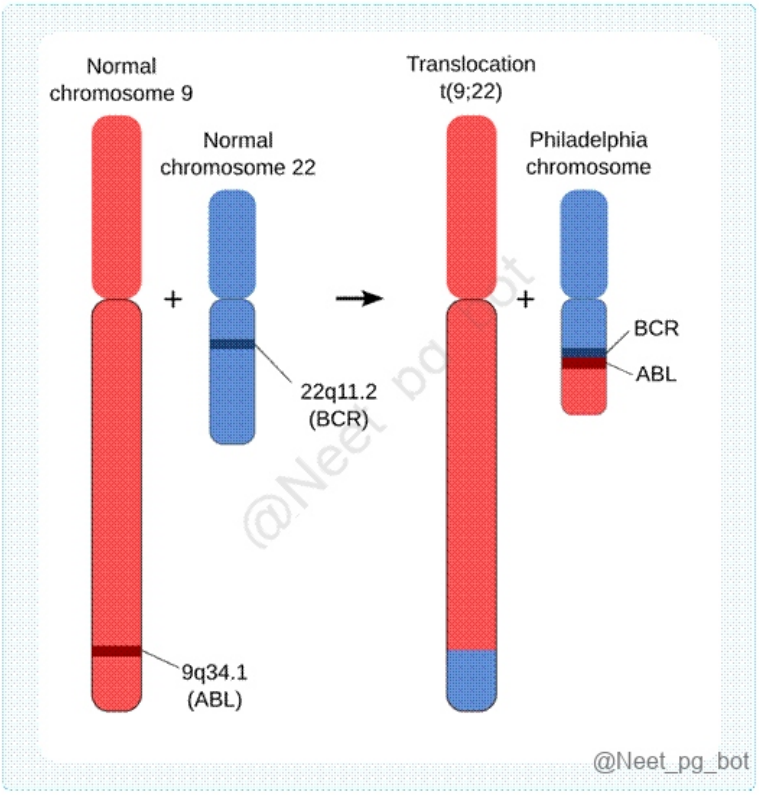

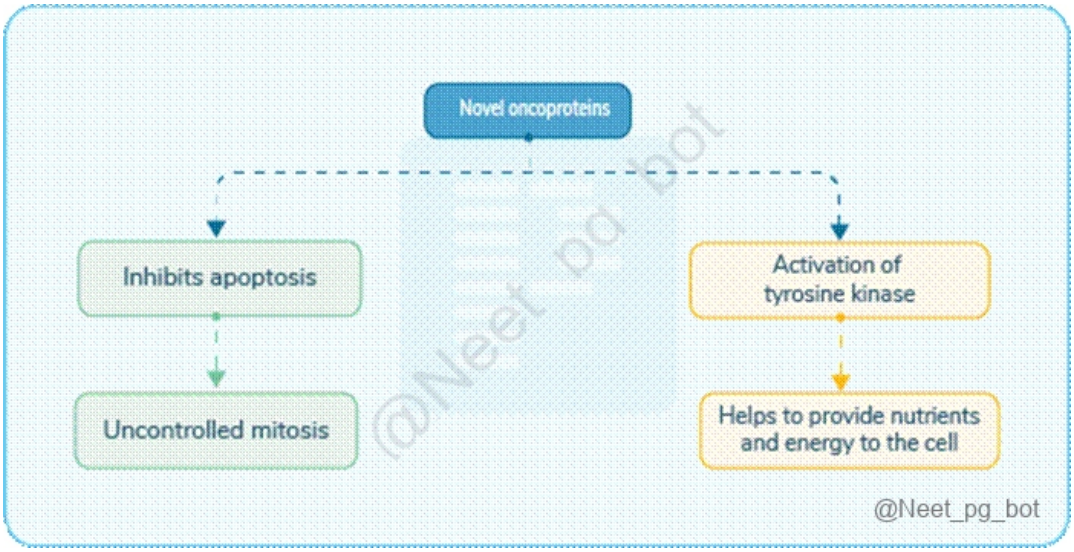

References:

Harrison’s Principles of Internal Medicine, 21st edition, Page 820

Robbins and Cotran, Pathologic Basis of Disease, 10th edition, Page 595,622

↑ *Back to this question in Part A*

@Neet_pg_bot

Q65: Most common cause of hypercalcemia in a hospitalized patient is: (Q857290)

A. Malignancy

B. Parathyroid Adenoma

C. Parathyroid hyperplasia

D. Follicular thyroid CA

Correct Answer: A. Malignancy

Explanation: etiology: Hypercalcemia of malignancy Paraneoplastic syndromes in Squamous cell carcinoma of lungs Breast carcinoma Parathyroid adenoma Sarcoidosis Vitamin D toxicity Milk alkali syndrome Jansen disease: Autosomal dominant defect in PTHR-1 leading to receptor gain mutation (hyperactive receptor) Lithium toxicity: Causes diabetes insipidus and activation of parathyroid glands. Familial hypocalciuric hypercalcemia: Autosomal dominant defect in CaSR receptor in parathyroid and kidneys, which leads to excess PTH secretion Investigations: Serum electrolytes: ↑ calcium and ↓ phosphate. ↑ Serum alkaline phosphatase. ↑↑↑ Serum PTH in cases of parathyroid adenoma Treatment: Aggressive hydration with normal saline: First-line management to correct dehydration and promote renal calcium excretion. Forced diuresis with loop diuretics: Can be used after adequate hydration to enhance calcium excretion in the urine. Intravenous Zoledronate: Drug of choice for lowering calcium. It begins to act within 1-2 days and lasts up to 3 weeks. Calcitonin: Promotes calcium deposition in bones but may develop tachyphylaxis (reduced response over time). Denosumab: Inhibits osteoclast differentiation by binding to RANK ligand, reducing bone resorption. Peritoneal dialysis: Indicated in renal failure, it can rapidly reverse life-threatening hypercalcemia. Parathyroid Adenoma (Option B): Primary hyperparathyroidism, most commonly due to a parathyroid adenoma, is the leading cause of hypercalcemia in the outpatient setting rather than hospitalized patients. It leads to increased secretion of parathyroid hormone (PTH), causing increased calcium resorption from bones and reduced renal calcium excretion. Parathyroid Hyperplasia (Option C): Parathyroid hyperplasia causes primary hyperparathyroidism, but it is less common than parathyroid adenoma. It is associated with multiple endocrine neoplasia (MEN) syndromes, particularly MEN 1 and MEN 2A. Like adenomas, it is more commonly seen in outpatient settings rather than as a cause of acute hypercalcemia in hospitalized patients. Follicular Thyroid Carcinoma (Option D): While follicular thyroid carcinoma can sometimes lead to bone metastases, resulting in hypercalcemia, it is not a common cause. Hypercalcemia from malignancy is more often seen in cancers that secrete PTHrP (e.g., squamous cell lung cancer) or cause direct bone destruction (e.g., multiple myeloma).

References:

Harrison’s principle of internal medicine, 21st edition, Page: 3182, 3183.

↑ *Back to this question in Part A*

@Neet_pg_bot

Q66: Which of the following is not used in management of tumor lysis syndrome? (Q793977)

A. Urine acidification

B. IV fluids

C. Dialysis

D. Rasburicase

Correct Answer: A. Urine acidification

Explanation: - Urine acidification: Tumor lysis syndrome (TLS) results in hyperuricemia, hyperkalemia, hyperphosphatemia, and hypocalcemia due to rapid tumor cell breakdown. Management includes aggressive IV hydration, rasburicase to rapidly degrade uric acid, and dialysis in severe or refractory cases. Urine acidification is not recommended because it increases the risk of uric acid and calcium phosphate crystal precipitation in renal tubules, worsening acute kidney injury. Incorrect Options: Option B - IV fluids: Aggressive IV hydration is the cornerstone of TLS management, helping maintain urine output and prevent crystal-induced renal failure. Option C – Dialysis: Dialysis is indicated in TLS with severe metabolic derangements or renal failure not responsive to medical therapy. Option D – Rasburicase: Rasburicase converts uric acid to allantoin, which is more soluble and easily excreted, making it highly effective in preventing and treating hyperuricemia in TLS.

References:

.

↑ *Back to this question in Part A*

@Neet_pg_bot

Q67: What is the most frequently observed delayed symptom of radiation therapy for the head and neck? (Q859545)

A. Dysphagia

B. Xerostomia

C. Myelopathy

D. Dysgeusia

Correct Answer: B. Xerostomia

Explanation: The most common late symptom of radiation therapy for head and neck cancers is xerostomia (dry mouth) . Late symptoms of radiation therapy for head and neck tumours Side effects Symptoms Management

Permanent dry mouth (xerostomia) Dry mouth, difficulty in eating, swallowing, and speaking Maintain adequate oral hygiene, salivary substitutes' saliva stimulation, low-level laser treatment of the salivary gland, chlorhexidine, antifungal therapy, adequate hydration, acupuncture Burning mouth syndrome Burning or scalded of mouth; dryness, increased thirst; loss of taste Oral rinses, lidocaine, saliva substitutes, capsaicin, clonazepam or Klonopin, antidepressants, pain medications, low-level laser therapy, cognitive behavioural therapy Dental caries Dental caries Oral hygiene, management of xerostomia, topical fluorides and/or remineralizing agents Osteoradionecrosis Pain, bad breath, dysgeusia, numbness, trismus, mastication and speech difficulties Debridement, antibiotic treatment and prophylaxis, hyperbaric oxygen Fibrosis Woody texture and limited neck enhance lymphedema Physiotherapy, myofascial release, external laser Physiotherapy, myofascial release, external laser Mastication muscles fibrosis Oral appliances, diet modification, pharyngeal strengthening, swallow retraining The dropped head syndrome Severe kyphotic deformity of the cervicothoracic spine Supportive care, external orthotic devices Pharyngoesophageal stenosis Dysphagia (Option A) Dilation, surgery and stents Skin changes and skin cancer Acute inflammatory reaction in an area previously exposed to radiation after a chemotherapeutic agent or other medication Removal of skin cancer, maintaining proper skin hygiene, hydrophilic or lipophilic barrier creams with or without hydrogel or hydrocolloid dressings Lymphedema Neck and facial swelling, heaviness, achiness Manual lymph drainage, compression bandages and garments, lymphatic pump Hypothyroidism Slowing of metabolic processes symptoms Thyroxine replacement Hyperparathyroidism Excessive urination, abdominal pain, tiring weakness, depression. bone and joint pain, nausea, vomiting and loss of appetite Calcimimetics, hormone replacement therapy, bisphosphonates Surgical removal of the parathyroid adenoma(s) is curative in most patients Brachial plexopathy Paresthesia, dysesthesia, decreased sensitivity, movement loss, muscular atrophy, shoulder joint dislocation Physical and occupational therapies Eye damage Cataract, retinopathy Monoclonal antibody, triamcinolone, laser, photodynamic therapy, hyperbaric oxygen, pentoxifylline Myelopathy (Option C) refers to a condition affecting the spinal cord and is not a common delayed symptom of head and neck radiation therapy. Dysgeusia (Option D) refers to a distorted or altered sense of taste. While taste changes can occur after head and neck radiation therapy, xerostomia is more commonly observed as a delayed symptom.

References:

https://pmc.ncbi.nlm.nih.gov/articles/PMC7533405/

↑ *Back to this question in Part A*

@Neet_pg_bot

Q68: For which of the following cancers is prophylactic cranial irradiation (PCI) routinely recommended as part of standard management (Q859648)

A. Lung cancer

B. Liver cancer

C. Prostate cancer

D. Breast cancer

Correct Answer: A. Lung cancer

Explanation: Prophylactic cranial irradiation (PCI) is given to cancers with a high risk of brain metastases. It is standard in small cell lung cancer (SCLC) to prevent occult brain metastases and improve survival. It is not routinely used in breast, prostate, or liver cancers.

References:

https://pmc.ncbi.nlm.nih.gov/articles/PMC9020164/

https://pmc.ncbi.nlm.nih.gov/articles/PMC4477380/

↑ *Back to this question in Part A*

@Neet_pg_bot

Q69: A patient with osteoarthritis, for the last 3 months, has been taking ibuprofen and has developed occult GI bleeding. Which is correct about the cause? (Q866795)

A. PGE-2 and prostacyclin production were reduced

B. Increased acid production

C. PGE-1 and prostacyclin production were reduced

D. Mucosal injury due to inhibition of COX-2

Correct Answer: A. PGE-2 and prostacyclin production were reduced

Explanation: NSAIDs like ibuprofen inhibit COX enzymes, reducing prostaglandin (PGE■) and prostacyclin synthesis. These mediators normally maintain gastric mucosal protection by increasing mucus and bicarbonate secretion and promoting mucosal blood flow. Loss of PGE■ and prostacyclin leads to impaired gastric mucosal defense, making the mucosa susceptible to acid-induced injury and bleeding. This is the primary mechanism for NSAID-induced gastritis and peptic ulcers. COX-1 inhibition is particularly responsible for GI side effects, as it is involved in constitutive prostaglandin synthesis for mucosal protection. NSAID-induced GI injury: Mechanism: COX-1 inhibition → ↓ PGE■, ↓ prostacyclin → ↓ mucus, ↓ bicarbonate, ↓ blood flow. Risk factors: High-dose/long-term NSAID use, elderly, alcohol, corticosteroids, H. pylori infection. Prevention: Co-prescription of proton pump inhibitors (PPIs) or misoprostol (PGE■ analog). Histology: Superficial mucosal erosions with inflammatory infiltrates. Complications : Peptic ulcers, GI bleeding, perforation. Incorrect Options: Increased acid production (Option B): NSAIDs do not significantly increase gastric acid secretion; the main issue is reduced mucosal defense. PGE-1 and prostacyclin production reduced (Option C): The main gastric protective prostaglandin is PGE■, not PGE■. Mucosal injury due to inhibition of COX-2 (Option D): COX-2 inhibition is more linked to anti-inflammatory effects and cardiovascular risk, not primary GI mucosal damage (which is COX-1–mediated).

↑ *Back to this question in Part A*

@Neet_pg_bot

Q70: 30 year old male is found to have anemia (MCV 110 fl) with leukonychia and enlarged spleen. The clinical diagnosis is? (Q866825)

A. Portal Hypertension

B. Plummer-Vinson syndrome

C. Achalasia cardia

D. Tylosis palmaris

Correct Answer: A. Portal Hypertension

Explanation: - Portal Hypertension: Portal hypertension is commonly associated with chronic liver disease, which can present with macrocytic anemia (MCV >100 fL) due to folate deficiency or alcohol-related marrow changes. Leukonychia is a classic sign of hypoalbuminemia seen in chronic liver disease. Splenomegaly occurs due to portal hypertension, causing congestive splenic enlargement (hypersplenism). Incorrect Options: Option B - Plummer–Vinson syndrome: This syndrome presents with iron deficiency anemia (microcytic anemia), esophageal webs, and dysphagia, mainly in middle-aged women. It is not associated with leukonychia or splenomegaly. Option C - Achalasia cardia: Achalasia is a primary esophageal motility disorder characterized by dysphagia to solids and liquids. It has no association with anemia, leukonychia, or splenomegaly. Option D - Tylosis palmaris: Tylosis palmaris is a hereditary palmoplantar keratoderma associated with esophageal carcinoma risk. It does not cause anemia, leukonychia, or splenic enlargement.

References:

.

↑ *Back to this question in Part A*

@Neet_pg_bot

Q71: Which classification is used for Barrett esophagus? (Q866826)

A. Prague classification

B. Savary-Miller classification

C. Johnson classification

D. Forrest classification

Correct Answer: A. Prague classification

Explanation: The Prague C & M classification is used for Barrett esophagus, where C denotes the circumferential extent of the Barrett mucosa and M denotes the maximal extent from the gastroesophageal junction, as measured endoscopically. It helps in standardizing reporting and guiding surveillance. Prague Classification Two key measurements: C (Circumferential extent) M (Maximum extent) Circumferential extent Distance (in cm) from the GE junction to the proximal limit of circumferential Barrett's mucosa Maximum extent: Distance from the GE junction to the furthest proximal extension of any Barrett's mucosa (including tongues or islands) Example: If Barrett's mucosa is circumferentially present for 3 cm, and a tongue extends up to 6 cm: Prague classification = C3M6 Incorrect Options: Savary-Miller classification (Option B): Used for grading reflux esophagitis severity based on endoscopic findings. Johnson classification (Option C): Used for types of gastroesophageal reflux depending on the location of the lower esophageal sphincter and diaphragm. Forrest classification (Option D): Used in upper GI bleeding to describe peptic ulcer bleeding stigmata and predict rebleeding risk.

↑ *Back to this question in Part A*

@Neet_pg_bot

Q72: 24-year-old female presents with dysphagia, weight loss and bronchiectasis. Which investigation should be done to confirm the diagnosis. Barium swallow was shown? (Q866504)

A. Esophageal manometry

B. Upper GI endoscopy

C. CT chest

D. CECT chest



Correct Answer: A. Esophageal manometry

Explanation: The barium swallow in this patient shows the classic bird-beak appearance suggestive of achalasia cardia . While barium swallow can suggest the diagnosis, the gold standard test for confirmation is esophageal manometry , which demonstrates incomplete lower esophageal sphincter (LES) relaxation and absence of peristalsis in the esophageal body. Achalasia cardia Definition It is characterized by the progressive degeneration of ganglion cells in the esophageal wall. This leads to a loss of peristalsis in the lower esophagus and failure of the lower esophageal sphincter (LES) to relax during swallowing Clinical Features Dysphagia: May initially affect liquids more than solids. Regurgitation Halitosis Chest Pain Weight Loss Investigations: Esophageal Manometry Gold Standard: This is the definitive diagnostic test for achalasia. It measures the pressure and pattern of muscle contractions in the esophagus. Elevated resting LES pressure (typically > 45 mmHg). Incomplete LES relaxation. Absence of peristalsis in the esophageal body. Periodic contractions with normal amplitude or high amplitude contractions (type I and II achalasia). Barium Swallow (Esophagram) Dilated esophagus with a narrowing at the LES (Bird beak appearance). Endoscopy: Normal mucosa but may show dilated esophagus with possible food debris, It is important to rule out other causes of dysphagia such as tumors. Upper GI endoscopy (Option B): Useful to rule out malignancy (pseudoachalasia) and assess mucosa, but does not confirm motility disorder. CT chest (Option C): Helpful in detecting mediastinal masses or external compression, but not diagnostic for achalasia. CECT chest (Option D): Similar to CT chest, used to rule out secondary causes but not confirm the motility disorder.

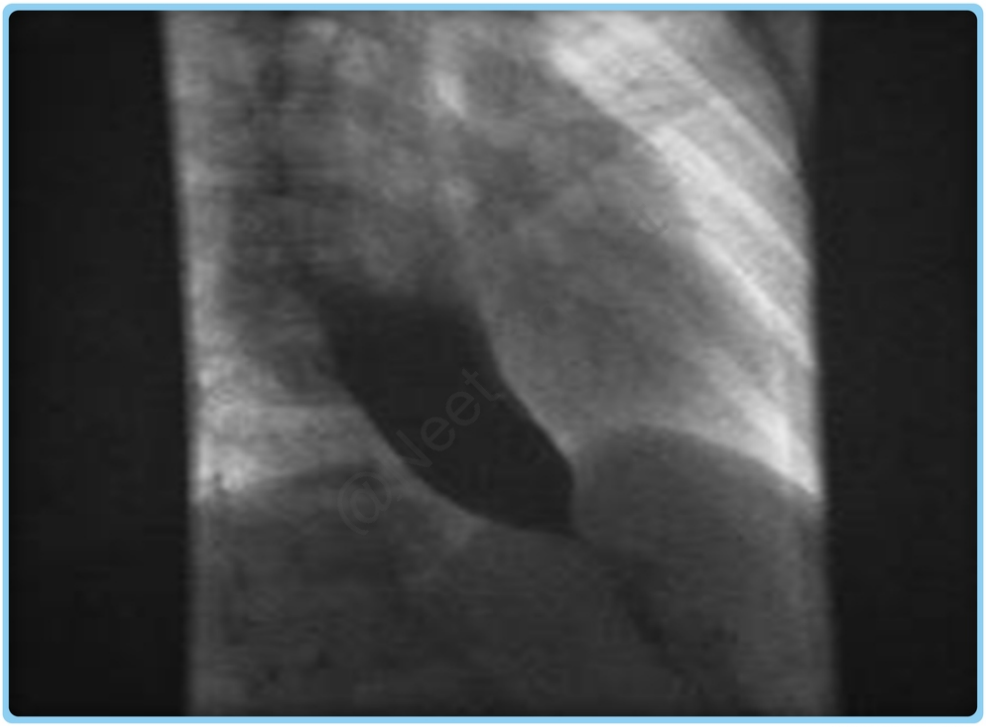

References:

.

↑ *Back to this question in Part A*

@Neet_pg_bot

Q73: Which of the following is not associated with celiac disease? (Q853345)

A. IgA transglutaminase positive

B. IgG antigliadin positive

C. Modified Marsh classification

D. HLA DQ6 and HLA DQ11

Correct Answer: D. HLA DQ6 and HLA DQ11

Explanation: HLA-DQ6 and HLA-DQ11 are not associated with celiac disease. In contrast, HLA-DQ2 and HLA-DQ8 are the primary genetic markers found in almost all individuals with celiac disease. Celiac disease is an autoimmune disorder triggered by gluten ingestion in genetically predisposed individuals. It primarily affects the proximal small intestine, with the duodenum most commonly involved. In some cases, it extends to the jejunum,

causing more severe symptoms. Pathophysiology: Genetics : HLA-DQ2 and HLA-DQ8 are associated with celiac disease. Immune Response : Gluten ingestion triggers inflammation in the small intestine Symptoms: Gastrointestinal : Diarrhea, abdominal pain, bloating, nausea, vomiting, steatorrhea. Extra-intestinal : Fatigue, skin rashes (dermatitis herpetiformis), weight loss, anemia, joint pain, headaches, peripheral neuropathy. In Children : Delayed growth, irritability, poor weight gain, bone issues due to malabsorption. Diagnosis: 1. Serological Testing: Tissue Transglutaminase (tTG) Antibodies: Most sensitive and specific test. (Option A ruled out) Anti-Endomysial Antibodies (EMA) Anti-Gliadin Antibodies (AGA): Less specific. (Option B ruled out) 2. Histological Confirmation: Upper gastrointestinal endoscopy with small bowel biopsy is the gold standard. Histological Changes : Villous Atrophy : Flattened villi. {{caption_text}} Crypt Hyperplasia : Increased crypt cells. Intraepithelial Lymphocytosis : Elevated lymphocytes. 3. Histological Grading (Modified Marsh Classification): (Option C ruled out) Type Definition 0 Normal duodenal biopsy I Normal mucosal architecture with increased intraepithelial lymphocytes II Hyperplastic crypts, but near normal Villi IIIa Hyperplastic crypts with partial villous atrophy IIIb Hyperplastic crypts with subtotal villous atrophy IIIc Hyperplastic crypts with total villous atrophy Treatment: Gluten-Free Diet : Lifelong, strict adherence is the only treatment. Gluten-containing foods (BROW) : Barley, Rye, Oats, Wheat. Complications: Malnutrition : Due to impaired absorption. Osteoporosis : From poor calcium and vitamin D absorption. Intestinal Lymphoma and Small Bowel Cancer : Rare but serious. Increased Risk of Autoimmune Disorders : Such as Type 1 diabetes and autoimmune thyroid disease. Feature Coeliac Sprue Whipple's Disease Tropical Sprue Description Autoimmune disorder triggered by gluten. Systemic infectious disease caused by Tropheryma whipplei. Malabsorption disorder seen in tropical regions. Cause often unknown, possibly infectious. Etiology Genetic predisposition (HLA-DQ2/DQ8). Environmental trigger: gluten (present in wheat, barley, rye) ingestion and an immune response to gliadin, a protein in gluten. Infection with Tropheryma whipplei, found in soil and sewage. Possibly due to bacterial, fungal or coronavirus infection. Clinical Features Affects mainly proximal small intestine. Intestinal Features: Chronic diarrhea or steatorrhea. Malabsorption: weight loss, vitamin deficiencies. Abdominal pain, bloating. Extraintestinal Features: Iron-deficiency anemia. Dermatitis herpetiformis (in some cases). Affects mainly distal small intestine. Intestinal Features: Chronic diarrhea. Malabsorption, weight loss. Abdominal pain and bloating. Extraintestinal Features: Arthralgia (joint pain). Fever. Lymphadenopathy. Neurological symptoms (cognitive impairment, seizures, ataxia in advanced stages, oculomasticatory myorhythmia). Uveitis Cardiac involvement (rare). Affects entire small intestinal Intestinal Features: Chronic diarrhea. Malabsorption, weight loss. Abdominal pain, bloating. Extraintestinal Features: Anemia (often megaloblastic). Histological Findings {{caption_text}} Loss or flattening of intestinal villi (villous atrophy). Hyperplastic crypts (crypt elongation). Increased infiltration of lymphocytes, especially CD8+ T cells. Increased plasma cells, lymphocytes, macrophages in lamina propria. {{caption_text}} Villous blunting and atrophy. Dense infiltration of lamina propria by macrophages containing PAS-positive granules. Foamy macrophages laden with Tropheryma whipplei in various tissues (e.g., lymph nodes, CNS, synovial fluid). {{caption_text}} Villous atrophy. Crypt hyperplasia. Increased inflammatory cells (similar to Celiac disease but without gliadin-specific immune response). Investigations Biopsy Serologic Tests: Most sensitive and most common antibody test: Anti-Tissue Transglutaminase Antibodies (Anti-tTG) - IgA and IgG Most specific antibody test: Anti-Endomysial Antibodies (EMA) - IgA. Anti-Deamidated Gliadin Peptide (DGP) Antibodies - IgA and IgG. Anti-Gliadin Antibodies (AGA) - IgA and IgG. Biopsy PCR for Tropheryma whipplei DNA. Immunohistochemistry for Tropheryma whipplei. Biopsy Response to Treatment: Antibiotic response helps confirm diagnosis. Management Lifelong gluten-free diet. Nutritional supplementation: iron, folate, calcium, vitamin D. Indications for steroids: Refractory disease for 6-12 months Celiac crisis Lymphoma Monitoring for complications Prolonged antibiotic therapy: Initially IV ceftriaxone or meropenem for 2 weeks. Followed by oral trimethoprim-sulfamethoxazole for a year. Tetracycline for 6 months. Folate supplementation. Some recommend a gluten-free diet. Complications Osteoporosis. Malignancy (e.g., small bowel lymphoma). Infertility. Neurological complications (rare). Failure to thrive. Untreated disease can be fatal due to multi-organ involvement. Relapses are common (especially CNS). Nutritional deficiencies can lead to osteoporosis, cachexia.

Nutritional deficiencies (e.g., vitamin B12, folate). Persistent malabsorption. Possible relapse and chronic diarrhea.

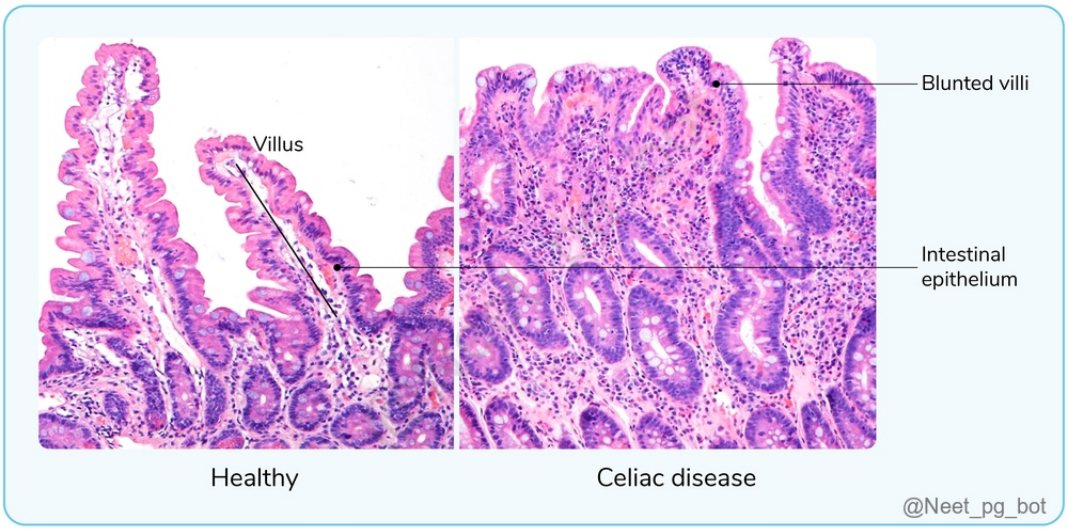

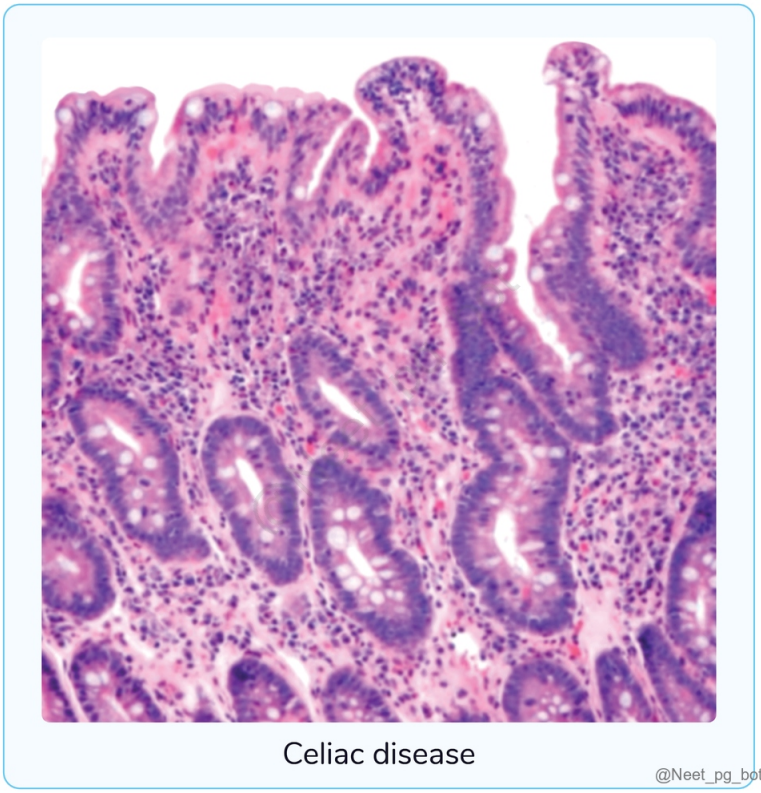

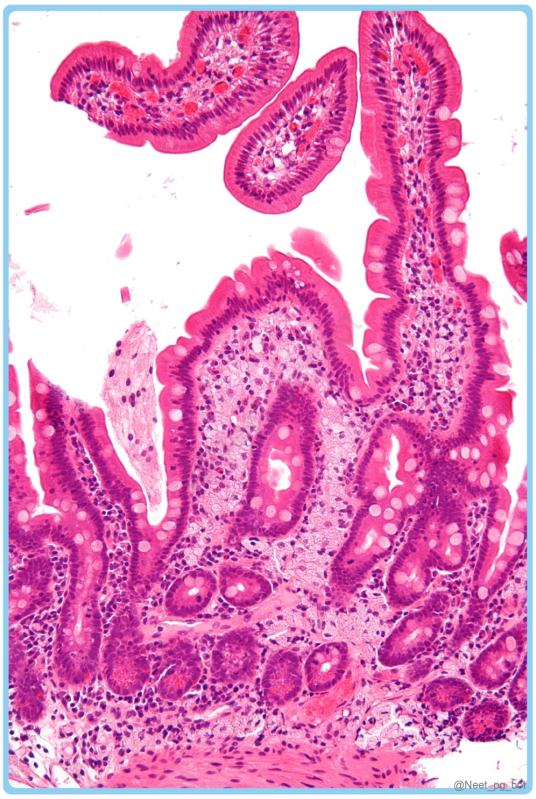

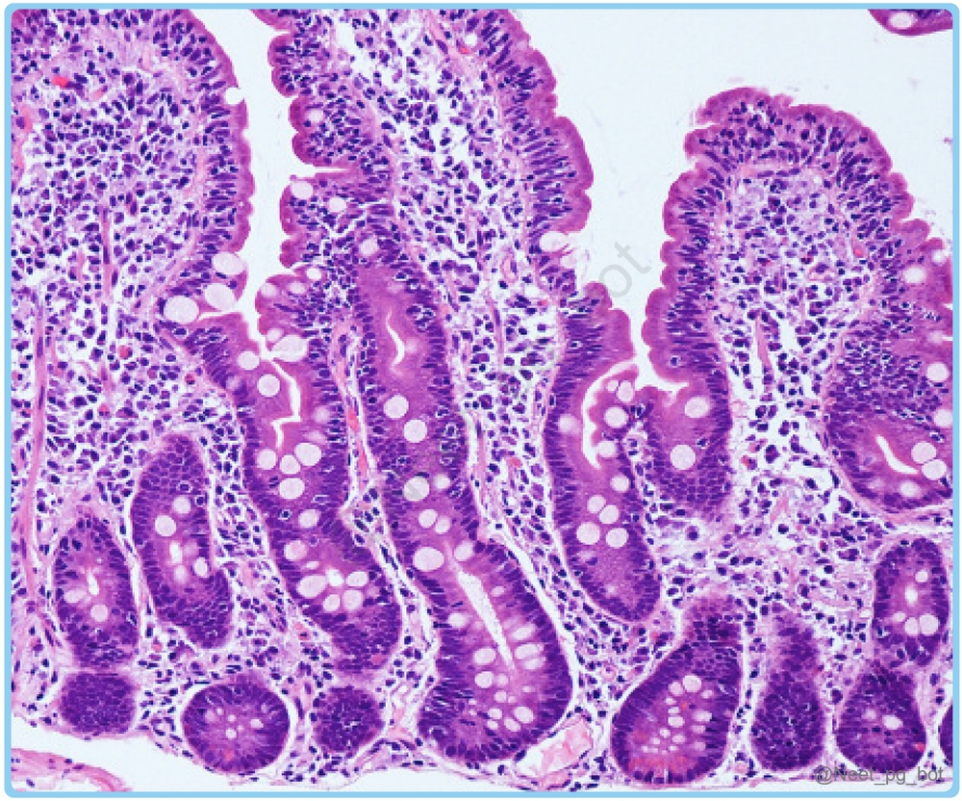

References:

Robbins and Cotran Pathologic Basis of Disease, 10th Edition, Pages 784-786, 794.

Harrison's Principles of Internal Medicine, 21st Edition, Pages 2464, 2465.

https://www.researchgate.net/figure/Modified-Marsh-classification-of-celiac-disease_tbl1_8505308

↑ *Back to this question in Part A*

@Neet_pg_bot

Q74: A known case of ulcerative colitis is not responding to an anti-TNF alpha agent. Which JAK inhibitor is preferred for moderate to severe ulcerative colitis? (Q853355)

A. Vedolizumab

B. Tofacitinib

C. Ozanimod

D. Leflunomide

Correct Answer: B. Tofacitinib

Explanation: Tofacitinib is a oral JAK inhibitor that works by inhibiting the JAK-STAT pathway, which regulates cytokine-mediated inflammation. It is approved for the treatment of moderate to severe ulcerative colitis, particularly in patients who are refractory or intolerant to anti-TNF agents like infliximab or adalimumab. Tofacitinib is a JAK 1/3 inhibitor and blocks the production of inflammatory cytokines such as interleukin-6 and interferons. It is effective for inducing and maintaining remission in moderate to severe ulcerative colitis. Side effects include an increased risk of infections, venous thromboembolism, and lipid elevation, requiring careful patient selection and monitoring. Vedolizumab (Option A) is an anti-integrin monoclonal antibody targeting $\alpha 4\beta 7$ integrin, used to treat moderate to severe ulcerative colitis and Crohn's disease. Ozanimod (Option C) is an FDA-approved sphingosine-1-phosphate (S1P1) receptor modulator for moderate to severe ulcerative colitis, reducing lymphocyte migration to the gut. Leflunomide (Option D) is a pyrimidine synthesis inhibitor primarily for rheumatoid arthritis treatment.

References:

Goodman & Gillman’s The Pharmacological Basis of Therapeutics, 14th Edition, Pages 782, 783, 790.

PMC Article

↑ *Back to this question in Part A*

@Neet_pg_bot

Q75: A 70-year-old male patient presents with a complaint of dysphagia, particularly for solids, which has been progressively worsening over the past few months.

Additionally, he has experienced significant weight loss and cachexia over the same period. Which of the following diagnostic choices is best for this patient? (Q860394)

A. UGIE

B. Manometry

C. Barium swallow

D. Barium meal follow through

Correct Answer: A. UGIE

Explanation: The presentation of progressive dysphagia for solids with significant weight loss and cachexia in an elderly patient strongly suggests esophageal carcinoma . Upper GI endoscopy (UGIE) is the gold standard diagnostic tool in this scenario as it allows direct visualization of the tumor and enables tissue biopsy for definitive diagnosis. UGIE also permits thorough examination of the larynx, trachea, and bronchi, which is crucial as this population has a higher risk of head and neck malignancies. Additionally, CT scanning of the chest and abdomen is typically performed to assess tumor spread to mediastinal and para-aortic lymph nodes. Manometry (Option B): While manometry is useful in diagnosing esophageal motility disorders such as achalasia, it is not the appropriate first-line investigation when malignancy is suspected (Option B ruled out). Manometry cannot provide visual confirmation of tumors or allow for tissue sampling. Barium swallow (Option C) : Although barium swallow can demonstrate mucosal abnormalities and strictures, it cannot provide tissue diagnosis which is essential when malignancy is suspected (Option C ruled out). It may be used as a complementary study but should not be the primary diagnostic tool in this scenario. Barium meal follow through (Option D) : This study is primarily used to evaluate the small intestine and is not appropriate for investigating suspected esophageal pathology (Option D ruled out). It would not provide the necessary information about the esophageal lesion or allow for tissue sampling.

↑ *Back to this question in Part A*

@Neet_pg_bot

Q76: Which of the following symptoms suggests the use of steroids in IgA vasculitis? (Q840121)

A. Joint inflammation

B. Gastrointestinal hemorrhage

C. Abdominal discomfort

D. Dermatological eruption

Correct Answer: B. Gastrointestinal hemorrhage

Explanation: Correct Option B - Gastrointestinal hemorrhage: Steroids are administered in cases of gastrointestinal bleeding or suspected perforation to mitigate inflammation and reduce the risk of complications. Incorrect Options: Options A, C & D are incorrect.

↑ *Back to this question in Part A*

@Neet_pg_bot

Q77: In which of the following conditions is pneumomediastinum commonly found? (Q860160)

A. Pulsion diverticulum

B. Boerhaave syndrome

C. Mallory-Weiss syndrome

D. Pericarditis

Correct Answer: B. Boerhaave syndrome

Explanation: Pneumomediastinum is one of the complication associated with Boerhaave syndrome , which is a condition characterized by spontaneous full-thickness rupture of the esophagus. Boerhaave syndrome clinically manifests as Mackler's triad (Vomiting, chest pain, and subcutaneous emphysema). The condition is often preceded by forceful vomiting. This condition typically occurs in the lower third of the esophagus and results in a direct communication between the esophageal lumen and mediastinal space. The rupture allows esophageal contents to spill into the mediastinum which can occasionally lead to complications such as pneumomediastinum and chemical mediastinitis . Boerhaave syndrome Definition It is a spontaneous esophageal rupture caused by a sudden increase in intraesophageal pressure, typically from vomiting against a closed glottis resulting in a left-sided esophageal perforation , which allows gastric contents to spill into the pleural cavity, leading to a left pleural effusion and subcutaneous emphysema . Classic triad Vomiting, chest pain, and subcutaneous emphysema. (Mackler's triad) Other Symptoms May include fever, tachycardia, and tachypnea in the presence of sepsis Physical examination Hamman's sign (crunching sound on auscultation due to surgical emphysema). Complications Pneumothorax/ Pneumomediastinum , mediastinitis, and sepsis. Pulsion diverticulum (Option A) occurs due to increased intraluminal pressure in the esophagus, forming an outpouching of the esophageal wall. While it can cause symptoms like dysphagia and regurgitation, it does not typically result in pneumomediastinum as the esophageal wall remains intact. Mallory-Weiss syndrome (Option C) involves longitudinal mucosal tears at the gastroesophageal junction, typically following forceful vomiting. While it can cause hematemesis, the tear is superficial and does not extend through the full thickness of the esophageal wall, thus not causing pneumomediastinum. Pericarditis (Option D) is inflammation of the pericardium, the fibrous sac surrounding the heart. While it causes chest pain and other symptoms related to inflammation, it does not involve the esophagus and does not cause pneumomediastinum.

References:

Bailey & Love's Short Practice of Surgery, 28th Edition, Page 1127,1128

↑ *Back to this question in Part A*

@Neet_pg_bot

Q78: A 42-year-old female presents with complaints of recurrent episodes of abdominal pain and cramps. An endoscopy is done and she is diagnosed with ulcerative colitis. She currently has 3-4 episodes of bloody stools per day. What is the appropriate initial treatment? (Q854665)

A. Budesonide

B. Sulfasalazine

C. Azathioprine

D. Bezlotoxumab

Correct Answer: B. Sulfasalazine

Explanation: Sulfasalazine is commonly used in the treatment of ulcerative colitis (inflammatory bowel disease). Sulfasalazine Anti-inflammatory Properties: Sulfasalazine is composed of two components: Sulfapyridine and 5-aminosalicylic acid (5-ASA) . The 5-ASA component is responsible for the drug's anti-inflammatory effects. It inhibits the production of inflammatory mediators such as prostaglandins and leukotrienes, which play a role in the inflammation seen in ulcerative colitis. Immunomodulatory Effects: Sulfasalazine also has immunomodulatory effects, which help to regulate the immune response in the gastrointestinal tract. By modulating the activity of immune cells such as macrophages and T cells, sulfasalazine can reduce inflammation. Antibacterial Activity: Sulfasalazine's sulfapyridine component has antibacterial properties. It acts by disrupting the metabolism of certain bacteria, particularly those in the gut microbiota. By targeting bacteria, sulfasalazine may help to restore balance to the gut microbiome. Local Action in the Colon: Sulfasalazine is administered orally, and its 5-ASA component is not absorbed systemically to a significant extent. Instead, it remains largely in the colon, where it exerts its anti-inflammatory effects directly on the inflamed tissue. This targeted action reduces the risk of systemic side effects commonly associated with corticosteroids or other systemic immunosuppressive agents. Maintenance Therapy: Sulfasalazine is often used as maintenance therapy in ulcerative colitis. It helps prevent flare-ups and maintain remission over the long term. Symptomatic Relief: In addition to its disease-modifying effects, sulfasalazine can provide symptomatic relief from the symptoms of ulcerative colitis, such as diarrhoea, abdominal pain, and rectal bleeding. Incorrect Options: Budesonide (Option A) is used in cases of exacerbation of ulcerative colitis, especially mild to moderate cases. Azathioprine (AZA) (Option C) is a medication used in the management and treatment of active rheumatoid arthritis (RA) and the prevention of kidney transplant rejection. Bezlotoxumab (Option D) is indicated to reduce the recurrence of Clostridium difficile infection (CDI) in patients who are receiving antibacterial drug treatment for CDI and are at high risk for CDI recurrence.

References:

Harrison’s Principles of Internal Medicine, 21st Edition, Page: 2474, 2475.

Goodman & Gillman’s The Pharmacological Basis of Therapeutics, 13th Edition, Page: 945.

↑ *Back to this question in Part A*

@Neet_pg_bot

Q79: A patient was taking ampicillin for an upper respiratory tract infection. Then he started having watery diarrhoea for the past 3 days. Which is the drug of choice to manage this condition? (Q854689)

A. Metronidazole

B. Fidaxomicin

C. Ciprofloxacin

D. Bezlotoxumab

Correct Answer: B. Fidaxomicin

Explanation: The overuse of antibiotics like ampicillin leads to diarrhoea and further, a condition called pseudomembranous colitis caused by Clostridium difficile and is treated with Fidaxomicin . Clostridioides Difficile Infection (CDI) A colonic disease caused by C. difficile, linked to antibiotic use disrupting normal gut microbiome. It results in diarrhoea and severe cases, of pseudomembranous colitis (PMC). Etiology & Epidemiology: C. difficile is a spore-forming, anaerobic bacterium. Most commonly acquired in hospitals, nursing homes, and after antibiotic use. High-risk antibiotics: Clindamycin , Ampicillin , Cephalosporins , and Fluoroquinolones (Option C) . CDI is common in healthcare settings and can also occur in the community without prior antibiotic use. Pathogenesis: Ingestion of spores leads to toxin production (Toxin A and Toxin B) causing gut damage, diarrhoea, and PMC. Toxin B is the more important virulence factor. Diagnosis: Based on diarrhoea (≥3 unformed stools/day for ≥2 days). Toxin detection in stool (via PCR or enzyme immunoassays). Endoscopy can detect PMC in advanced cases. Treatment: First-line: Oral Vancomycin or Fidaxomicin Metronidazole is an alternative for mild cases . (Option A) Hydration and avoiding antiperistaltic agents are recommended. For severe cases, Oral Vancomycin is preferred, especially if the patient is seriously ill. IV Vancomycin is ineffective. Bezlotoxumab (Option D) is a monoclonal antibody against C.difficile toxin B used in recurrent pseudomembranous colitis as an adjunct with vancomycin, fidaxomicin or metronidazole. It is not the first-line treatment for this condition.

References:

Harrison’s Principles of Internal Medicine, 21st Edition, Page: 1066-1069.

↑ *Back to this question in Part A*

@Neet_pg_bot

Q80: A 49-year-old male is experiencing recurring episodes of watery diarrhea, dehydration, hypokalemia, and achlorhydria. Which type of neuroendocrine tumor could potentially cause these symptoms? (Q858363)

A. Insulinoma

B. Somatostatinoma

C. VIPoma

D. Glucagonoma

Correct Answer: C. VIPoma

Explanation: VIPoma is a type of neuroendocrine tumour that produces vasoactive intestinal peptides (VIP). They are linked to syndromes like: Verner-Morrison syndrome. Pancreatic cholera. WDHA syndrome (watery diarrhoea, hypokalemia, achlorhydria). VIP, a 28-amino-acid peptide, mimics cholera toxin effects by: Stimulating chloride secretion in the small intestine. Increasing smooth muscle contractility. Leading to severe diarrhoea. Clinical features: Patients typically present with: Severe watery diarrhoea leads to hypokalemia and metabolic acidosis. Flushing episodes. Low stomach acid (achlorhydria / hypochlorhydria). Increased glycogen breakdown. Elevated calcium levels (hypercalcemia). Tumor Characteristics: Typically solitary. Often located in the pancreatic tail. Diagnosis: Elevated plasma VIP levels are common but not definitive for diagnosis, as they can occur in other conditions like: Inflammatory bowel disease. Post-surgery (small bowel resection). Radiation enteritis. Chronic laxative or diuretic use can complicate diagnosis. Treatment: Critical management includes: Fluid and electrolyte replacement to address dehydration, hypokalemia, and electrolyte losses. Long-term treatment options: Somatostatin analogues are effective in controlling diarrhoea. Surgical resection is recommended for localized tumours. Insulinoma (Option A) : An insulinoma presents with symptoms of hypoglycemia including weakness, fatigue, sweating, palpitations, confusion, and seizures. These tumors produce excess insulin, leading to low blood sugar, but do not cause the profound diarrhea and electrolyte disturbances seen in this patient. Somatostatinoma (Option B) : Somatostatinomas typically present with diabetes mellitus, cholelithiasis, diarrhea, and steatorrhea due to somatostatin's inhibitory effects on digestive enzyme secretion. While diarrhea can occur, the complete WDHA syndrome is not a feature of this tumor. Glucagonoma (Option D) : Glucagonomas are characterized by necrolytic migratory erythema, diabetes mellitus, weight loss, and anemia. They do not typically cause the severe secretory diarrhea and electrolyte abnormalities seen in this case.

References:

Harrison’s Principles of Internal Medicine, 21st edition, Page: 665.

Vasoactive Intestinal Peptide-Secreting Tumor (VIPoma) - Endotext - NCBI Bookshelf

Clinically Important Toxins in Bacterial Infection: Utility of Laboratory Detection - PMC

↑ *Back to this question in Part A*

@Neet_pg_bot

Q81: Mark the correct statement regarding inflammatory bowel disease. (Q855605)

A. Skip lesions are present in Crohn’s disease

B. Mucosal layers are involved in Crohn’s while transmural involvement seen in ulcerative colitis

C. Inflammatory bowel disease doesn’t have a genetic predisposition

D. Crohn’s is curable through surgical resection of the affected segment

Correct Answer: A. Skip lesions are present in Crohn’s disease

Explanation: Skip lesions refer to the characteristic feature of Crohn's disease where there are areas of inflammation that are separated by normal or unaffected segments of the bowel. This pattern of involvement is not seen in ulcerative colitis. Skip lesions can occur throughout the entire gastrointestinal tract, from the mouth to the anus, in Crohn's disease. In Crohn's disease, the inflammation can involve all layers of the bowel wall, which is known as transmural involvement . In ulcerative colitis, the inflammation is limited to the mucosal layer of the colon and rectum. (Option B) Both Crohn's disease and ulcerative colitis have a strong genetic component , indicating a predisposition to developing these conditions (Option C) . Family history of inflammatory bowel disease is a known risk factor. Crohn's disease is a chronic condition that requires long-term management and treatment (Option D) to control inflammation and maintain remission. Learning Objective: Distinguishing features between Crohn’s Disease and Ulcerative colitis Clinical features Crohn’s Disease Ulcerative colitis Affects Any part of GIT from mouth to anus. Primarily, the colon is involved. Rectal involvement The rectum is often spared. It almost always involves the rectum, hence associated with rectal bleeding. Skin lesions, Bowel wall thickening, Strictures, and Perianal manifestations Common Rare Inflammation Transmural and segmental Mucosal and continuous involvement Granulomas Noncaseating granulomas are characteristic of Crohn’s disease. Granulomas are not typically present.

References:

Harrison’s Principles of Internal Medicine, 21st Edition, Page 2474

↑ *Back to this question in Part A*

@Neet_pg_bot

Q82: Which of the following are not included in the components of the MELD (2016) score? (Q856338)

A. Bilirubin

B. INR

C. Albumin

D. Creatinine

Correct Answer: C. Albumin

Explanation: Albumin is included in the calculation of the PELD (Pediatric End-Stage Liver Disease) and not the MELD (Model for End-Stage Liver Disease) score. MELD (Model for End-Stage Liver Disease) score: Predicts prognosis in chronic liver disease It was developed to predict 3-month mortality in patients after TIPSS (transjugular portosystemic shunt) Used in UNOS (United Nations Organ Sharing Network) to determine priority for liver transplantation. Most patients with low MELD scores (less than 15) do not benefit from transplantation Score: 6 - 40 Components: C reatinine (Option D) B ilirubin (Option A) I NR (Option B) PELD (Pediatric End-Stage Liver Disease) Score: Used to determine priority for children awaiting liver transplantation Components: N utrition A ge B ilirubin I NR Albumin

References:

Bailey & Love's Short Practice Of Surgery, 27th edition, Page 1620

Sabiston Textbook of Surgery, 21st edition, Page 618, 619

https://pubmed.ncbi.nlm.nih.gov/12151728/

↑ *Back to this question in Part A*

@Neet_pg_bot

Q83: What is the probable diagnosis of a patient who has significant abdominal swelling and laboratory analysis of the fluid obtained through paracentesis reveals SAAG <1.1? (Q856355)

A. Congestive heart failure

B. Myxoedema

C. Budd Chiari syndrome

D. Tuberculosis

Correct Answer: D. Tuberculosis

Explanation: Among the given options, only in tuberculosis SAAG score will be < 1.1 mg/dl, all others will have SAAG >1.1mg/dl. Congestive heart failure (Option A) can also lead to the development of ascites. However, in this, the SAAG is usually greater than 1.1 g/dL. SAAG is usually greater than 1.1 g/dL in myxoedema (Option B) and Budd Chiari syndrome (Option C). Interpretations of SAAG: SAAG ≥1.1 g/dL: Portal hypertension (ascites is due to increased pressure in the hepatic sinusoids) Ascitic protein level ≥2.5 g/dL : Hepatic sinusoids are normal (allows passage of protein) Ascitic protein level <2.5 g/dL : Hepatic sinusoids are damaged and scarred (no passage of protein) SAAG <1.1 g/dL: Ascites is not related to portal hypertension.

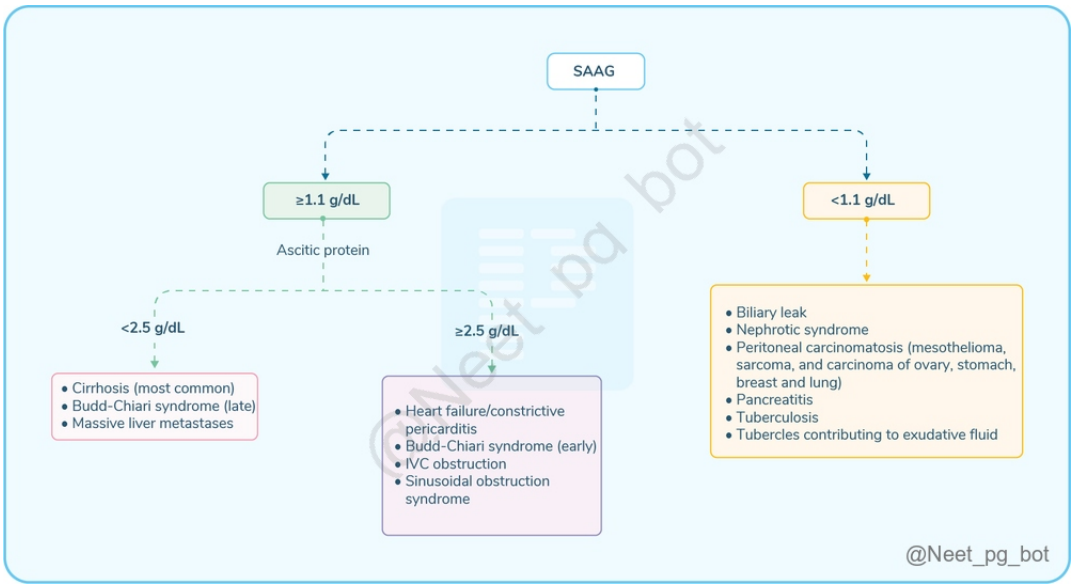

References:

Harrison’s Principles of Internal Medicine, 21st edition, Page 323

Davidson’s Principles and Practice of Medicine, 24th edition, Page 863

↑ *Back to this question in Part A*

@Neet_pg_bot

Q84: What is not a characteristic feature of Wilson's disease? (Q856381)

A. Autosomal recessive disease

B. No free radical injury

C. ATP7B gene involved

D. Presents before age 40 with liver disease

Correct Answer: B. No free radical injury

Explanation: Free radical injury due to an excess of copper ions is seen in patients with Wilson's disease. Wilson's disease Wilson's disease, also known as hepatolenticular degeneration , is a rare autosomal recessive disorder (Option A), usually presents before age 40 (Option D) with liver disease caused by the abnormal accumulation of copper in the liver, brain, eyes, and other organs. This results in elevated free copper levels, along with increased copper levels in the liver and urine, while serum ceruloplasmin levels are decreased. Gene Affected: The disease is caused by mutations in the ATP7B gene (Option C) on chromosome 13. This gene encodes a copper-transporting ATPase responsible for excreting copper from the liver into bile. Pathogenesis: Lab parameters of Wilson’s disease Parameter Change

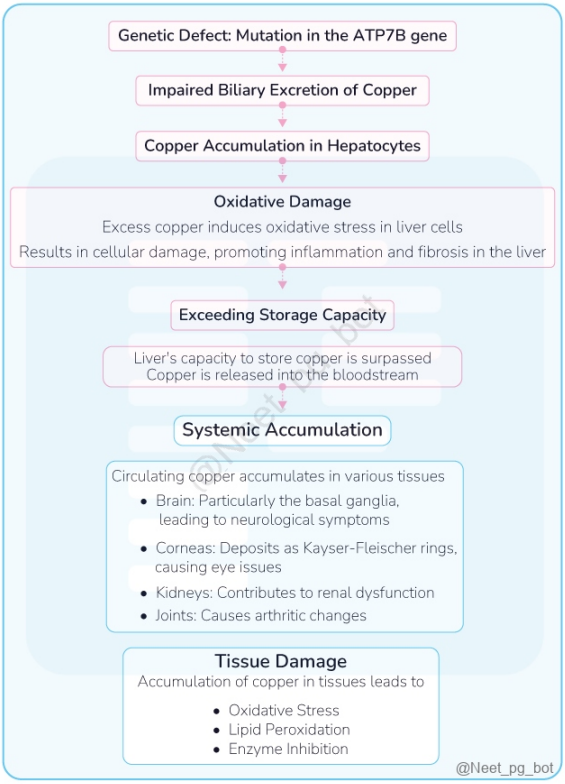

References:

Harrison's principles of internal medicine, 21st edition, Page 3235

Davidson's principles and practice of medicine, 24th edition, Page 896, 897

https://tinyurl.com/3ek9r4ym

↑ *Back to this question in Part A*

@Neet_pg_bot

Q85: A 15-year-old girl presented with fatigue, chronic diarrhoea, weight loss, bone pain and abdominal distension. Investigations revealed iron deficiency anemia and osteoporosis. Which of the following is the single best test to be done for her evaluation? (Q858444)

A. TSH levels

B. C-peptide levels

C. Urine sugar and ketone

D. IgA tissue transglutaminase antibody

Correct Answer: D. IgA tissue transglutaminase antibody

Explanation: The clinical scenario of fatigue, chronic diarrhea, weight loss, bone pain, abdominal distension, iron deficiency anemia, and osteoporosis strongly indicates celiac disease . The single best test for its evaluation is the IgA tissue transglutaminase antibody. Celiac Disease: Also called celiac sprue or gluten-sensitive enteropathy. Associated with HLA-DQ2 and DQ8. Small intestinal enteropathy caused by immune response to gluten. Characterized by autoantibodies to tissue transglutaminase. Gluten is found in wheat, rye, barley, and some oats. Pathogenesis: Tissue transglutaminase deamidates glutamine residues of gluten-derived peptides, facilitating immune response. Affects the proximal small intestine. Clinical Features: Diarrhea, weight loss , growth failure (children). Bloating , irregular bowel habits, migraines, ataxia. May present with osteoporosis, iron-deficiency anemia , or abnormal liver enzymes. Diagnosis: Serum antibodies: Tissue transglutaminase IgA , anti-endomysial, deamidated anti-gliadin antibodies. Measure serum IgA levels to detect IgA deficiency. Confirmatory testing: Endoscopy with small-intestinal biopsy. Biopsy findings: Villus blunting, crypt hyperplasia, increased intraepithelial lymphocytes. Marsh classification used for severity grading. Management: Lifelong strict gluten-free diet. TSH levels (Option A): Thyroid dysfunction can cause fatigue and weight loss, but it does not explain chronic diarrhea, iron deficiency anemia, or osteoporosis. These symptoms point toward malabsorption rather than thyroid disease, making TSH an inappropriate choice in this context. C-peptide levels (Option B): C-peptide is useful in evaluating insulin secretion and distinguishing between type 1 and type 2 diabetes. However, diabetes does not typically present with chronic diarrhea, iron deficiency anemia, or osteoporosis, making it irrelevant here. Urine sugar and ketones (Option C): While this test helps identify diabetes and diabetic ketoacidosis, the patient's symptoms, such as malabsorption and nutrient deficiencies, do not suggest these conditions. Chronic diarrhea and weight loss are not hallmark features of diabetes.

References:

Harrison’s Principle of Internal Medicine, 21st Edition, Page 2463,2464

↑ *Back to this question in Part A*

@Neet_pg_bot

Q86: A patient with inflammatory bowel disease presents with the following lesion. What is the most likely diagnosis? (Q859643)

A. Erythema nodosum

B. Pyoderma gangrenosum

C. Diabetic ulcer

D. Venous ulcer



Correct Answer: B. Pyoderma gangrenosum

Explanation: The given clinical scenario and image are suggestive of Pyoderma gangrenosum which is more common in Ulcerative colitis a type of inflammatory bowel disease. Pyoderma gangrenosum is a rare, inflammatory skin condition characterized by the development of painful, ulcerative lesions. It can occur in patients with inflammatory bowel disease, and the lower limbs are a common site of involvement. The ulcers typically have undermined borders and may have a necrotic or purulent appearance. Extraintestinal manifestations of IBD: Erythema nodosum (A skin condition characterized by painful red nodules typically found on the shins). (Option A) Ankylosing spondylitis (Arthritis of the spine) Pancreatitis Uveitis (Inflammation of the uvea) Osteoporosis and Osteonecrosis are overall the most common extra-intestinal manifestations of IBD. Pyoderma gangrenosum is common in Ulcerative colitis. Primary Sclerosing Cholangitis is common in Ulcerative colitis. Renal calculi is common in Crohn’s disease. Diabetic ulcer (Option C) is not associated with inflammatory bowel disease. It is a complication of uncontrolled diabetes mellitus. Venous ulcer (Option D) is usually caused by conditions like long-standing varicose veins. It is usually situated around the ankles.

References:

Harrison’s Principles of Internal Medicine, 21st Edition, Page: 2481.

↑ *Back to this question in Part A*

@Neet_pg_bot

Q87: Match the following? a. Trisomy 13 1. Huntington's disease b. Trisomy 18 2. Patau syndrome c. Trinucleotide repeat sequence 3. Sickle disease d. Hb point

mutation of glutamate to valine 4. Edward syndrome (Q857256)

A. a-2, b-4, c-1, d-3

B. b-1, a-3, d-2, c-4

C. a-2, b-1, c-4, d-3

D. a-4, b-1, c-3, d-2

Correct Answer: A. a-2, b-4, c-1, d-3

Explanation: hromosomal anomaly Disease Clinical features Trisomy 13 Patau syndrome Short life expectancy Cleft lip and palate Polydactyly Small head Frequent congenital heart disease Trisomy 18 Edward syndrome Early demise Characteristic skull and facies Frequent heart, kidney, and other organ anomalies Trinucleotide repeat sequence Huntington's disease Motor disturbances Behavioural and psychiatric symptoms Cognitive decline Hb point mutation of glutamate to valine Sickle disease Anemia Jaundice Dactylitis Sickle cell crisis Fatigue Fever Chest pain Shortness of breath

References:

Davidson’s Principles and Practice of Medicine, 24th Edition, Page: 44.

https://www.ncbi.nlm.nih.gov/books/NBK559166/

https://www.nhlbi.nih.gov/health/sickle-cell-disease/symptoms

↑ *Back to this question in Part A*

@Neet_pg_bot

Q88: How much sodium deficit needs to be corrected in a 40 kg female with a serum sodium level of 120 mEq/L to achieve a desired sodium concentration of 140 mEq/L? (Q830815)

A. 400 mEq

B. 300 mEq

C. 200 mEq

D. 100 mEq

Correct Answer: A. 400 mEq

Explanation: Correct Option A - 400 mEq: Sodium Deficit=(Desired Na−Current Na)×Total Body Water (TBW) where, TBW = 0.5 x body weight in Kg, for females Hence, Sodium deficit= 0.5 x 40 x (140-120) = 0.5 x 40 x 20 = 400 mEq

↑ *Back to this question in Part A*

@Neet_pg_bot

Q89: During the medication review of an elderly male patient with a history of COPD, hypertension, and diabetes, what criteria should the physician consider? (Q830826)

A. Duke’s criteria

B. Light criteria

C. Beer’s criteria

D. Jones criteria

Correct Answer: C. Beer’s criteria

Explanation: Correct Option C - Beer’s criteria: Beer's criteria are guidelines related to the use of medications in older adults, focusing on potentially inappropriate medications and drug-disease interactions in the elderly. It provides recommendations to avoid certain medications or adjust doses based on the potential risks and side effects in the geriatric population. Incorrect Options: Option A - Duke’s criteria: Duke's criteria are primarily used for the diagnosis of infective endocarditis. Option B - Light criteria: Light's criteria are employed in the assessment of pleural effusions to differentiate transudative from exudative effusions. Option D - Jones criteria: Jones criteria are used in the diagnosis of rheumatic fever.

↑ *Back to this question in Part A*

@Neet_pg_bot

Q90: What vitamin deficiency is responsible for the following symptoms in a patient: tingling sensation in the hands and feet, generalized weakness, easy fatigability, pallor, and ataxia? (Q793810)

A. Vitamin B1

B. Vitamin B12

C. Vitamin B2

D. Vitamin B3

Correct Answer: B. Vitamin B12

Explanation: The symptoms described in the question, including tingling sensation in hands and feet, generalized weakness, easy fatiguability, pallor, and ataxia, are suggestive of a neurological condition known as peripheral neuropathy. Several vitamin deficiencies can cause peripheral neuropathy, but the most common ones are deficiencies in vitamin B12. Vitamin B12, also known as cobalamin, is important to produce red blood cells and the proper functioning of the nervous system. Deficiency in vitamin B12 can cause pernicious anemia, which can manifest as peripheral neuropathy, as well as weakness, fatigue, and pallor. Therefore, vitamin B12 deficiency is a likely cause of the symptoms described in the question. Incorrect choices: Option a: Vitamin B1, also known as thiamine, is essential for the proper functioning of the nervous system, muscles, and cardiovascular system. A deficiency in vitamin B1 can cause a condition called beriberi, which can manifest as peripheral neuropathy, muscle wasting, and heart failure. However, the symptoms described in the question, such as ataxia and pallor, are not typical of beriberi. Option c: Vitamin B2, also known as riboflavin, is important to produce energy and the metabolism of fats, carbohydrates, and proteins. Deficiency in vitamin B2 can cause a condition called ariboflavinosis, which can manifest as glossitis, cheilosis, and skin rash, but not peripheral neuropathy. Option d: Vitamin B3, also known as niacin, is important for the proper functioning of the nervous system and the metabolism of fats, carbohydrates, and proteins. Deficiency in vitamin B3 can cause a condition called pellagra, which can manifest as the "3 Ds" - dermatitis, diarrhea, and dementia, but not peripheral neuropathy.

↑ *Back to this question in Part A*

@Neet_pg_bot

Q91: Cat scratch disease is caused by? (Q793845)

A. Bartonella henselae

B. Bartonella quintana

C. Bartonella bacilliformis

D. Borrelia burgdorferi

Correct Answer: A. Bartonella henselae

Explanation: Cat scratch disease (CSD) is a bacterial infection caused by the bacterium Bartonella henselae. The disease is most commonly transmitted to humans through the bite or scratch of an infected cat, although it can also be transmitted through fleas that have fed on an infected cat. Bartonella henselae is a gram-negative, rod-shaped bacterium that can survive and replicate within cells, including human cells. Once the bacteria enter the body through a cat scratch or bite, they typically spread to nearby lymph nodes, where they can cause inflammation and swelling. Incorrect Choices: b. Bartonella quintana, another species of the Bartonella genus, is the causative agent of trench fever, a common bacterial infection among soldiers during World War I. c. Bartonella bacilliformis is the causative agent of Carrion's disease, a bacterial infection transmitted by sandflies and found in parts of South America. d. Borrelia burgdorferi, conversely, is the causative agent of Lyme disease, a bacterial infection

transmitted to humans through the bite of infected ticks.

References:

.

↑ *Back to this question in Part A*

@Neet_pg_bot

Q92: A man brings his father who became unconscious while working in a field in the host sun at 42 degrees Celsius in May. One examination, there were no physical signs of dehydration. His serum electrolyte values were normal. The physician found that the body temperature was 106 F. Which of the following symptoms is least likely to be seen in this patient? (Q793895)

A. Nausea

B. Hypotension

C. Sweating

D. Headache

Correct Answer: C. Sweating

Explanation: Sweating is least likely to be seen in this patient. This is because the patient is suffering from heat stroke, which is a severe form of heat illness that occurs when the body's temperature regulation system fails. In heat stroke, the body's core temperature can rise to 104 F (40 C) or higher, which can lead to serious complications, including organ damage and death. Sweating is the body's natural mechanism to cool down in hot environments. However, in cases of severe heat stroke, the body's thermoregulatory system becomes impaired, and sweating may stop. This happens when the body's sweat glands fail to produce sweat or when the sweat evaporates too quickly due to the dry and hot environment. Incorrect choices: Option a: Nausea is a common symptom of heat stroke, as the body tries to cope with the high temperature by increasing blood flow to the skin and reducing blood flow to the digestive system. This can lead to nausea, vomiting, and diarrhea. Option b: Hypotension (low blood pressure) is also a common symptom of heat stroke, as the body tries to conserve fluid by constricting blood vessels. This can cause blood pressure to drop, which can lead to dizziness, fainting, and shock. Option d: Headache is another common symptom of heat stroke, as the brain tries to cope with the high temperature by increasing blood flow to the head. This can lead to headaches, confusion, and seizures.

↑ *Back to this question in Part A*

@Neet_pg_bot

Q93: What is the most likely diagnosis for a tall male with a lack of pubic and axillary hair, underdeveloped genitalia, elevated levels of LH and FSH, and a karyotype of XXY? (Q793914)

A. Vanishing testis syndrome

B. Klinefelter’s syndrome

C. Noonan syndrome

D. Adrenal hyperplasia

Correct Answer: B. Klinefelter’s syndrome

Explanation: The most probable diagnosis for a tall male with absent pubic and axillary hair, infantile genitalia, high LH and FSH levels, and an XXY karyotype is Klinefelter's syndrome. Klinefelter's syndrome is a genetic disorder that occurs in males who have an extra X chromosome, resulting in a karyotype of 47, XXY instead of the normal 46, XY. This condition can lead to a variety of physical, cognitive, and behavioral symptoms, including tall stature, decreased body hair, underdeveloped genitalia, infertility, and cognitive and language delays. The elevated levels of luteinizing hormone (LH) and follicle-stimulating hormone (FSH) are a result of testicular failure and impaired testosterone production. Incorrect choices: Option a: Vanishing testis syndrome is a condition in which one or both testes fail to descend into the scrotum and subsequently atrophy, resulting in reduced testosterone production. This condition can cause infertility and hormonal imbalances, but it typically presents with normal male external genitalia and normal LH and FSH levels. Option c: Noonan syndrome is a genetic disorder that affects multiple body systems and can cause a variety of symptoms, including short stature, heart defects, developmental delays, and abnormal facial features. While Noonan syndrome can affect sex hormone levels, it is not typically associated with the absence of pubic and axillary hair or infantile genitalia. Option d: Adrenal hyperplasia is a group of genetic disorders that affect the adrenal glands and can cause hormonal imbalances. Depending on the specific type of adrenal hyperplasia, symptoms can include abnormal genital development, early puberty, and elevated levels of sex hormones. However, the absence of pubic and axillary hair and infantile genitalia are not typical features of adrenal hyperplasia.

References:

.

↑ *Back to this question in Part A*

@Neet_pg_bot

Q94: A 25-year-old female with systemic lupus erythematosus presents with weight gain, moon facies, buffalo hump, and hirsutism. Which of the following is the most appropriate next investigation? (Q879210)

A. Serum ACTH and Serum cortisol levels

B. Serum ACTH and low-dose dexamethasone suppression test

C. Low-dose followed by high-dose dexamethasone suppression test

D. Serum ACTH and High-dose dexamethasone suppression test

Correct Answer: A. Serum ACTH and Serum cortisol levels

Explanation: In a patient with SLE who develops Cushingoid features (moon facies, buffalo hump, hirsutism), the most likely cause is iatrogenic Cushing's syndrome due to chronic corticosteroid therapy. In such cases, the first step is to measure serum cortisol and ACTH levels - both are suppressed in exogenous (iatrogenic) Cushing's syndrome. Dynamic tests like the dexamethasone suppression test are not indicated initially, as they are used for endogenous Cushing's evaluation.

References:

Harrison's Principles of Internal Medicine, 21st Edition, Pages 1163-1165.

↑ *Back to this question in Part A*

@Neet_pg_bot

Q95: A 10-year-old child is on long-term oral corticosteroid therapy for nephrotic syndrome. On examination, he has moon facies, truncal obesity, and a buffalo hump. There is no history of weight loss or hyperpigmentation. Most likely diagnosis is: (Q879213)

A. Addison's disease

B. Cushing's syndrome

C. Congenital adrenal hyperplasia

D. Hypothyroidism

Correct Answer: B. Cushing's syndrome

Explanation: The child's presentation of moon facies, truncal obesity, and buffalo hump is characteristic of Cushing's syndrome. Key features include: Moon facies: Rounded, full face due to fat deposits. Buffalo hump: Fat accumulation between the shoulders. Truncal obesity: Central fat distribution. This condition results from excess cortisol, often due to prolonged corticosteroid therapy, which can lead to iatrogenic Cushing's syndrome . Addison's disease (Option A) presents with weight loss, hypotension, and hyperpigmentation, not moon facies or buffalo hump. Congenital adrenal hyperplasia (Option C) manifests in infancy or early childhood with ambiguous genitalia or virilization, not truncal obesity in a 10-year-old. Hypothyroidism (Option D) causes weight gain, cold intolerance, and growth delay, but does not produce moon facies or buffalo hump.

References:

Harrison’s Principles of Internal Medicine, 22nd Edition, Page 3054, 3056-3057.

↑ *Back to this question in Part A*

@Neet_pg_bot

Q96: PTH is increased in (Q879216)

A. Immobility

B. Familial hypocalciuric hypercalcemia

C. Vitamin D toxicity

D. Thiazide diuretics

Correct Answer: B. Familial hypocalciuric hypercalcemia

Explanation: Familial hypocalciuric hypercalcemia (FHH) is caused by an inactivating mutation in the Ca-sensing receptor (CaSR), which causes the parathyroid gland to incorrectly sense the serum calcium levels as low, even when they are high, which leads to mild hypercalcemia, low urine calcium (hypocalciuria), and normal or inappropriately elevated PTH. Immobility (Option A): Immobility leads to increased bone resorption, which causes hypercalcemia. When serum calcium rises, the parathyroid gland responds by suppressing PTH. Vitamin D toxicity (Option C): It causes increased intestinal calcium absorption and bone resorption, leading to severe hypercalcemia, which in turn results in decreased PTH secretion. Thiazide diuretics (Option D): Thiazides cause hypercalcemia by increasing the renal calcium reabsorption, hence leading to decreased PTH secretion.

References:

Harrison’s Principles of Internal Medicine, 21st Edition, Pages 2492-2494. Familial Hypocalciuric Hypercalcemia - StatPearls - NCBI Bookshelf

↑ *Back to this question in Part A*

@Neet_pg_bot

Q97: A patient presents with complaints of sudden onset headache, palpitation, and profuse sweating . The patient has had multiple similar episodes in the past. During these episodes, the patient's blood pressure is elevated . A 24-hour urine metanephrine is elevated . What is the most likely diagnosis? (Q794485)

A. Addison's disease

B. Renal artery stenosis

C. Pheochromocytoma

D. Hyperthyroidism

Correct Answer: C. Pheochromocytoma

Explanation: Correct option C - Pheochromocytoma: Pheochromocytoma produces excessive amounts of catecholamines , leading to symptoms like sudden onset headache, palpitation and profuse sweating. The diagnosis is confirmed by measuring elevated levels of urinary metanephrines. A 24-hour urine metanephrine test is a diagnostic test for pheochromocytoma. Incorrect options: Option A - Addison's disease: It presents with symptoms like fatigue, weight loss, low blood pressure, and skin hyperpigmentation . While adrenal crisis can cause symptoms such as headache and sweating, it does not cause an episodic elevation of blood pressure. Option B - Renal artery stenosis : It can lead to high blood pressure but does not cause sudden onset headaches, palpitation, and profuse sweating. An elevated 24-hour urine metanephrine is not associated with renal artery stenosis. Option D - Hyperthyroidism: Hyperthyroidism symptoms include weight loss, increased appetite, tremors, heat intolerance, palpitations, and sweating . An elevated 24-hour urinary metanephrine is not associated with hyperthyroidism.

↑ *Back to this question in Part A*

@Neet_pg_bot

Q98: 70 year old man presents with low back ache and progressive pallor. On work up, KFT is deranged. LFT is normal with normal level of Albumin, but gamma globulins are disproportionately increased. X ray spine shows multiple lytic lesions. Which of the following is the cell of origin of the diagnosis of this patient? (Q820435)

A. Lymphocyte

B. Plasma cell

C. Histiocytes

D. Monocytes

Correct Answer: B. Plasma cell

Explanation: Correct Option B - Plasma cell: The clinical presentation of low back ache, progressive pallor, deranged KFT, disproportionately increased gamma globulins, and lytic lesions on X-ray spine is highly suggestive of multiple myeloma, a cancer of plasma cells. In multiple myeloma, abnormal plasma cells accumulate in the bone marrow and produce excessive amounts of a single type of immunoglobulin, leading to lytic bone lesions and other symptoms. Incorrect Options: Option A - Lymphocyte: They can give rise to lymphomas, but lymphomas typically present as lymph node enlargements and may involve other organs. Option C - Histiocytes:

Diseases involving histiocytes include Langerhans cell histiocytosis and hemophagocytic lymphohistiocytosis, but these conditions typically present with different clinical features and are not consistent with the provided symptoms and findings. Option D - Monocytes: Monocytes are another type of white blood cell involved in the immune response and can differentiate into macrophages and dendritic cells.

↑ *Back to this question in Part A*

@Neet_pg_bot

Q99: Calcitonin is a marker of which malignancy? (Q820447)

A. Papillary thyroid cancer

B. Follicular thyroid cancer

C. Medullary thyroid cancer

D. Anaplastic thyroid cancer

Correct Answer: C. Medullary thyroid cancer

Explanation: Correct Option C - Medullary thyroid cancer: Calcitonin is a hormone produced by the C-cells (also known as parafollicular cells) of the thyroid gland. Medullary thyroid cancer (MTC) is a type of thyroid cancer that arises from the parafollicular C-cells of the thyroid gland. Calcitonin is the tumour marker for medullary thyroid carcinoma Incorrect Options: Option A - Papillary thyroid cancer: Papillary thyroid cancer arises from the follicular cells of the thyroid gland, not the parafollicular C-cells. Option B - Follicular thyroid cancer: Similar to papillary thyroid cancer, follicular thyroid cancer also arises from the follicular cells of the thyroid gland and does not usually result in elevated calcitonin levels. Option D - Anaplastic thyroid cancer: Anaplastic thyroid cancer is an aggressive and rare form of thyroid cancer that is not typically associated with elevated calcitonin levels. It arises from the follicular cells of the thyroid gland, similar to papillary and follicular thyroid cancers.

References:

.

↑ *Back to this question in Part A*

@Neet_pg_bot

Q100: What should be done next in the management of a patient who is diabetic and presents with symptoms of vomiting and abdominal pain? Upon examination, the patient displays hyperventilation, sweet breath, and low blood pressure. The blood glucose level is 320 mg/dL, and urine ketones are detected. (Q793814)

A. IV insulin drip

B. IV soda-bicarbonate

C. Check blood ketone levels

D. IVF and check K+

Correct Answer: D. IVF and check K+

Explanation: Correct Option D - IVF and check K+: The patient in the given scenario presents with symptoms of diabetic ketoacidosis (DKA), a potentially life-threatening complication of diabetes. Patients with DKA are typically dehydrated due to excessive urination and vomiting, and they also lose potassium in the urine. Hypokalemia (low potassium levels) can occur due to insulin therapy, so it is important to check and monitor potassium levels closely during treatment. Incorrect Choices: Option A - IV insulin drip is a necessary treatment for DKA. Still, it should be initiated after fluid resuscitation to avoid causing a sudden drop in blood glucose levels, which can lead to cerebral edema. Option B - IV soda-bicarbonate is not recommended for the initial management of DKA as it may worsen the acidosis by causing a shift in the acid-base balance. Option C - While checking blood ketone levels is important for diagnosing DKA, it does not address the acute management of the condition.

References:

.

↑ *Back to this question in Part A*

@Neet_pg_bot

Q101: A 25-year-old P1L1 woman is planning for her second child. She has been recently diagnosed with Grave's disease. Which of the following is the antithyroid drug to be used in early gestation? (Q793948)

A. Propylthiouracil

B. Methimazole

C. Carbimazole

D. All the above

Correct Answer: A. Propylthiouracil

Explanation: Correct Option A - Propylthiouracil: Grave's disease is an autoimmune disorder that causes hyperthyroidism, which results in the overproduction of thyroid hormones by the thyroid gland. Propylthiouracil (PTU) is an antithyroid drug that works by inhibiting the production of thyroid hormones. PTU is the preferred drug for use during early pregnancy, particularly in the first trimester, as it has a lower risk of causing birth defects

compared to Methimazole. Incorrect choices: Option B - Methimazole is also an antithyroid drug that works by inhibiting the production of thyroid hormones. Methimazole is usually avoided during the first trimester of pregnancy due to its potential risk of causing birth defects. However, it can be used during the second and third trimesters of pregnancy if PTU is not well-tolerated. Option C - Carbimazole is a prodrug of Methimazole. Like Methimazole, it is avoided during the first trimester of pregnancy due to the risk of causing birth defects. Option D - Propylthiouracil can be used in early gestation, but Methimazole and Carbimazole are avoided during the first trimester of the pregnancy.

References:

Harrison's Principles of Internal Medicine, 21e

↑ *Back to this question in Part A*

@Neet_pg_bot

Q102: Patient is identified as having a tumor in the ileum leading to urinary 5 HIAA being elevated. What is the diagnosis? (Q793830)

A. Carcinoid tumor

B. Neuroblastoma

C. Leiomyoma

D. Chromaffinoma

Correct Answer: A. Carcinoid tumor

Explanation: Correct option A - Carcinoid tumors: Carcinoid tumors are a type of neuroendocrine tumor that can arise in various parts of the body, including the gastrointestinal tract (especially the ileum), lungs, and pancreas. They are usually slow-growing but can metastasize to other organs over time. One of the hallmark features of carcinoid tumors is the secretion of serotonin, which can lead to elevated levels of urinary 5-hydroxy indole acetic acid (5-HIAA). This is because serotonin is converted to 5-HIAA in the liver and then excreted in the urine. Incorrect Choices: Option B - Neuroblastoma is most commonly diagnosed in infants and young children and can cause symptoms such as abdominal swelling or pain, fever, and weight loss. Option C: Leiomyoma is a benign tumor arising from smooth muscle tissue and can occur in various parts of the body (including the uterus, gastrointestinal tract, and skin). Option D - Chromaffinoma (also known as a pheochromocytoma) is a type of tumor arising from chromaffin cells in the adrenal glands and sympathetic ganglia (part of the autonomic nervous system).

↑ *Back to this question in Part A*

@Neet_pg_bot

Q103: What is the probable diagnosis for a 50-year-old woman with a skin lesion visible in the provided image, which initially appeared small but has now spread to her entire limb and abdomen? Despite being on anticoagulation therapy, she has a longstanding history of diabetes and recurring deep vein thrombosis episodes. (Q793836)

A. Insulinoma

B. Gastrinoma

C. Glucagonoma

D. VIPoma



Correct Answer: C. Glucagonoma

Explanation: Correct Option C - Glucagonoma: Based on the information provided, the most likely diagnosis for this patient's condition is glucagonoma. A glucagonoma is a rare pancreatic neuroendocrine tumor that produces excessive amounts of glucagon. Clinical features of glucagonoma Diabetes mellitus/impaired glucose tolerance Diarrhea Dermatological features Migratory necrolytic erythema (red rash- bullae- erosions) Weight loss Incorrect Options: Option A - An insulinoma is a pancreatic neuroendocrine tumor that secretes excessive amounts of insulin. This condition can lead to hypoglycemia, which can cause symptoms such as weakness, confusion, sweating, and palpitations. Option B - A gastrinoma is a pancreatic neuroendocrine tumor that produces excessive amounts of gastrin, a hormone that stimulates the production of stomach acid. This can cause symptoms such as

abdominal pain, nausea, vomiting, and diarrhea. Option D - While VIPomas can cause skin lesions, they are not typically associated with recurrent deep vein thrombosis or long-standing diabetes, so it is an unlikely diagnosis in this case.

↑ *Back to this question in Part A*

@Neet_pg_bot

• [04_Nephrology] 021 Disorders Of Electrolyte Imbalance

« Back to Folder Directory

[04_Nephrology] 021 Disorders Of Electrolyte Imbalance — Quick Jump

Q1 (p. 1765) *Q2 (p. 1765)* *Q3 (p. 1766)* *Q4 (p. 1767)* *Q5 (p. 1767)* *Q6 (p. 1768)*
Q7 (p. 1769) *Q8 (p. 1770)* *Q9 (p. 1770)* *Q10 (p. 1771)* *Q11 (p. 1772)* *Q12 (p. 1773)*
Q13 (p. 1773) *Q14 (p. 1774)* *Q15 (p. 1775)*

Q1: A 32-year-old woman with a history of Sjögren syndrome presents with excessive thirst and passage of large volumes of urine. Labs are show below: Serum sodium: 154 mEq/L Plasma osmolality: 310 mOsm/kg Urine osmolality: 120 mOsm/kg Serum chloride: 104 mEq/L Serum potassium: 4.1 mEq/L Serum magnesium: 1.9 mg/dL (normal) Serum calcium: 9.2 mg/dL ABG: pH = 7.35, pCO 2 = 38 mm Hg, HCO 3 =24 mEq/L Which of the following is the most likely diagnosis? (Q850514)

A. Bartter syndrome

B. Gitelman syndrome

C. Distal renal tubular acidification defect/ Type 1 RTA

D. Impaired tubular response to ADH

Correct Answer: D. Impaired tubular response to ADH

Explanation: The Patient has low urine osmolality with high plasma osmolality. The inverse relation points to ADH being responsible. In the setting of Sjogren syndrome that damages renal tubules, the diagnosis goes in favour of the development of nephrogenic DI. Note that the ABG report is normal. Bartter syndrome (Option A) has hypokalemic metabolic alkalosis with normal/low sodium, while ABG is normal in this case. Gitelman syndrome (Option B) has hypokalemic metabolic alkalosis with hypomagnesemia and hypocalciuria, not hypernatremia. Distal RTA (Type I) (Option C) has normal anion gap metabolic acidosis on ABG.

References:

Harrison's Principles of Internal Medicine, 22nd Edition, Page 3018.

↑ *Back to this question in Part A*

@Neet_pg_bot

Q2: 25-year-old man presents with complaints of polyuria, polydipsia and dizziness on change of posture. He has a recent history of head trauma. Work up shows RBS: 100 mg/dl, serum sodium: 152 mEq/L, plasma osmolality: 308 mOsm/kg, Urine osmolality: 90 mOsm/kg. Serum copeptin levels are low and fail to rise with hypertonic saline stimulation. Which of the following is the most likely diagnosis? (Q850517)

A. Central diabetes insipidus

B. Nephrogenic diabetes insipidus

C. Primary polydipsia

D. Syndrome of inappropriate ADH secretion

Correct Answer: A. Central diabetes insipidus

Explanation: The inverse relationship between urine and plasma osmolality, along with elevated sodium levels, suggests diabetes insipidus. The random blood sugar is normal, and there is no evidence of glucosuria. Nephrogenic DI (Option B): Copeptin is the C-terminal part of pre-pro-vasopressin and is a precursor of ADH. Low levels and failure to improve with hypertonic saline stimulation are diagnostic of central diabetes insipidus. Nephrogenic DI has high copeptin levels Primary polydipsia (Option C) also has low copeptin levels, but they rise with hypertonic saline stimulation Syndrome of inappropriate ADH secretion (Option D) has low sodium with high urine osmolality

References:

Harrison's Principles of Internal Medicine, 22nd Edition, Page 3018.

↑ *Back to this question in Part A*

@Neet_pg_bot

Q3: Which of the following scenario will not lead to nephrogenic diabetes insipidus? (Q850518)

A. Patient of bipolar disorder on lithium

B. HIV patient with cerebral toxoplasmosis

C. Laxative abuse

D. Sickle cell anaemia

Correct Answer: B. HIV patient with cerebral toxoplasmosis

Explanation: CNS infections lead to loss of regulation over ADH release, leading to SIADH. Lithium (Option A) enters collecting duct principal cells via ENaC and interferes with ADH signalling downstream of the V2 receptor (affecting aquaporin-2 channel insertion). Laxative abuse (Option C) will cause long-standing hypokalaemia that blunts the responsiveness of V2 receptors to ADH, besides causing damage to renal collecting duct principal cells. Sickle cell anemia (Option D) causes recurrent vaso-occlusive crisis and resultant ischemia causes papillary necrosis and tubulointerstitial damage . This reduces medullary concentrating ability and decreases responsiveness to ADH

References:

Harrison's Principles of Internal Medicine, 22nd Edition, Pages 343, 348, 349.

https://pmc.ncbi.nlm.nih.gov/articles/PMC11750692/table/T2/

↑ *Back to this question in Part A*

@Neet_pg_bot

Q4: Which of the following causes will lead to nephrogenic diabetes insipidus? a. Hypercalcemia b. Toxoplasmosis c. Laxative abuse d. Sickle cell anaemia (Q850519)

A. a,b

B. a,b,c

C. b,c,d

D. a,c,d

Correct Answer: D. a,c,d

Explanation: CNS infections lead to loss of regulation over ADH release, leading to SIADH. High calcium levels reduce the expression and trafficking of aquaporin-2 water channels in the collecting duct (principal cells). This makes the collecting duct resistant to ADH. Laxative abuse will cause long-standing hypokalaemia that blunts the responsiveness of V2 receptors to ADH, besides causing damage to renal collecting duct principal cells. Sickle cell anemia causes recurrent vaso-occlusive crisis and ischemia, causing papillary necrosis and tubulointerstitial damage . This reduces medullary concentrating ability and decreases responsiveness to ADH.

References:

harrison's principles of internal medicine, 22nd Edition, Page 3017.

↑ *Back to this question in Part A*

@Neet_pg_bot

Q5: 58-year-old male smoker, recently diagnosed with small-cell lung carcinoma, presents with cough and shortness of breath. On examination, he is alert and oriented (GCS 15/15), vitals are stable, and he appears euvolemic. Laboratory tests show: Serum sodium: 120 mEq/L Serum osmolality: 255 mOsm/kg Urine osmolality: 650 mOsm/kg Which of the following is the most appropriate initial management for this patient? (Q850521)

A. 3% hypertonic saline bolus

B. 3% hypertonic saline infusion

C. Oral salt tablets with loop diuretics

D. Tolvaptan

Correct Answer: C. Oral salt tablets with loop diuretics

Explanation: This patient has small-cell lung carcinoma , a classic cause of SIADH . His lab profile supports this: Serum Na■: 120 mEq/L → marked hyponatremia Low serum osmolality High urine osmolality → inappropriate urine concentration Clinically euvolemic Because he is asymptomatic (normal GCS, no seizures, no confusion), the initial management of SIADH is conservative : Fluid restriction Oral salt tablets Loop diuretics (increase free-water excretion) This combination safely raises sodium without rapid correction. Hypertonic saline (Options A &B): Indicated only for symptomatic or severe neurologic manifestations , such as seizures, confusion, altered sensorium, or GCS decline. Tolvaptan (Option D) A vasopressin receptor antagonist reserved for chronic or refractory SIADH

References:

Harrison's Principles of Internal Medicine, 22nd Edition, Page 3017.

↑ *Back to this question in Part A*

@Neet_pg_bot

Q6: 22-year-old female presents with recurrent episodes of muscle cramps, weakness, and fatigue. Blood pressure is 110/70 mmHg. ECG shows a QT interval of 500 msec. Labs show serum potassium: 2.8 mEq/L, serum magnesium: 1.1 mg/dL, serum calcium: normal, 24 hour urinary calcium: low, plasma renin activity: high, aldosterone: high. Diagnosis is? (Q850561)

A. Barter syndrome

B. Gitelman syndrome

C. Liddle syndrome

D. Gordon syndrome

Correct Answer: B. Gitelman syndrome

Explanation: The presence of low serum magnesium, hypokalemic alkalosis (resulting from increased aldosterone), and hypocalciuria indicates a distal tubular defect characteristic of Gitelman syndrome. It has a loss of function of the Na■-Cl■ cotransporter in the distal convoluted tubule, leading to chronic renal salt wasting. This explains the increased aldosterone and increased renin. Loss of TRPM6 activity leads to magnesium wasting. Bartter syndrome (Option A) is ruled out as it has hypokalemic metabolic alkalosis and increased 24-hour urinary calcium. Liddle syndrome (Option C) has Hypertension with hypokalemic metabolic alkalosis with low renin and aldosterone Gordon syndrome (Option D) has hypertension with hyperkalemic metabolic acidosis.

References:

Harrison's Principles of Internal Medicine, 22nd Edition, Page 355, 2362.

↑ *Back to this question in Part A*

@Neet_pg_bot

Q7: 10-year-old boy presents with growth retardation and recurrent episodes of muscle weakness. BP is 100/60 mmHg. Labs reveal: serum potassium: 2.6 mEq/L, serum magnesium: normal, serum calcium: normal, 24-hour urinary calcium: high, plasma renin activity: high, aldosterone: high. What is the most likely diagnosis? (Q850565)

A. Bartter syndrome

B. Gitelman syndrome

C. Liddle syndrome

D. Gordon syndrome

Correct Answer: A. Bartter syndrome

Explanation: Bartter syndrome presents with hypokalemic metabolic alkalosis + hypercalciuria, normal BP, ↑renin, ↑ and aldosterone. Salt wasting is the reason for increased renin and aldosterone. BP is normal as salt gain and salt loss are counterbalancing each other. In Bartter syndrome, the TAL defect abolishes the lumen-positive potential and decreases the paracellular reabsorption of Ca^{2}■, causing hypercalciuria . Serum calcium remains normal due to a compensatory increase in intestinal absorption and bone resorption. Gitelman (Option B) has similar features but has hypomagnesemia + hypocalciuria . Liddle syndrome (Option C) has hypertension with hypokalemic alkalosis Gordon syndrome (Option D) has hypertension with hyperkalemic metabolic acidosis.

References:

Harrison's Principles of Internal Medicine, 22nd Edition, Page 355, 2368.

↑ *Back to this question in Part A*

@Neet_pg_bot

Q8: 25-year-old HIV-positive male presents with a GTCS episode and headache. MRI brain shows calcification in basal ganglia. On admission, serum sodium is 120 mEq/L, serum osmolality is 260 mOsm/kg, urine osmolality is 620 mOsm/kg, and urine sodium is 48 mEq/L. There is no edema, normal JVP and normal BP with no significant change on positional variation. Diagnosis? (Q850569)

A. Cerebral salt wasting

B. SIADH

C. Adrenal insufficiency

D. Psychogenic polydipsia

Correct Answer: B. SIADH

Explanation: Low serum osmolality + high urine osmolality + hyponatremia in the setting of CNS infection (suspected cerebral toxoplasmosis) is seen in SIADH. CSF PCR for Toxoplasma or IgG/IgM antibody will be required for confirmation. Cerebral salt wasting (Option A) will have hypovolemia (↓BP, ↓JVP, dehydration). Adrenal insufficiency (Option C) also causes hyponatremia but with hypotension, hyperkalemia and hypoglycaemia. Psychogenic polydipsia (Option D) leads to very low urine osmolality (<100 mOsm/kg) due to excess water intake, while it is high in the case scenario.

References:

Harrison's Principles of Internal Medicine, 22nd Edition, Page 350 738.

↑ *Back to this question in Part A*

@Neet_pg_bot

Q9: A patient is found to have hypotonic euvolemic hyponatremia with inappropriately concentrated urine. Which of the following respiratory conditions is least likely to cause this disorder? (Q890249)

A. Small cell carcinoma of the lung

B. Asthma

C. Respiratory failure requiring positive-pressure ventilation

D. Primary pulmonary emphysema

Correct Answer: D. Primary pulmonary emphysema

Explanation: This patient has SIADH , characterised by euvolemic hyponatremia with inappropriately concentrated urine. Pulmonary causes of SIADH produce non-osmotic ADH release via hypoxia, lung stretch receptor stimulation, and ectopic secretion . Small cell carcinoma of lung (Option A): Ectopic ADH secretion - the most common malignancy causing SIADH Asthma (Option B): Hypoxia and lung stretch → non-osmotic ADH release Positive-pressure ventilation (Option C): Lung stretch receptor activation → ADH release SIADH is also seen with: Mesothelioma Bacterial and viral pneumonias Pulmonary abscess Tuberculosis Aspergillosis Cystic fibrosis. Primary pulmonary emphysema is not a recognised cause of SIADH because it does not produce ectopic ADH nor reliably stimulate sustained non-osmotic ADH release.

References:

Harrison's Principles of Internal Medicine, 22nd Edition, Page 349.

↑ *Back to this question in Part A*

@Neet_pg_bot

Q10: A 45-year-old man presents with headache, nausea and confusion 5 days after starting a new medication. He is clinically euvolemic. His investigations reveal: Serum sodium - 116 mEq/L Plasma osmolality - Low Urine osmolality - Inappropriately high Which of the following drugs is least likely to be responsible for this condition? (Q890250)

A. Carbamazepine

B. Demeclocycline

C. Desmopressin

D. Selective serotonin reuptake inhibitors (SSRIs)

Correct Answer: B. Demeclocycline

Explanation: This patient has euvolemic hypotonic hyponatremia with inappropriately concentrated urine, establishing the diagnosis of SIADH due to excess or enhanced action of ADH. Demeclocycline does not cause SIADH. It antagonises V■-receptor-mediated ADH action in the collecting ducts, producing nephrogenic diabetes

insipidus and is therefore used therapeutically in chronic SIADH. Carbamazepine, SSRIs and desmopressin are among the most common pharmacologic causes of SIADH. Mechanism Drugs causing SIADH Stimulate ADH release (central action) Carbamazepine (Option A) , SSRIs (Option D) , Tricyclic antidepressants, Antipsychotics, Nicotine, Narcotics, MDMA (Ecstasy) Enhance renal ADH action Chlorpropamide, Carbamazepine, Clofibrate Cause tubular ADH-like effect / ectopic stimulation Vincristine, Ifosfamide, Cyclophosphamide ADH analogues (direct ADH effect) Desmopressin (Option C) , Vasopressin, Oxytocin

References:

Harrison's Principles of Internal Medicine, 22nd Edition, Page 349.

↑ *Back to this question in Part A*

@Neet_pg_bot

Q11: A 60-year-old man presents with progressive headache, nausea, lethargy and confusion. Examination shows no signs of dehydration or oedema. Investigations reveal: Serum sodium: 122 mEq/L Plasma osmolality: Low Urine osmolality: Inappropriately high Urine sodium: >40 mmol/L Which of the following tumours is least likely to be associated with this condition? (Q890251)

A. Small cell carcinoma of the lung

B. Thymoma

C. Ewing's sarcoma

D. Chromophobe pituitary adenoma

Correct Answer: D. Chromophobe pituitary adenoma

Explanation: This patient has euvolemic hypotonic hyponatremia with inappropriately concentrated urine, which is diagnostic of SIADH . SIADH is most commonly caused by ectopic ADH secretion from malignancies, especially neuroendocrine and pulmonary tumours. Chromophobe pituitary adenoma is a non-functioning pituitary adenoma that causes hypopituitarism by mass effect but does not ectopically secrete ADH and therefore does not cause SIADH. Malignant diseases commonly causing SIADH: Pulmonary / Neuroendocrine tumours Small cell carcinoma lung (Option A) Bronchial carcinoid Mesothelioma Thymoma (Option B) Sarcomas & lymphoid tumours Ewing's sarcoma (Option C) Lymphomas GI and GU malignancies Oropharyngeal carcinoma Gastric carcinoma Duodenal carcinoma Pancreatic carcinoma Ureteric, bladder, prostate and endometrial carcinomas These tumours either produce ADH ectopically or stimulate its secretion, leading to persistent water retention and dilutional hyponatremia.

References:

Harrison's Principles of Internal Medicine, 22nd Edition, Page 349.

↑ *Back to this question in Part A*

@Neet_pg_bot

Q12: A 38-year-old man is admitted following a subarachnoid haemorrhage. On day 4 of hospitalisation, he develops dizziness and postural hypotension. He is passing large volumes of urine. Laboratory evaluation shows: Serum sodium: 118 mEq/L Urine sodium: 140 mmol/L Urine output: High Central venous pressure: Low Which of the following is the most likely diagnosis? (Q890252)

A. Syndrome of inappropriate ADH secretion

B. Cerebral salt wasting

C. Central diabetes insipidus

D. Primary polydipsia

Correct Answer: B. Cerebral salt wasting

Explanation: This patient has hyponatremia with polyuria and true volume depletion following a CNS insult, which is diagnostic of cerebral salt wasting (CSW). CSW results from increased secretion of natriuretic peptides (BNP > ANP) from injured brain tissue, leading to: Renal sodium wasting High urine sodium excretion Polyuria Hypovolemia Secondary hyponatremia It is classically seen after: Subarachnoid hemorrhage Brain tumors Head trauma Hydrocephalus Neurosurgery Cerebrovascular accidents Brain death Treatment: Restoration of intravascular volume with Isotonic or hypertonic saline with volume repletion ± fludrocortisone. Clinical parameter SIADH (Option A) Cerebral salt wasting Central DI (Option C) Serum sodium Low Low High Urine output Normal/ Low High High Urine sodium High Very High Low Intravascular volume status Normal/ High Low Low Vasopressin level High Low Low Primary polydipsia (Option D): Produces hyponatremia, but urine sodium is low, and volume status is normal.

References:

Harrison’s Principles of Internal Medicine, 22nd Edition, Page 348.

↑ *Back to this question in Part A*

@Neet_pg_bot

Q13: A 58-year-old man is brought to the emergency department with a sudden onset of confusion, repeated vomiting and headache. Examination shows no signs of dehydration or oedema. His laboratory investigations reveal: Serum sodium - 114

mEq/L Plasma osmolality - Low Urine osmolality - Inappropriately high Urine sodium - 52 mmol/L Which of the following is the most appropriate initial management? (Q890253)

A. Infusion of hypertonic (3%) saline

B. Infusion of hypotonic (0.45%) saline

C. Infusion of normal (0.9%) saline

D. Administration of DDAVP

Correct Answer: A. Infusion of hypertonic (3%) saline

Explanation: This patient has acute symptomatic euvolemic hypotonic hyponatremia with inappropriately concentrated urine, which is diagnostic of acute SIADH . The presence of confusion and vomiting indicates cerebral oedema, making this a medical emergency. Hypertonic saline (3%) is the treatment of choice because: Rapidly raises serum sodium Reduces cerebral oedema Prevents seizures, herniation and death Is the recommended emergency therapy for acute symptomatic SIADH Hypotonic saline (Option B): It adds free water, which further lowers serum sodium and thereby worsens the cerebral oedema. Normal saline (Option C): In SIADH, sodium is excreted while water is retained, so normal saline acts as a hypotonic fluid, aggravating hyponatremia. DDAVP (Option D): It is an ADH analogue that increases water retention and, hence, can dangerously worsen SIADH.

References:

Harrison’s Principles of Internal Medicine, 22nd Edition, Pages 350-351.

↑ *Back to this question in Part A*

@Neet_pg_bot

Q14: A 62-year-old man with small-cell carcinoma of the lung has persistent asymptomatic hyponatremia (Na■ 124-128 mEq/L) for 3 weeks. He is clinically euvolemic and has been poorly compliant with fluid restriction. Which of the following is the drug of choice for long-term management? (Q890254)

A. Furosemide

B. Tolvaptan

C. Demeclocycline

D. Fludrocortisone

Correct Answer: B. Tolvaptan

Explanation: This patient has chronic SIADH, and the preferred long-term pharmacologic therapy is Tolvaptan , a selective V■-receptor antagonist (vaptan) . Mechanism : Vaptans block the antidiuretic action of AVP at the collecting ducts, producing aquaresis (free water excretion without sodium loss), which corrects dilutional hyponatremia. Although fluid restriction is the traditional mainstay, it is unreliable, impractical, slow to act and frequently fails due to intense thirst seen in SIADH. Furosemide (Option A): Produces natriuresis and water loss but does not block ADH-mediated water retention; therefore, it cannot correct the primary pathophysiology of SIADH and is only used as an adjunct. Demeclocycline (Option C): Induces nephrogenic diabetes insipidus and can improve hyponatremia, but has a delayed onset and significant nephrotoxicity, making it inferior to vaptans for chronic SIADH. Fludrocortisone (Option D): It is used in cerebral salt wasting to correct volume depletion and sodium loss, but does not treat SIADH, which is a euvolemic dilutional hyponatremia.

References:

Harrison’s Principles of Internal Medicine, 22nd Edition, Pages 350-351.

↑ *Back to this question in Part A*

@Neet_pg_bot

Q15: A 56-year-old man with a history of chronic alcoholism is admitted with altered sensorium. His serum sodium is 110 mEq/L. He is treated in a local hospital and discharged after 3 days. Two days later, he presents again with progressive quadriparesis, slurred speech, difficulty in swallowing, and preserved consciousness. His Brain MRI shows a symmetric lesion in the central pons. What is the most likely diagnosis? (Q890255)

A. Wernicke encephalopathy

B. Central pontine myelinolysis

C. Acute disseminated encephalomyelitis

D. Brainstem infarction

Correct Answer: B. Central pontine myelinolysis

Explanation: This patient developed osmotic demyelination syndrome (ODS) , classically central pontine myelinolysis (CPM) . In chronic hyponatremia, brain cells adapt by losing intracellular osmolytes. Rapid correction of sodium causes sudden water efflux from neurons, causing cellular dehydration leads to oligodendrocyte injury with demyelination, predominantly in the pons. Classic clinical triad of CPM: Acute quadriparesis Dysarthria Dysphagia (+ altered sensorium, locked-in syndrome in severe cases) MRI: Symmetric pontine hyperintensity, the trident sign. Hence, hyponatremia should be corrected at a rate not exceeding 10 mmol/L/24 h or 0.5 mEq/L/h; or 18 mEq/L/48hrs; thus potentially avoiding demyelination in chronic

hyponatremia. Wernicke encephalopathy (Option A): It presents with confusion, ophthalmoplegia and ataxia, not quadriparesis with pontine lesion. ADEM (Option C): Acute disseminated encephalomyelitis occurs post-viral/vaccination; MRI shows multifocal white-matter lesions , not isolated pontine demyelination. Brainstem infarction (Option D): Brainstem stroke syndromes, also known as crossed brainstem syndromes, refer to a group of syndromes that occur secondary to lesions, most commonly infarcts, of the brainstem. It produces sudden focal deficits, not delayed deterioration after electrolyte correction.

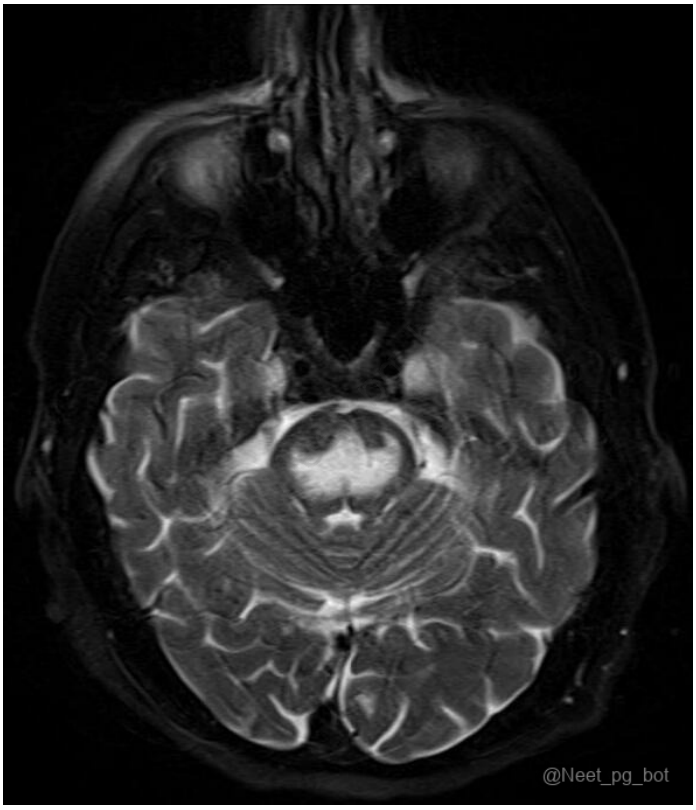

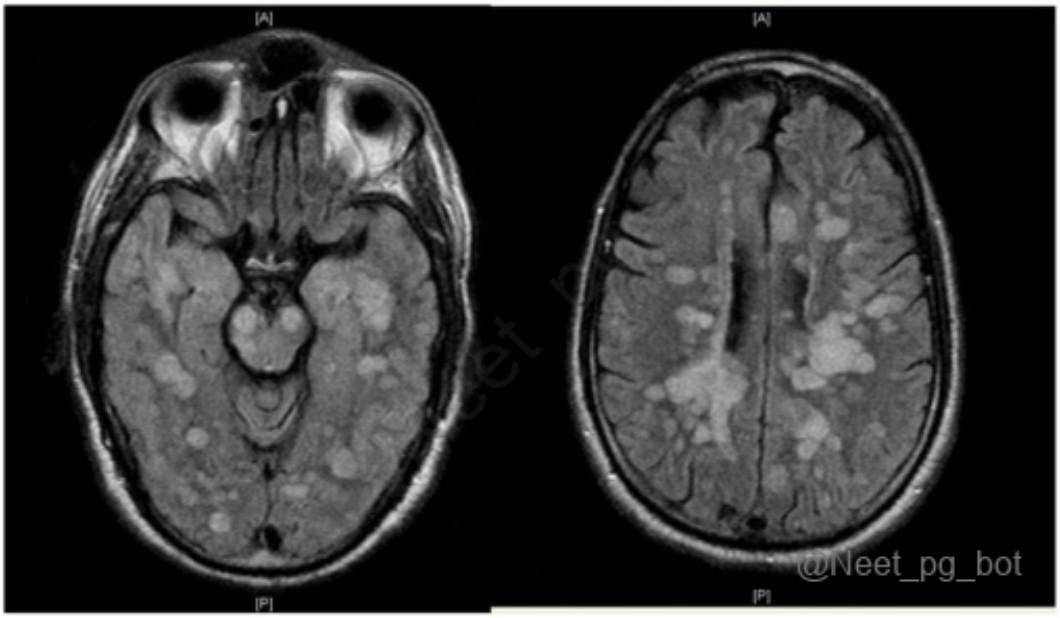

References:

Harrison’s Principles of Internal Medicine, 22nd Edition, Page 350.

↑ *Back to this question in Part A*

@Neet_pg_bot

• [04_Nephrology] 022 Electrolyte Imbalance

« Back to Folder Directory

[04_Nephrology] 022 Electrolyte Imbalance — Quick Jump

Q1 (p. 1778)	*Q2 (p. 1778)*	*Q3 (p. 1779)*	*Q4 (p. 1780)*	*Q5 (p. 1780)*	*Q6 (p. 1781)*
Q7 (p. 1782)	*Q8 (p. 1782)*	*Q9 (p. 1783)*	*Q10 (p. 1783)*	*Q11 (p. 1784)*	*Q12 (p. 1785)*
Q13 (p. 1786)	*Q14 (p. 1787)*	*Q15 (p. 1788)*	*Q16 (p. 1788)*	*Q17 (p. 1789)*	*Q18 (p. 1790)*
Q19 (p. 1790)	*Q20 (p. 1791)*	*Q21 (p. 1791)*	*Q22 (p. 1792)*	*Q23 (p. 1792)*	*Q24 (p. 1793)*
Q25 (p. 1794)	*Q26 (p. 1794)*	*Q27 (p. 1795)*	*Q28 (p. 1795)*	*Q29 (p. 1796)*	*Q30 (p. 1797)*

Q1: Which of the following conditions is least likely to be associated with hyperphosphatemia? (Q850713)

A. Hypoparathyroidism

B. Pseudohypoparathyroidism

C. Pseudo-pseudo-hypoparathyroidism

D. Chronic kidney disease

Correct Answer: C. Pseudo-pseudo-hypoparathyroidism

Explanation: Hyperphosphatemia occurs when PTH action is absent or impaired or when the kidneys cannot excrete phosphate effectively . Pseudo-pseudohypoparathyroidism differs because patients have only the physical features of Albright hereditary osteodystrophy without hormone resistance. PTH action is normal → phosphate levels remain normal Hypoparathyroidism (Option A) Low PTH → decreased renal phosphate excretion → high phosphate . Pseudohypoparathyroidism (Option B) idney resistance to PTH → same effect as hypoparathyroidism → high phosphate . In CKD (Option D) Reduced GFR → impaired phosphate excretion → high phosphate .

References:

Harrison's Principles of Internal Medicine, 22nd Edition, Page 3288.

↑ *Back to this question in Part A*

@Neet_pg_bot

Q2: Which of the following causes non anion gap acidosis? (Q850747)

A. Diarrhea

B. Ethylene glycol poisoning

C. Starvation

D. Glue sniffing

Correct Answer: A. Diarrhea

■ *Listen (English)*

■ *Listen (Hindi)*

Explanation: Anion gap = Na■ – (Cl■ + HCO■■) Diarrhoea causes loss of bicarbonate-rich intestinal secretions. Now, to maintain electroneutrality, the kidney will reabsorb chloride, causing the anion gap value to remain the same. Ethylene glycol (Option B) causes acute tubular necrosis leading to high anion gap metabolic acidosis. Starvation (Option C) leads to ketoacidosis and causes HAGMA. Glue sniffing (Option D): Toluene is metabolised in the liver to benzoic acid, which in turn is conjugated with glycine to hippuric acid. Large amounts of hippuric acid overwhelm renal excretion, causing high anion gap metabolic acidosis. Toluene directly causes Distal RTA. Hence, it causes combination of -HAGMA and NAGMA.

References:

Harrison's Principles of Internal Medicine, 22nd Edition, Page 354.

↑ *Back to this question in Part A*

@Neet_pg_bot

Q3: First line management of life-threatening hypercalcemia? (Q850744)

A. Normal saline

B. Lasix infusion

C. Hemodialysis

D. Zolendronate

Correct Answer: A. Normal saline

■ *Listen (English)*

■ *Listen (Hindi)*

Explanation: The first step in the management of life-threatening hypercalcemia is IV fluids. Severe hypercalcemia causes profound dehydration due to nephrogenic diabetes insipidus.Patients become volume-depleted , reducing renal calcium excretion. IV saline restores intravascular volume → increases GFR → enhances urinary calcium excretion .

References:

Harrison's Principles of Internal Medicine, 22nd Edition, Page 364.

↑ *Back to this question in Part A*

@Neet_pg_bot

Q4: Hypomagenesemia is seen in all except? (Q850743)

A. Renal failure

B. Alcoholism

C. Gitelman syndrome

D. Amphotericin B

Correct Answer: A. Renal failure

■ *Listen (English)*

■ *Listen (Hindi)*

Explanation: Renal failure, formerly called end-stage renal disease, will cause magnesium retention due to impaired filtration. Causes of Hypomagnesemia: Inadequate Intake Starvation Malnutrition Alcoholism (Option B) Parenteral alimentation Gastrointestinal Losses Prolonged vomiting/nasogastric aspiration Chronic diarrhoea/laxative abuse Malabsorption Small bowel bypass surgery Fistulae Urinary Losses Diuretic therapy Alcohol Tubulotoxic drugs (Gentamicin , Cisplatin, Amphotericin B) (Option D) Volume expansion Diabetic ketoacidosis Post-obstructive diuresis Recovery from acute tubular necrosis Inherited Tubular Defects Bartter's syndrome Gitelman's syndrome (Option C) Primary renal magnesium wasting Miscellaneous Acute pancreatitis Foscarnet therapy Proton pump inhibitor therapy Hungry bone syndrome Diabetes mellitus

References:

Harrison's Principles of Internal Medicine, 22nd Edition, Page 3266.

↑ *Back to this question in Part A*

@Neet_pg_bot

Q5: A 25 year old lady with eclampsia was given magnesium sulfate by the Pritchard regimen. She developed areflexia of bilateral ankle jerks and knee jerks with a respiratory rate of 8/min. Which of the following will be used? (Q850742)

A. Calcium gluconate

B. Calcium carbonate

C. Sevelamer

D. Lanthanum carbonate

Correct Answer: A. Calcium gluconate

Explanation: The patient has magnesium sulfate toxicity , evidenced by: Loss of deep tendon reflexes (earliest and most reliable sign) Respiratory depression (RR 8/min → dangerously low) The immediate antidote in severe Mg toxicity is 10 mL of 10% Calcium Gluconate IV given slowly Calcium antagonizes the neuromuscular and cardiac depressive effects of magnesium and rapidly reverses symptoms.

References:

Harrison's Principles of Internal Medicine, 22nd Edition, Page 3268.

↑ *Back to this question in Part A*

@Neet_pg_bot

Q6: A 5 year old child with jaw swelling is diagnosed with Burkitt lymphoma based on histopathology reports. You have started chemotherapy. Which of the following electrolyte imbalance will not be seen in this case? (Q850740)

A. Hyperphosphatemia

B. Hyperkalemia

C. Hypocalcemia

D. Hypernatremia

Correct Answer: D. Hypernatremia

■ *Listen (English)*

■ *Listen (Hindi)*

Explanation: Burkitt lymphoma has a high cell turnover rate. The institution of chemotherapy will cause destruction of cancer cells causing hyperkalemia, hyperuricemia and increased phosphate. The elevated phosphate chelates with calcium causing hypocalcemia. Sodium is not affected in tumor lysis syndrome.

References:

Harrison's Principles of Internal Medicine, 22nd Edition, Page 593, 594.

↑ *Back to this question in Part A*

@Neet_pg_bot

Q7: Euvolemic hyponatremia is seen with? (Q850738)

A. Secondary Addison disease

B. Primary Addison disease

C. Cushing syndrome

D. Congestive heart failure

Correct Answer: A. Secondary Addison disease

Explanation: Secondary adrenal insufficiency is caused by low ACTH , leading to low cortisol , but aldosterone remains normal because it is controlled by the RAAS system, not ACTH. Normal aldosterone → no sodium loss and no hypovolemia , but low cortisol increases ADH → euvolemic hyponatremia . Primary Addison disease (Option B): Incorrect because both cortisol and aldosterone are decreased , leading to salt loss, hypovolemia, and hypovolemic hyponatremia , not euvolemic. Cushing syndrome (Option C): Incorrect because excess cortisol causes sodium retention → normal or high sodium , not hyponatremia. Congestive heart failure (Option D): Incorrect because CHF causes hypervolemic hyponatremia , not euvolemic.

References:

Harrison's Principles of Internal Medicine, 22nd Edition, Page 348.

↑ *Back to this question in Part A*

@Neet_pg_bot

Q8: Tolvaptan can be used in management of all except? (Q850737)

A. Hypervolemic hyponatremia

B. Hypovolemic hyponatremia

C. Euvolemic hyponatremia

D. SIADH

Correct Answer: B. Hypovolemic hyponatremia

Explanation: Tolvaptan is used in CHF (hypervolemic hyponatremia) and acts by blocking V2 receptors. It acts by: Promoting aquaresis (excretion of free water without significant sodium loss) Reducing congestion without worsening renal function or electrolytes (compared to loop diuretics) SIADH and euvolemic hyponatremia are basically surrogate terms and are managed with tolvaptan.

References:

Harrison's Principles of Internal Medicine, 22nd Edition, Page 351.

↑ *Back to this question in Part A*

@Neet_pg_bot

Q9: A 62-year-old man is brought to the emergency department with sudden onset confusion, vomiting, and a generalized tonic-clonic seizure. He has a history of small cell lung carcinoma and was recently started on chemotherapy. On examination, he is drowsy and disoriented. Laboratory investigations reveal a serum sodium level of 112 mEq/L.What is the most appropriate immediate management for this patient? (Q850734)

A. Bolus of 3% saline

B. Slow correction with 3% saline over 24 hours

C. Slow correction with 3% saline over 46 hours

D. Water restriction with oral salt capsules

Correct Answer: A. Bolus of 3% saline

Explanation: This patient has acute symptomatic hyponatremia (seizure, confusion, Na■ = 112 mEq/L), which is a medical emergency. Severe symptoms (seizures, coma, severe confusion) → rapid partial correction is needed Treatment = hypertonic saline (3%) given as bolus Typically 100 mL IV bolus , can repeat up to 2–3 times Slow correction is used in chronic hyponatremia. For acute hyponatremia bolus of hypertonic saline is given. A few-point increment of sodium will cause sodium to rise beyond the threshold of 125 mEq/L and control the seizures.

References:

Harrison's Principles of Internal Medicine, 22nd Edition, Page 351.

↑ *Back to this question in Part A*

@Neet_pg_bot

Q10: While drawing blood for estimation of ionized calcium, all of the following pre-analytical factors can alter the test result except? (Q850732)

A. Prolonged tourniquet application

B. Isometric hand exercise during sampling

C. Exposure of sample to air before analysis

D. Haemolysis of sample

Correct Answer: D. Haemolysis of sample

Explanation: Tourniquet application causes hemoconcentration and leads to increased total calcium. Isometric hand exercise will cause lactate production, causing a fall in pH and increased ionised calcium. Air exposure causes CO■ loss, leading to increased pH and ↓ ionised calcium. Hemolysis, however, does not significantly alter calcium measurement.

References:

Harrison's Principles of Internal Medicine, 22nd Edition, Page 364.

↑ *Back to this question in Part A*

@Neet_pg_bot

Q11: Which of the following causes a steroid-responsive hypercalcemia? (Q850730)

A. Vitamin D intoxication

B. Multiple myeloma

C. Lung cancer

D. Parathyroid carcinoma

Correct Answer: A. Vitamin D intoxication

Explanation: Glucocorticoids reduce intestinal calcium absorption and inhibit 1-α hydroxylase , thereby lowering levels of active vitamin D (1,25-OH■-D). Thus, hypercalcemia caused by vitamin D excess either due to overdose or granulomatous diseases (sarcoidosis, lymphoma) is steroid responsive . Multiple Myeloma (Option B): Causes hypercalcemia due to osteolytic bone destruction by malignant plasma cells. Steroids are used in treatment regimens but do not acutely correct the hypercalcemia ; hydration and bisphosphonates are the primary therapy. Lung Cancer (Option C): Often causes hypercalcemia via PTH-related peptide (PTHrP) secretion. This mechanism does not respond to steroids ; treatment involves hydration and bisphosphonates . Parathyroid Carcinoma (Option D): Causes hypercalcemia due to markedly elevated PTH levels . Steroids do not reduce calcium in PTH-mediated

hypercalcemia .

References:

Harrison's Principles of Internal Medicine, 22nd Edition, Page 3281.

↑ *Back to this question in Part A*

@Neet_pg_bot

Q12: Which of the following is correct about Chvostek sign? (Q850724)

A. Twitching of the ipsilateral perioral levator and zygomaticus muscles

B. Twitching of the ipsilateral corrugator cili and zygomaticus muscles

C. Twitching of the contralateral perioral levator and zygomaticus muscles

D. Twitching of the contralateral corrugator cili and zygomaticus muscles

Correct Answer: A. Twitching of the ipsilateral perioral levator and zygomaticus muscles

Explanation: Chvostek sign is seen in hypocalcemia, indicating neuromuscular irritability. Elicited by tapping over the facial nerve (just anterior to the ear). Positive if there is twitching of the ipsilateral perioral muscles (levator anguli oris, zygomaticus).



References:

Harrison's Principles of Internal Medicine, 22nd Edition, Page 365.

↑ *Back to this question in Part A*

@Neet_pg_bot

Q13: Post thyroid surgery patient has developed muscle cramps followed by breathing difficulty due to bronchospasm. ECG shows QTc prolongation. Which of the following would be used for management? (Q850721)

A. KCL infusion 40meq/L

B. KCL infusion 40 meq/L with salbutamol nebulization

C. 10 ml of 10% calcium gluconate diluted in 50 ml of 5% dextrose over 10 min

D. 10 ml of 10% calcium gluconate over 1 min

Correct Answer: C. 10 ml of 10% calcium gluconate diluted in 50 ml of 5% dextrose over 10 min

Explanation: The case is classic acute hypocalcemia after thyroid surgery (due to inadvertent parathyroid damage/removal). Features: muscle cramps, bronchospasm, QT prolongation → hallmark of low calcium. Treatment of choice = IV 10 mL of 10% calcium gluconate diluted in 50 mL of 5% dextrose or 0.9% sodium chloride given intravenously over 5–10 min with telemetry There is no role for KCl or salbutamol here (those are for hyperkalemia) KCL infusion 40 meq/L (Option A): This treats hypokalemia, not hypocalcemia. Giving potassium when calcium is low can worsen muscle excitability and arrhythmias. KCL infusion 40 meq/L + salbutamol nebulization (Option B): Again treats hyperkalemia, not hypocalcemia. Salbutamol can further decrease potassium, worsening risk of arrhythmias. 10 ml of 10% calcium gluconate over 1 min (Option D): Dangerously rapid infusion; risk of severe arrhythmias, cardiac arrest, and tissue necrosis . Calcium must be infused slowly and diluted.

References:

Harrison's Principles of Internal Medicine, 22nd Edition, Page 366.

↑ *Back to this question in Part A*

@Neet_pg_bot

Q14: Which of the following conditions classically presents with elevated serum calcium, normal phosphate, and normal serum alkaline phosphatase (SAP)? (Q850718)

A. Osteoporosis

B. Paget disease

C. Multiple myeloma

D. Primary Hyperparathyroidism

Correct Answer: C. Multiple myeloma

Explanation: Multiple myeloma causes osteolytic bone destruction , leading to elevated serum calcium . However, because there is no increase in osteoblastic activity , the serum alkaline phosphatase (SAP) remains normal . Phosphate levels also remain normal , since phosphate handling is not significantly altered. Osteoporosis (Option A) Calcium, phosphate, and SAP remain normal because bone loss occurs without metabolic derangement, and osteoporosis never causes hypercalcemia . Paget disease (Option B) Calcium and phosphate are normal, but SAP is markedly elevated due to high bone turnover , so the normal SAP pattern rules this out. Primary Hyperparathyroidism (Option D) Shows high calcium and low phosphate from PTH-mediated phosphate wasting ; this does not match the normal-phosphate pattern.

References:

Harrison's Principles of Internal Medicine, 22nd Edition, Page 364.

↑ *Back to this question in Part A*

@Neet_pg_bot

Q15: Which of the following is the leading cause of hypoparathyroidism? (Q850716)

A. Autoimmunity

B. Hemochromatosis

C. Wilson disease

D. Riedel Struma

Correct Answer: A. Autoimmunity

Explanation: Among the given options, autoimmune damage is the leading cause of hypoparathyroidism. Note: The leading cause of hypoparathyroidism is thyroid or parathyroid surgery. Causes of Hypoparathyroidism: Iatrogenic (Most Common): Thyroid Surgery Parathyroid Surgery Radical Neck Dissection Radiation Therapy Autoimmune Destruction: Most common non-surgical cause Isolated Hypoparathyroidism APS-1 (Autoimmune Polyglandular Syndrome Type 1) Infiltrative Disorders: Hemochromatosis (Option B) Wilson Disease (Option C) Granulomatous Disease: Such as Sarcoidosis or Amyloidosis Metastatic Disease Genetic & Developmental DiGeorge Syndrome (22q11.2 deletion) Familial Isolated Hypoparathyroidism Functional (Reversible) Hypomagnesemia Hypermagnesemia Rare Miscellaneous Causes Riedel Struma (Option D) Hungry Bone Syndrome

References:

Harrison's Principles of Internal Medicine, 22nd Edition, Page 363, 365.

↑ *Back to this question in Part A*

@Neet_pg_bot

Q16: 30-year-old patient came in with a severe headache and seizure episode. Serum sodium on admission was 98 meq/L. You have started correction with 3% saline and now after 24 hours of infusion sodium is 110 meq/L. The patient develops quadriparesis and altered sensorium. Which investigation will you perform now? (Q850574)

A. MRI Head

B. LP for CSF

C. Brainstem evoked potentials

D. EEG

Correct Answer: A. MRI Head

Explanation: A rise of serum sodium by 12 mEq/L over 24 hours can lead to quadriparesis and altered sensorium, which is classic for Osmotic Demyelination Syndrome. MRI brain is the preferred modality to demonstrate this demyelination. The recommended rise of sodium in chronic hyponatremia is 6–8 mEq/24 hours. LP for CSF, Brainstem evoked potentials, and EEG (Options B, C, and D) cannot demonstrate demyelination of the brain in real time

References:

Harrison's Principles of Internal Medicine, 22nd Edition, Page 2348, 2349.

↑ *Back to this question in Part A*

@Neet_pg_bot

Q17: Leading cause of hypercalcemia in hospitalized patients? (Q850709)

A. Sarcoidosis

B. Oat cell cancer of lung

C. Non small cell cancer of lung

D. Inferior parathyroid adenoma

Correct Answer: C. Non small cell cancer of lung

Explanation: The leading cause of hypercalcemia in hospitalized patients is squamous cell cancer. It produces PTH-rp that leads to increased bone resorption and resultant hypercalcemia. Lung cancer will produce symptoms like cough, weight loss/ cachexia in a short period of time. Sarcoidosis (Option A): This causes hypercalcemia via increased Vitamin D activation (1-alpha-hydroxylase activity in macrophages). It is statistically rare compared to the high volume of malignancy-related cases seen in hospitals. Oat cell cancer of lung (Option B): This type is much more likely to cause Hyponatremia (via SIADH) or Cushing Syndrome (via ectopic ACTH). Hypercalcemia is actually rare in small cell lung cancer. Parathyroid adenoma (Option D): This is the most common cause of outpatient (asymptomatic) hypercalcemia. These patients are usually found on routine screening and are not frequently hospitalized for their calcium levels unless they develop a "parathyroid crisis," which is rare.

References:

Harrison's Principles of Internal Medicine, 22nd Edition, Page 3274, 3275.

↑ *Back to this question in Part A*

@Neet_pg_bot

Q18: Which of the following will have no role in immediate management of acute onset hyperkalemia? (Q850670)

A. Albuterol nebulization

B. Soda bicarbonate

C. Sodium polystyrene sulfonate

D. 50 ml of 50% dextrose with 10 units of regular insulin

Correct Answer: C. Sodium polystyrene sulfonate

Explanation: Sodium polystyrene sulfonate: Works by exchanging sodium for potassium in the gut. Onset of action: 24 hours → too slow for acute management. Rare but serious side effect: colonic necrosis/perforation . Therefore, not used for immediate hyperkalemia . Albuterol nebulization (Option A) : Drives potassium into cells, works within minutes. Sodium bicarbonate (Option B) : Only if metabolic acidosis is present; effect within 4–6 hours. 50 ml of 50% dextrose with 10 units of regular insulin (Option D): Rapidly lowers serum potassium within 15–30 minutes.

References:

Harrison's Principles of Internal Medicine, 22nd Edition, Page 361.

↑ *Back to this question in Part A*

@Neet_pg_bot

Q19: All of the following cause hyperkalemia except? (Q850665)

A. Yellow oleander

B. Prolonged immobilization

C. Autoimmune polyglandular syndrome

D. Cushing syndrome

Correct Answer: D. Cushing syndrome

Explanation: Cushing syndrome will have an excess of cortisol, leading to stimulation of ENac, causing hypokalemic metabolic alkalosis. Yellow oleander (Option A) contains digitalis glycosides that block the sodium-potassium pump. Prolonged immobilisation (Option B) leads to downregulation of Na■/K■-ATPase and

other cell membrane transporters in skeletal muscle with prolonged inactivity. This co-exists with hypercalcemia of immobilisation. Autoimmune polyglandular syndrome (Option C) is associated with Addison's disease, which leads to hyperkalemia and acidosis due to aldosterone deficiency.

References:

Harrison's Principles of Internal Medicine, 22nd Edition, Page 354, 358.

↑ *Back to this question in Part A*

@Neet_pg_bot

Q20: All of the following cause hypokalemia except? (Q850663)

A. Thyrotoxicosis

B. Salbutamol

C. Lupus nephritis

D. Conn syndrome

Correct Answer: C. Lupus nephritis

Explanation: Lupus nephritis will damage the glomerulus and cause chronic kidney disease. This leads to hyperkalemic metabolic acidosis. Thyrotoxicosis (Option A) and salbutamol (Option B) will cause sympathetic stimulation that leads to potassium influx into muscles. Conn syndrome (Option D) has excess of aldosterone leading to hypertension with hypokalemic metabolic alkalosis.

References:

Harrison's Principles of Internal Medicine, 22nd Edition, Page 354, 358.

↑ *Back to this question in Part A*

@Neet_pg_bot

Q21: Which of the following causes hypokalemia? (Q850659)

A. Tumor lysis syndrome

B. Crush injury

C. Hemolysis

D. Massive transfusion

Correct Answer: D. Massive transfusion

Explanation: Massive transfusion leads to large amounts of citrate entering the bloodstream. Citrate is metabolized to bicarbonate , causing metabolic alkalosis . In alkalosis, H■ moves out of cells , and K■ shifts into cells , lowering serum potassium, leading to hypokalemia . Tumor lysis syndrome (Option A): cell breakdown leads to release of intracellular K■ causing hyperkalemia . Crush injury (Option B): muscle cell destruction leads to K■ release which causes hyperkalemia . Hemolysis (Option C): RBC rupture leads to the release of K■.

References:

Harrison's Principles of Internal Medicine, 22nd Edition, Page 354.

↑ *Back to this question in Part A*

@Neet_pg_bot

Q22: Which of the following is a cause of chloride-resistant metabolic alkalosis? (Q850657)

A. Chronic vomiting

B. Bartter syndrome

C. Infantile hypertrophic pyloric stenosis

D. Gastric outlet obstruction

Correct Answer: B. Bartter syndrome

Explanation: Bartter syndrome has defect in Na■–K■–2Cl■ cotransporter (NKCC2) in thick ascending limb. This causes chronic renal NaCl wasting and volume depletion. This in turn leads to RAAS activation , ↑aldosterone and resultant H■ and K■ loss in urine causing metabolic alkalosis. It is chloride-resistant because the alkalosis persists despite chloride replacement , as the underlying defect is intrinsic tubular transport failure, not chloride depletion (unlike vomiting/NG suction)

References:

Harrison's Principles of Internal Medicine, 22nd Edition, Page 373, 374.

↑ *Back to this question in Part A*

@Neet_pg_bot

Q23: Which of the following is not a cause of chloride responsive metabolic alkalosis? (Q850651)

A. Gastric adenocarcinoma

B. IHPS

C. Ascites

D. Chronic vomiting

Correct Answer: C. Ascites

Explanation: Ascites leads to secondary hyperaldosteronism that causes metabolic alkalosis. The patient is given spironolactone that will counterbalance increased aldosterone and thereby treat metabolic alkalosis. Gastric adenocarcinoma, IHPS, and chronic vomiting (Options A, B, D) lead to dehydration and resultant hyperaldosteronism. The patient will develop hypochloremic hypokalemic metabolic alkalosis. They can be managed with normal saline (0.9% sodium chloride) and hence are called chloride responsive metabolic alkalosis.

References:

Harrison's Principles of Internal Medicine, 22nd Edition, Page 374.

↑ *Back to this question in Part A*

@Neet_pg_bot

Q24: Which of the following is fluid of choice for metabolic alkalosis? (Q850643)

A. Normal saline

B. Ringer lactate

C. 5% dextrose

D. Isolyte-P

Correct Answer: A. Normal saline

Explanation: Most cases of metabolic alkalosis are chloride-responsive (like vomiting, gastric suction, diuretics). In these, the primary problem is extracellular fluid contraction + chloride loss . Giving 0.9% NaCl (normal saline) corrects both: Restores intravascular volume that suppresses RAAS → reduces distal H■ and K■ excretion Supplies chloride that allows the kidney to excrete bicarbonate (since HCO■■ excretion is linked to chloride delivery in the collecting duct). Thus, saline replenishes volume + chloride → kidney can dump excess bicarbonate → alkalosis corrects. Ringer lactate (Option B): Contains lactate , which can be converted to bicarbonate; may worsen metabolic alkalosis . 5% dextrose (Option C): Free water without chloride; does not correct alkalosis and

can worsen hypokalemia. Isolyte-P (Option D): Balanced electrolyte solution; not ideal as first choice in chloride-responsive metabolic alkalosis .

References:

Harrison's Principles of Internal Medicine, 22nd Edition, Page 375.

↑ *Back to this question in Part A*

@Neet_pg_bot

Q25: For a patient of acute onset hypernatremia Na= 158 meq/L with confusion and seizures, which of the following fluids is not to be used? (Q850641)

A. 5% Dextrose

B. N/2 saline

C. N/4 saline

D. Normal saline

Correct Answer: D. Normal saline

Explanation: Normal Saline has 154 mEq/L of sodium. This is almost identical to the patient's level of 158 mEq/L. To treat hypernatremia, you must provide free water to dilute the serum. Normal Saline provides almost no free water relative to the patient's state. It can fail to lower the sodium or even worsen the hyperosmolarity, potentially exacerbating the seizures. For symptomatic hypernatremia the fluid of choice is 5% dextrose. N/2 or N/4 is a dilute fluid containing more water and can be used.

References:

Harrison's Principles of Internal Medicine, 22nd Edition, Page 353.

↑ *Back to this question in Part A*

@Neet_pg_bot

Q26: Which of the following is correct about the rate of correction for chronic hyponatremia? (Q850630)

A. 4-6 meq/ d

B. 6-8 meq/d

C. 8-10 meq/d

D. 10-12 meq/d

Correct Answer: B. 6-8 meq/d

Explanation: To minimize the chances of osmotic demyelination syndrome, the recommendation is to correct maximum of 6-8 meq in first 24 hours and < 6 meq in next 24 hours.

References:

Harrison's Principles of Internal Medicine, 22nd Edition, Page 351.

↑ *Back to this question in Part A*

@Neet_pg_bot

Q27: A 60-kg male runner develops cramps, disorientation, and seizures after completing a marathon. On admission, serum sodium is 120 mEq/L and serum potassium is 3.2 meq/L. What is the approximate sodium deficit in this patient? (Q850627)

A. 180 meq

B. 360 meq

C. 420 meq

D. 720 meq

Correct Answer: D. 720 meq

Explanation: This patient has acute symptomatic hyponatremia and seizures after endurance exercise. Sodium deficit calculation: 0.6 X weight X (Desired value – actual value) Sodium deficit calculation: 0.6 X 60 X (140-120) = 720 mEq Note: If a female patient, the multiplication factor will be 0.5 instead of 0.6

References:

Harrison's Principles of Internal Medicine, 22nd Edition, Page 351.

↑ *Back to this question in Part A*

@Neet_pg_bot

Q28: Which of the following is not a cause of hypervolemic hyponatremia? (Q850599)

A. HFrEF

B. CLD

C. Nephrotic syndrome

D. Atypical pneumonia

Correct Answer: D. Atypical pneumonia

Explanation: Atypical pneumonia (Legionella pneumophila) causes euvolemic hyponatremia via SIADH. HFrEF (Option A) leads to low cardiac output. This will cause increased RAAS and ADH activation, causing hypervolemic hyponatremia. Cirrhosis/ CLD (Option B) causes splanchnic vasodilation leading to increased RAAS and ADH activation, causing hypervolemic hyponatremia. Nephrotic syndrome (Option C) leads to hypoalbuminemia. It causes low plasma oncotic pressure, causing fluid retention with hyponatremia.

References:

Harrison's Principles of Internal Medicine, 22nd Edition, Page 348, 349.

↑ *Back to this question in Part A*

@Neet_pg_bot

Q29: Which of the following is not seen in patients with hypokalemia? (Q850577)

A. Ileus

B. Polyuria

C. Atrial arrhythmias

D. Metabolic acidosis

Correct Answer: D. Metabolic acidosis

■ *Listen (English)*

■ *Listen (Hindi)*

Explanation: Hypokalemia is classically associated with metabolic alkalosis , not metabolic acidosis. This happens because: Low K■ → K■ shifts out of cells → H■ shifts into cells → alkalosis Kidney compensates by increasing H■ secretion and bicarbonate reabsorption , further worsening alkalosis. Therefore, metabolic acidosis is not seen in hypokalemia Ileus (Option A): Hypokalemia causes hyperpolarization of smooth muscle , leading to decreased gut motility, paralytic ileus, and constipation. Polyuria (Option B): Hypokalemia causes nephrogenic DI due to decreased responsiveness of V2 receptors to ADH, leading to polyuria . Atrial arrhythmias (Option C): are common in hypokalemia due to delayed repolarization and prolongation of QT interval (esp. PACs, AF and atrial flutter)

References:

Harrison's Principles of Internal Medicine, 22nd Edition, Page 356.

↑ *Back to this question in Part A*

@Neet_pg_bot

Q30: Sudden shrinkage of brain cells in acute hypernatremia encountered in neonate on day 2 of life can lead to development of: (Q850576)

A. Intra- parenchymal bleeding

B. Osmotic demyelination syndrome

C. Paralytic ileus

D. Tachyarrhythmias

Correct Answer: A. Intra- parenchymal bleeding

Explanation: Hypernatremia increases the osmolality of the ECF, generating an osmotic gradient between the ECF and ICF. Hence, water shifts out of brain cells, causing cell shrinkage. This osmotic shift can cause tearing of cerebral vessels, causing intracerebral/intraparenchymal hemorrhage. Osmotic demyelination syndrome (ODS) (Option B) occurs with rapid correction of hyponatremia, not hypernatremia. Paralytic ileus (Option C) is seen with hypokalemia Tachyarrhythmias (Option D) are seen due to variation in potassium levels.

References:

Harrison's Principles of Internal Medicine, 22nd Edition, Page 352.

↑ *Back to this question in Part A*

@Neet_pg_bot

• [04_Nephrology] 023 Ciliopathies Pkd Ttp

« Back to Folder Directory

[04_Nephrology] 023 Ciliopathies Pkd Ttp — Quick Jump

Q1 (p. 1798) *Q2 (p. 1798)* *Q3 (p. 1799)* *Q4 (p. 1800)* *Q5 (p. 1801)* *Q6 (p. 1801)*
Q7 (p. 1802) *Q8 (p. 1802)* *Q9 (p. 1803)* *Q10 (p. 1804)* *Q11 (p. 1805)* *Q12 (p. 1805)*
Q13 (p. 1806)

Q1: Which of the following is not correct about thrombotic thrombocytopenic purpura? (Q850750)

A. Deficiency of ultra large multimers of vWF

B. Microangiopathic haemolytic anaemia

C. Deficiency of ADAMTS13

D. Treated with plasma exchanges

Correct Answer: A. Deficiency of ultra large multimers of vWF

Explanation: Deficiency of ultra-large multimers of vWF is incorrect. In fact, there is an excess of ultra-large vWF multimers due to decreased activity or absence of ADAMTS13. These ultra-large multimers form clots and shear erythrocytes, resulting in MAHA. TTP is now defined as MAHA associated with ADAMTS13 activity of <5–10%.

References:

Harrison's Principles of Internal Medicine, 22nd Edition, Page 2445.

↑ *Back to this question in Part A*

@Neet_pg_bot

Q2: A 32-year-old woman presents with fever, confusion, and generalized weakness for 3 days. On examination, she has pallor, multiple petechiae, and a right-sided facial droop. Laboratory investigations reveal: Hemoglobin: 7.8 g/dL Platelet count: 25,000/mm³ Peripheral smear shows numerous schistocytes LDH: markedly elevated Creatinine: 1.2 mg/dL Which of the following is the most likely diagnosis? (Q850758)

A. Thrombotic Thrombocytopenic Purpura

B. Henoch–Schönlein Purpura

C. Haemolytic Uremic Syndrome

D. Tubulointerstitial Kidney Disease

Correct Answer: A. Thrombotic Thrombocytopenic Purpura

Explanation: Thrombotic thrombocytopenic Purpura Explanattion: Combination of Fever + MAHA (haemolysis indicated by elevated LDH and schistocytes) + thrombocytopenia + neurological deficit (confusion, stroke-like episode, seizures) + mild renal dysfunction indicates TTP HUS (Option C) is seen in children post diarrheal illness and has MAHA + thrombocytopenia but with severe renal impairment and less prominent CNS features HSP (Option B) is seen in children and presents with palpable purpura, arthralgia, abdominal pain, IgA nephropathy ADTKD (Option D) presents with slowly progressive CKD without hemolysis, thrombocytopenia, or neuro features

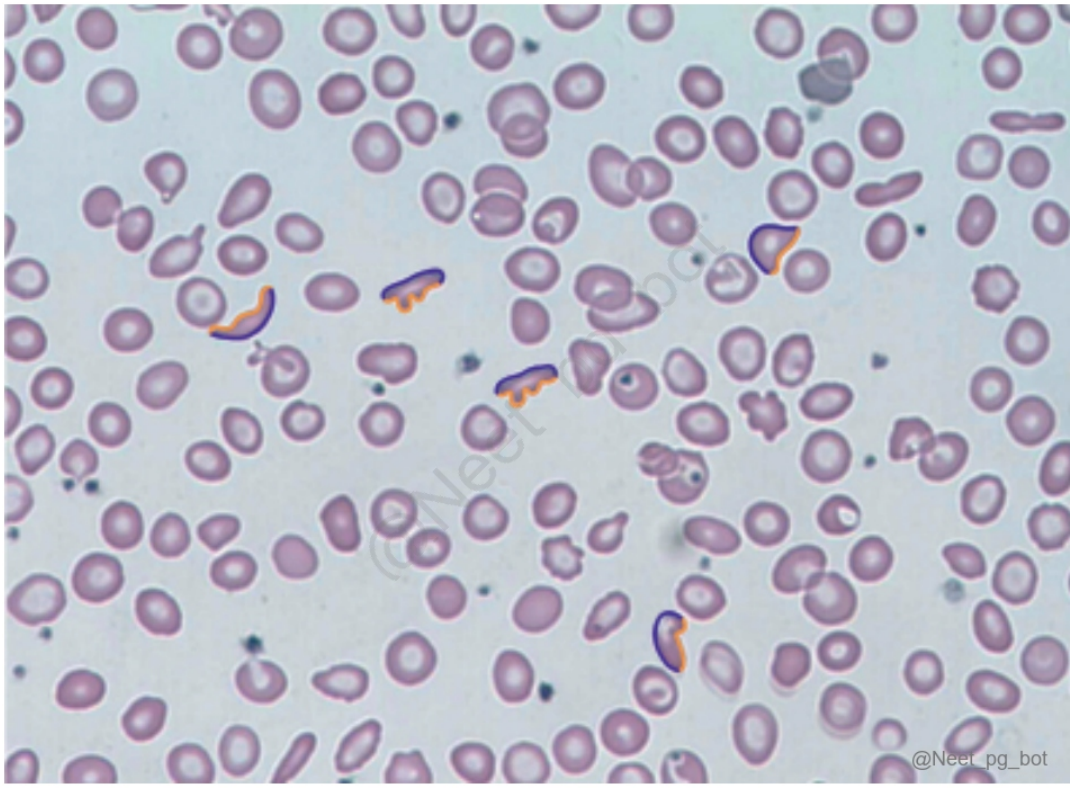

References:

Harrison's Principles of Internal Medicine, 22nd Edition, Page 2445.

↑ *Back to this question in Part A*

@Neet_pg_bot

Q3: 30-year-old man presents with dull aching bilateral flank pain. BP is 160/100 mmHg. Family history reveals that his father died of brain haemorrhage at age 60. What is the first investigation that should be done in this case? (Q850759)

A. NCCT: KUB

B. CECT: KUB

C. Ultrasound abdomen

D. DTPA scan

Correct Answer: C. Ultrasound abdomen

Explanation: The first differential diagnosis is ADPKD. It is associated with a berry aneurysm at the Circle of Willis bifurcations. USG abdomen should be done to evaluate corticomedullary differentiation and the number of cysts in each kidney (Ravine criteria). CT and MRI (Options A and B) can detect smaller cysts, but apart from radiation expose the patient to radio-contrast-that causes the risk of contrast-induced nephropathy. Radionuclide scans (DTPA/MAG3) (Option D) are used to assess split renal function and diagnosis.

References:

Harrison's Principles of Internal Medicine, 22nd Edition, Page 2432.

↑ *Back to this question in Part A*

@Neet_pg_bot

Q4: What is the leading cause of death in ADPKD? (Q850760)

A. Renal failure

B. Rupture of berry aneurysm

C. Renal cell cancer

D. CV mortality

Correct Answer: D. CV mortality

Explanation: Cardiovascular disease is the leading cause of death in ADPKD patients. Hypertension develops early due to cyst compression of renal vasculature, activating the RAAS system.

References:

Harrison's Principles of Internal Medicine, 22nd Edition, Page 2432.

↑ *Back to this question in Part A*

@Neet_pg_bot

Q5: In a follow-up visit of a 40-year-old man diagnosed with ADPKD based on Ravine criteria, which investigation should be done to screen for intracranial aneurysm and risk of subarachnoid bleeding? (Q850761)

A. Lumbar puncture

B. MRA

C. NCCT head

D. Transcranial doppler

Correct Answer: B. MRA

Explanation: Patients with ADPKD who have a positive family history of intracranial aneurysms (ICAs) should undergo presymptomatic screening with magnetic resonance angiography (MRA). Lumbar puncture (Option A): Detects subarachnoid hemorrhage when CT is negative, but not a screening tool. NCCT head (Option C): Used to diagnose subarachnoid hemorrhage in symptomatic patients, not for presymptomatic screening. Transcranial Doppler (Option D): Evaluates cerebral blood flow velocity, mainly used for vasospasm monitoring, not initial screening for ICAs.

References:

Harrison's Principles of Internal Medicine, 22nd Edition, Page 2432.

↑ *Back to this question in Part A*

@Neet_pg_bot

Q6: Which is the most common cardiac valvular lesion seen in patients of ADPKD? (Q850762)

A. Mitral valve prolapse

B. Tricuspid valve prolapse

C. Pulmonic insufficiency

D. Tricuspid insufficiency

Correct Answer: A. Mitral valve prolapse

Explanation: Mitral valve prolapse is the most common valvular abnormality in ADPKD, occurring in up to 30% of patients . Tricuspid valve prolapse can also occur but is much less frequent.

References:

Harrison's Principles of Internal Medicine, 22nd Edition, Page 2432.

↑ *Back to this question in Part A*

@Neet_pg_bot

Q7: Which is the most common cardiac valvular lesion seen in patients of carcinoid syndrome? (Q850763)

A. Tricuspid insufficiency and pulmonic stenosis

B. Tricuspid stenosis and pulmonic insufficiency

C. Mitral insufficiency and pulmonic stenosis

D. Mitral stenosis and pulmonic insufficiency

Correct Answer: A. Tricuspid insufficiency and pulmonic stenosis

Explanation: Remember mnemonic TIPS : Tricuspid insufficiency and pulmonic stenosis for cardiovascular features of carcinoid syndrome. The serotonin excess affects the RV inflow and outflow tract resulting in the clinical features shown below. Serotonin-induced fibrosis can thicken and shorten the tricuspid valve leaflets, causing them to not close properly. Similarly, serotonin can affect the pulmonary valve, leading to thickening and narrowing (stenosis), restricting blood flow from the right ventricle to the pulmonary artery.

References:

Harrison's Principles of Internal Medicine, 22nd Edition, Page 683.

↑ *Back to this question in Part A*

@Neet_pg_bot

Q8: Which of the following is not correct about autosomal dominant tubulointerstitial kidney disease? (Q850764)

A. Enlarged kidneys

B. Medullary cysts

C. UMOD gene defect

D. Increased incidence of gout

Correct Answer: A. Enlarged kidneys

Explanation: Patients with ADTKD-MUC1 have mutations in MUC1 gene. Kidney histology shows tubulointerstitial fibrosis and tubular atrophy leading to small fibrotic kidneys with medullary cysts ADTKD-UMOD is caused by mutations in the UMOD gene, which encodes the protein uromodulin, also known as Tamm-Horsfall protein. These patients have associated gout.

References:

Harrison's Principles of Internal Medicine, 22nd Edition, Page 2435.

↑ *Back to this question in Part A*

@Neet_pg_bot

Q9: 5-year-old child developed vomiting, cramping and bloody diarrhea that was managed with ORS and antibiotics. After 1 week the patient is admitted due to anuria for the last 24 hours and encephalopathy. Work up shows Hb 7gm%, TLC 15000 / cu.mm, platelet count 50,000 /cu.mm, LDH is elevated and peripheral smear is shown below. What is the diagnosis? (Q850765)

A. Hemolytic uremic syndrome (HUS)

B. Thrombotic thrombocytopenic purpura (TTP)

C. Acute tubular necrosis (ATN)

D. Henoch–Schönlein purpura (HSP)

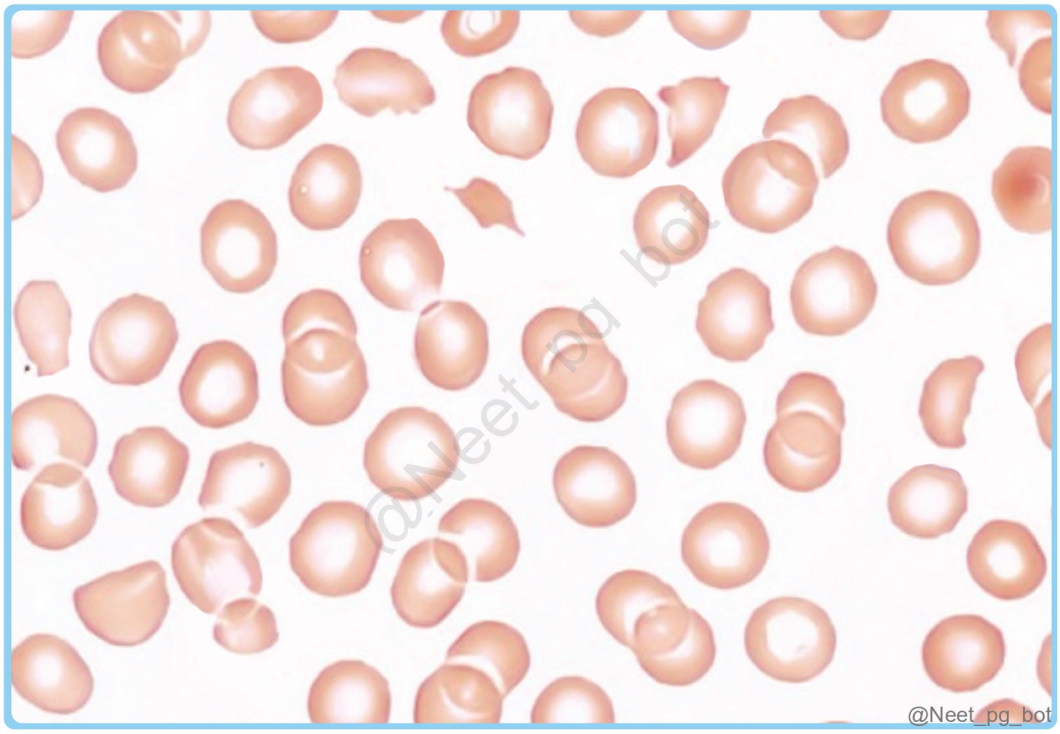

Correct Answer: A. Hemolytic uremic syndrome (HUS)

Explanation: The combination of MAHA (elevated LDH with schistocytes on PS) plus renal failure is seen in D+ HUS. The organism incriminated is EHEC (specifically the O157:H7 strain), which presents with abdominal pain, cramping, and vomiting, whereas fever is absent. Shiga toxin binds to glycolipid surface receptor globotriaosylceramide, which is richly expressed on cells of the renal microvasculature TTP (Option B): Presents with pentad (MAHA, thrombocytopenia, fever, neurological symptoms, renal involvement), usually in adults with ADAMTS13 deficiency. ATN (Option C): Causes renal failure but not associated with MAHA or thrombocytopenia. HSP (Option D): IgA-mediated vasculitis with palpable purpura, arthralgia, abdominal pain, and hematuria, not MAHA with schistocytes.

References:

Harrison's Principles of Internal Medicine, 22nd Edition, Page 2444.

↑ *Back to this question in Part A*

@Neet_pg_bot

Q10: The leading extra-renal manifestation of autosomal recessive polycystic kidney disease is? (Q850766)

A. Hepatic cysts

B. Hepatic fibrosis

C. Berry aneurysm

D. Arachnoid cysts

Correct Answer: B. Hepatic fibrosis

Explanation: In autosomal recessive Polycystic Kidney Disease, the leading extra-renal manifestation is hepatic fibrosis , which occurs due to ductal plate malformation. This leads to portal hypertension and splenomegaly in affected children. Hepatic cysts (Option A): The most common extra-renal manifestation of ADPKD. Berry aneurysm (Option C) and Arachnoid cysts (Option D): Seen with ADPKD.

References:

Harrison's Principles of Internal Medicine, 22nd Edition, Page 2430, 2432, 2434.

↑ *Back to this question in Part A*

@Neet_pg_bot

Q11: Which of the following is correct about genetic aspects of Autosomal recessive polycystic kidney disease? (Q850767)

A. PKHD1 gene, chromosome 6

B. PKD1 gene, chromosome 16

C. PKD2 gene, chromosome 4

D. UMOD gene, chromosome 16

Correct Answer: A. PKHD1 gene, chromosome 6

Explanation: PKHD1 gene, chromosome 6 = ARPKD. PKHD1 encodes fibrocystin/polyductin . PKD1 gene, chromosome 16 (Option B): ADPKD PKD2 gene, chromosome 4 (Option C): ADPKD (the milder form). UMOD gene, chromosome 16 (Option D): AD Tubulointerstitial Kidney Disease, not ARPKD.

References:

Harrison's Principles of Internal Medicine, 22nd Edition, Page 2433.

↑ *Back to this question in Part A*

@Neet_pg_bot

Q12: 35-year-old man is treated with amoxicillin + clavulanic acid for lobar pneumonia. After 10 days of therapy, he develops fever, maculopapular rash, and decreased urine output. Labs show serum creatinine of 3.2 mg/dL. Urinalysis reveals mild proteinuria, microscopic hematuria, and numerous WBCs. Wright's stain of the urine demonstrates eosinophiluria. Which of the following is the most likely diagnosis? (Q850768)

A. Acute tubular necrosis

B. Acute interstitial nephritis

C. Rapidly progressive glomerulonephritis

D. Nephrolithiasis

Correct Answer: B. Acute interstitial nephritis

Explanation: A combination of fever, rash, and eosinophiluria in a patient with renal shutdown after beta-lactam usage is seen in Acute interstitial nephritis. Acute tubular necrosis (Option A): Has muddy brown granular casts. Rapidly progressive glomerulonephritis (Option C): Has RBC casts and occurs due to anti-GBM, ANCA vasculitis. Nephrolithiasis (Option D): Presents with renal colic and hematuria.

References:

Harrison's Principles of Internal Medicine, 22nd Edition, Page 2437.

↑ *Back to this question in Part A*

@Neet_pg_bot

Q13: All of the following are correct about Renal vein thrombosis except? (Q850769)

A. Seen with membranous glomerulopathy

B. Associated with ADAMTS 13 deficiency

C. CT angiography is 100% sensitive

D. Oral anticoagulation is first line treatment

Correct Answer: B. Associated with ADAMTS 13 deficiency

Explanation: ADAMTS 13 deficiency causes TTP and not RVT. Normal role of ADAMTS13 is to cleave ultra-large vWF multimers into smaller fragments. Deficiency of ADAMTS13 causes ultra-large vWF multimers to accumulate and cause spontaneous platelet aggregation and widespread microthrombi formation. Seen with

membranous glomerulopathy (Option A): RVT is seen in paediatric population due to dehydration caused by diarrhea and in adults with MGN. CT angiography is 100% sensitive (Option C): Doppler is the initial investigation for work up but CT angiography is 100% sensitive. Oral anticoagulation is first line treatment (Option D): Oral anticoagulation is used though in some cases nephrectomy may be required.

References:

Harrison's Principles of Internal Medicine, 22nd Edition, Page 2447.

↑ *Back to this question in Part A*

@Neet_pg_bot

• [04_Nephrology] 024 Kidney Urine Analysis

« Back to Folder Directory

[04_Nephrology] 024 Kidney Urine Analysis — Quick Jump

Q1 (p. 1808) *Q2 (p. 1809)* *Q3 (p. 1809)* *Q4 (p. 1810)* *Q5 (p. 1811)* *Q6 (p. 1812)*
Q7 (p. 1813) *Q8 (p. 1813)* *Q9 (p. 1815)* *Q10 (p. 1815)* *Q11 (p. 1816)* *Q12 (p. 1816)*
Q13 (p. 1817)

Q1: A known Type II DM, 70 year old patient was under medication. He aslo takes Telmisartan. Patients current lab values: HbA1c- 8.5, eGFR- 50 mL/min/1.73 m. Normal potassium levels. What is the next appropriate step to decrease the risk of further eGFR decrement? (Q882282)

A. Shift to Ramipril

B. Increase the dose of antidiabetic meds

C. Start Carvedilol

D. Increase Telmisartan dose

Correct Answer: D. Increase Telmisartan dose

Explanation: The patient has diabetic kidney disease (DKD) with moderately reduced eGFR (CKD stage 3a). ACE inhibitors or ARBs are renoprotective and slow progression of DKD by: Reducing intraglomerular pressure Decreasing proteinuria Guidelines recommend titrating ACEi/ARB to the maximum tolerated dose, provided: Serum potassium is normal No significant fall in eGFR (>30%) Since the patient is already on Telmisartan with normal potassium, the best step is dose up-titration Shift to Ramipril (Option A): Switching from ARB to ACE inhibitor provides no additional renal benefit; combination or switching is not indicated. Increase the dose of antidiabetic medications (Option B): Better glycemic control is important, but RAAS blockade optimization is the most effective step to prevent further eGFR decline. Start Carvedilol (Option C): Beta-blockers have no proven renoprotective role in diabetic nephropathy.

References:

https://diabetesjournals.org/care/article/45/12/3075/147614/Diabetes-Management-in-Chronic-Kidney-Disease-A

https://pmc.ncbi.nlm.nih.gov/articles/PMC9727535/

↑ *Back to this question in Part A*

@Neet_pg_bot

Q2: Oval fat bodies in urine are seen in all of the following conditions except? (Q851037)

A. Minimal change disease

B. Focal segmental glomerulosclerosis

C. Membranous nephropathy

D. Fat embolism syndrome

Correct Answer: D. Fat embolism syndrome

Explanation: Oval fat bodies are lipid-laden renal tubular epithelial cells. They appear in nephrotic syndrome due to heavy proteinuria and lipiduria. It is a characteristic finding in MCD, FSGS, membranous nephropathy, diabetic nephropathy, etc. Fat embolism syndrome has free-floating fat globules and not fat inside cells Oval Fat Bodies vs Fat Globules in Fat Embolism Feature Ovale for Bodies (Nephrotic Syndrome Fat Globules (FAT Embolism Syndrome) Origin Renal tubular epithelial cells that have absorbed lipid from heavy proteinuria Neutral fat droplets entering circulation after bone marrow/fat trauma Appearance in urine Ovale/round cells with lipid droplets inside (best seen with polarized light → ” Maltese cross” pattern) Free-floating fat globules (not inside cells) Underlying disease Nephrotic syndrome (MCD, FSGS, Membranous, Diabetic nephropathy) Long bone fracture, orthopedic trauma, pancreatitis, burns

References:

Harrison's Principles of Internal Medicine, 22nd Edition, Page 2357.

↑ *Back to this question in Part A*

@Neet_pg_bot

Q3: 28-year-old man presents to the emergency department after ingesting a large quantity of over-the-counter cough syrup in a suicide attempt. He complains of severe abdominal pain and confusion. ABG shows high anion gap metabolic acidosis. Urinalysis microscopy is shown below. Which of the following is the most appropriate initial treatment? (Q851038)

A. Sodium bicarbonate infusion

B. Hemodialysis

C. Fomepizole

D. N-acetylcysteine

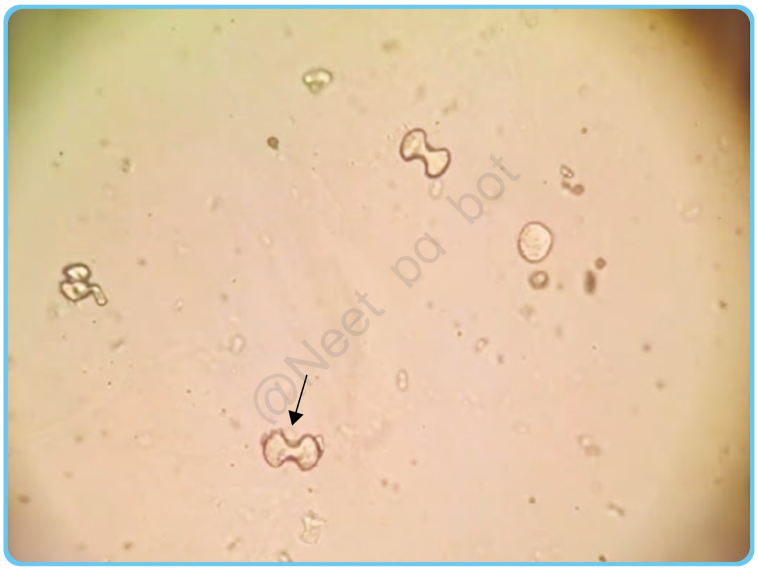

@Neet_pg_bot

Correct Answer: C. Fomepizole

Explanation: The clue in the question is the image “dumbbell-shaped crystals” which are characteristic of calcium oxalate monohydrate. Calcium oxalate crystalluria suggests ethylene glycol poisoning which can be present in over-the-counter local company manufactured cough syrups. The metabolites like glycolate will cause severe metabolic acidosis that causes CNS depression due to high anion gap metabolic acidosis. The antidote is fomepizole.

References:

Harrison's Principles of Internal Medicine, 22nd Edition, Page 371, 2440.

↑ *Back to this question in Part A*

@Neet_pg_bot

Q4: 25-year-old patient is having recurrent kidney stones. Urine microscopy is shown below. Which of the following drugs will prevent recurrence of these kidney stones. (Q851039)

A. Thiazides

B. Furosemide

C. Tiopronin

D. Mercaptopurine



@Neet_pg_bot

Correct Answer: C. Tiopronin

Explanation: The image shows “hexagonal crystals” in urine are diagnostic of cystine stones/ cystinuria. It is an inherited defect in renal tubular reabsorption of cystine, ornithine, lysine, and arginine (“COLA”). Tiopronin is a sulfhydryl compound that forms soluble complexes with cystine and prevents recurrence. Thiazides (Option A): Used in calcium stone prevention, not cystine stones. Furosemide (Option B): Increases urinary calcium excretion, can worsen nephrolithiasis. Mercaptopurine (Option D): An antimetabolite used in chemotherapy and immunosuppression, unrelated to stone prevention.

References:

Harrison's Principles of Internal Medicine, 22nd Edition, Page 2453.

↑ *Back to this question in Part A*

@Neet_pg_bot

Q5: Eosinophiluria is typically seen in all of the following conditions except: (Q851040)

A. Allergic interstitial nephritis

B. Atheroembolic kidney disease

C. Pyelonephritis

D. Tubulointerstitial nephritis

Correct Answer: D. Tubulointerstitial nephritis

Explanation: Tubulointerstitial nephritis leads to granular casts Eosinophils in urine are seen in Atheroembolic kidney disease (Purple toes + Livedo reticularis + Renal shut down) (Option B) Acute interstitial nephritis caused by PPI and antibiotics (Option A) Schistosomiasis Glomerulonephritis Pyelonephritis and cystitis (Option C)

References:

Harrison's Principles of Internal Medicine, 22nd Edition, Page 2380.

↑ *Back to this question in Part A*

@Neet_pg_bot

Q6: The presence of broad casts on urine microscopy is most suggestive of which condition? (Q851041)

A. Acute tubular necrosis

B. Acute interstitial nephritis

C. Chronic kidney disease

D. Thrombotic thrombocytopenic purpura

Correct Answer: C. Chronic kidney disease

Explanation: Broad casts are formed in dilated, atrophic tubules seen in chronic kidney disease, often referred to as “waxy casts.” Acute tubular necrosis (Option A): Characterized by granular/muddy brown casts , not broad casts. Acute interstitial nephritis (Option B): Shows WBC casts and sometimes eosinophiluria . Thrombotic thrombocytopenic purpura (Option D): Demonstrates schistocytes on peripheral smear, not urinary casts.

References:

Harrison's Principles of Internal Medicine, 22nd Edition, Page 2380.

↑ *Back to this question in Part A*

@Neet_pg_bot

Q7: What is the diagnostic cutoff used to define hematuria on urine microscopy? (Q851042)

A. > 1 RBC/ HPF in centrifuged sediment X 3 reports

B. > 5 RBC/ HPF in centrifuged urine sediment X 3 reports

C. > 50 RBC/ HPF in centrifuged urine sediment X 3 reports

D. > 500 RBC/ HPF in centrifuged urine sediment X 3 reports

Correct Answer: B. > 5 RBC/ HPF in centrifuged urine sediment X 3 reports

Explanation: Cut off for diagnosis of hematuria is > 100 RBC/ HPF of centrifuged sediment in single episode > 5 RBC / HPF of centrifuged sediment in three independent reports

References:

Harrison's Principles of Internal Medicine, 22nd Edition, Page 341, 343.

↑ *Back to this question in Part A*

@Neet_pg_bot

Q8: What is the hallmark feature of glomerular hematuria? (Q851043)

A. RBC casts

B. Dysmorphic RBC

C. Low C3

D. Cola color urine

Correct Answer: B. Dysmorphic RBC

Explanation: Dysmorphic RBCs (especially acanthocytes) are the hallmark of glomerular hematuria because RBCs get distorted while passing through the damaged glomerular basement membrane. These are RBCs with bleb-like protrusions ("Mickey Mouse ears") on phase-contrast microscopy. If >5% of urinary RBCs are acanthocytes, it is highly specific (>95%) for glomerular hematuria.

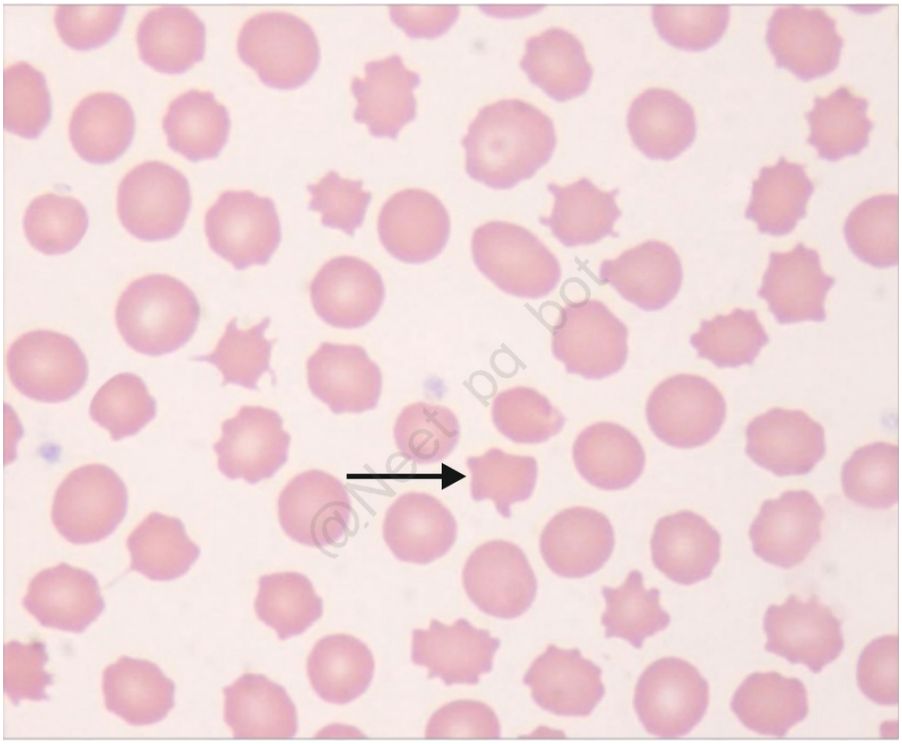

Acanthocyte @Neet_pg_bot

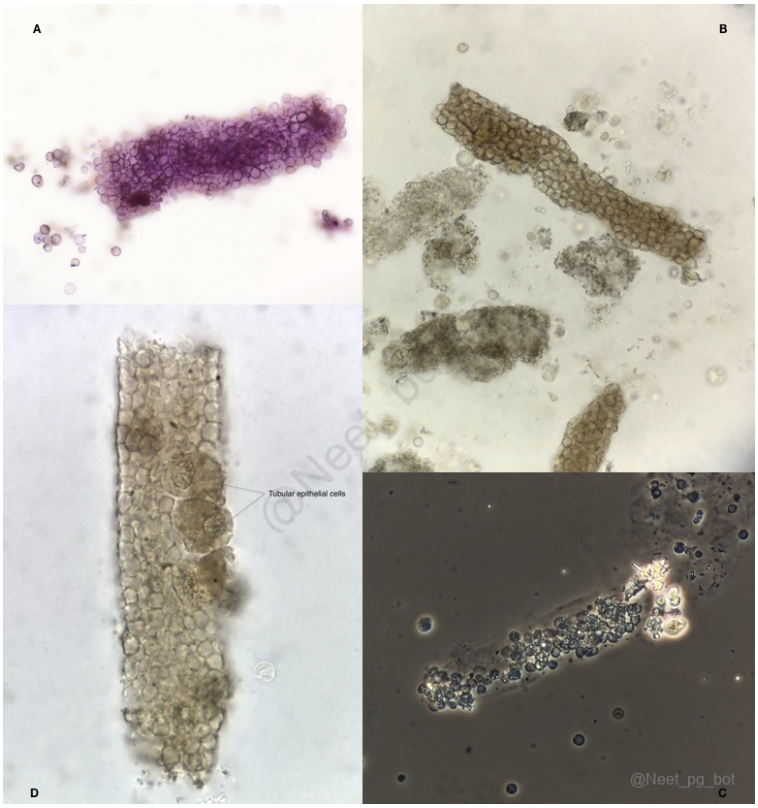

References:

Harrison's Principles of Internal Medicine, 22nd Edition, Page 343.

↑ *Back to this question in Part A*

@Neet_pg_bot

Q9: Muddy brown granular casts are seen in? (Q851044)

A. ATN

B. CGN

C. AIN

D. AGN

Correct Answer: A. ATN

Explanation: Muddy brown granular casts are the hallmark of Acute Tubular Necrosis (ATN) , formed by degenerated tubular cells. Chronic Glomerulonephritis (Option B): Broad, waxy casts reflecting chronic renal parenchymal damage are seen. Acute Interstitial Nephritis (AIN) (Option C) is characterized by WBC casts and eosinophils in urine because of allergic interstitial inflammation. Acute Glomerulonephritis (AGN) (Option D): The typical finding is RBC casts due to glomerular capillary injury.

References:

Harrison's Principles of Internal Medicine, 22nd Edition, Page 2353.

↑ *Back to this question in Part A*

@Neet_pg_bot

Q10: What is the recommended screening test for diabetic nephropathy? (Q851045)

A. 24-hour urine protein estimation

B. Serum creatinine

C. Spot urine albumin-to-creatinine ratio

D. Urine dipstick for protein

Correct Answer: C. Spot urine albumin-to-creatinine ratio

Explanation: Urine Albumin-to-Creatinine Ratio is the recommended screening test for detecting primary kidney disease in diabetes mellitus. Values >2.5 mg/mmol in men and >3.5 mg/mmol in women confirmed on 2 of 3 samples over 3–6 months is the correct method for detecting early DKD in annual check-up.

References:

Harrison's Principles of Internal Medicine, 22nd Edition, Page 2387.

↑ *Back to this question in Part A*

@Neet_pg_bot

Q11: 24-year-old man presents with red-colored urine after trauma due to being repeatedly punched in the abdomen during a street fight. On keeping the urine sample standing, the color clears in the next few hours. Which of the following is the most likely cause? (Q851046)

A. Hematuria

B. Hemoglobinuria

C. Myoglobinuria

D. Porphyria

Correct Answer: A. Hematuria

Explanation: Trauma to the urinary tract can cause hematuria. In hematuria , the urine appears red initially, but when the RBCs settle at the bottom on standing , the supernatant clears. Hemoglobinuria (Option B): Urine remains red/brown even after standing because free hemoglobin does not settle. Myoglobinuria (Option C): Similar to hemoglobinuria, remains dark, does not clear on standing. Porphyria (Option D): Causes port-wine discolouration that also does not clear on standing.

References:

Harrison's Principles of Internal Medicine, 22nd Edition, Page 343.

↑ *Back to this question in Part A*

@Neet_pg_bot

Q12: 9-year-old boy presents with his urine turned dark red after playing football. On examination, he has no hepatosplenomegaly. Laboratory studies reveal normal blood lactate after forearm exercise testing but elevated creatine kinase. Which of the following is the cause? (Q851047)

A. Orthostatic haematuria

B. Muscle glycogen phosphorylase deficiency

C. Trauma

D. Acid maltase deficiency

Correct Answer: B. Muscle glycogen phosphorylase deficiency

Explanation: This boy has McArdle disease (muscle glycogen phosphorylase deficiency) , where exercise leads to muscle breakdown with myoglobinuria (dark red urine) with elevated CPK but normal lactate after exercise test due to blocked glycolysis. Orthostatic hematuria (Option A) causes RBCs in urine after standing, not linked to exercise. Trauma (Option C) can cause hematuria or myoglobinuria, but here no injury is reported. Acid maltase deficiency (Pompe disease) (Option D) presents with infantile cardiomyopathy or late-onset proximal weakness, not exercise-induced myoglobinuria.

References:

Harrison's Principles of Internal Medicine, 22nd Edition, Page 3361.

↑ *Back to this question in Part A*

@Neet_pg_bot

Q13: 35-year-old woman diagnosed with rheumatoid arthritis presents with swelling of the face and legs for 2 weeks. Urine is frothy. On urine microscopy, the following are observed: 3 RBC per HPF Oval fat bodies Maltese crosses under polarized light 4+ proteinuria Which of the following is the most likely diagnosis? (Q851048)

A. Acute glomerulonephritis

B. Minimal change disease

C. Membranous glomerulopathy

D. Membranoproliferative glomerulopathy

Correct Answer: C. Membranous glomerulopathy

Explanation: The presence of frothy urine, 4+ proteinuria, oval fat bodies, and Maltese crosses is diagnostic of a nephrotic syndrome , most classically seen in Membranous glomerulopathy in adults. It is seen in patients with autoimmune diseases like SLE, RA, PBC and dermatitis herpetiformis. Light Microscopy finding: S hows diffuse, uniform thickening of the glomerular basement membrane (GBM). Silver stains (e.g., Jones stain) are crucial, revealing characteristic "spikes" of matrix material protruding between subepithelial immune deposits. Acute glomerulonephritis (Option A) presents with RBC casts and marked hematuria, not heavy proteinuria with fat bodies. Minimal change disease (Option B) is the commonest nephrotic syndrome in children, not adults. Membranoproliferative GN (Option D) shows hematuria, low complement, and tram-track appearance, not classic

lipiduria

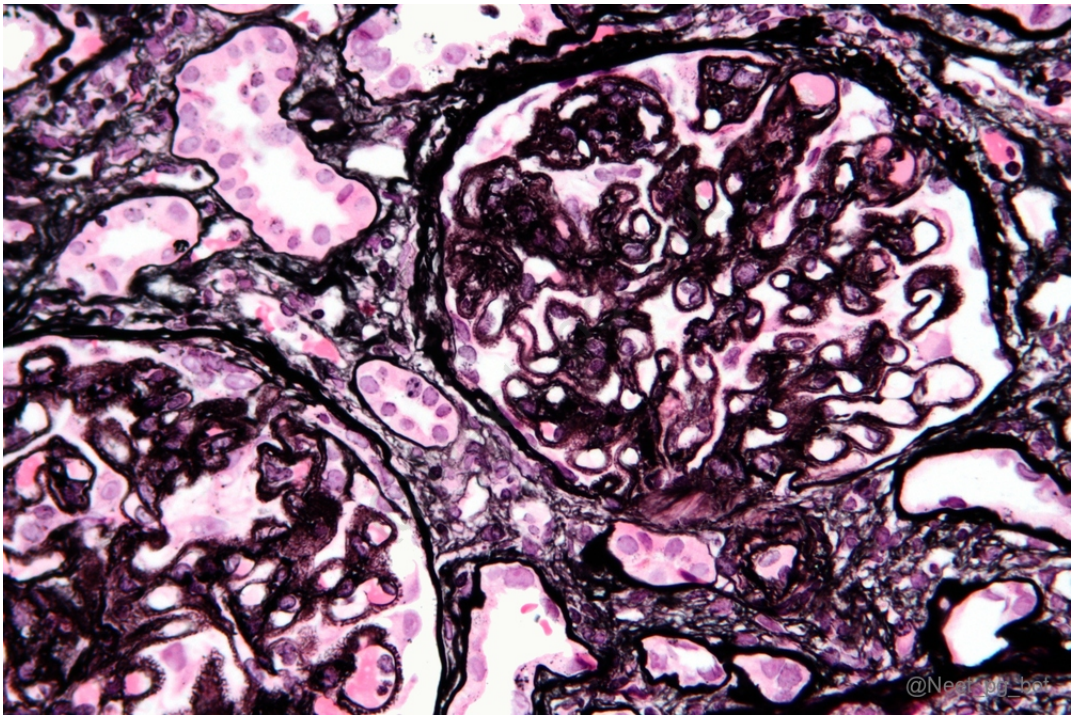

References:

Harrison's Principles of Internal Medicine, 22nd Edition, Page 2423.

↑ *Back to this question in Part A*

@Neet_pg_bot

• [04_Nephrology] 025 Aki Diabetic Nephropathy Renal Stones

« Back to Folder Directory

[04_Nephrology] 025 Aki Diabetic Nephropathy Renal Stones — Quick Jump

Q1 (p. 1819)	*Q2 (p. 1819)*	*Q3 (p. 1821)*	*Q4 (p. 1822)*	*Q5 (p. 1823)*	*Q6 (p. 1823)*
Q7 (p. 1824)	*Q8 (p. 1825)*	*Q9 (p. 1825)*	*Q10 (p. 1826)*	*Q11 (p. 1827)*	*Q12 (p. 1828)*
Q13 (p. 1829)	*Q14 (p. 1830)*	*Q15 (p. 1830)*	*Q16 (p. 1831)*	*Q17 (p. 1832)*	*Q18 (p. 1832)*
Q19 (p. 1833)	*Q20 (p. 1833)*	*Q21 (p. 1834)*	*Q22 (p. 1835)*		

Q1: 65-year-old man with hypertension and diabetes undergoes a coronary angiography. Two days later, his serum creatinine rises from 1.2 mg/dL to 2.0 mg/dL. Urine output is normal. Urinalysis shows muddy brown casts.Which of the following is the most likely diagnosis? (Q851006)

A. Contrast-associated AKI

B. Athero-embolic kidney disease

C. Pre-renal Azotemia

D. Acute glomerulonephritis

Correct Answer: A. Contrast-associated AKI

Explanation: CIN typically presents 24–72 hours after contrast exposure. Risk factors: CKD, diabetes, age >60, dehydration. Lab features: rise in serum creatinine, usually non-oliguric, muddy brown casts in urine (indicative of ATN) Athero-embolic disease usually has systemic embolic signs (blue toes, livedo reticularis, eosinophilia)

References:

Harrison's Principles of Internal Medicine, 22nd Edition, Page 2377.

↑ *Back to this question in Part A*

@Neet_pg_bot

Q2: 5-year-old child with chronic kidney disease presents with bow legs. He has low sunlight exposure. Laboratory investigations reveal: Serum calcium: 7 mg/dL (low) Serum phosphate: 6.3 mg/dL (elevated) Alkaline phosphatase: Elevated Vitamin D3 levels: Low What is the most appropriate next step in management? (Q851016)

A. Phosphate binder

B. Calcium acetate + Vitamin D3

C. Only vitamin D3

D. Haemodialysis

Correct Answer: B. Calcium acetate + Vitamin D3

Explanation: Patients with CKD-MBD (mineral bone disease) will develop secondary hyperparathyroidism. The rise of phosphate concentration is dangerous as it causes calcification of arteries. It should be managed with calcium acetate or calcium carbonate, which is a phosphate binder. Active vitamin D (calcitriol or alfacalcidol) is required because CKD patients cannot activate vitamin D .This can lead to vascular calcification and Calciphylaxis , a limb-threatening condition of small vessel occlusion and skin necrosis." Secondary hyperparathyroidism leads to Renal Osteodystrophy. In addition to the 'bow legs' seen in this child, X-rays may reveal a Rugger Jersey Spine , showing characteristic dense bands at the vertebral endplates." Phosphate binder (Option A): Not enough alone, because the child also has hypocalcemia + low Vit D3. Only Vitamin D3 (Option C): Would correct Vit D3 deficiency, but does not address phosphate overload. In CKD, controlling phosphate is critical. Haemodialysis (Option D): is not indicated just for metabolic bone disease





References:

Harrison's Principles of Internal Medicine, 22nd Edition, Page 2391.

↑ *Back to this question in Part A*

@Neet_pg_bot

Q3: Nephrologist has started empirical hemodialysis in a patient with sepsis whose BUN is 150 mg/dl and progressive decline in renal function. Which of the following is the leading side effect anticipated in this case? (Q851015)

A. Infection

B. Hypotension

C. Cerebral oedema

D. Hyponatremia

Correct Answer: B. Hypotension

Explanation: The major complication of hemodialysis is hypotension, particularly in the critically ill, which can perpetuate AKI It is an intermittent procedure that removes solutes through diffusive and convective clearance. Hemodialysis is done for 3–4 h per day, three to four times per week, and is the most common form of renal replacement therapy for AKI. Empirical HD can be started if BUN is > 100 mg/dl with progressive decline in renal functioning Management of Intradialytic Hypotension (IDH): Since hypotension is the leading side effect in this septic patient, the management focus is on restoring volume and stopping fluid removal Trendelenburg Position: Elevate the feet to improve venous return. Normal Saline Bolus: Administer 100–250 mL of 0.9% NaCl immediately. Decrease Ultrafiltration Rate: Reduce or stop the active removal of fluid. Supplemental Oxygen: Maintain tissue perfusion, especially in septic patients. Midodrine: For chronic prevention, this alpha-1 agonist can be given 30 minutes before dialysis to support blood pressure.

References:

Harrison's Principles of Internal Medicine, 22nd Edition, Page 2384.

↑ *Back to this question in Part A*

@Neet_pg_bot

Q4: All of the following drugs are useful in reducing progression of Diabetic Nephropathy except? (Q851014)

A. ACEi

B. Finrenone

C. Sitagliptin

D. Empagliflozin

Correct Answer: C. Sitagliptin

Explanation: Sitagliptin is a DPP-4 inhibitor that is used for glycaemic control but does not reduce nephropathy progression beyond glucose lowering. ACE inhibitors (ACEi) / ARBs are first-line in diabetic nephropathy; reduce intraglomerular pressure and slow proteinuria progression. Finerenone is a newer non-steroidal mineralocorticoid receptor antagonist (MRA); shown in clinical trials to slow CKD progression in diabetes. SGLT2 inhibitors (e.g., Empagliflozin, Dapagliflozin) tend to reduce intraglomerular hypertension, albuminuria, and CKD progression (CREDENCE, EMPA-KIDNEY trials). They are one of the most significant drugs that have shown survival benefit.

References:

Harrison's Principles of Internal Medicine, 22nd Edition, Page 2423, 2424.

↑ *Back to this question in Part A*

@Neet_pg_bot

Q5: Which of the following are common complications of acute kidney injury ? a. Bleeding b. Anemia c. Pericardial effusion d. Hypomagnesemia (Q851013)

A. a,b

B. b,c

C. a,b,c

D. a,b,c,d

Correct Answer: C. a,b,c

Explanation: Bleeding & Anemia: Uremia in AKI can impair platelet function and suppress bone marrow , leading to a bleeding tendency and anemia . Sepsis or other causes of AKI may also contribute via DIC . Pericardial effusion: Accumulation of uremic toxins can cause inflammation of the pericardium , resulting in pericardial effusion or even uremic pericarditis Hypomagnesemia: AKI typically causes hypermagnesemia due to impaired renal excretion of magnesium.

References:

Harrison's Principles of Internal Medicine, 22nd Edition, Page 2382, 2383.

↑ *Back to this question in Part A*

@Neet_pg_bot

Q6: Kidney injury molecule -1 is a transmembrane protein expressed in (Q851012)

A. PCT

B. DCT

C. Collecting duct

D. Pyramids

Correct Answer: A. PCT

Explanation: KIM-1 is Kidney Injury Molecule-1, a transmembrane protein expressed in proximal tubular cells injured by ischemia or multiple, distinct nephrotoxins, such as cisplatin. Significance is that KIM-1 can be detected after ischemic or nephrotoxic injury in the urine and plasma

References:

Harrison's Principles of Internal Medicine, 22nd Edition, Page 2382.

↑ *Back to this question in Part A*

@Neet_pg_bot

Q7: 25-year-old patient is having recurrent kidney stones. Urine microscopy is shown below. Which of the following drugs will prevent recurrence of these kidney stones. (Q851011)

A. Thiazides

B. Furosemide

C. Tiopronin

D. Mercaptopurine

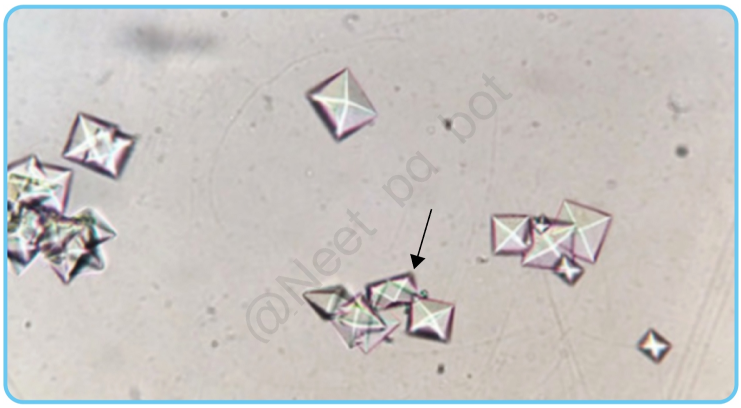

@Neet_pg_bot

Correct Answer: A. Thiazides

Explanation: The image shows envelope / bipyramidal-shaped calcium oxalate dihydrate crystals. To prevent recurrence of these stones, thiazides are used. The leading cause of these calcium oxalate stones is idiopathic hypercalciuria. Thiazides will reduce urinary calcium levels. Envelope / bipyramidal-shaped crystals are seen in

calcium oxalate dihydrate. Dumbbell or oval-shaped crystals are seen in calcium oxalate monohydrate (seen in ethylene glycol poisoning

References:

Harrison's Principles of Internal Medicine, 22nd Edition, Page 2452.

↑ *Back to this question in Part A*

@Neet_pg_bot

Q8: RBC casts are seen in all except? (Q851010)

A. Acute glomerulonephritis

B. Malignant hypertension

C. Thrombotic microangiopathy

D. Mismatched blood transfusion

Correct Answer: D. Mismatched blood transfusion

Explanation: Mismatched blood transfusion causes haemoglobinuria that leads to pigmented casts / renal tubular epithelial casts In renal tubules, haemoglobin precipitates with Tamm–Horsfall protein that forms pigmented (haemoglobin) casts . Tubular epithelial cells also take up Hb and can slough off, appearing as renal tubular epithelial cell casts .

References:

Harrison's Principles of Internal Medicine, 22nd Edition, Page 2380.

↑ *Back to this question in Part A*

@Neet_pg_bot

Q9: The patient is having recurrent kidney stones. Work up shows 24-hour urinary calcium excretion is three times normal and envelope shaped crystals are found in urine. The current stone in the renal pelvis was 1.5 cm and was successfully managed with ESWL. Which of the following dietary advice is best suited for this patient? (Q851009)

A. Restriction of calcium in diet

B. Restriction of sodium in diet

C. Restriction of calories and vitamin D3 in diet

D. Restriction of carbonated energy drinks

Correct Answer: B. Restriction of sodium in diet

Explanation: The patient has calcium oxalate stones (envelope-shaped crystals) and hypercalciuria (24-hr urine calcium three times normal). The most effective dietary intervention is sodium restriction . Why sodium restriction helps: Na■ and Ca²■ are reabsorbed together in the proximal tubule. High sodium intake → ↓ Na■ reabsorption → ↓ Ca²■ reabsorption → ↑ urine calcium (hypercalciuria) Restricting sodium → ↑ proximal Na■ reabsorption → ↑ Ca²■ reabsorption → ↓ urinary calcium This reduces the risk of recurrent calcium oxalate stones .

References:

Harrison's Principles of Internal Medicine, 22nd Edition, Page 2452.

↑ *Back to this question in Part A*

@Neet_pg_bot

Q10: Which of the following is the leading cause of kidney stones whose crystals are shown below? (Q851008)

A. Proteus mirabilis infection

B. Idiopathic hypercalciuria

C. Idiopathic hyperoxaluria

D. Defective transport of basic amino acids



@Neet_pg_bot

Correct Answer: B. Idiopathic hypercalciuria

Explanation: The image shows envelope-shaped crystals that are seen in patients with calcium oxalate stones. The leading cause of calcium oxalate stones is idiopathic hypercalciuria. To prevent recurrence of calcium oxalate stones, thiazide diuretics are used to reduce urinary calcium. Proteus mirabilis infection (Option A) leads to struvite (triple phosphate) stones. Defective transport of basic amino acids (Option D) implies cystinuria/ cystine stones, which have hexagonal crystals.

References:

Harrison's Principles of Internal Medicine, 22nd Edition, Page 2452.

↑ *Back to this question in Part A*

@Neet_pg_bot

Q11: Which of the following is the leading cause of kidney stones whose crystals are shown below? (Q851007)

A. Proteus mirabilis infection

B. Idiopathic hypercalciuria

C. Idiopathic hyperoxaluria

D. Defective transport of basic amino acids

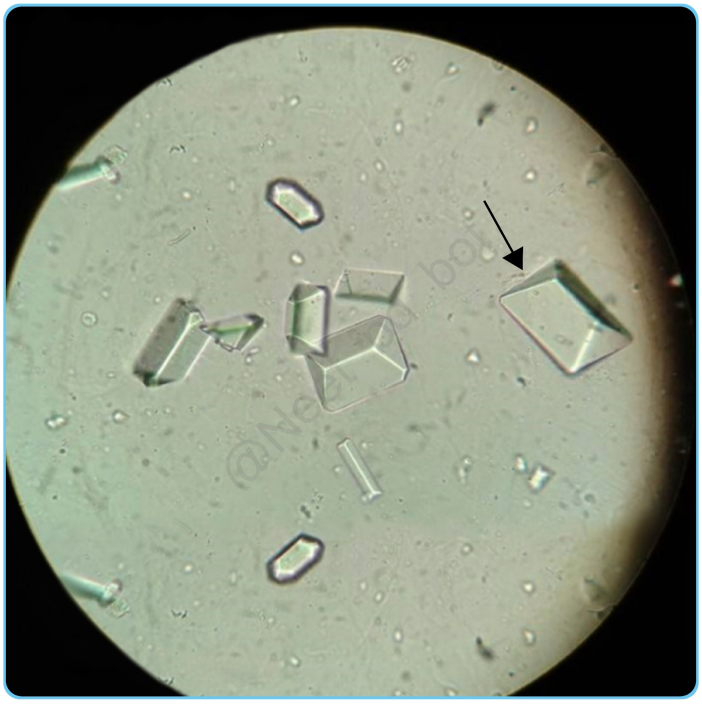

@Neet_pg_bot

Correct Answer: A. Proteus mirabilis infection

Explanation: - Proteus mirabilis infection: Proteus mirabilis is a urease-producing bacterium that alkalinizes urine, promoting struvite stone formation and recurrent urinary tract infections. Patients often present with staghorn calculi and chronic infections. This is the most common infectious cause of kidney stones with recurrent UTI. Incorrect Options: Option B - Idiopathic hypercalciuria: Causes calcium stones due to increased urinary calcium excretion, but is not associated with infection or urease-producing bacteria. Option C - Idiopathic hyperoxaluria: Leads to calcium oxalate stones, usually sterile, and is unrelated to infectious stones caused by Proteus. Option D - Defective transport of basic amino acids: Seen in cystinuria, causing cystine stones, not associated with infection or Proteus-induced struvite stones.

References:

Harrison's Principles of Internal Medicine, 22nd Edition, Page 2453.

↑ *Back to this question in Part A*

@Neet_pg_bot

Q12: A 65-year-old man is admitted with a CURB score of 3 for pneumonia for the past 2 days. His urine output in the last 24 hours is 100 ml and BP is 90/60 mm Hg on

Norepinephrine infusion. p02/FiO2 is 350. Labs are: Serum creatinine: 3.5 mg/dL Urine output: 300 mL/24 hr Urine sodium: 45 mEq/L Urine osmolality: 320 mOsm/kg pH= 7.2, pCO2= 30 mm Hg, HCO3 = 10 meq/ L Which of the following is the correct diagnosis of this patient? (Q850995)

A. Acute interstitial nephritis

B. Acute tubular necrosis

C. Acute respiratory distress syndrome

D. Systemic inflammatory response syndrome

Correct Answer: B. Acute tubular necrosis

Explanation: The patient developed pneumonia followed by septic shock (hypotension with need for vasopressors). This would cause ischemic acute tubular necrosis. High urine sodium > 40 mEq/L and urine osmolality < 350 mOsm/kg indicates ATN. The reason for high urinary sodium is that tubular cells are damaged and cannot reabsorb sodium. ABG shows metabolic acidosis (due to shock) with respiratory acidosis (By winter's formula, expected pCO 2 is 25 mm Hg and actual pCO 2 is 30 mm Hg) Acute interstitial nephritis (Option A): Usually presents with a history of new medication (like NSAIDs or antibiotics), rash, or eosinophilia. The labs here are classic for ischemic/toxic ATN. Acute respiratory distress syndrome (Option C): ARDS will have a PaO 2 /FiO 2 ratio less than 300 with normal left atrium pressure and bilateral infiltrates in CXR. This patient is on the verge of going into ARDS and subsequent MODS. Systemic inflammatory response syndrome (Option D): While the patient meets SIRS criteria (fever, tachycardia, etc., from pneumonia), but SIRS is a clinical state , not a specific renal diagnosis. ATN explains the high creatinine and urine chemistry; SIRS does not.

References:

Harrison's Principles of Internal Medicine, 22nd Edition, Page 2375.

↑ *Back to this question in Part A*

@Neet_pg_bot

Q13: A 4-year-old child weighing 12 kg presents for routine evaluation. His height is 100 cm, and laboratory testing shows a serum creatinine level of 1 mg/dL. Using the updated bedside Schwartz formula (eGFR = 0.41 × height in cm / serum creatinine), what is the estimated GFR of this child? (Q851005)

A. 20 mL/min/1.73 m^2

B. 32 mL/min/1.73 m^2

C. 41 mL/min/1.73 m²

D. 55 mL/min/1.73 m²

Correct Answer: C. 41 mL/min/1.73 m²

Explanation: To estimate renal function in children, the bedside Schwartz formula is the most commonly used method: eGFR=0.41× Height (cm)■ / Serum Creatinine (mg/dL) Schwartz constant (K = 0.413) Given data: Height = 100 cm Serum creatinine = 1 mg/dL eGFR=0.41×100/ 1 ■= 41 mL/min/1.73 m2

References:

https://pmc.ncbi.nlm.nih.gov/articles/PMC6336181/

↑ *Back to this question in Part A*

@Neet_pg_bot

Q14: Non oliguric acute kidney injury is seen with (Q851004)

A. Kanamycin

B. Captopril

C. Telmisartan

D. Cyclosporine

Correct Answer: A. Kanamycin

Explanation: Aminoglycosides accumulate in proximal tubular cells, leading to cellular injury and acute tubular necrosis. But this injury is patchy so urine output is usually maintained. The second reason is decreased responsiveness to vasopressin, leading to impaired concentrating ability and defective sodium reabsorption. Hence, aminoglycoside nephrotoxicity commonly presents as non-oliguric renal failure. Captopril (Option B), Telmisartan (Option C), and Cyclosporine (Option D) result in pre-renal AKI leading to anuria and oliguria

References:

Harrison's Principles of Internal Medicine, 22nd Edition, Page 2377.

↑ *Back to this question in Part A*

@Neet_pg_bot

Q15: A 35 year old man got electrocuted from a high tension cable while flying kites and presents with extensive burns. 12 hours after admission urine output is 100 ml,

urine heme is positive with few RBC and CK is elevated. Diagnosis is? (Q851003)

A. Rhabdomyolysis

B. Pre- renal AKI due to hypoperfusion of kidneys

C. Post renal AKI due to debris occluding ureters

D. Hematuria due to renal injury by electrocution

Correct Answer: A. Rhabdomyolysis

Explanation: Electrical injury causes muscle necrosis and myoglobin release . This causes false positive “heme-positive” urine with few RBCs. CK is markedly elevated due to skeletal muscle injury and release of myoglobin

References:

Harrison's Principles of Internal Medicine, 22nd Edition, Page 2373.

↑ *Back to this question in Part A*

@Neet_pg_bot

Q16: All of the following are causes of pre renal AKI except? (Q851002)

A. NSAIDS

B. ACEI

C. Amphotericin B

D. Cyclosporine

Correct Answer: C. Amphotericin B

Explanation: Amphotericin B binds ergosterol in fungal membranes. Mammalian cells lack ergosterol, but the drug can bind weakly to cholesterol■■■■■■. Amphotericin B causes intrinsic renal injury rather than pre-renal AKI. It produces direct tubular epithelial cell toxicity leading to acute tubular necrosis (ATN). Renal toxicity occurs mainly due to: Direct tubular epithelial cell toxicity Increased membrane permeability Renal vasoconstriction It results in: Acute tubular necrosis (ATN) Distal tubular dysfunction Electrolyte loss (K■, Mg^{2}■) Drug Mechanism of causing Pre-renal AKI NSAIDs (Option A) Inhibit prostaglandins that cause afferent arteriole vasoconstriction and decreased renal perfusion ACE inhibitors (Option B) Dilate the efferent arteriole and decrease the intraglomerular pressure Cyclosporine (Option D) Renal vasoconstriction via endothelin and decreases NO

References:

Harrison's Principles of Internal Medicine, 22nd Edition, Page 2373

↑ *Back to this question in Part A*

@Neet_pg_bot

Q17: Neutrophil Gelatinase-Associated Lipocalin is used as a biomarker for? (Q851001)

A. Immunodeficiency

B. Kidney injury

C. Pancreatic injury

D. Sepsis

Correct Answer: B. Kidney injury

Explanation: Neutrophil Gelatinase-Associated Lipocalin (NGAL) is an early and highly sensitive biomarker of acute kidney injury (AKI) . It rises within 2–4 hours of tubular injury, well before creatinine increases Immunodeficiency (Option A): Common biomarkers/tests include CD4 count, Immunoglobulin levels (IgG, IgA, IgM), DHR test (for CGD) . Pancreatic injury (Option C): Biomarkers used are Serum amylase, Serum lipase , and Trypsinogen activation peptide . Sepsis (Option D): Markers used include Procalcitonin (PCT) , CRP , and blood cultures .

References:

Harrison's Principles of Internal Medicine, 22nd Edition, Page 2382.

↑ *Back to this question in Part A*

@Neet_pg_bot

Q18: Which of the following electrolyte abnormalities is not correct about patient in acute kidney injury due to acute glomerulonephritis? (Q851000)

A. Hyponatremia

B. Normal anion gap metabolic acidosis

C. Hyperkalemia

D. Hyperphosphatemia

Correct Answer: B. Normal anion gap metabolic acidosis

Explanation: AKI in acute glomerulonephritis (intrinsic renal AKI) is associated with: Hyponatremia: Due to salt and water retention. Hyperkalemia: Due to decreased renal potassium excretion. Hyperphosphatemia: Due to impaired phosphate excretion. Metabolic acidosis in intrinsic AKI is typically a high anion gap acidosis (consumption of bicarbonate due to high H+ load that cannot be excreted). If negative charges decrease, the anion gap value will rise.

References:

Harrison's Principles of Internal Medicine, 22nd Edition, Page 2381.

↑ *Back to this question in Part A*

@Neet_pg_bot

Q19: Sodium nitroprusside test on urine is positive in which of the following kidney stones? (Q850999)

A. Calcium oxalate stones

B. Uric acid stones

C. Cystinuria

D. Struvite stones

Correct Answer: C. Cystinuria

Explanation: Sodium nitroprusside test detects cystine, a sulphur-containing amino acid, which is poorly soluble in urine and forms stones. A positive test: Appearance of purple color indicating high urinary cystine, seen in cystinuria.

References:

Harrison's Principles of Internal Medicine, 22nd Edition, Page 2450, 2451.

↑ *Back to this question in Part A*

@Neet_pg_bot

Q20: 72-year-old man with a history of coronary artery disease underwent coronary angiography 2 weeks ago. He now presents with progressive renal dysfunction, livedo reticularis over the lower limbs, and blue-toe lesions. Laboratory investigations show:

Serum creatinine: 3.2 mg/dL (baseline 1.1 mg/dL) Eosinophilia: 12% Urinalysis: mild proteinuria, bland sediment Which of the following is the most likely diagnosis? (Q850998)

A. Acute tubular necrosis

B. Athero-embolic kidney disease

C. Rapidly progressive glomerulonephritis

D. Post-renal obstruction

Correct Answer: B. Athero-embolic kidney disease

Explanation: Athero-embolic kidney disease occurs due to cholesterol emboli that develop after vascular interventions like angiography in patients with atherosclerosis. Clinical clues : blue toes, livedo reticularis, eosinophilia, plus subacute kidney injury. Urine sediment is usually bland (distinguishing from glomerulonephritis). ATN can also occur post-contrast, but ATN usually presents earlier, with muddy brown casts and without systemic embolic signs.

References:

Harrison's Principles of Internal Medicine, 22nd Edition, Page 2379.

↑ *Back to this question in Part A*

@Neet_pg_bot

Q21: 20-year-old patient with T1DM comes for a follow up visit. Which of the following is the earliest finding in diabetic nephropathy? (Q850997)

A. Hyperfiltration

B. Diffuse glomerulosclerosis

C. Kimmel stein Wilson changes

D. Armani ebstein changes

Correct Answer: A. Hyperfiltration

Explanation: Hyperfiltration is the earliest functional change in diabetic nephropathy and may precede any proteinuria. Pathophysiology of hyperfiltration in diabetic nephropathy Chronic hyperglycemia leads to increased filtered glucose . Proximal tubules increase Na■–glucose cotransport, and hence, more Na■ is reabsorbed in the proximal tubule Because more Na■ is reabsorbed proximally, less Na■ reaches the macula densa Macula densa “senses” this as reduced perfusion and triggers afferent arteriolar dilation via adenosine/NO imbalance. Macula

densa also activates the RAAS system, causing efferent arteriole vasoconstriction Afferent arteriolar dilation and efferent arteriole vasoconstriction will increase glomerular pressure, causing hyperfiltration.

References:

Harrison's Principles of Internal Medicine, 22nd Edition, Page 2423.

https://www.ncbi.nlm.nih.gov/books/NBK571718/table/db2021113.T1

↑ *Back to this question in Part A*

@Neet_pg_bot

Q22: A 60-year-old diabetic patient underwent coronary angiography for suspected triple vessel disease. After the procedure he develops oliguria and rising serum creatinine. Labs are Baseline serum creatinine: 1.5 mg/dL Current serum creatinine: 3.0 mg/dL Urine output: 0.35 mL/kg/hr for 18 hours According to KDIGO criteria, what is the stage of acute kidney injury in this patient? (Q850996)

A. Stage 1

B. Stage 2

C. Stage 3

D. Stage 4

Correct Answer: B. Stage 2

Explanation: KDIGO AKI staging Stage Serum Creatinine Urine Output 1 1.5 -1.9 x baseline or ≥ 0.3 mg/dl increase <0.5 mL/kg/hour for 6-12 hours 2 2.0 - 2.9 x baseline <0.5 mL/kg /hour for ≥ 12 hours 3 ≥ 3 x baseline or ≥4 mg/dl increase or initiation of RRT <0.3 mL/kg/hour for ≥24 hours or anuria ≥12 hours

References:

Harrison's Principles of Internal Medicine, 22nd Edition, Page 2372.

↑ *Back to this question in Part A*

@Neet_pg_bot

• [04_Nephrology] 026 Chronic Kidney Disease

« Back to Folder Directory

[04_Nephrology] 026 Chronic Kidney Disease — Quick Jump

Q1 (p. 1836)	*Q2 (p. 1836)*	*Q3 (p. 1838)*	*Q4 (p. 1838)*	*Q5 (p. 1839)*	*Q6 (p. 1839)*
Q7 (p. 1840)	*Q8 (p. 1841)*	*Q9 (p. 1841)*	*Q10 (p. 1842)*	*Q11 (p. 1843)*	*Q12 (p. 1843)*
Q13 (p. 1844)	*Q14 (p. 1844)*	*Q15 (p. 1845)*	*Q16 (p. 1846)*	*Q17 (p. 1846)*	*Q18 (p. 1847)*

Q1: A 60-year-old type 2 Diabetic patient with eGFR of 30 ml/min came with a headache and shortness of breath on climbing stairs fast. BP is 160/100 mmHg. Which of the following combination would not be suitable for this case profile? (Q850988)

A. ACEi with Furosemide

B. ACEi with Amiloride

C. ACEi with Metazolone

D. ACEi with Patiromer

Correct Answer: B. ACEi with Amiloride

Explanation: ACEi can be used in a CKD patient with eGFR <30 mL/min. Concomitant use of kaliuretics like Furosemide and Metazolone makes it possible to continue. However, Amiloride would be potassium-sparing and cause the patient to be exposed to the risk of hyperkalemia. Furosemide (loop diuretic) and Metolazone (thiazide-like diuretic) (Options A and C) are kaliuretic, so they offset ACEi-induced hyperkalemia and are often combined. Patiromer (Option D) is a potassium binder used to manage hyperkalemia in CKD patients on ACEi/ARBs, so this combination is safe.

References:

Harrison's Principles of Internal Medicine, 22nd Edition, Page 2392.

↑ *Back to this question in Part A*

@Neet_pg_bot

Q2: A 46-year-old man, 6 months after kidney transplantation, presents with malaise, rising creatinine, oliguria, and edema. Urine cytology shows renal tubular epithelial cells with large basophilic intranuclear inclusions. Which organism is the most likely

cause? (Q869059)

A. Cytomegalovirus

B. Epstein–Barr virus

C. BK polyomavirus

D. Adenovirus

Correct Answer: C. BK polyomavirus

Explanation: The key diagnostic clue in this patient is urine cytology showing renal tubular epithelial cells with large basophilic intranuclear inclusions , known as decoy cells , which are characteristic of BK polyomavirus infection . BK polyomavirus nephropathy occurs >6 months post-transplant and presents with rising creatinine, oliguria, and hypertension . Cytomegalovirus (Option A): Owl-eye inclusions, can affect multiple organs, not typical in urine cytology. Epstein–Barr virus (Option B): Associated with post-transplant lymphoproliferative disorder , not viral nephropathy. Adenovirus (Option D): Can cause hemorrhagic cystitis or tubulointerstitial nephritis but not the classic “decoy cells” with intranuclear inclusions.

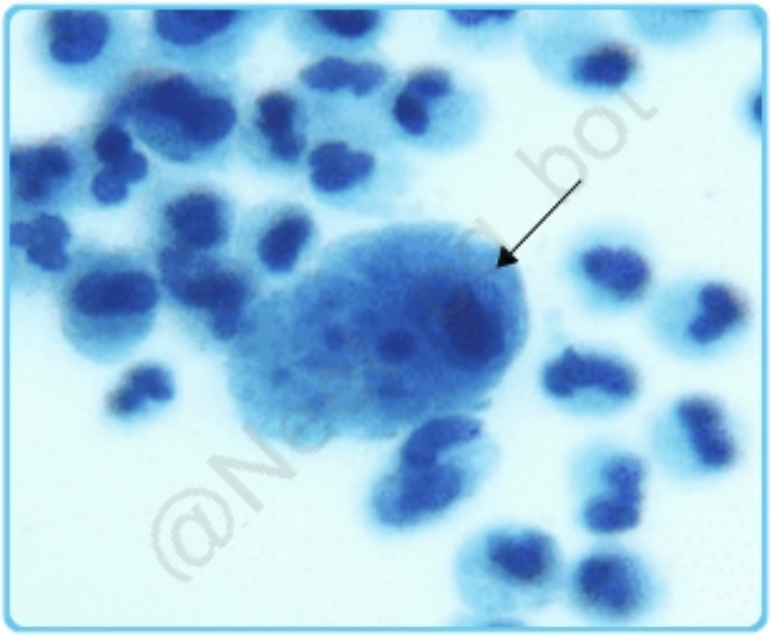

References:

Harrison's Principles of Internal Medicine, 22nd Edition, Page 2410: Harrison 22 nd edition

↑ *Back to this question in Part A*

@Neet_pg_bot

Q3: Which of the following is used for the management of dialysis disequilibrium? (Q869058)

A. Mannitol

B. Dexamethasone

C. 5% dextrose

D. N/2 in 5% dextrose

Correct Answer: A. Mannitol

Explanation: During initial or aggressive haemodialysis in severely uremic patients, BUN drops rapidly in blood, but brain urea equilibrates slowly across the blood–brain barrier. This creates an osmotic gradient that causes water to shift into brain cells, causing cytotoxic cerebral oedema. This responds to Mannitol. Dexamethasone (Option B) is for vasogenic cerebral edema 5% dextrose and N/2 in 5% dextrose (Option C and D) are hypotonic fluids that will worsen the osmotic gradient.

References:

Harrison's Principles of Internal Medicine, 22nd Edition, Page 2400

↑ *Back to this question in Part A*

@Neet_pg_bot

Q4: What is the most common complication of recurrent haemodialysis? (Q850994)

A. Dialysis dysequilibrium

B. Dialysis dementia

C. Peripheral neuropathy

D. Accelerated atherosclerosis

Correct Answer: D. Accelerated atherosclerosis

Explanation: Accelerated atherosclerosis occurs due to chronic inflammation, oxidative stress, dyslipidemia, and vascular calcification. This is the major long-term complication of repeated haemodialysis and the leading cause of mortality. Dialysis disequilibrium syndrome (Option A) occurs mostly during initial dialysis sessions, not

recurrent ones. Dialysis dementia (Option B) was more common in the past (due to aluminum toxicity from dialysate), but it is now rare. Peripheral neuropathy (Option C) is a complication of uremia, and improves with dialysis

References:

Harrison's Principles of Internal Medicine, 22nd Edition, Page 2400.

↑ *Back to this question in Part A*

@Neet_pg_bot

Q5: What is the most common acute complication of haemodialysis? (Q850993)

A. Bleeding

B. Infection

C. Hypotension

D. Myocardial infarction

Correct Answer: C. Hypotension

Explanation: Hypotension is the most common acute complication of hemodialysis. Causes are: Excessive ultrafiltration with inadequate compensatory vascular filling Diastolic and systolic malfunction of heart Impaired autonomic responses due to pre-existing diabetes mellitus Overzealous use of antihypertensive agents The management of hypotension during dialysis consists of discontinuing ultrafiltration, the administration of 100–250 mL of isotonic saline, or administration of salt-poor albumin

References:

Harrison's Principles of Internal Medicine, 22nd Edition, Page 2400.

↑ *Back to this question in Part A*

@Neet_pg_bot

Q6: A 72-year-old patient undergoing hemodialysis suddenly develops symptoms of dizziness, significant leg cramps, and chest pain during the treatment session. Which of the following is the most common acute complication occurring in patients undergoing dialysis? (Q850992)

A. Cardiac arrhythmias

B. Hypotension

C. Anaphylactoid reactions

D. Muscle cramps

Correct Answer: B. Hypotension

Explanation: Hypotension is the most common acute complication during hemodialysis. It often results from rapid fluid shifts and changes in blood volume during the dialysis session. While cardiac arrhythmias (Option A), Anaphylactoid reactions (Option C) and muscle cramps (Option D) are also potential complications, they are less frequently encountered than hypotension.

References:

Harrison's Principles of Internal Medicine, 22nd Edition, Page 2400.

↑ *Back to this question in Part A*

@Neet_pg_bot

Q7: Which of the following will help in differentiating acute kidney injury from chronic kidney disease? (Q850991)

A. Urine albumin

B. Size of kidney

C. Serum creatinine

D. Urine output

Correct Answer: A. Urine albumin

Explanation: Urine albumin is a marker of kidney damage as per the KDIGO definition of CKD, where Grade (progressive decline of eGFR) and Albuminuria are quantified. The size of the kidney can be normal to enlarged in diabetic nephropathy. Serum creatinine and urine output are both affected in AKI and CKD. AKI AKD CKD Duration Within 7 days ≤3 months > 3 months Functional criteria increased in SCr by 50% within 7 days or Oliguria for ≤6 hours AKI Or GFR <60 ml/min/1.73m2 Or Decreased in GFR by ≥35% Or Increase in SCr by>50% GFR <60ml/min/1.73 m2 And/or and/or and/or Structural criteria not defined Marker of kidney damage (albuminuria, hematuria, or pyuria are most common) Marker of kidney damage (albuminuria is most common) Kidney size (Option B) is not reliable: kidneys may be small in advanced CKD, but can be normal/enlarged in conditions like diabetic nephropathy, amyloidosis, or HIV nephropathy. Serum creatinine and urine output (Options C and D) are affected in both AKI and CKD, hence do not distinguish between them.

References:

https://kdigo.org/guidelines/

↑ *Back to this question in Part A*

@Neet_pg_bot

Q8: A 60-year-old man with chronic kidney disease eGFR of 45 ml/min presents with complaints of increasing fatigue and dyspnoea on exertion. On evaluation, he is found to have Hb=7 gm/dl with normocytic normochromic anaemia. What is the next step in management? (Q850990)

A. Oral iron therapy

B. Intravenous iron infusion

C. Blood transfusion

D. Darbepoetin alfa

Correct Answer: A. Oral iron therapy

Explanation: Adequate bone marrow iron stores should be available before treatment with ESA is initiated. Iron supplementation is usually essential to ensure an optimal response to ESA in patients with CKD because the demand for iron by the marrow frequently exceeds the amount of iron that is immediately available for erythropoiesis. Note that if the question said best treatment, then the answer changes to Darbepoetin alfa . IV Iron is used in settings of intolerance of oral iron. Darbepoetin alfa (Option D) is the best long-term treatment but is not started until iron sufficiency is confirmed. IV iron infusion (Option B) is reserved for patients intolerant to oral iron or those on dialysis with high iron requirements. Blood transfusion (Option C) is not first-line due to risks of sensitization and volume overload, and is used only for severe symptomatic anaemia requiring urgent correction.

References:

Harrison's Principles of Internal Medicine, 22nd Edition, Page 2393.

↑ *Back to this question in Part A*

@Neet_pg_bot

Q9: CKD patient with G5A3 status presents with chest pain for 6 hours. Auscultation shows a friction rub. ECG shows PR segment depression with global ST elevation. Which of the following should be done for management of this patient? (Q850989)

A. Call nephrologist for urgent hemodialysis

B. Start IVF with Colchicine/ NSAIDS

C. Arrange for pericardial drainage procedure

D. Start Morphine, oxygen 6L /min and chewable aspirin

Correct Answer: A. Call nephrologist for urgent hemodialysis

Explanation: The findings of friction rub and ECG showing PR segment depression with global ST elevation indicates uremic pericarditis. It has a huge risk of having haemorrhagic transformation and conversion to pericardial tamponade. Hence Dialysis must be instituted urgently. Uremic pericarditis is an absolute indication for hemodialysis Start IVF with Colchicine/ NSAIDS (Option B): Colchicine/NSAIDs are avoided in advanced CKD (toxicity risk). Arrange for pericardial drainage procedure (Option C): Pericardial drainage is done only if tamponade develops. Start Morphine, oxygen 6L /min, and chewable aspirin (Option D): ACS protocol (morphine, aspirin, O■) is not appropriate here.

References:

Harrison's Principles of Internal Medicine, 22nd Edition, Page 2392: Harrison 22 nd edition

↑ *Back to this question in Part A*

@Neet_pg_bot

Q10: In annual medical check up of type 2 DM patient with HbA1c of 10% which of the following tests will identify primary kidney disease? (Q850964)

A. UACR >2.5 mg/mmol on two occasions

B. Urine dipstick for protein 2+ on two occasions

C. Serum creatinine rise by 1.5-1.9 times over 48 hours

D. Urine output < 0.5 ml/kg/ hour for 24 hours

Correct Answer: A. UACR >2.5 mg/mmol on two occasions

Explanation: Urine Albumin-to-Creatinine Ratio is the recommended screening test for detecting primary kidney disease in diabetes mellitus. Values >2.5 mg/mmol in men and >3.5 mg/mmol in women confirmed on 2 of 3 samples over 3–6 months is the correct method for detecting early DKD in annual check-up.

References:

Harrison's Principles of Internal Medicine, 22nd Edition, Page 2387.

↑ *Back to this question in Part A*

@Neet_pg_bot

Q11: A CKD patient is determined to have adynamic bone disease. Which of the following is the best explanation for this presentation? (Q850987)

A. Excessive use of vitamin D preparations and phosphate binders

B. Less use of vitamin D preparations and phosphate binders

C. High levels of FGF-23

D. Low levels of FGF-23

Correct Answer: A. Excessive use of vitamin D preparations and phosphate binders

Explanation: Adynamic bone disease (ABD) is a form of renal osteodystrophy characterized by: Low bone turnover Suppressed osteoblast and osteoclast activity Causes: Over-suppression of parathyroid hormone (PTH) : Excessive vitamin D analogues → suppress PTH Overuse of calcium-containing phosphate binders → increase calcium load → suppress PTH Pathophysiology: Low PTH → ost eoblast and osteoclast inactivity → bones are "adynamic" Less use of vitamin D preparations and phosphate binders (Option B): may cause high-turnover bone disease (osteitis fibrosa) , not ABD High or low FGF-23(Option C & D): Mainly regulates phosphate and vitamin D metabolism; not a primary cause of ABD

References:

Harrison's Principles of Internal Medicine, 22nd Edition, Page 2390.

↑ *Back to this question in Part A*

@Neet_pg_bot

Q12: Cardiovascular disease is the leading cause of morbidity and mortality in patients at every stage of CKD. Which of the following correlates best with this morbidity and mortality pattern? (Q850986)

A. Elevated Phosphate levels

B. Elevated Calcium levels

C. Elevated H+ levels

D. Increased Total body water

Correct Answer: A. Elevated Phosphate levels

Explanation: There is a strong association between hyperphosphatemia and increased cardiovascular mortality in patients with CKD. Phosphate chelates with calcium and causes hardening of all blood vessels including coronary arteries.

References:

Harrison's Principles of Internal Medicine, 22nd Edition, Page 2390

↑ *Back to this question in Part A*

@Neet_pg_bot

Q13: Which of the following is calcimimetic agent that enhances the sensitivity of parathyroid cells to the suppressive effect of calcium? (Q850985)

A. Etelcalcetide

B. Teriparatide

C. Sodium Zirconate cyclosilicate

D. Lanthanum

Correct Answer: A. Etelcalcetide

Explanation: Calcimimetic agents that enhance the sensitivity of parathyroid cells to the suppressive effect of calcium are Etelcalcetide and cincalcet. Teriparatide (Option B) is a PTH analogue. Sodium Zirconate cyclosilicate (Option C) is potassium binder. Lanthanum (Option D) is phosphate binder.

References:

Harrison's Principles of Internal Medicine, 22nd Edition, Page 2391.

↑ *Back to this question in Part A*

@Neet_pg_bot

Q14: CKD patient presents with sudden onset chest pain and sweating. Which of the following is best practice for further management of this patient? (Q850984)

A. Troponin I

B. Serial Troponin I

C. Serial Troponin I + ECG

D. Troponin I + ECG

Correct Answer: C. Serial Troponin I + ECG

Explanation: In CKD patients, baseline troponin may be chronically elevated , so a single troponin is not reliable. The best practice is serial Troponin I measurements plus ECG to detect dynamic changes indicating acute MI. This combination provides the highest diagnostic accuracy. Troponin I (Option A): Single value may be misleading due to chronic elevation in CKD. Serial Troponin I (Option B): Better than single but still incomplete without ECG changes. Troponin I + ECG (Option D): Lacks serial measurements needed to confirm acute rise/fall.

References:

Harrison's Principles of Internal Medicine, 22nd Edition, Page 2391, Harrison 22 nd edition

↑ *Back to this question in Part A*

@Neet_pg_bot

Q15: A 45-year-old patient with chronic kidney disease is being evaluated for kidney transplantation. Doppler shows iliac artery calcification. Laboratory investigations reveal: Serum calcium: 8 mg/dL Serum phosphate: 6.5 mg/dL Alkaline phosphatase: Elevated Vitamin D3: Low What is the most appropriate next step in management? (Q850968)

A. Sevelamer

B. Sevelamer + Calcitriol

C. Calcium supplementation + Calcitriol

D. Haemodialysis

Correct Answer: B. Sevelamer + Calcitriol

Explanation: The patient has CKD-MBD (chronic kidney disease–mineral bone disorder) with secondary hyperparathyroidism , indicated by high phosphate, low calcium, low vitamin D3, and elevated alkaline phosphatase . Iliac artery calcification indicates vascular involvement; thus, calcium-containing phosphate binders should be avoided to prevent worsening calcification. Sevelamer is a non-calcium phosphate binder that lowers phosphate without increasing calcium load. Calcitriol (active vitamin D3) suppresses PTH secretion directly and by raising ionized calcium. Sevelamer alone (Option A) While Sevelamer lowers phosphate, it does not suppress PTH . The patient has secondary hyperparathyroidism , so calcitriol is also needed . Calcium supplementation + Calcitriol (Option B) Calcium-based therapy can worsen vascular calcification , especially in a patient who already has iliac artery calcification . Hemodialysis (Option D) Removes phosphate but does not control secondary hyperparathyroidism or calcification .

References:

Harrison's Principles of Internal Medicine, 22nd Edition, Page 2391.

↑ *Back to this question in Part A*

@Neet_pg_bot

Q16: A 45-year-old diabetic patient with an HbA 1 c of 12% is calculated by MDRD formula to have e-GFR of 50 ml/min/m 2 . Which is not correct about this patient? (Q850967)

A. Less ammonium ion production

B. Increased urinary chloride

C. Associated with severe protein catabolism

D. Start oral bicarbonate supplementation in grade 3 CKD

Correct Answer: B. Increased urinary chloride

Explanation: In CKD, ammonium /NH 4 ■ excretion falls, and since ammonium is excreted with chloride, urinary chloride falls. This leads to Hyperchloremic metabolic acidosis with hyperkalaemia. Logically, increased protein catabolism should lead to increased ammonia production. The proximal tubule converts glutamine → ammonium (NH4■) + bicarbonate. In CKD, due to reduced nephron mass, renal ammoniagenesis decreases , even if substrate (glutamine) availability increases . Supplementation of soda bicarbonate in grade 3-5 CKD reduces protein catabolism (Option D)

References:

Harrison's Principles of Internal Medicine, 22nd Edition, Page 2389.

↑ *Back to this question in Part A*

@Neet_pg_bot

Q17: Which of the following is the leading cause of chronic kidney disease? (Q850966)

A. Chronic Glomerulonephritis

B. Autosomal dominant polycystic kidney disease

C. Diabetes insipidus

D. Hypertension

Correct Answer: A. Chronic Glomerulonephritis

Explanation: Leading cause is diabetic nephropathy followed by chronic glomerulonephritis. This is followed by hypertension associated CKD and include vascular and parenchymal causes. Leading Categories of Etiologies of Chronic Kidney Disease Diabetic nephropathy Glomerulonephritis Hypertension-associated CKD (includes vascular and ischemic kidney disease and primary glomerular disease with associated hypertension) (Option D) Autosomal dominant polycystic kidney disease (Option B) Other cystic and tubulointerstitial nephropathy Diabetes insipidus (Option C): Causes polyuria but does not lead to CKD .

References:

Harrison's Principles of Internal Medicine, 22nd Edition, Page 2389.

↑ *Back to this question in Part A*

@Neet_pg_bot

Q18: A 38-year-old man with type 2 diabetes mellitus for the last 3 years undergoes an annual renal evaluation. His serum creatinine is 0.9mg/dL. Urine albumin excretion is 2 mg/mmol on multiple occasions. Which of the following represents the earliest renal abnormality in diabetic nephropathy? (Q850965)

A. Microalbuminuria (30–300 mg/day)

B. Decline in GFR <60 mL/min/1.73 m²

C. Glomerular hyperfiltration

D. Armani Ebstein changes in proximal convoluted tubule

Correct Answer: C. Glomerular hyperfiltration

Explanation: Progressive stages of renal damage in Diabetic nephropathy Hyperfiltration Microalbuminuria (in the Q the given value is less than threshold of 3.5 mg / mmol in males) (Option A) Macroalbuminuria Decline in GFR and renal failure/ ESRD (Option B)

References:

Harrison's Principles of Internal Medicine, 22nd Edition, Page 2423, 2424.

↑ *Back to this question in Part A*

@Neet_pg_bot

• [04_Nephrology] 027 Renal Tubular Acidosis And Renal Artery Stenosis

« Back to Folder Directory

[04_Nephrology] 027 Renal Tubular Acidosis And Renal Artery Stenosis — Quick Jump

Q1 (p. 1848) *Q2 (p. 1848)* *Q3 (p. 1849)* *Q4 (p. 1850)* *Q5 (p. 1850)* *Q6 (p. 1852)*

Q7 (p. 1853) *Q8 (p. 1854)* *Q9 (p. 1854)* *Q10 (p. 1855)* *Q11 (p. 1856)* *Q12 (p. 1856)*

Q1: Which of the following is most likely based on the lab values given? Blood pH: 7.32 Na + : 130mEq/L K + : 2.8 mEq/L Cl - : 110 mEq/L HCO 3 : 12 mEq/L Urea: 25 mg/dL Creatinine: 0.6 mg/dL Urinary pH: 9.4 (Q850782)

A. RTA 1

B. RTA 2

C. RTA 3

D. RTA 4

Correct Answer: A. RTA 1

Explanation: The patient has normal kidney function (normal urea, creatinine) but shows: Metabolic acidosis: pH 7.32, HCO■■ 12 Hypokalemia: K■ 2.8 Hyperchloremia: Cl■ 110 (→ non–anion gap metabolic acidosis) Very alkaline urine: pH 9.4 This combination is classic for Distal (Type 1) RTA , where the distal tubule cannot secrete H■ , so the urine stays inappropriately alkaline (>5.5) even when the blood is acidotic. RTA 2 (Proximal RTA)(Option B) is associated with glycosuria , aminoaciduria, phosphaturia, and hypokalemia. Urine pH depends on the serum bicarbonate level; when serum bicarbonate is low, urine pH is less than 5.5, and vice versa. RTA 3(Option C): Rare mixed RTA ; not applicable based on labs. RTA 4(Option D): Causes hyperkalemia , not hypokalemia.

References:

CMDT 2023, Page 897

↑ *Back to this question in Part A*

@Neet_pg_bot

Q2: 60-year-old smoker presents with difficult to control hypertension and is on Ramipril, amlodipine and thiazides. Duplex imaging shows increased flow velocity in bilateral renal artery. Which of the following is the leading cause of this presentation? (Q850789)

A. Fibromuscular dysplasia

B. Atherosclerosis

C. Takayasu arteritis

D. TTP

Correct Answer: B. Atherosclerosis

Explanation: Atherosclerosis is the most common cause overall, especially in older men with smoking, diabetes, hypertension, and dyslipidemia. Usually proximal renal artery. Fibromuscular dysplasia (Option A) is common in younger women (<40 yrs), “string-of-beads” on angiography, typically distal artery. Takayasu arteritis (Option C) causes large vessel vasculitis in young Asian women. Thrombotic thrombocytopenic purpura (Option D) causes microangiopathy, not renal artery stenosis.

References:

Harrison's Principles of Internal Medicine, 22nd Edition, Page 2150

↑ *Back to this question in Part A*

@Neet_pg_bot

Q3: 65-year-old man with hypertension presents with sudden onset breathlessness. He is found to have bilateral crackles, pink frothy sputum, and hypoxemia requiring non-invasive ventilation. His BP is persistently high despite ramipril, amlodipine and hydrochlorothiazide for past 6 months. Echo shows preserved LV ejection fraction. Duplex Doppler of renal arteries demonstrates markedly increased flow velocity bilaterally. Likely cause of this presentation is? (Q850792)

A. Thrombo-embolic disease of kidney

B. Atherosclerosis

C. Athero-embolic kidney disease

D. Fibromuscular dysplasia

Correct Answer: B. Atherosclerosis

Explanation: The clinical presentation is of flash pulmonary edema in a patient with resistant hypertension despite triple therapy. This is seen in high-renin hypertension caused by renal artery stenosis resulting from atherosclerotic narrowing of the arteries. This presentation is also called Pickering syndrome. Thrombo-embolic disease of the kidney (Option A) is seen with atrial fibrillation. Athero-embolic kidney disease (Option C) is seen with procedures like angiography. It causes blue toe, livedo reticularis and eosinophilia. Fibromuscular dysplasia (Option D) is seen in young females and has string of beads appearance.

References:

Harrison's Principles of Internal Medicine, 22nd Edition, Page 2018.

↑ *Back to this question in Part A*

@Neet_pg_bot

Q4: Renal tubular acidosis that presents with hyperkalemia is? (Q850794)

A. RTA 1

B. RTA 2

C. RTA 3

D. RTA 4

Correct Answer: D. RTA 4

Explanation: RTA 4 occurs secondary to diabetic nephropathy, obstructive uropathy, or chronic tubulointerstitial disease and leads to hypo-reninemic hypoaldosteronism due to damage to Distal tubule. Less aldosterone explains impaired potassium excretion and resultant hyperkalemia.

References:

Harrison's Principles of Internal Medicine, 22nd Edition, Page 372

↑ *Back to this question in Part A*

@Neet_pg_bot

Q5: 25-year-old young female is diagnosed with hypertension. Work up shows renal artery stenosis and renal angiogram image is shown. Diagnosis is: (Q850812)

A. Polyarteritis nodosa

B. Microscopic polyangiitis

C. Fibromuscular dysplasia

D. Takayasu arteritis



@Neet_pg_bot

Correct Answer: C. Fibromuscular dysplasia

Explanation: The image shows a string of beads appearance on a renal angiogram is diagnostic of Fibromuscular dysplasia . The "String of Beads" Appearance: Shows a series of concentric stenoses alternating with small aneurysmal dilatations. This classic pattern is caused by the overgrowth of smooth muscle and fibrous tissue in the arterial wall (specifically the tunica media in the most common "medial fibroplasia" type). Demographic: FMD is a non-inflammatory, non-atherosclerotic vascular disease that primarily affects young females . Clinical Presentation: It most commonly affects the renal arteries , leading to renovascular hypertension, and the carotid/vertebral arteries . Polyarteritis nodosa (Option A) is a medium vessel vasculitis involving smaller segmental branches of the renal artery, causing multiple microaneurysms, infarcts and systemic symptoms. Microscopic polyangiitis (Option B) has small vessel vasculitis, glomerulonephritis and pulmonary hemorrhage Takayasu arteritis (Option D) is an example of large vessel vasculitis in young women, but causes ostial narrowing and does not cause beaded appearance.

References:

Harrison's Principles of Internal Medicine, 22nd Edition, Page 2139.

↑ *Back to this question in Part A*

@Neet_pg_bot

Q6: Which is not correct about RTA 1? (Q850813)

A. Hypokalemia

B. Hypercalciuria

C. Positive Urinary anion gap

D. High urinary NH 4 +

Correct Answer: D. High urinary NH 4 +

Explanation: Distal RTA has a defect of acidification of urine due to defects in alpha intercalated cells, leading to low urinary NH 4 + . The Urine Anion Gap (UAG) Formula: UAG is a surrogate marker used to estimate the amount of Ammonium (NH 4+) in the urine. UAG = (Na + + K +) - Cl - Since NH■■ is the main unmeasured cation; high NH■■ makes UAG negative, while low NH■■ makes it positive. Positive vs Negative Urine Anion Gap: UAG Sign Interpretation NH■■ Level Common Causes Negative (-20 to -50 mEq/L) Appropriate renal response to acidosis High Diarrhea, GI HCO■■ loss Positive (>0 mEq/L) Impaired renal acidification Low Type 1 RTA, type 4 RTA Impaired H+ excretion leads to excess potassium loss in urine to maintain electroneutrality and causes hypokalemia (Option A) Chronic metabolic acidosis in distal RTA causes bone buffering of H■ ions and release of calcium and phosphate from bone. At the same time, acidosis reduces calcium reabsorption in the tubules more calcium in urine- hypercalciuria (Option B) In distal RTA, NH4■ excretion is impaired, so urinary chloride is low and mathematically, UAG remains positive (Option C).

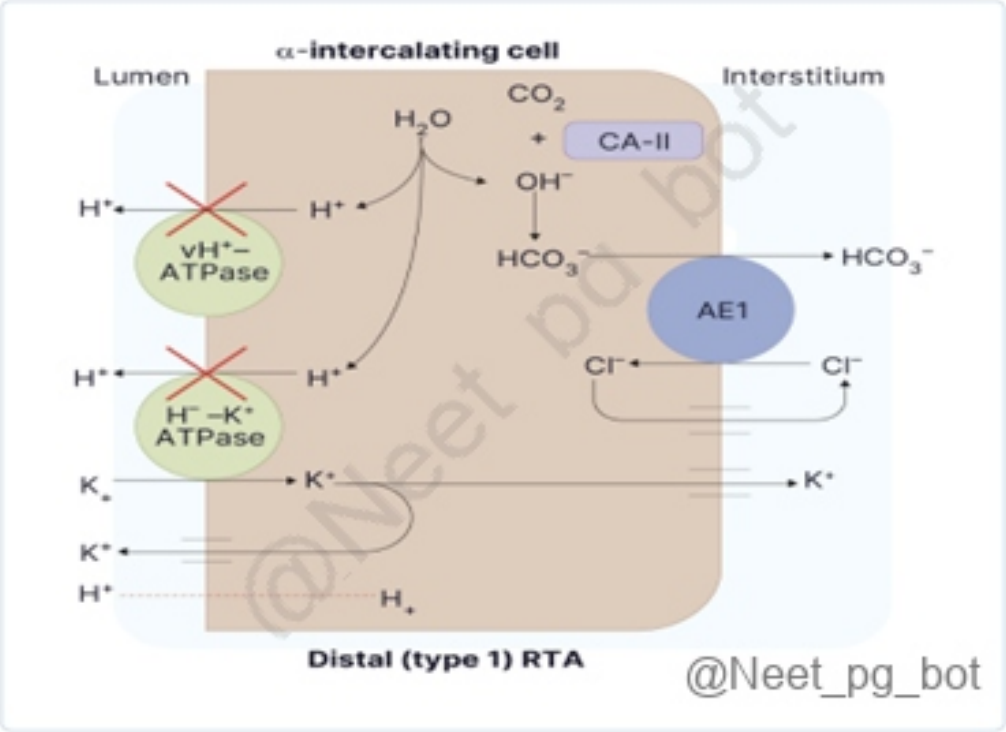

References:

Harrison's Principles of Internal Medicine, 22nd Edition, Page 372

↑ *Back to this question in Part A*

@Neet_pg_bot

Q7: Which type of Renal tubular acidosis is related to Fanconi syndrome? (Q850814)

A. RTA 1

B. RTA 2

C. RTA 3

D. RTA 4

Correct Answer: B. RTA 2

Explanation: Type 2 RTA is due to proximal tubular dysfunction manifested by glycosuria, generalized aminoaciduria, and phosphaturia. This is called Fanconi syndrome. It should not be mixed with Fanconi anemia which is congenital aplastic anemia.

References:

Harrison's Principles of Internal Medicine, 22nd Edition, Page 372

↑ *Back to this question in Part A*

@Neet_pg_bot

Q8: Which of the following drugs most commonly causes Type 2 (proximal) renal tubular acidosis? (Q850816)

A. Acetazolamide

B. Furosemide

C. Amiloride

D. Spironolactone

Correct Answer: A. Acetazolamide

Explanation: Type 2 RTA (proximal RTA) occurs due to reduced bicarbonate reabsorption in the proximal tubule. Acetazolamide , a carbonic anhydrase inhibitor , directly blocks bicarbonate reabsorption → bicarbonate loss in urine → metabolic acidosis . This mechanism closely mimics the pathophysiology of proximal RTA, making it the most common drug-induced cause Furosemide (Option B): causes metabolic alkalosis , not acidosis. Amiloride and spironolactone (Option C and D): affect distal nephron can cause (Type 4 RTA, hyperkalemic), not Type 2.

References:

Harrison's Principles of Internal Medicine, 22nd Edition, Page 372:

↑ *Back to this question in Part A*

@Neet_pg_bot

Q9: A 28-year-old woman presents with recurrent renal stones and bone pain. Investigations reveal: Serum potassium: 3.1 mEq/L Serum bicarbonate: 16 mEq/L Urine pH: 6.5 (not decreasing below 5.5 even after acid load) Positive urinary anion gap Which of the following is the most likely diagnosis? (Q850817)

A. Proximal RTA (Type 2)

B. Distal RTA (Type 1)

C. Hyperkalemic RTA (Type 4)

D. Carbonic anhydrase inhibitor–induced RTA

Correct Answer: B. Distal RTA (Type 1)

Explanation: Distal RTA is characterized by the inability to acidify urine (urine pH > 5.5) , hypokalemia, nephrolithiasis, and a positive urinary anion gap. Type 2 (proximal) (Option A) RTA has variable urine pH, no stones, and bicarbonaturia. Type 4 RTA (Option C) is associated with hyperkalemia , not hypokalemia. Carbonic anhydrase inhibitors (Option D) like acetazolamide cause proximal (Type 2) RTA.

References:

Harrison's Principles of Internal Medicine, 22nd Edition, Page 372

↑ *Back to this question in Part A*

@Neet_pg_bot

Q10: A 35-year-old woman with recurrent episodes of weakness and bone pain has xerostomia and Schirmer test of filter paper wetting of < 5 mm at 5 minutes. Laboratory results show: Serum potassium: 2.8 mEq/L Serum bicarbonate: 15 mEq/L Urine pH: 6.7 (does not fall below 5.5 on ammonium chloride loading) Positive urinary anion gap ANA and anti-SSA antibodies: positive Which of the following best explains her presentation? (Q850818)

A. Distal RTA due to autoimmune interstitial nephritis in Sjögren syndrome

B. Distal RTA due to autoimmune interstitial nephritis in Scleroderma

C. Distal RTA due to autoimmune interstitial nephritis in lupus nephritis

D. Distal RTA due to autoimmune interstitial nephritis in mixed connective tissue disorder

Correct Answer: A. Distal RTA due to autoimmune interstitial nephritis in Sjögren syndrome

Explanation: Patient is having positive UAG with hypokalemic metabolic acidosis due to RTA type 1. The presence of xerostomia, Schirmer test <5 mm (severe dry eye), and anti-SSA antibodies strongly support Sjögren syndrome.

References:

Harrison's Principles of Internal Medicine, 22nd Edition, Page 372, 2877

↑ *Back to this question in Part A*

@Neet_pg_bot

Q11: 10-year-old boy is evaluated for growth retardation and polyuria. Investigations reveal: Serum bicarbonate: 14 mEq/L Serum potassium: 3.2 mEq/L Urine pH: 4.8 after ammonium chloride loading Fractional excretion of bicarbonate: 20% No nephrolithiasis or nephrocalcinosis Aminoaciduria and glucosuria are also present Which of the following is the most likely diagnosis? (Q850820)

A. Distal RTA (Type 1)

B. Proximal RTA (Type 2) due to Fanconi syndrome

C. Hyperkalemic RTA (Type 4)

D. Distal RTA associated with Sjögren syndrome

Correct Answer: B. Proximal RTA (Type 2) due to Fanconi syndrome

Explanation: RTA type 2: Hypokalemia with low serum HCO■■. Urine pH <5.5 after acid load (distinguishes from Type 1). High fractional excretion of bicarbonate (>15%) after loading. Associated with Fanconi syndrome → glucosuria, aminoaciduria, phosphaturia.

References:

Harrison's Principles of Internal Medicine, 22nd Edition, Page 372

↑ *Back to this question in Part A*

@Neet_pg_bot

Q12: 55-year-old man with long-standing diabetes mellitus presents with weakness. His medications include lisinopril and spironolactone. Investigations show: Serum bicarbonate: 18 mEq/L Serum potassium: 5.9 mEq/L Serum sodium: 132 mEq/L Urine pH: 5.2 Transtubular potassium gradient (TTKG): 3 (low) Which of the following best explains his presentation? (Q850821)

A. Distal RTA due to impaired H■ secretion in α-intercalated cells

B. Proximal RTA due to defective bicarbonate reabsorption

C. Hyperkalemic RTA due to hypoaldosteronism/aldosterone resistance

D. Distal RTA due to excess glycogen deposition in distal tubule

Correct Answer: C. Hyperkalemic RTA due to hypoaldosteronism/aldosterone resistance

Explanation: Type 4 RTA: Features: Mild metabolic acidosis (HCO■■ usually >17 mEq/L). Hyperkalemia (key differentiator from RTA 1,2) Urine pH <5.5 (patients can still acidify urine, unlike Type 1). Low TTKG indicates reduced aldosterone effect on distal nephron. Causes: Diabetic nephropathy (hyporeninemic hypoaldosteronism). Drugs: ACE inhibitors, ARBs, K-sparing diuretics, heparin, trimethoprim. Addison’s disease

References:

Harrison's Principles of Internal Medicine, 22nd Edition, Page 372

↑ *Back to this question in Part A*

@Neet_pg_bot

• [04_Nephrology] 028 Nephrotic And Nephritic Syndromes

« Back to Folder Directory

[04_Nephrology] 028 Nephrotic And Nephritic Syndromes — Quick Jump

Q1 (p. 1858) *Q2 (p. 1861)* *Q3 (p. 1862)* *Q4 (p. 1865)* *Q5 (p. 1865)* *Q6 (p. 1866)*
Q7 (p. 1867) *Q8 (p. 1867)* *Q9 (p. 1868)* *Q10 (p. 1869)* *Q11 (p. 1869)* *Q12 (p. 1870)*
Q13 (p. 1871) *Q14 (p. 1872)* *Q15 (p. 1873)*

Q1: A 32-year-old man presents with generalized edema and frothy urine. Laboratory evaluation reveals 24-hour urine protein of 8 g/day, serum albumin of 2.2 g/dL, serum cholesterol of 310 mg/dL, and serum creatinine of 1.3 mg/dL. A kidney biopsy is performed and light microscopy is shown below. Which of the following is the most likely diagnosis? (Q850823)

A. Minimal change disease

B. Focal segmental glomerulosclerosis

C. Membranous nephropathy

D. Amyloidosis

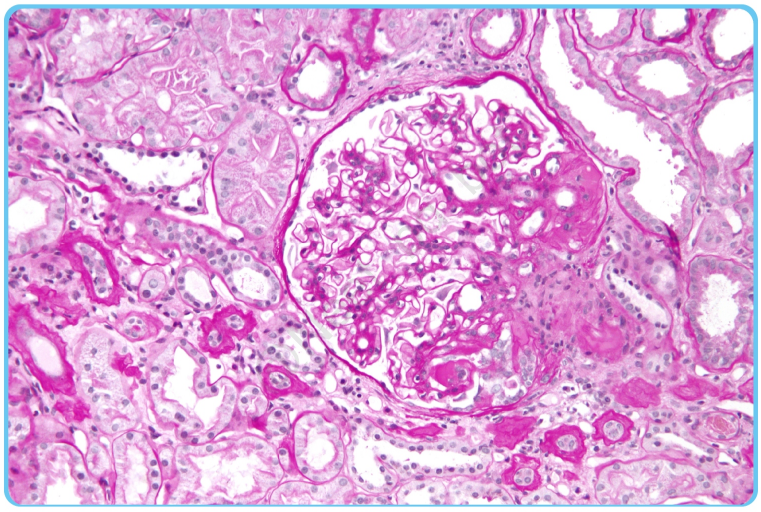

@Neet_pg_bot

Correct Answer: B. Focal segmental glomerulosclerosis

Explanation: The patient presents with classic nephrotic syndrome : massive proteinuria (8 g/day), hypoalbuminemia (2.2 g/dL), hyperlipidemia (310 mg/dL), and generalized edema. Light microscopy shows focal, segmental glomerular sclerosis and hyalinosis , which is characteristic of FSGS. Electron microscopy reveals patchy foot process effacement , distinguishing it from Minimal Change Disease (which shows diffuse effacement). Typical patient profile: Young adult, often with primary FSGS or secondary causes such as obesity, HIV infection, or drug exposure. Key point: FSGS often has a poorer response to steroids compared to Minimal Change Disease. Minimal Change Disease (Option A): Light microscopy shows normal glomeruli , not sclerosis. Electron microscopy reveals diffuse foot process effacement , unlike the patchy effacement seen in this patient. More common in children and usually steroid-responsive . Membranous Nephropathy (Option C): Light microscopy shows diffuse thickening of the glomerular basement membrane with spikes . Electron microscopy demonstrates subepithelial immune deposits (“spike and dome” appearance) . Typically occurs in older adults (40–60 years) . Renal Amyloidosis (Option D): Light microscopy reveals amorphous mesangial and capillary deposits . Electron microscopy shows non-branching fibrils (8–10 nm) . Usually associated with older age or chronic inflammatory disease . Findings are inconsistent with patchy sclerosis or the patient’s age.

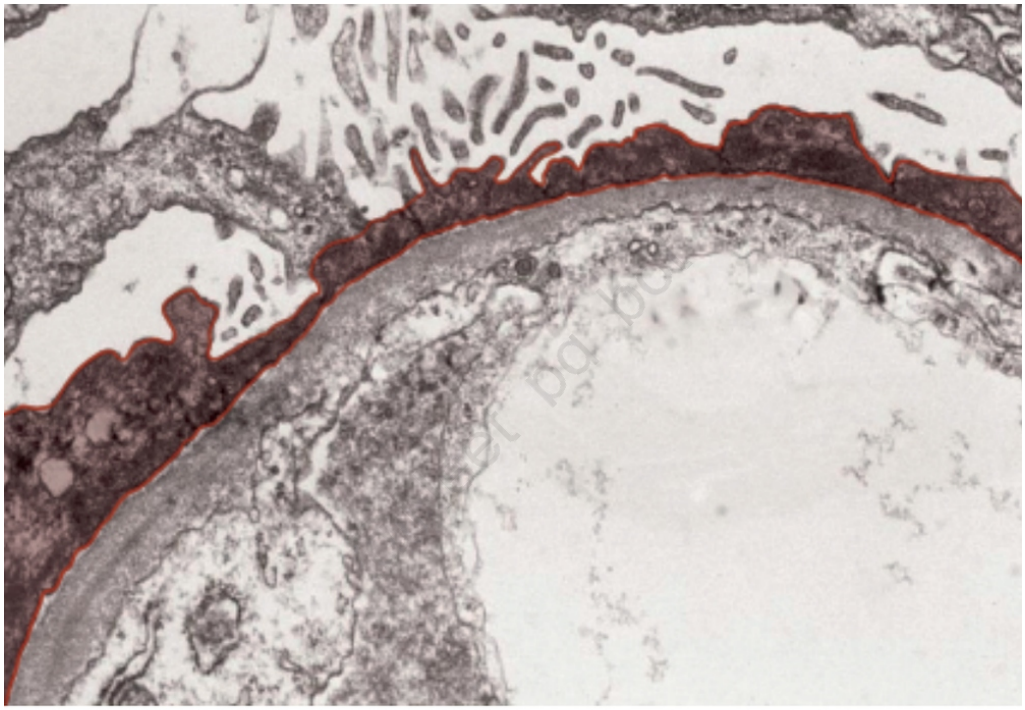

Diffuse loss of foot processes @Neet_pg_bot

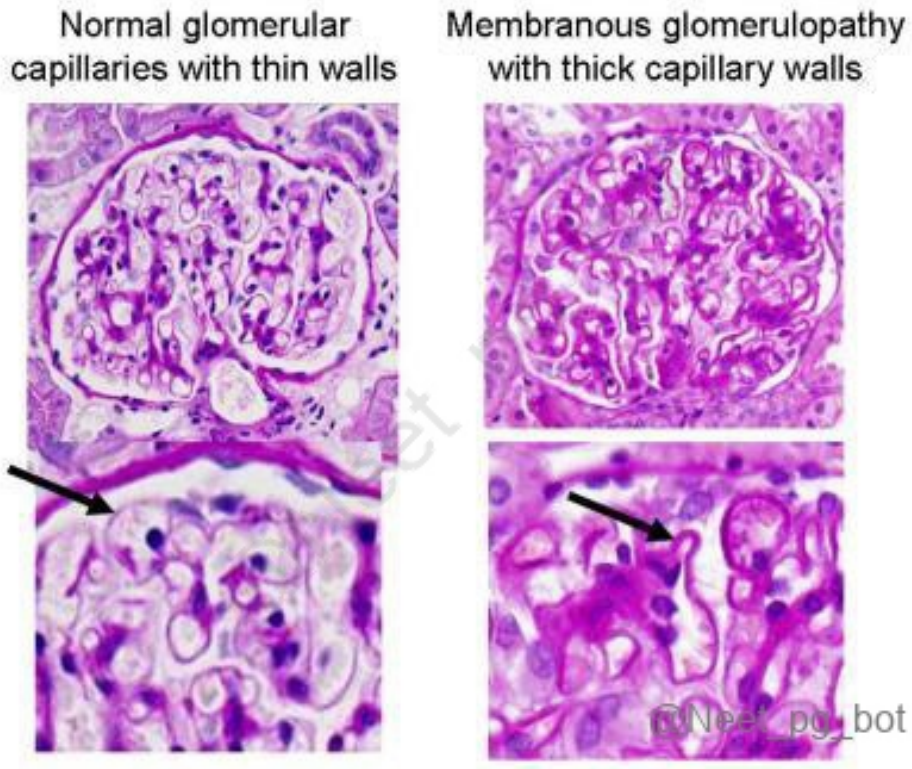

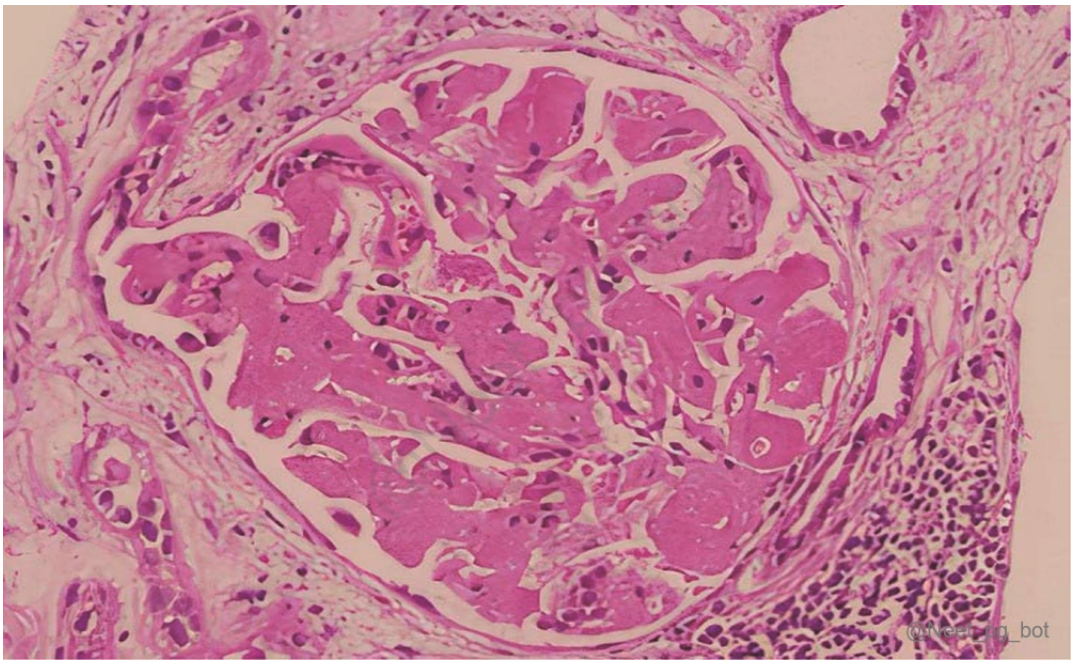

References:

Harrison's Principles of Internal Medicine, 22nd Edition, Page 2422

↑ *Back to this question in Part A*

@Neet_pg_bot

Q2: A 4-year-old child presents with swelling all over the body. Workup shows proteinuria >40 mg /m 2 BSA with hypoalbuminemia. KFT is normal. C3 levels are normal. USG shows normal-sized kidneys. What is the best treatment for this case? (Q850824)

A. Steroids plus spironolactone

B. Steroids plus hydrochlorothiazide

C. Steroids plus ACEI

D. Steroids plus cyclophosphamide

Correct Answer: A. Steroids plus spironolactone

Explanation: Child is having nephrotic range proteinuria with hypoalbuminemia and normal KFT implying minimal change disease. It is steroid responsive nephrotic syndrome. Spironolactone is required to reduce the edema component and helps in restoring normal body weight. Kidney biopsy is not mandatory for diagnosis of minimal change disease.

References:

Harrison's Principles of Internal Medicine, 22nd Edition, Page 2421: Harrison 22 nd edition

↑ *Back to this question in Part A*

@Neet_pg_bot

Q3: A 5-year-old girl presents with fever, abdominal pain, and dysuria. The consultant performs the imaging study shown. Which investigation has been performed? (Q850827)

A. Intravenous pyelography

B. Retrograde pyelography

C. Voiding cystourethrography

D. DTPA scan



Correct Answer: C. Voiding cystourethrography

Explanation: The image shows contrast filling the bladder with irregular projections and contrast refluxing into the ureter and renal calyces , which is diagnostic of vesicoureteral reflux (VUR) . The investigation used to detect

VUR is Voiding cystourethrography (VCUG) . IVP (Option A) : Shows both kidneys, both ureters, and the bladder , but does not show reflux during voiding . Retrograde pyelography (Option B) : Shows only the ureter and renal pelvis on the side where dye is injected, not the bladder . DTPA scan (Option D): A radionuclide scan used for renal function and obstruction; does not visualize bladder anatomy or reflux . VCUG Retrograde pyelography IVP







References:

Harrison's Principles of Internal Medicine, 22nd Edition, Page 2441

↑ *Back to this question in Part A*

@Neet_pg_bot

Q4: Patient presents with pitting pedal oedema for the past 2 weeks. Labs: LFT = normal, serum albumin= 2 gm/dl, KFT= deranged with massive proteinuria, Hb A1c 10% and Echo report is normal. USG abdomen shows bilaterally enlarged kidneys. Kidney biopsy was done. Which of the following histopathological reports is most likely to be seen? (Q850831)

A. Diffuse glomerulosclerosis

B. Nodular glomerulosclerosis

C. A-beta 2 microglobulin deposits

D. Apple green birefringence for Congo red deposits

Correct Answer: B. Nodular glomerulosclerosis

Explanation: Patient is having massive proteinuria + deranged KFT + HbA1c = 10% indicating long-standing poorly controlled diabetes. USG shows bilaterally enlarged kidneys is typical of Diabetic nephropathy. The characteristic biopsy finding is: Nodular glomerulosclerosis (Kimmelstiel–Wilson nodules) PAS-positive, spherical mesangial nodules Pathognomonic for diabetes mellitus Diffuse glomerulosclerosis (Option A): Seen in early diabetic nephropathy but not the most specific/definitive finding. A-beta 2 microglobulin deposits (Option C): Seen in long-term dialysis-related amyloidosis , not diabetes. Apple green birefringence for Congo red deposits (■■■Option D): Indicates amyloidosis , usually with systemic signs; kidneys may be enlarged, but diabetes + nephrotic range proteinuria makes this less likely.

References:

Harrison's Principles of Internal Medicine, 22nd Edition, Page 2423

↑ *Back to this question in Part A*

@Neet_pg_bot

Q5: 30-year-old man presents with periorbital oedema. Urine examination shows massive proteinuria and hypoalbuminemia. He undergoes a kidney biopsy and Congo red staining shows apple-green birefringence under polarized light. What is the most likely diagnosis? (Q850834)

A. Amyloidosis

B. Minimal change disease

C. Diabetic nephropathy

D. Membranous nephropathy

Correct Answer: A. Amyloidosis

Explanation: Apple-green birefringence on Congo red staining is the classic diagnostic feature of amyloidosis . Amyloid deposits in the glomeruli cause nephrotic syndrome with massive proteinuria, hypoalbuminemia, and edema. Minimal change disease (Option B): Normal glomeruli on LM, common in children, with diffuse podocyte foot process effacement on EM. Diabetic nephropathy (Option C): Nodular glomerulosclerosis (Kimmelstiel–Wilson lesions) on LM, not Congo red positivity. Membranous nephropathy (Option D): Diffuse GBM thickening with “spike and dome” appearance on silver stain, granular IgG & C3 deposits on IF.

References:

Harrison's Principles of Internal Medicine, 22nd Edition, Page 2423: Harrison 22 nd edition

↑ *Back to this question in Part A*

@Neet_pg_bot

Q6: A 40-year-old man presents with leg swelling and frothy urine. Labs show nephrotic-range proteinuria and low serum albumin. Kidney biopsy shows diffuse GBM thickening with subepithelial deposits, and immunofluorescence reveals granular IgG and C3 along the capillary wall. Which marker is most specific for primary membranous nephropathy? (Q850835)

A. Anti-dsDNA antibody

B. Anti-PLA2 receptor antibody

C. Anti-GBM antibody

D. ANCA antibody

Correct Answer: B. Anti-PLA2 receptor antibody

Explanation: The biopsy describes membranous nephropathy (diffuse GBM thickening + subepithelial deposits + granular IgG/C3). Primary (idiopathic) membranous nephropathy is specifically associated with IgG4 autoantibodies against the M-type PLA2 receptor on podocytes. Anti-dsDNA antibody (Option A): Marker of lupus nephritis, primary membranous nephropathy Anti-GBM antibody (Option C): Seen in Goodpasture syndrome causing rapidly progressive GN with hematuria and pulmonary hemorrhage. ANCA antibody (Option

D): Associated with pauci-immune crescentic GN/vasculitis, not membranous nephropathy.

References:

Harrison's Principles of Internal Medicine, 22nd Edition, Page 2423

↑ *Back to this question in Part A*

@Neet_pg_bot

Q7: Renal vein thrombosis is most commonly associated with which of the following conditions? (Q850838)

A. Membranous glomerulonephropathy (MGN)

B. Membranoproliferative glomerulonephritis (MPGN)

C. Minimal change disease

D. Focal segmental glomerulosclerosis (FSGS)

Correct Answer: A. Membranous glomerulonephropathy (MGN)

Explanation: MGN has the highest incidence of complications like RVT , pulmonary embolism, and deep-vein thrombosis. Reason is that it has non selective proteinuria. This leads to urinary loss of antithrombin III, protein C, and protein S in the urine, while fibrinogen and clotting factors increase in blood. This imbalance creates a pro-thrombotic state and increased incidence of RVT. MPGN (Option B): More often presents with hematuria and progressive renal dysfunction than with thrombotic complications. Minimal change disease (Option C): Common in children; highly steroid-responsive; thrombotic events are uncommon. FSGS (Option D): Associated with progressive renal failure and poor steroid response, but not classically with RVT.

References:

Harrison's Principles of Internal Medicine, 22nd Edition, Page 2423

↑ *Back to this question in Part A*

@Neet_pg_bot

Q8: 40-year-old man with nephrotic syndrome due to membranous glomerulonephropathy in on steroids with cyclophosphamide. He presents with sudden onset flank pain and hematuria. On examination, the left kidney is enlarged and tender. Which of the following is the most likely diagnosis? (Q850839)

A. Acute pyelonephritis

B. Hydronephrosis with pyelonephritis

C. Renal Abscess

D. Renal vein thrombosis

Correct Answer: D. Renal vein thrombosis

Explanation: MGN leads to urinary loss of protein C, S, and anti-thrombin III, which predisposes to a hypercoagulable state. A sudden onset unilateral, enlarged, tender kidney is due to RVT. Acute pyelonephritis (Option A) and Renal abscess (Option C): Will start with high-grade fever with chills, and rigors. Hydronephrosis with pyelonephritis (Option B): Develops over a period of time and does not cause tender kidneys.

References:

Harrison's Principles of Internal Medicine, 22nd Edition, Page 2423: Harrison 22 nd edition

↑ *Back to this question in Part A*

@Neet_pg_bot

Q9: 2-year-old child with a history of severe watery diarrhea and dehydration is brought to the emergency. He develops sudden onset hematuria and flank mass. Examination reveals unilateral enlarged tender kidney. Which of the following is the most likely diagnosis? (Q850841)

A. Haemolytic uremic syndrome

B. Pre-renal acute kidney injury

C. Renal vein thrombosis

D. Hydronephrosis due to ureteric stone

Correct Answer: C. Renal vein thrombosis

Explanation: Sudden onset unilateral enlarged kidneys with haematuria indicates RVT. Rationale is that dehydration caused by diarrhea causes increased haematocrit and sluggish circulation that predisposes to thrombosis. Haemolytic uremic syndrome (Option A): It has microangiopathic haemolytic anaemia with schistocytes in peripheral smear with renal shut down after GI illness with E.coli 0157: H7 Pre-renal acute kidney injury ■(■■■■■■ Option B) : It has normal size kidneys and occurs after severe dehydration Hydronephrosis due to ureteric stone (Option D) : will have chronic presentation and not acute onset presentation

References:

Harrison's Principles of Internal Medicine, 22nd Edition, Page 2423

↑ *Back to this question in Part A*

@Neet_pg_bot

Q10: Most common cause of Primary glomerulonephritis is? (Q850842)

A. Post-streptococcal glomerulonephritis (PSGN)

B. Rapidly progressive glomerulonephritis (RPGN)

C. Henoch–Schönlein purpura (HSP)

D. Berger disease (IgA nephropathy)

Correct Answer: D. Berger disease (IgA nephropathy)

Explanation: IgA nephropathy/ Berger disease is the most common cause of primary glomerulonephritis worldwide, especially in Asia. It presents with recurrent gross hematuria (often after a URI or GI infection) and mesangial IgA deposits on biopsy. PSGN (Option A): Common cause in children, but not the most frequent worldwide; follows streptococcal infection. RPGN (Option B): A severe, rapidly progressive form but much less common. HSP (Option C): Systemic small-vessel vasculitis with IgA deposition, but not the most common cause of GN overall.

References:

Harrison's Principles of Internal Medicine, 22nd Edition, Page 2419

↑ *Back to this question in Part A*

@Neet_pg_bot

Q11: 10-year-old boy presents with cola-colored urine, periorbital puffiness, and mild hypertension. He had a sore throat 2 weeks ago. Urine examination shows red blood cell casts and mild proteinuria. Serum C3 is decreased while C4 remains normal. Which of the following is the most likely diagnosis? (Q850844)

A. IgA nephropathy

B. Post-streptococcal glomerulonephritis

C. Membranous glomerulopathy

D. Rapidly progressive glomerulonephritis

Correct Answer: B. Post-streptococcal glomerulonephritis

Explanation: PSGN follows group A β-hemolytic streptococcal pharyngitis/impetigo by 1–3 weeks. It has a clinical triad of cola-colored urine/ hematuria + oedema + Hypertension. Labs show ↓ C3 with normal C4 (returns to normal in 6–8 weeks), RBC casts, mild–moderate proteinuria. IgA nephropathy (Option A): Hematuria occurs within 24–48 hrs of infection ("synpharyngitic"), not after latent period. Membranous glomerulopathy (Option C): Usually presents with nephrotic syndrome, not gross hematuria + low complement. Rapidly progressive glomerulonephritis (RPGN) (Option D): Rapidly progressive renal failure with crescents on biopsy, severe course, not classic latent period after infection.

References:

Harrison's Principles of Internal Medicine, 22nd Edition, Page 2417

↑ *Back to this question in Part A*

@Neet_pg_bot

Q12: A 15-year-old boy presents with periorbital edema, dyspnea, and dark-colored urine for 2 days. His BP is 160/100 mmHg, and urine microscopy shows 100 dysmorphic RBCs/HPF with S. creatinine 1.5 mg/dL. Kidney biopsy was done and H&E and IF findings are shown below. Which of the following correctly describes the pathogenesis of this condition? (Q850850)

A. Type III hypersensitivity with subepithelial humps

B. Type III hypersensitivitywith subendothelial deposits

C. Type IIhypersensitivity with anti-GBM deposition

D. Type III hypersensitivity with thickening of basement membrane

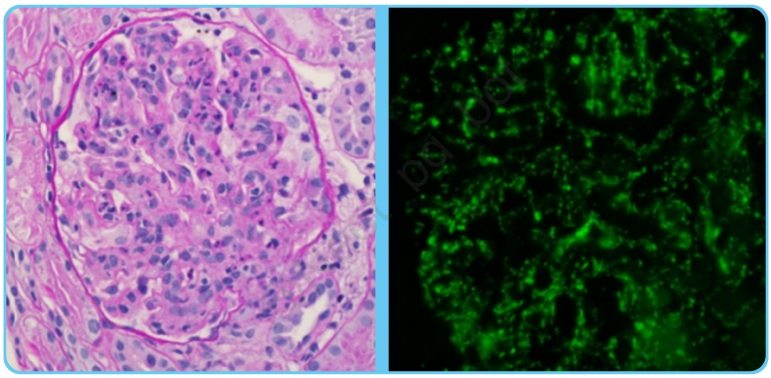

@Neet_pg_bot

Correct Answer: A. Type III hypersensitivity with subepithelial humps

Explanation: H&E shows hypercellular glomeruli (proliferative GN), and IF reveals “starry sky” granular deposits along the GBM and mesangium , characteristic of Post-streptococcal GN (PSGN) . It results from Type III hypersensitivity due to immune complexes against streptococcal SP-EB antigen , causing haematuria and low GFR . The electron microscopy finding is subepithelial humps . Type III with subendothelial deposits (Option B): Seen in lupus nephritis (class III/IV), not PSGN. Type III with thickening of basement membrane (Option C): Describes membranous nephropathy, not PSGN. Type II with anti-GBM deposition (Option D): Refers to Goodpasture syndrome, not PSGN.

References:

Harrison's Principles of Internal Medicine, 22nd Edition, Page 2417

↑ *Back to this question in Part A*

@Neet_pg_bot

Q13: Kidney biopsy showing diffuse endocapillary hypercellularity with diffuse subendothelial immune deposits is most consistent with which of the following conditions? (Q850853)

A. Post-streptococcal glomerulonephritis (PSGN)

B. Lupus nephritis

C. Rapidly progressive glomerulonephritis (RPGN)

D. Berger disease

Correct Answer: B. Lupus nephritis

Explanation: The keyword is subendothelial deposits that reveal the vasculitis component of the disease. Diffuse subendothelial immune deposits produce the classic “wire loop lesions” seen in lupus nephritis. PSGN (Option A) has endocapillary proliferation but shows subepithelial humps RPGN (Option C) shows crescents in Bowman’s space, not diffuse subendothelial deposits. Berger disease (Option D) shows Mesangial hypercellularity with mesangial IgA deposits, not subendothelial.

References:

Harrison's Principles of Internal Medicine, 22nd Edition, Page 2417

↑ *Back to this question in Part A*

@Neet_pg_bot

Q14: A 20-year-old college student presents with recurrent episodes of cola-colored urine 1–2 days after upper respiratory infections. Urinalysis shows dysmorphic RBCs and mild proteinuria. Renal biopsy demonstrates mesangial proliferation with IgA deposits on immunofluorescence. Which of the following best explains the pathophysiology of his condition? (Q850857)

A. Immune complex formation against glucose-deficient IgA1

B. Immune complex formation against galactose-deficient IgA1

C. Antibody formation against glomerular basement membrane antigens

D. T-cell mediated podocyte injury leading to foot process effacement

Correct Answer: B. Immune complex formation against galactose-deficient IgA1

Explanation: The clinical scenario is classic for IgA nephropathy (Berger disease) : recurrent hematuria after mucosal infections . Pathophysiology: Production of galactose-deficient IgA1 triggers formation of autoantibodies . These immune complexes deposit in the mesangium , causing mesangial proliferation and hematuria. Immune complex against glucose-deficient IgA1 (Option A): Pathogenesis involves galactose deficiency , not glucose. Antibody against GBM antigens (Option C): Anti-GBM antibodies cause rapidly progressive glomerulonephritis , not post-infectious IgA hematuria. T-cell mediated podocyte injury (Option D): Refers to minimal change disease , causing nephrotic syndrome, not hematuria.

References:

Harrison's Principles of Internal Medicine, 22nd Edition, Page 2419

↑ *Back to this question in Part A*

@Neet_pg_bot

Q15: A 45-year-old man with a history of IV drug use and HCV positivity presents with edema and fatigue. Labs show 3.8 g/day proteinuria, microscopic hematuria, and low C3. Kidney biopsy specimen under light microscopy is shown below. What is the most likely diagnosis? (Q850860)

A. Focal segmental glomerulosclerosis

B. Membranous nephropathy

C. Membranoproliferative glomerulonephritis

D. Minimal change disease

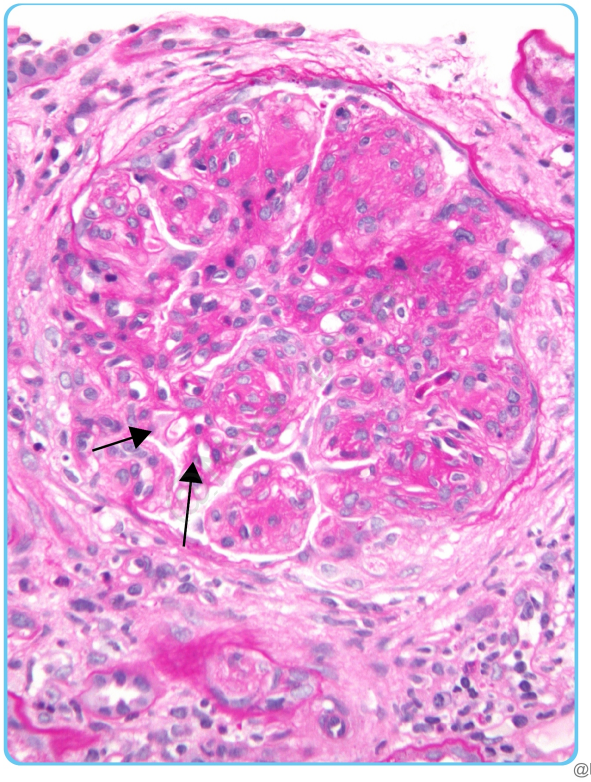

Correct Answer: C. Membranoproliferative glomerulonephritis

Explanation: Hepatitis C infection is classically associated with Type I MPGN. Low serum C3 → suggests complement activation via the classical pathway , typical of MPGN I. Light microscopy typically demonstrate: Mesangial and endocapillary proliferation “Tram-track” (double-contour) appearance of the basement membrane FSGS (Option A): Shows segmental sclerosis of some glomeruli, not lobular accentuation. Membranous nephropathy (Option B): GBM thickening with subepithelial “spike and dome” deposits , not tram-tracks. Minimal change disease (Option D): Glomeruli appear normocellular and normal on LM; EM shows podocyte foot process effacement.

References:

Harrison's Principles of Internal Medicine, 22nd Edition, Page 2420:

↑ *Back to this question in Part A*

@Neet_pg_bot

• [04_Nephrology] 029 Previous Year Questions

« Back to Folder Directory

[04_Nephrology] 029 Previous Year Questions — Quick Jump

Q1 (p. 1875)	*Q2 (p. 1876)*	*Q3 (p. 1877)*	*Q4 (p. 1878)*	*Q5 (p. 1879)*	*Q6 (p. 1882)*
Q7 (p. 1883)	*Q8 (p. 1884)*	*Q9 (p. 1886)*	*Q10 (p. 1888)*	*Q11 (p. 1888)*	*Q12 (p. 1889)*
Q13 (p. 1890)	*Q14 (p. 1891)*	*Q15 (p. 1891)*	*Q16 (p. 1892)*	*Q17 (p. 1894)*	*Q18 (p. 1896)*
Q19 (p. 1896)	*Q20 (p. 1899)*	*Q21 (p. 1899)*	*Q22 (p. 1901)*	*Q23 (p. 1901)*	*Q24 (p. 1902)*
Q25 (p. 1903)	*Q26 (p. 1904)*	*Q27 (p. 1905)*	*Q28 (p. 1906)*	*Q29 (p. 1906)*	*Q30 (p. 1907)*
Q31 (p. 1908)	*Q32 (p. 1909)*	*Q33 (p. 1910)*	*Q34 (p. 1911)*	*Q35 (p. 1912)*	*Q36 (p. 1913)*
Q37 (p. 1913)	*Q38 (p. 1914)*	*Q39 (p. 1915)*	*Q40 (p. 1915)*	*Q41 (p. 1916)*	*Q42 (p. 1917)*
Q43 (p. 1918)	*Q44 (p. 1919)*	*Q45 (p. 1920)*	*Q46 (p. 1921)*		

Q1: A 29-year-old male patient presents with multiple oral and genital ulcers. The patient claims these ulcers resolve spontaneously and that he experiences such episodes at least four times a year. Ocular examination reveals features of anterior uveitis. What is the likely diagnosis? (Q856261)

A. Rheumatoid arthritis

B. Psoriatic arthritis

C. SLE

D. Behcet’s disease

Correct Answer: D. Behcet’s disease

Explanation: This patient presents with classic features of Behcet's Disease: Young adult male Mucocutaneous manifestations (oral/genital ulcers) Ocular involvement (uveitis) Behcet's disease is a chronic autoimmune disorder characterized by recurrent oral and genital ulcers. It is a multi-systemic vasculitis that can affect blood vessels of all sizes. One of the common manifestations of Behcet's disease is uveitis Behcet’s Disease- Pathogenesis and Clinical Features Category Features Clinical Significance Pathogenesis T-cell mediated immunity Th1 cell activation Elevated cytokines (IL-1, TNF-α) Neutrophilic vasculitis No specific autoantibodies Auto-inflammatory rather than autoimmune Affects vessels of all sizes Treatment targets inflammation Mucocutaneous Oral ulcers (97-99%) Genital ulcers (>80%) Erythema nodosum Pathergy reaction Often initial presentation Oral ulcers heal without scarring Genital ulcers leave scars Major Organ Involvement Uveitis (>50%) Vascular (25%) Neurologic (5-10%) Arthritis (non-erosive) More severe in males Ocular disease can cause blindness Vascular involvement can be fatal

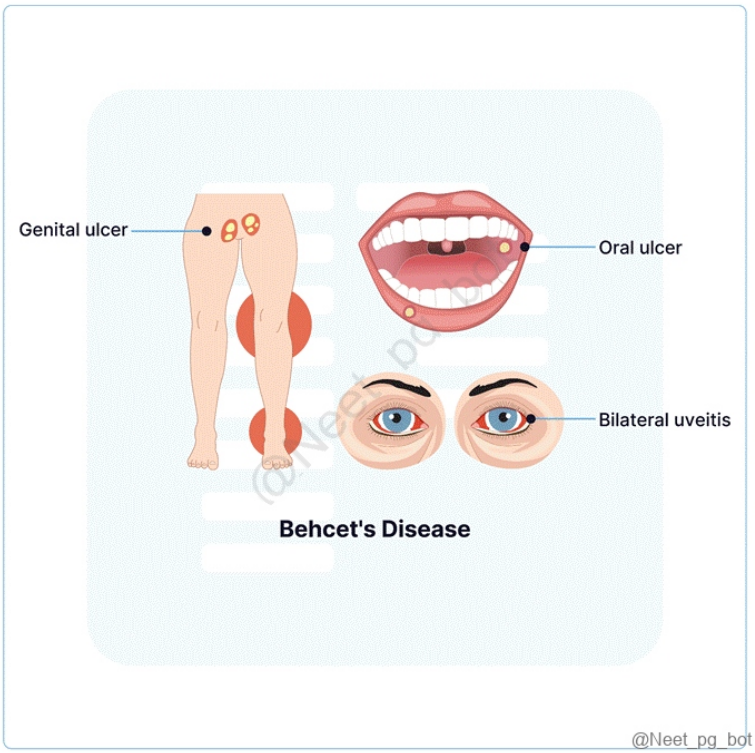

References:

Harrison’s Principles of Internal Medicine, 21st edition, Page 2817, 2818

www.ncbi.nlm.nih.gov/books/NBK470257/

↑ *Back to this question in Part A*

@Neet_pg_bot

Q2: What is the most probable cause of the muteness, quadriplegia, and rigidity observed in an elderly female patient who had a previous medical history of severe vomiting and was aggressively treated for severe dehydration at a different hospital one week ago? (Q855368)

A. Malignant hyperthermia

B. Severe catatonia

C. Rapid sodium correction

D. Neuroleptic malignant syndrome

Correct Answer: C. Rapid sodium correction

Explanation: Muteness, quadriplegia, and rigidity after treatment for dehydration in an elderly patient strongly suggest osmotic demyelination syndrome (ODS) due to rapid correction of hyponatremia . • Rapid sodium correction causes demyelination in the central pons (central pontine myelinolysis), leading to features like "locked-in syndrome" , rigidity , and pseudobulbar palsy . • History of severe vomiting and dehydration likely led to hyponatremia, which was overcorrected . {{caption_text}} Central Pontine Myelinolysis (CPM) / Osmotic Demyelination Syndrome Feature Description Etiology Rapid correction of chronic hyponatremia Common in Alcoholics, malnourished, post-liver transplant Neurological features Dysarthria, mutism, quadriplegia, pseudobulbar palsy Imaging MRI shows symmetric lesions in central pons Prevention Limit sodium correction to ≤8–10 mEq/L in 24 hrs Malignant hyperthermia (Option A): Incorrect because it occurs due to anesthetic agents (like succinylcholine or halothane) and presents with hyperthermia, rigidity, acidosis—not mutism or quadriplegia without fever. Severe catatonia (Option B): Incorrect because catatonia may explain mutism and rigidity but not quadriplegia. It is also not linked to sodium correction. Neuroleptic malignant syndrome (Option D): Incorrect because NMS occurs after neuroleptic use and features hyperthermia , lead-pipe rigidity , and altered mental status—not quadriplegia or locked-in features.

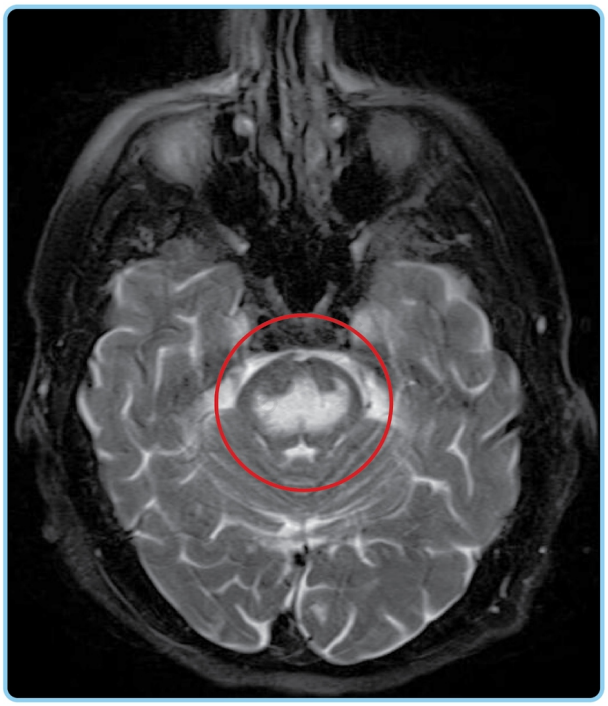

References:

Harrison's Principles of Internal Medicine, Twenty-First Edition Page 344, 347, 2273, 3408, 3435, 3554

↑ *Back to this question in Part A*

@Neet_pg_bot

Q3: In methanol intoxication, which of the subsequent electrolyte abnormalities is observed? (Q855370)

A. Metabolic alkalosis with high anion gap

B. Metabolic acidosis with high anion gap

C. Metabolic acidosis with normal anion gap

D. Metabolic alkalosis with normal anion gap

Correct Answer: B. Metabolic acidosis with high anion gap

Explanation: Methanol intoxication leads to the formation of toxic metabolites, including formic acid, which causes metabolic acidosis . The acidosis results from the accumulation of formic acid and its metabolites, leading to an increased anion gap . (Options A, C and D ruled out) Other causes Ketoacidosis Uremia Lactic acidosis

References:

Harrison's Principles of Internal Medicine, 21st Edition, Page 361

↑ *Back to this question in Part A*

@Neet_pg_bot

Q4: AKIN and RIFLE criteria is used for classification of which of the folowing coditions? (Q857655)

A. Acute kidney injury

B. Chronic kidney failure

C. Acute glomerulonephritis

D. Nephrotic syndrome

Correct Answer: A. Acute kidney injury

Explanation: The AKIN (Acute Kidney Injury Network) and RIFLE (Risk, Injury, Failure, Loss, End-stage kidney disease) criteria are used to classify and stage acute kidney injury (AKI). These criteria help healthcare professionals assess the severity of AKI and guide treatment decisions. RIFLE Classification Table for Acute Kidney Injury (AKI): Class SCr/GFR Criteria Urine Output (UO) Criteria R isk ↑ SCr × 1.5 or ↓ GFR > 25% < 0.5 mL/kg/h for 6 hours I njury ↑ SCr × 2 or ↓ GFR > 50% < 0.5 mL/kg/h for 12 hours F ailure ↑ SCr × 3 or ↓ GFR > 75% or Baseline SCr ≥ 353.6 µmol/L (≥ 4 mg/dL) + ↑ SCr > 44.2 µmol/L (> 0.5 mg/dL) < 0.3 mL/kg/h for 24 hours or Anuria for 12 hours L oss of Kidney Function Complete loss of kidney function for > 4 weeks - E nd-Stage Kidney Disease Complete loss of kidney function for > 3 months - SCr = Serum Creatinine GFR =

Glomerular Filtration Rate UO = Urine Output AKIN (Acute Kidney Injury Network) Classification Table for AKI: Stage Serum Creatinine (SCr) Criteria Urine Output (UO) Criteria 1 ↑ SCr ≥ 26.5 µmol/L (≥ 0.3 mg/dL) or ↑ SCr 150–200% (1.5–2 times) < 0.5 mL/kg/h for > 6 hours 2 ↑ SCr > 200–300% (> 2–3 times) < 0.5 mL/kg/h for > 12 hours 3 Baseline SCr ≥ 353.6 µmol/L (≥ 4 mg/dL) + ↑ SCr ≥ 44.2 µmol/L (≥ 0.5 mg/dL) or ↑ SCr > 300% (> 3 times) or Patients requiring Renal Replacement Therapy (RRT) , regardless of SCr or UO at the time of initiation. < 0.3 mL/kg/h for 24 hours or Anuria for 12 hours

References:

Davidson's Principles and Practice of Medicine, 24th edition, Page 411

https://pmc.ncbi.nlm.nih.gov/articles/PMC5094385/#s2

https://kdigo.org/wp-content/uploads/2016/10/KDIGO-2012-AKI-Guideline-English.pdf

↑ *Back to this question in Part A*

@Neet_pg_bot

Q5: Which of the following conditions is associated with hypokalemic metabolic alkalosis with hypertension? (Q855709)

A. Barter syndrome

B. Liddle syndrome

C. Gitelman syndrome

D. Gordon syndrome

Correct Answer: B. Liddle syndrome

Explanation: Liddle syndrome is associated with hypokalemic metabolic alkalosis with hypertension. Renal Tubular Syndromes Defect Seen in Cause Effects Fanconi Syndrome Generalised reabsorption defect in PCT {{caption_text}} Childhood Hereditary defects (wilson disease, tyrosinemia, glycogen storage disease, cystinosis) Multiple myeloma Ischemia Nephrotoxic drugs (ifosfamide, cisplatin, tenofovir, expired tetracycline) Lead poisoning Metabolic acidosis (proximal RTA) Hypophosphatemia Phosphaturia Osteopenia Gitelman Syndrome (Option C) Reabsorptive defect of NaCl- in DCT. Mimics chronic thiazide diuretic use. {{caption_text}} Late childhood or adulthood Autosomal recessive Hypokalemia Hypomagnesemia Metabolic alkalosis Hypocalciuria Bartter Syndrome (Option A) Reabsorptive defect in thick ascending loop of Henle. Affects Na+/K+/2Cl- cotransporter. Mimics chronic loop diuretic use. {{caption_text}} Childhood Autosomal recessive Hypokalemia Metabolic alkalosis Hypercalciuria Hyperchloremia Liddle Syndrome Gain of function mutation → ↑ Na+ reabsorption in collecting tubules (↑ activity of Na+ channel) {{caption_text}} Childhood Autosomal dominant Hypertension Hypokalemia Metabolic alkalosis Hypoaldosteronism Gordon syndrome (Option D) (also known as pseudohypoaldosteronism type II) is a rare autosomal dominant disorder that presents with hypertension, hyperkalemia, and metabolic acidosis, rather than the hypokalemic metabolic alkalosis.

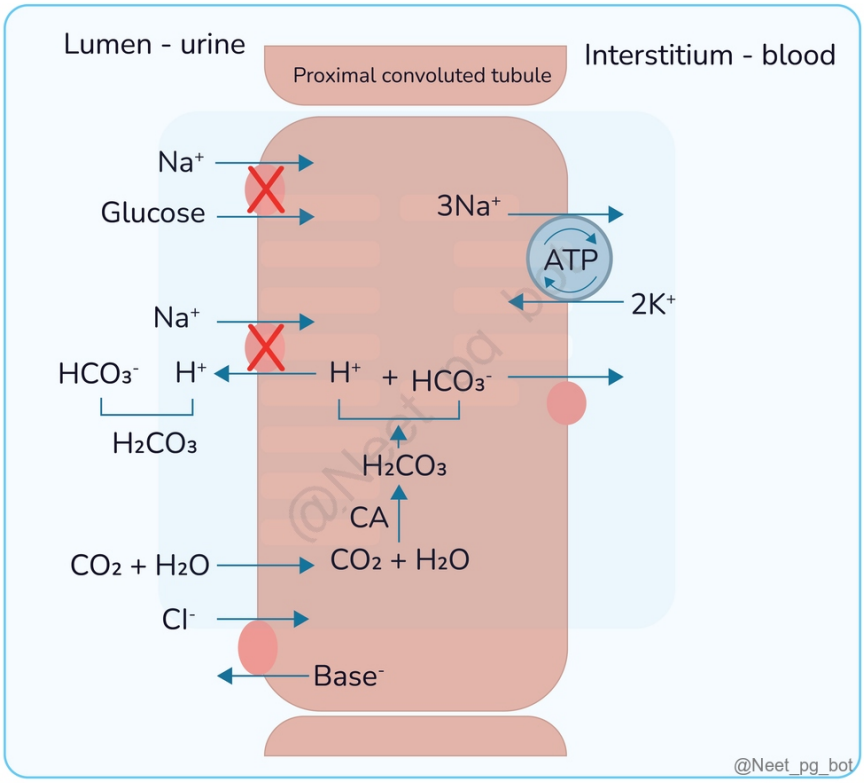
Lumen - urine
Proximal convoluted tubule
Interstitium - blood
Na+
Glucose
3Na+
ATP
2K+
Na+
HCO3-
H+
H+ + HCO3-
H2CO3
H2CO3
CA
CO2 + H2O
CO2 + H2O
Cl-
Base-
@Neet_pg_bot

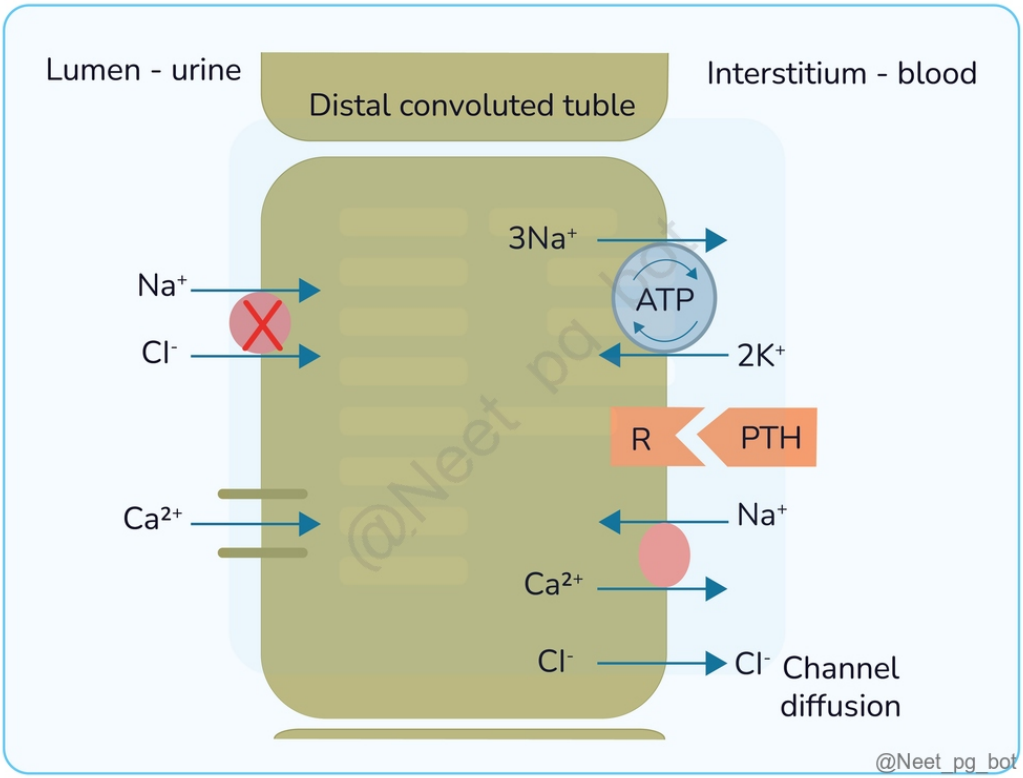
Lumen - urine
Distal convoluted tuble
Interstitium - blood
3Na+
ATP
Na+
Cl-
2K+
R
PTH
Ca2+
Na+
Ca2+
Cl-
Cl-
Channel diffusion
@Neet_pg_bot

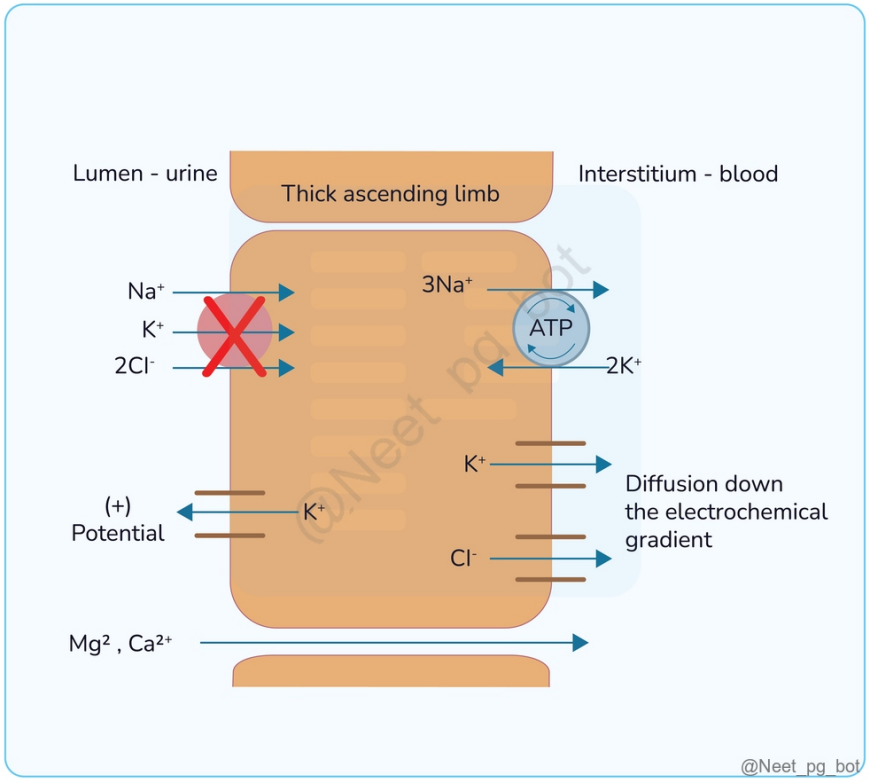
Lumen - urine
Thick ascending limb
Interstitium - blood
Na+
K+
2Cl-
3Na+
ATP
2K+
K+
Diffusion down
the electrochemical
gradient
(+)
Potential
K+
Cl-
Mg2 , Ca2+
@Neet_pg_bot

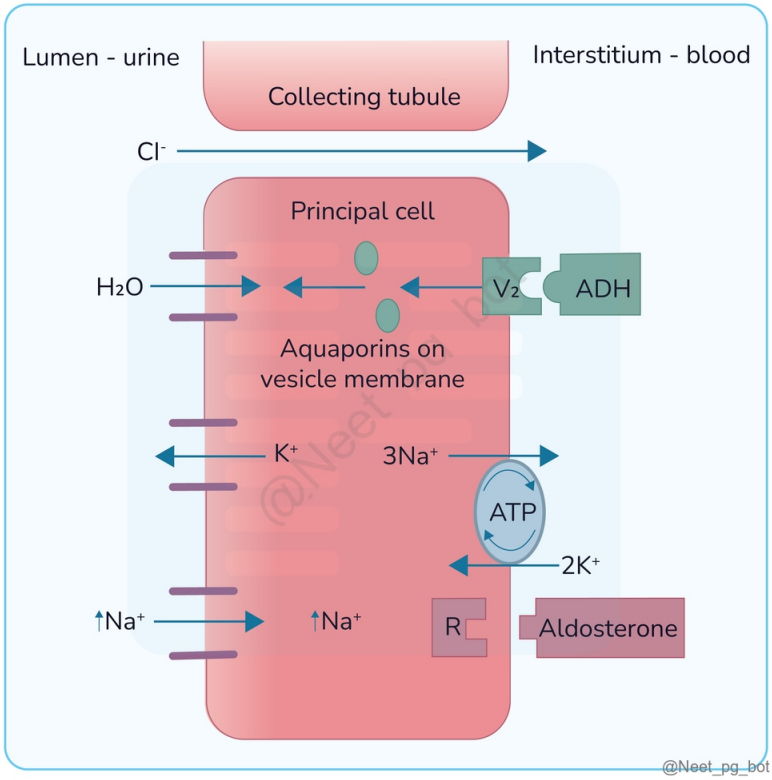
Lumen - urine
Collecting tubule
Interstitium - blood
Cl-
Principal cell
H2O
V2
ADH
Aquaporins on
vesicle membrane
K+
3Na+
ATP
2K+
↑Na+
↑Na+
R
Aldosterone
@Neet_pg_bot

References:

https://link.springer.com/referenceworkentry/10.1007/978-3-642-27843-3_38-1 https://www.sciencedirect.com/topics/medicine-and-dentistry/fanconi-syndrome https://www.msdmanuals.com/professional/pediatrics/congenital-renal-transport-abnormalities/bartter-syndrome-and-gitelman-syndrome#Etiology_v1098222 https://www.ncbi.nlm.nih.gov/books/NBK536911/#

↑ *Back to this question in Part A*

@Neet_pg_bot

Q6: Identify the urinary crystal shown below: (Q855724)

A. Calcium oxalate

B. Calcium phosphate

C. Uric acid

D. Cysteine

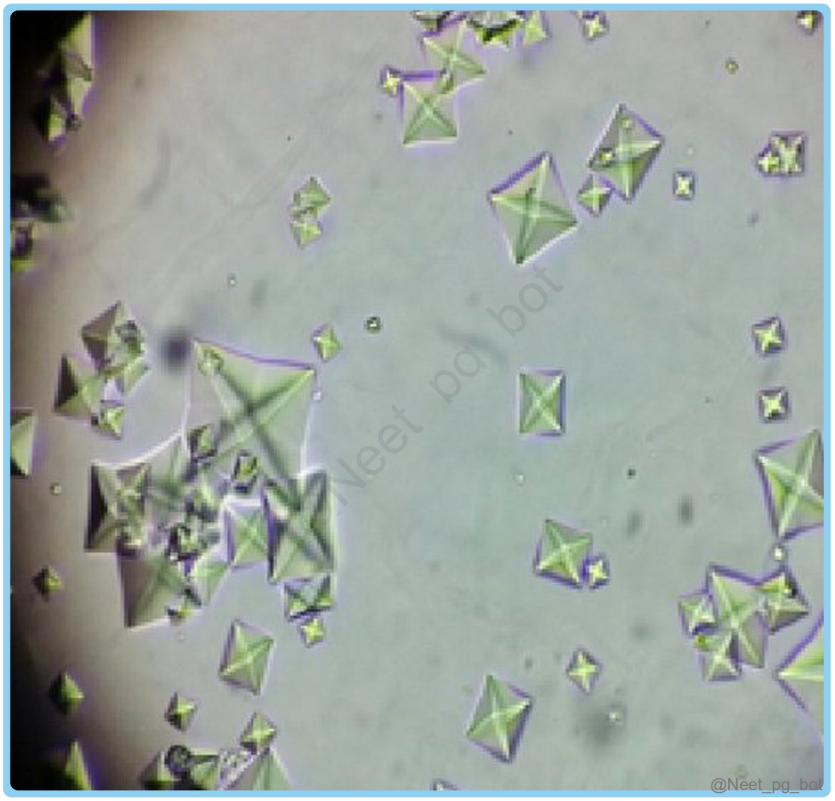

Correct Answer: A. Calcium oxalate

Explanation: The image shows classic calcium oxalate crystals, which appear as envelope-shaped (octahedral) structures. These crystals are strongly birefringent and can form both monohydrate (dumbbell) and dihydrate (envelope) forms. They are commonly found in acidic to neutral urine. Seen in conditions such as hyperoxaluria,

ethylene glycol poisoning, and normal individuals as well. Their characteristic shape makes them easy to identify microscopically. They are the most common crystals found in kidney stones. Incorrect Options: Option B) Calcium phosphate: Coffin-lid/prism-shaped crystals seen in alkaline urine — morphology and pH differ from envelope-shaped calcium oxalate. Option C) Uric acid: Yellow-brown, rhomboid or rosette crystals formed in acidic urine - color and shape do not match the envelope form. Option D) Cysteine: Colorless, flat hexagonal plates seen in cystinuria — distinctly hexagonal, not octahedral/envelope.

References:

Harrison's Principles of Internal Medicine, 21st Edition, pages 431,432, 433, 2372, 2373 Bailey & Love's Short Practice Of Surgery 28th Edition, page 1474

↑ *Back to this question in Part A*

@Neet_pg_bot

Q7: Which of the following is not true about syndrome of inappropriate antidiuretic hormone secretion (SIADH)? (Q856599)

A. Urinary sodium <20 mEq/L

B. Serum sodium <135 mEq/L

C. Urine osmolality >100 mOsm/kg

D. Patient can be clinically euvolemic to hypervolemic

Correct Answer: A. Urinary sodium <20 mEq/L

Explanation: NS disturbances: Stroke, infection, subarachnoid hemorrhage, etc. Malignancies: Small cell lung cancer (most common), other cancers. Drugs: Carbamazepine, oxcarbazepine, SSRIs, "Ecstasy", NSAIDs, etc. Surgery: Pain-induced ADH hypersecretion. Pulmonary diseases: Pneumonia (Option A ruled out), respiratory failure, etc. Hormone deficiency: Hypopituitarism, hypothyroidism. HIV: Associated with infections. Hereditary SIADH: V2 receptor mutation. Pathophysiology ADH function: Regulates water balance by controlling plasma osmolality; excess ADH causes water retention, leading to hyponatremia. Volume regulation: In hypovolemia, ADH release is driven by volume receptors, worsening hyponatremia. Clinical Presentation Acute hyponatremia: Nausea, vomiting, headache, seizures, coma. Chronic hyponatremia: Nonspecific symptoms (nausea, confusion, falls in elderly). Diagnosis Schwartz and Bartter Criteria: Serum sodium <135 mEq/L (Option B) Serum osmolality <275 mOsm/kg Urine sodium >40 mEq/L Urine osmolality >100 mOsm/kg (Option C) The absence of clinical evidence of volume depletion (like normal skin turgor, blood pressure within the reference range) The absence of hyponatremia due to other causes (like adrenal insufficiency, hypothyroidism, cardiac failure, pituitary insufficiency, renal disease with salt wastage, hepatic disease, drugs that impair renal water excretion.) Tests: Renal function, serum osmolality, cortisol levels, thyroid tests, imaging for underlying causes. Management Fluid restriction: For mild to moderate symptoms. Hypertonic saline (3%): For severe hyponatremia, with careful correction rate (<8 mEq/L in 24 hrs). Medications: Vasopressin receptor antagonists (Conivaptan, Tolvaptan) Other: Loop diuretics, salt tablets, demeclocycline, lithium. Complications Osmotic demyelination syndrome: Risk

from rapid sodium correction. Severe hyponatremia: Can lead to seizures, coma, and death in acute cases.

References:

Harrison's Principles of Internal Medicine 21st Edition, Page 342-342, 723

Syndrome of Inappropriate Antidiuretic Hormone Secretion - StatPearls - NCBI Bookshelf

↑ *Back to this question in Part A*

@Neet_pg_bot

Q8: A 40-year-old male presents with complaints of episodes of palpitations, headache, and profuse sweating for the past few days. MIBG scan shows a deep-seated tumour in the adrenal medulla. Which of the following statements is incorrect regarding the condition described? (Q856115)

A. Diagnosed by urine VMA & catecholamines

B. Surgical excision is the definitive treatment

C. Propranolol is given initially to manage hypertension

D. Can present as hypertension alone and sometimes with vomiting and pain abdomen

Correct Answer: C. Propranolol is given initially to manage hypertension

Explanation: The above condition is characteristic of pheochromocytoma . Episodes of palpitations, profuse sweating, and headache constitute a classic triad of pheochromocytoma. The diagnosis is typically confirmed by measuring urine vanillylmandelic acid (VMA) and catecholamine levels, and the definitive treatment is surgical excision. However, the initial management of hypertension in pheochromocytoma involves starting with an alpha-blocker to prevent a hypertensive crisis. Beta-blockers like propranolol are only added after adequate alpha blockade is established to avoid unopposed alpha-adrenergic stimulation, which could worsen the hypertension. Pheochromocytoma Description Pheochromocytomas are rare tumours arising from chromaffin cells of the adrenal medulla. The clinical features result from excessive secretion of catecholamines. Histopathology Histology of the lesion characteristically shows zellballen nests of chromaffin cells with strong positivity to chromogranin, synaptophysin, CD56, and focally to S100. {{caption_text}} The presence of chromaffin cells in the extra-adrenal tissue is the only pathognomonic characteristic of the malignant form of the entity. Clinical features Classical triad Episode of palpitation Headache Profuse sweating The dominant sign is Hypertension Vomiting (Option D) Pain abdomen Tachycardia Anxiety Subcutaneous neurofibromas Cafe-au-lait macules Thyroid mass Axillary freckling Lisch nodules on the iris Retinal angiomas Abdominal mass Diagnosis Diagnosis of pheochromocytoma can be established by biochemical confirmation of hypersecretion of metanephrines and catecholamines. 24-hour urine test Catecholamines (Option A) Fractionated metanephrines Total metanephrines Vanillylmandelic acid (VMA) (a metabolite of adrenaline and noradrenaline) (Option A) Imaging : CT scan of the abdomen and pelvis to locate the tumour. {{caption_text}} 18F-FDG PET scanning is recommended for metastatic disease. MIBG scintigraphy Somatostatin receptor scintigraphy Gallium DOTATATE PET scanning {{caption_text}} Differential Diagnosis

Hyperthyroidism Renal artery stenosis Hyperaldosteronism Cardiomyopathy Postural tachycardia syndrome (POTS) Treatment The definitive treatment of pheochromocytoma is surgical resection. (Option B) Preoperative preparation of the patient has to be considered, and blood pressure should be consistently < 160/90 mm Hg. Blood pressure is controlled by alpha-adrenergic blockers (phenoxybenzamine 0.5-4 mg/kg of body weight) (vs Option C) Oral Prazosin or IV phentolamine can be used to control paroxysm. Unilateral Pheochromocytoma: Minimally invasive adrenalectomy: Preferred treatment for most unilateral adrenal pheochromocytomas. Open adrenalectomy Bilateral pheochromocytomas: Bilateral total adrenalectomy is associated with a lifelong need for steroid replacement with long-term side effects. Bilateral partial or cortical sparing adrenalectomy (open or laparoscopic) Complications Myocardial infarction Cardiogenic shock Renal Failure Pulmonary edema Acute respiratory distress syndrome (ARDS) Lactic acidosis Hypertensive retinopathy Hypertensive encephalopathy

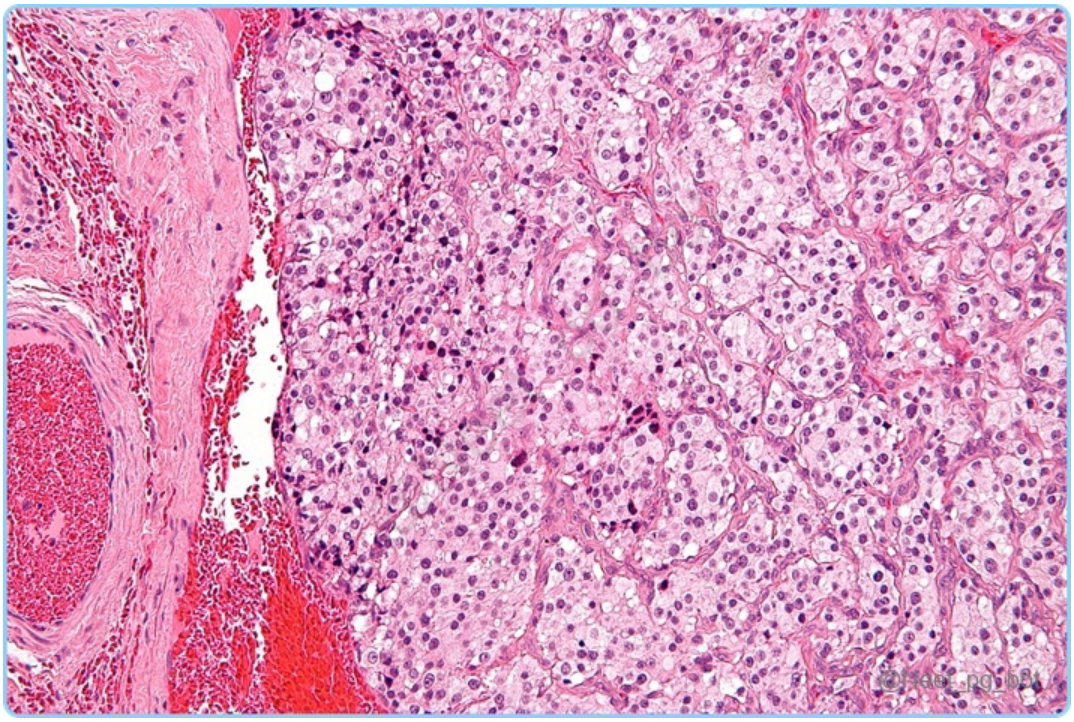

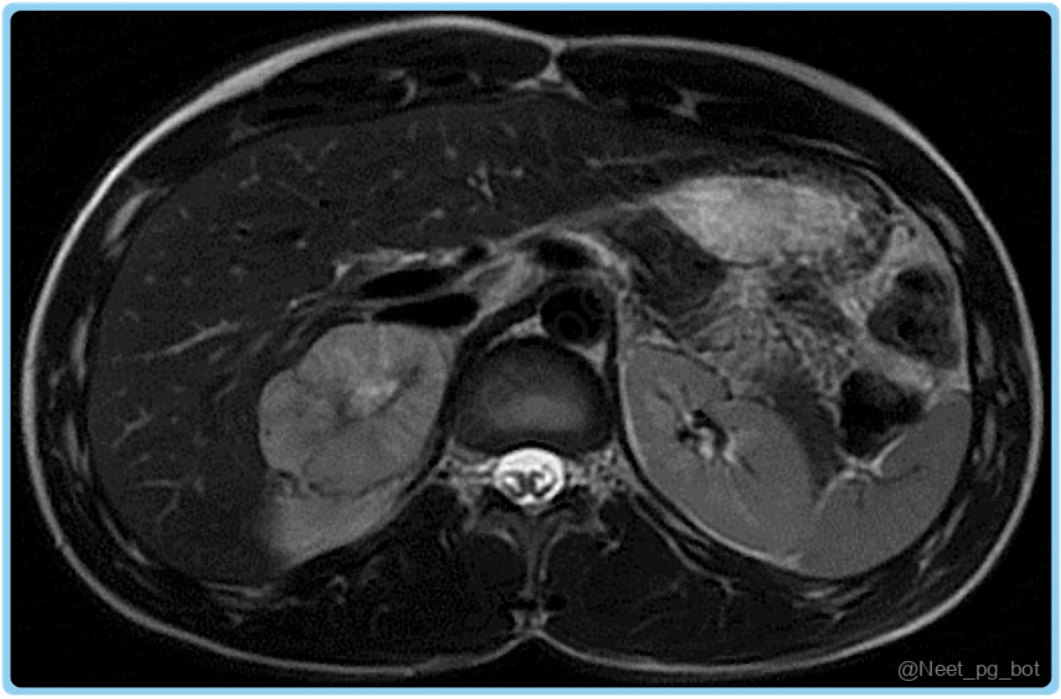

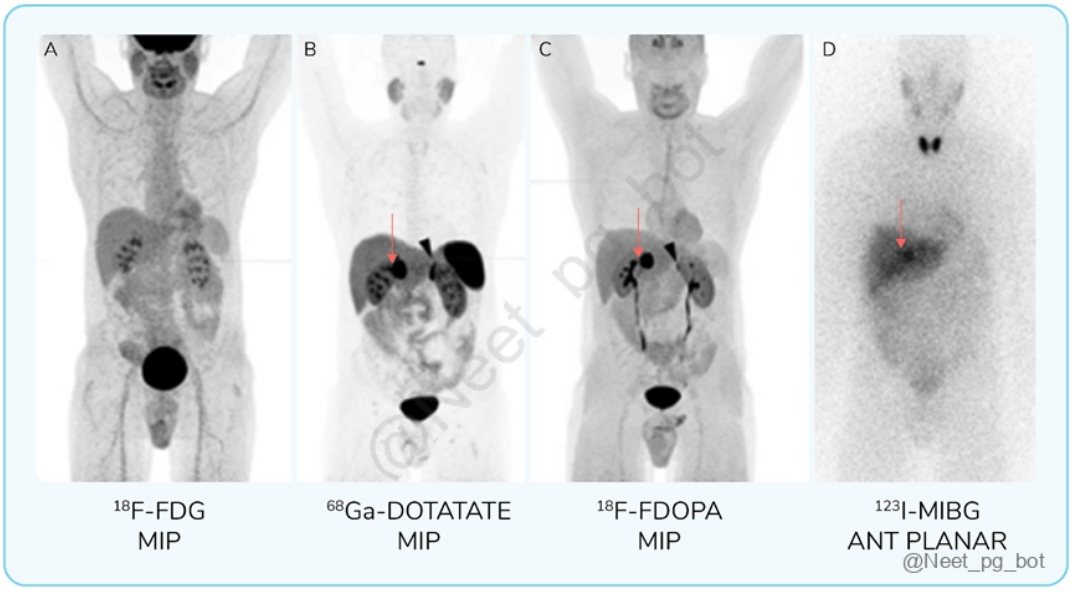

References:

Harrison's Principles of Internal Medicine, 21st edition, Page: 2976-2979.

↑ *Back to this question in Part A*

@Neet_pg_bot

Q9: A patient presents with a seizure. On evaluation, urine osmolality is 1000 mOsm/kg, and serum osmolality is 270 mOsm/kg. Which electrolyte abnormality can be expected in this patient? (Q856120)

A. Hypernatremia

B. Hyponatremia

C. Hyperkalaemia

D. Hypokalaemia

Correct Answer: B. Hyponatremia

Explanation: The serum osmolality is low (270 mOsm/kg, below the normal 285–295 mOsm/kg), indicating a diluted serum, while the high urine osmolality (1000 mOsm/kg) shows that the kidneys are still concentrating urine. This pattern is characteristic of euvolemic (dilutional) hyponatremia, most commonly seen in SIADH, where inappropriate ADH secretion leads to water retention and dilution of serum sodium. This severe dilutional hyponatremia can lower sodium levels enough to trigger seizures. Causes of euvolemic (dilutional) hyponatremia include: Drugs (desmopressin, oxytocin, antidepressants, opioids, thiazide diuretics, carbamazepine or its analogues, vincristine , nicotine, antipsychotics, chlorpropamide, cyclophosphamide , nonsteroidal anti-inflammatory drugs, MDMA) Syndrome of inappropriate antidiuretic hormone (SIADH) Increased ADH leads to water retention with near-normal sodium levels. Water overload leads to the release of ANP (Atrial natriuretic peptide) from atria. ANP causes natriuresis which leads to euvolemic hyponatremia. No edema occurs. Causes of SIADH: Tumours Central nervous system disorders: stroke, trauma, infection, psychosis, porphyria Pulmonary disorders: pneumonia, tuberculosis, obstructive lung disease Drugs: anticonvulsants, psychotropics, antidepressants, cytotoxics, oral hypoglycaemic agents, opiates Idiopathic Addison's disease Hypothyroidism High fluid intake in conditions like primary polydipsia or potomania, caused by a low intake of solutes with relatively high fluid intake Medical testing related to excessive fluids, such as a colonoscopy or cardiac catheterisation Iatrogenic Incorrect Options: Plasma osmolality in hypernatremia (Option A) would typically be associated with increased serum osmolality (>295 mOsm/kg) due to a deficit of water in relation to sodium. Hyperkalemia (Option C) refers to an elevated level of potassium in the blood. It is not related to the given scenario as it occurs in conditions of metabolic acidosis, particularly in kidney disease, where potassium excretion is impaired. Hypokalemia (Option D) is a condition characterized by a low level of potassium in the blood. It is caused by diuretics, GI losses, and hyperaldosteronism.

References:

Davidson's Principles and Practice of Medicine, 24th edition, Page: 357.

https://www.ncbi.nlm.nih.gov/books/NBK470386/#:

https://www.ncbi.nlm.nih.gov/books/NBK470386/#:

↑ *Back to this question in Part A*

@Neet_pg_bot

Q10: Hemodialysis is an indication for all the below conditions except? (Q856921)

A. Uremic encephalopathy

B. Peripheral neuropathy

C. Metabolic acidosis

D. Uremic pericarditis

Correct Answer: B. Peripheral neuropathy

Explanation: Peripheral neuropathy in CKD patients develops gradually and is less likely to improve rapidly with hemodialysis. It often requires long-term management of underlying renal disease and symptomatic treatment rather than acute dialysis. Indications of Hemodialysis: Indication Acute (AKI) Chronic(CKD) Fluid Overload Pulmonary edema Pulmonary Edema Severe Hypertension Edema resistant to diuretics Hyperkalemia >6.5 mmol/L with ECG changes (Broad QRS) Potassium resistant to treatment Uraemia Pericarditis (Option D) Encephalopathy (Option A) Uremic syndrome (anorexia, nausea, lethargy, etc.), typically when eGFR < 10 mL/min/1.73 m^2 Metabolic Acidosis (Option C) Severe acidosis(H^+ > 79 nmol/L ; pH < 7.1) Chronic acidosis resistant to bicarbonate therapy Relative indications Bleeding diathesis due to uremia-induced platelet dysfunction Intractable anemia despite erythropoietin and iron supplementation Hyperphosphatemia despite phosphate binders

References:

Davidson’s Principles and Practice of Medicine, 24th edition, Page 422

↑ *Back to this question in Part A*

@Neet_pg_bot

Q11: Which of the following options represents the most severe manifestation of Chronic Kidney Disease (CKD)? (Q856933)

A. Decreased GFR

B. Increased creatinine

C. Hyperkalaemia

D. Proteinuria

Correct Answer: C. Hyperkalaemia

Explanation: In CKD, declining GFR reduces the kidney’s ability to excrete potassium, leading to hyperkalemia , which can rapidly become life-threatening. Hyperkalemia is the most severe complication of CKD because it can

cause fatal cardiac arrhythmias and cardiac arrest . Decreased GFR, raised creatinine, and proteinuria indicate declining renal function but do not directly threaten life in the short term. Therefore, hyperkalemia is considered the most dangerous and severe manifestation requiring urgent management. Chronic Kidney Disease Leading causes Diabetic nephropathy (Most common) Glomerulonephritis Hypertension Ischemic heart disease (Cardiorenal syndrome) Autosomal dominant polycystic kidney disease Tubulointerstitial kidney disease Manifestations Weight loss Nausea Electrolyte Imbalances Hiccups (urea irritates gastric mucosa) Pedal oedema Muscle cramping and twitching Pruritus and skin pigmentation Uremic fetor Restless leg syndrome Uremic pericarditis Hypertension Fluid and serum electrolytes in CKD Electrolyte Imbalances Management Hypervolemic hyponatremia: High circulating aldosterone levels. Increase in water > sodium retention. Water restriction Hyperkalemia Patiromer Calcium resonium Sodium polystyrene Calcium gluconate or calcium chloride (for cardiac protection). Insulin and glucose (to shift potassium back into cells) Hypokalemia (rare): Usually due to overuse of diuretics Increase dietary intake and reduce the dose of diuretics Hyperphosphatemia Sevelamer Calcium acetate or carbonate Hypocalcemia Paricalcitol Decreased glomerular filtration rate (Option A) (GFR) is a hallmark of CKD and represents impaired kidney function. While decreased GFR is a key diagnostic criterion for CKD, it alone does not indicate the severity of the disease. The progression of CKD and its complications, such as hyperkalemia, are influenced by factors beyond the GFR. Increased creatinine (Option B) levels are indicative of reduced kidney function in CKD, they do not directly reflect the severity of the disease. Creatinine levels can also vary depending on various factors, including muscle mass, age, and hydration status. Proteinuria (Option D), the presence of excess protein in the urine, is a common finding in CKD. While it is an important marker of kidney damage and can be associated with disease progression, it is not considered the most severe manifestation of CKD.

References:

Harrison’s Principle of Internal Medicine, 21st edition, Page 2312, 2313

https://pubmed.ncbi.nlm.nih.gov/1619503/

K and pH

↑ *Back to this question in Part A*

@Neet_pg_bot

Q12: A 56-year-old man presents to the casualty with severe shortness of breath and fatigue for the past 3 hours. He reports a history of vomiting and epigastric pain 2 days back, for which he took an anti-emetic. His past medical history is significant for hypertension and diabetes mellitus type 1. As the CBG valve of this patient showed 356mg/dL, the physician advises immediate ABG analysis, which reveals a pH=7.32, pCO 2 =38mEq/L, and HCO 3 -=15mEq/L. This report showed a type of acidosis with an increased anion gap. Which of the following conditions does not belong to the same classification of metabolic acidosis as in this patient? (Q856972)

A. Renal failure

B. Lactic acidosis

C. Renal aciduria

D. Aspirin poisoning

Correct Answer: C. Renal aciduria

Explanation: Renal aciduria Renal aciduria refers to a condition characterized by the inability of the kidneys to effectively reabsorb bicarbonate or excrete hydrogen ions, leading to a decreased bicarbonate and metabolic acidosis. However, renal aciduria presents with normal anion gap metabolic acidosis (NAGMA). It is a form of renal tubular acidosis (RTA). Metabolic acidosis High anion gap (MUDPILES) (HAGMA) Non-anion gap (USED PART) (NAGMA) M ethanol poisoning U remia: AKI, CKD (Option A) D iabetic ketoacidosis P aracetamol poisoning I ron and isoniazid L actic acidosis (Option B) E thylene glycol poisoning S alicylate poisoning (Option D) U : Urinary diversion / Ureterenterostomy S : Small Bowel Fistula, S pironolactone and K-sparing diuretics, S aline infusion (rapid infusion) E : Extra Chloride D : Diarrhea P : Pancreatic fistula A : Addison, Acetazolamide R: RTA (Renal tubular acidosis) T : Tenofovir, Topiramate Reduced anion gap: Multiple myeloma and nephrotic syndrome

References:

Harrison’s Principle of Internal Medicine, 21st edition, Page 359 - 361, 364

↑ *Back to this question in Part A*

@Neet_pg_bot

Q13: An increased anion gap is seen in: (Q855362)

A. Respiratory acidosis

B. Respiratory alkalosis

C. Metabolic acidosis

D. Metabolic alkalosis

Correct Answer: C. Metabolic acidosis

Explanation: An increased anion gap occurs when there is accumulation of unmeasured acids in the blood. This is characteristic of metabolic acidosis . Metabolic acidosis High anion gap Non-anion gap M ethanol poisoning U remia: AKI, CKD D iabetic ketoacidosis P aracetamol poisoning I ron and isoniazid L actic acidosis E thylene glycol poisoning S alicylate poisoning H yperchloremia A ddison's disease R enal tubular acidosis D iarrhoea and conditions causing GI loss of HCO3- (ureterosigmoidostomy or external bowel drainage) A cetazolamide S pironolactone and K-sparing diuretics S aline infusion (rapid infusion) Reduced anion gap: Multiple myeloma and nephrotic syndrome Respiratory acidosis and Respiratory alkalosis (Options A and B) normal anion gap Metabolic alkalosis (Options D): normal AG or slightly ↓ anion gap

References:

Harrison’s Principle of Internal Medicine, 21st Edition, Page 359 - 361, 364

↑ *Back to this question in Part A*

@Neet_pg_bot

Q14: A 55-year-old man with long-standing diabetes mellitus and end-stage renal disease (eGFR <20 mL/min) is being evaluated for renal transplantation. Which of the following statements correctly describes an ideal candidate outcome or consideration for renal graft transplant in a patient with diabetic nephropathy? (Q856285)

A. The survival rate of graft is 95% in the first year

B. The transplantation is cost effective after the second transplant year

C. The life expectancy is doubled in a diabetic patient with renal transplant

D. The treatment of chronic rejection has improved over the last 10 years

Correct Answer: B. The transplantation is cost effective after the second transplant year

Explanation: Renal transplantation is the treatment of choice for end-stage renal disease (ESRD) in patients with diabetic nephropathy , as it improves both quality of life and long-term survival compared to dialysis. Although the initial cost of transplantation is higher, it becomes cost-effective after approximately two years due to reduced ongoing treatment expenses and improved patient outcomes. The survival rate of the graft is 95% in the first year (Option A) While the survival rate of renal grafts in the first year can be relatively high, it is not consistently 95% for all patients. The life expectancy is doubled in a diabetic patient with renal transplant(Option C) Renal transplantation can increase life expectancy in patients with ESRD, it does not necessarily double it. The treatment of chronic rejection has improved over the last 10 years(Option D) Chronic rejection remains a challenge in renal transplantation.

References:

Bailey and Love’s Short Practice of Surgery, 28th edition, Page 1602-1607

Sabiston Textbook of Surgery, 21st edition, Page 628

↑ *Back to this question in Part A*

@Neet_pg_bot

Q15: Calculate the sodium deficit in the male patient, who weighs 60 kg, using the provided serum electrolyte values: pH of 7.42, sodium (Na+) level of 120 mEq/L, and serum chloride (CI-) level of 90 mEq/L. (Q856302)

A. 20 mEq

B. 200 mEq

C. 400 mEq

D. 720 mEq

Correct Answer: D. 720 mEq

Explanation: Sodium Deficit Formula: Sodium deficit = (Desired Na■ - Actual Na■) × Total Body Water (TBW) Total Body Water (TBW): TBW = 0.6 × Body Weight(for males) = 0.5 x Body Weight(for females) TBW for this patient: 0.6 × 60 kg = 36 litres Desired Sodium Increase: The target increase in serum sodium = 140 mEq/L - 120 mEq/L = 20 mEq/L Sodium Deficit Calculation: Sodium deficit = 20 mEq/L × 36 L = 720mEq Safe Increase in Sodium: In acute symptomatic hyponatremia with seizures, an initial rapid correction of 4-6 mEq/L in the first few hours is recommended to stabilize neurological symptoms. The total correction should not exceed 8-12 mEq/L in the first 24 hours to avoid complications such as osmotic demyelination syndrome.

References:

Sodium deficit correction

↑ *Back to this question in Part A*

@Neet_pg_bot

Q16: In the given acid-base nomogram diagram, areas marked A and D indicated which of the following conditions? (Q856341)

A. Chronic respiratory acidosis, acute metabolic alkalosis

B. Acute metabolic alkalosis, acute respiratory acidosis

C. Acute respiratory acidosis, acute respiratory alkalosis

D. Acute respiratory acidosis, acute metabolic alkalosis

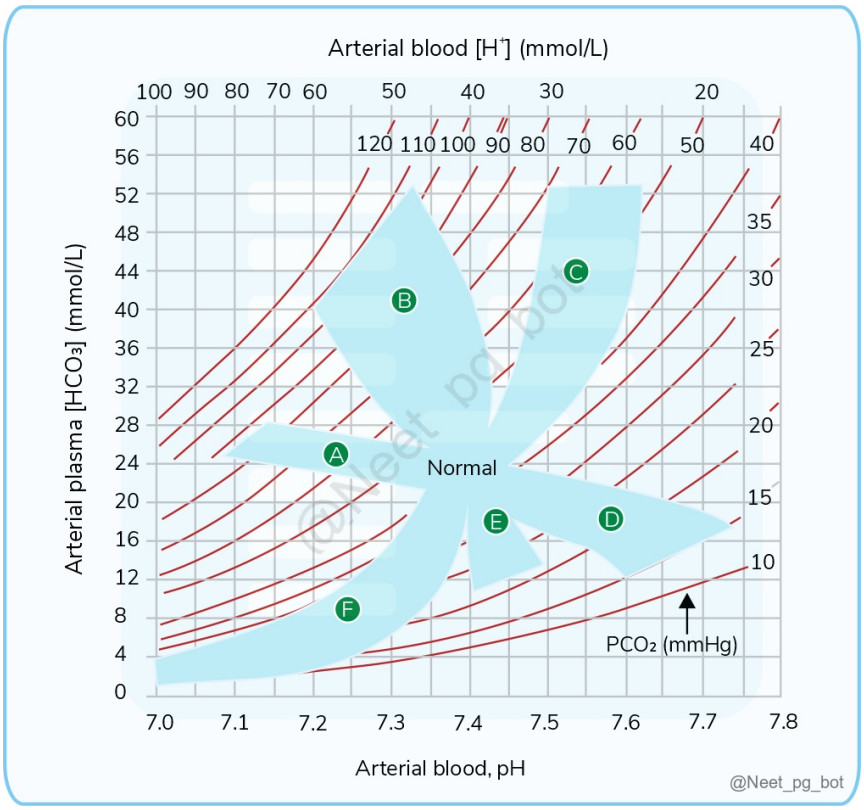

Correct Answer: C. Acute respiratory acidosis, acute respiratory alkalosis

Explanation: A - Acute respiratory acidosis occurs when there is an increase in the partial pressure of carbon dioxide (PaCO 2) in the blood due to inadequate ventilation. This can be caused by conditions such as pneumonia, pulmonary edema, or airway obstruction. D - Acute respiratory alkalosis occurs when there is a decrease in PaCO 2 in the blood due to excessive ventilation. It can be caused by hyperventilation due to anxiety, fever, or high altitude. Acid-base disorders Simple acid-base disorders and their compensatory mechanisms: Primary respiratory disturbances (changes in PaCO■) lead to metabolic compensation (changes in [HCO■■]). Primary metabolic disturbances (changes in [HCO■■]) lead to respiratory compensation (changes in PaCO■). Compensation moves pH toward normal , but typically does not fully correct it, except for chronic respiratory alkalosis , which may restore normal pH. Metabolic acidosis (e.g., from ketoacidosis or lactic acidosis) lowers [HCO■■] and extracellular pH , triggers ventilation (lowers PaCO■) to compensate. Winter's equation predicts expected PaCO■ in metabolic acidosis: PaCO■= (1.5×[HCO3–]) + 8 ± 2 Example: If [HCO■■] = 12 mmol/L , expected PaCO■ ≈ 26 mmHg ± 2 If PaCO■ is <24 mmHg or >28 mmHg , a mixed disorder (e.g., metabolic acidosis + respiratory alkalosis/acidosis) is likely to be present. Compensation direction : Metabolic disorders : PaCO■ moves in same direction as [HCO■■] . Respiratory disorders : [HCO■■] moves in same direction as PaCO■ . Mixed acid-base disorders and the use of an acid-base nomogram : Opposing Changes Indicate a Mixed Disorder: If PaCO■ and [HCO■■] move in opposite directions (one increases while the other decreases), a mixed acid-base disorder is present. Example: PaCO■ increases (respiratory acidosis) while [HCO■■] decreases (metabolic acidosis) → Mixed acidosis . Acid-Base Nomogram: An acid-base nomogram is a graphical tool used to analyze and interpret acid-base disturbances in the body. It helps in determining the primary acid-base disorder and assessing compensatory responses. The nomogram typically consists of a graph with axes representing the partial pressure of carbon dioxide (PaCO2) and the bicarbonate (HCO3-) concentration. The diagonal lines on the graph represent different levels of blood pH. The shaded areas represent the 95% confidence limits for compensation in simple disorders . Values within the shaded area do not rule out a mixed disorder , since

overlapping conditions might mimic a different disorder. Equations vs Nomogram: The nomogram is useful but not a substitute for calculations. Equations like Winter’s equation provide a more precise assessment of compensation. Disorder Prediction of Compensation Range of Values (pH, HCO■■, PaCO■) Metabolic Acidosis PaCO■ = (1.5 × HCO■■) + 8 ± 2 / PaCO■ ↓ 1.25 mmHg per mmol/L ↓ in HCO■■ / PaCO■ = HCO■■ + 15 Low, Low, Low Metabolic Alkalosis PaCO■ ↑ 0.75 mmHg per mmol/L ↑ in HCO■■ PaCO■ ↑ 6 mmHg per 10 mmol/L ↑ in HCO■■ PaCO■ = HCO■■ + 15 High, High, High Respiratory Alkalosis Acute: HCO■■ ↓ 0.2 mmol/L per mmHg ↓ in PaCO■ Chronic: HCO■■ ↓ 0.4 mmol/L per mmHg ↓ in PaCO■ High, Low, Low Respiratory Acidosis Acute: HCO■■ ↑ 0.1 mmol/L per mmHg ↑ in PaCO■ Chronic: HCO■■ ↑ 0.4 mmol/L per mmHg ↑ in PaCO■ Low, High, High

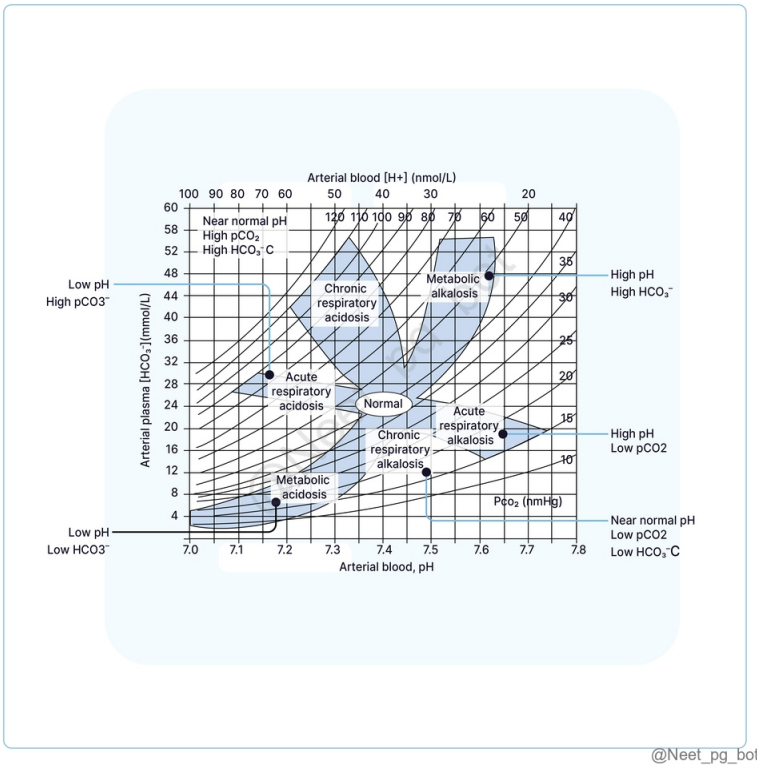

References:

Harrison's Principles of Internal Medicine, 21st edition, Page 359, 360

↑ *Back to this question in Part A*

@Neet_pg_bot

Q17: A mutation in the gene for the aquaporin channel leads to which of the following conditions? (Q855043)

A. Liddle’s syndrome

B. Nephrogenic DI

C. Cystic fibrosis

D. Barter syndrome

Correct Answer: B. Nephrogenic DI

Explanation: I): It is a disorder characterized by excessive hypotonic urinary output (>50 mL/kg body weight per 24 hours) and polydipsia (>3 litres/day). It results from an inability to concentrate urine adequately due to a deficiency or insensitivity to antidiuretic hormone (ADH). Types of Diabetes Insipidus: Feature Central DI Nephrogenic DI Primary Polydipsia Gestational DI Definition Deficiency of AVP (Arginine vasopressin) secretion from the pituitary gland. Kidneys are unable to respond to AVP, even if levels are normal. Excessive water intake, suppressing AVP secretion. Increased activity of placental enzyme degrading AVP during pregnancy. Causes Acquired : Head trauma, tumours, granulomas, infections, inflammation, toxins, vascular events, hypoxia. Acquired : Drugs (lithium, demeclocycline), metabolic disorders (hypercalcaemia, hypokalaemia), obstruction, vascular issues, granulomas, tumours, and infiltration. Dipsogenic : Inappropriate thirst, head trauma, brain diseases. Increased placental vasopressinase activity. Psychogenic : Psychiatric conditions, compulsive water drinking. Genetic : Mutations in the AVP–neurophysin II or WFS1 genes. Genetic: Mutations in the V2 receptor or aquaporin-2 genes. Iatrogenic : Belief in the health benefits of excessive water intake. Basal Plasma AVP Low or undetectable (<1 pg/mL). Normal or elevated (>1 pg/mL). Low due to suppression by excessive water intake. Low due to increased degradation. Urine Osmolarity Low (<280 mOsm/L). Low (<280 mOsm/L). Low (<280 mOsm/L) but can temporarily concentrate with fluid deprivation. Low (<280 mOsm/L). Plasma Osmolarity Increased Increased Decreased Increased Fluid Deprivation Test Urine does not concentrate. AVP or desmopressin injection increases urine osmolarity in severe CDI. Urine does not concentrate. AVP or desmopressin injection has no effect on severe NDI. Plasma osmolarity and sodium increase above normal without urine concentration. Not typically performed during pregnancy. MRI Posterior pituitary bright spot absent or small. Posterior pituitary bright- spot may be faint or absent. Posterior pituitary bright spot present. Not routinely used for diagnosis. Desmopressin (DDAVP) Trial Abolishes polyuria and polydipsia; reduces plasma osmolarity/sodium. No effect on urine output, fluid intake, or plasma osmolarity/sodium. Eliminates polyuria but not polydipsia, leading to hyponatremia. Effective in controlling symptoms. Plasma Copeptin Low or undetectable. It may be normal or elevated. Suppressed due to low AVP. It may be low due to AVP degradation. Treatment Desmopressin (DDAVP). Thiazide diuretics, amiloride, low-sodium diet, prostaglandin inhibitors. Behavioral therapy, education about overhydration. Desmopressin (DDAVP). Resolution Lifelong treatment usually needed for acquired CDI Genetic forms may improve. Dependent on the underlying cause Lithium-induced NDI may persist. Dependent on behavioural modification and addressing the underlying cause. Usually, it resolves after delivery. Liddle’s syndrome (Option A) is caused by an inherited gain-of-function mutation in genes regulating the ENaC (epithelial sodium channel) in the collecting duct. Cystic fibrosis (Option C) is an autosomal recessive disorder caused by mutations in the CFTR gene, which encodes a chloride channel in the luminal plasma membranes of epithelial cells. Bartter syndrome (Option D) results from loss-of-function mutations in transporters and ion channels in the thick ascending limb of the loop of Henle, most frequently affecting the Na-K-2Cl transporter.

References:

Harrison's Principles of Internal Medicine, 21st Edition, Page 337- 339, 346, 2918- 2926
https://pubmed.ncbi.nlm.nih.gov/34718110/

↑ *Back to this question in Part A*

@Neet_pg_bot

Q18: A 30-year-old woman presents to the OPD with palpitation and weight loss. On examination of her legs the following lesion was found which on applying pressure, the indentation does not persist on release. ECG shows sinus rhythm. What is the probable cause of the oedema? (Q859558)

A. Myxedema

B. Nephrotic syndrome

C. Chronic lymphangitis

D. Dilated cardiomyopathy

Correct Answer: A. Myxedema

Explanation: The patient has palpitations and weight loss, suggestive of hypermetabolic or hyperthyroid state. The leg lesion described is a form of edema where indenting the swollen area does not leave a persistent indentation on release —this is non-pitting edema . ECG shows sinus rhythm (normal heart rhythm), so no arrhythmia implying heart failure currently. Myxedema causes non-pitting edema due to mucopolysaccharide (glycosaminoglycan) deposition in the skin and tissues, commonly seen in severe hypothyroidism. The edema does not pit on pressure. Nephrotic syndrome (Option B) : Causes pitting edema due to low albumin and fluid retention. Chronic lymphangitis (Option C) : Usually causes non-pitting edema along with skin changes but is an inflammatory condition often with signs of infection. Dilated cardiomyopathy (Option D) : Usually causes pitting edema due to heart failure and fluid overload.

References:

Harrison’s Principles of Internal Medicine, 21st Edition, Page: 2282, 2283.

Davidson’s Principles and Practice of Medicine, 24th Edition, Page: 395.

↑ *Back to this question in Part A*

@Neet_pg_bot

Q19: A hepatitis B-positive adult presents with massive proteinuria (>3.5 g/day). Renal biopsy was performed as shown below. What is the most likely diagnosis? (Q859566)

A. Focal segmental glomerulosclerosis

B. Membranous glomerulonephritis

C. Membranoproliferative glomerulonephritis

D. Minimal change disease

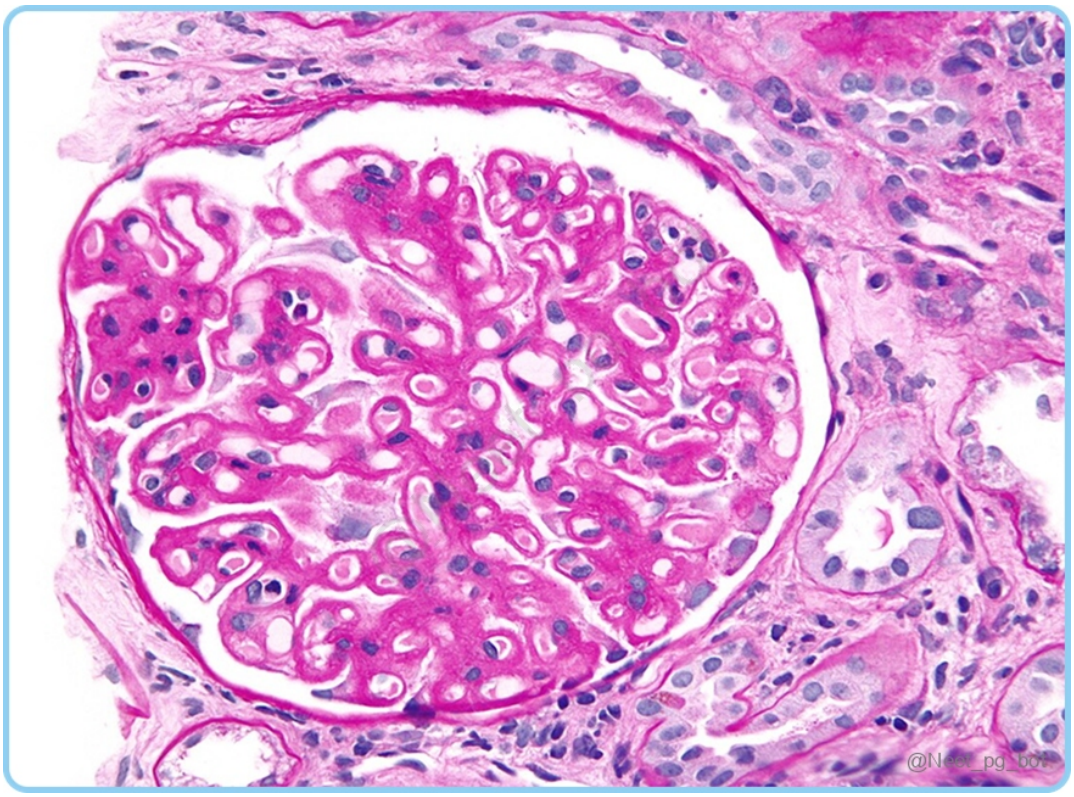

Correct Answer: B. Membranous glomerulonephritis

Explanation: The patient is a hepatitis B-positive adult with nephrotic-range proteinuria . features are Light Microscopy findings (as seen in the image) are classic for membranous glomerulonephritis (MGN) Uniform thickening of glomerular capillary walls along peripheral loops. No significant hypercellularity (distinguishes from MPGN). {{caption_text}} Immunofluorescence: Diffuse granular deposits of IgG and C3 Electron Microscopy: Dense subepithelial deposits Spike & dome appearance (arrows & asterisk) {{caption_text}} Autoantibody Testing: Autoantibodies against M-type phospholipase A2 receptor (PLA2R) are present in 70% of cases. Thrombospondin type-1 domain containing 7A (THSD7A) (3-10%) Secondary MGN often lacks these autoantibodies. Focal segmental glomerulosclerosis (FSGS) (Option A) is characterized by scarring and sclerosis of certain glomeruli in a focal and segmental pattern. Membranoproliferative glomerulonephritis (MPGN) (Option C) is characterized by both thickening and proliferation of the glomerular basement membrane. Minimal change disease (Option D) is a common cause of nephrotic syndrome in children but is less common in adults.

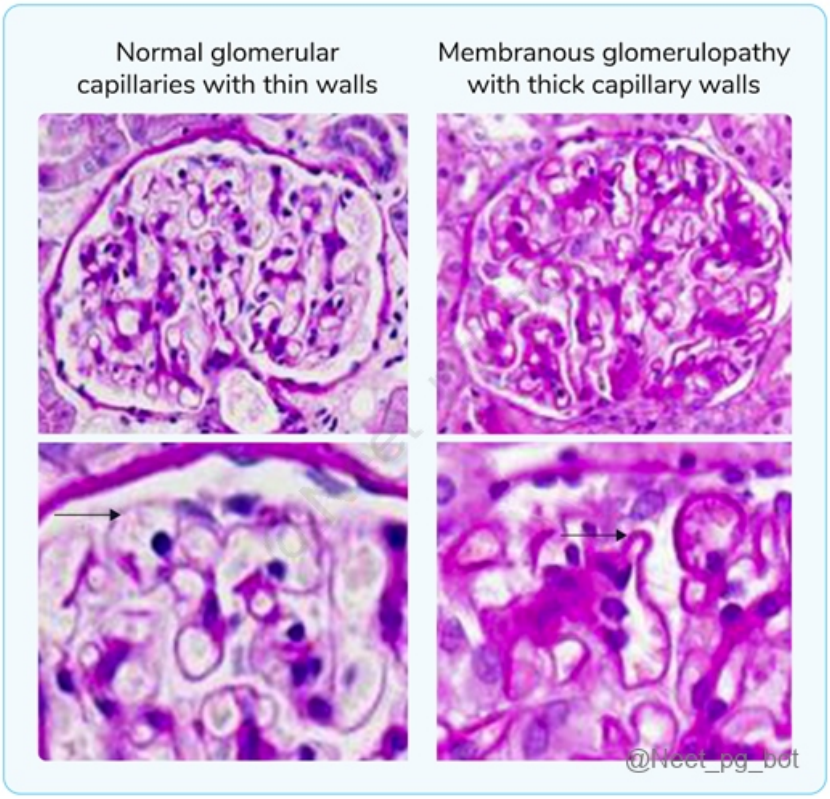

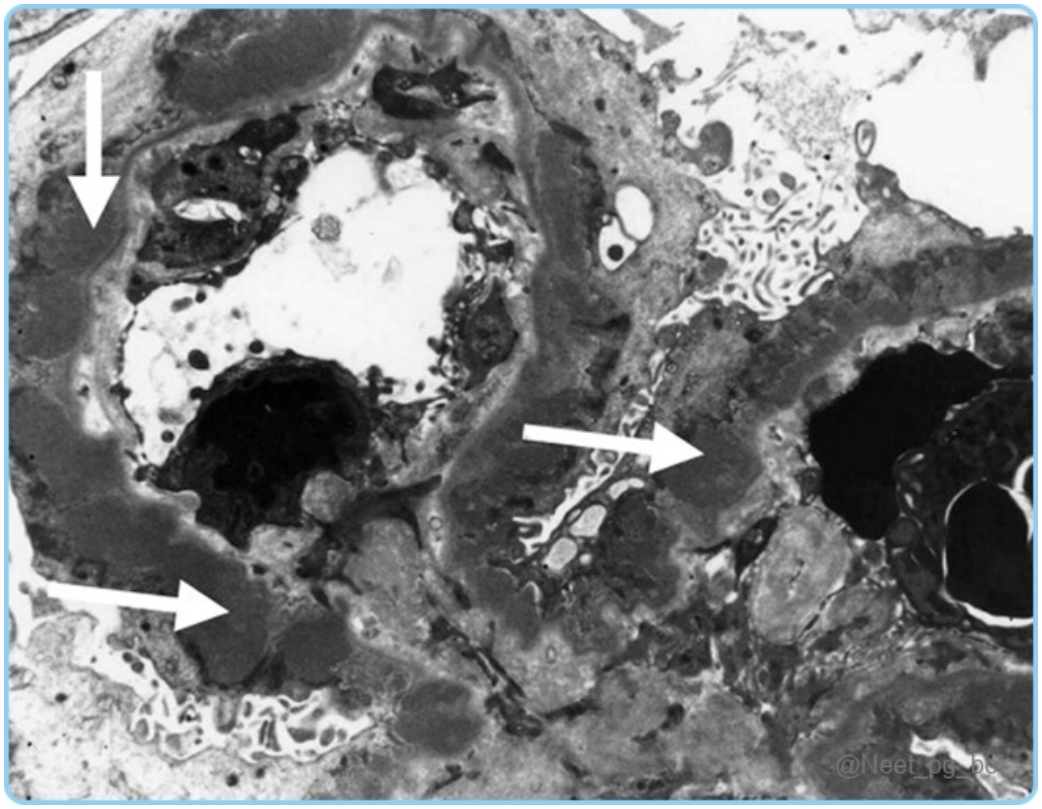

References:

Harrison’s Principles of Internal Medicine, 21st Edition, Page: 2342, 2343.

Davidson’s Principles and Practice of Medicine, 24th Edition, Page: 398.

↑ *Back to this question in Part A*

@Neet_pg_bot

Q20: Which of the following agents is most likely causing the condition in a 60-year-old woman, who had a kidney transplant 2 months ago, and is now experiencing a high fever, severe difficulty in breathing, and a dry cough with a hacking sound? A chest x-ray shows widespread interstitial infiltrates in both lungs, and urine examination reveals the presence of cells with an 'owl-eye' appearance. (Q859782)

A. Adenovirus

B. Cytomegalovirus

C. Influenza virus

D. Respiratory syncytial

Correct Answer: B. Cytomegalovirus

Explanation: Cytomegalovirus infection is the most common opportunistic infection post renal transplantation, and it usually occurs within 1- 6 months of transplantation. Complications following Renal transplant Graft rejection Hyperacute, acute and chronic Opportunistic infections < 1 Month: Wound infection, HSV, UTI, Oral candidiasis 1-6 Months: CMV (most common), HBV, HCV, Pneumocystis carinii, Listeria >6 Months: BK Virus , Aspergillus, Nocardia, HBV, HCV, HZV Hypercalcemia This may indicate failure of parathyroid gland regression post-transplant. Anemia Common post-transplant, often due to immunosuppressive medications. Gastrointestinal bleeding can occur from steroid use. Chronic hepatitis Particularly from hepatitis B virus, which can progress over time. Skin and lip cancers Most common malignancy The leading causes of death among kidney transplant recipients include: Cardiovascular events (29%) Infections (18%) Malignancies (17%)

References:

Harrison’s Principle of Internal Medicine, 21st Edition, Page: 2330.

↑ *Back to this question in Part A*

@Neet_pg_bot

Q21: A patient exhibits symptoms of increased urination, nighttime urination, and involuntary urination, along with a recorded 24-hour urine volume of 7 litres. He has

a urine osmolarity of 260 mOsm/L. The ADH assay shows a recorded value of 0.8 pg/ml, and an MRI of the brain reveals the absence of a bright spot on T1-weighted imaging. What is the probable diagnosis? (Q859788)

A. Nephrogenic DI

B. Primary polydipsia

C. Pituitary DI

D. Mannitol infusion

Correct Answer: C. Pituitary DI

Explanation: The above case is most suggestive of pituitary diabetes insipidus. The absence of a pituitary bright spot is suggestive of central DI. Feature Central DI (Option C) Nephrogenic DI (Option A) Primary Polydipsia (Option B) Gestational DI Definition Deficiency of AVP (Arginine vasopressin) secretion from the pituitary gland . Kidneys are unable to respond to AVP, even if levels are normal. Excessive water intake suppresses AVP secretion. Increased activity of placental enzyme degrading AVP during pregnancy. Causes Acquired : Head trauma, tumours, granulomas, infections, inflammation, toxins, vascular events, hypoxia. Acquired : Drugs (lithium, demeclocycline), metabolic disorders (hypercalcaemia, hypokalaemia), obstruction, vascular issues, granulomas, tumours, and infiltration. Dipsogenic : Inappropriate thirst, head trauma, brain diseases. Increased placental vasopressinase activity. Psychogenic : Psychiatric conditions, compulsive water drinking. Genetic : Mutations in the AVP–neurophysin II or WFS1 genes. Genetic : Mutations in the V2 receptor or aquaporin-2 genes. Iatrogenic : Belief in the health benefits of excessive water intake. Basal Plasma AVP Low or undetectable (<1 pg/mL). Normal or elevated (>1 pg/mL). Low due to suppression by excessive water intake. Low due to increased degradation. Urine Osmolarity Low (<280 mOsm/L). Low (<280 mOsm/L). Low (<280 mOsm/L) but can temporarily concentrate with fluid deprivation. Low (<280 mOsm/L). Plasma Osmolarity Increased Increased Decreased Increased Fluid Deprivation Test Urine does not concentrate. AVP or desmopressin injection increases urine osmolarity in severe CDI. Urine does not concentrate. AVP or desmopressin injection does not affect severe NDI. Plasma osmolarity and sodium increase above normal without urine concentration. Not typically performed during pregnancy. MRI Posterior pituitary bright spot absent or small. The posterior pituitary bright- spot may be faint or absent. Posterior pituitary bright spot present. Not routinely used for diagnosis. Desmopressin (DDAVP) Trial Abolishes polyuria and polydipsia; reduces plasma osmolarity/sodium. No effect on urine output, fluid intake, or plasma osmolarity/sodium. Eliminates polyuria but not polydipsia, leading to hyponatremia. Effective in controlling symptoms. Plasma Copeptin Low or undetectable. It may be normal or elevated. Suppressed due to low AVP. It may be low due to AVP degradation. Treatment Desmopressin (DDAVP). Thiazide diuretics, amiloride, low-sodium diet, prostaglandin inhibitors. Behavioural therapy, education about overhydration. Desmopressin (DDAVP). Resolution Lifelong treatment is usually needed for acquired CDI Genetic forms may improve. Dependent on the underlying cause Lithium-induced NDI may persist. Dependent on behavioural modification and addressing the underlying cause. Usually, it resolves after delivery. In mannitol infusion (Option D) , the urine osmolality is >300 mOsm/L.

References:

Harrison's Principles of Internal Medicine, 21st Edition, Pages 337, 378, 339, 346, 2918- 2926

↑ *Back to this question in Part A*

@Neet_pg_bot

Q22: A 10-year-old male child presents with headache and cola-colored urine. His parents report throat pain 2 weeks ago. Work up shows RBC casts in urine and his KFT is increased two fold. What is the likely light microscopy finding in this case? (Q859810)

A. Spike and dome appearance

B. Starry sky appearance

C. Enlarged hypercellular glomeruli with obliteration of bowman space

D. Electron dense deposits

Correct Answer: C. Enlarged hypercellular glomeruli with obliteration of bowman space

Explanation: owman space: This child has acute post-streptococcal glomerulonephritis (PSGN), suggested by cola-colored urine, RBC casts, recent throat infection, and an acute rise in KFT. On light microscopy, PSGN classically shows diffuse endocapillary proliferative glomerulonephritis, with enlarged, hypercellular glomeruli due to proliferation of mesangial and endothelial cells and leukocyte infiltration. This leads to narrowing or obliteration of capillary lumina and the Bowman space. Incorrect Options: Option A - Spike and dome appearance: This is a feature of membranous nephropathy seen on electron microscopy due to subepithelial immune complex deposition. It is not seen in PSGN. Option B - Starry sky appearance: This refers to the granular immune complex deposition of IgG and C3 on immunofluorescence, not a light microscopy finding. Option D - Electron-dense deposits: Electron-dense subepithelial “humps” are seen on electron microscopy, not light microscopy.

References:

Harrison’s Principles of Internal Medicine, 21st Edition, Volume I, Page 2337

Davidson’s Principles and Practice of Medicine, 24th Edition, Page 401.

Robbins and Cotran’s Pathologic Basis of Diseases, 10th Edition, Elsevier, Page, 906-909.

↑ *Back to this question in Part A*

@Neet_pg_bot

Q23: Which of the following clinical conditions are correctly matched with their anion gap status? Starvation – Increased anion gap Diabetic ketoacidosis – Increased anion gap Severe vomiting – Increased anion gap (Q879184)

A. Only b is correct

B. a and b are correct

C. a and c are correct

D. Only a is correct

Correct Answer: B. a and b are correct

Explanation: Starvation and diabetic ketoacidosis (DKA) cause increased anion gap metabolic acidosis due to the accumulation of ketone bodies (acetoacetate and β-hydroxybutyrate) in the blood. Severe vomiting leads to loss of gastric acid (HCl), resulting in metabolic alkalosis, not increased anion gap acidosis.

References:

Harrison's Principles of Internal Medicine, 21st Edition, Page 2107.

↑ *Back to this question in Part A*

@Neet_pg_bot

Q24: An 8-year-old child with a history of GTCS came with an episode of convulsions for more than 45 minutes. What will be the appropriate management for this patient? (Q860439)

A. Lorazepam followed by levetiracetam

B. Valproate followed by gabapentin

C. Carbamazepine followed by lorazepam

D. Levetiracetam followed by valproate

Correct Answer: A. Lorazepam followed by levetiracetam

Explanation: Status epilepticus (SE) is defined as continuous seizures or repetitive, discrete seizures with impaired consciousness lasting more than 30 minutes. They are generally of 2 types: Generalized convulsive status epilepticus (GCSE) GCSE is an emergency and must be treated immediately (e.g., persistent, generalized electrographic seizures, coma, and tonic-clonic movements). Nonconvulsive status epilepticus (NCSE) E.g., persistent absence seizures or focal seizures with confusion or partially impaired consciousness, and minimal motor abnormalities. In the case of impending and early SE, the standard protocol involves administering IV lorazepam 0.1 mg/kg followed by levetiracetam 20-30 mg/kg . For established and early refractory SE, the treatment progresses to Propofol 2 mg/kg IV followed by 2-10 mg/kg/hr with the addition of anticonvulsants like levetiracetam . Management of Status Epilepticus: Valproate followed by gabapentin (Option B) : While valproate can be used in the treatment of GTCS, this combination is not the standard first-line treatment for status epilepticus. Gabapentin is typically used for chronic seizure management rather than acute status epilepticus.

Carbamazepine followed by lorazepam (Option C) : Carbamazepine is primarily used in the treatment of partial or focal seizures and is not appropriate for acute status epilepticus. Additionally, benzodiazepines should be administered first in status epilepticus, not after other anticonvulsants. Levetiracetam followed by valproate (Option D) : This sequence is incorrect as benzodiazepines (lorazepam) should be the first-line treatment in early status epilepticus.

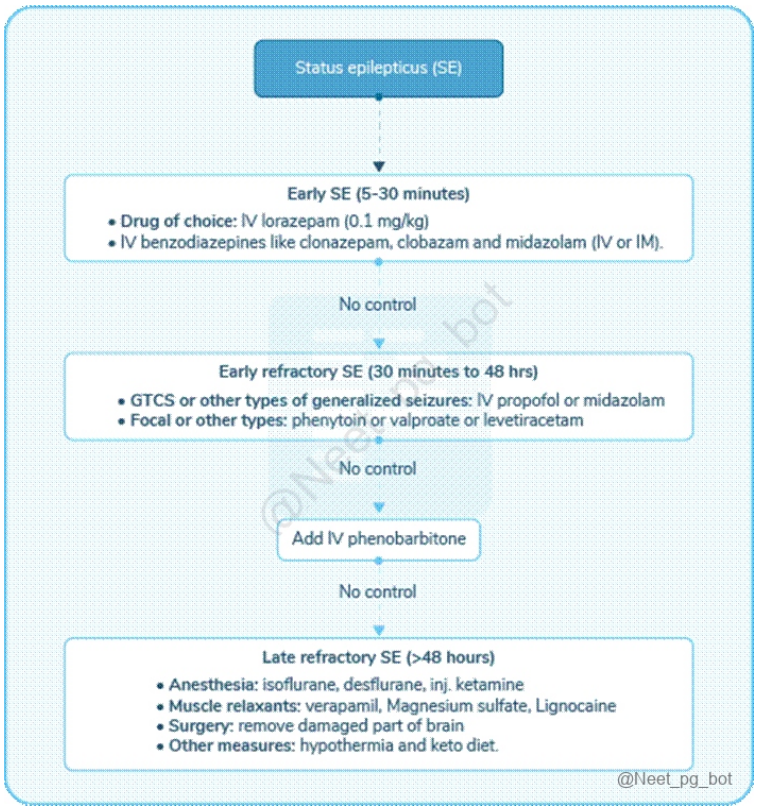

References:

Harrison’s Principle of Internal Medicine, 21st Edition, Page, 3317.

KDT- Essentials of Pharmacology, 8th Edition, Page, 449.

↑ *Back to this question in Part A*

@Neet_pg_bot

Q25: A patient after RTA had a renal shut down. Work-up shows: FeNa: < 1%, Urine osmolality: 300 mOsm/kg, Urinary sodium: 40 mEq/L. Most likely diagnosis? (Q866812)

A. Acute Tubular Necrosis

B. Pre-renal AKI

C. Post-renal AKI

D. Renal AKI

Correct Answer: A. Acute Tubular Necrosis

Explanation: This presentation points to intrinsic renal injury , specifically ATN , where damaged renal tubules lose the ability to reabsorb sodium and concentrate urine. Key features in this case: Urinary sodium > 40 mEq/L → tubular sodium wasting Urine osmolality ~300 mOsm/kg → isosthenuria (urine similar to plasma) FeNa < 1% is more typical of pre-renal AKI, but in early ATN or mixed states it can also be low. Here, the high urinary sodium and poor urine concentration outweigh FeNa alone, supporting ATN. Clinical Phases of ATN Phase Description Prerenal Phase (Pre-ATN) ↓ Renal perfusion (e.g., hypovolemia, CHF) Tubular function intact FeNa <1%, BUN:Cr >20 Responds to fluids Reversible if corrected early Initiation Phase Time of original injury (ischemia/toxins) Mild ↓ GFR, slight ↑ creatinine Urine output may be normal Damage beginning but potentially reversible Extension Phase Ongoing injury + inflammation (days 1–3) Tubular necrosis, obstruction Key sign: ↑ Creatinine + new oliguria despite fluids FeNa >2%, granular casts may appear Maintenance Phase Established tubular damage Low GFR, sustained ↑ creatinine/BUN Oliguric or non-oliguric Electrolyte imbalances: hyperkalemia, acidosis Recovery (Repair) Phase Tubular regeneration Polyuric phase: ↑ urine output Gradual ↓ creatinine Risk: volume depletion, electrolyte loss Pre-renal AKI (Option B): Characterized by low urinary sodium (<20 mEq/L) and high urine osmolality (>500 mOsm/kg) . Post-renal AKI (Option C): Labs are variable; diagnosis usually requires imaging evidence of obstruction. Renal AKI (Option D): Too broad; ATN is the specific intrinsic renal diagnosis here.

References:

.

↑ *Back to this question in Part A*

@Neet_pg_bot

Q26: A 58-year-old male presents with complaints of burning micturition. Prostatic examination was normal. Urinalysis shows >50 pus cells per high power field, but urine culture shows no growth. What is the most likely diagnosis? (Q865326)

A. Chronic bacterial prostatitis

B. Acute bacterial prostatitis

C. Granulomatous prostatitis

D. Sterile pyuria

Correct Answer: D. Sterile pyuria

Explanation: Sterile pyuria is defined as the presence of >10 WBCs/mm³ or >3 WBCs/HPF in unspun urine, or a positive dipstick for leukocyte esterase/nitrites , without significant bacteriuria (i.e., <10■ CFU/mL on culture). It is the presence of pus cells in urine without bacterial growth on culture . It can result from non-bacterial infections (e.g., tuberculosis), inflammatory conditions , or prior antibiotic use. A normal prostate exam and no bacterial growth despite significant pyuria support this diagnosis. Incorrect Options: Chronic bacterial prostatitis (Option A): Typically shows positive urine culture and may have prostatic tenderness . Acute bacterial prostatitis (Option B): Presents with fever, painful prostate on DRE , and positive culture . Granulomatous prostatitis (Option C): Rare, often associated with tuberculosis , would show prostatic abnormalities .

References:

Sterile Pyuria - StatPearls - NCBI Bookshelf

↑ *Back to this question in Part A*

@Neet_pg_bot

Q27: A 56-year-old diabetic male presents with a complicated urinary tract infection and is found to be hypotensive. His blood pressure does not respond to intravenous fluids. Which of the following is the most appropriate antibiotic to manage his condition? (Q865371)

A. Amoxicillin-Clavulanate

B. Nitrofurantoin

C. Meropenem

D. Ciprofloxacin

Correct Answer: C. Meropenem

Explanation: Meropenem is the most appropriate antibiotic for a diabetic patient in septic shock due to a complicated UTI, providing necessary broad-spectrum coverage, including for ESBL-producing organisms. In the given scenario, the patient with a complicated UTI and septic shock is most likely infected with Pseudomonas or Klebsiella, for which the drug of choice is meropenem, a Carbapenem antibiotic. MOA: Inhibits transpeptidase (penicillin-binding protein) and prevents cross-linking. Drugs: Imipenem Meropenem Faropenem Doripenem Ertapenem Uses of carbapenems: Used in nosocomial infections. Meropenem is a reserve drug for the treatment of serious nosocomial infections like septicaemia, febrile neutropenia, intraabdominal and pelvic infections, etc., caused by cephalosporin-resistant bacteria and diabetic foot. (Option C) DOC in Acinetobacter baumannii (Ventilator-associated pneumonia) Klebsiella Burkholderia Serratia Proteus Pseudomonas Incorrect Options: Amoxicillin-clavulanate (amoxiclav) (Option A) is ineffective for complicated UTIs with resistant Pseudomonas or ESBL-producing Klebsiella and is unsuitable for severe infections where meropenem is preferred. Nitrofurantoin (Option B) is effective for uncomplicated lower UTIs but poorly penetrates blood and renal tissue, making it ineffective for complicated UTIs or septic shock. It also lacks activity against Pseudomonas and many Klebsiella strains in severe infections. Ciprofloxacin (Option D) has broad activity, including against

Pseudomonas, but rising resistance in hospital settings limits its use. It is not first-line for critically ill septic patients, where meropenem is preferred.

References:

KDT - Essentials of Pharmacology 8th Edition, Page 782-783.

Complicated UTI - Infectious Disease Advisor

Complicated Urinary Tract Infections - StatPearls - NCBI Bookshelf

↑ *Back to this question in Part A*

@Neet_pg_bot

Q28: A 60-year-old man with chronic kidney disease presents with complaints of increasing fatigue, dyspnea on exertion, and signs of congestive heart failure. On evaluation, he is found to have anemia. Work up shows Hb=7 gm/dl and Peripheral Smear shows Normocytic normochromic anemia. What is the next step in management of this case? (Q866502)

A. Oral iron therapy

B. IV iron infusion

C. Blood transfusion

D. Darbepoetin alfa

Correct Answer: D. Darbepoetin alfa

Explanation: Normocytic anemia (Hb 7 g/dl) in CKD with CHF symptoms is due to erythropoietin (EPO) deficiency ; ESA therapy (darbepoetin alfa) is the next step after iron correction to target Hb 10 -11 g/dl. Oral iron therapy & IV iron infusion (Options A & B): Oral/IV iron if iron deficient (low ferritin/TSAT); but normocytic CKD anemia is primarily EPO-driven, not iron deficiency Blood transfusion (Option C): Blood transfusion only if symptomatic/critical (Hb <7 or unstable); avoid routinely in CKD due to sensitization risks

References:

Reference: page 2393: Harrison 22 nd edition

↑ *Back to this question in Part A*

@Neet_pg_bot

Q29: A patient has undergone an acute renal allograft transplantation. What would indicate its rejection? (Q853353)

A. Rise of creatinine by more than 10% is suggestive of acute rejection.

B. Rise of creatinine by more than 5% is suggestive of acute rejection.

C. Serum creatinine does not rise in acute renal allograft rejection.

D. Any rise in serum creatinine will be suggestive of acute renal allograft rejection.

Correct Answer: D. Any rise in serum creatinine will be suggestive of acute renal allograft rejection.

Explanation: Serum creatinine is the earliest and most sensitive marker of acute renal allograft rejection. Even a small, unexplained rise should immediately raise suspicion and prompt evaluation.

References:

Robbins and Cotran Pathologic Basis of Disease, 10th Edition, Pages 235-237.

↑ *Back to this question in Part A*

@Neet_pg_bot

Q30: As per KDIGO, which of the following falls under G3b? (Q853357)

A. 45-59

B. 60-89

C. 30-44

D. 15-29

Correct Answer: C. 30-44

Explanation: This range corresponds to Stage 3b of CKD , which is classified as a moderate to severe decrease in kidney function, with GFR between 30-44 mL/min/1.73m². According to the Kidney Disease: Improving Global Outcomes (KDIGO) classification for chronic kidney disease (CKD): GFR: A GFR of 50 mL/min falls into Stage 3 CKD (G3a), defined as 30–59 mL/min. Albuminuria: An albuminuria level of 12 mg/g is categorised as A1 (normal to mildly increased), which is <30 mg/g. Combining these classifications: GFR Stage: G3a (Stage 3) Albuminuria Category: A1 G F R The prognosis of CKD, according to KDIGO 2012 classification Persistent albuminuria A1 A2 A3 Normal to mild increase Moderate increase Severe increase <30mg/g 30-300 mg/g >300mg/g G1 Normal or high >=90 Low risk Moderate risk High risk G2 Mildly decreased 60-89 Low risk Moderate risk High risk G3a Mild to moderate decrease 45-59 Moderate risk High risk Very high risk G3b Moderate to severe decrease 30-44 High risk Very high risk Very high risk G4 Severe decrease 15-29 Very high

risk Very high risk Very high risk G5 Kidney failure <15 Very high risk Very high risk Very high risk {{caption_text}} 45-59 (Option A): This corresponds to Stage 3a. 60-89 (Option B): This corresponds to Stage 2. 15-29 (Option D): This corresponds to Stage 4.

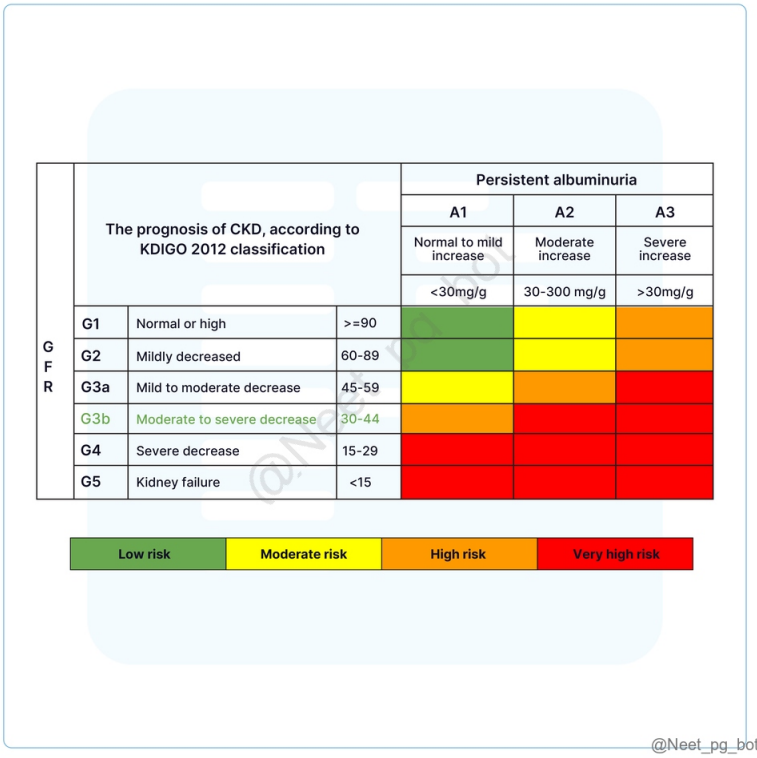

References:

Harrison's Principles of Internal Medicine, 21st Edition, Page 2309.

↑ *Back to this question in Part A*

@Neet_pg_bot

Q31: A 25-year-old male presents with hematuria. Which of the following are seen in glomerular hematuria? Statements: Brown-colored urine Dysuria absent Crystals present Edema rare (Q853360)

A. 1 only

B. 1, 2

C. 1, 2, 3

D. 1, 2, 4

Correct Answer: B. 1, 2

Explanation: Glomerular hematuria presents with brown-colored urine due to RBC breakdown, absence of dysuria as it is not due to lower urinary tract infection, and edema may occur in nephritic syndrome, but is not rare; however, crystals are not a feature of glomerular hematuria. Glomerular Hematuria Glomerular hematuria occurs due to damage to the glomerular filtration barrier, leading to the leakage of red blood cells (RBCs) into the urine. Causes: Glomerulonephritis (Post-streptococcal, IgA nephropathy, lupus nephritis, membranoproliferative GN) Small Vessel Vasculitis (ANCA-associated vasculitis, Goodpasture's syndrome) Hereditary Conditions (Alport syndrome, Thin basement membrane disease) Distinguishing Features of Glomerular and Non-Glomerular Hematuria: Features Glomerular diseases Non-glomerular causes History Dysuria Absent Present in urethritis and cystitis Systemic complaints Edema, fever, pharyngitis, rash, arthralgia Fever with UTI, pain with calculi Family history Deafness, hematuria in Alport's syndrome May be positive with calculi and hypercalcuria Physical examination Hypertension, edema Usually present Less common Abdominal mass Absent Present in Wilm's tumor, obstructive uropathy Rash, arthritis Lupus erythematosus, Henoch- Schonlein purpura Absent unless part of drug induced interstitial nephritis Urinalysis Color Brown, tea, cola bright red, clots may be present Proteinuria 2+ or more Less than 2+ Dysmorphic RBCs More than 20% Not common, less than 15% RBC casts Common Absent Crystals Absent Positive in few

References:

Harrison's Principles of Internal Medicine, 21st Edition, Page 337.

↑ *Back to this question in Part A*

@Neet_pg_bot

Q32: What is the recommended treatment for nephrotic syndrome in children? (Q852685)

A. Steroids

B. Steroids and cyclophosphamide

C. Cyclophosphamide

D. ACE inhibitors

Correct Answer: A. Steroids

Explanation: Steroids are the first-line treatment for nephrotic syndrome , particularly in minimal change disease, which is the most common cause in children . Corticosteroids work by reducing inflammation and suppressing the immune response that leads to proteinuria. The typical initial treatment consists of oral prednisone, with most patients showing a response within 4-8 weeks of therapy. Feature Steroid-Responsive Nephrotic Syndrome Steroid-Resistant Nephrotic Syndrome Definition Nephrotic syndrome that responds well to corticosteroid treatment. Nephrotic syndrome that does not improve despite adequate corticosteroid treatment (e.g., prednisolone at 2 mg/kg/day for 6 weeks). Types: Initial Steroid Resistance: Lack of response from the onset. Late Steroid

Resistance: Resistance develops after initial response. Common Type Minimal Change Nephrotic Syndrome (MCNS) accounts for about 80% of cases in children. It is often associated with Focal Segmental Glomerulosclerosis (FSGS) or genetic mutations affecting podocytes. Diagnosis Diagnosed without kidney biopsy; characterised by heavy proteinuria, low serum albumin, and no significant glomerular damage. Further investigation (e.g., kidney biopsy) is required to determine the underlying cause. Management Responds to high-dose corticosteroids (e.g., prednisolone) , leading to remission of proteinuria and oedema within 10-14 days. Treatment may include immunosuppressive agents, calcineurin inhibitors, or other therapies, as corticosteroids are often ineffective. Steroids and cyclophosphamide (Option B): While this combination may be used in steroid-resistant cases or specific types of nephrotic syndrome, it is not the first-line treatment for nephrotic syndrome in children, which is mainly due to Minimal change disease. The addition of cyclophosphamide is reserved for cases that fail to respond to steroids alone or have frequent relapses. Also, the potential toxicity of cyclophosphamide makes it unsuitable as an initial therapy. Cyclophosphamide (Option C): Using cyclophosphamide alone is not the recommended initial treatment for nephrotic syndrome in children. It is typically used as a second-line agent in steroid-resistant cases or specific pathological variants. ACE inhibitors (Option D): While ACE inhibitors can help reduce proteinuria and are often used as adjunctive therapy, they are not the primary treatment for nephrotic syndrome. They are typically used in conjunction with immunosuppressive therapy, which is the mainstay for treating the underlying cause of nephrotic syndrome.

References:

OP Ghai, Essential Pediatrics, 10th Edition, Page 500, 503

↑ *Back to this question in Part A*

@Neet_pg_bot

Q33: A 55-year-old woman with a history of type 2 diabetes presents for a routine follow-up. Her serum creatinine and potassium levels are normal, but she has microalbuminuria and an HbA1c of 8%. Her blood pressure and pulse are within normal limits, and she is currently on metformin for diabetes management. What should be the next step in her management? (Q852754)

A. Begin a thiazide diuretic

B. Start insulin therapy

C. Stop Metformin and start a different OHA

D. Start an ACE inhibitor

Correct Answer: D. Start an ACE inhibitor

Explanation: Starting ACE inhibitors early in the progression of diabetic nephropathy, particularly with the presence of microalbuminuria, has demonstrated significant benefits in reducing the risk of kidney failure and cardiovascular events . Management of Diabetic nephropathy Oral Hypoglycemic agents (OHAs) SGLT2

inhibitors lower the risk of cardiovascular events and renal failure; they are also recently approved for HFpEF. For HbA1C < 9.5%, OHAs can be used Metformin is withheld if eGFR is < 30 mL/min/1.73 m2 (Option C) , and drugs safe in renal failure can be used like Glipizide Linagliptin Repaglinide Insulin 80% of the calculated dose is started if HbA1C > 9.5% (Option B) Antihypertensives In the presence of microalbuminuria, ACEi and ARBs have shown evidence to slow the progression of nephropathy if started in early stages. In hypertension, for BP > 130/90, ACEi or ARBs are preferred If BP is still not under control, Calcium channel blocker (CCB) can be added Thiazide diuretic - in the presence of oedema (Option A) If eGFR <30 ml/min, then the diuretic used - Metolazone. ACEi/ARB comes with a side effect of hyperkalemia; hence, regular monitoring of potassium is necessary. In the presence of hyperkalemia , ACEi/ARB is replaced by CCB Alpha blocker (Prazosin) - hyperkalemia in ESRD. For Hyperkalemia K Binding resins (Bind to potassium in the gastrointestinal tract and promote its excretion) Sodium polystyrene sulfonate Patiromer Sodium zirconate Renal Transplant If eGFR is < 20 mL/min/1.73 m2 .

References:

Davidson's Principles and Practice of Medicine, 24th Edition, Page 746

Harrison's Principles of Internal Medicine, 21st Edition, Volume I, Page 2316, 2344, 2345, 3124

↑ *Back to this question in Part A*

@Neet_pg_bot

Q34: Which of the following is most likely based on the lab values given? Blood pH: 7.3 (indicating mild acidosis) Sodium (Na+): 134 mEq/L (mildly decreased) Potassium (K+): 2.8 mEq/L (hypokalemia) Chloride (Cl-): 113 mEq/L (elevated) Bicarbonate (HCO■■): 12 mEq/L (low, indicating metabolic acidosis) Blood Urea Nitrogen (BUN): 3 mg/dL (low-normal) Creatinine: 0.6 mg/dL (normal) Urinary pH: 9.4 (alkaline) (Q844330)

A. Renal Tubular Acidosis (RTA) Type 1 (Distal RTA)

B. Renal Tubular Acidosis (RTA) Type 2 (Proximal RTA)

C. Renal Tubular Acidosis (RTA) Type 4

D. High Anion Gap Metabolic Acidosis (HAGMA)

Correct Answer: A. Renal Tubular Acidosis (RTA) Type 1 (Distal RTA)

Explanation: RTA Type 1, also known as distal RTA, is characterized by the inability of the distal tubules of the kidneys to excrete hydrogen ions, leading to an alkaline urinary pH (usually >5.5). Patients typically have a normal anion gap metabolic acidosis, hypokalemia (low potassium), and a low serum bicarbonate level. In this case, the blood pH is mildly acidotic (7.3), with a low HCO■■ (12 mEq/L) and hypokalemia (K+ of 2.8 mEq/L). The urine pH is markedly alkaline (9.4), which is consistent with RTA Type 1. RTA Type 2 (Proximal RTA) (Option B) : RTA Type 2, or proximal RTA, involves a defect in bicarbonate reabsorption in the proximal tubule, leading to a

loss of bicarbonate in the urine and subsequent metabolic acidosis. Urine is typically acidic (pH < 5.5) after the loss of bicarbonate is maximized. Patients can have hypokalemia, but the urinary pH would not remain as high (9.4) after the plasma bicarbonate is depleted, making this less likely. RTA Type 4 (Option C) : RTA Type 4 is characterized by hyperkalemia (high potassium) and a normal anion gap metabolic acidosis. This type results from hypoaldosteronism or aldosterone resistance. In this case, the patient has hypokalemia (K+ of 2.8 mEq/L), not hyperkalemia, making RTA Type 4 an unlikely diagnosis. High Anion Gap Metabolic Acidosis (HAGMA) (Option D) : HAGMA is characterized by a high anion gap due to the accumulation of unmeasured anions (e.g., lactate, ketoacids, toxins). The calculated anion gap here is normal (AG = Na - [Cl + HCO■] = 134 - [113 + 12] = 9), which does not support a diagnosis of HAGMA.

References:

.

↑ *Back to this question in Part A*

@Neet_pg_bot

Q35: A patient having hypertension is on thiazides and is complaining of fatigue and hypokalemia. Which of the following drugs can prevent potassium loss? (Q860435)

A. Furosemide

B. Amiloride

C. Acetazolamide

D. Indapamide

Correct Answer: B. Amiloride

Explanation: Amiloride is a potassium-sparing diuretic that acts by inhibiting the epithelial sodium channel (ENaC) in the distal nephron. When used in combination with thiazide diuretics, it helps prevent hypokalemia while maintaining Thiazide's antihypertensive efficacy . This combination approach is particularly useful in patients experiencing thiazide-induced hypokalemia. Amiloride works as a weak antihypertensive but is valuable for its potassium-sparing properties, though it should be used cautiously in patients with renal failure or hyperkalemia. Classification of Diuretics : Type Mechanism of action Examples Clinical uses Side effects Carbonic anhydrase inhibitors Inhibit carbonic anhydrase enzyme in the proximal tubule, decreasing bicarbonate reabsorption Acetazolamide, Methazolamide Glaucoma, Altitude sickness Metabolic acidosis, Hypokalemia Loop diuretics Inhibit the Na-K-2Cl symporter in the thick ascending loop of Henle Furosemide, Bumetanide Acute pulmonary edema, Chronic heart failure, Hypercalcemia Hypokalemia, Ototoxicity, Metabolic alkalosis, Hyperglycemia, Hyperuricemia Thiazide diuretics Inhibit sodium reabsorption in the distal convoluted tubule Hydrochlorothiazide, Chlorthalidone Hypertension, Edema Hypokalemia, Hyponatremia, Hyperglycemia Hyperuricemia Potassium-sparing Inhibit sodium channels in the distal nephron or block aldosterone receptors Spironolactone, Amiloride Heart failure, Hyperaldosteronism Hyperkalemia, Gynecomastia (for Spironolactone) Osmotic diuretics Increase osmolarity of the glomerular filtrate, inhibiting water reabsorption. Mannitol, Glycerin

Cerebral oedema, Acute glaucoma Dehydration, Electrolyte imbalance Furosemide (Option A): This is a loop diuretic that actually increases potassium excretion and can worsen hypokalemia. It is primarily used in patients with reduced GFR, CHF, or conditions requiring significant sodium excretion. Acetazolamide (Option C) : This carbonic anhydrase inhibitor is mainly used for treating glaucoma, altitude sickness, and periodic paralysis. It does not prevent potassium loss and can actually contribute to electrolyte imbalances. Indapamide (Option D) : This thiazide-like diuretic, similar to traditional thiazides, can cause potassium depletion and would not help prevent hypokalemia. It shares the same mechanism of action and side effect profile as other thiazide diuretics.

References:

Goodman & Gilman's The Pharmacological Basis of Therapeutics, 14th Edition, Page 562

↑ *Back to this question in Part A*

@Neet_pg_bot

Q36: A patient with RTA is passing red color urine due to myoglobinuria. Which of the following will most likely be seen in this patient? (Q866811)

A. Hypernatremia

B. Hyperkalemia

C. Hyponatremia

D. Hypokalemia

Correct Answer: B. Hyperkalemia

Explanation: Myoglobinuria typically occurs after rhabdomyolysis , where muscle breakdown releases myoglobin and intracellular potassium into the bloodstream. Myoglobin is nephrotoxic, causing acute tubular necrosis (ATN) . Tubular injury in ATN often impairs potassium excretion, resulting in Type 4 RTA physiology , which is characterized by hyperkalemia and mild metabolic acidosis. The potassium rise is further exacerbated by direct release from damaged muscle cells. Incorrect Options: Hypernatremia (Option A): Less common in ATN; if anything, sodium tends to be low due to renal losses and fluid shifts. Hyponatremia (Option C): Can occur in kidney injury but not a hallmark feature of RTA with rhabdomyolysis. Hypokalemia (Option D): Seen in Type 1 (distal) and Type 2 (proximal) RTA, but not in Type 4 RTA or ATN — here potassium retention predominates.

↑ *Back to this question in Part A*

@Neet_pg_bot

Q37: A 30-year-old male is admitted to the medicine ward with complaints of vomiting and diarrhea. Lab investigations reveal a serum potassium level of 3.2 mEq/L. All of

the following can be signs of underlying dyselectrolytemia except: (Q840102)

A. Ventricular tachycardia

B. Quadriplegia

C. Diabetes insipidus

D. Cerebral edema

Correct Answer: D. Cerebral edema

Explanation: Correct Option D - Cerebral edema: The given scenario points towards hypokalemia. Cerebral edema is related to fluctuations in the value of sodium (hyponatremia). Potassium does not play a role in plasma osmolality hence do not cause cerebral edema. Incorrect Options: Option A - Ventricular tachycardia: Hypokalemia can contribute to the development of Torsades de Pointes a type of polymorphic ventricular tachycardia. Option B - Quadriplegia: Hypokalemia causes excessive hyperpolarization in skeletal muscles, impairing their ability to contract and leading to weakness and potential paralysis. Option C - Diabetes insipidus: Hypokalemic polyuria results from both excessive drinking (central polydipsia) and the kidneys' reduced response to antidiuretic hormone (AVP-resistant renal concentrating defect).

↑ *Back to this question in Part A*

@Neet_pg_bot

Q38: Which of the following is the most likely condition responsible for a 35-year-old male experiencing nausea, diarrhea, and vomiting, with ABG results indicating pH of 7.55, PCO2 of 50 mmHg, and HCO3- of 44 mmol? (Q840111)

A. Respiratory Acidosis

B. Respiratory Alkalosis

C. Metabolic Acidosis

D. Metabolic Alkalosis

Correct Answer: D. Metabolic Alkalosis

Explanation: Correct Option D - Metabolic Alkalosis: Given that all three parameters are moving in the same direction, indicating a metabolic disorder, and with an increase in pH, the condition is likely metabolic alkalosis. Incorrect Options: Options A, B & C are correct.

↑ *Back to this question in Part A*

@Neet_pg_bot

Q39: Which of the following best characterizes the acid-base status of a 45-year-old diabetic patient presenting to the emergency department with abdominal pain, tachypnea, and tachycardia, whose arterial blood gas analysis reveals the following: pH: 7.34 Sodium (Na): 135 Potassium (K): 5 Bicarbonate (HCO3): 12 Chloride (Cl): 92 RBS = 450 mg/dl (Q840113)

A. Non-Anion Gap Metabolic Acidosis (NAGMA)

B. High Anion Gap Metabolic Acidosis (HAGMA)

C. Compensated Metabolic Alkalosis

D. Respiratory Acidosis

Correct Answer: B. High Anion Gap Metabolic Acidosis (HAGMA)

Explanation: Correct Option B - High Anion Gap Metabolic Acidosis (HAGMA): The pH and bicarbonate levels are reduced hence it indicates metabolic acidosis. Formula for Anion gap = [Na +] - [Cl - + HCO 3 -] In this scenario, Anion gap = 135 - [92 + 12] = 31 Therefore, the anion gap is >12 mEq/L which indicates a High Anion Gap Metabolic Acidosis (HAGMA) Incorrect Options: Options A, C & D are incorrect.

References:

.

↑ *Back to this question in Part A*

@Neet_pg_bot

Q40: Which of the following is not a cause of chronic bipedal edema? (Q840123)

A. Chronic liver disease

B. Nephrotic syndrome

C. Chronic venous insufficiency

D. Lupus nephritis

Correct Answer: C. Chronic venous insufficiency

Explanation: Correct Option C - Chronic venous insufficiency: Chronic venous insufficiency typically presents with unilateral pedal edema rather than bilateral. The edema, often pitting, can be limited to the ankles, extend

upwards to the knees, or even involve the thighs in severe instances. With progression, the edema may transition from being primarily pitting to becoming more indurated over time. Incorrect Options: Option A - Chronic liver disease: In chronic liver disease (CLD), decreased albumin levels result in reduced oncotic pressure, contributing to the development of bipedal edema. Option B - Nephrotic syndrome: Nephrotic syndrome also leads to bipedal edema by lowering oncotic pressure due to decreased albumin levels. Option D - Lupus nephritis: Lupus nephritis results in bipedal edema due to the presence of hyperaldosteronism.

↑ *Back to this question in Part A*

@Neet_pg_bot

Q41: A patient presented with complaints of pain in the flank region with hematuria. On investigation, an X-ray shows multiple calcifications (stones) in both kidneys. What is the probable diagnosis? (Q857275)

A. Parathyroid Adenoma

B. Renal calculi

C. Polycystic kidney disease

D. CKD

Correct Answer: B. Renal calculi

Explanation: linical manifestations of Renal stones: Renal colic is typically characterised by severe, sharp, and fluctuating pain originating in the flank and radiating toward the lower abdomen or groin, based on the location of the stone within the ureter. Upper ureteral stone: Pain radiates anteriorly. Lower ureteral stone: Pain radiates to the ipsilateral groin or labium in females/testicles in males. Hematuria is a common finding due to ureteral irritation and damage caused by the sharp edges of the stone. Nausea and vomiting are frequently present due to the intensity of pain and the reno-gastric reflex. Investigations for renal calculi Lab investigations: Urine analysis (24-hour urine analysis) and blood tests should be conducted to assess serum levels of calcium, uric acid, phosphate, oxalate, and other relevant substances. Radiological investigations: Helical CT abdomen (non-contrast) is the investigation of choice (gold standard) to confirm the diagnosis and locate the stones . {{caption_text}} Ultrasonography (abdomen, KUB) can also be done. X-ray (KUB) can also reveal radio-opaque stones such as Calcium oxalate, calcium phosphate, and struvite. Management of renal stones Medical management Surgical Management Analgesics like diclofenac, ketorolac, tramadol Fluid therapy: IVF (intravenous fluids) are administered to prevent dehydration Alpha 1 blocker: Tamsulosin (relaxes ureter and expels the stone). Extracorporeal shock wave lithotripsy (ESWL): Indicated if the size of the calculi <2 cm . (Contraindicated in pregnancy and bleeding diathesis). PCNL (Percutaneous nephrolithotomy): If the size is >2 cm. Uretrorenoscopy Retrograde intrarenal surgery Pyelolithotomy and nephrolithotomy (rarely used). Parathyroid adenoma (Option A) refers to the enlargement of one or more of the parathyroid glands, which are responsible for regulating calcium levels in the body. While Polycystic kidney disease (PKD) (Option C) can lead to kidney-related symptoms, such as flank pain and hematuria. PKD can get stones, but not multiple stones in all calyces as in nephrocalcinosis/stones CKD (Option D): CKD may have stones, especially due to secondary

hyperparathyroidism, but the typical picture with flank pain + acute hematuria + multiple radiopaque opacities fits renal calculi better.

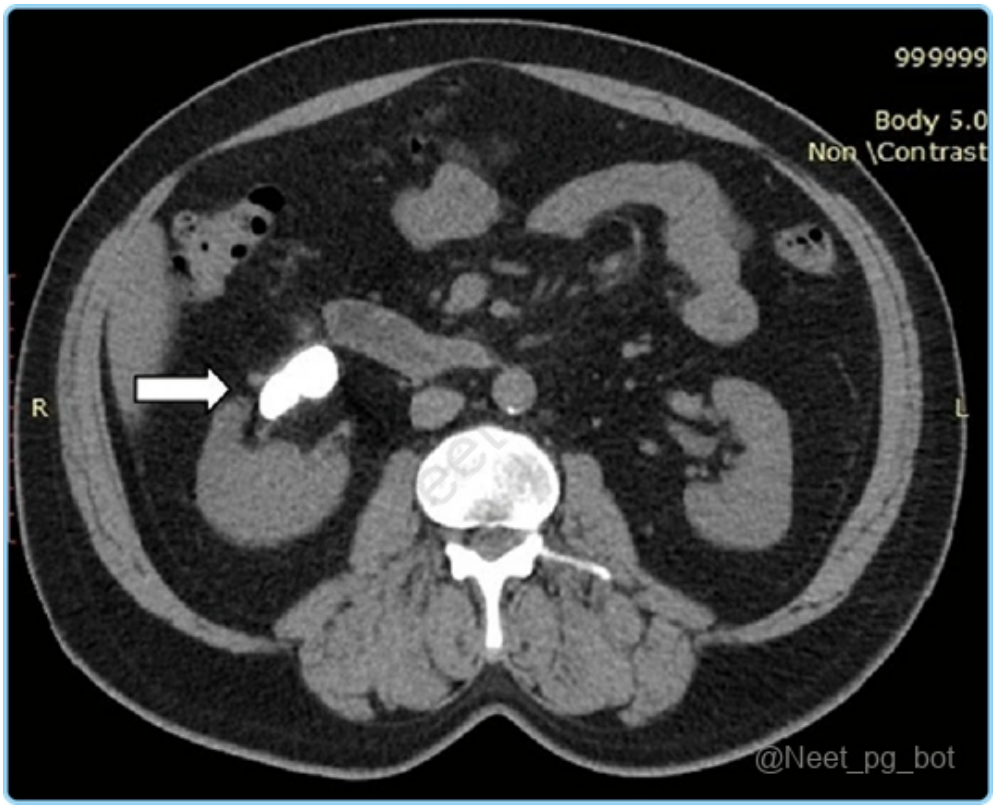

References:

Harrison’s Principles of Internal Medicine, 21st Edition, Volume I, Page: 2370-2373.

Davidson’s Principles and Practice of Medicine, 24th Edition, Page: 431, 432, 433.

↑ *Back to this question in Part A*

@Neet_pg_bot

Q42: A young patient developed hyperpigmentation of distal fingers after being hospitalized post-adrenalectomy. What could be the possible cause? (Q857289)

A. Addison’s disease

B. Conn's syndrome

C. Nelson syndrome

D. Cushing syndrome

Correct Answer: C. Nelson syndrome

Explanation: TH Levels: Very high levels. Diagnosis confirmed by an ACTH increase >30% of the initial result on three consecutive samples after bilateral adrenalectomy. Decreased levels of anterior pituitary hormones . Brain MRI shows pituitary tumours or enlargement of existing tumours. Screening: Regular screening with fasting plasma ACTH levels and brain MRI in patients after bilateral adrenalectomy. Management Surgical Removal of the Tumor Radiotherapy / Radiosurgery Medical Treatment Hormonal Replacement Therapy Addison's disease (Option A) involves primary adrenal insufficiency, where the adrenal glands do not produce sufficient steroid hormones. Hyperpigmentation can occur due to increased ACTH levels, but Addison's disease is typically associated with adrenal atrophy or autoimmune destruction, not post-adrenalectomy. Conn's syndrome (Option B) , or primary hyperaldosteronism, is characterized by excessive production of aldosterone by the adrenal glands. It does not typically cause hyperpigmentation. Symptoms are usually related to hypertension and hypokalemia. Cushing syndrome (Option D) is caused by prolonged exposure to high levels of cortisol. It usually leads to symptoms such as central obesity, moon face, and purple striae, rather than hyperpigmentation of the fingers.

References:

Harrison’s Principles of Internal Medicine, 21st edition, Page 2916

https://www.ncbi.nlm.nih.gov/books/NBK560755/

↑ *Back to this question in Part A*

@Neet_pg_bot

Q43: A 5 year old male child was brought to the hospital with complaints of flank pain and fatigue with a history of red coloured urine. On investigation there were more than 20 RBC/ hpf and microscopy showed dysmorphic RBC. What is the most likely diagnosis? (Q820455)

A. Minimal change disease

B. PSGN

C. UTI

D. Bladder calculi

Correct Answer: B. PSGN

Explanation: Correct Option B - PSGN: The symptoms described, including flank pain, fatigue, history of red-colored urine, and the presence of more than 20 red blood cells (RBCs) per high-power field (hpf) with dysmorphic RBCs on microscopy, are indicative of glomerular involvement, which points toward a kidney-related issue. Among the options provided, PSGN is the most likely diagnosis for several reasons: Hematuria (Presence of RBCs in urine): The patient's history of red-colored urine and the presence of more than 20 RBCs/hpf in the urine sample indicate hematuria, which is a hallmark of glomerular pathology. Dysmorphic RBCs: Dysmorphic RBCs in

the urine are a characteristic feature of glomerular bleeding. These abnormally shaped RBCs are a result of mechanical damage as they pass through the damaged glomerular capillaries. Flank Pain and Fatigue: Flank pain and fatigue can be associated with glomerulonephritis due to impaired kidney function and inflammation. History of Red-Colored Urine: The history of red-colored urine, also known as hematuria, further supports the presence of glomerular involvement. Incorrect Options: Option A - Minimal Change Disease: This is a form of nephrotic syndrome, characterized by massive proteinuria and minimal changes on light microscopy. It typically presents with proteinuria, edema, and normal to slightly elevated blood pressure. It doesn't usually cause gross hematuria or flank pain. Option C - UTI (Urinary Tract Infection): While a UTI can cause hematuria, it is less likely to cause dysmorphic RBCs and would not explain the flank pain and fatigue. Option D - Bladder Calculi: Bladder calculi (stones) might cause hematuria, but they would not explain the presence of dysmorphic RBCs, and typically, the pain associated with bladder stones is localized to the lower abdomen and not the flanks.

References:

.

↑ *Back to this question in Part A*

@Neet_pg_bot

Q44: A patient with hyperkalemia and elevated urea levels underwent dialysis. Towards the end of the session, she became drowsy and had a sudden seizure episode. On examination, the patient was hypotensive. What is the treatment for this condition? (Q855427)

A. Bumetanide

B. Ethacrynic acid

C. Nesiritide

D. IV Mannitol

Correct Answer: D. IV Mannitol

Explanation: - IV Mannitol: The given scenario is suggestive of the dialysis disequilibrium syndrome (DDS) or the reverse urea effect. Dialysis Disequilibrium Syndrome (DDS) is an acute neurological complication, often seen in patients undergoing their first hemodialysis session. It results from the rapid removal of urea and other solutes, creating an osmotic gradient between the blood and the brain's interstitial fluid. This gradient causes water to shift into brain cells, leading to cerebral edema. Features: Symptoms: Headache, nausea, vomiting, blurred vision, restlessness, confusion, muscle cramps, tremors, and in severe cases, seizures or coma. Risk Factors: First hemodialysis session, high blood urea nitrogen (BUN >175 mg/dL), children, elderly, rapid dialysis, and pre-existing neurological conditions. Management: Modify dialysis parameters to reduce urea removal rates. Administer osmotic agents like mannitol to reduce cerebral edema. Provide supportive care for symptoms. Prevention: Initiate dialysis at a slower rate with shorter sessions. Adjust dialysate composition, particularly sodium levels. Avoid aggressive uremia correction, especially in high-risk patients. Complications associated with

Hemodialysis During treatment Between treatment Hypotension: Hypotension is a common complication of dialysis but is not caused by DDS itself. Muscle cramps . Anaphylactoid reactions: These reactions, particularly to the dialyser, are most common during its first use and are often associated with biocompatible cellulosic-containing membranes. Cardiac arrhythmias: D/t potassium & acid-base shifts. Hemorrhage: D/t anticoagulation & venous needle disconnection. Air embolism: D/t faulty lines & equipment malfunction. Pulmonary oedema (D/t fluid overload). Systemic sepsis: Usually involves vascular access devices (catheter or fistula). Dialysis disequilibrium syndrome typically occurs during or after a patient's first dialysis session. It presents with confusion, restlessness, headache, and muscle twitching. It is caused by a urea gradient between the CSF and blood that raises intracranial pressure. Amyloidosis (D/t beta 2 microglobulin) Carpal tunnel syndrome (due to amyloid deposition in the flexor retinaculum). Peripheral neuropathy Bumetanide (Option A): Bumetanide is a loop diuretic used to treat conditions like fluid overload or edema, but it is not indicated for the management of dialysis disequilibrium syndrome. It works by inhibiting sodium and chloride reabsorption in the kidney, and does not address the osmotic shifts causing cerebral edema in DDS. Ethacrynic acid (Option B): Ethacrynic acid is another loop diuretic that can be used in conditions like edema, but it is not the first choice for treating DDS. It does not counteract the osmotic gradient responsible for cerebral edema during dialysis. Nesiritide (Option C): Nesiritide is a recombinant form of B-type natriuretic peptide, used to treat acute decompensated heart failure. It does not address the underlying pathophysiology of dialysis disequilibrium syndrome, which involves osmotic shifts causing cerebral edema.

References:

Harrison's Principles of Internal Medicine, 21st Edition, Page: 2323. Davidson’s Principles and Practice of Medicine, 24th Edition, Page 424. NCBI Bookshelf

↑ *Back to this question in Part A*

@Neet_pg_bot

Q45: Which one of the following medications is not employed for the urgent (immediate) treatment of hyperkalemia? (Q855701)

A. 10% calcium gluconate over 10 min

B. Salbutamol nebulisation

C. Insulin-dextrose

D. Injection MgSO4

Correct Answer: D. Injection MgSO4

Explanation: Magnesium sulfate (MgSO 4) is not typically used for the immediate management of hyperkalemia. It may be used in certain situations, such as if the patient has concurrent magnesium deficiency, which can contribute to electrolyte imbalances. However, it is not the primary drug of choice for immediate intervention in hyperkalemia. Calcium gluconate (Option A) is commonly used in the emergency management of hyperkalaemia. It helps stabilise the cardiac membrane and counteracts the effects of elevated potassium levels on the heart.

Salbutamol (Option B) , a beta-2 agonist, is frequently used for the immediate management of hyperkalaemia. It promotes the cellular uptake of potassium, effectively lowering its concentration in the blood. Insulin (Option C) , often administered with dextrose, is a key component of emergency hyperkalaemia management. Insulin drives potassium from the bloodstream into the cells, reducing serum potassium levels.

References:

Harrison's Principles of Internal Medicine, 21st Edition, Page 352, 353, 354, 355

↑ *Back to this question in Part A*

@Neet_pg_bot

Q46: All of the following aid in the localization of the lesion to the spinal cord except? (Q855322)

A. Contralateral hemiplegia

B. Fasciculation at the level of lesion

C. Upper motor neuron lesion and lower motor neuron lesion

D. Bladder involvement

Correct Answer: A. Contralateral hemiplegia

Explanation: Contralateral hemiplegia refers to weakness or paralysis affecting one side of the body that is opposite to the side of the lesion. However, contralateral hemiplegia is not characteristic of lesions within the spinal cord . It is more commonly associated with brainstem lesions. Fasciculation at the level of the lesion (Option B) is observed at the uppermost level of the lesion in the spinal cord; it can provide clues about the involvement of the corresponding spinal cord segment. UMN lesions (Option C) involve the descending motor pathways (corticospinal) originating from the brain and traveling through the spinal cord , while LMN (Option C) lesions affect the peripheral nerves or nerve roots exiting the spinal cord . Bladder involvement (Option D), such as urinary retention or incontinence, can indicate dysfunction or damage to the nerves controlling bladder function within the spinal cord .

References:

Harrison’s Principles of Internal Medicine, 21st edition, Page 3446, 3429

↑ *Back to this question in Part A*

@Neet_pg_bot

• [05_Gastrointestinal System] 030 Zollinger Ellison Syndrome

« Back to Folder Directory

[05_Gastrointestinal System] 030 Zollinger Ellison Syndrome — Quick Jump

Q1 (p. 1922) *Q2 (p. 1922)* *Q3 (p. 1923)* *Q4 (p. 1924)*

Q1: A patient is undergoing an endoscopy for epigastric pain. The report shows a giant duodenal ulcer in the duodenal cap, and a second one is noted in the second part of the duodenum. Which investigation should be done next in this patient? (Q850867)

A. Secretin study

B. Somatostatin scintigraphy

C. Endoscopic ultrasound

D. Breath urea test

Correct Answer: A. Secretin study

■ *Listen (English)*

■ *Listen (Hindi)*

Explanation: Secretin study is indicated to diagnose Zollinger-Ellison syndrome, which can present with multiple or giant duodenal ulcers due to excessive gastric acid secretion. It entails fasting gastrin levels and then levels a few minutes after secretin injection. Breath urea test (Option D) only detects H. pylori infection, not causes of multiple/giant ulcers. Somatostatin scintigraphy (Option B) identifies neuroendocrine tumors but is not diagnostic for acid hypersecretion. Endoscopic ultrasound (Option C) visualizes lesions but does not assess gastric secretory function.

References:

Harrison's Principles of Internal Medicine, 22nd Edition, Page 2536.

↑ *Back to this question in Part A*

@Neet_pg_bot

Q2: 30-year-old man is having peptic ulcers refractory to PPI. Work up shows elevated serum calcium. Which of the following investigations will not be useful in assessment of this patient? (Q850869)

A. Serum PTH assay

B. Tc 99 Sestamibi SPECT CT

C. Gene sequencing for RET gene

D. MRI head

Correct Answer: C. Gene sequencing for RET gene

■ *Listen (English)*

■ *Listen (Hindi)*

Explanation: The combination of PUD and hypercalcemia raises suspicion of MEN1 in this patient. However, gene sequencing for the RET gene is related to MEN 2 syndrome , which is typically associated with medullary thyroid carcinoma and pheochromocytoma. Therefore, it is not relevant for this patient's assessment. MEN 1 is caused by mutations in the MEN1 gene, which encodes the tumor suppressor protein menin. This gene is located on the long arm of chromosome 11 at position 13 (11q13) and consists of 10 exons encoding a 610 amino acid protein.

References:

Harrison's Principles of Internal Medicine, 22nd Edition, Page 3080, 3085.

↑ *Back to this question in Part A*

@Neet_pg_bot

Q3: Which of the following is correct about location of ZES? (Q850871)

A. Bounded by the duodenum (D2-D3), pancreas, and confluence of the cystic and common bile ducts

B. Bounded by the duodenum(D2-D3), pancreas, and confluence of the common hepatic and common bile ducts

C. Bounded by the jejunum, pancreas, and confluence of the cystic and common bile ducts

D. Bounded by the jejunum, pancreas, and confluence of the common hepatic and common bile ducts

Correct Answer: A. Bounded by the duodenum (D2-D3), pancreas, and confluence of the cystic and common bile ducts

■ *Listen (English)*

■ *Listen (Hindi)*

Explanation: The gastrinoma triangle, also known as Passaro's triangle, is an anatomical area in the abdomen where about 90% of gastrinomas arise. Its boundaries can be remembered by the three key anatomical points

forming a triangle: Superiorly (A): Junction of the cystic duct and common bile duct Medially (B): Junction of the neck and body of the pancreas Inferiorly (C): Junction of the second and third parts of the duodenum

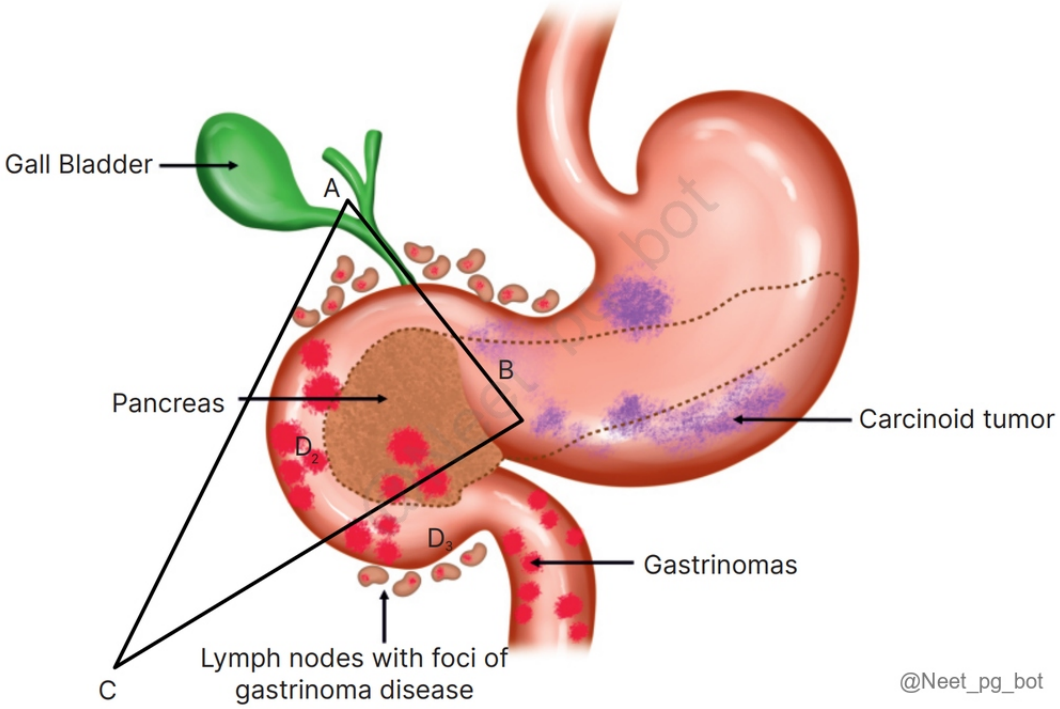

References:

Harrison's Principles of Internal Medicine, 22nd Edition, Page 2534.

↑ *Back to this question in Part A*

@Neet_pg_bot

Q4: Functional imaging of choice for diagnosis of ZES is? (Q850872)

A. Ga-68 DOTATE PET-CT

B. Octreoscan

C. Portal vein sampling

D. Selective arterial secretin injection

Correct Answer: A. Ga-68 DOTATE PET-CT

■ *Listen (English)*

■ *Listen (Hindi)*

Explanation: Ga-68 DOTATATE PET-CT is the imaging modality of choice now for Neuroendocrine tumors and pheochromocytoma, with sensitivity > 90%. Octreoscan (Option B) is an older somatostatin receptor scintigraphy with lower resolution. Portal vein sampling (Option C) is invasive and rarely used for localization. Selective arterial secretin injection (Option D) is mainly used for functional confirmation, not imaging localization.

References:

Harrison's Principles of Internal Medicine, 22nd Edition, Page 2536.

↑ *Back to this question in Part A*

@Neet_pg_bot

• [05_Gastrointestinal System] 031 Inflammatory Bowel Disease-I

« Back to Folder Directory

[05_Gastrointestinal System] 031 Inflammatory Bowel Disease-I — Quick Jump

Q1 (p. 1926) *Q2 (p. 1926)* *Q3 (p. 1927)* *Q4 (p. 1928)* *Q5 (p. 1929)* *Q6 (p. 1929)*
Q7 (p. 1930) *Q8 (p. 1930)* *Q9 (p. 1931)* *Q10 (p. 1932)* *Q11 (p. 1933)* *Q12 (p. 1933)*
Q13 (p. 1934) *Q14 (p. 1935)* *Q15 (p. 1935)*

Q1: Which of the following test is best correlates well with histologic inflammation and predicts relapses in a patient with ulcerative colitis? (Q850874)

A. Faecal Calprotectin

B. Faecal Lactoferrin

C. Faecal Elastase

D. Faecal Chymotrypsin

Correct Answer: A. Faecal Calprotectin

■ *Listen (English)*

■ *Listen (Hindi)*

Explanation: Fecal Calprotectin Answer: Fecal calprotectin is the best test for correlating with histologic inflammation and predicting relapses in ulcerative colitis because it is a sensitive and specific marker of neutrophil activity in the intestinal mucosa. It reflects the degree of mucosal inflammation and has been extensively validated to monitor disease activity and predict flare-ups. Fecal lactoferrin (Option B) , although an inflammation marker, is less sensitive and specific compared to calprotectin. Fecal elastase and fecal chymotrypsin (Option C and D) are markers of pancreatic exocrine function and are not related to intestinal inflammation or ulcerative colitis activity.

References:

Harrison's Principles of Internal Medicine, 22nd Edition, Page 2557.

↑ *Back to this question in Part A*

@Neet_pg_bot

Q2: Which of the following clinical findings is not seen in patient of ulcerative colitis ? (Q850876)

A. Hepatic Tympanitic note

B. Tenderness over colon

C. Bleeding on digital rectal examination

D. Peri-anal fistula

Correct Answer: D. Peri-anal fistula

■ *Listen (English)*

■ *Listen (Hindi)*

Explanation: Peri-anal fistulas are characteristic of Crohn’s disease , not ulcerative colitis (UC) due to its transmural inflammation leading to fistula formation. UC is limited to the mucosa and submucosa and does not cause deep transmural inflammation required to form fistulas. Tympanic note (Option A) over the liver (normally dullness) can be present in ulcerative colitis due to toxic megacolon. Tenderness over the colon (Option B) is common in active disease because of mucosal inflammation. Bleeding on digital rectal examination (Option C) is frequent due to friable mucosa and ulceration.

References:

Harrison's Principles of Internal Medicine, 22nd Edition, Page 2556, 2557.

↑ *Back to this question in Part A*

@Neet_pg_bot

Q3: Which of the following is not a component of Vienna and Montreal classification for Crohn disease? (Q850878)

A. Age at diagnosis

B. Location

C. Behaviour

D. Biomarkers

Correct Answer: D. Biomarkers

■ *Listen (English)*

■ *Listen (Hindi)*

Explanation: The Vienna and Montreal classifications for Crohn's disease do not include biomarkers. Parameter Vienna Classification Montreal Classification Age at Diagnosis A1: < 40 years A2: > 40 years A1: < 16 years A2: 17–40 years A3: > 40 years Location L1: Ileal L2: Colonic L3: Ileocolonic L4: Upper GI L1: Ileal L2: Colonic L3:

Ileocolonic L4: Isolated upper disease (modifier) Behavior B1: Nonstricturing, nonpenetrating B2: Stricturing B3: Penetrating B1: Nonstricturing, nonpenetrating B2: Stricturing B3: Penetrating p: Perianal disease (modifier)

References:

Harrison's Principles of Internal Medicine, 22nd Edition, Page 2557.

↑ *Back to this question in Part A*

@Neet_pg_bot

Q4: Which of the following is not correct about microscopic features of Crohn's disease? (Q850880)

A. Non caseating granuloma in all layers of bowel wall

B. Apthoid ulceration

C. Subepithelial collagen bands

D. Sub-serosal lymphoid aggregates

Correct Answer: C. Subepithelial collagen bands

■ *Listen (English)*

■ *Listen (Hindi)*

Explanation: A subepithelial collagen band ≥10 µm on biopsy is a characteristic feature of collagenous colitis. Crohn's disease has transmural involvement with non-caseating granulomas in all layers of the bowel wall. Microscopic features of Crohn's disease: Non-caseating Granulomas (Option A): Collections of epithelioid histiocytes and giant cells without central necrosis. These are found in all layers of the bowel wall (and often in mesenteric lymph nodes). Aphthoid Ulceration (Option B): Small, superficial ulcers that typically form over a lymphoid follicle; these are the earliest microscopic lesions. Sub-serosal Lymphoid Aggregates (Option D): Clusters of lymphocytes (often called "Crohn's Rosettes") found at the outer edge of the bowel wall. Transmural Inflammation: Chronic inflammatory cells (lymphocytes and plasma cells) involving the mucosa, submucosa, and muscularis propria. Knife-like Fissures: Deep, narrow ulcers that penetrate through the muscle layers, predisposing the patient to fistulas . Crypt Distortion & Abscesses: Branching/shortening of the intestinal crypts and collections of neutrophils within the crypt lumen. Metaplasia: Appearance of Paneth cells in the left colon (where they don't belong) or pyloric-type glands in the ileum. Neural Hyperplasia: Enlargement of the nerve plexuses (Auerbach's and Meissner's) within the bowel wall.

References:

Harrison's Principles of Internal Medicine, 22nd Edition, Page 2556.

↑ *Back to this question in Part A*

@Neet_pg_bot

Q5: All of the following are used to assess severity of ulcerative colitis except? (Q850883)

A. > 6 bloody stools per day

B. Pulse> 90 /min

C. BP < 90/60 mm Hg

D. Haemoglobin < 10.5 gm%, ESR> 30 mm /hr

Correct Answer: C. BP < 90/60 mm Hg

■ *Listen (English)*

■ *Listen (Hindi)*

Explanation: A BP value < 90/60 mm Hg would be seen with massive GI hemorrhage. UC causes daily blood loss, but not substantial enough to cause hemodynamic instability. Severity of UC >6 bloody stools per day Pulse > 90/min Temperature > 37.5C Hb< 10.5 gm% and ESR> 30 mm /hr

References:

Harrison's Principles of Internal Medicine, 22nd Edition, Page 2557.

↑ *Back to this question in Part A*

@Neet_pg_bot

Q6: Which of the following features will not be seen in patients with Crohn’s disease? (Q850885)

A. Entero-vesical fistula

B. Enterocutaneous fistula

C. Nephrolithiasis

D. Proctitis

Correct Answer: D. Proctitis

■ *Listen (English)*

■ *Listen (Hindi)*

Explanation: Proctitis, or inflammation confined to the rectum, is rare in Crohn's disease as it more commonly involves skip lesions and the ileum/colon; proctitis is a feature of ulcerative colitis. Entero-vesical fistula (Option A) is a common complication of Crohn's disease due to transmural inflammation causing abnormal connections between the intestine and bladder. Enterocutaneous fistula (Option B) , where the intestine connects to the skin surface, occurs in Crohn's disease from penetrating inflammation. Normally, calcium binds oxalate forming an insoluble complex that is excreted in stool, but when calcium preferentially binds unabsorbed fatty acids instead due to malabsorption caused by CD, free oxalate is left unbound and more readily absorbed by the colon into the bloodstream. This causes calcium oxalate nephrolithiasis (Option C).

References:

Harrison's Principles of Internal Medicine, 22nd Edition, Page 2557, 2558.

↑ *Back to this question in Part A*

@Neet_pg_bot

Q7: Which of the following is correct radiological finding of ischemic colitis? (Q850887)

A. String sign

B. Thumb print sign

C. Pipe stem colon

D. Lead pipe colon

Correct Answer: B. Thumb print sign

■ *Listen (English)*

■ *Listen (Hindi)*

Explanation: The thumbprint sign is a classic radiological finding in ischemic colitis, caused by submucosal hemorrhage and edema leading to mucosal and submucosal thickening that resembles thumbprints on imaging. String sign (Option A) is seen in Crohn's disease due to a narrowed, strictured segment of bowel. Pipe stem colon/ lead pipe colon (Options C and D) refers to the loss of haustral folds seen in long-standing ulcerative colitis.

References:

Harrison's Principles of Internal Medicine, 22nd Edition, Page 2470.

↑ *Back to this question in Part A*

@Neet_pg_bot

Q8: IBD is usually associated with extraintestinal features. Which of the following hepatobiliary features is not seen in Patients with IBD? (Q850889)

A. Fatty liver

B. Cholelithiasis

C. Primary sclerosing cholangitis

D. Primary biliary cholangitis

Correct Answer: D. Primary biliary cholangitis

■ *Listen (English)*

■ *Listen (Hindi)*

Explanation: Hepatobiliary disease is seen in patients with IBD as an extraintestinal feature. Primary biliary cholangitis is not seen in IBD; rather, Primary sclerosing cholangitis is seen. Extraintestinal manifestations of IBD: Osteoporosis (M/c) Hepatobiliary manifestation- Fatty liver (Option A), cholelithiasis (Option B), and Primary sclerosing cholangitis (Option C) (M/c with UC, p-ANCA associated) Nephrolithiasis Rheumatological- Asymmetrical migratory polyarthritis, Sacroilitis, Ankylosing spondylitis & HLA B27+

References:

Harrison's Principles of Internal Medicine, 22nd Edition, Page 2562.

↑ *Back to this question in Part A*

@Neet_pg_bot

Q9: Which of the following is correct about joint involvement seen in patient with IBD? (Q850891)

A. Migratory peripheral arthritis, Sacroilitis and HLA B27 positive

B. Erosive small joint arthritis, Sacroilitis and HLA B27 positive

C. Migratory peripheral arthritis, tenosynovitis and HLA B27 positive

D. Erosive small joint arthritis, tenosynovitis and HLA B27 positive

Correct Answer: A. Migratory peripheral arthritis, Sacroilitis and HLA B27 positive

■ *Listen (English)*

■ *Listen (Hindi)*

Explanation: HLA B27 positivity is frequently found in patients with sacroiliitis and ankylosing spondylitis associated with IBD. Erosive small joint arthritis and tenosynovitis are less characteristic of IBD-related arthritis; erosive arthritis is more typical of rheumatoid arthritis, whereas IBD arthritis generally is non-erosive and involves large joints in a migratory pattern.

References:

Harrison's Principles of Internal Medicine, 22nd Edition, Page 2562.

↑ *Back to this question in Part A*

@Neet_pg_bot

Q10: A 28-year-old woman with a history of migraine presents with a 3-month history of bloody diarrhoea and tenesmus. Labs show Hb 10 gm%, CRP positive, and sigmoidoscopy showing erythema, mucosal friability starting from the rectum and extending proximally. Which of the following drugs will be started for the management of this patient? (Q850894)

A. Sulphasalazine

B. Mesalamine

C. Azathioprine

D. Methylprednisolone

Correct Answer: B. Mesalamine

■ *Listen (English)*

■ *Listen (Hindi)*

Explanation: Mesalamine is the first-line treatment for mild to moderate ulcerative colitis, as it directly reduces mucosal inflammation and is effective in inducing and maintaining remission. Other drugs used in treating mild to moderate ulcerative colitis: Budesonide, Hydrocortisone (rectal), & Oral Prednisolone Sulphasalazine (Option A): Sulphasalazine also works but has more side effects due to its sulfapyridine component, making mesalamine the preferred choice. Azathioprine (Option C): It is reserved for steroid-dependent or refractory cases and is not used as initial therapy. Methylprednisolone (Option D): Used for moderate to severe flares or when patients do not respond to mesalamine, not as initial treatment.

References:

Harrison's Principles of Internal Medicine, 22nd Edition, Page 2564.

↑ *Back to this question in Part A*

@Neet_pg_bot

Q11: Which of the following small molecule is approved for treatment of ulcerative colitis? (Q850896)

A. Tofacitnib

B. Ustekinumab

C. Certolizumab

D. Azathioprine

Correct Answer: A. Tofacitnib

■ *Listen (English)*

■ *Listen (Hindi)*

Explanation: Small molecules (drugs with molecular weight <1 kDa) are a new class of orally administered medications developed for IBD that lack the immunogenicity associated with monoclonal antibodies. Tofacitinib is a reversible and competitive JAK inhibitor used for mild to moderate UC refractory to biologicals Ustekinumab (Option B): Monoclonal antibody targeting IL-12/23 approved for Crohn's disease and UC Certolizumab (Option C): Anti-TNF monoclonal antibody used in Crohn's disease , not UC Azathioprine (Option D): Immunomodulator (purine analogue), not a small molecule targeted therapy and used mainly for maintenance, not induction of remission.

References:

Harrison's Principles of Internal Medicine, 22nd Edition, Page 2567.

↑ *Back to this question in Part A*

@Neet_pg_bot

Q12: A 35-year-old patient with ulcerative colitis presents with severe abdominal distension, pain, fever, and tachycardia. Abdominal X-ray shows colonic dilatation >6 cm. Ultrasound show no free fluid in peritoneal cavity. What is the first-line medical management for this condition? (Q850898)

A. Intravenous corticosteroids

B. Oral mesalamine

C. Azathioprine

D. Subtotal colectomy

Correct Answer: A. Intravenous corticosteroids

■ *Listen (English)*

■ *Listen (Hindi)*

Explanation: The first-line medical management for a patient with severe colonic dilatation (>6 cm) on X-ray in the context of ulcerative colitis is intravenous corticosteroids, typically methylprednisolone 40 to 60 mg daily. This treatment quickly reduces severe colonic inflammation and systemic toxicity. Note that our patient does not have a perforation of bowel as there is no free fluid in peritoneal cavity If there is no improvement within this period, escalation to second-line medical therapies such as infliximab or cyclosporine may be tried to avoid surgery. Early surgical consultation is recommended to prepare for intervention if medical therapy fails. Oral mesalamine (Option B): For mild–moderate UC, not suitable for acute severe disease. Azathioprine (Option C): Used for maintenance therapy, not for acute management. Subtotal colectomy (Option D): Reserved for non-responders to medical therapy or complications (e.g., perforation).

References:

Harrison's Principles of Internal Medicine, 22nd Edition, Page 2564.

↑ *Back to this question in Part A*

@Neet_pg_bot

Q13: Leading cause of death in patients with Crohn’s disease? (Q850900)

A. Infection

B. Lymphoma of gut

C. Adenocarcinoma of gut

D. Malabsorption

Correct Answer: A. Infection

■ *Listen (English)*

■ *Listen (Hindi)*

Explanation: The leading cause of death in patients with Crohn’s disease is infection, particularly sepsis related to complications such as postoperative infections, bowel perforation, and immunosuppression. Approximately 25-40% of deaths are directly attributable to Crohn’s disease complications, including infections.

References:

Harrison's Principles of Internal Medicine, 22nd Edition, Page 2559.

↑ *Back to this question in Part A*

@Neet_pg_bot

Q14: Which of the following is the most commonly acquired hospital acquired diarrheal illness? (Q850901)

A. Staph aureus

B. Clostridium difficile

C. Shigella

D. Isospora belli

Correct Answer: B. Clostridium difficile

■ *Listen to Audio 1*

Explanation: lostridium difficile is the most common cause of hospital-acquired (nosocomial) diarrhea. It typically occurs after antibiotic use, which disrupts normal gut flora, allowing overgrowth of C. difficile. The organism produces toxins A and B, leading to colitis and pseudomembrane formation. Incorrect Options: Option A - Staphylococcus aureus: Staphylococcus aureus causes acute food poisoning due to preformed enterotoxins, usually presenting within hours of ingestion, not as a nosocomial diarrheal illness. Option C – Shigella: Shigella causes community-acquired bacillary dysentery, transmitted by the fecal–oral route, and is not a common cause of hospital-acquired diarrhea. Option D - Isospora belli: Isospora causes chronic diarrhea in immunocompromised patients, especially with HIV, and is not a typical nosocomial pathogen.

References:

Harrison's Principles of Internal Medicine, 22nd Edition, Page 2560.

↑ *Back to this question in Part A*

@Neet_pg_bot

Q15: Patient on ceftriaxone develops watery loose stools and low-grade fever. Blood counts show TLC of 15000 cells/cu.mm. Which of the following test will help in quick detection of an incriminating organism? (Q850903)

A. NAAT for toxin A and Toxin B in stool

B. EIA for toxin A and toxin B in stool

C. Colonoscopy showing pseudo-membranes

D. Stool culture for Cl. Difficile

Correct Answer: A. NAAT for toxin A and Toxin B in stool

■ *Listen (English)*

■ *Listen (Hindi)*

Explanation: NAAT / PCR is part of the diagnostic criteria of PMC and gives high diagnostic sensitivity and specificity. Other tests include ELISA Colonoscopy (ulcers, plaques, pseudo-membrane can be visualized) CECT-Accordion sign EIA for toxin in stool (Option B): EIA has high sensitivity but lacks specificity. Colonoscopy showing pseudo-membranes (Option C): is specific but not sensitive, as pseudo-membranes take time to develop. Stool culture for Cl. Difficile (Option D): can be used, but turnaround time is too slow for practical use.

References:

Harrison's Principles of Internal Medicine, 22nd Edition, Page 1084.

↑ *Back to this question in Part A*

@Neet_pg_bot

• [05_Gastrointestinal System] 032 Inflammatory Bowel Disease-Ii

« Back to Folder Directory

[05_Gastrointestinal System] 032 Inflammatory Bowel Disease-Ii — Quick Jump

Q1 (p. 1937) *Q2 (p. 1938)* *Q3 (p. 1938)* *Q4 (p. 1939)* *Q5 (p. 1940)* *Q6 (p. 1942)* *Q7 (p. 1942)*

Q1: Which of the following is first investigation to be done in patient with acute lower GI Bleeding with hemodynamic instability? (Q850899)

A. Colonoscopy

B. Upper GI endoscopy

C. Sigmoidoscopy

D. Digital rectal examination

Correct Answer: B. Upper GI endoscopy

■ *Listen (English)*

■ *Listen (Hindi)*

Explanation: In patients with Lower GI bleeding with hemodynamic instability first investigation done is Upper GI endoscopy In patients with Lower GI bleeding without hemodynamic instability first investigation is colonoscopy (Option B).

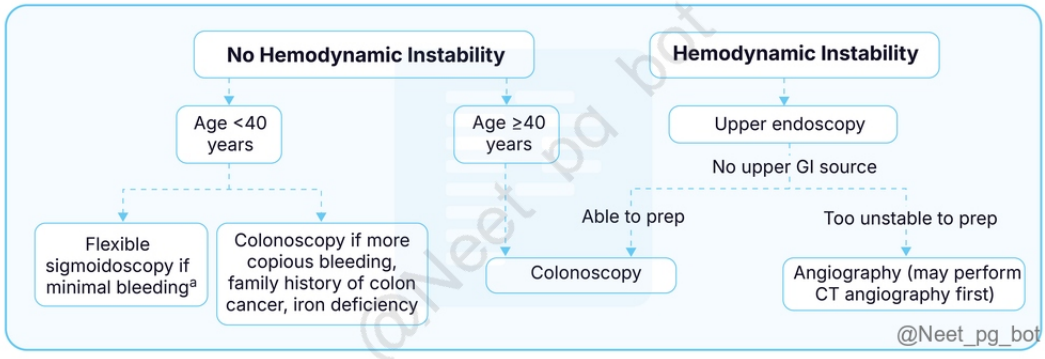

References:

Harrison's Principles of Internal Medicine, 22nd Edition, Page 319.

↑ *Back to this question in Part A*

Q2: Which of the following investigations is best for detecting lesions of active Crohn's disease? (Q850902)

A. Wireless capsule endoscopy

B. MR enterography

C. CT enterography

D. Barium enema

Correct Answer: A. Wireless capsule endoscopy

■ *Listen (English)*

■ *Listen (Hindi)*

Explanation: Wireless capsule endoscopy allows direct visualization of the entire small-bowel mucosa. The diagnostic yield of detecting lesions suggestive of active CD is higher with WCE than magnetic resonance or CT enterography (Options B and C)

References:

Harrison's Principles of Internal Medicine, 22nd Edition, Page 2558.

↑ *Back to this question in Part A*

@Neet_pg_bot

Q3: Which of the following classification system is used exclusively for determination of severity of ulcerative colitis? (Q850904)

A. Truelove and Witts

B. Montreal classification

C. Vienna classification

D. Marsh classification

Correct Answer: A. Truelove and Witts

■ *Listen (English)*

■ *Listen (Hindi)*

Explanation: This is a closely worded question, as Truelove and Witts and Montreal classification are both used. Montreal classification (Option B) is for extent and severity, while Truelove and Witts is exclusively for the severity of ulcerative colitis. Vienna classification (Option C): Also used for Crohn's disease , categorizing disease location and behavior. Marsh classification (Option D): Used for celiac disease , assessing histological changes in the small intestine.

References:

https://pmc.ncbi.nlm.nih.gov/articles/PMC5797274/

↑ *Back to this question in Part A*

@Neet_pg_bot

Q4: 50-year-old man presents with complaints of blood and mucus in thin ribbon like stool, tenesmus and weight loss. MRI abdomen shows bowel wall thickening in descending colon and perirectal fat thickening and enlarged lymph nodes. First differential diagnosis is? (Q850905)

A. Colorectal cancer

B. Ulcerative colitis

C. Microscopic colitis

D. Crohn's disease

Correct Answer: A. Colorectal cancer

■ *Listen (English)*

■ *Listen (Hindi)*

Explanation: Presentation with blood and mucus in thin, ribbon-like stools , tenesmus , weight loss , and bowel wall thickening with lymphadenopathy on imaging is highly suggestive of colorectal cancer . Ulcerative colitis (Option B): Typically causes continuous mucosal inflammation and bloody diarrhea, but significant lymphadenopathy is unusual. Microscopic colitis (Option C): Presents with chronic watery diarrhea without blood or radiologic bowel wall thickening. Crohn's disease (Option D): Usually involves skip lesions, transmural inflammation , and may affect any part of the GI tract.

References:

Harrison's Principles of Internal Medicine, 22nd Edition, Page 655.

↑ *Back to this question in Part A*

@Neet_pg_bot

Q5: Patient with ulcerative colitis presents with ulcerated lesions with violaceous edges surrounded by a margin of erythema on both shins. Diagnosis is? (Q850906)

A. Erythema nodosum

B. Pyoderma gangrenosum

C. Pyoderma vegetans

D. Sweet syndrome

Correct Answer: B. Pyoderma gangrenosum

■ *Listen (English)*

■ *Listen (Hindi)*

Explanation: Pyoderma gangrenosum begins as painful pustules or nodules which rapidly progress into deep ulcers with violaceous /purple margins and undermined edges surrounded by an erythematous margin. Erythema nodosum (Option A): Presents as tender, red or purple nodules usually on the shins, but these are nodular lesions without ulceration or violaceous borders. Pyoderma vegetans (Option C): A much rarer vegetative variant with verrucous, vegetative plaques. Sweet syndrome (Option D) : Presents with tender, erythematous plaques or nodules often accompanied by fever and leukocytosis.

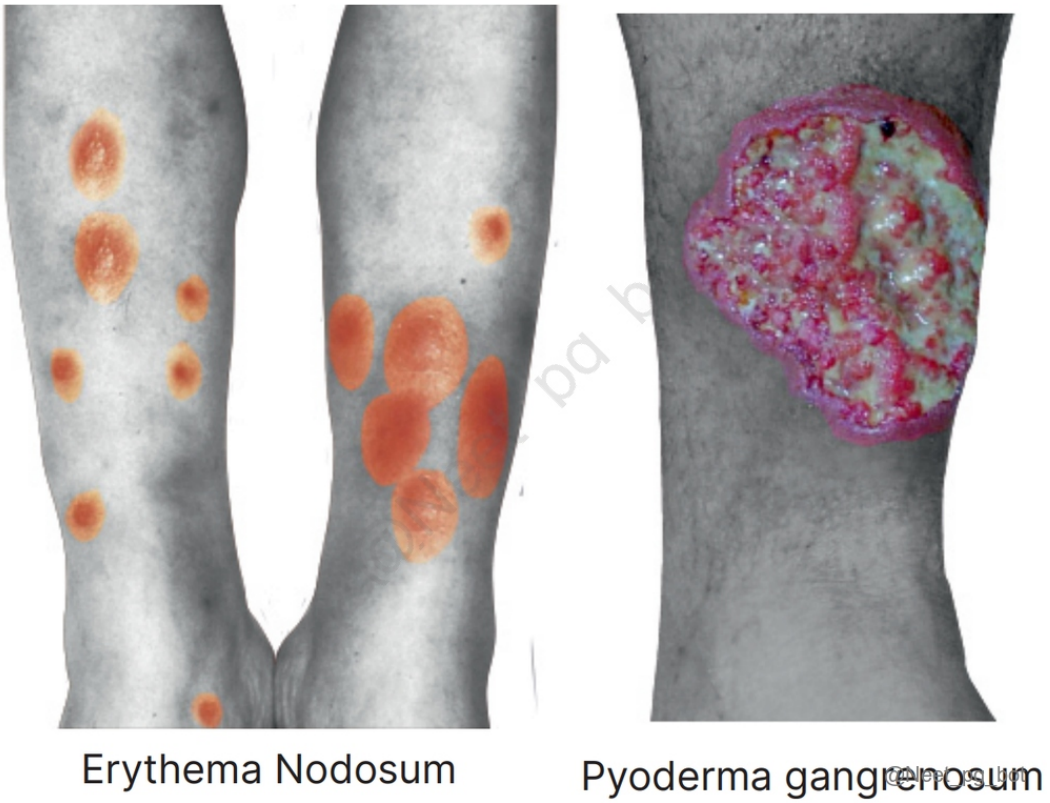





References:

Harrison's Principles of Internal Medicine, 22nd Edition, Page 2561.

↑ *Back to this question in Part A*

@Neet_pg_bot

Q6: Which of the following is the most common extraintestinal feature seen in IBD? (Q850907)

A. Metabolic bone disorder

B. Arthritis

C. Ocular involvement

D. Hepatobiliary involvement

Correct Answer: A. Metabolic bone disorder

■ *Listen (English)*

■ *Listen (Hindi)*

Explanation: Metabolic bone disorder includes osteoporosis and osteonecrosis and is seen in 40% of patients with IBD. Hepatobiliary involvement (Option D) is seen in 10 to 35% of cases of IBD. Arthritis (Option B): Occurs frequently but is secondary to IBD activity and less prevalent than metabolic bone disease. Ocular involvement (Option C): Rare, includes uveitis or episcleritis.

References:

Harrison's Principles of Internal Medicine, 22nd Edition, Page 2562, 2563.

↑ *Back to this question in Part A*

@Neet_pg_bot

Q7: 32-year-old male with ulcerative colitis presents with increased frequency of bloody diarrhea (8–10 times/day) for the past week, associated with abdominal pain and fever. On examination, his pulse is 110/min, BP 100/60 mmHg, temperature 38.2°C. Abdominal examination reveals diffuse tenderness without guarding. Labs are shown below. Which of the following is the most appropriate next step in management Hemoglobin: 9.8 g/dL ESR: 68 mm/hr CRP: markedly elevated Stool culture: negative for pathogens (Q850908)

A. Oral mesalamine

B. Sulfasalazine enema

C. Initiate intravenous corticosteroids

D. Schedule Proctolectomy immediately

Correct Answer: C. Initiate intravenous corticosteroids

■ *Listen (English)*

■ *Listen (Hindi)*

Explanation: The patient is presenting with severe ulcerative colitis flare (bloody diarrhea >6/day, tachycardia, fever, hypotension, elevated inflammatory markers). IV corticosteroids are first-line treatment for severe flares. By Truelove and Witt's criteria , this patient requires IV steroids followed by oral steroids and then steroid enemas . Oral mesalamine (Option A): Used for mild to moderate UC; insufficient in severe flares. Sulfasalazine enema (Option B): Limited to distal disease; not appropriate for severe pancolitis. Schedule Proctolectomy immediately (Option D): Surgery is reserved for refractory cases or complications, not initial management.

References:

Harrison's Principles of Internal Medicine, 22nd Edition, Page 2564.

↑ *Back to this question in Part A*

@Neet_pg_bot

• [05_Gastrointestinal System] 033 Irritable Bowel Syndrome

« Back to Folder Directory

[05_Gastrointestinal System] 033 Irritable Bowel Syndrome — Quick Jump

Q1 (p. 1944)	*Q2 (p. 1944)*	*Q3 (p. 1945)*	*Q4 (p. 1946)*	*Q5 (p. 1947)*	*Q6 (p. 1947)*
Q7 (p. 1948)	*Q8 (p. 1949)*	*Q9 (p. 1950)*	*Q10 (p. 1951)*	*Q11 (p. 1951)*	*Q12 (p. 1952)*
Q13 (p. 1953)	*Q14 (p. 1954)*	*Q15 (p. 1954)*	*Q16 (p. 1955)*	*Q17 (p. 1956)*	*Q18 (p. 1957)*

Q1: Patients with Irritable Bowel Syndrome (IBS) have demonstrated preferential activation of which brain region in response to distal colonic stimulation, correlating with altered attention processes and response selection? (Q890588)

A. Mid-cingulate cortex

B. Cerebellum

C. Occipital lobe

D. Hippocampus

Correct Answer: A. Mid-cingulate cortex

Explanation: Functional MRI studies show increased activation of the mid-cingulate cortex in IBS patients during distal colonic stimulation. This region is involved in attention modulation, vigilance, and response selection, linking visceral input to altered pain perception in IBS. IBS is a disorder of gut-brain interaction, not a structural gastrointestinal disease. Abnormalities exist in the central processing of visceral afferent signals, rather than peripheral injury. Key neural features include the following: Enhanced activation of the mid-cingulate cortex Engagement of the prefrontal vigilance network Altered descending pain modulation These changes explain visceral hypersensitivity and heightened symptom awareness despite normal endoscopy and imaging. Cerebellum (Option B): Primarily coordinates motor activity; not implicated in IBS pain processing. Occipital lobe (Option C): Visual processing centre; no role in visceral sensation. Hippocampus (Option D): Involved in memory and emotion, but not selectively activated during colonic stimulation in IBS.

References:

Harrison’s Principles of Internal Medicine, 22nd Edition, Page 2572.

↑ *Back to this question in Part A*

@Neet_pg_bot

Q2: A 35 y/o man with constipation-predominant Irritable Bowel Syndrome (IBS-C) has persistent symptoms despite lifestyle modification and over-the-counter laxatives. He has started on a medication that inhibits the gastrointestinal sodium-hydrogen exchanger 3 (NHE3). Which medication has most likely been prescribed? (Q890596)

A. Tenapanor

B. Prucalopride

C. Eluxadoline

D. Rifaximin

Correct Answer: A. Tenapanor

Explanation: Tenapanor is a small-molecule inhibitor of NHE3 located on the intestinal epithelium. Inhibition of NHE3 decreases sodium and phosphate absorption, leading to increased luminal water retention, softer stools, and improved bowel frequency. It is specifically approved for IBS-C, not for diarrhoea-predominant diseases. IBS-C management targets stool hydration, motility, and visceral symptoms. Pharmacologic options include: Secretagogues (e.g., chloride channel or GC-C agonists) NHE3 inhibitors (Tenapanor) Prokinetic agents (5-HT■ agonists) Tenapanor represents a novel mechanism, acting locally with minimal systemic absorption. Prucalopride (Option B): A 5-HT■ agonist prokinetic; does not affect sodium absorption. Eluxadoline (Option C): Used for IBS-D; opioid receptor modulator that slows transit. Rifaximin (Option D): Nonabsorbable antibiotic used in IBS-D, not constipation.

References:

Harrison’s Principles of Internal Medicine, 22nd Edition, Pages 2575, 2576.

↑ *Back to this question in Part A*

@Neet_pg_bot

Q3: A 42 y/o woman with irritable bowel syndrome (IBS) reports recurrent lower abdominal cramping and pain shortly after meals. To optimise symptom control for her postprandial pain pattern, what is the most appropriate change to her dosing schedule? (Q890595)

A. Take the medication 30 minutes before meals

B. Take the medication with the first bite of food

C. Take the medication 1 hour after meals

D. Take the medication only at bedtime

Correct Answer: A. Take the medication 30 minutes before meals

Explanation: Antispasmodics such as dicyclomine are most effective for postprandial IBS pain when given ~30 minutes before meals. This timing allows adequate absorption before eating, enabling the drug to blunt the gastrocolic reflex that triggers post-meal cramping. Postprandial IBS pain is driven by an exaggerated gastrocolic reflex. Antispasmodics work by reducing smooth-muscle spasm and cholinergic activity. Prophylactic dosing before meals is superior to reactive dosing after pain begins. Correct timing can significantly improve efficacy without increasing dose or side effects. Take the medication with the first bite of food (Option B): Drug absorption is delayed; the reflex is already initiated. Take the medication 1 hour after meals (Option C): Misses the preventive window and treats established spasms poorly. Take the medication only at bedtime (Option D): Does not target meal-related symptoms.

References:

Harrison's Principles of Internal Medicine, 22nd Edition, Page 2575.

↑ *Back to this question in Part A*

@Neet_pg_bot

Q4: A 68 y/o woman with constipation-predominant Irritable Bowel Syndrome (IBS-C) and mild cognitive impairment presents with dry mouth, blurred vision, and difficulty initiating urination shortly after starting a new medication for abdominal cramping and pain. Which of the following agents is most likely responsible for her symptoms? (Q890594)

A. Linaclotide

B. Peppermint oil

C. Hyoscyamine

D. Lubiprostone

Correct Answer: C. Hyoscyamine

Explanation: Hyoscyamine is an anticholinergic antispasmodic (belladonna alkaloid) used to relieve IBS-related pain. Its antimuscarinic effects cause xerostomia, blurred vision, urinary retention, and cognitive effects, which are particularly pronounced in elderly patients. IBS pain is often treated with antispasmodics, but these agents carry significant anticholinergic toxicity. Anticholinergic adverse effects include the following: Dry mouth Blurred vision Urinary hesitancy or retention Constipation Cognitive impairment and drowsiness Elderly patients and those with baseline cognitive dysfunction are especially vulnerable. Medication choice in IBS must balance symptom relief vs. tolerability, particularly in older adults. Linaclotide (Option A): A guanylate cyclase-C agonist (GC-C agonist); causes diarrhoea, not anticholinergic effects. Peppermint oil (Option B): It's an antispasmodic,

but most commonly causes heartburn. Lubiprostone (Option D): Chloride channel activator; nausea and diarrhoea are typical.

References:

Harrison's Principles of Internal Medicine, 22nd Edition, Page 2575.

↑ *Back to this question in Part A*

@Neet_pg_bot

Q5: Pharmacologic agents targeting serotonin receptors are used in the management of irritable bowel syndrome (IBS). While 5-HT■ agonists stimulate intestinal peristalsis, drugs that act as serotonin antagonists (5-HT■ antagonists) fall under which therapeutic category for IBS? (Q890593)

A. Stool-bulking agents

B. Prescription antidiarrheals

C. Osmotic laxatives

D. Antiflatulence therapy

Correct Answer: B. Prescription antidiarrheals

Explanation: 5-HT■ antagonists (e.g., alosetron) reduce visceral pain, slow colonic transit, and decrease intestinal secretion. Because they reduce diarrhoea and urgency, they are classified as prescription antidiarrheals in IBS management. IBS-D is associated with excess serotonin signalling and visceral hypersensitivity. 5-HT■ antagonists act by: Reducing intestinal secretion Slowing colonic transit Decreasing visceral pain perception Prescription antidiarrheals for IBS-D include the following: Opioid agents Anticholinergic antispasmodics Tricyclic antidepressants Bile acid binders Serotonin (5-HT■) antagonists Alosetron is specifically approved for severe IBS-D (with restricted use due to ischemic colitis risk). Stool-bulking agents (Option A): Used mainly in IBS-C or mixed IBS; do not block serotonin receptors. Osmotic laxatives (Option C): Increase stool water; used for constipation, not diarrhoea. Antiflatulence therapy (Option D): Targets gas production or fermentation, not serotonin pathways.

References:

Harrison's Principles of Internal Medicine, 22nd Edition, Pages 2463, 2575

↑ *Back to this question in Part A*

@Neet_pg_bot

Q6: A patient with irritable bowel syndrome (IBS) is being treated with paroxetine. On follow-up, the patient reports fatigue and jaundice. Paroxetine is most commonly associated with which pattern of hepatic injury? (Q890592)

A. Fatty liver (steatosis)

B. Granulomatous hepatitis

C. Hepatitis (hepatocellular injury)

D. Vascular injury

Correct Answer: C. Hepatitis (hepatocellular injury)

Explanation: Paroxetine, an SSRI used in IBS for pain modulation and gut-brain axis effects, is known to cause hepatocellular injury (hepatitis). This pattern presents with aminotransferase elevation ± jaundice, consistent with the patient's findings. Antidepressants (TCAs and SSRIs) are used in IBS for central pain modulation and visceral hypersensitivity, not for mood alone. SSRIs such as paroxetine are especially used in IBS-C or mixed IBS due to fewer anticholinergic effects. Although uncommon, SSRIs can cause drug-induced liver injury, most often with a hepatocellular pattern. Recognition of DILI morphology helps distinguish drug toxicity from primary liver disease. Fatty liver (Option A): Seen with drugs like amiodarone, valproate, and tetracycline, but not paroxetine. Granulomatous hepatitis (Option B): Associated with allopurinol, sulfonamides, and quinidine. Vascular injury (Option D): Linked to chemotherapeutic agents (e.g., oxaliplatin), not SSRIs.

References:

Harrison's Principles of Internal Medicine, 22nd Edition, Pages 2665, 2666.

↑ *Back to this question in Part A*

@Neet_pg_bot

Q7: Which of the following clinical features, if reported by a patient, most strongly suggests inflammatory bowel disease (IBD) or another organic pathology rather than irritable bowel syndrome (IBS)? (Q890591)

A. Relief of abdominal pain with defecation

B. Presence of visible mucus in the stool

C. Waking from sleep due to diarrhoea (nocturnal diarrhoea)

D. Sensation of incomplete evacuation

Correct Answer: C. Waking from sleep due to diarrhoea (nocturnal diarrhoea)

Explanation: Nocturnal diarrhoea is an alarm feature that indicates diarrhoea occurring independent of meals or conscious awareness. IBS is a functional disorder and rarely causes symptoms that awaken patients from sleep. Nighttime diarrhoea strongly suggests organic pathology, such as IBD or secretory diarrhoea. Irritable bowel syndrome (IBS): A functional disorder, symptoms often related to meals and stress, absent during sleep. IBD / organic disease: inflammatory or secretory processes that continue day and night. Alarm features that favour IBD include: Nocturnal symptoms Weight loss GI bleeding Anemia Elevated inflammatory markers The presence of alarm features warrants further diagnostic evaluation, not a diagnosis of IBS. Feature Irritable Bowel Syndrome (IBS) Inflammatory Bowel Disease (IBD) Pathophysiology Functional disorder: visceral hypersensitivity, motility disturbance, and gut-brain axis dysfunction. Organic disease: chronic immune-mediated inflammation (mucosal or transmural). Abdominal Pain Related to defecation; often relieved by passing stool/gas. Chronic; may be constant or cramping; often associated with meals or obstruction (CD). Stool Character Mucus is common; blood is rare (unless haemorrhoids). Blood and pus are common (especially in ulcerative colitis). Nocturnal Symptoms Rare (symptoms usually only during waking hours). Common (diarrhoea often wakes the patient). Weight Loss Rare. Common (due to malabsorption, anorexia, catabolic state). Fecal Biomarkers Normal Calprotectin/Lactoferrin. Elevated Calprotectin/Lactoferrin (indicates inflammation). Anaemia/CRP/ESR Normal. Often elevated/abnormal (anaemia of chronic disease or iron deficiency). Endoscopy/Biopsy Normal mucosa. Ulcers, erythema, friability, granulomas (CD), crypt abscesses (UC). Relief of abdominal pain with defecation (Option A): Classic feature of IBS and included in Rome criteria. Presence of visible mucus in the stool (Option B): Common in IBS; blood or pus would be more concerning. Sensation of incomplete evacuation (Option D): Frequently reported in IBS; not specific for organic disease.

References:

Harrison’s Principles of Internal Medicine, 22nd Edition, Pages 2573, 2574.

↑ *Back to this question in Part A*

@Neet_pg_bot

Q8: Which of the following sets of diagnostic tests is recommended as part of the initial evaluation for a patient with diarrhoea-predominant irritable bowel syndrome who has no alarm features? (Q890590)

A. Complete blood count (CBC), faecal calprotectin, and serologic testing for celiac disease

B. Colonoscopy with random biopsies and stool examination for ova and parasites

C. Abdominal CT scan and erythrocyte sedimentation rate (ESR)

D. Hydrogen breath test and upper gastrointestinal endoscopy (EGD)

Correct Answer: A. Complete blood count (CBC), faecal calprotectin, and serologic testing for celiac disease

Explanation: In patients with suspected IBS-D and no alarm features, the recommended initial workup is limited and targeted. CBC screens for anaemia or inflammation, faecal calprotectin (or lactoferrin/CRP) helps exclude

IBD, and celiac serology is advised because celiac disease can mimic IBS-D. IBS is a clinical diagnosis based on the Rome criteria, once serious pathology is excluded. Recommended baseline tests in IBS-D include: CBC Faecal calprotectin or CRP Serologic testing for celiac disease (especially where prevalence ≥1%) Extensive testing is discouraged in the absence of alarm features (weight loss, anaemia, nocturnal symptoms, GI bleeding, family history of Colorectal cancer/IBD). Colonoscopy with random biopsies and stool examination for ova and parasites (Option B): Colonoscopy is reserved for alarm features or older age; ova and parasites testing is selective, not routine. Abdominal CT scan and erythrocyte sedimentation rate (ESR) (Option C): Routine imaging is unnecessary, costly, and low yield in typical IBS. Hydrogen breath test and upper gastrointestinal endoscopy (EGD) (Option D): Used only when specific alternative diagnoses are suspected, not for routine IBS-D evaluation.

References:

Harrison's Principles of Internal Medicine, 22nd Edition, Page 2574.

↑ *Back to this question in Part A*

@Neet_pg_bot

Q9: Which demographic profile is most strongly associated with an increased risk of developing post-infectious irritable bowel syndrome (IBS) following an episode of acute gastroenteritis? (Q890589)

A. Male patients over the age of 50

B. Female patients of younger age

C. Male patients of younger age

D. Female patients over the age of 60

Correct Answer: B. Female patients of younger age

Explanation: Post-infectious IBS occurs most commonly in younger patients, with a female predominance, as explicitly noted in the text. Female sex and younger age are the strongest demographic predictors of IBS developing after acute infectious gastroenteritis. Post-infectious IBS is a subset of IBS that follows acute bacterial or viral gastroenteritis. Established risk factors include: Female sex Younger age Severe initial infection Prolonged diarrhoea during the acute illness Psychological stress or anxiety Proposed mechanisms include persistent low-grade inflammation, altered gut permeability, immune activation, and changes in gut-brain signalling. Male patients over 50 (Option A): Neither male sex nor older age increases risk. Male patients of younger age (Option C): Younger age alone is insufficient without female sex. Female patients over 60 (Option D): Older age is not a recognised risk factor despite female sex.

References:

Harrison's Principles of Internal Medicine, 22nd Edition, Page 2572.

↑ *Back to this question in Part A*

@Neet_pg_bot

Q10: A 30-year young female is diagnosed as having IBS. Which of the following is not a feature of irritable bowel syndrome? (Q850815)

A. Dyspepsia and bloating

B. Recurrent abdominal pain

C. Constipation alternating with diarrhoea

D. Nocturnal diarrhoea

Correct Answer: D. Nocturnal diarrhoea

■ *Listen (English)*

■ *Listen (Hindi)*

Explanation: Nocturnal diarrhoea does not occur in IBS. Night time sleep in not interrupted in IBS. Altered bowel habits and altered GI motility are features of IBS and leads to recurrent abdominal pain. Rome IV Diagnostic Criteria for Irritable Bowel Syndrome Recurrent abdominal pain, on average, at least 1 day per week in the last 3 months, associated with 2 or more of the following criteria: Related to defection Associated with a change in frequency of stool Associated with a change in form (appearance) of stool Criteria fulfilled for the last 3 months with symptom onset at least 6 months prior to diagnosis. Dyspepsia and bloating (Option A): Common features of IBS. Recurrent abdominal pain (Option B): Core symptom of IBS. Constipation alternating with diarrhoea (Option C): Typical bowel pattern in IBS.

References:

Harrison's Principles of Internal Medicine, 22nd Edition, Page 2571.

↑ *Back to this question in Part A*

@Neet_pg_bot

Q11: A 34 y/o woman has a 2-year history of recurrent abdominal cramping and frequent loose, watery stools that worsen with stress and meals. She is diagnosed with diarrhoea-predominant irritable bowel syndrome (IBS-D). Which of the following cellular abnormalities is most likely to be identified in her colonic mucosa? (Q890587)

A. Decreased density of mast cells in the lamina propria

B. Increased number of serotonin-containing enterochromaffin cells

C. Atrophy of myenteric plexus ganglion cells

D. Reduced expression of cholecystokinin (CCK) receptors

Correct Answer: B. Increased number of serotonin-containing enterochromaffin cells

Explanation: IBS-D is associated with increased serotonin (5-HT) signalling due to a higher number of serotonin-containing enterochromaffin cells in the colon. Increased serotonin enhances intestinal motility and visceral sensitivity, driving diarrhoea and abdominal pain. IBS-D: A disorder of gut-brain interaction with altered neurotransmission rather than structural disease. Key neurotransmitter abnormalities include the following: ↑ Serotonin (5-HT) → increased motility and visceral hypersensitivity Altered 5-HT■ and 5-HT■ receptor signaling Interaction with enteric nerves and central pain pathways These changes explain why 5-HT■ antagonists (e.g., alosetron) are effective in IBS-D. Decreased density of mast cells in the lamina propria (Option A): Mast cells are often increased or activated, especially near enteric nerves. Atrophy of myenteric plexus ganglion cells (Option C): Seen in degenerative neuropathies, not functional disorders like IBS. Reduced expression of cholecystokinin (CCK) receptors (Option D): Not a defining mechanism; serotonin pathways are the key abnormality in IBS-D.

References:

Harrison's Principles of Internal Medicine, 22nd Edition, Page 2573.

↑ *Back to this question in Part A*

@Neet_pg_bot

Q12: Which pathophysiologic abnormality is most consistently observed in patients with IBS, particularly those with the diarrhoea-predominant subtype, during simulated visceral stimulation? (Q890586)

A. Decreased contractile activity in the rectosigmoid colon

B. Higher threshold for pain perception during rectal balloon inflation

C. Exaggerated sensory response to visceral stimulation (visceral hypersensitivity)

D. Generalised somatic hypersensitivity involving skin and muscle

Correct Answer: C. Exaggerated sensory response to visceral stimulation (visceral hypersensitivity)

Explanation: IBS is characterised by visceral hypersensitivity, where patients perceive visceral stimuli as painful at lower-than-normal thresholds. Rectal balloon inflation studies show IBS patients report pain at lower volumes without increased rectal wall tension, confirming abnormal sensory processing rather than structural disease. Pathogenesis of IBS: IBS is a disorder of gut-brain interaction, not structural pathology. Key mechanisms include the following: Visceral hypersensitivity (hallmark feature) Altered central pain processing Abnormal enteric nervous system signalling Dysregulated motility (especially postprandial) Psychosocial stress amplification These

abnormalities are most prominent in IBS-D, explaining pain with otherwise normal investigations. Decreased contractile activity in the rectosigmoid colon (Option A): IBS often shows exaggerated motor responses, not reduced activity. Higher threshold for pain perception during rectal balloon inflation (Option B): IBS patients have a lower, not a higher, pain threshold. Generalised somatic hypersensitivity involving skin and muscle (Option D): IBS selectively affects visceral afferents; somatic sensation is usually normal.

References:

Harrison's Principles of Internal Medicine, 22nd Edition, Page 2572.

↑ *Back to this question in Part A*

@Neet_pg_bot

Q13: According to the Rome IV criteria, which of the following symptoms is a mandatory prerequisite for establishing a diagnosis of irritable bowel syndrome (IBS)? (Q890585)

A. Abdominal bloating and distention

B. Recurrent abdominal pain

C. Chronic watery diarrhoea

D. Feeling of incomplete evacuation

Correct Answer: B. Recurrent abdominal pain

Explanation: Recurrent abdominal pain is the core defining symptom required for IBS diagnosis under Rome IV. It must occur at least 1 day per week over the last 3 months and be associated with defecation and/or a change in stool frequency or form. IBS cannot be diagnosed in the absence of abdominal pain. Rome IV Criteria for Irritable Bowel Syndrome (IBS) Diagnosis requires: Recurrent abdominal pain , on average, ≥1 day/week in the last 3 months , associated with ≥2 of the following: Related to defecation Associated with a change in stool frequency Associated with a change in stool form (appearance) IBS is classified based on stool pattern, but all subtypes share abdominal pain as a prerequisite. IBS patterns include: IBS-D: diarrhoea-predominant IBS-C: constipation-predominant IBS-M: mixed bowel habits IBS-U: unclassified Painless diarrhoea or constipation excludes IBS and suggests alternative diagnoses. Abdominal bloating/distention (Option A): Common supportive symptom, but not required for diagnosis. Chronic watery diarrhoea (Option C): Describes IBS-D, but diarrhoea alone without pain does not meet the criteria. Feeling of incomplete evacuation (Option D): Frequent in IBS, but not a mandatory Rome IV criterion.

References:

Harrison's Principles of Internal Medicine, 22nd Edition, Page 2571.

↑ *Back to this question in Part A*

@Neet_pg_bot

Q14: 65-year-old man with obesity and hypertension develops haematochezia needing hospitalization. Which of the following is probable cause? (Q850828)

A. Diverticulitis

B. Colorectal cancer

C. Irritable bowel syndrome

D. Internal Haemorrhoids

Correct Answer: A. Diverticulitis

■ *Listen (English)*

■ *Listen (Hindi)*

Explanation: The leading cause of haematochezia in the geriatric age group that needs immediate hospitalization is diverticulitis. Colorectal cancer (Option B) will cause symptoms like constipation, weight loss over a period of time. Irritable bowel syndrome (Option C) will present with recurrent abdominal pain with diarrhea alternating with constipation. Internal Haemorrhoids (Option D) will not require hospitalization in most cases.

References:

Harrison's Principles of Internal Medicine, 22nd Edition, Page 2579.

↑ *Back to this question in Part A*

@Neet_pg_bot

Q15: A 30-year-old lady with GERD symptoms underwent a UGI endoscopy that shows loss of vascular pattern, multiple rings and trachealization appearance of oesophagus. Which of the following is correct diagnosis? (Q850826)

A. IBS-D

B. Barrett oesophagus

C. Eosinophilic esophagitis

D. Achalasia cardia

Correct Answer: C. Eosinophilic esophagitis

■ *Listen (English)*

■ *Listen (Hindi)*

Explanation: Key words are “trachealisation” or ringed appearance of the esophagus, which is seen in eosinophilic esophagitis. It is associated with GERD. IBS-D (Irritable bowel syndrome -Diarrhea predominant) (Option A): This is a functional bowel disorder and unrelated to esophageal endoscopic findings. Barrett's oesophagus (Option B): Characterized by a salmon-pink, velvety mucosa replacing normal pale squamous mucosa, usually involves mucosal metaplasia at the distal esophagus, not multiple rings or corrugation. Achalasia cardia (Option D): Endoscopy often shows a dilated esophagus with retained food and smooth esophageal mucosa

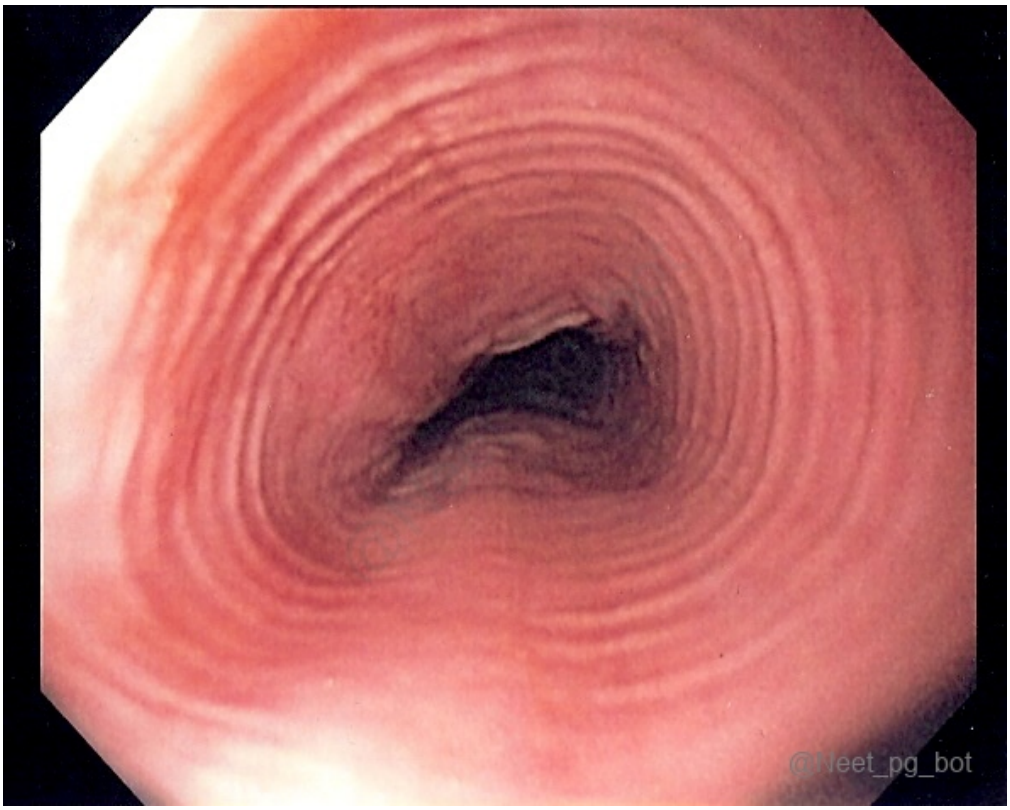

References:

Harrison's Principles of Internal Medicine, 22nd Edition, Page 2512.

↑ *Back to this question in Part A*

@Neet_pg_bot

Q16: A 35-year-old female presents with chronic abdominal pain, bloating, and alternating diarrhea and constipation. Following a diagnosis of Irritable Bowel Syndrome (IBS), which dietary approach is considered the most effective for managing her symptoms? (Q850825)

A. Low gluten diet

B. Atkins diet

C. Ketogenic diet

D. Low FODMAP diet

Correct Answer: D. Low FODMAP diet

■ *Listen (English)*

■ *Listen (Hindi)*

Explanation: A Low FODMAP diet in IBS patients involves restricting certain fermentable carbohydrates known as FODMAPs (fermentable oligosaccharides, disaccharides, monosaccharides, and polyols) that are poorly absorbed in the small intestine. These FODMAPs can cause symptoms of IBS such as bloating, abdominal pain, diarrhoea, and gas due to their fermentation by gut bacteria and osmotic effects in the intestine. Low gluten diet (Option A): Advised in Celiac sprue. Atkins diet (Option B) & Ketogenic diet (Option C): Followed for weight loss.

References:

Harrison's Principles of Internal Medicine, 22nd Edition, Page 2576, 2577.

↑ *Back to this question in Part A*

@Neet_pg_bot

Q17: A 28-year-old patient presents with months of recurrent abdominal pain and diarrhea, now alternating with constipation. He also reports weight loss, low-grade fever, and laboratory findings of normocytic anemia with elevated inflammatory markers. What is the most likely diagnosis? (Q850822)

A. IBS

B. IBD

C. Tropical sprue

D. Bacterial overgrowth syndrome

Correct Answer: B. IBD

■ *Listen (English)*

■ *Listen (Hindi)*

Explanation: This patient has red flag features —weight loss, fever, and anemia—along with elevated inflammatory markers, all of which strongly indicate organic inflammation , not a functional disorder. IBD (Crohn disease or ulcerative colitis) typically presents with chronic diarrhea, abdominal pain, systemic symptoms, and inflammatory anemia. Irritable bowel syndrome (IBS) (Option A) : IBS can cause alternating diarrhea and constipation but never causes fever, weight loss, anemia, or elevated inflammatory markers. These systemic findings exclude IBS. Tropical sprue (Option C): Usually presents with severe malabsorption and megaloblastic anemia , and is associated with travel to tropical regions. Bacterial overgrowth syndrome (Option D): Can cause diarrhea and bloating but rarely causes systemic inflammation or anemia.

References:

Harrison's Principles of Internal Medicine, 22nd Edition, Page 2556.

↑ *Back to this question in Part A*

@Neet_pg_bot

Q18: Which of the following is correct about mechanism of action of Lubiprostone used in IBS-C? (Q850819)

A. Increase intestinal chloride secretion

B. 5HT4 receptor agonist

C. 5HT4 receptor antagonist

D. Guanylate cyclase -C agonist

Correct Answer: A. Increase intestinal chloride secretion

■ *Listen (English)*

■ *Listen (Hindi)*

Explanation: Lubiprostone is a secretagogue that acts on intestinal enterocytes by activating chloride channels on the apical membrane of the intestinal epithelial cells. To maintain electroneutrality, sodium ions follow the chloride ions into the intestinal lumen. This ionic movement creates an osmotic gradient that draws water into the lumen. The influx of water softens the stool and increases intestinal fluid content, which helps relieve constipation by promoting easier bowel movements. This mechanism makes lubiprostone an effective treatment for constipation-predominant irritable bowel syndrome (IBS-C) and chronic idiopathic constipation, as it improves stool consistency and bowel movement frequency by enhancing intestinal fluid secretion and motility. 5HT4 receptor agonist (Option B): This describes drugs like Prucalopride or Tegaserod , which stimulate serotonin receptors to increase motility. 5HT4 receptor antagonist (Option C): These drugs like Alosetron are actually used for IBS-D (diarrhea-predominant) to slow down the gut, not for constipation. Guanylate cyclase-C agonist (Option D): This is the mechanism for Linaclotide and Plecanatide , which increase cyclic GMP to stimulate fluid secretion.

References:

Harrison's Principles of Internal Medicine, 22nd Edition, Page 2576.

↑ *Back to this question in Part A*

@Neet_pg_bot

• [05_Gastrointestinal System] 034 Peptic Ulcer And Gastrointestinal Bleeding

« Back to Folder Directory

[05_Gastrointestinal System] 034 Peptic Ulcer And Gastrointestinal Bleeding — Quick Jump

Q1 (p. 1959) *Q2 (p. 1960)* *Q3 (p. 1960)* *Q4 (p. 1961)* *Q5 (p. 1962)* *Q6 (p. 1963)*
Q7 (p. 1964) *Q8 (p. 1964)* *Q9 (p. 1965)* *Q10 (p. 1966)* *Q11 (p. 1967)* *Q12 (p. 1968)*
Q13 (p. 1969) *Q14 (p. 1970)*

Q1: A 30-year-old alcoholic patient presents with vomiting episode and hematemesis. On examination pulse thready 120/min, BP is 80/60 mmHg with cold clammy hands and feet. Per abdomen shows splenomegaly. Which is next best step in management of this patient? (Q850830)

A. UGIE

B. Large-bore IV access and rapid blood transfusion

C. Octreotide infusion

D. Bolus terlipressin

Correct Answer: B. Large-bore IV access and rapid blood transfusion

■ *Listen (English)*

■ *Listen (Hindi)*

Explanation: Patient with upper GI bleeding is having hemodynamic instability. Presence of splenomegaly in an alcoholic indicates portal hypertension and variceal bleeding. Fluid resuscitation followed by massive transfusion is the top priority for management of this patient. UGIE (Option A): Diagnostic and therapeutic but should be done after stabilization . Octreotide infusion (Option C): Adjunct for variceal bleeding, not first step in unstable patients. Bolus terlipressin (Option D): Can reduce portal hypertension in variceal bleeding but after resuscitation is initiated .

References:

Harrison's Principles of Internal Medicine, 22nd Edition, Page 319.

↑ *Back to this question in Part A*

@Neet_pg_bot

Q2: An elderly man had undergone PCI with stenting 6 weeks ago. Today he passed fresh blood in stool and then collapses in the washroom. On admission pulse is 130 /min, low volume and BP is 80/60 mm Hg. His wife tells that yesterday he was complaining of melena. Medication history is of use of aspirin and clopidogrel for last 6 weeks. Which of the following investigations should be done to determine source of bleeding? (Q850832)

A. Upper GI Endoscopy

B. Colonoscopy

C. Stool for occult blood

D. USG abdomen

Correct Answer: A. Upper GI Endoscopy

■ *Listen (English)*

■ *Listen (Hindi)*

Explanation: The patient is having upper GI bleeding due to the use of aspirin. Erosive gastritis / PUD would have caused melena initially and later haematochezia. The investigations to determine the source of bleeding include upper GI endoscopy Colonoscopy (Option B) is typically reserved for when an upper GI endoscopy is negative or when bleeding is clearly from the lower GI tract. Stool occult blood testing (Option C) is not useful here because the bleeding is overt, and the patient is unstable. Abdominal ultrasound (Option D) will not help in identifying the source of GI bleeding.

References:

Harrison's Principles of Internal Medicine, 22nd Edition, Page 317, 319.

↑ *Back to this question in Part A*

@Neet_pg_bot

Q3: Alcoholic patient with bleeding oesophageal varices is stabilized in ICU. Which of the following interventions will be done in this patient to prevent recurrence of such an event? (Q850833)

A. Endoscopic variceal ligation

B. Trans-jugular intrahepatic portosystemic shunting

C. Octreotide infusion with albumin

D. Terlipressin with midodrine

Correct Answer: A. Endoscopic variceal ligation

■ *Listen (English)*

■ *Listen (Hindi)*

Explanation: Endoscopic variceal ligation is the primary recommended procedure for both emergency control and secondary prevention of esophageal variceal bleeding. After initial EVL therapy, repeat sessions are often needed until varices are eradicated or sufficiently reduced. Transjugular intrahepatic portosystemic shunting (TIPS) (Option B) is generally reserved for patients who fail endoscopic and medical therapy or have recurrent bleeding. Medical therapies such as vasoactive drugs-octreotide or terlipressin (Options C and D), are used acutely to control bleeding and as adjuncts but are not sufficient alone for long-term prevention.

References:

Harrison's Principles of Internal Medicine, 22nd Edition, Page 317.

↑ *Back to this question in Part A*

@Neet_pg_bot

Q4: Patient with upper GI bleeding and pedal oedema is found to have ‘cerebriform appearance of stomach mucosa’ on UGI endoscopy. Diagnosis is? (Q850836)

A. Gastric antral vascular ectasia

B. Menetrier disease

C. GIST

D. MALToma

Correct Answer: B. Menetrier disease

■ *Listen (English)*

■ *Listen (Hindi)*

Explanation: Menetrier disease is a rare hypertrophic gastropathy characterized by enlarged, thickened gastric folds with a characteristic cerebriform /brain-like convoluted appearance on endoscopy. The disease features foveolar hyperplasia (proliferation of mucus-secreting cells), leading to thickened gastric folds visible endoscopically with this distinctive appearance. Gastric antral vascular ectasia (Option A): “Watermelon stomach,” vascular ectasia in antrum, not cerebriform. GIST (Option C): Submucosal tumor, usually nodular/mass-like, not diffuse cerebriform folds. MALToma (Option D): Lymphoma of gastric mucosa, presents as ulcer or mass, not cerebriform mucosal folds.



References:

Harrison's Principles of Internal Medicine, 22nd Edition, Page 2549.
https://www.ncbi.nlm.nih.gov/books/NBK563154/

↑ *Back to this question in Part A*

@Neet_pg_bot

Q5: Which of the following is most common site of Mallory Weiss syndrome? (Q850837)

A. Lower 1/3 rd of Oesophagus

B. Middle 1/3 rd of Oesophagus

C. Lower Oesophageal sphincter

D. Pylorus of stomach

Correct Answer: C. Lower Oesophageal sphincter

■ *Listen (English)*

■ *Listen (Hindi)*

Explanation: Mallory–Weiss tears are longitudinal mucosal lacerations occurring at the gastroesophageal junction , most often at the lower esophageal sphincter , typically on the gastric side of the GE junction. Lower 1/3rd of Oesophagus (Option A): Tears may extend slightly into this region but the classical location is the gastro-esophageal junction/LES , not the oesophagus alone. Second most common site. Middle 1/3rd of Oesophagus (Option B): Not typical for Mallory-Weiss tears. Pylorus of stomach (Option D): Not involved; the lesion occurs proximally at the gastro-esophageal junction.

References:

Harrison's Principles of Internal Medicine, 22nd Edition, Page 317, 2489.
https://www.ncbi.nlm.nih.gov/books/NBK538190/

↑ *Back to this question in Part A*

@Neet_pg_bot

Q6: Alcoholic went for a party and did binge drinking. He developed coffee ground vomitus episodes and developed cold clammy extremities. Post volume resuscitation UGI endoscopy was done revealed a ulcer in first part of duodenum. Which of the tests will be done to determine the aetiology of this presentation? (Q850840)

A. Ultrasound abdomen for liver echotexture

B. Urease test

C. Doppler to measure portal vein pressure

D. Oesophageal manometry

Correct Answer: B. Urease test

■ *Listen (English)*

■ *Listen (Hindi)*

Explanation: Duodenal ulcers are most commonly caused by Helicobacter pylori infection, especially in the context of acute upper GI bleeding. The urease test detects H. pylori, which produces the urease enzyme. Ultrasound abdomen for liver echotexture (Option A): Useful for alcoholic liver disease and check for ascites, splenomegaly, which indicate portal hypertension. Doppler to measure portal vein pressure (Option C): This is ruled out as the question itself mentions an ulcer in D1. Esophageal manometry (Option D): Used for motility disorders, not for ulcer etiology.

References:

Harrison's Principles of Internal Medicine, 22nd Edition, Page 1301.

↑ *Back to this question in Part A*

@Neet_pg_bot

Q7: H. Pylori can lead to development of all of the following except? (Q850843)

A. MALToma

B. Duodenal ulcer

C. Gastric adenocarcinoma

D. Barrett oesophagus

Correct Answer: D. Barrett oesophagus

■ *Listen (English)*

■ *Listen (Hindi)*

Explanation: Barrett esophagus: Barrett's esophagus is linked to GERD and not linked to H. pylori infection. There is an inverse relationship with H. pylori infection reducing the risk of developing Barrett's esophagus H. Pylori is a class I carcinogen and leads to gastric adenocarcinoma (Option C) and MALToma (Option A). The hyperchlorhydria state induced by this bacteria explains the development of duodenal ulcer (Option C).

References:

Harrison's Principles of Internal Medicine, 22nd Edition, Page 1300.

↑ *Back to this question in Part A*

@Neet_pg_bot

Q8: You have given triple therapy to a patient with documented H. Pylori infection by urease test. Which is correct about follow up of this patient? (Q850845)

A. Call after 4 weeks of treatment completion and do urea breath test

B. Call after 4 weeks of treatment completion and do repeat endoscopy

C. Call after 4 weeks of treatment completion and do stool PCR for toxin A and toxin B

D. Call after 4 weeks of treatment completion and give reassurance

Correct Answer: A. Call after 4 weeks of treatment completion and do urea breath test

■ *Listen (English)*

■ *Listen (Hindi)*

Explanation: The guidelines are to wait at least 1 month after treatment finishes. During that period, no antibiotics, bismuth compounds, or proton pump inhibitors are to be given as these can influence test accuracy. Subsequently, the patient is to be tested with either UBT or stool antigen for H. Pylori. In summary, UBT is used not only for screening for documentation of eradication of infection. Stool PCR for toxins A and B (Option C) is for Clostridium difficile infection and not H. pylori.

References:

Harrison's Principles of Internal Medicine, 22nd Edition, Page 1302.

↑ *Back to this question in Part A*

@Neet_pg_bot

Q9: 60 year old obese man is having osteoarthritis and he is taking ibuprofen daily for the past 3 months. He developed epigastric pain and occult GI bleeding. Which of the following is correct about the cause? (Q850846)

A. PGE2 and prostacyclin production reduced with decreased mucosal barrier

B. Increased acid production due to ibuprofen

C. PGE1 and prostacyclin production reduced with decreased mucosal barrier

D. Mucosal injury due to inhibition of COX-2

Correct Answer: A. PGE2 and prostacyclin production reduced with decreased mucosal barrier

■ *Listen (English)*

■ *Listen (Hindi)*

Explanation: Ibuprofen is a non-steroidal anti-inflammatory drug (NSAID) that inhibits cyclooxygenase enzymes (COX-1 and COX-2). This inhibition decreases the synthesis of protective prostaglandins, especially PGE2 and prostacyclin (PGI2), in the gastric mucosa. Increased acid production due to ibuprofen (Option B): NSAIDs don't directly increase acid; injury is due to reduced mucosal protection. PGE1 and prostacyclin production reduced (Option C): PGE2 is the key gastric protective prostaglandin, not PGE1. Mucosal injury due to inhibition of COX-2 (Option D): COX-2 inhibition mainly affects inflammation, COX-1 inhibition causes gastric mucosal injury.

References:

Harrison's Principles of Internal Medicine, 22nd Edition, Page 2517.

↑ *Back to this question in Part A*

@Neet_pg_bot

Q10: 30-year-old alcoholic male presents with diffuse abdominal pain and prostration. On examination guarding and rigidity of anterior abdominal wall is noted. Urgent X ray abdomen is done. Past medical records show multiple hospital visits for epigastric pain and positive “clo test’. Which of the following is the cause of this presentation? (Q850847)

A. Viscus perforation

B. Necrotising pancreatitis

C. Pseudo-pancreatic cyst

D. Acute mesenteric insufficiency

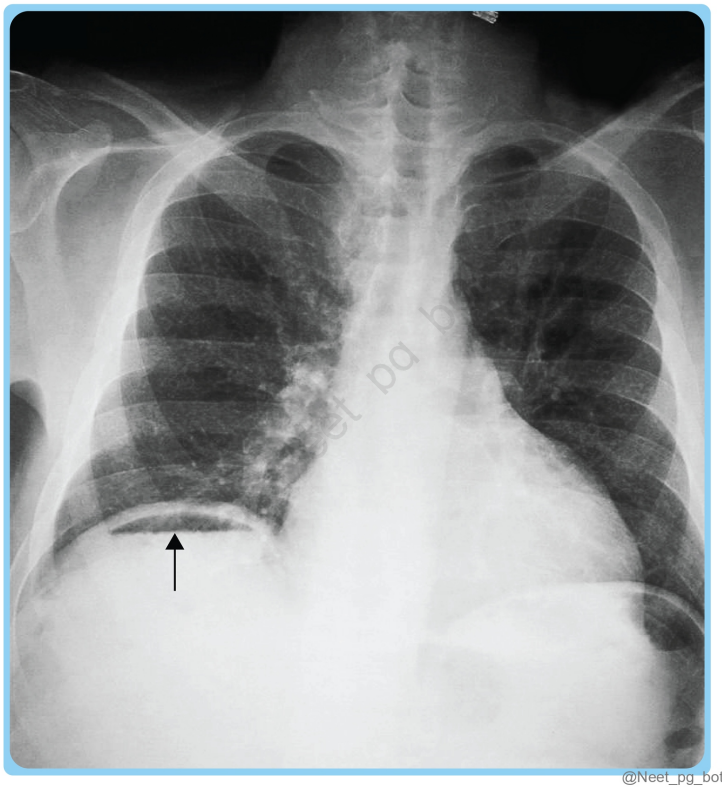

Correct Answer: A. Viscus perforation

■ *Listen (English)*

■ *Listen (Hindi)*

Explanation: Guarding and rigidity of the abdomen are classic signs of peritonitis, which occurs when there is leakage of gastrointestinal contents into the peritoneal cavity, causing inflammation. A positive Clo test implies a positive urease test. The patient is having an H. Pylori infection that would have caused PUD. Due to a possible

lack of compliance with medication, he has currently developed viscus perforation. Necrotising pancreatitis (Option B): Imaging shows pancreatic enlargement, peripancreatic fat stranding, or fluid collections, not free air. Pseudo-pancreatic cyst (Option C): Imaging shows well-defined fluid-filled cyst in pancreas, without signs of perforation. Acute mesenteric insufficiency (Option D): Imaging (CT angiography) may show bowel wall thickening, pneumatosis, or mesenteric vessel occlusion, not free intraperitoneal air.

References:

Harrison's Principles of Internal Medicine, 22nd Edition, Page 2522.

↑ *Back to this question in Part A*

@Neet_pg_bot

Q11: A 65-year-old patient with a history of atrial fibrillation presents with vomiting and sudden onset severe diffuse abdominal pain that is disproportionate to physical examination findings. On examination, the abdomen is soft with minimal tenderness, but tachycardia is noted. Laboratory studies reveal elevated lactate levels. What is the most appropriate next step to confirm the diagnosis? (Q850848)

A. Abdominal X-ray

B. CT angiography

C. Colonoscopy

D. Upper gastrointestinal endoscopy

Correct Answer: B. CT angiography

■ *Listen (English)*

■ *Listen (Hindi)*

Explanation: Correct answer is B: CT angiography Atrial fibrillation is a common risk factor for embolic events, including embolism to the mesenteric arteries. The hallmark clinical feature is severe abdominal pain that is disproportionate to physical findings (soft abdomen with minimal tenderness), and the clinical diagnosis is acute mesenteric insufficiency. Elevated lactate indicates tissue hypoperfusion and ischemia. Tachycardia is a response to pain and early systemic stress. Hence, the most appropriate next step is to perform CT angiography of the mesenteric vessels Abdominal X-ray (Option A): May show nonspecific bowel gas changes, not reliable for diagnosis. Colonoscopy (Option C): Not indicated acutely; may risk perforation in ischemic bowel. Upper gastrointestinal endoscopy (Option D): Evaluates esophagus, stomach, and duodenum, not mesenteric vessels.

References:

Harrison's Principles of Internal Medicine, 22nd Edition, Page 2587.

↑ *Back to this question in Part A*

Q12: HIV positive truck driver presents with odynophagia. UGIE shows serpiginous ulcers in oesophagus. Biopsy from ulcer base shows basophilic intranuclear and intracytoplasmic bodies. Which is the likely cause of this presentation? (Q850849)

A. HSV

B. CMV

C. Candida

D. Varicella zoster

Correct Answer: B. CMV

■ *Listen (English)*

■ *Listen (Hindi)*

Explanation: The keyword is serpiginous ulcers in the esophagus with histological finding of basophilic intranuclear and intracytoplasmic inclusion bodies that is seen with CMV. HSV (Option A): Presents as small, deep, "punched-out" (volcano) ulcers; biopsy must be from the ulcer edge and shows only intranuclear (Cowdry A) inclusions. Candida Albicans (Option C): The most common cause, but presents as white, adherent plaques (like cottage cheese) rather than ulcers, showing pseudohyphae on microscopy. Varicella Zoster (Option D): Extremely rare and typically occurs alongside a visible skin rash (shingles), sharing the same "ulcer edge" biopsy features as HSV.

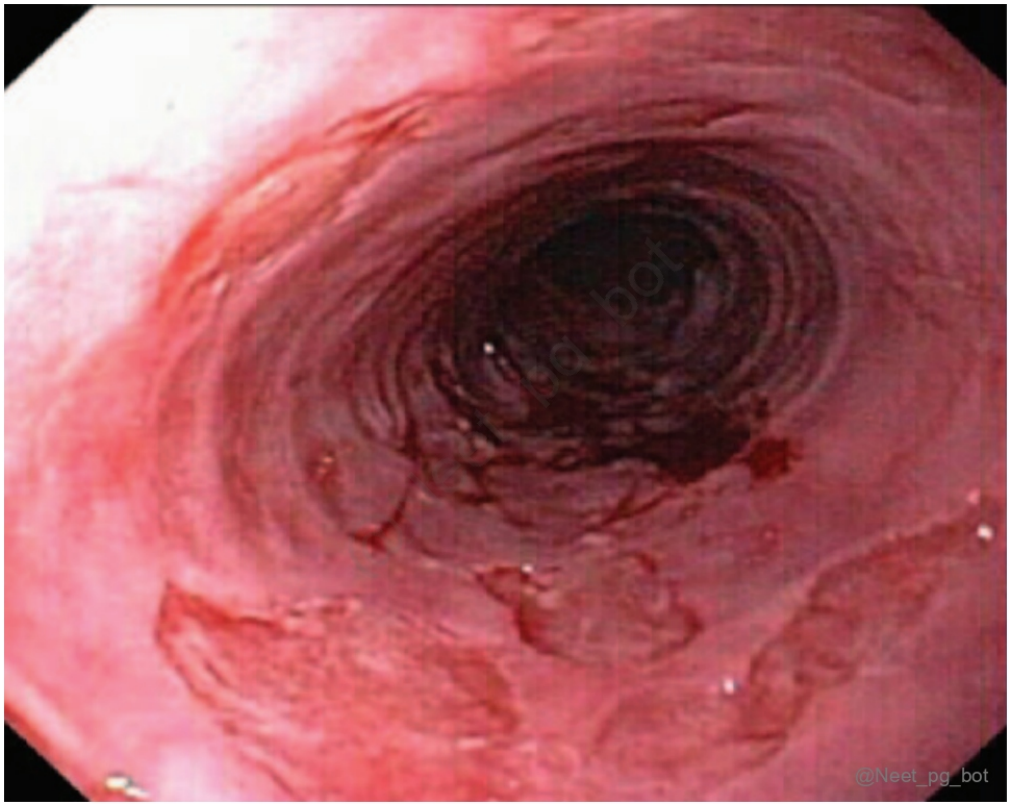

References:

Harrison's Principles of Internal Medicine, 22nd Edition, Page 2513.

↑ *Back to this question in Part A*

@Neet_pg_bot

Q13: 40-year-old female patient presents with dysphagia for past one year to solid food items . On examination, she has pallor with cheilosis and koilonychia. The diagnosis is? (Q850851)

A. Plummer Vinson syndrome

B. Oesophageal cancer

C. Achalasia cardia

D. Tylosis palmaris

Correct Answer: A. Plummer Vinson syndrome

■ *Listen (English)*

■ *Listen (Hindi)*

Explanation: Plummer-Vinson syndrome is characterized by the classical triad of dysphagia, iron deficiency anemia, and esophageal webs. Dysphagia in PVS is due to esophageal webs leading to difficulty swallowing, typically solids. Oesophageal cancer (Option B): Usually presents later in life with progressive dysphagia, weight loss, and may lack iron deficiency signs. Achalasia cardia (Option C): Dysphagia involves both solids and liquids, not associated with iron deficiency anemia. Tylosis palmaris (Option D): Involves thickened palms/soles; dysphagia is not a feature.

References:

Harrison's Principles of Internal Medicine, 22nd Edition, Page 765.

↑ *Back to this question in Part A*

@Neet_pg_bot

Q14: Which of the following conditions will have "watermelon appearance of stomach mucosa" on upper GI endoscopy? (Q850852)

A. Gastric antral vascular ectasia

B. Menetrier disease

C. MALToma

D. Gastrointestinal stromal tumor

Correct Answer: A. Gastric antral vascular ectasia

■ *Listen (English)*

■ *Listen (Hindi)*

Explanation: In GAVE , longitudinal columns of ectatic mucosal vessels radiate outward from the pylorus, resembling the stripes of a watermelon. It can also be seen in patients with systemic sclerosis. It presents with chronic blood loss Histology: fibromuscular hyperplasia, spindle cell proliferation, and capillary ectasia in the lamina propria. Menetrier disease (Option B) presents with giant rugal folds due to protein-losing gastropathy, not vascular stripes. MALToma (Option C) occurs due to H. Pylori and presents as nodularity or ulceration GIST (Option D) is a stromal tumor and presents as a submucosal mass

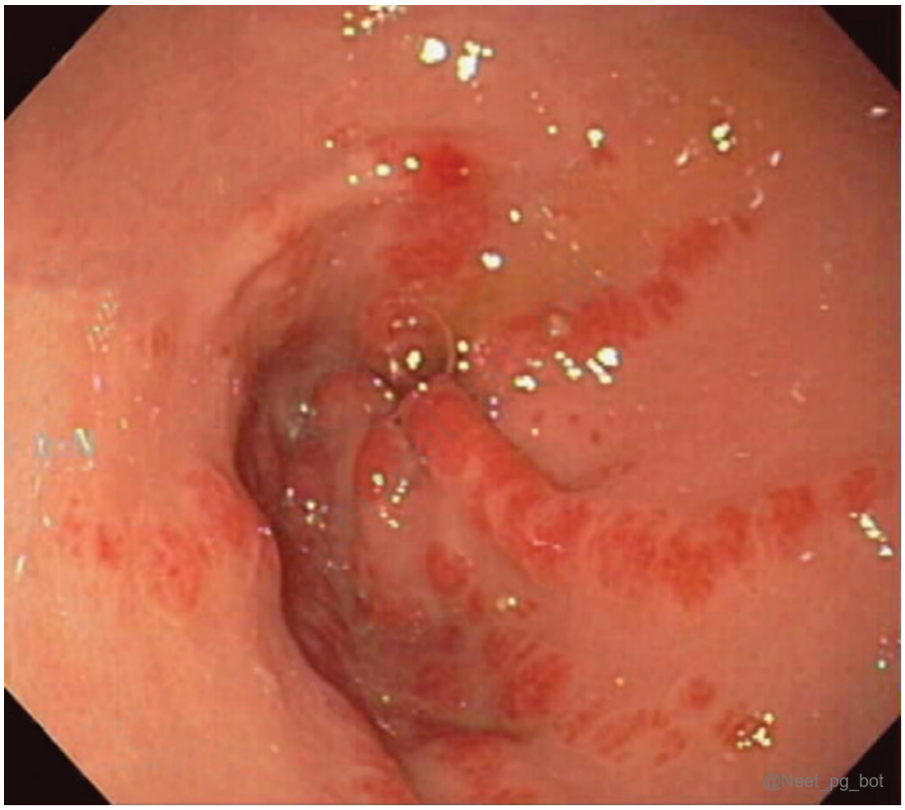

References:

Harrison's Principles of Internal Medicine, 22nd Edition, Page 2870.

↑ *Back to this question in Part A*

@Neet_pg_bot

• [05_Gastrointestinal System] 035 Diarrhea Malabsorption Syndromes - I

« Back to Folder Directory

[05_Gastrointestinal System] 035 Diarrhea Malabsorption Syndromes - I — Quick Jump

Q1 (p. 1972)	*Q2 (p. 1973)*	*Q3 (p. 1973)*	*Q4 (p. 1975)*	*Q5 (p. 1975)*	*Q6 (p. 1976)*
Q7 (p. 1977)	*Q8 (p. 1977)*	*Q9 (p. 1978)*	*Q10 (p. 1979)*	*Q11 (p. 1980)*	*Q12 (p. 1980)*
Q13 (p. 1981)	*Q14 (p. 1982)*	*Q15 (p. 1983)*	*Q16 (p. 1984)*	*Q17 (p. 1984)*	*Q18 (p. 1985)*
Q19 (p. 1986)	*Q20 (p. 1987)*	*Q21 (p. 1987)*	*Q22 (p. 1988)*	*Q23 (p. 1989)*	*Q24 (p. 1989)*

Q1: Which of the following GI condition will have intestinal biopsy finding of normal villi with epithelial cells vacuolated with fat post prandially? (Q850870)

A. Abetalipoproteinemia

B. Agammaglobulinemia

C. Intestinal lymphangiectasia

D. Intestinal lymphoma

Correct Answer: A. Abetalipoproteinemia

■ *Listen (English)*

■ *Listen (Hindi)*

Explanation: Abetalipoproteinemia has a deficiency of microsomal triglyceride transfer protein (MTTP). This defect causes failure to transport dietary fats, cholesterol, and fat-soluble vitamins (A, D, E, and K) from the intestines and liver into the bloodstream. Agammaglobulinemia (Option B) : There is a significant deficiency of immunoglobulins, including IgA, which compromises this protective mucosal immunity. As a result, patients are more susceptible to recurrent infections such as bloody diarrhea and infectious gastroenteritis. Gut biopsy will have absence of plasma cells. Intestinal lymphangiectasia (Option C) has dilated lymphatics with clubbing of villi. Intestinal lymphoma (Option D) will have malignant cells in the lamina propria and submucosa.

References:

Harrison's Principles of Internal Medicine, 22nd Edition, Page 2545.

↑ *Back to this question in Part A*

@Neet_pg_bot

Q2: Which of the following organisms is most classically associated with gastroenteritis due to ingestion of a preformed toxin? (Q890578)

A. Salmonella enterica

B. Staphylococcus aureus

C. Shigella dysenteriae

D. Campylobacter jejuni

Correct Answer: B. Staphylococcus aureus

Explanation: Staphylococcus aureus causes gastroenteritis by ingestion of preformed, heat-stable enterotoxins already present in contaminated food. Symptoms develop rapidly (1-6 hours) after ingestion because illness is toxin-mediated, not due to bacterial invasion or replication. Disease results from toxins produced in food before ingestion. Characterised by abrupt onset, prominent nausea and vomiting, and minimal or no fever. Illness is self-limited and resolves without antibiotics. Classic causative organisms: Staphylococcus aureus Bacillus cereus (emetic type, classically reheated rice) Salmonella enterica (Option A): Causes invasive infection after ingestion; toxin is not produced. Shigella dysenteriae (Option C): Produces toxin after colonic invasion, causing inflammatory diarrhoea. Campylobacter jejuni (Option D): Causes inflammatory colitis with fever and abdominal pain.

References:

Harrison’s Principles of Internal Medicine, 22nd Edition, Page 306.

↑ *Back to this question in Part A*

@Neet_pg_bot

Q3: A 40 y/o woman presents with acute, profuse watery diarrhoea and severe dehydration after consuming contaminated water. Stool microscopy findings are shown below. She is hypotensive, with laboratory evidence of prerenal azotemia. Which of the following statements best distinguishes this presentation from osmotic diarrhoea in terms of fluid and electrolyte pathophysiology? (Q890577)

A. The diarrhoea would cease immediately upon stopping oral intake

B. The diarrhoea persists despite a 24-hour fast

C. The stool pH is acidic due to bacterial fermentation

D. The primary driver of fluid loss is nutrient malabsorption

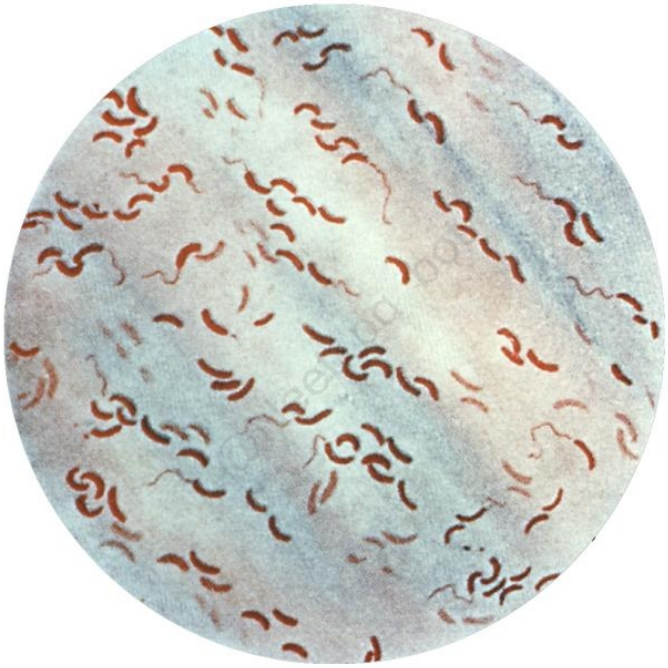

@Neet_pg_bot

Correct Answer: B. The diarrhoea persists despite a 24-hour fast

Explanation: The clinical features and stool microscopy describe acute secretory diarrhoea , classically seen with cholera or other toxin-mediated infections , leading to profuse watery stools and severe dehydration . In secretory diarrhoea , there is active secretion of electrolytes and water by the intestinal epithelium, so diarrhoea continues even during fasting . Cholera: Cholera causes secretory diarrhoea due to toxin-mediated activation of chloride secretion. Mechanism of action: Fluid loss is driven by active ion secretion; diarrhoea persists despite fasting, unlike osmotic diarrhoea. Cholera toxin activates adenylate cyclase, increasing intracellular cAMP. This leads to massive Cl■ secretion via CFTR channels, followed by Na■ and water. Resulting electrolyte abnormalities include: Severe hypovolemia Hyponatremia Hypokalemia Metabolic acidosis (bicarbonate loss) Prerenal azotemia due to volume depletion Diarrhoea is high-volume, watery (“rice-water stools”), and continues during fasting and sleep. The diarrhoea would cease immediately upon stopping oral intake (Option A): Characteristic of osmotic diarrhoea, not cholera. The stool pH is acidic due to bacterial fermentation (Option C): Seen in carbohydrate malabsorption with bacterial fermentation. The primary driver of fluid loss is nutrient malabsorption (Option D): Drives osmotic diarrhoea; cholera involves active secretion, not malabsorption.

References:

Harrison’s Principles of Internal Medicine, 22nd Edition, Pages 1327, 1328.

↑ *Back to this question in Part A*

@Neet_pg_bot

Q4: A history of exposure to contaminated water in a patient presenting with diarrhoea most strongly raises concern for which of the following etiologic agents? (Q890576)

A. Staphylococcus aureus

B. Giardia lamblia

C. Clostridioides difficile

D. Cytomegalovirus

Correct Answer: B. Giardia lamblia

Explanation: Exposure to contaminated water classically raises concern for protozoal pathogens, particularly Giardia lamblia and Cryptosporidium. Traveller's diarrhoea is most commonly infectious and related to food or water contamination. Route of infection: Waterborne, especially in travellers and campers. Protozoa (Giardia and Cryptosporidium) are strongly associated with contaminated water sources. Protozoal diarrhoea is often subacute or persistent, with bloating, malabsorption, and non-bloody stools. Bacterial causes (e.g., E. coli) are more food-associated, while protozoa dominate waterborne exposure histories. Staphylococcus aureus (Option A): Causes food poisoning via preformed toxin, not waterborne illness. Clostridioides difficile (Option C): Associated with antibiotic or healthcare exposure, not travel or water exposure. Cytomegalovirus (Option D): Causes colitis in immunocompromised hosts, not typical traveller’s diarrhoea.

References:

Harrison’s Principles of Internal Medicine, 22nd Edition, Page 2546.

↑ *Back to this question in Part A*

@Neet_pg_bot

Q5: A 22 y/o man with 2 days of fever and right lower-quadrant abdominal pain with mild diarrhoea. O/E, he has tenderness at McBurney's point. Laparoscopy reveals the terminal ileum is thickened and inflamed with mesenteric lymphadenopathy. Which organism is the most likely etiologic agent responsible for this presentation? (Q890575)

A. Campylobacter jejuni

B. Yersinia enterocolitica

C. Shigella dysenteriae

D. Giardia lamblia

Correct Answer: B. Yersinia enterocolitica

Explanation: This presentation is classic for pseudoappendicitis . Yersinia enterocolitica preferentially infects the terminal ileum and Peyer's patches , causing RLQ pain , fever , mild diarrhoea, thickened terminal ileum , and mesenteric lymphadenitis , closely mimicking acute appendicitis. Yersinia enterocolitica preferentially infects the terminal ileum and mesenteric lymph nodes. It causes terminal ileitis with mesenteric adenitis, producing RLQ pain and fever that clinically mimics acute appendicitis ("pseudoappendicitis"). Pseudoappendicitis refers to appendicitis-like symptoms with a normal appendix. The classic cause is Yersinia enterocolitica, especially in young adults. Pathology includes ileal wall thickening, mucosal ulceration, neutrophilic invasion, and lymph node enlargement. Mild diarrhoea may be present, helping distinguish it from true appendicitis. Campylobacter jejuni (Option A): Primarily causes colitis resembling ulcerative colitis, not terminal ileitis. Shigella dysenteriae (Option C): Causes distal colitis with dysentery and tenesmus, not ileitis. Giardia lamblia (Option D): Causes malabsorption and watery diarrhoea without inflammatory ileal thickening.

References:

Harrison's Principles of Internal Medicine, 22nd Edition, Pages 2559, 2560.

↑ *Back to this question in Part A*

@Neet_pg_bot

Q6: In the evaluation of diarrhoea in an immunocompromised adult, which of the following viral agents should be considered a potential aetiology? (Q890574)

A. Hepatitis A virus

B. Adenovirus

C. Hepatitis C virus

D. Epstein-Barr virus

Correct Answer: B. Adenovirus

Explanation: In immunocompromised adults (e.g., transplant recipients, HIV, chemotherapy), adenovirus is a well-recognised cause of viral gastroenteritis and chronic diarrhoea . It can cause severe, persistent diarrhoea and colitis in this population. Along with cytomegalovirus, adenovirus is a well-recognised viral pathogen producing persistent or severe diarrhoea in this population. In immunocompetent adults, viral diarrhoea is usually self-limited (e.g., norovirus). In immunocompromised patients, atypical and opportunistic viruses must be considered. Adenovirus and CMV are specifically highlighted as causes ofdiarrhoeaa in immunocompromised hosts. These infections may cause prolonged, severe, or refractory diarrhoea, unlike typical viral gastroenteritis. Hepatitis A virus (Option A): Transmitted fecally but causes acute hepatitis, not diarrheal illness. Hepatitis C virus (Option C): Blood-borne virus causing chronic hepatitis, not diarrhoea. Epstein-Barr virus (Option D): Causes infectious

mononucleosis; diarrhoea is not a primary feature.

References:

Harrison’s Principles of Internal Medicine, 22nd Edition, Pages 2550, 2551.

↑ *Back to this question in Part A*

@Neet_pg_bot

Q7: Which pathophysiologic mechanism is primarily responsible for the diarrhoea observed in patients with bile acid malabsorption? (Q890572)

A. Osmotic retention of water by unabsorbed fatty acids

B. Stimulation of active colonic fluid and electrolyte secretion

C. Exudation of protein and fluid due to mucosal inflammation

D. Inhibition of pancreatic enzyme activity

Correct Answer: B. Stimulation of active colonic fluid and electrolyte secretion

Explanation: In bile acid malabsorption, unabsorbed bile acids reach the colon, where they directly stimulate active secretion of water and electrolytes. This produces a secretory diarrhoea, classically termed cholerheic diarrhoea, with a low stool osmotic gap. Features of bile acid diarrhoea: Occurs most commonly after limited ileal disease or resection (<100 cm). The bile acid pool is preserved, so fat absorption remains relatively intact. Diarrhoea is watery, high-volume, and persists during fasting, distinguishing it from osmotic diarrhoea. Bile acids also activate TGR5 receptors, increasing colonic motility and worsening diarrhoea. Osmotic retention by fatty acids (Option A): Mechanism of steatorrhea due to bile acid depletion, not bile-acid diarrhoea. Exudative protein loss (Option C): Seen in inflammatory mucosal disease (e.g., IBD), not bile acid-mediated effects. Inhibition of pancreatic enzymes (Option D): Pancreatic secretion is intact; bile acids do not inhibit enzymes.

References:

Harrison’s Principles of Internal Medicine, 22nd Edition, Page 2543.

↑ *Back to this question in Part A*

@Neet_pg_bot

Q8: A 30 y/o woman presents with chronic diarrhoea and hypokalemia. Stool analysis shows a low faecal osmotic gap (<50 mOsm/kg). Factitious diarrhoea due to laxative abuse is suspected. Which of the following is the most appropriate diagnostic test to

confirm the diagnosis? (Q890571)

A. Urine D-xylose test

B. Stool laxative screen

C. 72-hour faecal fat collection

D. Serum chromogranin A

Correct Answer: B. Stool laxative screen

Explanation: This patient has chronic diarrhoea with hypokalemia and a low faecal osmotic gap (<50 mOsm/kg) , pointing to secretory diarrhoea . One classic cause of secretory diarrhoea is factitious diarrhoea due to stimulant laxative abuse . The definitive way to confirm this diagnosis is by detecting laxative metabolites in stool using a stool laxative screen . Factitious diarrhoea is most commonly caused by surreptitious stimulant laxative use (e.g., senna, bisacodyl). These agents induce secretory diarrhoea, producing a low stool osmotic gap and electrolyte disturbances such as hypokalemia. A stool laxative screen directly detects stimulant laxatives and is the confirmatory test. Features of factitious diarrhoea: Seen in patients with unexplained chronic diarrhoea, often with normal imaging and endoscopy. Characterised by low osmotic gap diarrhoea, hypokalemia, metabolic alkalosis or acidosis. Frequently associated with psychiatric illness or healthcare exposure. Diagnosis requires chemical detection, not functional or absorptive testing. Urine D-xylose test (Option A): Assesses proximal small-bowel absorption, not laxative use. 72-hour faecal fat collection (Option C): Evaluates steatorrhea, not secretory diarrhoea. Serum chromogranin A (Option D): Screens for neuroendocrine tumours, a rare cause of secretory diarrhoea.

References:

Harrison’s Principles of Internal Medicine, 22nd Edition, Page 310.

↑ *Back to this question in Part A*

@Neet_pg_bot

Q9: Which of the following faecal osmotic gap values is most characteristic of secretory diarrhoea? (Q890570)

A. >125 mOsm/kg

B. >100 mOsm/kg

C. >50 mOsm/kg

D. <50 mOsm/kg

Correct Answer: D. <50 mOsm/kg

Explanation: Secretory diarrhoea is caused by active secretion of electrolytes (Na■ and K■) and water by the intestinal epithelium. As a result, stool osmolality is largely explained by measured electrolytes, producing a low faecal osmotic gap (<50 mOsm/kg). This reflects the absence of significant unmeasured osmoles in the stool. Osmotic vs. secretory diarrhoea: Feature Secretory Diarrhoea Osmotic Diarrhoea Stool osmotic gap Low (<50 mOsm/kg) High (>100 mOsm/kg) Underlying mechanism Active secretion of electrolytes (Na■, Cl■) into the lumen Presence of unabsorbed, osmotically active solutes Effect of fasting Persists during fasting and sleep Improves or resolves with fasting Stool volume Large-volume stools Moderate-volume stools Stool composition Rich in electrolytes Rich in unmeasured osmoles Common causes Cholera, VIPoma, laxative abuse (secretory) Lactose intolerance, sorbitol, and malabsorption Stool pH Usually normal Often acidic (esp. carbohydrate malabsorption) The stool osmotic gap is calculated as 290 – 2 × (stool Na + stool K).

References:

Harrison's Principles of Internal Medicine, 22nd Edition, Pages 307, 308, 2549, 2550.

↑ *Back to this question in Part A*

@Neet_pg_bot

Q10: Which of the following clinical features is most characteristic of diarrhoea originating from the small intestine? (Q890568)

A. Frequent passage of small-volume stools

B. Presence of tenesmus

C. Large-volume watery stools

D. Frank hematochezia (bright red blood)

Correct Answer: C. Large-volume watery stools

Explanation: Small bowel diarrhoea produces large-volume watery stools because the small intestine is the primary site of fluid and nutrient absorption. When absorption is impaired or secretion is increased, large amounts of fluid reach the colon, overwhelming its absorptive capacity. Small vs. large bowel diarrhoea: Small bowel diarrhoea: large-volume stools, watery or steatorrheic; weight loss; nutritional deficiencies; minimal urgency. Large bowel diarrhoea: small-volume frequent stools, blood or mucus, urgency, tenesmus, and rectal discomfort. Stool volume, not frequency, is the most reliable discriminator between small and large bowel sources. Frequent passage of small-volume stools (Option A): Frequent small-volume stools: Indicates colonic disease with reduced storage capacity. Presence of tenesmus (Option B): Hallmark of rectal or distal colonic inflammation. Frank hematochezia (Option D): Typical of colonic pathology, small bowel bleeding usually presents as melena unless it is massive.

References:

Harrison's Principles of Internal Medicine, 22nd Edition, Pages 305, 2498, 2499.

↑ *Back to this question in Part A*

@Neet_pg_bot

Q11: A 27 y/o man develops abdominal bloating, crampy pain, and diarrhoea shortly after consuming milk. Stool analysis is performed while he is symptomatic. Which of the following stool profiles is most consistent with lactose intolerance? (Q890566)

A. High pH (>7.0) and a low stool osmotic gap (<50 mOsm/kg)

B. Low pH (<6.0) and a high stool osmotic gap (>100 mOsm/kg)

C. High pH (>7.0) and a high stool osmotic gap (>100 mOsm/kg)

D. Low pH (<6.0) and a low stool osmotic gap (<50 mOsm/kg)

Correct Answer: B. Low pH (<6.0) and a high stool osmotic gap (>100 mOsm/kg)

Explanation: Lactose intolerance causes osmotic diarrhoea due to undigested lactose remaining in the intestinal lumen. This unabsorbed lactose increases the stool osmotic gap . Colonic bacteria ferment lactose into short-chain fatty acids and lactic acid , which lowers stool pH . In lactose intolerance, lactase deficiency prevents the digestion of lactose in the small intestine. Unabsorbed lactose remains in the lumen, acting as an osmotically active, unmeasured solute, producing a high stool osmotic gap. Colonic bacteria ferment lactose into short-chain fatty acids (acetate, propionate, and butyrate) and hydrogen gas. These fatty acids acidify the stool, resulting in a low stool pH (<6.0). Core features of lactose intolerance: It is a classic cause of osmotic diarrhoea due to carbohydrate malabsorption. Symptoms include bloating, flatulence, abdominal pain, and diarrhoea after dairy ingestion. Diarrhoea improves with fasting, distinguishing it from secretory diarrhoea. Stool findings reflect unabsorbed carbohydrates, not inflammation or infection. High pH (>7.0) and a low stool osmotic gap (<50 mOsm/kg) (Option A): A low osmotic gap indicates secretory diarrhoea, not carbohydrate malabsorption. High pH (>7.0) and a high stool osmotic gap (>100 mOsm/kg) (Option C): The osmotic gap fits, but stool pH should be acidic, not alkaline. Low pH (<6.0) and a low stool osmotic gap (<50 mOsm/kg) (Option D): Acidic stool may occur, but a low osmotic gap excludes osmotic diarrhoea.

References:

Harrison’s Principles of Internal Medicine, 22nd Edition, Page 2544, 2545.

↑ *Back to this question in Part A*

@Neet_pg_bot

Q12: A 34 y/o man with Crohn's disease undergoes surgical resection. Six months later, he presents with progressive weight loss and bulky, foul-smelling, floating stools

despite a balanced diet.Which of the following pathophysiologic mechanisms best explains his steatorrhea? (Q890565)

A. Stimulation of colonic fluid secretion by unabsorbed bile acids

B. Hepatic bile acid synthesis compensating for faecal losses

C. Depletion of the circulating bile acid pool

D. Primary failure of pancreatic enzyme secretion

Correct Answer: C. Depletion of the circulating bile acid pool

Explanation: Patients with Crohn's disease involving resection of the terminal ileum lose the primary site of bile acid reabsorption . This leads to reduced enterohepatic circulation and depletion of the bile acid pool , impairing micelle formation and fat absorption → resulting in steatorrhea (bulky, foul-smelling, floating stools and weight loss). Short bowel syndrome: Results from loss of functional small-intestinal length, especially the ileum. Extensive ileal resection causes excessive faecal loss of bile acids, exceeding hepatic synthetic capacity. This leads to depletion of the enterohepatic bile acid pool. Luminal bile acid concentration falls below the critical micellar concentration, impairing fat emulsification. Result: severe fat malabsorption → frank steatorrhea, the hallmark of short bowel syndrome. Steatorrhea in short bowel syndrome: Steatorrhea arises from loss of absorptive surface area and bile acid depletion, not dietary fat intake. The severity depends on the length and location of the bowel resected, with ileal loss being most critical. Fat malabsorption persists despite normal pancreatic function and adequate nutrition. Patterns of diarrhoea after ileal resection: <100 cm ileal resection → bile acid-induced secretory (watery) diarrhoea >100 cm ileal resection → bile acid pool depletion → steatorrhea Stimulation of colonic fluid secretion by unabsorbed bile acids (Option A): Occurs in limited ileal resection (<100 cm) where bile acids reach the colon → watery diarrhoea, not steatorrhea. Hepatic bile acid synthesis compensating for faecal losses (Option B): Compensation occurs only in small resections; impossible with large ileal losses. Primary failure of pancreatic enzyme secretion (Option D): Seen in chronic pancreatitis; SBS steatorrhea is due to bile acid loss, not enzyme deficiency.

References:

Harrison's Principles of Internal Medicine, 22nd Edition, Page 2543.

↑ *Back to this question in Part A*

@Neet_pg_bot

Q13: A 16-year-old boy presents with intensely itchy vesicular skin lesions on elbows and knees. Her mother says that she is giving him rice based diet only and he does not tolerate cereals. Skin biopsy was performed from the lesions and IF staining is shown below. Which of the following is the most likely diagnosis? (Q850854)

A. Bullous pemphigoid

B. Pemphigus vulgaris

C. Dermatitis herpetiformis

D. Psoriasis

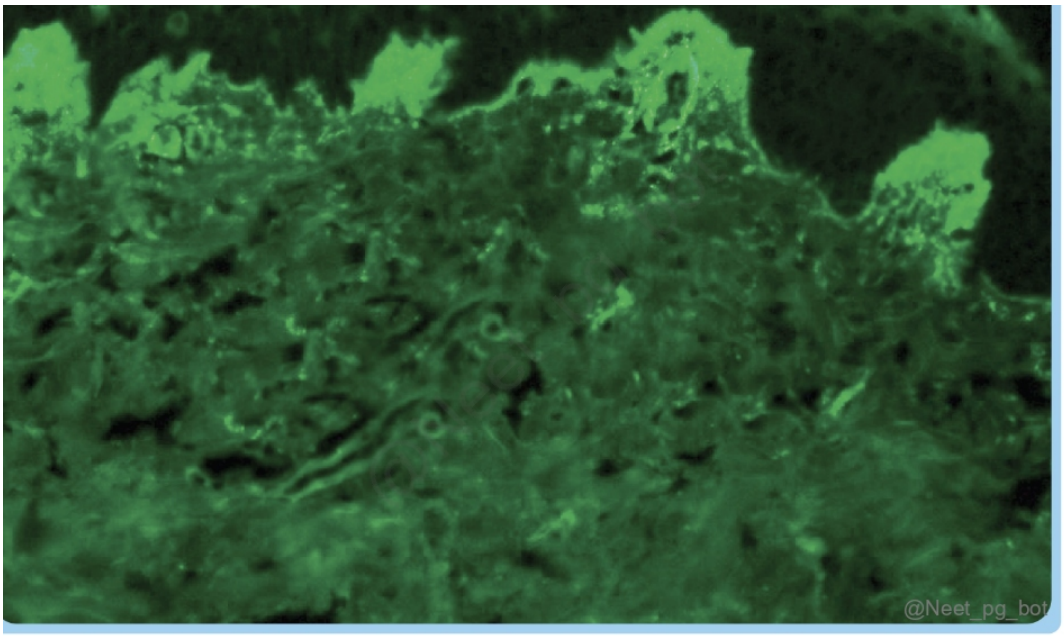

Correct Answer: C. Dermatitis herpetiformis

■ *Listen (English)*

■ *Listen (Hindi)*

Explanation: The patient's intolerance to cereals (gluten-containing foods) and rice-based diet suggests an underlying gluten sensitivity , which is typical of dermatitis herpetiformis Dermatitis herpetiformis is a chronic autoimmune blistering skin condition associated with gluten sensitivity or celiac disease. It presents as intensely pruritic, grouped vesicles and papules predominantly on extensor surfaces such as elbows and knees. Immunofluorescence staining shows granular/ focal IgA deposits in dermal papillae. Bullous pemphigoid (Option A) has bullous lesions with linear IgG deposits instead of focal granular deposits seen here. Pemphigus vulgaris (Option B) has Fish net appearance on IF due to damage to desmosomes Psoriasis (Option D) presents with mica-like scales with characteristic bleeding on removal of scales

References:

Harrison's Principles of Internal Medicine, 22nd Edition, Page 412.

↑ *Back to this question in Part A*

@Neet_pg_bot

Q14: Which of the following diseases is not a cause of protein losing enteropathy? (Q850868)

A. Ulcerative colitis

B. Menetrier’s disease

C. Intestinal lymphangiectasia

D. Abetalipoproteinemia

Correct Answer: D. Abetalipoproteinemia

■ *Listen (English)*

■ *Listen (Hindi)*

Explanation: Abetalipoproteinemia causes malabsorption of fat and fat-soluble vitamins but does not lead to loss of protein through the gastrointestinal tract. Ulcerative colitis (Option A) can cause protein loss due to mucosal inflammation and ulceration. Menetrier’s disease (Option B) leads to protein-losing gastropathy due to hypertrophic gastric folds and increased mucus production that rich in protein. Intestinal lymphangiectasia (Option C) causes protein loss via dilated intestinal lymphatics.

References:

Harrison's Principles of Internal Medicine, 22nd Edition, Page 2545.

↑ *Back to this question in Part A*

@Neet_pg_bot

Q15: Gold standard investigation for steatorrhea is? (Q850866)

A. 72-hour faecal fat estimation

B. Breath triolein test

C. PIVKA test

D. Small intestinal mucosal biopsy

Correct Answer: A. 72-hour faecal fat estimation

■ *Listen (English)*

■ *Listen (Hindi)*

Explanation: Steatorrhea is defined as stool fat excretion > 7% fat of dietary fat. The gold standard investigation for it is the 72-hour faecal fat estimation. Breath triolein test (Option B) is a non-invasive screening method, but

not the gold standard; it is less sensitive and rarely used in clinical practice. PIVKA test (Option C) measures abnormal prothrombin due to vitamin K deficiency, mainly used as a marker for liver cancer Small intestinal mucosal biopsy (Option D) is useful for identifying underlying mucosal diseases (like celiac disease) causing malabsorption, but it does not directly quantify fat loss.

References:

Harrison's Principles of Internal Medicine, 22nd Edition, Page 2549.

↑ *Back to this question in Part A*

@Neet_pg_bot

Q16: You are asked to evaluate lab reports of patient with peripheral oedema. Serum albumin is low and serum globulin is low. Which of the following is likely cause? (Q850865)

A. Cirrhosis

B. Minimal change disease

C. Protein losing enteropathy

D. SCID

Correct Answer: C. Protein losing enteropathy

■ *Listen (English)*

■ *Listen (Hindi)*

Explanation: Protein-losing enteropathy leads to loss of both albumin and globulins through the gastrointestinal tract, causing generalized hypo-proteinemia and peripheral edema. Cirrhosis (Option A) will have low albumin due to less production, but globulin is increased due to decreased clearance. Minimal change disease (Option B) has selective proteinuria leading to low albumin. SCID (Option D) will have low globulin, but protein-losing enteropathy has both low albumin and low globulin due to losses via GIT

References:

Harrison's Principles of Internal Medicine, 22nd Edition, Page 2548.

↑ *Back to this question in Part A*

@Neet_pg_bot

Q17: Stool alpha1 anti-trypsin levels are used for diagnosis of which of the following disease? (Q850864)

A. Alpha 1 antitrypsin deficiency

B. Protein losing enteropathy

C. Small bowel syndrome

D. Abetalipoproteinemia

Correct Answer: B. Protein losing enteropathy

■ *Listen (English)*

■ *Listen (Hindi)*

Explanation: Alpha 1 antitrypsin accounts for 4% of total serum proteins and is resistant to proteolysis. When there is excessive protein loss through the gastrointestinal tract, alpha1 antitrypsin leaks into the intestines and appears in the stool, and if elevated is diagnostic of protein-losing enteropathy Alpha 1 antitrypsin deficiency (Option A): This is a genetic disorder causing deficient or dysfunctional alpha1 antitrypsin protein, causing cirrhosis with pan-acinar emphysema. Diagnosis is based on serum levels, phenotype, and genetic testing. Small bowel syndrome (Option C): Occurs due to extensive removal of the small intestine, resulting in <200 cm remaining. Abetalipoproteinemia (Option D): This is a rare inherited disorder of fat absorption caused by defective lipoprotein production. Diagnosis relies on clinical features like acanthocytosis, lipid profile abnormalities, and genetics

References:

Harrison's Principles of Internal Medicine, 22nd Edition, Page 2548.

↑ *Back to this question in Part A*

@Neet_pg_bot

Q18: Which of the following is correct treatment of tropical sprue? (Q850863)

A. Tetracycline with folic acid

B. Ceftriaxone with TMP-SMX

C. Ofloxacin with Ornidazole

D. Budesonide ileal release preparation

Correct Answer: A. Tetracycline with folic acid

■ *Listen (English)*

■ *Listen (Hindi)*

Explanation: The exact organism causing tropical sprue is not known. However, broad-spectrum antibiotics like tetracycline have been found to be useful. Folic acid is absorbed from the duodenum and proximal jejunum. Ceftriaxone with TMP-SMX (Option B) is not standard therapy for tropical sprue and is used for other bacterial infections. Ofloxacin with Ornidazole (Option C) is used for other gastrointestinal infections, not tropical sprue. Budesonide ileal release preparation (Option D) is used for localized inflammatory bowel disease, not tropical sprue.

References:

Harrison's Principles of Internal Medicine, 22nd Edition, Page 2546.

↑ *Back to this question in Part A*

@Neet_pg_bot

Q19: 30-year-old woman with scleroderma was having steatorrhea and anaemia. She was found to have vitamin B12 deficiency and elevated serum folate levels. Which is next best investigation to be done in this patient? (Q850862)

A. Anti topoisomerase antibody

B. Duodenal aspirate for bacterial titers

C. Small intestinal mucosal biopsy

D. Breath urea test

Correct Answer: B. Duodenal aspirate for bacterial titers

■ *Listen (English)*

■ *Listen (Hindi)*

Explanation: Scleroderma causes bowel stasis leading to small intestinal bacterial overgrowth (SIBO), which damages the ileal mucosa, causing low vitamin B12 and high folate levels. The gold standard investigation for this case is a duodenal aspirate for bacterial cultures. It may not be available routinely. So, a breath hydrogen test can be done, but it must be interpreted with caution. Otherwise, empirical antibiotic therapy can be given and the response evaluated. Anti-topoisomerase antibody (Option A): Used for the diagnosis of scleroderma, not for the evaluation of malabsorption. Small intestinal mucosal biopsy (Option C): Helps diagnose celiac disease or Whipple’s disease, not SIBO. Breath urea test (Option D): Used to detect Helicobacter pylori infection.

References:

Harrison's Principles of Internal Medicine, 22nd Edition, Page 2543.

↑ *Back to this question in Part A*

@Neet_pg_bot

Q20: 30-year-old woman with scleroderma was having steatorrhea and anaemia. She was found to have vitamin B12 deficiency and elevated serum folate levels. Which of the following is probable cause of her malabsorptive diarrhoea? (Q850861)

A. Chronic pancreatitis

B. Autoimmune gastritis

C. Small intestinal bacterial overgrowth

D. Whipple’s disease

Correct Answer: C. Small intestinal bacterial overgrowth

■ *Listen (English)*

■ *Listen (Hindi)*

Explanation: Patients with scleroderma can develop small intestinal bacterial overgrowth (SIBO) due to intestinal hypomotility. This damages the ileal mucosa. Bacterial overgrowth leads to malabsorption , steatorrhea , and vitamin B12 deficiency (bacteria consume B12), while serum folate is elevated due to bacterial synthesis. Chronic pancreatitis (Option A): Causes fat malabsorption but does not raise folate or lower B12 levels. Autoimmune gastritis (Option B): Leads to B12 deficiency but not steatorrhea or high folate. Whipple’s disease (Option D): Causes steatorrhea and arthritis but not elevated folate levels.

References:

Harrison's Principles of Internal Medicine, 22nd Edition, Page 2543.

↑ *Back to this question in Part A*

@Neet_pg_bot

Q21: Severity of celiac sprue is determined by which classification? (Q850859)

A. Forrest

B. Marsh

C. Vienna and Montreal

D. Truelove and Witts

Correct Answer: B. Marsh

■ *Listen (English)*

■ *Listen (Hindi)*

Explanation: The severity of celiac sprue is determined by the Marsh classification. It grades the histological changes in the small intestinal mucosa from type 0 (normal mucosa) to type 4 (total architectural atrophy). Parameters are- Crypt hyperplasia Villous atrophy Degree of intraepithelial lymphocytosis Forrest classification (Option A) is used for the assessment of patients with GI bleeding due to peptic ulcers Vienna and Montreal classifications (Option C) are related to inflammatory bowel disease (Crohn's disease and ulcerative colitis) classifications. Truelove and Witts' classification (Option D) is for the severity of ulcerative colitis.

References:

https://pmc.ncbi.nlm.nih.gov/articles/PMC1861744/

↑ *Back to this question in Part A*

@Neet_pg_bot

Q22: Middle aged man presented with arthralgias, diarrhoea, weight loss and abdominal pain. Small intestinal mucosal biopsy shows PAS positive macrophages laden with intracellular bacteria. Which of the following is correct about management of this patient? (Q850858)

A. Oral TMP-SMX

B. Ceftriaxone

C. Ceftriaxone plus oral TMP-SMX

D. Tetracycline plus oral TMP-SMX

Correct Answer: C. Ceftriaxone plus oral TMP-SMX

■ *Listen (English)*

■ *Listen (Hindi)*

Explanation: The patient’s biopsy showing PAS-positive macrophages containing Tropheryma whipplei confirms Whipple’s disease . The recommended treatment is initial intravenous ceftriaxone for 2 weeks , followed by oral TMP-SMX for 1 year to prevent relapse and ensure eradication from the CNS. Oral TMP-SMX (Option A): Used only after IV induction therapy, not sufficient as monotherapy. Ceftriaxone (Option B): Effective for the induction phase, but relapse risk is high if used alone. Tetracycline plus oral TMP-SMX (Option D): Not a standard recommended regimen.

References:

Harrison's Principles of Internal Medicine, 22nd Edition, Page 1370.

↑ *Back to this question in Part A*

@Neet_pg_bot

Q23: Which of the following is not correct about celiac sprue? (Q850856)

A. Lactase deficiency

B. Steatorrhea

C. Secretory diarrhoea

D. Lipid laden intestinal epithelial cells that appears normal after 72 hours fasting

Correct Answer: D. Lipid laden intestinal epithelial cells that appears normal after 72 hours fasting

■ *Listen (English)*

■ *Listen (Hindi)*

Explanation: Lipid-laden intestinal epithelial cells that appear normal after 72 hours of fasting are characteristic of abetalipoproteinemia and not celiac sprue . Celiac sprue causes crypt hyperplasia and fluid hypersecretion from crypt epithelium. Lactase deficiency (Option A): Secondary to villous atrophy in celiac sprue, leading to lactose intolerance. Steatorrhea (Option B): Due to fat malabsorption from villous atrophy. Secretory diarrhoea (Option C): Diarrhea in celiac sprue is mainly osmotic, not secretory, but crypt hyperplasia may contribute to fluid loss.

References:

Harrison's Principles of Internal Medicine, 22nd Edition, Page 2545.

↑ *Back to this question in Part A*

@Neet_pg_bot

Q24: Which of the following is correct about celiac sprue? (Q850855)

A. Demonstration of host genetic factors HLA DQ2 DQ8 is a must for diagnosis

B. BROW cereals intake is mainstay of managing the disease

C. Presents with iron deficiency anaemia

D. Leading cause is colonization of gut by Tropheryma whippelli

Correct Answer: C. Presents with iron deficiency anaemia

■ *Listen (English)*

■ *Listen (Hindi)*

Explanation: Celiac sprue presentation can range from malabsorption of multiple nutrients to iron deficiency anemia due to duodenal involvement. Demonstration of host genetic factors HLA DQ2 and DQ8 is a must for diagnosis (Option A): Incorrect, as HLA typing is not essential for diagnosis; it is present in 25–35% of the general population. BROW cereals intake is mainstay of managing the disease (Option B): Incorrect, BROW cereals (Barley, Rye, Oats, Wheat) must be restricted. Leading cause is colonization of gut by Tropheryma whippelli (Option D): Incorrect, this is the cause of Whipple's disease, not celiac sprue.

References:

Harrison's Principles of Internal Medicine, 22nd Edition, Page 2545.

↑ *Back to this question in Part A*

@Neet_pg_bot

• [05_Gastrointestinal System] 036 Previous Year Questions

« Back to Folder Directory

[05_Gastrointestinal System] 036 Previous Year Questions — Quick Jump

Q1 (p. 1991)	*Q2 (p. 1992)*	*Q3 (p. 1993)*	*Q4 (p. 1994)*	*Q5 (p. 1994)*	*Q6 (p. 1996)*
Q7 (p. 1997)	*Q8 (p. 1998)*	*Q9 (p. 1999)*	*Q10 (p. 2000)*	*Q11 (p. 2001)*	*Q12 (p. 2002)*
Q13 (p. 2003)	*Q14 (p. 2004)*	*Q15 (p. 2005)*	*Q16 (p. 2006)*	*Q17 (p. 2007)*	*Q18 (p. 2010)*
Q19 (p. 2011)	*Q20 (p. 2011)*				

Q1: What is not a characteristic feature of Wilson's disease? (Q856381)

A. Autosomal recessive disease

B. No free radical injury

C. ATP7B gene involved

D. Presents before age 40 with liver disease

Correct Answer: B. No free radical injury

Explanation: Free radical injury due to an excess of copper ions is seen in patients with Wilson's disease. Wilson's disease Wilson's disease, also known as hepatolenticular degeneration , is a rare autosomal recessive disorder (Option A), usually presents before age 40 (Option D) with liver disease caused by the abnormal accumulation of copper in the liver, brain, eyes, and other organs. This results in elevated free copper levels, along with increased copper levels in the liver and urine, while serum ceruloplasmin levels are decreased. Gene Affected: The disease is caused by mutations in the ATP7B gene (Option C) on chromosome 13. This gene encodes a copper-transporting ATPase responsible for excreting copper from the liver into bile. Pathogenesis: Lab parameters of Wilson’s disease Parameter Change

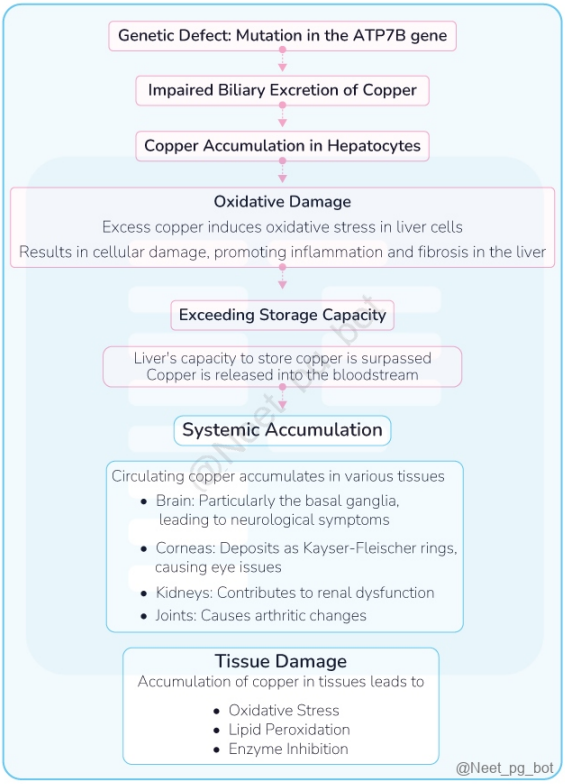

References:

Harrison's principles of internal medicine, 21st edition, Page 3235

Davidson's principles and practice of medicine, 24th edition, Page 896, 897

https://tinyurl.com/3ek9r4ym

↑ *Back to this question in Part A*

@Neet_pg_bot

Q2: Which classification is used for Barrett esophagus? (Q866826)

A. Prague classification

B. Savary-Miller classification

C. Johnson classification

D. Forrest classification

Correct Answer: A. Prague classification

Explanation: The Prague C & M classification is used for Barrett esophagus, where C denotes the circumferential extent of the Barrett mucosa and M denotes the maximal extent from the gastroesophageal junction, as measured endoscopically. It helps in standardizing reporting and guiding surveillance. Prague Classification Two key measurements: C (Circumferential extent) M (Maximum extent) Circumferential extent Distance (in cm) from the GE junction to the proximal limit of circumferential Barrett's mucosa Maximum extent: Distance from the GE junction to the furthest proximal extension of any Barrett's mucosa (including tongues or islands) Example: If Barrett's mucosa is circumferentially present for 3 cm, and a tongue extends up to 6 cm: Prague classification = C3M6 Incorrect Options: Savary-Miller classification (Option B): Used for grading reflux esophagitis severity based on endoscopic findings. Johnson classification (Option C): Used for types of gastroesophageal reflux depending on the location of the lower esophageal sphincter and diaphragm. Forrest classification (Option D): Used in upper GI bleeding to describe peptic ulcer bleeding stigmata and predict rebleeding risk.

↑ *Back to this question in Part A*

@Neet_pg_bot

Q3: 30 year old male is found to have anemia (MCV 110 fl) with leukonychia and enlarged spleen. The clinical diagnosis is? (Q866825)

A. Portal Hypertension

B. Plummer-Vinson syndrome

C. Achalasia cardia

D. Tylosis palmaris

Correct Answer: A. Portal Hypertension

Explanation: - Portal Hypertension: Portal hypertension is commonly associated with chronic liver disease, which can present with macrocytic anemia (MCV >100 fL) due to folate deficiency or alcohol-related marrow changes. Leukonychia is a classic sign of hypoalbuminemia seen in chronic liver disease. Splenomegaly occurs due to portal hypertension, causing congestive splenic enlargement (hypersplenism). Incorrect Options: Option B - Plummer–Vinson syndrome: This syndrome presents with iron deficiency anemia (microcytic anemia), esophageal webs, and dysphagia, mainly in middle-aged women. It is not associated with leukonychia or splenomegaly. Option C - Achalasia cardia: Achalasia is a primary esophageal motility disorder characterized by dysphagia to solids and liquids. It has no association with anemia, leukonychia, or splenomegaly. Option D - Tylosis palmaris: Tylosis palmaris is a hereditary palmoplantar keratoderma associated with esophageal carcinoma risk. It does not cause anemia, leukonychia, or splenic enlargement.

References:

.

↑ *Back to this question in Part A*

@Neet_pg_bot

Q4: A patient with osteoarthritis, for the last 3 months, has been taking ibuprofen and has developed occult GI bleeding. Which is correct about the cause? (Q866795)

A. PGE-2 and prostacyclin production were reduced

B. Increased acid production

C. PGE-1 and prostacyclin production were reduced

D. Mucosal injury due to inhibition of COX-2

Correct Answer: A. PGE-2 and prostacyclin production were reduced

Explanation: NSAIDs like ibuprofen inhibit COX enzymes, reducing prostaglandin (PGE■) and prostacyclin synthesis. These mediators normally maintain gastric mucosal protection by increasing mucus and bicarbonate secretion and promoting mucosal blood flow. Loss of PGE■ and prostacyclin leads to impaired gastric mucosal defense, making the mucosa susceptible to acid-induced injury and bleeding. This is the primary mechanism for NSAID-induced gastritis and peptic ulcers. COX-1 inhibition is particularly responsible for GI side effects, as it is involved in constitutive prostaglandin synthesis for mucosal protection. NSAID-induced GI injury: Mechanism: COX-1 inhibition → ↓ PGE■, ↓ prostacyclin → ↓ mucus, ↓ bicarbonate, ↓ blood flow. Risk factors: High-dose/long-term NSAID use, elderly, alcohol, corticosteroids, H. pylori infection. Prevention: Co-prescription of proton pump inhibitors (PPIs) or misoprostol (PGE■ analog). Histology: Superficial mucosal erosions with inflammatory infiltrates. Complications : Peptic ulcers, GI bleeding, perforation. Incorrect Options: Increased acid production (Option B): NSAIDs do not significantly increase gastric acid secretion; the main issue is reduced mucosal defense. PGE-1 and prostacyclin production reduced (Option C): The main gastric protective prostaglandin is PGE■, not PGE■. Mucosal injury due to inhibition of COX-2 (Option D): COX-2 inhibition is more linked to anti-inflammatory effects and cardiovascular risk, not primary GI mucosal damage (which is COX-1–mediated).

↑ *Back to this question in Part A*

@Neet_pg_bot

Q5: 24-year-old female presents with dysphagia, weight loss and bronchiectasis. Which investigation should be done to confirm the diagnosis. Barium swallow was shown? (Q866504)

A. Esophageal manometry

B. Upper GI endoscopy

C. CT chest

D. CECT chest



Correct Answer: A. Esophageal manometry

Explanation: The barium swallow in this patient shows the classic bird-beak appearance suggestive of achalasia cardia . While barium swallow can suggest the diagnosis, the gold standard test for confirmation is esophageal manometry , which demonstrates incomplete lower esophageal sphincter (LES) relaxation and absence of peristalsis in the esophageal body. Achalasia cardia Definition It is characterized by the progressive degeneration of ganglion cells in the esophageal wall. This leads to a loss of peristalsis in the lower esophagus and failure of the lower esophageal sphincter (LES) to relax during swallowing Clinical Features Dysphagia: May initially affect liquids more than solids. Regurgitation Halitosis Chest Pain Weight Loss Investigations: Esophageal Manometry Gold Standard: This is the definitive diagnostic test for achalasia. It measures the pressure and pattern of muscle contractions in the esophagus. Elevated resting LES pressure (typically > 45 mmHg). Incomplete LES relaxation. Absence of peristalsis in the esophageal body. Periodic contractions with normal amplitude or high amplitude contractions (type I and II achalasia). Barium Swallow (Esophagram) Dilated esophagus with a narrowing at the LES (Bird beak appearance). Endoscopy: Normal mucosa but may show dilated esophagus with possible food debris, It is important to rule out other causes of dysphagia such as tumors. Upper GI endoscopy (Option B): Useful to rule out malignancy (pseudoachalasia) and assess mucosa, but does not confirm motility disorder. CT chest (Option C): Helpful in detecting mediastinal masses or external compression, but not diagnostic for achalasia. CECT chest (Option D): Similar to CT chest, used to rule out secondary causes but not confirm the motility disorder.

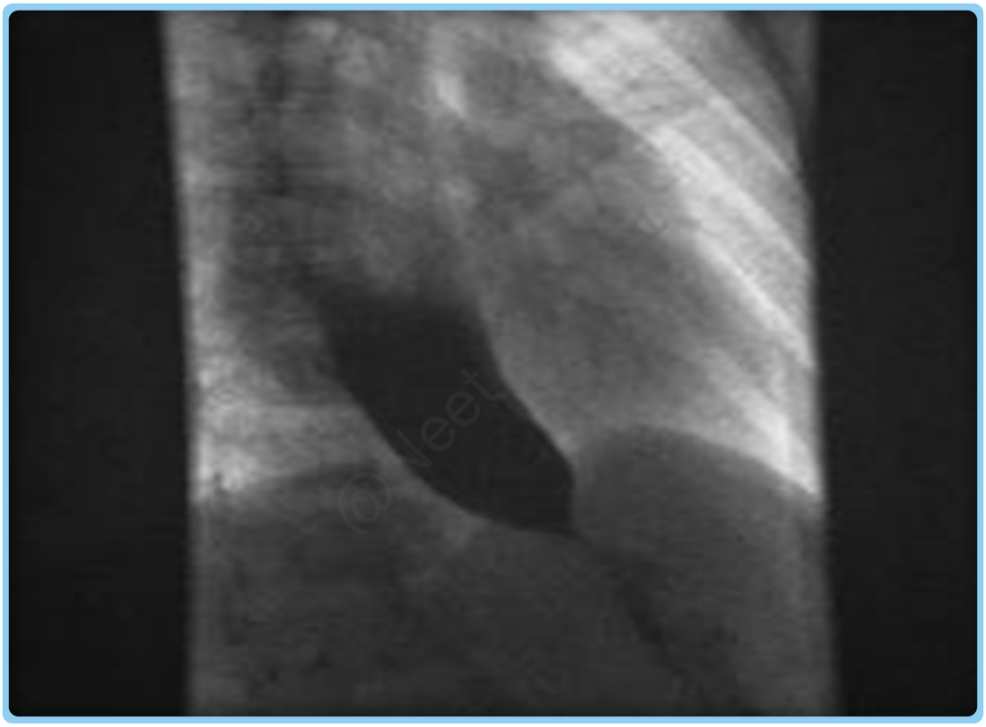

References:

.

↑ *Back to this question in Part A*

@Neet_pg_bot

Q6: A 70-year-old male patient presents with a complaint of dysphagia, particularly for solids, which has been progressively worsening over the past few months. Additionally, he has experienced significant weight loss and cachexia over the same period. Which of the following diagnostic choices is best for this patient? (Q860394)

A. UGIE

B. Manometry

C. Barium swallow

D. Barium meal follow through

Correct Answer: A. UGIE

Explanation: The presentation of progressive dysphagia for solids with significant weight loss and cachexia in an elderly patient strongly suggests esophageal carcinoma . Upper GI endoscopy (UGIE) is the gold standard diagnostic tool in this scenario as it allows direct visualization of the tumor and enables tissue biopsy for definitive diagnosis. UGIE also permits thorough examination of the larynx, trachea, and bronchi, which is crucial as this population has a higher risk of head and neck malignancies. Additionally, CT scanning of the chest and abdomen is typically performed to assess tumor spread to mediastinal and para-aortic lymph nodes. Manometry (Option B): While manometry is useful in diagnosing esophageal motility disorders such as achalasia, it is not the appropriate first-line investigation when malignancy is suspected (Option B ruled out). Manometry cannot provide visual confirmation of tumors or allow for tissue sampling. Barium swallow (Option C) : Although barium swallow can demonstrate mucosal abnormalities and strictures, it cannot provide tissue diagnosis which is essential when malignancy is suspected (Option C ruled out). It may be used as a complementary study but should not be the primary diagnostic tool in this scenario. Barium meal follow through (Option D) : This study is primarily used to evaluate the small intestine and is not appropriate for investigating suspected esophageal pathology (Option D ruled out). It would not provide the necessary information about the esophageal lesion or allow for tissue sampling.

↑ *Back to this question in Part A*

@Neet_pg_bot

Q7: In which of the following conditions is pneumomediastinum commonly found? (Q860160)

A. Pulsion diverticulum

B. Boerhaave syndrome

C. Mallory-Weiss syndrome

D. Pericarditis

Correct Answer: B. Boerhaave syndrome

Explanation: Pneumomediastinum is one of the complication associated with Boerhaave syndrome , which is a condition characterized by spontaneous full-thickness rupture of the esophagus. Boerhaave syndrome clinically manifests as Mackler’s triad (Vomiting, chest pain, and subcutaneous emphysema). The condition is often preceded by forceful vomiting. This condition typically occurs in the lower third of the esophagus and results in a direct communication between the esophageal lumen and mediastinal space. The rupture allows esophageal contents to spill into the mediastinum which can occasionally lead to complications such as pneumomediastinum and chemical mediastinitis . Boerhaave syndrome Definition It is a spontaneous esophageal rupture caused by a sudden increase in intraesophageal pressure, typically from vomiting against a closed glottis resulting in a left-sided esophageal perforation , which allows gastric contents to spill into the pleural cavity, leading to a left pleural effusion and subcutaneous emphysema . Classic triad Vomiting, chest pain, and subcutaneous emphysema. (Mackler’s triad) Other Symptoms May include fever, tachycardia, and tachypnea in the presence of sepsis Physical examination Hamman’s sign (crunching sound on auscultation due to surgical emphysema). Complications Pneumothorax/ Pneumomediastinum , mediastinitis, and sepsis. Pulsion diverticulum (Option A)

occurs due to increased intraluminal pressure in the esophagus, forming an outpouching of the esophageal wall. While it can cause symptoms like dysphagia and regurgitation, it does not typically result in pneumomediastinum as the esophageal wall remains intact. Mallory-Weiss syndrome (Option C) involves longitudinal mucosal tears at the gastroesophageal junction, typically following forceful vomiting. While it can cause hematemesis, the tear is superficial and does not extend through the full thickness of the esophageal wall, thus not causing pneumomediastinum. Pericarditis (Option D) is inflammation of the pericardium, the fibrous sac surrounding the heart. While it causes chest pain and other symptoms related to inflammation, it does not involve the esophagus and does not cause pneumomediastinum.

References:

Bailey & Love's Short Practice of Surgery, 28th Edition, Page 1127,1128

↑ *Back to this question in Part A*

@Neet_pg_bot

Q8: A patient with inflammatory bowel disease presents with the following lesion. What is the most likely diagnosis? (Q859643)

A. Erythema nodosum

B. Pyoderma gangrenosum

C. Diabetic ulcer

D. Venous ulcer



Correct Answer: B. Pyoderma gangrenosum

Explanation: The given clinical scenario and image are suggestive of Pyoderma gangrenosum which is more common in Ulcerative colitis a type of inflammatory bowel disease. Pyoderma gangrenosum is a rare, inflammatory skin condition characterized by the development of painful, ulcerative lesions. It can occur in patients with inflammatory bowel disease, and the lower limbs are a common site of involvement. The ulcers typically have undermined borders and may have a necrotic or purulent appearance. Extraintestinal manifestations of IBD: Erythema nodosum (A skin condition characterized by painful red nodules typically found on the shins). (Option A) Ankylosing spondylitis (Arthritis of the spine) Pancreatitis Uveitis (Inflammation of the uvea) Osteoporosis and Osteonecrosis are overall the most common extra-intestinal manifestations of IBD. Pyoderma gangrenosum is common in Ulcerative colitis. Primary Sclerosing Cholangitis is common in Ulcerative colitis. Renal calculi is common in Crohn's disease. Diabetic ulcer (Option C) is not associated with inflammatory bowel disease. It is a complication of uncontrolled diabetes mellitus. Venous ulcer (Option D) is usually caused by conditions like long-standing varicose veins. It is usually situated around the ankles.

References:

Harrison's Principles of Internal Medicine, 21st Edition, Page: 2481.

↑ *Back to this question in Part A*

@Neet_pg_bot

Q9: A 15-year-old girl presented with fatigue, chronic diarrhoea, weight loss, bone pain and abdominal distension. Investigations revealed iron deficiency anemia and

osteoporosis. Which of the following is the single best test to be done for her evaluation? (Q858444)

A. TSH levels

B. C-peptide levels

C. Urine sugar and ketone

D. IgA tissue transglutaminase antibody

Correct Answer: D. IgA tissue transglutaminase antibody

Explanation: The clinical scenario of fatigue, chronic diarrhea, weight loss, bone pain, abdominal distension, iron deficiency anemia, and osteoporosis strongly indicates celiac disease . The single best test for its evaluation is the IgA tissue transglutaminase antibody. Celiac Disease: Also called celiac sprue or gluten-sensitive enteropathy. Associated with HLA-DQ2 and DQ8. Small intestinal enteropathy caused by immune response to gluten. Characterized by autoantibodies to tissue transglutaminase. Gluten is found in wheat, rye, barley, and some oats. Pathogenesis: Tissue transglutaminase deamidates glutamine residues of gluten-derived peptides, facilitating immune response. Affects the proximal small intestine. Clinical Features: Diarrhea, weight loss , growth failure (children). Bloating , irregular bowel habits, migraines, ataxia. May present with osteoporosis, iron-deficiency anemia , or abnormal liver enzymes. Diagnosis: Serum antibodies: Tissue transglutaminase IgA , anti-endomysial, deamidated anti-gliadin antibodies. Measure serum IgA levels to detect IgA deficiency. Confirmatory testing: Endoscopy with small-intestinal biopsy. Biopsy findings: Villus blunting, crypt hyperplasia, increased intraepithelial lymphocytes. Marsh classification used for severity grading. Management: Lifelong strict gluten-free diet. TSH levels (Option A): Thyroid dysfunction can cause fatigue and weight loss, but it does not explain chronic diarrhea, iron deficiency anemia, or osteoporosis. These symptoms point toward malabsorption rather than thyroid disease, making TSH an inappropriate choice in this context. C-peptide levels (Option B): C-peptide is useful in evaluating insulin secretion and distinguishing between type 1 and type 2 diabetes. However, diabetes does not typically present with chronic diarrhea, iron deficiency anemia, or osteoporosis, making it irrelevant here. Urine sugar and ketones (Option C): While this test helps identify diabetes and diabetic ketoacidosis, the patient's symptoms, such as malabsorption and nutrient deficiencies, do not suggest these conditions. Chronic diarrhea and weight loss are not hallmark features of diabetes.

References:

Harrison’s Principle of Internal Medicine, 21st Edition, Page 2463,2464

↑ *Back to this question in Part A*

@Neet_pg_bot

Q10: A 49-year-old male is experiencing recurring episodes of watery diarrhea, dehydration, hypokalemia, and achlorhydria. Which type of neuroendocrine tumor could potentially cause these symptoms? (Q858363)

A. Insulinoma

B. Somatostatinoma

C. VIPoma

D. Glucagonoma

Correct Answer: C. VIPoma

Explanation: VIPoma is a type of neuroendocrine tumour that produces vasoactive intestinal peptides (VIP). They are linked to syndromes like: Verner-Morrison syndrome. Pancreatic cholera. WDHA syndrome (watery diarrhoea, hypokalemia, achlorhydria). VIP, a 28-amino-acid peptide, mimics cholera toxin effects by: Stimulating chloride secretion in the small intestine. Increasing smooth muscle contractility. Leading to severe diarrhoea. Clinical features: Patients typically present with: Severe watery diarrhoea leads to hypokalemia and metabolic acidosis. Flushing episodes. Low stomach acid (achlorhydria / hypochlorhydria). Increased glycogen breakdown. Elevated calcium levels (hypercalcemia). Tumor Characteristics: Typically solitary. Often located in the pancreatic tail. Diagnosis: Elevated plasma VIP levels are common but not definitive for diagnosis, as they can occur in other conditions like: Inflammatory bowel disease. Post-surgery (small bowel resection). Radiation enteritis. Chronic laxative or diuretic use can complicate diagnosis. Treatment: Critical management includes: Fluid and electrolyte replacement to address dehydration, hypokalemia, and electrolyte losses. Long-term treatment options: Somatostatin analogues are effective in controlling diarrhoea. Surgical resection is recommended for localized tumours. Insulinoma (Option A) : An insulinoma presents with symptoms of hypoglycemia including weakness, fatigue, sweating, palpitations, confusion, and seizures. These tumors produce excess insulin, leading to low blood sugar, but do not cause the profound diarrhea and electrolyte disturbances seen in this patient. Somatostatinoma (Option B) : Somatostatinomas typically present with diabetes mellitus, cholelithiasis, diarrhea, and steatorrhea due to somatostatin's inhibitory effects on digestive enzyme secretion. While diarrhea can occur, the complete WDHA syndrome is not a feature of this tumor. Glucagonoma (Option D) : Glucagonomas are characterized by necrolytic migratory erythema, diabetes mellitus, weight loss, and anemia. They do not typically cause the severe secretory diarrhea and electrolyte abnormalities seen in this case.

References:

Harrison’s Principles of Internal Medicine, 21st edition, Page: 665.

Vasoactive Intestinal Peptide-Secreting Tumor (VIPoma) - Endotext - NCBI Bookshelf

Clinically Important Toxins in Bacterial Infection: Utility of Laboratory Detection - PMC

↑ *Back to this question in Part A*

@Neet_pg_bot

Q11: What is the probable diagnosis of a patient who has significant abdominal swelling and laboratory analysis of the fluid obtained through paracentesis reveals SAAG <1.1? (Q856355)

A. Congestive heart failure

B. Myxoedema

C. Budd Chiari syndrome

D. Tuberculosis

Correct Answer: D. Tuberculosis

Explanation: Among the given options, only in tuberculosis SAAG score will be < 1.1 mg/dl, all others will have SAAG >1.1mg/dl. Congestive heart failure (Option A) can also lead to the development of ascites. However, in this, the SAAG is usually greater than 1.1 g/dL. SAAG is usually greater than 1.1 g/dL in myxoedema (Option B) and Budd Chiari syndrome (Option C). Interpretations of SAAG: SAAG ≥1.1 g/dL: Portal hypertension (ascites is due to increased pressure in the hepatic sinusoids) Ascitic protein level ≥2.5 g/dL : Hepatic sinusoids are normal (allows passage of protein) Ascitic protein level <2.5 g/dL : Hepatic sinusoids are damaged and scarred (no passage of protein) SAAG <1.1 g/dL: Ascites is not related to portal hypertension.

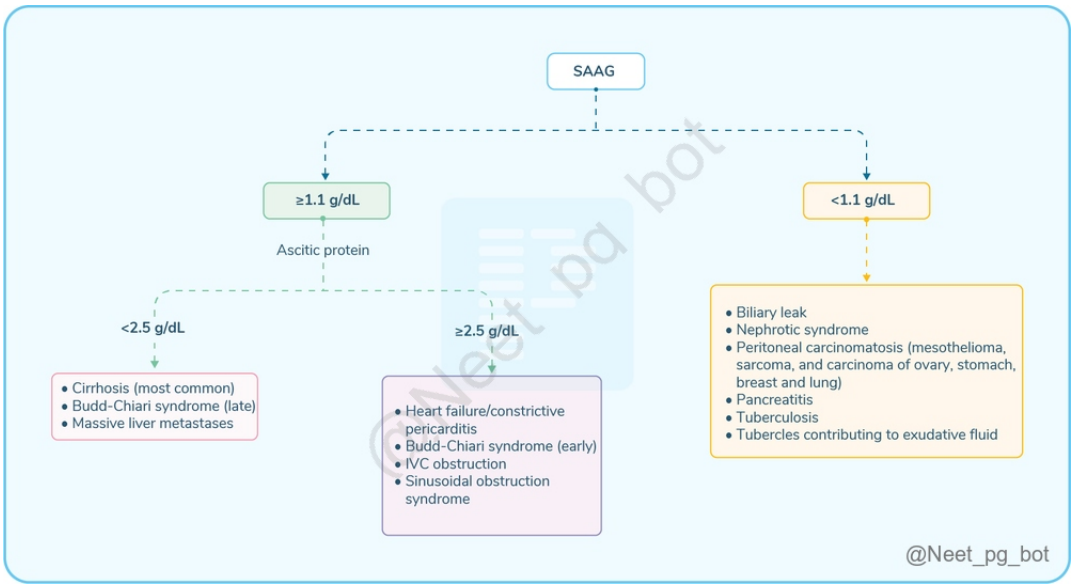

References:

Harrison’s Principles of Internal Medicine, 21st edition, Page 323

Davidson’s Principles and Practice of Medicine, 24th edition, Page 863

↑ *Back to this question in Part A*

@Neet_pg_bot

Q12: Which of the following are not included in the components of the MELD (2016) score? (Q856338)

A. Bilirubin

B. INR

C. Albumin

D. Creatinine

Correct Answer: C. Albumin

Explanation: Albumin is included in the calculation of the PELD (Pediatric End-Stage Liver Disease) and not the MELD (Model for End-Stage Liver Disease) score. MELD (Model for End-Stage Liver Disease) score: Predicts prognosis in chronic liver disease It was developed to predict 3-month mortality in patients after TIPSS (transjugular portosystemic shunt) Used in UNOS (United Nations Organ Sharing Network) to determine priority for liver transplantation. Most patients with low MELD scores (less than 15) do not benefit from transplantation Score: 6 - 40 Components: C reatinine (Option D) B ilirubin (Option A) I NR (Option B) PELD (Pediatric End-Stage Liver Disease) Score: Used to determine priority for children awaiting liver transplantation Components: N utrition A ge B ilirubin I NR Albumin

References:

Bailey & Love's Short Practice Of Surgery, 27th edition, Page 1620

Sabiston Textbook of Surgery, 21st edition, Page 618, 619

https://pubmed.ncbi.nlm.nih.gov/12151728/

↑ *Back to this question in Part A*

@Neet_pg_bot

Q13: Mark the correct statement regarding inflammatory bowel disease. (Q855605)

A. Skip lesions are present in Crohn’s disease

B. Mucosal layers are involved in Crohn’s while transmural involvement seen in ulcerative colitis

C. Inflammatory bowel disease doesn’t have a genetic predisposition

D. Crohn’s is curable through surgical resection of the affected segment

Correct Answer: A. Skip lesions are present in Crohn’s disease

Explanation: Skip lesions refer to the characteristic feature of Crohn's disease where there are areas of inflammation that are separated by normal or unaffected segments of the bowel. This pattern of involvement is not seen in ulcerative colitis. Skip lesions can occur throughout the entire gastrointestinal tract, from the mouth to the anus, in Crohn's disease. In Crohn's disease, the inflammation can involve all layers of the bowel wall, which is

known as transmural involvement . In ulcerative colitis, the inflammation is limited to the mucosal layer of the colon and rectum. (Option B) Both Crohn's disease and ulcerative colitis have a strong genetic component , indicating a predisposition to developing these conditions (Option C) . Family history of inflammatory bowel disease is a known risk factor. Crohn's disease is a chronic condition that requires long-term management and treatment (Option D) to control inflammation and maintain remission. Learning Objective: Distinguishing features between Crohn’s Disease and Ulcerative colitis Clinical features Crohn’s Disease Ulcerative colitis Affects Any part of GIT from mouth to anus. Primarily, the colon is involved. Rectal involvement The rectum is often spared. It almost always involves the rectum, hence associated with rectal bleeding. Skin lesions, Bowel wall thickening, Strictures, and Perianal manifestations Common Rare Inflammation Transmural and segmental Mucosal and continuous involvement Granulomas Noncaseating granulomas are characteristic of Crohn’s disease. Granulomas are not typically present.

References:

Harrison’s Principles of Internal Medicine, 21st Edition, Page 2474

↑ *Back to this question in Part A*

@Neet_pg_bot

Q14: A patient was taking ampicillin for an upper respiratory tract infection. Then he started having watery diarrhoea for the past 3 days. Which is the drug of choice to manage this condition? (Q854689)

A. Metronidazole

B. Fidaxomicin

C. Ciprofloxacin

D. Bezlotoxumab

Correct Answer: B. Fidaxomicin

Explanation: The overuse of antibiotics like ampicillin leads to diarrhoea and further, a condition called pseudomembranous colitis caused by Clostridium difficile and is treated with Fidaxomicin . Clostridioides Difficile Infection (CDI) A colonic disease caused by C. difficile, linked to antibiotic use disrupting normal gut microbiome. It results in diarrhoea and severe cases, of pseudomembranous colitis (PMC). Etiology & Epidemiology: C. difficile is a spore-forming, anaerobic bacterium. Most commonly acquired in hospitals, nursing homes, and after antibiotic use. High-risk antibiotics: Clindamycin , Ampicillin , Cephalosporins , and Fluoroquinolones (Option C) . CDI is common in healthcare settings and can also occur in the community without prior antibiotic use. Pathogenesis: Ingestion of spores leads to toxin production (Toxin A and Toxin B) causing gut damage, diarrhoea, and PMC. Toxin B is the more important virulence factor. Diagnosis: Based on diarrhoea (≥3 unformed stools/day for ≥2 days). Toxin detection in stool (via PCR or enzyme immunoassays). Endoscopy can detect PMC in advanced cases. Treatment: First-line: Oral Vancomycin or Fidaxomicin Metronidazole is an alternative for mild cases . (Option A) Hydration and avoiding antiperistaltic agents are recommended. For severe

cases, Oral Vancomycin is preferred, especially if the patient is seriously ill. IV Vancomycin is ineffective. Bezlotoxumab (Option D) is a monoclonal antibody against C.difficile toxin B used in recurrent pseudomembranous colitis as an adjunct with vancomycin, fidaxomicin or metronidazole. It is not the first-line treatment for this condition.

References:

Harrison's Principles of Internal Medicine, 21st Edition, Page: 1066-1069.

↑ *Back to this question in Part A*

@Neet_pg_bot

Q15: A 42-year-old female presents with complaints of recurrent episodes of abdominal pain and cramps. An endoscopy is done and she is diagnosed with ulcerative colitis. She currently has 3-4 episodes of bloody stools per day. What is the appropriate initial treatment? (Q854665)

A. Budesonide

B. Sulfasalazine

C. Azathioprine

D. Bezlotoxumab

Correct Answer: B. Sulfasalazine

Explanation: Sulfasalazine is commonly used in the treatment of ulcerative colitis (inflammatory bowel disease). Sulfasalazine Anti-inflammatory Properties: Sulfasalazine is composed of two components: Sulfapyridine and 5-aminosalicylic acid (5-ASA) . The 5-ASA component is responsible for the drug's anti-inflammatory effects. It inhibits the production of inflammatory mediators such as prostaglandins and leukotrienes, which play a role in the inflammation seen in ulcerative colitis. Immunomodulatory Effects: Sulfasalazine also has immunomodulatory effects, which help to regulate the immune response in the gastrointestinal tract. By modulating the activity of immune cells such as macrophages and T cells, sulfasalazine can reduce inflammation. Antibacterial Activity: Sulfasalazine's sulfapyridine component has antibacterial properties. It acts by disrupting the metabolism of certain bacteria, particularly those in the gut microbiota. By targeting bacteria, sulfasalazine may help to restore balance to the gut microbiome. Local Action in the Colon: Sulfasalazine is administered orally, and its 5-ASA component is not absorbed systemically to a significant extent. Instead, it remains largely in the colon, where it exerts its anti-inflammatory effects directly on the inflamed tissue. This targeted action reduces the risk of systemic side effects commonly associated with corticosteroids or other systemic immunosuppressive agents. Maintenance Therapy: Sulfasalazine is often used as maintenance therapy in ulcerative colitis. It helps prevent flare-ups and maintain remission over the long term. Symptomatic Relief: In addition to its disease-modifying effects, sulfasalazine can provide symptomatic relief from the symptoms of ulcerative colitis, such as diarrhoea, abdominal pain, and rectal bleeding. Incorrect Options: Budesonide (Option A) is used in cases of exacerbation of ulcerative colitis, especially mild to moderate cases. Azathioprine (AZA) (Option C) is a medication used in the management

and treatment of active rheumatoid arthritis (RA) and the prevention of kidney transplant rejection. Bezlotoxumab (Option D) is indicated to reduce the recurrence of Clostridium difficile infection (CDI) in patients who are receiving antibacterial drug treatment for CDI and are at high risk for CDI recurrence.

References:

Harrison’s Principles of Internal Medicine, 21st Edition, Page: 2474, 2475.

Goodman & Gillman’s The Pharmacological Basis of Therapeutics, 13th Edition, Page: 945.

↑ *Back to this question in Part A*

@Neet_pg_bot

Q16: A known case of ulcerative colitis is not responding to an anti-TNF alpha agent. Which JAK inhibitor is preferred for moderate to severe ulcerative colitis? (Q853355)

A. Vedolizumab

B. Tofacitinib

C. Ozanimod

D. Leflunomide

Correct Answer: B. Tofacitinib

Explanation: Tofacitinib is a oral JAK inhibitor that works by inhibiting the JAK-STAT pathway, which regulates cytokine-mediated inflammation. It is approved for the treatment of moderate to severe ulcerative colitis, particularly in patients who are refractory or intolerant to anti-TNF agents like infliximab or adalimumab. Tofacitinib is a JAK 1/3 inhibitor and blocks the production of inflammatory cytokines such as interleukin-6 and interferons. It is effective for inducing and maintaining remission in moderate to severe ulcerative colitis. Side effects include an increased risk of infections, venous thromboembolism, and lipid elevation, requiring careful patient selection and monitoring. Vedolizumab (Option A) is an anti-integrin monoclonal antibody targeting $\alpha 4\beta 7$ integrin, used to treat moderate to severe ulcerative colitis and Crohn's disease. Ozanimod (Option C) is an FDA-approved sphingosine-1-phosphate (S1P1) receptor modulator for moderate to severe ulcerative colitis, reducing lymphocyte migration to the gut. Leflunomide (Option D) is a pyrimidine synthesis inhibitor primarily for rheumatoid arthritis treatment.

References:

Goodman & Gillman’s The Pharmacological Basis of Therapeutics, 14th Edition, Pages 782, 783, 790.

PMC Article

↑ *Back to this question in Part A*

@Neet_pg_bot

Q17: Which of the following is not associated with celiac disease? (Q853345)

A. IgA transglutaminase positive

B. IgG antigliadin positive

C. Modified Marsh classification

D. HLA DQ6 and HLA DQ11

Correct Answer: D. HLA DQ6 and HLA DQ11

Explanation: HLA-DQ6 and HLA-DQ11 are not associated with celiac disease. In contrast, HLA-DQ2 and HLA-DQ8 are the primary genetic markers found in almost all individuals with celiac disease. Celiac disease is an autoimmune disorder triggered by gluten ingestion in genetically predisposed individuals. It primarily affects the proximal small intestine, with the duodenum most commonly involved. In some cases, it extends to the jejunum, causing more severe symptoms. Pathophysiology: Genetics : HLA-DQ2 and HLA-DQ8 are associated with celiac disease. Immune Response : Gluten ingestion triggers inflammation in the small intestine Symptoms: Gastrointestinal : Diarrhea, abdominal pain, bloating, nausea, vomiting, steatorrhea. Extra-intestinal : Fatigue, skin rashes (dermatitis herpetiformis), weight loss, anemia, joint pain, headaches, peripheral neuropathy. In Children : Delayed growth, irritability, poor weight gain, bone issues due to malabsorption. Diagnosis: 1. Serological Testing: Tissue Transglutaminase (tTG) Antibodies: Most sensitive and specific test. (Option A ruled out) Anti-Endomysial Antibodies (EMA) Anti-Gliadin Antibodies (AGA): Less specific. (Option B ruled out) 2. Histological Confirmation: Upper gastrointestinal endoscopy with small bowel biopsy is the gold standard. Histological Changes : Villous Atrophy : Flattened villi. {{caption_text}} Crypt Hyperplasia : Increased crypt cells. Intraepithelial Lymphocytosis : Elevated lymphocytes. 3. Histological Grading (Modified Marsh Classification): (Option C ruled out) Type Definition 0 Normal duodenal biopsy I Normal mucosal architecture with increased intraepithelial lymphocytes II Hyperplastic crypts, but near normal Villi IIIa Hyperplastic crypts with partial villous atrophy IIIb Hyperplastic crypts with subtotal villous atrophy IIIc Hyperplastic crypts with total villous atrophy Treatment: Gluten-Free Diet : Lifelong, strict adherence is the only treatment. Gluten-containing foods (BROW) : Barley, Rye, Oats, Wheat. Complications: Malnutrition : Due to impaired absorption. Osteoporosis : From poor calcium and vitamin D absorption. Intestinal Lymphoma and Small Bowel Cancer : Rare but serious. Increased Risk of Autoimmune Disorders : Such as Type 1 diabetes and autoimmune thyroid disease. Feature Coeliac Sprue Whipple's Disease Tropical Sprue Description Autoimmune disorder triggered by gluten. Systemic infectious disease caused by Tropheryma whipplei. Malabsorption disorder seen in tropical regions. Cause often unknown, possibly infectious. Etiology Genetic predisposition (HLA-DQ2/DQ8). Environmental trigger: gluten (present in wheat, barley, rye) ingestion and an immune response to gliadin, a protein in gluten. Infection with Tropheryma whipplei, found in soil and sewage. Possibly due to bacterial, fungal or coronavirus infection. Clinical Features Affects mainly proximal small intestine. Intestinal Features: Chronic diarrhea or steatorrhea. Malabsorption: weight loss, vitamin deficiencies. Abdominal pain, bloating. Extraintestinal Features: Iron-deficiency anemia. Dermatitis herpetiformis (in some cases). Affects mainly distal small intestine. Intestinal Features: Chronic diarrhea. Malabsorption, weight loss. Abdominal pain and bloating. Extraintestinal Features: Arthralgia (joint pain). Fever. Lymphadenopathy. Neurological symptoms (cognitive impairment, seizures, ataxia in advanced stages, oculomasticatory myorhythmia). Uveitis Cardiac involvement

(rare). Affects entire small intestinal Intestinal Features: Chronic diarrhea. Malabsorption, weight loss. Abdominal pain, bloating. Extraintestinal Features: Anemia (often megaloblastic). Histological Findings {{caption_text}} Loss or flattening of intestinal villi (villous atrophy). Hyperplastic crypts (crypt elongation). Increased infiltration of lymphocytes, especially CD8+ T cells. Increased plasma cells, lymphocytes, macrophages in lamina propria. {{caption_text}} Villous blunting and atrophy. Dense infiltration of lamina propria by macrophages containing PAS-positive granules. Foamy macrophages laden with Tropheryma whipplei in various tissues (e.g., lymph nodes, CNS, synovial fluid). {{caption_text}} Villous atrophy. Crypt hyperplasia. Increased inflammatory cells (similar to Celiac disease but without gliadin-specific immune response). Investigations Biopsy Serologic Tests: Most sensitive and most common antibody test: Anti-Tissue Transglutaminase Antibodies (Anti-tTG) - IgA and IgG Most specific antibody test: Anti-Endomysial Antibodies (EMA) - IgA. Anti-Deamidated Gliadin Peptide (DGP) Antibodies - IgA and IgG. Anti-Gliadin Antibodies (AGA) - IgA and IgG. Biopsy PCR for Tropheryma whipplei DNA. Immunohistochemistry for Tropheryma whipplei. Biopsy Response to Treatment: Antibiotic response helps confirm diagnosis. Management Lifelong gluten-free diet. Nutritional supplementation: iron, folate, calcium, vitamin D. Indications for steroids: Refractory disease for 6-12 months Celiac crisis Lymphoma Monitoring for complications Prolonged antibiotic therapy: Initially IV ceftriaxone or meropenem for 2 weeks. Followed by oral trimethoprim-sulfamethoxazole for a year. Tetracycline for 6 months. Folate supplementation. Some recommend a gluten-free diet. Complications Osteoporosis. Malignancy (e.g., small bowel lymphoma). Infertility. Neurological complications (rare). Failure to thrive. Untreated disease can be fatal due to multi-organ involvement. Relapses are common (especially CNS). Nutritional deficiencies can lead to osteoporosis, cachexia. Nutritional deficiencies (e.g., vitamin B12, folate). Persistent malabsorption. Possible relapse and chronic diarrhea.

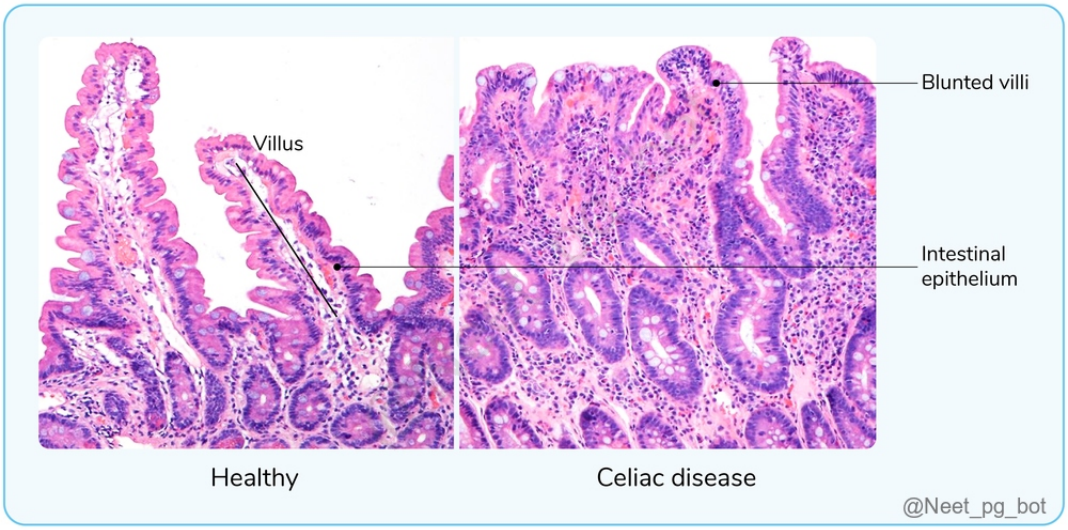

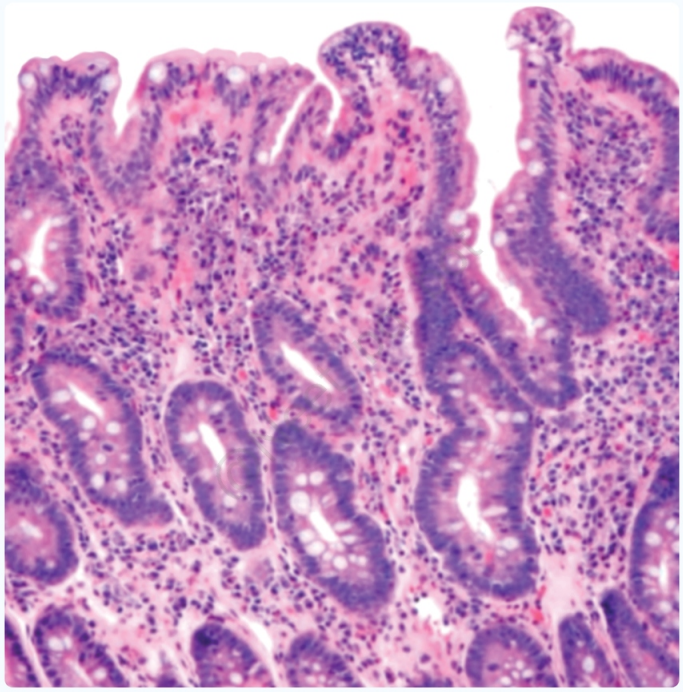

Celiac disease

@Neet_pg_bot

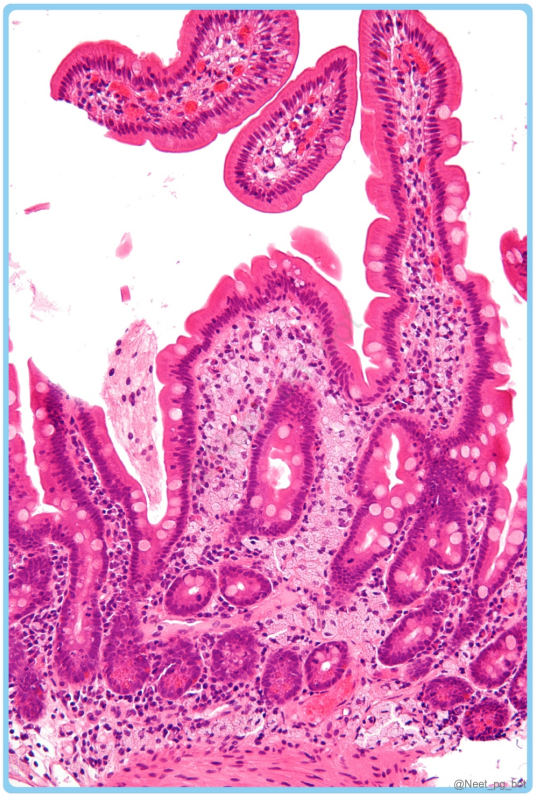

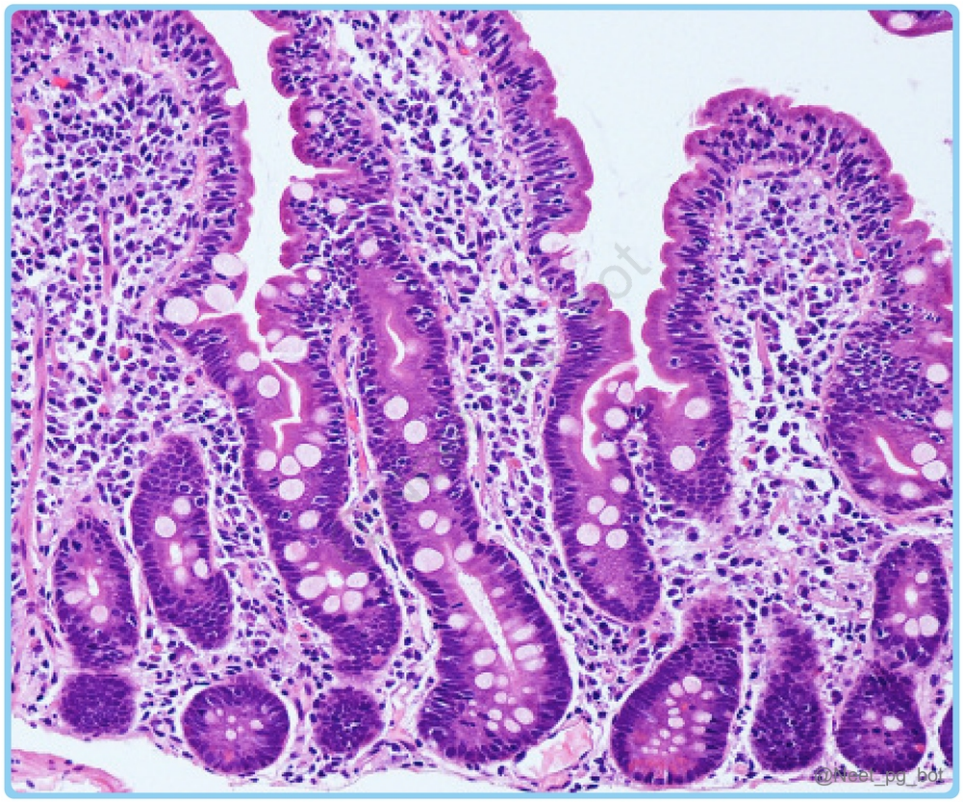

References:

Robbins and Cotran Pathologic Basis of Disease, 10th Edition, Pages 784-786, 794.

Harrison's Principles of Internal Medicine, 21st Edition, Pages 2464, 2465.

https://www.researchgate.net/figure/Modified-Marsh-classification-of-celiac-disease_tbl1_8505308

↑ *Back to this question in Part A*

@Neet_pg_bot

Q18: Which of the following symptoms suggests the use of steroids in IgA vasculitis? (Q840121)

A. Joint inflammation

B. Gastrointestinal hemorrhage

C. Abdominal discomfort

D. Dermatological eruption

Correct Answer: B. Gastrointestinal hemorrhage

Explanation: Correct Option B - Gastrointestinal hemorrhage: Steroids are administered in cases of gastrointestinal bleeding or suspected perforation to mitigate inflammation and reduce the risk of complications. Incorrect Options: Options A, C & D are incorrect.

↑ *Back to this question in Part A*

@Neet_pg_bot

Q19: Patient is identified as having a tumor in the ileum leading to urinary 5 HIAA being elevated. What is the diagnosis? (Q793830)

A. Carcinoid tumor

B. Neuroblastoma

C. Leiomyoma

D. Chromaffinoma

Correct Answer: A. Carcinoid tumor

Explanation: Correct option A - Carcinoid tumors: Carcinoid tumors are a type of neuroendocrine tumor that can arise in various parts of the body, including the gastrointestinal tract (especially the ileum), lungs, and pancreas. They are usually slow-growing but can metastasize to other organs over time. One of the hallmark features of carcinoid tumors is the secretion of serotonin, which can lead to elevated levels of urinary 5-hydroxy indole acetic acid (5-HIAA). This is because serotonin is converted to 5-HIAA in the liver and then excreted in the urine. Incorrect Choices: Option B - Neuroblastoma is most commonly diagnosed in infants and young children and can cause symptoms such as abdominal swelling or pain, fever, and weight loss. Option C: Leiomyoma is a benign tumor arising from smooth muscle tissue and can occur in various parts of the body (including the uterus, gastrointestinal tract, and skin). Option D - Chromaffinoma (also known as a pheochromocytoma) is a type of tumor arising from chromaffin cells in the adrenal glands and sympathetic ganglia (part of the autonomic nervous system).

↑ *Back to this question in Part A*

@Neet_pg_bot

Q20: What is the probable diagnosis for a 50-year-old woman with a skin lesion visible in the provided image, which initially appeared small but has now spread to her entire limb and abdomen? Despite being on anticoagulation therapy, she has a longstanding history of diabetes and recurring deep vein thrombosis episodes. (Q793836)

A. Insulinoma

B. Gastrinoma

C. Glucagonoma

D. VIPoma



Correct Answer: C. Glucagonoma

Explanation: Correct Option C - Glucagonoma: Based on the information provided, the most likely diagnosis for this patient's condition is glucagonoma. A glucagonoma is a rare pancreatic neuroendocrine tumor that produces excessive amounts of glucagon. Clinical features of glucagonoma Diabetes mellitus/impaired glucose tolerance Diarrhea Dermatological features Migratory necrolytic erythema (red rash- bullae- erosions) Weight loss Incorrect Options: Option A - An insulinoma is a pancreatic neuroendocrine tumor that secretes excessive amounts of insulin. This condition can lead to hypoglycemia, which can cause symptoms such as weakness, confusion, sweating, and palpitations. Option B - A gastrinoma is a pancreatic neuroendocrine tumor that produces excessive amounts of gastrin, a hormone that stimulates the production of stomach acid. This can cause symptoms such as abdominal pain, nausea, vomiting, and diarrhea. Option D - While VIPomas can cause skin lesions, they are not typically associated with recurrent deep vein thrombosis or long-standing diabetes, so it is an unlikely diagnosis in this case.

↑ *Back to this question in Part A*

@Neet_pg_bot

• [06_Hematology] 037 Chronic Lymphocytic Leukemia

« Back to Folder Directory

[06_Hematology] 037 Chronic Lymphocytic Leukemia — Quick Jump

Q1 (p. 2013) *Q2 (p. 2013)* *Q3 (p. 2014)* *Q4 (p. 2015)* *Q5 (p. 2016)* *Q6 (p. 2017)*
Q7 (p. 2017) *Q8 (p. 2018)* *Q9 (p. 2019)* *Q10 (p. 2019)* *Q11 (p. 2020)* *Q12 (p. 2021)*
Q13 (p. 2021)

Q1: 70-year-old retired man presents with low grade fever, painless swelling in the neck and fatigue for the past 3 months. Examination reveals generalized lymphadenopathy and mild splenomegaly. CBC shows WBC 85,000/µL with absolute lymphocyte count 65,000/µL. Peripheral smear shows numerous small mature-appearing lymphocytes and smudge cells. Which of the following is the investigation of choice to confirm the diagnosis? (Q850873)

A. Peripheral blood flow cytometry

B. Bone marrow aspiration showing lymphoblasts > 20%

C. FISH analysis for 17p deletion

D. PCR for ZAP-70 expression

Correct Answer: A. Peripheral blood flow cytometry

■ *Listen (English)*

■ *Listen (Hindi)*

Explanation: CLL diagnosis is made by demonstrating a monoclonal B-cell population with CLL immunophenotype (CD19+, CD20dim, CD5+, CD23+) using flow cytometry on peripheral blood. Bone marrow aspiration showing lymphoblasts > 20% is cut off for acute leukemia FISH and PCR for ZAP-70 are prognostic markers, not first-line diagnostic tests.

References:

Harrison's Principles of Internal Medicine, 22nd Edition, Page, 850.

↑ *Back to this question in Part A*

@Neet_pg_bot

Q2: A 65-year-old man on an annual medical check-up is found to have lymphocytosis on routine CBC (total leukocyte count: 11,000/µL; absolute lymphocyte count: 4,200/µL). He is asymptomatic with no lymphadenopathy or organomegaly. Peripheral smear shows mature-appearing small lymphocytes. Flow cytometry reveals a monoclonal B-cell population with CLL immunophenotype. Which of the following features will help distinguish this condition from CLL? (Q850875)

A. Presence of B symptoms

B. Absolute B-cell count < 5 × 10y/L

C. Positive Coombs test

D. Expression of CD19, CD20, CD5

Correct Answer: B. Absolute B-cell count < 5 × 10y/L

■ *Listen (English)*

■ *Listen (Hindi)*

Explanation: Monoclonal B-cell lymphocytosis (MBL) is a premalignant condition characterized by a small population of monoclonal B cells in peripheral blood < 5 × 10y/L , with CLL-like immunophenotype, no lymphadenopathy, hepatosplenomegaly, or cytopenias . CLL diagnosis requires monoclonal B-cell count ≥ 5 × 10y/L or tissue infiltration. CD19, CD20, CD5 expression occurs in both MBL and CLL, so it does not help differentiate. Presence of B symptoms or cytopenias would favor CLL.

References:

Harrison's Principles of Internal Medicine, 22nd Edition, Page 852.

↑ *Back to this question in Part A*

@Neet_pg_bot

Q3: Radiation exposure is associated with increased risk of several hematological malignancies. Which of the following is least likely to be related to radiation exposure (Q850877)

A. ALL

B. AML

C. CML

D. CLL

Correct Answer: D. CLL

■ *Listen (English)*

■ *Listen (Hindi)*

Explanation: Radiation is not a risk factor for CLL. Hematological malignancies linked to radiation: Acute and chronic myeloid leukemia Acute lymphoblastic leukemia Non-Hodgkin leukemia

References:

Harrison's Principles of Internal Medicine, 22nd Edition, Page 849-850.

↑ *Back to this question in Part A*

@Neet_pg_bot

Q4: Which of the following peripheral smear findings is not seen in CLL? (Q850879)

A. Spherocytes

B. Smudge cells

C. Prolymphocytes

D. Lymphoblasts

Correct Answer: D. Lymphoblasts

■ *Listen (English)*

■ *Listen (Hindi)*

Explanation: Lymphoblasts are a hallmark of ALL and not CLL CLL peripheral smear findings Small mature lymphocytes Smudge cells (fragile lymphocytes) Prolymphocytes (< 55%) Spherocytes can appear if autoimmune hemolytic anemia develops as a complication.

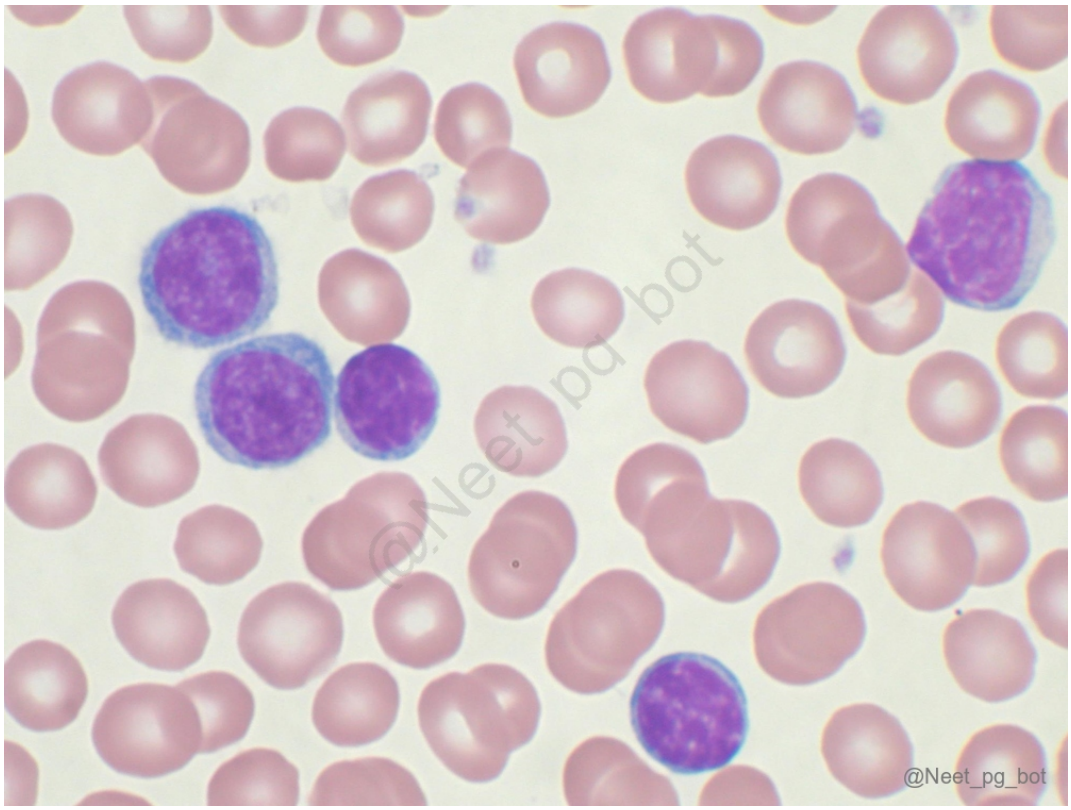

References:

Harrison's Principles of Internal Medicine, 22nd Edition, Page 850.

↑ *Back to this question in Part A*

@Neet_pg_bot

Q5: Which of the following statements regarding Richter transformation is correct? (Q850881)

A. Transformation of CLL into diffuse large B-cell lymphoma

B. Transformation of follicular lymphoma into diffuse large B-cell lymphoma

C. Transformation of marginal zone lymphoma into diffuse large B-cell lymphoma

D. Transformation of mantle cell lymphoma into diffuse large B-cell lymphoma

Correct Answer: A. Transformation of CLL into diffuse large B-cell lymphoma

■ *Listen (English)*

■ *Listen (Hindi)*

Explanation: Remember Ritcher transformation as “Rich CLL turns bold” ie CLL transformation into new avatar as diffuse large B cell lymphoma. Follicular lymphoma, marginal zone lymphoma, and mantle cell lymphoma can all transform into DLBCL, but these are not called Richter transformation — they are simply termed histologic transformations

References:

Harrison's Principles of Internal Medicine, 22nd Edition, Page 853-854.

↑ *Back to this question in Part A*

@Neet_pg_bot

Q6: Leading cause of death in patients diagnosed with CLL? (Q850882)

A. Hypo-gammaglobulinemia

B. Heart disease

C. Kidney failure

D. Hyper viscosity syndrome

Correct Answer: A. Hypo-gammaglobulinemia

■ *Listen (English)*

■ *Listen (Hindi)*

Explanation: In CLL, B cells are monoclonal, abnormal, and do not mount proper antibody responses. They also dysregulate the immune system, sometimes producing autoantibodies against the patient’s own red cells or platelets causing autoimmune haemolytic anaemia and ITP. With progressive decline in functional immunoglobulins, patients become especially vulnerable to encapsulated bacteria (e.g., Streptococcus pneumoniae, Haemophilus influenzae), as well as viral reactivations.

References:

Harrison's Principles of Internal Medicine, 22nd Edition, Page 853.

↑ *Back to this question in Part A*

@Neet_pg_bot

Q7: Known case of CLL is admitted with shortness of breath on minimal activity. Work up shows Hb= 7 gm%, TLC 25000 cells/cu.mm, platelet count of 50K/cu.mm, reticulocyte count is 2% with low haptoglobin and elevated LDH. Which of the

following test would help in further evaluation of this patient? (Q850884)

A. Direct coombs test

B. ZAP-70

C. FISH

D. Treadmill test

Correct Answer: A. Direct coombs test

■ *Listen (English)*

■ *Listen (Hindi)*

Explanation: CLL can be complicated by autoimmune haemolytic anemia and autoimmune thrombocytopenia. Laboratory signs of hemolysis: low haptoglobin, elevated LDH, anemia with reticulocytosis. Direct Coombs (Direct antiglobulin) test detects antibodies (usually warm IgG) bound to RBCs, confirming autoimmune etiology . ZAP-70 and FISH are for prognosis , not acute diagnostic clarification. (Option B and C) Treadmill test is unrelated to this presentation. (Option D)

References:

Harrison's Principles of Internal Medicine, 22nd Edition, Page 853.

↑ *Back to this question in Part A*

@Neet_pg_bot

Q8: Which of the following is drug used in CLL acts is inhibitor of antiapoptotic protein BCL-2? (Q850886)

A. Venetoclax

B. Ibrutinib

C. Idelalisib

D. Duvelisib

Correct Answer: A. Venetoclax

■ *Listen (English)*

■ *Listen (Hindi)*

Explanation: Drug Mechanism of action Venetoclax inhibitor of antiapoptotic protein BCL-2 and promotes apoptosis Ibrutinib BTK inhibitor: blocking B-cell receptor signaling that inhibits B-cell proliferation and survival

Idelalisib PI3K inhibitor: blocking downstream survival pathways (AKT/mTOR) that induces apoptosis and reduces trafficking of malignant B-cells Duvelisib PI3K inhibitor: same as above

References:

Harrison's Principles of Internal Medicine, 22nd Edition, Page 855.

↑ *Back to this question in Part A*

@Neet_pg_bot

Q9: Evan syndrome is defined as? (Q850888)

A. Autoimmune hemolytic anemia + autoimmune thrombocytopenia

B. Autoimmune hemolytic anemia + autoimmune granulocytopenia

C. Pure red cell aplasia + autoimmune granulocytopenia

D. Pure red cell aplasia + autoimmune thrombocytopenia

Correct Answer: A. Autoimmune hemolytic anemia + autoimmune thrombocytopenia

■ *Listen (English)*

■ *Listen (Hindi)*

Explanation: Evan’s syndrome is coexistence (simultaneous or sequential) of autoimmune hemolytic anemia and immune thrombocytopenia. It can occur idiopathically or secondary to conditions like SLE and CLL.

References:

Harrison's Principles of Internal Medicine, 22nd Edition, Page 853.

↑ *Back to this question in Part A*

@Neet_pg_bot

Q10: Which of the following is not a component of Rai staging system used in CLL? (Q850890)

A. Lymphocytosis

B. Lymphadenopathy

C. Hepatosplenomegaly

D. Autoimmune hemolytic anemia

Correct Answer: D. Autoimmune hemolytic anemia

■ *Listen (English)*

■ *Listen (Hindi)*

Explanation: It is anaemia or thrombocytopenia caused by bone marrow involvement that is considered and not autoimmune hemolytic anaemia. Staging of CLL Rai Staging System Low risk (stage 0) Lymphocytosis only Intermediate risk (stage I/II) Lymphocytosis with lymphadenopathy, with or without splenomegaly or hepatomegaly High risk (stage III/IV) Lymphocytosis with anemia or thrombocytopenia due to bone marrow involvement

References:

Harrison's Principles of Internal Medicine, 22nd Edition, Page 854.

↑ *Back to this question in Part A*

@Neet_pg_bot

Q11: Which of the following is not a component of CLL prognostic index? (Q850893)

A. Age

B. Beta 2 microglobulin

C. Clinical staging

D. BCL-2

Correct Answer: D. BCL-2

■ *Listen (English)*

■ *Listen (Hindi)*

Explanation: CLL International Prognostic Index VARIABLE ADVERSE FACTOR RISK SCORE TP53 status Deleted or mutated 4 IGHV mutational status Unmutated 2 β 2 -microglobulin concentration >3.5 mg/L 2 Clinical stage Rai I-IV or Binet B-C 1 Age >65 years 1

References:

Harrison's Principles of Internal Medicine, 22nd Edition, Page 854.

↑ *Back to this question in Part A*

@Neet_pg_bot

Q12: What secondary malignancy can be seen in patients with CLL? (Q850895)

A. Skin and prostate cancer

B. Oro-pharyngeal cancer

C. Ca- larynx

D. Hepatocellular cancer

Correct Answer: A. Skin and prostate cancer

■ *Listen (English)*

■ *Listen (Hindi)*

Explanation: The secondary malignancies most commonly seen in patients with chronic lymphocytic leukemia (CLL) are skin cancers (especially non-melanoma skin cancers) and prostate cancer. CLL-related immunosuppression, older age, and previous therapy increase the incidence of these secondary cancers.

References:

Harrison's Principles of Internal Medicine, 22nd Edition, Page 853.

↑ *Back to this question in Part A*

@Neet_pg_bot

Q13: A 62-year-old man presents with generalized lymphadenopathy and mild splenomegaly. Peripheral smear shows small-to-medium sized lymphoid cells with irregular nuclear contours. Lymph node biopsy reveals a diffuse proliferation of small lymphocytes with cleaved nuclei. Immunophenotyping shows CD19+, CD20+, CD5+, cyclin D1+, and negative for CD23. Which is the most likely diagnosis? (Q850897)

A. Chronic lymphocytic leukemia

B. Mantle cell lymphoma

C. Follicular lymphoma

D. Marginal zone lymphoma

Correct Answer: B. Mantle cell lymphoma

■ *Listen (English)*

■ *Listen (Hindi)*

Explanation: Typical Immunophenotype of CLL compared with other B Cell Malignancies DISEASE CD5 CD10 CD19 CD20 CD23 CYCLIN D1 SURFACE IG CLL + - + +(dim) + - +(dim) Mantle cell lymphoma + - + +(mod/bright) - + +(mod/bright) Marginal zone lymphoma -/+ - + +(mod/bright) -/+ - +(mod/bright) Follicular lymphoma - + + + + -

References:

Harrison's Principles of Internal Medicine, 22nd Edition, Page 872-873.

↑ *Back to this question in Part A*

@Neet_pg_bot

• [06_Hematology] 038 Chronic Myeloid Leukemia

« Back to Folder Directory

[06_Hematology] 038 Chronic Myeloid Leukemia — Quick Jump

Q1 (p. 2023) *Q2 (p. 2023)* *Q3 (p. 2024)* *Q4 (p. 2025)* *Q5 (p. 2025)* *Q6 (p. 2026)*
Q7 (p. 2027) *Q8 (p. 2027)* *Q9 (p. 2028)* *Q10 (p. 2029)* *Q11 (p. 2030)*

Q1: Which of the following is correct about the Philadelphia chromosome? (Q850439)

A. Balanced translocation between long arms of chromosome 9 and 22

B. Balanced translocation between short arms of chromosome 9 and 22

C. Unbalanced translocation between long arms of chromosome 9 and 22

D. Unbalanced translocation between short arms of chromosome 9 and 22

Correct Answer: A. Balanced translocation between long arms of chromosome 9 and 22

■ *Listen (English)*

■ *Listen (Hindi)*

Explanation: The Philadelphia chromosome is formed due to a balanced reciprocal translocation between: Chromosome 9 (q34) – contains the ABL proto-oncogene Chromosome 22 (q11) – contains the BCR gene This results in the formation of the BCR-ABL fusion gene , which codes for a constitutively active tyrosine kinase , leading to uncontrolled myeloid proliferation—hallmark of Chronic Myeloid Leukemia (CML) .

References:

Harrison's Principles of Internal Medicine, 22nd Edition, Page 834.

↑ *Back to this question in Part A*

@Neet_pg_bot

Q2: Which of the following is correct about CML? (Q850533)

A. Reciprocal exchange between breakpoint Cluster Region gene on chromosome 22, ABL1 gene on chromosome 9

B. Reciprocal exchange between breakpoint Cluster Region gene on chromosome 9, ABL1 gene on chromosome 22

C. Non-reciprocal exchange between breakpoint Cluster Region gene on chromosome 22, ABL1 gene on chromosome 9

D. Non-reciprocal exchange between breakpoint Cluster Region gene on chromosome 9, ABL1 gene on chromosome 22

Correct Answer: A. Reciprocal exchange between breakpoint Cluster Region gene on chromosome 22, ABL1 gene on chromosome 9

■ *Listen (English)*

■ *Listen (Hindi)*

Explanation: A part of chromosome 9 at band q34 (where the ABL1 proto-oncogene is located) breaks off. A part of chromosome 22 at band q11 (where the BCR gene is located) breaks off. These segments swap places (reciprocal exchange). The result on chromosome 22 is the BCR-ABL1 fusion gene , producing a constitutively active tyrosine kinase . This altered chromosome 22 is called the Philadelphia chromosome . Hack to remember: Amitabh Bacchan favourite number is 9 (ABL1: chromosome 9)

References:

Harrison's Principles of Internal Medicine, 22nd Edition, Page 834-835.

↑ *Back to this question in Part A*

@Neet_pg_bot

Q3: Best for management of gatekeeper mutation T315I that prevents binding and causes resistance to known TKI in Chronic myeloid leukemia is? (Q850538)

A. Dasatinib

B. Nilotinib

C. Bosutinib

D. Ponatinib

Correct Answer: D. Ponatinib

■ *Listen (English)*

■ *Listen (Hindi)*

Explanation: The T315I mutation in CML confers resistance to most TKIs; Ponatinib is specifically designed to inhibit BCR-ABL with the T315I mutation. AGENT APPROVED INDICATIONS Dasatinib All phases Nilotinib All phases except blastic phase Bosutinib All phases Ponatinib Optimal TKI if T315l mutation; Failure of ≥2 tyrosine kinase inhibitors Omacetaxine CML resistant to ≥ TKIs; Effective in T315l

References:

Harrison's Principles of Internal Medicine, 22nd Edition, Page 835-836.

↑ *Back to this question in Part A*

@Neet_pg_bot

Q4: Bcr-abl1 fusion gene is seen in which of the following blood cancers? (Q850559)

A. ALL

B. AML

C. CLL

D. Hairy cell leukemia

Correct Answer: A. ALL

■ *Listen (English)*

■ *Listen (Hindi)*

Explanation: The BCR-ABL1 fusion gene is seen in Philadelphia chromosome–positive acute lymphoblastic leukemia (ALL) and chronic myeloid leukemia (CML), resulting from t(9;22) translocation. AML (Option B): Common mutations include FLT3, NPM1, CEBPA. CLL (Option C): Frequently associated with del(13q), del(11q), TP53 mutations. Hairy cell leukemia (Option D): Characteristically shows BRAF V600E mutation.

References:

Harrison's Principles of Internal Medicine, 22nd Edition, Page 844.

↑ *Back to this question in Part A*

@Neet_pg_bot

Q5: Which of the following findings is not seen in patients with CML? (Q850582)

A. Basophilia

B. Low serum Vitamin B12 levels

C. Low NAP score

D. Reticulin fibrosis in bone marrow

Correct Answer: B. Low serum Vitamin B12 levels

■ *Listen (English)*

■ *Listen (Hindi)*

Explanation: In CML, serum B12 is high, not low, because increased granulocytes produce more transcobalamin I, which binds B12 and is responsible for DNA synthesis Basophilia (Option A) is seen in CML as it is a myeloproliferative disorder. Neutrophil Alkaline Phosphatase (Option C) score is low in CML, and it helps to differentiate from leukemoid reaction, where it is high. A low NAP score implies that post-expiry date neutrophils that have lost the ability to fight are circulating in the bloodstream. This explains the development of recurrent infections. In CML, as the disease progresses (especially toward accelerated phase or blast crisis), there is fibroblast stimulation by growth factors (PDGF, TGF-β) released from abnormal megakaryocytes and other marrow cells. This leads to increased deposition of reticulin and "reticulin fibrosis" (Option D).

References:

Harrison's Principles of Internal Medicine, 22nd Edition, Page 837.

↑ *Back to this question in Part A*

@Neet_pg_bot

Q6: A 48-year-old male presents with fatigue and early satiety. On examination massive splenomegaly is seen. Work up is shown below. What is next best investigation to be done in this case CBC Bone marrow aspiration report Hb: 10.5 g/dL TLC: 1.5 × 10■ /mm³ Platelets: 4.0 × 10■ /mm³ Myeloblasts: 2% , Promyelocytes: 15% , Myelocytes: 25% , Metamyelocytes: 20% Band forms & neutrophils: 18% , Basophils: 6%, Blasts + promyelocytes together: <10%, NAP score: low (Q850605)

A. Bone marrow biopsy

B. Peripheral blood FISH for BCR-ABL1

C. Peripheral blood RT-PCR for BCR-ABL1

D. G-banding cytogenetics

Correct Answer: B. Peripheral blood FISH for BCR-ABL1

■ *Listen (English)*

■ *Listen (Hindi)*

Explanation: FISH detects the t(9;22) Philadelphia chromosome or BCR-ABL1 fusion gene without cell culture, so results are quicker than G-banding. It can be done directly from peripheral blood, so you avoid an invasive bone marrow procedure. Bone marrow biopsy (Option A): Not immediately required; CML can often be diagnosed from peripheral blood and FISH/RT-PCR. Peripheral blood RT-PCR for BCR-ABL1 (Option C): Useful for quantitative monitoring, but FISH is faster for initial detection. G-banding cytogenetics (Option D): Can detect Philadelphia chromosome but is slower than FISH.

References:

Harrison's Principles of Internal Medicine, 22nd Edition, Page 837.

↑ *Back to this question in Part A*

@Neet_pg_bot

Q7: A 35-year-old male with CML in chronic phase is started on imatinib. At diagnosis, bone marrow cytogenetics showed t(9;22)(q34;q11) in all metaphases. The treating physician now wants to assess whether he has achieved deep molecular remission. Which is the most appropriate investigation at this stage? (Q850613)

A. Conventional karyotyping from bone marrow aspirate

B. FISH for BCR-ABL on peripheral blood

C. Quantitative RT-PCR for BCR-ABL transcript levels

D. Qualitative PCR for BCR-ABL transcript

Correct Answer: C. Quantitative RT-PCR for BCR-ABL transcript levels

■ *Listen (English)*

■ *Listen (Hindi)*

Explanation: Molecular response : Quantitative RT-PCR (qPCR) for BCR-ABL mRNA every 3–6 months thereafter Deep molecular remission is defined as BCR-ABL ≤ 0.01% on the International Scale. qPCR is ~100–1000× more sensitive, detecting 1 leukemic cell among 10■–10■ normal cells. Karyotyping and FISH detect cytogenetic remission but are less sensitive (~1–5% abnormal cells detection limit). Conventional karyotyping from bone marrow aspirate (Option A): Less sensitive; cannot detect minimal residual disease. FISH for BCR-ABL on peripheral blood (Option B): Detects fusion gene but less sensitive than quantitative PCR for deep remission. Qualitative PCR for BCR-ABL transcript (Option D): Only detects presence/absence, not the level of transcript, so cannot assess depth of remission.

References:

Harrison's Principles of Internal Medicine, 22nd Edition, Page 838-839.

↑ *Back to this question in Part A*

@Neet_pg_bot

Q8: Which of the following is the most common presenting feature of CML? (Q850649)

A. Lymphadenopathy

B. Splenomegaly

C. Petechiae

D. Bone pain

Correct Answer: B. Splenomegaly

■ *Listen (English)*

■ *Listen (Hindi)*

Explanation: Splenomegaly is the most common and characteristic presenting feature of CML. Patients often notice early satiety, abdominal fullness, or left upper quadrant discomfort. Lymphadenopathy (Option A): Rare in CML; more common in CLL. Petechiae (Option C): Can occur with thrombocytopenia but is not a typical initial feature. Bone pain (Option D): Less common; may appear in accelerated or blast phase.

References:

Harrison's Principles of Internal Medicine, 22nd Edition, Page 836-837.

↑ *Back to this question in Part A*

@Neet_pg_bot

Q9: Which of the following drugs is approved for CML in case of failure of >2 or more TKI (Q850656)

A. Omacetaxine

B. Dasatinib

C. Bosutinib

D. Nilotinib

Correct Answer: A. Omacetaxine

■ *Listen (English)*

■ *Listen (Hindi)*

Explanation: Omacetaxine is approved for CML patients resistant or intolerant to two or more TKIs , acting via a BCR-ABL–independent mechanism. AGENT (BRAND NAME) APPROVED INDICATIONS DOSE

SCHEDULE NOTABLE TOXICITIES Imatinib mesylate (Gleevec) All phases 400 mg daily Fluid retention/edema, muscle cramps; skin rash; hepatotoxicity Dasatinib (Sprycel) All phases First-line: 100 mg daily Salvage: 100 mg daily in chronic phase; 140 mg daily in transformation Myelosuppression; pleural and pericardial effusions; pulmonary hypertension Nilotinib (Tasigna) All phases except blastic phase First-line: 300 mg twice daily Salvage: 400 mg twice daily Diabetes; arterio-occlusive events; pancreatitis Bosutinib (Bosulif) All phases First line: 400 mg daily Salvage: 500 mg daily Diarrhea; liver toxicity; renal dysfunction Ponatinib (Iclusig) T315I mutation; failure of ≥2 tyrosine kinase inhibitors 45 mg daily (may consider lower starting doses, e.g., 30 mg daily; lower the dose to 15 mg daily once a complete cytogenetic response is achieved) Skin rashes (10–20%); pancreatitis (5%); arterio-occlusive events (10–20%); systemic hypertension (10–15%) Asciminib (Scemblix) Third-line therapy; T315I mutation 40 mg twice daily or 80 mg daily; T315I: 200 mg twice daily Arterial occlusive events; hypertension Omacetaxine mepesuccinate (Synribo) Failure ≥2 tyrosine kinase inhibitors 1.25 mg/m² subcutaneously twice daily for 14 days of induction; 7 days of maintenance every month (consider shorter dose schedules, 7 days of induction, 2–5 days of maintenance) Myelosuppression

References:

Harrison's Principles of Internal Medicine, 22nd Edition, Page 838-839.

↑ *Back to this question in Part A*

@Neet_pg_bot

Q10: 48-year-old man presents with fatigue, headache, and visual blurring. Examination reveals splenomegaly. CBC shows: Hb 9.8 g/dL, TLC 1.2 × 10■/µL, platelet count 650 × 10³/µL. Peripheral smear shows marked myeloid proliferation with occasional myeloblasts. Fundoscopy reveals retinal vein engorgement. Which of the following is the most appropriate immediate next step in management? (Q850678)

A. Start imatinib therapy

B. Leukapheresis

C. Hydroxyurea + hydration

D. Allopurinol prophylaxis

Correct Answer: B. Leukapheresis

■ *Listen (English)*

■ *Listen (Hindi)*

Explanation: This patient with CML has symptomatic hyperleukocytosis (headache, visual symptoms, retinal vein engorgement). Leukostasis is a medical emergency; immediate cytoreduction is needed. Leukapheresis rapidly lowers WBC count and relieves symptoms, while hydroxyurea can be added for ongoing control. Imatinib (Option A) is for definitive therapy but should be started after stabilization. Hydroxyurea + hydration (Option C): Useful for cytoreduction but slower onset than leukapheresis. Allopurinol (Option D) is for tumor lysis prevention, not

acute management of leukostasis.

References:

Harrison's Principles of Internal Medicine, 22nd Edition, Page 838-839.

↑ *Back to this question in Part A*

@Neet_pg_bot

Q11: 70-year-old male presents with fatigue, unintentional weight loss, and recurrent respiratory infections over the last 6 months. Examination reveals pallor and mild splenomegaly. CBC shows: Hb: 9.8 g/dL TLC: 28,000/µL (Monocytes: 5,500/µL) Platelets: 110,000/µL Peripheral smear shows monocytosis with occasional myelocytes and metamyelocytes. Bone marrow aspirate is hypercellular with increased monocytes, <20% blasts, and dysplastic features in granulocytic and megakaryocytic lineages. Cytogenetic analysis is negative for the Philadelphia chromosome Diagnosis is? (Q850681)

A. CML

B. AML

C. CMML

D. JMML

Correct Answer: C. CMML

■ *Listen (English)*

■ *Listen (Hindi)*

Explanation: The patient shows persistent monocytosis (>1 × 10■/µL) , dysplasia in myeloid lineages, <20% blasts , and absence of Philadelphia chromosome , which are diagnostic for Chronic Myelomonocytic Leukemia (CMML) . Chronic Myeloid Leukemia (CML) (Option A): Typically shows Philadelphia chromosome positivity and basophilia rather than monocytosis. Acute Myeloid Leukemia (AML) (Option B): Requires ≥20% blasts, which is not present here. Juvenile Myelomonocytic Leukemia (JMML) (Option D): Occurs in children, not adults.

References:

Harrison's Principles of Internal Medicine, 22nd Edition, Page 877.

↑ *Back to this question in Part A*

@Neet_pg_bot

• [06_Hematology] 039 Acute Myeloid Leukemia

« Back to Folder Directory

[06_Hematology] 039 Acute Myeloid Leukemia — Quick Jump

Q1 (p. 2032) *Q2 (p. 2032)* *Q3 (p. 2033)* *Q4 (p. 2035)* *Q5 (p. 2035)* *Q6 (p. 2036)*
Q7 (p. 2036) *Q8 (p. 2037)* *Q9 (p. 2038)* *Q10 (p. 2038)*

Q1: Arsenic trioxide is used for treatment of which of the following malignancy? (Q850715)

A. Acute promyelocytic leukemia

B. Acute myelomonocytic leukemia

C. Acute monocytic leukemia

D. Acute megakaryocytic leukemia

Correct Answer: A. Acute promyelocytic leukemia

Explanation: All trans retinoic acid and arsenic trioxide are used for management of APL Mechanism of action of Arsenic trioxide Degradation of PML-RARA oncoprotein: It promotes ubiquitin-mediated proteasomal degradation of the abnormal PML-RARA fusion protein that blocks differentiation. Induction of apoptosis: ATO generates reactive oxygen species and mitochondrial damage, triggering programmed cell death of leukemic cells. Promotion of differentiation: Similar to ATRA, ATO helps leukemic promyelocytes mature into normal granulocytes.

References:

Harrison's Principles of Internal Medicine, 22nd Edition, Page 834.

↑ *Back to this question in Part A*

@Neet_pg_bot

Q2: 34-year-old female presented with progressive pallor and organomegaly. Work up shows low Hb, platelet count of 25000/mm3. raised PT and aPTT. Peripheral smear is given. Which of the following fusion gene is affected? (Q850689)

A. PML RARA

B. RUNX1 RUNX1T1

C. IGH NSD2

D. BCR ABL

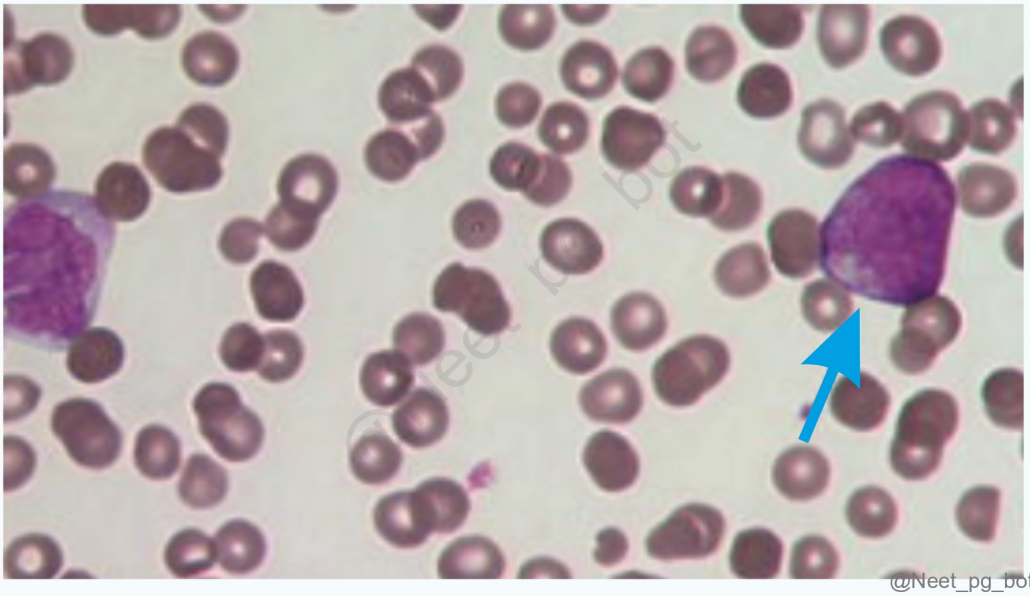

Correct Answer: A. PML RARA

Explanation: PML RARA Patient with features of blood cancer is having a low platelet count with elevated PT and aPTT. This implies DIC, which is seen in M3 AML. Acute promyelocytic leukemia has the PML-RARA rearrangement. RUNX1–RUNX1T1 (Option B) is associated with AML with t(8;21) (M2). IGH–NSD2 (Option C) is associated with Lymphoid malignancies (rare). BCR–ABL (Option D) is associated with CML or Ph+ ALL.

References:

Harrison's Principles of Internal Medicine, 22nd Edition, Page 826.

↑ *Back to this question in Part A*

@Neet_pg_bot

Q3: A 60-year-old man presents with recurrent episodes of bleeding from nose and progressive pallor. Peripheral smear shows the presence of cells shown below. Which of the following is the most common chromosomal abnormality seen in this condition? (Q850693)

A. t (8:21)

B. t (15:17)

C. t (14:18)

D. Inv (16)



Correct Answer: B. t (15:17)

Explanation:

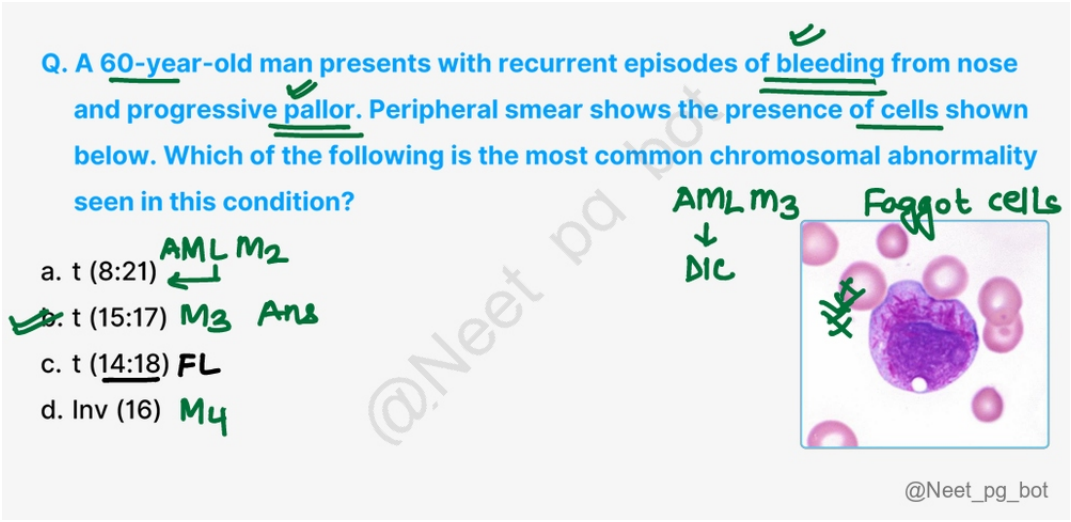

References:

Harrison's Principles of Internal Medicine, 22nd Edition, Page 828.

↑ *Back to this question in Part A*

@Neet_pg_bot

Q4: A 45-year-old male presents with fatigue, progressive pallor and recurrent nasal bleeds. Bone marrow aspiration shows 10% myeloblasts with abnormal eosinophils. Cytogenetic analysis reveals inv(16) (p13;q22). Which of the following is the most appropriate diagnosis? (Q850695)

A. Myelodysplastic syndrome

B. Acute myeloid leukemia

C. Chronic myelomonocytic leukemia

D. Chronic myeloid leukemia

Correct Answer: B. Acute myeloid leukemia

Explanation: The findings are diagnostic of Acute Myeloid Leukemia (AML) with inv(16)(p13q22) , also called AML with abnormal eosinophils Marrow blast count of ≥20% is required, except for AML with the recurrent genetic abnormalities t (15;17) t (8;21) inv (16) t (16;16)

References:

Harrison's Principles of Internal Medicine, 22nd Edition, Page 826.

↑ *Back to this question in Part A*

@Neet_pg_bot

Q5: A 60-year-old man presented with early satiety and abdominal pain. On examination grossly enlarged spleen and liver is palpable Work up shows low Hb with WBC-50000/mm3 and platelet count of 6 lac/cu.mm. Which of the following will cause this presentation? (Q850702)

A. t (9:22)

B. Del 1q

C. t (15:17)

D. Del 3q

Correct Answer: A. t (9:22)

Explanation: An enlarged spleen with high TLC is a feature of CML. The cause is the Philadelphia chromosome, which results from a balanced translocation between chromosomes 9 and 22, creating a BCR-ABL fusion gene that activates tyrosine kinase and leads to uncontrolled mitosis. CML in chronic phase has leucocytosis with thrombocytosis. Del 1q (Option B): seen in multiple myeloma t(15;17) (Option C): seen in acute promyelocytic leukemia (APL) Del 3q (Option D): associated with myelodysplastic syndrome/poor-risk AML.

References:

Harrison's Principles of Internal Medicine, 22nd Edition, Page 836-837.

↑ *Back to this question in Part A*

@Neet_pg_bot

Q6: Which of the following chromosomal aberrations occur in topoisomerase II inhibitor–associated acute myeloid leukemia? (Q850705)

A. t (15:17)

B. inv16

C. 11q23

D. t (8:21)

Correct Answer: C. 11q23

Explanation: Topoisomerase II inhibitor–associated leukemia occurs 1–3 years after exposure, and affected individuals often have AML with monocytic features and aberrations involving chromosome 11q23. t(15;17) (Option A): seen in acute promyelocytic leukemia. inv(16) (Option B): seen in AML with abnormal eosinophils (M4Eo). t(8;21) (Option D): seen in AML with maturation (M2).

References:

Harrison's Principles of Internal Medicine, 22nd Edition, Page 826.

↑ *Back to this question in Part A*

@Neet_pg_bot

Q7: Which type of AML shows extensive infiltration of skin, soft tissues, gingiva and meninges? (Q850710)

A. AML with maturation

B. Acute promyelocytic leukemia

C. Acute myelomonocytic leukemia

D. Acute monocytic leukemia

Correct Answer: D. Acute monocytic leukemia

Explanation: Infiltration of skin and soft tissues, known as chloroma, gingival hyperplasia, and CNS leukemia due to meningeal infiltration, is commonly seen with acute monocytic leukemia that has 11q23 abnormalities. AML with maturation (Option A) presents with marrow blasts and Auer rods, not tissue infiltration. Acute promyelocytic leukemia (Option B) presents with DIC due to t(15;17). Acute myelomonocytic leukemia (Option C) may show some tissue involvement, but less extensive than monocytic type.

References:

Harrison's Principles of Internal Medicine, 22nd Edition, Page 828.

↑ *Back to this question in Part A*

@Neet_pg_bot

Q8: Which of the following genetic mutations is not responsible for AML (Q850711)

A. NPM1

B. FLT3-ITD

C. CEBPA

D. NOTCH1

Correct Answer: D. NOTCH1

Explanation: NOTCH1 mutations are primarily associated with T-cell acute lymphoblastic leukemia (T-ALL) and are not involved in AML pathogenesis. NPM1, FLT3-ITD, and CEBPA (Options A, B, C) mutations are commonly seen in AML and influence prognosis and treatment.

References:

Harrison's Principles of Internal Medicine, 22nd Edition, Page 812, 827.

↑ *Back to this question in Part A*

@Neet_pg_bot

Q9: A 28-year-old female with acute promyelocytic leukemia is started on ATRA therapy. After 10 days, she develops fever, dyspnea, weight gain, and pulmonary infiltrates on chest X-ray. Which of the following is the most appropriate treatment for this complication? (Q850719)

A. Discontinue ATRA permanently

B. Initiate high-dose corticosteroids

C. Start broad-spectrum antibiotics

D. Urgent leukapheresis

Correct Answer: B. Initiate high-dose corticosteroids

Explanation: The patient has developed Differentiation Syndrome , a potentially life-threatening complication caused by rapid differentiation and cytokine release by malignant cells. The syndrome is related to adhesion of differentiated neoplastic cells to the pulmonary vasculature endothelium. Symptoms include fever, respiratory distress, weight gain, pleural/pericardial effusions, and pulmonary infiltrates. Early corticosteroid therapy with dexamethasone is the cornerstone of treatment and can be continued along with ATRA.

References:

Harrison's Principles of Internal Medicine, 22nd Edition, Page 834.

↑ *Back to this question in Part A*

@Neet_pg_bot

Q10: Which of the following clinical features is/are seen in patient with AML Gum hypertrophy Skin infiltration Lower extremity weakness Papilledema (Q850725)

A. 1,2

B. 1,2,3

C. 1,3,4

D. 1,2,3,4

Correct Answer: D. 1,2,3,4

Explanation: Gum hypertrophy (leukemic infiltration, most common in monocytic leukemia) Skin infiltration or nodules (leukemia infiltration, most common in monocytic leukemia) Back pain, lower extremity weakness (spinal granulocytic sarcoma, most likely in t(8:21) patients) Papilledema is explained by CNS leukemia

References:

Harrison's Principles of Internal Medicine, 22nd Edition, Page 828.

↑ *Back to this question in Part A*

@Neet_pg_bot

• [06_Hematology] 040 Acute Lymphocytic Leukemia

« Back to Folder Directory

[06_Hematology] 040 Acute Lymphocytic Leukemia — Quick Jump

Q1 (p. 2040) *Q2 (p. 2041)* *Q3 (p. 2042)* *Q4 (p. 2042)* *Q5 (p. 2043)* *Q6 (p. 2044)*
Q7 (p. 2044) *Q8 (p. 2045)* *Q9 (p. 2045)*

Q1: Adult T cell leukemia is caused by which of the following viruses? (Q850770)

A. HTLV-1

B. EBV

C. HPV

D. Polyoma virus

Correct Answer: A. HTLV-1

Explanation: Adult T-cell leukemia/lymphoma (ATLL) is a malignancy of mature CD4■ T-cells that arises due to chronic infection with Human T-cell Lymphotropic Virus type 1 (HTLV-1) . EBV (Option B): Burkitt lymphoma, Hodgkin lymphoma, nasopharyngeal carcinoma HPV (Option C): Cervical and anogenital cancers Polyoma virus (Option D): JC virus (PML), BK virus (nephropathy in transplants)

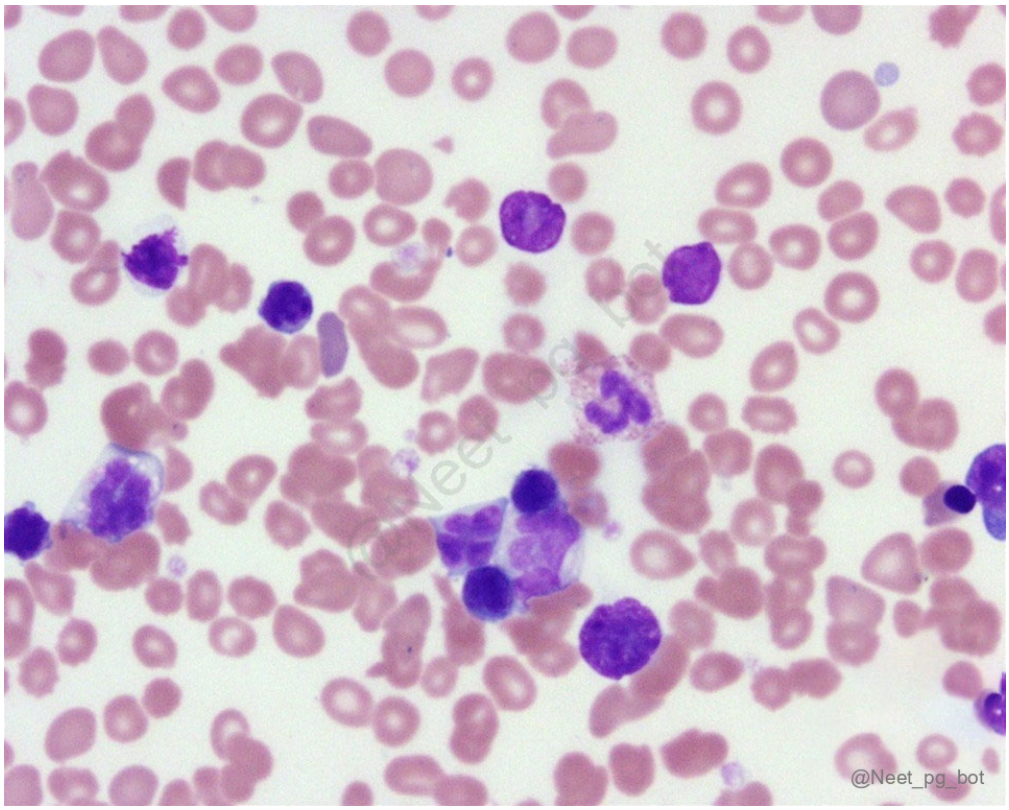

References:

Harrison's Principles of Internal Medicine, 22nd Edition, Page 844.

↑ *Back to this question in Part A*

@Neet_pg_bot

Q2: Which of the following is not correct about CNS leukemia? (Q850771)

A. LP is restricted to patients with platelet count less than 20K /cu mm

B. Intrathecal methotrexate to be given after performing lumbar puncture

C. LP is routine diagnostic test during work up of patient of ALL

D. Cell count > 5 cells/uL or leukemic blast cells on morphology is diagnostic

Correct Answer: A. LP is restricted to patients with platelet count less than 20K /cu mm

Explanation: LP is contraindicated if platelet count is <20,000/µL due to bleeding risk. Intrathecal methotrexate is given after lumbar puncture (Option B): Intrathecal methotrexate is part of CNS prophylaxis/therapy LP is a routine diagnostic test in ALL to assess CNS involvement (Option C) . CNS leukemia is diagnosed when CSF shows >5 cells/µL or leukemic blasts (Option D): Either of these in CSF confirms CNS leukemia.

References:

Harrison's Principles of Internal Medicine, 22nd Edition, Page 844.

↑ *Back to this question in Part A*

@Neet_pg_bot

Q3: A 10-year-old patient presents with fatigue and bleeding. Peripheral blood shows anaemia, thrombocytopenia and neutropenia. Bone marrow flow cytometry shows blasts positive for both CD19, CD79a , CD13, CD33, along with cytoplasmic myeloperoxidase. Which of the following is the most likely diagnosis? (Q850772)

A. B cell ALL

B. T cell ALL

C. Biphenotypic ALL

D. AML

Correct Answer: C. Biphenotypic ALL

Explanation: The blasts express both B-lymphoid markers : CD19, CD79a and myeloid markers : CD13, CD33, and cytoplasmic MPO Co-expression of lymphoid + myeloid lineage markers on the same population of blasts fulfills WHO criteria for Mixed Phenotype Acute Leukemia (MPAL), formerly called Biphenotypic ALL . B-cell ALL (Option A) expresses CD19, CD79a but lacks myeloid markers. T-cell ALL (Option B) shows T-cell markers (CD3, CD7) not seen here. AML (Option D) shows only myeloid markers without lymphoid markers.

References:

Harrison's Principles of Internal Medicine, 22nd Edition, Page 845

↑ *Back to this question in Part A*

@Neet_pg_bot

Q4: Which of the following is correct about complete molecular response in patients with ALL? (Q850773)

A. Patient in remission, MRD not detectable, < 1 leukemia cell in 1,000 BM cells

B. Patient in remission, MRD not detectable, < 1 leukemia cell in 10,000 BM cells

C. Patient in remission, MRD not detectable, < 1 leukemia cell in 100,000 BM cells

D. Patient in remission, MRD not detectable, < 1 leukemia cell in 100,0000 BM cells

Correct Answer: B. Patient in remission, MRD not detectable, < 1 leukemia cell in 10,000 BM cells

Explanation: Complete molecular response in ALL means the patient is in remission with no detectable MRD , corresponding to a sensitivity of <1 leukemic cell in 10,000 bone marrow cells . Response Parameters According to Minimal Residual Disease (MRD) Complete hematologic remission (CHR) Leukemic cells not detectable by light microscopy (<5% blast cells in bone marrow [BM]) Complete molecular remission/MRD negativity Patient in complete remission, MRD not detectable, ≤0.01% = <1 leukemia cell in 10,000 BM cells

References:

Harrison's Principles of Internal Medicine, 22nd Edition, Page 846.

↑ *Back to this question in Part A*

@Neet_pg_bot

Q5: Which of the following types of ALL is associated with the Philadelphia chromosome? (Q850775)

A. Common ALL

B. Mature B cell ALL

C. T cell ALL

D. Pro B- ALL

Correct Answer: A. Common ALL

Explanation: The Philadelphia chromosome [t(9;22), BCR-ABL fusion] is most commonly associated with Common ALL (CD10 positive B-ALL) , especially in adults. SUBTYPES INCIDENCE FREQUENT CYTOGENETIC ABERRATIONS B-lineage ALL (B-ALL) 76% Pro B-ALL (Option D) 12% t(4;11) Common ALL 49% t(9;22) Pre-B-ALL 11% t(9;22) t(1;19) Mature B-ALL (Option B) 4% t(8;14) t(2;8) t(8;22) T-lineage ALL (T-ALL) (Option C) 24% t(10;14) t(11;14)

References:

Harrison's Principles of Internal Medicine, 22nd Edition, Page 845.

↑ *Back to this question in Part A*

@Neet_pg_bot

Q6: What drugs are used in pre-phase therapy for a patient with Acute lymphoblastic leukemia? (Q850777)

A. Rasburicase

B. Allopurinol

C. Dexamethasone plus vincristine

D. Dexamethasone plus methotrexate

Correct Answer: C. Dexamethasone plus vincristine

Explanation: Pre-phase therapy in ALL consists of giving steroids with vincristine or cyclophosphamide for 5-7 days. The advantages are Avoid tumor lysis syndrome Give time to institute support therapy like PRBC, platelets and treat infections Lead time for reports of cytogenetics and molecular genetics to come in Rasburicase (Option A) is used to treat or prevent tumor lysis syndrome, not as cytoreductive pre-phase therapy. Allopurinol (Option B) is used to prevent uric acid accumulation but not as pre-phase chemotherapy. Dexamethasone plus methotrexate (Option D) is part of induction/consolidation, not pre-phase therapy.

References:

Harrison's Principles of Internal Medicine, 22nd Edition, Page 847.

↑ *Back to this question in Part A*

@Neet_pg_bot

Q7: A 12-year-old boy with relapsed B-cell ALL is planned for therapy with CAR-T cells. In this context, CAR stands for which of the following? (Q850783)

A. Chimeric Antigen Receptor

B. Chimeric Antibody Receptor

C. Clustered Antigen Receptor

D. Chimeric Antigen Recognition

Correct Answer: A. Chimeric Antigen Receptor

Explanation: CAR-T cells are genetically engineered T lymphocytes that express Chimeric Antigen Receptors, enabling them to specifically recognize and kill tumor cells, most often targeting CD19 in B-cell ALL.

References:

Harrison's Principles of Internal Medicine, 22nd Edition, Page 847.

↑ *Back to this question in Part A*

@Neet_pg_bot

Q8: Which of the following is an anti CD-19 targeting antibody used in acute lymphoblastic leukemia? (Q850788)

A. Blinatumomab

B. Rituximab

C. Ruxolitinib

D. Dasatinib

Correct Answer: A. Blinatumomab

Explanation: Blinatumomab is a bispecific T-cell engager (BiTE) antibody that binds CD19 on B-cells and CD3 on T-cells, redirecting T-cells to kill B-cell blasts in B-ALL . Rituximab (Option B) is an anti-CD20 monoclonal antibody (used in B-cell NHL, CLL). Ruxolitinib (Option C) is a JAK1/JAK2 inhibitor (used in myelofibrosis, polycythemia vera, Ph-like ALL with JAK mutations). Dasatinib (Option D) is a TKI targeting BCR-ABL (used in CML, Ph+ ALL).

References:

Harrison's Principles of Internal Medicine, 22nd Edition, Page 849.

↑ *Back to this question in Part A*

@Neet_pg_bot

Q9: The most common benign tumor in children is? (Q850791)

A. Hemangioma

B. Acute lymphoblastic lymphoma

C. Cerebellar astrocytoma

D. Medulloblastoma

Correct Answer: A. Hemangioma

Explanation: Hemangioma is the most common benign tumor of childhood , usually presenting as a red/blue skin lesion that often regresses spontaneously. Acute lymphoblastic lymphoma (Option B) is malignant, not benign. Cerebellar astrocytoma (Option C) is a common benign brain tumor , but it is less common overall than hemangioma. Medulloblastoma (Option D) is a malignant pediatric brain tumor .

References:

Robbin and Cotran's Pathologic Basis of Diseases, 10th Edition, Page 476.

↑ *Back to this question in Part A*

@Neet_pg_bot

• [06_Hematology] 041 Multiple Myeloma Plasma Cell Disorders

« Back to Folder Directory

[06_Hematology] 041 Multiple Myeloma Plasma Cell Disorders — Quick Jump

Q1 (p. 2047) *Q2 (p. 2047)* *Q3 (p. 2048)* *Q4 (p. 2049)* *Q5 (p. 2051)* *Q6 (p. 2051)*
Q7 (p. 2052) *Q8 (p. 2052)* *Q9 (p. 2053)* *Q10 (p. 2054)* *Q11 (p. 2054)* *Q12 (p. 2055)*

Q1: Which of the following is not a biomarker of malignancy in patient with symptomatic multiple myeloma (Q850793)

A. M protein on urinary or serum electrophoresis

B. Involved: uninvolved free light chain ratio > 100

C. > 1 focal lesion on MRI studies

D. Clonal bone marrow plasma cell percentage > 60%

Correct Answer: A. M protein on urinary or serum electrophoresis

Explanation: Any one or more of the following biomarkers of malignancy: Clonal bone marrow plasma cell percentage ≥ 60% Involved: uninvolved serum free light chain ratio ≥ 100 > 1 focal lesion on MRI studies M protein in serum/urine is part of the diagnosis but, not by itself a biomarker of malignancy unless CRAB criteria (hyper C alcemia, R enal failure, A nemia, B one lesions) or the above biomarkers are present.

References:

Harrison's Principles of Internal Medicine, 22nd Edition, Page 887-888.

↑ *Back to this question in Part A*

@Neet_pg_bot

Q2: A 72-year-old man presents with 3 months of low back pain, fatigue, and weight loss. Examination shows pallor and mild splenomegaly. Investigations reveal: Hemoglobin: 8.5 g/dL Serum calcium: 12.2 mg/dL Creatinine: 2.3 mg/dL Serum protein electrophoresis: M-spike in γ-region MRI spine: Multiple lytic lesions Peripheral smear: 25% plasma cells What is the most likely diagnosis? (Q850797)

A. Multiple myeloma

B. Monoclonal gammopathy of undetermined significance (MGUS)

C. Smoldering multiple myeloma

D. Primary plasma cell leukemia

Correct Answer: D. Primary plasma cell leukemia

Explanation: Primary plasma cell leukemia (PCL) is diagnosed when: ≥20% plasma cells in peripheral blood. This patient has 25% → diagnostic. He also has CRAB features (hypercalcemia, renal failure, anemia, bone lesions), but the high circulating plasma cell count is the defining feature distinguishing PCL from multiple myeloma. Multiple myeloma (Option A): requires ≥10% clonal plasma cells in bone marrow + CRAB/biomarkers, but here the defining feature is peripheral blood plasma cells ≥20% → plasma cell leukemia. MGUS (Option B): has <10% plasma cells and no CRAB features. Smoldering multiple myeloma (Option C): has ≥10% plasma cells or M-protein ≥3 g/dL but no CRAB features .

References:

Harrison's Principles of Internal Medicine, 22nd Edition, Page 887-888.

↑ *Back to this question in Part A*

@Neet_pg_bot

Q3: You calculated eGFR of multiple myeloma on a follow up visit as 20 ml/min. Which of the following is the leading cause of this presentation? (Q850800)

A. Amyloidosis

B. Hypercalcemia

C. Pyelonephritis

D. Tubular damage by bence jones proteins

Correct Answer: B. Hypercalcemia

Explanation: Hypercalcemia is the leading cause of renal failure in patients with multiple myeloma, and the rest are contributory factors Amyloidosis (Option A) causes proteinuria and nephrotic syndrome, not the most common GFR decline. Pyelonephritis (Option C) is not related to MM pathology. Tubular damage by Bence Jones proteins (Option D) is the main cause of acute renal failure, but not the leading cause of chronic low eGFR.

References:

Harrison's Principles of Internal Medicine, 22nd Edition, Page 888.

↑ *Back to this question in Part A*

Q4: Comment on agarose gel electrophoresis and immunofixation reports? (Q850801)

A. Monoclonal Ig A kappa

B. Monoclonal Ig G kappa

C. Monoclonal Ig G kappa lambda

D. Polyclonal

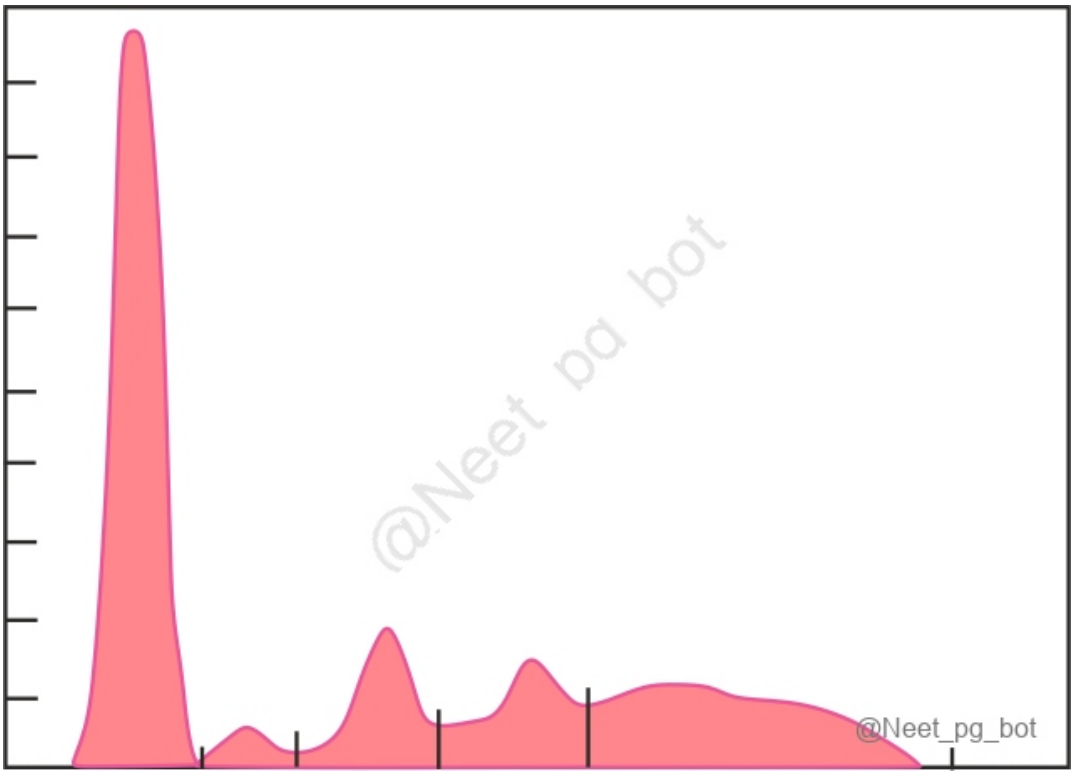

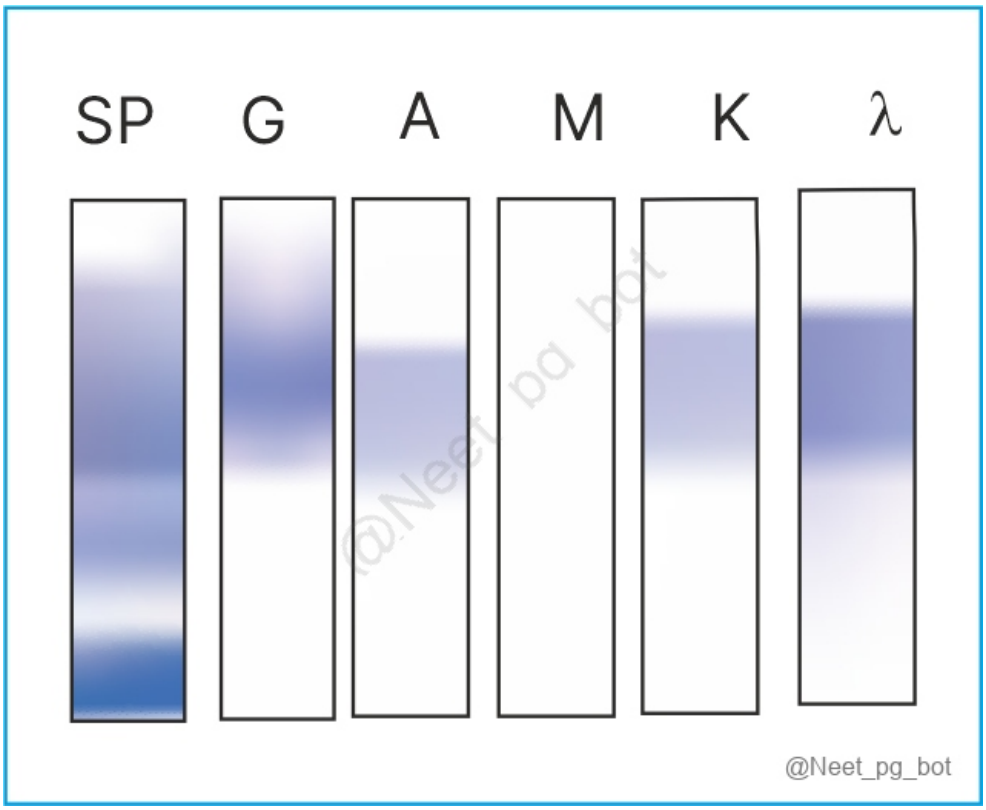

Correct Answer: D. Polyclonal

Explanation:

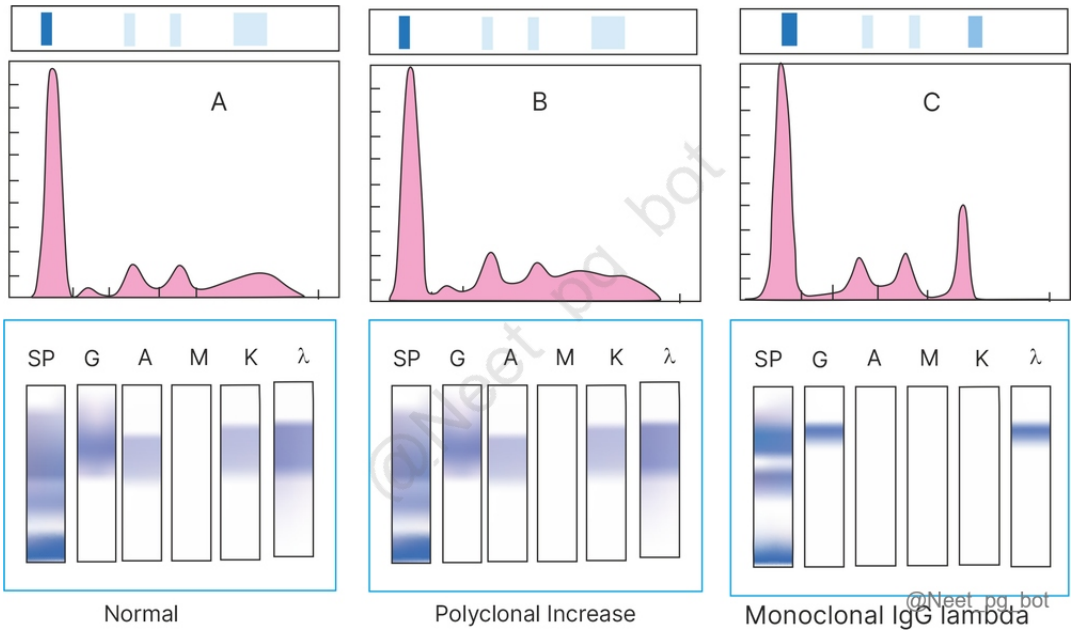

References:

Harrison's Principles of Internal Medicine, 22nd Edition, Page 885.

↑ *Back to this question in Part A*

@Neet_pg_bot

Q5: Which of the following is incorrect about histopathological findings in multiple myeloma? (Q850802)

A. Clock face chromatin

B. Intracytoplasmic Dutcher bodies

C. Mott cells

D. Eccentric nucleus with basophilic cytoplasm

Correct Answer: B. Intracytoplasmic Dutcher bodies

Explanation: Dutcher bodies are intranuclear, and Russell bodies are intracytoplasmic aggregates of light chains in plasma cells. Clock face chromatin (Option A) and eccentric nucleus with basophilic cytoplasm (Option D) are characteristic of plasma cells. Mott cells (Option C) are plasma cells characterised by the presence of multiple Russell bodies.

References:

Harrison's Principles of Internal Medicine, 22nd Edition, Page 885.

↑ *Back to this question in Part A*

@Neet_pg_bot

Q6: Earliest manifestation of tubular damage in multiple myeloma due to bence jones proteins causes? (Q850803)

A. Glucosuria and aminoaciduria

B. Hematuria

C. Proteinuria

D. Metabolic alkalosis

Correct Answer: A. Glucosuria and aminoaciduria

Explanation: The earliest manifestation of this tubular damage is the adult Fanconi's syndrome (a type 2 proximal renal tubular acidosis), with loss of glucose and amino acids, as well as defects in the ability of the kidney to acidify and concentrate the urine. Hematuria (Option B) is not typical of Bence Jones–related injury. Proteinuria (Option C) does occur, but it is not the earliest tubular manifestation (it's due to overflow proteinuria). Metabolic alkalosis (Option D) is not associated; Fanconi syndrome causes metabolic acidosis .

References:

Harrison's Principles of Internal Medicine, 22nd Edition, Page 886-887.

↑ *Back to this question in Part A*

@Neet_pg_bot

Q7: Which of the following is not correct about multiple myeloma? (Q850804)

A. Increased anion gap

B. Pseudohyponatremia

C. Hyperviscosity

D. Reduced creatinine clearance

Correct Answer: A. Increased anion gap

Explanation: Multiple myeloma causes excess positively charged monoclonal immunoglobulins (especially IgG). The kidney, to maintain electroneutrality, will increase the reabsorption of negatively charged anions like chloride and bicarbonate, leading to a reduced gap. Pseudohyponatremia (Option B) occurs due to high protein content interfering with sodium measurement in certain lab methods. Hyperviscosity (Option C) occurs due to increased production of light chains of antibodies. Reduced creatinine clearance (Option D) occurs due to myeloma kidney developing from light chain cast nephropathy and hypercalcemia-related renal injury.

References:

Harrison's Principles of Internal Medicine, 22nd Edition, Page 887

↑ *Back to this question in Part A*

@Neet_pg_bot

Q8: A 70-year-old male presents with progressive fatigue, recurrent headaches, blurred vision, and episodes of epistaxis for the past 2 months. On examination, there is pallor and mild hepatosplenomegaly. Labs are shown below. What is the most likely

diagnosis? Hb: 8.5 g/dL Serum protein electrophoresis: M spike in the β–γ region Immunofixation: IgM monoclonal protein Bone marrow: infiltration with small lymphocytes and plasma cells (Q850807)

A. Multiple myeloma

B. Chronic lymphocytic leukemia

C. Waldenström macroglobulinemia

D. Monoclonal gammopathy of undetermined significance

Correct Answer: C. Waldenström macroglobulinemia

Explanation: Waldenström macroglobulinemia: IgM monoclonal spike, which is a hallmark of WM and causes hyperviscosity syndrome (headache, blurred vision, epistaxis, retinal changes) Bone marrow: lymphoplasmacytic infiltration. Splenomegaly is common in WM but rare in classic multiple myeloma. Multiple myeloma (Option A): Incorrect because it typically involves an M protein that is IgG or IgA, not IgM. Chronic lymphocytic leukemia (Option B): Incorrect, as it typically doesn't present with an IgM M spike or hyperviscosity syndrome. Monoclonal gammopathy of undetermined significance (Option D): Incorrect, as it is a common condition with an M spike but lacks the clinical symptoms and organ damage seen in this patient.

References:

Harrison's Principles of Internal Medicine, 22nd Edition, Page 893.

↑ *Back to this question in Part A*

@Neet_pg_bot

Q9: A 70-year-old man presents with pallor and a low back ache. MRI spine shows lytic lesions in L5 and S1. In his past medical history, he had pneumonia last winter. Workup shows Hb 7 gm/dl, deranged RFT and serum calcium 11.2 mg/dl. Which of the following investigations is the next best test for the suspected diagnosis of this patient? (Q850808)

A. Serum electrophoresis

B. Peripheral blood flow cytometry

C. Serum free light chain assay

D. Bone marrow biopsy

Correct Answer: A. Serum electrophoresis

Explanation: This patient has classical features suggestive of multiple myeloma (pallor, anemia, renal dysfunction, hypercalcemia, lytic bone lesions, history of recurrent infection). The next best test to confirm monoclonal protein is serum protein electrophoresis (SPEP) , which demonstrates an M-spike . Peripheral blood flow cytometry (Option B) is useful in leukemias/lymphomas, not first-line for suspected myeloma. Serum free light chain assay (Option C) is complementary for non-secretory or light-chain myeloma, but SPEP is the standard first test. Bone marrow biopsy (Option D) is confirmatory after demonstrating M-protein, not the initial test. It is invasive and painful , requiring local anesthesia. Should be done only after evidence of monoclonality.

References:

Harrison's Principles of Internal Medicine, 22nd Edition, Page 885, 2379.

↑ *Back to this question in Part A*

@Neet_pg_bot

Q10: Which of the following is correct about multiple myeloma? 1. Decreased anion gap 2. Glucosuria and aminoaciduria 3. Hypoviscosity 4. Increased creatinine clearance (Q850809)

A. 1,2

B. 1,4

C. 1,2,3

D. 1,2,4

Correct Answer: A. 1,2

Explanation: Paraproteins are positively charged proteins rising in the blood. Hence, to maintain electroneutrality, negatively charged ions are increased by upgrading the reabsorption via tubules. This will cause a mathematical reduction in the anion gap value (statement 1). Damage to PCT causes Fanconi syndrome, leading to glucosuria and aminoaciduria (Statement 2). Increased antibody light chain production causes hyperviscosity and not hypoviscosity (Statement 3) . The damage to the kidney will cause reduced creatinine clearance (Statement 4) .

References:

Harrison's Principles of Internal Medicine, 22nd Edition, Page 887-888.

↑ *Back to this question in Part A*

@Neet_pg_bot

Q11: A 70 year old man recently diagnosed with multiple myeloma has been declared non eligible for transplantation due to poor cardiovascular health. Which of the following drug combinations is used for management of this patient? (Q850810)

A. Lenalidomide + dexamethasone + Bortezomib + daratumumab

B. Rituximab + cyclophosphamide + Vincristine

C. Adriamycin + bleomycin+ Vinblastine

D. Fludarabine + cyclophosphamide+ Rituximab + daratumumab

Correct Answer: A. Lenalidomide + dexamethasone + Bortezomib + daratumumab

Explanation: In transplant-ineligible multiple myeloma patients, Lenalidomide + Dexamethasone + Bortezomib + Daratumumab is an accepted regimen. Daratumumab is an anti-CD38 antibody that has helped upgrade the response to the conventional three drugs already used. Autologous bone marrow transplantation can be done in eligible patients with good CV status. Rituximab + cyclophosphamide + vincristine (Option B) is used in Non-Hodgkin's lymphoma (e.g., R-CVP). Adriamycin + bleomycin + vinblastine (Option C): ABVD regimen for Hodgkin lymphoma. Fludarabine + cyclophosphamide + rituximab + daratumumab (Option D) is not a standard regimen for multiple myeloma.

References:

Harrison's Principles of Internal Medicine, 22nd Edition, Page 891.

↑ *Back to this question in Part A*

@Neet_pg_bot

Q12: A 60-year-old female presents with weakness, back pain and repeated infections. Work up shows M spike on serum electrophoresis. Bone marrow biopsy shows 15% plasma cells. The prognosis of this patient is best determined by which of the following? (Q850811)

A. Ig G and albumin

B. Hb and albumin

C. Albumin and LDH

D. Albumin and beta 2 Micro-globulin

Correct Answer: D. Albumin and beta 2 Micro-globulin

Explanation: Prognosis in multiple myeloma is best determined using the International Staging System (ISS) , which relies on serum albumin and beta-2 microglobulin levels to stratify patients into stages I–III. International staging system (ISS) Stage Median Survival Months β2M<3.5, alb ≥3.5 I 62 β2M <3.5, alb <3.5 or β2 = 3.5 -5.5 II 44 β2 >5.5 III 29 Revised International Staging System (R- ISS) Stage I: ISS stage 1: standard risk for CA and normal LDH Stage II: Patients not meeting criteria for stage I or stage III Stage III: ISS stage III and either high risk for CA or high LDH

References:

Harrison's Principles of Internal Medicine, 22nd Edition, Page 889.

↑ *Back to this question in Part A*

@Neet_pg_bot

• [06_Hematology] 042 Hodgkin S And Non-Hodgkin S Lymphoma

« Back to Folder Directory

[06_Hematology] 042 Hodgkin S And Non-Hodgkin S Lymphoma — Quick Jump

Q1 (p. 2057)	*Q2 (p. 2057)*	*Q3 (p. 2058)*	*Q4 (p. 2062)*	*Q5 (p. 2062)*	*Q6 (p. 2065)*
Q7 (p. 2068)	*Q8 (p. 2068)*	*Q9 (p. 2069)*	*Q10 (p. 2069)*	*Q11 (p. 2070)*	*Q12 (p. 2070)*
Q13 (p. 2072)	*Q14 (p. 2072)*	*Q15 (p. 2073)*	*Q16 (p. 2074)*	*Q17 (p. 2074)*	*Q18 (p. 2075)*

Q1: Which of the following neoplasms has the highest incidence of causing tumor lysis syndrome (Q851117)

A. Burkitt lymphoma

B. DLBCL

C. AML

D. ALL

Correct Answer: A. Burkitt lymphoma

Explanation: Burkitt lymphoma has one of the fastest proliferation rates of any human tumor (doubling time <24 hours ; Ki-67 approaching 100%). On starting chemotherapy, the rapid cell death causes massive release of potassium, phosphate, uric acid causing acute kidney injury, arrhythmias, seizures (tumor lysis syndrome)

References:

Harrison's Principles of Internal Medicine, 22nd Edition, Page 862.

↑ *Back to this question in Part A*

@Neet_pg_bot

Q2: Lumbar puncture and CSF cytology is part of diagnostic workup of all except? (Q851127)

A. ALL

B. AML

C. NHL

D. HL

Correct Answer: D. HL

Explanation: CSF cytology is used to detect malignant cells in the cerebrospinal fluid, mainly in malignancies with a high risk of leptomeningeal spread. Common indications: NHL especially high-grade types like Burkitt, lymphoblastic, DLBCL ALL (routine in initial staging because CNS involvement is common) AML (in specific subtypes or when neurologic signs are present, e.g., monocytic variants)

References:

Harrison's Principles of Internal Medicine, 22nd Edition, Page 869.

www.pathologyoutlines.com/topic/cytopathologycerebrospinalfluid.html

↑ *Back to this question in Part A*

@Neet_pg_bot

Q3: A 72-year-old man presents with progressive abdominal distension and early satiety for 3 months. USG shows multiple enlarged para-aortic lymph nodes. CT abdomen confirms bulky retroperitoneal lymphadenopathy. Excisional biopsy of a lymph node was done and is shown below. Immunohistochemistry is positive for CD10, CD19, CD20, and BCL6. Which of the following is the most likely diagnosis? (Q851124)

A. Burkitt lymphoma

B. DLBCL

C. Follicular lymphoma

D. Mycosis fungoides

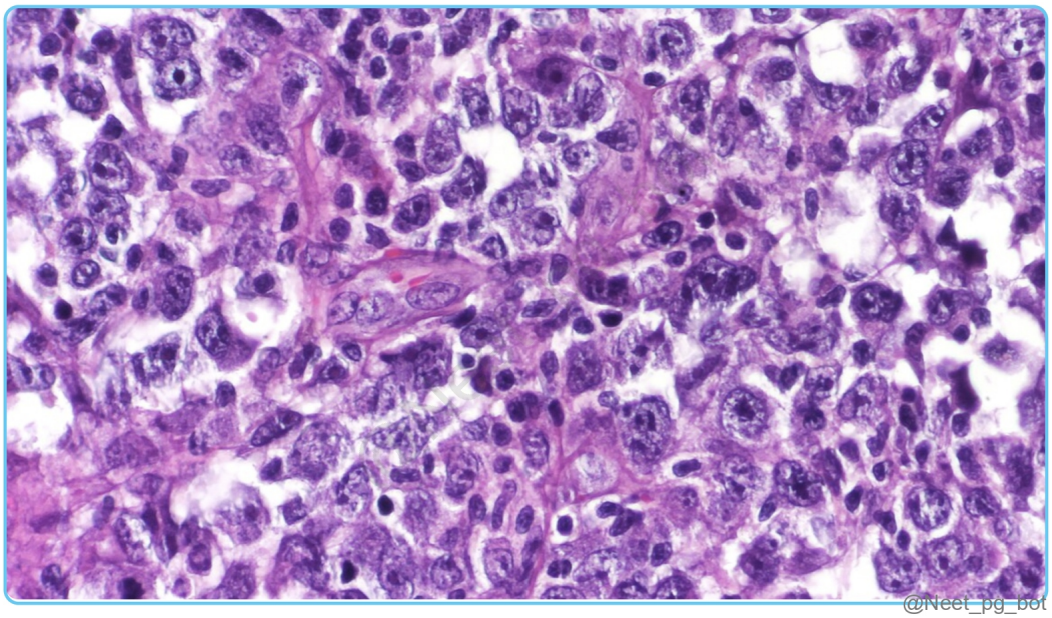

Correct Answer: B. DLBCL

Explanation: Slide shows diffuse effacement of architecture by “large atypical lymphoid cells with vesicular nuclei, prominent nucleoli, and abundant cytoplasm”. The patient is an elderly man with abdominal lymphadenopathy. These cells are expressing B-cell antigens CD19, CD20. Expression of CD10 and BCL6 is consistent with the tumor cell being of germinal center origin. Diagnosis is DLBCL Burkitt lymphoma (Option A): Morphology: Medium-sized, uniform cells with high mitotic rate. Numerous tingible-body macrophages creating the classic "starry sky" appearance. Pattern: Diffuse, but very cohesive. Key Markers: CD10+, CD19+, CD20+, BCL6+ , BCL2 (-) , MYC translocation [t(8;14)] , Ki-67 >95% (very high proliferation). Clinical: Extremely aggressive; often presents as a jaw mass (Endemic) or abdominal mass (Sporadic) Follicular lymphoma (Option C) has centroblasts in a nodular growth pattern and indolent course. Morphology: Mix of small cleaved cells (centrocytes) and larger non-cleaved cells (centroblasts). Pattern: Nodular/Follicular (mimics germinal centers but lacks a mantle zone and lacks polarity). Key Markers: CD10+, CD19+, CD20+, BCL2+ (distinguishes it from reactive follicles), t(14;18) . Clinical: Indolent (slow-growing), painless generalized lymphadenopathy in older adults. Mycosis fungoides (Option D) has cutaneous involvement. Morphology: Small to medium T-cells with cerebriform nuclei . Key Markers: CD3+ , CD4+ , CD8(-), CD20(-). Pathology: Pautrier microabscesses (clusters of malignant T-cells in the epidermis). Clinical: Skin patches, plaques, or tumors.

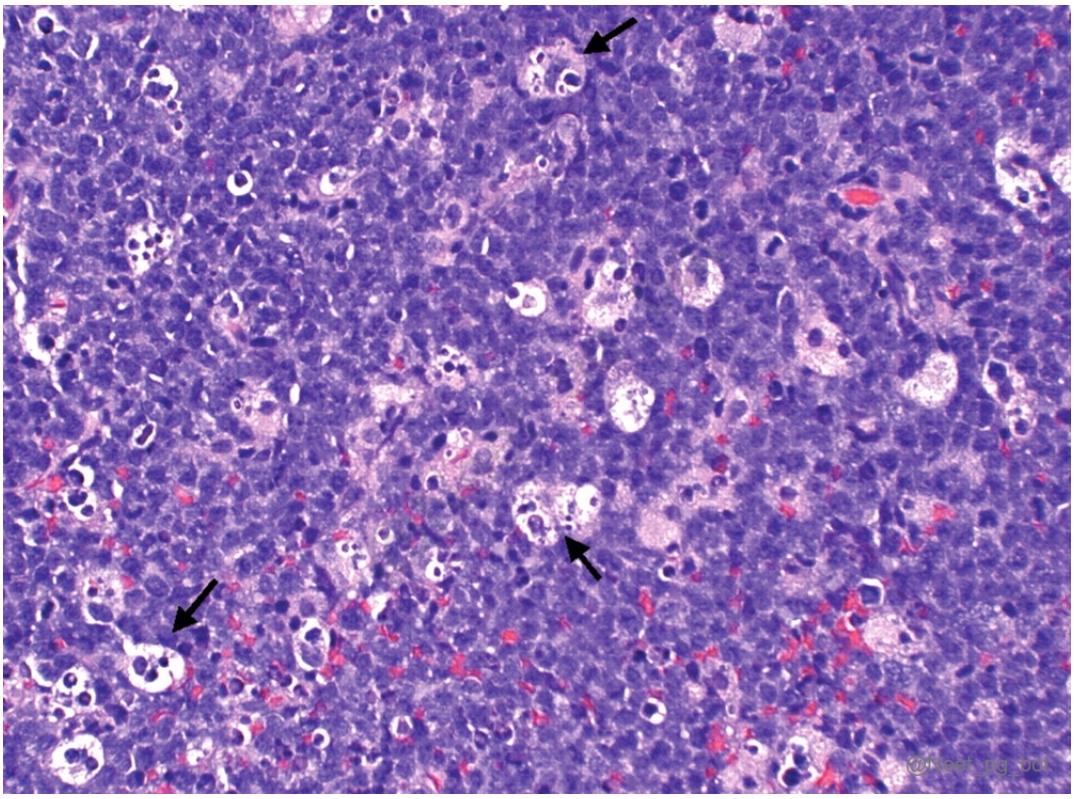

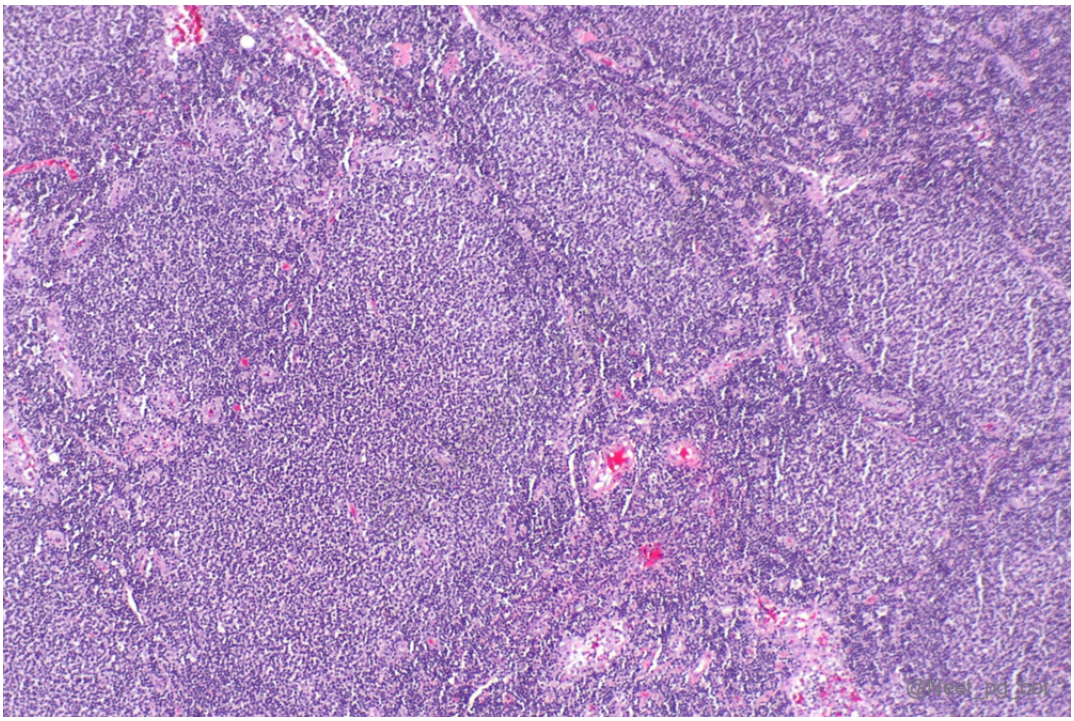

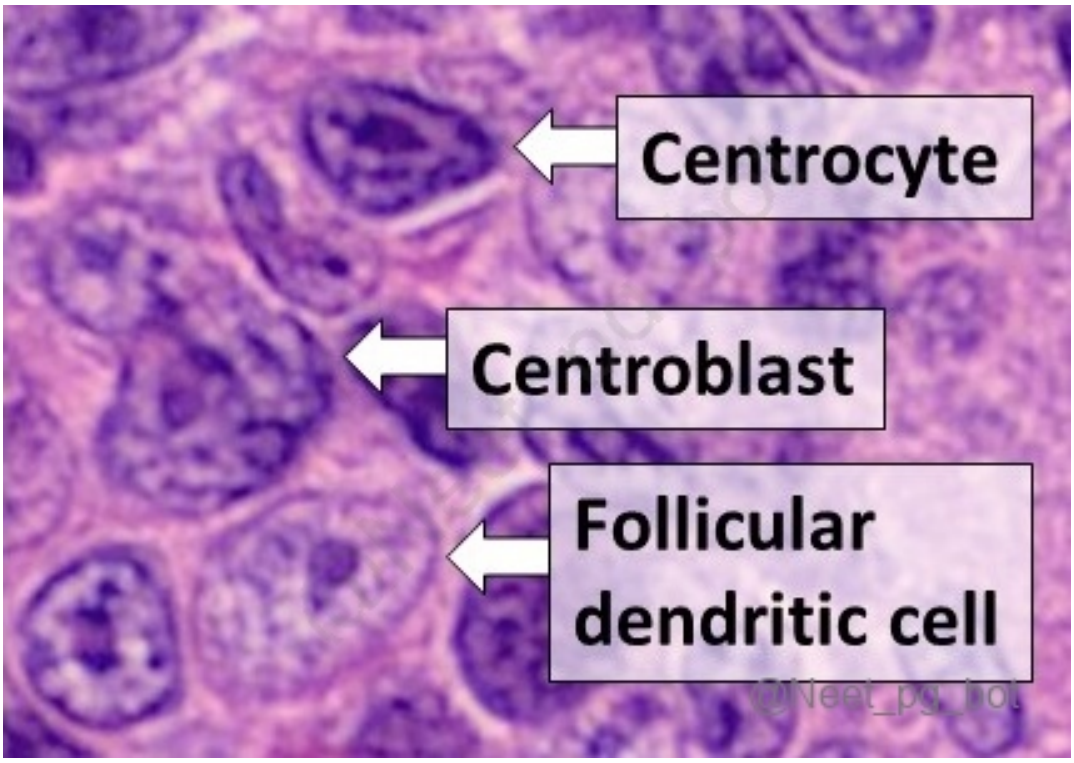

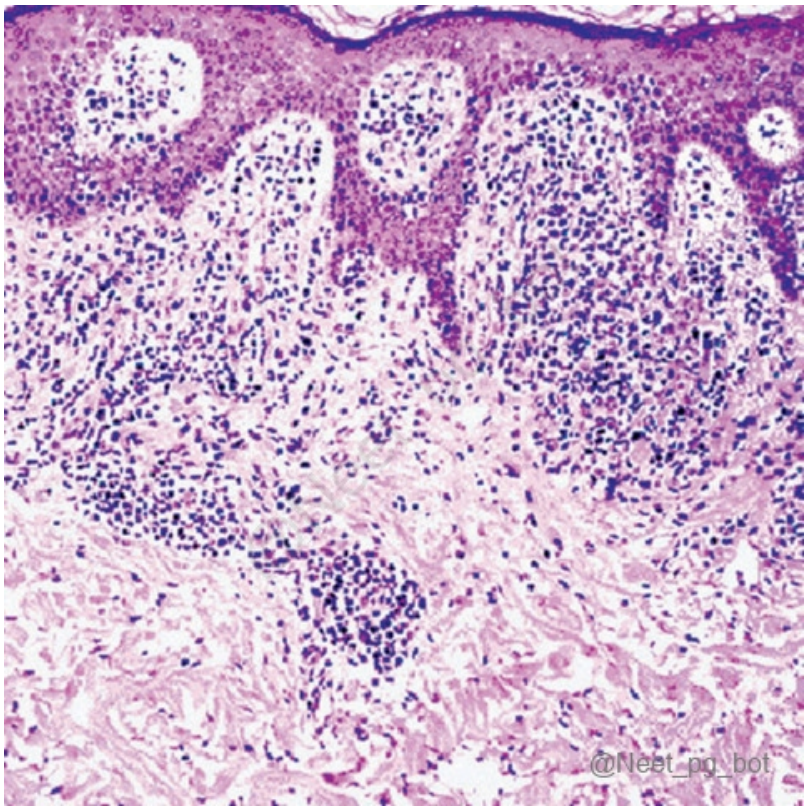

References:

Harrison's Principles of Internal Medicine, 22nd Edition, Page 862-863.

↑ *Back to this question in Part A*

@Neet_pg_bot

Q4: Which of the following is the most common type of Non-Hodgkin lymphoma (NHL)? (Q851123)

A. Nodular sclerosis

B. Mixed cellularity

C. Nodular lymphocytic predominant

D. Diffuse large B cell lymphoma

Correct Answer: D. Diffuse large B cell lymphoma

Explanation: Diffuse large B-cell lymphoma (DLBCL): It is the most frequent type of NHL, accounting for the majority of adult cases worldwide. It is aggressive but potentially curable. Pathology: Large B-cells growing in diffuse sheets that completely erase the lymph node architecture. Markers: CD20+ , CD19+, BCL6+. (Negative for CD15/CD30). Nodular sclerosis (Option A): Most common subtype of Hodgkin Lymphoma . Often affects young adults/females and presents with a mediastinal mass. Pathology: Characterized by dense collagen bands that divide the lymph node into nodules. Key Cell: Lacunar cells (a variant of Reed-Sternberg cells that sit in empty-looking spaces or "lacunae" after formalin fixation). Markers: CD15+, CD30+, CD20–. Mixed cellularity (Option B): Second most common Hodgkin Lymphoma ; often seen in older men or those with HIV . Strongest association with EBV . Pathology: A "mixed" background of lymphocytes, eosinophils, plasma cells, and histiocytes. Key Cell: Numerous classic Reed-Sternberg (RS) cells ("Owl's eye" nuclei). Markers: CD15+, CD30+, CD20–. Nodular lymphocytic predominant (Option C): A rare, indolent (slow-growing) variant of Hodgkin Lymphoma . Unlike the others, it is often CD20 positive . Pathology: Large nodules of small B-cells. Key Cell: Popcorn cells (L&H cells) which have multi-lobed, puffy nuclei resembling popcorn. Markers: CD20+ , CD45+, CD15–, CD30– (This is the opposite of Classical HL).

References:

Harrison's Principles of Internal Medicine, 22nd Edition, Page 862.

↑ *Back to this question in Part A*

@Neet_pg_bot

Q5: A 62-year-old man presents with generalized redness and scaling of the skin involving more than 80% of his body surface area, associated with intense itching. Examination reveals generalized lymphadenopathy and hepatosplenomegaly. Peripheral smear is shown below. Which of the following is the most likely diagnosis?

(Q851122)

A. Mycosis fungoides

B. Sézary syndrome

C. Psoriasis vulgaris

D. Adult T-cell leukemia/lymphoma

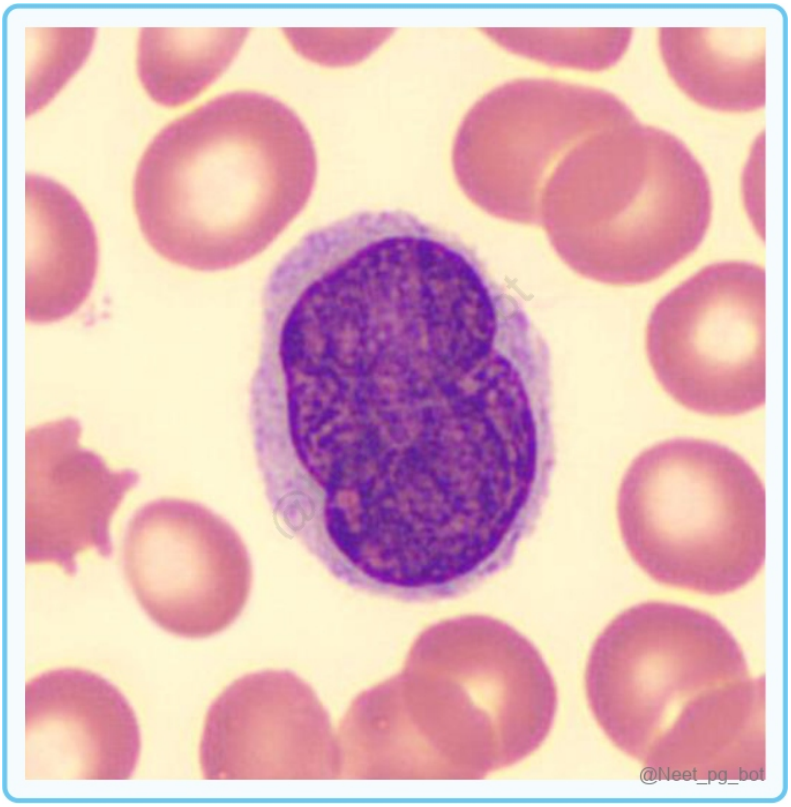

Correct Answer: B. Sézary syndrome

Explanation: The image shows a WBC with cereberiform appearance of nuclei due to convoluted nuclear membrane. The clinical presentation is of erythroderma. The patient has developed dissemination of cutaneous T cell lymphoma leading to organomegaly. This spread of CTCL is called Sezary syndrome and evolves from mycosis fungoides. It has a triad Erythroderma Generalized lymphadenopathy Circulating malignant T cells (Sézary cells). Mycosis fungoides (Option A): Mycosis fungoides typically start with patch/plaque skin lesions that may be misdiagnosed as atopic dermatitis. It evolves into erythroderma with circulating cerebriform cells and organomegaly , which is called Sézary syndrome. Psoriasis vulgaris (Option C): This is an inflammatory condition, not neoplastic. It would not show cerebriform T-cells on a peripheral smear nor typically cause hepatosplenomegaly. Adult T-cell leukemia/lymphoma (Option D): While it involves T-cells and skin, the classic cell is the "Flower cell" (highly lobulated nucleus), and it is strongly associated with hypercalcemia and HTLV-1.

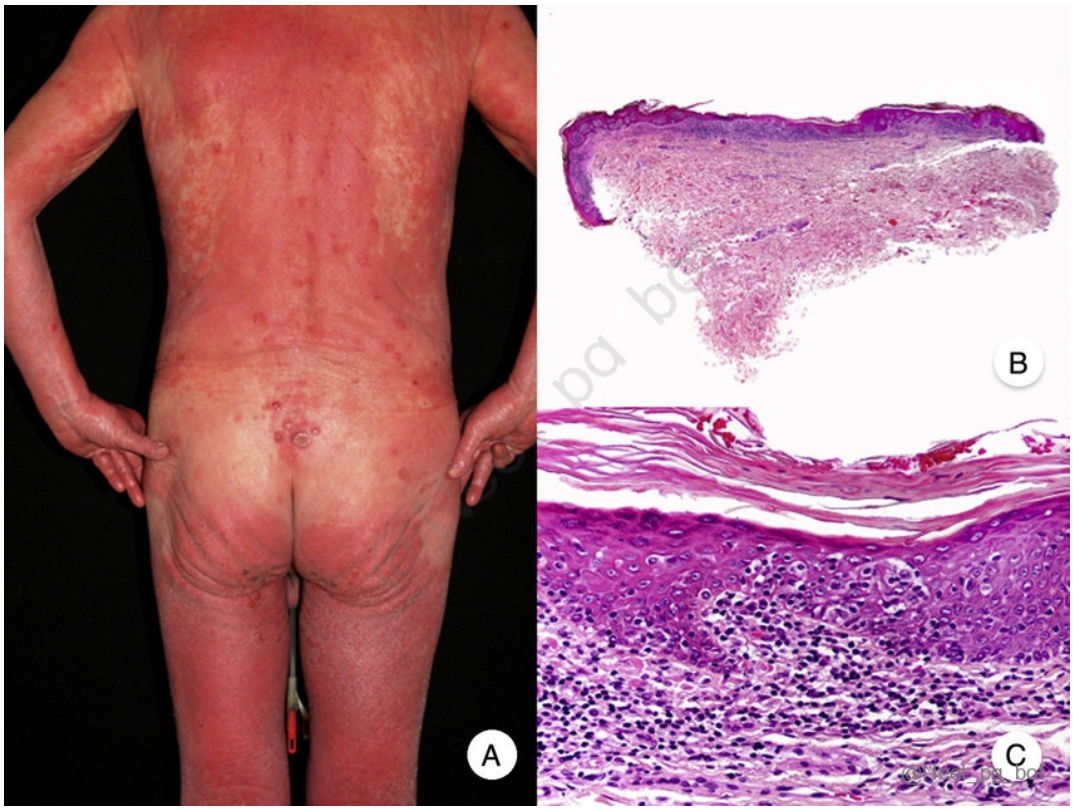



Patches | Plaques | Tumours | Erythroderma

@Neet_pg_bot



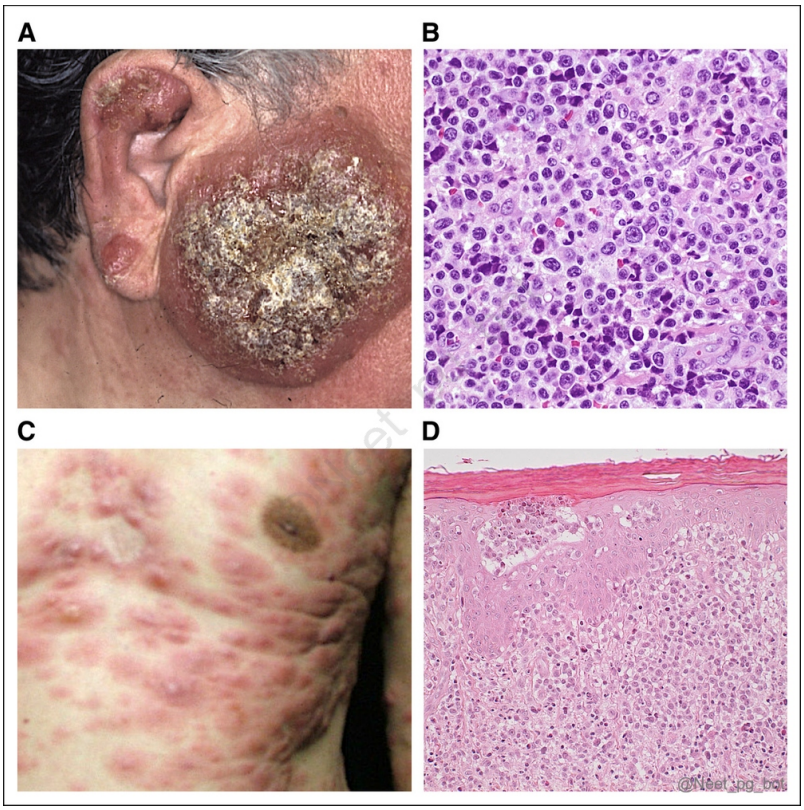

References:

Harrison's Principles of Internal Medicine, 22nd Edition, Page 866.

↑ *Back to this question in Part A*

@Neet_pg_bot

Q6: A 48-year-old man on medical tourism presents with generalized lymphadenopathy, skin rash, and hypercalcemia. Peripheral smear is shown below. Which of the following is the most likely diagnosis? (Q851121)

A. Sézary syndrome

B. Adult T-cell leukemia/lymphoma

C. Mycosis fungoides

D. Multiple myeloma

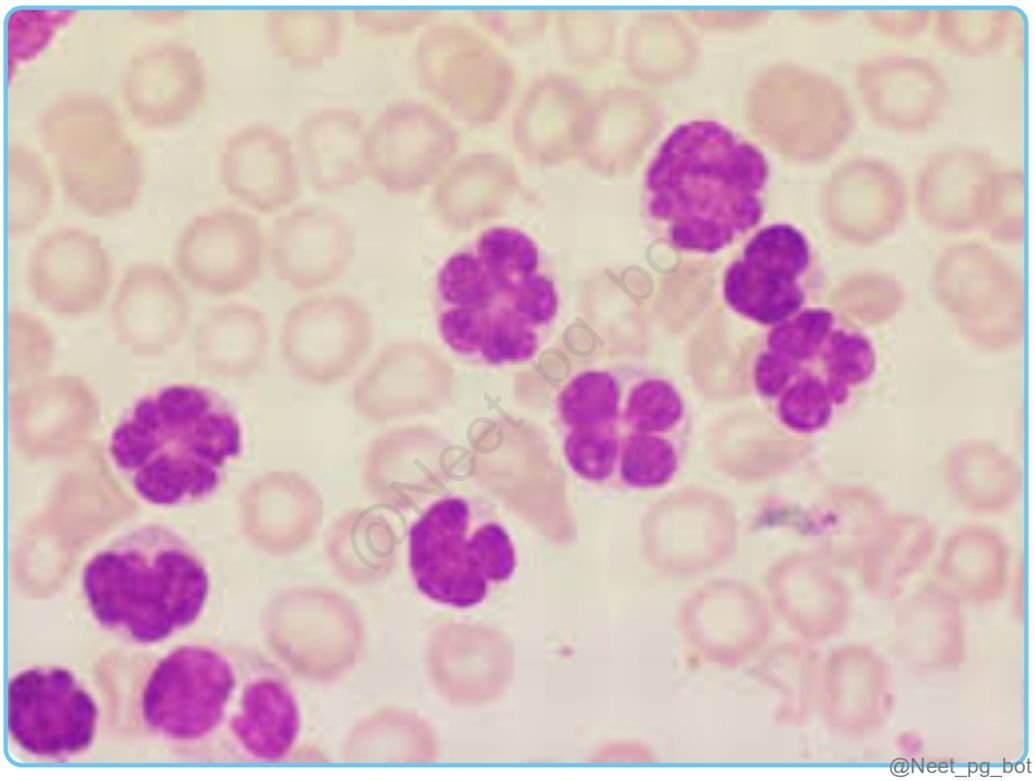

Correct Answer: B. Adult T-cell leukemia/lymphoma

Explanation: The peripheral smear shows “flower cells” —lymphocytes with polylobulated cloverleaf nuclei , which are classic for Adult T-cell leukemia/lymphoma , a malignancy caused by HTLV-1 infection. Common features include: Generalized lymphadenopathy Skin lesions/rash Hypercalcemia (due to cytokine-mediated bone resorption) Occurs in patients from HTLV-1 endemic regions (Japan, Caribbean, Africa) Sézary syndrome (Option A): Has cerebriform (brain-like) nuclei, erythroderma, and prominent pruritus. Mycosis fungoides (Option C): A skin-limited cutaneous T-cell lymphoma; blood smear typically normal until late “Sézary” stage. Multiple myeloma (Option D): Causes hypercalcemia but shows plasma cells, bone pain, and monoclonal spike.

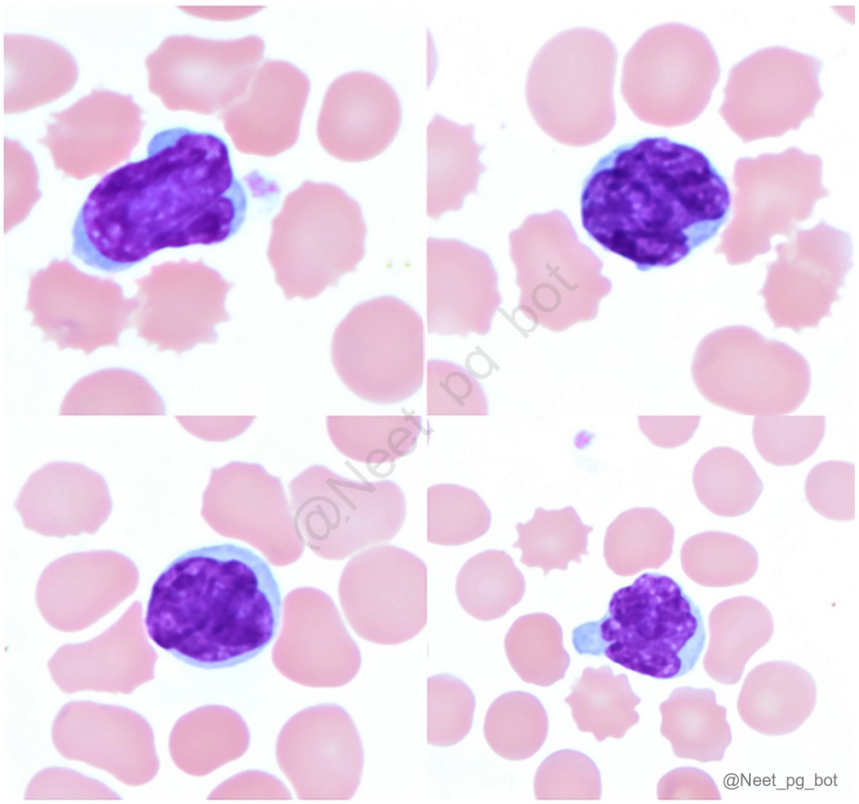

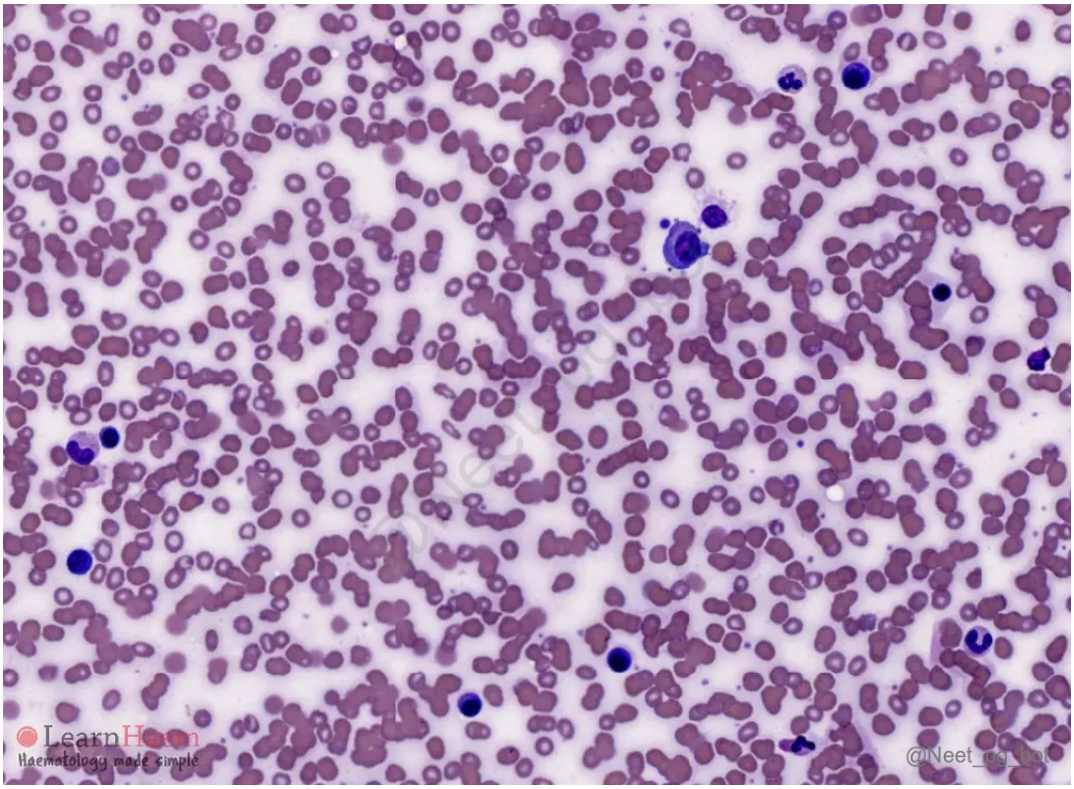

References:

Harrison's Principles of Internal Medicine, 22nd Edition, Page 867.

↑ *Back to this question in Part A*

@Neet_pg_bot

Q7: A 54-year-old woman presents with painless, generalized lymphadenopathy. Lymph node biopsy shows a nodular growth pattern with centrocytes and centroblasts. Immunohistochemistry is positive for CD10 and BCL2. Which chromosomal translocation is most commonly associated with this lymphoma? (Q851120)

A. t(2:5)

B. t(2:8)

C. t(14:18)

D. t(11:14)

Correct Answer: C. t(14:18)

Explanation: Centroblasts are a type of activated B-cell found in germinal centers of lymphoid follicles. They have 2-3 nucleoli, frequent mitosis and basophilic cytoplasm. They are found in the germinal center–derived lymphomas (e.g., follicular lymphoma, Burkitt lymphoma). Feature Mantle cell lymphoma Follicular Lymphoma Cell of origin Mantle zone naive B - cell Germinal center B cell Common translocation t(11:14) (q13:q32) - Cyclin D1/IgH t(14:18) (q32:q21)- BCL2/IgH Cyclin D1 + - SOX11 + - CDS + - CD10 - + BCL2 + + BCL6 - +

References:

Harrison's Principles of Internal Medicine, 22nd Edition, Page 863-864.

↑ *Back to this question in Part A*

@Neet_pg_bot

Q8: Which of the following lymphoma is seen in a 30 year old woman with SLE? (Q851119)

A. Extra nodal marginal zone B cell lymphoma

B. Diffuse large B cell lymphoma

C. Enteropathy associated T cell lymphoma

D. MALToma

Correct Answer: B. Diffuse large B cell lymphoma

Explanation: Autoimmune disease Most common NHL subtyp e Sjogren syndrome Extranodal marginal zone B-cell lymphoma Systemic lupus erythematosus Diffuse large B-cell lymphoma (DLBCL) Hashimoto thyroiditis Extranodal marginal zone B-cell lymphoma Celiac disease Enteropathy - associated T cell lymphoma Rheumatoid arthritis Diffuse large B cell lymphoma Dermatomyositis/ Polymyositis B-cell NHL (often DLBCL)

References:

Harrison's Principles of Internal Medicine, 22nd Edition, Page 862.

↑ *Back to this question in Part A*

@Neet_pg_bot

Q9: Which of the following is not correct about burkitt lymphoma? (Q851118)

A. Most common chromosomal translocation is t(8:22)

B. Non endemic form presents with ascites

C. Biopsy shows sheets of monotonous cells with basophilic cytoplasm with interspersed macrophages

D. CD10, CD19, CD20, and BCL-6 positive and BCL-2 negative

Correct Answer: A. Most common chromosomal translocation is t(8:22)

Explanation: The most frequent chromosomal translocation in Burkitt lymphoma is t(8:14) , involving c-MYC and the IgH locus. Non-endemic form with ascites (Option B): Sporadic Burkitt lymphoma can involve abdominal organs. Biopsy features (Option C): “Starry-sky” appearance due to interspersed macrophages is characteristic. Immunophenotype (Option D): Cells are CD10, CD19, CD20, BCL6 positive and BCL2 negative.

References:

Harrison's Principles of Internal Medicine, 22nd Edition, Page 862.

↑ *Back to this question in Part A*

@Neet_pg_bot

Q10: Which of the following is incorrect about Hodgkin’s lymphoma? (Q851094)

A. B-cell tumor

B. HIV and EBV are risk factor

C. CD19, CD20, CD23, PAX-5 positive cells

D. Genetic aberration on chromosome 9

Correct Answer: C. CD19, CD20, CD23, PAX-5 positive cells

Explanation: Reed–Sternberg (RS) cells in Hodgkin's lymphoma are of B-cell origin (Option A) and express PAX-5 positivity , but they typically show absent or very low expression of CD19, CD20, CD23 . Both Epstein–Barr virus (EBV) infection and HIV immunosuppression are established risk factors for Hodgkin's lymphoma. (Option C) HL is associated with alterations involving chromosome 9p24. (Option D)

References:

Harrison's Principles of Internal Medicine, 22nd Edition, Page 868.

↑ *Back to this question in Part A*

@Neet_pg_bot

Q11: Which of the following chromosomal translocations is correct about anaplastic lymphoma? (Q851114)

A. t(2:5)

B. t(8:14)

C. t(8:22)

D. t(11:14)

Correct Answer: A. t(2:5)

Explanation: Genetic features Lymphoma t(8:14) t(2:8) t(8:22) Burkitt's lymphoma t(11:14) Mantle cell lymphoma; multiple myeloma t(14:18) t(3:14) Follicular lymphoma, diffuse large B-cell lymphoma t(11: 18) MALT lymphoma t(9:14) Lymphoplasmacytic lymphoma t(2:5) t(1:2) Anaplastic large -cell lymphoma

References:

Harrison's Principles of Internal Medicine, 22nd Edition, Page 867.

↑ *Back to this question in Part A*

@Neet_pg_bot

Q12: A 45-year-old male presents with fever, night sweats, fatigue, and unintentional weight loss for 2 months. On examination, he has generalized lymphadenopathy and mild hepatosplenomegaly. Laboratory tests reveal anemia, elevated ESR, and hypergammaglobulinemia. Excision lymph node biopsy is shown. Which of the following viruses is implicated in its pathology (Q851108)

A. HIV

B. EBV

C. HCV

D. HHV8

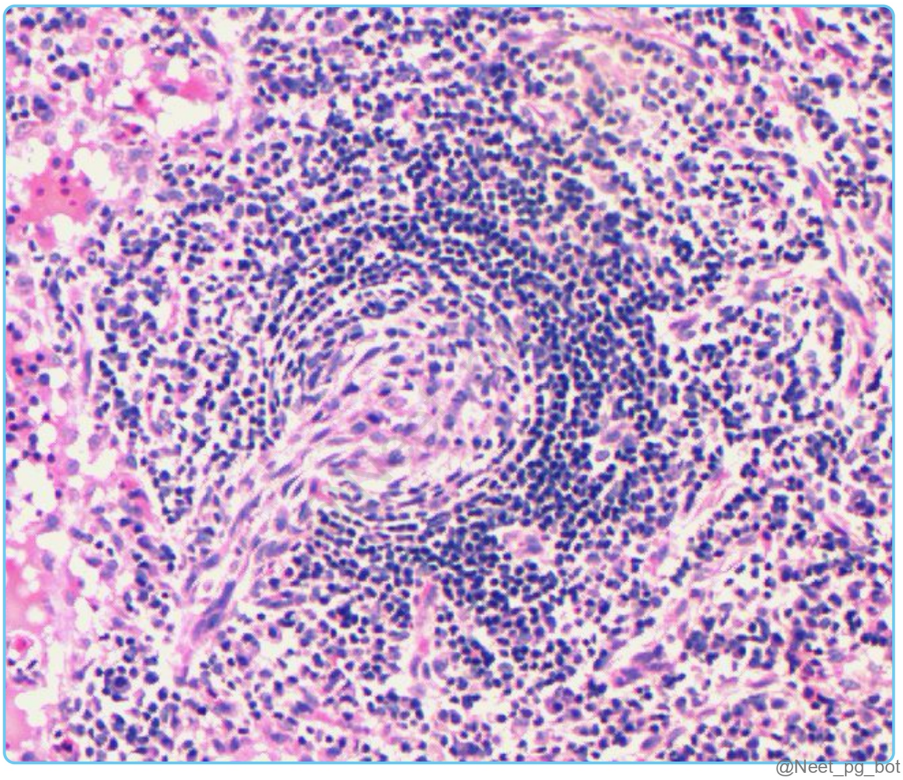

Correct Answer: D. HHV8

Explanation: Excisional lymph node biopsy shows “onion-skinning”/ hyperplastic germinal centers with concentric layering of lymphocytes. This along with systemic symptoms points to diagnosis of Castleman disease. The organism incriminated is HHV8 Other viruses like HIV, EBV, and HCV may coexist but are not the primary etiologic agent.

References:

Harrison's Principles of Internal Medicine, 22nd Edition, Page 1516.

↑ *Back to this question in Part A*

@Neet_pg_bot

Q13: A patient is diagnosed with lymphoplasmacytic lymphoma (LPL). Which of the following viruses is most strongly associated with this condition? (Q851106)

A. EBV

B. HIV

C. HCV

D. HHV8

Correct Answer: C. HCV

Explanation: Lymphoplasmacytic lymphoma (LPL) is a low-grade B-cell lymphoma, most classically associated with Waldenström macroglobulinemia (IgM paraprotein) and infectious cause hepatitis C EBV (Option A): Associated with Hodgkin lymphoma and some B-cell lymphoproliferative disorders, not LPL. HIV (Option B): Increases risk of some lymphomas but is not the primary cause of LPL. HHV-8 (Option D): Implicated in multicentric Castleman disease and some Kaposi sarcoma–associated lymphoproliferative disorders, not LPL.

References:

Harrison's Principles of Internal Medicine, 22nd Edition, Page 858.

↑ *Back to this question in Part A*

@Neet_pg_bot

Q14: Which organism causes primary effusion lymphoma? (Q851104)

A. EBV

B. HIV

C. HCV

D. HHV8

Correct Answer: D. HHV8

Explanation: Infectious agent Lymphoma Malignancy Epstein – Barr virus Burkitt’s lymphoma Post-organ transplant lymphoma Primary CNS diffuse large B -cell lymphoma Hodgkin’s lymphoma Extranodal NK/T cell lymphoma, nasal type HTLV-1 Adult T -cell leukemia/ lymphoma HIV Diffuse large B-cell lymphoma Burkitt’s lymphoma Hepatitis C virus Lymphoplasmacytic lymphoma Helicobacter pylori Gastric MALT lymphoma Human herpesvirus 8 Kaposi Sarcoma Primary effusion lymphoma Multicentric Castleman’s disease KSHV Inflammatory Cytokine Syndrome

References:

Harrison's Principles of Internal Medicine, 22nd Edition, Page 873.

↑ *Back to this question in Part A*

@Neet_pg_bot

Q15: A 28-year-old male presents with painless cervical lymphadenopathy for 3 months. He also reports intermittent fever, night sweats, and unintentional weight loss. Excisional lymph node biopsy shows classical Reed-Sternberg cells that are CD15+, CD30+, and weakly PAX-5+, with negative CD20. Staging scans reveal involvement of cervical and mediastinal lymph nodes without extranodal disease. What is the treatment of choice for this patient? (Q851103)

A. ABVD

B. R-CHOP

C. PCR

D. FCR

Correct Answer: A. ABVD

Explanation: The presence of Reed-Sternberg cells (CD15+, CD30+, weak PAX-5+) confirms classical Hodgkin lymphoma (HL) . The standard first-line regimen for HL is ABVD (Adriamycin/doxorubicin, Bleomycin, Vinblastine, Dacarbazine) , typically given for 4–6 cycles depending on stage and risk. CHOP (Option B): Cyclophosphamide, Doxorubicin, Vincristine, Prednisone is used for non-Hodgkin lymphomas , not HL. PCR (Option C): Fludarabine-based regimen (Pentostatin, Cyclophosphamide, Rituximab) is used in CLL , not HL. FCR (Option D): Fludarabine, Cyclophosphamide, Rituximab is also used for CLL , not HL.

References:

Harrison's Principles of Internal Medicine, 22nd Edition, Page 870.

↑ *Back to this question in Part A*

@Neet_pg_bot

Q16: Which of the following is not a category B symptom in ann arbor classification for HL? (Q851101)

A. Unexplained weight loss of > 10% during 6 months

B. Unexplained cough > 2weeks

C. Unexplained fever > 38 C in last month

D. Recurrent drenching night sweats

Correct Answer: B. Unexplained cough > 2weeks

Explanation: Category A, B, E in Ann Arbor classification for HL A No symptoms B Unexplained weight loss of >10% of the body weight during the 6 months before staging investigation Unexplained, persistent or recurrent fever with temperatures >38 0 C during the previous month Recurrent drenching night sweats during the previous month E Localized, solitary involvement of extralymphatic tissue, excluding liver and bone marrow

References:

Harrison's Principles of Internal Medicine, 22nd Edition, Page 869, 861.

↑ *Back to this question in Part A*

@Neet_pg_bot

Q17: A 20 year old girl presents with breathing difficulty at rest. On examination enlarged cervical lymph are palpated with rubbery consistency. CXR shows hilar lymphadenopathy. Biopsy shows large cells with abundant cytoplasm and bilobed nuclei. Which of the following is/are correct about this condition 1. Stellate inclusions in cytoplasm 2. Langhans type of giant cells 3. Aberration in chromosome 9 4. CD15 and CD 30 positivity (Q851099)

A. only 1

B. 1,2

C. 2,3

D. 3,4

Correct Answer: D. 3,4

Explanation: The clinical diagnosis based on rubbery consistency of lymph nodes and biopsy finding of large cells with abundant cytoplasm and bilobed nuclei indicates hodgkin lymphoma. It occurs due to aberration of chromosome 9. RS cells exhibit CD15 and CD30 and PAX-5 positivity with absent/ dim CD19, CD20

References:

Harrison's Principles of Internal Medicine, 22nd Edition, Page 868-869.

↑ *Back to this question in Part A*

@Neet_pg_bot

Q18: A 20 year old girl presents with breathing difficulty at rest. On examination enlarged cervical lymph are palpated with rubbery consistency. CXR shows hilar lymphadenopathy. Biopsy shows large cells with abundant cytoplasm and bilobed nuclei. What is the diagnosis? (Q851097)

A. Sarcoidosis

B. Pulmonary TB

C. Langhans cell histiocytosis

D. Lymphoma

Correct Answer: D. Lymphoma

Explanation: The biopsy description of large cells with abundant cytoplasm and bilobed nuclei indicating Reed-Sternberg cells with owl eye appearance , seen in Hodgkin lymphoma . Sarcoidosis (Option A): Presents with non-caseating granulomas, not Reed-Sternberg cells. Pulmonary TB (Option B): Shows caseating granulomas with epithelioid cells and Langhans giant cells, not bilobed nuclei. Langerhans cell histiocytosis (Option C): Shows Birbeck granules (“tennis racket” appearance) on EM, not RS cells. Birbeck granules (“tennis racket” appearance) on EM



@Neet_pg_bot

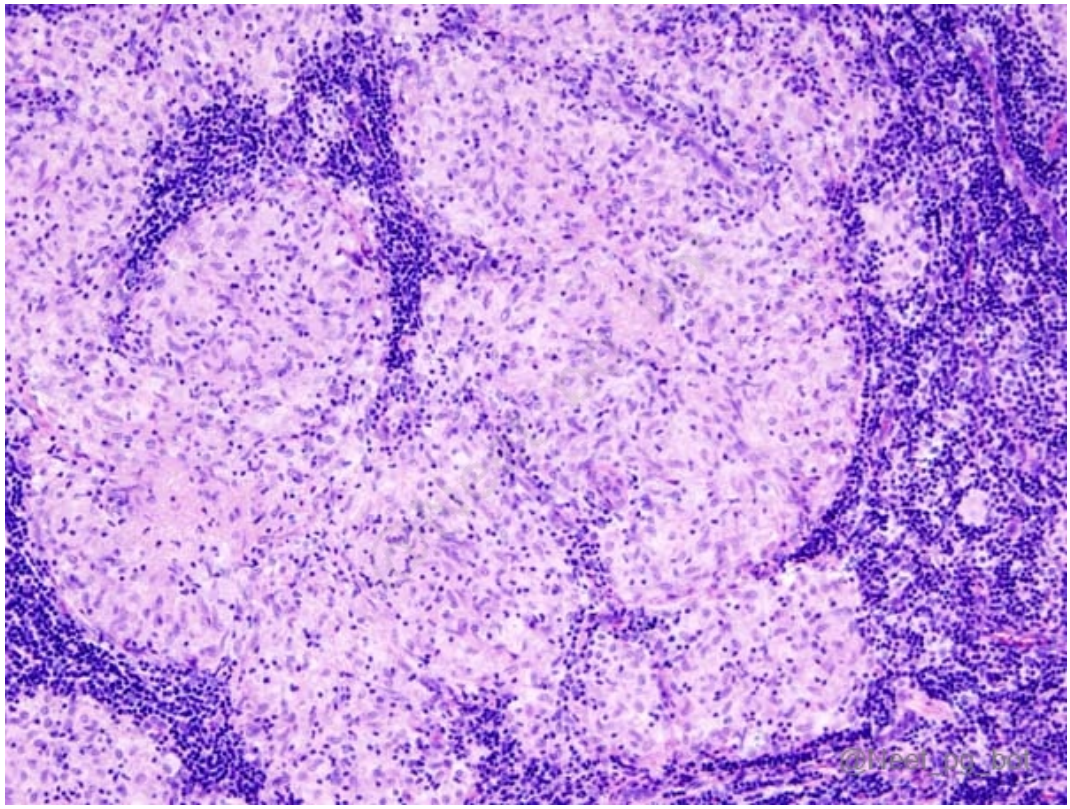

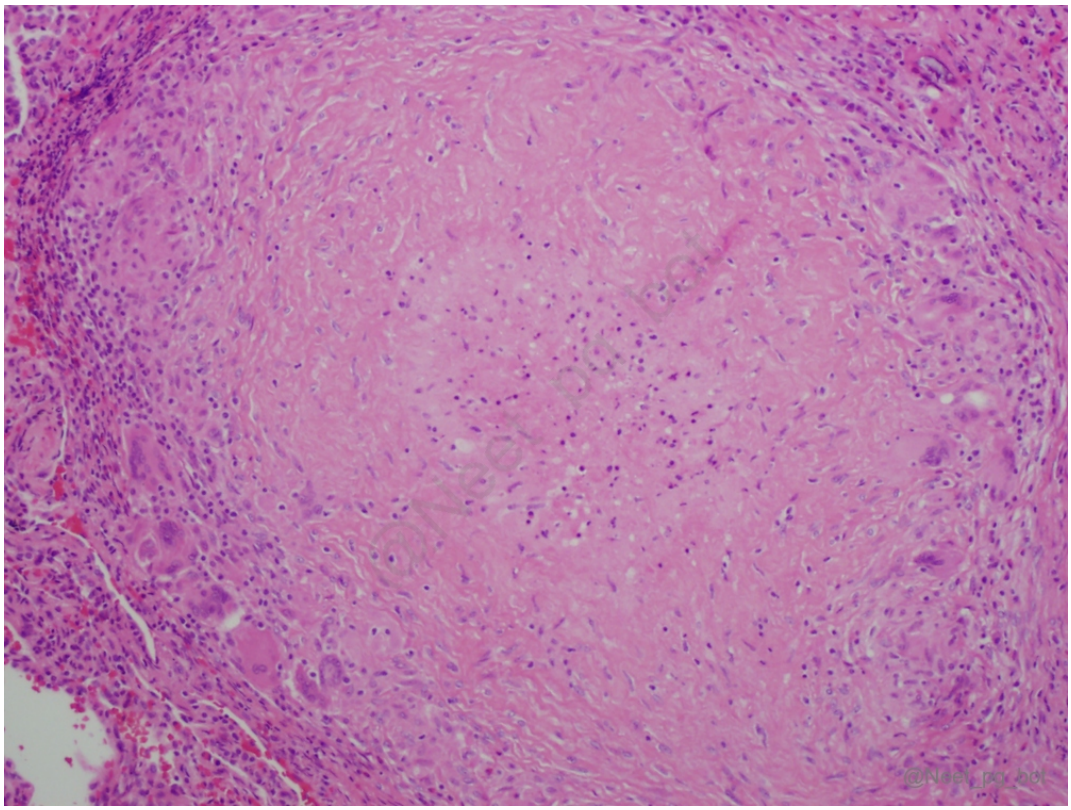

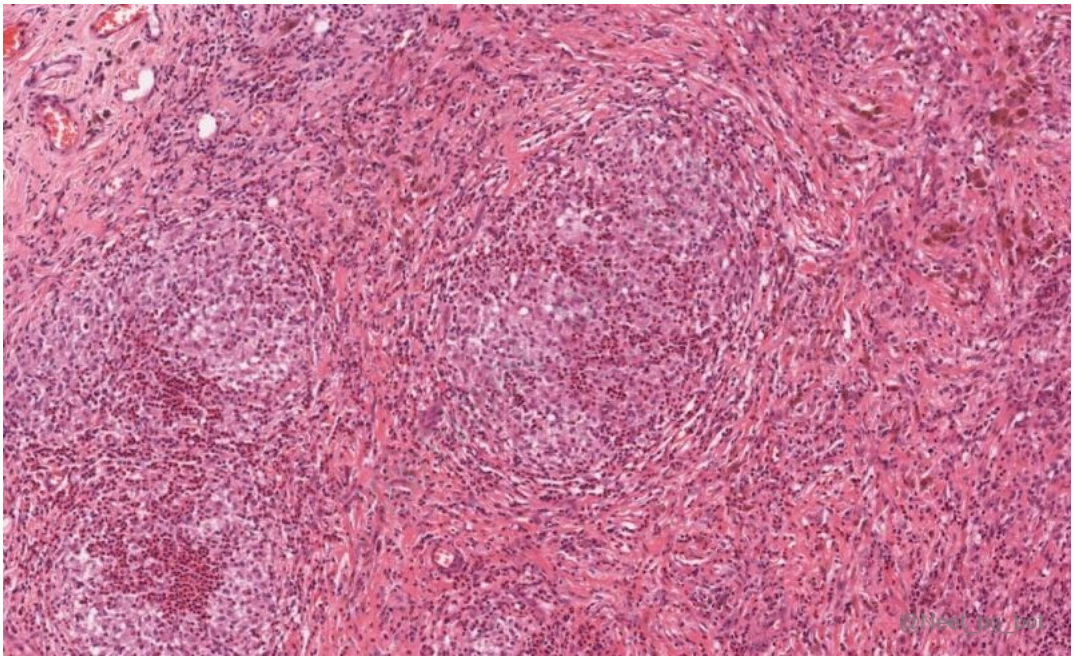

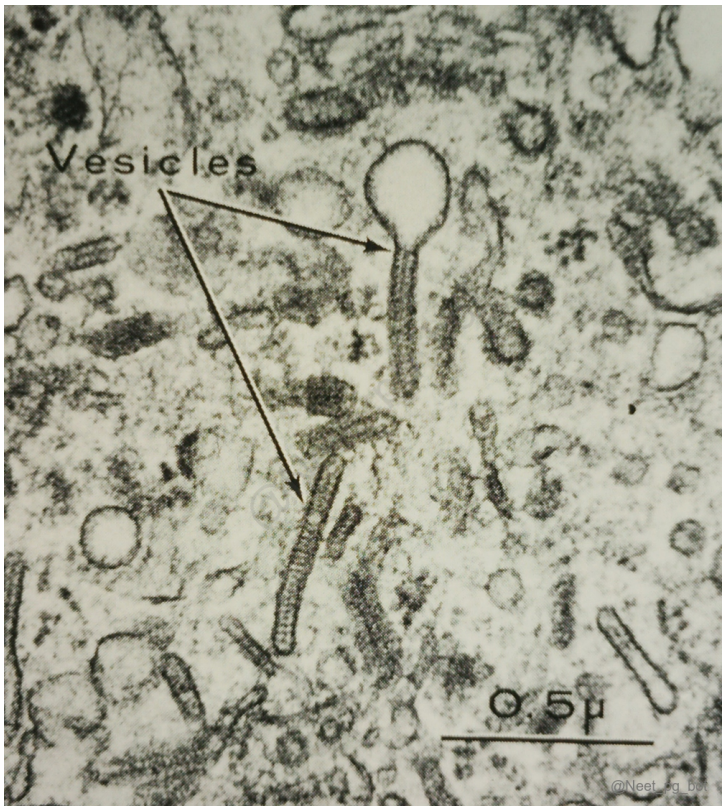

References:

Harrison's Principles of Internal Medicine, 22nd Edition, Page 869.

↑ *Back to this question in Part A*

@Neet_pg_bot

• [06_Hematology] 043 Thalassemia And Hereditary Spherocytosis

« Back to Folder Directory

[06_Hematology] 043 Thalassemia And Hereditary Spherocytosis — Quick Jump

Q1 (p. 2079) *Q2 (p. 2079)* *Q3 (p. 2080)* *Q4 (p. 2081)* *Q5 (p. 2083)* *Q6 (p. 2083)*
Q7 (p. 2084) *Q8 (p. 2085)* *Q9 (p. 2086)* *Q10 (p. 2086)* *Q11 (p. 2087)* *Q12 (p. 2089)*

Q1: In a child with thalassemia major, which of the following drugs should be started to reduce transfusion dependency? (Q851128)

A. Luspatercept

B. Deferoxamine

C. Deferiprone

D. Deferasirox

Correct Answer: A. Luspatercept

■ *Listen (English)*

■ *Listen (Hindi)*

Explanation: The question is not on iron chelation but measures to reduce transfusion dependency or number of transfusions required per year. Luspatercept is a novel erythroid maturation agent that promotes late-stage erythropoiesis and improves endogenous hemoglobin production . It does not replace iron chelators that are used to prevent complications like bronze diabetes or cardiomyopathy.

References:

Harrison's Principles of Internal Medicine, 22nd Edition, Page 777.

Nelson's Textbook of Pediatrics, 22nd Edition, Page 2984

↑ *Back to this question in Part A*

@Neet_pg_bot

Q2: A 4-year-old child with anemia, chipmunk facies and splenomegaly is found to have low Hb A and elevated HbF and HbA2. He has received multiple blood transfusions for which no records are available Which of the following is least likely to

occur as a complication in this case? (Q851129)

A. Lung fibrosis

B. Cardiomyopathy

C. Diabetes

D. Infections with capsulated organisms

Correct Answer: D. Infections with capsulated organisms

■ *Listen (English)*

■ *Listen (Hindi)*

Explanation: This child has β-thalassemia major , a transfusion-dependent hemoglobinopathy. Multiple transfusions cause iron overload , leading to deposition of iron in various organs. Infections with encapsulated organisms (e.g., S. pneumoniae, H. influenzae) occur mainly after splenectomy . This patient has splenomegaly , not splenectomy → spleen is still present. Therefore, encapsulated organism infections are NOT expected here. Lung fibrosis (Option A): Iron deposition and transfusion-related oxidative damage can lead to pulmonary fibrosis. Cardiomyopathy (Option B) Iron overload frequently affects the heart → dilated or restrictive cardiomyopathy, leading to heart failure. This is a major cause of mortality in thalassemia major. Diabetes (Option C): Iron deposition in the pancreas damages β-cells → “bronze diabetes” is common in chronic transfusion recipients.

References:

Harrison's Principles of Internal Medicine, 22nd Edition, Page 778.

Nelson's Textbook of Pediatrics, 22nd Edition, Page 2984

↑ *Back to this question in Part A*

@Neet_pg_bot

Q3: Investigation of choice for diagnosis of beta thalassemia ? (Q851130)

A. NESTROFT

B. Gene sequencing

C. HPLC

D. Hemoglobin electrophoresis

Correct Answer: B. Gene sequencing

■ *Listen (English)*

■ *Listen (Hindi)*

Explanation: WHO and Thalassemia International Federation guidelines now recommend molecular confirmation for all cases for diagnosis by demonstration of HBB gene mutation. Additional benefits are It allows accurate genetic counseling Guides prenatal testing via chorionic villus sampling. NESTROFT (Option A): A screening test, not diagnostic; used for detecting carrier states. HPLC (Option C): Helps quantify HbA■ and HbF levels but cannot define mutation type. Hemoglobin electrophoresis (Option D): Useful for initial evaluation but lacks precision in identifying molecular defects.

References:

Harrison's Principles of Internal Medicine, 22nd Edition, Page 777.

↑ *Back to this question in Part A*

@Neet_pg_bot

Q4: Earliest radiological finding in patients with beta thalassemia is (Q851131)

A. Widening of diploic spaces of skull

B. Lytic lesion in vertebrae

C. Squaring of metacarpals

D. AVN of metacarpals

Correct Answer: C. Squaring of metacarpals

■ *Listen (English)*

■ *Listen (Hindi)*

Explanation: The earliest skeletal deformities in thalassemia are observed in the metacarpals, metatarsals and phalanges of hands. The patient develops marrow hyperplasia causing cortical thinning and a “squared or sausage-shaped configuration” of these small tubular bones. Subsequently, widening of diploic spaces with prominent bone trabeculations, giving rise to a “hair on end” appearance, is observed.



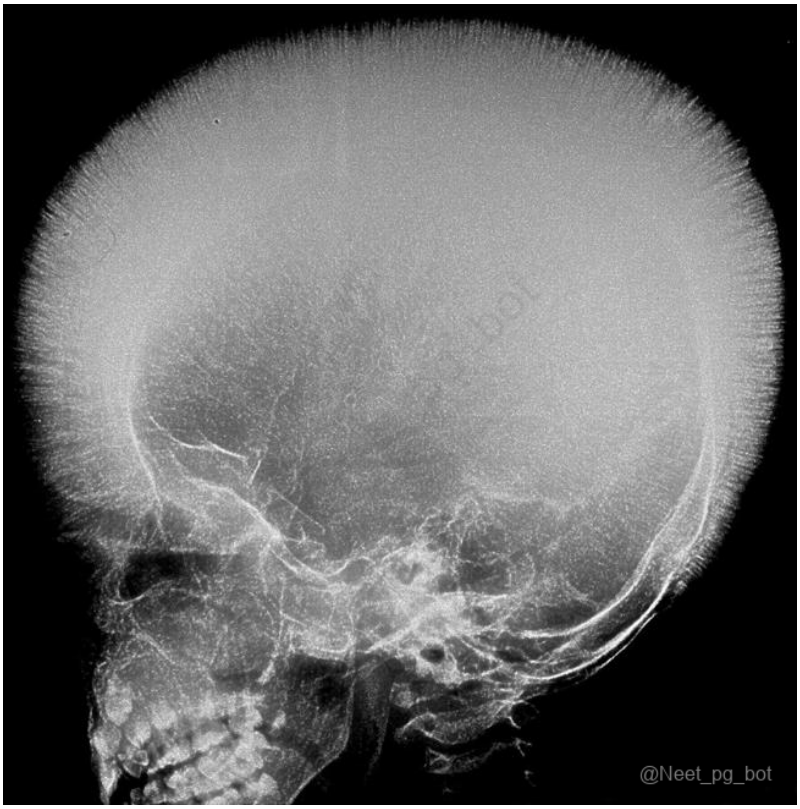

References:

Harrison's Principles of Internal Medicine, 22nd Edition, Page 2968.

↑ *Back to this question in Part A*

@Neet_pg_bot

Q5: A 2 year old child is undergoing workup for severe anemia. Labs show Low MCV, Increased MCHC. USG abdomen shows enlarged spleen with acoustic shadows in gall bladder. Which of the following is not correct about this patient? (Q851133)

A. Peripheral smear shows RBC that lack central pallor

B. Black pigmented gall stones in gall bladder

C. Counsel about Elective splenectomy

D. Defective gene on chromosome 14

Correct Answer: D. Defective gene on chromosome 14

■ *Listen (English)*

■ *Listen (Hindi)*

Explanation: The keyword is increased MCHC with anemia, suggesting a diagnosis of hereditary spherocytosis. The acoustic shadows in the gall bladder are pigmented gallstones. Spherocytes lack central pallor and are smaller in size than normal RBCs. GENE Chromosomal mutation Protein produced Pattern of Inheritance SPTA1 1q22-q23 α-Spectrin HE (dominant) SPTB 14q23-q24.1 β-Spectrin HE (dominant) ANK1 8p11.2 Ankyrin HS (dominant) SLC4A1 17q21 B and 3; also known as anion exchanger HS (dominant)

References:

Harrison's Principles of Internal Medicine, 22nd Edition, Page 794.

↑ *Back to this question in Part A*

@Neet_pg_bot

Q6: In a transfusion dependent thalassemia major child, deferoxamine should be started at serum ferritin values > _____ ug/L (Q851134)

A. 500

B. 1000

C. 1500

D. 2000

Correct Answer: B. 1000

■ *Listen (English)*

■ *Listen (Hindi)*

Explanation: Deferoxamine chelation should begin in chronic transfusional iron overload: 10-15 transfusions or Two years after starting transfusions Serum ferritin > 1,000 µg/L Liver iron concentration > 3 mg Fe/g dry weight This information should not be mixed with indications for starting DFO in acute iron poisoning when serum iron > 500 ug/dl at 4-6 hours after ingestion.

References:

Harrison's Principles of Internal Medicine, 22nd Edition, Page 777.

https://www.ncbi.nlm.nih.gov/books/NBK526131/

↑ *Back to this question in Part A*

@Neet_pg_bot

Q7: A 10 year old boy presents with pallor. Work up shows Hb= 8 gm%, Peripheral smear has anisocytosis with poikilocytosis, Hemoglobin electrophoresis report has Hb A = 60%, HbF = 34%, HbA2 = 6%. Diagnosis is? (Q851135)

A. Thalassemia minor

B. Thalassemia major

C. Thalassemia intermedia

D. Thalassemia trait

Correct Answer: C. Thalassemia intermedia

■ *Listen (English)*

■ *Listen (Hindi)*

Explanation: Condition HbA HbF HbA2 Notes Thalassemia minor/trait Usually >90% N or slightly increased Increased (3.5 - 8%) HbF rarely >5% Thalassemia intermedia Markedly reduced ↑(up to 30 - 70%) Increased Variable transfusion need Thalassemia major Absent or very low (<10%) Very High (70-90%) Normal/slightly increased Transfusion-dependent from infancy

References:

Harrison's Principles of Internal Medicine, 22nd Edition, Page 777.

↑ *Back to this question in Part A*

@Neet_pg_bot

Q8: Which of the following is incorrect about Hb Barts? (Q851136)

A. Extremely low oxygen affinity

B. Causes functional tissue hypoxia

C. Unstable structure so precipitates in RBC

D. Presents as non immunogenic hydrops fetalis

Correct Answer: A. Extremely low oxygen affinity

■ *Listen (English)*

■ *Listen (Hindi)*

Explanation: Hb Barts has extremely high oxygen affinity. That explains poor oxygen delivery to body tissue, including heart, leading to congestive heart failure and edema (non-immunogenic hydrops fetalis). All hemoglobinopathies cause unstable structure of hemoglobin.

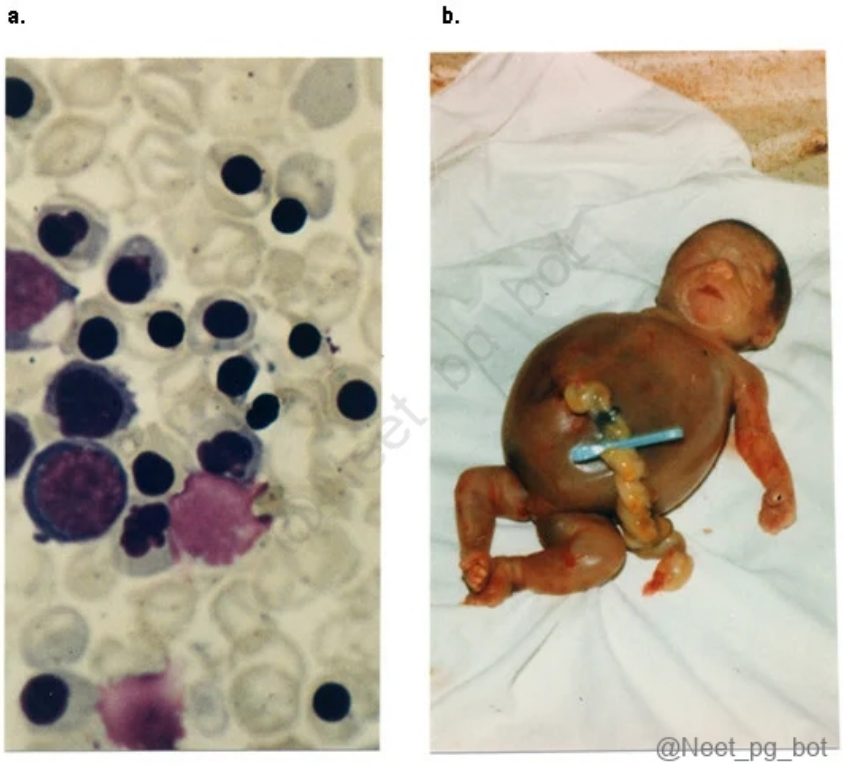

References:

Harrison's Principles of Internal Medicine, 22nd Edition, Page 778-779.

↑ *Back to this question in Part A*

@Neet_pg_bot

Q9: In a newly diagnosed beta thalassemia major patient which manifestation will not be seen? (Q851137)

A. Ectopic hematopoiesis

B. Reticulocyte count of 0.1%

C. Ineffective erythropoiesis

D. Elevated LDH and low Haptoglobin levels

Correct Answer: B. Reticulocyte count of 0.1%

■ *Listen (English)*

■ *Listen (Hindi)*

Explanation: Normal reticulocyte count is 0.5 -1.5% . Hemolytic anaemia will cause reticulocyte count to increase. Patients develop extramedullary hematopoiesis also called ectopic hematopoiesis. It means RBC synthesis in liver and spleen which causes them to enlarge. The production of defective RBC containing alpha tetramers in the bone marrow due to the absence of beta chains is present.

References:

Harrison's Principles of Internal Medicine, 22nd Edition, Page 777.

↑ *Back to this question in Part A*

@Neet_pg_bot

Q10: You are counseling parents of a 3 year old severely anaemic child diagnosed with hereditary spherocytosis about surgical options. Which of the following will you inform them about? (Q851138)

A. Splenectomy

B. Gall bladder removal

C. Splenectomy plus gall bladder removal

D. Nephrectomy

Correct Answer: A. Splenectomy

■ *Listen (English)*

■ *Listen (Hindi)*

Explanation: Elective splenectomy should be done in severe cases of HS by 4-6 years of age. For mild cases splenectomy can be avoided. Gall bladder removal is not done in all cases and must be done if symptoms are present. All cases should be vaccinated with Neisseria meningitidis and Haemophilus influenzae before splenectomy.

References:

Harrison's Principles of Internal Medicine, 22nd Edition, Page 795.

↑ *Back to this question in Part A*

@Neet_pg_bot

Q11: Which of the following tests is used in diagnosis of hereditary spherocytosis? (Q851139)

A. Acidified lysis test

B. Acid glycerol lysis test

C. Sucrose hemolysis test

D. Flow cytometry for CD55 and CD59

Correct Answer: B. Acid glycerol lysis test

■ *Listen (English)*

■ *Listen (Hindi)*

Explanation: Acid glycerol lysis test is used for diagnosis of autosomal recessive forms of Hereditary spherocytosis. The more specific tests used are eosin-5'-maleimide (EMA) - binding test, and SDS-gel electrophoresis. Eosin-5'-maleimide (EMA) - binding test: SDS-gel electrophoresis: Acidified lysis test and Sucrose hemolysis test (Option A and C) are outdated tests for diagnosis of paroxysmal nocturnal hemoglobinuria. Flow cytometry for CD55 and CD59 (Option D) is currently used for testing for PNH.

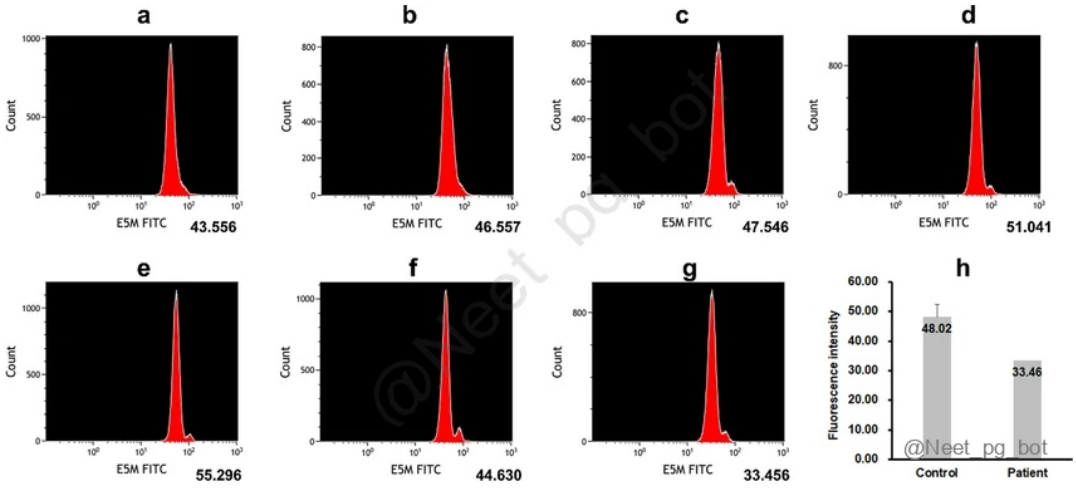
a
b
c
d
e
f
g
h
Count
E5M FITC
43.556
46.557
47.546
51.041
55.296
44.630
33.456
Fluorescence intensity
48.02
33.46
Control
Patient
@Neet_pg_bot

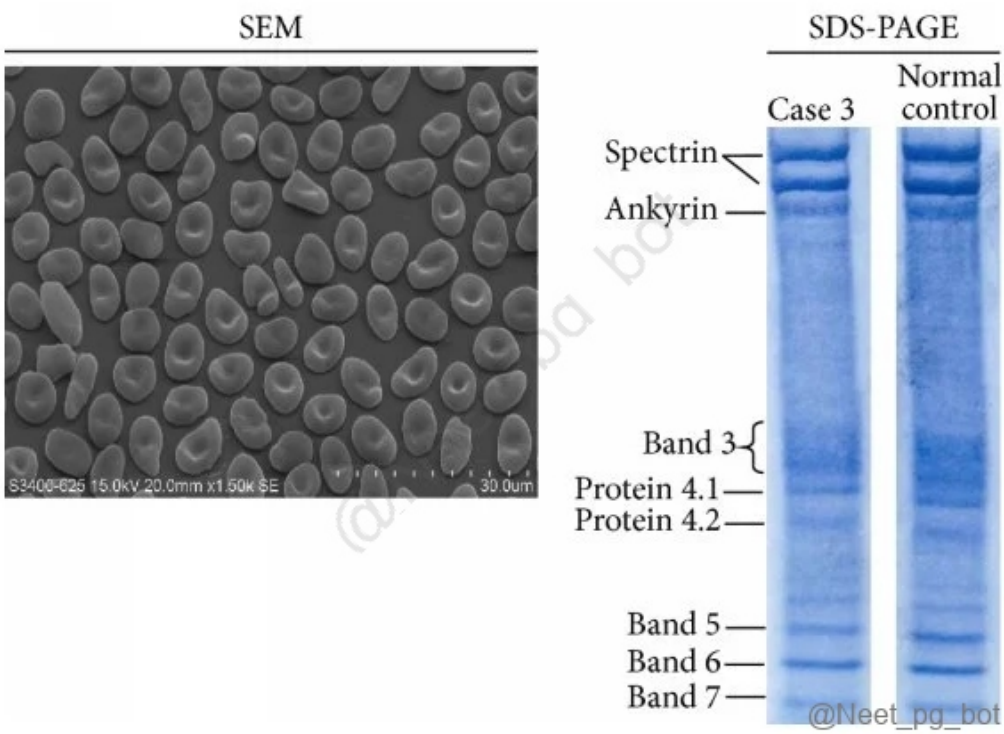
SEM
S3400-625 15.0kV 20.0mm x1.50k SE
30.0um
SDS-PAGE
Case 3
Normal control
Spectrin
Ankyrin
Band 3
Protein 4.1
Protein 4.2
Band 5
Band 6
Band 7
@Neet_pg_bot

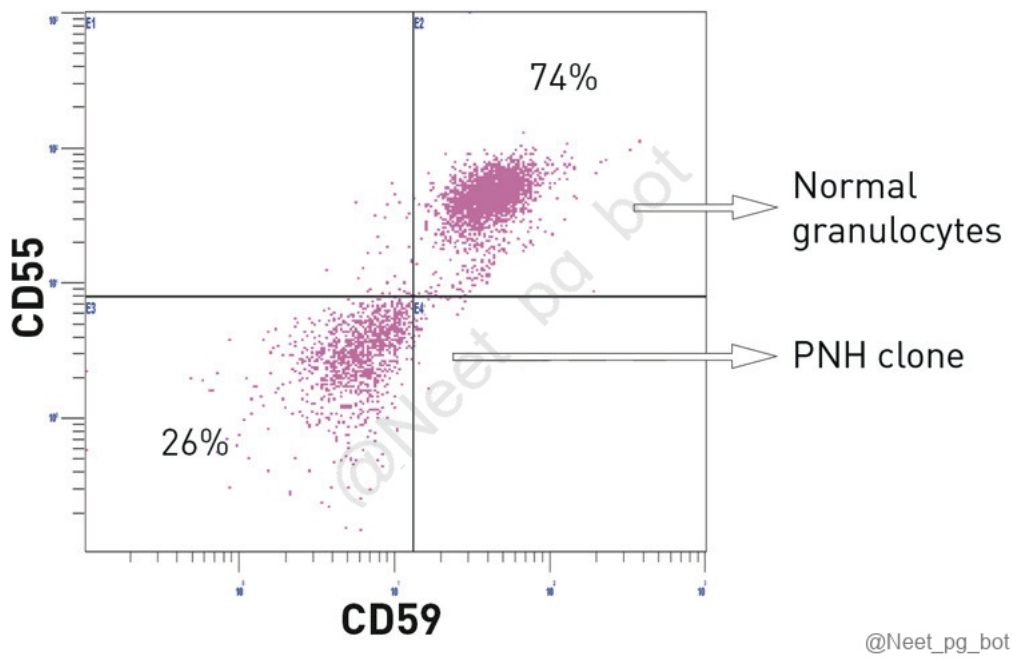

References:

Harrison's Principles of Internal Medicine, 22nd Edition, Page 794.

↑ *Back to this question in Part A*

@Neet_pg_bot

Q12: A 25-year-old man of Southeast Asian origin presents with anemia and fatigue. CBC shows : Hemoglobin: 9.2 g/dL, MCV: 68 fL, MCH: 22 pg/dl. Peripheral smear shows microcytosis, hypochromia, and numerous target cells. Supravital staining with brilliant cresyl blue reveals multiple small inclusions in RBCs giving a “golf ball” appearance. Which of the following is the most likely diagnosis? (Q851140)

A. β-thalassemia minor

B. HbH disease

C. Sideroblastic anemia

D. Hereditary spherocytosis

Correct Answer: B. HbH disease

■ *Listen (English)*

■ *Listen (Hindi)*

Explanation: "Golf ball" inclusions are precipitated β■ tetramers in alpha thalassemia/ HbH disease and are seen on supravital stain in α-thalassemia with three gene deletions. β-thalassemia minor (Option A) has target cells on P. smear. Sideroblastic anemia (Option C) shows ring sideroblasts in bone marrow, not peripheral smear inclusions. Hereditary spherocytosis (Option D) shows small RBC that lack central pallor.



References:

Harrison's Principles of Internal Medicine, 22nd Edition, Page 778-779.

↑ *Back to this question in Part A*

@Neet_pg_bot

• [06_Hematology] 044 Sickle Cell Disease G6Pd Deficiency And Other Hemolytic Anemias

« Back to Folder Directory

[06_Hematology] 044 Sickle Cell Disease G6Pd Deficiency And Other Hemolytic Anemias — Quick Jump

Q1 (p. 2091)	*Q2 (p. 2091)*	*Q3 (p. 2092)*	*Q4 (p. 2093)*	*Q5 (p. 2095)*	*Q6 (p. 2097)*
Q7 (p. 2098)	*Q8 (p. 2099)*	*Q9 (p. 2099)*	*Q10 (p. 2100)*	*Q11 (p. 2101)*	*Q12 (p. 2101)*
Q13 (p. 2102)	*Q14 (p. 2102)*	*Q15 (p. 2104)*	*Q16 (p. 2104)*	*Q17 (p. 2105)*	*Q18 (p. 2106)*
Q19 (p. 2107)	*Q20 (p. 2109)*	*Q21 (p. 2111)*			

Q1: All of the following are complications of sickle cell disease except? (Q851153)

A. Stroke

B. Pulmonary hypertension

C. Vitreous hemorrhage

D. Neonatal jaundice

Correct Answer: D. Neonatal jaundice

Explanation: In sickle cell disease , hemolysis is extravascular and sickling develops after HbF declines (~6 months of age). Therefore, neonatal jaundice is not a complication , unlike in hereditary spherocytosis or G6PD deficiency. HbF prevents sickling. Hemolysis is minimal until HbF levels drop over months. Stroke (Option A): Seen in children with sickle cell anemia. Pulmonary hypertension (Option B): Chronic hemolysis leads to NO depletion → pulmonary hypertension. Vitreous hemorrhage (Option C): Seen due to proliferative sickle cell retinopathy.

References:

Harrison's Principles of Internal Medicine, 22nd Edition, Page 774.

↑ *Back to this question in Part A*

@Neet_pg_bot

Q2: A 15-year-old male with sickle cell anemia presents with hematuria and flank pain. Urinalysis shows isosthenuria (urine specific gravity ~1.010). Which of the

following is the most likely explanation? (Q851199)

A. Medullary infarction causing papillary necrosis

B. Glomerulonephritis due to immune complex deposition

C. Recurrent urinary tract infection causing tubular damage

D. Hyperfiltration injury from chronic anemia

Correct Answer: A. Medullary infarction causing papillary necrosis

Explanation: In sickle cell anemia, sickling in the hypertonic, hypoxic renal medulla can cause papillary necrosis , leading to hematuria and impaired urine concentrating ability (isosthenuria) . Glomerulonephritis due to immune complex deposition (Option B): Usually presents with proteinuria, hypertension, and not isolated hematuria with isosthenuria. Recurrent urinary tract infection causing tubular damage (Option C): Can cause hematuria, but isosthenuria is more typical of papillary necrosis. Hyperfiltration injury from chronic anemia (Option D): Leads to proteinuria and eventual CKD, not acute hematuria with isosthenuria.

References:

Harrison's Principles of Internal Medicine, 22nd Edition, Page 773-774.

↑ *Back to this question in Part A*

@Neet_pg_bot

Q3: For prenatal diagnosis of sickle cell anemia which is the best test? (Q851195)

A. NESTROFT

B. Sickling test

C. DNA analysis

D. Hb electrophoresis

Correct Answer: C. DNA analysis

Explanation: Prenatal diagnosis of sickle cell anemia requires molecular DNA analysis to detect the β-globin gene mutation in the fetus. DNA analysis (via CVS at 10–12 weeks or amniocentesis at 15–18 weeks) detects the specific HBB gene point mutation. NESTROFT (Option A): A screening test for β-thalassemia trait , not prenatal diagnosis. Sickling test (Option B): Detects HbS in peripheral blood , not suitable for fetal testing. Hb electrophoresis (Option D): Cannot reliably diagnose sickle cell in early gestation because fetal Hb (HbF) predominates.

References:

Harrison's Principles of Internal Medicine, 22nd Edition, Page 776.

↑ *Back to this question in Part A*

@Neet_pg_bot

Q4: Heinz bodies in G6PD deficiency is? (Q851193)

A. Denatured Hemoglobin

B. DNA remnants

C. RNA remnants

D. Iron granules

Correct Answer: A. Denatured Hemoglobin

Explanation: In G6PD deficiency , oxidative stress causes hemoglobin to denature and form Heinz bodies , which are visible with supravital staining . Composition Inclusion body Image DNA remnants (Option B) Howell- Jolly bodies RNA remnants (Option C) Basophilic stippling. Iron granules (Option D) Siderotic granules, seen with Prussian blue stain in sideroblastic anemia.

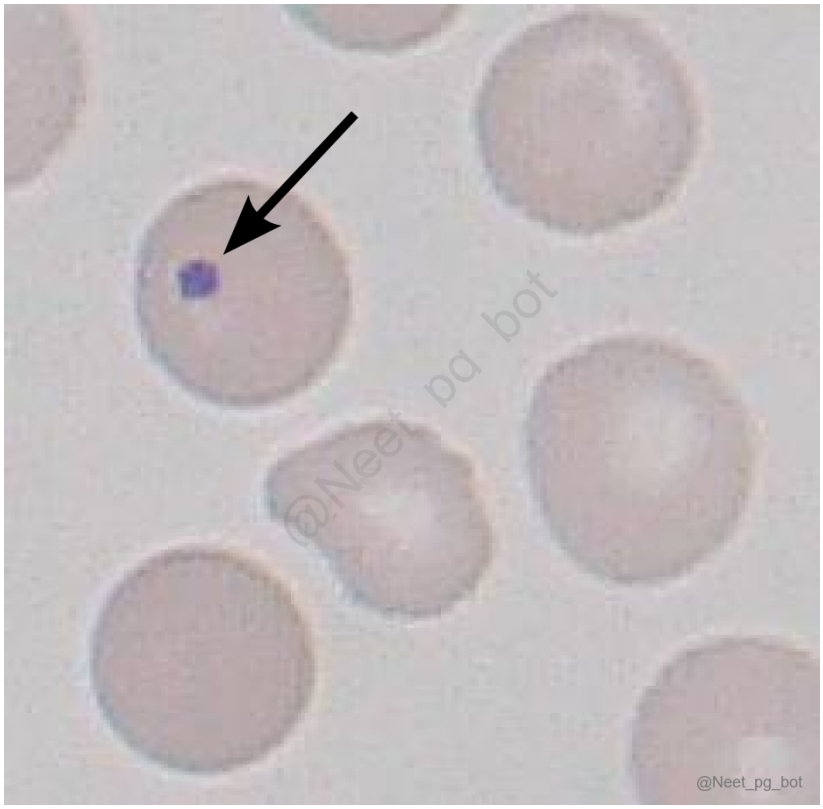

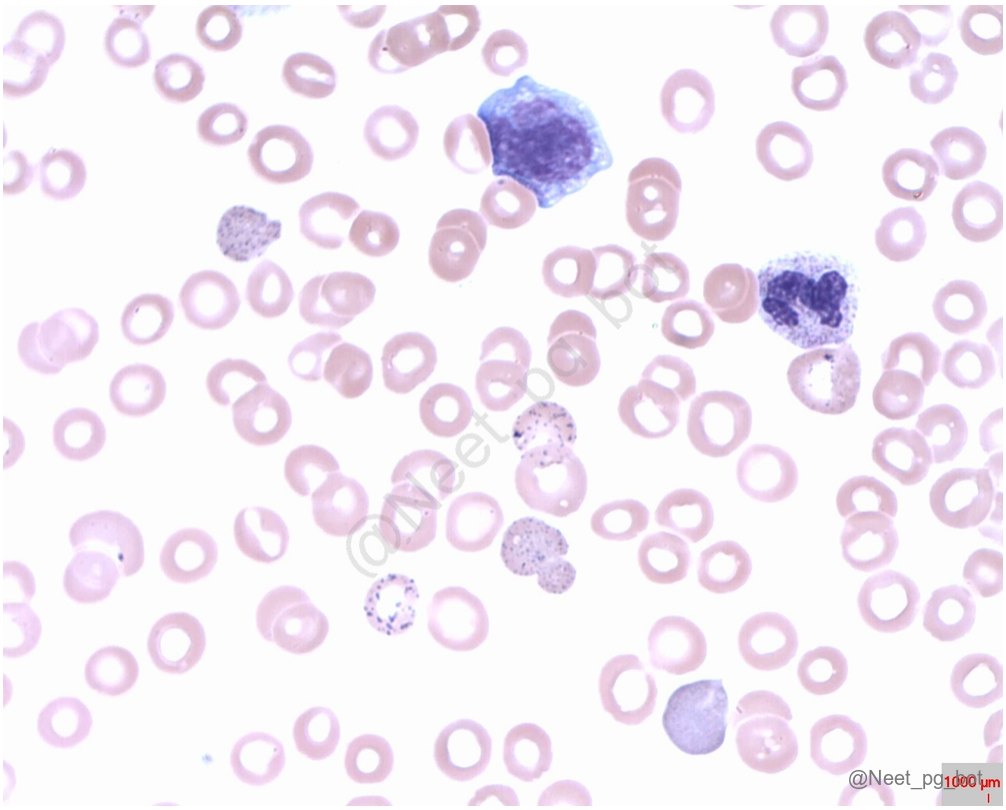

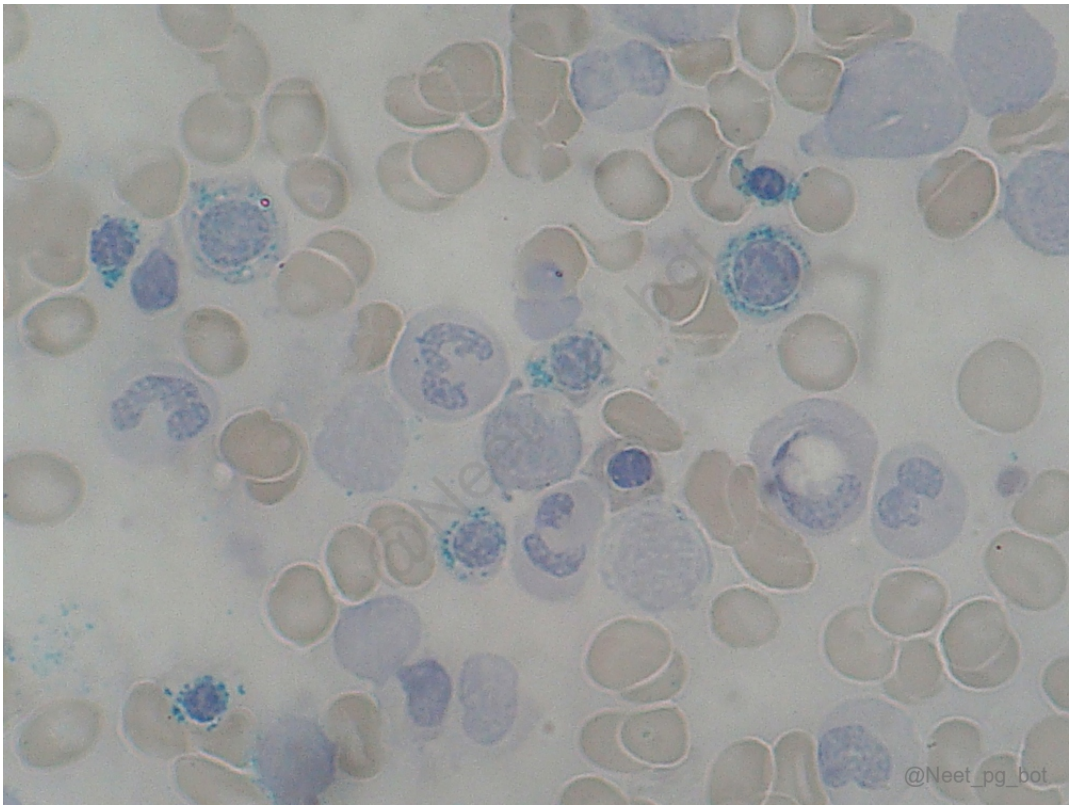

References:

Harrison's Principles of Internal Medicine, 22nd Edition, Page 798.

↑ *Back to this question in Part A*

@Neet_pg_bot

Q5: Which of the following is correctly matched? (Q851191)

A. Heinz bodies: Asplenia

B. Howell Jolly bodies: G6PD

C. Cabot rings : Dyserythropoiesis

D. Pappenheimer bodies: Lead poisoning

Correct Answer: C. Cabot rings : Dyserythropoiesis

Explanation: Option Inclusion body Given match Correct Association Verdict 1 Heinz bodies Asplenia Heinz bodies are denatured hemoglobin seen classically in G6PD deficiency , unstable hemoglobins, and oxidant drug exposure Incorrect 2 Howell-Jolly bodies G6PD Howell-Jolly bodies are nuclear DNA remnants seen in asplenia or hyposplenism Incorrect 3 Cabot rings Dyserythropoiesis Cabot rings represent mitotic spindle remnants seen in severe anemia, dyserythropoiesis, and megaloblastic anemia Correct 4 Pappenheimer bodies Lead poisoning Pappenheimer bodies are iron granules seen in sideroblastic anemia, thalassemia, and post-splenectomy states . Lead poisoning classically causes basophilic stippling , not Pappenheimer bodies. Incorrect

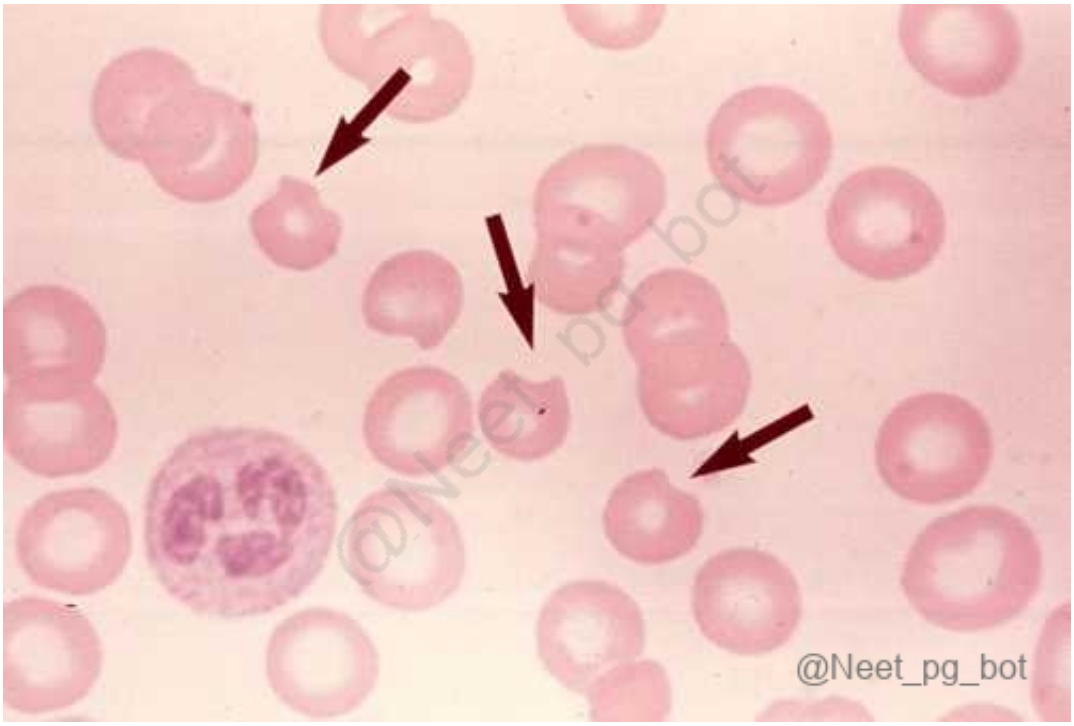

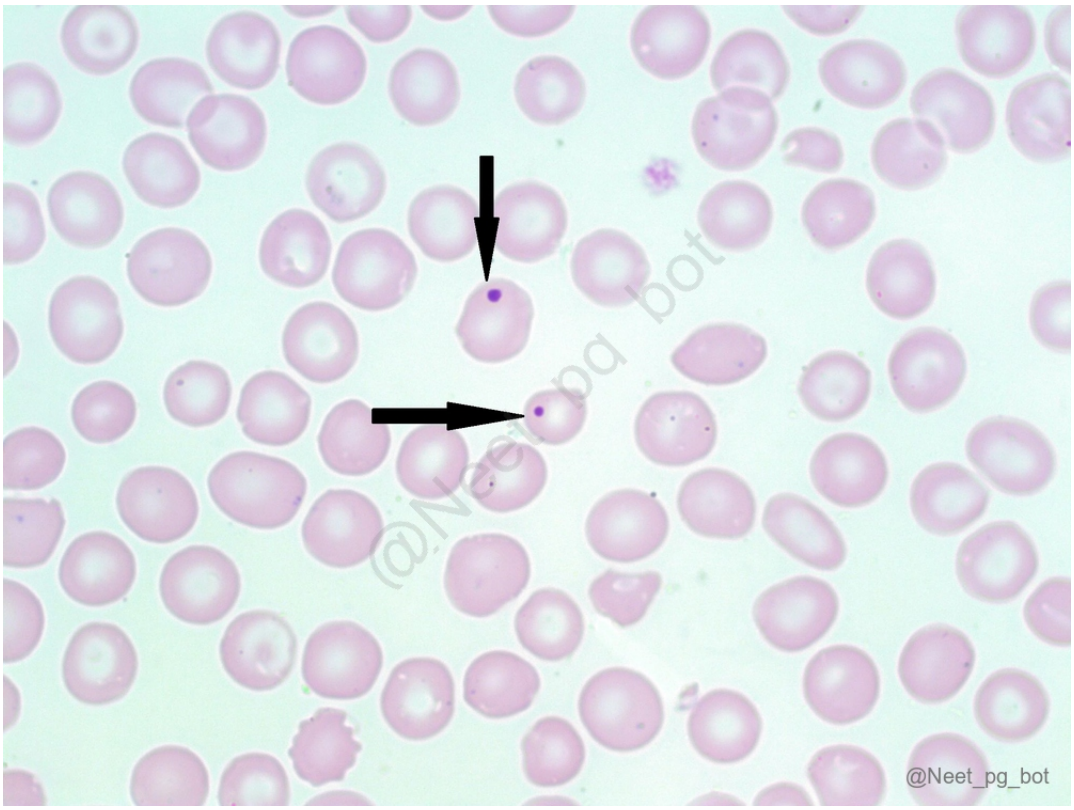
@Neet_pg_bot

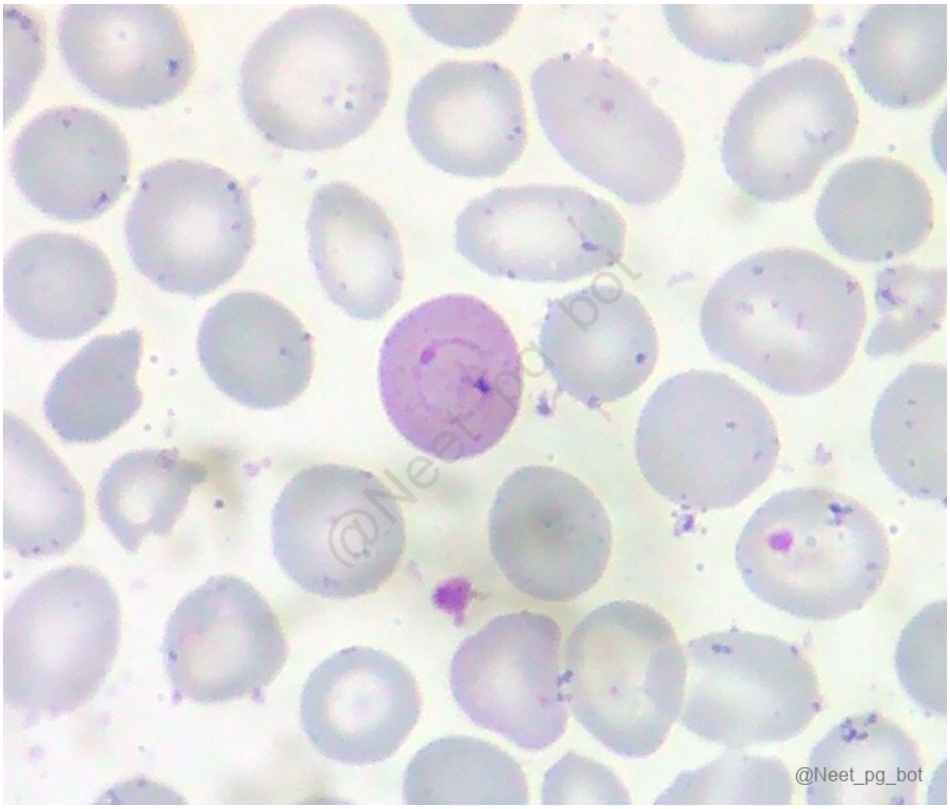
@Neet_pg_bot

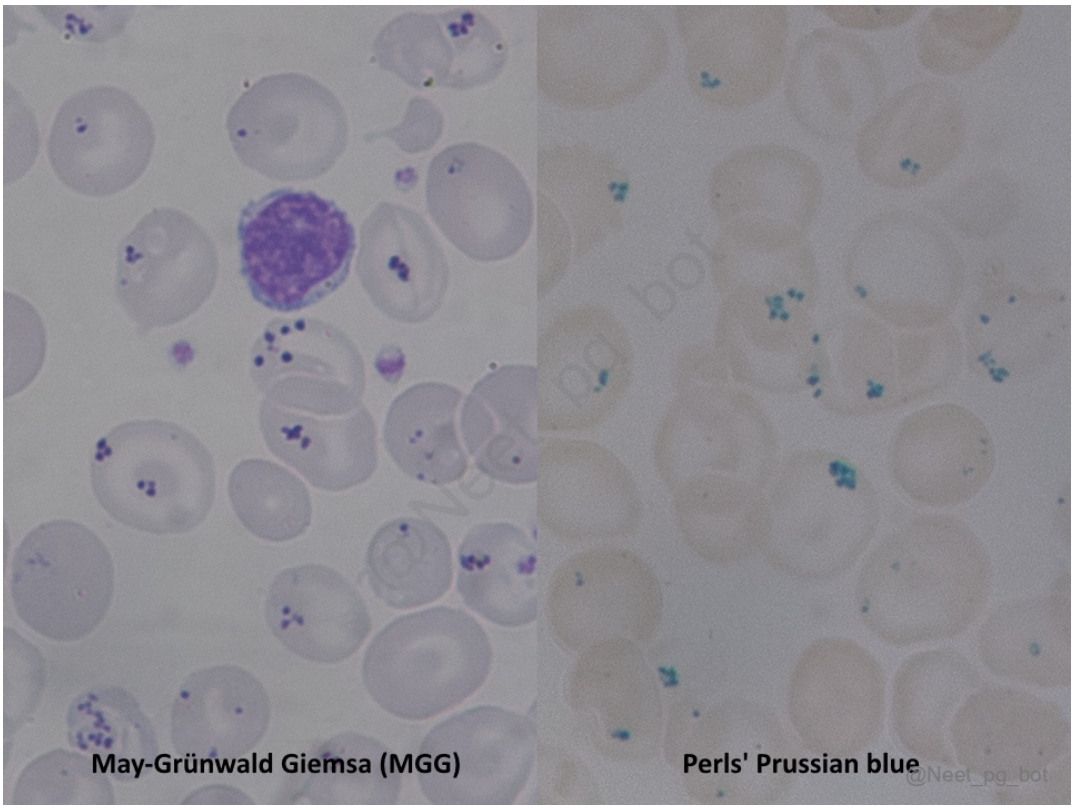

References:

www.ncbi.nlm.nih.gov/books/NBK594259/

↑ *Back to this question in Part A*

@Neet_pg_bot

Q6: Which of the following is correct about Paroxysmal nocturnal hemoglobinuria (Q851188)

A. Extravascular hemolysis

B. Sucrose hemolysis test is gold standard

C. Thrombosis of hepatic veins

D. Hypocellular bone marrow that becomes hypercellular in late stages

Correct Answer: C. Thrombosis of hepatic veins

Explanation: PNH occurs due to defects of PIGA gene and has CD55 and CD59 negativity. This makes Red blood cells susceptible to complement mediated destruction and results in intravascular hemolysis. (Option A) Sucrose

hemolysis is an outdated test and flow cytometry helps in diagnosis. (Option B) Due to RBC loss initially hypercellular marrow is seen with erythroid hyperplasia. Later hypocellular marrow or aplastic status may be seen. (Option D) PNH: Poor quality RBC that undergo complement mediated destruction: Black color urine and low Hb Poor quality WBC: so infections and low NAP score Poor quality Platelets that so spontaneous aggregation: Budd chiari syndrome, cerebral venous thrombosis.

References:

Harrison's Principles of Internal Medicine, 22nd Edition, Page 804-806.

↑ *Back to this question in Part A*

@Neet_pg_bot

Q7: A 6-year-old boy is brought to the clinic with multiple petechiae over his lower limbs and mild gum bleeding for 2 days. He had an upper respiratory infection about 3 weeks ago. Examination shows scattered ecchymoses and petechial rash but no hepatosplenomegaly or lymphadenopathy. CBC reveals: Hemoglobin: 12.4 g/dL, Total leukocyte count: 8,500/mm³ and Platelet count: 35,000/mm³ Peripheral smear confirms thrombocytopenia with normal RBC and WBC morphology. Coagulation profile is normal. What is the most likely diagnosis and next step in management? (Q851185)

A. Acute lymphoblastic leukemia; bone marrow biopsy

B. Acute immune thrombocytopenic purpura; observation

C. Hemophilia A; factor VIII assay

D. Thrombotic thrombocytopenic purpura; plasma exchange

Correct Answer: B. Acute immune thrombocytopenic purpura; observation

Explanation: This child has isolated thrombocytopenia after a viral infection with normal hemoglobin, WBC, and smear, consistent with acute ITP. Most children recover spontaneously and observation only unless there is severe bleeding or platelets <10,000/μL. Bone marrow exam is not required unless atypical features are present (e.g., organomegaly, anemia, leukopenia). Acute lymphoblastic leukemia; bone marrow biopsy (Option A): Would show abnormalities in other cell lines and often hepatosplenomegaly/lymphadenopathy. Hemophilia A; factor VIII assay (Option C): Would present with prolonged APTT and deep tissue bleeding, not isolated thrombocytopenia. Thrombotic thrombocytopenic purpura; plasma exchange (Option D): Typically presents with MAHA, renal/CNS involvement, fever, not isolated post-viral thrombocytopenia.

References:

Harrison's Principles of Internal Medicine, 22nd Edition, Page 924.

↑ *Back to this question in Part A*

@Neet_pg_bot

Q8: A patient with acute kidney injury is found to have hemolytic uremic syndrome. Which of the following is not correct about this patient? (Q851183)

A. Thrombocytopenia

B. Microangiopathic hemolytic anemia

C. Schistocytes

D. Antibodies to ADAMTS13

Correct Answer: D. Antibodies to ADAMTS13

Explanation: Hemolytic uremic syndrome (HUS) is characterized by the triad of microangiopathic hemolytic anemia, thrombocytopenia, and acute kidney injury . Peripheral smear shows schistocytes . HUS has shiga toxin induced microthrombi in kidney circulation causing renal shut down with MAHA and schistocytes. Antibodies to ADAMTS13 are seen in Thrombotic Thrombocytopenic Purpura (TTP) , not HUS. Autoimmune Hemolytic Anemia (AIHA) Hemolytic Uremic Syndrome (HUS) Primary Mechanism Antibody destruction. The patient's own autoantibodies (IgG or IgM) mistakenly tag and destroy their red blood cells. Mechanical destruction (Microangiopathy). Red blood cells are physically sheared and damaged as they pass through small blood vessels that are obstructed by microthrombi (tiny clots) Primary Cause Often idiopathic (unknown), secondary to lymphoma/leukemia, or triggered by drugs (like the antibiotics in the scenario) or viruses. Usually caused by a Shiga toxin-producing E. coli infection (STEC-HUS), leading to toxins damaging blood vessel walls. Key Clinical Triad Anemia, Jaundice, Splenomegaly (or Hepatosplenomegaly). Microangiopathic Hemolytic Anemia , Thrombocytopenia (low platelets), and Acute Kidney Injury (Uremia) . Diagnostic Test Direct Coombs Test (DAT) is positive. Schistocytes on smear. DAT is neagtive.

References:

Harrison's Principles of Internal Medicine, 22nd Edition, Page 800-801.

↑ *Back to this question in Part A*

@Neet_pg_bot

Q9: A 45-year-old diabetic with an HbA1c of 10% has been detected with a low EGFR of 10, has come for a hemodialysis session. His Hb is 6gm% with normocytic normochromic anemia. Which of the following is the first-line treatment for this patient? (Q851179)

A. Oral iron

B. Darbepoeitin

C. Hemodialysis

D. Roxadustat

Correct Answer: A. Oral iron

Explanation: Hemodialysis patients commonly develop iron deficiency due to repeated blood loss in the dialysis circuit. Iron stores must be replenished FIRST before giving erythropoiesis-stimulating agents (ESAs), otherwise ESAs will not be effective. Therefore, the first-line therapy in dialysis-associated anemia is iron supplementation , and among the given options, oral iron is correct. Darbepoetin (Option B)): Given after iron deficiency is corrected. Hemodialysis (Option C): Already being done; does not correct anemia. Roxadustat (Option D) is a hypoxia-inducible factor prolyl hydroxylase inhibitor (HIF-PHI) and is a newer oral drug for anemia in CKD.

References:

Harrison's Principles of Internal Medicine, 22nd Edition, Page 769.

↑ *Back to this question in Part A*

@Neet_pg_bot

Q10: Which of the following is correct about anemia of chronic disease? (Q851155)

A. Low serum iron, elevated serum ferritin, low erythropoietin

B. Low serum iron, low serum ferritin, low erythropoietin

C. High serum iron, low serum ferritin, low erythropoietin

D. High serum iron, elevated serum ferritin, low erythropoietin

Correct Answer: A. Low serum iron, elevated serum ferritin, low erythropoietin

Explanation: In anemia of chronic disease, also called anemia of inflammation, the key lab pattern is: Serum iron is low as iron is trapped in macrophages due to increased levels of hepcidin Ferritin is elevated as the stores are not utilized Erythropoietin is low due to blunted marrow stimulation Low ferritin (Option B) suggests iron deficiency anemia , not ACD.

References:

Harrison's Principles of Internal Medicine, 22nd Edition, Page 767-768.

↑ *Back to this question in Part A*

@Neet_pg_bot

Q11: A 55-year-old woman presents with fatigue, glossitis, and paresthesias. Laboratory tests show macrocytic anemia and low vitamin B12 levels. Further testing reveals the presence of parietal cell antibodies. What is the most common underlying cause of her condition? (Q851154)

A. Alcoholism

B. Autoimmune gastritis

C. Malabsorption syndrome

D. Ileal resection

Correct Answer: B. Autoimmune gastritis

Explanation: The most common cause of pernicious anemia is autoimmune gastritis , in which autoantibodies target parietal cells and intrinsic factor . Parietal cell antibodies are present in ~90% of patients and destroy the gastric proton pump (H■/K■-ATPase), leading to loss of intrinsic factor and impaired vitamin B12 absorption , resulting in megaloblastic anemia. Alcoholism (Option A): Causes folate deficiency, not pernicious anemia. Malabsorption syndrome (Option C): Causes B12 deficiency but not specifically pernicious anemia. Ileal resection (Option D): Prevents absorption of B12 but is not the primary cause of pernicious anemia.

References:

Harrison's Principles of Internal Medicine, 22nd Edition, Page 786.

↑ *Back to this question in Part A*

@Neet_pg_bot

Q12: Which of the following is true about hand and foot syndrome seen in sickle cell anemia? (Q851141)

A. Usually seen after 5 year of age

B. Infection with capsulated organisms causing osteomyelitis of small bones of hands

C. Causes swan neck joint deformities

D. X-ray-shows periostitis and soft tissue swelling

Correct Answer: D. X-ray-shows periostitis and soft tissue swelling

Explanation: Hand-foot syndrome (dactylitis) in sickle cell anemia presents with painful swelling of hands and feet , and X-ray may reveal periosteal reaction and soft tissue swelling . It is not seen after 5 years as hematopoiesis shifts out of the bone marrow after 5 years (Option A), it typically occurs in infants and toddlers <2 years . Osteomyelitis (Option B): not classic hand-foot syndrome. Causes swan neck joint deformities (Option C): Seen in rheumatoid arthritis .

References:

Harrison's Principles of Internal Medicine, 22nd Edition, Page 775-776.

↑ *Back to this question in Part A*

@Neet_pg_bot

Q13: Which of the following is correct about sickle cell anaemia? (Q851152)

A. Beta 7 valine residues cause polymerization of HbS on deoxygenation

B. Beta 7 valine residues cause polymerization of HbS on oxygenation

C. Beta 6 glutamate residues cause polymerization of HbS on oxygenation

D. Beta 6 glutamate residues cause polymerization of HbS on deoxygenation

Correct Answer: A. Beta 7 valine residues cause polymerization of HbS on deoxygenation

Explanation: Normal β-globin (HbA): Sixth amino acid = glutamate (hydrophilic). In sickle cell anemia, there is a point mutation in the β-globin gene where glutamic acid (polar) is replaced by valine (non-polar) at position 6 (sometimes referred to as the 7th amino acid due to counting differences). This hydrophobic valine promotes polymerization of deoxygenated HbS , causing RBC sickling. Later, the RBC became irreversibly deformed. Consequences: Hemolytic anemia, vaso-occlusion, and sickle cell complications. Polymerization occurs on deoxygenation. (Option B ruled out) . Mutation is at β6 glutamate → valine causing polymerization (Option C & D ruled out).

References:

Harrison's Principles of Internal Medicine, 22nd Edition, Page 772-773.

↑ *Back to this question in Part A*

@Neet_pg_bot

Q14: A patient is suspected of having sickle cell anemia. Which of the following hemoglobin electrophoresis patterns is most consistent with this diagnosis? (Q851151)

A. HbA absent , Hb S present, Hb F elevated, Hb A2 elevated

B. HbA present ,Hb S present, Hb F elevated, Hb A2 elevated

C. HbA present ,Hb S present , Hb F elevated, Hb A2 elevated

D. HbA absent , Hb S present, Hb F reduced , Hb A2 elevated

Correct Answer: A. HbA absent , Hb S present, Hb F elevated, Hb A2 elevated

Explanation: Sickle cell anemia (homozygous HbSS) results from mutation in both beta-globin genes , producing primarily HbS . HbA (normal adult hemoglobin) is absent , as no normal beta chains are produced. HbF (fetal hemoglobin) is usually elevated as a compensatory response and can ameliorate disease severity. HbA2 is slightly elevated . HbA present, HbS present, HbF elevated, HbA2 elevated (Option B) : Presence of HbA suggests sickle cell trait (HbAS) , not homozygous sickle cell anemia. HbA present, HbS present, HbF reduced, HbA2 normal (Option C) : HbA present → trait , not disease; reduced HbF is not typical in HbSS. HbA absent, HbS present, HbF reduced, HbA2 elevated (Option D): HbF is usually elevated in sickle cell anemia; reduced HbF is inconsistent with HbSS.

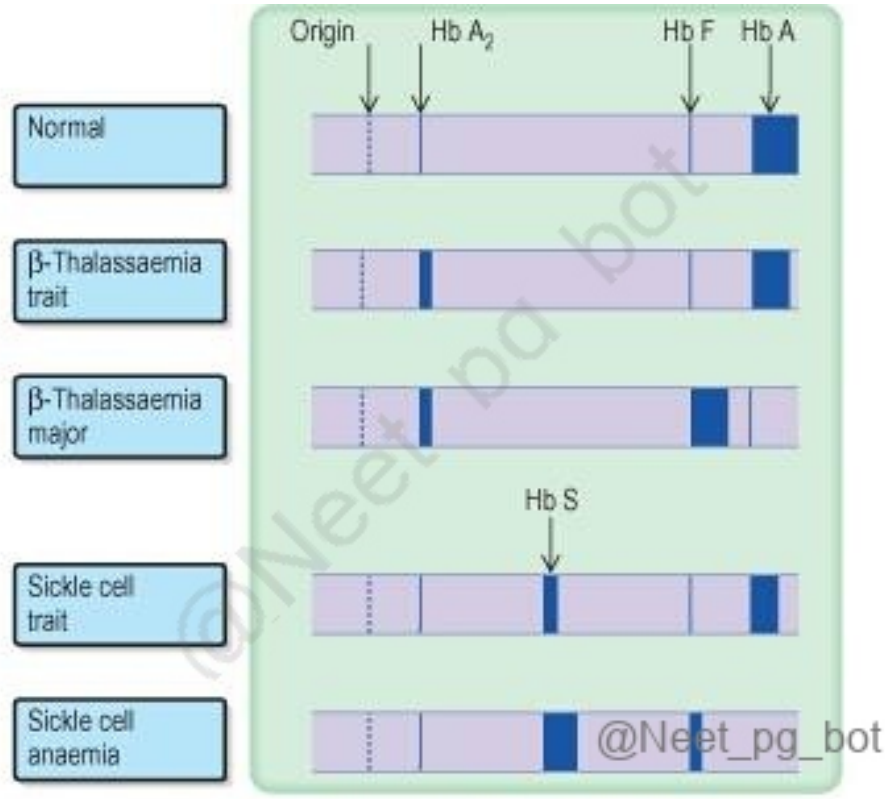

References:

Harrison's Principles of Internal Medicine, 22nd Edition, Page 774.

↑ *Back to this question in Part A*

@Neet_pg_bot

Q15: Which of the following is the earliest embryonic hemoglobin to appear? (Q851150)

A. Gower 1

B. Gower 2

C. Portland

D. Fetal hemoglobin

Correct Answer: A. Gower 1

Explanation: The earliest embryonic hemoglobin to appear is Hb Gower 1 (ζ■ε■) , seen in the yolk sac during the 3rd week of embryogenesis. Stage Hemoglobin types (order of appearance Site of synthesis 3-8 weeks Gower 1 - Gower 2 - Portland yolk sac 8 weeks -birth HbF (dominant), HbA appears late Liver - Spleen Birth -adult HbA (major), HbA, Small HbF Bone Marrow

References:

Harrison's Principles of Internal Medicine, 22nd Edition, Page 770.

↑ *Back to this question in Part A*

@Neet_pg_bot

Q16: A 15 year old patient presents with anemia with splenomegaly. P. Smear is shown below. Comment on the Peripheral smear shown below (Q851149)

A. Hereditary spherocytosis

B. Hereditary elliptocytosis

C. Hemolytic uremic syndrome

D. Pyropokilocytosis

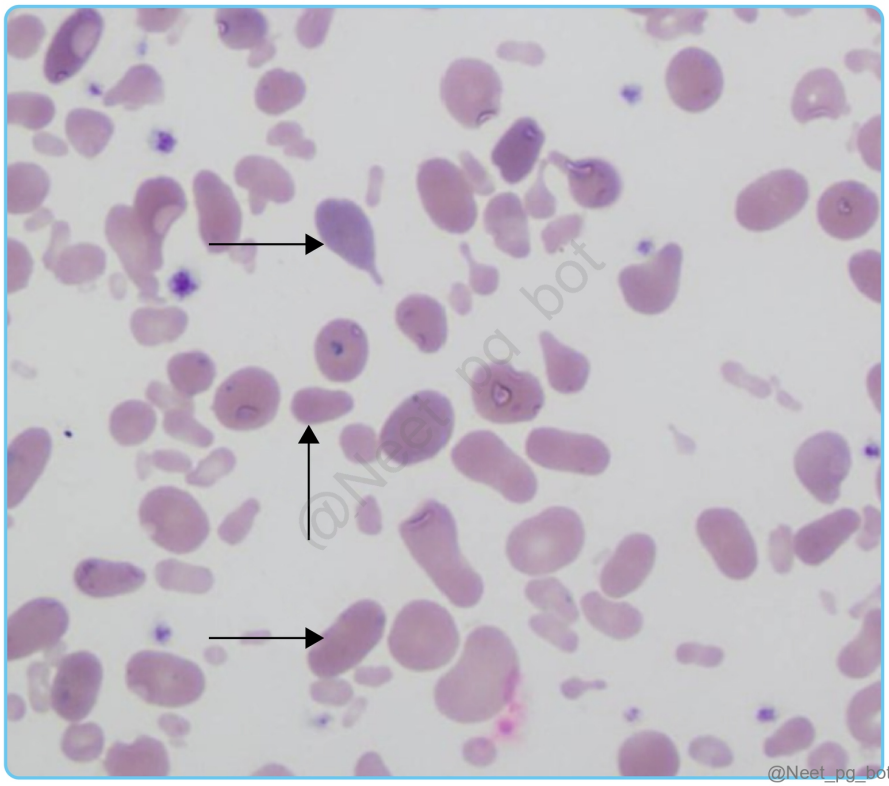

Correct Answer: D. Pyropokilocytosis

Explanation: The peripheral smear in hereditary pyropoikilocytosis shows marked poikilocytosis with fragmented RBCs, microspherocytes, and elliptocytes , often resembling a thermal burn smear. It is a severe variant of hereditary elliptocytosis, presenting with anemia and splenomegaly in childhood. Pyropoikilocytosis is a rare form of hereditary elliptocytosis characterized by extreme red blood cell shape abnormalities and marked thermal sensitivity of the RBC membrane. It is autosomal recessive and occurs when a person inherits two abnormal spectrin alleles. Hereditary spherocytosis (Option A): Shows uniform spherocytes with loss of central pallor. Hereditary elliptocytosis (Option B): Shows elliptocytes/ovalocytes , but not marked fragmentation. Hemolytic uremic syndrome (Option C): Shows schistocytes (helmet cells) due to microangiopathy.

References:

Harrison's Principles of Internal Medicine, 22nd Edition, Page 795.

↑ *Back to this question in Part A*

@Neet_pg_bot

Q17: A 5 year child born to consanguineous marriage is brought with complaints of pain in both hands over the metacarpals. Work up shows low Hb with increased reticulocyte count, increased LDH and low haptoglobin levels. Spleen is not palpable. Hb electrophoresis report is awaited. He has had previous hospitalizations for acute

abdomen. Diagnosis is? (Q851148)

A. Sickle cell anemia

B. Beta Thalassemia

C. Hereditary spherocytosis

D. ITP

Correct Answer: A. Sickle cell anemia

Explanation: The child has painful crises involving bones (metacarpals = dactylitis) , anemia with hemolytic features (↑ reticulocytes, ↑ LDH, ↓ haptoglobin), a history of acute abdomen (vaso-occlusive crises) , and autosplenectomy (non-palpable spleen). Repeated vaso-occlusion in the spleen causes autosplenectomy over time. The spleen becomes small, fibrotic, and eventually nonfunctional → may not be visualized on imaging - All classic for sickle cell anemia . Beta Thalassemia (Option B) : Causes anemia and splenomegaly, but not vaso-occlusive bone pain or autosplenectomy. Hereditary spherocytosis (Option C) : Causes splenomegaly, jaundice, spherocytes on smear, but not vaso-occlusive crises. ITP (Option D) : Causes isolated thrombocytopenia with bleeding, not hemolysis or bone pain.

References:

Harrison's Principles of Internal Medicine, 22nd Edition, Page 758.

↑ *Back to this question in Part A*

@Neet_pg_bot

Q18: Which of the following drugs can be used in patients with G6PD? (Q851147)

A. Primaquine

B. Artesunate

C. Dapsone

D. Rasburicase

Correct Answer: B. Artesunate

Explanation: rtesunate is an antimalarial drug belonging to the artemisinin class. It does not cause oxidative stress in red blood cells and is therefore safe in patients with G6PD deficiency. Incorrect Options: Option A – Primaquine: Primaquine is an 8-aminoquinoline antimalarial that induces oxidative hemolysis in G6PD-deficient individuals, making it unsafe. Option C – Dapsone: Dapsone is an oxidant drug used in leprosy and prophylaxis of Pneumocystis jirovecii; it can trigger hemolytic anemia in G6PD deficiency. Option D – Rasburicase: Rasburicase,

used to prevent tumor lysis syndrome, generates hydrogen peroxide and can cause severe hemolysis in G6PD-deficient patients.

References:

Harrison's Principles of Internal Medicine, 22nd Edition, Page 799.

↑ *Back to this question in Part A*

@Neet_pg_bot

Q19: Peripheral smear of a neonate with jaundice shows normocytic normochromic anemia with anisocytosis and poikilocytosis with RBC showing unevenly distributed hemoglobin " hemighosts" or "blister cells". This is seen in which of the following? (Q851146)

A. Abetalipoproteinemia

B. Hemolytic uremic syndrome

C. G6PDdeficiency

D. Pyruvate kinase deficiency

Correct Answer: C. G6PDdeficiency

Explanation: The findings given here are of bite cells containing denatured hemoglobin. Oxidative stress damages hemoglobin in the absence of glucose-6-phosphate dehydrogenase. The clinical hint is of neonatal jaundice. G6PD deficiency can present in premature babies with infection or environmental risk factors like naphthalene camphor balls that may be used in babies bedding and clothing. In G6PD deficiency , oxidative stress leads to RBC damage, producing "blister cells" or "hemighost cells" , where hemoglobin is unevenly distributed due to oxidative denaturation. Abetalipoproteinemia (Option A): Shows acanthocytes (spur cells) , not blister cells. Hemolytic uremic syndrome (Option B): Peripheral smear shows schistocytes (fragmented RBCs) . Pyruvate kinase deficiency (Option D): Causes echinocytes (burr cells) due to ATP depletion.

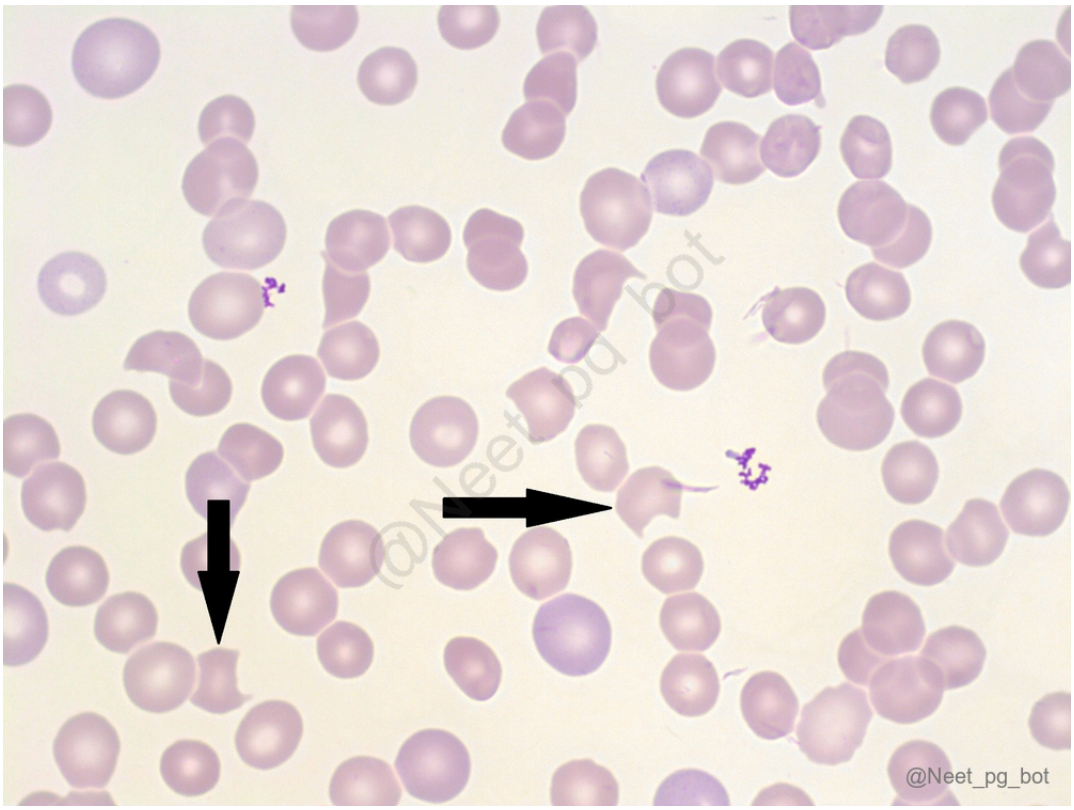
@Neet_pg_bot

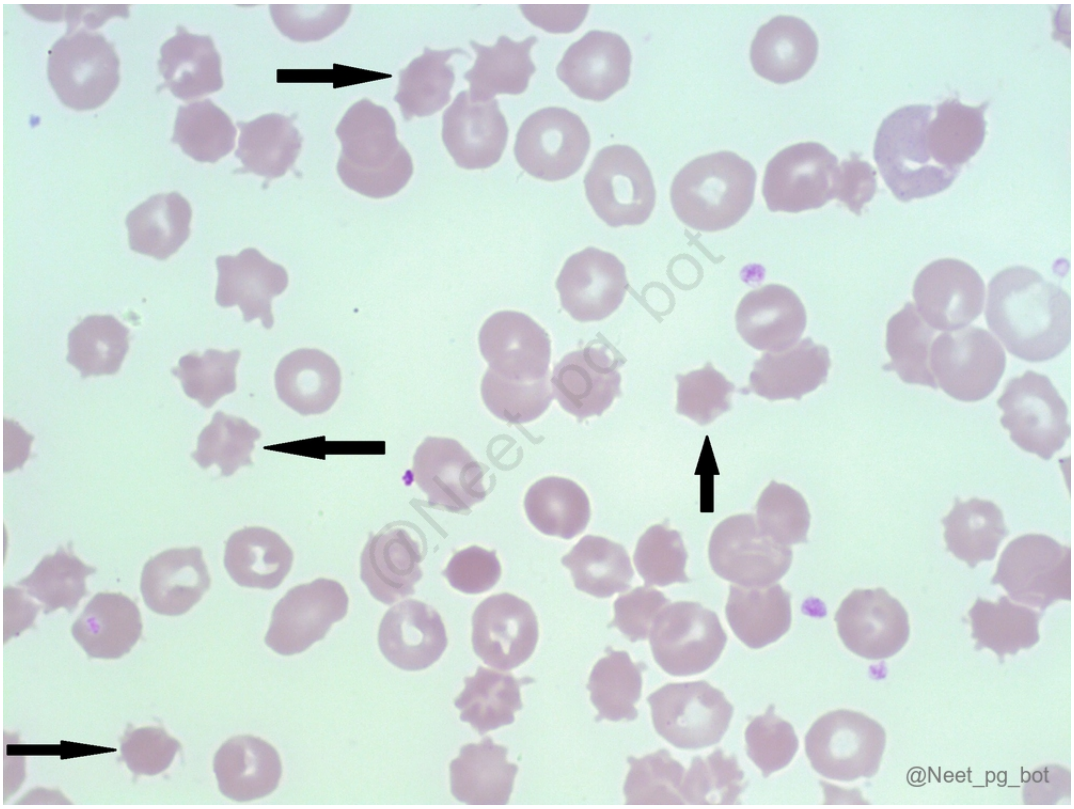
@Neet_pg_bot

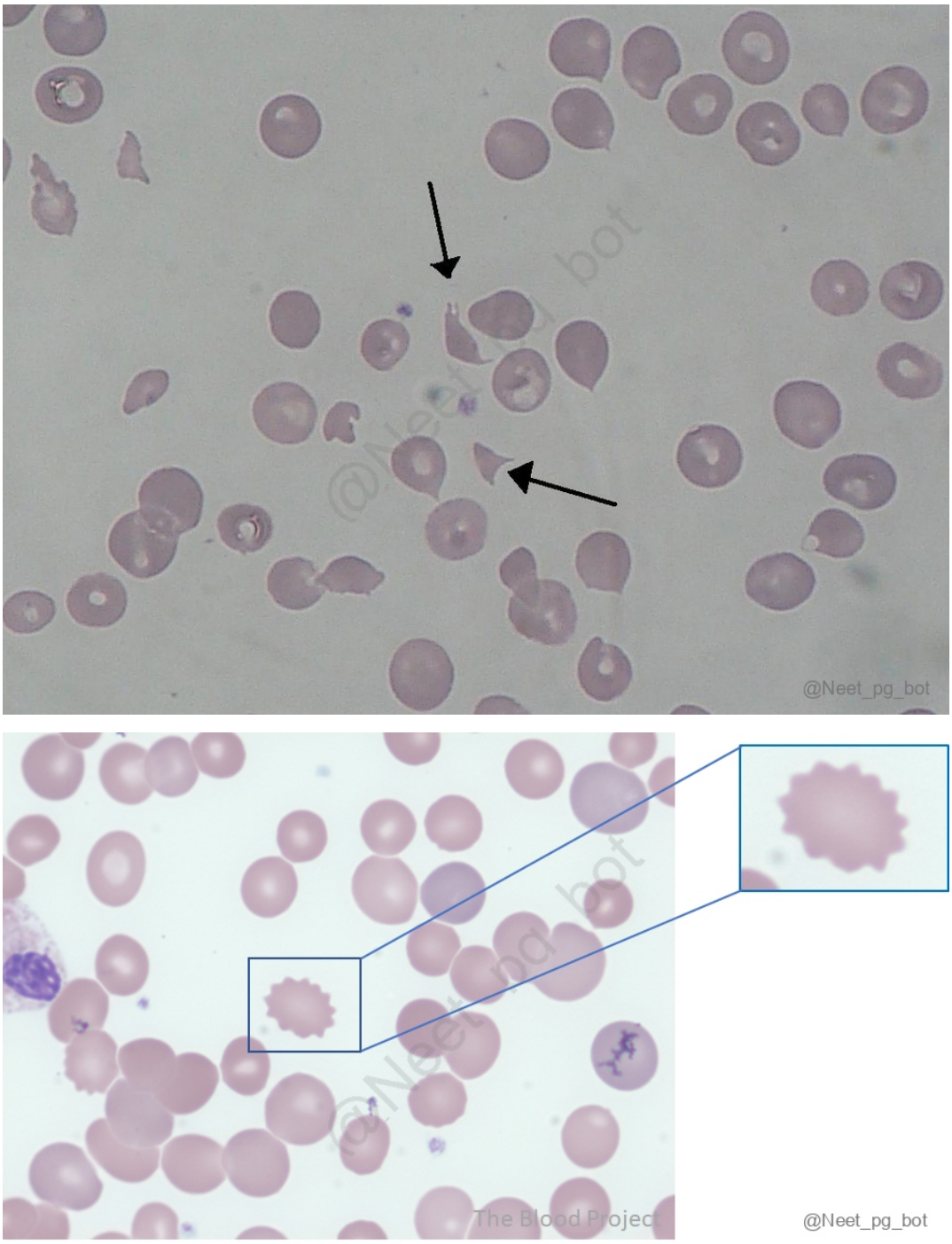

References:

Harrison's Principles of Internal Medicine, 22nd Edition, Page 797.

↑ *Back to this question in Part A*

@Neet_pg_bot

Q20: A 5 year old child is brought with complaints of pain in hands. On examination he has severe pallor, elevated LDH and low haptoglobin. The HPLC report is shown below. Which of the following is the drug of choice for this patient? (Q851144)

A. Hydroxy urea

B. Azacytidine

C. Voxeletor

D. Bortezomib

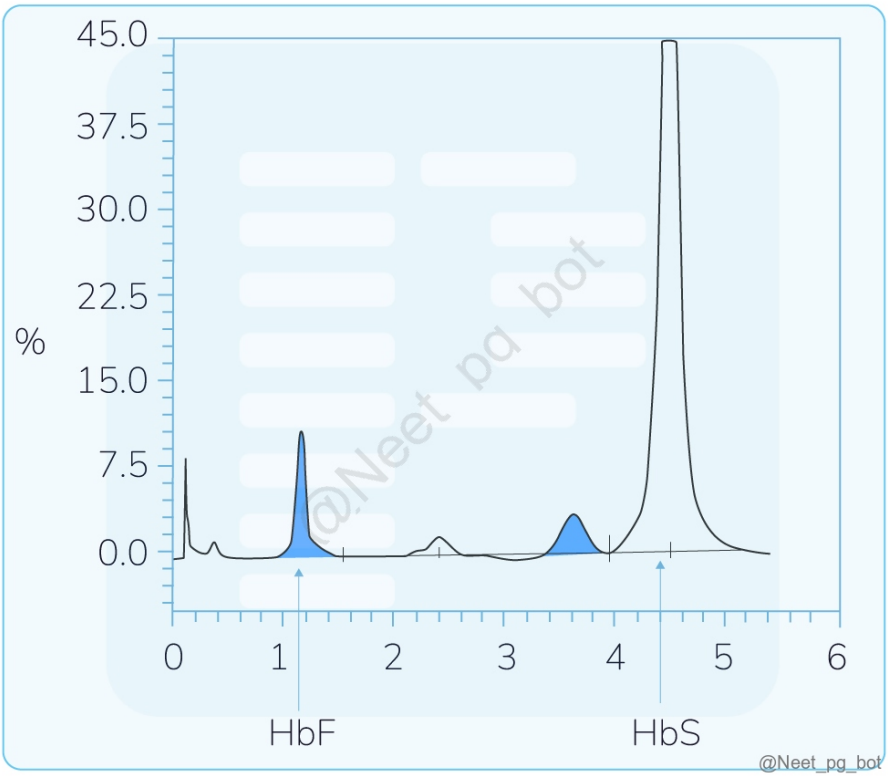

Correct Answer: A. Hydroxy urea

Explanation: The clinical diagnosis is sickle cell anemia, and hydroxyurea is the drug of choice for patients of all ages, regardless of symptom profile. The major mechanism of action of hydroxyurea is to induce high levels of HbF so that cells have greater protection from HbS polymerization than others. Azacytidine (Option B) is used in MDS. Voxeltor (Option C) has recently been recalled. Bortezomib (Option D) is used in multiple myeloma.

References:

Harrison's Principles of Internal Medicine, 22nd Edition, Page 775.

↑ *Back to this question in Part A*

@Neet_pg_bot

Q21: Which of the following treatments is curative in sickle cell anemia? (Q851142)

A. Hyroxyurea

B. Hematopoietic stem cell transplantation

C. Voxelotor

D. Packed RBC transfusions

Correct Answer: B. Hematopoietic stem cell transplantation

Explanation: Allogeneic hematopoietic stem cell transplantation (HSCT) is currently the only curative treatment for sickle cell anemia, replacing defective hematopoietic stem cells with healthy donor cells. Hydroxyurea (Option A): Increases HbF and reduces vaso-occlusive crises and complications but not curative . Voxelotor (Option C): HbS polymerization inhibitor and has recently been withdrawn. Packed RBC transfusions (Option D): Manage anemia and prevent complications, not curative .

References:

Harrison's Principles of Internal Medicine, 22nd Edition, Page 776.

↑ *Back to this question in Part A*

@Neet_pg_bot

• [06_Hematology] 045 Platelet Disorders And Hematology Images

« Back to Folder Directory

[06_Hematology] 045 Platelet Disorders And Hematology Images — Quick Jump

Q1 (p. 2112)	*Q2 (p. 2113)*	*Q3 (p. 2114)*	*Q4 (p. 2115)*	*Q5 (p. 2115)*	*Q6 (p. 2116)*
Q7 (p. 2117)	*Q8 (p. 2117)*	*Q9 (p. 2118)*	*Q10 (p. 2119)*	*Q11 (p. 2119)*	*Q12 (p. 2122)*
Q13 (p. 2125)	*Q14 (p. 2125)*	*Q15 (p. 2126)*	*Q16 (p. 2129)*	*Q17 (p. 2130)*	*Q18 (p. 2131)*
Q19 (p. 2132)	*Q20 (p. 2133)*	*Q21 (p. 2134)*	*Q22 (p. 2134)*	*Q23 (p. 2135)*	*Q24 (p. 2136)*

Q1: A 6-year-old boy presents with recurrent skin and respiratory infections since infancy. Examination reveals partial albinism and peripheral neuropathy. Peripheral smear is shown below. Which of the following is the most likely underlying defect? (Q851167)

A. Defective lysosomal trafficking

B. NADPH oxidase deficiency

C. Defective adhesion molecule

D. Myeloperoxidase deficiency

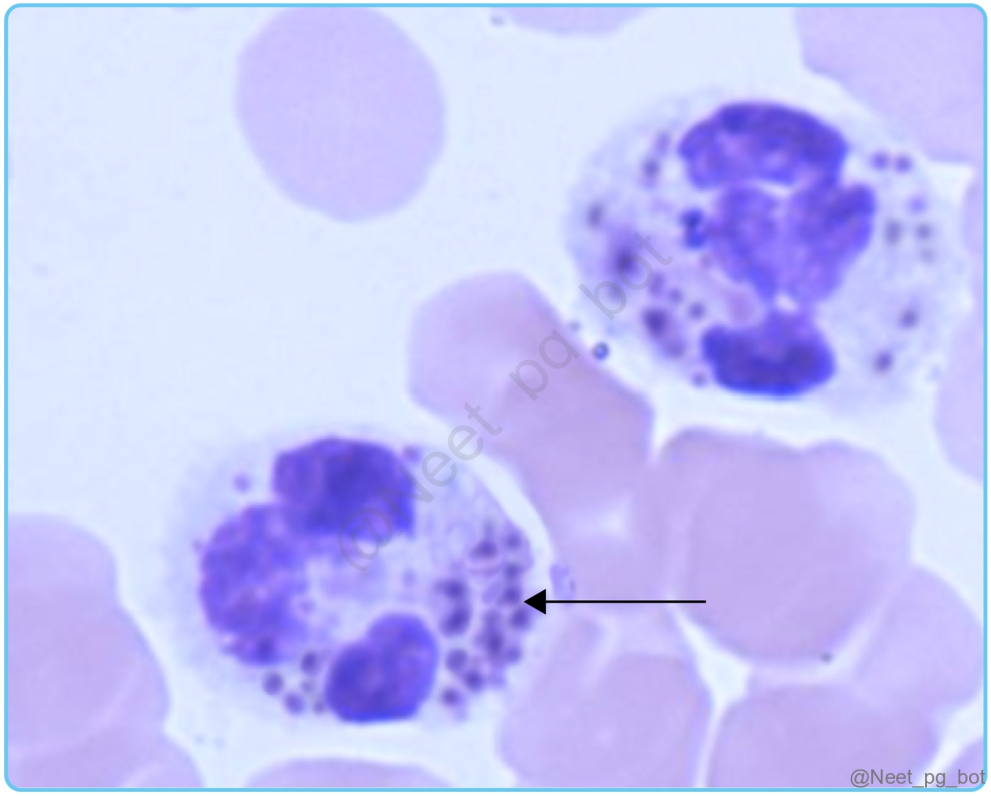

Correct Answer: A. Defective lysosomal trafficking

Explanation: The slide shows giant granules in the cytoplasm of neutrophil. This along with history of recurrent infections and albinism points to diagnosis as Chediak higashi syndrome. It occurs due to LYST gene mutation on chromosome 1 that leads to impaired microtubule-dependent trafficking of lysosomes. This causes defective phagolysosomal fusion and trafficking inside the neutrophils. NADPH oxidase deficiency (Option B) is seen in chronic granulomatous disease and leads to recurrent catalase-positive infections, defective oxidative burst (diagnosed by DHR test). CD18 defect seen in Leukocyte adhesion deficiency (Option C) . It presents with delayed umbilical cord separation and recurrent infections without pus Myeloperoxidase deficiency (Option D) is usually asymptomatic, impaired killing of Candida

References:

Harrison's Principles of Internal Medicine, 22nd Edition, Page 458.

↑ *Back to this question in Part A*

@Neet_pg_bot

Q2: Which of the following statements regarding von Willebrand disease is not true? (Q866839)

A. Type 2 vWD is associated with a moderate bleeding tendency

B. Type 3 vWD is associated with a complete absence of factor VIII

C. Type 1 vWD presents with severe bleeding since childhood

D. Type 2 vWD includes subtypes with varying defects in the von Willebrand factor

Correct Answer: C. Type 1 vWD presents with severe bleeding since childhood

Explanation: Types of Von Willebrand Disease Quantitative defect in Von Willebrand Factor Type 1 Partial quantitative deficiency of vWF Type 3 Virtually complete deficiency of vWF Quantitative defect in Von Willebrand Factor Type 2A Point mutation leading to variant in vWF molecule with increased susceptibility to proteolysis of ADAMTS13 Type 2B Mutations causing increasing affinity of vWF to platelet glycoprotein Type 2M Qualitative variant with decreased platelet dependent function Type 2N Qualitative variant with markedly decreased affinity for factors VIII

References:

Harrison's Principles of Internal Medicine, 22nd Edition, Page 926-927.

↑ *Back to this question in Part A*

@Neet_pg_bot

Q3: Which of the following is the correct presentation of Bernard–Soulier syndrome? (Q851177)

A. Presence of large platelets with thrombocytopenia and defective platelet adhesion

B. Small platelets, eczema, recurrent infections, and thrombocytopenia due to an X-linked disorder

C. Umbilical stump bleeding on day 1 of life

D. Normal platelet count with defective platelet aggregation caused by absent GPIIb/IIIa receptors

Correct Answer: A. Presence of large platelets with thrombocytopenia and defective platelet adhesion

Explanation: Bernard–Soulier syndrome is an autosomal recessive disorder caused by deficiency of GpIb receptor Platelets hence cannot bind vWF leading to defective adhesion . Peripheral smear shows giant platelets with thrombocytopenia. Wiskott–Aldrich syndrome (Option B) i s X-linked disorder: triad of eczema, recurrent infections, and thrombocytopenia with small platelets . Factor XIII deficiency (Option C) presents with umbilical stump bleeding in neonates (day 1–2 of life) , poor wound healing, and recurrent intracranial hemorrhage. PT, aPTT, BT all normal . Glanzmann thrombasthenia (Option D) is an autosomal recessive defect of GpIIb/IIIa receptor and platelets cannot bind fibrinogen and leads to defective aggregation .

References:

Harrison's Principles of Internal Medicine, 22nd Edition, Page 926.

↑ *Back to this question in Part A*

@Neet_pg_bot

Q4: Which of the following is correct about the mechanism of action of Ticagrelor? (Q851176)

A. Inhibiting P2Y12 , ADP receptor

B. Acetylation of COX-1

C. Blocking activated glycoprotein Gp IIb/IIIa

D. Inhibiting production of COX-1

Correct Answer: A. Inhibiting P2Y12 , ADP receptor

Explanation:

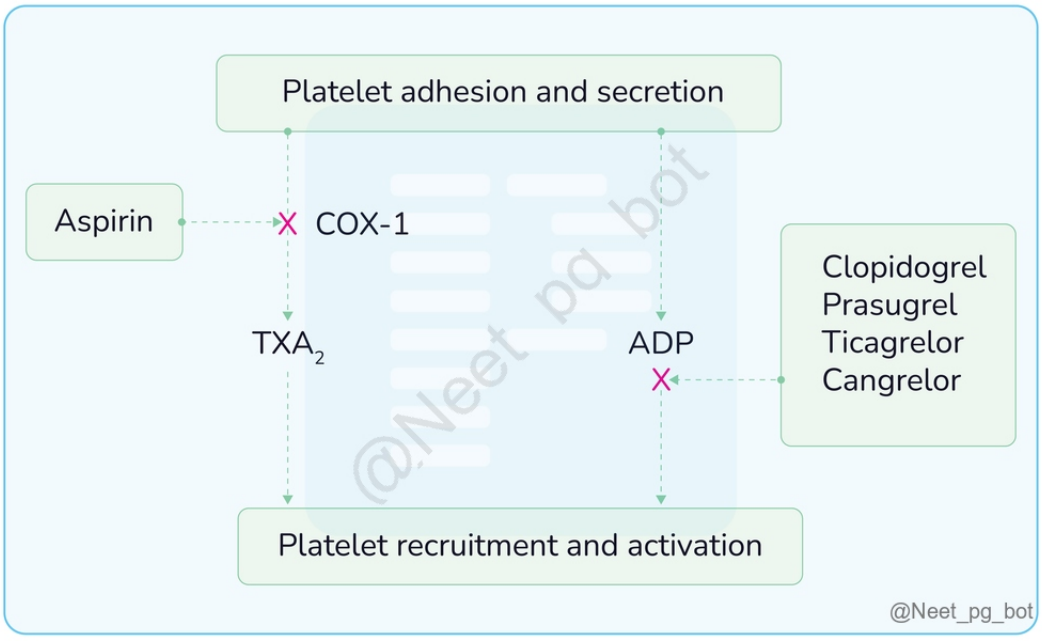

References:

Harrison's Principles of Internal Medicine, 22nd Edition, Page 939.

↑ *Back to this question in Part A*

@Neet_pg_bot

Q5: What is the life span of a platelet in the body? (Q851175)

A. 3-5 days

B. 5-7 days

C. 7-10 days

D. 10-14 days

Correct Answer: C. 7-10 days

Explanation: Life span of platelets Physiological in body 7-10 days (no consumption and no alloimmunization) Storage in blood bank at 20-24 C 3-5 days Special situations like DHF, DIC 24 hours

References:

Harrison's Principles of Internal Medicine, 22nd Edition, Page 937.

↑ *Back to this question in Part A*

@Neet_pg_bot

Q6: A 30 year old multigravida post-partum female developed multiple bruises and ecchymosis after delivery. coagulogram shows prolonged aPTT, normal TT and normal PT. and TT and a mixing study that does not correct with normal pooled plasma. The Bethesda assay using factor-specific deficient plasma is planned. What is the first differential diagnosis? (Q851174)

A. Von Willebrand disease

B. HELLP syndrome

C. Acquired Hemophilia A

D. DIC

Correct Answer: C. Acquired Hemophilia A

Explanation: Post-partum women can develop autoantibodies against factor VIII. This causes isolated prolonged aPTT that fails to correct on mixing study , and diagnosis is confirmed with a Bethesda assay. Von Willebrand disease (Option A): Also prolongs aPTT, but mixing study corrects since it is a deficiency, not an inhibitor. HELLP syndrome (Option B): Presents with hemolysis, elevated liver enzymes, and thrombocytopenia DIC (Option D): Causes both PT and aPTT prolongation with low fibrinogen and thrombocytopenia

References:

Harrison's Principles of Internal Medicine, 22nd Edition, Page 936.

↑ *Back to this question in Part A*

@Neet_pg_bot

Q7: Which of the following cause/s lead to DIC? a. Fulminant hepatic failure b. Acute promyelocytic leukemia c. Carcinoma prostate d. Fungal sepsis (Q851173)

A. b,c,d

B. a,c,d

C. a,b,d

D. a,b,c,d

Correct Answer: D. a,b,c,d

Explanation: DIC is triggered by widespread activation of coagulation. Conditions known to cause DIC include: Fulminant hepatic failure → reduced synthesis of clotting and anticoagulant factors Acute promyelocytic leukemia → Auer rods release procoagulants Carcinoma prostate (and pancreas) → tumors release tissue factor–like procoagulants Sepsis (bacterial, viral, fungal) → most common cause via cytokine-mediated coagulation activation

References:

Harrison's Principles of Internal Medicine, 22nd Edition, Page 933.

↑ *Back to this question in Part A*

@Neet_pg_bot

Q8: A 9-year old with acquired factor IX deficiency. However, the coagulation abnormality corrected after administration of Vitamin K. What is the most likely diagnosis? (Q851172)

A. Classic Hemophilia

B. Pernicious anemia

C. Hepatitis A

D. Bile duct obstruction

Correct Answer: D. Bile duct obstruction

Explanation: Acquired factor IX deficiency can occur in Vitamin K deficiency because factor IX is a Vitamin K–dependent clotting factor (along with II, VII, X, and proteins C & S). Now the correction with Vitamin K strongly suggests that this is not true factor IX deficiency (i.e. Hemophilia B, which does not correct with Vitamin K), but rather a Vitamin K deficiency state. In children, bile duct obstruction (cholestasis) causes fat-soluble vitamin malabsorption. This causes Vitamin K deficiency that will reduce the levels of factors II, VII, IX, X and cause prolonged PT/PTT, which corrects with Vitamin K.

References:

Harrison's Principles of Internal Medicine, 22nd Edition, Page 473.

↑ *Back to this question in Part A*

@Neet_pg_bot

Q9: Which of the following are used in non transfusion therapy for hemophilia A? a. Factor VIII concentrate b. Cryoprecipitate c. DDAVP d. Epsilon amino caproic acid (Q851171)

A. a,b

B. a,c

C. a,d

D. c,d

Correct Answer: D. c,d

Explanation: The question is on non-transfusion therapy that uses DDAVP and Epsilon amino caproic acid.
DDAVP (Desmopressin): Non-transfusion therapy. It causes transient increase in circulating Factor VIII and vWF by stimulating their release from endothelial stores. Effective in mild Hemophilia A and vWD.
Epsilon-aminocaproic acid (EACA): An antifibrinolytic agent that stabilizes clots by inhibiting plasminogen activation, preventing breakdown of fibrin clots. Useful as adjunctive therapy in mucosal bleeding. Factor VIII concentrate and Cryoprecipitate are transfusion therapies (replacement of deficient clotting factor).

References:

Harrison's Principles of Internal Medicine, 22nd Edition, Page 930.

↑ *Back to this question in Part A*

@Neet_pg_bot

Q10: Which clotting factor has the longest half life? (Q851170)

A. 2

B. 7

C. 9

D. 13

Correct Answer: D. 13

Explanation: Factor XIII (fibrin-stabilizing factor) has the longest half-life (9-12 days) . Factor VII has the shortest half-life (4–6 hours). Factor II (prothrombin): ~60–72 hours. Factor IX: ~18–24 hours.

References:

Harrison's Principles of Internal Medicine, 22nd Edition, Page 928.

↑ *Back to this question in Part A*

@Neet_pg_bot

Q11: The following inclusions inside RBC are called _____ (Q851169)

A. Dohle bodies

B. Pappenheimer bodies

C. Howell Jolly bodies

D. Dutcher bodies

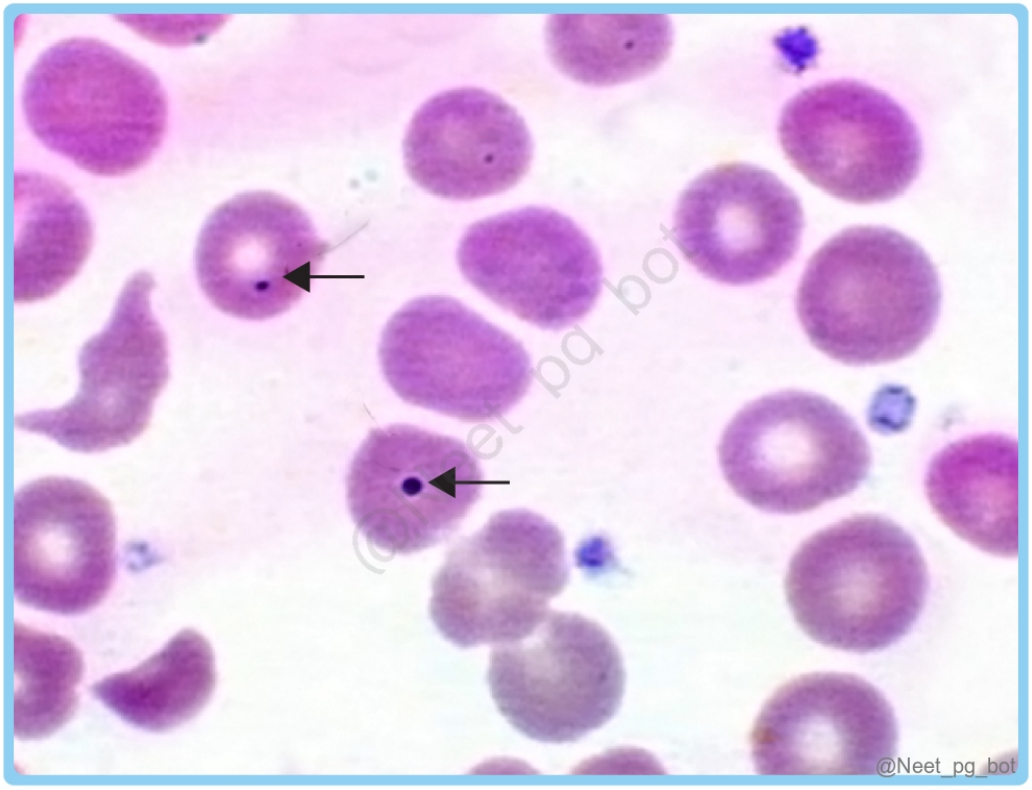

Correct Answer: C. Howell Jolly bodies

Explanation: The image shows solitary basophilic inclusion inside RBC which is Howell jolly bodies. Dohle bodies (Option A) are seen in Neutrophils. Dutcher bodies (Option D) are seen in plasma cells. Pappenheimer bodies (Option B) are multiple bodies inside RBC. Howell Jolly bodies (Option C) Dohle bodies (Option A) Pappenheimer bodies (Option B) Dutcher bodies (Option D)

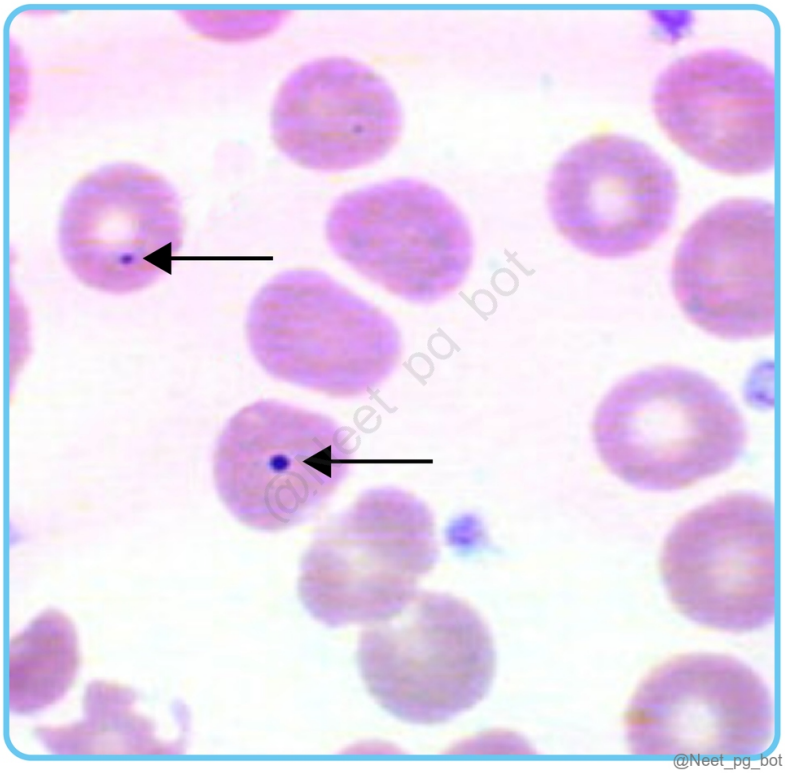
@Neet_pg_bot

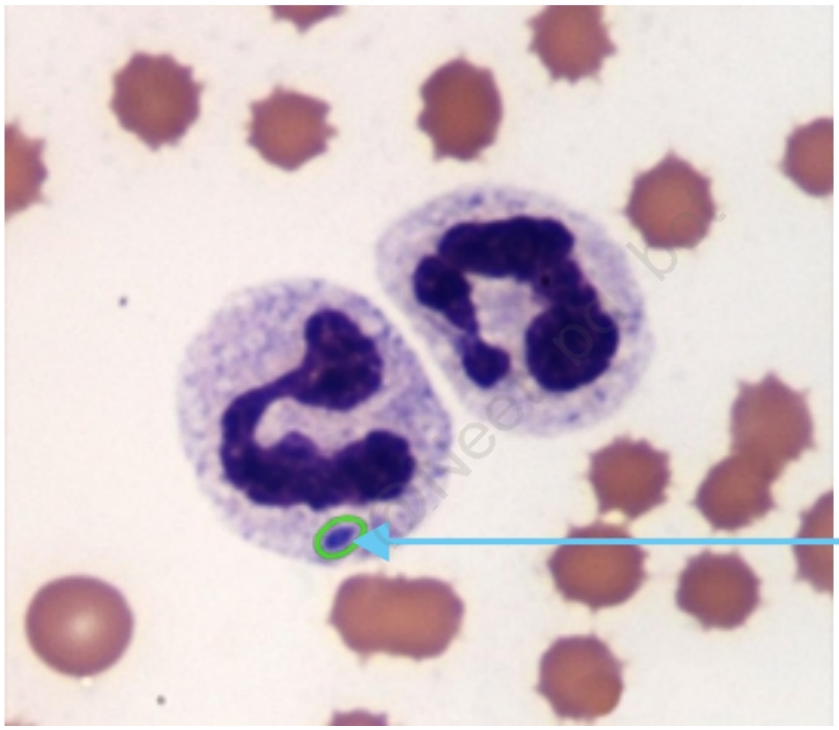
Dohle
Bodies
@Neet_pg_bot



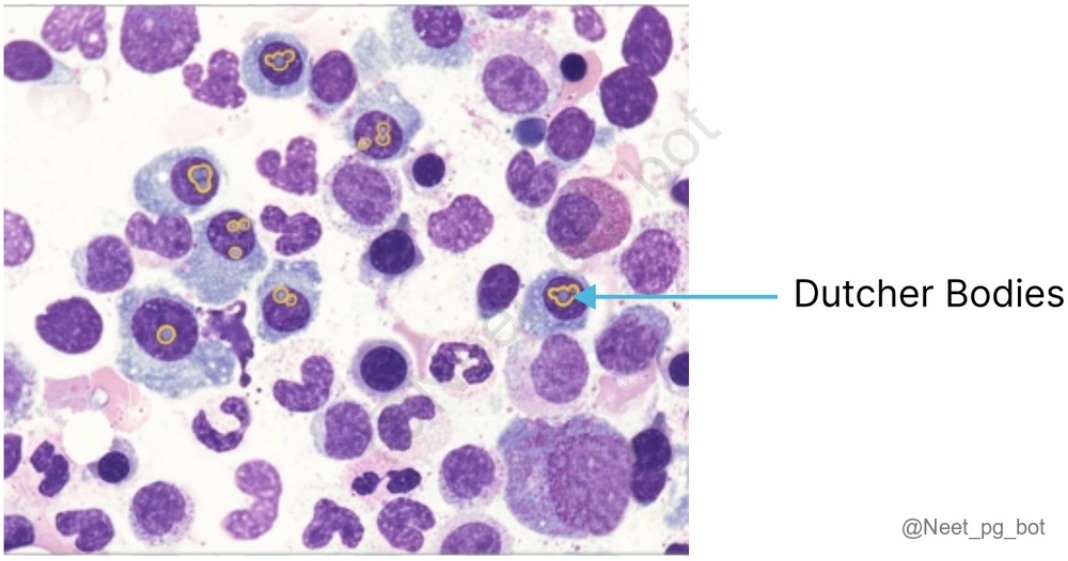

References:

Harrison's Principles of Internal Medicine, 22nd Edition, Page 482.

↑ *Back to this question in Part A*

@Neet_pg_bot

Q12: The following inclusions in neutrophils are seen in? (Q851168)

A. Burns

B. Chediak higashi granules

C. Celiac sprue

D. Whipple disease

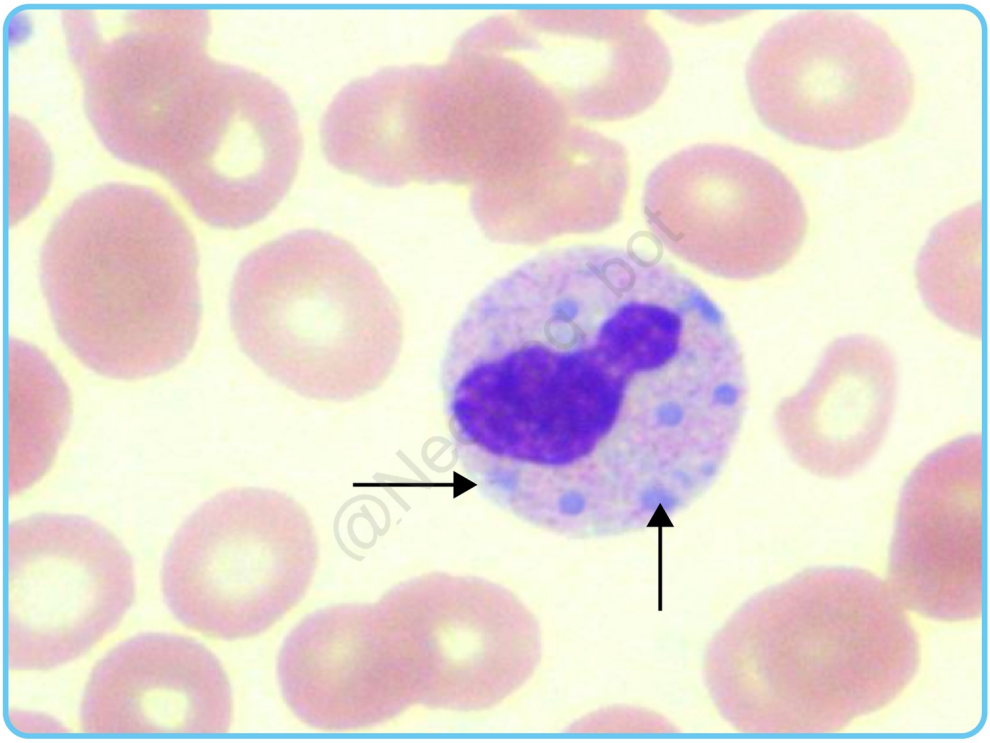

Correct Answer: A. Burns

Explanation: Döhle bodies are pale blue-gray, oval inclusions in the peripheral cytoplasm of neutrophils, representing aggregates of rough endoplasmic reticulum and ribosomal RNA. They are typically seen in toxic systemic states such as bacterial infections, burns, and pregnancy Dohle bodies Chediak Higashi

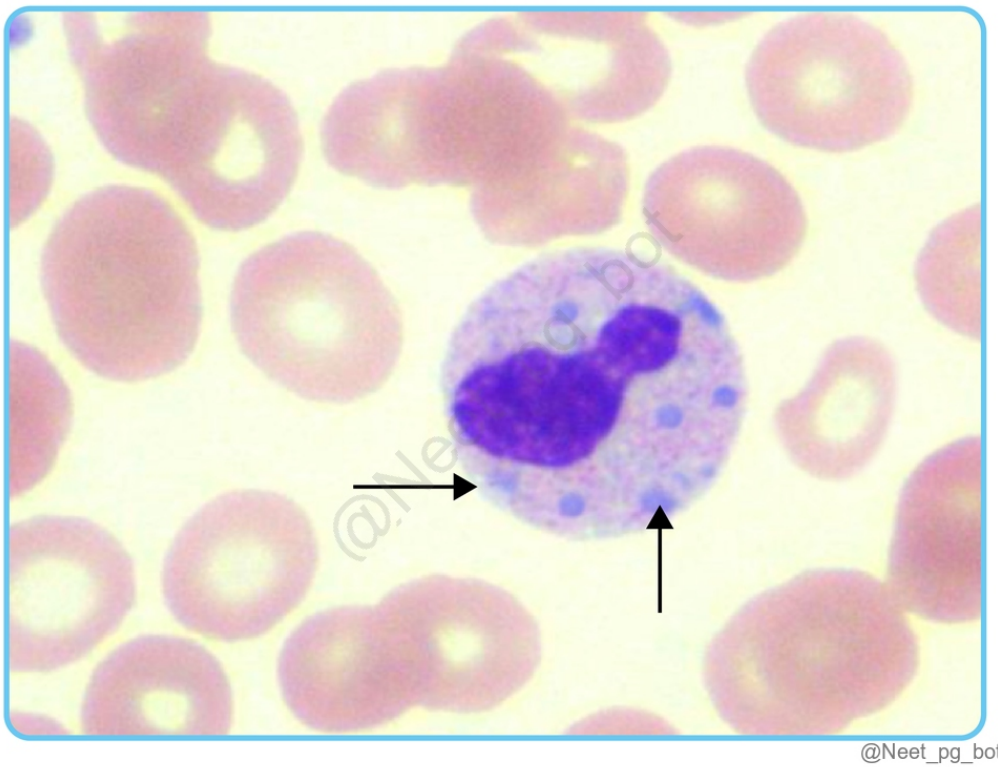

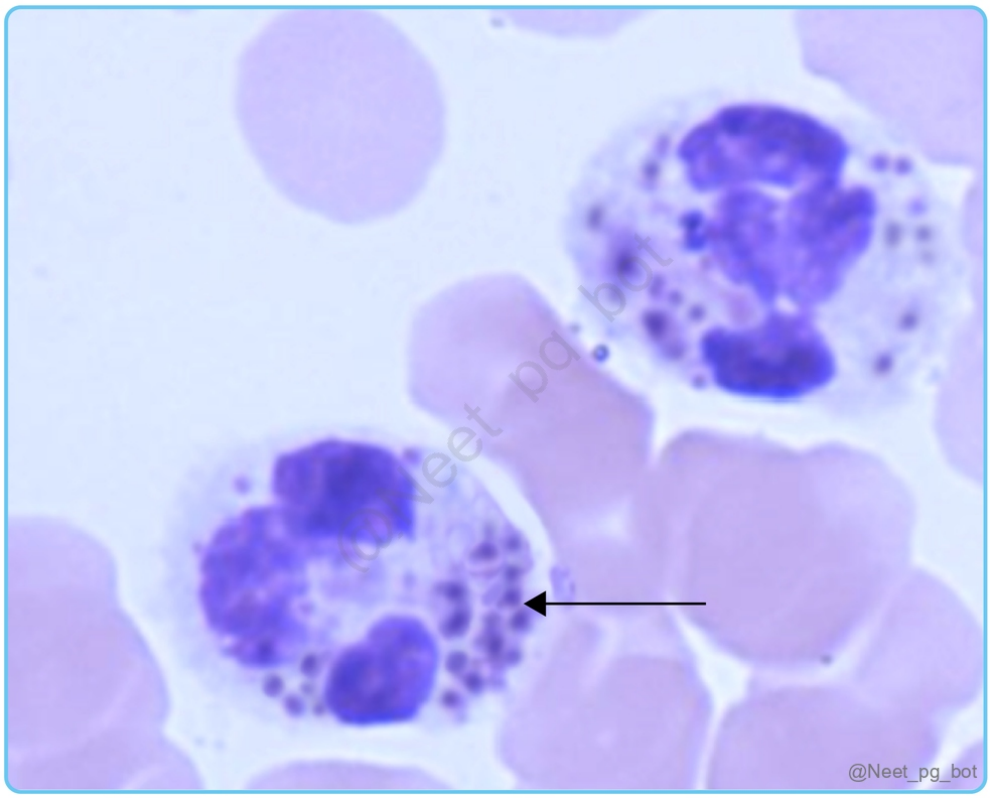

References:

Harrison's Principles of Internal Medicine, 22nd Edition, Page 455.

↑ *Back to this question in Part A*

@Neet_pg_bot

Q13: Which of the following is not correct about ITP? (Q851143)

A. Secondary ITP occurs due to autoimmune causes like SLE and infections like HIV , HCV

B. Wet purpura heralds life threatening bleed

C. Severe ITP needs emergency splenectomy

D. Eltrombopag is used in patients who relapse

Correct Answer: C. Severe ITP needs emergency splenectomy

Explanation: Emergency splenectomy is not first-line for severe ITP; initial management involves corticosteroids, IVIG, or anti-D immunoglobulin. Splenectomy is considered only in chronic or refractory cases, not as an emergency measure. Secondary ITP occurs due to autoimmune causes like SLE and infections like HIV, HCV (Option A ruled out) Wet purpura means bleeding in oral mucosa and it heralds life-threatening bleeding including intracranial hemorrhage. (Option B ruled out) Eltrombopag is a thrombopoietin receptor agonist for chronic/refractory ITP to stimulate platelet production. (Option D ruled out)

References:

Harrison's Principles of Internal Medicine, 22nd Edition, Page 924.

↑ *Back to this question in Part A*

@Neet_pg_bot

Q14: Which of the following is correct about the neutrophil shown in peripheral smear? (Q851166)

A. Chediak higashi Syndrome

B. Myelodysplastic syndrome

C. Perinicious anemia

D. Burns

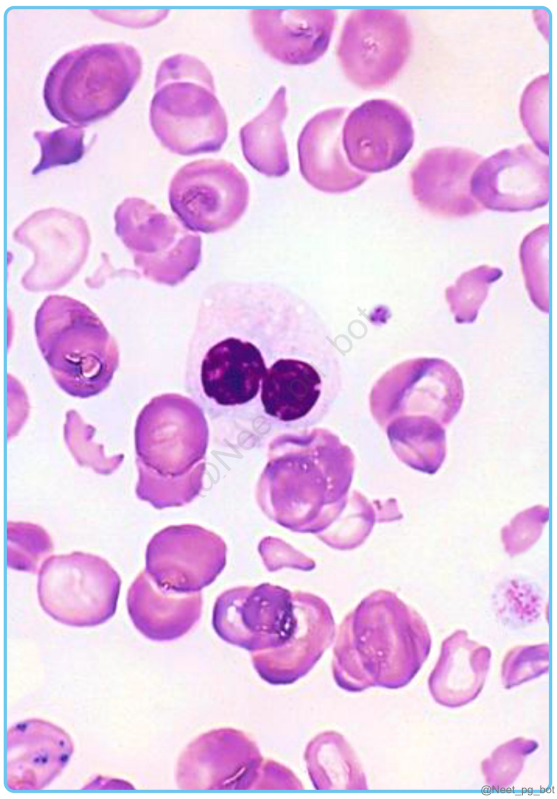

Correct Answer: B. Myelodysplastic syndrome

Explanation: The peripheral smear shows hyposegmented neutrophils with clear cytoplasms seen in MDS. Chediak higashi syndrome will have inclusions in neutrophils. (Option A) Pernicious anemia will have hypersegmented neutrophils. (Option C) Burns will have Dohle bodies which are basophilic inclusions (Option D)

References:

Harrison's Principles of Internal Medicine, 22nd Edition, Page 455.

↑ *Back to this question in Part A*

@Neet_pg_bot

Q15: The following feature is seen in which of the following conditions (Q851165)

A. Plasma cell dyscrasia

B. Multiple lineage dysplasia

C. Myelofibrosis

D. Leukemoid reaction



Correct Answer: A. Plasma cell dyscrasia

Explanation: The image shows rouleaux formation which is seen in multiple myeloma/ plasma cell dyscrasia . In multiple myeloma, malignant plasma cells produce large amounts of monoclonal immunoglobulins. These excess proteins coat the RBC surface, reducing the zeta potential (normal electrostatic repulsion between red cells), so the RBCs stick together in stacks - rouleaux formation. Multiple lineage dysplasia (Option B): This would show morphological abnormalities in cells (like hyposegmented neutrophils or ring sideroblasts) rather than stacking. Myelofibrosis (Option C): This typically presents with Tear-drop cells (dacrocytes) and a leukoerythroblastic blood picture. Leukemoid reaction (Option D): This is characterized by a significant increase in mature white blood cells (neutrophilia) in response to infection or stress, not usually Rouleaux.

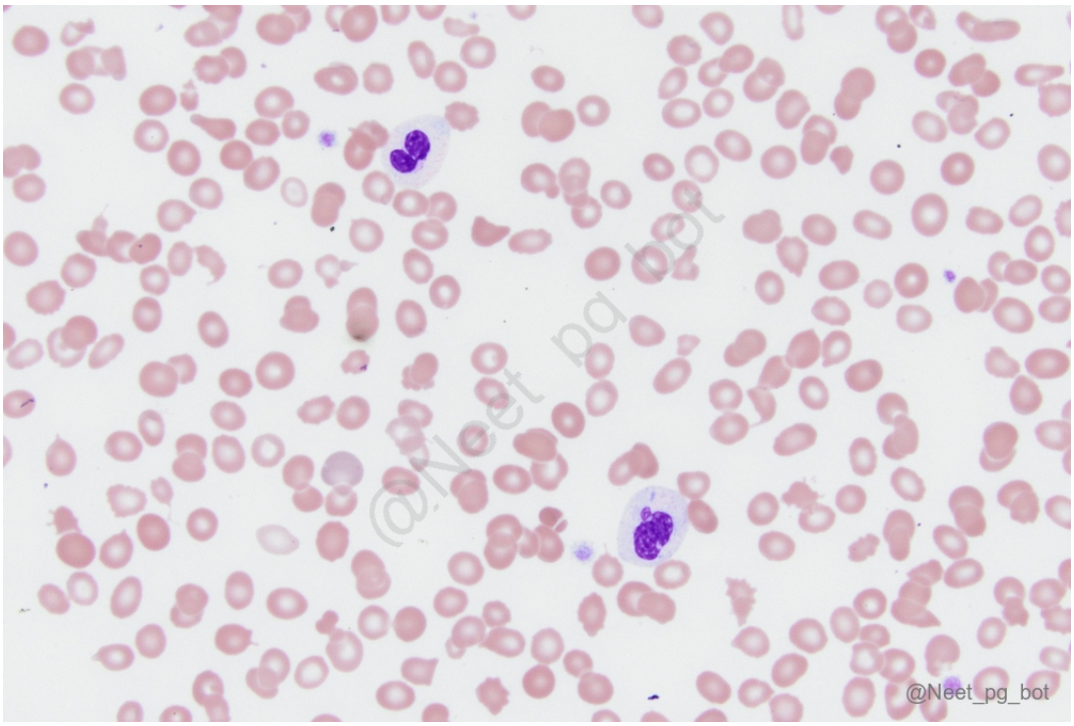
@Neet_pg_bot

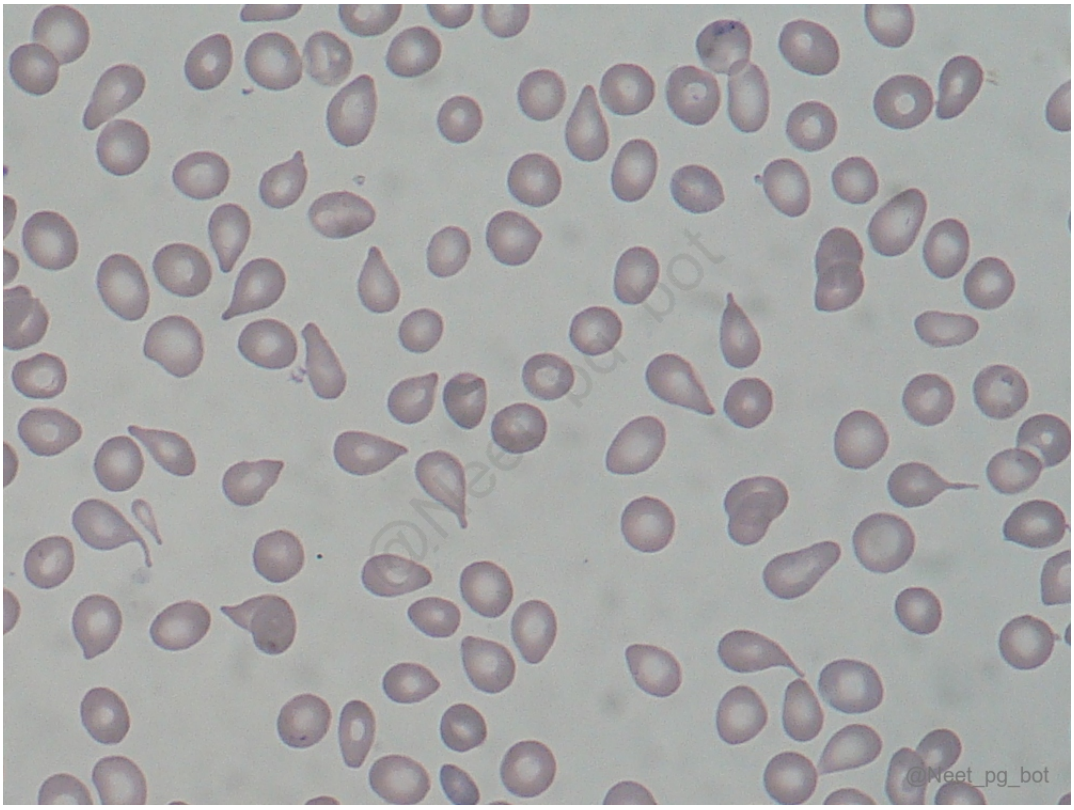
@Neet_pg_bot

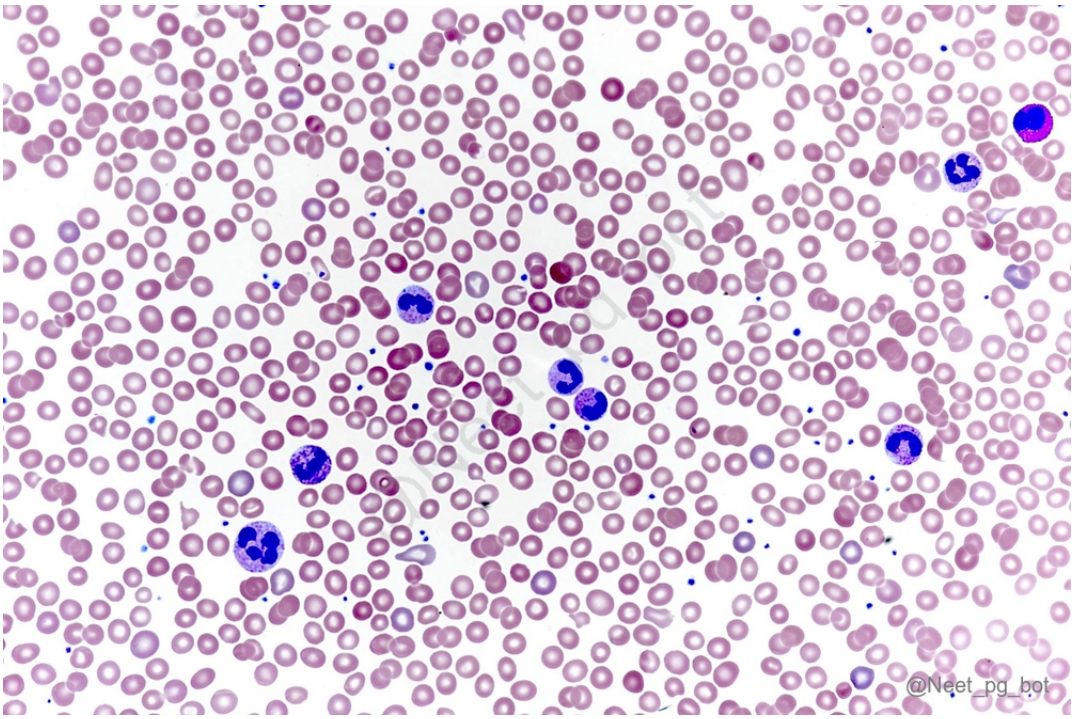

References:

Harrison's Principles of Internal Medicine, 22nd Edition, Page 889.

↑ *Back to this question in Part A*

@Neet_pg_bot

Q16: A 60-year-old man presents with progressive fatigue, early satiety, and weight loss over 3 months. Examination reveals massive splenomegaly. Laboratory findings: Hemoglobin: 8.5 g/dL, WBC: 3,000/µL, Platelets: 90,000/µL, Peripheral smear is shown below.. Which of the following is the most likely diagnosis? (Q851164)

A. Chronic myeloid leukemia

B. Myelofibrosis

C. Polycyathemia vera

D. Aplastic anemia

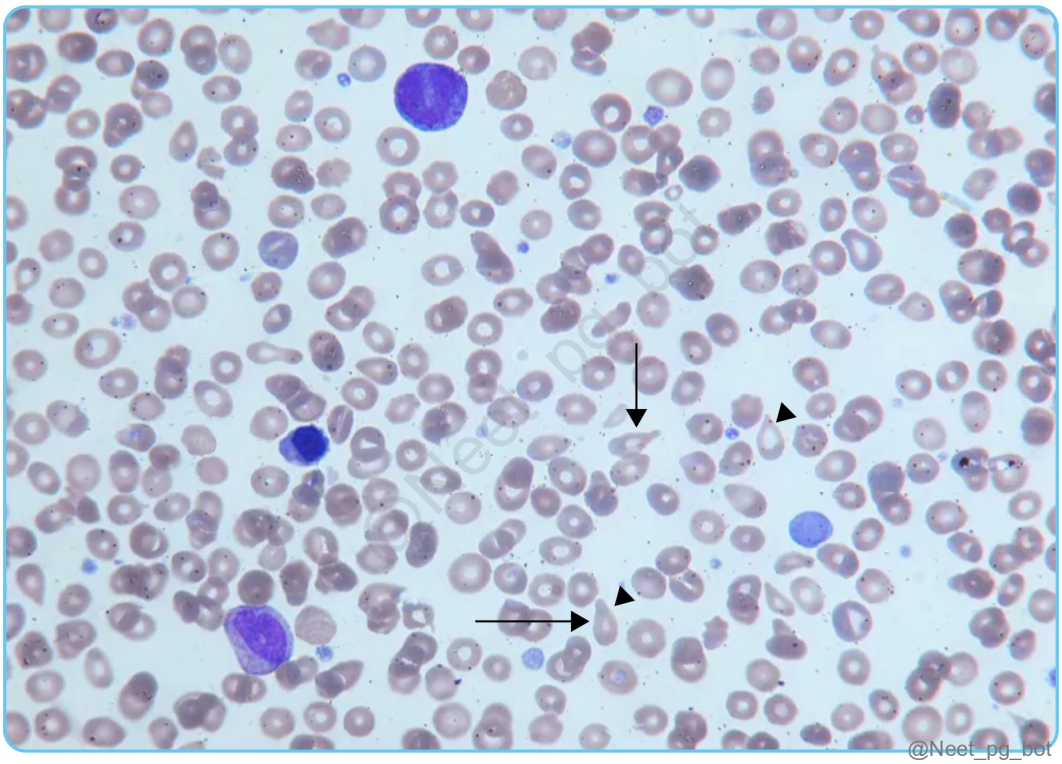

Correct Answer: B. Myelofibrosis

Explanation: Peripheral smear finding of tear drop RBC + immature WBC in circulation + pancytopenia + Splenomegaly indicate diagnosis as Myelofibrosis. The reason for splenomegaly is extramedullary hematopoiesis. The initial impression due to immature cells in circulation and massive splenomegaly and counts can cause misdiagnosis as CML. (Option A) It does not have “tear drop RBC”. Polycyathemia vera (Option C) will have high hemoglobin Aplastic anemia (Option D) will have pancytopenia without organomegaly.

References:

Harrison's Principles of Internal Medicine, 22nd Edition, Page 822.

↑ *Back to this question in Part A*

@Neet_pg_bot

Q17: A patient diagnosed with Acute promyelocytic leukemia develops bleeding from body orifices. Which of the following coagulogram report will be seen in this case? (Q851163)

A. PT increased, BT increased, aPTT increased

B. PT increased, BT normal, aPTT increased

C. PT normal, BT increased, aPTT increased

D. PT normal, BT normal , aPTT increased

Correct Answer: A. PT increased, BT increased, aPTT increased

Explanation: Acute promyelocytic leukemia (APL / M3 AML) is notorious for triggering acute DIC due to release of procoagulant substances/ auer rods from promyelocytes. In DIC: PT ↑, aPTT ↑ (due to clotting factor consumption) + Bleeding time ↑ (due to thrombocytopenia/platelet dysfunction). This explains simultaneous prolongation of PT, aPTT, and BT in such a patient.

References:

Harrison's Principles of Internal Medicine, 22nd Edition, Page 933.

↑ *Back to this question in Part A*

@Neet_pg_bot

Q18: All of the following are contraindications to use of the following instruments in hematology except? (Q851162)

A. Consumptive coagulopathy

B. Local site infection

C. Patient on warfarin

D. Low platelet count 40,000/uL



Correct Answer: D. Low platelet count 40,000/uL

Explanation: Low platelet count is often the reason for performing a bone marrow biopsy to determine its cause, and with very low counts platelet transfusion can be given before the procedure. Consumptive coagulopathy and a patient on warfarin (Option A and C): Absolute contraindication until corrected because of uncontrolled bleeding risk. Local site infection (Option B): Absolute contraindication as biopsy can disseminate infection beside increasing risk of osteomyelitis.

References:

Harrison's Principles of Internal Medicine, 22nd Edition, Page 448.

↑ *Back to this question in Part A*

@Neet_pg_bot

Q19: A 5-year-old boy presents with petechiae over his legs, pallor and decreased urine output. His mother reports that he had bloody diarrhea a week ago. The examination shows mild edema and hypertension. Laboratory results reveal: Hemoglobin: 7.8 g/dL, platelet count: 65,000/µL, Creatinine: 2.5 mg/dL, Peripheral smear: schistocytes present. Which of the following is the most likely diagnosis? (Q851161)

A. Immune thrombocytopenic purpura

B. Hemolytic uremic syndrome

C. Henoch Scholein Purpura

D. Post-infectious-glomerulonephritis

Correct Answer: B. Hemolytic uremic syndrome

Explanation: Schistocytes with low platelet count and renal failure (reduced urine output + Hypertension and oedema) favours diagnosis as HUS. Platelet count is low due to consumption in formation of microthrombi. Immune thrombocytopenic purpura (Option A): Isolated thrombocytopenia without anemia, schistocytes, or renal failure; no preceding bloody diarrhea. Thrombotic thrombocytopenic purpura (Option C): Shares MAHA + thrombocytopenia + renal signs but usually occurs in adults, with prominent neurological symptoms and no diarrheal prodrome. Acute post-streptococcal glomerulonephritis (Option D): Causes hematuria and hypertension after strep infection, but no MAHA, thrombocytopenia, or schistocytes.

References:

Harrison's Principles of Internal Medicine, 22nd Edition, Page 2904.

↑ *Back to this question in Part A*

@Neet_pg_bot

Q20: Which of the following causes non thrombocytopenic purpura? (Q851160)

A. HUS

B. TTP

C. DIC

D. HSP

Correct Answer: D. HSP

Explanation: HSP causes purpura due to small-vessel leukocytoclastic vasculitis with IgA deposition — platelet count is normal (non-thrombocytopenic purpura). HUS, TTP, and DIC all cause purpura with thrombocytopenia because of platelet consumption in microthrombi or coagulation activation.

References:

Harrison's Principles of Internal Medicine, 22nd Edition, Page 776.

↑ *Back to this question in Part A*

@Neet_pg_bot

Q21: An 18-year-old boy with severe hemophilia A (factor VIII activity <1%) is scheduled for wisdom tooth extraction. His past history includes multiple episodes of hemarthrosis but no inhibitors to factor VIII. Which of the following is the best strategy to prevent perioperative bleeding? (Q851159)

A. Administer desmopressin (DDAVP) before the procedure

B. Transfuse fresh frozen plasma 1 hour before surgery

C. Give prophylactic factor VIII concentrate to raise levels to ≥50% before the procedure

D. Start oral tranexamic acid only after the extraction

Correct Answer: C. Give prophylactic factor VIII concentrate to raise levels to ≥50% before the procedure

Explanation: Patients with severe hemophilia A require factor VIII concentrate to raise their levels to at least ≥50% before procedures like tooth extraction to prevent serious bleeding. Desmopressin (Option A) : Useful only in mild hemophilia A or vWD by releasing endogenous factor VIII and vWF Fresh frozen plasma (Option B): Contains factor VIII but in low concentration and large volumes would be required Tranexamic acid (Option D): Helps stabilize clots but does not replace deficient factor VIII; used only as adjunct

References:

Harrison's Principles of Internal Medicine, 22nd Edition, Page 929.

↑ *Back to this question in Part A*

@Neet_pg_bot

Q22: A 16-year-old girl presents with a history of heavy menstrual bleeding since menarche and frequent gum bleeding after brushing her teeth. She reports prolonged bleeding after a tooth extraction last year. There is no history of joint swelling or muscle hematomas. Examination reveals pallor but no petechiae or ecchymoses. Laboratory results show: Hemoglobin: 9.5 g/dL, Platelet count: 250,000/µL, PT: Normal, aPTT: Mildly prolonged, Bleeding time: Prolonged, Ristocetin cofactor assay: Decreased. Which of the following is the most likely diagnosis? (Q851158)

A. Hemophilia A

B. Bernard–Soulier syndrome

C. Von Willebrand disease

D. Glanzmann thrombasthenia

Correct Answer: C. Von Willebrand disease

Explanation: This 16-year-old girl has mucocutaneous bleeding (heavy menstrual bleeding, gum bleeding), prolonged bleeding after dental extraction , and normal platelet count , which strongly point toward a platelet function disorder , not a clotting factor deficiency like hemophilia. Key Lab Clues: PT: Normal → extrinsic pathway intact aPTT: Mildly prolonged → due to reduced factor VIII levels (because VWF stabilizes it) Bleeding time: Prolonged → impaired platelet adhesion Ristocetin cofactor assay: Decreased → hallmark of vWD These findings are classic for von Willebrand disease. Hemophilia A (Option A): Causes deep tissue/joint bleeds, not mucocutaneous bleeds with only aPTT prolonged Bernard–Soulier syndrome (Option B): Shows thrombocytopenia + giant platelets + absent ristocetin response; here platelet count is normal. Glanzmann thrombasthenia (Option D): Normal ristocetin test but absent aggregation with ADP, collagen, epinephrine; not seen here.

References:

Harrison's Principles of Internal Medicine, 22nd Edition, Page 926.

↑ *Back to this question in Part A*

@Neet_pg_bot

Q23: A 4-year-old boy presents with a history of easy bruising and frequent nosebleeds since infancy. His parents report prolonged bleeding after minor cuts, but there is no history of deep muscle or joint bleeds. Examination reveals petechiae and multiple ecchymoses over the extremities. Laboratory findings show:Platelet count: 250,000/µL, PT: Normal, aPTT: Normal, Bleeding time: Prolonged, Platelet aggregation absent with ADP, collagen, and epinephrine; normal with ristocetin. Which of the following is the most likely diagnosis? (Q851157)

A. Bernard–Soulier syndrome

B. Hemophilia A

C. Glanzmann thrombasthenia

D. Von Willebrand disease

Correct Answer: C. Glanzmann thrombasthenia

Explanation: Mucocutaneous bleeding with a platelet aggregation defect, characterized by absence of response to ADP, collagen, and epinephrine, but normal response to ristocetin, is classic for GpIIb/IIIa deficiency. GTA-RACE negative: G lanzmann T hrombasthenia has A ggregation with R istocein but ACE A: ADP , C: collagen, E: epinephrine absent Bernard–Soulier syndrome (Option A): Low platelet count + giant platelets + absent aggregation with ristocetin. Hemophilia A (Option B): Presents with deep tissue/joint bleeds + prolonged aPTT Von Willebrand disease (Option D): Causes mucocutaneous bleeding but shows defective ristocetin-induced aggregation and often prolonged aPTT

References:

Harrison's Principles of Internal Medicine, 22nd Edition, Page 926.

↑ *Back to this question in Part A*

@Neet_pg_bot

Q24: Elective splenectomy is done in which of the following conditions? a. Beta thalassemia major with 50% increase in transfusion requirement over last one year b. Hereditary spherocytosis with severe anemia by 5 years of age c. Chronic ITP non responsive to steroids d. Myelopthisis (Q851156)

A. a,b

B. a,c

C. a,b,c

D. a,b,c,d

Correct Answer: C. a,b,c

Explanation: Elective splenectomy is done in: Hypersplenism seen with beta thalassemia major HS with severe anaemia Chronic ITP not responding to medication Myelophthisis means bone marrow failure caused by replacement of normal hematopoietic tissue with abnormal cells like metastatic cancers ,TB, Sarcoidosis and gaucher disease. It presents with pancytopenia and leukoerythroblastic blood picture (nucleated RBCs + immature myeloid cells in peripheral smear).

References:

Harrison's Principles of Internal Medicine, 22nd Edition, Page 924.

↑ *Back to this question in Part A*

@Neet_pg_bot

• [06_Hematology] 046 Blood Components And Complications Of Blood Transfusion

« Back to Folder Directory

[06_Hematology] 046 Blood Components And Complications Of Blood Transfusion — Quick Jump

Q1 (p. 2137)	*Q2 (p. 2137)*	*Q3 (p. 2138)*	*Q4 (p. 2139)*	*Q5 (p. 2140)*	*Q6 (p. 2140)*
Q7 (p. 2141)	*Q8 (p. 2142)*	*Q9 (p. 2143)*	*Q10 (p. 2144)*	*Q11 (p. 2144)*	*Q12 (p. 2145)*
Q13 (p. 2146)	*Q14 (p. 2146)*	*Q15 (p. 2147)*	*Q16 (p. 2147)*	*Q17 (p. 2148)*	*Q18 (p. 2149)*
Q19 (p. 2149)	*Q20 (p. 2150)*				

Q1: Which is the correct ratio for acute hypovolemic coagulopathy requiring massive transfusion? (Q851027)

A. 1 RBCC: 1 plasma: 0.25 platelet concentrate

B. 1 RBCC: 1 plasma: 0.5 platelet concentrate

C. 1 RBCC: 1 plasma: 1 platelet concentrate

D. 1 RBCC: 1 plasma: 4 platelets concentrate

Correct Answer: C. 1 RBCC: 1 plasma: 1 platelet concentrate

Explanation: For massive transfusion for bleeding patients, 6 units of packed RBC, 6 units of fresh frozen plasma, and 6 units of platelet-rich plasma should be given in a ratio of 1:1:1. However, in cases of Single donor platelets - one unit of platelet concentrate/ Single donor platelet = 4-6 units of platelet-rich plasma of Random donor platelets which changes the ratio to 1:1:0.25. Therefore, 1:1:0:25 ratio is correct for SDP & 1:1:1 is correct for RDP. When SDP or RDP is not mentioned in the question stem, the best answer is 1:1:1 ratio.

References:

Harrison's Principles of Internal Medicine, 22nd Edition, Page 907.

↑ *Back to this question in Part A*

@Neet_pg_bot

Q2: Which transfusion reaction is most strongly associated with HLA antibodies in donor plasma? (Q851036)

A. TRALI

B. TACO

C. Acute hemolytic reaction

D. Sepsis

Correct Answer: A. TRALI

Explanation: TRALI (Transfusion-Related Acute Lung Injury) is most strongly linked to anti-HLA or anti-HNA antibodies in donor plasma. These antibodies bind to the recipient's leukocytes, causing neutrophil activation in lung capillaries and resultant non-cardiogenic pulmonary edema. It has a typical onset: within 6 hours of transfusion. Prevention of TRALI: Use plasma from male donors or screen multiparous women for HLA antibodies.

References:

Harrison's Principles of Internal Medicine, 22nd Edition, Page 911.

↑ *Back to this question in Part A*

@Neet_pg_bot

Q3: 30-year-old man receives a unit of O■ packed RBCs. Within 10 minutes, he develops fever, chills, hypotension, and flank pain. Which investigation will be most specific for confirming the diagnosis? (Q851035)

A. Indirect antiglobulin test

B. Direct antiglobulin Coombs test

C. Blood cultures from patient

D. Reticulocyte count

Correct Answer: B. Direct antiglobulin Coombs test

Explanation: In acute hemolytic transfusion reactions, the Direct Antiglobulin Test (DAT) detects antibodies or complement bound to RBCs in vivo. It is the most specific for confirming immune-mediated hemolysis after transfusion.

References:

Harrison's Principles of Internal Medicine, 22nd Edition, Page 905.

↑ *Back to this question in Part A*

Q4: The patient is started on blood transfusion in a post operative room and within 5 minutes you notice that the patient develops a rash all over the body with cold clammy extremities. pulse is 120/min, BP is 80/60 mm Hg with inspiratory rhonchi in bilateral lungs The blood group of the patient is 0+ and the patient was given 0+ blood as verified by the blood bank. Which of the following is the first differential diagnosis? (Q851034)

A. Alloimmunization

B. Anaphylaxis

C. TACO

D. Mismatched blood transfusion

Correct Answer: B. Anaphylaxis

Explanation: Some IgA-deficient individuals develop anti-IgA antibodies (often IgE type). This happens because their immune system sees IgA as a foreign antigen - they've never been tolerized to it. Development of rash + Hypotension, + Bronchospasm indicates anaphylaxis. Allergic transfusion reactions: Cause: Related to plasma proteins in transfused components. Mild Allergic Transfusion Reactions (majority) Symptoms: Rash, pruritus, urticaria, localized edema. Management: Temporarily stop the transfusion. Administer antihistamine drugs. Prevention: Premedication with antihistamines may be used, although no consensus exists. Washed cellular components can be considered for extremely sensitized patients. Severe Allergic (Anaphylactic) Transfusion Reactions (rare) Anaphylactic reactions can occur within minutes of starting a transfusion, even after just a few milliliters of blood transfusion. Symptoms: Bronchospasm, respiratory distress, hypotension, rash, nausea, vomiting, shock. Management: Stop the transfusion immediately and maintain vascular access. Administer adrenaline (0.3-0.5 mg subcutaneously). Additional treatments may include steroids, antihistamines, and bronchodilators. Alloimmunization (Option A): This is a delayed process where the body develops antibodies against donor antigens; it does not cause an acute, life-threatening crash within minutes. TACO (Transfusion Associated Circulatory Overload) (Option C): This presents with hypertension (due to fluid volume) and crackles (pulmonary edema), not a rash and hypotension. Mismatched blood transfusion (Option D): While this also causes hypotension and tachycardia (Acute Hemolytic Transfusion Reaction), it typically presents with fever, chills, and flank pain . In this case, the blood group was verified as a match (O+ to O+), making mismatch less likely than a direct allergic response to plasma proteins.

References:

Harrison's Principles of Internal Medicine, 22nd Edition, Page 911.

https://www.ncbi.nlm.nih.gov/books/NBK482202/#:~:text=Continuing%20Education%20Activity,with%20little%20or%20no%20treatment.

↑ *Back to this question in Part A*

@Neet_pg_bot

Q5: Which of the following blood components has the highest chances of causing transfusion transmitted infection? (Q851033)

A. Platelet concentrate

B. Packed RBC

C. Plasma

D. Whole blood

Correct Answer: A. Platelet concentrate

Explanation: Platelets are stored at room temperature (20–24 °C) with constant agitation. This environment is ideal for bacterial growth if contamination occurs during collection or processing. Even a small number of bacteria introduced during venipuncture or processing can multiply rapidly during the 3–7 days of storage.

References:

Harrison's Principles of Internal Medicine, 22nd Edition, Page 912-913.

↑ *Back to this question in Part A*

@Neet_pg_bot

Q6: Which of the following is not correct about usage and storage of blood components? (Q851032)

A. Packed RBC can be stored for up to 42 days at 4 °C

B. Platelets can be stored for 3–7 days at 20–24 °C

C. Granulocyte concentrate at room temperature and used within 24 hours of end of collection

D. Plasma is cryopreserved at –4 °C and should be used within 1 hour of thawing

Correct Answer: D. Plasma is cryopreserved at –4 °C and should be used within 1 hour of thawing

Explanation: Plasma is cryopreserved at -18 °C and should be used within 6 hours of thawing to preserve maximum labile factor activity (factor V and Factor VIII activity) Other options: Option A: Packed RBC can be

stored for up to 42 days at 4 °C With additive solutions (e.g., SAGM) Stored at 2–6 °C Shelf life: 35–42 days Option B: Platelets can be stored for 3–7 days at 20–24 °C Stored at room temperature Requires continuous gentle agitation Shelf life: usually 5 days (can be extended to 7 days in some settings) Option C: Granulocyte concentrate at room temperature and used within 24 hours Stored at 20–24 °C Must be transfused as soon as possible, within 24 hours Cannot be refrigerated or frozen

References:

Harrison's Principles of Internal Medicine, 22nd Edition, Page 902-903.

↑ *Back to this question in Part A*

@Neet_pg_bot

Q7: Deleucocytation is defined as ? (Q851031)

A. <1–5. 10 6 leukocytes per unit of blood components

B. <1–5. 10 7 leukocytes per unit of blood components

C. <1–5. 10 8 leukocytes per unit of blood components

D. <1–5. 10 9 leukocytes per unit of blood components

Correct Answer: A. <1–5. 10 6 leukocytes per unit of blood components

Explanation: Deleucocytation (Leukoreduction) refers to the removal of leukocytes from blood components to a very low level before transfusion. Deleucocytated blood = blood containing fewer than < 1–5 × 10■ leukocytes per unit This reduction in white cells is clinically important because it helps prevent several transfusion-related complications. Benefits of Deleucocytation Reduces Febrile Non-Hemolytic Transfusion Reactions (FNHTR) (most common leukocyte-mediated reaction) Prevents alloimmunization to HLA antigens (important for patients receiving multiple transfusions—e.g., thalassemia, oncology)



References:

Harrison's Principles of Internal Medicine, 22nd Edition, Page 902.

↑ *Back to this question in Part A*

@Neet_pg_bot

Q8: High efficiency deleucocytation is being done using the filter shown in the image. It will reduce all of the following complications of blood transfusion except? (Q851030)

A. Mismatched blood transfusion

B. Febrile non hemolytic transfusion reaction

C. Transmission of CMV

D. Alloimmunization

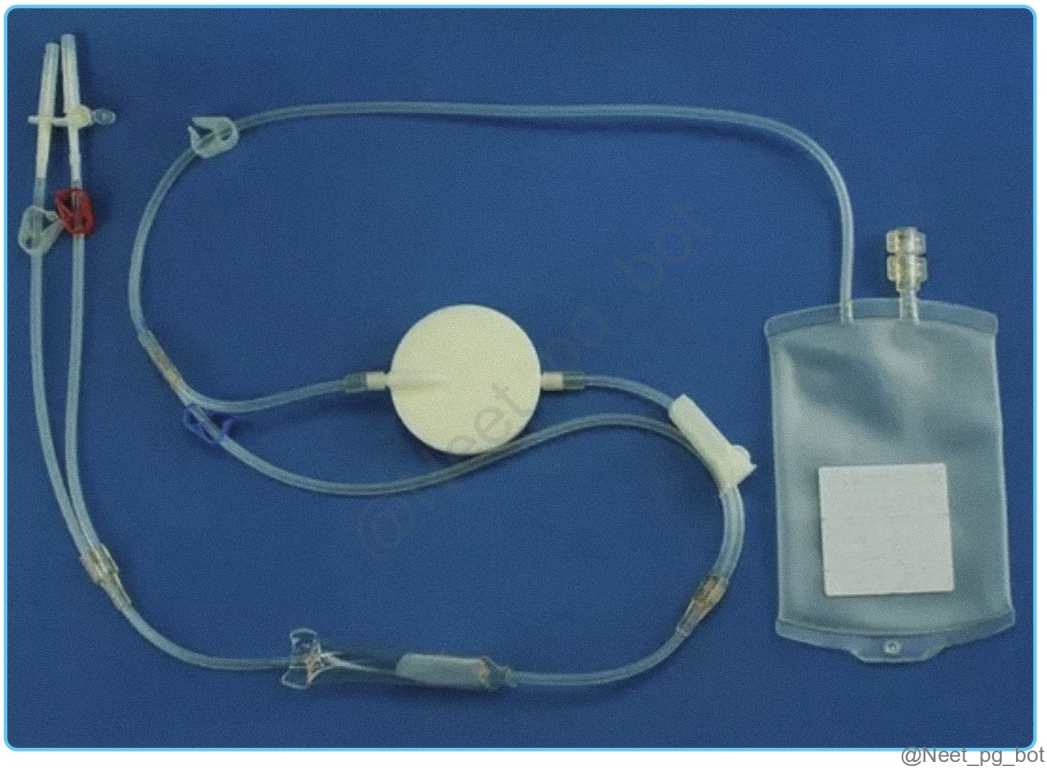

Correct Answer: A. Mismatched blood transfusion

Explanation: Mismatched blood transfusion is an ABO/Rh incompatibility reaction caused by recipient antibodies attacking donor RBC antigens. It is usually a clerical error and cannot be prevented by performing deleucocytation. High-efficiency deleucocytation filters remove WBCs, so they prevent complications caused by donor leukocytes, such as: Febrile non-hemolytic transfusion reaction (Option B): due to cytokines from WBCs CMV transmission (Option C): resides in WBC) HLA alloimmunization (Option D): immune sensitization to leukocyte antigens Reduction of transfusion-transmitted infections

References:

Harrison's Principles of Internal Medicine, 22nd Edition, Page 903.

↑ *Back to this question in Part A*

@Neet_pg_bot

Q9: Which of the following is immunodominant sugar in patient with blood group A (Q851029)

A. N-acetyl- glucosamine

B. N- acetyl- galactosamine

C. Galactose

D. Fucose

Correct Answer: B. N- acetyl- galactosamine

Explanation: Blood group antigens are determined by specific terminal sugars attached to the H antigen on RBC membranes. Group A : Enzyme adds N-acetyl-galactosamine to H antigen. Group B : Enzyme adds galactose to H antigen Group AB: Enzyme adds both of the above to the H antigen Group O : No additional sugar (H antigen remains as a fucose-based structure).

References:

Harrison's Principles of Internal Medicine, 22nd Edition, Page 903.

↑ *Back to this question in Part A*

@Neet_pg_bot

Q10: Which of the following blood groups is a universal plasma donor? (Q851028)

A. A

B. B

C. AB

D. O

Correct Answer: C. AB

Explanation: Group AB plasma has no anti-A and no anti-B antibodies, and can be given to recipients of any blood group without causing hemolysis. Universal RBC donor = O negative (Rationale: It has no A/B/D antigens on RBCs) Universal plasma donor = AB (Rationale: no A/B antibodies in plasma)

References:

Harrison's Principles of Internal Medicine, 22nd Edition, Page 902.

↑ *Back to this question in Part A*

@Neet_pg_bot

Q11: An unbooked 30 year old multigravida in the 36 weeks of pregnancy is having severe anemia with Hb of 6.8 gm/dl. She was prescribed 2 units of PRBC . She

develops high grade fever 40 C with chills and rigors, hypotension and bleeding from IV cannula site 1 hour after completion of transfusion. Diagnosis is? (Q851017)

A. Mismatched Blood transfusion

B. Febrile non hemolytic transfusion reaction

C. Transfusion transmitted bacterial infection

D. TRALI

Correct Answer: C. Transfusion transmitted bacterial infection

Explanation: Contaminated PRBC (often with gram-negative bacteria like Yersinia enterocolitica or Serratia) can cause sudden high fever (>39–40 °C), chills, hypotension, and DIC (hence bleeding from the IV site). Symptoms often appear during or shortly after transfusion completion. Diagnosis is a transfusion-transmitted infection . Mismatched Blood Transfusion (Option A): Usually starts during transfusion (not after completion) with symptoms including fever, chills, back pain, dark urine, and hypotension. Bleeding from the IV site due to DIC can occur, but timing favours the above-mentioned diagnosis. Febrile Non-Hemolytic Transfusion Reaction (Option B) : It has no hypotension, no DIC, and no severe sepsis-like picture. TRALI (Option D) presents with acute respiratory distress, hypoxemia, and bilateral pulmonary infiltrates within 6 hours.

References:

Harrison's Principles of Internal Medicine, 22nd Edition, Page 908.

↑ *Back to this question in Part A*

@Neet_pg_bot

Q12: “Lethal triad of death” includes (Q851026)

A. Acidosis, hypothermia and coagulopathy

B. Alkalosis, hypothermia and coagulopathy

C. Acidosis, hyperthermia and coagulopathy

D. Alkalosis, hyperthermia and coagulopathy

Correct Answer: A. Acidosis, hypothermia and coagulopathy

Explanation: The lethal triad of death in trauma patients consists of: Hypothermia – cooling from exposure, shock, and infusion of cold fluids/blood. Acidosis – from hypoperfusion, anaerobic metabolism, and lactate buildup. Coagulopathy – from consumption of clotting factors, dilution by fluids, and hypothermia-induced enzyme dysfunction.

References:

Bailey & Love's Short Practice of Surgery, 28th Edition, Page 671. EMS Tactical Paramedic Lethal Triad - StatPearls - NCBI Bookshelf

↑ *Back to this question in Part A*

@Neet_pg_bot

Q13: Which of the following complications can occur after multiple blood transfusions? 1. Hypokalemia 2. Hyperkalemia 3. Hypocalcemia 4. Metabolic acidosis (Q851025)

A. 1,3

B. 2,3

C. 1,2,3

D. 1,3,4

Correct Answer: C. 1,2,3

Explanation: Hyperkalemia can be seen immediately after multiple transfusions due to K■-rich supernatant fluid. The reason is RBC membrane Na■/K■-ATPase pump fails over time because the RBCs run out of ATP. Hypokalemia occurs after a few hours to days after a blood transfusion, as RBC will take glucose from the recipient's bloodstream. Besides, the metabolic alkalosis due to citrate excess will also cause hypokalemia. Potassium and pH of blood have an inverse relation. Hypocalcemia can be explained by citrate excess. Citrate excess causes metabolic alkalosis.

References:

Harrison's Principles of Internal Medicine, 22nd Edition, Page 911.

↑ *Back to this question in Part A*

@Neet_pg_bot

Q14: Cryoprecipitate can be used in all of the following cases except (Q851024)

A. Type II vWD

B. Type III vWD

C. Haemophilia A in absence of factor VIII concentrate

D. Hemophilia B in absence of factor IX concentrate

Correct Answer: D. Hemophilia B in absence of factor IX concentrate

Explanation: Cryoprecipitate is rich in Factor VIII, vWF, fibrinogen, Factor XIII, but lacks Factor IX. So it would not be useful to control bleeding in a patient with Hemophilia B. Von Willebrand disease type II has quality and type III has quantitative issues that can be managed with cryoprecipitate This question is more theory-oriented as we avoid using cryoprecipitate due to the risk of transmission of infection.

References:

Harrison's Principles of Internal Medicine, 22nd Edition, Page 907.

↑ *Back to this question in Part A*

@Neet_pg_bot

Q15: A stable patient without fever or infection has severe thrombocytopenia. At what platelet count threshold is platelet transfusion generally indicated? (Q851023)

A. < 5,000 / uL

B. <10,000/ uL

C. <20,000/ uL

D. <50,000/ uL

Correct Answer: A. < 5,000 / uL

Explanation: Threshold of platelet transfusion In absence of fever or infection <5,0000 / uL If fever or infection <10,000 / uL If surgery planned, DIC, endoscopy or invasive procedure < 50,000 / uL If neurosurgery or eye surgery < 80,000 / uL

References:

Harrison's Principles of Internal Medicine, 22nd Edition, Page 906.

↑ *Back to this question in Part A*

@Neet_pg_bot

Q16: The RTA victim was given 6 units of whole blood in the last 6 hours. Which of the following complications is most likely in this patient? (Q851022)

A. Hypokalemia

B. Hyponatremia

C. Hypocalcemia

D. Hypercalcemia

Correct Answer: C. Hypocalcemia

Explanation: In massive transfusion (>1 blood volume in 24 hours or >2.5L in 6 hours), the amount of citrate infused can overwhelm the liver's ability to metabolize it. Citrate binds ionized calcium, leading to hypocalcemia . This manifests as hypotension, prolonged QT interval, paresthesias, tetany, and bleeding (due to impaired clotting factor function). Hypokalemia (Option A): Stored blood tends to increase potassium levels (due to RBC lysis over time), not lower it. Hyponatremia (Option B): Whole blood is isotonic; rapid transfusion does not dilute serum sodium enough to cause hyponatremia. Hypercalcemia (Option D): Transfusion never causes elevated calcium; citrate always lowers calcium.

References:

Harrison's Principles of Internal Medicine, 22nd Edition, Page 912.

↑ *Back to this question in Part A*

@Neet_pg_bot

Q17: A 65-year-old man with chronic kidney disease on maintenance hemodialysis receives 2 units of PRBCs over 4 hours for severe anemia. Shortly after transfusion, he develops acute dyspnea, elevated JVP, hypertension, and bilateral basal crackles. Which of the following is the most likely diagnosis? (Q851021)

A. Transfusion-related acute lung injury

B. Transfusion-associated circulatory overload

C. Febrile non-hemolytic reaction

D. Acute hemolytic reaction

Correct Answer: B. Transfusion-associated circulatory overload

Explanation: TACO occurs in elderly, CKD, and heart-failure patients due to rapid or excessive transfusion . Key features: Dyspnea + pulmonary edema Elevated JVP Hypertension Positive fluid balance Transfusion-related acute lung injury (Option A): Causes non-cardiogenic pulmonary edema. JVP is normal and BP often low, unlike this case. Febrile non-hemolytic reaction (Option C): Presents with fever and chills, not fluid overload signs. ■■■■■■■Acute Hemolytic Reaction (Option D): Features fever, flank pain, hemoglobinuria, hypotension—not seen here.

References:

Harrison's Principles of Internal Medicine, 22nd Edition, Page 912.

↑ *Back to this question in Part A*

@Neet_pg_bot

Q18: A 30 year old woman on steroids for SLE had received one unit of blood transfusion after her recent delivery of a healthy boy baby. 10 days later she developed fever, rashes and diarrhea. Which complication of blood transfusion would you suspect? (Q851020)

A. Mismatched blood transfusion

B. Graft versus host disease

C. Febrile non-hemolytic transfusion reaction

D. Transfusion transmitted infection

Correct Answer: B. Graft versus host disease

Explanation: GVHD is mediated by donor T lymphocytes in a recipient unable to reject such allogenic lymphocytes, like severely immunosuppressed patients. Donor T lymphocytes interact with host HLA Ags and mount an immune response, which occurs 5–10 days after transfusion and causes the following: Fever, Cytopenia, Characteristic skin rash Diarrhea and liver function abnormalities. Mismatched blood transfusion (Option A) , Febrile non-hemolytic transfusion reaction (Option C) , and transfusion-transmitted infection (Option D) will occur during or immediately after the transfusion.

References:

Harrison's Principles of Internal Medicine, 22nd Edition, Page 911.

↑ *Back to this question in Part A*

@Neet_pg_bot

Q19: Which of the following is not correct about TRALI (Q851019)

A. Donor antibodies bind to recipient neutrophils in pulmonary endothelium causing release or pro inflammatory cytokines

B. Usually occurs within 6 hours of transfusion

C. Bilateral interstitial infiltrates due to cardiogenic pulmonary edema

D. Reduced incidence by taking plasma from only male donor

Correct Answer: C. Bilateral interstitial infiltrates due to cardiogenic pulmonary edema

Explanation: TRALI is non-cardiogenic pulmonary edema. It occurs due to: Transfusion of donor plasma containing high-titer anti-HLA class II Abs that bind recipient cognate Ag. Anti-HLA class I and anti–human neutrophil antigen The damage to the pulmonary endothelium makes it leaky and causes fluid to leak out into the alveoli. It is more common in the first 6 hours but can occur up to 72 hours.

References:

Harrison's Principles of Internal Medicine, 22nd Edition, Page 911.

↑ *Back to this question in Part A*

@Neet_pg_bot

Q20: The leading cause of death due to blood transfusion is? (Q851018)

A. TACO

B. TRALI

C. Mismatched blood transfusion

D. Dilutional coagulopathy

Correct Answer: A. TACO

Explanation: TACO is the most commonly reported cause of transfusion-related mortality worldwide, especially in the elderly and patients with underlying cardiac/renal disease. TRALI (Option B) used to be the leading cause, but with better donor screening, its incidence has declined. Mismatched blood transfusion (Option C) can be fatal, but is much less common due to strict cross-matching protocols. Dilutional coagulopathy (Option D) occurs after massive transfusion but is not the leading cause of transfusion-related death.

References:

Harrison's Principles of Internal Medicine, 22nd Edition, Page 912.

↑ *Back to this question in Part A*

@Neet_pg_bot

• [06_Hematology] 047 Previous Year Questions

« Back to Folder Directory

[06_Hematology] 047 Previous Year Questions — Quick Jump

Q1 (p. 2152)	*Q2 (p. 2153)*	*Q3 (p. 2154)*	*Q4 (p. 2155)*	*Q5 (p. 2157)*	*Q6 (p. 2158)*
Q7 (p. 2159)	*Q8 (p. 2161)*	*Q9 (p. 2163)*	*Q10 (p. 2164)*	*Q11 (p. 2166)*	*Q12 (p. 2166)*
Q13 (p. 2167)	*Q14 (p. 2168)*	*Q15 (p. 2169)*	*Q16 (p. 2172)*	*Q17 (p. 2173)*	*Q18 (p. 2174)*
Q19 (p. 2174)	*Q20 (p. 2175)*	*Q21 (p. 2176)*	*Q22 (p. 2176)*	*Q23 (p. 2178)*	*Q24 (p. 2178)*
Q25 (p. 2179)	*Q26 (p. 2180)*	*Q27 (p. 2181)*	*Q28 (p. 2182)*	*Q29 (p. 2182)*	*Q30 (p. 2184)*
Q31 (p. 2184)	*Q32 (p. 2185)*	*Q33 (p. 2187)*			

Q1: A 60-year-old female presents with weakness, back pain and repeated infections. Work up shows M spike on serum electrophoresis. Prognosis is determined by which of the following factors? (Q866809)

A. IgG and albumin

B. IgM and albumin

C. Albumin and LDH

D. Albumin and β■-microglobulin

Correct Answer: D. Albumin and β■-microglobulin

Explanation: The International Staging System (ISS) for multiple myeloma — a widely accepted prognostic model — uses two lab values: serum β■-microglobulin and serum albumin . β■-Microglobulin is a marker of tumor burden and renal function; elevated levels indicate more advanced disease and poorer prognosis. Albumin reflects the patient’s general health and disease activity; lower levels are associated with more aggressive disease and worse outcomes. ISS Staging Stage Criteria Prognosis I β■-microglobulin < 3.5 mg/L albumin ≥ 3.5 g/dL Best prognosis II Intermediate values (not fitting I or III) Intermediate prognosis III Intermediate values (not fitting I or III) Poor prognosis Incorrect Options: IgG and albumin (Option A): While IgG is commonly the paraprotein in multiple myeloma, it is not part of the ISS prognostic criteria. IgM and albumin (Option B): Elevated IgM is characteristic of Waldenström macroglobulinemia , which differs from multiple myeloma in pathology and prognosis. Albumin and LDH (Option C): Elevated LDH may suggest high tumor turnover or aggressive disease but is not part of standard ISS staging (though it may appear in the Revised-ISS combined with cytogenetics).

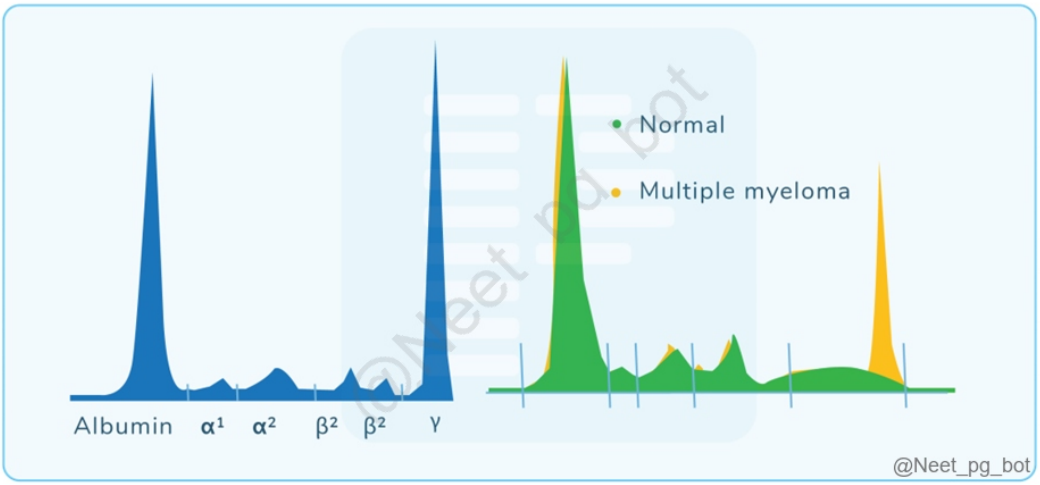

References:

.

↑ *Back to this question in Part A*

@Neet_pg_bot

Q2: A girl experiences prolonged menstrual bleeding and has normal platelet count, PT, and aPTT, but an increased bleeding time, which was determined to be due to a deficiency of GpIIb-IIIa after further analysis. What is the diagnosis? (Q859787)

A. Bernard Soulier syndrome

B. Glanzmann thrombasthenia

C. Haemophilia A

D. Von Willebrand disease

Correct Answer: B. Glanzmann thrombasthenia

Explanation: - Glanzmann Thrombasthenia: Glanzmann Thrombasthenia is an autosomal recessive disorder caused by a deficiency or dysfunction of the glycoprotein IIb/IIIa (GPIIb/IIIa) complex. This complex is the primary receptor for fibrinogen; its absence prevents platelet-to-platelet aggregation, leading to a prolonged bleeding time despite a normal platelet count. Characteristically, these platelets fail to aggregate with all agonists (ADP, collagen, thrombin) except ristocetin, which remains normal because it relies on GPIb rather than GPIIb/IIIa. Incorrect Options: Option A - Bernard-Soulier Syndrome: This is caused by a deficiency of the GPIb-IX-V complex, leading to defective platelet adhesion; unlike Glanzmann, it typically presents with thrombocytopenia and giant platelets on a peripheral smear. Option C - von Willebrand Disease (vWD) : While it also presents with a prolonged bleeding time, it is usually an autosomal dominant defect of vWF that often shows a

decreased response to ristocetin and may have a prolonged aPTT due to low Factor VIII levels. Option D - Immune Thrombocytopenia (ITP) : This is an acquired condition characterized by an isolated low platelet count (thrombocytopenia) due to antibody-mediated destruction, whereas Glanzmann specifically features a normal platelet count with functional defects.

References:

Glanzmann Thrombasthenia - StatPearls - NCBI Bookshelf

Harrison’s Principle of Internal Medicine, 21st Edition, Page: 908, 909.

GLANZMANN's THROMBASTHENIA-SPECTRUM OF CLINICAL PRESENTATION ON SAUDI PATIENTS IN THE EASTERN PROVINCE - PMC

↑ *Back to this question in Part A*

@Neet_pg_bot

Q3: A 30-year-old female with a history of recurrent headaches presented for further evaluation. On further workup, haemoglobin and total WBC count were normal, while an elevated platelet count was seen. Bone marrow aspiration showed increased megakaryocytes and a JAK2 mutation. Which is the most likely diagnosis? (Q859739)

A. Polycythemia vera

B. Essential thrombocytosis

C. Primary myelofibrosis

D. Chronic myelogenous leukaemia

Correct Answer: B. Essential thrombocytosis

Explanation: The high platelet count and JAK 2 mutation with increased megakaryocytes in the bone marrow aspiration point to the diagnosis of essential thrombocythemia. Essential Thrombocythemia (ET) This is a type of myeloproliferative neoplasm. Aetiology: Caused by mutations in JAK2, CALR, or MPL genes, known as "driver mutations." Other mutations associated: SH2B3, TP53, IDH2, 20q-, etc. Pathophysiology: JAK2V617F mutation (valine to phenylalanine) activates hematopoietic cytokine receptors, leading to myeloproliferation. CALR mutations result in abnormal protein, affecting cellular proliferation and differentiation. MPL mutations affect thrombopoietin receptor function, increasing thrombocytosis risk. Extreme thrombocytosis (>1 million platelets) can lead to bleeding episodes due to acquired von Willebrand disease. Symptoms & Risks: Characterized by high platelet count and megakaryocytic hyperplasia in bone marrow. Risks include thrombosis, haemorrhage, and potential progression to myelofibrosis or leukemic transformation. Diagnosis: Platelet count >450,000 and presence of JAK2, CALR, or MPL mutation. Bone marrow examination may show megakaryocytic hyperplasia. Management: Cytoreduction may be necessary to manage thrombocytosis and prevent complications like thrombosis. Regular monitoring of platelet count and mutation status is key for management. Polycythemia vera

(Option A) is a myeloproliferative disorder and patients have uncontrolled RBC production. These patients may have raised WBC and platelets due to stimulation of megakaryocyte and myeloid lineages but the most definite feature is the elevated RBC mass. Primary myelofibrosis (Option C): This is a myeloproliferative neoplasm leading to the deposition of fibrous connective tissue in the bone marrow resulting in bone marrow failure. Chronic myelogenous leukaemia (Option D): Characterized by the presence of the BCR-ABL1 gene, it is a type of myeloproliferative disorder mainly involving the overproduction of granulocytes. It is defined by the presence of the Philadelphia chromosome, which results from a translocation between chromosomes 9 and 22 (t(9;22)(q34;q11.2)).

References:

https://www.ncbi.nlm.nih.gov/books/NBK539709/

↑ *Back to this question in Part A*

@Neet_pg_bot

Q4: A 68-year-old male came to the physician with complaints of chronic back pain, easy fatigability and a history of multiple urinary tract infections in the last 3 months. His ESR is elevated, and an x-ray of his skull is shown below. Which of the following investigations is useful for diagnosis? (Q859531)

A. MRI brain

B. PET scan

C. Head CT scan with contrast

D. Serum electrophoresis

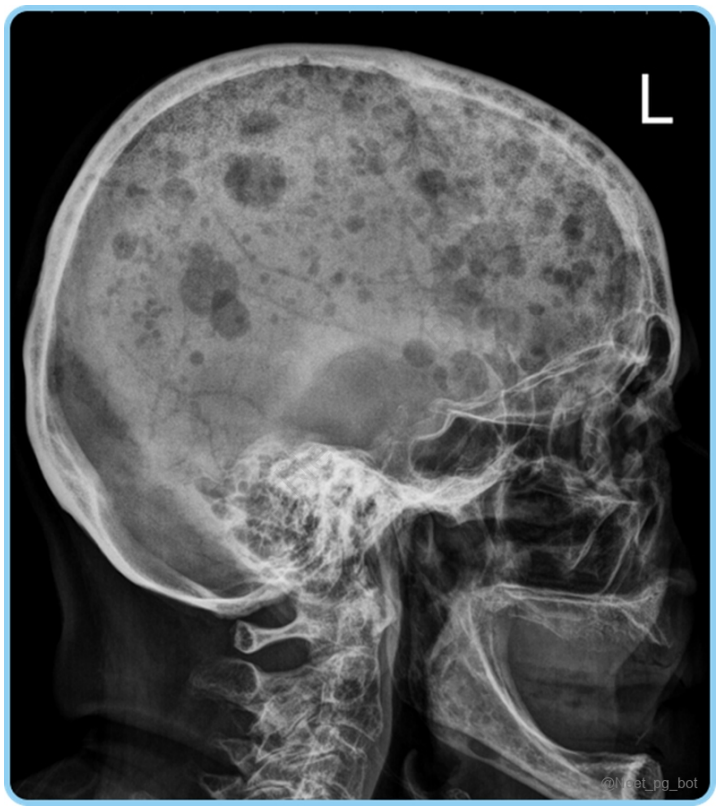

Correct Answer: D. Serum electrophoresis

Explanation: The clinical features of chronic back pain, easy fatigability, and the x-ray skull features depict multiple myeloma Investigations of Multiple myeloma Hematological Analysis: It may reveal anaemia; ESR is usually elevated. Rare cases of plasma cell leukaemia with high plasma cell counts >2000 plasma cells/µL. Serum calcium and urea nitrogen may be elevated. Serum alkaline phosphatase is usually normal. Peripheral smear : Rouleaux formation A/G ratio: Decreased Increased level of β2 microglobulin. Decreased albumin Renal function test: Increased serum creatinine and uric acid. Imaging: Chest and bone radiographs: Lytic lesions/diffuse osteopenia MRI: Extent of bone marrow infiltration and cord or root compression in patients with pain syndrome PET/CT: Assess bone damage, extramedullary sites of the disease Serum or urine electrophoresis: M spike M spikes are monoclonal immunoglobulins The presence of the M spike is a hallmark of monoclonal gammopathies . Serum Protein Electrophoresis (SPEP): (Option D) Preliminary test for multiple myeloma detection Used for detection and quantification of monoclonal gammopathy. Separates serum proteins into five main bands: Albumin, α1 globulins, α2 globulins, β globulins and γ globulins. The gamma region , rich in immunoglobulins, is key in SPEP interpretation for detecting monoclonal gammopathies , which produce a sharp, church-spire-like peak. MRI (Option A) : To evaluate the extent of bone marrow infiltration and cord or root compression in patients with pain syndrome PET/CT (Option B & C) : Assess bone damage, extramedullary sites of the disease Anion gap: (Na + + K +) – (Cl - + HCO 3 -): Decreased Serum light chain assay: Increased Immunofixation: Detects subtypes of light chain 24-hour urine specimen: Bence Jones protein (serum-free light chains) excretion Fat pad biopsy: To detect amyloid deposits Flow cytometry: CD 138+ (bone marrow plasma cells) FISH: Done to detect chromosomal abnormalities Chromosome 17 deletion and translocation leads to poor prognosis. Bone marrow biopsy: Plasmacytosis >10% Clinicopathologic diagnosis of multiple myeloma is based on the following: Clonal plasma cells in bone marrow Presence of CRAB criteria (hypercalcemia, renal dysfunction, anaemia and bone lesions)

References:

Harrison’s Principles of Internal Medicine, 21st Edition, Page 871,872

Davidson’s Principles and Practice of Medicine, 24th Edition, Page 967

Robbins & Cotran Pathologic Basis of Disease, 10th Edition, Page 609

https://pmc.ncbi.nlm.nih.gov/articles/PMC6650180/

https://journals.lww.com/jasn/fulltext/2022/11001/hyperuricemia_and_kidney_function_in_patients.2257.aspx

https://pmc.ncbi.nlm.nih.gov/articles/PMC4973001/

https://www.sciencedirect.com/science/article/abs/pii/S0009912006003213#

https://www.ncbi.nlm.nih.gov/books/NBK539757/#

https://pmc.ncbi.nlm.nih.gov/articles/PMC8627691/

https://www.sciencedirect.com/topics/biochemistry-genetics-and-molecular-biology/immunofixation#:

https://pubmed.ncbi.nlm.nih.gov/18648809/

↑ *Back to this question in Part A*

@Neet_pg_bot

Q5: A ten-year-old boy was brought to the OPD with fever and swelling of his hands after playing football. He gives a history of previous episodes of swelling of his hands. On imaging, his spleen was found to be shrunken. Which of the following is a likely diagnosis? (Q855013)

A. Sickle cell anaemia

B. Malaria

C. Pancreatitis

D. Measles

Correct Answer: A. Sickle cell anaemia

Explanation: The clinical scenario of a child with fever, recurrent swelling of the hands, and a shrunken spleen is consistent with the diagnosis of sickle cell anemia. Clinical Features of Sickle Cell Anemia: Fetal hemoglobin (HbF) persists up to 6 months of life, with a residual amount (<1%) in adulthood. In regions without newborn screening, affected children are typically identified after 6 months of age. Sickle cell disease does not predispose to neonatal jaundice. Fever: Autosplenectomy , along with reduced splenic function, increases susceptibility to infections from encapsulated bacteria: Pneumococci Meningococci H. influenzae Acute abdominal pain: Occurs during vaso-occlusion or distal tissue ischemia. Constant, non-positional abdominal pain, not aggravated by food,

was located in the left upper quadrant and epigastric area. Misdiagnosed as acute pancreatitis or splenic abscess. Bone pain: Sickled cells can obstruct blood flow in blood vessels supplying the bones, leading to inadequate oxygen delivery. Lack of oxygen to bone tissue can cause cell death, leading to a complication called avascular necrosis (AVN). IOC for avascular necrosis: MRI Dactylitis/Hand and foot syndrome: Refers to painful, symmetric swelling of the hands and feet in children with sickle cell disease. It occurs due to infarction of the metacarpals, metatarsals, and phalanges caused by sickled erythrocytes blocking blood vessels. Swelling is followed by hyperemia and subperiosteal new bone formation, visible on radiographs 10-14 days after the swelling subsides. Malaria (Option B): While malaria can cause splenomegaly (enlarged spleen) due to the sequestration of parasitized red blood cells, it does not typically lead to splenic atrophy (shrunken spleen). Additionally, recurrent hand swelling is not a characteristic symptom of malaria. Pancreatitis (Option C) refers to inflammation of the pancreas, typically presenting with severe abdominal pain, nausea, and vomiting. It does not cause symptoms such as fever, hand swelling, or splenic atrophy, which are present in this patient. Measles (Option D) is a viral infection primarily affecting the respiratory system, with characteristic symptoms such as cough, coryza, conjunctivitis, and a maculopapular rash. It does not cause splenic atrophy or recurrent hand swelling, making it unlikely in this case.

References:

Harrison’s Principles of Internal Medicine, 21st Edition, Page 758

https://pmc.ncbi.nlm.nih.gov/articles/PMC9759007/

https://pubmed.ncbi.nlm.nih.gov/3358402/

https://www.ajol.info/index.php/nhp/article/view/119295#

https://pmc.ncbi.nlm.nih.gov/articles/PMC6952462/#

https://www.cdc.gov/sickle-cell/complications/avascular-necrosis.html

https://www.ncbi.nlm.nih.gov/books/NBK537007/#

https://www.ncbi.nlm.nih.gov/pmc/articles/PMC4621170/

↑ *Back to this question in Part A*

@Neet_pg_bot

Q6: Thrombocytopenia, eczema and recurrent infections are seen in: (Q854999)

A. Wiskott-Aldrich syndrome

B. Chediak-Higashi syndrome

C. Thrombocytopenia - absent radius syndrome

D. Hermansky-Pudlak syndrome

Correct Answer: A. Wiskott-Aldrich syndrome

Explanation: Thrombocytopenia, eczema and recurrent infections are seen in Wiskott-Aldrich syndrome. Wiskott-Aldrich Syndrome X-linked recessive Caused by mutations in the gene located at Xp11.23 that encodes Wiskott-Aldrich syndrome protein (WASP) Pathology: Mutations in the WASP gene affect T lymphocytes and other lymphocyte subsets, i.e. dendritic cells, and platelets WASp regulates the actin cytoskeleton and thus plays an important role in many lymphocyte functions, including cell adhesion and migration and the formation of synapses between antigen-presenting and target cell.s Clinical Triad: Immunodeficiency, thrombocytopenia, and eczema. Clinical manifestation: Recurrent bacterial infections Eczema Bleeding Associated with IBD - Colitis Increased risk of development of malignant lymphoma Investigation: IgM levels in the serum are low, but levels of IgG are usually normal. Paradoxically the levels of IgA and IgE are often elevated Blood smear: Thrombocytopenia , reduced-sized platelets, impaired platelet aggregation. Diagnosis is made by expression of intracellular immunofluorescence analysis of WAS protein (WASp) in blood cells. There is defective or absent WAS protein. Treatment: Prophylactic antibiotics Immunoglobulin G (IgG) supplementation Topical treatment of eczema Chediak-Higashi syndrome (Option B) (CHS) is an autosomal recessive disorder characterized by recurrent pyogenic infections, partial oculocutaneous albinism, neurologic abnormalities, and thrombocytopenia. However, eczema is not a feature of CHS. Thrombocytopenia-absent radius syndrome (Option B) (TAR syndrome) is characterized by severe thrombocytopenia at birth and the absence of the radius bone in the forearm, with thumbs typically present. Eczema is not part of the presentation in TAR syndrome. Hermansky-Pudlak syndrome (Option D) involves oculocutaneous albinism, platelet dysfunction causing bleeding, pulmonary fibrosis, and granulomatous colitis. While thrombocytopenia and recurrent infections may occur, eczema is not a characteristic of this syndrome.

References:

Harrison’s Principle of Internal Medicine, 21st Edition, Page 842, 907, 2472, 2716

Robbins & Cotran Pathologic Basis Of Disease, 10th Edition, Page 246

https://www.ncbi.nlm.nih.gov/books/NBK539838/#

↑ *Back to this question in Part A*

@Neet_pg_bot

Q7: For hairy cell leukemia, which drug is considered the preferred choice? (Q856268)

A. Rituximab

B. Vemurafenib

C. Cladribine

D. Interferon-alpha

Correct Answer: C. Cladribine

Explanation: Cladribine (also known as 2-chlorodeoxyadenosine or 2-CdA) is a purine analog chemotherapy drug that has shown high efficacy in the treatment of hairy cell leukemia. It is considered the drug of choice because it achieves high response rates and durable remissions in most patients. Deoxycoformycin is also shown to have a good remission rate. Hairy cell leukemia Mutations BRAF V600E Pathogenesis Mutation of BRAF V600E gene → Activation of the BRAF protein → MAPK/ERK signalling pathway → Uncontrolled proliferation and survival of mature B-cells (Hairy cells). Clinical Presentation Presents with fatigue, recurrent infections, easy bruising, and symptoms related to splenomegaly (e.g., early satiety, abdominal discomfort), pancytopenia Peripheral Blood Findings Hairy cells with round, oblong, or reniform nuclei and pale blue cytoplasm. {{caption_text}} Bone Marrow Biopsy Findings Hypocellular or fibrotic marrow with "hairy cells". Fried egg appearance. {{caption_text}} Diagnosis Flow cytometry Immunophenotyping Genetic testing for BRAF V600E mutation Treatment Splenectomy : Often leads to prolonged remission. Nucleosides (Cladribine, Deoxycoformycin) : Highly effective but cause immunosuppression; Interferon-α (Option D): Effective but less so than nucleosides. Vemurafenib (Option B) (BRAF inhibitor) : Used in chemotherapy-refractory cases; not curative but maintains response with chronic use. Vemurafenib + Rituximab (Option A) : Leads to more durable remissions. Prognosis Excellent While rituximab has shown efficacy in the treatment of various B-cell lymphomas, it is not the drug of choice for hairy cell leukemia. Cladribine is the preferred treatment for HCL. Vemurafenib is a targeted therapy drug primarily used for the treatment of certain forms of metastatic melanoma with BRAF V600E mutation. Interferon-alpha is a type of immunotherapy that has been used in the treatment of hairy cell leukemia in the past. It is now less commonly used.

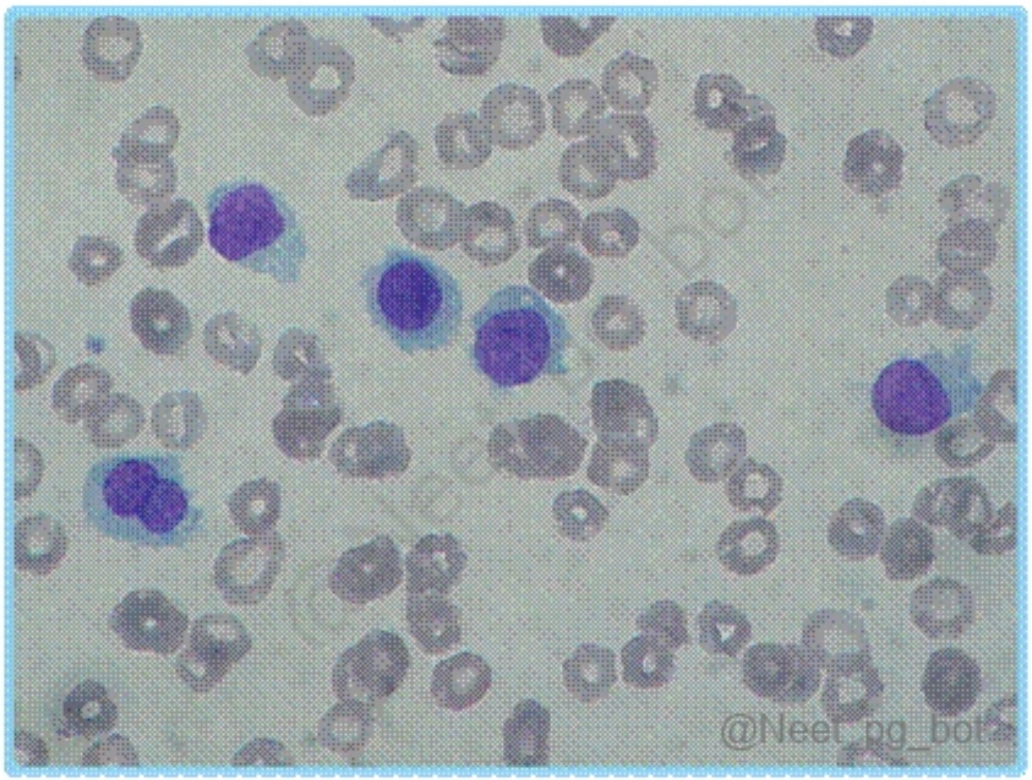

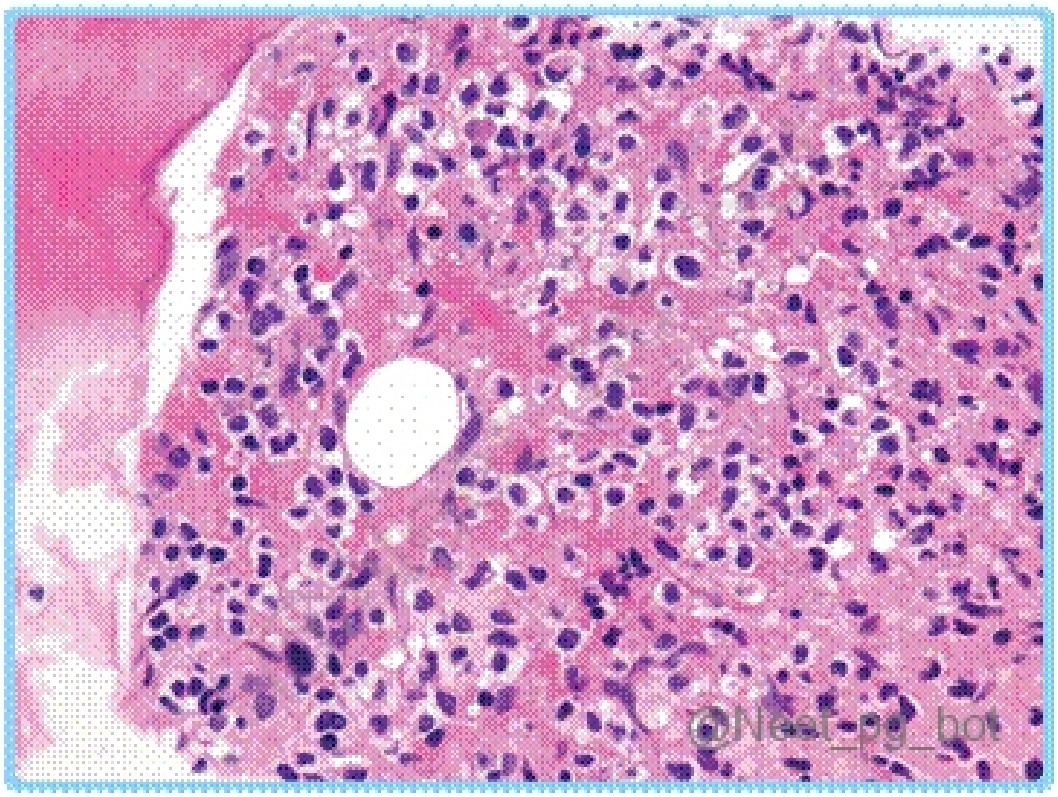

References:

Harrison’s Principles of Internal Medicine, 21st edition, Page 3472, 856

Robbin’s Pathology, 10th edition, Page 604

↑ *Back to this question in Part A*

@Neet_pg_bot

Q8: A 65-year-old woman was brought to the emergency department with symptoms of breathlessness anemia and severe bone pain. On evaluation a hemoglobin level was found to be 5.4 g/dl, urea level of 86 mg/dl, creatinine level of 6 mg/dl, calcium level of 12, and potassium level of 4.4 and the bone marrow aspiration revealed over 60% of plasma cells. Which of the following could be the appropriate next course of action for the management of this patient? (Q856938)

A. Urgent consultation for dialysis

B. Dexamethasone + lenalidomide

C. Dexamethasone + fluids

D. Bone marrow transplantation

Correct Answer: C. Dexamethasone + fluids

Explanation: Clinical and laboratory features of CRAB (hypercalcemia, renal dysfunction, anemia, and bone lesions) and >10% clonal plasma cells in the bone marrow, point towards the diagnosis of Multiple myeloma. The next line of management for this typically involves initiating treatment with a combination of dexamethasone (corticosteroid) and fluids. Investigations of Multiple myeloma: Hematological Analysis: It may reveal anemia; ESR is usually elevated. Rare cases of plasma cell leukemia with high plasma cell counts >2000 plasma cells/μL. Serum calcium and urea may be elevated. Serum alkaline phosphatase is usually normal. Peripheral smear: Rouleaux formation A/G ratio: Decreased Increased level of β2 microglobulin. Decreased albumin Renal function test: Increased serum creatinine and uric acid. Imaging: Chest and bone radiographs: Lytic lesions/diffuse osteopenia MRI: Extent of bone marrow infiltration and cord or root compression in patients with pain syndrome PET/CT: Assess bone damage, extramedullary sites of the disease Anion gap: (Na+ + K+) – (Cl- + HCO3-): Decreased Serum or urine electrophoresis: M spike Serum light chain assay: Increased Immunofixation: Detects subtypes of light chain. 24-hour urine specimen: Bence Jones protein (serum-free light chains) excretion Fat pad biopsy: To detect amyloid deposits Flow cytometry: CD 138+ (bone marrow plasma cells) FISH: Done to detect chromosomal abnormalities Chromosome 17 deletion and translocation leads to poor prognosis. Bone marrow biopsy: Plasmacytosis >10% Treatment of Multiple Myeloma: Induction Phase: Drugs used: Steroids: Dexamethasone/Prednisolone Immunomodulatory agents: Thalidomide/Lenalidomide Proteasome inhibitors: Bortezomib/Carfilzomib Targeted antibodies: Daratumumab (CD 38 Ab) Autologous Stem Cell Transplantation: Involves removal, storage, and reinfusion of the patient's own stem cells after high-dose myeloablative therapy. Prognosis of Multiple Myeloma: Durie-Salmon staging system (earlier) International Staging System (ISS): Three-stage system to predict survival based on: β2-microglobulin Albumin levels Dialysis (Option A) is not the immediate next step in the management of the presented case. Dialysis is primarily used in cases of severe renal failure where conservative management measures have failed. Dexamethasone + lenalidomide (an immunomodulatory drug) (Option B) combination is typically included in the treatment regimen for multiple myeloma, but it is not the immediate next step. Bone marrow transplantation (Option D) is a treatment option for multiple myeloma in certain cases, particularly in younger patients or those with high-risk disease, but not the immediate next step.

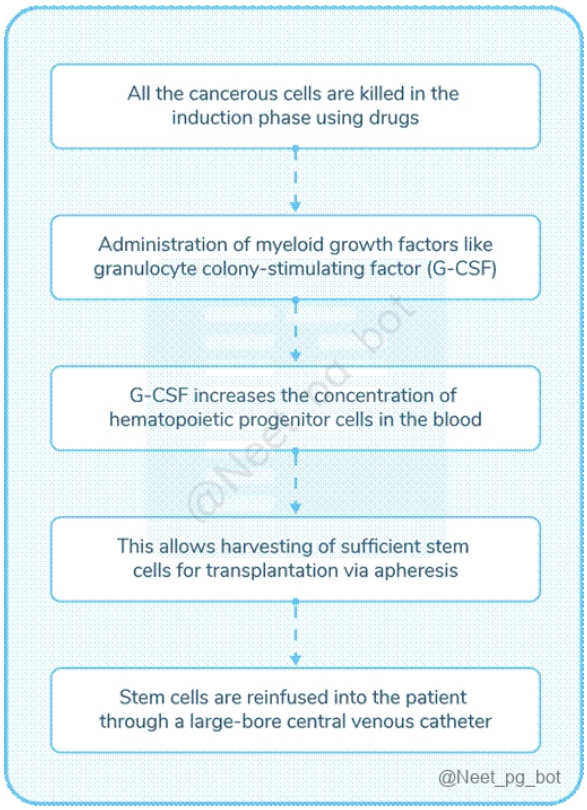

References:

Harrison’s Principles of Internal Medicine, 21st edition, Page 871, 872, 873, 874, 898, 899

Davidson’s Principles and Practice of Medicine, 24th edition, Page 967

Robbins & Cotran Pathologic Basis of Disease, 10th edition, Page 609

↑ *Back to this question in Part A*

@Neet_pg_bot

Q9: A 62-year-old male patient with heart failure is scheduled for a heart transplant. His renal function test is deranged, and haemoglobin is 6gm%. The physician ordered 2 units of whole blood. Four hours after transfusion, he developed severe respiratory distress. On examination, he is hypoxemic, has tachycardia and his mean arterial pressure is elevated. Which of the following are the best investigations for the above scenario? Chest X-ray Brain natriuretic peptide (BNP) level Absolute neutrophil count Leucocyte antibodies Platelets (Q856626)

A. 4 and 5

B. 3 and 5

C. 1 and 2

D. 2 only

Correct Answer: C. 1 and 2

Explanation: O): Features Occur after transfusion of red blood cells or plasma products in 1% to 8.9% of transfusions. Has become the leading cause of transfusion-related deaths Causes/Risk Factors Older age Renal failure Preexisting fluid overload Cardiac dysfunction Administration of a large volume of blood components Excessive transfusion rate beyond the patient's hemodynamic tolerance. Diagnosis Hypoxia, dyspnea Tachycardia Systolic hypertension Left heart failure Pulmonary edema Increased central venous pressure Elevated brain natriuretic peptide (BNP) Chest X-ray: Bilateral alveolar infiltrates Prevention Identify at-risk patients. Close monitoring and slow transfusion rates, 1 RBC concentrate over 3-4 hours. Diuretics for hemodynamically stable patients with a history of TACO. Treatment Stopping the transfusion Administering oxygen Diuretics Absolute neutrophil count (Option 3) (ANC) measures the number of neutrophils and is used to assess infection or inflammation. However, TACO is a condition caused by fluid overload and not by infection or inflammation, so ANC is not relevant in this case. Leucocyte antibodies (Option 4) are typically used to identify immune reactions related to transfusions, such as Transfusion-Related Acute Lung Injury (TRALI) or febrile non-hemolytic transfusion reactions, which are not the primary concern in TACO. Platelets (Option 5): While platelet levels are useful for assessing bleeding or platelet-related disorders, they are not directly relevant in the diagnosis of TACO.

References:

Harrison’s Principles of Internal Medicine, 21st Edition, Page 895

Wintrobe’s Clinical Hematology, 14th Edition, Page 552,572

↑ *Back to this question in Part A*

@Neet_pg_bot

Q10: An elderly woman presented with symptoms of confusion, thirst, and abdominal pain. On examination, she had pallor and thoracic spine tenderness. X-ray spine showed osteolytic lesions. Her lab investigations showed the following findings. What is the most likely diagnosis? Hb - 6.9g/dl WBC 4000/cm3 with normal differential count Serum calcium 13mg/dl Creatinine 2.3mg/dl Total protein 9g/dl Albumin 2.4g/dl (Q856590)

A. Metastatic breast cancer

B. Multiple myeloma

C. Primary hyperparathyroidism

D. Milk alkali syndrome

Correct Answer: B. Multiple myeloma

Explanation: features), hypoalbuminemia, and elevated total proteins, points towards the diagnosis of multiple myeloma. Multiple Myeloma (MM): Malignant disorder characterized by proliferation of a single clone of plasma cells derived from β-cells in the bone marrow. It is the second most common adult hematological malignancy. Most common cancer with skeletal components as its primary site. Investigations of Multiple myeloma: Hematological Analysis: It may reveal anemia ; ESR is usually elevated. Rare cases of plasma cell leukemia with high plasma cell counts >2000 plasma cells/μL. Serum calcium and urea nitrogen may be elevated. Serum alkaline phosphatase is usually normal. Peripheral smear: Rouleaux formation A/G ratio: Decreased Increased level of β2 microglobulin. Decreased albumin Renal function test: Increased serum creatinine and uric acid. Imaging: Chest and bone radiographs: Lytic lesions /diffuse osteopenia MRI: Extent of bone marrow infiltration and cord or root compression in patients with pain syndrome PET/CT: Assess bone damage, extramedullary sites of the disease Anion gap: (Na+ + K+) – (Cl- + HCO3-): Decreased Serum or urine electrophoresis: M spike Serum light chain assay: Increased Immunofixation: Detects subtypes of light chain. 24-hour urine specimen: Bence Jones protein (serum-free light chains) excretion Fat pad biopsy: To detect amyloid deposits Flow cytometry: CD 138+ (bone marrow plasma cells) FISH: Done to detect chromosomal abnormalities Chromosome 17 deletion and translocation leads to poor prognosis. Bone marrow biopsy: Plasmacytosis >10% Clinicopathologic diagnosis of multiple myeloma is based on the following: Clonal plasma cells in bone marrow Presence of CRAB criteria (hypercalcemia, renal dysfunction, anemia and bone lesions) Metastatic breast cancer (Option A): While metastatic breast cancer can involve bones and cause hypercalcemia, the presence of monoclonal gammopathy (elevated total protein) and anemia strongly favors multiple myeloma. Primary hyperparathyroidism (Option C) is typically characterized by hypercalcemia and low phosphorus but does not cause anemia, monoclonal gammopathy, hypoalbuminemia, or osteolytic bone lesions. Milk-alkali syndrome (Option D) arises from excessive intake of calcium and alkali (often in the form of calcium supplements or vitamin D). It results in hypercalcemia, alkalosis, nephrocalcinosis, and nephrolithiasis, none of which are evident in this patient.

References:

Harrison’s Principles of Internal Medicine, 21st edition, Page 871,872

Davidson’s Principles and Practice of Medicine, 24th Edition, Page 967

Robbins & Cotran Pathologic Basis of Disease, 10th Edition, Page 609

https://pmc.ncbi.nlm.nih.gov/articles/PMC6650180/

https://journals.lww.com/jasn/fulltext/2022/11001/hyperuricemia_and_kidney_function_in_patients.2257.aspx

https://pmc.ncbi.nlm.nih.gov/articles/PMC4973001/

https://www.sciencedirect.com/science/article/abs/pii/S0009912006003213#

https://www.ncbi.nlm.nih.gov/books/NBK539757/#

https://pmc.ncbi.nlm.nih.gov/articles/PMC8627691/

https://www.sciencedirect.com/topics/biochemistry-genetics-and-molecular-biology/immunofixation#:

https://pubmed.ncbi.nlm.nih.gov/18648809/

↑ *Back to this question in Part A*

@Neet_pg_bot

Q11: Which of the following interfere with iron absorption? (Q857690)

A. Vitamin C

B. Phytates

C. Oxalate

D. Myoglobin

Correct Answer: B. Phytates

Explanation: Phytates are naturally occurring compounds found in certain plant foods such as whole grains, legumes, and nuts . These compounds have the ability to bind to iron and form insoluble complexes in the digestive tract, significantly reducing iron absorption and bioavailability. Factors Increasing Iron Absorption Factors Decreasing Iron Absorption Acidic stomach environment Vitamin C (ascorbic acid) (Option A Ruled Out) Empty stomach Meat proteins Citric acid Haem iron sources (meat, fish) Fermented foods Iron deficiency state Reduced stomach acid Proton pump inhibitors Antacids Tetracycline (chelates iron) Phytates (Option B) (in cereals, legumes) Tea and coffee (tannins) Calcium-rich foods High fiber meals Vitamin C (Option A): Vitamin C, also known as ascorbic acid, enhances iron absorption rather than interfering with it. It helps in the conversion of non-heme iron (the form of iron found in plant-based foods) to a more absorbable form. Oxalate (Option C): Oxalate, found in certain foods like spinach, rhubarb, and beet greens, can affect calcium absorption, but it does not affect iron absorption. While oxalates can bind to minerals, their primary impact is on calcium rather than iron metabolism. Myoglobin (Option D): Myoglobin is a protein found in muscle tissue that stores oxygen and is found in food such as meat. While myoglobin does contain iron, it is not involved in the absorption of iron from the diet.

References:

https://pubmed.ncbi.nlm.nih.gov/37965925/#:~:text=Different%20components%20in%20food%20can,and%20polyphenols%20reduce%20iron%20absorption.

Harrison’s Principles of Internal Medicine, 21st Edition, Page 748, 749

↑ *Back to this question in Part A*

@Neet_pg_bot

Q12: What is the interpretation of elevated serum Calcium levels in a patient with normal serum alkaline phosphatase, PTH, and Vitamin D3 levels? (Q857688)

A. Vitamin D intoxication

B. Hyperparathyroidism

C. Multiple myeloma

D. Nutritional rickets

Correct Answer: C. Multiple myeloma

Explanation: Multiple myeloma is a malignant plasma cell disorder characterized by the excessive production of monoclonal immunoglobulins (M-protein) . In multiple myeloma, serum calcium levels can be elevated while SAP, PTH, and vitamin D3 levels remain normal . This occurs due to osteolytic lesions and release of calcium from damaged bone tissue due to increased osteoclast activity stimulated by cytokines produced by malignant plasma cells. The normal SAP levels in multiple myeloma help distinguish it from other bone disorders, as SAP is typically elevated in conditions with increased osteoblastic activity . In multiple myeloma, the predominant process is osteolytic rather than osteoblastic , hence SAP remains normal despite bone involvement. Diagnostic Criteria for Multiple Myeloma Presence of clonal bone marrow plasma cells or biopsy-proven bony/extramedullary plasmacytoma and anyone or more of the following myeloma-defining events: Evidence of one or more indicators of end-organ damage attributed to the plasma cell disorder, specifically: (CRAB) Hypercalcemia : Serum calcium >0.25 mmol/L above the upper limit of normal or >2.75 mmol/L (>11 mg/dL) . PTH levels, Vit-D levels are normal Renal Insufficiency : Creatinine clearance <40 mL/min or serum creatinine >177 µmol/L (>2 mg/dL) . Anemia : Hemoglobin >20 g/L below the lower limit of normal or haemoglobin <100 g/L or <10g/100ml . Bone Lesions : One or more osteolytic lesions identified on skeletal radiography, CT, or PET-CT. Biomarkers of Malignancy (any one of the following) : Clonal bone marrow plasma cells ≥60%. Involved: uninvolved serum-free light chain ratio ≥100. 1 focal lesion on MRI studies. Serum markers: Hypercalcemia, ↑ β2 microglobulin Vitamin D intoxication (Option A): In vitamin D intoxication, both serum calcium and vitamin D3 levels are typically elevated. Additionally, PTH levels are usually suppressed due to the negative feedback mechanism between vitamin D and PTH. Since vitamin D3 levels are normal in this case, vitamin D intoxication can be ruled out. Hyperparathyroidism (Option B): Hyperparathyroidism is characterized by increased PTH levels, which stimulate the release of calcium from bone, resulting in elevated serum calcium levels. In this case, since PTH levels are normal, hyperparathyroidism is not the likely diagnosis. Nutritional rickets (Option D): This option is incorrect as nutritional rickets is a condition caused by a deficiency of vitamin D, calcium, or phosphate. In rickets, serum calcium levels would typically be decreased rather than elevated. Additionally, vitamin D levels would be low, which is not the case here.

References:

Harrison’s Principles of Internal Medicine, 21st edition, Page 871

↑ *Back to this question in Part A*

@Neet_pg_bot

Q13: Which of the following investigations should be conducted in a 7-month-old child who has a hemoglobin level of 6.3, a history of recurrent blood transfusions, an MCV

of 70 fl, normal MCH, normal MCHC, and a peripheral smear indicating a hypochromic microcytic image? (Q857031)

A. Serum iron

B. Direct coomb's test

C. Osmotic fragility test

D. Hb electrophoresis

Correct Answer: D. Hb electrophoresis

Explanation: The above child is most probably suffering from thalassemia. The next best step is to get Hb electrophoresis done for confirmation of diagnosis. In Thalassemia, Hb electrophoresis indicates elevated levels of HbF and HbA2. It is best for identifying thalassemia minor HbA2: >3%. Hb electrophoresis Hemoglobin At Birth (1st day) At Adult (6 months) HbF (Fetal Hemoglobin) 95% 2% HbA (Adult Hemoglobin) 2% 95% ($\alpha 2\beta 2$) HbA2 3% 3% Serum iron (Option A) is measured to check for iron overload due to repeated blood transfusions and is not the next best step. Direct coomb's test (Option B) is for autoimmune haemolytic anemia and not for thalassemia. Osmotic fragility test (Option C) is done for hereditary spherocytosis.

References:

Harrison's Textbook for Internal Medicine, 21st edition, Page 436

↑ *Back to this question in Part A*

@Neet_pg_bot

Q14: What is the diagnosis of a 50-year-old man who presents with symptoms of anemia, fever, and recurrent nosebleeds? The patient has hepatosplenomegaly and lab investigations indicate a hemoglobin level of 6g/dL, a total leukocyte count of 40,000/cu.mm with 10% blasts, and a platelet count of 12,000/cu.mm. Further investigation reveals the presence of t(8;21) in the blasts. (Q857007)

A. Acute lymphoblastic leukemia

B. Acute myeloblastic leukemia

C. Preleukemia

D. Aleukemic leukemia

Correct Answer: B. Acute myeloblastic leukemia

Explanation: The diagnosis for this patient is Acute myeloblastic leukemia (AML) as it has clinical and laboratory features consistent with AML and chromosomal translocation of t(8;21). AML is the most common type of acute leukaemia in adults and is typically seen in the elderly. When symptomatic, clinical features are those of pancytopenia. The diagnosis is clinched by bone marrow showing >20% myeloblasts. Emergencies include hyperleukocytosis, neurologic involvement, and DIC. Aetiology of AML: Idiopathic 25-50% cases Bone Marrow Failure Fanconi Anemia Diamond-Blackfan Syndrome Diamond-Blackfan Anemia (DBA) is a rare inherited form of macrocytic anemia characterised by a failure of erythropoiesis in the bone marrow. Shwachman-Diamond Syndrome: An autosomal recessive disorder involving exocrine pancreatic insufficiency. Defective DNA Repair Bloom Syndrome Ataxia Telangiectasia Down Syndrome AML is associated with Down syndrome, particularly the subtype known as Acute Megakaryoblastic Leukemia (AML M7), which involves the GATA1 gene. Exposure to Anticancer Drugs Alkylating agents -> Monosomy 5 & 7 -> AML (After 4-6 years). Anticancer drugs (Topoisomerase 2 inhibitors) -> Chromosome 11 involvement -> AML (After 1-3 years). Radiation Exposure Exposure to radiation, benzene, phenylbutazone, and chloramphenicol may increase the risk of developing AML and bone marrow failure. t(15:17) Chromosomal translocation results in the PML-RARA fusion gene, which is associated with acute promyelocytic leukaemia (APL), a subtype of AML. t(8:21) Chromosomal translocation (RUNX1- RUNX1T1) is associated with myeloid sarcoma. Inversion 16 or t(16;16). - Work up of AML: Blast concentration <20% in peripheral blood/bone marrow aspiration. Decreased Hb Decreased platelet count Decreased TLC initially ALL (Option A) is the most common childhood leukaemia having symptoms such as fever, night sweats, unexplained weight loss painless lymphadenopathy bone pain which are not present here. Pre-leukaemia (Option C) Is a myelodysplastic syndrome Aleukemic leukaemia (Option D) Is a rare type of leukaemia in which the leucocyte count is normal or to the lower side.

References:

Harrison's Textbook for Internal Medicine, 21st edition, Page 809, 810, 811

↑ *Back to this question in Part A*

@Neet_pg_bot

Q15: A 68-year-old male came to the physician with complaints of chronic back pain, easy fatigability, and a past history of multiple urinary tract infections in the last 3 months. His ESR is elevated, x-ray of his skull is shown below. Which of the following investigations is useful for diagnosis? (Q856997)

A. MRI brain

B. PET scan

C. Head CT scan with contrast

D. Serum electrophoresis

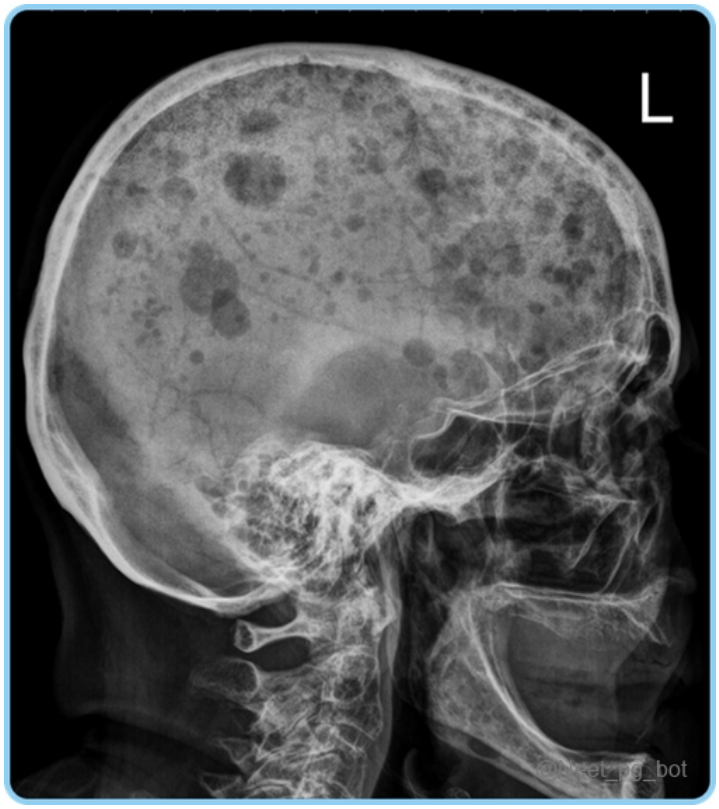

Correct Answer: D. Serum electrophoresis

Explanation: The patient's clinical presentation and x-ray features are suggestive of multiple myeloma. Screening tests for the diagnosis of multiple myeloma: Serum protein electrophoresis > urine protein electrophoresis - Shows spike in monoclonal M-protein Multiple myeloma is a malignant plasma cell dyscrasia which is depicted by uncontrolled proliferation of cells or bone marrow . The skull x-ray reveals Raindrop configuration of Lytic lesions of the skull which is a characteristic feature for multiple myeloma . Diagnostic modalities include hypercalcaemia, creatinine > 2 mg and Bence Jones protein is typical in Urine analysis. Investigations of Multiple myeloma: Hematological Analysis: It may reveal anemia; ESR is usually elevated. Rare cases of plasma cell leukemia with high plasma cell counts >2000 plasma cells/μL. Serum calcium and urea nitrogen may be elevated. Serum alkaline phosphatase is usually normal. Peripheral smear: Rouleaux formation A/G ratio: Decreased Increased level of β2 microglobulin. Decreased albumin Renal function test: Increased serum creatinine and uric acid. Imaging: Chest and bone radiographs: Lytic lesions/diffuse osteopenia MRI: Extent of bone marrow infiltration and cord or root compression in patients with pain syndrome PET/CT: Assess bone damage, extramedullary sites of the disease Anion gap: (Na+ + K+) – (Cl- + HCO3-): Decreased Serum or urine electrophoresis: M spike Serum light chain assay: Increased Immunofixation: Detects subtypes of light chain. 24-hour urine specimen: Bence Jones protein (serum-free light chains) excretion Fat pad biopsy: To detect amyloid deposits Flow cytometry: CD 138+ (bone marrow plasma cells) FISH: Done to detect chromosomal abnormalities Chromosome 17 deletion and translocation leads to poor prognosis. Bone marrow biopsy: Plasmacytosis >10%, often >30% of cellularity Flame cells: Fiery red cytoplasm. Mott cells: Contain multiple grapelike cytoplasmic droplets. Russell bodies: Globular cytoplasmic inclusions. Dutcher bodies: Globular nuclear inclusions. {{caption_text}} Mott cells: Russell bodies seen within the cytoplasm as vesicles {{caption_text}}

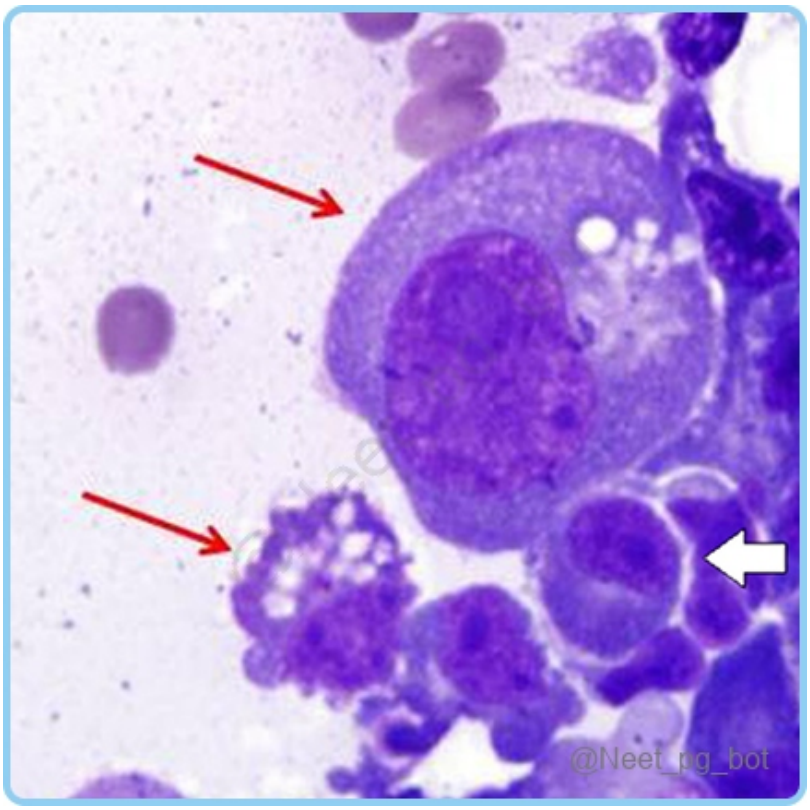

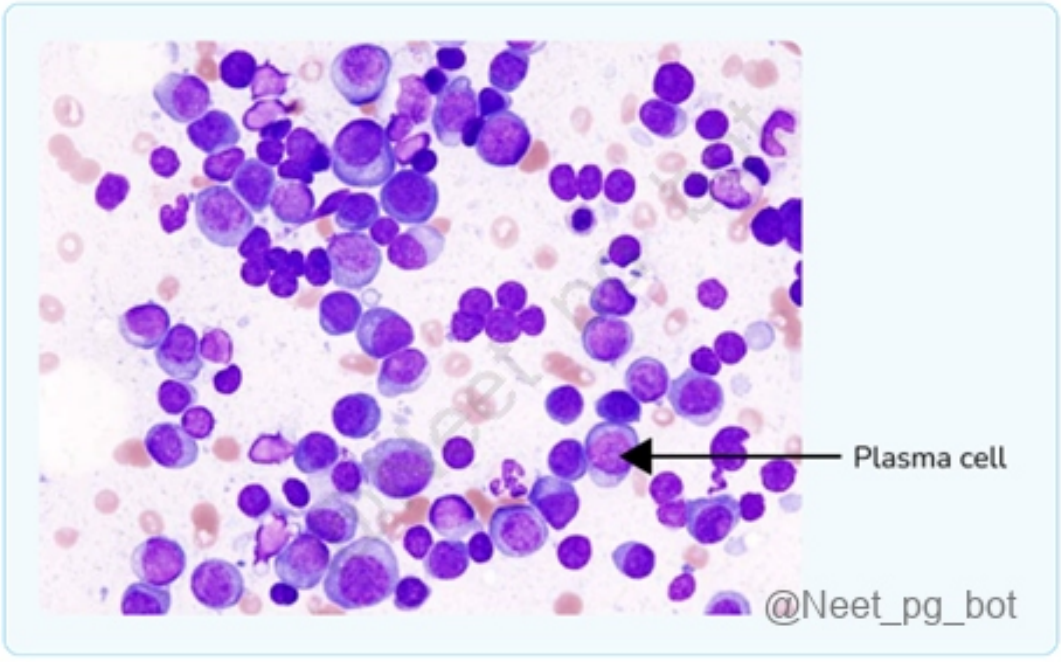

References:

Harrison’s Principles of Internal Medicine, 21st edition, Page 871,872

Davidson’s Principles and Practice of Medicine, 24th edition, Page 967

Robbins & Cotran Pathologic Basis of Disease, 10th edition, Page 609

https://pmc.ncbi.nlm.nih.gov/articles/PMC6650180/

https://journals.lww.com/jasn/fulltext/2022/11001/hyperuricemia_and_kidney_function_in_patients.2257.aspx

https://pmc.ncbi.nlm.nih.gov/articles/PMC4973001/

https://www.sciencedirect.com/science/article/abs/pii/S0009912006003213#

https://www.ncbi.nlm.nih.gov/books/NBK539757/#

https://pmc.ncbi.nlm.nih.gov/articles/PMC8627691/

https://www.sciencedirect.com/topics/biochemistry-genetics-and-molecular-biology/immunofixation#:

https://pubmed.ncbi.nlm.nih.gov/18648809/

↑ *Back to this question in Part A*

@Neet_pg_bot

Q16: A female patient presents to the AIIMS emergency department with severe fatigue. She is a known case of chronic stable angina. While collecting a blood sample, you notice the blood has a brownish hue. What is the underlying diagnosis? (Q855354)

A. Carboxy-hemoglobinemia

B. Sideroblastic anaemia

C. Methemoglobinemia

D. Sulfhemoglobinemia

Correct Answer: C. Methemoglobinemia

Explanation: The underlying diagnosis in this case is methemoglobinemia . Methemoglobinemia is a condition in which there is an increased level of methemoglobin , a form of hemoglobin that is unable to bind and transport oxygen effectively. The blood sample has a characteristic brownish hue on examination. As the patient has a known case of chronic stable angina, it is likely that she is on nitrates, and methemoglobinemia is a side effect of nitrate. Carboxyhemoglobinemia (Option A) results from carbon monoxide poisoning , where CO binds to hemoglobin with high affinity, reducing oxygen delivery. Patients present with cherry-red skin, headache, confusion, and severe hypoxia, but blood appears bright red, not brown . Sideroblastic anemia (Option B) is a disorder of heme synthesis , often associated with iron overload and ringed sideroblasts in the bone marrow , leading to microcytic anemia . It does not cause brown-colored blood. Sulfhemoglobinemia (Option D) is caused by sulfur-containing drugs (e.g., sulfonamides, metoclopramide) , leading to irreversible oxidation of hemoglobin and presenting with greenish/bluish blood and cyanosis , which, unlike methemoglobinemia, does not respond to methylene blue .

References:

Harrison Principles of Internal Medicine, 21 st edition, Page 765, 767

↑ *Back to this question in Part A*

@Neet_pg_bot

Q17: A young woman presents with recurrent headaches, easy bruising, and episodes of visual blurring. Her platelet count is elevated, while her red blood cell (RBC) and white blood cell (WBC) counts are normal. What is the most likely diagnosis? (Q860145)

A. Essential Thrombocytosis

B. Polycythemia Vera

C. Chronic Myeloid Leukemia (CML)

D. Acute Myeloid Leukemia (AML)

Correct Answer: A. Essential Thrombocytosis

Explanation: The clinical manifestations indicate Essential Thrombocytosis , a myeloproliferative neoplasm characterized by an isolated elevation in platelet count. The patient presents with classic symptoms including headaches , easy bruising , and visual disturbances , along with the key diagnostic finding of elevated platelets with normal RBC and WBC counts . This condition results from abnormal proliferation of megakaryocytes in the bone marrow, leading to excessive platelet production. Essential Thrombocytosis Definition Clonal myeloproliferative disorder Characterized by increased platelet production Abnormal megakaryocyte proliferation Genetics JAK2 V617F mutation (50-60% of cases) CALR mutations (type 1 and 2) MPL mutations Lab Findings Platelet count >450,000/µL Increased bone marrow megakaryocytes Normal RBC and WBC Count Clinical Features Often asymptomatic Thrombotic events (arterial > venous) Erythromelalgia Ocular migraines & visual disturbances TIAs Spontaneous bleeding & easy bruising Diagnostic Criteria Platelet count >450,000/µL Bone marrow showing megakaryocyte proliferation Not meeting WHO criteria for other myeloid neoplasms Presence of JAK2, CALR, or MPL mutation Complications Thrombosis (major cause of morbidity) Hemorrhage (especially with counts >1 million/µL) Progression to myelofibrosis Small risk of leukemic transformation Treatment Low-dose aspirin for thrombosis prevention Hydroxyurea for high-risk patients Anagrelide for cytoreduction Plateletpheresis for severe cases Polycythemia Vera (Option B) presents with elevated levels of all three blood cell lines—RBCs, WBCs, and platelets. The normal RBC count in this case makes this diagnosis unlikely. Patients typically present with ruddy complexion, pruritus, and thrombotic complications. Chronic Myeloid Leukemia (Option C) typically shows elevation in granulocytes and often an increase in platelets as well. The presence of normal WBC count makes CML an unlikely diagnosis, as it characteristically presents with marked leukocytosis. Acute Myeloid Leukemia (Option D) typically presents with abnormal levels of blood cells and can show varying counts of WBCs, RBCs, and platelets. The normal blood counts except for platelets make AML less likely, as it usually presents with cytopenias and blast cells in the peripheral blood.

References:

Harrison's Principles of Internal Medicine, 21st Edition, Page 807-808

↑ *Back to this question in Part A*

@Neet_pg_bot

Q18: A child with progressive pallor and bone has an elevated HbS based on the HPLC report. Which is the best treatment to manage hemolysis in this patient? (Q866807)

A. Hydroxyurea

B. Azacytidine

C. Voxelator

D. Bortezomib

Correct Answer: A. Hydroxyurea

Explanation: HPLC (High-Performance Liquid Chromatography) showing elevated HbS indicates Sickle Cell Disease (SCD). SCD is due to a mutation in β-globin gene → HbS polymerizes under low oxygen → sickling → chronic hemolysis + vaso-occlusive crises. Hydroxyurea is the standard of care for all patients with sickle cell anemia and HbS-β0 thalassemia regardless of symptoms. Although in some symptomatic patients with HbSC disease, its benefits in this genotype are understudied. The major mechanism of action of hydroxyurea is to induce high levels of HbF. Hydroxyurea increases HbF unevenly among red cells (heterocellularly), so some cells have greater protection from HbS polymerization than others. Incorrect Options: Azacytidine (Option B) – DNA methyltransferase inhibitor used in myelodysplastic syndromes/AML, not for SCD. Voxelator (Option C): Voxelotor increases the affinity of the hemoglobin molecule for O 2 . Its effects on acute vasoocclusive events are unclear. Bortezomib (Option D) – Proteasome inhibitor used in multiple myeloma, unrelated to SCD.

↑ *Back to this question in Part A*

@Neet_pg_bot

Q19: What defect is seen in Bernard Soulier syndrome? (Q866817)

A. Deficiency of GpIIb/IIIa receptor

B. Deficiency of GpIb receptors

C. Deficiency of von Willebrand factor

D. Deficiency of ADP receptors

Correct Answer: B. Deficiency of GpIb receptors

Explanation: Bernard–Soulier syndrome is a rare autosomal recessive platelet disorder characterized by a defect in platelet adhesion due to deficiency or dysfunction of the platelet membrane glycoprotein Ib (GpIb) complex, which is the receptor for von Willebrand factor (vWF). This defect prevents platelets from binding to exposed subendothelial vWF during vascular injury, leading to defective primary hemostasis. Clinically, it presents with mucocutaneous bleeding, prolonged bleeding time, and thrombocytopenia with giant platelets on peripheral smear. Incorrect Options: Deficiency of GpIIb/IIIa receptor (Option A): Seen in Glanzmann thrombasthenia — causes defective platelet aggregation, not adhesion. Deficiency of von Willebrand factor (Option C): Seen in von Willebrand disease — results in both defective platelet adhesion and secondary coagulation defect due to reduced factor VIII stability. Deficiency of ADP receptors (Option D): Seen in rare platelet function disorders like P2Y12 receptor defects — affects aggregation via ADP pathway, not adhesion.

↑ *Back to this question in Part A*

@Neet_pg_bot

Q20: Which of the following is not a feature of thrombotic thrombocytopenic purpura? (Q853347)

A. Thrombocytopenia

B. Thrombosis

C. Microangiopathic hemolytic anemia

D. Renal failure

Correct Answer: D. Renal failure

Explanation: Renal failure, while it can occur as a consequence of microvascular injury in TTP, is not a defining feature of the disease. Thrombotic Thrombocytopenic Purpura (TTP) is a rare hematological disorder characterized by: Thrombocytopenia (Option A) Thrombosis (Option B) Microangiopathic hemolytic anemia (Option C) TTP vs HUS Feature Thrombotic Thrombocytopenic Purpura (TTP) Hemolytic-Uremic Syndrome (HUS) Etiology Deficiency or antibodies to ADAMTS13 leading to platelet aggregation Diarrhea associated with E. coli O157:H7 or shigella Features Pentad 1. Microangiopathic hemolytic anemia (MAHA) 2. Thrombocytopenia (severe) 3. Renal failure, 4. Neurologic findings 5. Fever Triad 1. Microangiopathic hemolytic anemia (MAHA) 2. Thrombocytopenia 3. Renal failure Age Group More common in adults More common in children Association Often women , especially those with HIV or during pregnancy Preceded by diarrhea , especially hemorrhagic diarrhea Renal Failure Not a predominant feature Renal failure is a hallmark, especially in children ADAMTS13 Activity <10% ADAMTS13 activity is diagnostic ADAMTS13 activity is normal, except in rare cases (Atypical HUS) Common Precipitating Factors Idiopathic Infections (HIV) Medications (Ticlopidine, Cyclosporine) Pregnancy Often follows GI infections Atypical HUS has genetic/ complement involvement Treatment Plasma exchange (mainstay) Glucocorticoids Supportive care Dialysis (in severe cases) Relapse Rate 25-45% relapse Relapses can occur, but less frequent than TTP

References:

Harrison's Principles of Internal Medicine, 21st Edition, Pages 907, 908.

↑ *Back to this question in Part A*

@Neet_pg_bot

Q21: What is the mutation seen in Sickle cell anemia? (Q853348)

A. Glu → Val (6)

B. Lys → Arg

C. Glu → Lysine

D. Ala → Gly (9)

Correct Answer: A. Glu → Val (6)

Explanation: Sickle cell anemia is caused by a missense point mutation in the β-globin (HBB) gene on chromosome 11. This mutation changes - Glutamic acid (Glu) → Valine (Val) at position 6 of the β-globin chain. This single amino-acid substitution produces Hemoglobin S (HbS) . When HbS becomes deoxygenated, it polymerizes , distorting red blood cells into a sickle shape , leading to hemolysis, vaso-occlusion, and recurrent painful crises.

References:

https://pmc.ncbi.nlm.nih.gov/articles/PMC4510747/

https://pmc.ncbi.nlm.nih.gov/articles/PMC5558763/

https://www.ncbi.nlm.nih.gov/books/NBK537130/#

https://www.nirth.res.in/publications/nsth/14.AC.Gorakshakar.pdf

https://www.sciencedirect.com/science/article/pii/S2213398421002244

https://pmc.ncbi.nlm.nih.gov/articles/PMC7053558/#

↑ *Back to this question in Part A*

@Neet_pg_bot

Q22: In hemolytic anemia, which of the following statements are true? Indirect Van den Bergh test is positive. Serum conjugated bilirubin is raised. Serum transaminases

are raised. Urobilinogen is high. GGT is elevated. (Q853352)

A. 1, 3, 5

B. 1, 4

C. 2, 5

D. 1, 4, 5

Correct Answer: B. 1, 4

Explanation: In hemolytic anemia, excessive destruction of red blood cells leads to the following changes Indirect Van den Bergh test is positive (1): Hemolysis causes increased levels of unconjugated (indirect) bilirubin. The indirect Van den Bergh test measures this rise, making it a hallmark of hemolytic anemia. Urobilinogen is high (4): Increased hemoglobin breakdown leads to more bilirubin being converted into urobilinogen in the intestines, resulting in elevated urinary urobilinogen. Serum conjugated bilirubin is raised (2): Hemolysis results in an increase in unconjugated bilirubin, not conjugated bilirubin, which is associated with liver or biliary tract conditions. Serum transaminases are raised (3): Raised transaminases (ALT, AST) are markers of liver damage, not hemolysis. GGT is elevated (5): Gamma-glutamyl transferase (GGT) elevation is specific to liver and biliary tract pathology and is unrelated to hemolysis. Feature Prehepatic Jaundice Hepatic Jaundice Posthepatic (Obstructive) Jaundice Etiology Hemolysis (e.g., hemolytic anemia , malaria) Sickle cell disease G6PD deficiency Liver diseases (e.g., viral hepatitis, cirrhosis, alcoholic liver disease) Liver tumors Drug-induced liver injury Bile duct obstruction (e.g., gallstones, pancreatic cancer, cholangiocarcinoma, strictures, tumors) Mechanism Increased breakdown of red blood cells Excessive bilirubin production Impaired bilirubin conjugation and excretion due to liver dysfunction Blocked bile flow Accumulation of conjugated bilirubin in bloodstream Clinical Features Yellowing of skin and sclera Anemia Fatigue Splenomegaly Yellowing of skin and sclera Fatigue Nausea Hepatomegaly Pruritus Yellowing of skin and sclera Pale stools Dark urine Pruritus Hepatomegaly Bilirubin Elevated unconjugated (indirect) bilirubin Elevated unconjugated and conjugated (direct) bilirubin Elevated conjugated (direct) bilirubin Liver Enzyme Values AST, ALT: Normal or slightly elevated ALP: Normal GGT: Normal AST, ALT: Markedly elevated ALP: Elevated GGT: Elevated AST, ALT: Mildly elevated ALP: Markedly elevated GGT: Elevated Prothrombin time (PT) Normal Prolonged PT Prolonged PT Prolonged PT Urine Normal or slightly dark urine due to excess urobilinogen Dark urine (due to increased conjugated bilirubin) Dark urine (due to conjugated bilirubin) Pale stools (due to reduced bile excretion) Van den Bergh test : Purpose: Differentiates between conjugated and unconjugated bilirubin in serum. Principle: Based on diazotization reaction: Bilirubin reacts with diazotized sulfanilic acid to form a colored complex. Reagents Used: Diazotized sulfanilic acid, methanol (for indirect reaction) Types of Reactions : Reaction Type Findings Bilirubin Type Clinical Significance Direct (Positive within seconds) Immediate pink-red color in aqueous solution Conjugated (Water-soluble) Seen in obstructive jaundice, hepatocellular jaundice Indirect (Delayed or requires methanol) Pink-red color appears only after adding methanol Unconjugated (Water-insoluble) Seen in hemolytic jaundice, Gilbert syndrome, Crigler-Najjar syndrome Biphasic (Both direct and indirect reaction present) Color change seen both in aqueous and after methanol addition Mixed (Conjugated + Unconjugated) Seen in hepatic jaundice (e.g., viral hepatitis, cirrhosis)

References:

Harrison's Principles of Internal Medicine, 21st Edition, Pages 316, 708, 709.

Lippincott’s Illustrated Biochemistry, 6th Edition, Pages 283.

Harper’s Illustrated Biochemistry, 31st Edition, Pages 315.

↑ *Back to this question in Part A*

@Neet_pg_bot

Q23: Which of the following statements regarding von Willebrand disease is incorrect? (Q844288)

A. Type 2 von Willebrand disease is associated with a moderate bleeding tendency

B. Type 3 von Willebrand disease causes almost complete absence of von Willebrand factor, resulting in very low factor VIII levels.Type 3 von Willebrand disease is associated with a complete absence of factor VIII

C. Type 1 von Willebrand disease presents with severe bleeding since childhood

D. Type 2 von Willebrand disease includes subtypes with varying defects in von Willebrand factor.

Correct Answer: C. Type 1 von Willebrand disease presents with severe bleeding since childhood

Explanation: Type 1 VWD is the most common form (≈70–80% of cases). It involves a partial quantitative deficiency of von Willebrand factor (vWF). Bleeding tendency is usually mild to moderate, not severe. Symptoms may include easy bruising, epistaxis, menorrhagia, or bleeding after surgery/dental extraction. Severe bleeding since childhood is more characteristic of Type 3 VWD. Incorrect Options: Option A - Type 2 von Willebrand disease is associated with a moderate bleeding tendency: This statement is correct. Type 2 von Willebrand disease is characterized by a qualitative defect in von Willebrand factor, which leads to a moderate bleeding tendency. This type includes several subtypes with different defects in the von Willebrand factor. Option B -Type 3 von Willebrand disease causes almost complete absence of von Willebrand factor, resulting in very low factor VIII levels: This statement is correct. Type 3 VWD is the most severe form.There is virtually no vWF, leading to markedly reduced factor VIII. Clinical features: severe mucocutaneous bleeding, hemarthroses, and spontaneous hemorrhage, similar to hemophilia. Option D - Type 2 von Willebrand disease includes subtypes with varying defects in von Willebrand factor: This statement is correct. Type 2 von Willebrand disease includes several subtypes (e.g., 2A, 2B, 2M, 2N), each with different defects affecting the function of von Willebrand factor.

↑ *Back to this question in Part A*

@Neet_pg_bot

Q24: Which of the following is incorrect regarding myelodysplastic syndrome? (Q840143)

A. More commonly seen in females

B. Treatment-induced MDS is not dependent on age

C. Median age of onset 70 years

D. It can be radiation-induced

Correct Answer: A. More commonly seen in females

Explanation: Correct Option A - More commonly seen in females: MDS is actually more commonly seen in males than in females. Incorrect Options: Options B, C, and D are true regarding myelodysplastic syndrome. The median age of onset for MDS is around 70 years, making it primarily a disease of the elderly. It can be induced by radiation exposure, either as a part of cancer treatment or from other sources of significant radiation exposure. Treatment-induced MDS is not dependent on age.

↑ *Back to this question in Part A*

@Neet_pg_bot

Q25: A 46-year-old male presents to the outpatient department with a history of lower back pain and painful urination. Upon investigation, he is found to have normocytic normochromic anemia and hypercalcemia. Serum protein electrophoresis reveals an M-spike in the gamma region. Which of the following tests is most appropriate to confirm the diagnosis of multiple myeloma? (Q860141)

A. Liver function test

B. Bence Jones protein in urine

C. Urine albumin-to-creatinine ratio (UACR) test

D. Heat and acetic acid test

Correct Answer: B. Bence Jones protein in urine

Explanation: Clinical features of CRAB (hypercalcemia, renal dysfunction, anemia, and bone lesions), along with the presence of an Gamma region M spike in serum electrophoresis, point towards the diagnosis of Multiple myeloma. Investigations of Multiple myeloma: Hematological Analysis: It may reveal anemia; ESR is usually elevated. Rare cases of plasma cell leukemia with high plasma cell counts >2000 plasma cells/μL. Serum calcium and urea nitrogen may be elevated. Serum alkaline phosphatase is usually normal. Peripheral smear: Rouleaux formation A/G ratio: Decreased Increased level of β2 microglobulin. Decreased albumin Renal function test: Increased serum creatinine and uric acid. Imaging: Chest and bone radiographs: Lytic lesions/diffuse osteopenia MRI: Extent of bone marrow infiltration and cord or root compression in patients with pain syndrome PET/CT: Assess bone damage, extramedullary sites of the disease Anion gap: (Na+ + K+) – (Cl- + HCO3-): Decreased Serum or urine electrophoresis: M spike Serum light chain assay: Increased Immunofixation: Detects subtypes of

light chain. 24-hour urine specimen: Bence Jones protein (serum-free light chains) excretion Fat pad biopsy: To detect amyloid deposits Flow cytometry: CD 138+ (bone marrow plasma cells) FISH: Done to detect chromosomal abnormalities Chromosome 17 deletion and translocation leads to poor prognosis. Bone marrow biopsy: Plasmacytosis >10% Liver function test (Option A): While liver function tests may be abnormal in some patients with multiple myeloma, they are not specific or diagnostic for the condition. LFTs are more useful in assessing liver involvement or complications. Urine albumin-to-creatinine ratio (Option C): This test assesses kidney function and proteinuria but is not specific for multiple myeloma. While renal function may be affected in myeloma, UACR doesn't detect the characteristic Bence Jones proteins. Heat and acetic acid test (Option D): This is an outdated test that is not used in modern diagnosis of multiple myeloma. Current diagnostic methods are more sensitive and specific.

References:

Harrison's Principles of Internal Medicine, 21st Edition, Pages 867-875

↑ *Back to this question in Part A*

@Neet_pg_bot

Q26: A patient presents with fatigue, pallor, and weakness. Laboratory tests reveal low hemoglobin and a markedly low reticulocyte count, while white blood cell and platelet counts remain normal. Which of the following is the most likely diagnosis? (Q860244)

A. Aplastic Anemia

B. Pure Red Cell Aplasia

C. Iron Deficiency Anemia

D. Hemolytic Anemia

Correct Answer: B. Pure Red Cell Aplasia

Explanation: Pure Red Cell Aplasia (PRCA) is characterized by selective failure of red blood cell production , while other cell lines (WBCs and platelets) remain normal. The hallmark laboratory finding is: Low hemoglobin + severe reticulocytopenia (very low reticulocyte count) This reflects the underlying marrow problem: Erythroid precursors are absent or extremely reduced , causing minimal or no reticulocyte release. Common causes include thymoma, autoimmune disease, parvovirus B19 infection, medications, and lymphoid malignancies. Aplastic Anemia (Option A): Produces pancytopenia (↓RBCs, ↓WBCs, ↓platelets). Not consistent with the normal WBC and platelet counts in this case. Iron Deficiency Anemia (Option C): Usually shows increased reticulocyte count after treatment, but even before treatment, reticulocytes are not severely suppressed as in PRCA. Also presents with microcytic hypochromic RBCs , not mentioned here. Hemolytic Anemia (Option D): Characterized by elevated reticulocyte count due to increased marrow response. A low reticulocyte count rules out hemolysis.

References:

Harrison's Principles of Internal Medicine, 21st Edition, Page 798

↑ *Back to this question in Part A*

@Neet_pg_bot

Q27: A 26-year-old female presents with menorrhagia and excessive bleeding after a minor surgery. She gave the history of her father and sister having the same bleeding issues and the pattern of inheritance was determined to be autosomal dominant. What is the most likely disorder? (Q857254)

A. Von Willebrand disease

B. Hemophilia A

C. Christmas disease

D. Factor 10 deficiency

Correct Answer: A. Von Willebrand disease

Explanation: - Von Willebrand disease Von Willebrand disease is the most common bleeding disorder with an autosomal dominant pattern of inheritance. It is the most common inherited bleeding disorder, caused by a deficiency or dysfunction of von Willebrand factor (vWF), a glycoprotein crucial for platelet adhesion and stabilizing factor VIII in the coagulation cascade. Functions of vWF: Platelet Adhesion: Mediates binding of platelets to subendothelial collagen at sites of vascular injury. Stabilization of Factor VIII: Protects Factor VIII from degradation, prolonging its half-life. Clinical manifestation: Superficial bruising, epistaxis, menorrhagia and gastrointestinal haemorrhage Excessive haemorrhage might only be observed after trauma or surgery Heavy menstrual bleeding Might first manifest with dental extractions, particularly wisdom tooth extraction, or tonsillectomy Investigation: Types aPTT vWF antigen vWF activity FVIII activity Multimer Inheritance 1 Normal or ↑ ↓ ↓ ↓ Normal distribution, decreased in quantity Autosomal dominant 2A Normal or ↑ ↓ ↓↓ ↓ Loss of high- and intermediate-MW multimers Autosomal dominant 2B Normal or ↑ ↓ ↓↓ ↓ Loss of high-MW multimers Autosomal dominant 2M Normal or ↑ ↓ ↓↓ ↓ Normal distribution, decreased in quantity Autosomal dominant 2N ↑↑ Normal or ↓ Normal or ↓ ↓↓ Normal distribution Autosomal recessive 3 ↑↑ ↓↓ ↓↓ ↓↓ Absent Autosomal recessive In general, increase in aPTT and BT, but normal PT and platelet count. (Option A) Treatment: Desmopressin (DDAVP) Tranexamic acid or epsilon-aminocaproic acid for mucosal bleeding or non-serious bleeding Factor VIII concentrates are given to manage serious or persistent bleeding Bleeding in type 3 patients responds only to factor VIII/vWF concentrate Hemophilia A (Option B) and Christmas Disease (Option C) have X-linked recessive patterns of inheritance and are not autosomal dominant. Factor 10 deficiency (Option D) has both autosomal dominant and recessive inheritance but AD pattern of inheritance is less common in Factor 10 deficiency.

References:

Harrison’s Principle of Internal Medicine, 21st Edition, Page: 909, 910.

↑ *Back to this question in Part A*

@Neet_pg_bot

Q28: Which of the following is NOT a complication of blood transfusion in a 25-year-old mother who developed acute postpartum haemorrhage, hypovolemic shock, and underwent major blood transfusion after delivering a baby boy? (Q857272)

A. Hypocalcemia

B. Hypokalemia

C. Hypothermia

D. Hyperkalemia

Correct Answer: B. Hypokalemia

Explanation: acterial contamination

References:

Harrison's principles of internal medicine, 21st Edition, Page: 888-896.

↑ *Back to this question in Part A*

@Neet_pg_bot

Q29: Elective splenectomy is preferred in which of the following conditions? (Q858020)

A. G6PD deficiency-Glucose-6-phosphate dehydrogenase deficiency

B. Paroxysmal nocturnal hemoglobinuria

C. Hereditary spherocytosis

D. Hairy cell leukemia

Correct Answer: C. Hereditary spherocytosis

Explanation: lective splenectomy is the primary treatment for Hereditary spherocytosis. In HS, splenectomy is particularly effective because the spleen is the primary site of spherocyte destruction. The timing of splenectomy

varies with disease severity: severe HS requires elective splenectomy at 4-6 years of age, moderate HS can be delayed until puberty, while mild cases may be managed with folic acid supplementation alone. Management of Hereditary Spherocytosis (HS) Splenectomy as Primary Treatment Splenectomy significantly improves anemia by prolonging red cell survival, reducing the need for transfusions, and preventing iron overload and related organ damage. Post splenectomy: Spherocytosis and altered osmotic fragility persist, but reticulocyte counts and erythrocyte lifespan normalize. Blood Film Changes Post-Splenectomy Features like Howell-Jolly bodies , acanthocytes, target cells, cabot ring and Pappenheimer bodies appear after splenectomy. {{caption_text}} Indications for Splenectomy Recommended for patients with severe, transfusion-dependent anemia, growth failure, skeletal changes, leg ulcers, or extramedullary hematopoietic tumors. Timing of Splenectomy : Should be delayed until age 5–9 if possible or at least age 3, to reduce the risk of post-splenectomy sepsis while balancing the increased risk of gallstones in older children. Laparoscopic Splenectomy Preferred method, with benefits like less discomfort, quicker recovery, and shorter hospital stays. Combined laparoscopic splenectomy and cholecystectomy is an option for patients with symptomatic gallstones. Partial Splenectomy Used in infants or young children to alleviate anemia while preserving some splenic immune function. It reduces transfusion needs but may eventually require total splenectomy in about half of patients. Pre- and Post-Splenectomy Care Vaccination : Patients should receive vaccines against pneumococcus, Haemophilus influenzae type B, and meningococcus before surgery. Antibiotic Prophylaxis : Use of prophylactic antibiotics post-splenectomy is controversial but recommended by some for at least 5 years or even lifelong. Folic Acid : Continued supplementation (1 mg/day) is recommended to prevent folate deficiency. G6PD deficiency (Option A): In G6PD deficiency, splenectomy may actually worsen the anemia because the spleen filters and removes damaged red blood cells from the circulation. The primary management involves avoiding oxidative stressors and managing acute hemolytic episodes. Paroxysmal nocturnal hemoglobinuria (Option B): In PNH, there is an abnormality in the complement system, and stem cell transplant is the best curative treatment. Splenectomy is not indicated as the hemolysis is complement-mediated and occurs throughout the circulation. Hairy cell leukemia (Option D): In hairy cell leukemia, chemotherapy is the standard treatment. Splenectomy may be considered only in cases with massively enlarged spleen or if there is resistance to other treatments, but it is not the preferred initial treatment option.

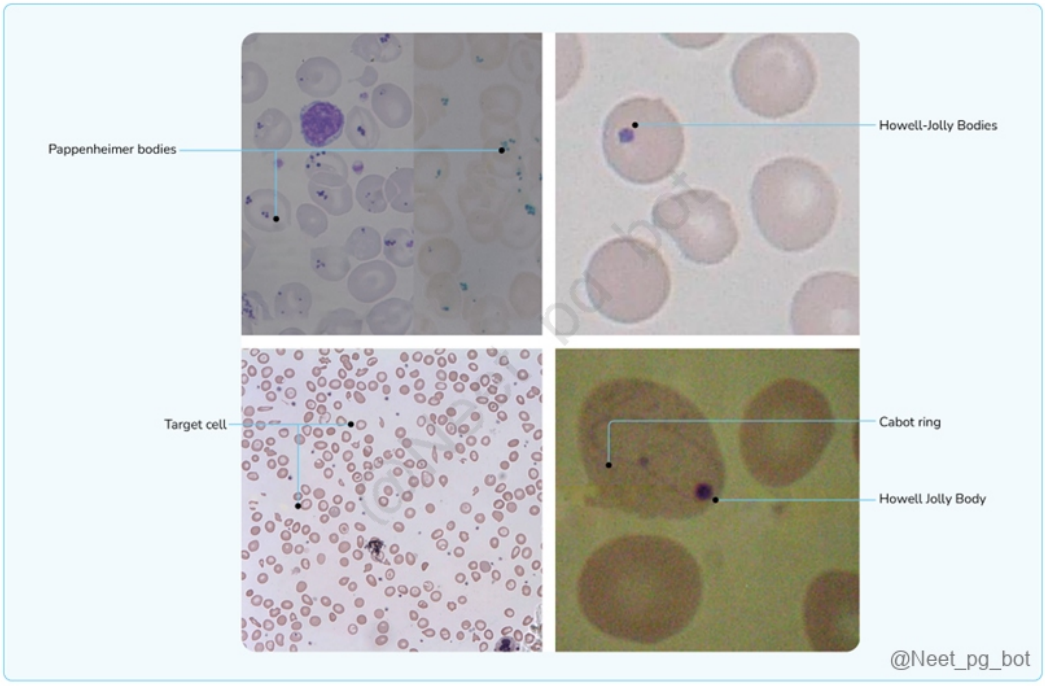

References:

Williams Hematology, 10th Edition, Page 736

↑ *Back to this question in Part A*

@Neet_pg_bot

Q30: Which of the following is not a feature of Gaisböck syndrome? (Q858031)

A. Hypotension

B. Erythrocytosis

C. Normal leukocyte counts

D. Obesity

Correct Answer: A. Hypotension

Explanation: lcohol reduction/cessation Stress management

References:

https://pmc.ncbi.nlm.nih.gov/articles/PMC8865286/

↑ *Back to this question in Part A*

@Neet_pg_bot

Q31: A 60-year-old man presents with fatigue, pallor, weight loss, and heaviness in the left hypochondrium, for the past 2 months. Abdominal palpation reveals splenomegaly. His hemogram and peripheral smear results are given below. What is the most likely diagnosis? Hemogram: Hb-10 gm/dl WBC count – 1,65,000/cu.mm (leukocytosis) Platelet count – 3 lakhs/mm 3 Peripheral smear: Metamyelocytes – 15% Promyeloblasts – 30% Myeloblasts – 45% (Q793841)

A. Chronic lymphocytic leukemia

B. Chronic myeloid leukemia

C. Acute lymphoblastic leukemia

D. Acute myeloid leukemia

Correct Answer: B. Chronic myeloid leukemia

Explanation: The most likely diagnosis for the patient in this scenario is chronic myeloid leukemia (CML). The patient has leukocytosis with a very high white blood cell count (1,65,000/cu.mm), which is a hallmark of CML. Additionally, the peripheral smear shows an increase in myeloblasts, promyelocytes, and metamyelocytes, which are immature forms of white blood cells commonly seen in CML. Incorrect choices: Option A: Chronic lymphocytic leukemia (CLL) is a type of leukemia that typically presents with lymphocytosis, or an increase in lymphocytes, rather than leukocytosis. The peripheral smear would also show an increase in lymphocytes rather than myeloid cells. Option C: In Acute lymphoblastic leukemia (ALL) , the peripheral smear would show a predominance of lymphoblasts rather than myeloblasts. Option D: In Acute myeloid leukemia (AML) is a type of leukemia that presents with symptoms such as fatigue, fever, and easy bruising or bleeding. AML typically presents with more acute symptoms and a shorter disease course compared to CML.

References:

Harrison's Principles of Internal Medicine, 21e

↑ *Back to this question in Part A*

@Neet_pg_bot

Q32: What would be the most appropriate course of action for managing a patient presenting with fatigue, a haemoglobin level below 9 g/dl, and sickle-shaped red blood cells on peripheral smear examination? (Q793796)

A. Administer IV antibiotics

B. Blood transfusion

C. Administer desferoxamine

D. Wait and watch

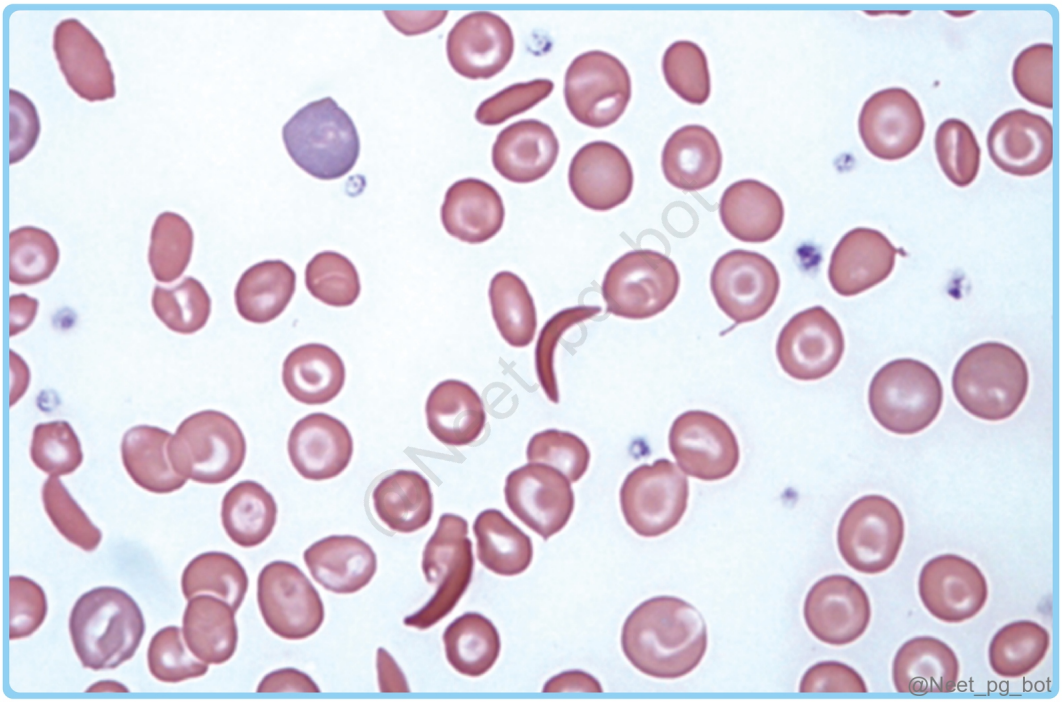

Correct Answer: B. Blood transfusion

Explanation: The most appropriate course of action for managing a patient presenting with fatigue, a hemoglobin level below 9 g/dL, and sickle-shaped red blood cells on peripheral smear examination is blood transfusion . In patients with sickle cell disease (SCD), a hemoglobin (Hb) level below 9 g/dL accompanied by symptoms such as fatigue indicates significant anemia. Blood transfusion is the primary treatment to increase the oxygen-carrying capacity of the blood, alleviate symptoms, and prevent complications associated with severe anemia. According to the 2014 evidence-based report by expert panel members, transfusion therapy is recommended in SCD patients with symptomatic anemia to improve oxygen delivery and reduce the risk of stroke and other complications. Administer IV antibiotics (Option A): While antibiotics are essential in managing infections in SCD patients, they do not address anemia directly. Administer desferoxamine (Option C): Desferoxamine is an iron-chelating agent used to treat iron overload from chronic transfusions. It is not suitable for acute management of anemia. Wait and watch (Option D): Delaying treatment in symptomatic anemia can lead to worsening hypoxia and increased risk of complications.

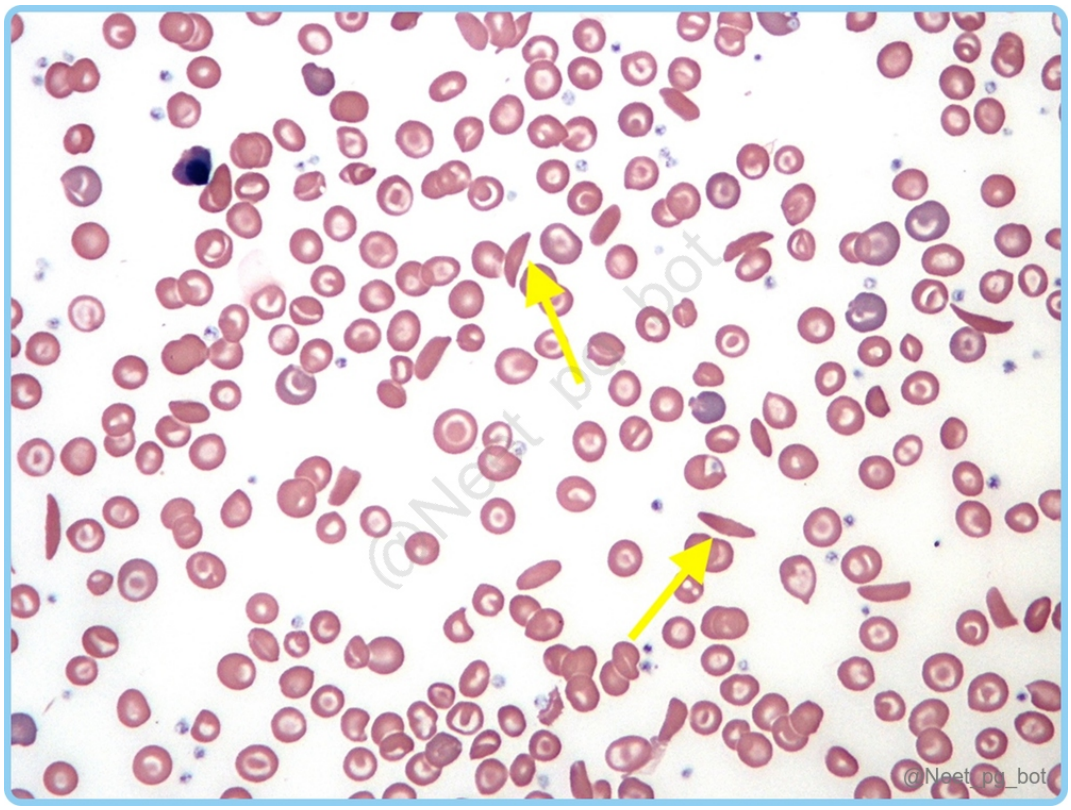

References:

https://www.ncbi.nlm.nih.gov/books/NBK482164/ https://pmc.ncbi.nlm.nih.gov/articles/PMC10195315/

↑ *Back to this question in Part A*

@Neet_pg_bot

Q33: An elderly woman presented with symptoms of confusion, thirst, and abdominal pain. On examination, she had pallor and thoracic spine tenderness. Her lab investigations showed the following findings. An x-ray of her skull is shown below. What is the most likely diagnosis? Hb-6.9g/dl WBC 4000/cm3 with normal differential count Serum calcium 13mg/dl Creatinine 2.3mg/dl Albumin 2.4g/dl Urinalysis: positive for Bence-Jones proteins (Q793847)

A. Metastatic breast cancer

B. Multiple myeloma

C. Primary hyperparathyroidism

D. Milk alkali syndrome



Correct Answer: B. Multiple myeloma

Explanation: Option B. Multiple myeloma: Multiple myeloma, also known as plasma celldyscrasia, presents with CRAB features C- Hypercalcemia R- Renal failure A- Anemia B- Bleeding The X-ray of the skull showing lytic lesions- Classical rain drop configuration. Incorrect choices: Option A: Metastatic breast cancer: Metastasis of breast cancer to the bones can cause hypercalcemia, bone pain, and pathological fractures. Option C: Primary hyperparathyroidism is a condition in which there is an overproduction of parathyroid hormone, leading to hypercalcemia. Option D: Milk alkali syndrome is a condition that can occur due to excessive intake of calcium and absorbable alkali. This can lead to hypercalcemia and metabolic alkalosis.

References:

Harrison's Principles of Internal Medicine, 21e

↑ *Back to this question in Part A*

@Neet_pg_bot

• [07_Neurology] 048 Epilepsy And Eeg

« Back to Folder Directory

[07_Neurology] 048 Epilepsy And Eeg — Quick Jump

Q1 (p. 2189)	*Q2 (p. 2190)*	*Q3 (p. 2190)*	*Q4 (p. 2191)*	*Q5 (p. 2192)*	*Q6 (p. 2193)*
Q7 (p. 2194)	*Q8 (p. 2195)*	*Q9 (p. 2200)*	*Q10 (p. 2201)*	*Q11 (p. 2202)*	*Q12 (p. 2203)*
Q13 (p. 2204)	*Q14 (p. 2206)*	*Q15 (p. 2208)*	*Q16 (p. 2209)*	*Q17 (p. 2211)*	*Q18 (p. 2212)*
Q19 (p. 2213)	*Q20 (p. 2213)*	*Q21 (p. 2214)*	*Q22 (p. 2215)*	*Q23 (p. 2217)*	*Q24 (p. 2217)*
Q25 (p. 2218)					

Q1: Most common childhood epilepsy syndrome is? (Q851091)

A. Janz Syndrome

B. Lennox-Gastaut Syndrome

C. Rolandic epilepsy

D. Febrile seizures

Correct Answer: C. Rolandic epilepsy

■ *Listen (English)*

■ *Listen (Hindi)*

Explanation: Most common seizure seen in children is febrile seizures and leading childhood epilepsy syndrome is Benign rolandic epilepsy (bening because of self limiting nature). Note that question is not asking most type of seizures in children but the most common type of epilepsy syndrome. Benign Rolandic Epilepsy Occurs in children aged 4–10 years Seizures often occur during sleep and involve face and cause drooling of saliva. Episodes during awake stage might lead to speech arrest Self-limiting , resolves by adolescence EEG: centrotemporal spikes Carbamazepine is used for focal seizures seen Janz Syndrome (Juvenile Myoclonic Epilepsy - JME) (Option A): This is the most common idiopathic generalized epilepsy syndrome, but its onset is typically in adolescence (mean age 12-18 years), making it less common than Rolandic epilepsy in the general "childhood" population. Lennox-Gastaut Syndrome (LGS) (Option B): This is a severe and rare form of childhood epilepsy (an epileptic encephalopathy). It accounts for only about 1-2% of childhood epilepsies. Febrile seizures (Option D): This is a key distinction. While febrile seizures are the most common type of seizure in childhood (affecting 2-5% of young children), they are generally not considered an epilepsy syndrome . Epilepsy is defined as a tendency toward recurrent, unprovoked seizures. Febrile seizures are provoked by fever and typically do not require chronic anti-seizure medication.

References:

https://www.ncbi.nlm.nih.gov/books/NBK534845/

↑ *Back to this question in Part A*

@Neet_pg_bot

Q2: Match each drug with its preferred use for the corresponding type of seizure. 1. Focal seizures a. Lorazepam 2. Dravet syndrome b. Clobazam 3. Febrile seizures prophylaxis c. Cannabinoids 4. Status epilepticus d. Carbamazepine (Q851113)

A. 1-d, 2-c, 3-b, 4-a

B. 1-c, 2-d, 3-b, 4-a

C. 1-b, 2-d, 3-a, 4-c

D. 1-d, 2-b, 3-a, 4-c

Correct Answer: A. 1-d, 2-c, 3-b, 4-a

■ *Listen (English)*

■ *Listen (Hindi)*

Explanation: Antiepileptic Drug Choice by Seizure Type: Type of Seizure Anti-Epileptic Drugs Partial or focal seizure Lamotrigine Oxcarbazepine Eslicarbazepine Carbamazepine Phenytoin Levetiracetam Febrile seizure Lorazepam or diazepam (rectal) Prevention: Oral clobazam and diazepam Status epilepticus Lorazepam Dravet's syndrome Valproate (drug of choice) and cannabinoids



References:

Harrison’s Principles of Internal Medicine, 22nd Edition, Page 3421, 3422, 3423.

↑ *Back to this question in Part A*

@Neet_pg_bot

Q3: A 27-year-old woman with a history of seizures and poor medication adherence presents to the ER after a 6-minute seizure followed by another, with impaired consciousness between episodes. She is unresponsive and has labored breathing.

Which of the following is correct about managment this patient? (Q851112)

A. IV Lorazepam followed by phenytoin infusion

B. Rectal diazepam followed by midazolam drip

C. Intranasal midazolam

D. IV midazolam infusion

Correct Answer: A. IV Lorazepam followed by phenytoin infusion

■ *Listen (English)*

■ *Listen (Hindi)*

Explanation: The scenario describes a seizure lasting 6 minutes with impaired consciousness during the interictal period, indicating impending and early status epilepticus . The treatment in this case is IV Lorazepam followed by Phenytoin infusion. Rectal diazepam + midazolam drip (Option B) : Rectal route is for prehospital or pediatric use; midazolam infusion is for refractory SE. Intranasal midazolam (Option C) : Used if IV access is unavailable, not in ER setting with IV access and labored breathing. IV midazolam infusion (Option D) : Reserved for refractory status (seizures not controlled with first/second-line therapy).

References:

Harrison’s Principle of Internal Medicine, 22nd Edition, Page 3426.

↑ *Back to this question in Part A*

@Neet_pg_bot

Q4: A 4 year girl presents to the clinic with a frequent seizure episodes. You notice she has port-wine stain on her forehead and upper eyelid. Neuroimaging reveals tram-track calcifications in the brain. Which type of seizures is seen in this condition ? (Q851111)

A. Focal seizures

B. Myoclonic jerks

C. Atonic seizures

D. Febrile seizures

Correct Answer: A. Focal seizures

■ *Listen (English)*

■ *Listen (Hindi)*

Explanation: The combination of a port-wine stain in the trigeminal distribution, seizures, unilateral weakness, and tram-track calcifications aligns with the clinical features of Sturge-Weber syndrome. It has focal-onset seizures because of leptomeningeal angiomas causing unilateral cortical irritation. They can secondarily generalize to tonic-clonic seizures. Seizures usually start in infancy, often within the first year of life.

References:

Harrison's Principles of Internal Medicine, 22nd Edition, Page 3409.
https://www.ninds.nih.gov/health-information/disorders/sturge-weber-syndrome

↑ *Back to this question in Part A*

@Neet_pg_bot

Q5: Which of the following manifestations is earliest to be seen in this neurocutaneous disorder (Q851110)

A. A

B. B

C. C

D. All of the above



Correct Answer: C. C

■ *Listen (English)*

■ *Listen (Hindi)*

Explanation: The presence of A= facial angiofibromas, B= shagreen patches, C= Hypomelanotic macules aligns perfectly with the clinical features of tuberous sclerosis. Hypopigmented macules (also called “ ash leaf spots ”) are usually the earliest skin manifestation, often seen at birth or in infancy. Adenoma sebaceum appear between 2–5 years of age and become more prominent at puberty, due to hormonal influences.

References:

Harrison’s Principles of Internal Medicine, 22nd Edition, Page 723.

↑ *Back to this question in Part A*

@Neet_pg_bot

Q6: Which of the following is not correct about SSPE? (Q851107)

A. Delayed neurological complication of measles vaccine

B. CSF IgG Measles antibody

C. Periodic generalized high-voltage slow-wave complexes

D. Isoprinosine improves survival

Correct Answer: A. Delayed neurological complication of measles vaccine

■ *Listen (English)*

■ *Listen (Hindi)*

Explanation: SSPE is caused by persistent defective measles virus in the brain (usually wild-type virus). It a ppears an average of ~6–8 years after natural measles infection. It is not caused by MMR vaccine (measles-mumps-rubella). The risk is highest if measles infection occurred before age 2 of years. Inosine pranobex (Inoprinosine) is an antiviral and immunomodulatory agent that has been used to improve survival along with intraventricular interferon. SSPE can be diagnosed if three out of five criteria are met: Typical clinical presentation (progressive neurologic deterioration) EEG showing stereotyped periodic complexes/ Periodic generalized high-voltage slow-wave complexes Brain biopsy or autopsy with characteristic histopathological findings CSF globulin levels greater than 20% of total CSF protein Elevated CSF measles antibody titers (≥1/4 by hemagglutination inhibition or ≥1/20 by ELISA)

References:

Harrison’s Principles of Internal Medicine, 22nd Edition, Page 1117, 1118.

↑ *Back to this question in Part A*

@Neet_pg_bot

Q7: A 10 year boy unvaccinated child is brought to hospital with increased irritability, social withdrawal, and difficulty in school. On examination he has myoclonic jerks and motor difficulties. EEG shows periodic spikes of slow-wave discharges occurring every 4–10 seconds. Select the best investigation to be performed in this patient? (Q851105)

A. CSF electrophoresis showing oligoclonal bands

B. CSF showing albuminocytogical dissociation

C. CSF shows Anti measles antibody

D. CSF IgG index

Correct Answer: C. CSF shows Anti measles antibody

■ *Listen (English)*

■ *Listen (Hindi)*

Explanation: A 10-year-old unvaccinated child with behavioral changes, myoclonic jerks, motor decline , and EEG showing periodic high-voltage slow-wave complexes every 4–10 seconds is classic for Subacute Sclerosing Panencephalitis (SSPE) —a late complication of measles. Best confirmatory test : CSF measles IgG antibody (elevated) — strongly supports SSPE diagnosis CSF electrophoresis showing oligoclonal bands (Option A): Seen in multiple sclerosis, not in SSPE. CSF showing albuminocytologic dissociation (Option B): Characteristic of Guillain–Barré syndrome (GBS) — high protein, normal cells. SSPE does not present this way. CSF IgG index (Option D): May be mildly elevated in SSPE, but not the diagnostic test of choice. Specific anti-measles antibody is required for confirmation.

References:

Harrison’s Principles of Internal Medicine, 22nd Edition, Page 1118.

↑ *Back to this question in Part A*

@Neet_pg_bot

Q8: Match the following conditions with their respective EEGs. 1) Focal seizure a) 2) Absence seizure b) 3) Hypsarrythmia c) 4) Periodic sharp wave complexes d) (Q851102)

A. 1-c, 2-a, 3-d, 4-b

B. 1-b, 2-d, 3-c, 4-a

C. 1-d, 2-c, 3-b, 4-a

D. 1-d, 2-b, 3-c, 4-a

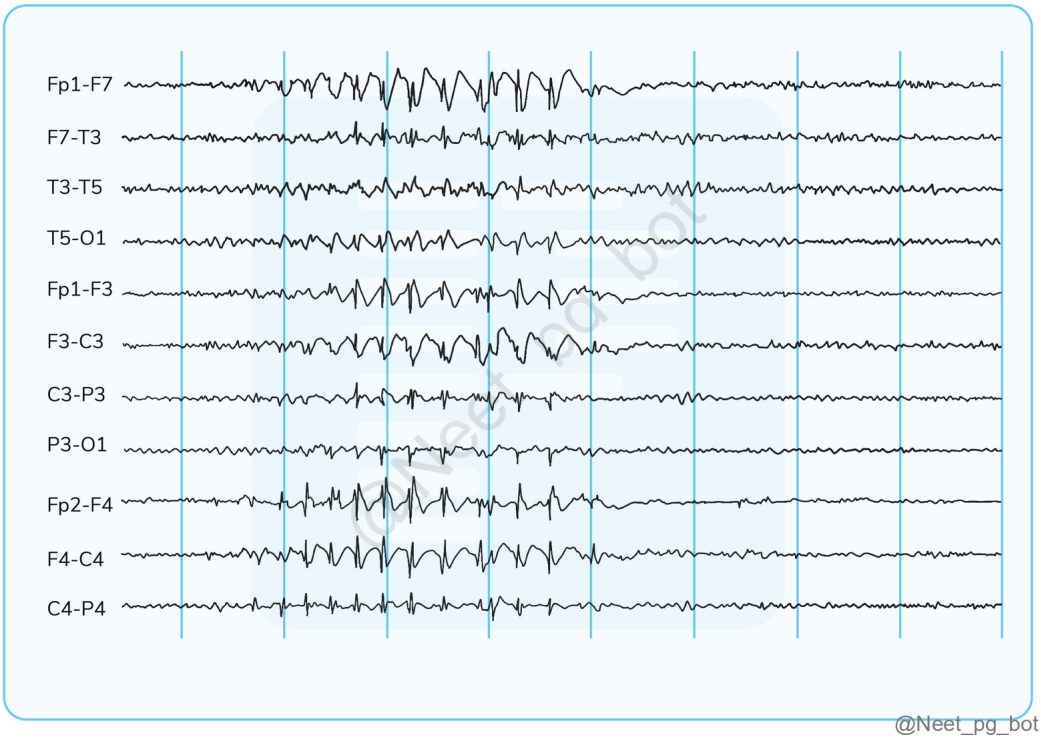

@Neet_pg_bot

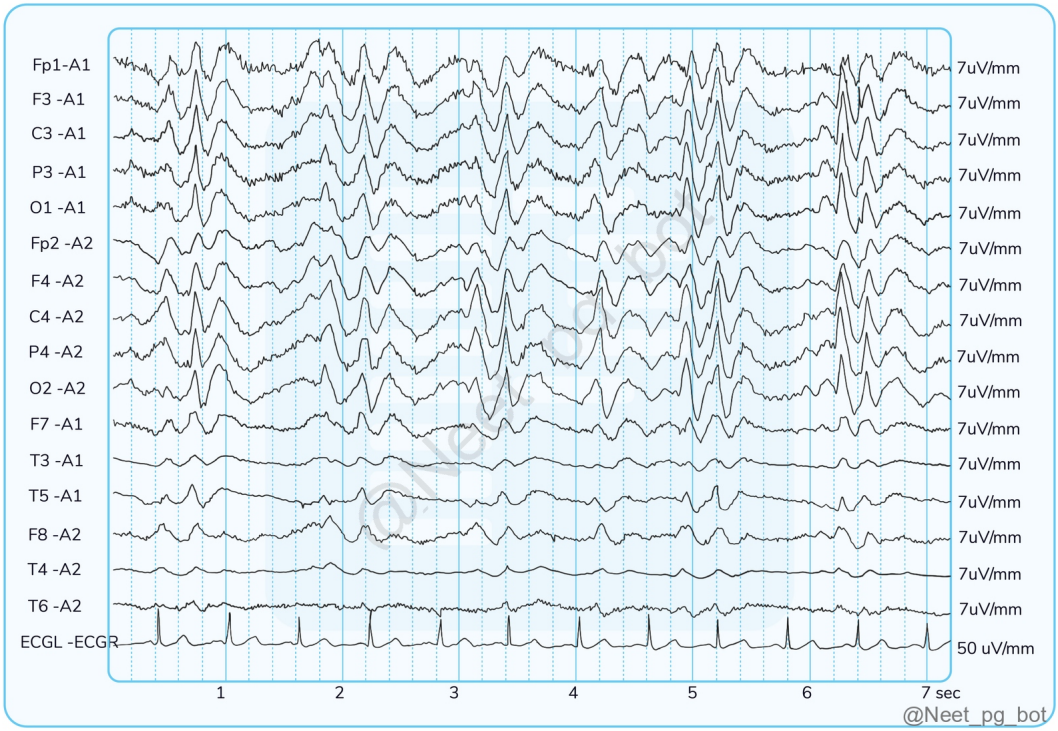

@Neet_pg_bot

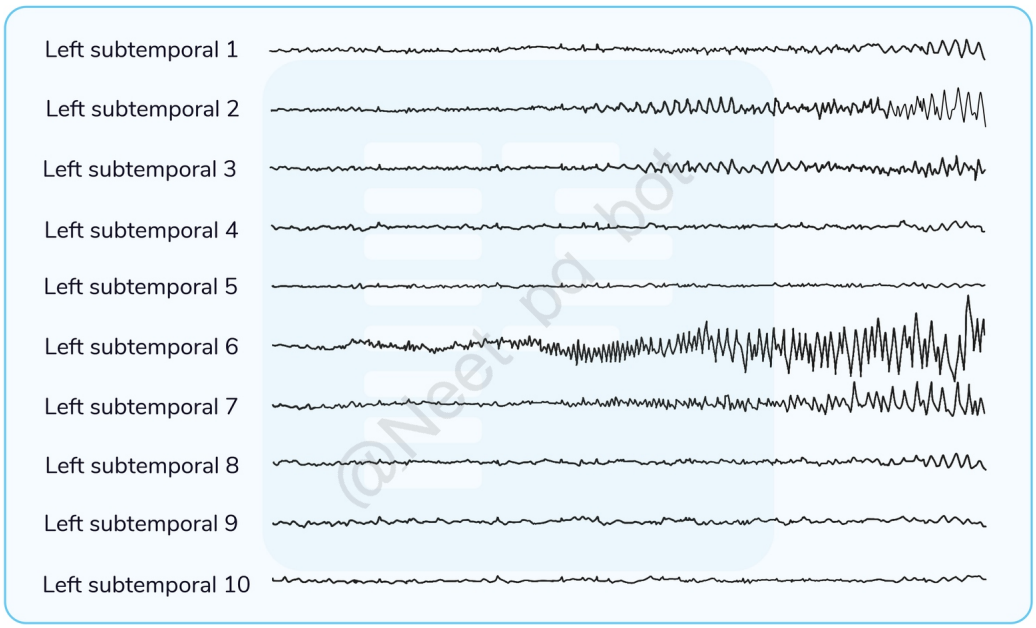

@Neet_pg_bot



@Neet_pg_bot

Correct Answer: A. 1-c, 2-a, 3-d, 4-b

■ *Listen (English)*

■ *Listen (Hindi)*

Explanation: Focal seizure EEG shows localized spikes or sharp waves in the region of the brain corresponding to the seizure onset. Absence seizure EEG exhibits 3 Hz spike-and-slow wave discharges, typically generalized and symmetric. Hypsarrythmia EEG presents chaotic, bursts of bilateral asynchronous high-amplitude slow waves

interspersed with spikes followed by generalized voltage attenuation. Periodic sharp wave complexes EEG reveals generalized synchronized high-voltage sharp waves occurring at 1–2 Hz.

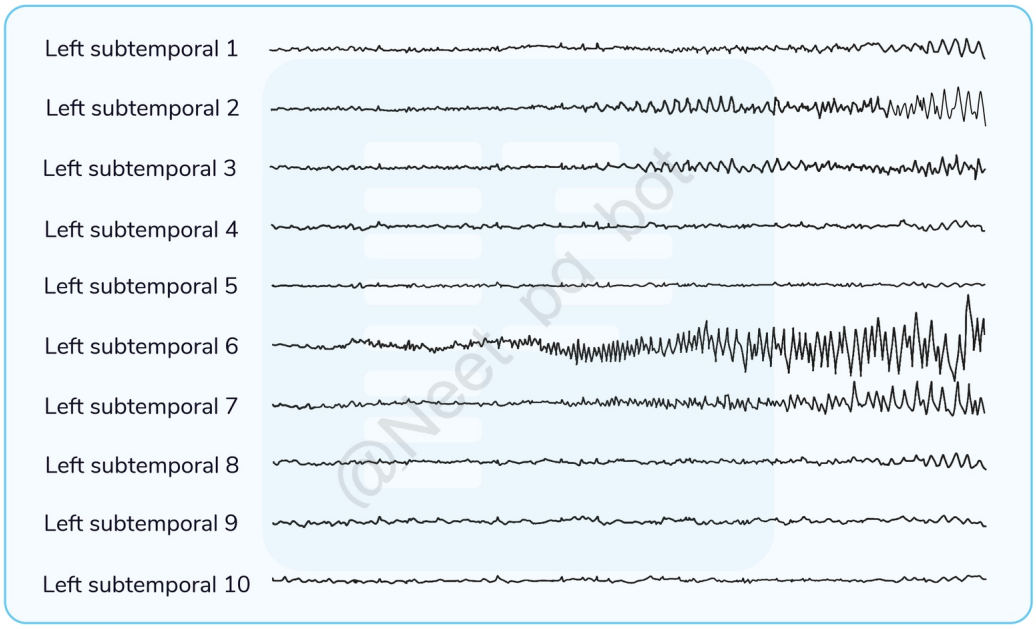

@Neet_pg_bot

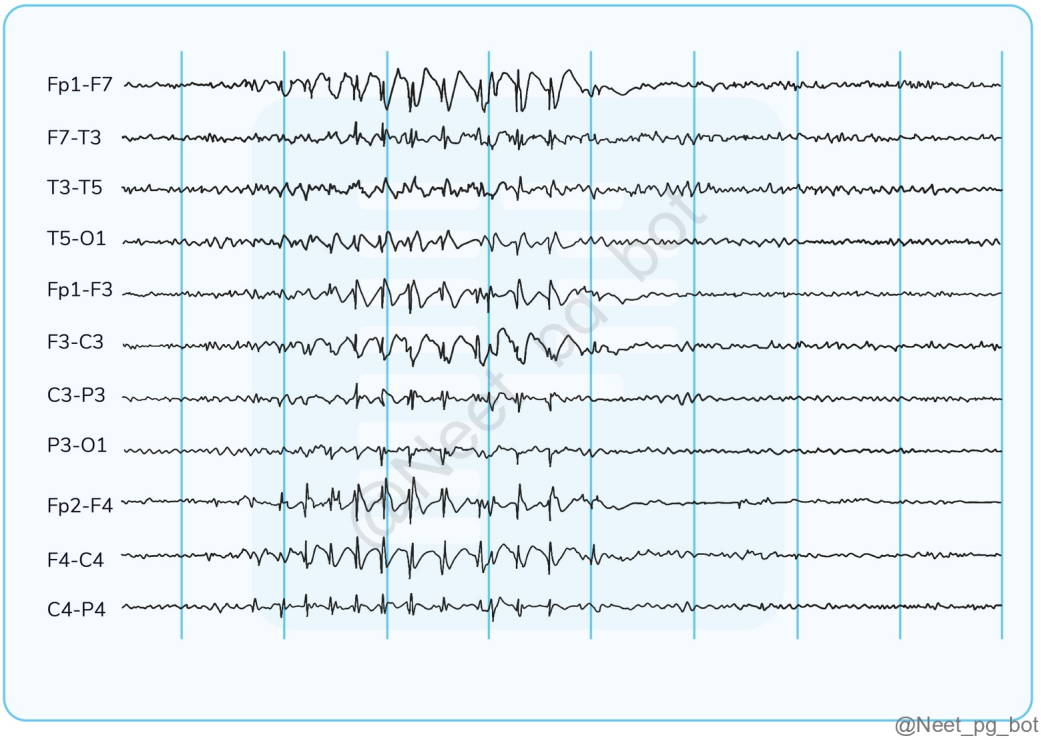

@Neet_pg_bot



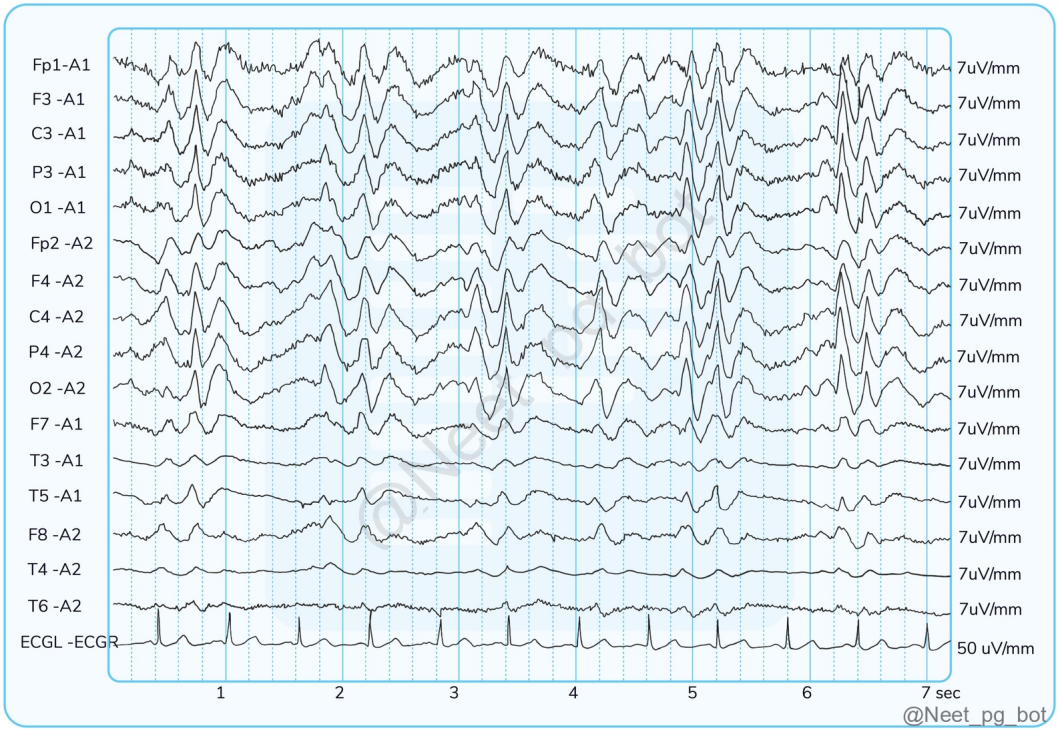

References:

Harrison's Principles of Internal Medicine, 22nd Edition, Page 3409, 3410, 3417, 3418.

↑ *Back to this question in Part A*

@Neet_pg_bot

Q9: A 62 y/o man presents with rapid cognitive decline, visual disturbances, and myoclonus. An EEG shows localized frontal intermittent rhythmical delta activity (FIRDA) that evolves to periodic sharp wave complexes (PSWC) after a few weeks. Based on this presentation and EEG findings, which of the following conditions is most likely associated with his symptoms? (Q851100)

A. Hepatic encephalopathy

B. Creutzfeldt-Jakob disease

C. Renal encephalopathy

D. Alzheimer’s disease

Correct Answer: B. Creutzfeldt-Jakob disease

■ *Listen (English)*

■ *Listen (Hindi)*

Explanation: The progression from localized frontal intermittent rhythmical delta activity (FIRDA) to PSWC is characteristic of Creutzfeldt-Jakob disease (CJD), along with the patient's rapid cognitive decline and myoclonus. Periodic sharp wave complexes (PSWC) The first EEG finding in Creutzfeldt-Jakob disease (CJD) is often localized frontal intermittent rhythmical delta activity (FIRDA). FIRDA evolves to typical periodic sharp wave complexes (PSWC) after a few weeks. PSWC is characterized by generalized synchronized high-voltage sharp waves with frequencies of 1–2 Hz. While PSWC usually appear generalized, they may exhibit lateralized or localized distributions in the early stages of CJD. PSWC is one of the criteria for the clinical diagnosis of CJD. Hence, Creutzfeldt-Jakob disease (CJD) presents with PSWC and myoclonic jerks. {{caption_text}} Periodic sharp wave complexes are seen on the EEG Cerebrospinal fluid (CSF) analysis in CJD shows: 14-3-3 protein (SA 14-3-3): Positive Tau protein: Increased Usually no pleocytosis Hepatic and renal encephalopathy (Options A & C) may cause altered mental status, but not the rapid cognitive decline, myoclonus, and specific EEG findings seen in CJD. Alzheimer’s disease (Option D) typically has a much slower progression and lacks these EEG patterns and associated myoclonus.

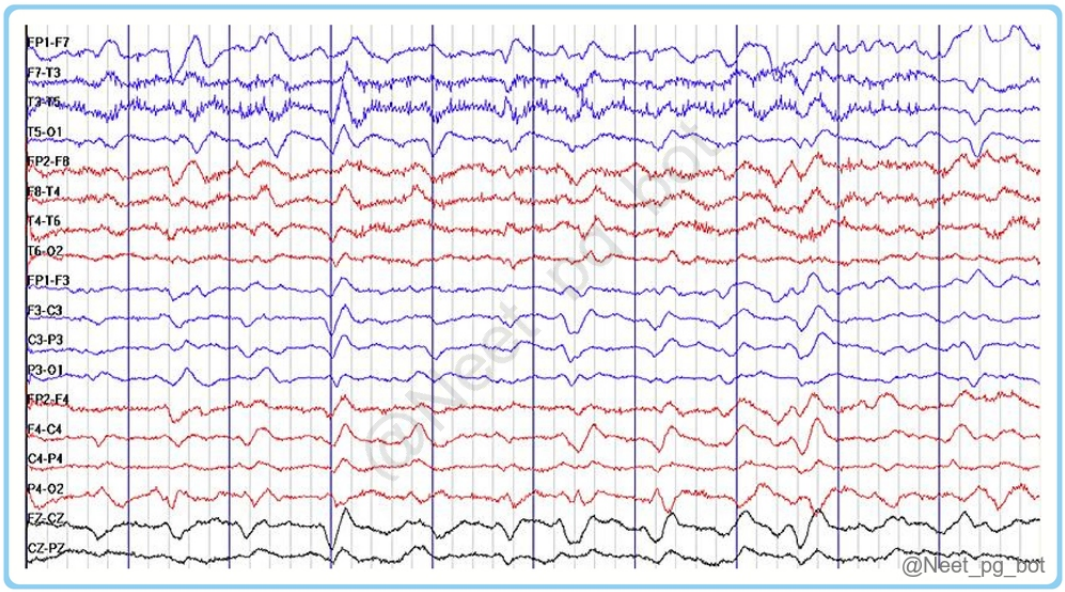

References:

Harrison's Principles of Internal Medicine, 22nd Edition, Pages 3530, 3531

↑ *Back to this question in Part A*

@Neet_pg_bot

Q10: A 2-day-old neonate born at 39 weeks gestation by venthouse is having jitteriness. Which of the following is correct about this presentation? (Q851098)

A. Benign Rolandic epilepsy

B. Subtle seizure

C. Febrile seizures

D. Myoclonic seizures

Correct Answer: B. Subtle seizure

■ *Listen (English)*

■ *Listen (Hindi)*

Explanation: Subtle seizures are the most common seizure type in newborns , often presenting with changes in tone or subtle movements called jitteriness that often go unnoticed. Types of Movements: Ocular Movements: Includes random eye movements, sustained conjugate tonic deviation, eyelid blinking or fluttering, eye-rolling, and nystagmus. Oral-Buccal-Lingual Movements: Such as sucking, smacking, chewing, and tongue protrusions. Progressive Movements: Including rowing, swimming, pedalling, thrashing, or struggling movements. Complex

Purposeless Movements: Characterized by sudden arousal, episodic limb hyperactivity, and crying. Benign rolandic epilepsy (Option A) is the most common type of epilepsy in children. It's also known as benign epilepsy with centrotemporal spikes (BECTS). Febrile seizures (Option C) are the most common type of epilepsy in infants and young children aged 6 months to 5 years, with a peak incidence between 12 and 18 months. Myoclonic seizures (Option D) are less common than subtle seizures. They are rapid, single, or rhythmic repetitive jerks that involve a finger, limb, or the entire body. They are more common in pre-term infants than term infants. I

References:

https://www.ncbi.nlm.nih.gov/books/NBK2599/

↑ *Back to this question in Part A*

@Neet_pg_bot

Q11: A 25 y/o woman with a history of catamenial epilepsy reports an increase in seizure frequency just before her menstrual period. She is currently taking carbamazepine and is newly started on OCPs by her GP for contraception. What is the most appropriate advice for her regarding her current situation? (Q851096)

A. Change to Levetiracetam due to high risk of neural tube defects

B. Switch to Valproate to reduce risk of neural tube defects

C. Consider alternative contraception methods due to carbamazepine's effect on oral contraceptives.

D. Stop all antiseizure medications while trying to conceive.

Correct Answer: C. Consider alternative contraception methods due to carbamazepine's effect on oral contraceptives.

■ *Listen (English)*

■ *Listen (Hindi)*

Explanation: Carbamazepine can significantly reduce the effectiveness of oral contraceptives, so alternative methods (like IUDs) are recommended for women not planning to conceive. Catamenial Epilepsy Increased seizure frequency around menses due to estrogen/progesterone effects or antiseizure drug level changes. Some women may require increased antiseizure drug dosages during menses. Natural progestins or intramuscular medroxyprogesterone may benefit certain women. Pregnancy ~50% of women experience unchanged seizure frequency; ~30% may increase, and ~20% decrease. Monitoring of serum antiseizure drug levels is essential during pregnancy. Lamotrigine and levetiracetam are recommended as first-line monotherapy for generalized and focal onset seizures. The higher teratogenic risk with multiple antiseizure drugs is noted. Valproic acid is strongly associated with adverse fetal outcomes and is thus contraindicated in pregnancy. Folate supplementation (1–4 mg/d) is recommended due to antifolate effects of anticonvulsants. Enzyme-inducing drugs (phenytoin, carbamazepine, oxcarbazepine, topiramate, phenobarbital, primidone) may cause vitamin K deficiency in

newborns. Hence mothers should take oral vitamin K, and infants should receive intramuscular vitamin K at birth. Contraception Certain antiseizure medications (carbamazepine, phenytoin, phenobarbital, topiramate) reduce oral contraceptive efficacy via enzyme induction. Alternative contraception methods (IUDs, long-acting reversible contraceptives) should be considered. Breast-Feeding Antiseizure medications are excreted in breast milk at varying levels (5% for valproic acid to 300% for levetiracetam). Encouraged to breastfeed unless infant shows signs of drug effects (e.g., lethargy, poor feeding).

References:

Harrison's Principles of Internal Medicine, 22nd Edition, Page 3427.

↑ *Back to this question in Part A*

@Neet_pg_bot

Q12: Which of the following antiepileptic drugs can worsen generalized seizures, particularly absence or myoclonic types, and should be avoided in idiopathic generalized epilepsy? (Q851095)

A. Valproate

B. Lamotrigine

C. Carbamazepine

D. Topiramate

Correct Answer: C. Carbamazepine

■ *Listen (English)*

■ *Listen (Hindi)*

Explanation: Carbamazepine is a sodium channel blocker that is effective for focal seizures But in idiopathic generalized epilepsies including absence, myoclonic, and juvenile myoclonic epilepsy, carbamazepine can exacerbate seizures . This occurs because carbamazepine enhances thalamocortical oscillations and interferes with inhibitory circuits, promoting generalized epileptiform discharges. Valproate, lamotrigine, and topiramate are broad-spectrum antiepileptics effective in generalized tonic–clonic, myoclonic, and absence seizures, and do not exacerbate them.

References:

https://pubmed.ncbi.nlm.nih.gov/16895979/ https://pubmed.ncbi.nlm.nih.gov/10722956/

↑ *Back to this question in Part A*

@Neet_pg_bot

Q13: Which statement about Mesial Temporal Lobe Epilepsy Syndrome is false? (Q851092)

A. EEG may show unilateral or bilateral anterior temporal spikes.

B. MRI typically reveals an enlarged hippocampus with trilaminar architecture.

C. It is often refractory to anticonvulsants but may respond well to surgical intervention.

D. Auras, postictal disorientation and memory loss can occur.

Correct Answer: B. MRI typically reveals an enlarged hippocampus with trilaminar architecture.

■ *Listen (English)*

■ *Listen (Hindi)*

Explanation: MRI findings in Mesial Temporal Lobe Epilepsy usually show a smaller hippocampus with a loss of the normal trilaminar architecture, reflecting the structural changes associated with the syndrome. {{caption_text}} Mesial Temporal lobe Epilepsy Syndrome Clinical Observations(Option D ruled out) Auras are commonly experienced. Postictal disorientation. Behavioural arrest or staring episodes. Memory loss can occur. Presence of complex automatisms. Dysphasia may occur if the focus is in the dominant hemisphere. Unilateral posturing is observed. Laboratory Studies EEG may show unilateral or bilateral anterior temporal spikes. (Option A ruled out) Interictal PET scans reveal hypometabolism. Ictal SPECT scans demonstrate hyperperfusion. Intracranial amobarbital (Wada) test may indicate material-specific memory deficits. MRI Findings The hippocampus appears smaller with increased signal on T2-weighted sequences. Loss of the trilaminar architecture of the hippocampus. (Option B) Reduced size of the temporal lobe Enlargement of the temporal horn. {{caption_text}} Treatment Refractory to anticonvulsants. Responds well to Surgical intervention. (Option C ruled out) {{caption_text}} ■■■ {{caption_text}}

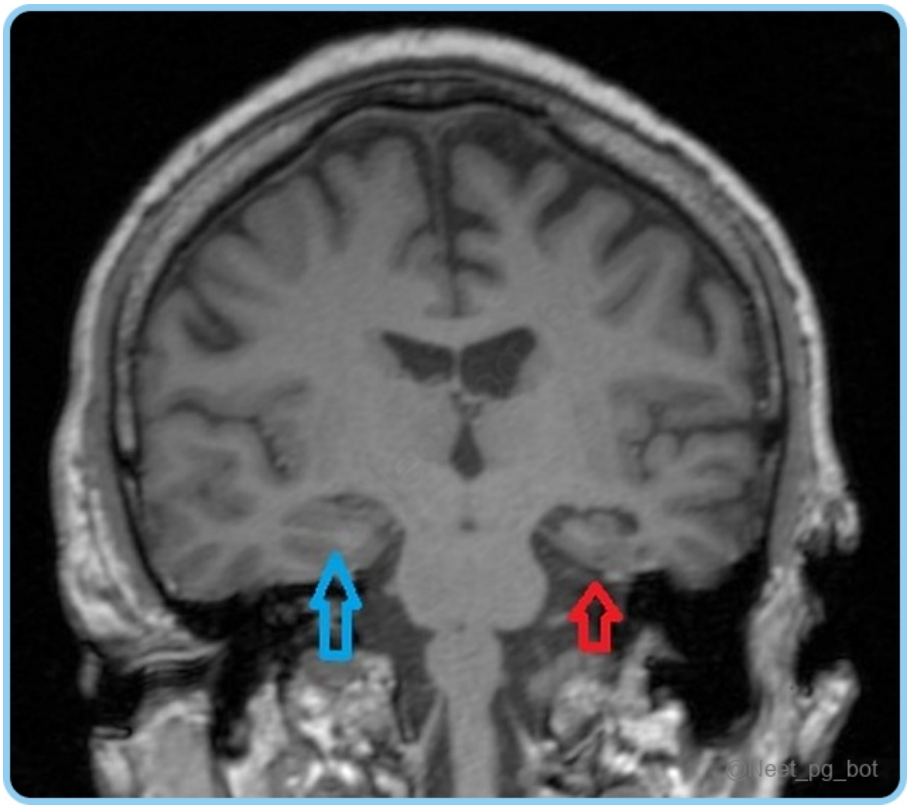
@Neet_pg_bot

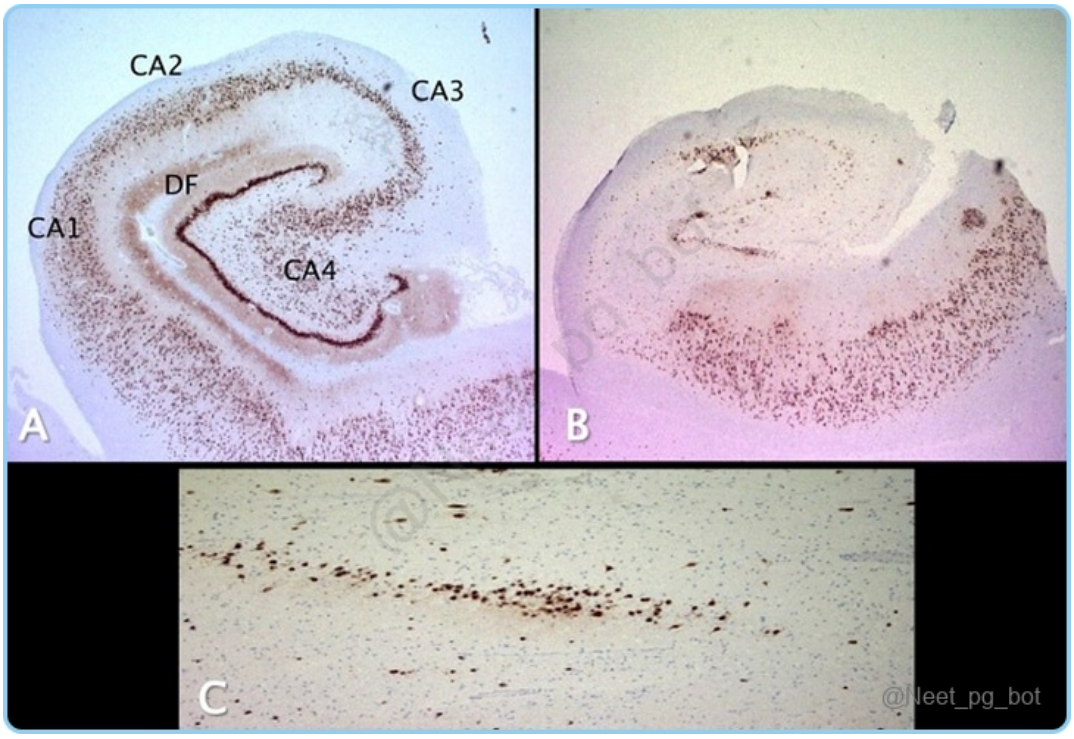
CA2
CA3
DF
CA1
CA4
A
B
C
@Neet_pg_bot

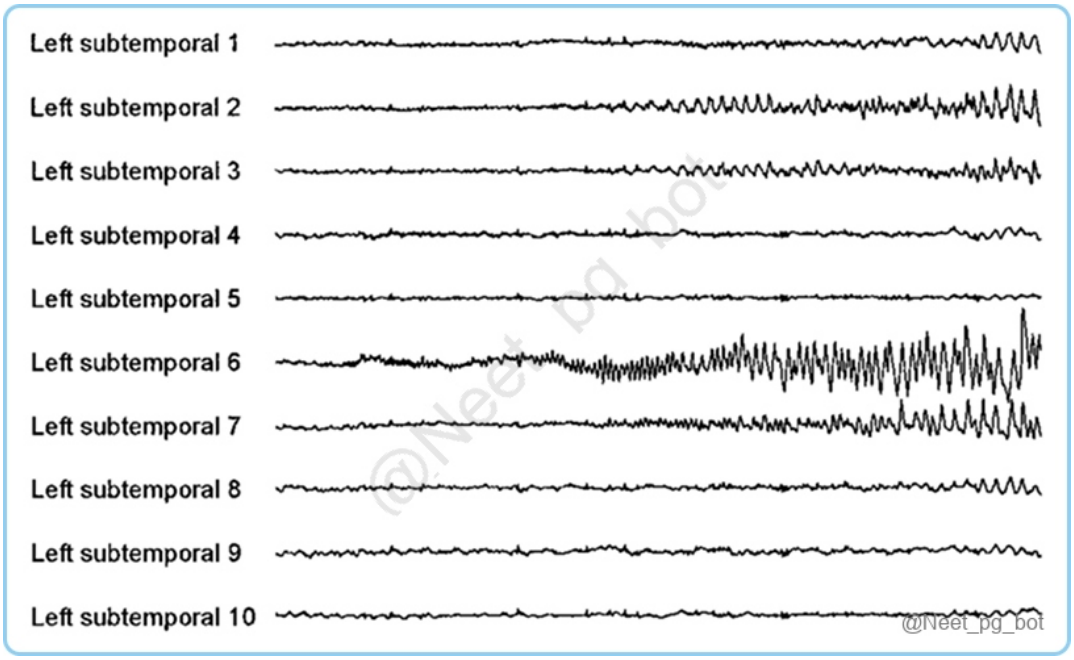

References:

Harrison's Principles of Internal Medicine, 22nd Edition, Page 3411.

↑ *Back to this question in Part A*

@Neet_pg_bot

Q14: A 30 y/o man is brought to the neurology clinic for evaluation after a brief period of unconsciousness. He is awake and alert during the examination. An EEG is performed while his eyes are closed. What is the frequency range recorded in the patient's EEG? (Q851076)

A. 8-13 Hz

B. >13 Hz

C. <4 Hz

D. 4-8 Hz

Correct Answer: A. 8-13 Hz

■ *Listen (English)*

■ *Listen (Hindi)*

Explanation: The patient’s EEG shows alpha waves , as he is awake with his eyes closed. Normal Brain Electrical Activity Wave Situation Frequency Alpha (Option A) Awake with eyes closed 8–13 Hz Beta (Option B ruled out) Most frequently seen. Enhanced in drowsiness and sedative drugs like benzodiazepines. >13 Hz Theta (Option D ruled out) When sleeping. Drifting to sleep. NREM Stage 1 sleep 4–8 Hz Sigma Also called as sleep spindles (associated with K complexes) Deeper sleep NREM Stage 2 sleep 12–14 Hz Delta (Option C ruled out) NREM Stage 3 sleep Deepest sleep <4 Hz {{caption_text}} EEG - Brain waves {{caption_text}}

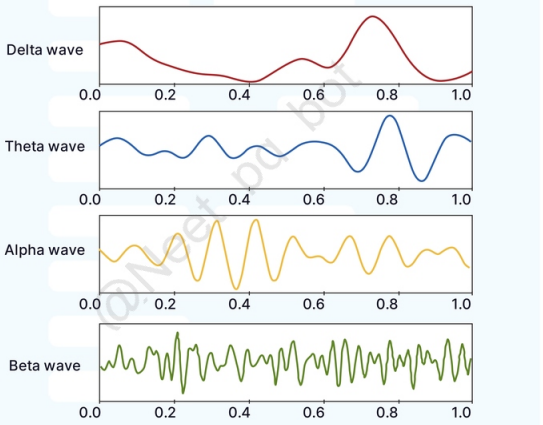

@Neet_pg_bot

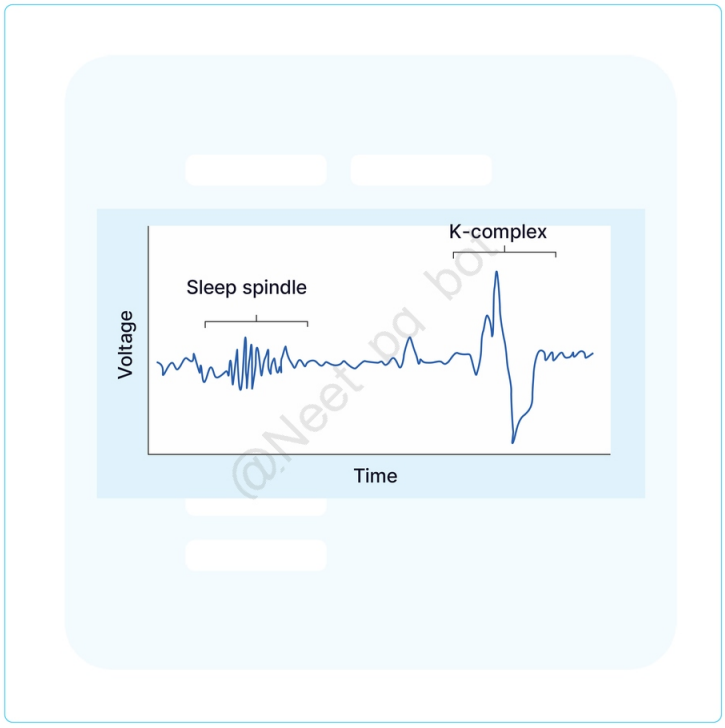

@Neet_pg_bot

References:

Harrison's Principles of Internal Medicine, 22nd Edition, Page 3417

↑ *Back to this question in Part A*

@Neet_pg_bot

Q15: A 7 y/o girl presents to the pediatric neurology clinic with a history of multiple seizure types. Her parents report that she has experienced GTCS, atonic seizures where she suddenly drops to the ground, and atypical absence seizures. The child has also shown signs of cognitive impairment. Which of the following statements is true regarding her condition? (Q851090)

A. Characterized by bilateral myoclonic jerks that are most frequent in the morning.

B. The EEG findings show diffuse, symmetric, bilateral 4 to 6 Hz polyspike and wave discharges.

C. Valproate and Topiramate are used in treatment.

D. The condition typically presents in early adolescence.

Correct Answer: C. Valproate and Topiramate are used in treatment.

■ *Listen (English)*

■ *Listen (Hindi)*

Explanation: The diagnosis is likely Lennox-Gastaut Syndrome, characterized by multiple seizure types, including generalized tonic-clonic, atonic, and atypical absence seizures, along with cognitive impairment in a child. The presence of these varied seizures and cognitive issues supports this diagnosis. Valproate and Topiramate are among the first-line treatment options for Lennox-Gastaut Syndrome. Characteristics Lennox-Gastaut Syndrome Juvenile Myoclonic Epilepsy (JME/ JANZ Syndrome) Onset Occurs in children Early adolescence (Option D ruled out) Myoclonic Seizures Not a primary feature Most frequent in the morning after awakening; can be provoked by sleep deprivation. (Option A ruled out) EEG Findings Shows slow (<3 Hz) spike-and-wave discharges. Shows diffuse, symmetric, bilateral 4 to 6 Hz polyspike and wave discharges, predominantly in the fronto-central region. (Option B ruled out) Ictal EEG recordings reveal 10-16 Hz polyspike discharges that correlate with myoclonic jerks. Treatment Valproate, lamotrigine, and topiramate Valproic acid

References:

https://www.ncbi.nlm.nih.gov/sites/books/NBK532965

↑ *Back to this question in Part A*

@Neet_pg_bot

Q16: A 25 y/o man is brought to the ED after experiencing a generalized tonic-clonic seizure. An EEG is performed after the seizure. Which of the following statements is true regarding the EEG findings associated with his seizure? (Q851089)

A. The interictal EEG shows electrodecremental response

B. During the tonic phase, the EEG typically shows a progressive increase in generalized low-voltage fast activity.

C. The postictal EEG usually reveals localized spikes corresponding to the seizure focus.

D. The EEG during the clonic phase shows low frequency polyspikes with variable amplitude

Correct Answer: B. During the tonic phase, the EEG typically shows a progressive increase in generalized low-voltage fast activity.

■ *Listen (English)*

■ *Listen (Hindi)*

Explanation: In the case of GTCS, EEG during the tonic phase shows a progressive increase in generalized low-voltage fast activity. and clonic phase there is High-amplitude spike-wave bursts. Hack to Rememeber In the clonic phase patient is shaking violenty , so high amplitude and S for S pike wave bursts. Focal Seizure- EEG GTCS- EEG The routine interictal EEG in patients with focal seizures is often normal. (Option A ruled out) It may

show brief discharges, such as epileptiform spikes or sharp waves. Focal seizures can arise from areas like the medial temporal lobe or inferior frontal lobe, which may be distant from the scalp. As a result, the EEG recorded during the seizure may be nonlocalizing. The region of seizure onset can be identified using surgically placed intracranial electrodes. During the tonic phase , the EEG shows a progressive increase in generalized low-voltage fast activity. (Option B) This is followed by generalized high-amplitude polyspike discharges. In the clonic phase , high-amplitude activity is typically interrupted by slow waves, creating a spike-and-slow-wave pattern. (Option D ruled out) Generalized seizures tend to terminate synchronously across widespread brain regions. The postictal EEG displays diffuse suppression of all cerebral activity, followed by slowing that gradually recovers as the patient awakens. (Option C ruled out) {{caption_text}} {{caption_text}}

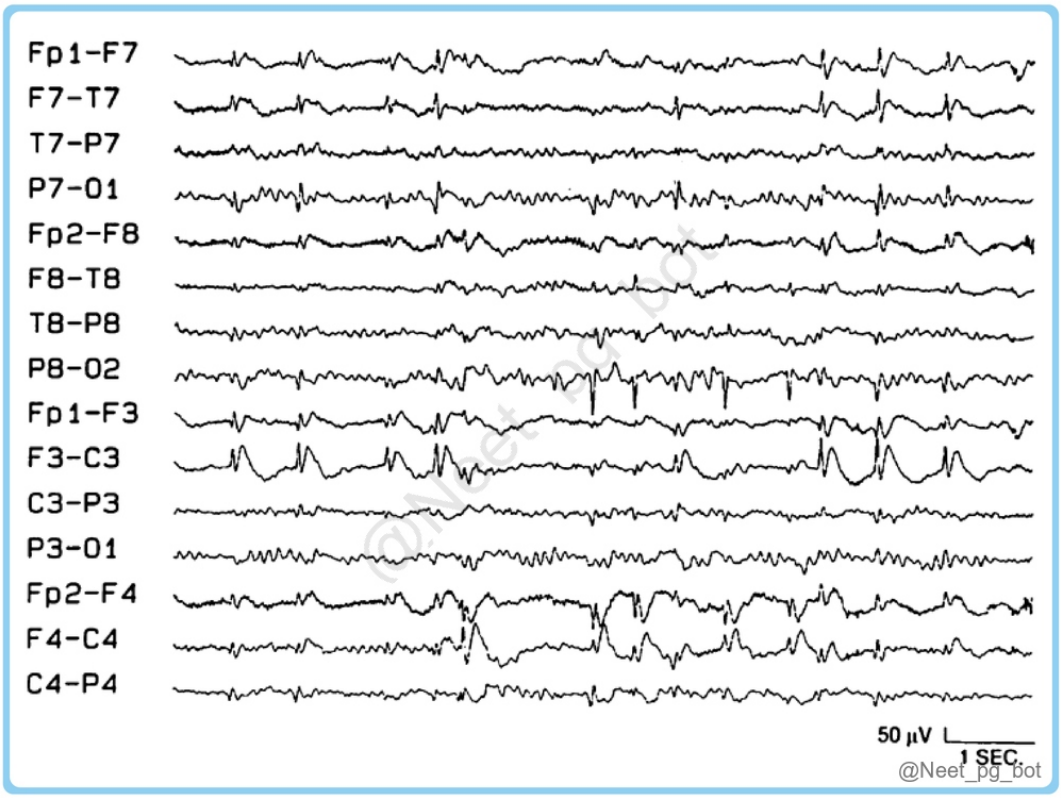



References:

Harrison's Principles of Internal Medicine, 22nd Edition, Page 3410.

↑ *Back to this question in Part A*

@Neet_pg_bot

Q17: A 25-year-old patient with a recently diagnosed PNET experiences recurrent episodes of fainting, often preceded by sweating, tremors and confusion. What is the most likely cause? (Q851088)

A. Orthostatic Hypotension

B. Vasovagal Syncope

C. Metabolic cause

D. Electrolyte imbalance

Correct Answer: C. Metabolic cause

■ *Listen (English)*

■ *Listen (Hindi)*

Explanation: PNET implies pancreatic neuroendocrine tumor. This implies he can be having insulinoma that would be causing hypoglycemia (metabolic cause). Dyselectrolytemia is second close option that can be explained if PNET is a VIPoma. The answer is based on the fact that insulinoma is more common. RBS of this patient along with RIA Fasting insulin and serum electrolytes will help in that exclusion or inclusion.

References:

Harrison's Principles of Internal Medicine, 22nd Edition, Page 3414.

↑ *Back to this question in Part A*

@Neet_pg_bot

Q18: A 6-month-old infant presents with brief episodes of sudden flexion of the trunk and limbs, lasting a few seconds. EEG shows hypsarrhythmia, and during the episodes, there's marked background suppression on the EEG. What is the most likely diagnosis? (Q851087)

A. Absence seizures

B. Atonic seizures

C. Epileptic spasms

D. Lennox-Gastaut syndrome

Correct Answer: C. Epileptic spasms

■ *Listen (English)*

■ *Listen (Hindi)*

Explanation: This is a classic case of epileptic spasms . A 6-month-old infant presenting with brief episodes of sudden flexion of the trunk and limbs , each lasting a few seconds, is highly suggestive of epileptic spasms (infantile spasms/West syndrome) . These events typically occur in clusters , especially after waking. The EEG finding of hypsarrhythmia is characteristic. It shows: Chaotic, disorganized background High-amplitude slow waves Multifocal spikes and sharp waves During the actual spasm, there is often electrodecremental response (background suppression) , which is a key diagnostic feature. Clinically, these spasms involve: Sudden flexion (more common) or extension Predominantly proximal muscles (neck, trunk, limbs) Also called "salaam attacks" Absence seizures (Option A) occur in older children (4–14 years) with staring spells and 3 Hz spike-and-wave EEG , without motor flexion spasms. Atonic seizures (Option B) cause sudden loss of muscle tone (drop attacks) , not flexor spasms. EEG typically shows slow spike-wave (<3 Hz). Lennox-Gastaut syndrome (Option D) presents later (1–8 years) with multiple seizure types and slow spike-wave EEG (<3 Hz) , not hypsarrhythmia.

References:

Harrison’s Principles of Internal Medicine, 22nd Edition, Page 3410

↑ *Back to this question in Part A*

@Neet_pg_bot

Q19: A 23 year patient presents with sudden, brief muscle jerks on loud auditory stimuli and dementia. T2/FLAIR MRI shows hyperintensity in the pulvinar nucleus of the thalamus. What is the first differential diagnosis? (Q851086)

A. Epileptic spasms

B. Juvenile Myoclonic Epilepsy

C. Variant Creutzfeldt-Jakob Disease (vCJD)

D. Anoxic brain injury

Correct Answer: C. Variant Creutzfeldt-Jakob Disease (vCJD)

■ *Listen (English)*

■ *Listen (Hindi)*

Explanation: The diagnosis is most likely to be variant creutzfeldt-jakob disease, due to the combination of dementia and myoclonic jerks (startle myoclonus). Hyperintensity in the pulvinar nucleus of the thalamus on T2/FLAIR MRI is considered highly specific for vCJD. It is also called the " hockey stick sign " when it extends to the dorsomedial thalamus. Epileptic spasms (Option A) typically occur in infants and present with different EEG findings (hypsarrhythmia) rather than spike-and-slow-wave discharges. Juvenile Myoclonic Epilepsy (Option B) : Although JME can cause myoclonic seizures and spike-and-slow-wave discharges, the history of beef consumption strongly suggests prion disease. Anoxic brain injury (Option D) : There's no evidence of hypoxia or brain injury, and the patient’s symptoms are better explained by prion-related vCJD.

References:

Harrison’s Principles of Internal Medicine, 22nd Edition, Page 3530

↑ *Back to this question in Part A*

@Neet_pg_bot

Q20: A 7 year child is brought to the clinic due to frequent episodes of "daydreaming" during school, which last for a few seconds and are accompanied by subtle eyelid blinking. Which of the following is correct about this condition? (Q851084)

A. Episodes can be stopped by hyperventilation

B. Episodes are triggered by photic stimulation

C. < 2.5 Hz spike and slow wave pattern

D. Occur due to defect of sodium channel closure in thalamocortical circuit

Correct Answer: B. Episodes are triggered by photic stimulation

■ *Listen (English)*

■ *Listen (Hindi)*

Explanation: This is a case of Absence seizures. They occur due to T-type calcium channel dysfunction in the thalamus , which causes rhythmic 3 Hz spike-and-wave discharges on EEG. They are often triggered by hyperventilation, stress, or flashing lights in mainly children aged 4–14 years.

References:

Harrison’s Principles of Internal Medicine, 22nd Edition, Pages 3410, 3414

↑ *Back to this question in Part A*

@Neet_pg_bot

Q21: A 35 y/o woman experiences sudden unresponsiveness during conversations, followed by repetitive hand movements and lip-smacking. Afterwards, she seems confused and does not remember the event. Which of the following is the most likely diagnosis? (Q851083)

A. Absence Seizure

B. Panic Attack

C. Focal Seizure with Impaired Awareness

D. Focal Seizure with Intact Awareness

Correct Answer: C. Focal Seizure with Impaired Awareness

■ *Listen (English)*

■ *Listen (Hindi)*

Explanation: The patient's unresponsiveness, automatisms, and post-seizure confusion are characteristics of focal seizure with impaired awareness. {{caption_text}} Image showing abnormal high voltage in right temporal leads. Since the abnormal electrical activity is seen only in some leads, it is a focal seizure. Absence Seizure (Option A): Typically involves brief episodes of staring without postictal confusion or automatisms, which is more common in

children. Panic Attack (Option B): Presents with intense fear and physical symptoms, but does not include automatisms or loss of awareness. Focal Seizure with Intact Awareness (Option D): Involves preserved awareness throughout the event, which is not seen in this case.

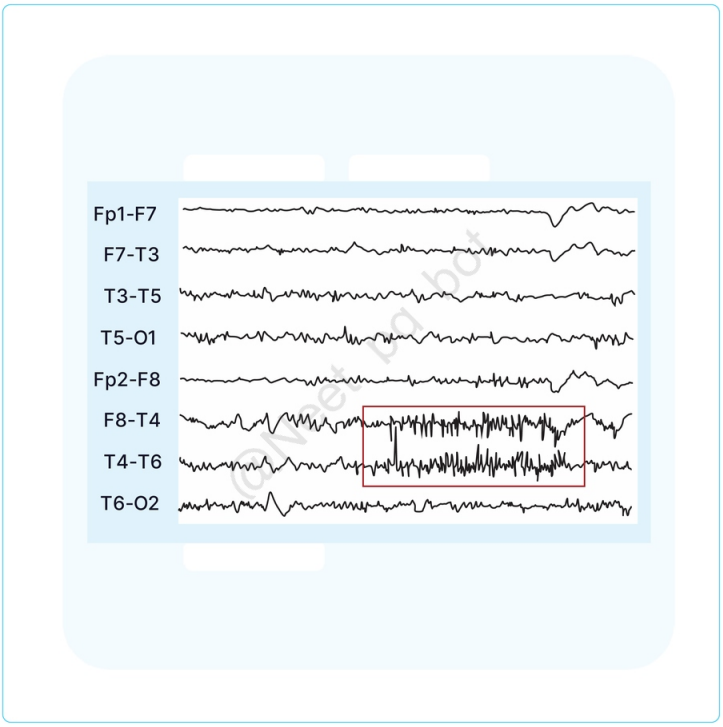

References:

Harrison's Principles of Internal Medicine, 22nd Edition, Page 3409.

↑ *Back to this question in Part A*

@Neet_pg_bot

Q22: A 32 y/o woman experiences involuntary movements that begin in her right hand and progressively spread to her right arm and face. She remains fully aware throughout the episode. What is the most likely diagnosis? (Q851080)

A. Absence seizure

B. Todd's paralysis

C. Epilepsia partialis continua

D. Jacksonian march

Correct Answer: D. Jacksonian march

■ *Listen (English)*

■ *Listen (Hindi)*

Explanation: The patient has focal seizure activity without loss of awareness , consistent with a Jacksonian March . This refers to a focal motor seizure in which abnormal clonic movements begin in one area (e.g., hand) and gradually spread to adjacent regions (e.g., arm and face). The seizure progresses in a “ marching ” pattern, following the motor cortex's representation of the body. {{caption_text}} Absence seizure (Option A): This seizure typically involves a brief loss of awareness, where the person appears to “zone out” and is unresponsive. It is predominantly seen in children. Motor symptoms are usually absent , and the person does not experience the spreading involuntary movements seen in this patient. Todd’s paralysis (Option B): Todd’s paralysis is a temporary weakness (paresis) affecting the same area involved in a seizure. It usually occurs after the seizure has ended (postictally), which is not the case in this patient. It is also a feature of focal motor seizures with intact awareness. Epilepsia partialis continua (Option C): This refers to prolonged, continuous focal motor seizures, often restricted to one part of the body, lasting hours or even days . While awareness is usually intact, the condition is characterised by ongoing motor activity rather than the brief spreading movements described here.



@Neet_pg_bot

References:

Harrison’s Principles of Internal Medicine, 22nd Edition, Page 3409.

↑ *Back to this question in Part A*

@Neet_pg_bot

Q23: A 20-year-old student experiences episodes of sudden drop attacks with brief loss of consciousness and confusion after the episode. What is the likely diagnosis? (Q851079)

A. Orthostatic hypotension

B. Atonic seizures

C. GTCS

D. Myoclonic seizure

Correct Answer: B. Atonic seizures

■ *Listen (English)*

■ *Listen (Hindi)*

Explanation: Post-ictal confusion further supports a seizure origin rather than a cardiovascular syncope. Orthostatic hypotension (Option A) usually occurs upon standing, is gradual in onset, and typically does not cause post-event confusion . In contrast, atonic seizures present with sudden loss of muscle tone , leading to abrupt falls (drop attacks) and brief loss of consciousness . It is not GTCS (Option C) , as there is no tonic-clonic movement or prolonged post-ictal phase—only a sudden loss of tone. It is not myoclonic seizure (Option D) , because those involve brief jerks without loss of consciousness or post-ictal confusion.

References:

Harrison’s Principles of Internal Medicine, 22nd Edition, Page 3410.

↑ *Back to this question in Part A*

@Neet_pg_bot

Q24: A 15-year-old boy is brought to the OPD with complaints of repeated episodes of blank staring, and lip-smacking movements lasting around 1–2 minutes. He is confused afterward and has no memory of the episode. Diagnosis is? (Q851078)

A. Focal seizure

B. Absence seizures

C. Pseudo seizures

D. Generalised tonic-clonic seizure

Correct Answer: A. Focal seizure

■ *Listen (English)*

■ *Listen (Hindi)*

Explanation: This is a focal seizure with impaired awareness, as indicated by the automatisms (lip-smacking), duration of 1–2 minutes, and post-ictal confusion with amnesia. In contrast, absence seizures are brief (typically <20 seconds), occur mostly in young children, and lack post-ictal confusion or automatisms. (Option B) The presence of prolonged altered awareness and automatisms strongly points to temporal lobe epilepsy.

References:

Harrison’s Principles of Internal Medicine, 22nd Edition, Page 3409.

↑ *Back to this question in Part A*

@Neet_pg_bot

Q25: A 19-year-old medical student collapses in the anatomy dissection hall. His friends report a brief period of limb jerking lasting about 10–15 seconds during the episode. He regained consciousness in a minute, he appeared pale around the lips with sweating on forehead. Diagnosis is? (Q851077)

A. Vasovagal syncope

B. GTCS

C. Pseudoseizures

D. Focal seizures with secondary generalization

Correct Answer: A. Vasovagal syncope

■ *Listen (English)*

■ *Listen (Hindi)*

Explanation: Vasovagal syncope can sometimes include brief convulsive movements, especially if there's cerebral hypoperfusion. The event could have been triggered by prolonged standing. GTCS (Option B) presents with post-ictal confusion , delayed recovery, incontinence, and often tongue biting Features against GTCS: Autonomic features like sweating No tongue biting or incontinence Perioral pallor (GTCS epidose has perioral pallor) Quick recovery within 1 minute

References:

Harrison’s Principles of Internal Medicine, 22nd Edition, Page 3418.

↑ *Back to this question in Part A*

• [07_Neurology] 049 Basics Of Cranial Nerves Mechanical Thrombectomy Stroke

« Back to Folder Directory

[07_Neurology] 049 Basics Of Cranial Nerves Mechanical Thrombectomy Stroke — Quick Jump

Q1 (p. 2220)	*Q2 (p. 2221)*	*Q3 (p. 2221)*	*Q4 (p. 2223)*	*Q5 (p. 2224)*	*Q6 (p. 2225)*
Q7 (p. 2226)	*Q8 (p. 2226)*	*Q9 (p. 2227)*	*Q10 (p. 2228)*	*Q11 (p. 2229)*	*Q12 (p. 2230)*
Q13 (p. 2231)	*Q14 (p. 2232)*	*Q15 (p. 2233)*	*Q16 (p. 2234)*	*Q17 (p. 2235)*	*Q18 (p. 2236)*
Q19 (p. 2236)	*Q20 (p. 2237)*	*Q21 (p. 2238)*	*Q22 (p. 2239)*	*Q23 (p. 2240)*	*Q24 (p. 2241)*
Q25 (p. 2242)	*Q26 (p. 2242)*	*Q27 (p. 2243)*	*Q28 (p. 2247)*		

Q1: A 50-year-old woman with T2DM is brought in by her family due to strange behaviour. Her daughter says that she noticed that her mother at her wedding was applying makeup only to the left side of her face and eating food from only the left half of her plate. When asked to copy simple shapes such as a triangle, square, and circle her drawings are incomplete and poorly organized. Which of the following brain regions is most likely affected? (Q851256)

A. Left parietal lobe

B. Right parietal lobe

C. Left temporal lobe

D. Right temporal lobe

Correct Answer: B. Right parietal lobe

■ *Listen to Audio 1*

Explanation: The patient is showing left-sided hemineglect —ignoring the left half of her face and plate—as well as constructional apraxia (inability to copy simple shapes). These features are classic for a lesion in the right (non-dominant) parietal lobe , which is responsible for spatial attention and visuospatial integration. Left parietal lobe (Option A): The dominant (usually left) parietal lobe is responsible for language functions such as reading, writing, naming, and calculation. Damage here causes Gerstmann syndrome (agraphia, acalculia, finger agnosia, left–right disorientation), not hemispatial neglect. Left temporal lobe (Option C): Dominant temporal lobe lesions typically cause Wernicke's aphasia (fluent but nonsensical speech, poor comprehension). Right temporal lobe (Option D): The temporal lobe is mainly involved in memory, emotion, and auditory processing .

References:

Harrison’s Principles of Internal Medicine, 22nd Edition, Page 204.

↑ *Back to this question in Part A*

@Neet_pg_bot

Q2: A 60 -year-old retired banker and right-handed man is brought with complaints of speech difficulties. He speaks fluently and with normal grammar, and appears to understand both verbal and written commands. However, when asked to repeat phrases, he is unable to do so. His naming and reading comprehension are intact. Which of the following regions is most likely affected? (Q851269)

A. Broca’s area

B. Wernicke’s area

C. Arcuate fasciculus

D. Angular gyrus

Correct Answer: C. Arcuate fasciculus

■ *Listen (English)*

■ *Listen (Hindi)*

Explanation: The patient’s features are classic for conduction aphasia , which occurs due to damage to the arcuate fasciculus —the fiber tract connecting Broca’s and Wernicke’s areas. Fluent speech → Broca’s area intact Intact comprehension → Wernicke’s area intact Impaired repetition → hallmark of arcuate fasciculus lesion Naming and reading preserved Broca’s area (Option A): Non-fluent, effortful speech → NOT seen here Wernicke’s area (Option B): Fluent but nonsensical speech with poor comprehension → NOT seen here Angular gyrus(Option D): Causes Gerstmann syndrome Agraphia Acalculia Finger agnosia Left–right disorientation

References:

Harrison’s Principles of Internal Medicine, 22nd Edition, Page 202.

↑ *Back to this question in Part A*

@Neet_pg_bot

Q3: Which of the following is not a feature of Weber syndrome? (Q851268)

A. Contralateral lower face weakness

B. Eye down and out (ipsilateral)

C. Vertical gaze palsy

D. Hemiplegia (contralateral)

Correct Answer: C. Vertical gaze palsy

■ *Listen (English)*

■ *Listen (Hindi)*

Explanation: Weber syndrome is a midbrain ventral (basilar) lesion involving the oculomotor nerve fascicles and corticospinal/corticobulbar tracts. This produces ipsilateral CN III palsy (eye down and out) and contralateral hemiplegia + contralateral lower face weakness . Vertical gaze palsy is not a feature; it occurs in dorsal midbrain (Parinaud) syndrome , not Weber. It presents with: Ipsilateral CN III palsy (ptosis, mydriasis, "down and out" eye) Contralateral hemiplegia due to pyramidal tract involvement Contralateral lower facial weakness may occur due to corticobulbar tract involvement

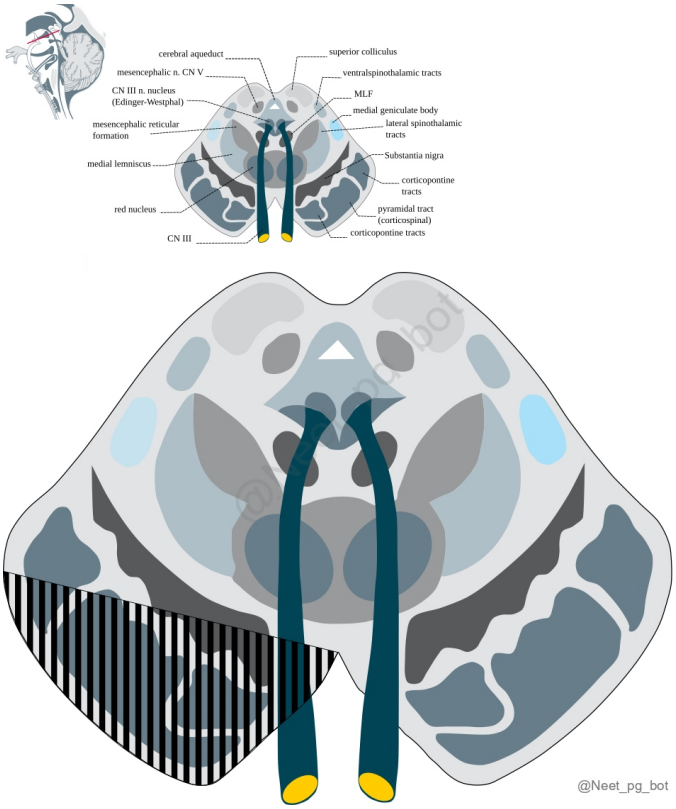

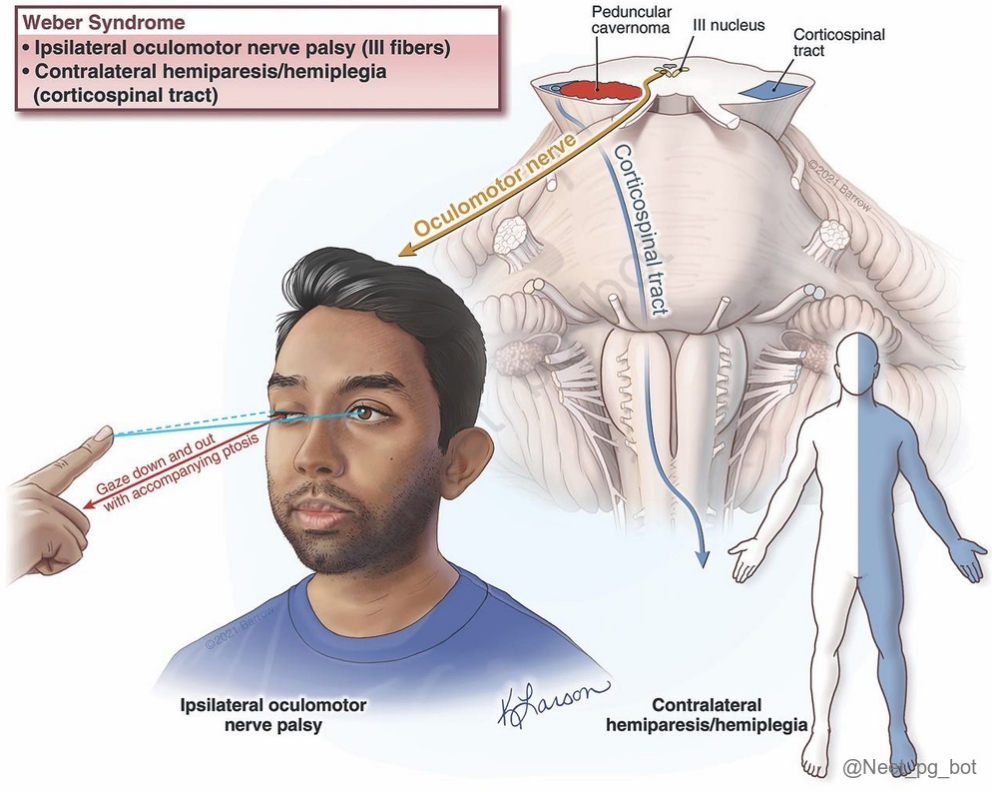

References:

Harrison's Principles of Internal Medicine, 22nd Edition, Page 234, 3431

↑ *Back to this question in Part A*

@Neet_pg_bot

Q4: A 65-year-old woman presents to ER with history of suddenly falling down with difficulty in swallowing. On examination patient can stick out her tongue without any deviation, and gag reflex is diminished. Ipsilateral nystagmus is noted with ataxia of limbs, ipsilateral face numbness with a contralateral pain and temperature loss. Diagnosis is? (Q851267)

A. Brown sequard syndrome

B. Wallenberg Syndrome

C. Locked in syndrome

D. Medial Medullary Syndrome

Correct Answer: B. Wallenberg Syndrome

■ *Listen (English)*

■ *Listen (Hindi)*

Explanation: This pattern of crossed sensory deficits (ipsilateral face + contralateral body), ataxia, and bulbar symptoms (dysphagia) is hallmark for lateral medullary infarction called Wallenberg syndrome. Key features supporting the diagnosis: Ipsilateral signs Facial numbness (trigeminal spinal nucleus/tract involvement) Limb ataxia & nystagmus (inferior cerebellar peduncle/vestibular nuclei) Dysphagia, hoarseness, diminished gag reflex (nucleus ambiguus → CN IX, X) Contralateral signs: Loss of pain and temperature sensation on the body (spinothalamic tract involvement) Brown-Séquard syndrome (Option A) causes ipsilateral motor loss + proprioception loss with contralateral pain/temp loss below lesion, but no cranial nerve involvement . Locked-in syndrome (Option C) occurs due to ventral pons lesion, causing quadriplegia and loss of speech with preserved consciousness and vertical eye movements. Medial medullary syndrome (Option D) causes contralateral hemiparesis + proprioception loss with ipsilateral tongue paralysis,

References:

Harrison's Principles of Internal Medicine, 22nd Edition, Page 3433.
https://www.ncbi.nlm.nih.gov/books/NBK470174/

↑ *Back to this question in Part A*

@Neet_pg_bot

Q5: A 70-year-old diabetic man presents with sudden right-sided weakness. On examination, there is loss of proprioception and vibration on the right side of the body, and his tongue deviates to the left on protrusion. Facial sensation is intact. What is the most likely diagnosis? (Q851266)

A. Lateral medullary syndrome

B. Medial medullary syndrome

C. Central pontine myelinosis

D. Anterior cerebral artery stroke

Correct Answer: B. Medial medullary syndrome

■ *Listen (English)*

■ *Listen (Hindi)*

Explanation: This syndrome is caused by infarction of the anterior spinal artery affecting the medial medulla. It presents with contralateral hemiparesis, contralateral loss of proprioception and vibration (medial lemniscus), and ipsilateral tongue deviation (hypoglossal nerve). Facial sensation remains intact because the trigeminal nucleus lies more laterally. Lateral Medullary Syndrome (Option A) involves the posterior inferior cerebellar artery and

presents with dysphagia, hoarseness, ipsilateral facial sensory loss, and contralateral body pain/temp loss. Central Pontine Myelinolysis (Option C) typically occurs in rapid correction of hyponatremia, leading to quadriplegia and pseudobulbar palsy. Anterior Cerebral Artery Stroke (Option D) causes leg-predominant weakness and abulia.

References:

Harrison's Principles of Internal Medicine, 22nd Edition, Page 3433
https://www.ncbi.nlm.nih.gov/books/NBK560590/

↑ *Back to this question in Part A*

@Neet_pg_bot

Q6: A 38-year-old Formula 1 driver suffers a high-speed crash. At the hospital, he is unable to move his limbs, talk, or drink from a straw. Examination reveals quadriplegia with bilateral long tract signs, with absent gag reflex, but a nurse notices that he can move his eyes vertically on command. What is the most likely diagnosis? (Q851265)

A. Brain stem death

B. Locked in syndrome

C. Vegetative state

D. Decerebrate posturing

Correct Answer: B. Locked in syndrome

■ *Listen (English)*

■ *Listen (Hindi)*

Explanation: Due to high speed crash patient has developed damage to bilateral pons causing locked-in syndrome. It is characterized by quadriplegia and anarthria with preserved consciousness, and patients communicate using vertical eye movements or blinking. Patients are fully conscious but "locked in" - they can hear conversations (including discussions about their prognosis) but cannot respond except via blinking or vertical eye movement , often using eye-tracking or blink-coded communication systems. Brainstem death (Option A) presents with loss of all brainstem reflexes including pupillary, corneal, and oculocephalic reflexes, and there is no spontaneous breathing or eye movement, making vertical eye movements impossible. Vegetative state (Option C) involves preserved sleep-wake cycles and autonomic functions, but no awareness of self or environment, and patients do not follow commands with eye movements. Decerebrate posturing (Option D) occurs due to midbrain or upper pontine damage, leading to extension of arms and legs, often seen in comatose patients - not associated with preserved consciousness or vertical eye movement.

References:

Harrison’s Principles of Internal Medicine, 22nd Edition, Page 3434.

https://www.ncbi.nlm.nih.gov/books/NBK559026/

↑ *Back to this question in Part A*

@Neet_pg_bot

Q7: A 62-year-old patient presents with left-sided arm and leg weakness, right-sided facial paralysis with lateral rectus gaze palsy and nystagmus. Which of the following syndromes is consistent with these symptoms? (Q851264)

A. Foville Syndrome

B. Benedikt syndrome

C. Millard Gubler

D. Wallenberg syndrome

Correct Answer: A. Foville Syndrome

■ *Listen (English)*

■ *Listen (Hindi)*

Explanation: Patient has crossed features implying brain stem stroke. Left sided weakness with right sided 6 th and 7 th nerve palsy Foville’s syndrome is involvement of nucleus of 6 th nerve . It communicates with opposite side 3 rd nerve via medial longitudinal fasciculus. Damage to 6 th nerve nucleus means that gaze palsy will occur with lateral rectus of involved and medial rectus of non-involved side being involved. Benedikt syndrome (Option B) has 3 rd nerve palsy. Millard Gubler (Option C) will have only lateral rectus weakness as only the nerve fascicle is involved. Wallenberg syndrome (Option D) has 5,8,9,10,11 cranial nerve palsy.

References:

Harrison’s Principles of Internal Medicine, 22nd Edition, Page 235.
https://www.ncbi.nlm.nih.gov/books/NBK544268/

↑ *Back to this question in Part A*

@Neet_pg_bot

Q8: A 60-year-old male presents to neurology follow-up OPD four weeks after a stroke with persistent allodynia, especially while taking a bath with warm water. Which of the following is correct about this case? (Q851263)

A. Complex regional pain syndrome type I

B. Thalamic infarct

C. Internal capsule infarct

D. Complex regional pain syndrome type II

Correct Answer: B. Thalamic infarct

■ *Listen (English)*

■ *Listen (Hindi)*

Explanation: This case is presenting with the classic triad of features that define Dejerine Roussy syndrome: Timing: Pain develops after stroke (in this case, few weeks post-stroke) Location: Lesion in ventroposterolateral thalamus confirmed by MRI Pain characteristics like Constant burning pain or hyperalgesia and allodynia especially to warm water which may be percieved as boiling water or acid. Complex regional pain syndrome (Option A and D) is seen due to peripheral neuropathy. Internal capsule infarct (Option C) will cause motor deficit like pure motor stroke or pure sensory stroke.

References:

Harrison’s Principles of Internal Medicine, 22nd Edition, Page 176, 3432.

↑ *Back to this question in Part A*

@Neet_pg_bot

Q9: A 25-year-old woman presents with double vision. On examination, she has paralysis of vertical gaze and pupils that constrict during accommodation but not in response to light (light-near dissociation). CT head shows mass arising in pineal region. Diagnosis is? (Q851262)

A. M.Gravis

B. Neurosyphilis

C. Internuclear opthalmoplegia

D. Perinaud syndrome

Correct Answer: D. Perinaud syndrome

■ *Listen (English)*

■ *Listen (Hindi)*

Explanation: The patient has Parinaud syndrome /dorsal midbrain syndrome which is typically caused by a pineal gland tumor as seen on neuroimaging in this case. It affects the vertical gaze center / rostral interstitial nucleus of the medial longitudinal fasciculus. The classic triad includes Paralysis of upward gaze C onvergence-retraction nystagmus (jerky eye movements on attempted up gaze) Pupillary light-near dissociation (pupils poorly reactive to light but responsive to near stimuli) This results from compression of structures like the superior colliculi and pretectal area , which are involved in vertical gaze and pupillary light reflexes. The chin-up posture is a compensatory mechanism for the vertical gaze palsy M. Gravis (Option A) will present with diurnal variation in muscle weakness. Neurosyphilis (Option B) will have Argyl robertson pupul with light near disssociation as described in this patient but is ruled out due to CT head showing pineal mass. INO (Option C) will present with impaired adduction of the ipsilateral eye on lateral gaze and abducting eye nystagmus on the contralateral side

References:

Harrison’s Principles of Internal Medicine, 22nd Edition, Page 236.

↑ *Back to this question in Part A*

@Neet_pg_bot

Q10: A 60-year-old man presents with a sudden onset drooping of left eye and balance issues. On examination, he has left-sided ptosis, dilated left pupil, and the left eye is "down and out." He demonstrates significant right-sided ataxia. He is unable to move his eyes vertically . Diagnosis is? (Q851261)

A. Weber syndrome

B. Nonthangel syndrome

C. Benedikt syndrome

D. Millard gubler syndrome

Correct Answer: B. Nonthangel syndrome

■ *Listen (English)*

■ *Listen (Hindi)*

Explanation: The patient has crossed features implying brain stem involvement. He has ipsilateral 3 rd nerve palsy with contralateral ataxia implying lesion in the midbrain tegmentum affecting superior cerebellar peduncle , leading to contralateral ataxia . Weber syndrome (Option A): It involves the cerebral peduncle and oculomotor nerve, causing ipsilateral third nerve palsy with contralateral hemiparesis (not ataxia) Benedikt syndrome (Option C) : It has red nucleus involvement causing basal ganglia features like chorea and tremors with 3rd nerve palsy Millard Gubler syndrome (Option D) : It has ispsilateral 6,7 th nerve palsy with contralateral hemiplegia

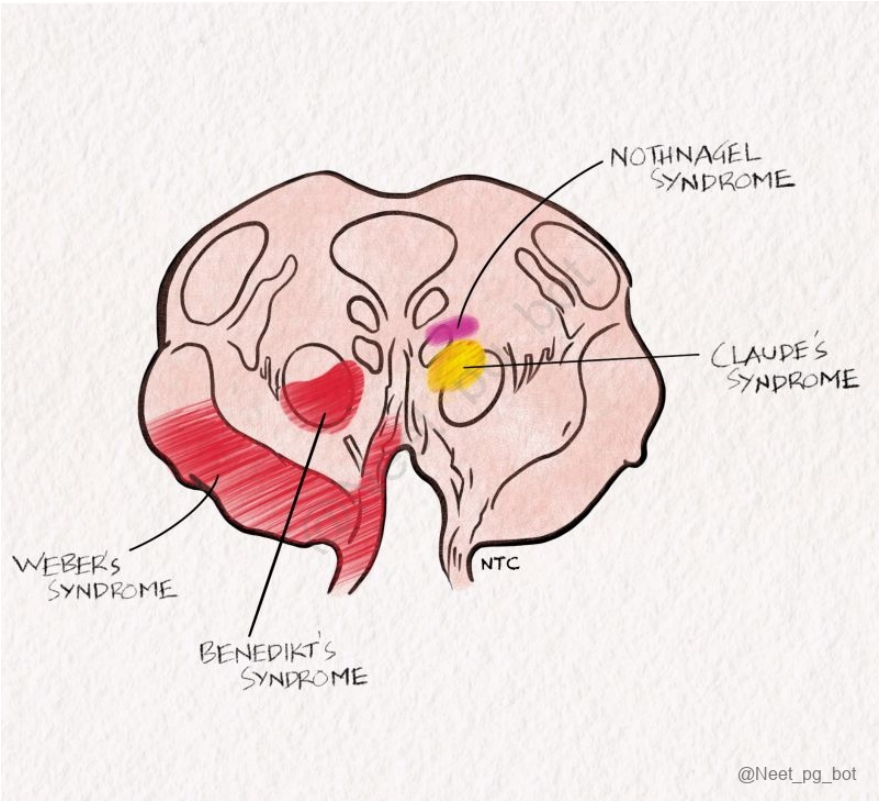

References:

Harrison's Principles of Internal Medicine, 22nd Edition, Page 234.

https://pmc.ncbi.nlm.nih.gov/articles/PMC11668228/

↑ *Back to this question in Part A*

@Neet_pg_bot

Q11: A 35-year-old alcoholic patient presents with palpitations for the last 2 hours. On examination, he has an irregularly irregular pulse, BP 130/100 mm Hg, and a GCS of 15/15. Higher mental functions and cranial nerve examination are normal. There is no focal neurological deficit. What is the most appropriate next step in management? (Q851260)

A. Thrombolysis as patient is in window period

B. Control ventricular rate

C. Start anticoagulation with warfarin

D. Start anticoagulation with novel oral anticoagulants

Correct Answer: B. Control ventricular rate

■ *Listen (English)*

■ *Listen (Hindi)*

Explanation: The patient is having atrial fibrillation and has presented with cardiovascular symptoms. So using RACE algorithm: First, Rate control and then oral anticoagulation will be started. C is for C hemical cardioversion, and E is for E lectrical cardioversion if the patient develops hemodynamic instability.

References:

Harrison's Principles of Internal Medicine, 22nd Edition, Page 1949, 3677.

↑ *Back to this question in Part A*

@Neet_pg_bot

Q12: A patient presents with sudden onset aphasia and right sided arm weakness for the past 4 hours. On examination he has irregularly irregular pulse. Which of the following investigations will be done to determine etiology of this case presentation? (Q851259)

A. Transthoracic echocardiography

B. Carotid doppler

C. Transesophageal echaocardiography

D. MRI Brain

Correct Answer: C. Transesophageal echaocardiography

■ *Listen (English)*

■ *Listen (Hindi)*

Explanation: An irregularly irregular pulse is a classic clinical sign of atrial fibrillation . In AF, chaotic atrial contractions lead to blood stasis, particularly in the left atrial appendage , which predisposes to clot formation. These clots can embolize and cause ischemic strokes, often affecting the left middle cerebral artery territory. This results in symptoms such as aphasia (due to dominant hemisphere involvement) and right-sided weakness (including the right arm), as the left MCA supplies the corresponding brain regions. Transesophageal echocardiography (TEE) is the preferred imaging modality to evaluate the left atrial appendage for thrombus presence. Detecting clots with TEE is critical to determine the indication for oral anticoagulation to prevent stroke recurrence. This assessment guides timely anticoagulant therapy, which is essential in managing patients with AF and stroke risk. Transthoracic Echocardiography (TTE): TTE is usually the first-line screening tool for heart structure because it is non-invasive. However, it has very low sensitivity for detecting clots in the Left Atrial Appendage. In a patient with a high suspicion of a cardioembolic source (like this one), a "negative" TTE is not

enough to rule out a clot. Carotid Doppler (Option B): This is used to look for Carotid Artery Stenosis , which causes "artery-to-artery" embolic strokes. While this is a common cause of stroke in older patients, the "irregularly irregular pulse" in this patient points directly to a cardiac source rather than a carotid one. Carotid Doppler would not explain the pulse finding. MRI Brain (Option D): MRI (specifically Diffusion-Weighted Imaging) is the most sensitive test to confirm the diagnosis of an acute ischemic stroke and visualize the extent of brain tissue damage. However, MRI tells us where the stroke is, not why it happened. The question asks for the investigation to determine the etiology , which is the cardiac embolus.

References:

Harrison's Principles of Internal Medicine, 22nd Edition, Page 3444.

↑ *Back to this question in Part A*

@Neet_pg_bot

Q13: A 54-year-old male presents with a sudden onset of double vision and left-sided weakness. On examination he has a right-sided ptosis, a dilated pupil that does not react to light, and an outward deviation of the right eye. The left side of his body shows spastic weakness with hyperreflexia. MRI reveals an ischemic lesion in the midbrain. Which of the following structures is most likely involved in this patient's condition? (Q851258)

A. Occulomotor motor and red nucleus

B. Oculomotor nerve and crus cerebri

C. Occulomotor nerve and superior cerebellar penduncle

D. Occulomotor nerve and substania nigra

Correct Answer: B. Oculomotor nerve and crus cerebri

■ *Listen (English)*

■ *Listen (Hindi)*

Explanation: This patient presents with: Right-sided ptosis, dilated pupil, eye deviated outward → Right oculomotor nerve (CN III) palsy Left-sided spastic weakness, hyperreflexia → Contralateral corticospinal tract involvement MRI: midbrain ischemic lesion These features are classic for Weber syndrome (medial midbrain syndrome) . Arteries involved are paramedian branches of the posterior cerebral artery. Structures Involved in a Midbrain Stroke: Oculomotor Nerve Nucleus (Cranial Nerve III): Function: Controls most of the eye movements, pupillary constriction, and eyelid elevation (levator palpebrae superioris). Clinical Findings: Damage to the oculomotor nerve leads to ptosis , a dilated pupil (mydriasis) , and an eye that is deviated outward and downward (due to unopposed action of the lateral rectus and superior oblique muscles). Trochlear Nerve (Cranial Nerve IV): Function: Innervates the superior oblique muscle, which helps in depression and intorsion of the eye. Clinical

Findings: A lesion of the trochlear nerve causes vertical diplopia - difficulty looking downwards and inwards, noticed while reading or descending stairs. Trochlear nerve damage would not explain the ptosis or mydriasis seen in this patient Substantia Nigra: Function: Part of the basal ganglia, it plays a crucial role in motor control and coordination, with loss of dopamine-producing neurons here leading to Parkinsonism . Clinical Findings: Midbrain strokes affecting the substantia nigra can result in motor deficits, tremors, and bradykinesia, similar to Parkinson's disease. The patient's main issues involve cranial nerve III and motor weakness, not Parkinsonism features Crus Cerebri (Corticospinal Tracts): Function: Contains descending fibers of the corticospinal and corticobulbar tracts, responsible for voluntary motor control. Clinical Findings: Damage here leads to contralateral hemiparesis due to involvement of the corticospinal tract. In Weber syndrome, the lesion commonly affects both the oculomotor nerve and the crus cerebri. While the crus cerebri is affected in this case, it alone does not account for the cranial nerve signs Oculomotor motor and red nucleus (Option A): Lesion here → Claude syndrome Features: Ipsilateral CN III palsy + contralateral ataxia / tremor (from red nucleus) Oculomotor nerve and superior cerebellar peduncle (Option C): Lesion → Benedikt syndrome Features: Ipsilateral CN III palsy + contralateral involuntary movements / tremor Oculomotor nucleus and substantia nigra (Option D): Nuclear lesion → may cause conjugate gaze palsy Substantia nigra → parkinsonism features

References:

Harrison’s Principles of Internal Medicine, 22nd Edition, Page 234.

↑ *Back to this question in Part A*

@Neet_pg_bot

Q14: A patient with stroke cannot perform simple actions on command, such as waving goodbye or pretending to brush teeth, even though they understand what to do and have no muscle weakness. When spoken a phrase “Repeat after me: ‘The sky is blue’”, the patient struggles to repeat it but speaks fluently and understands spoken language. Which lobe is most likely affected? (Q851257)

A. Right Parietal

B. Right Temporal

C. Left Parietal

D. Left Temporal

Correct Answer: C. Left Parietal

■ *Listen (English)*

■ *Listen (Hindi)*

Explanation: The patient cannot perform learned motor actions on command (e.g., waving goodbye, brushing teeth) despite intact comprehension and no weakness - this is ideomotor apraxia , which localizes to the dominant (left) parietal lobe , especially the supramarginal gyrus. The patient also has impaired repetition with fluent speech

and intact comprehension , which is characteristic of conduction aphasia . This occurs due to damage to the arcuate fasciculus , which passes through the left parietal region connecting Wernicke's and Broca's areas. Both findings strongly point to left parietal lobe involvement . Right Parietal (Option A): Lesions in the non-dominant (usually right) parietal lobe typically cause Hemispatial Neglect (ignoring the left side of the world) and Constructional Apraxia (inability to draw or build simple objects like a clock or a house). It does not typically cause aphasia or the inability to follow verbal motor commands. Right Temporal (Option B): The right temporal lobe is involved in processing non-verbal sounds, music, and social cues. A lesion here might lead to Amusia (loss of musical ability) or difficulty interpreting the emotional tone of speech (Aprosadia). Left Temporal (Option D): A lesion in the posterior left temporal lobe (Wernicke's area) results in Sensory Aphasia . While the patient would be fluent, they would have poor comprehension (they wouldn't understand the command to "brush teeth" in the first place) and their speech would be "word salad" - fluent but meaningless. This patient understands the command, so the temporal lobe is largely intact.

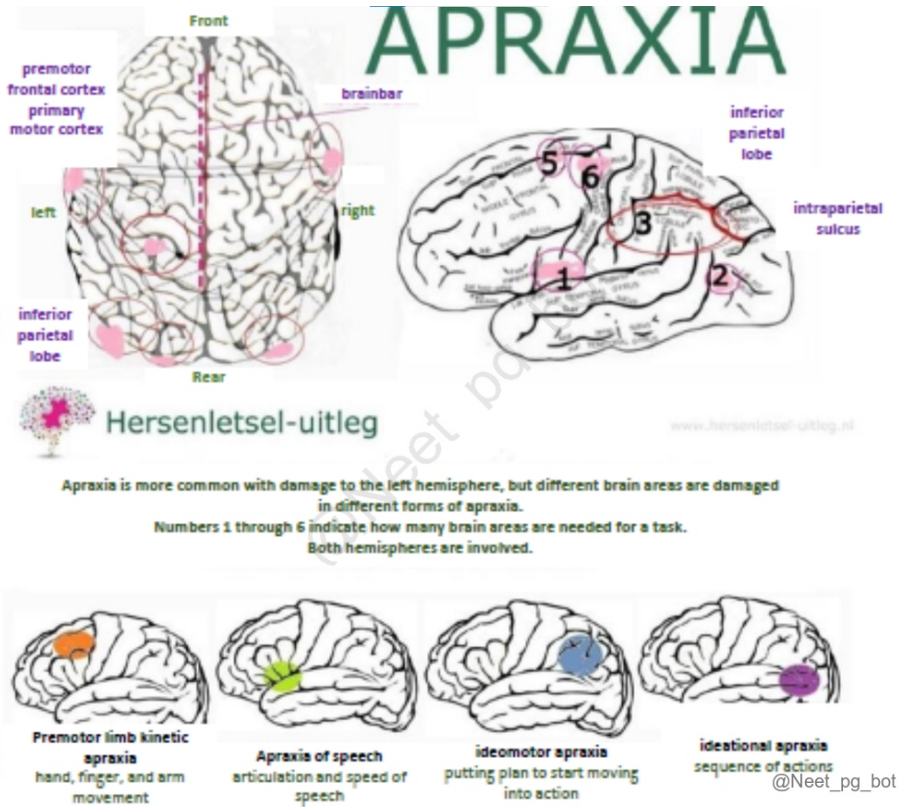

References:

Harrison's Principles of Internal Medicine, 22nd Edition, Page 203.

↑ *Back to this question in Part A*

@Neet_pg_bot

Q15: A 60-year-old man presents with sudden onset of right-sided face and arm weakness at the breakfast table at 8 am. He arrives at the ER at 4 pm in the evening.

His pulse is 100/min, BP 180/100 mm Hg, NIHSS is 6, and GCS is 13/15. NCCT head shows hypodensity in the left MCA territory and CTA reveals a M1 left MCA occlusion. . Which of the following is the best intervention for management of this patient? (Q851178)

A. Rapid lowering of BP with nicardipine to achieve target BP 140/100 mm Hg

B. Thrombectomy

C. Secure airway

D. Schedule for thrombolysis after lowering of BP

Correct Answer: B. Thrombectomy

■ *Listen (English)*

■ *Listen (Hindi)*

Explanation: Note the patient is outside the 4.5-hour thrombolysis window (option D), but he is within the 6–24 hour extended window for thrombectomy for proven large vessel occlusion (LVO). Rapid lowering of BP with nicardipine to achieve target BP 140/100 mm Hg (Option A): It would be perfect for hemorrhagic stroke presentation Secure airway (Option C): No mention of airway compromise in the question

References:

Harrison’s Principles of Internal Medicine, 22nd Edition, Page 3440.

↑ *Back to this question in Part A*

@Neet_pg_bot

Q16: A 60-year-old hypertensive man presents with sudden onset slurred speech and difficulty comprehending language. NCCT head scan reveals an ischemic stroke. The stroke likely involves which of the following vessels? (Q851198)

A. Left anterior cerebral artery

B. Left middle cerebral artery

C. Right middle cerebral artery

D. Right anterior cerebral artery

Correct Answer: B. Left middle cerebral artery

■ *Listen (English)*

■ *Listen (Hindi)*

Explanation: Sudden onset slurred speech and difficulty in understanding language (receptive aphasia) strongly suggest involvement of the left MCA (assuming left hemisphere dominance), which supplies Broca's and Wernicke's areas. Thus, the MCA is the vessel most likely involved in this patient's presentation. Slurring of speech/ dysarthria can also be explained by weakness, paralysis, or incoordination of the muscles used for speech (face, tongue, lips, palate). Left anterior cerebral artery (Option A): Supplies the medial surface of the frontal and parietal lobes —stroke causes contralateral leg weakness and sensory loss , not aphasia. Right middle cerebral artery (Option C): Affects the right hemisphere , leading to left-sided hemiplegia and hemispatial neglect , not language deficits. Right anterior cerebral artery (Option D): Causes contralateral leg weakness and abulia (lack of willpower) , with no speech involvement .

References:

Harrison's Principles of Internal Medicine, 22nd Edition, Page 3429.

↑ *Back to this question in Part A*

@Neet_pg_bot

Q17: A 40-year old lady complains of difficulty in kneading the dough for past 6 months. On examination she has atrophy of right hand muscles and fasiculations are noted in thenar muscles. Select the site of lesion? (Q851197)

A. Right anterior horn cells in spinal cord

B. Left anterior horn cells in spinal cord

C. Right Parietal Lobe

D. Left Parietal Lobe

Correct Answer: A. Right anterior horn cells in spinal cord

■ *Listen (English)*

■ *Listen (Hindi)*

Explanation: The presence of muscle atrophy and fasciculations indicates a lower motor neuron (LMN) lesion . Involvement of the right hand with corresponding muscle wasting and fasciculations localizes the lesion to the right anterior horn cells of the spinal cord — the site of LMNs that directly innervate skeletal muscle. Left anterior horn cells (Option B): Would produce LMN signs on the left side , not the right. Right parietal lobe (Option C): Involvement would cause contralateral sensory deficits or neglect , not LMN signs like fasciculations or atrophy. Left parietal lobe (Option D): Would affect contralateral (right-sided) sensory and motor integration , but not cause LMN findings.

References:

Harrison's Principles of Internal Medicine, 22nd Edition, Page 168, 169.

↑ *Back to this question in Part A*

@Neet_pg_bot

Q18: Gait apraxia and urinary incontinence are clinical features associated with damage to which lobe of the brain? (Q851196)

A. Temporal

B. Parietal

C. Occipital

D. Frontal

Correct Answer: D. Frontal

■ *Listen (English)*

■ *Listen (Hindi)*

Explanation: Gait apraxia/ magnetic gait and urinary incontinence are hallmark features of frontal lobe dysfunction, particularly involving the medial aspect of the frontal lobes where the motor cortex and the bladder control centers reside. Conditions like NPH/normal pressure hydrocephalus cause stretching or compression of the periventricular frontal white matter, disrupting these areas. Temporal lobe (Option A): Associated with memory, emotion, and auditory processing. Symptoms: Wernicke's aphasia (fluent but nonsensical speech), memory loss (hippocampal involvement), and upper quadrantanopia (vision loss in the upper outer corner). It does not control the lower limb motor planning (gait) or the autonomic signals for the bladder. Parietal lobe (Option B): Involved in sensory integration and spatial awareness , not motor planning or continence. Symptoms: Hemispatial neglect (ignoring one side of the body/world), agnosia (inability to recognize objects), and cortical sensory loss (inability to identify an object by touch). While it deals with "where" things are in space, the actual "how-to" motor program for walking and the reflex inhibition for the bladder are frontal functions. Occipital lobe (Option C): Responsible for visual processing . Symptoms: Cortical blindness, homonymous hemianopia (losing half the visual field in both eyes), and visual hallucinations. It has no direct role in motor coordination or urinary sphincters.

References:

Harrison's Principles of Internal Medicine, 22nd Edition, Page 178.

↑ *Back to this question in Part A*

@Neet_pg_bot

Q19: A 65 year man can recognise voices of family members while talking over mobile phone. But when he meets them in person he is not able to recognise them. Lesion is

present in which part of brain? (Q851194)

A. Frontal lobe

B. Temporal Lobe

C. Parietal Lobe

D. Occipital Lobe

Correct Answer: B. Temporal Lobe

■ *Listen (English)*

■ *Listen (Hindi)*

Explanation: The patient’s selective inability to recognize familiar faces despite recognizing voices indicates prosopagnosia , caused by a lesion in the right fusiform gyrus (also called the fusiform face area). This region, located in the inferior temporo-occipital area , is responsible for facial perception and recognition . Auditory recognition pathways remain intact, explaining preserved voice identification. Frontal lobe (Option A): Involved in executive functions, decision-making, and motor control. Damage here affects behavior or movement , not recognition. A patient might act inappropriately toward a family member, but they would still know who they are looking at. Parietal lobe (Option C): Handles spatial orientation and sensory integration. Damage here causes spatial neglect or difficulty reaching for objects. The patient can't figure out where the person is in the room, but they don't lose the ability to identify the face once they see it. Occipital lobe (Option D): Processes basic visual input (color, shape, motion) but not complex identification such as faces. Pure occipital lesions cause blindness (scotomas) or field cuts.

References:

Harrison’s Principles of Internal Medicine, 22nd Edition, Page 206.

↑ *Back to this question in Part A*

@Neet_pg_bot

Q20: A 60-year-old right-handed woman is brought by her husband after he notices she has trouble doing dishes and confuses her left and right sides since last evening. On examination, she cannot perform simple calculations, but her speech is fluent. The lesion is most likely in which structure? (Q851192)

A. Right Temporal Lobe

B. Left Temporal Lobe

C. Left Parietal Lobe

D. Right Parietal Lobe

Correct Answer: C. Left Parietal Lobe

■ *Listen (English)*

■ *Listen (Hindi)*

Explanation: The left parietal lobe is responsible for writing, calculations, left-right orientation, and finger recognition—disruption causes the classic Gerstmann syndrome given in this case. Left Temporal Lobe (Option A): Lesions here often cause receptive aphasia or memory impairment. Right Parietal Lobe (Option B): Right parietal lesions can lead to left-sided neglect, constructional apraxia, and visuospatial deficits Right Temporal Lobe (Option C): Lesions cause deficits in memory, facial recognition, or emotional processing

References:

Harrison's Principles of Internal Medicine, 22nd Edition, Page 203.

↑ *Back to this question in Part A*

@Neet_pg_bot

Q21: A patient presents with sudden onset weakness affecting the face, arm, and leg on one side of the body without sensory loss or cortical signs. Which is the most likely site of lesion? (Q851190)

A. Anterior limb of internal capsule

B. Posterior limb of internal capsule

C. Genu of internal capsule

D. Thalamus

Correct Answer: B. Posterior limb of internal capsule

■ *Listen (English)*

■ *Listen (Hindi)*

Explanation: The posterior limb of the internal capsule contains corticospinal and corticobulbar motor fibers; infarcts here cause contralateral pure motor weakness affecting face, arm, and leg without sensory or cortical deficits. Anterior limb of internal capsule (Option A): The anterior limb contains frontopontine and thalamocortical fibers. Its involvement causes cognitive and behavioral changes like confusion, impaired attention, agitation, and memory disturbances. Genu of internal capsule (Option C): The genu contains corticobulbar fibers mainly affecting face muscles; isolated lesions here cause mostly facial weakness. Thalamus (Option D): Thalamic lesions typically produce sensory disturbances rather than isolated motor weakness.

References:

Harrison’s Principles of Internal Medicine, 22nd Edition, Page 3446.

↑ *Back to this question in Part A*

@Neet_pg_bot

Q22: A 70-year-old male presents to ER with sudden-onset right-sided arm weakness and difficulty speaking which started 2 hours ago. His medical history includes hypertension, hyperlipidemia, and a prior TIA. His BP is 160/100 mm Hg. A CT scan of the head rules out hemorrhagic stroke. Which of the following is the most appropriate initial management for this patient? (Q851189)

A. Administer intravenous Alteplase immediately.

B. Start intravenous heparin for anticoagulation therapy.

C. Intubate the pateint

D. Control BP with Labetalol

Correct Answer: A. Administer intravenous Alteplase immediately.

■ *Listen (English)*

■ *Listen (Hindi)*

Explanation: The diagnosis of ischemic stroke is indicated by the patient's sudden-onset right-sided weakness and difficulty speaking coupled with CT scan ruling out hemorrhagic stroke further confirms the diagnosis. Administering intravenous Alteplase immediately is appropriate as the patient presents with signs of an ischemic stroke and is within the treatment window for intravenous thrombolysis (within 3-4.5 hours). Since the CT scan has ruled out hemorrhagic stroke, administering rtPA is crucial for improving outcomes by restoring blood flow to the affected area of the brain. This patient is much below the threshod for contraindication for thrombolysis which is < 185/110 mm Hg. Hence lowering of BP is not required.

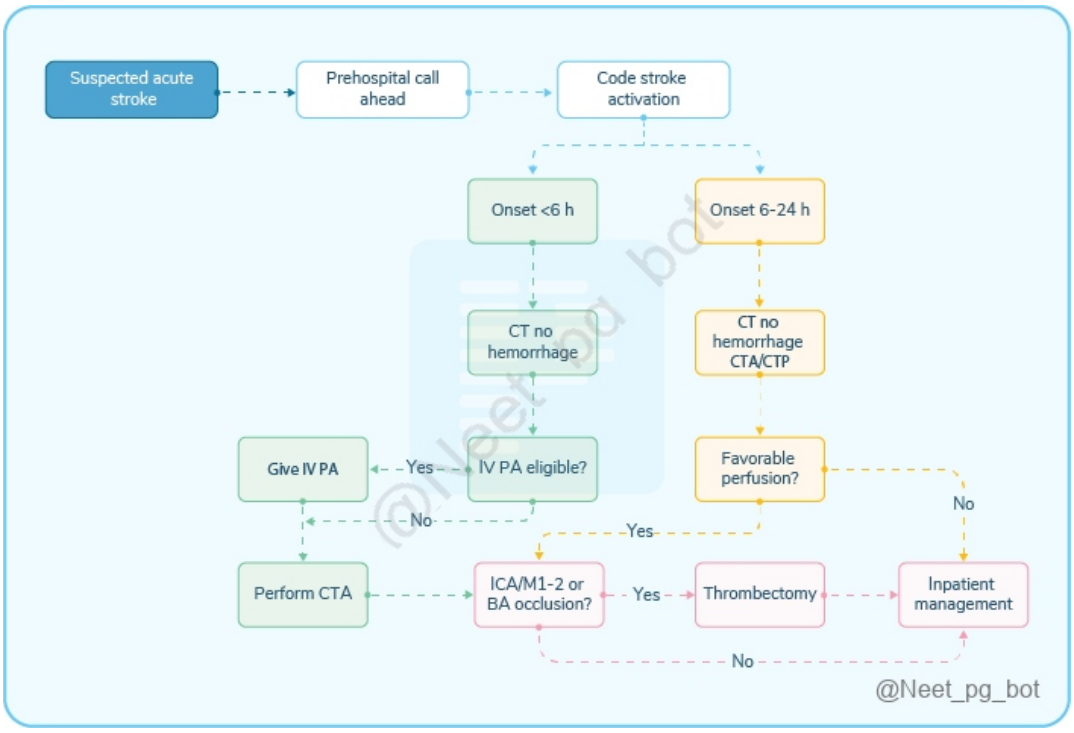

References:

Harrison's Principles of Internal Medicine, 22nd Edition, Page 3440.

↑ *Back to this question in Part A*

@Neet_pg_bot

Q23: A 65-year-old diabetic male presents to the emergency department with a sudden onset of right-sided weakness and slurred speech that resolved completely within 2 hours. His blood pressure is 160/90 mmHg. Based on his ABCD2 score of 6, what is the most appropriate immediate management? (Q851187)

A. Start oral aspirin 81 mg daily alone

B. Combination of ticagrelor plus aspirin

C. Warfarin with target INR 2-3

D. Tenecteplase

Correct Answer: B. Combination of ticagrelor plus aspirin

■ *Listen (English)*

■ *Listen (Hindi)*

Explanation: Short-term dual antiplatelet therapy (DAPT) with ticagrelor/ clopidogrel-aspirin for 21-90 days is superior to aspirin alone in preventing recurrent stroke after TIA. This regimen reduces 90-day stroke risk from 11.7% to 8.2% without significant increase in major hemorrhage ABCD2 score helps stratify TIA patients' risk of stroke: Age ≥60 years (1 point) BP ≥140/90 (1 point) Clinical features (weakness=2, speech disturbance=1) Duration (≥60 min=2, 10-59 min=1) Diabetes (1 point) High ABCD2 score (≥4) indicates high risk of early recurrent stroke: Early aggressive antiplatelet therapy with DAPT (first 21-90 days) followed by monotherapy is the current standard of care for high-risk TIA patient

References:

Harrison's Principles of Internal Medicine, 22nd Edition, Page 3449.

↑ *Back to this question in Part A*

@Neet_pg_bot

Q24: Which of the following is not correct about ABCD2 score for diagnosis of Transient ischemic attack? (Q851186)

A. Age > 60 years

B. Elevated BP

C. Past history of stroke

D. Duration of symptoms

Correct Answer: C. Past history of stroke

■ *Listen (English)*

■ *Listen (Hindi)*

Explanation: In ABCD2 score we consider current neurological symptoms in the patient and not the patient's past medical history of stroke. In fact, past medical history is considered in the CHADS2-VASc score used in atrial fibrillation. ABCD2 score: Age ≥60 years (1 point) BP ≥140/90 (1 point) Clinical features (weakness=2, speech disturbance=1) Duration (≥60 min=2, 10-59 min=1) Diabetes (1 point) Risk of Stroke (2-Day Risk): The primary purpose of the score is to determine how likely a patient is to have a massive stroke within 48 hours of the TIA. Score Risk Category 2-Day Stroke Risk Management Recommendation 0–3 Low 1.0% Outpatient evaluation 4–5 Moderate 4.1% Usually observation/hospitalization 6–7 High 8.1% Urgent hospitalization

References:

Harrison's Principles of Internal Medicine, 22nd Edition, Page 3448.

↑ *Back to this question in Part A*

@Neet_pg_bot

Q25: A 60-year-old man presents with sudden onset right arm weakness and slurred speech for 1 hour. His blood pressure is 170/100 mm Hg. He has a history of atrial fibrillation and is on warfarin; current INR is 2.0. NCCT head shows no intracranial hemorrhage. CT angiography reveals a left MCA occlusion. Which of the following is the most appropriate next step in management? (Q851184)

A. Intravenous Alteplase

B. Mechanical thrombectomy after confirming salvageable tissue with CT perfusion

C. Cardiology consult for chemical cardioversion

D. Mannitol and dual antiplatelet therapy

Correct Answer: B. Mechanical thrombectomy after confirming salvageable tissue with CT perfusion

■ *Listen (English)*

■ *Listen (Hindi)*

Explanation: INR = 2.0 → IV thrombolysis is contraindicated (cutoff for Alteplase is INR ≤ 1.7). The patient has a large vessel occlusion (LVO) in the left MCA , the most appropriate therapy is mechanical thrombectomy , provided CT perfusion (CTP) demonstrates a salvageable penumbra . Thrombectomy is indicated both in the early window (0–6 h) and the extended window (up to 24 h) when CTP shows favorable perfusion. Intravenous Alteplase (Option A): is contraindicated with INR >1.7 due to high bleeding risk. Cardiology consult for chemical cardioversion (Option C): is a distraction option and focus should be on stroke management. Mannitol and dual antiplatelet therapy (Option D): There is no evidence of raised ICP requiring mannitol; dual antiplatelets are not first-line for acute LVO stroke.

References:

Harrison’s Principles of Internal Medicine, 22nd Edition, Page 3451.

https://www.ncbi.nlm.nih.gov/books/NBK557411/

↑ *Back to this question in Part A*

@Neet_pg_bot

Q26: A 58-year-old right-handed man is brought to the ER for speaking fluently but producing nonsensical words and sentences. He has difficulty understanding spoken commands. Neurological exam shows no significant motor weakness. Which of the following vessels is most likely involved? (Q851182)

A. Superior division of left middle cerebral artery

B. Inferior division of left middle cerebral artery

C. Left anterior cerebral artery

D. Left posterior cerebral artery

Correct Answer: B. Inferior division of left middle cerebral artery

■ *Listen (English)*

■ *Listen (Hindi)*

Explanation: The inferior division of the left MCA supplies Wernicke's area in the posterior superior temporal gyrus, and its infarction leads to fluent aphasia with impaired comprehension, without motor deficits. The superior division of the left MCA supplies Broca's area (Option A) in the frontal lobe, so its infarct causes non-fluent aphasia with right face and arm weakness, not fluent speech with comprehension deficits. The left anterior cerebral artery (Option C) supplies the medial frontal lobes, leading to contralateral leg weakness and abulia rather than language problems. The left posterior cerebral artery (Option D) supplies the occipital lobe and inferomedial temporal regions, where infarction causes visual field defects or visual agnosia, not aphasia.

References:

Harrison's Principles of Internal Medicine, 22nd Edition, Page 3429.

↑ *Back to this question in Part A*

@Neet_pg_bot

Q27: A 65-year-old male presents with sudden onset of vertigo, dysphagia, hoarseness, and left-sided facial numbness. On examination, he has left-sided Horner's syndrome, right-sided loss of pain and temperature sensation in the body, and left-sided cerebellar signs. Which of the following is the most likely diagnosis? (Q851181)

A. Parinaud syndrome

B. Dejerine syndrome

C. Wallenberg syndrome

D. Weber syndrome

Correct Answer: C. Wallenberg syndrome

■ *Listen (English)*

■ *Listen (Hindi)*

Explanation: Wallenberg syndrome (lateral medullary syndrome) is caused by occlusion of the vertebral artery or PICA , leading to crossed findings: ipsilateral facial sensory loss and Horner's, contralateral body pain/temp loss, and cerebellar signs. Parinaud syndrome (Option A): Vertical gaze palsy from dorsal midbrain lesion Dejerine syndrome (Option B): Medial medullary infarction causes contralateral hemiparesis and tongue weakness Weber syndrome (Option D): Midbrain base infarct causes ipsilateral oculomotor palsy + contralateral hemiparesis, not cerebellar or sensory signs

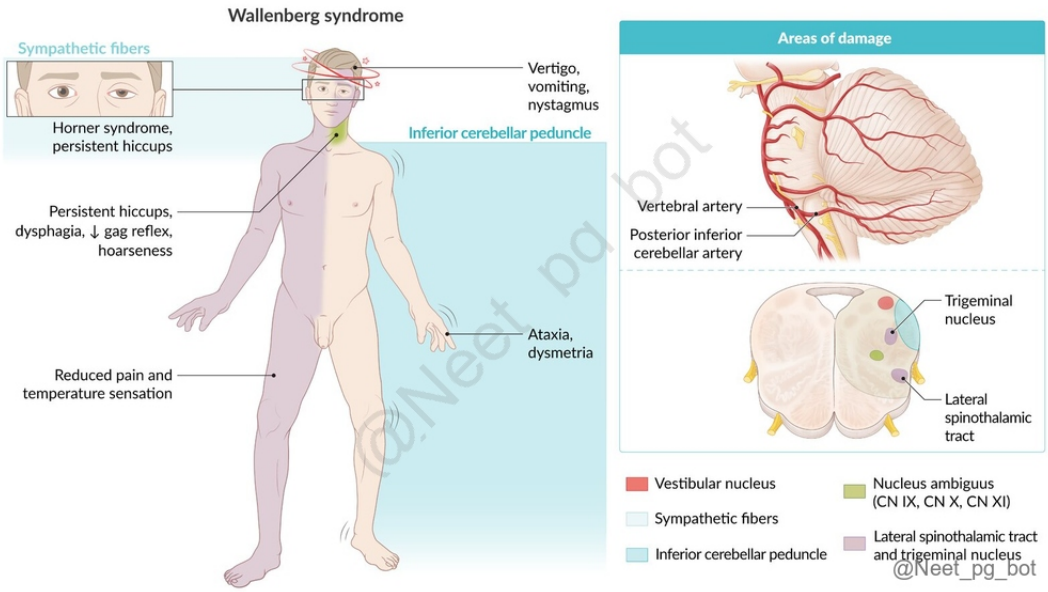



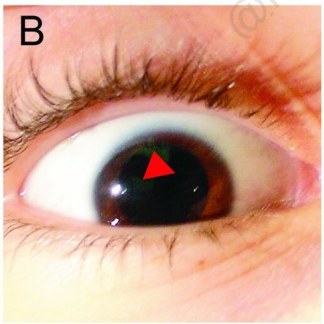

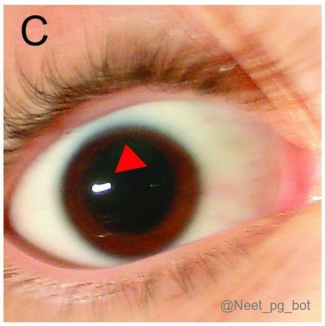

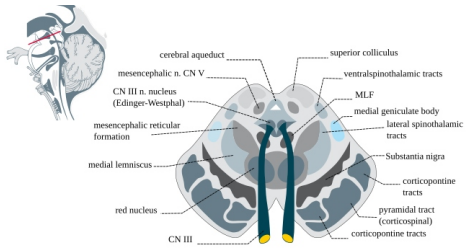



@Neet_pg_bot

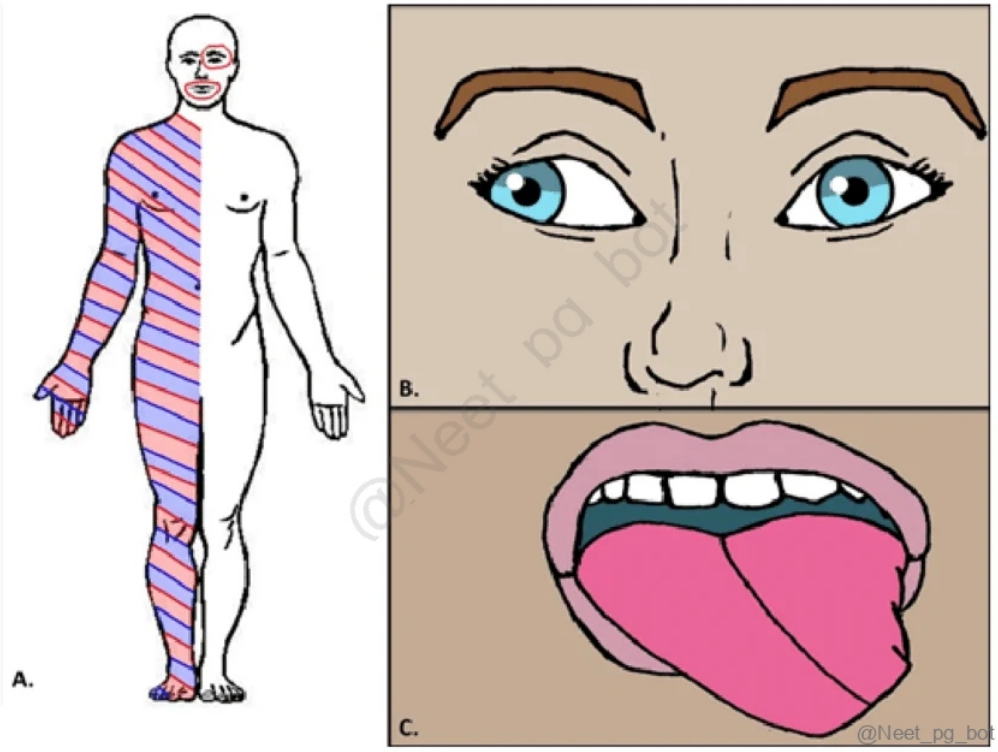

@Neet_pg_bot

Medulla

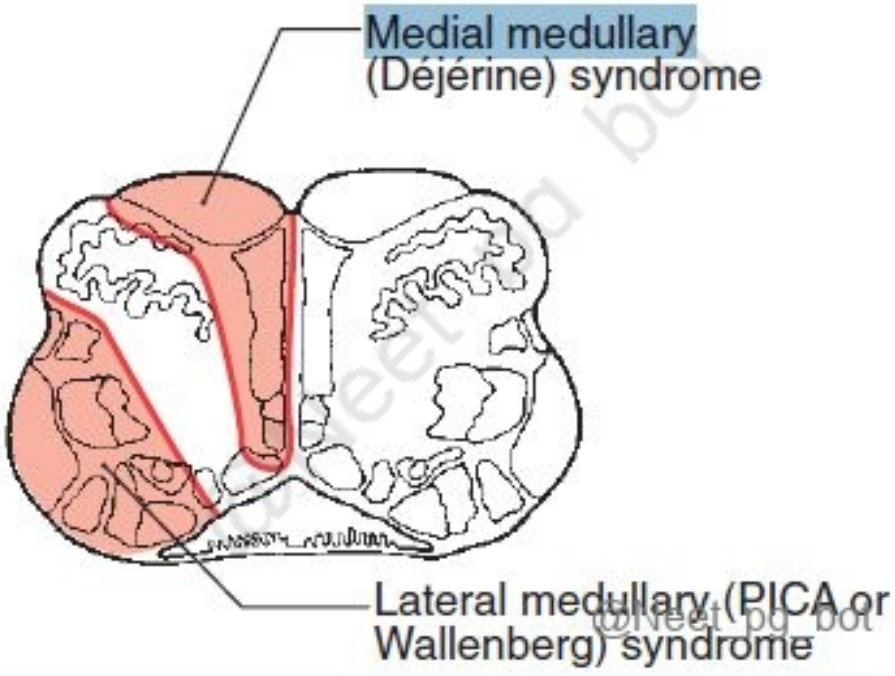

@Neet_pg_bot

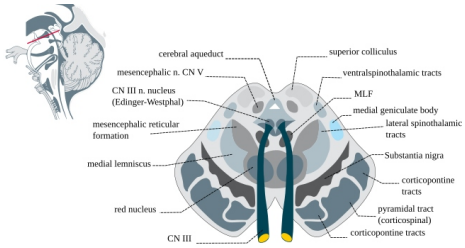



@Neet_pg_bot

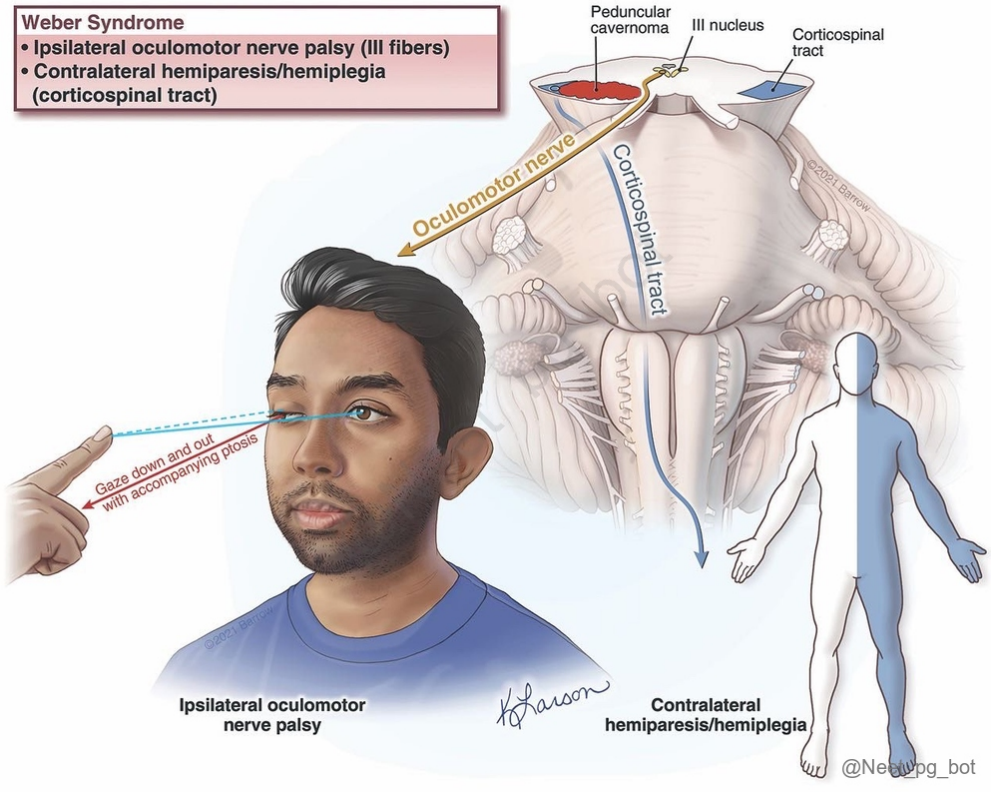

References:

Harrison's Principles of Internal Medicine, 22nd Edition, Page 3433.

↑ *Back to this question in Part A*

@Neet_pg_bot

Q28: A 65-year-old hypertensive man presents with a sudden onset of right-sided weakness affecting his face, arm, and leg. The NCCT head shows an intraparenchymal bleed in left side basal ganglia. Which of the following vessels is most likely involved in this pathology? (Q851180)

A. Internal carotid artery

B. Posterior communicating artery

C. Penentrating branches of lenticulostriate arteries

D. Anterior communicating artery

Correct Answer: C. Penentrating branches of lenticulostriate arteries

■ *Listen (English)*

■ *Listen (Hindi)*

Explanation: The penetrating branches of lenticulostriate arteries arise from M1 segment of the middle cerebral artery . They supply important deep structures, including the internal capsule, putamen, and caudate nucleus. The described pure motor hemiparesis is a classic lacunar syndrome resulting from occlusion of a lenticulostriate artery affecting the posterior limb of the internal capsule. Lacunar strokes result from occlusion of small penetrating arteries and typically cause distinct clinical syndromes like pure motor stroke described in stem of this question.

References:

Harrison’s Principles of Internal Medicine, 22nd Edition, Page 3429.

↑ *Back to this question in Part A*

@Neet_pg_bot

• [07_Neurology] 050 Stroke Tia And Image Based Questions

« Back to Folder Directory

[07_Neurology] 050 Stroke Tia And Image Based Questions — Quick Jump

Q1 (p. 2249)	*Q2 (p. 2250)*	*Q3 (p. 2251)*	*Q4 (p. 2252)*	*Q5 (p. 2254)*	*Q6 (p. 2255)*
Q7 (p. 2257)	*Q8 (p. 2259)*	*Q9 (p. 2263)*	*Q10 (p. 2264)*	*Q11 (p. 2267)*	*Q12 (p. 2270)*
Q13 (p. 2271)	*Q14 (p. 2273)*	*Q15 (p. 2275)*	*Q16 (p. 2276)*	*Q17 (p. 2277)*	*Q18 (p. 2278)*
Q19 (p. 2279)	*Q20 (p. 2280)*	*Q21 (p. 2282)*	*Q22 (p. 2283)*	*Q23 (p. 2283)*	*Q24 (p. 2284)*
Q25 (p. 2285)	*Q26 (p. 2286)*	*Q27 (p. 2287)*	*Q28 (p. 2288)*	*Q29 (p. 2289)*	

Q1: A 62-year-old woman presents with chronic burning pain, numbness, and tingling on the right side of her body not relieved with NSAIDs. The symptoms began 2 months after she suffered a stroke. On examination, she has hyperesthesia and allodynia on the right side. The clinician suspected it to be due to lacunar infarct. What could be the likely site of infarct causing her present symptoms? (Q851217)

A. Ventroposterolateral thalamus

B. Posterior limb of internal capsule

C. Genu of internal capsule

D. Cortical pontocerebellar tract

Correct Answer: A. Ventroposterolateral thalamus

■ *Listen (English)*

■ *Listen (Hindi)*

Explanation: Chronic burning pain not relieved by usual NSAIDs following a stroke is due to lacunar infarct of Ventroposterolateral Thalamus , known as Dejerine-Roussy syndrome (aka) Thalamic pain syndrome . Small vessel stroke: Sites & manifestations Posterior limb of internal capsule (Option B) Pure motor hemiparesis Genu of internal capsule (Option C) Clumsy hand dysarthria lacunar syndrome (facial weakness) Cortical pontocerebellar tract (Option D) I/L ataxia + C/L hemiparesis Ventroposterolateral thalamus (Option A) Dejerine-Roussy syndrome

References:

Harrison’s Principles of Internal Medicine, 22nd Edition, Page 176, 3432.

↑ *Back to this question in Part A*

@Neet_pg_bot

Q2: An elderly patient presented with a history of slowing of movements, frequent falls and forgetfulness. MRI done is as shown below. Which among the following is not a feature of this condition? (Q852414)

A. Defective downward gaze

B. Resting tremors

C. Poor response to levodopa

D. Gunslinger's gait

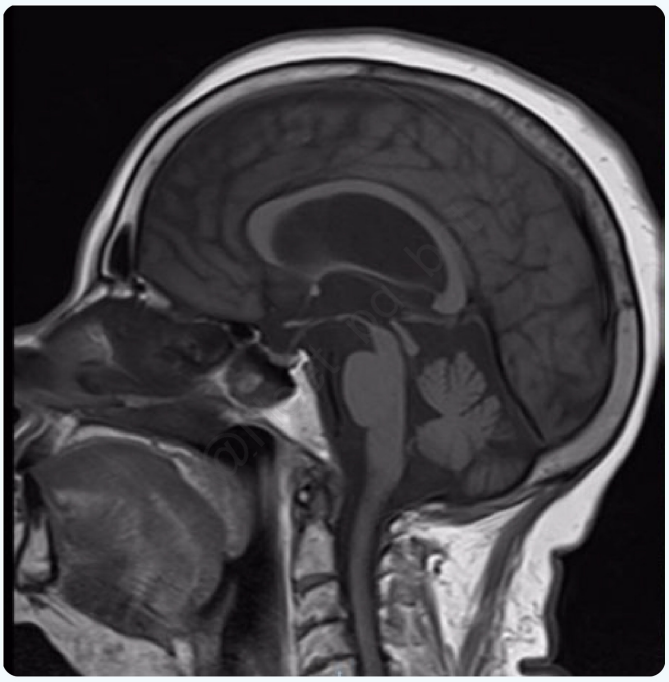

Correct Answer: B. Resting tremors

Listen (English)

Listen (Hindi)

Explanation: MRI shows Hummingbird sign - suggestive of Progressive supranuclear palsy [PSP] (a Parkinson-plus disorder). Tremors are not a feature of PSP . Progressive supranuclear palsy [PSP] Early onset postural instability - H/O frequent falls + Dementia Tremors - absent (Option B) Defective downward gaze (Option A) + extended posture of body Dystonia: Procerus sign (forehead) + Gunslinger's gait (flexion at elbow & adduction at upper limb) (Option D) Poor response to levodopa (Option C) MRI: Hummingbird sign

References:

Harrison’s Principles of Internal Medicine, 22nd Edition, Page 3487.

↑ *Back to this question in Part A*

@Neet_pg_bot

Q3: Which of the following clinical signs of upper motor neuron lesion is described correctly ? (Q851230)

A. Babinski’s sign - Lateral stroke of the sole resulting in flexion of all toes

B. Gordon’s sign - A stroke beneath and in front of the lateral malleolus causing an extensor plantar response.

C. Oppenheim’s sign - Apply pressure along the medial aspect of tibia causing an extensor plantar response

D. Chaddock’s sign - Squeeze the calf muscles to produce extensor plantar response.

Correct Answer: C. Oppenheim’s sign - Apply pressure along the medial aspect of tibia causing an extensor plantar response

■ *Listen (English)*

■ *Listen (Hindi)*

Explanation: Oppenheim’s sign is elicited by applying pressure along the medial aspect of tibia to cause an extensor plantar response i.e. dorsiflexion of the great toe and fanning of the other toes. Babinski’s sign is elicited by stroking the lateral aspect of the sole from the heel towards the little toe and then continuing up to the great toe. This results in an extensor plantar response as described above in a case of upper motor neuron lesion. Flexion of all toes indicates a normal person or the presence of a lower motor neuron lesion. Gordon’s sign is elicited by squeezing the calf muscles to produce an extensor plantar response. Chaddock’s sign is elicited by stimulating the dorsolateral aspect of the foot from the posterior portion of the skin just beneath the lateral malleolus anteriorly and along the external edge of the foot.



References:

https://www.ncbi.nlm.nih.gov/medgen/735510

↑ *Back to this question in Part A*

@Neet_pg_bot

Q4: A 5 year old female child presented to the casualty with recurrent seizures and left sided hemiplegia. On physical examination, a reddish skin lesion was found since birth over the right side of her forehead involving the right eye, nose and cheek. On CT imaging of the brain, the following picture was seen. What is the probable diagnosis? (Q851229)

A. Von Hippel Lindau syndrome

B. Sturge Weber syndrome

C. Neurofibromatosis

D. Ataxia telangiectasia



Correct Answer: B. Sturge Weber syndrome

■ *Listen (English)*

■ *Listen (Hindi)*

Explanation: The given clinical scenario of a 5 year old female child with complaints of recurrent seizures , left sided hemiplegia with a description of port-wine stain in the right ophthalmic division of trigeminal nerve and a CT image showing the classical tram-track or rail-road sign suggests a diagnosis of Sturge Weber syndrome . {{caption_text}} Von-Hippel Lindau syndrome (Option A): Mutations (3p deletion) lead to numerous vascular tumours in the body such as clear cell carcinoma of the kidneys, cerebellar and retinal hemangioblastomas and spinal cord angiomas. Cerebellar signs and raised intracranial tension are the usual manifestations. Neurofibromatosis (Option C): This is the most common type of neurocutaneous syndrome. They also present with recurrent seizures but instead of port-wine stain, they show neurofibromas with nervous system abnormalities of optic glioma , intraspinal neurofibroma, aqueductal stenosis and dural ectasia . Ataxia telangiectasia (Option D): It usually presents with slowly progressive truncal ataxia starting in infancy. Skin manifestations start after the age of 2-3 years with cutaneous (at flexures) and ocular (bulbar conjunctiva) telangiectasia . In addition, there is an immunodeficiency component leading to frequent sino-pulmonary infections and risk of lymphoreticular malignancies .



References:

https://www.ncbi.nlm.nih.gov/books/NBK459163/

↑ *Back to this question in Part A*

@Neet_pg_bot

Q5: A 15 year old adolescent male patient came with his parents with complaints of neuropsychiatric symptoms such as tremors and an irritable mood. On physical examination, stigmata of liver disease and the following ophthalmological finding is seen. Which of the following is correct about this condition? (Q851228)

A. Defect in P type ATP ase ATP7B protein

B. Defect in P type ATP ase ATP7A protein

C. ATP7B gene defect with increased ceruloplasmin

D. ATP7A gene defect with increased ceruloplasmin



Correct Answer: A. Defect in P type ATP ase ATP7B protein

■ *Listen (English)*

■ *Listen (Hindi)*

Explanation: The given clinical scenario of an adolescent male with neuropsychiatric symptoms, hepatomegaly and ophthalmological finding of Kayser-Fleischer ring is suggestive of Wilson's disease. The gene involved is ATP7B gene on chromosome 13. (ATP 7A In menke kinky hair disease). The protein whose functioning is defective in Wilson disease is P type ATP ase ATP7B protein in liver that is responsible for hepatobiliary excretion of copper and incorporation into ceruloplasmin . Due to this defect copper will accumulate in liver and other body tissue.

References:

Harrison's Principles of Internal Medicine, 22nd Edition, Page 3339.

↑ *Back to this question in Part A*

@Neet_pg_bot

Q6: A 30 year old male patient was brought to the ER with a history of RTA and sustained multiple injuries. On primary assessment, he was disoriented and complained of severe headache. Meningeal signs are noted. On neuroimaging the following image was seen. What is the most probable diagnosis in this patient?

(Q851227)

A. Intracerebral hemorrhage

B. Subdural hemorrhage

C. Subarachnoid hemorrhage

D. Extradural hemorrhage



@Neet_pg_bot

Correct Answer: C. Subarachnoid hemorrhage

■ *Listen (English)*

■ *Listen (Hindi)*

Explanation: CT brain shows hyperdensities in bilateral sylvian cisterns and the basal cisterns producing star of death appearance. The combination of CT findings and headache with nuchal rigidity implies subarachnoid hemorrhage. Most common cause of SAH is trauma. Intracerebral hemorrhage (Option A): Appears as a localized hyperdensity within brain parenchyma , not in the cisterns. Subdural hemorrhage (Option B): Presents as a crescent-shaped collection between dura and arachnoid, not involving basal cisterns. Extradural hemorrhage (Option D): Seen as a biconvex/lentiform hyperdensity between skull and dura, typically with lucid interval.

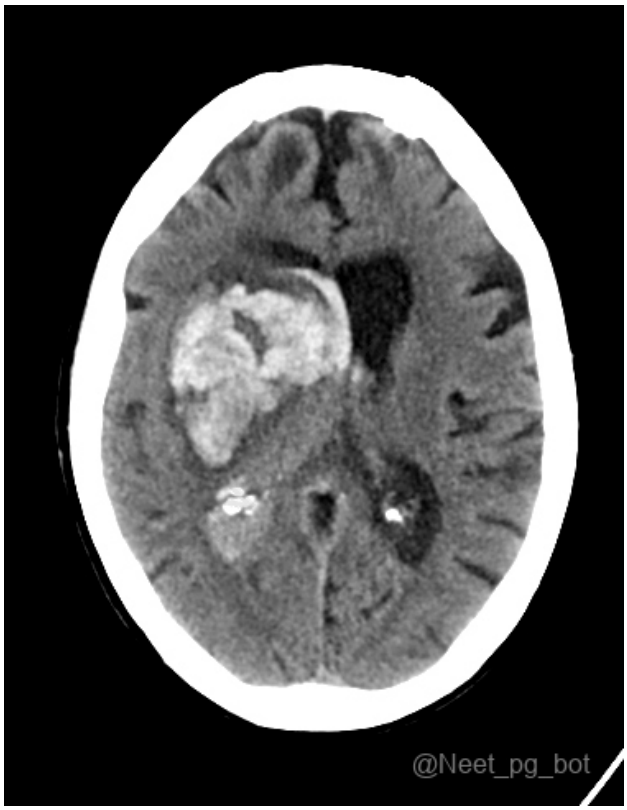

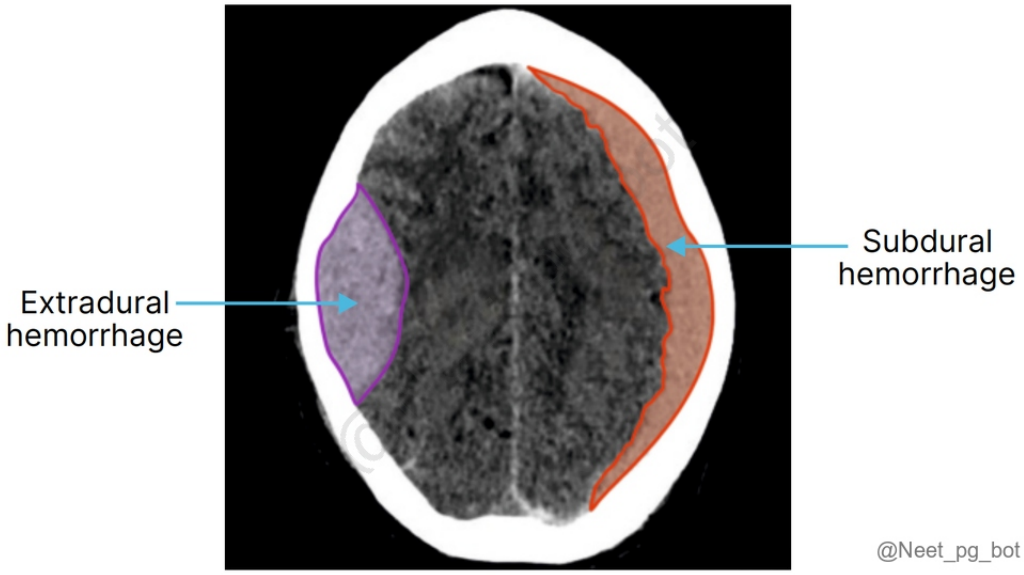

References:

Harrison's Principles of Internal Medicine, 22nd Edition, Page 3458, 3459.

↑ *Back to this question in Part A*

@Neet_pg_bot

Q7: A 75 year old male patient came to the OPD with complaints of recent onset stooping, broad based abnormal gait, short-term memory loss and urge incontinence. On radiological investigation, the following image is obtained. What is the probable diagnosis? (Q851226)

A. Parkinson’s disease

B. Alzheimer’s disease

C. Normal pressure hydrocephalus

D. Idiopathic intracranial hypertension

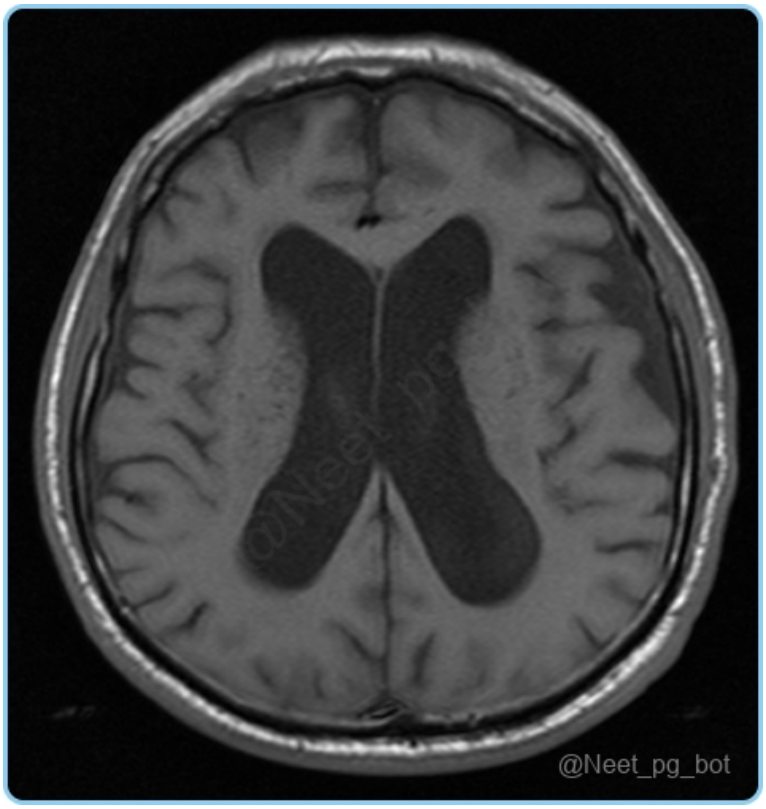

Correct Answer: C. Normal pressure hydrocephalus

■ *Listen (English)*

■ *Listen (Hindi)*

Explanation: The given clinical scenario of an elderly male patient with complaints of recent onset stooping, Broad based abnormal gait (gait apraxia/ gait instability), short term memory loss (dementia) and urge incontinence and on radiological investigation the image shows bilateral lateral ventriculomegaly which is suggestive of normal pressure hydrocephalus. Parkinson’s disease (Option A): Characterized by resting tremor, rigidity, and bradykinesia , not broad-based gait or incontinence. Alzheimer’s disease (Option B): Presents with progressive memory loss and cognitive decline but no gait disturbance or urinary symptoms. Idiopathic intracranial hypertension (Option D): Occurs mainly in young obese females with headache, papilledema, and visual

symptoms , not ventriculomegaly or gait apraxia.

References:

Harrison’s Principles of Internal Medicine, 22nd Edition, Page 3483.

↑ *Back to this question in Part A*

@Neet_pg_bot

Q8: A 13 year old male patient presented with complaints of poor scholastic performance, history of recurrent seizures since infancy and the following incidental finding on his back. What does the incidental finding denote and probable diagnosis of this patient? (Q851225)

A. Neurofibroma and Neurofibromatosis

B. Adenoma sebaceum and Tuberous sclerosis

C. Shagreen patch and Tuberous sclerosis

D. Cafe-au-lait spots and Neurofibromatosis



Correct Answer: C. Shagreen patch and Tuberous sclerosis

■ *Listen (English)*

■ *Listen (Hindi)*

Explanation: The given clinical scenario of an adolescent male patient with complaints of poor scholastic performance (low IQ), history of recurrent seizures since infancy and clinical image showing shagreen patch suggests diagnosis of tuberous sclerosis. Other skin manifestations include: Adenoma sebaceium seen on face (Option B) Adenoma sebaceium {{caption_text}} Hypomelanotic macules (Ash leaf macules) Ash leaf macules {{caption_text}} Periungual fibromas (Koenen tumours) Koenen tumour {{caption_text}} Neurofibroma and Neurofibromatosis (Options A) and Cafe-au-lait spots and Neurofibromatosis (Option D): Neurofibromas and cafe-au-lait spots are associated with neurofibromatosis . Cafe-au-lait spots {{caption_text}} Neurofibromas {{caption_text}}




@Neet_pg_bot


@Neet_pg_bot





References:

Harrison's Principles of Internal Medicine, 22nd Edition, Page 723.

↑ *Back to this question in Part A*

@Neet_pg_bot

Q9: A 45-year-old woman presents with progressive hearing loss in the right ear, occasional imbalance while walking, and a sensation of fullness in the ear. On examination, she has decreased corneal reflex on the right side. MRI of the brain is shown below. Which of the following is the most likely diagnosis? (Q851224)

A. Vestibular schwannoma

B. Cerebellar Astrocytoma

C. Craniopharyngioma

D. Prion disease

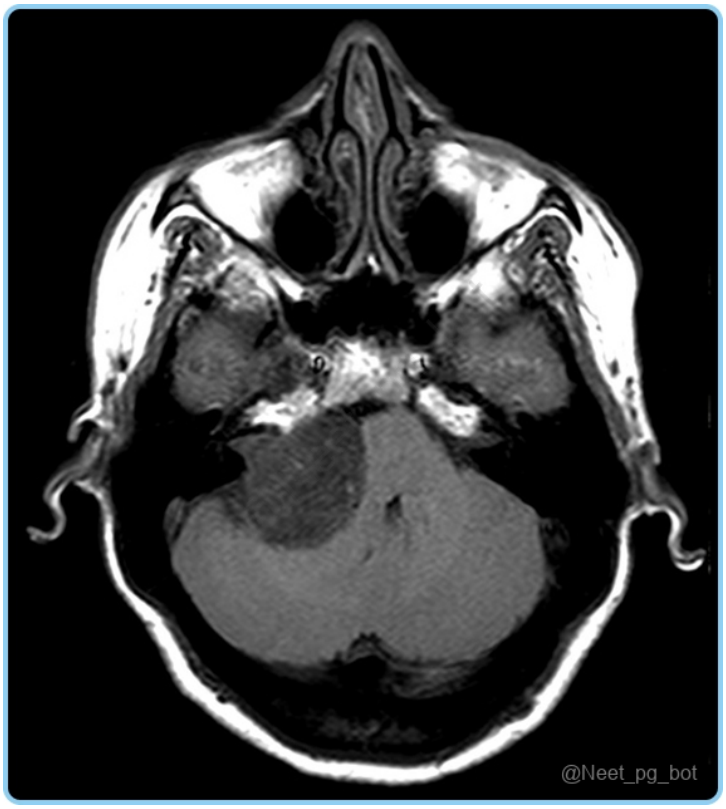

Correct Answer: A. Vestibular schwannoma

■ *Listen (English)*

■ *Listen (Hindi)*

Explanation: MRI Brain shows Vestibular schwannoma with ice cream cone appearance at the cerebellopontine angle. The trigeminal nerve (CN V) emerges from the lateral pons, superior and anterior to the entry of CN VIII. So in case of tumor originating from 8th nerve, the fifth nerve is compressed and causes absent corneal reflex.

Cerebellar astrocytoma (Option B) is ruled out based on location and absence of features suggesting raised intracranial pressure. Craniopharyngioma (Option C): MRI reveals a suprasellar cystic and solid mass, often with calcifications. Prion Disease (Option D): MRI typically shows hyperintensity in the basal ganglia, thalamus (including the "hockey stick sign" in variant CJD), and cortical ribboning on diffusion-weighted imaging (DWI) and FLAIR sequences, reflecting spongiform changes.

References:

Harrison’s Principles of Internal Medicine, 22nd Edition, Page 164.

↑ *Back to this question in Part A*

@Neet_pg_bot

Q10: A 9-year-old child presents with progressive dystonia, difficulty walking, and slurred speech. On examination, he has oromandibular dystonia and choreoathetosis. MRI brain shows bilateral hypointensity of the globus pallidus with a central area of hyperintensity. Which of the following is the most likely diagnosis? (Q851223)

A. Pantothenate kinase-associated neurodegeneration

B. Huntington disease

C. Craniopharyngioma

D. Prion disease

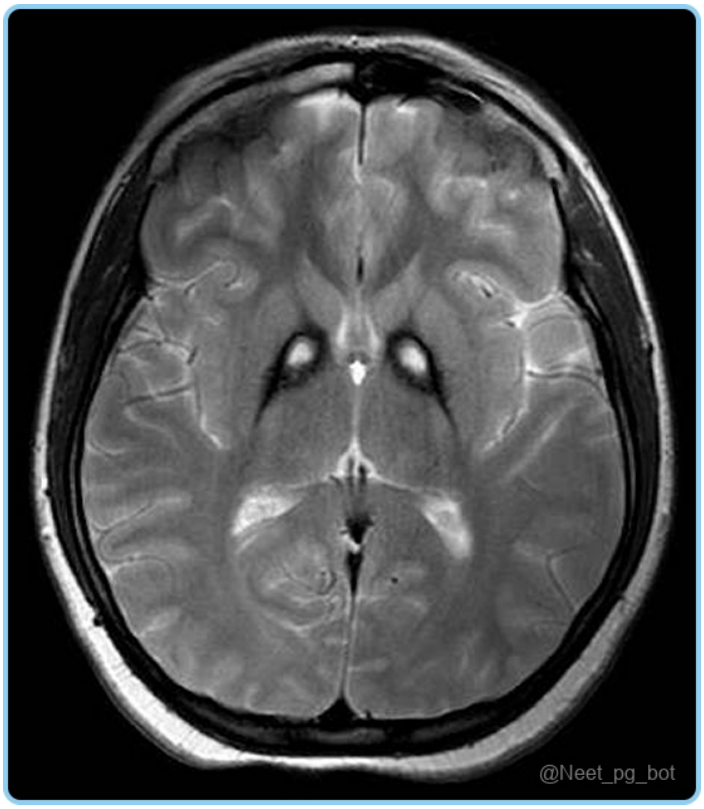

Correct Answer: A. Pantothenate kinase-associated neurodegeneration

■ *Listen (English)*

■ *Listen (Hindi)*

Explanation: Child is having parkinson like features and MRI shows bilateral hypointensity of the globus pallidus with a central area of hyperintensity. This is called eye of tiger sign and is seen in Pantothenate kinase-associated neurodegeneration (PKAN) (aka Halloverdan spatz disease). It is rare autosomal recessive neurodegenerative disorder marked by the accumulation of iron in the brain's nuclei. Huntington disease (Option B) is seen with chorea. Craniopharyngioma (Option C) is seen in children and presents with raised ICP. Prion disease (Option D) will present dementia and myoclonic jerks.

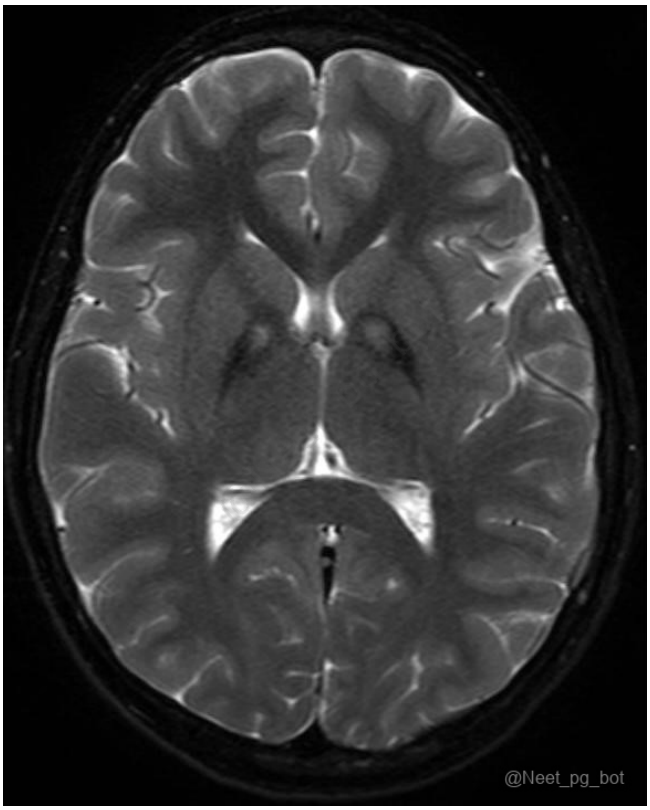

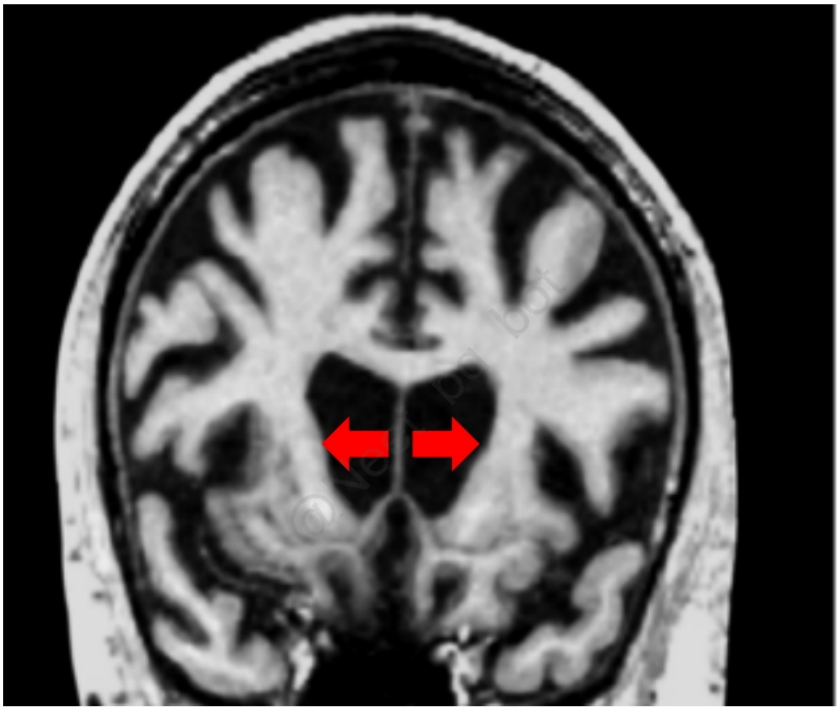

Enlarged lateral ventricle

@Neet_pg_bot

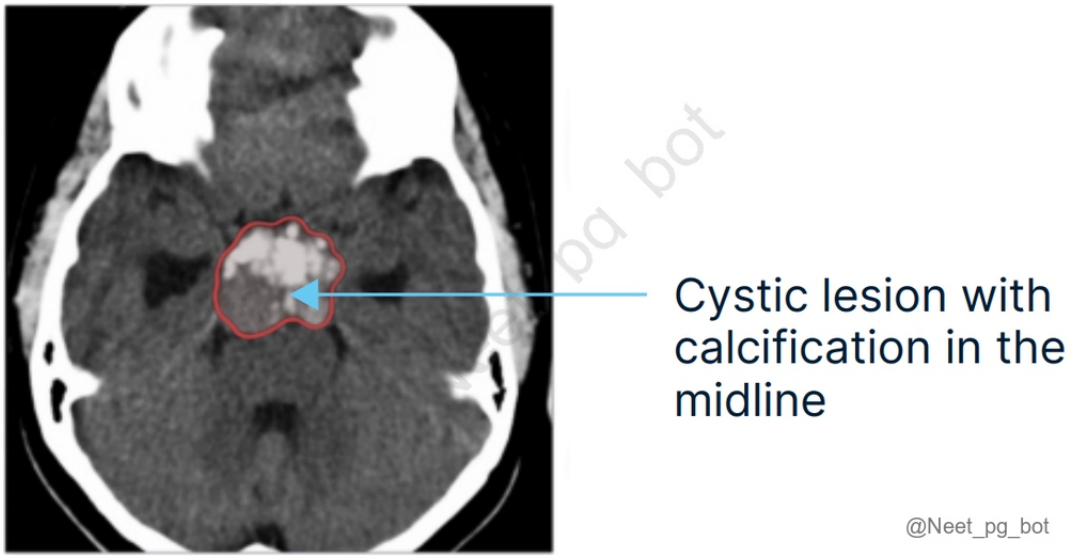

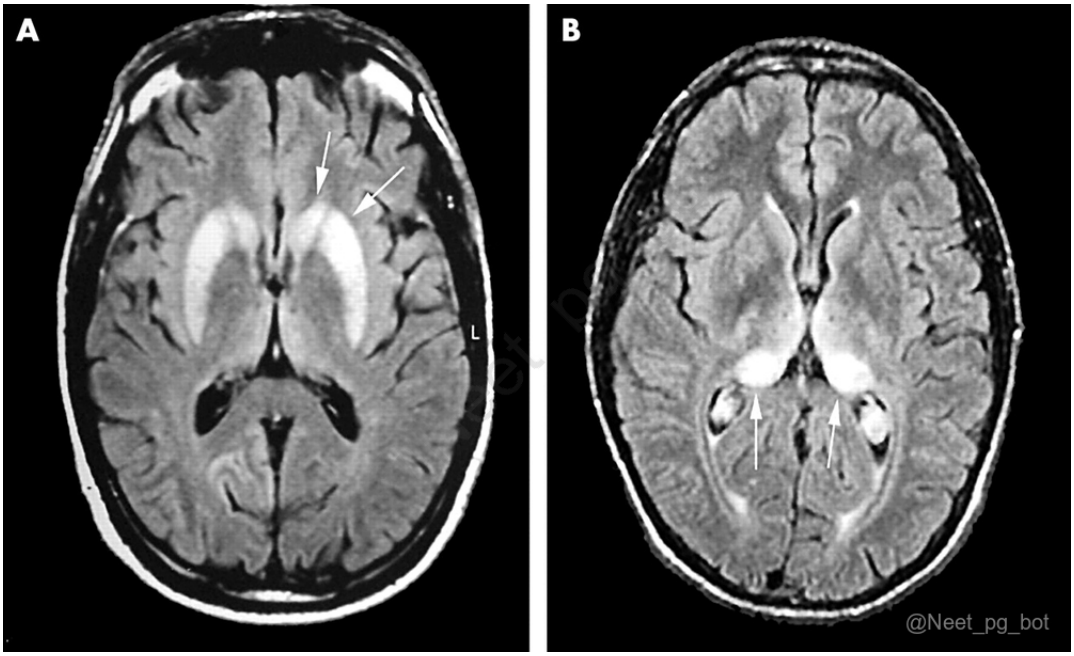

References:

Harrison's Principles of Internal Medicine, 22nd Edition, Page 3518.

↑ *Back to this question in Part A*

@Neet_pg_bot

Q11: Which of the following is a CT finding of Pneumocephalus? (Q851222)

A. Mount Fuji Sign

B. Air Bubble Sign

C. Peaking Sign

D. All of the above

Correct Answer: D. All of the above

■ *Listen (English)*

■ *Listen (Hindi)*

Explanation: Pneumocephalus/pneumatocele/intracranial aerocele: The presence of air in the epidural, subdural, or subarachnoid space or within the brain parenchyma or ventricular cavities. CT findings: Sign Observation Mount Fuji Sign Seen in Tension pneumocephalus and has accumulation of air in the frontal region, Frontal lobes are separated and compressed by air under pressure , forming a shape like Mount Fuji {{caption_text}} Air Bubble Sign Small, round areas of low attenuation (dark regions) representing air pockets within cerebrospinal fluid spaces. {{caption_text}} Peaking Sign Frontal lobes are compressed toward each other , but not separated, seen in non tension pneumocephalus. {{caption_text}}



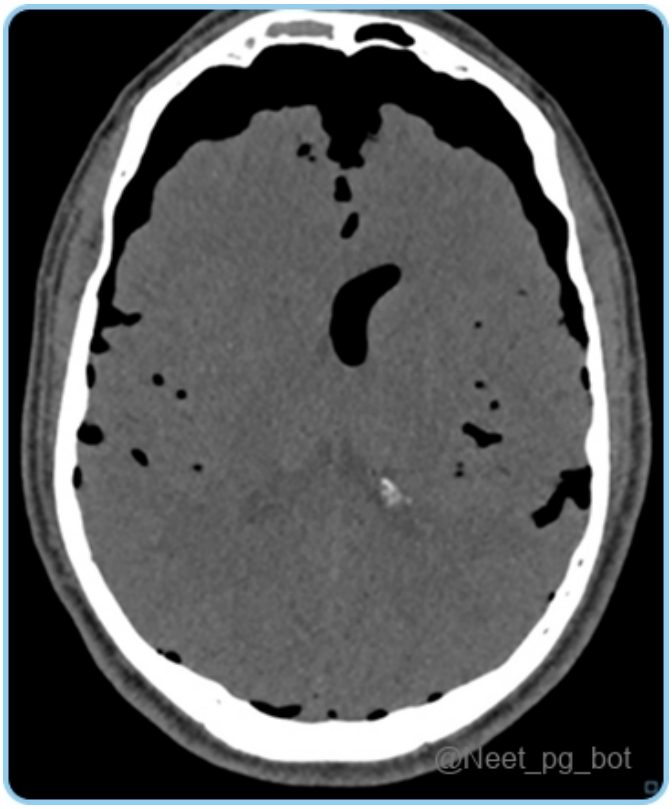



References:

https://www.ncbi.nlm.nih.gov/books/NBK535412/

↑ *Back to this question in Part A*

@Neet_pg_bot

Q12: A 5-year-old is having daily headaches and difficulty copying from the board. He was found to have bitemporal hemianopia, and an MRI of the head was done. Which of the following is not correct about this condition? {{caption_text}} (Q851221)

A. Cystic swelling with calcification

B. Derived from Rathke pouch

C. Compression of optic chiasma

D. Leading infratentorial brain tumor in children

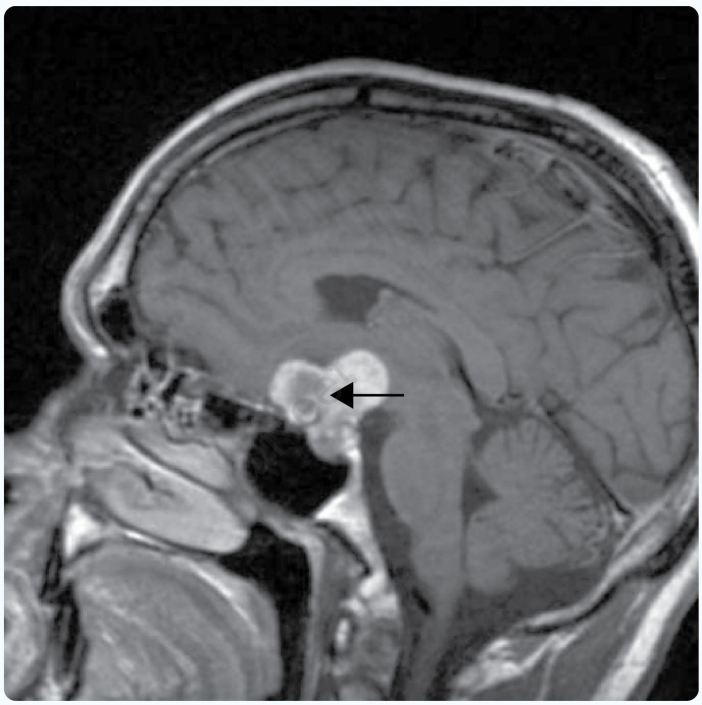

@Neet_pg_bot

Correct Answer: D. Leading infratentorial brain tumor in children

■ *Listen (English)*

■ *Listen (Hindi)*

Explanation: The MRI findings are typical of a craniopharyngioma , a benign, supratentorial tumor seen primarily in children. It commonly causes optic chiasm compression , leading to bitemporal hemianopia .

Craniopharyngiomas arise from Rathke pouch remnants and are often cystic with calcified walls , giving a heterogeneous appearance on imaging. Pediatric tumors are usually of the adamantinomatous type ; adults get the papillary type .

References:

Harrison’s Principles of Internal Medicine, 22nd Edition, Page 3002.

↑ *Back to this question in Part A*

@Neet_pg_bot

Q13: Which of the following is incorrect about variant creutzfeldt-jakob disease? (Q851220)

A. Periodic sharp wave complexes on EEG

B. Cortical ribboning in MRI

C. Increased intensity in the basal ganglia

D. JEV-specific IgM in CSF by MAC■ELISA

Correct Answer: D. JEV-specific IgM in CSF by MAC■ELISA

■ *Listen (English)*

■ *Listen (Hindi)*

Explanation: JEV-specific IgM in CSF by MAC■ELISA is seen in Japanese encephalitis. vCJD is a prion disease that causes progressive neurodegeneration. Usual case presentation is a young person with dementia and myoclonic jerks. Creutzfeldt-Jakob disease (CJD) findings: Electroencephalography (EEG) Periodic sharp wave complexes (PSWC) (Option A ruled out) These can be either lateralized in earlier stages or generalized in later stages. {{caption_text}} MRI findings Increased intensity in the basal ganglia (Option C ruled out) Cortical ribboning (Option B ruled out) {{caption_text}}

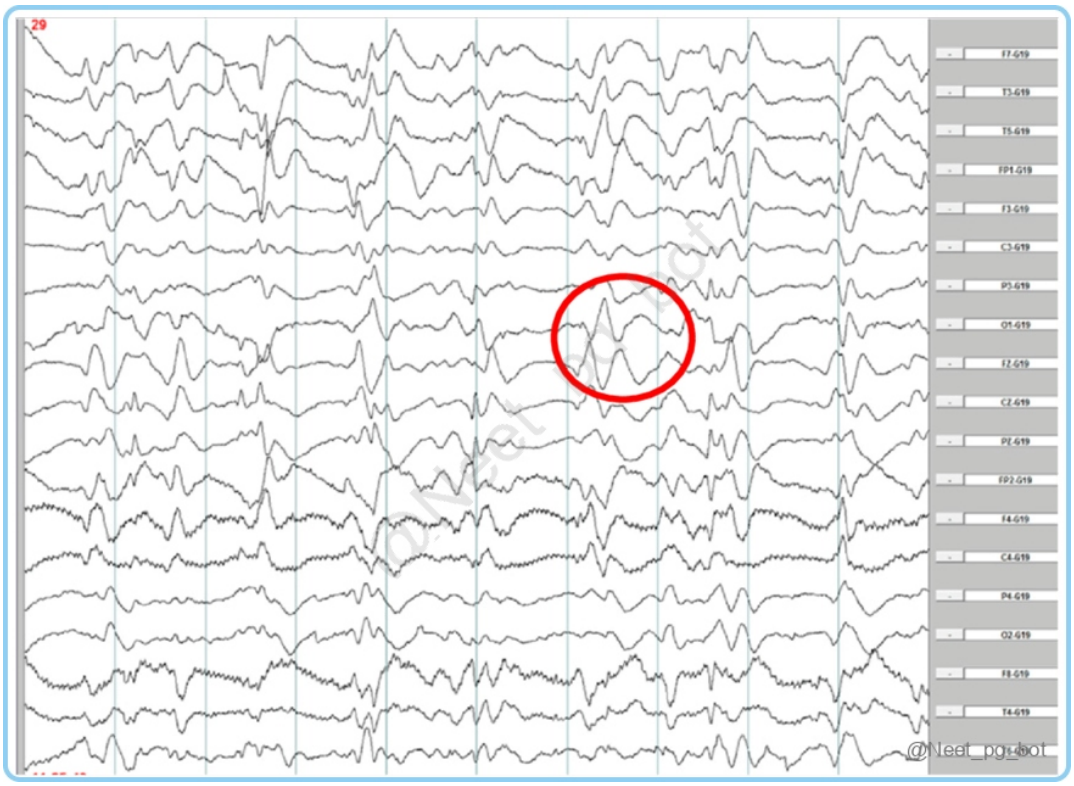

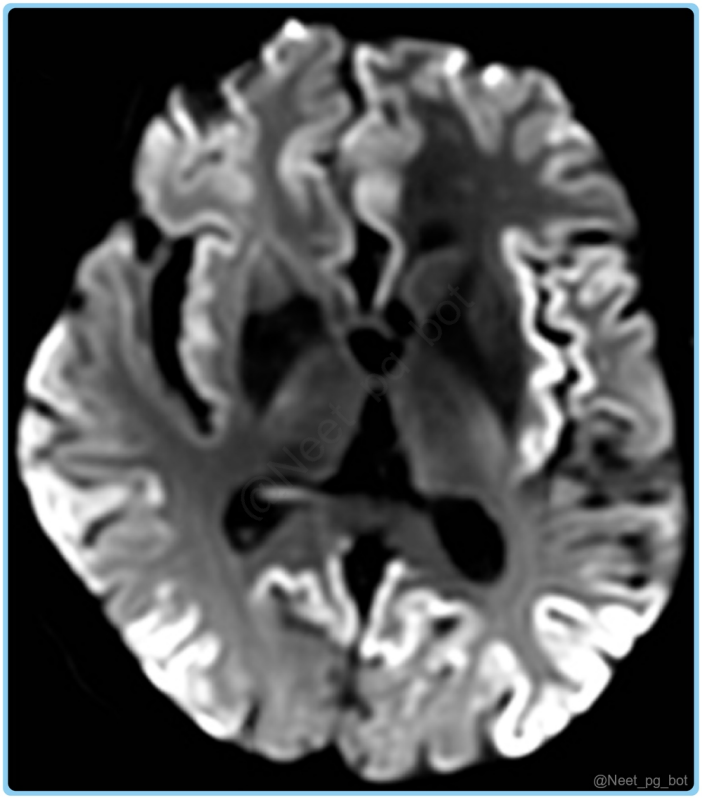

References:

Harrison’s Principles of Internal Medicine, 22nd Edition, Page 3529.

↑ *Back to this question in Part A*

@Neet_pg_bot

Q14: A 35-year-old male presents to the ER after a fall, initially conscious but rapidly deteriorates following a brief lucid interval. The CT image is given below. What is the diagnosis? {{caption_text}} (Q851219)

A. Epidural hematoma

B. Subarachnoid hemorrhage

C. Subdural hematoma

D. Intracerebral hematoma



Correct Answer: A. Epidural hematoma

■ *Listen (English)*

■ *Listen (Hindi)*

Explanation: Given CT shows biconvex mass which is present in epidural hematoma. CT findings: Epidural hematoma Subdural hematoma (Option C ruled out) Biconvex or lens-shaped mass due to the limited ability of

blood to expand within the fixed attachment of the dura to the cranial sutures Does not cross suture lines. {{caption_text}} Typically crescentic in configuration, extending over the cerebral convexity due to the lack of anatomical constraints in the subdural space. {{caption_text}} Extradural Hematoma (Option B): This is synonym for epidural hematoma. While not incorrect in meaning, it is less commonly used in clinical practice, and "epidural" is the more standard term, making A the best answer. Intracerebral Hematoma (Option D): Bleeding within the brain parenchyma itself, often due to hypertension or trauma. On CT, it appears as a hyperdense area within the brain tissue and is not typically associated with a lucid interval or a lens-shaped bleed.

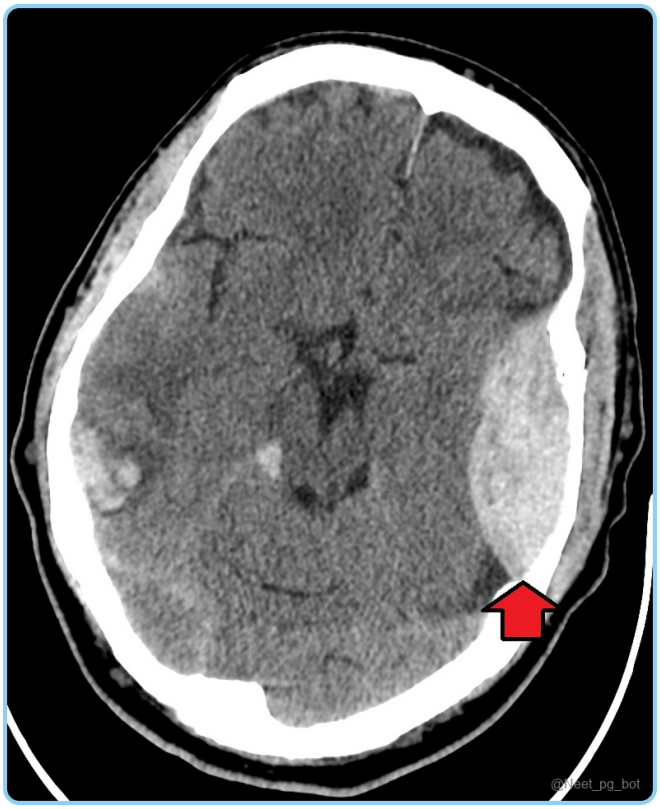



References:

Harrison’s Principles of Internal Medicine, 22nd Edition, Page 3572.

↑ *Back to this question in Part A*

@Neet_pg_bot

Q15: Based on the MRI finding (shown below) , Which of the following criteria and corresponding treatment used in this condition? {{caption_text}} (Q851218)

A. Brighton’s criteria, IV Steroids

B. Brighton’s criteria, IV Immunoglobulin

C. McDonald’s criteria, IV Steroids

D. McDonald’s criteria, IV Immunoglobulin

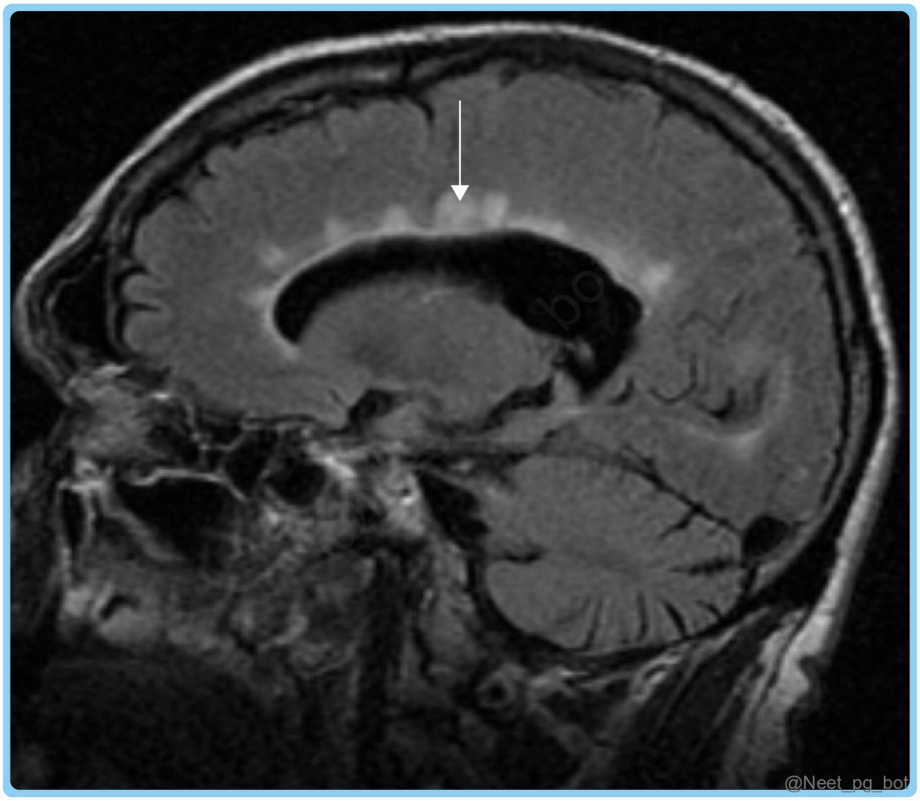

Correct Answer: C. McDonald's criteria, IV Steroids

■ *Listen (English)*

■ *Listen (Hindi)*

Explanation: MRI shows Dawson's fingers , characteristic finding in Multiple Sclerosis (MS) . Criteria used is McDonald's criteria and IV Methylprednisolone (Steroid) is the treatment of choice in MS. Brighton criteria (Option B): Used for Gullaine barre syndrome (GBS) and treatment of choice is IVIg (Immunoglobulin).

References:

Harrison's Principles of Internal Medicine, 22nd Edition, Page 3583.

↑ *Back to this question in Part A*

@Neet_pg_bot

Q16: A 68-year-old male presents to the ER with a sudden onset of headache and right-sided arm weakness that started while brushing his teeth in morning at 7 am. He is known case of hypertension and says he slept on couch last night while watching TV. On examination at 9 am he has irregularly irregular pulse, his arm weakness has improved significantly (power grade 4/5) and he can talk, drink water, chew food and walk normally. NCCT head is normal. Which of the following is the cause of this

presentation? (Q851201)

A. Spontaneous subarachnoid hemorrhage with resorption

B. Cerebral embolism with spontaneous reperfusion

C. Neuronal death due to cerebral anoxia

D. Saturday night palsy due to neurapraxia

Correct Answer: B. Cerebral embolism with spontaneous reperfusion

■ *Listen (English)*

■ *Listen (Hindi)*

Explanation: The patient has had spontaneous resolution of neurological symptoms in 2 hours, implying a transient ischemic attack. He has hypertension and atrial fibrillation as risk factors. The clot in the brain was spontaneously lysed due to the activity of plasmin/tissue plasminogen activator, and he escaped with a mini-stroke/TIA. CT scan of the brain is normal, which rules out any hemorrhagic event. CT can be normal in AIS during the first 6 hours. Spontaneous subarachnoid hemorrhage with resorption (Option A) would have nuchal rigidity, and CT would be abnormal. Neuronal death due to cerebral anoxia (Option C) will cause symptoms to persist or have neurological deterioration. Saturday night palsy due to neurapraxia (Option D) would occur when a person fell asleep on a couch with an overhanging arm and would present with tingling and paresthesias as well.

References:

Harrison’s Principles of Internal Medicine, 22nd Edition, Page 3448.

↑ *Back to this question in Part A*

@Neet_pg_bot

Q17: A 30-year-old female who delivered a male baby via C-section owing to eclampsia developed a sudden onset headache, seizures, visual disturbances, and altered sensorium 2 days following delivery. BP is 180/120 mm Hg. An MRI head is shown. What is the likely diagnosis? {{caption_text}} (Q851216)

A. Reversible cerebral vasoconstriction syndrome (RCVS)

B. CADASIL

C. Post partum TIA

D. Posterior reversible encephalopathy syndrome (PRES)

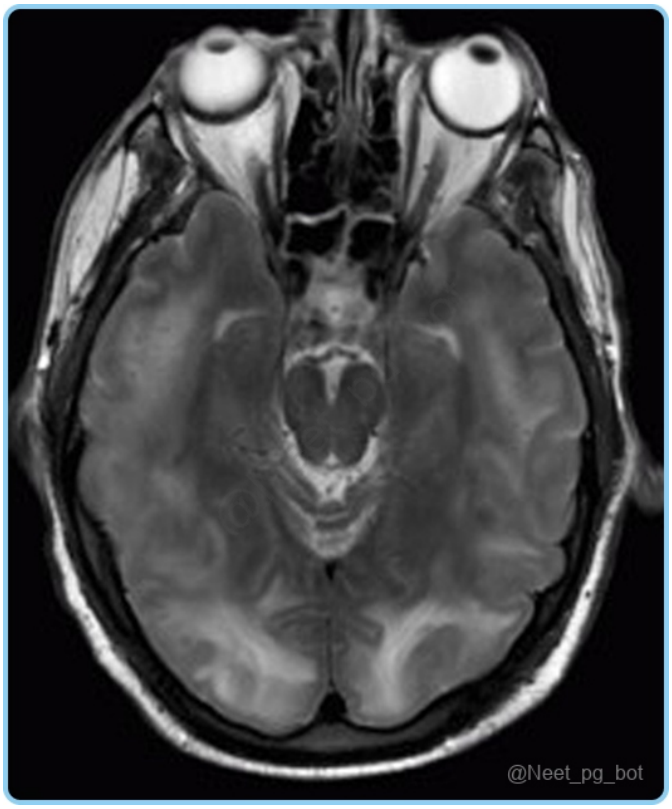

Correct Answer: D. Posterior reversible encephalopathy syndrome (PRES)

■ *Listen (English)*

■ *Listen (Hindi)*

Explanation: Key finding is MRI showing hyperintensities over the occipital lobe in setting of postpartum female with history of eclampsia. Cerebral edema explains the development of sudden onset headache and other focal deficits. With aggressive BP control pateint shows significant improvement and recovers. This is seen in PRES. Reversible cerebral vasoconstriction syndrome (Option A) presents with sudden onset severe thunderclap headache (similar to SAH). It presents with severe new-onset hypertension. Cerebral Angiography reveals segmental narrowing and dilation of cerebral arteries (“ string-of-beads ” appearance), It is non-inflammatory diffuse vasccular changes that are reversible in 1-3 months. CADASIL (Option B): Presents in the 5th-6th decade with stroke-like symptoms (small vessel syndrome). Lack of associated features like Migraine with aura , dementia makes this diagnosis unlikely. Postpartum transient ischemic attack (TIA) (Option C): Usually symptoms last < 1 hour (definition: < 24 hours) , although sudden onset headache with altered mentation makes TIA less likely.

References:

Harrison’s Principles of Internal Medicine, 22nd Edition, Page 2349, 2350.

↑ *Back to this question in Part A*

@Neet_pg_bot

Q18: Which among the following statements is/are false regarding CADASIL ? 1) Autosomal Dominant inheritance 2) Predominantly causes Large-vessel stroke 3) Characteristic symptom is Migraine with aura 4) Notch-3 gene is involved (Q851215)

A. 2

B. 1,3

C. 1,2

D. 2,3

Correct Answer: A. 2

■ *Listen (English)*

■ *Listen (Hindi)*

Explanation: CADASIL - Cerebral Autosomal Dominant Arteriopathy with Subcortical Infarcts and Leukoencephalopathy is an inherited disorder characterized by small-vessel strokes. CADASIL (Cerebral Autosomal Dominant Arteriopathy with Subcortical Infarcts and Leukoencephalopathy) Description Inherited disorder characterized by small-vessel strokes (Statement-2) Etio- pathogenesis Notch-3 gene (Statement-4) Autosomal Dominant inheritance (Statement-1) Notch-3 gene regulates Epidermal growth factor (EGF) Clinical features Age: 4th-5th decade Small-vessel stroke Progressive dementia Migraine with aura: characteristic feature (Statement-3) Diagnosis MRI: Extensive symmetric white matter changes over anterior temporal lobe

References:

Harrison’s Principles of Internal Medicine, 22nd Edition, Page 3448.

↑ *Back to this question in Part A*

@Neet_pg_bot

Q19: Child presented with reccurent TIA events. Cerebral angiography was performed. Which among the following is false regarding this condition? {{caption_text}} (Q851214)

A. Involves occlusion of predominantly large arteries

B. Associated with vascular inflammation

C. Anticoagulation is contraindicated

D. Can present in adults with brain hemorrhage

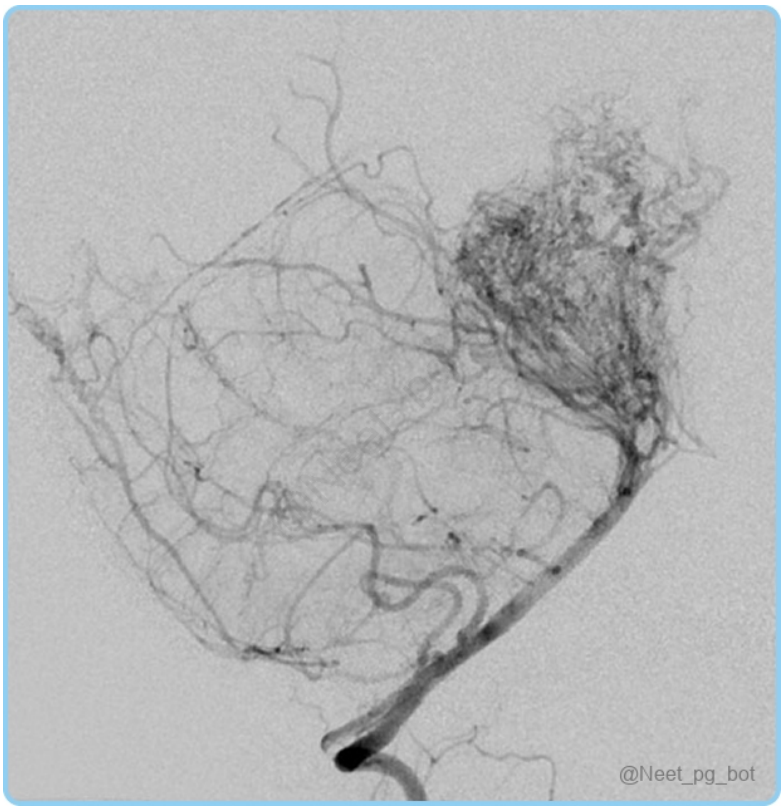

Correct Answer: B. Associated with vascular inflammation

■ *Listen (English)*

■ *Listen (Hindi)*

Explanation: Cerebral angiography shows a “Puff of smoke” appearance which is suggestive of Moyamoya disease . Moyamoya disease is a rare “Non-Inflammatory” neurological disorder characterized by occlusion predominantly involving internal carotid arteries. It can present with both ischaemic - secondary to occlusion (in pediatric age group) and hemorrhagic features - secondary to burst of collaterals (in adult age group) Moyamoya disease Description Isolated chronic, non-inflammatory (Option B) usually bilateral vasculopathy of undetermined etiology characterized by progressive narrowing of large arteries (Option A) - distal part of internal carotid artery (ICA) , stem of middle cerebral (MCA) and anterior cerebral artery (ACA) Management Medical Management: Aspirin 50-100mg: for maintenance Anticoagulation: is usually contraindicated (Option C) as risk of collaterals induced hemorrhage can occur. Surgical Management: Revascularization procedures usually using superficial temporal artery bypass may be beneficial.

References:

Harrison’s Principles of Internal Medicine, 22nd Edition, Page 3447.

↑ *Back to this question in Part A*

@Neet_pg_bot

Q20: A 35 year old woman presents with sudden onset headache, seizures and focal neurological deficits. BP on admission is 160/100 mm Hg. She has a history of oral contraceptive use. CECT head is shown below. What is the most appropriate initial treatment for this patient? {{caption_text}} (Q851213)

A. Thrombolysis

B. Heparin

C. Oral warfarin immediately

D. Thrombectomy

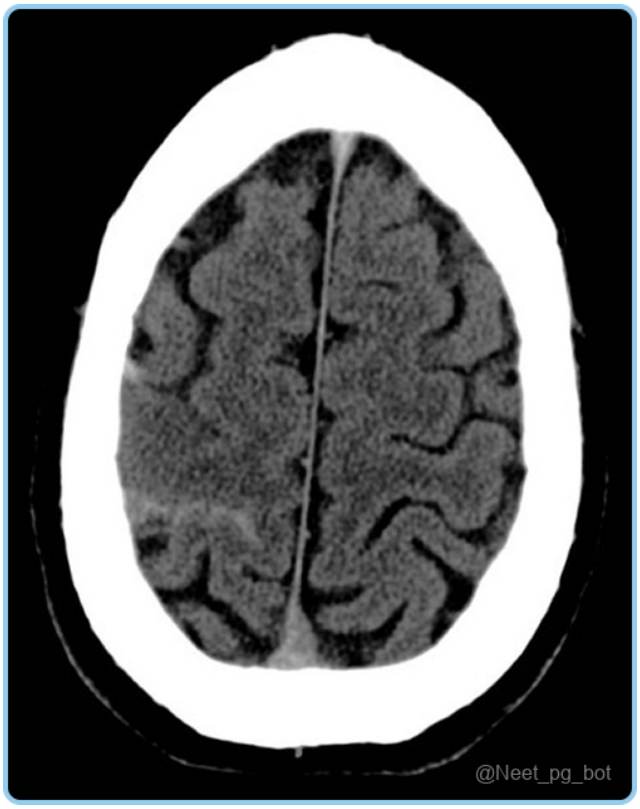

Correct Answer: B. Heparin

■ *Listen (English)*

■ *Listen (Hindi)*

Explanation: Patient is having hypercoagulable state due to use of OCP and CT head shows empty delta sign. It indicates involvement of superior sagittal sinus where contrast outlines a triangular filling defect due to a thrombus. The obstruction of superior sagittal sinus will cause raised ICP as absorption of CSF will be affected. The resultant cerebral edema can explain seizures These features are suggestive of cerebral venous thrombosis. Immediate anticoagulation with heparin is the first-line treatment, even in the presence of hemorrhagic infarcts. Endovascular thrombolysis (Option A) : Reserved for cases where anticoagulation fails or is contraindicated. Oral warfarin immediately (Option C): Warfarin is used after heparin therapy, not as the initial treatment (effect takes a

few days to develop so cannot be used for immediate anticoagulation, also it increases coagulation initially). Blood pressure management for hypotension (Option D): Hypotension is not a common trigger for CVT and is not the primary treatment.

References:

Harrison's Principles of Internal Medicine, 22nd Edition, Page 3447.

↑ *Back to this question in Part A*

@Neet_pg_bot

Q21: As an intern in the medicine ward, you are asked to guide the nursing staff about the various supportive care measures to improve the outcome in of Acute ischemic stroke patients who are managed with thrombolysis. Which among the following will you not advise? (Q851212)

A. Monitor vitals and place in head end elevated position

B. Perform urinary catheterisation for input output charting

C. Pneumatic compression stockings to prevent deep vein thrombosis.

D. Give antipyretics to patients with fever to prevent infarct expansion

Correct Answer: B. Perform urinary catheterisation for input output charting

■ *Listen (English)*

■ *Listen (Hindi)*

Explanation: Routine urinary catheterisation is not recommended due to increased risk of infection and urethral trauma ; it should be done only if clinically indicated. Bleeding Risk: Thrombolytic agents (like tPA or TNK) induce a systemic lytic state. Inserting a catheter is an invasive procedure that can cause urethral trauma and significant mucosal bleeding . Infection Risk: Catheters increase the risk of Urinary Tract Infections (UTIs), which can lead to post-stroke fever and worsen the neurological outcome. It is recommended only in cases of acute urinary retention or incontinence threatening to pressure areas . Monitor vitals and place in head end elevated position (Option A) helps prevent aspiration and cerebral edema. Pneumatic compression stockings (Option C) are advised to prevent DVT in immobile stroke patients. Give antipyretics to patients with fever (Option D) helps reduce infarct expansion and metabolic stress.

References:

Harrison's Principles of Internal Medicine, 22nd Edition, Page 3441.

↑ *Back to this question in Part A*

@Neet_pg_bot

Q22: Which of the following is a contraindication to thrombolysis in a patient with acute ischemic stroke? (Q851211)

A. CT showing ischemic changes in > 1/3 MCA territory

B. CT scan showing Hyperdense MCA sign

C. Large Hematochezia episode 10 days ago requiring banding

D. Recent epistaxis requiring nasal packing

Correct Answer: A. CT showing ischemic changes in > 1/3 MCA territory

■ *Listen (English)*

■ *Listen (Hindi)*

Explanation: Extensive early ischemic changes involving more than one-third of the MCA territory on CT scan are a major contraindication to thrombolysis. This finding indicates a large infarct core with a high risk of hemorrhagic transformation if alteplase is administered. Because the benefit of thrombolysis is low and the bleeding risk is very high, thrombolysis is not recommended in such patients. Hence, this is a definite absolute contraindication. Incorrect Options: CT scan showing Hyperdense MCA sign (Option B): This indicates acute thrombus in MCA, which actually supports the diagnosis of acute ischemic stroke and is NOT a contraindication to thrombolysis. It often predicts a good response to early reperfusion. Large hematochezia 10 days ago requiring banding (Option C): Although GI bleeding is a relative concern, thrombolysis is contraindicated only if there has been active internal bleeding within the last 21 days. A treated episode 10 days ago with no ongoing bleeding is considered a relative, not absolute, contraindication. Recent epistaxis requiring nasal packing (Option D): Epistaxis especially if controlled with packing is not an absolute contraindication. Once the bleeding has stopped, thrombolysis can be considered. Only active, uncontrolled bleeding is a contraindication.

References:

Harrison’s Principles of Internal Medicine, 22nd Edition, Page 3441.

↑ *Back to this question in Part A*

@Neet_pg_bot

Q23: A 58 year old T2DM male with hypertension presents to the emergency department 2 hours after developing sudden onset of right sided arm weakness and face asymetry. His blood pressure is 170/90 mmHg, and a NCCT head shows no hemorrhage. He is on metformin, metoprolol and atorvastatin. What is the most appropriate initial treatment for this patient? (Q851210)

A. Thrombolysis with alteplase

B. Antiplatelet therapy with aspirin

C. Mechanical thrombectomy

D. Immediate blood pressure reduction followed by Alteplase

Correct Answer: A. Thrombolysis with alteplase

■ *Listen (English)*

■ *Listen (Hindi)*

Explanation: The patient is presenting with an acute ischemic stroke within the 4.5-hour window (sudden onset focal deficits, NCCT negative for hemorrhage). Intravenous alteplase (thrombolysis) is the standard initial treatment to restore cerebral perfusion if there are no contraindications. Antiplatelet therapy with aspirin (Option B) is indicated after thrombolysis or if thrombolysis is contraindicated, not as first-line within the window. Mechanical thrombectomy (Option C) is reserved for large vessel occlusions and can be adjunctive to thrombolysis. Immediate blood pressure reduction followed by alteplase (Option D) is incorrect; BP should only be lowered if >185/110 mmHg before thrombolysis.

References:

Harrison’s Principles of Internal Medicine, 22nd Edition, Page 3441.

↑ *Back to this question in Part A*

@Neet_pg_bot

Q24: A 50 year old male patient came to the ER with complaints of headache, blurring of vision and right sided hemiparesis for 2 hours. He is a known case of diabetes mellitus and hypertension. On examination pulse is 92/min with BP 190/110 mm Hg. What is the most appropriate statement regarding management of this patient? {{caption_text}} (Q851209)

A. Blood pressure of the patient should be reduced to <140/90 with nicardipine

B. The head end of the patient's bed should be flat to prevent coning of the brain.

C. Immediate intravenous thrombolysis is recommended since the patient is in window period

D. Urgent lowering of BP with nicardipine followed by thrombolysis since patient is in window period



Correct Answer: A. Blood pressure of the patient should be reduced to <140/90 with nicardipine

■ *Listen (English)*

■ *Listen (Hindi)*

Explanation: The patient is having an intracerebral hemorrhage due to hypertensive crisis. Hyperdensity is noted in the putamen and affects the internal capsule, causing a motor deficit. According to current guidelines, BP of these patients should be aggressively lowered to < 140/90 mm Hg to reduce the chances of CNS bleeding. Head end should be elevated, not flat (Option B) to reduce ICP. Immediate intravenous thrombolysis is not indicated (Option C) because thrombolysis is contraindicated in hemorrhagic stroke. Urgent BP lowering followed by thrombolysis (Option D) is incorrect as thrombolysis is contraindicated in hemorrhagic stroke.

References:

Harrison's Principles of Internal Medicine, 22nd Edition, Page 3453.

↑ *Back to this question in Part A*

@Neet_pg_bot

Q25: A 65 year old male presents to the emergency department with a sudden onset of right sided weakness, slurred speech and facial drooping for the past 1 hour. NCCT head is normal. What is the appropriate scoring done to confirm the diagnosis of this patient? (Q851208)

A. ABCD2

B. CHADS2VASc

C. NIHSS

D. Agatson

Correct Answer: C. NIHSS

■ *Listen (English)*

■ *Listen (Hindi)*

Explanation: The National Institute of Health Stroke Scale (NIHSS) is used to confirm the diagnosis of stroke . It has 15 parameters to do a structured neurological examination with a score ranging from 0 (Normal) to 42 (Severe stroke). Components (11): Level of consciousness, gaze, visual fields, facial palsy, motor strength (arms/legs), limb ataxia, sensory, language, dysarthria, and extinction/inattention. Score > 5 indicates need for intervention in the form of either thrombolysis or thrombectomy. ABCD2 (Option A): This is used to predict the risk of a future stroke following a TIA (Transient Ischemic Attack). Since this patient has current, objective neurological deficits (weakness, slurred speech), he is having an active stroke, not just a TIA. Components: A ge (≥ 60), B lood Pressure (≥ 140/90), C linical features (weakness/speech), D uration of symptoms, and D iabetes. Scoring: 0 -7. A score ≥ 4 indicates moderate-to-high risk, usually requiring inpatient workup. CHADS2VASc (Option B): This score is used specifically for patients with Atrial Fibrillation to determine their risk of thromboembolism and the need for long-term anticoagulation (Warfarin/DOACs). It is not a diagnostic tool for an acute stroke in progress. Components: C HF, H ypertension, A ge (≥ 75 is 2 pts), D iabetes, S troke/TIA history (2 pts), V ascular disease, A ge (65–74), and S ex C ategory (Female). Agatson (Option D): This is a tool used in radiology to quantify coronary artery calcium on a CT scan to assess the risk of coronary artery disease (heart attacks). It has no role in acute stroke management. Components: Based on the area and density of calcium deposits in the coronary arteries. Scoring: 0: No identifiable disease. 1–100: Mild plaque. > 400: Extensive plaque (high risk of Heart Attack).

References:

https://www.ninds.nih.gov/health-information/stroke/assess-and-treat/nih-stroke-scale

↑ *Back to this question in Part A*

@Neet_pg_bot

Q26: A 70 year old woman presents to the ER with sudden-onset slurred speech and right-sided facial weakness that resolved after 90 minutes. The resident has asked you to calculate ABCD2 score. Which of the following is not a component of this score (Q851207)

A. Blood pressure

B. History of stroke

C. Diabetes mellitus

D. Duration of symptoms

Correct Answer: B. History of stroke

■ *Listen (English)*

■ *Listen (Hindi)*

Explanation: The ABCD² score is a clinical tool used to predict the risk of stroke following a transient ischemic attack (TIA). It includes clinical features of the TIA , not the past history of stroke. It helps stratify patients into different risk categories to determine the likelihood of having a stroke in the short term, usually within 48 hours to 7 days after a TIA event. The score is based on five clinical parameters: Age: ≥ 60 years = 1 point Blood Pressure: Systolic ≥ 140 mmHg or diastolic ≥ 90 mmHg = 1 point Clinical Features: Unilateral weakness = 2 points Speech disturbance without weakness = 1 point Duration of Symptoms: ≥ 60 minutes = 2 points 10-59 minutes = 1 point Diabetes: History of diabetes = 1 point ABCD2 Score Interpretation: < 4 points: Low risk of stroke (1% risk of stroke within 2 days) 4-5 points: Moderate risk of stroke (4% risk of stroke within 2 days) > 5 points: High risk of stroke (8% risk of stroke within 2 days)

References:

Harrison’s Principles of Internal Medicine, 22nd Edition, Page 3448.

↑ *Back to this question in Part A*

@Neet_pg_bot

Q27: A 45-year-old man with hypertension presents to the ER at 6 am in morning with excruciating headache and sudden onset face, arm and leg weakness. On examination GCS is 8 and blood pressure is 220/110 mmHg. NCCT head is shown. Cause of this presentation is? {{caption_text}} (Q851206)

A. Ruptured saccular aneurysm

B. Rupture of penetrating arteries supplying internal capsule

C. Dural sinus thrombosis

D. Posterior reversible encephalopathy syndrome



Correct Answer: B. Rupture of penetrating arteries supplying internal capsule

■ *Listen (English)*

■ *Listen (Hindi)*

Explanation: This patient's presentation is suggestive of a hemorrhagic stroke, with NCCT head showing hyperdensity involving the Putamen. This is most commonly associated with long-standing hypertension, leading to rupture of penetrating arteries supplying the internal capsule. Ruptured saccular aneurysm (Option A) will have nuchal rigidity. Dural sinus thrombosis (Option C) is seen in a setting of a hypercoagulable state, while our case has hypertension. Posterior reversible encephalopathy syndrome (Option D) will cause cerebral edema involving the occipital lobes.

References:

Harrison’s Principles of Internal Medicine, 22nd Edition, Page 3454.

↑ *Back to this question in Part A*

@Neet_pg_bot

Q28: A 60-year-old man is brought to ER with sudden onset of right-sided arm weakness and difficulty speaking. His gaze is deviated to the left, and he has a right homonymous hemianopia. Which of the following is the most likely location of the thrombus causing this patient's symptoms? (Q851203)

A. Left MCA, Non dominant hemisphere

B. Left MCA, Dominant hemisphere

C. Left PCA, Dominant hemisphere

D. Right PCA, Non Dominant hemisphere

Correct Answer: B. Left MCA, Dominant hemisphere

■ *Listen (English)*

■ *Listen (Hindi)*

Explanation: The patient presents with a left MCA territory stroke causing right-sided arm weakness and affecting the dominant hemisphere . That explains Broca's aphasia. In a cortical stroke, the patient looks to the side of the lesion; hence, the patient is looking to the left. Reason is a destructive lesion in the left frontal eye field Involvement of left optic radiations (MCA supplies parietal and temporal lobes) explains the right-sided homonymous hemianopia Left MCA, Non-dominant hemisphere (Option A) will present with right-sided motor and sensory deficits and right homonymous hemianopia, without aphasia . Left PCA, Dominant hemisphere (Option C) will present with Alexia without agraphia. Right PCA, Non-Dominant hemisphere (Option D) will cause spatial neglect, map-reading issues and prosopagnosia.

References:

Harrison’s Principles of Internal Medicine, 22nd Edition, Page 202, 3429.

↑ *Back to this question in Part A*

@Neet_pg_bot

Q29: A 60 year old man presents with sudden onset right face deviation and arm weakness for last 8 hours. BP on admission is 185/110 mm Hg. NCCT head shows hypodensity in parietal lobe and CTA shows clot in M2 segment of MCA. Which is the best intervention for this patient? (Q851202)

A. Endovascular coiling

B. CT perfusion with endovascular thrombectomy

C. Lower BP with Nicardipine followed by Tenecteplase

D. Lower BP with Nicardipine followed by Aspirin loading 325 mg

Correct Answer: B. CT perfusion with endovascular thrombectomy

■ *Listen (English)*

■ *Listen (Hindi)*

Explanation: The clinical presentation of Acute ischemic stroke with symptoms persisting for > 6 hours . Hence, CT Perfusion will be done, followed by thrombectomy to remove the clot occluding the M2 segment of MCA. The patient is outside the window period of thrombolysis of 4.5 hours. Endovascular coiling (Option A) is used for the treatment of SAH. Lower BP with Nicardipine followed by Tenecteplase (Option C) is done if thrombolysis is scheduled. Lower BP with Nicardipine followed by Aspirin loading 325 mg (Option D) is wrong as aspirin is started after 24-48 hours of admission in AIS.

References:

Harrison’s Principles of Internal Medicine, 22nd Edition, Page 3440.

↑ *Back to this question in Part A*

@Neet_pg_bot

• [07_Neurology] 051 Guillian Barre Syndrome And Alzheimer S Disease

« Back to Folder Directory

[07_Neurology] 051 Guillian Barre Syndrome And Alzheimer S Disease — Quick Jump

Q1 (p. 2291) *Q2 (p. 2292)* *Q3 (p. 2292)* *Q4 (p. 2293)* *Q5 (p. 2294)* *Q6 (p. 2294)*
Q7 (p. 2295) *Q8 (p. 2296)* *Q9 (p. 2297)* *Q10 (p. 2297)* *Q11 (p. 2298)* *Q12 (p. 2299)*
Q13 (p. 2300) *Q14 (p. 2301)*

Q1: A 30-year-old man from Pune presents with recurrent falls in stairs from past 3 days with leg muscle weakness and root pains in both legs. On examination flaccid paralysis is noted in both legs with arreflexia. Sensory examination shows distinct level below T10 where radicular pain is being felt. Bladder was catheterized due to urinary incontience. MRI spine shows inflammation of spinal cord. He had a diarrheal episodes 2 weeks ago. Diagnosis is? (Q851492)

A. Acute inflammatory demyelinating polyneuropathy

B. Miller Fisher syndorme

C. Transverse Myelitis

D. Chronic inflammatory demyelinating polyneuropathy

Correct Answer: C. Transverse Myelitis

■ *Listen (English)*

■ *Listen (Hindi)*

Explanation: This patient has acute flaccid paraparesis with a clear sensory level (below T10) and bladder involvement, suggesting a lesion in the spinal cord rather than the peripheral nerves. The presence of a sensory level and spinal cord inflammation on MRI confirms the diagnosis of transverse myelitis. AIDP (Guillain-Barré Syndrome) (Option A) also presents with ascending flaccid paralysis and areflexia; it lacks a sensory level, and bladder/bowel involvement is rare. Miller Fisher syndrome (Option B) has a triad of ophthalmoplegia, areflexia without weakness and ataxia. CIDP (Option D) is a chronic, progressive form of demyelinating polyneuropathy where LMNL features evolve over > 9 weeks.

References:

Harrison's Principles of Internal Medicine, 22nd Edition, Page 3565.

↑ *Back to this question in Part A*

@Neet_pg_bot

Q2: Which of the following is not correct about GBS? (Q851493)

A. Prolonged F wave latency

B. Diaphragmatic paralysis

C. Pseudo-bulbar weakness may cause difficulty in handling secretions

D. Proprioception loss

Correct Answer: C. Pseudo-bulbar weakness may cause difficulty in handling secretions

■ *Listen (English)*

■ *Listen (Hindi)*

Explanation: GBS is an LMN lesion and has bulbar weakness, causing difficulty in handling oral secretions that may mimic brainstem ischemia. Pseudo-bulbar palsy implies a UMN lesion. Brighton criteria for GBS mention NCV shows Prolonged F-waves (Option A) + slowed conduction + conduction block in demyelinating GBS. Diaphragmatic paralysis (Option B) can occur due to cervical spine demyelination Proprioception loss (Option D) in GBS occurs due to demyelination of large-diameter sensory fibres in dorsal roots, disrupting input to the posterior column pathway

References:

Harrison's Principles of Internal Medicine, 22nd Edition, Page 3617.

↑ *Back to this question in Part A*

@Neet_pg_bot

Q3: Which of the following statements is incorrect regarding the types of Guillain-Barré syndrome? (Q851494)

A. AIDP is the most common form in adults

B. AMSAN has best prognosis amongst all variants

C. AMAN involves axonal degeneration in children and young adults

D. Miller-Fisher syndrome is associated with anti-GQ1b antibodies

Correct Answer: B. AMSAN has best prognosis amongst all variants

■ *Listen (English)*

■ *Listen (Hindi)*

Explanation: AMSAN typically has a worse prognosis than AMAN Type Features Neural Target Electrodiagnostic Study AIDP (Acute Inflammatory Demyelinating Polyneuropathy) Most common in adults (Option A); Rapid recovery; IgG Anti-GM1 a/b Schwann cells Demyelination AMAN (Acute Motor Axonal Neuropathy) Seen in children & young adults (Option C); Poor prognosis; IgG Anti-GM1 a/b Nodes of Ranvier Axonal degeneration AMSAN (Acute Motor Sensory Axonal Neuropathy) Uncommon; Seen in adults; Worst prognosis; IgG Anti-GM1 a/b Nodes of Ranvier Axonal degeneration Miller Fisher Syndrome Triad: Ophthalmoplegia, Areflexia, Ataxia; Seen in 5% cases; Anti-GQ1b (Option D) Identical to AIDP Demyelination or axonal degeneration

References:

Harrison's Principles of Internal Medicine, 22nd Edition, Page 3619.

↑ *Back to this question in Part A*

@Neet_pg_bot

Q4: A 35-year-old man presents with a 2-day history of progressive weakness that started in his legs after returning from his international trip. Today he cannot get up from bed and is having hand weakness. On examination, distal arreflexia is noted with power grade 1/5 for muscles at all joints of lower limbs and 3/5 for upper limbs. CSF study shows cytoalbuminological dissociation. Which criteria are used for diagosis of this condition? (Q851495)

A. Brighton

B. Macdonald'

C. Adam and Victor

D. Dubois

Correct Answer: A. Brighton

■ *Listen (English)*

■ *Listen (Hindi)*

Explanation: Brighton criteria are used for the diagnosis of GBS. These criteria grade diagnostic certainty from Level 1 (highest) to Level 4 based on clinical findings, CSF analysis (albuminocytologic dissociation), and electrophysiological testing. Macdonald' (Option B) is used for multiple sclerosis. Adam and Victor (Option C) is used for Normal pressure hydrocephalus. Dubois (Option D) is used for Alzheimer's disease (Clinical + biomarker-based diagnosis).

References:

Harrison's Principles of Internal Medicine, 22nd Edition, Page 3621.

↑ *Back to this question in Part A*

@Neet_pg_bot

Q5: A 40-year-old man presents with a one-day history of progressive weakness, initially localised to his legs but now involving the arms. He tells about the inability to button his shirt along with fatigue during minimal exertion. On examination, there is flaccid quadriparesis with absent deep tendon reflexes. What is the next best step in the management of this patient? (Q851496)

A. Nerve conduction studies

B. Lumbar puncture for cytoalbuminological dissociation

C. Anti GM1 and Anti GQ1 antibody titers

D. PCR stool for C. jejuni

Correct Answer: A. Nerve conduction studies

■ *Listen (English)*

■ *Listen (Hindi)*

Explanation: Nerve conduction studies are the next best step to confirm Guillain-Barré syndrome , showing demyelination or axonal neuropathy. Lumbar puncture for cytoalbuminological dissociation (Option B): Typically done after 1 week, as CSF protein elevation develops later. Anti-GM1 and Anti-GQ1 antibody titers (Option C): Supportive tests, not initial diagnostic step. PCR stool for C. jejuni (Option D): Identifies antecedent infection, not useful for immediate diagnosis.

References:

Harrison's Principles of Internal Medicine, 22nd Edition, Page 3619.

↑ *Back to this question in Part A*

@Neet_pg_bot

Q6: A 50-year-old man presents with difficulty in walking due to imbalance following a recent viral illness. He also reports double vision. Examination reveals bilateral ptosis, ophthalmoplegia, and areflexia. He has a history of alcohol use but no diabetes

or hypertension.What is the most appropriate treatment? (Q851497)

A. Intravenous immunoglobulin

B. Corticosteroids

C. Thiamine with dextrose

D. Dextrose

Correct Answer: A. Intravenous immunoglobulin

■ *Listen (English)*

■ *Listen (Hindi)*

Explanation: The diagnosis is Miller-Fisher Syndrome (a variant of GBS), characterized by the classic triad of ophthalmoplegia (ptosis, double vision), ataxia (lack of coordination), and areflexia (absence of tendon reflexes). The cranial nerve involved is the 3rd nerve. IVIG is the first-line treatment, targeting the underlying autoimmune process. Thiamine with dextrose (Option C) is used for Wernicke encephalopathy, where the patient has global confusion, ophthalmoplegia and ataxia. The cranial nerve involved in the 6th nerve.

References:

Harrison's Principles of Internal Medicine, 22nd Edition, Page 3620.
https://www.ncbi.nlm.nih.gov/books/NBK507717/

↑ *Back to this question in Part A*

@Neet_pg_bot

Q7: A 20-year-old female presents with acute dysphagia, particularly for liquids, and nasal regurgitation, following a recent dengue fever. Examination reveals bilateral facial weakness and areflexia in the upper limbs. Brain and cervical spine MRI is normal, while cerebrospinal fluid analysis shows elevated protein with normal opening pressure, cells and glucose. What is the most likely diagnosis? (Q851498)

A. Acute pharyngeal cervicobrachial neuropathy

B. Miller-Fisher syndrome

C. Multiple sclerosis

D. Botulism

Correct Answer: A. Acute pharyngeal cervicobrachial neuropathy

■ *Listen (English)*

■ *Listen (Hindi)*

Explanation: The diagnosis is Acute pharyngeal cervicobrachial Neuropathy . This condition is characterized by oropharyngeal and cervicobrachial weakness, often with areflexia in the upper limbs. It is triggered by viral infections like dengue. The normal MRI findings and elevated protein in cerebrospinal fluid further support this diagnosis. Associated with anti-GT1a antibodies Miller Fisher syndrome (Option B): typically presents with a triad of ophthalmoplegia, ataxia, and areflexia. Multiple sclerosis (Option C) usually shows distinct clinical features like visual disturbances and sensory deficits, and MRI would have plaques Botulism (Option D): the specific findings of elevated protein with normal glucose in the CSF suggest PCB over botulism.

References:

Harrison's Principles of Internal Medicine, 22nd Edition, Page 3619.

↑ *Back to this question in Part A*

@Neet_pg_bot

Q8: A 75-year-old man presents with progressive memory loss, difficulty in performing daily activities, and mood changes. His family notes that he often repeats the same questions and becomes easily confused. Neurological examination reveals no focal deficits, but cognitive testing indicates significant impairment in memory and language skills. What is the possible neurotransmitter status for this condition? (Q851499)

A. Increased Acetylcholine, decreased Norepinephrine, decreased Serotonin

B. Decreased Acetylcholine, decreased Norepinephrine, decreased Serotonin

C. Normal Acetylcholine, increased Norepinephrine, normal Serotonin

D. Increased Acetylcholine, increased Norepinephrine, decreased Serotonin

Correct Answer: B. Decreased Acetylcholine, decreased Norepinephrine, decreased Serotonin

■ *Listen (English)*

■ *Listen (Hindi)*

Explanation: The diagnosis is Alzheimer's disease, characterized by progressive memory loss and cognitive decline. There is a significant decrease in acetylcholine levels (hence, AchE inhibitor drugs are preferred for the treatment to increase Ach levels), which is critical for memory and learning. Additionally, norepinephrine and serotonin levels are often decreased. Neurotransmitters involved in Alzheimer’s Neurotransmitter Location of Synthesis Decreased ACh Nucleus basalis of Meynert (forebrain) Decreased Norepinephrine Locus coeruleus (pons) Decreased Serotonin Dorsal raphe (brainstem)

References:

Harrison's Principles of Internal Medicine, 22nd Edition, Page 3479.

↑ *Back to this question in Part A*

@Neet_pg_bot

Q9: A 30-year-old man with Down syndrome is being monitored for cognitive decline due to his increased risk for Alzheimer's disease. Why is this patient at a higher risk for developing Alzheimer's disease? (Q851500)

A. Presenilin 1 gene mutation

B. Overexpression of the APP gene

C. Mutation in the ApoE4 gene

D. Release of pro-inflammatory cytokines and promoting insulin resistance

Correct Answer: B. Overexpression of the APP gene

■ *Listen (English)*

■ *Listen (Hindi)*

Explanation: Individuals with Down syndrome have trisomy 21, meaning they have an extra copy of chromosome 21. With the extra copy of chromosome 21, individuals with Down syndrome have overexpression of the (Amyloid Precursor Protein) APP gene, leading to increased production of amyloid-beta (A-beta). This excess amyloid-beta tends to form amyloid plaques in the brain, a hallmark of Alzheimer's disease. Presenilin 1 gene mutation (Option A): Causes familial early-onset Alzheimer’s, not associated with Down syndrome. Mutation in the ApoE4 gene (Option C): Linked to sporadic late-onset Alzheimer’s disease. Release of pro-inflammatory cytokines and promoting insulin resistance (Option D): Seen in Alzheimer’s related to chronic inflammation or metabolic syndrome, not trisomy 21.

References:

Harrison's Principles of Internal Medicine, 22nd Edition, Page 3479.

↑ *Back to this question in Part A*

@Neet_pg_bot

Q10: Which of the following neurodegenerative disorders is not classified as a tauopathy? (Q851501)

A. Alzheimer’s disease

B. Punch-drunk syndrome

C. Parkinson’s disease

D. Pick's disease

Correct Answer: C. Parkinson’s disease

■ *Listen (English)*

■ *Listen (Hindi)*

Explanation: Parkinson’s disease is not classified as a tauopathy. It is primarily associated with Lewy bodies, composed mainly of misfolded alpha-synuclein, not tau. Tauopathy (abnormal hyperphosphorylation of tau protein accumulation): Pick- CAP-Down P ick disease C hronic traumatic encephalopathy / Punch drunk and C orticobasal syndrome A lzeihmer's disease P rogressive supranuclear gaze palsy D own syndrome

References:

https://pubmed.ncbi.nlm.nih.gov/28987182/

↑ *Back to this question in Part A*

@Neet_pg_bot

Q11: A 60-year-old woman has been diagnosed with early-stage Alzheimer's disease. Her husband reports that she frequently struggles to remember recent events and has begun to repeat herself in conversations. Additionally, she has difficulty managing her finances and has gotten lost while driving to familiar places. Despite these issues, she insists that she is “just fine” and is not concerned about her memory. Which term best describes the unawareness of her cognitive decline? (Q851502)

A. Subjective cognitive decline

B. Anosognosia

C. Apraxia

D. Confabulation

Correct Answer: B. Anosognosia

■ *Listen (English)*

■ *Listen (Hindi)*

Explanation: Anosognosia is a condition in which a person is unaware of their own illness or cognitive decline. This lack of awareness can lead to a denial of any problems and is commonly observed in Alzheimer's disease. Subjective cognitive decline (Option A): This refers to self-reported memory loss without objective cognitive impairment - the opposite of this case (here, the patient denies the problem). Apraxia (Option C): Inability to perform learned motor tasks (e.g., dressing, brushing hair), despite intact strength. Confabulation (Option D): Confabulation refers to the unintentional fabrication or distortion of memories without the intention to deceive. Patients truly believe the false memories they are sharing. it is seen in Korsakoff psychosis.

References:

Harrison's Principles of Internal Medicine, 22nd Edition, Page 3476.

↑ *Back to this question in Part A*

@Neet_pg_bot

Q12: A 74-year-old woman is brought to a memory clinic by her daughter, who reports increasing forgetfulness over the past year. The daughter notes that her mother often misplaces items, struggles to find the right words during conversations, and repeats questions she has just asked. Recently, she became lost while driving to her regular grocery store, which she has frequented for years. On examination, she has difficulty following a conversation, and signs of apraxia are present. There are no significant findings on routine laboratory tests, and an FDG-PET is ordered. Which finding in FDG-PET is most consistent with the diagnosis of this patient's condition? (Q851503)

A. Hypometabolism in the posterior temporal-parietal cortex

B. Cerebral atrophy

C. Widened third ventricle

D. Detection of amyloid depositions

Correct Answer: A. Hypometabolism in the posterior temporal-parietal cortex

■ *Listen (English)*

■ *Listen (Hindi)*

Explanation: Clinical manifestations strongly correlate with a diagnosis of Alzheimer's disease. FDG-PET scans commonly reveal hypometabolism in the posterior temporal-parietal cortex. This pattern correlates with the cognitive deficits associated with Alzheimer's disease, including memory loss and difficulties with language and visuospatial skills. Imaging findings of Alzheimer's disease: CT: Cerebral atrophy, widened third ventricle (Options B & C) MRI: Atrophy in the entorhinal cortex, medial temporal cortex, and hippocampi Amyloid PET detects amyloid depositions (Option D) FDG-PET reveals hypometabolism in the posterior temporal-parietal

cortex (Option A) Functional brain imaging techniques such as Positron Emission Tomography (PET), functional MRI (fMRI), and Single-Photon Emission Computed Tomography (SPECT) help in mapping patterns of dysfunction in smaller brain areas of the medial temporal and parietal lobes

References:

Harrison's Principles of Internal Medicine, 22nd Edition, Page 3477.

↑ *Back to this question in Part A*

@Neet_pg_bot

Q13: A 75-year-old woman with moderate Alzheimer's disease has been on Donepezil for the past year. On routine follow-up, her cognitive abilities are declining further, and the physician decides to add another medication. Which treatment would be most appropriate to consider at this stage? (Q851504)

A. Rivastigmine

B. Memantine

C. Lecanemab

D. Galantamine

Correct Answer: B. Memantine

■ *Listen (English)*

■ *Listen (Hindi)*

Explanation: A common approach to Alzheimer's disease drug therapy is to initiate a cholinesterase inhibitor for a patient diagnosed with mild AD dementia and to add memantine when patients enter the moderate stage of the disease. Memantine blocks excessive glutamate activity at NMDA receptors in the CNS and reduces excitotoxic neuronal injury. Cholinesterase Inhibitors Rivastigmine (Option A): Acetylcholinesterase inhibitor and similar to Donepezil, so not added together routinely. Galantamine (Option D): Reversible AChE inhibitor and an allosteric modulator of nAChRs. Therapies Targeting Amyloid-β Aducanumab: Withdrawn. Lecanemab (Option C): Humanized monoclonal antibody targeting soluble amyloid-beta protofibril that reduces amyloid plaque accumulation in the brain—believed to slow disease progression. Approved for mild cognitive impairment (MCI) and early Alzheimer's. Must confirm amyloid pathology via PET scan or CSF biomarkers before starting. Administered as intravenous infusion every 2 weeks. Side effects include vasogenic cerebral edema, cortical microhemorrhages, and superficial siderosis.

References:

Harrison's Principles of Internal Medicine, 22nd Edition, Page 3480.

↑ *Back to this question in Part A*

Q14: Which of the following is NOT part of the clinical triad of Normal Pressure Hydrocephalus (NPH)? (Q851508)

A. Ataxia

B. Urinary incontinence

C. Dementia

D. Visual disturbances

Correct Answer: D. Visual disturbances

■ *Listen (English)*

■ *Listen (Hindi)*

Explanation: Visual disturbance is not part of the clinical triad. They are not typically associated with NPH. The clinical triad of Normal Pressure hydrocephalus: Abnormal gait (ataxic or apractic) (Option A) Dementia (usually mild to moderate) (Option C) Urinary urgency or incontinence (Option B) Shuffling gait with preserved arm swing {{caption_text}}

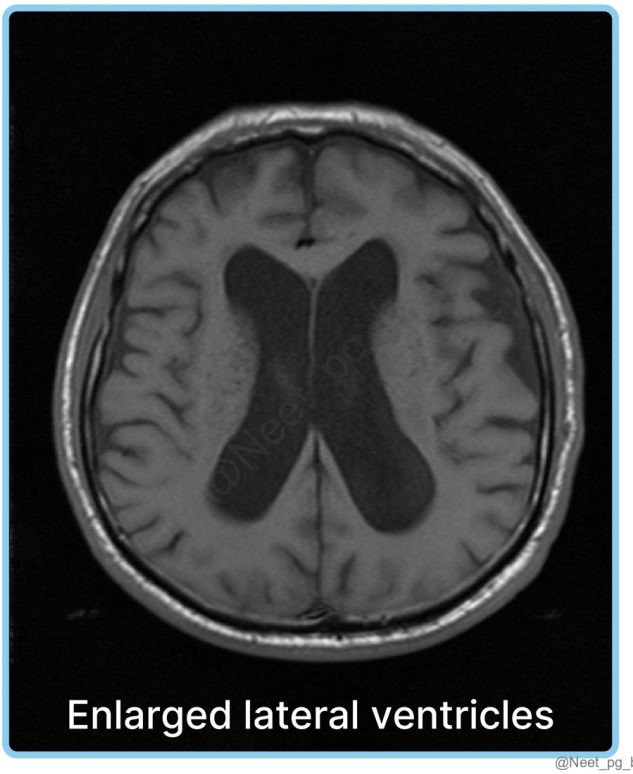

References:

Harrison's Principles of Internal Medicine, 22nd Edition, Page 3483.

↑ *Back to this question in Part A*

@Neet_pg_bot

• [07_Neurology] 052 Syringomelia Conus Medullaris Channelopathies And Sah

« Back to Folder Directory

[07_Neurology] 052 Syringomelia Conus Medullaris Channelopathies And Sah — Quick Jump

Q1 (p. 2303)	*Q2 (p. 2304)*	*Q3 (p. 2304)*	*Q4 (p. 2305)*	*Q5 (p. 2306)*	*Q6 (p. 2307)*
Q7 (p. 2308)	*Q8 (p. 2309)*	*Q9 (p. 2310)*	*Q10 (p. 2310)*	*Q11 (p. 2311)*	*Q12 (p. 2312)*
Q13 (p. 2312)	*Q14 (p. 2313)*	*Q15 (p. 2314)*	*Q16 (p. 2315)*	*Q17 (p. 2316)*	*Q18 (p. 2316)*
Q19 (p. 2317)	*Q20 (p. 2318)*	*Q21 (p. 2319)*			

Q1: Which of the following is used to prevent delayed cererbral ischemia in aneurysmal bleeding? (Q851241)

A. Nifedipine

B. Amlodipine

C. Nimodipine

D. Felodipine

Correct Answer: C. Nimodipine

■ *Listen (English)*

■ *Listen (Hindi)*

Explanation: Nimodipine is used to prevent delayed ischemia in the acute phase of subarachnoid hemorrhage. Nifedipine (Option A): It does not cross the blood-brain barrier effectively and is not used to prevent cerebral vasospasm or delayed ischemia in subarachnoid hemorrhage (SAH). Amlodipine (Option B): Long-acting calcium channel blocker used for systemic hypertension and angina. Like nifedipine, it lacks specificity for cerebral vessels and is not effective in preventing delayed cerebral ischemia after SAH. Felodipine (Option D): Dihydropyridine calcium channel blocker used in managing hypertension, but it has no proven benefit in preventing cerebral vasospasm or ischemia post-SAH.

References:

Harrison's Principles of Internal Medicine, 22nd Edition, Page 3461.

↑ *Back to this question in Part A*

@Neet_pg_bot

Q2: A 45-year-old male presents with poorly localized burning pain in the lower torso and legs. Then he noticed progressive weakness in both arms and legs over the past 3 months. On neurological examination, there is spasticity and hyperreflexia in both upper and lower limbs, with preserved perianal sensation. Which of the following is the most likely site of pathology? (Q851651)

A. Extradural compression

B. Intradural compression

C. Foramen magnum syndrome

D. Intramedullary compression

Correct Answer: D. Intramedullary compression

■ *Listen (English)*

■ *Listen (Hindi)*

Explanation: If the lesion is inside the cord, sensory symptoms (especially burning or poorly localized pain) tend to appear early, whereas if the lesion is outside the cord, motor/root symptoms usually dominate first due to outside-in compression. In this case, the patient presents with sensory symptoms with sacral sparing, which is characteristic of an intramedullary lesion. The involvement of the spinothalamic tract explains the dysesthesia, and bilateral corticospinal tract involvement points toward a cervical cord location. Extradural compression (Option A): Typically causes localized back/radicular pain and asymmetric motor symptoms early. Intradural extramedullary(Option B): Often presents with root pain, early motor weakness, and dorsal column signs, not burning dysesthesia. Foramen magnum lesion (Option C): Would cause spastic quadriparesis but typically includes cranial nerve involvement (e.g., dysphagia, facial symptoms), which is absent here.

References:

Harrison's Principles of Internal Medicine, 22nd Edition, Page 3561.

↑ *Back to this question in Part A*

@Neet_pg_bot

Q3: A patient presented with complaints of radicular pain on the lower back associated with loss of sensations over sacrum and urinary incontinence. There was weakness, started over lower limbs one month back and now weakness is present over upper limbs. What is the ideal imaging of choice to diagnose this condition? (Q851650)

A. CECT

B. MRI

C. CT angiography

D. X-ray LS spine AP and lateral view

Correct Answer: B. MRI

■ *Listen (English)*

■ *Listen (Hindi)*

Explanation: Radicular pain with sacral loss + Ascending paralysis + early Bladder involvement is suggestive of extramedullary compression of the spinal cord . MRI, preferably T2-sequence, is the ideal imaging modality of choice to diagnose spinal pathologies. CECT (Option A): Less sensitive for soft tissue and spinal cord lesions; mainly for bony assessment. CT angiography (Option C): Used for vascular abnormalities, not first-line for compressive lesions. X-ray LS spine AP and lateral view (Option D): Only detects bony abnormalities, cannot visualize cord or nerve roots effectively.

References:

Harrison's Principles of Internal Medicine, 22nd Edition, Page 3561

https://www.ncbi.nlm.nih.gov/books/NBK557604/

↑ *Back to this question in Part A*

@Neet_pg_bot

Q4: Which among the following is seen in this spinal cord lesion as shown below? (Q851253)

A. C/L loss of vibration sense below the level of lesion

B. C/L loss of thermal sensation at and above the same level

C. I/L loss of muscle tone at the level of lesion

D. C/L loss of pain 2 segments above the level of lesion

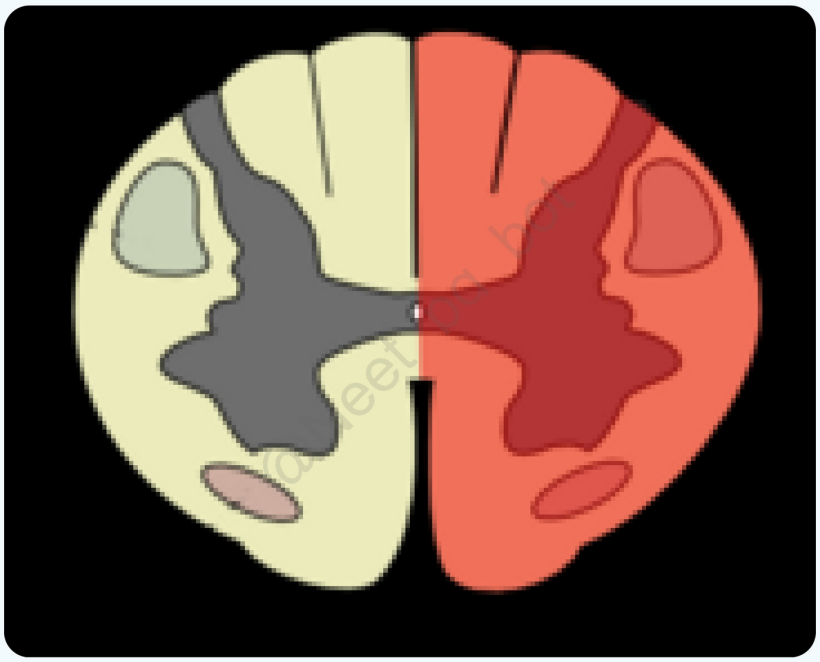

Correct Answer: C. I/L loss of muscle tone at the level of lesion

■ *Listen (English)*

■ *Listen (Hindi)*

Explanation: Hemisection of the spinal cord/Brown-Sequard syndrome results in I/L loss of sensations carried by the dorsal and pyramidal column tracts and C/L loss of sensations carried by the spinothalamic tract 2 segments below the level of the lesion. Features of Brown-Sequard syndrome/ Hemisection of Spinal Cord: Feature At the Level of Lesion Below the Level of Lesion Ipsilateral LMN paralysis, radicular pain; loss of vibration & proprioception (dorsal column) UMN paralysis (corticospinal tract); loss of vibration & proprioception (dorsal column) Contralateral - Loss of pain and temperature (spinothalamic tract)

References:

Harrison's Principles of Internal Medicine, 22nd Edition, Page 3561

↑ *Back to this question in Part A*

@Neet_pg_bot

Q5: A 30 year old female presents with complaints of progressive weakness of lower limbs, numbness, difficulty walking and recent onset forgetfulness. On examination, bilateral loss of vibration sense is noted, bilateral ankle jerks are absent with bilateral babinski sign. Romberg sign is present with eyes closed. Peripheral blood smear done

was normal. What is the most likely diagnosis? (Q851252)

A. Subacute combined demyelination of Spinal cord

B. Tabes dorsalis

C. Friedrich ataxia

D. Brown sequard syndrome

Correct Answer: A. Subacute combined demyelination of Spinal cord

■ *Listen (English)*

■ *Listen (Hindi)*

Explanation: This clinical scenario is classic for Subacute Combined Degeneration due to Vitamin B12 deficiency, which affects both the dorsal columns (causing loss of vibration sense, positive Romberg sign) and the lateral corticospinal tracts (causing weakness and bilateral Babinski sign). The presence of absent ankle jerks with extensor plantar response suggests a mixed UMN and LMN picture seen in SACD, as it involves both peripheral nerves and dorsal column. Note: Neurological features can exist without hematological features. Tabes dorsalis (Option B) also affects the dorsal columns and can cause sensory ataxia, but there is no UMN involvement (Babinski sign would not be present). Friedreich's ataxia (Option C) has an onset in adolescence and has cardiomyopathy, and a family history, which are not mentioned. Brown-Séquard syndrome (Option D) presents with ipsilateral motor and vibration loss with contralateral pain loss, not a bilateral symmetrical presentation as seen here.

References:

Harrison's Principles of Internal Medicine, 22nd Edition, Page 3568.

↑ *Back to this question in Part A*

@Neet_pg_bot

Q6: A 32-year-old woman presents with sudden symmetrical onset of both lower extremity weakness, numbness, and urinary retention. She reports a history of a respiratory tract infection two weeks ago. Neurological examination reveals reduced muscle strength and sensory loss below the mid-thoracic region, along with hyperreflexia. MRI of the spine shows a focal area of increased T2 signal in the thoracic spinal cord without evidence of compression. What is the most likely diagnosis? (Q851251)

A. Multiple sclerosis

B. Guillain-Barré syndrome

C. Transverse myelitis

D. Amyotrophic lateral sclerosis

Correct Answer: C. Transverse myelitis

■ *Listen (English)*

■ *Listen (Hindi)*

Explanation: Rapid onset B/L symmetrical weakness post-infective sequelae with Hyperintensities within the spinal cord on T2-MRI is suggestive of Transverse Myelitis . Multiple sclerosis (Option A): MS can present with spinal cord lesions, but typically these are asymmetrical and multifocal . This patient's rapid, symmetrical onset of symptoms and the absence of other characteristic findings like Optic neuritis, Lhermitte sign, Uhthoff's phenomenon , MRI shows characteristic Dawson's fingers and CSF analysis reveals Oligoclonal bands - thereby making MS less likely. Guillain-Barré syndrome (Option B): GBS often presents with ascending asymmetric weakness and areflexia , affecting peripheral nerves. CSF analysis reveals Albumino-cytological dissociation. However, this patient has hyperreflexia and sensory loss in a well-defined spinal cord region, which is more indicative of central nervous system pathology, ruling out GBS. Amyotrophic lateral sclerosis (ALS) (Option D): ALS causes progressive motor neuron degeneration, leading to both upper and lower motor neuron signs without sensory deficits . The acute onset, sensory involvement, and bladder dysfunction are not typical of ALS.

References:

Harrison's Principles of Internal Medicine, 22nd Edition, Page 3565

https://www.ninds.nih.gov/health-information/disorders/transverse-myelitis

↑ *Back to this question in Part A*

@Neet_pg_bot

Q7: A 55-year-old man presents with multiple episodes of involuntary urine passage in clothes, lower back pain and bilateral lower limb weakness. On examination, he has saddle anesthesia, intact knee jerks and absent ankle jerks. What is the most likely diagnosis? (Q851250)

A. Conus medullaris syndrome

B. Cauda Equina Syndrome

C. Transverse myelitis

D. Spinal shock

Correct Answer: A. Conus medullaris syndrome

■ *Listen (English)*

■ *Listen (Hindi)*

Explanation: The presence of saddle anaesthesia, early bladder involvement, bilateral lower limb weakness, and mixed UMN (knee jerk preserved) + LMN (ankle jerk absent) signs points strongly to conus medullaris syndrome. Cauda equina syndrome (Option B) shows asymmetric LMN signs, severe radicular pain, and late bladder involvement, which is not seen here. Transverse myelitis (Option C) usually presents with a clear sensory level, spasticity, and UMN signs, unlike the mixed picture here. Spinal shock (Option D) causes flaccid paralysis and areflexia in the acute phase but lacks the saddle anesthesia and early bladder symptoms that define conus medullaris.

References:

Harrison's Principles of Internal Medicine, 22nd Edition, Page 3560

↑ *Back to this question in Part A*

@Neet_pg_bot

Q8: Which of the following findings is least likely to be seen in cauda equina syndrome? (Q851249)

A. Back pain

B. Saddle anesthesia

C. Brisk bulbocavernosus reflex

D. Impotence

Correct Answer: C. Brisk bulbocavernosus reflex

■ *Listen (English)*

■ *Listen (Hindi)*

Explanation: Brisk bulbocavernosus reflex , which is least likely in cauda equina syndrome as it a LMN lesion. It occurs due to compression of lumbosacral nerve roots, so reflexes like the bulbocavernosus are reduced or absent. Back pain, saddle anesthesia, and impotence are hallmark features due to sensory and autonomic involvement. A brisk reflex would suggest an UMN lesion, which is not characteristic of CES. Cauda Equina Syndrome: Compression and disruption of the nerve roots from the distal spinal cord (typically L1-L5), often resulting from damage (secondary to trauma, tumors, herniated discs , or spinal stenosis) to L3-L5 nerve roots Clinical features: Back pain and sciatica (Option A) Bladder and bladder dysfunction (retention or incontinence) Saddle anesthesia (Option B) Sexual dysfunction (impotence in men). (Option D) Motor or sensory deficits in the legs, often asymmetric. Lower motor neuron signs: areflexia, hypotonia, atrophy. Decreased rectal tone. Absent bulbocavernosus reflex (Option C)

References:

Harrison's Principles of Internal Medicine, 22nd Edition, Page 589.

↑ *Back to this question in Part A*

@Neet_pg_bot

Q9: Which of the following statements is wrong about conus medullaris syndrome? (Q851248)

A. Loss of anal reflex

B. Urinary incontinence

C. Bilateral saddle anesthesia

D. Priapism

Correct Answer: D. Priapism

■ *Listen (English)*

■ *Listen (Hindi)*

Explanation: Priapism is not seen in conus lesions; it is more characteristic of acute high spinal cord injuries above T6 due to sympathetic disruption. Loss of anal reflex (Option A) and bilateral saddle anaesthesia (Option C) are hallmark features of conus medullaris syndrome , due to involvement of sacral (S2–S4) nerve roots. Early urinary incontinence (Option B) occurs from autonomic dysfunction affecting bladder control. These are typical findings in CMS.

References:

Harrison's Principles of Internal Medicine, 22nd Edition, Page 3560.

↑ *Back to this question in Part A*

@Neet_pg_bot

Q10: A 45-year-old woman presents with progressive weakness and sensory loss in her arms, along with muscle wasting in her hands. MRI reveals a large intramedullary spinal cord tumor, with an associated syrinx. What is the management? (Q851247)

A. Tumor resection

B. Radiation therapy

C. Chemotherapy

D. Decompression

Correct Answer: A. Tumor resection

■ *Listen (English)*

■ *Listen (Hindi)*

Explanation: A large intramedullary spinal cord tumor with syrinx causing progressive neurological deficits requires surgical resection as the primary management to relieve compression and prevent further deterioration . Radiation therapy (Option B): Considered adjuvant for certain tumor types or unresectable tumors, not first-line. Chemotherapy (Option C): Rarely used for primary intramedullary tumors, except specific histologies. Decompression (Option D): Non-specific; definitive management is tumor resection, not just decompression.

References:

Harrison's Principles of Internal Medicine, 22nd Edition, Page 3568.

↑ *Back to this question in Part A*

@Neet_pg_bot

Q11: Which of the following statements about syringomyelia is wrong? (Q851246)

A. A developmental cavity in the cervical cord

B. Symptoms begin in adolescence or early adulthood

C. The majority linked with Chiari type 2 malformation

D. Sensory loss in a cape distribution

Correct Answer: C. The majority linked with Chiari type 2 malformation

■ *Listen (English)*

■ *Listen (Hindi)*

Explanation: More than half of cases are linked with Chiari type 1 malformations (cerebellar tonsils protrude through the foramen magnum and cervical spinal canal). A developmental cavity in the cervical cord (Option A) that can enlarge or remain asymptomatic. Symptoms begin in adolescence or early adulthood (Option B) , progress irregularly, and may undergo spontaneous arrest. Suspended sensory loss in a cape distribution (Option D) (nape, shoulders, upper arms, hands).

References:

Harrison's Principles of Internal Medicine, 22nd Edition, Page 3567.

↑ *Back to this question in Part A*

@Neet_pg_bot

Q12: Which gene mutation is primarily associated with hyperkalemic periodic paralysis? (Q851231)

A. KCNJ2

B. CACNA1S

C. SCN4A

D. RYR1

Correct Answer: C. SCN4A

■ *Listen (English)*

■ *Listen (Hindi)*

Explanation: Mutations in the SCN4A gene , which encodes a sodium channel, are responsible for hyperkalemic periodic paralysis. KCNJ2 (Option A): Associated with Anderson-Tawil syndrome and hypokalemic periodic paralysis. CACNA1S (Option B): Mutations in this gene are linked to hypokalemic periodic paralysis and other channelopathies. RYR1 (Option D): Mutations in this gene are associated with malignant hyperthermia and central core disease.

References:

Harrison's Principles of Internal Medicine, 22nd Edition, Page 3646.

↑ *Back to this question in Part A*

@Neet_pg_bot

Q13: A 52-year-old woman presents with a sudden, severe "thunderclap" headache followed by brief loss of consciousness. NCCT head reveals blood in the basal cisterns. CT angiography shows a ruptured anterior communicating artery aneurysm. She is alert and oriented (Hunt and Hess grade II). BP on admission is 160/100 mm Hg. Which of the following is the most appropriate definitive treatment to prevent rebleeding in this patient? (Q851240)

A. Administration of nimodipine to prevent vasospasm

B. Strict blood pressure control with IV labetalol

C. Surgical clipping of the aneurysm

D. Endovascular coiling of the aneurysm

Correct Answer: D. Endovascular coiling of the aneurysm

■ *Listen (English)*

■ *Listen (Hindi)*

Explanation: This patient has aneurysmal SAH confirmed on CT angiography. The definitive treatment to prevent rebleeding is securing the aneurysm , and endovascular coiling is the preferred method in most cases, especially in good-grade patients (like Hunt & Hess I–III) or when the aneurysm is accessible via catheter. Nimodipine (Option A) is essential to reduce the risk of delayed cerebral ischemia , but it doesn't prevent rebleeding Blood pressure control (Option B) is supportive but not definitive therapy. Clipping (Option C) is an alternative but more invasive and typically reserved for unfavorable anatomy or failed coiling.

References:

Harrison's Principles of Internal Medicine, 22nd Edition, Page 3460

↑ *Back to this question in Part A*

@Neet_pg_bot

Q14: A 45-year-old patient presents to the ER with a sudden headache described as the "worst headache of their life." A non-contrast head CT is normal. Despite this, the suspicion of subarachnoid hemorrhage remains high. What is the most appropriate next step in the evaluation of this patient? (Q851239)

A. Repeat the head CT scan in 24 hours

B. Lumbar puncture to assess for xanthochromia

C. Immediate cerebral angiography

D. Perform a Time-of-Flight Magnetic Resonance Angiography (TOF-MRA)

Correct Answer: B. Lumbar puncture to assess for xanthochromia

■ *Listen (English)*

■ *Listen (Hindi)*

Explanation: Lumbar puncture to assess for xanthochromia is the next step if the initial CT scan is negative but clinical suspicion for SAH remains high. Ideally, the LP should be performed at least > 6 hours after the headache onset to detect xanthochromia, which indicates blood breakdown in the cerebrospinal fluid {{caption_text}} Repeat CT in 24 hours (Option A) : No added benefit — bleeding would have been evident initially. Immediate cerebral angiography (Option C) : Only indicated after confirming SAH (via CT or LP). TOF-MRA (Option D) :

Not the diagnostic standard in acute suspected SAH — and again, requires proof of hemorrhage first .



References:

Harrison's Principles of Internal Medicine, 22nd Edition, Page 3459.

↑ *Back to this question in Part A*

@Neet_pg_bot

Q15: A 26-year-old woman is brought to the emergency department with sudden-onset severe headache. On admission, her GCS is 12/15 and non-contrast CT head shows blood in the Sylvian fissure. On day 4 of hospitalization, she becomes increasingly drowsy and develops slow speech. Repeat CT reveals no new hemorrhage or infarct. She has polyuria, and her serum sodium is 125 mEq/L. On examination, she appears dehydrated. What is the most likely cause of her clinical deterioration? (Q851238)

A. Rebleeding from the aneurysm

B. Spasm of feeder vessel

C. Delayed cerebral ischemia

D. Cerebral salt-wasting syndrome

Correct Answer: D. Cerebral salt-wasting syndrome

■ *Listen (English)*

■ *Listen (Hindi)*

Explanation: The patient with subarachnoid hemorrhage (SAH) develops hyponatremia, polyuria, and signs of dehydration without new infarct or rebleed. This is characteristic of cerebral salt-wasting syndrome , where renal sodium loss leads to hypovolemia and worsening neurological status. Rebleeding from the aneurysm (Option A): Would show new hemorrhage on CT. Spasm of feeder vessel (Option B): Usually asymptomatic unless severe; detected on angiography. Delayed cerebral ischemia (Option C): Causes new neurological deficits with ischemic changes on imaging, which are absent here.

References:

Harrison's Principles of Internal Medicine, 22nd Edition, Page 3459.

↑ *Back to this question in Part A*

@Neet_pg_bot

Q16: A 45-year-old woman presents with a sudden onset severe headache for past 6 hours and nuchal rigidity. CTA shows berry aneurysm at posterior communicating artery. Which of the following clinical features is most likely associated with this scenario? (Q851237)

A. 6th cranial nerve palsy

B. Visual field defects

C. 3rd cranial nerve palsy

D. Occipital pain

Correct Answer: C. 3rd cranial nerve palsy

■ *Listen (English)*

■ *Listen (Hindi)*

Explanation: Third cranial nerve palsy is typically seen with an aneurysm at the posterior communicating artery and internal carotid junction. It presents with symptoms like pupillary dilation, loss of the ipsilateral light reflex, and eye pain. 6th cranial nerve palsy (Option A): Typically associated with increased intracranial pressure or cavernous sinus lesions. Visual field defects (Option B): Usually due to optic chiasm compression, e.g., pituitary adenoma Occipital pain (Option D): More typical of posterior circulation stroke or vertebrobasilar pathology, not

PComm aneurysm.

References:

Harrison's Principles of Internal Medicine, 22nd Edition, Page 3458.

↑ *Back to this question in Part A*

@Neet_pg_bot

Q17: A 25-year-old female presents to the ER with a sudden onset of severe headache with prostration. On examination, BP 180/100 mm Hg and nuchal rigidity is noted. The NCCT head shows blood in the Sylvian fissure. Which is the next best step in the management of this patient? (Q851236)

A. Lowering of BP

B. Cerebral angiography

C. Nimodipine

D. Mannitol

Correct Answer: B. Cerebral angiography

■ *Listen (English)*

■ *Listen (Hindi)*

Explanation: In a diagnosed case of SAH, the next investigation done is cerebral angiography. This will help in the diagnosis of the site of berry rupture and also identify the site(s) of any coexistent berry aneurysm on the contralateral site. Following angiography, endovascular coiling can be done to prevent re-bleeding. Lowering of BP (Option A) will not be required as it will maintain cerebral perfusion. Nimodipine (Option C) will be given after the procedure to prevent delayed cerebral ischemia that occurs due to protective vasospasm. Mannitol (Option D): Used for raised intracranial pressure, not the initial diagnostic step.

References:

Harrison's Principles of Internal Medicine, 22nd Edition, Page 3459.

↑ *Back to this question in Part A*

@Neet_pg_bot

Q18: Which of the following is correct about Anderson Tawil syndrome? (Q851235)

A. Sodium channelopathy affecting the cardiac conduction system

B. Potassium channelopathy affecting skeletal muscle and cardiac conduction

C. Calcium channelopathy affecting cardiac muscle

D. Abnormal chloride transport in skeletal and cardiac muscle

Correct Answer: B. Potassium channelopathy affecting skeletal muscle and cardiac conduction

■ *Listen (English)*

■ *Listen (Hindi)*

Explanation: Potassium channelopathy affecting skeletal muscle and cardiac conduction is consistent with Anderson-Tawil syndrome, which is caused by mutations in the KCNJ2 gene. Anderson-Tawil syndrome summary: Clinical Features: Triad of periodic paralysis, ventricular arrhythmias, prolonged QT interval. Dysmorphic Features: Craniofacial (broad forehead, small mandible, low-set ears, hypertelorism) and skeletal (short stature, scoliosis, clinodactyly, syndactyly). Treatment: Oral potassium (20–30 mEq/L), acetazolamide to prevent paralysis, avoid triggers (fasting, strenuous exercise). Cardiac Management: Beta-blockers, ICD, antiarrhythmics (flecainide, amiodarone).

References:

Harrison's Principles of Internal Medicine, 22nd Edition, Page 3647.

↑ *Back to this question in Part A*

@Neet_pg_bot

Q19: A 19-year-old male presents to the emergency department with a sudden onset of generalized muscle weakness, particularly in his legs, after a day of strenuous exercise followed by a high-carbohydrate meal. He reports experiencing similar episodes of muscle weakness in the past, often triggered by exercise or large meals. What is the most appropriate first-line treatment for this patient's acute presentation? (Q851234)

A. Oral potassium supplementation

B. Intravenous potassium

C. Acetazolamide

D. Beta-blockers

Correct Answer: A. Oral potassium supplementation

■ *Listen (English)*

■ *Listen (Hindi)*

Explanation: In most cases of acute hypokalemic periodic paralysis, oral potassium supplementation is preferred as the first-line treatment , especially when the patient's symptoms are not life-threatening and potassium levels are moderately low. Hypokalemic Periodic Paralysis (HypoPP) : Autosomal dominant mutations in voltage-gated calcium channels (CACNA1S) or sodium channels (SCN4A). Treatment: First-line: Oral potassium chloride (0.5–1 mEq/kg), monitor if >100 mEq; max 200 mEq/24h. IV potassium: Reserved for arrhythmias, swallowing issues, or respiratory paralysis; usually with mannitol. Long-term: Acetazolamide or potassium-sparing diuretics (spironolactone) to reduce episode frequency/severity. Intravenous potassium (Option B): Used in severe cases of hypokalemia or if oral intake is not feasible; faster correction is generally not needed unless symptoms are life-threatening. Acetazolamide (Option C): Used for long-term prevention of episodes, but not for acute treatment. Beta-blockers (Option D): Not indicated for hypokalemic periodic paralysis, primarily used in arrhythmias or hypertension.

References:

Harrison's Principles of Internal Medicine, 22nd Edition, Page 3646.

↑ *Back to this question in Part A*

@Neet_pg_bot

Q20: An 18-year-old male presents to the emergency department with a sudden onset of severe muscle weakness, primarily in his legs, which started a few hours after consuming a large, carbohydrate-heavy meal following exercise. He reports similar episodes in the past, often triggered by large meals or after rest following physical activity. His vital signs are stable, and he has no respiratory involvement. Blood work reveals a serum potassium level of 2.3 mEq/L. What is the most likely underlying mechanism for this patient's condition? (Q851233)

A. Sodium channel dysfunction causing an inability to generate action potentials

B. Potassium channel dysfunction leading to excessive potassium loss

C. Calcium or sodium channel mutations causing abnormal potassium influx into cells

D. Excessive release of acetylcholine at the neuromuscular junction

Correct Answer: C. Calcium or sodium channel mutations causing abnormal potassium influx into cells

■ *Listen (English)*

■ *Listen (Hindi)*

Explanation: Hypokalemic periodic paralysis (HypoPP) is typically caused by mutations in the CACNA1S gene - in 80% cases (calcium channels) or the SCN4A gene - in 10% cases (sodium channels) , leading to abnormal

potassium shifting into cells. Hypokalemic Periodic Paralysis (HypoPP) Genetic disorder caused by skeletal muscle ion channel mutation, mainly affecting sodium or calcium channels. The majority of hypoPP cases are hereditary or familial. The familial form of hypoPP is a rare channelopathy resulting from mutations in either the calcium or sodium ion channels, predominantly affecting skeletal muscle cells. Sodium channel dysfunction causing an inability to generate action potentials (Option A): Does not specifically explain episodic hypokalemia. Potassium channel dysfunction leading to excessive potassium loss (Option B): Hypokalemia is due to shift into cells, not renal or gastrointestinal loss. Excessive release of acetylcholine at the neuromuscular junction (Option D): Would cause muscle cramps or fasciculations, not hypokalemia-induced paralysis.

References:

Harrison's Principles of Internal Medicine, 22nd Edition, Page 3646.

↑ *Back to this question in Part A*

@Neet_pg_bot

Q21: A 23-year-old male presents to the clinic with complaints of muscle stiffness, especially in his face and hands, following exposure to cold weather. He reports that his symptoms worsen with repeated movements and improve with rest. Upon examination, his muscles are stiff but not weak. His symptoms do not improve with warming. What is the most likely diagnosis? (Q851232)

A. Myotonic Dystrophy

B. Paramyotonia Congenita

C. Hypokalemic Periodic Paralysis

D. Becker Muscular Dystrophy

Correct Answer: B. Paramyotonia Congenita

■ *Listen (English)*

■ *Listen (Hindi)*

Explanation: Paramyotonia congenita is a sodium channelopathy (SCN4A mutation) characterized by paradoxical myotonia : worsens with activity and cold, not relieved by warming . Myotonic dystrophy (Option A) shows progressive weakness, distal wasting , cataracts, and symptoms improve with repeated activity ("warm-up phenomenon"). Hypokalemic periodic paralysis (Option C) presents with episodic weakness , not stiffness, often triggered by rest after exertion or high-carb meals. Becker muscular dystrophy (Option D) involves progressive muscle weakness , especially proximal limbs, without cold sensitivity or stiffness.

References:

Harrison's Principles of Internal Medicine, 22nd Edition, Page 3635, 3646.

↑ *Back to this question in Part A*

@Neet_pg_bot

• [07_Neurology] 053 Myasthenia Gravis

« Back to Folder Directory

[07_Neurology] 053 Myasthenia Gravis — Quick Jump

Q1 (p. 2321) *Q2 (p. 2322)* *Q3 (p. 2322)* *Q4 (p. 2323)* *Q5 (p. 2324)* *Q6 (p. 2325)*
Q7 (p. 2326) *Q8 (p. 2326)* *Q9 (p. 2327)* *Q10 (p. 2328)*

Q1: A 45-year-old woman presents with fluctuating muscle weakness that worsens with repetitive activity and improves with rest. She also reports more pronounced symptoms in the evening. Neurological examination shows normal deep tendon reflexes. Workup reveals positive anti-MuSK antibodies and negative anti-acetylcholine receptor (AChR) antibodies. Which of the following best describes the underlying mechanism of her condition? (Q851549)

A. T-cell mediated destruction of anterior horn cells

B. Autoantibodies disrupt clustering of acetylcholine receptors

C. Disruption of post synaptic voltage-gated calcium channels

D. Inhibition of acetylcholine release from synaptic vesicles

Correct Answer: B. Autoantibodies disrupt clustering of acetylcholine receptors

■ *Listen (English)*

■ *Listen (Hindi)*

Explanation: Anti-MuSK antibodies in myasthenia gravis disrupt the regulation and clustering of acetylcholine receptors at the neuromuscular junction, impairing efficient nerve-to-muscle signalling and causing muscle weakness, particularly with repetitive activity. T-cell-mediated destruction of anterior horn cells (Option A) describes motor neuron disease. Disruption of post-synaptic voltage-gated calcium channels (Option C) is incorrect, as voltage-gated calcium channels are present pre-synaptically and are not post-synaptically. Moreover, they are not involved in Myasthenia Gravis. Inhibition of acetylcholine release from synaptic vesicles (Option D) implies a pre-junctional defect.

References:

Harrison's Principles of Internal Medicine, 22nd Edition, Page 3624, 3625.

↑ *Back to this question in Part A*

@Neet_pg_bot

Q2: A 35-year-old woman presents with fluctuating muscle weakness, especially affecting her speech and swallowing. Repetitive nerve stimulation shows a decremental response. Her blood tests are negative for acetylcholine receptor (AChR) antibodies. Which of the following antibodies is most likely responsible for her symptoms? (Q851550)

A. Anti-dsDNA antibodies

B. Anti-MuSK antibodies

C. Anti-TPO antibodies

D. Anti-Ro antibodies

Correct Answer: B. Anti-MuSK antibodies

■ *Listen (English)*

■ *Listen (Hindi)*

Explanation: MuSK is essential for clustering AChRs at the neuromuscular junction. Anti-MuSK antibodies are found in AChR-negative patients, often presenting with bulbar muscle weakness (affecting speech and swallowing). Anti-dsDNA antibodies (Option A) : Seen in systemic lupus erythematosus (SLE) , not associated with neuromuscular transmission issues. Anti-TPO antibodies (Option C) : Linked with autoimmune thyroid disorders (e.g., Hashimoto's thyroiditis). Anti-Ro antibodies (Option D) : Found in Sjogren's syndrome and neonatal lupus , not relevant to myasthenia gravis.

References:

Harrison's Principles of Internal Medicine, 22nd Edition, Page 3624, 3627.

↑ *Back to this question in Part A*

@Neet_pg_bot

Q3: A 20-year-old woman who is known case of myasthenia gravis presents to the clinic with worsening symptoms, including difficulty in lifting her arms and shortness of breath. On examination, you notice that her eyelids are drooping, and she has double vision. What is the most significant risk associated with her current condition if not addressed promptly? (Q851551)

A. Impaired vision

B. Aspiration due to swallowing difficulties

C. Respiratory failure

D. Muscle atrophy

Correct Answer: C. Respiratory failure

■ *Listen (English)*

■ *Listen (Hindi)*

Explanation: Respiratory failure is the most significant risk in a patient with myasthenia gravis, especially when muscle weakness affects the respiratory muscles. This can lead to inadequate ventilation, making it a critical and life-threatening condition that requires immediate intervention to prevent severe complications. If FVC is <15–20 mL/kg or there's hypercapnia, immediate ICU admission is needed for possible ventilatory support. Impaired vision (Option A) : While double vision is concerning, it is not immediately life-threatening. Aspiration due to swallowing difficulties (Option B) : This is a risk but secondary to the more critical concern of respiratory failure. Muscle atrophy (Option D) : This is a long-term consequence of disuse and not an immediate risk in the acute setting.

References:

Harrison's Principles of Internal Medicine, 22nd Edition, Page 3626, 3632.

↑ *Back to this question in Part A*

@Neet_pg_bot

Q4: A 28-year-old woman presents to the ER with acute muscle weakness, double vision, and difficulty swallowing. He has a history of myasthenia gravis and has been experiencing increased fatigue over the past few days. Which of the following clinical features would best help differentiate a myasthenic crisis from a cholinergic crisis? (Q851552)

A. Muscle fasciculations

B. Small pupils

C. Response to edrophonium

D. Pallor and sweating

Correct Answer: C. Response to edrophonium

■ *Listen (English)*

■ *Listen (Hindi)*

Explanation: The edrophonium (Tensilon) test helps differentiate between myasthenic crisis and cholinergic crisis : In a myasthenic crisis , symptoms improve after edrophonium administration because it temporarily increases acetylcholine availability at the neuromuscular junction. In a cholinergic crisis , symptoms worsen after edrophonium due to excessive acetylcholine causing continuous depolarization and muscle weakness. Muscle fasciculations (Option A): Seen in cholinergic crisis due to excess acetylcholine, not a distinguishing test. Small pupils (Option B): Miosis occurs in cholinergic crisis but is not diagnostic. Pallor and sweating (Option D): Nonspecific autonomic signs, not useful for differentiation.

References:

Harrison's Principles of Internal Medicine, 22nd Edition, Page 3627.

https://www.ncbi.nlm.nih.gov/books/NBK559331/

↑ *Back to this question in Part A*

@Neet_pg_bot

Q5: A 40-year-old female presents with symptoms of fluctuating double vision and drooping eyelids that worsen through the day. On neuro-examination DTRs are normal and power of all muscle groups except ocular muscles is normal. Blood tests confirms the presence of Anti-MuSK antibody. What is the most appropriate management strategy for this patient? (Q851553)

A. Initiate high-dose corticosteroids as the first-line treatment

B. Recommend immediate thymectomy regardless of symptom severity

C. Start anticholinesterase medications and consider immunosuppressants if symptoms persist

D. Advise the patient to undergo regular monitoring without any treatment

Correct Answer: C. Start anticholinesterase medications and consider immunosuppressants if symptoms persist

■ *Listen (English)*

■ *Listen (Hindi)*

Explanation: This patient has MuSK-positive MG , which often shows: Bulbar and ocular weakness Poor or transient response to anticholinesterase therapy (e.g., pyridostigmine) Thymic pathology is rare , so thymectomy is usually not indicated Anticholinesterase medications, such as pyridostigmine, are the first-line treatment for ocular myasthenia gravis, as they help improve neuromuscular transmission and alleviate muscle weakness. If symptoms continue despite initial treatment, immunosuppressants may be considered to reduce autoantibody production and improve outcomes. Rarely, pyridostigmine may worsen symptoms (particularly if the ptosis is already severe), possibly due to excess cholinergic stimulation → increased eyelid fatigue or paradoxical neuromuscular junction desensitization. Initiate high-dose corticosteroids as the first-line treatment (Option A): Used if symptoms persist

despite anticholinesterase therapy, not initially. Recommend immediate thymectomy regardless of symptom severity (Option B): Thymectomy is less effective in Anti-MuSK–positive MG. Advise the patient to undergo regular monitoring without any treatment (Option D): Untreated MG can progress and cause life-threatening weakness. Key points for MuSK-positive MG: Anticholinesterase agents: Limited efficacy; sometimes worsen symptoms. Immunosuppression: Mainstay of treatment; rituximab is especially effective. Thymectomy: Rarely beneficial.

References:

Harrison's Principles of Internal Medicine, 22nd Edition, Page 3630.

https://pn.bmj.com/content/25/5/422

↑ *Back to this question in Part A*

@Neet_pg_bot

Q6: A 45-year-old woman presents with fluctuating muscle weakness, particularly affecting her eyelids and causing double vision. She also has difficulty in swallowing and develops dysarthria after speaking continously for few minutes. Which of the following diagnostic tests would confirm the suspicion of Myasthenia Gravis? (Q851554)

A. Single Fiber EMG showing increased Jitter

B. Nerve conduction velocity showing slowed conduction of impulses

C. Ice pack test

D. Tensilon test

Correct Answer: A. Single Fiber EMG showing increased Jitter

■ *Listen (English)*

■ *Listen (Hindi)*

Explanation: Myasthenia Gravis (MG) is an autoimmune disorder affecting the neuromuscular junction , causing fluctuating muscle weakness , commonly involving: Ocular muscles → ptosis, diplopia Bulbar muscles → dysarthria, dysphagia Limb muscles → proximal weakness Diagnostic tests: Single-fiber electromyography (SFEMG) : Most sensitive test for MG. Shows increased jitter, which reflects variability in neuromuscular transmission. Nerve conduction velocity (Option B) Used for peripheral neuropathies, not MG; nerve conduction is usually normal. Ice pack test (Option C) Can temporarily improve ptosis in ocular MG; supportive, not confirmatory. Tensilon (edrophonium) test (Option D) Historically used; shows temporary improvement after IV edrophonium. Less commonly used now due to risk of bradycardia and other side effects. Key point: SFEMG (increased jitter) is the confirmatory diagnostic test . Ice pack and Tensilon are supportive/clinical tests , not definitive.

References:

Harrison's Principles of Internal Medicine, 22nd Edition, Page 3627.

↑ *Back to this question in Part A*

@Neet_pg_bot

Q7: A 28-year-old woman presents with diplopia that develops daily in evening hours along with difficulty in swallowing. On examination left eye ptosis is noted. Ice pack test shows improvement in ptosis. Repetitive nerve stimulation shows a decremental response. The report of antibody panel is awaited. Which of the following will not be useful in management of this patient? (Q851556)

A. Physostigmine

B. Plasma Exchange

C. Pyridostigmine

D. Intravenous immunoglobulin

Correct Answer: A. Physostigmine

■ *Listen (English)*

■ *Listen (Hindi)*

Explanation: This is a case of Myasthenia Gravis, as diurnal variation of neuro-symptoms is seen, and the ice pack test shows resolution of ptosis. Physostigmine crosses the blood-brain barrier and has a central action. It has no role in the management of disorders of the peripheral nervous system. Plasma exchange (Option B) & Intravenous immunoglobulins (Option D): IVIg and PLEX would be required if this patient develops Myasthenic crisis. Pyridostigmine (Option C): Pyridostigmine is an anticholinesterase drug that is specifically used to increase acetylcholine activity at the neuromuscular junction, making it the most appropriate treatment for this patient

References:

Harrison's Principles of Internal Medicine, 22nd Edition, Page 3628.

↑ *Back to this question in Part A*

@Neet_pg_bot

Q8: A 45-year-old man known case of myasthenia gravis presents to the emergency department with severe muscle weakness and respiratory distress. On examination he

is using accessory muscles of respiration, spO2 on room air is 85% and he cannot speak full sentences. ABG shows pH: 7.2, pC02 50 mm Hg and HCO3= 27 meq/L. Which of the following treatments is most appropriate for immediate management of this patient's condition? (Q851557)

A. IVIg

B. Endotracheal intubation and IVIg

C. High flow nasal cannula and IVIg

D. Plasma exchange (PLEX)

Correct Answer: B. Endotracheal intubation and IVIg

■ *Listen (English)*

■ *Listen (Hindi)*

Explanation: Diagnosis is Myasthenic Crisis and administration of intravenous immunoglobulin (IVIg) is an appropriate and immediate treatment for myasthenic crises as it rapidly reduces harmful antibody levels and improves muscle strength and respiratory function. Since the patient is having CO2 retention and is having signs of respiratory distress, intubation is also required. Indications for Intubation in Myasthenic Crisis: Clinical signs: Use of accessory muscles, paradoxical/labored breathing, inability to speak full sentences Respiratory parameters: FVC < 15–20 mL/kg, NIF < –20 cm H■O, PaCO■ > 45 mmHg, PaO■ < 60 mmHg, RSBI > 105 Bulbar weakness: Dysphagia, weak cough, pooling of secretions, risk of aspiration IVIg alone (Option A): Does not address respiratory failure, which requires urgent ventilatory support. High flow nasal cannula and IVIg (Option C): Insufficient in impending respiratory failure. Plasma exchange (PLEX) (Option D): Effective but not the immediate step before airway stabilization.

References:

Harrison's Principles of Internal Medicine, 22nd Edition, Page 3632, 3633.

↑ *Back to this question in Part A*

@Neet_pg_bot

Q9: A 60-year-old man presents with progressive muscle weakness, dry mouth, and absent tendon reflexes. He has a history of smoking. Electrophysiological testing reveals post-tetanic potentiation of motor response to nerve stimulation at a frequency of 20–50/sec. Which of the following treatments is most appropriate for this patient? (Q851558)

A. Corticosteroids

B. 3,4-Diaminopyridine

C. Azathioprine

D. Intravenous immunoglobulin (IVIg)

Correct Answer: B. 3,4-Diaminopyridine

■ *Listen (English)*

■ *Listen (Hindi)*

Explanation: The patient's symptoms and diagnostic findings of incremental response on high-frequency stimulation are consistent with Lambert-Eaton myasthenic syndrome. This condition is characterized by muscle weakness, autonomic dysfunction, and impaired neurotransmitter release due to antibodies against presynaptic voltage-gated calcium channels. 3,4-Diaminopyridine is the most appropriate treatment as it enhances neurotransmitter release at the neuromuscular junction, improving muscle strength. Corticosteroids (Option A): Mainly used in autoimmune myasthenia gravis, less effective in LEMS. Azathioprine (Option C): Immunosuppressant used in MG, not first-line in LEMS. Intravenous immunoglobulin (IVIg) (Option D): Reserved for severe or refractory cases; not the first-line therapy.

References:

Harrison's Principles of Internal Medicine, 22nd Edition, Page 3628.

↑ *Back to this question in Part A*

@Neet_pg_bot

Q10: A 50-year-old woman presents with arm weakness, diplopia, and ptosis. Strength improves with repeated activity, and deep tendon reflexes are absent. Repetitive nerve stimulation shows a decremental response at low frequency. Which of the following best explains the underlying defect? (Q851560)

A. Pre junctional defect affecting P/Q voltage gated calcium channels

B. Leading cause is thymic hyperplasia

C. Antibodies Target clustering of Ach receptors

D. Increased effficiency of neuromuscular transmission

Correct Answer: A. Pre junctional defect affecting P/Q voltage gated calcium channels

■ *Listen (English)*

■ *Listen (Hindi)*

Explanation: The patient’s symptoms— proximal weakness , diplopia/ptosis , areflexia , improvement with repeated activity, and a decremental response on low-frequency stimulation —are characteristic of Lambert–Eaton Myasthenic Syndrome (LEMS) . LEMS is caused by a prejunctional defect due to autoantibodies against P/Q-type voltage-gated calcium channels , leading to reduced acetylcholine release. Thymic hyperplasia or anti-AChR antibodies (Options B and C): These are characteristic of Myasthenia Gravis , not LEMS. Increased efficiency of neuromuscular transmission (Option D): Incorrect, because the efficiency of neuromuscular transmission is reduced.

References:

Harrison's Principles of Internal Medicine, 22nd Edition, Page 3628.

↑ *Back to this question in Part A*

@Neet_pg_bot

• [07_Neurology] 054 Multiple Sclerosis Neuromyelitis Optica Spectrum Disorder And Als

« Back to Folder Directory

[07_Neurology] 054 Multiple Sclerosis Neuromyelitis Optica Spectrum Disorder And Als — Quick Jump

Q1 (p. 2330)	*Q2 (p. 2330)*	*Q3 (p. 2331)*	*Q4 (p. 2332)*	*Q5 (p. 2333)*	*Q6 (p. 2333)*
Q7 (p. 2334)	*Q8 (p. 2335)*	*Q9 (p. 2336)*	*Q10 (p. 2336)*	*Q11 (p. 2337)*	*Q12 (p. 2338)*
Q13 (p. 2339)	*Q14 (p. 2340)*	*Q15 (p. 2342)*	*Q16 (p. 2343)*	*Q17 (p. 2344)*	*Q18 (p. 2345)*
Q19 (p. 2347)	*Q20 (p. 2349)*				

Q1: Which of the following is not correct about neuromyelitis optica spectrum disorder? (Q851527)

A. Eye pain with eye movement

B. Longitudinally extensive transverse myelitis

C. Unilateral thinning of optic nerve

D. Afferent pupillary defect

Correct Answer: C. Unilateral thinning of optic nerve

■ *Listen (English)*

■ *Listen (Hindi)*

Explanation: NMOSD usually causes bilateral optic neuritis , unlike MS which more often presents with unilateral involvement and has inflamamtion and thickened appearance on MRI orbits. Eye pain with eye movement (Option A) is a common symptom of optic neuritis in NMOSD. Longitudinally extensive transverse myelitis (LETM) (Option B) is a hallmark of NMOSD, involving ≥3 vertebral segments. Afferent pupillary defect (RAPD) (Option D) occurs due to optic nerve involvement.

References:

Harrison's Principles of Internal Medicine, 22nd Edition, Page 3590.

↑ *Back to this question in Part A*

@Neet_pg_bot

Q2: A 45-year-old man presents with asymmetric muscle weakness in the arms and legs. Nerve conduction studies reveal focal demyelination with conduction block. Anti GM1 antibody is present. Which of the following conditions is most likely indicated by these findings? (Q851540)

A. Amyotrophic Lateral Sclerosis

B. Multifocal Motor Neuropathy with Conduction Block

C. Acute inflammatory demyelinating polyneuropathy

D. Charcot-Marie-Tooth Disease

Correct Answer: B. Multifocal Motor Neuropathy with Conduction Block

■ *Listen (English)*

■ *Listen (Hindi)*

Explanation: Features that support diagnosis of Multifocal motor neuropathy with conduction block are 1. Asymmetric limb weakness, especially in the upper limbs 2. Nerve conduction studies showing focal demyelination with conduction block is a hallmark of MMN 3. Presence of anti-GM1 IgM antibodies supports the diagnosis Amyotrophic Lateral Sclerosis (ALS) (Option A) has LMN and UMN findings. Acute inflammatory demyelinating polyneuropathy (AIDP) (Option C) is caused by Anti GM1 antibodies but has leg weakness > arm weakness and no conduction block on NCV. Charcot-Marie-Tooth Disease (CMT) (Option D) is seen in children with stork leg appearance.

References:

Harrison's Principles of Internal Medicine, 22nd Edition, Page 3524.
https://www.ncbi.nlm.nih.gov/books/NBK554524/

↑ *Back to this question in Part A*

@Neet_pg_bot

Q3: Which of the following is not correct about Spinal muscular atrophy? (Q851539)

A. Cognitive milestones are delayed

B. Tongue fasiculations

C. Risdiplam increases the production of SMN protein

D. Respiratory infections

Correct Answer: A. Cognitive milestones are delayed

■ *Listen (English)*

■ *Listen (Hindi)*

Explanation: Cognitive development is preserved in children with Spinal Muscular Atrophy (SMA), even in severe forms. SMA primarily affects anterior horn cells , leading to motor weakness, flaccid paralysis, and tongue fasciculations (Option B). Unlike cerebral palsy or metabolic disorders, SMA does not impair intellectual or cognitive function. Recurrent pneumonia and respiratory infections are explained by weakness of chest muscles, muscles of inspiration and poor cough effort. (Option D) Treatment Description FDA-Approved Treatments Nusinersen (Spinraza): Increases SMN protein production by modifying splicing of the SMN2 gene. Onasemnogene Abeparvovec (Zolgensma): It is a gene therapy that delivers a functional copy of the SMN1 gene to motor neurons, enabling the production of the SMN protein. Risdiplam (Option C) It is an oral medication that increases the production of SMN protein in the body.

References:

Harrison's Principles of Internal Medicine, 22nd Edition, Page 3524.

↑ *Back to this question in Part A*

@Neet_pg_bot

Q4: A 55-year-old woman with Amyotrophic Lateral Sclerosis is experiencing significant difficulty swallowing . CXR shows evidence of bronchiectasis, Which treatment option is most appropriate for potentially extending survival? (Q851537)

A. Riluzole

B. Monthly broad spectrum antibiotics with N-acetlycystiene

C. Percutaneous Gastrostomy (PEG)

D. Tofersen

Correct Answer: C. Percutaneous Gastrostomy (PEG)

■ *Listen (English)*

■ *Listen (Hindi)*

Explanation: PEG – Prevents aspiration by bypassing the oropharynx, improves nutrition , and is proven to extend survival in ALS with dysphagia . Riluzole (Option A): Slightly prolongs median survival in ALS by 2-3 months but does not address dysphagia or bronchiectasis due to aspiration. Monthly antibiotics with NAC (Option B): May help recurrent infections but is supportive , not definitive or survival-extending in ALS. Tofersen (Option D): Only for SOD1 mutation-positive ALS , which is rare (~2%). No mention of genetic testing in the question. It is latest drug for managment of ALS.

References:

Harrison's Principles of Internal Medicine, 22nd Edition, Page 3524.

↑ *Back to this question in Part A*

@Neet_pg_bot

Q5: A 62-year-old man presents with left hand grip weakness for past one week with difficulty swallowing. On examination tongue fasiculations are present, depressed gag reflex with right leg showing spasticity with brisk knee and ankle jerks. His daughter tells that their grandfather also died due to some neurological illness. Which of the following tests will be least contributory for diagnosis of this patient? (Q851536)

A. Electromyography

B. Genetic testing

C. Spinal fluid analysis

D. Nerve conduction studies

Correct Answer: C. Spinal fluid analysis

■ *Listen (English)*

■ *Listen (Hindi)*

Explanation: The patient has a combination of LMN and UMN features. Diagnosis suspected is amyotrophic lateral sclerosis. Spinal fluid analysis is normal in ALS. It’s more useful to exclude mimics (e.g., MS, infections, inflammatory disorders). Electromyography (Option A) in ALS shows denervation in multiple regions and chronic reinnervation along with muscle fasicultations Genetic testing (Option B): 5–10% of ALS is inherited (e.g., SOD1, C9orf72), especially in younger or familial cases. Less helpful in sporadic ALS, but overall genetic studies are helpful in diagnosis NCV (Option D0 will helps to differentiate ALS from peripheral neuropathies (which show reduced sensory conduction). In ALS, motor conduction ↓, but sensory normal.

References:

Harrison's Principles of Internal Medicine, 22nd Edition, Page 3521.

↑ *Back to this question in Part A*

@Neet_pg_bot

Q6: Which of the following signs or symptoms is not associated with Amyotrophic Lateral Sclerosis (ALS) ? (Q851535)

A. Fasciculations

B. Hoffman sign

C. Sensory loss

D. Muscle wasting

Correct Answer: C. Sensory loss

■ *Listen (English)*

■ *Listen (Hindi)*

Explanation: ALS does not involve sensory deficits; sensory function remains intact. The presence of significant sensory loss is a distinguishing feature of Subacute Combined Degeneration compared to ALS. ALS has features of both LMN and UMN lesion hence fasiculation, muscle wasting and hoffman sign are present. Hoffman sign is upper limb Babinski equivalent. It has Involuntary flexion of the thumb and/or index finger in response to flick or snap the distal phalanx of the middle or ring finger downward.

References:

Harrison's Principles of Internal Medicine, 22nd Edition, Page 3521.

↑ *Back to this question in Part A*

@Neet_pg_bot

Q7: A 55-year-old man presents with progressive weakness in his limbs, accompanied by muscle wasting and dysarthria. Neurological examination reveals both upper and lower motor neuron signs. Based on the clinical features, which of the following conditions is the most likely diagnosis? (Q851533)

A. Progressive Muscular Atrophy

B. Progressive Lateral Sclerosis

C. Amyotrophic Lateral Sclerosis

D. Progressive Bulbar Palsy

Correct Answer: C. Amyotrophic Lateral Sclerosis

■ *Listen (English)*

■ *Listen (Hindi)*

Explanation: Amyotrophic Lateral Sclerosis is the most common type of motor neuron disease, featuring both upper and lower motor neuron signs, consistent with the patient's symptoms. Types of Motor Neuron Disease

(MND) Type of MND Motor Neuron Involvement Key Symptoms Amyotrophic Lateral Sclerosis Both upper and lower motor neurons Most common form of MND. Weakness and muscle wasting Progressive Muscular Atrophy (Option A ruled out) Predominantly lower motor neurons Described as a " pure lower motor neuron " variant. Weakness and wasting of distal limb muscles Progressive Lateral Sclerosis (Option B ruled out) Primarily upper motor neurons Characterized as a " pure upper motor neuron " variant. Spasticity, few lower motor neuron signs Progressive Bulbar Palsy (Option D ruled out) Early involvement of cranial nerves Dysarthria, dysphagia

References:

Harrison's Principles of Internal Medicine, 22nd Edition, Page 3520.

↑ *Back to this question in Part A*

@Neet_pg_bot

Q8: Which of the following is not correct about Amyotrophic lateral sclerosis? (Q851532)

A. Bunina bodies

B. SOD1 gene mutations

C. Extraocular muscle weakness

D. Can coexist with Frontotemporal dementia

Correct Answer: C. Extraocular muscle weakness

■ *Listen (English)*

■ *Listen (Hindi)*

Explanation: Amyotrophic Lateral Sclerosis is a pure motor neuron disease involving both upper motor neurons and lower motor neurons. It spares sensory pathways and typically does not affect extraocular muscles . Bladder and bowel function are also generally preserved until the late stages. Bunina bodies (Option A) , a pathological hallmark of ALS, are eosinophilic intracytoplasmic inclusions found in the anterior horn cells (LMNs) of the spinal cord and brainstem. SOD1 gene mutations (Option B) lead to oxidative stress and neurotoxicity, contributing to motor neuron degeneration in ALS. The C9orf72 gene is the leading genetic cause of familial ALS and is also commonly associated with familial Frontotemporal Dementia (FTD). (Option D)

References:

Harrison's Principles of Internal Medicine, 22nd Edition, Page 3521.

↑ *Back to this question in Part A*

@Neet_pg_bot

Q9: Which of the following treatments will be used to manage acute attack of NMOSD? (Q851530)

A. Azathioprine

B. Plasmapheresis

C. Cyclophosphamide

D. Monoclonal antibodies

Correct Answer: B. Plasmapheresis

■ *Listen (English)*

■ *Listen (Hindi)*

Explanation: First line drug is IV methyprednisolone. However since it is not in options, plasmapheresis is beneficial in NMOSD and acts by removing pathogenic antibodies from the blood, thereby reducing inflammation and preventing further damage. Azathioprine (Option A): Used for long-term maintenance therapy in NMOSD, not for acute attacks . Cyclophosphamide (Option C): Also used for severe or refractory cases but not first-line in acute management. Monoclonal antibodies (Option D): Like eculizumab, satralizumab, or inebilizumab, are used for relapse prevention , not acute treatment.

References:

Harrison's Principles of Internal Medicine, 22nd Edition, Page 3592.

↑ *Back to this question in Part A*

@Neet_pg_bot

Q10: A 30-year-old female experiences bilateral vision loss and lower limb weakness. MRI of the spinal cord shows lesions spanning more than three vertebral segments. What is the most specific test for diagnosis? (Q851528)

A. Oligoclonal bands in CSF

B. AQP4-IgG antibody testing

C. Evoked potential studies

D. Brain MRI findings

Correct Answer: B. AQP4-IgG antibody testing

■ *Listen (English)*

■ *Listen (Hindi)*

Explanation: The presence of AQP4-IgG (aquaporin 4) antibodies is a highly specific biomarker for Neuromyelitis Optica Spectrum Disorder (NMOSD), distinguishing it from other demyelinating diseases like multiple sclerosis. This test effectively confirms the diagnosis in patients exhibiting characteristic clinical features, such as bilateral optic neuritis and transverse myelitis. Investigations Investigation Description Magnetic Resonance Imaging (MRI) Can show high-signal lesions, typically in periventricular areas. Spinal MRI: Reveals lesions over three spinal segments, distinguishing NMOSD from MS. Cerebrospinal Fluid (CSF) Analysis Lumbar puncture to assess inflammation and rule out other conditions. Pleocytosis: Increased lymphocytes may be observed. Oligoclonal Bands: Less common in NMOSD compared to MS. (Option A ruled out) Evoked Potentials It measures the brain's electrical activity in response to stimuli; it is less used with MRI advancement. (Option C ruled out)

References:

Harrison's Principles of Internal Medicine, 22nd Edition, Page 3590.

↑ *Back to this question in Part A*

@Neet_pg_bot

Q11: A 28-year-old woman presents with subacute onset of blurry vision in one eye and painful eye movements. She reports tingling in both legs and occasional urinary urgency over the past few months. MRI brain shows periventricular white matter lesions perpendicular to the lateral ventricles. CSF shows oligoclonal bands. What is the most likely diagnosis? (Q851513)

A. Neuromyelitis optica

B. Acute disseminated encephalomyelitis

C. Multiple sclerosis

D. Neurosarcoidosis

Correct Answer: C. Multiple sclerosis

■ *Listen (English)*

■ *Listen (Hindi)*

Explanation: Based on classic features of optic neuritis, sensory symptoms, urinary urgency, periventricular lesions and oligoclonal bands in CSF. Diagnosis is Multiple sclerosis (MS) . Neuromyelitis optica (NMO) (Option A) has bilateral optic neuritis and longitudinally extensive transverse myelitis; associated with anti-AQP4 antibodies, no oligoclonal bands. Acute disseminated encephalomyelitis (ADEM) (Option B) occurs post-viral/post-vaccination in children; causes diffuse lesions and altered sensorium and not relapsing symptoms in

adults. Neurosarcoidosis (Option D): May mimic MS but often involves cranial nerves, meninges, and non-caseating granulomas; CSF may show elevated ACE/protein but not oligoclonal bands.

References:

Harrison's Principles of Internal Medicine, 22nd Edition, Page 3577, 3578, 3583.

↑ *Back to this question in Part A*

@Neet_pg_bot

Q12: 30-year-old is diagnosed as case of Neuromyelitis optica. Which of the following cells of brain is damaged in this condition? (Q851525)

A. Neurons

B. Astrocytes

C. Oligodendrocytes

D. Microglia

Correct Answer: B. Astrocytes

■ *Listen (English)*

■ *Listen (Hindi)*

Explanation: NMOSD is an autoimmune demyelinating astrocytopathy caused by AQP4 antbodies that damage the blood brain barrier via complement activation. Aquaporin-4 is a water channel protein highly expressed in astrocyte foot processes, especially around CNS blood vessels.

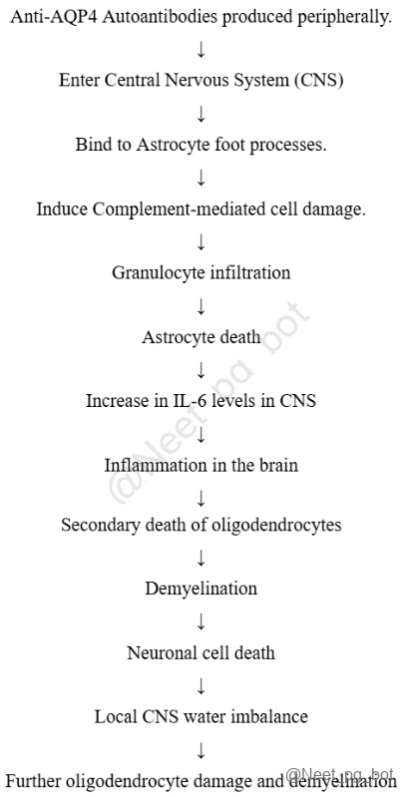

References:

Harrison's Principles of Internal Medicine, 22nd Edition, Page 3590.

↑ *Back to this question in Part A*

@Neet_pg_bot

Q13: 40 year old woman is diagnosed with autoimmune demyelinating astrocytopathy. Which of the following areas of brain are targetted by AQP4 antibodies seen in this condition? (Q851524)

A. Area postrema

B. Spinal cord

C. Circumventricular areas

D. All of the above

Correct Answer: D. All of the above

■ *Listen (English)*

■ *Listen (Hindi)*

Explanation: Autoimmune demyelinating astrocytopathy implies neuromyelitis optica spectrum disorder due to the presence of IgG antibodies against aquaporin-4, which is a hallmark of the disease. Aquaporin-4 antibodies are primarily concentrated in several key areas of the central nervous system Optic nerve → explains optic neuritis and visual loss Spinal cord → associated with longitudinally extensive transverse myelitis Area postrema → causes intractable hiccups, nausea, and vomiting (a classic clue) Circumventricular areas (e.g., periaqueductal gray matter) → due to high expression of aquaporin-4 channels and lack of blood-brain barrier. Area postrema is circumventricular organ implying that option A and C are essentially same.

References:

Harrison's Principles of Internal Medicine, 22nd Edition, Page 3590.

↑ *Back to this question in Part A*

@Neet_pg_bot

Q14: A 38-year-old African woman presents with four months of progressive bilateral visual loss and temporal headaches. Neurological examination reveals spastic paraplegia and brisk knee jerks and ankle jerks. Work up shows Anti- aquaporin-4 antibodies. Which of the following is not seen in this condition ? (Q851523)

A. Crossed hemiplegia

B. Diencephalic syndrome

C. Cloud like tumefactive lesions on MRI head

D. Intracranial hypertension

Correct Answer: D. Intracranial hypertension

■ *Listen (English)*

■ *Listen (Hindi)*

Explanation: The patient's presentation of progressive bilateral visual loss, temporal headaches, and neurological deficits, alongside the detection of aquaporin-4 antibodies , strongly indicates neuromyelitis optica spectrum disorder (NMOSD). Raised ICP is not a feature of NMOSD. Lesion in hypothalamus will cause diencephalic syndrome causing severe emaciation/weight loss despite normal or increased appetite. (Option B) Crossed hemiplegia is due to development of lesions in brainstem . Crossed means cranial nerve palsy will be ipsilateral to lesion along with contralateral hemiplegia. (Option A) Radiological findings in NMOSD Location Characteristics Spinal Cord Longitudinally extensive lesions (≥3 vertebral segments) Central/gray matter involvement T1 hypointensity in acute lesions {{caption_text}} Brain Periependymal lesions around the ventricular system Hemispheric tumefactive lesions (Option C) Cloud-like enhancing lesions. {{caption_text}}



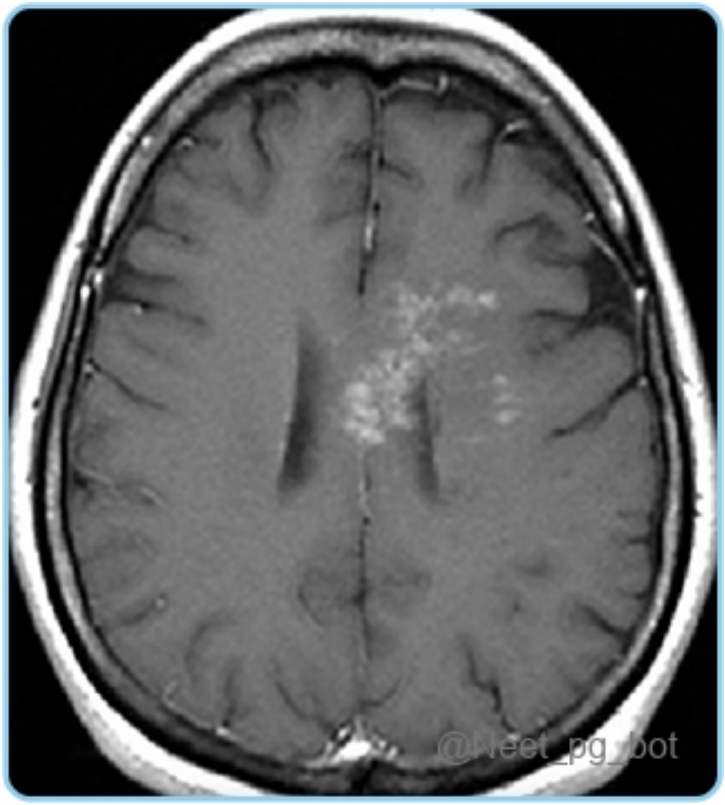

References:

Harrison's Principles of Internal Medicine, 22nd Edition, Page 3590.

↑ *Back to this question in Part A*

@Neet_pg_bot

Q15: A 36-year-old caucasian woman on medical tourism visit presents with a history of recent onset left lower limb weakness, gait unsteadiness, and paresthesias. She experiences an electric shock sensation that radiates down her spine when flexing her neck. An MRI of the brain is given below. What is the most appropriate treatment for this patient's condition? (Q851522)

A. High-dose IV corticosteroids

B. Oral dimethyl fumarate

C. Ocrelizumab

D. Baclofen

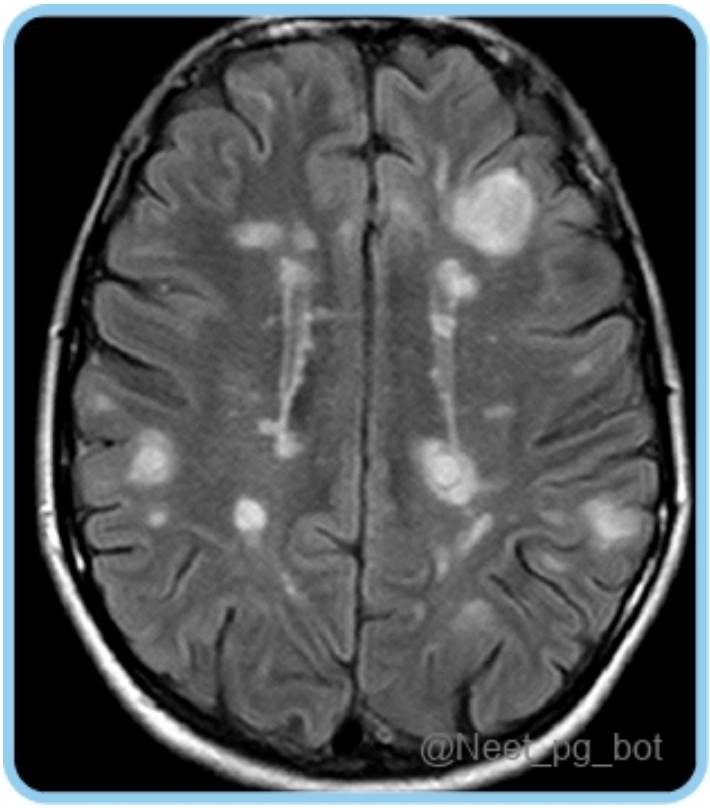

Correct Answer: A. High-dose IV corticosteroids

■ *Listen (English)*

■ *Listen (Hindi)*

Explanation: This case is consistent with Multiple Sclerosis (Acute exacerbation) Because of the patient's symptoms, including limb weakness, gait unsteadiness, paresthesias, and Lhermitte sign. The MRI findings of multiple periventricular white matter lesions further support the diagnosis. High-dose IV corticosteroids are the most appropriate treatment for acute exacerbations of MS, as they reduce inflammation and accelerate recovery from attacks. Treatment Category Interventions Acute Exacerbations High-dose IV corticosteroids first-line treatment for acute flares (Option A) Plasma exchange for patients who do not respond to corticosteroids. Disease-Modifying Therapies (Option B, C) Natalizumab and Ocrelizumab are highly effective for patients who haven't responded to other therapies. Natalizumab: blocks integrin α4, preventing leukocyte adhesion to endothelial cells. It has a risk of PML Ocrelizumab: targets and depletes CD20-positive B cells. Patients with less active disease may be started on oral medications like Dimethyl fumarate or Fingolimod (sphingosine-1-phosphate modulator) β-interferon and Glatiramer have the highest safety profiles but lower effectiveness. Symptomatic Therapy Baclofen used for spasticity (Option D) Cholinergic for urinary retention Anticholinergics for urinary incontinence Carbamazepine, amitriptyline for painful paresthesias Antidepressants Neurogenic bladder treatments Catheterization, muscarinic antagonists, botulinum toxin injection Spasticity treatments (GABA B receptor agonists)

References:

Harrison's Principles of Internal Medicine, 22nd Edition, Page 3585.

↑ *Back to this question in Part A*

@Neet_pg_bot

Q16: A 30-year-old woman presents with a 2-day history of acute, painful vision loss in her left eye, associated with a dull ache that worsens with eye movement. She also reports episodes of leg weakness, difficulty maintaining balance, and tingling sensations in her arms. Her medical history includes recurrent episodes of blurred vision and fatigue, particularly worsening in warm conditions. What is the diagnostic test of choice for this condition? (Q851521)

A. Visual evoked potential

B. Lumbar puncture

C. MRI of the brain and spinal cord

D. CSF electrophoresis for oligoclonal bands

Correct Answer: C. MRI of the brain and spinal cord

■ *Listen (English)*

■ *Listen (Hindi)*

Explanation: This is a case of Multiple Sclerosis (MS), characterized by episodes of neurological symptoms. The patient's symptoms, including acute vision loss, weakness, and sensory disturbances, are consistent with MS. MRI of the brain and spinal cord is the diagnostic test of choice because it can effectively identify the characteristic lesions associated with MS, particularly in the periventricular regions and spinal cord Test Description MRI Imaging modality of choice for MS Shows multiple asymmetric, periventricular white matter lesions (Dawson fingers) Red arrowheads referred to as Dawson ■ngers Active lesions enhanced with gadolinium due to increased BBB permeability Presence of plaques and black holes (T1-weighted) Visual Evoked Potential Assesses optic nerve damage (Option A) CSF Analysis ↑IgG index indicates intrathecal synthesis Agarose electrophoresis: > 2 oligoclonal bands (not found in serum) (Option D) Lumbar puncture: can provide supportive evidence (Option B) > 5 cells/microliter; protein > 1g, cells > 75 suggests alternative diagnosis



References:

Harrison's Principles of Internal Medicine, 22nd Edition, Page 3583.

↑ *Back to this question in Part A*

@Neet_pg_bot

Q17: What additional Mcdonald criteria are required for a diagnosis of Multiple Sclerosis in patient with 2 or more attacks and clinical evidence of 2 or more lesions? (Q851520)

A. None, dissemination in space and in time are met

B. Presence of enhancing and non-enhancing lesions on MRI

C. Presence of CSF oligoclonal bands

D. New T2 or enhancing MRI lesion compared to baseline

Correct Answer: A. None, dissemination in space and in time are met

■ *Listen (English)*

■ *Listen (Hindi)*

Explanation: In a person with 2 or more attacks and clinical evidence of 2 or more lesions, both dissemination in space (DIS) and dissemination in time (DIT) have already been established. DIS is confirmed because multiple lesions exist in the central nervous system (CNS) regions DIT is confirmed because multiple clinical attacks have occurred over time. Therefore, no additional criteria are necessary to make the diagnosis of MS in this scenario Scenario Requirement for diagnosis ≥ 2 Clinical attacks + Objective evidence of ≥ 2 lesions MS can be diagnosed – No further tests needed ≥2 attacks + 1 lesion Dissemination in space required (MRI or new attack at different site) 1 attack + ≥ 2 lesions Dissemination in time required (MRI or second clinical attack) 1 attack + 1 lesion Need both DIS and DIT (Via MRI or clinical evidence) Progressive neurological symptoms from onset (≥1 year) Evidence of progression plus: 2 of 3 DIS in brain DIS in spinal cord Positive CSF (oligoclonal bands or IgG index) Abbreviations: DIT = dissemination in time DIS = dissemination in space CNS = central nervous system CSF = cerebrospinal fluid T2 lesion = hyperintense lesion on T2 weighted MRI

References:

Harrison's Principles of Internal Medicine, 22nd Edition, Page 3583.

↑ *Back to this question in Part A*

@Neet_pg_bot

Q18: Which of the following statements regarding one and a half syndrome in multiple sclerosis is not true? (Q851518)

A. It is characterized by ipsilateral horizontal gaze palsy

B. Limited adduction of the ipsilateral eye

C. The contralateral eye exhibits exotropia and abduction nystagmus.

D. Vertical gaze and convergence are impaired in this syndrome.

Correct Answer: D. Vertical gaze and convergence are impaired in this syndrome.

■ *Listen (English)*

■ *Listen (Hindi)*

Explanation: Vertical gaze is mediated by rostral midbrain. In one and half syndrome the lesion is in the parapontine reticular formation or abducens nerve nucleus and contralateral medial longitudinal fasiculus Clinical Presentation: Ipsilateral horizontal gaze palsy. (Option A ruled out) Limited adduction of the ipsilateral eye (INO). (Option B ruled out) Contralateral eye: Exotropia with abduction nystagmus. (Option C ruled out) Preserved vertical gaze and convergence. (Option D) {{caption_text}} {{caption_text}}

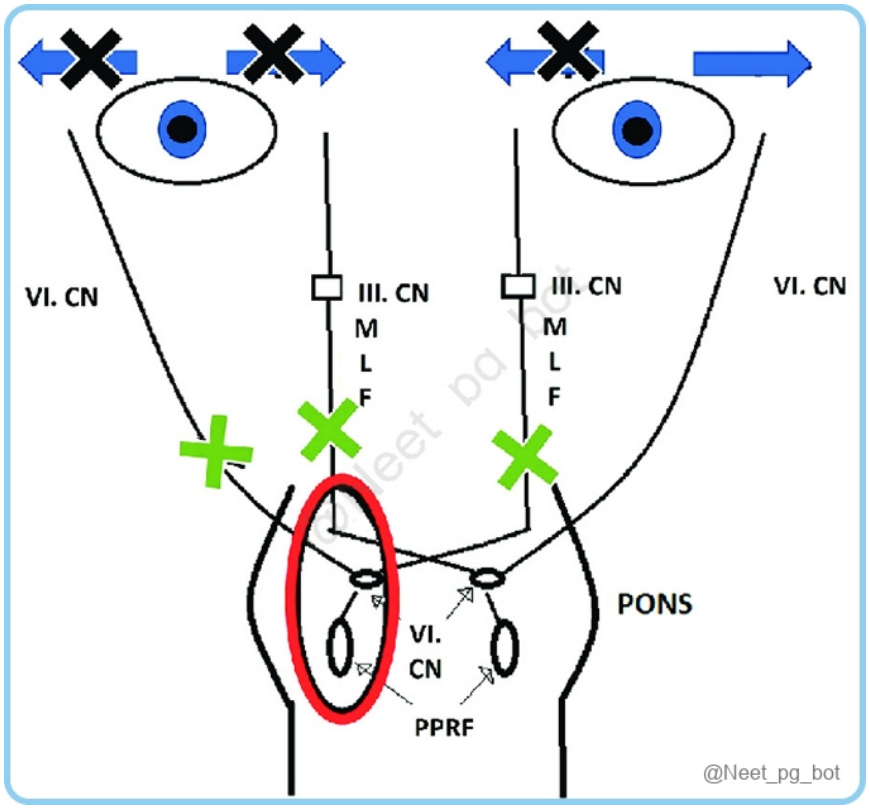

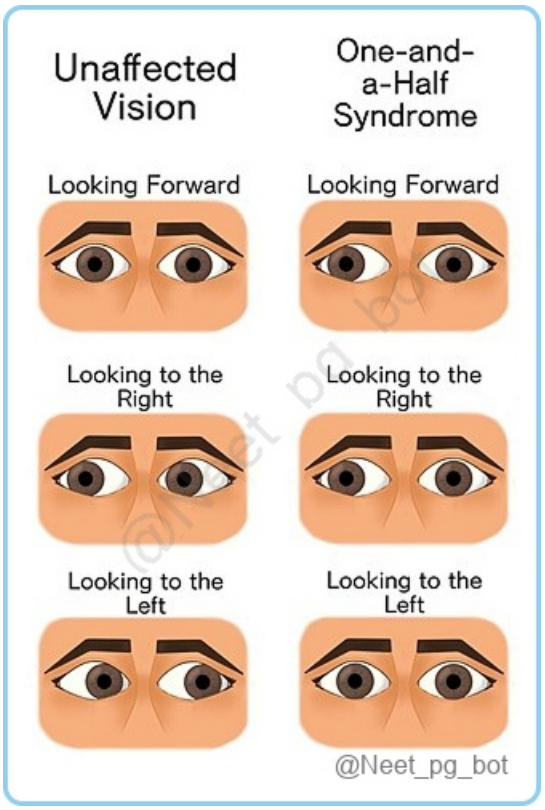

References:

Harrison's Principles of Internal Medicine, 22nd Edition, Page 236.

↑ *Back to this question in Part A*

@Neet_pg_bot

Q19: A 45-year-old woman who is a known case of multiple sclerosis has come for follow up consultation. On examination, the left eye has slowed adduction when attempting to look to the right, and there is horizontal nystagmus in the right eye when it is abducting. Which of the following best explains the underlying pathology of this patient's symptoms? (Q851516)

A. Lesion in the right sixth cranial nerve

B. Lesion in the left sixth cranial nerve

C. Lesion in the left medial longitudinal fasciculus

D. Lesion in the right medial longitudinal fasciculus



Correct Answer: C. Lesion in the left medial longitudinal fasciculus

■ *Listen (English)*

■ *Listen (Hindi)*

Explanation: Based on the history of multiple sclerosis and clinical manifestations the diagnosis is internuclear ophthalmoplegia. In this case, the lesion in the left medial longitudinal fasciculus interrupts communication between the left third cranial nerve nucleus (responsible for adducting the left eye) and the right sixth cranial nerve nucleus (responsible for abducting the right eye). This results in slowed adduction of the left eye when attempting to look to the right and horizontal nystagmus in the right eye as it abducts. {{caption_text}}

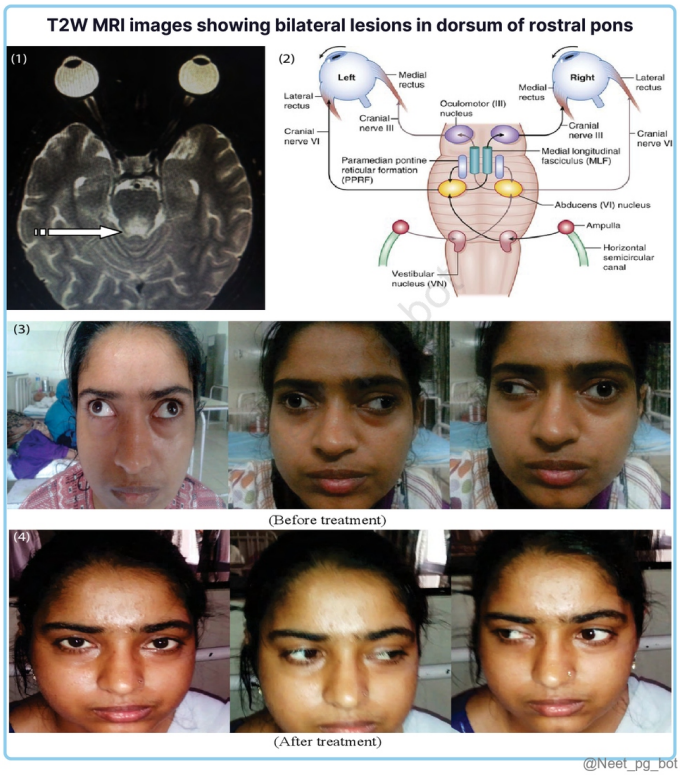

References:

Harrison's Principles of Internal Medicine, 22nd Edition, Page 3578.

↑ *Back to this question in Part A*

@Neet_pg_bot

Q20: A 34-year-old woman with a known diagnosis of multiple sclerosis visited a sauna in her gym. After the visit her vision becomes blurry and her leg weakness worsened that she had to be assisted by gym staff to her house. This presentation is called? (Q851515)

A. Lhermitte’s symptoms

B. Uthoff’s symptoms

C. Ancillary symptoms

D. Internuclear oopthalmoplegia

Correct Answer: B. Uthoff’s symptoms

■ *Listen (English)*

■ *Listen (Hindi)*

Explanation: Uthoff's symptom refers to the temporary worsening of neurological symptoms due to increased body temperature, often triggered by heat exposure, such as spending time in a sauna. This symptom is common in patients with multiple sclerosis. Lhermitte’s symptom (Option A) : An electric shock-like sensation that radiates down the back into the legs. Typically induced by flexion or other movements of the neck. Internuclear ophthalmoplegia (Option D) is caused by a lesion in the medial longitudinal fasciculus (MLF), and is characterized by impaired adduction of the ipsilateral eye and nystagmus of the abducting contralateral eye.

References:

Harrison's Principles of Internal Medicine, 22nd Edition, Page 3578.

↑ *Back to this question in Part A*

@Neet_pg_bot

• [07_Neurology] 055 Cns Hemorrhage Headaches And Migraine

« Back to Folder Directory

[07_Neurology] 055 Cns Hemorrhage Headaches And Migraine — Quick Jump

Q1 (p. 2350)	*Q2 (p. 2351)*	*Q3 (p. 2351)*	*Q4 (p. 2352)*	*Q5 (p. 2353)*	*Q6 (p. 2354)*
Q7 (p. 2355)	*Q8 (p. 2356)*	*Q9 (p. 2356)*	*Q10 (p. 2357)*	*Q11 (p. 2358)*	*Q12 (p. 2359)*
Q13 (p. 2360)	*Q14 (p. 2360)*	*Q15 (p. 2361)*	*Q16 (p. 2362)*	*Q17 (p. 2363)*	*Q18 (p. 2365)*
Q19 (p. 2366)	*Q20 (p. 2367)*	*Q21 (p. 2368)*			

Q1: A 40-year-old woman reports experiencing recurrent headaches that last between 6 and 48 hours. She often feels fatigued and has mood changes before the headaches begin. According to the International Headache Society's criteria, which features are essential for diagnosing her condition as migraine? (Q851065)

A. Bilateral pricking pain with nausea

B. Unilateral pain with photophobia without nausea

C. Unilateral throbbing pain with phonophobia

D. Bilateral pain with photophobia and nausea

Correct Answer: C. Unilateral throbbing pain with phonophobia

■ *Listen (English)*

■ *Listen (Hindi)*

Explanation: Unilateral throbbing pain with phonophobia meets the diagnostic criteria for migraines. It specifies unilateral pain, describes the pain as throbbing (a key characteristic), and includes phonophobia (sensitivity to sound), fulfilling the requirement for at least three features from the specified list. Simplified Diagnostic Criteria for Migraine by International Headache Society Repeated attacks of headache lasting 4–72h in patients with a normal physical examination, no other reasonable cause for the headache, and: At least 2 of the following features: Unilateral pain Throbbing pain Aggravation by movement Moderate or severe intensity Plus at least 1 of the following features: Nausea/vomiting Photophobia and phonophobia

References:

Harrison’s Principles of Internal Medicine, 22nd Edition, Page 3466.

↑ *Back to this question in Part A*

@Neet_pg_bot

Q2: A 35-year-old woman presents with a 9-month history of frequent headaches occurring at least 3 times per week. She describes the pain as a dull, bilateral ache that feels like a tight band around her head. The headaches are often accompanied by neck tension, stress, and fatigue. Which of the following is the most appropriate first-line treatment for this patient's condition? (Q851075)

A. Amitriptyline, starting at 20 mg daily, with gradual increases as needed.

B. Combination of Ibuprofen 400 mg plus acetaminophen 1000 mg.

C. Aspirin and Botulinum toxin type A injections

D. Combination of massage therapy and acupuncture

Correct Answer: A. Amitriptyline, starting at 20 mg daily, with gradual increases as needed.

■ *Listen (English)*

■ *Listen (Hindi)*

Explanation: This patient likely has chronic tension-type headache (TTH) , given her 9-month history of frequent headaches (at least 3 times per week). The pain is described as a dull, bilateral ache , often associated with neck tension, stress, and fatigue , which are characteristic features of TTH. Her report of difficulty concentrating and disrupted sleep further supports the chronic nature of the headaches, distinguishing them from episodic TTH. Amitriptyline is the first-line treatment for chronic tension-type headaches (TTH) . It is a tricyclic antidepressant (TCA) used for prevention , and it should be started at a low dose (10–25 mg daily) and increased gradually. Combination of Ibuprofen 400 mg plus acetaminophen 1000 mg (Option B): Used for acute headache relief, not preventive therapy. Aspirin and Botulinum toxin type A injections (Option C): Botulinum toxin is primarily used for chronic migraine, not tension-type headache. Combination of massage therapy and acupuncture (Option D): Can be adjunctive, but not first-line preventive therapy.

References:

Harrison’s Principles of Internal Medicine, 22nd Edition, Page 3471.

↑ *Back to this question in Part A*

@Neet_pg_bot

Q3: A 58-year-old man presents with recurrent, sharp, electric shock-like pain on the right side of her face, affecting her jaw and cheek. The pain is triggered by light touch, such as brushing her teeth or shaving. She reports these episodes happening multiple times a day and lasting only a few seconds. Which of the following statements is TRUE regarding her condition? (Q851074)

A. The most likely diagnosis is glossopharyngeal neuralgia, as the pain is localized to the jaw and oral cavity and is triggered by chewing.

B. Most commonly caused by vascular compression of the trigeminal nerve, often by the superior cerebellar artery.

C. The primary treatment is surgical decompression of the glossopharyngeal nerve.

D. This patient's condition is most likely to involve the ophthalmic branch (V1) of the trigeminal nerve.

Correct Answer: B. Most commonly caused by vascular compression of the trigeminal nerve, often by the superior cerebellar artery.

■ *Listen (English)*

■ *Listen (Hindi)*

Explanation: This patient has trigeminal neuralgia (TN) , characterized by sharp, electric shock-like pain affecting the maxillary (V2) and mandibular (V3) branches of the trigeminal nerve, triggered by light touch. The condition is most commonly caused by vascular compression , often by the superior cerebellar artery , leading to demyelination of the nerve. Aspect Trigeminal Neuralgia Glossopharyngeal Neuralgia About "Tic douloureux"; recurrent, brief electric shock-like pain; usually V2/V3; triggered by touch, chewing, cold air. Rare; brief sharp unilateral pain in jaw angle, ear, tonsillar fossa, tongue base; triggered by coughing, talking, swallowing (Option A). Etiopathogenesis Mainly vascular compression (superior cerebellar artery); demyelination; also tumors or MS. Idiopathic or secondary: vascular compression, MS, infections, tumors, Eagle syndrome, rarely oropharyngeal cancer. Clinical Features Unilateral, sharp, brief, multiple times/day; trigger zones; V1 rare autonomic signs (Option D). Intense, brief unilateral pain in ear/tongue/tonsil; may cause syncope/bradycardia; relapsing-remitting; weight loss. Diagnosis Clinical ± MRI/MRA for vascular compression; ICHD criteria. Clinical ± MRI/MRA; CT/X-ray for Eagle syndrome; cardiac eval if syncope. Treatment Pharmacologic: Carbamazepine/oxcarbazepine first-line (Option C); second-line: gabapentin, baclofen. Surgery: Microvascular decompression, rhizotomy, peripheral neurectomy. Other: Botulinum toxin, deep brain stimulation. Medications: Carbamazepine/oxcarbazepine; gabapentin, duloxetine. Nerve blocks: anesthetic or radiofrequency. Surgery: microvascular decompression, rhizotomy, stylectomy.

References:

Harrison’s Principles of Internal Medicine, 22nd Edition, Page 3551.

↑ *Back to this question in Part A*

@Neet_pg_bot

Q4: Match the following: 1. Naratriptan a) 5-HT1F Agonist 2. Lasmiditan b) Dopamine Receptor Antagonist 3. Rimegepant c) 5-HT1B/1D Agonist 4. Prochlorperazine d) CGRP Receptor Antagonist (Q851073)

A. 1-d, 2-c, 3-b, 4-a

B. 1-a, 2-c, 3-b, 4-d

C. 1-c, 2-a, 3-d, 4-b

D. 1-b, 2-d, 3-c, 4-a

Correct Answer: C. 1-c, 2-a, 3-d, 4-b

■ *Listen (English)*

■ *Listen (Hindi)*

Explanation: Triptans (5-HT1B/1D Agonists): Sumatriptan, rizatriptan, naratriptan, eletriptan, frovatriptan, zolmitriptan. Gepants (CGRP Receptor Antagonists): Rimegepant, ubrogepant. Ditans (5-HT1F Agonists): Lasmiditan. Dopamine Receptor Antagonists: Metoclopramide, prochlorperazine.

References:

Harrison's Principles of Internal Medicine, 22nd Edition, Page 3467.

↑ *Back to this question in Part A*

@Neet_pg_bot

Q5: A patient with left-sided facial paralysis and arm weakness for the last eight hours. BP on admission is 160/100 mm Hg. Her CT head is normal. What is the next step in the management of this patient? (Q851072)

A. Monitor Blood pressure and neurology consult

B. IV labetalol

C. IV thrombolysis

D. Nimodipine

Correct Answer: A. Monitor Blood pressure and neurology consult

■ *Listen (English)*

■ *Listen (Hindi)*

Explanation: This patient presents with an acute onset of focal neurological deficits (left-sided facial paralysis and arm weakness), which is highly suggestive of an acute ischemic stroke . The CT head is normal , which is expected in early ischemic stroke, as changes may not be visible in the first few hours. The critical factor here is the time of onset , which is 8 hours , placing the patient outside the therapeutic window for IV thrombolysis (4.5 hours) . Stepwise Approach to Acute Ischemic Stroke: Confirm stroke type Non-contrast CT: No hemorrhage Assess time window IV thrombolysis (Alteplase) within 4.5 hours only This patient: 8 hours (NOT eligible) Blood Pressure Management BP = 160/100 mm Hg In ischemic stroke (without thrombolysis): Do NOT lower BP unless

>220/120 mm Hg Mildly elevated BP helps maintain cerebral perfusion (permissive hypertension) Next best step : Monitoring + urgent neurology consultation Plan further evaluation (MRI, vascular imaging, secondary prevention) IV labetalol (Option B) is n ot indicated here as BP is not severely elevated (>220/120 mm Hg) . Aggressive BP reduction may worsen cerebral ischemia. IV thrombolysis (Option C) is c ontraindicated because the patient is outside the 4.5-hour window . Nimodipine (Option D) is u sed in subarachnoid hemorrhage to prevent vasospasm, not in ischemic stroke.

References:

Harrison's Principles of Internal Medicine, 22nd Edition, Page 3453, 3454

↑ *Back to this question in Part A*

@Neet_pg_bot

Q6: A 45-year-old male presents with a history of recurrent headaches. After a thorough evaluation, he is diagnosed with a headache that has a stinging character and characterized by the following features: Duration: 5-240 seconds Attacks: 3-200 attacks per day. Which of the following treatments is most appropriate for this condition? (Q851071)

A. High-flow oxygen

B. Sumatriptan

C. IV Lidocaine

D. Verapamil

Correct Answer: C. IV Lidocaine

■ *Listen (English)*

■ *Listen (Hindi)*

Explanation: The patient in question presents with a type of headache characterized by a duration of 5-240 seconds and a frequency of 3-200 attacks per day. These features align with SUNCT (Short-lasting Unilateral Neuralgiform headache attacks with Conjunctival injection and Tearing) . Duration: Very brief, 5–240 seconds per attack. Frequency: High, 3–200 attacks/day, distinguishing it from cluster headaches (1–8/day). Pain Quality: Unilateral, sharp or stabbing, similar to cluster headaches but shorter. Treatment: IV lidocaine provides relief via sodium channel blockade. High-flow oxygen (Option A) This treatment is effective for Cluster Headaches , as inhaling high-flow oxygen can significantly decrease the severity of the pain. However, it is not indicated for SUNCT, where the duration and frequency of attacks are much different. Sumatriptan (Option B) Triptans, such as Sumatriptan, are typically used for the acute treatment of Cluster Headaches and are effective for relieving pain when used at the onset of an attack. However, they are not the first-line treatment for SUNCT and are generally less effective for this condition. Verapamil (Option D) While preventive medications such as verapamil are commonly used for Cluster Headaches to reduce the frequency of attacks, they do not specifically address acute

SUNCT episodes and are not the preferred initial treatment for this condition.

References:

Harrison’s Principles of Internal Medicine, 22nd Edition, Page 3473

↑ *Back to this question in Part A*

@Neet_pg_bot

Q7: A 70-year-old female presents with a 3-month history of new-onset headaches, scalp tenderness, and jaw claudication. She also reports significant fatigue and unintentional weight loss. Laboratory studies reveal an elevated erythrocyte sedimentation rate (ESR) and C-reactive protein (CRP). What is the most appropriate next step in the management of this patient? (Q851070)

A. Start high-dose corticosteroids

B. Perform temporal artery biopsy

C. Initiate aspirin therapy

D. Refer for imaging studies of the carotid arteries

Correct Answer: A. Start high-dose corticosteroids

■ *Listen (English)*

■ *Listen (Hindi)*

Explanation: The clinical features are suggestive of Giant cell Arteritis Starting high-dose corticosteroids is the most appropriate next step in the management of Giant Cell Arteritis. Prompt initiation of high-dose corticosteroids is crucial to prevent complications, particularly vision loss, which can occur if the condition progresses. Perform temporal artery biopsy (Option B): While a temporal artery biopsy is the gold standard for diagnosis and is often performed, it should ideally be done after the initiation of corticosteroids if the diagnosis of GCA is highly suspected, especially considering the risk of blindness. Initiate aspirin therapy (Option C): Aspirin may be considered for vascular protection, but it is not the primary treatment for GCA. The immediate focus should be on controlling inflammation with corticosteroids. Refer for imaging studies of the carotid arteries (Option D) While imaging can be helpful in assessing the extent of vascular involvement, it is not the immediate step when GCA is suspected. The clinical presentation and laboratory findings are sufficient to start treatment.

References:

Harrison’s Principles of Internal Medicine, 22nd Edition, Page 2903.

↑ *Back to this question in Part A*

@Neet_pg_bot

Q8: Match the variants of Migraine in Column A with their characteristic clinical features in Column B: Column A Column B 1. Ophthalmoplegic Migraine A. Associated with blindness and scintillating scotomas 2. Cluster Headaches B. Retro-orbital pain in males 3. Retinal Migraine C. Associated with occulomotor palsy 4. Familial Hemiplegic Migraine D. Presents with hemiplegia and can be confused with stroke E. Diagnosis often involves neuroimaging to rule out cerebrovascular accidents (Q851069)

A. 1-C, 2-E, 3-A, 4-B

B. 1-C, 2-B, 3-A, 4-D

C. 1-B, 2-E, 3-C, 4-D

D. 1-B, 2-E, 3-A, 4-B

Correct Answer: B. 1-C, 2-B, 3-A, 4-D

■ *Listen (English)*

■ *Listen (Hindi)*

Explanation: Ophthalmoplegic Migraine Ophthalmoplegic migraine can present with neurological deficits, such as third nerve palsy, which may include symptoms like ptosis and squinting. Cluster Headaches Cluster headaches are known for their unilateral, severe pain typically located around the eye, often described as retro-orbital pain. Retinal Migraine Associated with transient vision loss or blindness due to vasospasm of the retinal arteries. Symptoms such as scintillating scotomas are also present. Familial Hemiplegic Migraine Rare type of migraine that includes hemiplegia (temporary paralysis on one side of the body) as a symptom. Because of this, it can easily be confused with a stroke.

References:

Harrison’s Principles of Internal Medicine, 22nd Edition, Page 3462.

↑ *Back to this question in Part A*

@Neet_pg_bot

Q9: A 35-year-old man with a history of chronic migraines visits his physician to discuss treatment options. He is interested in triptans but has some health concerns that he wants to clarify. Which of the following is NOT a contraindication for triptans based on the provided information? (Q851068)

A. History of coronary artery disease

B. History of seasonal allergies

C. Wolff-Parkinson-White syndrome

D. Concurrent use with MAO inhibitors

Correct Answer: B. History of seasonal allergies

■ *Listen (English)*

■ *Listen (Hindi)*

Explanation: Seasonal allergies do not affect the safety or efficacy of triptans and do not pose a risk in the context of migraine treatment. History of coronary artery disease (Option A): Risk of coronary vasospasm; triptans are contraindicated. Wolff-Parkinson-White syndrome (Option C): Contraindicated due to sympathomimetic action that can trigger fast conduction via bundle of kent Concurrent use with MAO inhibitors (Option D): Increases risk of serotonin syndrome and impairs triptan metabolism.

References:

Goodman & Gilman's the Pharmacological Basis of Therapeutics, 14th Edition, Page 293.

↑ *Back to this question in Part A*

@Neet_pg_bot

Q10: A 28-year-old woman completes the MIDAS questionnaire during her follow-up for chronic migraines. Her headaches have significantly impacted her work and social life. What is the primary purpose of the MIDAS assessment? (Q851067)

A. To determine the specific medication needed for treatment.

B. To assess the frequency of headache attacks.

C. To evaluate headache-related disability and its impact on daily activities.

D. To classify the type of headache.

Correct Answer: C. To evaluate headache-related disability and its impact on daily activities.

■ *Listen (English)*

■ *Listen (Hindi)*

Explanation: The MIDAS questionnaire specifically measures how migraines affect a person's productivity in work, school, and social activities, providing insights into their overall disability. MIDAS Test: The MIDAS (Migraine Disability Assessment) is a self-administered questionnaire. It assesses headache-related disability over

the past three months. The questionnaire consists of five questions about productivity loss and limitations in work, school, household, and social activities. It includes a global question on migraine severity, rated from 0 (no pain) to 10 (very severe pain). Additional questions gather information on headache frequency and intensity. The MIDAS is a reliable and valid tool with good test-retest reliability and correlates with clinical needs for medical care. Grading: Total MIDAS scores categorize migraine-related disability into four grades: Grade I: Little or no disability (0–5) Grade II: Mild disability (6–10) Grade III: Moderate disability (11–20) Grade IV: Severe disability (≥ 21)

References:

Harrison's Principles of Internal Medicine, 22nd Edition, Page 3464, 3466.

↑ *Back to this question in Part A*

@Neet_pg_bot

Q11: A 35-year-old obese NRI woman presents to her doctor with a history of frequent migraines. She reports experiencing about ten migraine attacks per month. Her father is a diabetic and underwent CABG recently. She says due to ill health of her father her symptoms tend to last upto 24 hours. Her recent lipid profile is deranged. Which of the following preventive treatments is most appropriate for this patient? (Q851066)

A. Rizatriptan

B. Fremanezumab

C. Propranolol

D. Rimegepant

Correct Answer: B. Fremanezumab

■ *Listen (English)*

■ *Listen (Hindi)*

Explanation: The patient has frequent migraine attacks, experiencing > five per month, which qualifies her for preventive treatment according to clinical guidelines. Fremanezumab once a month is suitable for this patient due to following reasons- Highly effective in frequent migraines No metabolic side effects: Weight-neutral, lipid-neutral, glucose-neutral. This patient has deranged lipids, has obesity and has family history of both diabetes mellitus and heart disease. Once-monthly injection = high compliance . only limitation is high cost Can be used safely in patients with metabolic syndrome, obesity, or diabetes risk. Rizatriptan (Option A): Acute migraine therapy, not preventive. Propranolol (Option C): Beta-blockers are first-line in many patients, but caution in obese patients with migraine comorbidities or cardiovascular concerns may favor CGRP monoclonal antibodies. Rimegepant (Option D): Can be used for acute attacks or prevention, but Fremanezumab is more effective for

high-frequency prophylaxis.

References:

Harrison’s Principles of Internal Medicine, 22nd Edition, Page 3469, 3470.

↑ *Back to this question in Part A*

@Neet_pg_bot

Q12: A 17-year-old boy is brought to the ER after collapsing at a rave party. His friends report that he had been dancing intensely and suddenly developed a severe headache followed by a generalized tonic-clonic seizure. On arrival, he is unconscious with a BP of 180/100 mmHg. NCCT brain shows an hyperdensity in the basal ganglia region. Urine toxicology screen is positive for benzoylecgonine. Which of the following is the most likely cause of his presentation? (Q851054)

A. Acute hypertensive crisis due to pheochromocytoma

B. Intracranial aneurysm rupture

C. Cocaine-induced vasospasm and hypertension

D. Amphetamine-induced serotonin syndrome

Correct Answer: C. Cocaine-induced vasospasm and hypertension

■ *Listen (English)*

■ *Listen (Hindi)*

Explanation: The patient presents with intracerebral hemorrhage (basal ganglia) , severe hypertension, and a positive cocaine metabolite (benzoylecgonine) . Cocaine causes acute hypertension and cerebral vasospasm , precipitating hemorrhagic stroke. Acute hypertensive crisis due to pheochromocytoma (Option A): Usually presents with paroxysmal hypertension, palpitations, and episodic symptoms, not acute basal ganglia hemorrhage in this setting. Intracranial aneurysm rupture (Option B): Typically causes sudden thunderclap headache and subarachnoid hemorrhage, not basal ganglia bleed. Amphetamine-induced serotonin syndrome (Option D): Characterized by hyperthermia, autonomic instability, and neuromuscular abnormalities, not intracerebral hemorrhage.

References:

Harrison’s Principles of Internal Medicine, 22nd Edition, Page 3454.

↑ *Back to this question in Part A*

@Neet_pg_bot

Q13: Which of the following types of headaches is not classified as a primary headache? (Q851064)

A. Tension-type headache

B. Medication overuse headache

C. Migraine

D. Cluster headache

Correct Answer: B. Medication overuse headache

■ *Listen (English)*

■ *Listen (Hindi)*

Explanation: Medication overuse headache is classified as a secondary headache because it results from the frequent use of headache medication including opioids. Tension-type headaches, migraines, and primary stabbing headaches are all considered primary headaches. Primary Headaches Secondary Headaches Migraine (with or without aura) (Option C) Tension-type headache – Most common (Option A) Trigeminal autonomic cephalalgia (cluster) (Option D) Primary stabbing headache Primary coughing headache Primary exertional headache Sex-related headache Thunderclap headache New daily persistent headache syndrome Medication overuse headache (chronic daily headache) Medication overuse headache (chronic daily headache) Intracranial bleeding (subdural hematoma, subarachnoid or intracerebral hemorrhage) Raised intracranial pressure (brain tumor, idiopathic intracranial hypertension) Infection (meningitis, encephalitis, brain abscess) Inflammatory disease (temporal arteritis, other vasculitis, arthritis) Referred pain from other structures (orbit, temporomandibular joint, neck)

References:

Harrison’s Principles of Internal Medicine, 22nd Edition, Page 115, 3469.

↑ *Back to this question in Part A*

@Neet_pg_bot

Q14: A newborn delivered by forceps has a high-pitched cry and bulging anterior fontanelle. The mother notes that the baby seems unusually irritable. Which of the following is the most appropriate initial diagnostic step and management? (Q851063)

A. CT head and surgical evacuation

B. USG skull and phenobarbitone

C. USG skull with phenytoin

D. X-ray skull and lamotrigine

Correct Answer: B. USG skull and phenobarbitone

■ *Listen (English)*

■ *Listen (Hindi)*

Explanation: The newborn has signs suggestive of intracranial hemorrhage , likely due to birth trauma (forceps delivery). The high-pitched cry, bulging anterior fontanelle, and irritability are concerning for increased intracranial pressure (ICP) , potentially due to subdural or epidural hemorrhage . CT scan of the head is the initial diagnostic imaging of choice for detecting intracranial hemorrhage in neonates, especially in emergency situations. Phenobarbital is thought to stabilize blood pressure and potentially offer protection from free radicals CT head and surgical evacuation (Option A): CT is more invasive and usually reserved if USG shows a large hematoma or urgent intervention is needed. USG skull with phenytoin (Option C): Phenytoin is less preferred than phenobarbitone in neonates for seizure control. X-ray skull and lamotrigine (Option D): X-ray cannot detect intracranial hemorrhage, and lamotrigine is not first-line in neonates.

References:

pmc.ncbi.nlm.nih.gov/articles/PMC2901530/

www.ncbi.nlm.nih.gov/books/NBK538310/

↑ *Back to this question in Part A*

@Neet_pg_bot

Q15: A 75-year-old man with atrial fibrillation on warfarin presents with progressive confusion and unsteady gait over the past month. His wife reports he had a minor fall 6 weeks ago. On examination, he is confused, has mild right sided weakness. NCCT brain is given below. Which of the following is correct about this patient? (Q851062)

A. Arterial bleeding with craniotomy

B. Arterial bleeding with craniotomy and ligation of bleeder

C. Venous bleeding with craniotomy

D. Venous bleeding with burr hole surgery



Correct Answer: D. Venous bleeding with burr hole surgery

■ *Listen (English)*

■ *Listen (Hindi)*

Explanation: This case presents classic features of chronic subdural hematoma due to the following reasons: Risk factors: elderly, anticoagulation, brain atrophy, minor trauma Gradual symptom progression over weeks (came at one month) Nonspecific symptoms: confusion, gait issues, mild weakness Left-sided concave hyperdensity with islands of hypodensity due to resorption of blood Hence, the patient will require a Burr hole surgery. It will help in the evacuation of liquified hematoma Arterial bleeding with craniotomy (Option A): Describes epidural hematoma, usually acute with rapid deterioration. Arterial bleeding with craniotomy and ligation of bleeder (Option B): Relevant for epidural hematoma with arterial source, not chronic subdural. Venous bleeding with craniotomy (Option C): Burr hole is less invasive and preferred for chronic subdural; craniotomy reserved for complicated cases.

References:

Harrison’s Principles of Internal Medicine, 22nd Edition, Page 3572, 3573.

↑ *Back to this question in Part A*

@Neet_pg_bot

Q16: A 25-year-old man presents to the emergency department after being struck in the temporal region during a hockey game. Initially conscious at the scene, he now presents with decreasing consciousness, right-sided pupillary dilation, and left hemiparesis. CT head shows a lentiform hyperdense lesion in the right temporal region with 12mm midline shift. Which of the following is most appropriate treatment of this patient? (Q851061)

A. Observe and monitor neurological status

B. Start mannitol and hyperventilate

C. Burr hole followed by craniotomy and ligation of the bleeder

D. Conservative management with anticonvulsants

Correct Answer: C. Burr hole followed by craniotomy and ligation of the bleeder

■ *Listen (English)*

■ *Listen (Hindi)*

Explanation: This case presents a classic epidural hematoma requiring emergency intervention because of: Deteriorating consciousness Focal neurological signs (pupillary dilation, hemiparesis) Significant midline shift (>5mm) Classic temporal location suggesting middle meningeal artery involvement Other indications of Evacuation: Clot >30cc volume Thickness >15 mm GCS <9 Epidural hematoma management: Immediate decompression (burr hole) to relieve pressure Definitive craniotomy to evacuate hematoma Ligation of the middle meningeal artery (the bleeder) Observe and monitor neurological status (Option A): Incorrect because observation alone is dangerous in a deteriorating patient with significant mass effect. Start mannitol and hyperventilate (Option B): Incorrect because while these measures may temporarily help, they are adjuncts to definitive surgical management. Conservative management with anticonvulsants (Option D): Incorrect because conservative management is inappropriate for a large, symptomatic extradural hematoma.

References:

Harrison’s Principles of Internal Medicine, 22nd Edition, Page 3572.
https://www.ncbi.nlm.nih.gov/books/NBK518982/

↑ *Back to this question in Part A*

@Neet_pg_bot

Q17: A 75-year-old man on warfarin (INR 2.5) falls and hits his head. He is initially alert and oriented, but after 2 hours, becomes progressively drowsy and confused. His CT scan is given below. Which of the following is the most likely diagnosis? (Q851060)

A. Epidural hematoma

B. Subdural hematoma

C. Intraparenchymal hemorrhage

D. Subarachnoid hemorrhage



Correct Answer: A. Epidural hematoma

■ *Listen (English)*

■ *Listen (Hindi)*

Explanation: This case presents the classic scenario of an epidural hematoma as suggested by the presence of a lucid interval and CT showing a characteristic biconvex (lentiform) hyperdense lesion . A lucid interval (LI) refers to a brief period of normal consciousness following an initial loss of consciousness, often seen in cerebral concussion or cerebral compression . In cases like epidural hematoma , the lucid interval occurs as the brain temporarily recovers before increased pressure from the hematoma leads to further deterioration. Subdural hematoma (Option B): Usually crescent-shaped, crosses suture lines, and deterioration is more gradual, especially in elderly or anticoagulated patients. Intraparenchymal hemorrhage (Option C): Typically spontaneous, often in hypertensive patients, not directly trauma-related. Subarachnoid hemorrhage (Option D): Presents with sudden, severe “thunderclap” headache, not delayed deterioration.

References:

Harrison’s Principles of Internal Medicine, 22nd Edition, Page 3572

↑ *Back to this question in Part A*

@Neet_pg_bot

Q18: A 52-year-old man presents with headache, left-sided facial, arm, and leg weakness. His sensorium is fast deteriorating, and he is a known case of rheumatic heart disease on warfarin. His INR is 10. The NCCT head is given below. Which of the following is correct about his management? (Q851059)

A. Vitamin K 10mg IV only

B. Fast infusion of fresh frozen plasma

C. Fast infusion of fresh frozen plasma and urgent neurosurgery

D. 4-factor Prothrombin Complex Concentrate and Vitamin K 10mg IV

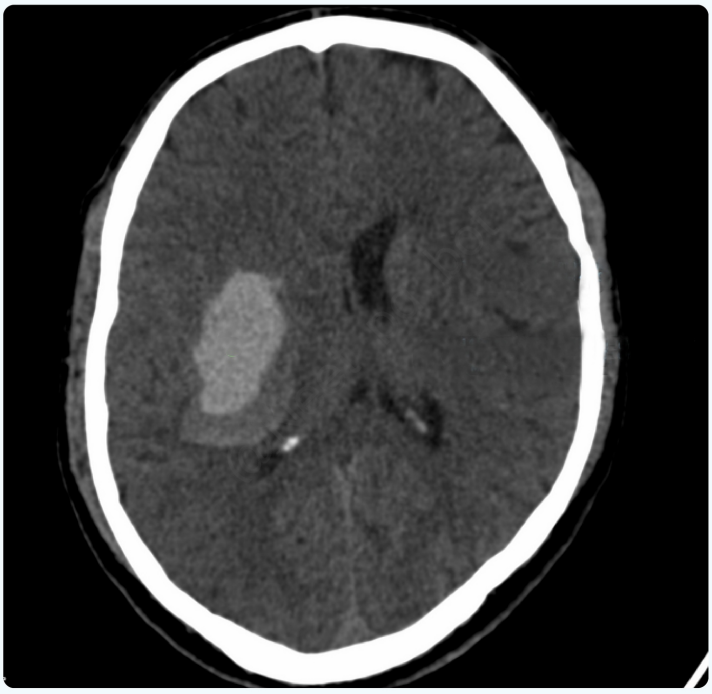

Correct Answer: D. 4-factor Prothrombin Complex Concentrate and Vitamin K 10mg IV

■ *Listen (English)*

■ *Listen (Hindi)*

Explanation: This patient presents with classic features of warfarin-associated intracranial hemorrhage: Patient is on warfarin therapy Supratherapeutic INR 10.0 Acute neurological symptoms (headache, weakness, altered mental status) Confirmed intraparenchymal hemorrhage on CT This represents a life-threatening emergency requiring immediate reversal of anticoagulation by 4-factor Prothrombin Complex Concentrate (PCC) & Vitamin K 10mg IV. Tranexamic acid may also be considered. Vitamin K 10mg IV only (Option A): Too slow to reverse anticoagulation in acute hemorrhage. Fast infusion of fresh frozen plasma (Option B): Works slower than PCC and requires large volume, may worsen intracranial pressure. Fast infusion of fresh frozen plasma and urgent neurosurgery (Option C): Surgery cannot be safely done until coagulopathy is corrected; FFP alone is slower than PCC.

References:

Harrison's Principles of Internal Medicine, 22nd Edition, Page 3455

↑ *Back to this question in Part A*

@Neet_pg_bot

Q19: A 50-year-old hypertensive man suddenly develops facial asymetry and right arm weakness during a meeting. His BP on arrival is 220/130 mmHg. CT shows putaminal hemorrhage. What is the most appropriate immediate management? (Q851058)

A. IV Mannitol

B. Immediate surgical evacuation

C. Nicardipine to achieve target BP of 140/90 mm Hg or lesser

D. Sodium nitroprusside to achieve target BP of 140/90 mm Hg or lesser

Correct Answer: C. Nicardipine to achieve target BP of 140/90 mm Hg or lesser

■ *Listen (English)*

■ *Listen (Hindi)*

Explanation: Nicardipine is recommended as a first-line agent in the acute management of hemorrhagic stroke to reduce elevated blood pressure. According to the latest guidelines, blood pressure should be rapidly but safely lowered to a target of <140/90 mm Hg , as this has been shown to reduce the risk of re-bleeding without increasing the risk of ischemia. Earlier guidelines advocated a more gradual reduction in blood pressure, but recent evidence supports early intensive control for better outcomes. Mannitol (Option A) is generally contraindicated in active CNS bleeding unless there is evidence of raised intracranial pressure with herniation risk, as it may worsen bleeding by altering intracranial hemodynamics. Immediate surgical evacuation (Option B): Indicated only for cerebellar hemorrhage, large lobar hemorrhage with mass effect, or deterioration, not all basal ganglia bleeds. Sodium nitroprusside (Option D) is not preferred due to its tendency to cause a rapid and uncontrolled drop in blood pressure, which can lead to cerebral hypoperfusion and infarction, especially in patients with impaired

cerebral autoregulation during hypertensive crises.

References:

Harrison’s Principles of Internal Medicine, 22nd Edition, Page 3453.

↑ *Back to this question in Part A*

@Neet_pg_bot

Q20: A 65-year-old hypertensive male presents with sudden onset weakness of right face and arm, along with difficulty speaking. He is unable to form words properly but appears to understand commands. Brain imaging shows an acute infarct. Which division of the MCA is most likely involved? (Q851057)

A. Superior division of left MCA

B. Inferior division of left MCA

C. Main trunk of left MCA

D. Penentrating branches of lenticulostriate artery

Correct Answer: A. Superior division of left MCA

■ *Listen (English)*

■ *Listen (Hindi)*

Explanation: The combination of: Right facial weakness Right arm weakness Non-fluent (Broca's) aphasia Preserved comprehension This pattern suggests a superior division MCA stroke in the dominant (left) hemisphere, affecting the frontal opercular region and motor cortex. Inferior division of left MCA (Option B) typically presents with Wernicke's (fluent) aphasia, Poor comprehension, Jargon speech, Superior quadrantanopia, usually no significant motor deficits Main trunk of left MCA (Option C) would cause a complete MCA syndrome, more severe motor deficits including face, arm, and leg-Complete hemiparesis, both expressive and receptive language deficits-Global aphasia (if dominant hemisphere), hemisensory loss, hemianopia. Lenticulostriate branches of left MCA (Option D) causes lacunar syndromes- pure motor stroke or sensory-motor stroke, affects internal capsule, no cortical symptoms like aphasia, affects internal capsule

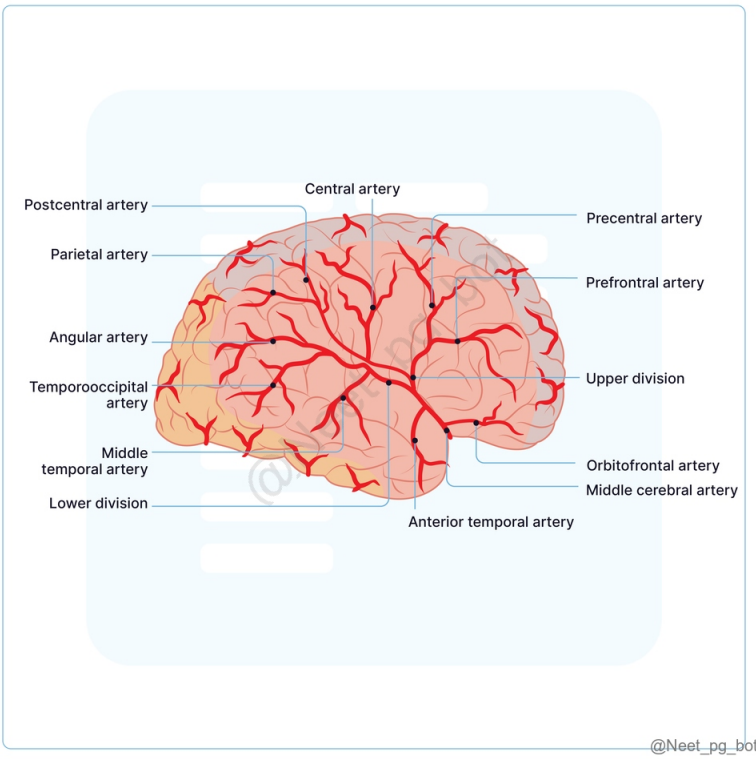

References:

Harrison's Principles of Internal Medicine, 22nd Edition, Page 3429.

↑ *Back to this question in Part A*

@Neet_pg_bot

Q21: An 82-year-old normotensive, non-diabetic man presents with sudden onset confusion and headache. MRI shows multiple lobar hemorrhages. Which is the MOST likely diagnosis? (Q851055)

A. Cerebral amyloid angiopathy

B. Berry aneurysm rupture

C. Hypertensive crisis

D. Venous sinus thrombosis

Correct Answer: A. Cerebral amyloid angiopathy

■ *Listen (English)*

■ *Listen (Hindi)*

Explanation: Cerebral amyloid angiopathy fits the characteristic features of this patient: Elderly patient (>60 years) No history of hypertension Multiple lobar hemorrhages in MRI Acute neurological presentation {{caption_text}} Berry aneurysm rupture (Option B): Usually causes sudden subarachnoid hemorrhage, not multiple lobar hemorrhages. Hypertensive crisis (Option C): Typically causes deep intracerebral hemorrhages (basal ganglia, thalamus) rather than lobar. Venous sinus thrombosis (Option D): Can cause hemorrhagic infarcts, but usually associated with headache, seizures, and venous congestion rather than isolated lobar hemorrhages.

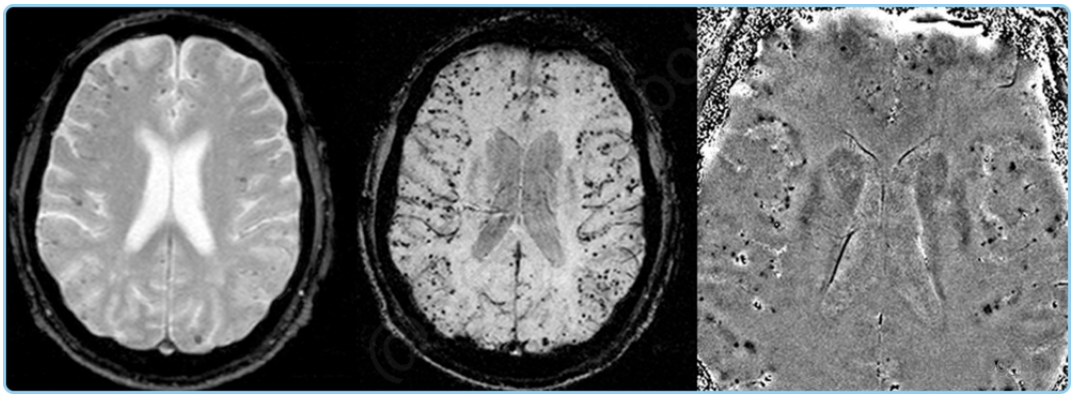

References:

Harrison’s Principles of Internal Medicine, 22nd Edition, Page 3454.

↑ *Back to this question in Part A*

@Neet_pg_bot

• [07_Neurology] 056 Parkinsonism And Parkinson S Disease

« Back to Folder Directory

[07_Neurology] 056 Parkinsonism And Parkinson S Disease — Quick Jump

Q1 (p. 2370) *Q2 (p. 2371)* *Q3 (p. 2372)* *Q4 (p. 2373)* *Q5 (p. 2373)* *Q6 (p. 2374)*
Q7 (p. 2375) *Q8 (p. 2376)* *Q9 (p. 2377)* *Q10 (p. 2377)* *Q11 (p. 2379)* *Q12 (p. 2379)*
Q13 (p. 2380) *Q14 (p. 2381)* *Q15 (p. 2381)* *Q16 (p. 2382)* *Q17 (p. 2383)* *Q18 (p. 2384)*
Q19 (p. 2384)

Q1: A 60-year-old man presents with a 1-year history of progressive unsteadiness while walking, slurred speech, and frequent falls. He also reports urinary urgency and mild orthostatic dizziness. Neurological examination reveals cerebellar signs including dysmetria and truncal ataxia. MRI is shown below. Which of the following is the most likely diagnosis? (Q851452)

A. Parkinson disease

B. Progressive supranuclear gaze palsy

C. Multi-system atrophy

D. Spinocerebellar ataxia



Correct Answer: C. Multi-system atrophy

■ *Listen (English)*

■ *Listen (Hindi)*

Explanation: The patient has combination of basal ganglia features with autonomic insufficiency and cerebellar signs. MRI finding shows widened folia and fissures of cerebellum due to its atrophy and cross-shaped pattern in pons due to the degeneration of pontine neurons and transverse pontocerebellar fibres. This is seen in Multiple-system atrophy

References:

Harrison's Principles of Internal Medicine, 22nd Edition, Page 3496.

↑ *Back to this question in Part A*

@Neet_pg_bot

Q2: Which of the following pathological features is seen in Frontotemporal dementia? (Q851470)

A. α-synuclein-positive Lewy bodies

B. β-amyloid plaques and neurofibrillary tangles

C. Tau-positive neuronal inclusions

D. Prion protein accumulation in the brain

Correct Answer: C. Tau-positive neuronal inclusions

■ *Listen (English)*

■ *Listen (Hindi)*

Explanation: Frontotemporal dementia is often a tauopathy , characterized by the accumulation of hyperphosphorylated tau protein in neurons and glia. Other tauopathies include progressive supranuclear palsy and corticobasal degeneration . Alzheimer's disease shows both β-amyloid plaques and tau tangles . Lewy body dementia is an α-synucleinopathy. Creutzfeldt-Jakob disease involves prion protein accumulation. Tau and α-syn protein aggregation leads to neurotoxicity, resulting in: synaptic dysfunction and neuronal loss

References:

Harrison's Principles of Internal Medicine, 22nd Edition, Page 3486.

↑ *Back to this question in Part A*

@Neet_pg_bot

Q3: A 70-year-old man with advanced Parkinson's disease is considered for deep brain stimulation after experiencing significant motor fluctuations and dyskinesias despite optimal medication therapy. Which of the following brain structures is most commonly targeted in DBS to improve tremor, bradykinesia, and rigidity? (Q851468)

A. Ventral Intermediate Nucleus of the Thalamus

B. Subthalamic Nucleus

C. Globus Pallidus Internus

D. Caudate Nucleus

Correct Answer: B. Subthalamic Nucleus

■ *Listen (English)*

■ *Listen (Hindi)*

Explanation: STN stimulation has been shown to improve tremor, bradykinesia, and rigidity in patients with Parkinson's disease. Targeted Brain Structures in DBS Subthalamic Nucleus (STN) : Improves tremor, bradykinesia, and rigidity. Globus Pallidus Internus (GPi) (Option C) : Reduces dyskinesias and enhances overall motor function. Ventral Intermediate Nucleus of the Thalamus (Option A) : Primarily used for tremor reduction.

References:

Harrison's Principles of Internal Medicine, 22nd Edition, Page 3505.

↑ *Back to this question in Part A*

@Neet_pg_bot

Q4: Which of the following is correct about istradefylline? (Q851467)

A. COMT inhibitor

B. Anticholinergic drug

C. Adenosine A2A receptor antagonists

D. Dopamine agonists

Correct Answer: C. Adenosine A2A receptor antagonists

■ *Listen (English)*

■ *Listen (Hindi)*

Explanation: A2A receptors are located in the indirect pathway of the basal ganglia. By blocking A2A, istradefylline enhances motor activity and helps reduce the inhibitory output from the globus pallidus interna (GPi) → facilitating movement Drug class Example Notes COMT Inhibitors Entacapone, Opicapone Best with levodopa MAO-B Inhibitors Rasagiline, Safinamide Mild-Moderate effect Dopamine Agonists Pramipexole, Rotigotine Useful in younger patients Istradefylline Istradefylline Non-dopaminergic Duodopa/DBS - For advanced PD

References:

Harrison's Principles of Internal Medicine, 22nd Edition, Page 3503.

↑ *Back to this question in Part A*

@Neet_pg_bot

Q5: A 65-year-old man with Parkinson's disease is currently on levodopa with carbidopa but is experiencing significant motor fluctuations and "wearing off" between doses. His neurologist is considering adding a medication to improve his overall motor function. Which of the following is a commonly used dopamine agonist that could be added to his treatment regimen? (Q851465)

A. Apomorphine

B. Selegiline

C. Entacapone

D. Trihexyphenidyl

Correct Answer: A. Apomorphine

■ *Listen (English)*

■ *Listen (Hindi)*

Explanation: Apomorphine is a non-ergot-derived dopamine agonist that can be used to enhance motor function and address "wearing off" symptoms in Parkinson's disease patients. Selegiline (Option B) : This is a MAO-B inhibitor that can provide some symptomatic relief but is not classified as a dopamine agonist. This option is incorrect because it does not fit the category of dopamine agonists. Entacapone (Option C) : This is a COMT inhibitor used to prolong the effects of levodopa but is not a dopamine agonist. This option is incorrect as it does not meet the requirement of being a dopamine agonist. Trihexyphenidyl (Option D) : This is an anticholinergic medication primarily used for tremor control but is not a dopamine agonist. This option is incorrect as it does not belong to the category of dopamine agonists.

References:

Harrison's Principles of Internal Medicine, 22nd Edition, Page 3502.

↑ *Back to this question in Part A*

@Neet_pg_bot

Q6: A 70-year-old man with a diagnosis of Parkinson's disease has been experiencing increased motor fluctuations despite being on a stable dose of levodopa for the past two years. He reports that his symptoms improve shortly after taking his medication but then return before his next dose is due. The physician considers adding a medication to help extend the effect of his current treatment. Which of the following is the most appropriate addition to his regimen? (Q851463)

A. Dopamine agonist

B. COMT inhibitor

C. Anticholinergic agent

D. Beta blocker

Correct Answer: B. COMT inhibitor

■ *Listen (English)*

■ *Listen (Hindi)*

Explanation: COMT inhibitors, such as entacapone, block the breakdown of levodopa, thereby extending its duration of action and addressing the "wearing off" phenomenon. Dopamine agonist (Option A) : These medications mimic dopamine effects in the brain and can be used in Parkinson's treatment but do not specifically address the issue of "wearing off" associated with levodopa therapy. This option is incorrect as it does not directly prolong the effect of levodopa. Anticholinergic agent (Option C) : These medications can help with tremors in early PD but are not effective in managing motor fluctuations or "wearing off" associated with levodopa. This option is incorrect as it does not address the patient's specific issue. Beta-blocker (Option D) : Beta-blockers are used for managing symptoms like tremors or hypertension but do not have an effect on extending levodopa's duration of action or reducing "wearing off."

References:

Harrison's Principles of Internal Medicine, 22nd Edition, Page 3503.

↑ *Back to this question in Part A*

@Neet_pg_bot

Q7: A 68-year-old woman presents with a 1-year history of progressive difficulty controlling her right arm. She reports that her arm occasionally moves on its own, and she has trouble performing simple tasks like buttoning her shirt. On examination, she has dystonic posturing of the right hand, mild bradykinesia, and intermittent myoclonic jerks. Her cognitive function appears intact except for mild apraxia. What is the most likely diagnosis? (Q851461)

A. Parkinson's disease

B. Corticobasal syndrome

C. Multiple system atrophy

D. Progressive supranuclear palsy

Correct Answer: B. Corticobasal syndrome

■ *Listen (English)*

■ *Listen (Hindi)*

Explanation: A neurodegenerative condition involving parkinsonism, dystonia, myoclonus, and cortical features such as apraxia and the alien limb phenomenon. The patient's symptoms, including dystonia, myoclonus, and alien limb, are classic for corticobasal syndrome. Parkinson's disease (Option A) : A neurodegenerative disorder primarily characterised by tremor, bradykinesia, rigidity, and postural instability. This option is incorrect as the presence of alien limb phenomenon and apraxia points more towards corticobasal syndrome. Multiple system atrophy (Option C) : A Parkinsonian syndrome with features of autonomic dysfunction, such as orthostatic hypotension, and cerebellar signs. This is incorrect as there is no mention of autonomic or cerebellar dysfunction

in the patient. Progressive supranuclear palsy (Option D) : A disorder that presents with early postural instability, vertical gaze palsy, and parkinsonism. This option is incorrect because the patient does not display the characteristic eye movement abnormalities seen in PSP.

References:

Harrison's Principles of Internal Medicine, 22nd Edition, Page 3488, 3497.

↑ *Back to this question in Part A*

@Neet_pg_bot

Q8: A 65-year-old man presents with his family, who report that over the past year, he has developed significant personality changes. He has become socially inappropriate, often acting impulsively and showing a lack of empathy. He also struggles to initiate tasks and frequently forgets appointments. On examination, his language production is impaired, though his comprehension remains intact. What is the most likely diagnosis? (Q851459)

A. Alzheimer's disease

B. Vascular dementia

C. Frontotemporal dementia

D. Lewy body dementia

Correct Answer: C. Frontotemporal dementia

■ *Listen (English)*

■ *Listen (Hindi)*

Explanation: Patient is having neurodegenerative disorder affecting the frontal lobe leading to personality changes, disinhibition, difficulty initiating tasks. Impaired language (esp. semantic dementia), loss of empathy, poor emotional processing are features of temporal lobe involvement. Alzheimer's disease (Option A) has 4A: aphasia, apraxia, anosoagnosia, amnesia. Vascular dementia (Option B) : Usually presents with a stepwise decline in cognitive function and may include focal neurological deficits. This is incorrect as the patient's symptoms are not consistent with the stepwise deterioration typical of vascular dementia. Lewy body dementia (Option D) : Characterised by visual hallucinations, cognitive fluctuations, and parkinsonism. This is incorrect as the patient does not show the hallucinations or motor symptoms associated with this condition.

References:

Harrison's Principles of Internal Medicine, 22nd Edition, Page 3486.

↑ *Back to this question in Part A*

@Neet_pg_bot

Q9: A 65-year-old male presents with frequent, unexplained falls. On examination, impaired downward gaze, neck hyperextension, and square wave jerks in his eye movements are present. MRI head is shown below. Diagnosis is? (Q851456)

A. Multiple system atrophy (MSA)

B. Progressive supranuclear gaze palsy (PSP)

C. Huntington chorea disease (HD)

D. Parkinson disease (PD)

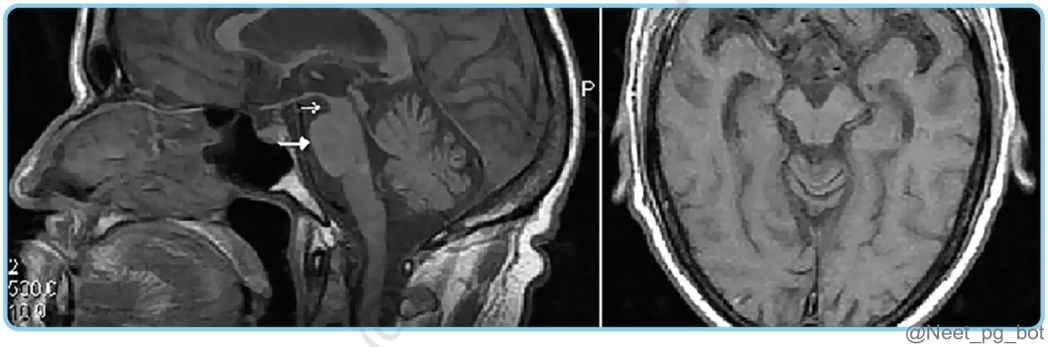

Correct Answer: B. Progressive supranuclear gaze palsy (PSP)

■ *Listen (English)*

■ *Listen (Hindi)*

Explanation: The key word in this case with recurrent falls is impaired downward gaze with square wave jerks in eyes. MRI brain shows humming bird sign. Diagnosis is Progressive supranuclear gaze palsy . MSA (Option A) is ruled at it has autonomic insufficiency with or without cerebellar features. HD (Option C) presents with Chorea and dementia. PD (Option D) presents with bradykinesia with resting tremors and rigidity.

References:

Harrison's Principles of Internal Medicine, 22nd Edition, Page 3497.

↑ *Back to this question in Part A*

@Neet_pg_bot

Q10: 60 year old man with multiple system atrophy is having dizzy spells and tilt table test is positive. MRI head is shown below. Which of the following is most appropriate treatment for this case? (Q851454)

A. Tertrabenazine

B. Levodopa plus Carbidopa

C. Midodrine

D. Hydrocortisone



Correct Answer: C. Midodrine

■ *Listen (English)*

■ *Listen (Hindi)*

Explanation: MRI shows Prominent cerebellar sulci and fissures and Mild atrophy of the brainstem suggesting MSA. Midodrine is an alpha-1 adrenergic agonist that causes vasoconstriction, thereby increasing blood pressure. It is a commonly used medication to treat symptomatic orthostatic hypotension, which aligns well with the patient's symptoms (dizzy spells, positive tilt table test) in the context of MSA.

References:

Harrison's Principles of Internal Medicine, 22nd Edition, Page 1936.

↑ *Back to this question in Part A*

@Neet_pg_bot

Q11: Which of the following is a must have criteria for diagnosis of Parkinson disease ? (Q851349)

A. Bradykinesia

B. Cog wheel rigidity

C. Postural instability

D. Tremors that worsen with goal directed activity

Correct Answer: A. Bradykinesia

■ *Listen (English)*

■ *Listen (Hindi)*

Explanation: Must have criteria for diagnosis of PD is bradykinesia and progressive reduction in speed and amplitude during continued movement (e.g., finger tapping or hand opening-closing). Tremors that worsen with goal directed activity are a feature of essential tremors. Cog wheel rigidity and postural instability can be present in atypical parkinsonism also.

References:

Harrison's Principles of Internal Medicine, 22nd Edition, Page 3495.
https://pmc.ncbi.nlm.nih.gov/articles/PMC2605160/

↑ *Back to this question in Part A*

@Neet_pg_bot

Q12: Which of the following is not correct about managment of Parkinson disease? (Q851451)

A. Rotigotine is ergot derived D2 receptor agonist

B. Entacapone reduces wearing off phenomenon with levodopa

C. Amantadine reduces levodopa induced peak dose dyskinesias

D. Istradefylline is adjunct to levodopa to reduce off time

Correct Answer: A. Rotigotine is ergot derived D2 receptor agonist

■ *Listen (English)*

■ *Listen (Hindi)*

Explanation: Rotigotine is a non-ergot dopamine agonist that acts on D2/D3 receptors and is delivered via a transdermal patch . Entacapone is a COMT inhibitor that helps reduce "wearing-off" by prolonging levodopa's effect. (Option B) Amantadine is effective in reducing peak-dose dyskinesias due to NMDA receptor antagonism. (Option C) Istradefylline , a selective adenosine A2A antagonist, is used as adjunct to levodopa to reduce OFF time . (Option D)

References:

Harrison's Principles of Internal Medicine, 22nd Edition, Page 3502.

↑ *Back to this question in Part A*

@Neet_pg_bot

Q13: Which gene is responsible for development of juvenile-onset Parkinson's disease? (Q851416)

A. PARK-GBA

B. PARK-LRRK2

C. PARK-Parkin

D. All of the above

Correct Answer: C. PARK-Parkin

■ *Listen (English)*

■ *Listen (Hindi)*

Explanation: PARK-Parkin mutations are the most common genetic cause of juvenile-onset Parkinson's disease. Genetic Causes of Parkinson's Disease Classical PD PARK-SNCA Missense mutations cause classical Parkinsonism. PARK-LRRK2 Clinically typical PD. Most common gene causing PD in Ashkenazi Jews and North African Berber Arabs. Most common gene responsible for sporadic cases. (Option B ruled out) PARK-VPS35 Clinically typical PD. PARK-GBA (glucocerebrosidase gene) Clinically typical PD—possibly faster progression and greater risk of cognitive impairment. Most common genetic association with PD. (Option A ruled out) Early-onset PD PARK-Parkin Often presents with dystonia, typically in a leg. Most common gene responsible for juvenile-onset PD. (Option C) PARK-PINK1 Often presents with psychiatric features. PARK-DJ1 -

References:

Harrison's Principles of Internal Medicine, 22nd Edition, Page 3498, 3499.

↑ *Back to this question in Part A*

@Neet_pg_bot

Q14: Which of the following is not a clinical feature of atypical parkinsonism? (Q851415)

A. Slow ocular saccades

B. Resting pill rolling tremor

C. Early gait impairment

D. Poor response to Levodopa

Correct Answer: B. Resting pill rolling tremor

■ *Listen (English)*

■ *Listen (Hindi)*

Explanation: Atypical parkinsonism usually lacks a resting tremor. Symptoms and signs of atypical Parkinsonism: Early speech impairment Early gait impairment (Option C ruled out) Absent resting tremor (Option B) Lack of motor asymmetry Early falls Poor or no response to an adequate trial of levodopa (Option D ruled out) More aggressive clinical course

References:

Harrison's Principles of Internal Medicine, 22nd Edition, Page 3496, 3497.

↑ *Back to this question in Part A*

@Neet_pg_bot

Q15: A 15-year-old boy is brought by his parents due to involuntary movements of his hands, behavioral changes such as irritability and poor concentration affecting school performance and attendance. On examination, choreiform movements in hands are noted along with pallor. Work up shows elevated transaminases and increased PT and urine examination showing proteinuria and glucosuria. Which of the following is first differential diagnosis for this patient? (Q851414)

A. Wilson’s Disease

B. Sydenham Chorea

C. Huntington’s Disease

D. Spinocerebellar Ataxia

Correct Answer: A. Wilson’s Disease

■ *Listen to Audio 1*

Explanation: isease: This adolescent presents with neuropsychiatric symptoms (behavioral changes, poor concentration), movement disorder (choreiform movements), hepatic involvement (elevated transaminases, prolonged PT), and renal tubular dysfunction (proteinuria, glucosuria). These features are classical for Wilson’s disease, an autosomal recessive disorder of copper metabolism. Early recognition is crucial to prevent progression. Incorrect Options: Option B - Sydenham Chorea: Sydenham chorea typically occurs post-streptococcal infection and presents with isolated choreiform movements and behavioral changes, usually without liver or renal involvement. Option C - Huntington’s Disease: Huntington’s disease is a genetic adult-onset chorea with cognitive decline and psychiatric symptoms, rarely presenting in adolescence or with liver dysfunction. Option D - Spinocerebellar Ataxia: Spinocerebellar ataxias mainly present with progressive gait and limb ataxia, dysarthria, and cerebellar signs, not with hepatic or renal involvement or isolated choreiform movements in a 15-year-old.

References:

Harrison's Principles of Internal Medicine, 22nd Edition, Page 3338, 3339.

↑ *Back to this question in Part A*

@Neet_pg_bot

Q16: Which of the following medications is least likely to contribute to the development of drug induced parkinsonism? (Q851412)

A. Haloperidol

B. Risperidone

C. Domperidone

D. Metoclopramide

Correct Answer: C. Domperidone

■ *Listen (English)*

■ *Listen (Hindi)*

Explanation: Domperidone is a dopamine receptor blocker but does not cross the blood-brain barrier, making it less likely to cause drug-induced Parkinsonism compared to other dopamine-blocking agents. Drugs frequently causing Parkinsonism. Drug Class Examples Typical antipsychotics Chlorpromazine, Prochlorperazine, Perphenazine, Fluphenazine, Promethazine, Haloperidol, Pimozide, Sulpiride Atypical antipsychotics Risperidone,

Olanzapine, Ziprasidone, Aripiprazole Dopamine depleters Reserpine, Tetrabenazine Calcium-channel blockers Flunarizine, Cinnarizine Antiemetics Metoclopramide, Levosulpiride, Clebopride

References:

https://pmc.ncbi.nlm.nih.gov/articles/PMC3325428/

↑ *Back to this question in Part A*

@Neet_pg_bot

Q17: A 68-year-old man presents with difficulty in initiating movements like getting out of a chair or toilet seat . He experiences a resting tremor in his right hand and has noticed a decline in his balance, leading to several near falls. His Family members notice that he does not do activitites that he once liked. He is at risk of developing all of the following except? (Q851409)

A. REM sleep disorders

B. Decreased sweating

C. Restless leg syndrome

D. Urinary urgency

Correct Answer: B. Decreased sweating

■ *Listen (English)*

■ *Listen (Hindi)*

Explanation: The patient is presenting with symptoms consistent with Parkinson's disease In Parkinson's disease, patients are more likely to experience increased sweating, along with a range of other non-motor symptoms such as REM disorders, restless leg syndrome, and urinary urgency. Category Non-Motor Symptoms Autonomic Dysfunction Neurogenic orthostatic hypotension Increased sweating Oily skin Constipation Sexual dysfunction Urinary urgency Dysphagia Neuropsychiatric Symptoms Dementia (advanced disease) Executive/visuospatial dysfunction Visual hallucinations Delusions Sleep disorders Insomnia Restless leg syndrome REM disorders Daytime sleepiness with sleep attacks Vivid dreams Sleep fragmentation (night awakenings) Depression Anxiety Apathy Anosmia

References:

Harrison's Principles of Internal Medicine, 22nd Edition, Page 3494.

↑ *Back to this question in Part A*

@Neet_pg_bot

Q18: Which of the following indicates that patient is having atypical parkinsonism? (Q851400)

A. Tremors that disappear on goal-directed activity

B. Recurrent falls due to downward gaze palsy

C. Pill rolling tremors with low frequency

D. Bradykinesia

Correct Answer: B. Recurrent falls due to downward gaze palsy

■ *Listen (English)*

■ *Listen (Hindi)*

Explanation: Recurrent falls due to downward gaze palsy is a feature of Progressive supranuclear gaze palsy. It is atypical parkinsonism. Tremors that disappear on goal directed activity implies resting tremors which are seen in PD. Low frequency means frequency less than 8 Hz. PD has pill rolling tremors that 4-6 Hz frequency and are asymetrical. Bradykinesia is a must have criteria for considering diagnosis of PD. Tremors that disappear on goal-directed activity (Option A): This describes a resting tremor , the most common sign of Parkinson's Disease. It stops when the patient moves to perform a task. Pill-rolling tremors with low frequency (Option C): This is the "classic" PD tremor. It usually occurs at a frequency of 3–6 Hz and involves the thumb and index finger moving against each other. It is a hallmark sign of dopamine depletion in the substantia nigra. Bradykinesia (Option D): Must have criteria for PD. It manifests as a progressive loss of amplitude or speed during repetitive movements (like finger tapping).

References:

Harrison's Principles of Internal Medicine, 22nd Edition, Page 3497.

↑ *Back to this question in Part A*

@Neet_pg_bot

Q19: Involvement of the marked area of brain will result in which of the following disease? (Q851350)

A. Weber syndrome

B. Parkinson disease

C. Nonthangel syndrome

D. Perinaud syndrome

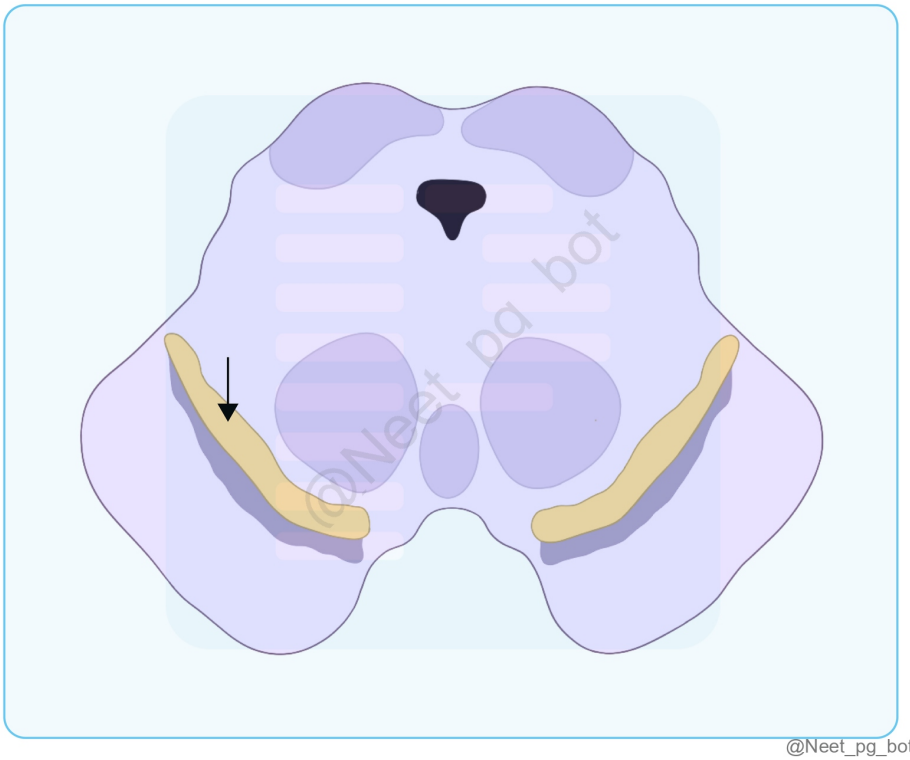

Correct Answer: B. Parkinson disease

■ *Listen (English)*

■ *Listen (Hindi)*

Explanation: The area marked is Substania nigra pars compacta. Degeneration of dopaminergic neurons occurs in the pars compacta that leads to reduced dopamine levels in the striatum (caudate + putamen). The hallmark histopathology includes: loss of pigmented neurons in SNpc . The area ventral to arrow position is substantia nigra pars reticulata is GABAergic and is involved in output pathways from the basal ganglia. SNpr may be functionally affected later, but not the focus of neurodegeneration. Weber syndrome (Option A) occurs due to involvement of crus cerebri which are present anteriorly in this image. For Perinaud syndrome (Option D) , the lesion is pinealoma that will affect the most posterior part of this diagram.

References:

Harrison's Principles of Internal Medicine, 22nd Edition, Page 3494.

↑ *Back to this question in Part A*

@Neet_pg_bot

• [07_Neurology] 057 Meningitis And Cns Infections

« Back to Folder Directory

[07_Neurology] 057 Meningitis And Cns Infections — Quick Jump

Q1 (p. 2386)	*Q2 (p. 2390)*	*Q3 (p. 2392)*	*Q4 (p. 2393)*	*Q5 (p. 2394)*	*Q6 (p. 2395)*
Q7 (p. 2396)	*Q8 (p. 2397)*	*Q9 (p. 2397)*	*Q10 (p. 2398)*	*Q11 (p. 2399)*	*Q12 (p. 2400)*
Q13 (p. 2402)	*Q14 (p. 2403)*	*Q15 (p. 2403)*	*Q16 (p. 2404)*	*Q17 (p. 2405)*	*Q18 (p. 2406)*
Q19 (p. 2408)	*Q20 (p. 2408)*	*Q21 (p. 2410)*	*Q22 (p. 2411)*	*Q23 (p. 2411)*	*Q24 (p. 2412)*

Q1: A 32 year old HIV-positive truck driver presents with fever, headache and drowsiness. Lumbar puncture is performed, and CSF shows elevated opening pressure with 20 lymphocytes /cu.mm with low sugar and protein of 60 mg/dl. MRI of the brain is shown below. Which of the following is the most likely diagnosis? (Q851546)

A. Tuberculous meningitis

B. Cryptococcal meningitis

C. Cytomegalovirus encephalitis

D. Toxoplasmosis

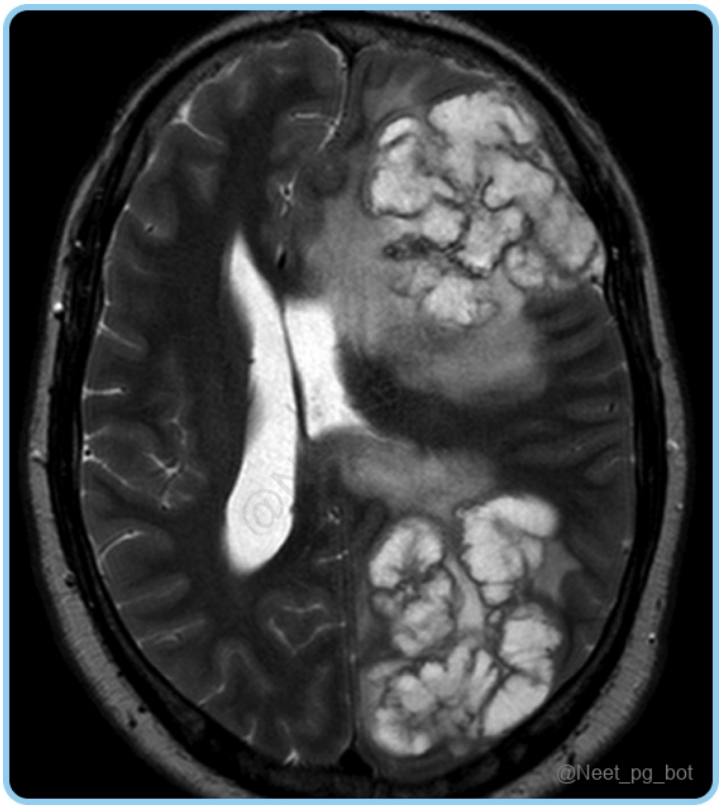

Correct Answer: B. Cryptococcal meningitis

■ *Listen (English)*

■ *Listen (Hindi)*

Explanation: The MRI shows dilated perivascular (Virchow–Robin) spaces filled with gelatinous material—classically called “soap-bubble lesions” , seen in Cryptococcal meningitis , especially in AIDS patients with very low CD4 counts. CSF findings (↑ opening pressure, lymphocytic pleocytosis, ↓ sugar, mildly ↑ protein) strongly support cryptococcal infection . Tuberculous meningitis (Option A): Typically presents with a subacute onset, and CSF shows a lymphocytic pleocytosis, low glucose, and high protein; encapsulated yeast is not seen. Cytomegalovirus encephalitis (Option C): MRI brain will show periventricular and subependymal hyperintensities with contrast enhancement. Lots of time it will co-exist with CMV retinitis showing pizza pie retinopathy. Toxoplasmosis (Option D): Usually presents with multiple ring-enhancing lesions on MRI, but does not involve encapsulated yeast or fungal elements in the CSF. Staining Imaging {{caption_text}} {{caption_text}} India ink staining of Cryptococcus neoformans {{caption_text}} Gram staining of the CSF reveals clusters of thin-walled, encapsulated yeast forms of various sizes with narrow-based budding consistent with Cryptococcus. {{caption_text}} MRI showing “Soap bubble appearance” of C.Neoformans

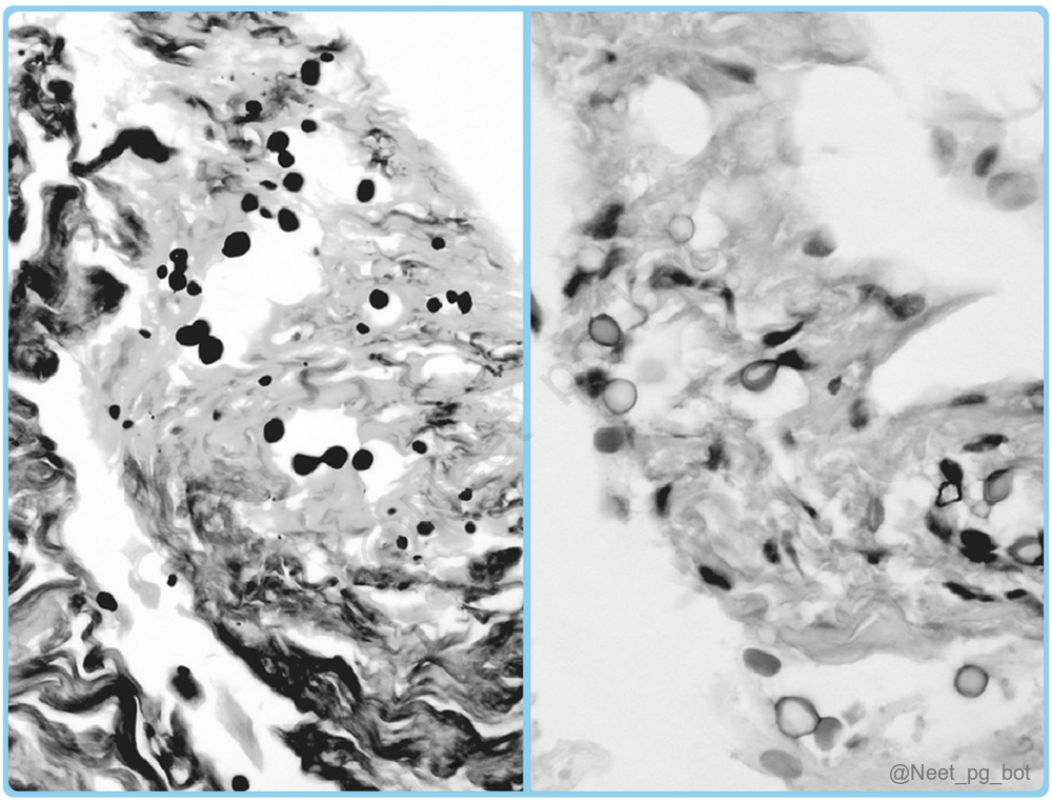
@Neet_pg_bot

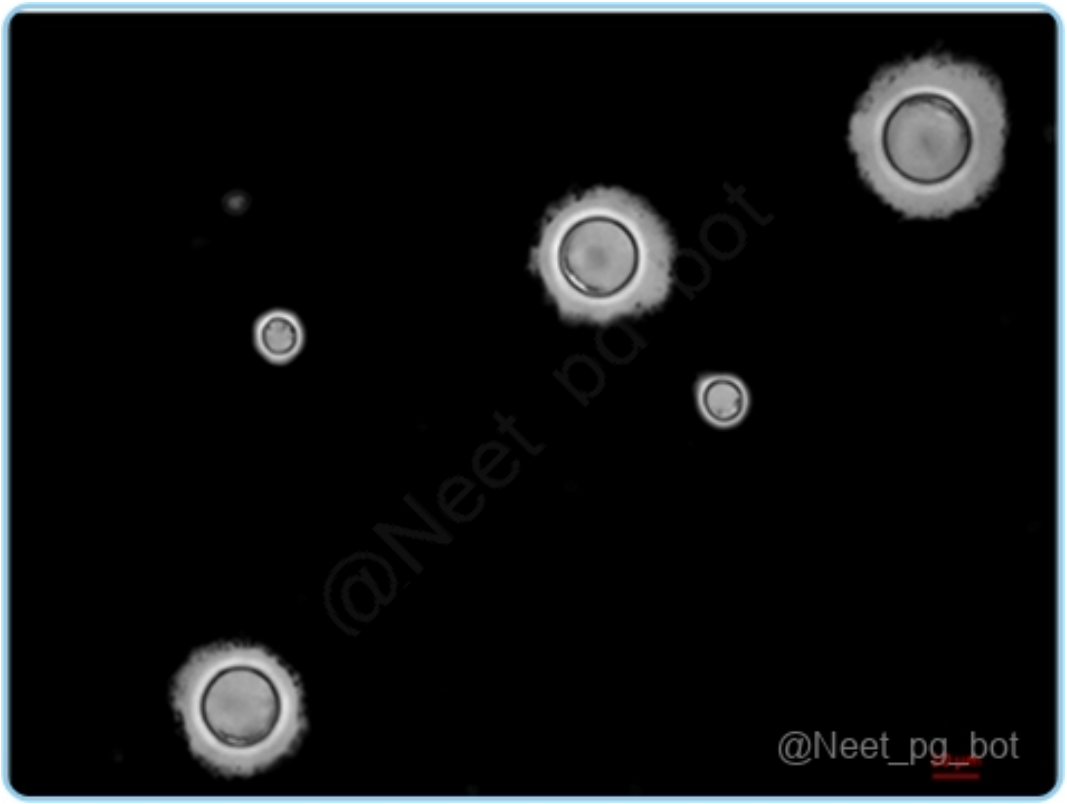
@Neet_pg_bot

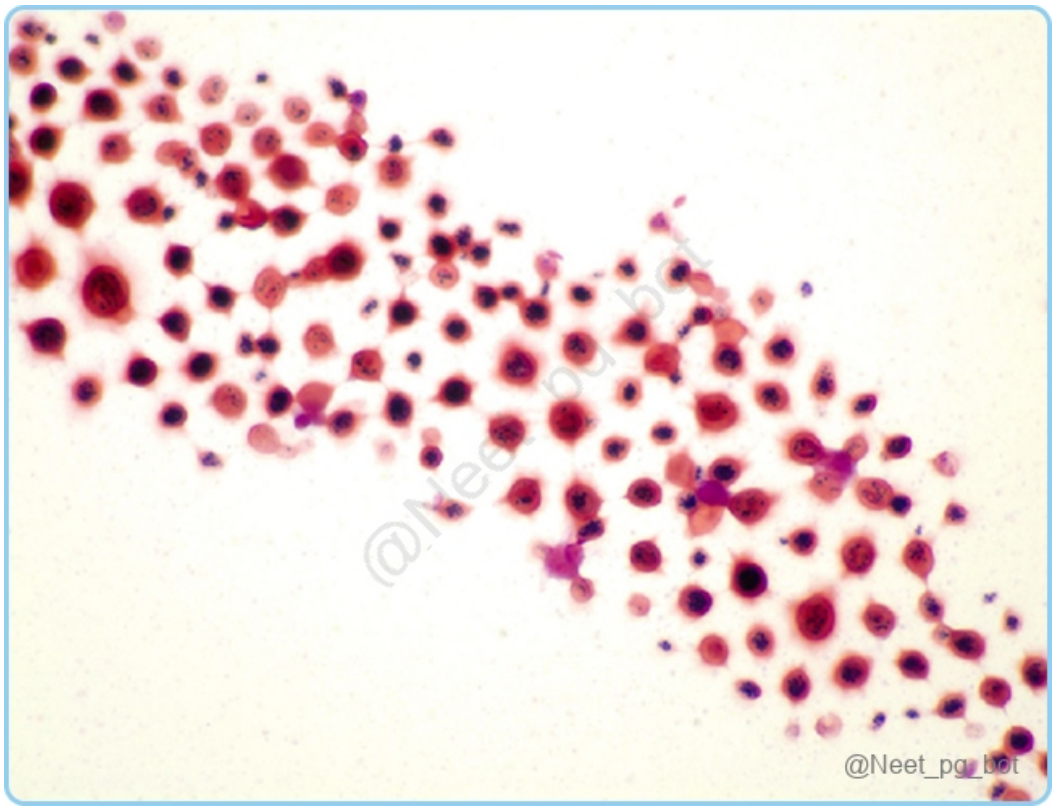

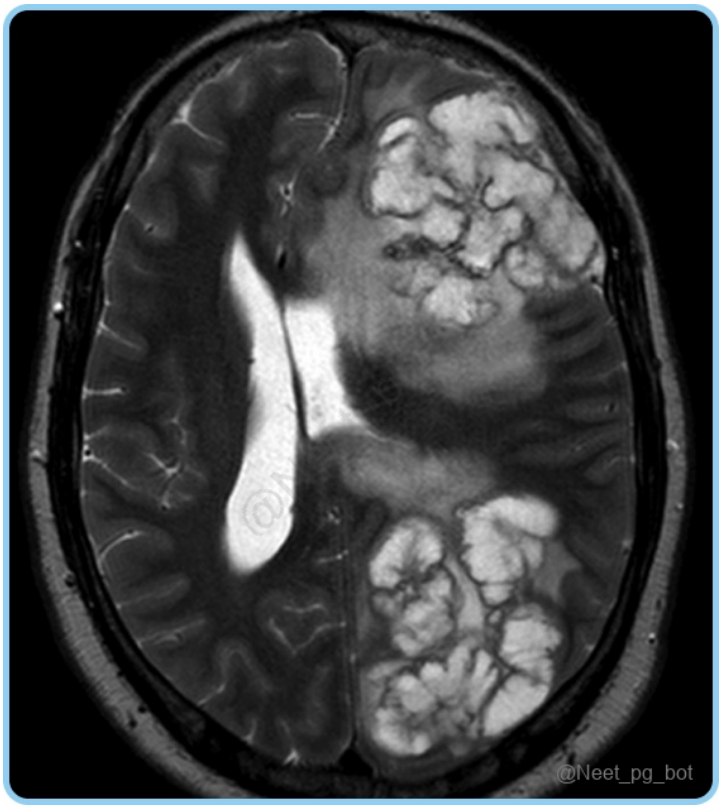

References:

David Sutton Textbook of Radiology and Imaging, 8th Edition, Page 1952.

↑ *Back to this question in Part A*

@Neet_pg_bot

Q2: A 65-year-old male presents with a gradually progressive cognitive decline over recent months and episodic, irregular jerky movements, with an EEG finding shown below. What is the most likely underlying diagnosis? (Q890931)

A. Subacute sclerosing panencephalitis

B. Progressive multifocal leukoencephalopathy

C. Creutzfeldt-Jakob disease

D. Neurosyphilis



Correct Answer: C. Creutzfeldt-Jakob disease

Explanation: The clinical triad of rapidly progressive dementia, myoclonus (intermittent, irregular jerky movements), and characteristic electroencephalogram (EEG) findings revealing the presence of generalised periodic sharp wave complexes (PSWC), which typically manifest as triphasic waves occurring synchronously at a frequency of 1 to 2 Hz, strongly points to sporadic Creutzfeldt-Jakob disease (CJD). CJD is a fatal, transmissible spongiform encephalopathy caused by the accumulation of misfolded infectious prion proteins (PrPSc) in the brain. Sporadic CJD - most common (~85%) Familial CJD - PRNP gene mutation Pathology Spongiform degeneration of brain tissue Neuronal loss and gliosis No inflammation Spongiform degeneration Clinical Features Rapidly progressive dementia Myoclonus (jerky movements) Ataxia and visual disturbances Behavioral changes

Progresses to akinetic mutism Investigations EEG: Periodic sharp wave complexes MRI: Cortical ribboning and basal ganglia hyperintensity (DWI/FLAIR) CSF: Increased 14-3-3 protein , RT-QuIC positive Cortical ribboning Prognosis / Treatment No curative treatment Supportive care only Fatal within ~1 year in most cases. Subacute sclerosing panencephalitis (Option A) presents with progressive dementia and myoclonus with periodic EEG complexes (Radermecker complexes). It almost exclusively affects children and adolescents. Progressive multifocal leukoencephalopathy (Option B), caused by the reactivation of the JC virus in severely immunocompromised individuals, causes progressive focal neurologic deficits, behavioural changes, and cognitive decline. Neurosyphilis (Option D): Late-stage central nervous system infection by Treponema pallidum can manifest as general paresis, leading to progressive dementia, personality changes, and tremors.

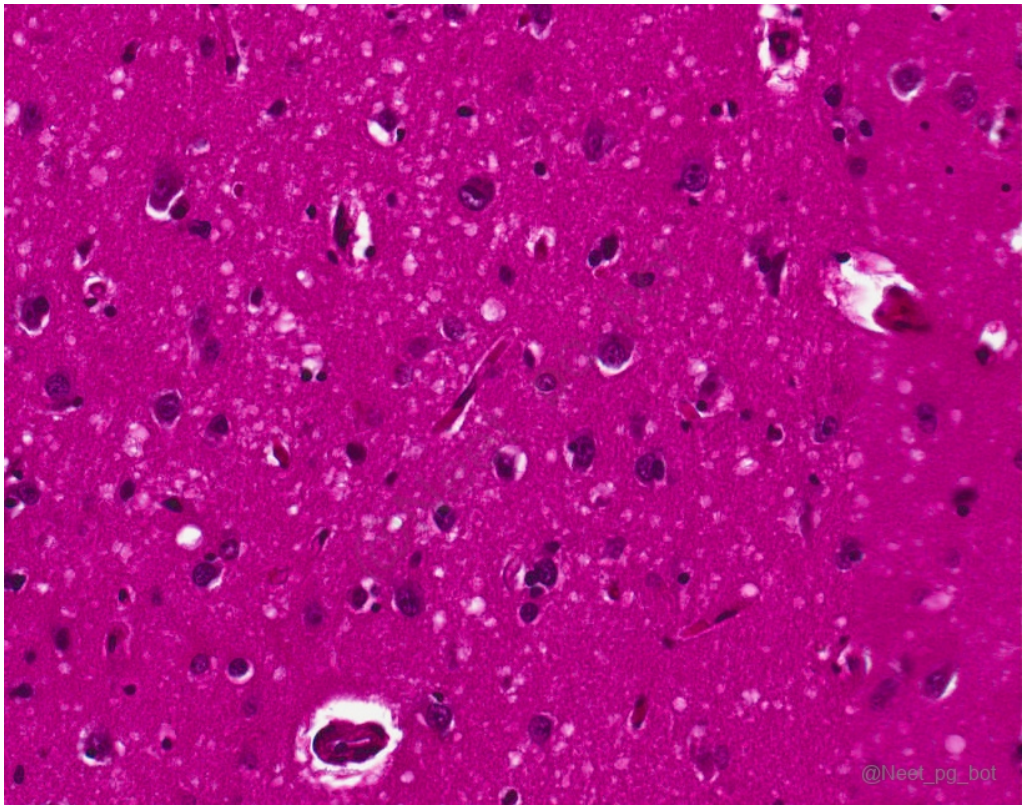

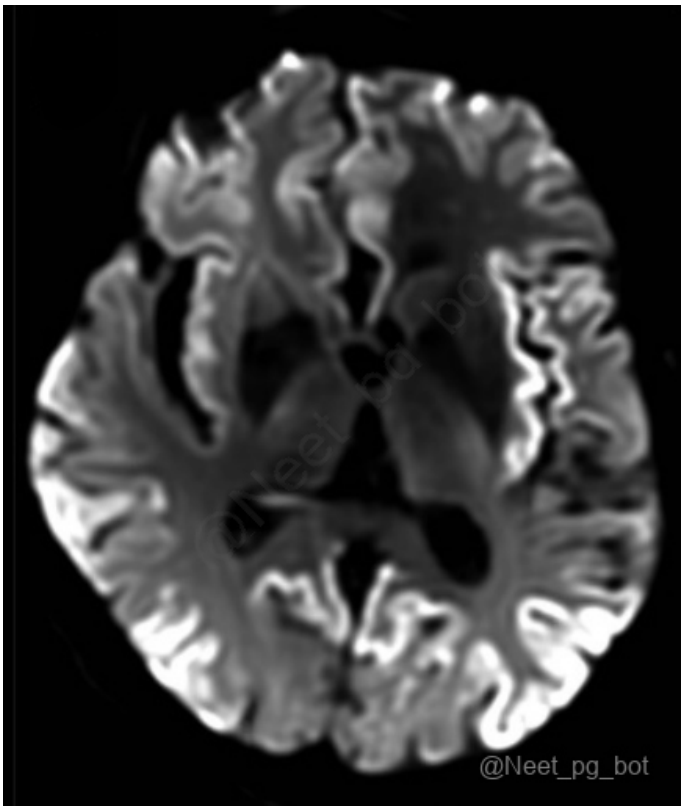

References:

Harrison's Principles of Internal Medicine, 22nd Edition, Pages 3531, 3532.

↑ *Back to this question in Part A*

@Neet_pg_bot

Q3: Which of the following findings would you not expect to see in a patient's CSF analysis with Herpes simplex virus encephalitis? (Q890929)

A. Elevated protein levels

B. Mild to moderate lymphocytic pleocytosis

C. Elevated red blood cell count

D. Profoundly decreased glucose

Correct Answer: D. Profoundly decreased glucose

Explanation: In viral central nervous system infections, including Herpes simplex virus (HSV) encephalitis, the cerebrospinal fluid (CSF) glucose level remains normal. Therefore, profoundly decreased glucose is an unexpected

finding. In Herpes Simplex Encephalitis , typical CSF findings include: Mild-moderate lymphocytic pleocytosis (Option B ruled out) Elevated protein (Option A ruled out) Elevated RBC count due to hemorrhagic necrosis of the temporal lobes (Option C ruled out) Normal glucose A markedly low CSF glucose is the classic hallmark of acute pyogenic bacterial meningitis or tuberculous meningitis. Type of Meningitis Sugar (Glucose) TLC Protein Bacterial ↓ ↑↑ (Neutrophils) ↑↑ Viral Normal ↑ (Lymphocytes) ↑ (mild) Tubercular ↓ ↑ (Lymphocytes) ↑↑

References:

Harrison's Principles of Internal Medicine, 22nd Edition, Page 1499.

↑ *Back to this question in Part A*

@Neet_pg_bot

Q4: A 42-year-old male is brought to the emergency department with a 2-day history of high fever, confusion, and new-onset focal seizures preceded by the smell of burning rubber. Cerebrospinal fluid polymerase chain reaction is positive for a double-stranded DNA virus. MRI of the brain is most likely to reveal abnormal hyperintensities in which of the following areas? (Q890928)

A. Bilateral cerebellar hemispheres

B. Temporal lobe

C. Basal ganglia and thalami

D. Parieto-occipital cortex

Correct Answer: B. Temporal lobe

Explanation: The clinical presentation of acute fever, confusion, and focal neurological signs (olfactory hallucinations) is highly characteristic of acute viral encephalitis caused by Herpes simplex virus (HSV) type 1. HSV has a predilection for the medial temporal lobes and inferior frontal lobes , where MRI typically shows hyperintensities due to hemorrhagic necrosis . Clinical Features of HSV Encephalitis: Focal Seizures: Often temporal lobe seizures, which may present with olfactory or gustatory auras (e.g., smelling burning rubber). Altered Sensorium: Rapid onset of confusion, delirium, or lethargy. Focal Neurological Deficits: Expressive aphasia (if the dominant hemisphere is involved) or hemiparesis. Behavioural Changes: Personality alterations, hyperorality, profound memory loss, or bizarre psychiatric behaviour. HSV-1 has a classic, strong tropism for the temporal lobes, which is the hallmark location for hemorrhagic and necrotising inflammation in this disease. MRI is the neuroimaging modality of choice and typically demonstrates oedema, haemorrhage, and hyperintensity primarily in this region. Bilateral cerebellar hemispheres (Option A): Lesions in this area are characteristic of acute cerebellar ataxia, which can be a post-viral autoimmune phenomenon following Varicella-zoster virus infection in children. Basal ganglia and thalami (Option C): Bilateral involvement of the deep grey matter structures, such as the basal ganglia and thalami, is the classic neuroimaging hallmark of flavivirus infections, most notably Japanese encephalitis virus and West Nile virus. Parieto-occipital cortex (Option D): Lesions predominantly affecting the

posterior white matter are characteristic of Posterior Reversible Encephalopathy Syndrome (PRES) or Progressive Multifocal Leukoencephalopathy (PML) caused by the JC virus.

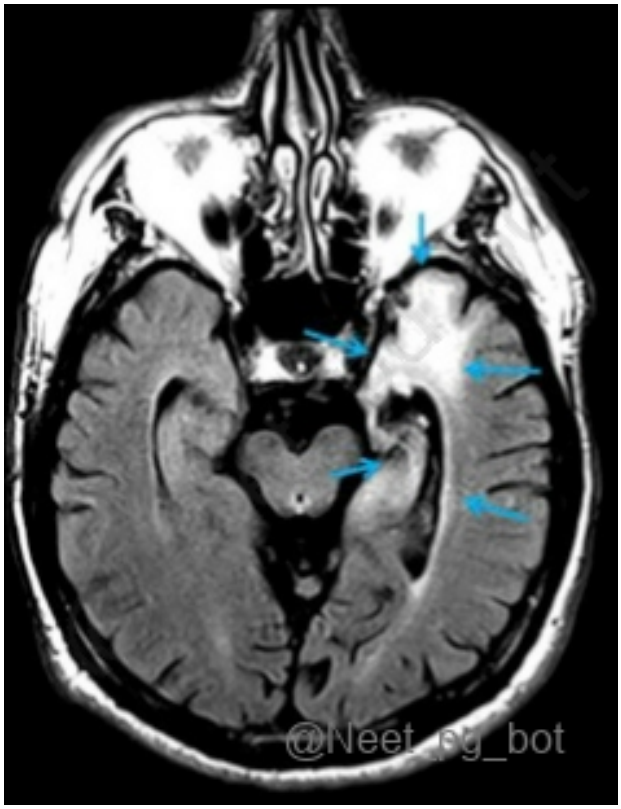

References:

Harrison's Principles of Internal Medicine, 22nd Edition, Page 1499.

↑ *Back to this question in Part A*

@Neet_pg_bot

Q5: A 45-year-old male with a history of untreated HIV infection presents with a 4-week history of progressively worsening headache, low-grade fever, night sweats, and recent-onset double vision. MRI of the brain reveals hydrocephalus and abnormal enhancements of the basal cisterns. Which of the following CSF profiles is most consistent with this patient's likely diagnosis? (Q890925)

A. Neutrophilic pleocytosis, low glucose, markedly elevated protein

B. Lymphocytic pleocytosis, low glucose, markedly elevated protein

C. Lymphocytic pleocytosis, normal glucose, normal protein

D. Monocytic pleocytosis, normal glucose, markedly elevated protein

Correct Answer: B. Lymphocytic pleocytosis, low glucose, markedly elevated protein

Explanation: The clinical presentation of a 4-week history of fever, night sweats, cranial nerve palsy (double vision), and neuroimaging showing basal cistern enhancement with hydrocephalus is highly characteristic of subacute to chronic meningitis caused by Mycobacterium tuberculosis. Examination of cerebrospinal fluid reveals a high leukocyte count (up to 1000/µL), usually with a predominance of lymphocytes but sometimes with a predominance of neutrophils in the early stage; a protein content of 1-8 g/L (100-800 mg/dL); and a low glucose concentration. This classic lymphocytic, hypoglycorrhachic, and hyperproteinorrhachic profile confirms the diagnosis. Type of Meningitis Sugar (Glucose) TLC Protein Bacterial (Option A ruled out) ↓ ↑↑ (Neutrophils) ↑↑ Viral (Option C ruled out) Normal ↑ (Lymphocytes) ↑ (mild) Tubercular ↓ ↑ (Lymphocytes) ↑↑

References:

Harrison's Principles of Internal Medicine, 22nd Edition, Page 1389.

↑ *Back to this question in Part A*

@Neet_pg_bot

Q6: Which of the following is the most appropriate empirical treatment for a suspected case of meningococcal meningitis? (Q890923)

A. Intravenous Penicillin G

B. Intravenous Ceftriaxone and Vancomycin

C. Oral Ciprofloxacin

D. Intravenous Cefotetan

Correct Answer: B. Intravenous Ceftriaxone and Vancomycin

Explanation: When acute bacterial meningitis is suspected, empirical therapy must be started immediately before culture results are available. The treatment should cover the most common pathogens: Streptococcus pneumoniae Neisseria meningitidis Sometimes Haemophilus influenzae Empirical antibiotic therapy for suspected meningococcal disease consists of a third-generation cephalosporin such as intravenous ceftriaxone (75-100 mg/kg per day) or cefotaxime. This is required to cover various other potentially penicillin-resistant bacteria. Intravenous vancomycin is also recommended in combination with the cephalosporin for the empiric management of sepsis and suspected bacterial meningitis. The conventional duration for treating both meningococcal meningitis and septicemia is 7 days. Once the organism is confirmed as Neisseria meningitidis , therapy can be de-escalated to penicillin G or ceftriaxone alone . Intravenous Penicillin G (Option A): Reduced meningococcal sensitivity to penicillin has been increasingly reported. Therefore, the use of penicillin is only appropriate as definitive therapy once specific information on antimicrobial resistance patterns is available. Oral Ciprofloxacin (Option C) is utilised for the eradication of nasopharyngeal carriage in close contacts. Intravenous Cefotetan (Option D): Cefotetan is a second-generation cephamycin with primarily anti-anaerobic activity. It has poor cerebrospinal fluid

penetration and is not indicated for the treatment of bacterial meningitis.

References:

Harrison's Principles of Internal Medicine, 22nd Edition, Page 1249.

↑ *Back to this question in Part A*

@Neet_pg_bot

Q7: A 26-year-old pregnant woman in her second trimester presents to the emergency department with a 2-day history of high-grade fever, severe headache, and vomiting. She recently attended a crowded indoor school gathering. On examination, she exhibits marked neck stiffness and a rapidly spreading petechial rash over her trunk and lower extremities. Which of the following statements is false regarding the disease she is most likely suffering from? (Q890919)

A. Deficiency of C5-C9 components significantly increases the risk of this infection.

B. Oral ciprofloxacin is the preferred agent for chemoprophylaxis in this patient.

C. Cultures typically become sterile within 24 hours of initiating appropriate therapy.

D. The causative organism is an aerobic, Gram-negative diplococcus.

Correct Answer: B. Oral ciprofloxacin is the preferred agent for chemoprophylaxis in this patient.

Explanation: The patient's clinical presentation of fever, meningeal signs, and a characteristic petechial rash following exposure at a crowded gathering is highly suggestive of meningococcal meningitis caused by Neisseria meningitidis. For chemoprophylaxis to eradicate nasopharyngeal carriage in pregnant women, a single intramuscular dose of ceftriaxone is the preferred and safest agent. Oral ciprofloxacin (a fluoroquinolone) is generally contraindicated in pregnancy due to potential risks to fetal cartilage development, making this statement false. Meningococcal Meningitis Causative organism: Neisseria meningitidis, an aerobic Gram-negative diplococcus (Option D ruled out). Appears as kidney-shaped diplococci on Gram stain. Often found intracellularly within neutrophils. Transmission Spread through respiratory droplets. Common in crowded environments (hostels, schools, military barracks). Risk factors: Complement deficiency: Terminal complement components (C5-C9) form the membrane attack complex (MAC). Deficiency of C5-C9 increases susceptibility to Neisseria infections (Option A ruled out) Asplenia Clinical features High fever Severe headache Neck stiffness Altered mental status Petechial or purpuric rash due to meningococcemia. Complications Waterhouse-Friderichsen syndrome Septic shock Disseminated intravascular coagulation (DIC) Diagnosis CSF examination showing neutrophilic pleocytosis. Gram stain showing Gram-negative diplococci. Blood and CSF cultures: With appropriate antibiotics (e.g., ceftriaxone or penicillin), CSF cultures often become sterile within 24 hours (Option C ruled out). Management: Treatment: Third-generation cephalosporins (ceftriaxone or cefotaxime) are first-line therapy. Chemoprophylaxis Given to close contacts of the patient. Drugs include: Rifampicin Ciprofloxacin Ceftriaxone Meningococcal vaccines (MenACWY, MenB) help prevent outbreaks.

References:

Harrison's Principles of Internal Medicine, 22nd Edition, Pages 1248, 1249.

↑ *Back to this question in Part A*

@Neet_pg_bot

Q8: Which of the following is the most frequently identified pathogen responsible for meningitis following the implantation of an indwelling central nervous system device? (Q890917)

A. Streptococcus pneumoniae

B. Coagulase-negative staphylococci

C. Pseudomonas aeruginosa

D. Group B streptococci

Correct Answer: B. Coagulase-negative staphylococci

Explanation: The most common pathogens implicated in healthcare-associated meningitis related to neurosurgical hardware are skin commensals. Because these devices involve percutaneous entry and the presence of a foreign body, they are highly susceptible to colonisation by skin flora. Staphylococcus aureus and Coagulase-negative staphylococci (e.g., Staphylococcus epidermidis) are the predominant causative agents for long-term indwelling CNS device infections, such as Ommaya reservoirs and ventriculoperitoneal shunts. These bacteria are skin commensals. They easily adhere to prosthetic material. They form biofilms on medical devices , making them the commonest cause of shunt/device infections. Streptococcus pneumoniae (Option A) is the most common cause of community-acquired meningitis. Pseudomonas aeruginosa (Option C) is a known cause of healthcare-associated meningitis, particularly following major neurosurgical procedures or trauma, but it is not the most common pathogen specifically isolated from indwelling reservoir devices. Group B streptococci (Option D) are primarily associated with meningitis in neonates and specific immunocompromised adult populations (such as those with diabetes or malignancy).

References:

Harrison's Principles of Internal Medicine, 22nd Edition, Pages 583, 1119.

↑ *Back to this question in Part A*

@Neet_pg_bot

Q9: A 30-year-old previously healthy male presents with the acute triad of high-grade fever, severe headache, and neck stiffness. Examination reveals positive Kernig's and Brudzinski's signs. Which of the following is the most common cause of community-acquired bacterial meningitis? (Q890916)

A. Staphylococcus aureus

B. Neisseria meningitidis

C. Streptococcus pneumoniae

D. Listeria monocytogenes

Correct Answer: C. Streptococcus pneumoniae

Explanation: The diagnosis is acute bacterial meningitis, characterised by the classic triad of fever, neck rigidity, and headache. In adults, Streptococcus pneumoniae is the most frequently identified pathogen. The following are the most common causative organisms for community-acquired bacterial meningitis: Streptococcus pneumoniae (~50%): The leading cause of bacterial meningitis in adults > 20 years. Neisseria meningitidis (~25%): Often associated with epidemics of meningitis occurring every 8-12 years; frequent in adolescents and young adults. (Option B ruled out) Group B streptococci (~15%) Listeria monocytogenes (~10%): Common in neonates, elderly patients, and immunocompromised individuals. (Option D ruled out) Haemophilus influenzae type b (<10%): Following widespread vaccination, this organism now accounts for a minor proportion of cases in most clinical series. Staphylococcus aureus (Option A): This organism is rarely a cause of community-acquired meningitis; it is primarily associated with neurosurgical procedures, trauma, or hematogenous spread from endocarditis, otitis, mastoiditis, and sinusitis.

References:

Harrison's Principles of Internal Medicine, 22nd Edition, Pages 1118, 1119.

↑ *Back to this question in Part A*

@Neet_pg_bot

Q10: A 30-year-old man from the village is admitted with high-grade fever and altered sensorium. On examination, bilateral Babinski and exaggerated ankle jerks were noted. Nuchal rigidity is absent. Workup shows Hb:7 gm%, TLC: 10K/cu.mm, platelet count: 1.5 Lac/cu.mm, elevated LDH, LFT is normal, and Serum creatinine is 1.5mg/dl. What is the best course of action for this patient? (Q851555)

A. LP followed by IV acyclovir

B. Peripheral smear followed by IV Artensunate

C. LP followed by IV Dexamethasone

D. Lateral flow assay followed by IV Sulphamethoxazole plus Trimethoprim

Correct Answer: B. Peripheral smear followed by IV Artensunate

■ *Listen (English)*

■ *Listen (Hindi)*

Explanation: The patient is having high grade fever with evidence of brain parenchymal involvement (bilateral Babinski and brisk DTR). Evidence of hemolysis is given in form on elevated LDH and low Hb. HRP-2 card tesrt and peripheral smear must be done and empirical Artesunate can be started in this case pending investigations. Presence of banana shaped gametocytes in peripheral smear with multiple ring stage will confirm the diagnosis of falciparum malaria. The infection makes the RBC sticky causing microinfarctions in brain parenchyma that will explain the development of altered sensorium.

References:

Harrison's Principles of Internal Medicine, 22nd Edition, Page 1763, 1768.

↑ *Back to this question in Part A*

@Neet_pg_bot

Q11: A 42■year■old HIV positive man with CD4 count 80 cells/mm³ presents with 3 weeks of visual blurring, weakness in right arm and dysarthria. MRI brain (FLAIR sequence) shows multiple asymmetric hyperintense lesions in the frontal and parietal white matter, with no mass effect and no contrast enhancement. Which of the following is the most likely cause? (Q851548)

A. JC virus

B. BK virus reactivation

C. Cerebral toxoplasmosis

D. CMV encephalitis

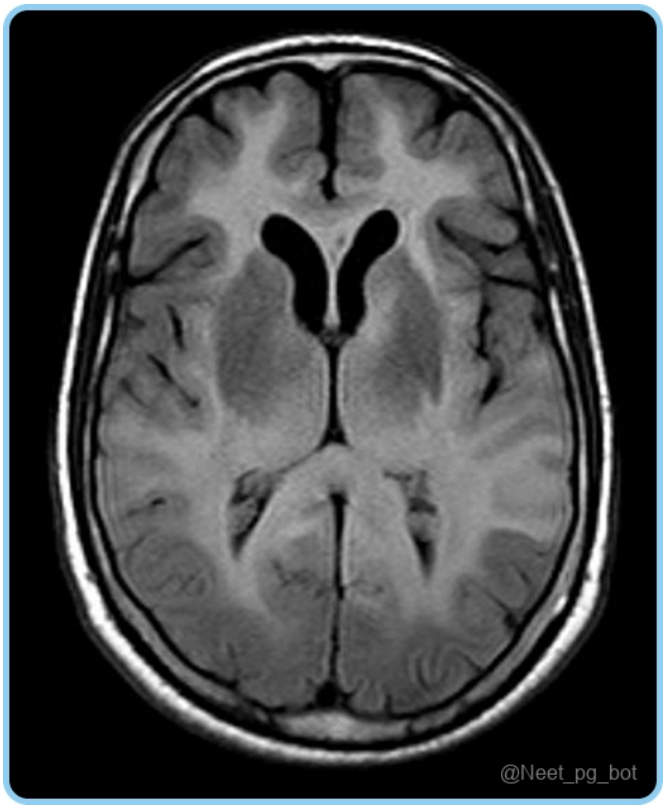

Correct Answer: A. JC virus

■ *Listen (English)*

■ *Listen (Hindi)*

Explanation: MRI shows multiple sub-cortical hyperintense lesions in frontal, parietal and occipital lobes. The patient's symptoms, including progressive weakness in her right arm, blurred vision along with a low CD4+ T-cell count and MRI findings of non-enhancing hyperintense lesions, are consistent with progressive multifocal leukoencephalopathy (PML) caused by the JC virus. The JC virus in PML infects and destroys oligodendrocytes , leading to demyelination of subcortical white matter tracts. The specific neurological deficits—like visual loss and dysarthria —reflect the location of those demyelinating lesions: The presence of JC virus DNA in the CSF is a key diagnostic marker for PML, with high specificity. No enhancement and minimal mass effect distinguish it from toxoplasmosis (ring■enhancing) or CMV (ventriculitis, periventricular enhancement). (Option C and D) BK virus reactivation (Option B) is cause of graft failure after kidney transplantation.

References:

Harrison's Principles of Internal Medicine, 22nd Edition, Page 1117, 1671.

↑ *Back to this question in Part A*

@Neet_pg_bot

Q12: A 25 year old HIV positive man presents with complaints of a severe headache, fever, and confusion. His CD4+ T-cell count is 80 cells/μL. Neurological examination reveals right-sided hand weakness and difficulty speaking. An MRI of the patient is given below. Which of the following is the most appropriate next step in management? (Q851547)

A. Initiate treatment with sulfadiazine and pyrimethamine with leucovorin

B. Perform a brain biopsy to confirm the diagnosis.

C. Order a chest X-ray to rule out tuberculosis.

D. Start empiric treatment for bacterial meningitis.

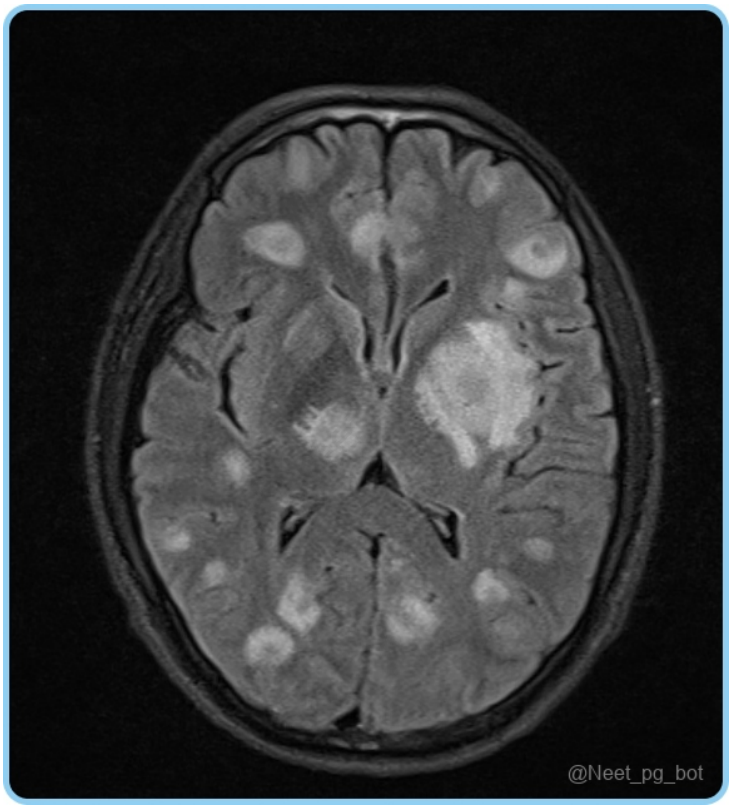

Correct Answer: A. Initiate treatment with sulfadiazine and pyrimethamine with leucovorin

■ *Listen (English)*

■ *Listen (Hindi)*

Explanation: MRI head shows ring-enhancing l esions seen in the basal ganglia and corticomedullary junction. They lack the eccentric scolex appearance of NCC or the target sign with the solid nodule appearance of TB meningitis. TBM also has leptomeningeal enhancement and hydrocephalus. Ideally, we should do MR spectroscopy to distinguish them, but here, considering the options given, we will consider cerebral toxoplasmosis. It is a common opportunistic infection in patients with advanced HIV/AIDS, especially with a CD4+ count <100

cells/µL. Therefore, the appropriate initial management is to start treatment with sulfadiazine and pyrimethamine with leucovorin. Perform a brain biopsy to confirm the diagnosis (Option B): Brain biopsy is definitive but is reserved for patients who fail 2-4 weeks of empiric therapy . Order a chest X-ray to rule out tuberculosis (Option C): While TB is a concern in HIV patients, the acute neurological symptoms and MRI findings align more with cerebral toxoplasmosis. A chest X-ray is not the immediate priority here. Start empiric treatment for bacterial meningitis (Option D): Bacterial meningitis could present similarly, but the MRI findings of ring-enhancing lesions are not typical for meningitis. The strong indication of cerebral toxoplasmosis suggests treating that condition first.

References:

Harrison's Principles of Internal Medicine, 22nd Edition, Page 1803.

↑ *Back to this question in Part A*

@Neet_pg_bot

Q13: A 2-week-old infant presents with lethargy, poor feeding, irritability, and a bulging fontanelle. Born prematurely at 34 weeks with low birth weight, a lumbar puncture reveals cloudy cerebrospinal fluid (CSF) with high white blood cell count, decreased glucose, and elevated protein levels. Which is not a causative factor for this infant's condition? (Q851517)

A. Group B Streptococcus

B. Escherichia coli

C. Streptococcus pneumoniae

D. Listeria monocytogenes

Correct Answer: C. Streptococcus pneumoniae

■ *Listen (English)*

■ *Listen (Hindi)*

Explanation: While Streptococcus pneumoniae is a significant cause of bacterial meningitis in children and adults, it is less common in neonates. Given the infant's age, prematurity, and other clinical factors, it is less likely to be the causative organism. Common Causes of Bacterial meningitis by Age Group Neonates Pre-school Children Older Children Escherichia coli (gram-negative bacilli) Group B streptococci Listeria monocytogenes (Option A, B and D ruled out) Haemophilus influenzae type b Neisseria meningitidis Streptococcus pneumoniae Neisseria meningitidis Streptococcus pneumoniae

References:

Harrison's Principles of Internal Medicine, 22nd Edition, Page 1213.

↑ *Back to this question in Part A*

@Neet_pg_bot

Q14: A 34-year-old male HIV positive truck driver presents with severe headache. Examination shows nuchal rigidity and altered mental status. Lumbar puncture shows elevated opening pressure, low glucose, normal protein and encapsulated yeast on India ink staining. What is the most appropriate initial treatment? (Q851545)

A. Liposomal amphotericin B with High-dose IV fluconazole

B. Liposomal amphotericin B with capsofungin

C. Liposomal amphotericin B plus 5 Flucytosine

D. Oral corticosteroids plus broad-spectrum antibiotics

Correct Answer: C. Liposomal amphotericin B plus 5 Flucytosine

■ *Listen (English)*

■ *Listen (Hindi)*

Explanation: The diagnosis is cryptococcal meningitis because the patient's clinical presentation, including HIV with low CD4+ count, elevated CSF opening pressure, and the identification of encapsulated yeast in the CSF via India ink stain, is characteristic of Cryptococcus neoformans infection. IV amphotericin B plus flucytosine is the standard initial treatment for cryptococcal meningitis to reduce fungal load and manage CNS infection. Amphotericin should be continued until CSF culture is negative, followed by fluconazole (400 mg/d PO for 8 weeks, then 200 mg/d) unt il CD4+ T-cell count >200 cells/μL for 6 months.

References:

Harrison’s Principles of Internal Medicine, 22nd Edition, Page 1705.

https://www.ncbi.nlm.nih.gov/books/NBK525986/

↑ *Back to this question in Part A*

@Neet_pg_bot

Q15: A 45 y/o patient presents with fever, headache, neck stiffness, and photophobia. On examination, the patient is lethargic and lumbar puncture reveals elevated CSF opening pressure, PMN leukocytosis, decreased glucose levels, and increased protein concentration. Which of the following will not be seen in this patient? (Q851544)

A. Woltman sign

B. Brudzinki sign

C. Jolt accentuation

D. Kernig sign

Correct Answer: A. Woltman sign

■ *Listen (English)*

■ *Listen (Hindi)*

Explanation: Woltman sign is seen in hypothyroidism and has delayed relaxation phase of ankle jerks due to myxedema of achilles tendon. Brudzinki sign (Option B): Assisted neck flexion will cause involuntary hip and knee joint flexion Jolt accentuation (Option C): Ask patient to turn head left and right at 2-3 turns per second. This will cause worsening of headache. Kernig sign (Option D): With hip and knee flexed at 90 degrees, we extend the knee to meet with stiff hamstrings.

References:

Harrison's Principles of Internal Medicine, 22nd Edition, Page 1119,1120, 3028.
https://pmc.ncbi.nlm.nih.gov/articles/PMC2492977/

↑ *Back to this question in Part A*

@Neet_pg_bot

Q16: A 68 year old patient with diabetic nephropathy presents to the ER with fever, headache, and neck stiffness. Blood cultures are pending, and a lumbar puncture reveals elevated CSF protein, decreased glucose, and neutrophilic pleocytosis. Which of the following is the most appropriate empirical antibiotic regimen? (Q851543)

A. Ceftriaxone and Vancomycin

B. Ceftriaxone and Gentamycin

C. Ampicillin + Ceftriaxone + Vancomycin

D. Meropenem and Vancomycin

Correct Answer: C. Ampicillin + Ceftriaxone + Vancomycin

■ *Listen (English)*

■ *Listen (Hindi)*

Explanation: The diagnosis in this scenario is bacterial meningitis. Due to advanced ag e of patient along with comoribidity we need to give coverage for streptococcus pneumoniae as well as Listeria monocytogenes plus cover for penicillin■resistant Streptococcus pneumoniae. The correct treatment includes Ampicillin for Listeria coverage in addition to Ceftriaxone and Vancomycin for broad-spectrum bacterial coverage including Streptococcus pneumoniae and Neisseria meningitidis For patients with hospital acquired menngitis, post traumatic meningitis, post neurosurgery or neutropenic patients Meropenem and Vancomycin (Option D) will be used

References:

Harrison's Principles of Internal Medicine, 22nd Edition, Page 1122.

↑ *Back to this question in Part A*

@Neet_pg_bot

Q17: A 36 year old HIV positive patient presents with double vision, vomitting epsiodes with daily frontal headaches that dont respond to painkillers. Patient is not cooperative during physical examination due to headache. Fundus examination shows papilledema. Neuroimaging is performed. Which of the following is not correct about immediate management of this patient? (Q851542)

A. Lumbar puncture for CSF CBNAAT for MTB

B. Empirical ATT

C. IV dexamathasone

D. Mannitol

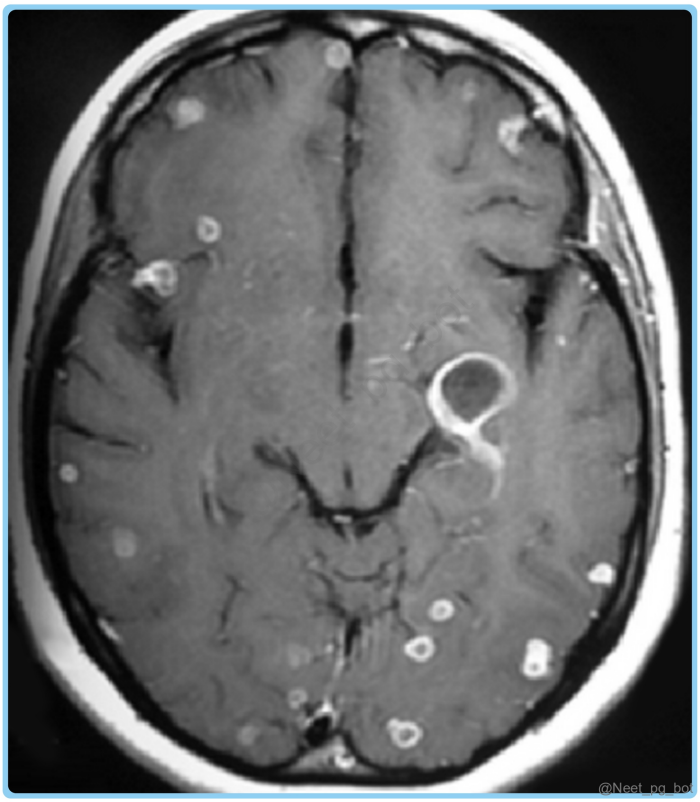

Correct Answer: A. Lumbar puncture for CSF CBNAAT for MTB

■ *Listen (English)*

■ *Listen (Hindi)*

Explanation: This immunocompromised patient is having ring enhanching lesions seen on MRI head. Lesions show “Target sign” with solid central nodule. First differential diagnosis in India - TB meningitis. Due to raised ICP lumbar puncture cannot be performed in this patient as of now due to risk of brain herniation. Empirical ATT with steroids will be started along with measures like Mannitol to lower raised ICP. (Option B,C and D) Double vision is seen this case due to 6th nerve palsy seen in raised ICP. Contraindications to Lumbar puncture Papilledema Focal neurologic deficit (esp. new onset) Midline shift or mass on CT/MRI Bleeding disorders / Anticoagulants Skin infection at site Uncontrolled seizures Signs of raised ICP with impending herniation

References:

Harrison’s Principles of Internal Medicine, 22nd Edition, Page 1120.
https://www.ncbi.nlm.nih.gov/books/NBK557553/

↑ *Back to this question in Part A*

@Neet_pg_bot

Q18: A 38 year old man presented to ER with inability to stand and sit up in bed since yesterday evening. He reports that the weakness began as slipping in stairs multiple

times in last 3 days along with tingling in his fingertips. Power in both legs at all joints is grade 2/5 and bilateral ankle jerks are absent. Which is not correct about this patient? (Q851541)

A. Electrodiagnostics show absent F waves

B. MRI shows spinal cord inflammation

C. Cytoabuminological dissociation

D. Bladder and Bowel are spared

Correct Answer: B. MRI shows spinal cord inflammation

■ *Listen (English)*

■ *Listen (Hindi)*

Explanation: The diagnosis based on symmetrical flaccid paralysis with areflexia and ascending nature is GBS (can't walk followed by can't sit). The condition spares the bladder and bowel. (Option D) MRI spine will show dorsal nerve root demyelination and not inflammation. Inflammation is seen in transverse myelitis. CSF study shows cytoabuminological dissociation. (Option C) Electrodiagnostic study/ nerve conduction velocity will show prolonged or absent F waves due to demyelination affecting proximal nerve segments. (Option A) Below is the image of an MRI showing chronic inflammatory demyelinating polyneuropathy typically seen in GBS patients

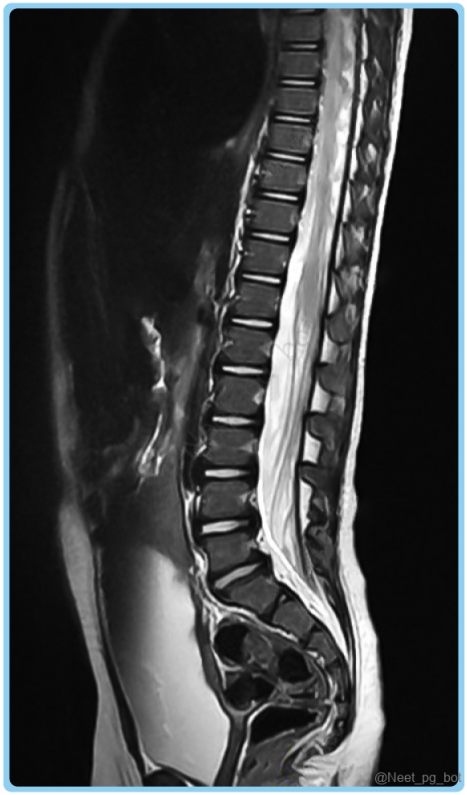

References:

Harrison’s Principles of Internal Medicine, 22nd Edition, Page 3619.

↑ *Back to this question in Part A*

@Neet_pg_bot

Q19: Which of the following is not required for management of Post dural puncture headache? (Q851538)

A. Intravenous caffeine

B. Low volume blood patch

C. Bladder catheterization and laxatives

D. Plenty of fluids

Correct Answer: C. Bladder catheterization and laxatives

■ *Listen (English)*

■ *Listen (Hindi)*

Explanation: Postdural puncture headache (PDPH) is a potential complication of a lumbar puncture, with symptoms caused by traction on pain-sensitive structures from low cerebrospinal fluid pressure (intracranial hypotension) following a leak of cerebrospinal fluid at the puncture site. Mainstay of management is Bed rest, hydration (Option D) , analgesia. If headache persists inspite of use of caffiene (Option A) (Drug of choice for PDPH) and opioids then Low volume blood patch (Option B) is used.

References:

Harrison’s Principles of Internal Medicine, 22nd Edition, Page 116.

↑ *Back to this question in Part A*

@Neet_pg_bot

Q20: During a lumbar puncture, the needle passes through several anatomical layers before reaching the subarachnoid space. Which of the following is the correct sequence of structures pierced during this procedure? (Q851534)

A. Skin → Ligamentum flavum → Supraspinous ligament → Interspinous ligament → Dura → Arachnoid

B. Skin → Supraspinous ligament → Interspinous ligament → Ligamentum flavum → Arachnoid → Dura

C. Skin → Supraspinous ligament → Ligamentum flavum → Interspinous ligament → Dura → Arachnoid

D. Skin → Supraspinous ligament → Interspinous ligament → Ligamentum flavum → Dura → Arachnoid

Correct Answer: D. Skin → Supraspinous ligament → Interspinous ligament → Ligamentum flavum → Dura → Arachnoid

■ *Listen (English)*

■ *Listen (Hindi)*

Explanation: Mnemonic for structures pierced while performing lumbar puncture : "Some Say I Like Drinking Alcohol" S kin S upraspinous ligament I nterspinous ligament L igamentum flavum D ura A rachnoid
{{caption_text}}

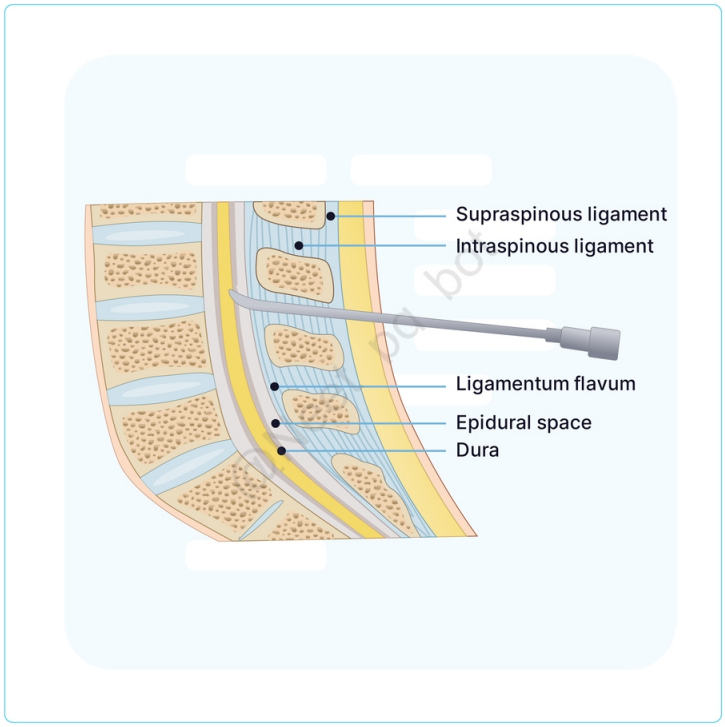

@Neet_pg_bot

References:

https://www.ncbi.nlm.nih.gov/books/NBK557553/

↑ *Back to this question in Part A*

@Neet_pg_bot

Q21: A 45 y/o male with a history of HIV infection presents to the ED with headache, fever, photophobia, and neck stiffness. His CD4 count is 80 cells/mm³. Lumbar puncture reveals an elevated opening pressure, low glucose, and elevated protein levels. India ink staining of the cerebrospinal fluid showed the following picture. Which of the following is the most appropriate initial treatment regimen for this patient? (Q851531)

A. Fluconazole monotherapy

B. Amphotericin B and Flucytosine

C. Voriconazole monotherapy

D. Caspofungin and Fluconazole



Correct Answer: B. Amphotericin B and Flucytosine

■ *Listen (English)*

■ *Listen (Hindi)*

Explanation: The patient's presentation is consistent with cryptococcal meningitis , as indicated by the encapsulated yeast cells on India ink staining , most commonly caused by Cryptococcus neoformans . The recommended initial treatment is a combination of amphotericin B and flucytosine for induction therapy, followed

by fluconazole for consolidation.

References:

Harrison’s Principles of Internal Medicine, 22nd Edition, Page 1705.

↑ *Back to this question in Part A*

@Neet_pg_bot

Q22: A 25 year old HIV positive male is brought to the emergency after developing high grade fever and altered sensorium for past 2 days. Meningeal signs are absent and bilateral babinski sign is noted. MRI head shows predominant temporal lobe inflammation. Which of the following is correct about immediate managment of this patient? (Q851529)

A. Start empirical Artesunate

B. Start Empirical acyclovir

C. Start empirical ATT plus dexamethasone

D. Start empirical Liposomal amphotericin B with 5 flucytosine

Correct Answer: B. Start Empirical acyclovir

■ *Listen (English)*

■ *Listen (Hindi)*

Explanation: The key words of temporal lobe invovlement in a patient with short duration illness causing altered sensoroium points to HSV-1 encephalitis. HIV positive status does not change the etiology of viral meningitis. It is still HSV-1 encephaltiis Any delay in starting acyclovir can cause permanent neurological deficits, including memory loss, difficulty with speech, and personality changes. Balbinski sign implies bilateral corticospinal tract is involved due to encephalitis. Absence of meningeal signs indicates parenchymal involvement. Start empirical Artesunate (Option A) for cerebral malaria. Start empirical ATT plus dexamethasone (Option C) for TBM Start empirical Liposomal amphotericin B with 5 flucytosine (Option D) for cryptococcal meningitis

References:

Harrison’s Principles of Internal Medicine, 22nd Edition, Page 1115.

↑ *Back to this question in Part A*

@Neet_pg_bot

Q23: Which of the following accurately describes the CSF findings in viral encephalitis caused by HSV-1? (Q851526)

A. Lymphocytic pleocytosis with low glucose levels

B. Lymphocytic pleocytosis with normal glucose levels

C. Lymphocytic pleocytosis with cob web coagulum

D. Lymphocytic pleocytosis with elevated glucose levels

Correct Answer: B. Lymphocytic pleocytosis with normal glucose levels

■ *Listen (English)*

■ *Listen (Hindi)*

Explanation: In cases of viral encephalitis , particularly caused by HSV-1 , the CSF usually demonstrates an increased number of lymphocytes , indicating a viral infection. Glucose levels remain normal , which helps differentiate it from bacterial meningitis, where glucose is often low.

References:

Harrison’s Principles of Internal Medicine, 22nd Edition, Page 1112.

↑ *Back to this question in Part A*

@Neet_pg_bot

Q24: A 45-year-old male presents to the emergency with fever, severe headache and confusion for last 3 days. Nuchal rigidity is present. Fundus is normal. CSF study shows 1000 cells with 10% lymphocytes and 90% PMN cells , CSF /plasma sugar 0.4 and CSF protein 80 mg/dl. What is the next best step in managment of this patient? (Q851519)

A. IV Cannula and start IV fluids at 20 ml per kg per hour

B. Empirical Ceftriaxone plus Vancomycin

C. Empirical ATT plus dexamethasone

D. NCCT head

Correct Answer: B. Empirical Ceftriaxone plus Vancomycin

■ *Listen (English)*

■ *Listen (Hindi)*

Explanation: The clinical features and lumbar puncture findings of high WBC, with the predominance of neutrophils, low sugar, and elevated protein, point to bacterial meningitis . Immediate initiation of intravenous broad-spectrum antibiotics is essential due to high mortality. The steps to be followed will be V cannulation and draw blood culture (Meningitis patients can develop SIADH, so they need restricted IV fluids) Perform LP after ruling out raised ICP or focal neurological deficit. If anyone presents, neuroimaging to be done first (in this cas,e Fundus examination was normal) Empirical antibiotics after CSF microscopy (start antibiotics within one hour of hospitalization)

References:

Harrison’s Principles of Internal Medicine, 22nd Edition, Page 1122.

↑ *Back to this question in Part A*

@Neet_pg_bot

• [07_Neurology] 058 Intracranial Pathologies Icp Brain Death Tumors And Neurocysticercosis

« Back to Folder Directory

[07_Neurology] 058 Intracranial Pathologies Icp Brain Death Tumors And Neurocysticercosis — Quick Jump

Q1 (p. 2414)	*Q2 (p. 2415)*	*Q3 (p. 2416)*	*Q4 (p. 2417)*	*Q5 (p. 2418)*	*Q6 (p. 2418)*
Q7 (p. 2419)	*Q8 (p. 2420)*	*Q9 (p. 2420)*	*Q10 (p. 2422)*	*Q11 (p. 2425)*	*Q12 (p. 2427)*
Q13 (p. 2428)	*Q14 (p. 2429)*	*Q15 (p. 2431)*	*Q16 (p. 2432)*	*Q17 (p. 2433)*	*Q18 (p. 2433)*
Q19 (p. 2434)	*Q20 (p. 2435)*	*Q21 (p. 2436)*	*Q22 (p. 2438)*	*Q23 (p. 2438)*	

Q1: A 25 year rickshaw puller presents with daily headaches and multiple episodes of focal seizures. MRI head is shown below. Which of the following is first line intervention in this patient? (Q851450)

A. Albendazole

B. A.T.T

C. Dexamethasone

D. Albendazole and praziquental

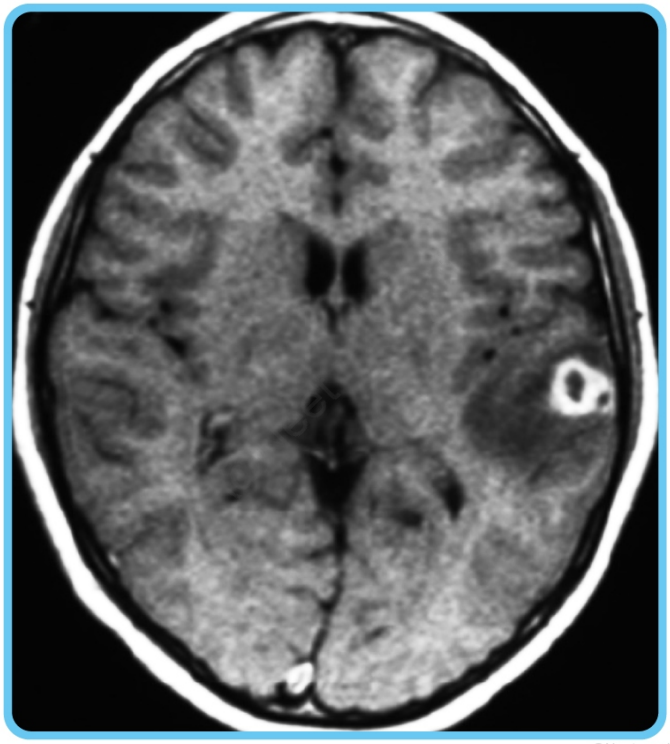

Correct Answer: C. Dexamethasone

■ *Listen (English)*

■ *Listen (Hindi)*

Explanation: MRI head shows a single ring-enhancing lesion in the right parietal lobe. It shows central hypointensity with peripheral rim enhancement . The perilesional edema is causing mass effect and slight effacement of nearby sulci. To control the seizures the first intervention would be dexamethasone that will reduce the vasogenic cerebral edema. Subsequently albendazole will be started. Stages of NCC 1. Vesicular: Cystic lesions with scolex. 2. Colloidal: Cysts degenerate, causing surrounding oedema. This is the stage seen in the image 3. Granulonodular: Cysts with less oedema, more solidified 4. Nodular-Calcified: Parasite is no longer viable. Cysts calcify, with no active inflammation.

References:

Harrison’s Principles of Internal Medicine, 22nd Edition, Page 1138, 1835.

↑ *Back to this question in Part A*

@Neet_pg_bot

Q2: A 30 year old man presented with high grade fever, headache and vomitting for past 5 days. MRI head shows double rim sign in left temporal lobe . Guided aspiration from lesion shows gram positive filamentous bacteria stained with a positive modified

ZN staining and paraffin bait technique. What is the likely organism causing this? (Q851514)

A. Mycobacterium Tuberculosis

B. Atypical mycobacteria

C. Actinomyces israelli

D. Nocardia

Correct Answer: D. Nocardia

■ *Listen (English)*

■ *Listen (Hindi)*

Explanation: Double rim sign on MRI is a specific imaging feature of brain abscesses. The clinical features of headache and vomiting are explained by raised ICP and vasogenic cerebral edema seen in this patient. Gram-positive filamentous bacteria that are acid-fast with modified Ziehl-Neelsen staining strongly suggest Nocardia . The paraffin bait technique further supports Nocardia diagnosis.

References:

Harrison’s Principles of Internal Medicine, 22nd Edition, Page 1359, 1360.

↑ *Back to this question in Part A*

@Neet_pg_bot

Q3: Which of the following is the most common brain tumour in childhood? (Q851512)

A. Pilocytic astrocytoma

B. Medulloblastoma

C. Ependymoma

D. Metastasis

Correct Answer: A. Pilocytic astrocytoma

■ *Listen (English)*

■ *Listen (Hindi)*

Explanation: Pilocytic astrocytoma is the most common brain tumour found in children. It is a slow-growing, low-grade (Grade 1) tumour that typically occurs in the cerebellum. Most tumors in children are located

infratentorially . The most common childhood malignant brain tumors: Medulloblastomas High-grade gliomas Ependymomas

References:

Harrison’s Principles of Internal Medicine, 22nd Edition, Page 720.

↑ *Back to this question in Part A*

@Neet_pg_bot

Q4: Match the following syndromes with their most commonly seen brain tumours respectively. 1. Von Hippel Landau a) Bilateral vestibular schwannomas 2. Tuberous sclerosis b) Glioma 3. Neurofibromatosis 2 c) Hemangioblastoma of the cerebellum 4. Li Fraumeni Syndrome d) Subependymal giant cell astrocytoma (Q851511)

A. 1-c, 2-d, 3-a, 4-b

B. 1-b, 2-d, 3-c, 4-a

C. 1-d, 2-a, 3-b, 4-c

D. 1-b, 2-d, 3-a, 4-c

Correct Answer: A. 1-c, 2-d, 3-a, 4-b

■ *Listen (English)*

■ *Listen (Hindi)*

Explanation: Syndrome Associated Tumours Cowden's syndrome Dysplastic cerebellar gangliocytoma (Lhermitte-Duclos disease), meningioma, astrocytoma, breast, endometrial, thyroid cancer, trichilemmomas Gardner's syndrome Medulloblastoma, glioblastoma, craniopharyngioma, familial polyposis, multiple osteomas, skin and soft tissue tumours Li-Fraumeni syndrome Gliomas, medulloblastomas, sarcomas, breast cancer, leukaemia, and others Lynch syndrome Glioblastomas and other gliomas Multiple endocrine neoplasia type 1 (Wermer's syndrome) Pituitary adenoma, malignant schwannoma and pancreatic islet cell tumours NF1 Schwannomas, astrocytomas, optic nerve gliomas, meningiomas, neurofibromas, neurofibrosarcomas, and others NF2 Bilateral vestibular schwannomas, astrocytomas, multiple meningiomas, ependymomas Tuberous Sclerosis (Bourneville disease) Subependymal giant cell astrocytoma, ependymomas, glioma, ganglioneuroma, hamartoma Turcot syndrome Gliomas, medulloblastomas Von Hippel Landau Hemangioblastomas of the cerebellum, retinal angiomas, renal cell carcinoma, pheochromocytoma, pancreatic tumours and cysts, endolymphatic sac tumours of the middle ear

References:

Harrison’s Principles of Internal Medicine, 22nd Edition, Page 717.

↑ *Back to this question in Part A*

@Neet_pg_bot

Q5: A 40 year old man with a known brain tumour has recently undergone radiation therapy. During a follow-up visit, his doctor ordered imaging studies to evaluate the tumour. The physician wants to determine whether the changes observed on the imaging are due to tumour progression or necrosis resulting from treatment. Which imaging technique can help differentiate between the two? (Q851510)

A. Computed Tomography

B. Gadolinium-enhanced Magnetic Resonance Imaging

C. MR Spectroscopy

D. PET CT

Correct Answer: C. MR Spectroscopy

■ *Listen (English)*

■ *Listen (Hindi)*

Explanation: MR Spectroscopy provides insights into the chemical composition of the tissue, helping to distinguish between tumour progression and necrosis due to treatment. Magnetic Resonance Spectroscopy (MRS) is more specific than PET-CT in differentiating radiation necrosis from tumour recurrence, because: MRS detects elevated lipid-lactate peaks in necrosis (due to cell membrane breakdown). Tumour recurrence shows elevated choline (marker of cell membrane turnover). Hence, MRS is preferred when available for metabolic fingerprinting of lesions post-radiotherapy .

References:

Harrison's Principles of Internal Medicine, 22nd Edition, Page 716.

↑ *Back to this question in Part A*

@Neet_pg_bot

Q6: A 75-year-old male presents with recent onset frontal headache and seizures. Fundus reveals papilledema. MRI brain reveals a ring-enhancing lesion in the right frontal lobe with surrounding edema. MR Spectroscopy shows a high choline peak, low N-acetylaspartate (NAA), and elevated lipid-lactate peaks. Which of the following is the most likely diagnosis? (Q851509)

A. Tuberculoma

B. Neurocysticercosis

C. Brain tumor

D. Brain abscess

Correct Answer: C. Brain tumor

■ *Listen (English)*

■ *Listen (Hindi)*

Explanation: An elderly patient with new-onset headache, seizures, and papilledema suggests an intracranial space-occupying lesion. MRI shows a ring-enhancing frontal lesion with surrounding edema, raising suspicion for a malignant tumor. MR spectroscopy with high choline, low NAA, and an elevated lipid-lactate peak is characteristic of high-grade glioma/GBM, not TB, NCC, or abscess. Most likely diagnosis: Brain tumor (GBM). Tuberculoma (Option A) shows a prominent lipid peak, no amino acids, and a less choline rise, while our case has high choline. Plus, there is no history of fever, weight loss, or meningeal signs . NCC (Option B) causes can show lipid peak (only if degenerating cysts), but choline and NAA are reduced or absent. Brain abscess (Option D) causes very high-grade fever, a toxic appearance, which is not seen here. MRS shows amino acid peaks + lactate + restricted diffusion

References:

Harrison’s Principles of Internal Medicine, 22nd Edition, Page 719.
https://www.ncbi.nlm.nih.gov/books/NBK558954/

↑ *Back to this question in Part A*

@Neet_pg_bot

Q7: Identify the correct statements on CNS tumours Calcifications are found in Meningioma and Oligodendroglioma Craniopharyngioma are present as suprasellar mass Giant cell Astrocytoma and Ependymoma occur as Intraventricular tumours Metastatic lesions occur at white matter-gray matter junction (Q851507)

A. 1,2

B. 1,2,4

C. 1,2,3

D. 1,2,3,4

Correct Answer: D. 1,2,3,4

■ *Listen (English)*

■ *Listen (Hindi)*

Explanation: Intracranial calification is seen in meningioma, oligodendroglioma and craniophyrangioma. Craniophyrangioma is an supra sellar mass causing bitemporal hemianopia. Giant cell Astrocytoma and Ependymoma occur as Intraventricular tumours The usual source of metastasis to brain is oat cell cancer of lung that presents at gray and white matter interface. The metastatic cells can get trapped in the smaller blood vessels at the gray-white matter interface.

References:

Harrison's Principles of Internal Medicine, 22nd Edition, Page 718, 722, 723, 720.

↑ *Back to this question in Part A*

@Neet_pg_bot

Q8: Which of the following is the most common primary malignant brain tumour in adults? (Q851506)

A. Meningioma

B. Glioma

C. Metastasis from oat cell cancer of lung

D. CNS Lymphoma

Correct Answer: B. Glioma

■ *Listen (English)*

■ *Listen (Hindi)*

Explanation: Gliomas are the most common primary malignant brain tumours, with Grade IV glioma (formerly called glioblastoma multiforme) being the most aggressive subtype Overall the most common brain tumour: Metastasis Small cell cancer of lung/ oat cell cancer Breast cancer Malignant melanoma Prostate Cancer Most common primary benign cancer is meningioma (shows intracranial calcification)

References:

Harrison's Principles of Internal Medicine, 22nd Edition, Page 716.

↑ *Back to this question in Part A*

@Neet_pg_bot

Q9: A 30 year female presents with repeated episodes of GTCS since last 3 months. Neuroimaging is shown below. Which of the following treatment regimens is most appropriate? (Q851505)

A. Valproate

B. Praziquantel + Valproate

C. Steroids + Albendazole + Praziquantel

D. Steroids + Albendazole + Praziquental + Valproate



Correct Answer: A. Valproate

■ *Listen (English)*

■ *Listen (Hindi)*

Explanation: Diagnosis is Neurocysticercosis (NCC) and single calcified cyst is seen. Since this is end stage of parasite life cycle, there is no need for any cysticidal therapy. Since there is no vasogenic cererbral edema steroids are not required. Anti epileptic drugs will be required for atleast 2 years. Treatment for NCC Stage wise Vesicular (V iable) : Albendazole (± praziquantel for heavy/multiple or subarachnoid disease) with steroids. Colloidal (degenerating, inflammatory): Commonly treated with albendazole + steroids to hasten resolution and reduce seizure recurrence. Granular–nodular : Parasite largely dead; many guidelines do not routinely give anti-helminthics. Calcified : No anti-helminthic, no steroids; manage seizures only. Operative indication for Hydrocephalus

References:

Harrison’s Principles of Internal Medicine, 22nd Edition, Page 1138.

↑ *Back to this question in Part A*

@Neet_pg_bot

Q10: A 30-year-old man presents with progressive headaches, fever, weight loss, and left arm weakness over the past month. He remembers taking a long duration of antibiotic course for a respiratory illness in his childhood, but the specific details he is unable to recall. CT head is shown below. What is the most likely diagnosis? (Q851471)

A. Neurocysticercosis

B. Tuberculoma

C. Brain abscess

D. Metastasis

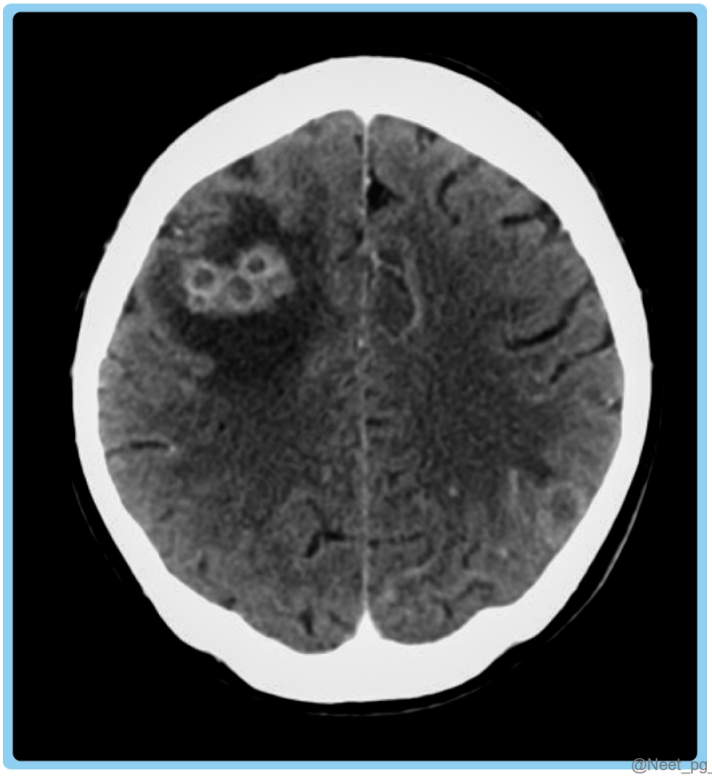

Correct Answer: B. Tuberculoma

■ *Listen (English)*

■ *Listen (Hindi)*

Explanation: The patient's symptoms of progressive headaches, fever, weight loss, focal neurological deficits, and the presence of larger, conglomerated lesions on the CT scan suggest tuberculoma, which is commonly associated with meningitis. Clinical manifestations of tuberculomas and tuberculous abscesses depend on their location. Most are located in the supratentorial compartment, and Present with headaches, seizures, papilledema and focal deficits occur. They present months to years after primary infection. CT - appear as low- or high-density round or lobulated masses with irregular walls showing homogenous enhancement after contrast administration. May be solitary or multiple Frontal and parietal lobe (most commonly affected) Radiographic appearance depends on whether the lesion is noncaseating, caseating with a solid center or caseating with a liquid center. Degree of perilesional edema is inversely proportional to the duration of the lesion. “Target sign” with a central nidus of calcification surrounded by a ring of enhancement was once thought to be diagnostic of a tuberculoma, but is now known to be quite non specific. Ring-enhancing lesions are usually seen on contrast imaging. Magnetic resonance spectroscopy is used to distinguish tuberculomas from cysticercosis. In patients with HIV, tuberculomas can cavitate and fill with fluid, turning into abscesses. CSF - may be normal Staining and culture for MTB would be normal if parenchyma only is involved. Feature Neurocysticercosis Tuberculoma of the Brain Lesions Smaller (< 20 mm), single or multiple Larger (> 20 mm), often multiple, conglomerated. Associated Meningitis Absent Present Location Junction of grey-white matter Common in the posterior fossa MR Spectroscopy Multiple amino acid peaks Lipid peaks Focal Neurological Deficits Absent Present Raised ICP Transient Present Constitutional Symptoms Absent Present CT images {{caption_text}} {{caption_text}} Brain Abscess (Option C): It usually presents as a smooth ring-enhancing lesion with fever, headache and other focal neurological deficits with marked vasogenic edema. {{caption_text}} Metastasis (Option D): Metastatic lesions can be multiple, and larger but they are usually ill-defined and typically do not present with significant meningitis. Additionally, the combination of fever, weight loss, and neurological deficits is more indicative of tuberculoma. {{caption_text}}

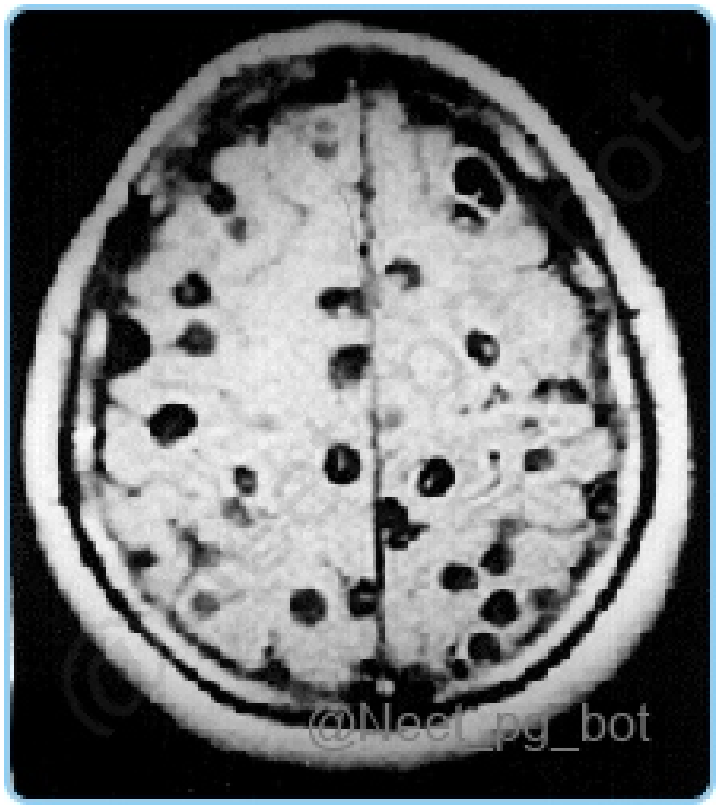


@Neet_pg_bot


@Neet_pg_bot



References:

Harrison’s Principles of Internal Medicine, 22nd Edition, Page 1389.

https://pmc.ncbi.nlm.nih.gov/articles/PMC8648135/

↑ *Back to this question in Part A*

@Neet_pg_bot

Q11: A 28 year old female presents with recurrent headaches and occasional seizures. Neuroimaging is done. Which stage of development of parasite is shown below? (Q851458)

A. Vesicular Stage

B. Colloidal Stage

C. Granulonodular Stage

D. Calcified Stage



Correct Answer: A. Vesicular Stage

- *Listen (English)*
- *Listen (Hindi)*

Explanation: Neurocysticercosis is a parasitic infection of the central nervous system caused by the larvae of Taenia solium , presenting with seizures, headaches, and neurological deficits. Diagnosis is typically confirmed through imaging (CT or MRI) showing cystic lesions, often with visible scolex, and supported by serological tests. The vesicular Stage is characterized by cystic lesions containing a visible scolex, often described as having a "hole-with-dot" appearance on MRI . There is no significant surrounding oedema or abnormal enhancement on gadolinium-enhanced MRI, which aligns with the findings described in the clinical scenario. MRI (Gadolinium-Enhanced) Features in Neurocysticercosis: Gadolinium-enhanced MRI is crucial for identifying and differentiating between the stages of neurocysticercosis. Vesicular Stage: (Live stage) Cystic lesions with a visible scolex ("hole-with-dot" appearance). No significant surrounding oedema or abnormal enhancement on gadolinium-enhanced MRI. Colloidal Stage: (Degenerating stage) Lesions show peripheral ring enhancement after gadolinium contrast administration. (Option B ruled out) Substantial surrounding oedema is visible, particularly on T2-weighted images. Granulonodular Stage: (Degenerating stage) Lesions exhibit homogeneous enhancement on post-contrast MRI. (Option C ruled out) No surrounding oedema is present, as seen on FLAIR images. Nodular-Calcified Stage: (Dead stage) No significant enhancement on gadolinium MRI. (Option D ruled out) Calcifications are better seen with susceptibility-weighted imaging (SWI), as they may not enhance well on standard MRI. {{caption_text}} A: MRI of a vesicular cyst- Well-defined scolex, minimal contrast enhancement, and mass effect. B: MRI of a colloidal cyst- Ring enhancement, loss of the scolex, and perilesional oedema. C: MRI of the nodular/granular stage- Nodule with diffuse enhancement and no cystic component. D: Noncontrast CT showing multiple punctuate calcifications.

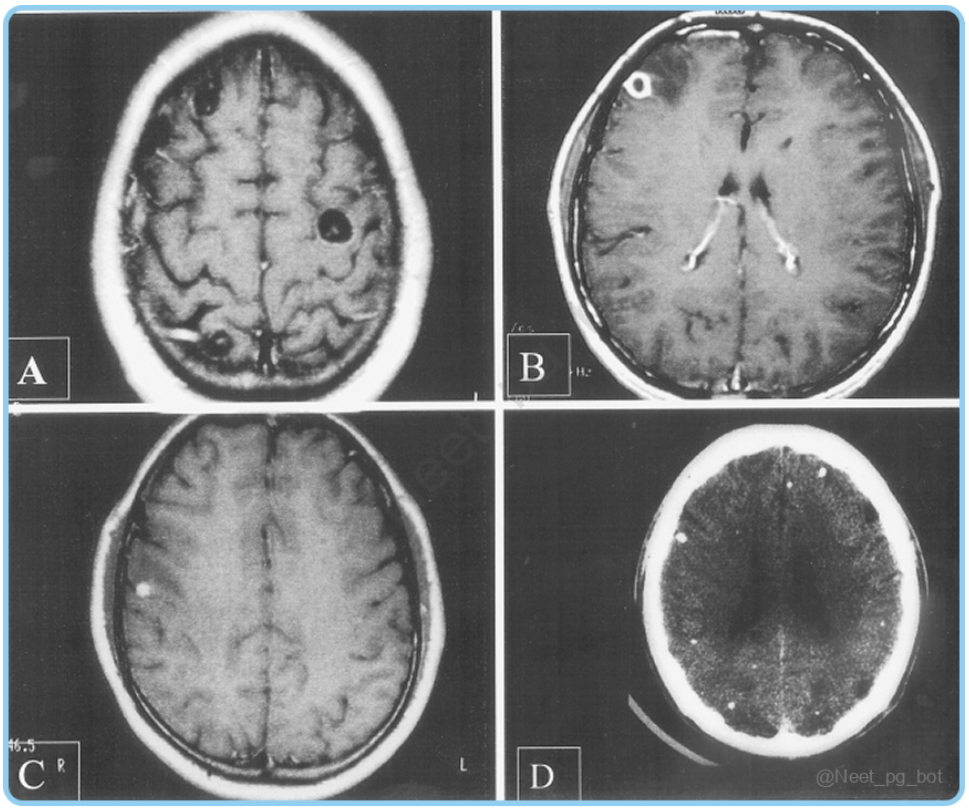

References:

Harrison’s Principles of Internal Medicine, 22nd Edition, Page 1139.

↑ *Back to this question in Part A*

@Neet_pg_bot

Q12: A 35 year old male presents with multiple episodes of GTCS and persistent headaches. Neuroimaging of patient is shown. Which of the following tests will help in confirmation of diagnosis of this patient? (Q851453)

A. PCR CBNAAT for MTB

B. Enzyme-Linked Immunotransfer Blot

C. Susceptibility-weighted imaging

D. Fundoscopic Exam

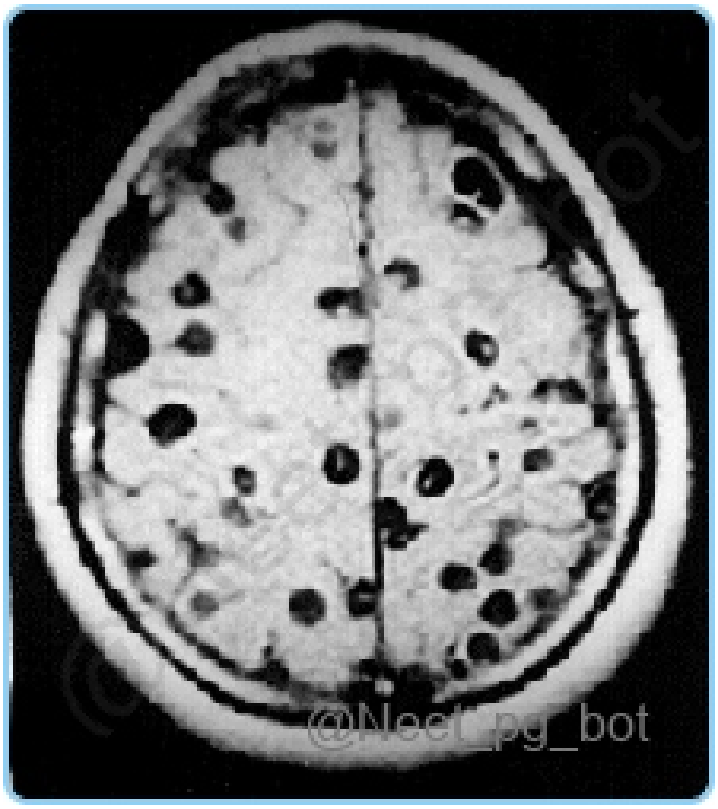

Correct Answer: B. Enzyme-Linked Immunotransfer Blot

■ *Listen (English)*

■ *Listen (Hindi)*

Explanation: The clinical presentation of GTCS, persistent headaches and neuroimaging showing several hypointense lesions with central white dot indicating scolex of developing larva are seen in Neurocysticercosis. Enzyme-Linked Immunotransfer Blot detects antibodies to Taenia solium antigens. It is a highly specific test and aids is confirmation of diagnosis.

References:

Harrison's Principles of Internal Medicine, 22nd Edition, Page 1138.

↑ *Back to this question in Part A*

@Neet_pg_bot

Q13: A 50 year hypertensive man suddenly develops face, arm and leg weakness. Imaging confirms a large putaminal bleed. What type of brain herniation is most likely to occur in this case? (Q851296)

A. Subfalcine herniation

B. Foraminal herniation

C. Transtentorial herniation

D. Cingulate herniation

Correct Answer: C. Transtentorial herniation

■ *Listen (English)*

■ *Listen (Hindi)*

Explanation: A transtentorial herniation is the most common type of brain herniation and involves the medial temporal gyrus (uncus) being pushed through the tentorium cerebelli due to increased ICP. Subfalcine herniation and cingulate herniation (Option A and D) mean the same. It occurs when the cingulate gyrus is pushed under the falx cerebri., crossing the midline. In Foraminal herniation (Option B), cerebellar tonsils are forced downward through the foramen magnum, which can compress the brainstem and disrupt vital structures and occurs when LP is done in case of raised ICP . {{caption_text}} Different types of brain herniations

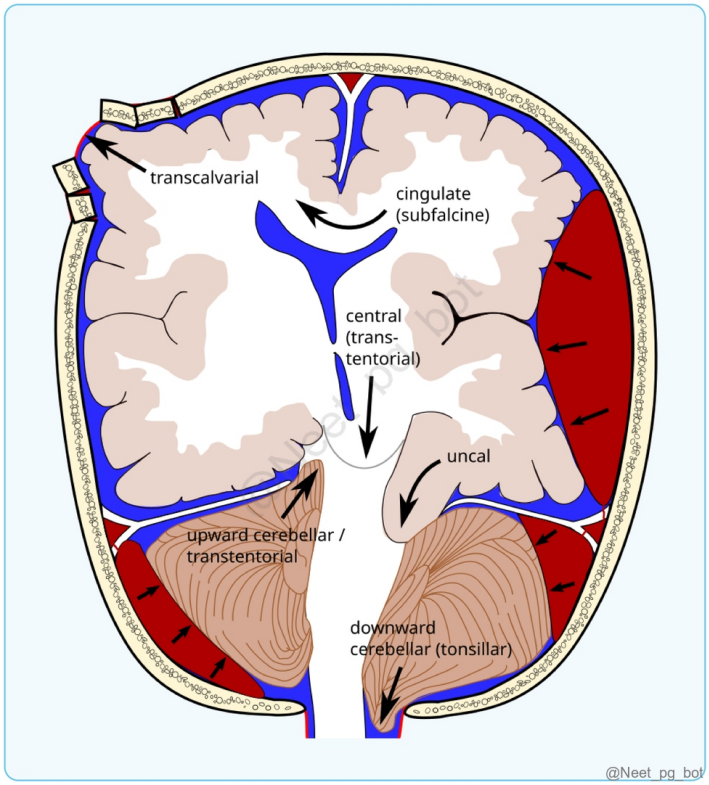

References:

Harrison’s Principles of Internal Medicine, 22nd Edition, Page 187, 188.

↑ *Back to this question in Part A*

@Neet_pg_bot

Q14: 32 year man presents with recurrent seizures. MRI brain shows multiple hypointense lesions with scolex. What is the most likely cause of his condition? 1. Consumption of semi cooked pork containing Cysticerci cellulosae 2. Feco-oral 3. Consumption of semi cooked beef containing Cysticercus bovis 4. Autoinfection (Q851369)

A. 1

B. 1,2

C. 2,4

D. 1,2,3,4

Correct Answer: C. 2,4

■ *Listen (English)*

■ *Listen (Hindi)*

Explanation: Neurocysticercosis occurs when humans ingest T. solium eggs in contaminated food items like cabbage and lettuce. The proglottids containing eggs are sticky and stick to peri-anal area. So autoinfection is also possible Consumption of semi cooked pork containing cysticerci cellulosae : This leads to tapeworm (taeniasis/intestinal infection), NOT cysticercosis in humans (Statement 1) Consumption of semi cooked beef containing cysticercus bovis: Irrelevant to the case; beef tapeworm (Taenia saginata) does not cause cysticercosis in humans. (Statement 3) {{caption_text}}

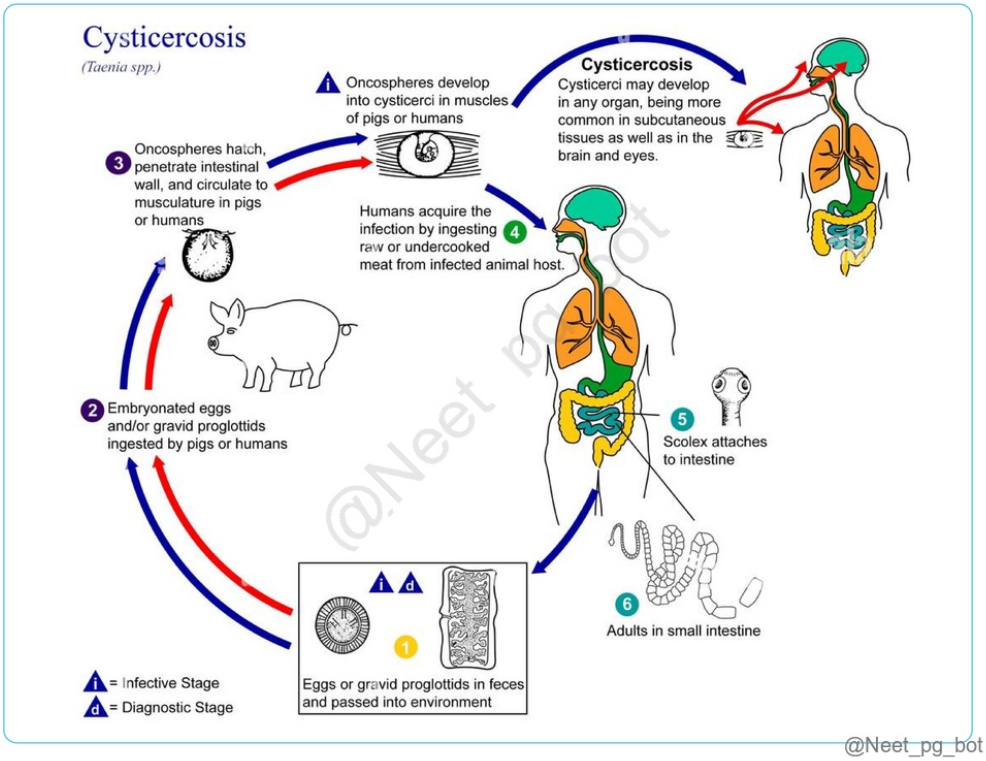

References:

Harrison's Principles of Internal Medicine, 22nd Edition, Page 1833.

↑ *Back to this question in Part A*

@Neet_pg_bot

Q15: An elderly diabetic patient living alone is found unconscious and unresponsive by the maid. On admission, pulse is 100/min, BP =90/60 mm Hg. Workup shows RBS is 200 mg/dl, urine ketostix is 1+, pH =7.42, pC02= 40 mm Hg, HCO3= 26 meq, Na = 130 meq/L and K= 4.0 meq/L and procalcitonin and CRP is normal . Which is the next best step in management of this patient? (Q851367)

A. Start normal saline drip and urgent NCCT head

B. Start normal saline drip and insulin drip

C. Give 50 ml of 50% dextrose

D. Give bolus 10 units of regular insulin followed by insulin drip

Correct Answer: A. Start normal saline drip and urgent NCCT head

■ *Listen (English)*

■ *Listen (Hindi)*

Explanation: This unconscious, unresponsive diabetic is hypotensive on admission with hyponatremia. Neuroimaging should be done to rule out stroke as the cause of the unconscious state. Fluids should be given to stabilise the BP. DKA is ruled out as ABG is normal. Hyperosmolar coma is ruled out as blood sugar is 200 mg/dl only. CRP and procalcitonin is normal and rules out sepsis.

References:

Harrison's Principles of Internal Medicine, 22nd Edition, Page 192.

↑ *Back to this question in Part A*

@Neet_pg_bot

Q16: A 50 year woman presents with seizure episode. She in ER she tells that she wakes up with daily early morning frontal headaches and vomiting. NCCT head shows intracranial space-occupying lesion in frontal lobe with dural tail sign. Which of the following cranial nerves is most likely to be involved in this patient? (Q851364)

A. I

B. II

C. III

D. IV

Correct Answer: B. II

■ *Listen (English)*

■ *Listen (Hindi)*

Explanation: The patient is having a brain tumour/ meningioma based on radiological findings. Raised ICP commonly leads to papilledema, which is swelling of the optic disc due to increased pressure transmitted via the cerebrospinal fluid around the optic nerve. So the answer will be optic nerve. Seizures in this patient can be explained by vasogenic cerebral edema seen with brain tumor. Overall the most common cranial nerve involved in raised ICP is the abducens nerve (CN VI), leading to lateral gaze difficulty (inability to move the eye outward)

References:

Harrison's Principles of Internal Medicine, 22nd Edition, Page 222.

↑ *Back to this question in Part A*

@Neet_pg_bot

Q17: 38-year-old HIV-positive man presents with recurrent seizures and altered sensorium. MRI brain reveals multiple ring-enhancing lesions with perilesional edema in the basal ganglia and frontal lobe, showing the "concentric target" sign. What is the most likely cause of his seizures? (Q851338)

A. Cerebral toxoplasmosis

B. Primary CNS Lymphoma

C. Neurocysticercosis

D. Tuberculoma

Correct Answer: A. Cerebral toxoplasmosis

■ *Listen (English)*

■ *Listen (Hindi)*

Explanation: Cerebral toxoplasmosis is the leading cause of multiple "concentric target" sign ring lesions in HIV patients, typically in basal ganglia or frontal lobes. Primary CNS lymphoma (Option B) usually appears as a solitary enhancing lesion, less often with target signs. Neurocysticercosis (Option C) shows cysts with scolex ("dot sign") rather than concentric targets. Tuberculoma (Option D) may have ring enhancement but lacks the classic concentric target appearance seen in toxoplasmosis.

References:

Harrison’s Principles of Internal Medicine, 22nd Edition, Page 1802.

↑ *Back to this question in Part A*

@Neet_pg_bot

Q18: Which of the following is not a correct component in brain death evaluation? (Q851337)

A. Apnea test with pCO■ rise to ≥60 mmHg or ≥20 mmHg above baseline

B. Positive caloric stimulation test

C. Pupils are fixed and non reactive to light

D. Absence of blinking on touching cornea with wisp of cotton

Correct Answer: B. Positive caloric stimulation test

■ *Listen (English)*

■ *Listen (Hindi)*

Explanation: A positive caloric test means the presence of nystagmus in response to cold or warm water irrigation of the ear, indicating an intact brainstem vestibulo-ocular reflex. In the context of brain death assessment, a positive caloric test is inconsistent with brain death , Brain Death Investigations Clinical Tests to Confirm Brain Death Absence of brainstem reflexes : Fixed, non-reactive pupils. Absent corneal and vestibulo-ocular reflexes. No motor response to cranial nerve stimulation. Absent gag reflex and no response to tracheal suctioning. Apnoea Test : Checks for Spontaneous respiratory effort. There is no respiratory effort in brain death when disconnected from the ventilator, despite PaCO2 rising above 60 mmHg.

References:

Harrison's Principles of Internal Medicine, 22nd Edition, Page 192.

↑ *Back to this question in Part A*

@Neet_pg_bot

Q19: 30-year-old biker is brought to the emergency room after a head injury. On examination, he is unconscious with an ipsilateral mid-dilated fixed pupil. NCCT head shows lenticular hyperdensity. Which of the following is the most likely cause and urgent next step? (Q851335)

A. Uncal herniation due to epidural hematoma; immediate burr hole surgery required

B. Cingulate herniation due to epidural hematoma; immediate burr hole surgery required

C. Cingulate herniation due to epidural hematoma; urgent craniotomy

D. Subdural hematoma causing contralateral pupil dilation; urgent craniotomy

Correct Answer: A. Uncal herniation due to epidural hematoma; immediate burr hole surgery required

■ *Listen (English)*

■ *Listen (Hindi)*

Explanation: An ipsilateral mid-dilated fixed pupil following head trauma strongly suggests uncal herniation from an epidural hematoma causing compression of the third cranial nerve. This is a neurosurgical emergency requiring immediate surgical decompression, often by burr hole drainage. The other options either describe different injury patterns or pupillary findings that do not match the clinical picture requiring urgent burr hole surgery.

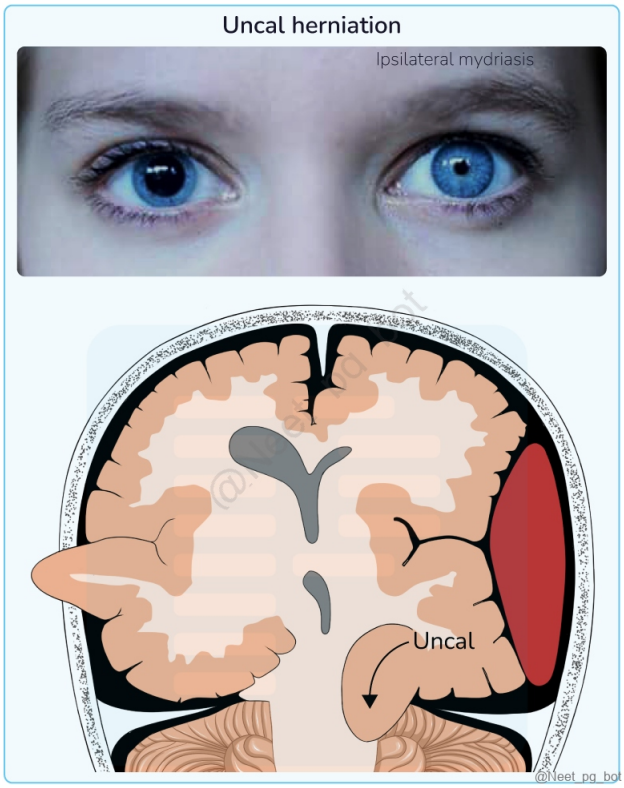

References:

Harrison’s Principles of Internal Medicine, 22nd Edition, Page 187.

↑ *Back to this question in Part A*

@Neet_pg_bot

Q20: Adult patient involved in a high-speed road traffic accident had a normal CT scan on admission but died within 6 hours. Autopsy reveals petechial hemorrhages in the corpus callosum and retraction balls. The diagnosis is? (Q851333)

A. Diffuse axonal injury

B. SAH

C. SDH

D. EDH

Correct Answer: A. Diffuse axonal injury

■ *Listen (English)*

■ *Listen (Hindi)*

Explanation: Diffuse axonal injury occurs due to rapid acceleration-deceleration or rotational forces in high-impact trauma, causing shearing injury to the axons, especially in areas like the corpus callosum and brainstem. The "retraction balls" represent swollen, broken ends of damaged axons, a hallmark microscopic finding in DAI. Petechial hemorrhages in the corpus callosum and other white matter areas are caused by small vessel rupture during shearing injury. Initial CT scans are often normal or show minimal findings despite severe injury, making early diagnosis challenging.

References:

Harrison's Principles of Internal Medicine, 22nd Edition, Page 3573.
https://www.ncbi.nlm.nih.gov/books/NBK448102/

↑ *Back to this question in Part A*

@Neet_pg_bot

Q21: A patient diagnosed with TB meningitis develops posturing as shown in the diagram. Which of the following is correct about the cause of this presentation (Q851332)

A. Inhibition of the rubrospinal with overactivity of vestibulospinal and reticulospinal pathways

B. Stimulation of the rubrospinal tract with simultaneous facilitation of vestibulospinal and reticulospinal tracts

C. Intact or overactive rubrospinal tract with loss of extensor facilitation from vestibulospinal and reticulospinal tracts

D. Loss of rubrospinal tract activity with strong extensor inhibition from vestibulospinal and reticulospinal tracts

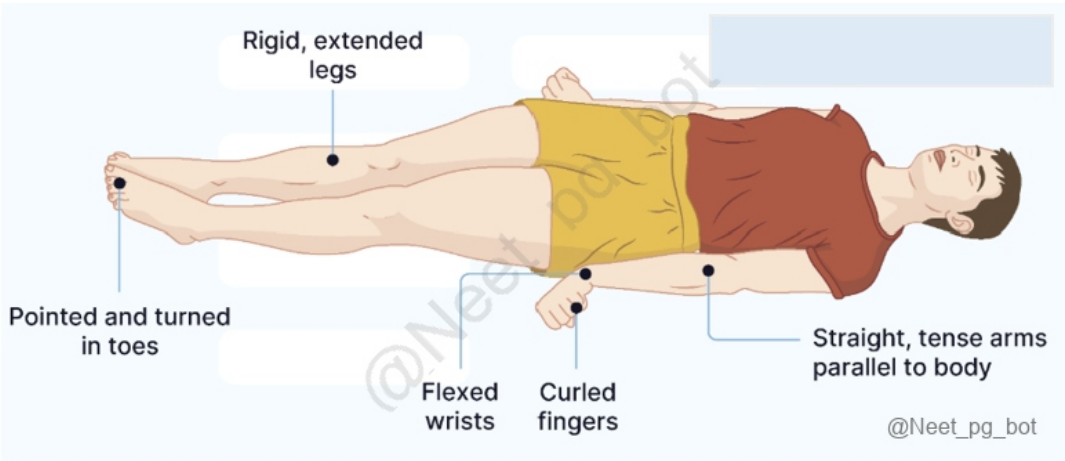

Correct Answer: A. Inhibition of the rubrospinal with overactivity of vestibulospinal and reticulospinal pathways

■ *Listen (English)*

■ *Listen (Hindi)*

Explanation: Patient has extension in arms and legs seen in decerebrate posturing. The key issue is damage below the red nucleus in the brainstem , which affects the balance of motor pathways controlling flexor and extensor muscles. Flexors in arms are controlled by Rubrospinal tract , originating from the red nucleus in the midbrain. These are the ones damaged in decerebrate posturing where damage is below the level of red nucleus. Extensor in arms and legs are controlled by Vestibulospinal tract and Pontine reticulospinal tract. These extensor pathways remain intact and become overactive due to loss of inhibitory/facilitatory input from the damaged flexor pathways. Intact or overactive rubrospinal tract with loss of extensor facilitation from vestibulospinal and reticulospinal tracts (Option C) describes a lesion above the red nucleus , where rubrospinal activity is preserved and drives upper-limb flexion while extensors act on the legs — the hallmark of decorticate posturing. Loss of rubrospinal tract activity with strong extensor inhibition from vestibulospinal and reticulospinal tracts (Option D) is the opposite of decorticate mechanisms, with both rubrospinal and extensor systems suppressed, which would not result in a classical rigid posture but rather severe hypotonia. Posturing

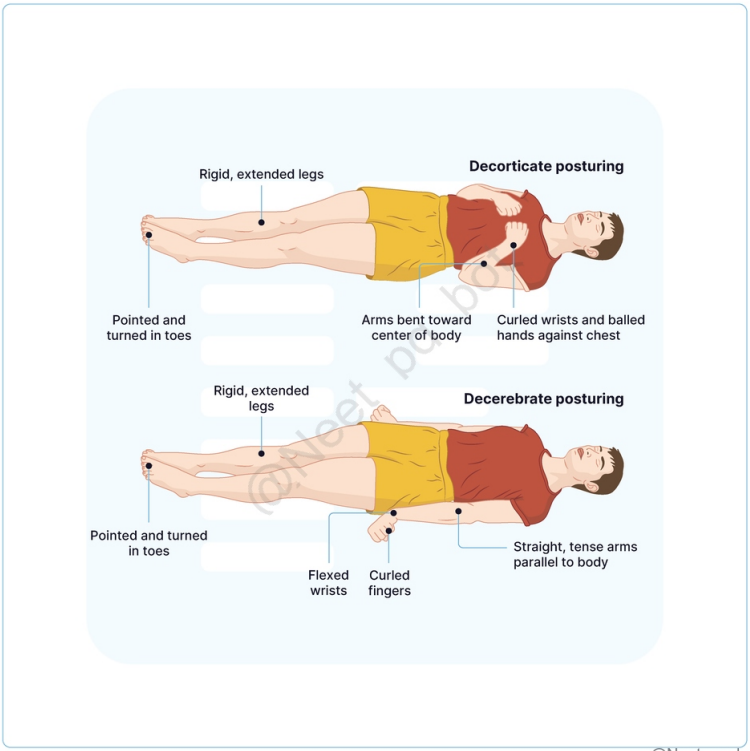

@Neet_pg_bot

References:

Harrison’s Principles of Internal Medicine, 22nd Edition, Page 189.
https://www.ncbi.nlm.nih.gov/books/NBK555949/

↑ *Back to this question in Part A*

@Neet_pg_bot

Q22: 60-year-old hypertensive man is brought to ER with sudden onset right-sided weakness and aphasia. His BP is 190/100 mmHg. CT scan done 1 hour after admission shows putaminal bleed and midline shift. Which of the following is not useful for management of this patient? (Q851331)

A. Ventriculostomy

B. Start IV dexamethasone

C. Mannitol

D. Labetalol

Correct Answer: B. Start IV dexamethasone

■ *Listen (English)*

■ *Listen (Hindi)*

Explanation: The patient is having hemorrhagic stroke with midline shift. Both Labetalol to control BP to <140/90 mm Hg and mannitol for midline shift are required in this case. (Option C and D) Ventriculostomy would be the most efficient step to control raised ICP in this patient. (Option A) There is no role steroids in this case. Steroids are used in case of vasogenic cerebral edema while stroke patient will have cytotoxic cerebral edema.

References:

Harrison's Principles of Internal Medicine, 22nd Edition, Page 2345.

↑ *Back to this question in Part A*

@Neet_pg_bot

Q23: A 35 year old biker male is brought to the ED after a road traffic accident. He is unconscious with a GCS score of 9/15. Vitals are Pulse 60/min with BP: 160/100 mmHg and irregular respiration. What is the first step in managing of this patient? (Q851330)

A. Elective Hyperventilation

B. Administer mannitol

C. Elevate head end of bed and secure airway

D. Burr hole surgery

Correct Answer: C. Elevate head end of bed and secure airway

■ *Listen (English)*

■ *Listen (Hindi)*

Explanation: The patient shows signs of raised intracranial pressure, including a low GCS value and cushing triad. The first step in managing raised ICP is to elevate the head end of the bed to 30 degrees and secure airway . T his simple, non-invasive measure helps facilitate venous drainage from the brain, reducing intracranial pressure without compromising cerebral perfusion. Mnemonic for Initial Raised ICP Management:"HEADS UP" H ead elevation (30°) E nsure Airway (intubate if GCS <8) A void hypotension/hypoxia D rugs like mannitol (after airway secured) S can (CT brain) U rgent neurosurgical referral P aCO■ control (hyperventilation if signs of herniation)

References:

Harrison’s Principles of Internal Medicine, 22nd Edition, Page 2345.

↑ *Back to this question in Part A*

@Neet_pg_bot

• [07_Neurology] 059 Previous Year Questions

« Back to Folder Directory

[07_Neurology] 059 Previous Year Questions — Quick Jump

Q1 (p. 2440)	*Q2 (p. 2441)*	*Q3 (p. 2442)*	*Q4 (p. 2443)*	*Q5 (p. 2444)*	*Q6 (p. 2445)*
Q7 (p. 2446)	*Q8 (p. 2446)*	*Q9 (p. 2447)*	*Q10 (p. 2448)*	*Q11 (p. 2449)*	*Q12 (p. 2450)*
Q13 (p. 2452)	*Q14 (p. 2455)*	*Q15 (p. 2456)*	*Q16 (p. 2457)*	*Q17 (p. 2457)*	*Q18 (p. 2458)*
Q19 (p. 2459)	*Q20 (p. 2459)*	*Q21 (p. 2460)*	*Q22 (p. 2462)*	*Q23 (p. 2465)*	*Q24 (p. 2466)*
Q25 (p. 2467)	*Q26 (p. 2469)*	*Q27 (p. 2474)*	*Q28 (p. 2474)*	*Q29 (p. 2475)*	*Q30 (p. 2476)*
Q31 (p. 2478)	*Q32 (p. 2479)*	*Q33 (p. 2480)*	*Q34 (p. 2481)*	*Q35 (p. 2482)*	*Q36 (p. 2484)*
Q37 (p. 2486)	*Q38 (p. 2488)*	*Q39 (p. 2489)*	*Q40 (p. 2491)*	*Q41 (p. 2492)*	*Q42 (p. 2494)*
Q43 (p. 2495)	*Q44 (p. 2496)*	*Q45 (p. 2498)*	*Q46 (p. 2499)*	*Q47 (p. 2499)*	*Q48 (p. 2502)*
Q49 (p. 2502)	*Q50 (p. 2503)*	*Q51 (p. 2504)*	*Q52 (p. 2505)*	*Q53 (p. 2505)*	*Q54 (p. 2507)*
Q55 (p. 2507)	*Q56 (p. 2508)*	*Q57 (p. 2509)*	*Q58 (p. 2510)*	*Q59 (p. 2511)*	*Q60 (p. 2512)*
Q61 (p. 2512)	*Q62 (p. 2513)*	*Q63 (p. 2514)*	*Q64 (p. 2515)*	*Q65 (p. 2516)*	*Q66 (p. 2517)*
Q67 (p. 2518)	*Q68 (p. 2519)*	*Q69 (p. 2520)*	*Q70 (p. 2521)*	*Q71 (p. 2522)*	*Q72 (p. 2523)*
Q73 (p. 2524)	*Q74 (p. 2525)*	*Q75 (p. 2526)*	*Q76 (p. 2527)*	*Q77 (p. 2528)*	*Q78 (p. 2529)*
Q79 (p. 2530)	*Q80 (p. 2530)*	*Q81 (p. 2531)*	*Q82 (p. 2532)*	*Q83 (p. 2533)*	*Q84 (p. 2533)*
Q85 (p. 2534)	*Q86 (p. 2535)*	*Q87 (p. 2536)*	*Q88 (p. 2537)*	*Q89 (p. 2538)*	*Q90 (p. 2539)*
Q91 (p. 2539)	*Q92 (p. 2540)*	*Q93 (p. 2541)*	*Q94 (p. 2542)*	*Q95 (p. 2543)*	*Q96 (p. 2544)*
Q97 (p. 2544)	*Q98 (p. 2545)*	*Q99 (p. 2546)*	*Q100 (p. 2547)*		

Q1: Where is the site of the lesion that leads to the occurrence of hemiballismus in a patient displaying forceful, flinging movements? (Q855718)

A. Putamen

B. Subthalamic nucleus

C. Caudate nucleus

D. Globus pallidus

Correct Answer: B. Subthalamic nucleus

Explanation: Ballismus is a violent form of choreiform movement composed of wild, flinging, large-amplitude movements most frequently affecting proximal limb muscles on one side of the body (hemiballism). It is typically caused by a lesion in the subthalamic nucleus (STN) of the basal ganglia. Lesions in the putamen (Option A) are

associated with chorea, not hemiballismus. Lesions in the caudate nucleus (Option C) are associated with Huntington's disease, which causes chorea as well. Lesions in the globus pallidus (Option D) can cause various movement disorders, such as dystonia or Parkinson's disease, but they are not specifically associated with hemiballismus. Movement disorder Lesions Chorea Lesions in the putamen Dystonia Lesions in the globus pallidus Ballism/Hemiballismus Lesion in subthalamic nucleus (STN) Huntington's Disease (HD) Lesions in the caudate nucleus Sydenham's chorea Rheumatic heart disease Condition Description Tremor Rhythmic oscillation of a body part due to intermittent muscle contractions. Dystonia Involuntary, patterned, sustained, or repeated muscle contractions often associated with twisting movements and abnormal posture. Athetosis Slow, distal, writhing, involuntary movements with a propensity to affect the arms and hands (this represents a form of dystonia with increased mobility). Chorea Rapid, semipurposeful, graceful, dance like non patterned involuntary movements involving distal or proximal muscle groups. When the movements are of large amplitude and predominant proximal distribution, the term ballism is used. Ballismus Violent form of choreiform movement composed of wild, flinging, large-amplitude movements most frequently affecting proximal limb muscles on one side of the body Myoclonus Sudden, brief (<100 ms), jerklike, arrhythmic muscle twitches. Tic Brief, repeated, stereotyped muscle contractions that can often be suppressed for a short time. These can be simple and involve a single muscle group or complex and affect a range of motor activities.

References:

Harrison's Principles of Internal Medicine, 21st Edition, Page 3401 - 3407

↑ *Back to this question in Part A*

@Neet_pg_bot

Q2: A 45 year old male patient presented with a history of bilateral lower limb weakness which progressed to his upper limbs in a year. On examination, he had weakness in both lower limbs and wasting in the left upper limb. Babinski sign was positive and the deep tendon reflexes were absent. He has no sensory loss or any autonomic dysfunction. What is the likely diagnosis? (Q856621)

A. MS

B. ALS

C. GBS

D. Tropical spastic paraparesis

Correct Answer: B. ALS

Explanation: LS is the most common progressive motor neuron disease and a prime example of neurodegenerative disorders. Genetic Causes: Mutant Proteins: SOD1, ubiquilin-1/-2, and p62 mutations disrupt protein degradation. RNA Processing: C9orf72, TDP43, and FUS mutations affect RNA transport/processing. Axonal Transport: Mutations in dynactin and profilin-1 affect axonal transport. Pathology: The hallmark of ALS is the death of both

lower motor neurons (anterior horn cells and brainstem motor neurons) and upper motor neurons (corticospinal neurons). ALS involves both denervation and muscle atrophy, particularly in proximal muscles, and results in selective loss of motor neurons. Clinical Manifestations: Lower Motor Neuron Dysfunction: Asymmetric muscle weakness , muscle cramping, fasciculations, muscle atrophy and bulbar palsy. Upper Motor Neuron Dysfunction: Reflex hyperactivity , muscle stiffness, spasticity and pseudobulbar palsy. Corticobulbar Projection Degeneration: Results in dysarthria (speech difficulty) and pseudobulbar affect (excessive weeping or laughing). Symmetric Muscle Involvement: Over time, more muscle groups become involved , leading to a symmetric distribution of the disorder in all regions. Preserved Sensory and Cognitive Functions: Sensory, bowel and bladder , and cognitive functions are preserved even in the late stages. Ocular Motility Sparing: Ocular motility remains unaffected until the very late stages of ALS. Treatment: No treatment halts the underlying ALS pathology. Riluzole: Reduces excitotoxicity via decreased glutamate release. Edaravone: Acts as an antioxidant and it modestly reduces disability progression. Phenylbutyrate and Taurursodiol: Oral combination shown to slow disease progression and extend survival by improving mitochondrial and endoplasmic reticulum function. Multiple sclerosis (Option A) typically presents with relapsing-remitting episodes, optic neuritis, and a combination of upper motor neuron (UMN) and sensory deficits, which are absent in this case, and the patient lacks the characteristic visual and brainstem symptoms like ataxia and nystagmus. Guillain-barre syndrome (Option C) causes rapidly progressive ascending paralysis with areflexia, sensory involvement, and autonomic dysfunction, which this patient does not exhibit, as the weakness is bilateral and progressive over a longer period without sensory loss. Tropical spastic paraparesis (Option D) is associated with spastic paraparesis, sensory deficits, and bladder disturbances but no lower motor neuron (LMN) involvement, which contrasts with this patient's presentation of muscle wasting (suggestive of LMN involvement) and absence of bladder dysfunction.

References:

Harrison’s Principles of Internal Medicine, 21st Edition, Page 3410-3415

↑ *Back to this question in Part A*

@Neet_pg_bot

Q3: Which of the following drugs is preferred in the management of primary progressive multiple sclerosis? (Q856612)

A. Natalizumab

B. Ocrelizumab

C. Fingolimod

D. Alemtuzumab

Correct Answer: B. Ocrelizumab

Explanation: - Ocrelizumab The preferred drug in the management of primary progressive multiple sclerosis is Ocrelizumab. Multiple Sclerosis (MS): MS is an autoimmune disease of the central nervous system (CNS) characterized by chronic inflammation, demyelination, gliosis (plaques or scarring) and neuronal loss. Clinical

Types of MS: Relapsing or Bout-Onset MS (RMS) Secondary Progressive MS (SPMS) Primary Progressive MS (PPMS) Management of MS: Acute Attacks or Initial Demyelinating Episodes: Glucocorticoids are used to reduce the severity and duration of attacks: Intravenous methylprednisolone: 500-1000 mg/day for 3-5 days. Oral glucocorticoids (methylprednisolone, prednisone, dexamethasone) can replace IV therapy. Disease-Modifying Therapies (DMTs): Drugs used for treatment of Relapsing MS: Highly Effective Moderately Effective Modestly Effective Anti-CD20 Monoclonal Antibodies: Ocrelizumab, Ofatumumab, Rituximab Anti-α4 Integrin Monoclonal Antibody: Natalizumab (Option A) Mitoxantrone Hydrochloride Anti-CD52 Antibody: Alemtuzumab (Option D) S1P Receptor Modulators: Fingolimod , Ozanimod, Ponesimod (Option C) Dimethyl Fumarate Cladribine Glatiramer acetate Interferon beta Teriflunomide Drugs used for treatment of Progressive MS: Siponimod: Selective S1P1/S1P5 receptor modulator. Reduces progression, relapse risk, and MRI burden in SPMS with active disease. Ocrelizumab, cladribine, and ponesimod are approved for active SPMS. Drugs used for treatment of Primary Progressive MS (PPMS): Ocrelizumab: Reduces disability progression by 24% in PPMS. Improves clinical and MRI markers of disease activity.

References:

Harrison's Principles of Internal Medicine 21st Edition, Page 871,872

↑ *Back to this question in Part A*

@Neet_pg_bot

Q4: Treatment of choice for an acute attack of cluster headache is: (Q856604)

A. Oral sumatriptan

B. Subcutaneous sumatriptan

C. 100% oxygen at 6 L/minute

D. 100% oxygen at 8 L/minute

Correct Answer: B. Subcutaneous sumatriptan

Explanation: - Subcutaneous sumatriptan: For an acute attack of cluster headache, the treatment of choice is 100% oxygen at 10-12 L/minute and subcutaneous sumatriptan. Cluster Headache: Rare primary headache, with a prevalence of ~0.1%, characterized by excruciating, nonfluctuating, retro-orbital pain of explosive quality. Periodicity: Attacks occur daily, with one or two short-duration, unilateral pain episodes lasting 15-180 minutes. Cluster bouts last for weeks, followed by a pain-free interval, typically lasting less than a year. Chronic cluster headache is defined by <3 months of sustained remission. Symptoms: Ipsilateral autonomic symptoms: Conjunctival injection, lacrimation, nasal congestion, and aural fullness. Sympathetic dysfunction (e.g., Ptosis) Unilateral photophobia and phonophobia Treatment of Acute Attack of Cluster Headache: Oxygen: Inhaled 100% oxygen at 10-12 L/min for 15-20 minutes. (Option C & D) Sumatriptan: Subcutaneous 6 mg is effective , reducing attack duration to 10-15 minutes. Sumatriptan and Zolmitriptan Nasal Sprays: Effective alternatives for patients who prefer not to self-inject. Noninvasive Vagus Nerve Stimulation (nVNS): FDA approved for episodic cluster headache; involves three 2-minute stimulation cycles at headache onset. Oral sumatriptan (Option A) is not

suitable for acute cluster headache attacks because it may not provide the same rapid relief as subcutaneous sumatriptan.

References:

Harrison's Principles of Internal Medicine 21st Edition, Page 3366

↑ *Back to this question in Part A*

@Neet_pg_bot

Q5: A 50-year-old man presents with sudden right-sided weakness and aphasia for 2 hours. His blood pressure is 160/110 mmHg, and non-contrast CT of the brain is normal. To identify a possible large vessel occlusion, what is the next best step in management? (Q856595)

A. CT angiography

B. MRI to look for intact

C. Tab labetalol 10 mg stat

D. Thrombolysis

Correct Answer: A. CT angiography

Explanation: The patient presents with acute ischemic stroke symptoms within the therapeutic window, non-contrast CT ruled out hemorrhage and is the initial imaging step. To identify a large vessel occlusion (LVO), CT angiography (CTA) is recommended as the next imaging modality. CTA quickly visualizes intracranial and extracranial vessels to detect occlusions amenable to endovascular therapy. Early identification of LVO allows timely planning for possible thrombectomy. Workup for stroke Initial Assessment and Stabilization Upon arrival, ensure the ABCs (Airway, Breathing, Circulation) are stable. Blood glucose levels should be checked quickly to address hypoglycemia or hyperglycemia. Determining Stroke Type: Imaging is Key A non-contrast CT scan is the primary imaging modality for differentiating between ischemic and hemorrhagic strokes. Clinical features may suggest stroke type, but imaging is essential for confirmation as no clinical finding can definitively differentiate between the two. Further Investigations: Uncovering the Cause Detailed History and Physical Exam: Consider risk factors (hypertension, diabetes, smoking, atrial fibrillation, etc.) and perform a neurological exam to localize the affected brain area. Laboratory Tests: Perform CBC, electrolytes, renal function, blood glucose, lipid profile, coagulation studies, ESR, and ECG (to detect arrhythmias and signs of recent MI). Visualizing the Cerebral Vasculature: Imaging Techniques CT Angiography (CTA) : Assesses cerebral vasculature and identifies blockages/stenosis , but is performed after non-contrast CT has ruled out hemorrhage (not for stroke type differentiation). CT Perfusion Imaging : Assesses blood flow, identifying reduced perfusion and ischemic penumbra. MRI: Provides more detail but takes longer than CT and is not as widely available, thus not the first imaging choice for acute stroke evaluation. (Option B ruled out) MRA: Offers detailed images of blood vessels, similar to CTA. Cerebral Angiography: Gold standard for vessel evaluation, used when other techniques are inconclusive or before endovascular intervention. Ultrasound Techniques : Carotid Duplex Ultrasonography

assesses carotid stenosis but is not a first-line acute imaging modality; Transcranial Doppler (TCD) measures blood flow velocity in intracranial arteries. Tailoring Investigations Based on Stroke Type Ischemic Stroke : Focuses on identifying the source of the blockage (cardioembolic, artery-to-artery embolic, small vessel disease). Hemorrhagic Stroke: Investigations focus on identifying causes of bleeding (e.g., hypertension, aneurysm, vascular malformation). Tablet labetalol 10 mg stat (Option C): BP control alone does not address the underlying large vessel occlusion. Thrombolysis (Option D) Should only be given after confirming eligibility and assessing vessel status; CT angiography helps guide this decision.

References:

Harrison's Principles of Internal Medicine, 21st Edition, Page 3335-3340

↑ *Back to this question in Part A*

@Neet_pg_bot

Q6: True about electroencephalogram (EEG) is all except: (Q855720)

A. 1-5% of the population can have epileptiform discharges

B. Scalp EEG may be helpful in localizing frontal lobe epilepsy

C. Doing EEG is mandatory for diagnosis of seizures

D. Progressive multifocal leukoencephalopathy shows triphasic and slow waves on EEG

Correct Answer: C. Doing EEG is mandatory for diagnosis of seizures

Explanation: Doing EEG is not mandatory for diagnosis of seizures. Electroencephalography (EEG): Records electrical activity in the brain using electrodes placed on the scalp. It is a dynamic test, EEG frequencies and distribution vary based on factors like brain maturation, age, alertness, and medication. NICE Guidelines: Emphasize not relying solely on EEG for diagnosis. It should be used to: Define seizure type and syndrome. Guide treatment and prognosis. EEG is critical when: Non-convulsive status epilepticus is suspected. Continuous Spike Wave in Slow Wave Sleep (CSWS) is suspected. Avoid in Certain Cases: EEG should not be requested for children with autistic regression. EEG is not needed in developmentally/neurologically normal children with simple or complex febrile seizures. Repeat EEG: Once a seizure type or syndrome has been diagnosed, repeat EEGs have limited value for monitoring treatment or deciding on drug withdrawal. 1-5% of the population can have epileptiform discharges (Option A) : This statement is correct. These discharges are not specific to epilepsy, and even in known epilepsy cases, routine interictal EEG can be normal in 60% of cases. Therefore, EEG cannot establish the diagnosis of epilepsy in many individuals. Scalp EEG may be useful in localizing frontal focal seizures (Option B) : However, it is often misleading or normal, particularly when seizures arise from areas distant from the scalp, such as the inferior frontal or medial temporal lobe. In such cases, the EEG may not localize the seizures or may show non-specific activity. Progressive multifocal leukoencephalopathy (PMLE) shows triphasic and slow waves on EEG (Option D) : EEG in PMLE typically shows slow background activity and triphasic and slow waves, predominantly in the frontal regions.

References:

https://www.sciencedirect.com/science/article/abs/pii/S1751722218300763#
https://pubmed.ncbi.nlm.nih.gov/21532379/ https://pmc.ncbi.nlm.nih.gov/articles/PMC6294573/#
https://www.elsevier.es/index.php?p=revista&pRevista=pdf-simple&pii=S2173580816301353&r=495

↑ *Back to this question in Part A*

@Neet_pg_bot

Q7: Which of the following does not show both hyperkinetic and hypokinetic movements? (Q855708)

A. Parkinson’s disease

B. Wilson’s disease

C. Neurodegeneration with brain iron accumulation

D. Huntington’s chorea

Correct Answer: D. Huntington’s chorea

Explanation: Huntington’s chorea predominantly manifests with hyperkinetic movements, such as chorea. Huntington’s Disease (HD): A progressive, fatal, autosomal dominant disorder. Characterized by motor, behavioral, oculomotor, and cognitive dysfunction. Onset typically between 25-45 years. Pathophysiology: Affects the striatum, progressing to involve the cerebral cortex. Caused by >40 CAG repeats in the huntingtin gene on chromosome 4. Clinical Features: Early-stage: Focal or segmental chorea. Late-stage: Dystonia , rigidity, bradykinesia, and myoclonus. Behavioral changes: Depression, aggression, psychosis, and suicidal tendencies. Cognitive impairment leading to dementia. Non-neurological features: Diabetes mellitus and hypothalamic dysfunction. Parkinson’s disease (Option A) is characterized by both hyperkinetic movements such as resting tremor and hypokinetic features like rigidity, stiffness, and bradykinesia. Wilson’s disease (Option B) results from basal ganglia damage, leading to hyperkinetic features such as dystonia and tremor, and hypokinetic features like parkinsonism with bradykinesia. Additionally, it can cause incoordination, dysarthria, dysphagia, and in advanced stages, a characteristic wing-beating (flapping) tremor. Neurodegeneration with brain iron accumulation (Option C) presents with a combination of hyperkinetic movements, including dystonia, and hypokinetic features, such as parkinsonism, along with spasticity.

References:

Harrison’s Principles of Internal Medicine, 21st Edition, Page 3401,3404,3405

↑ *Back to this question in Part A*

@Neet_pg_bot

Q8: Which of the following is not a major diagnostic criterion for neuromyelitis optica? (Q855707)

A. Area postrema syndrome

B. Acute myelitis

C. Focal epilepsy

D. Optic neuritis

Correct Answer: C. Focal epilepsy

Explanation: Focal epilepsy is not a major diagnostic criterion for neuromyelitis optica. Neuromyelitis optica (NMO): An inflammatory central nervous system syndrome distinct from multiple sclerosis (MS) that is associated with serum aquaporin-4 immunoglobulin G antibodies (AQP4-IgG). Diagnostic criteria : Clinical events : At least one of the following: Optic neuritis (Option D) Transverse myelitis (requires LETM MRI lesion) (Option B) Area postrema syndrome (requires associated medullary MRI lesion) (Option A)

References:

https://pmc.ncbi.nlm.nih.gov/articles/PMC4515040/#

↑ *Back to this question in Part A*

@Neet_pg_bot

Q9: What is the GCS of a patient with a head injury who opens her eyes in response to a loud voice, localizes pain and is confused and disoriented but can answer questions? (Q857650)

A. E3 M5 V4

B. E3 M6 V5

C. E4 M4 V5

D. E3 M5 V5

Correct Answer: A. E3 M5 V4

Explanation: Eye opening response (E3): Eyes open to verbal command, speech or shout Motor response (M5): Purposeful movement to painful stimulus Verbal response (V4): Confused and disoriented. The Glasgow Coma Scale (GCS) is a tool used to assess a patient’s level of consciousness based on three parameters: eye-opening , verbal response , and motor response . Each parameter is scored, and the total GCS score ranges from 3 (deep coma) to 15 (fully awake). Simplified Glasgow Coma Scale (GCS) Table Category Response Score Eye Opening

(E) Spontaneous 4 To speech 3 To pain 2 None 1 Verbal Response (V) Oriented 5 Confused conversation 4 Inappropriate words 3 Incomprehensible sounds 2 None 1 Motor Response (M) Obeys commands 6 Localizes to pain 5 Withdraws from pain 4 Abnormal flexion (decorticate) 3 Abnormal extension (decerebrate) 2 No response 1 Head Injury Severity: Clinical Classification Minor head injury GCS 15 with no LOC (loss of consciousness) Mild head injury GCS 14 or 15 with LOC Moderate head injury GCS 9 - 13 Severe head injury GCS 3 - 8 The GCS-P score is calculated by subtracting the Pupil Reactivity Score (PRS) from the Glasgow Coma Scale (GCS) total score: GCS-P = GCS - PRS. Pupils Unreactive to Light Pupil Reactivity Score Both Pupils 2 One Pupil 1 Neither Pupil 0 GCS-P score can range from 1 to 15 GCS-P score values between one and 8 denote a severe injury

References:

Bailey & Love's Short Practice of Surgery, 28th edition, Page 357, 361

https://www.glasgowcomascale.org/what-is-gcs-p/

https://www.ncbi.nlm.nih.gov/books/NBK513298/

↑ *Back to this question in Part A*

@Neet_pg_bot

Q10: A 55-year-old woman is diagnosed with a slow-growing, well-circumscribed meningioma on MRI. She has mild headaches but no major neurological deficits. Histopathology confirms a WHO Grade I meningioma. What is the treatment of choice for this patient? (Q857040)

A. Reassurance

B. Surgical excision

C. Chemotherapy

D. Radiotherapy

Correct Answer: B. Surgical excision

Explanation: Grade I meningiomas are benign, slow-growing tumors . Surgical excision is curative and is the treatment of choice . Radiotherapy or chemotherapy is reserved for Grade II/III tumors , incomplete resection, or recurrence. Observation is only for small, asymptomatic incidental tumors . Meningioma Meningioma is a primary CNS tumor, originating in the brain or spinal cord. Most common type of primary brain tumor, but high grade meningiomas (Grade 2 and 3) are rare. Diagnosis often requires tumor biopsy . Cause: Mostly due to genetic mutations Risk factors : Radiation exposure (especially in childhood) Neurofibromatosis type 2 (genetic disorder) Age > 60 Grades of Meningioma: Grade 1 (Low Grade) : Slow-growing, most common grade, more common in females whereas Grade 2 and 3 are more common in males. Grade 2 (Atypical, Mid-Grade) : Higher recurrence risk Subtypes: Chordoid Clear cell Grade 3 (Anaplastic, Malignant) : Fast-growing, aggressive Subtypes: Papillary Rhabdoid Origin and Spread: Originates in dura mater (outer brain and spinal cord covering). Grade 2

meningiomas can invade nearby bone tissue . Grade 3 meningiomas can spread to the brain and other organs . Symptoms: Depends on location but may include: Vision changes Hearing/smell loss Confusion Seizures Morning headaches MRI Appearance: Grade 2 and 3 meningioma appear as an enhancing mass along the outer brain lining. May brighten with contrast on MRI scans. {{caption_text}}

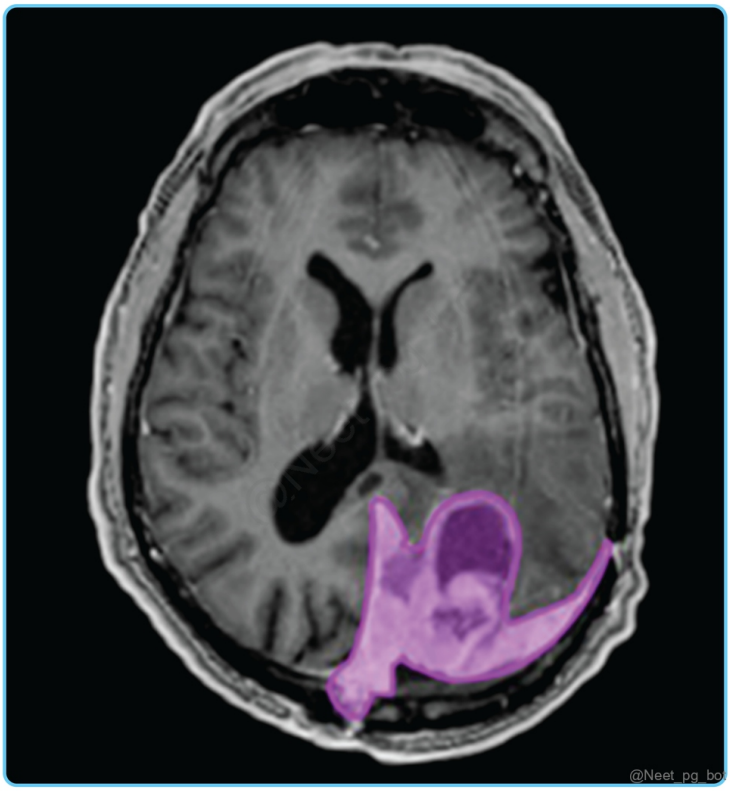

References:

https://www.cancer.gov/rare-brain-spine-tumor/tumors/meningioma

↑ *Back to this question in Part A*

@Neet_pg_bot

Q11: A 20 year old male was brought for psychiatric evaluation for intellectual disability. On examination, his IQ was 45. He has a long face, large ears, large testis and a cardiac murmur and history of poor intellectual function is present in the paternal family. What is his diagnosis? (Q857039)

A. Cushing’s syndrome

B. Rett syndrome

C. Fragile X syndrome

D. William syndrome

Correct Answer: C. Fragile X syndrome

Explanation: The diagnosis for this patient is Fragile X syndrome. It is the second most common cause of mental retardation whereas Down's syndrome is the most common cause. Fragile X syndrome is an X-linked dominant disease due to CGG trinucleotide repeat expansion. Fragile X Syndrome Genetic Basis CGG repeats on FMR-1 (Familial mental retardation) gene on X chromosome CGG Repeat Numbers Normal population: 5-55 repeats Carriers (premutation): 55-200 repeats Fragile X Syndrome: >200 repeats Gender Prevalence More common in males Females mostly carriers Clinical Features Long face and large ears Large mandible/Prominent jaw High arched palate Hyperextensible joints Mitral valve prolapse Macroorchidism (seen in adolescent age group) Intellectual disability Clinical features of female carriers May be associated with premature ovarian failure 10% may have an intellectual disability/low IQ Cushing syndrome (Option A) presents with acne, hirsutism, thin skin, delayed wound healing, anxiety, irritability, depression are seen along with involvement of musculoskeletal, endocrine and metabolic systems. Rett syndrome(Option B) presents with autistic-like behaviors, breathing irregularities, feeding and swallowing difficulties, growth retardation, and seizures. Williams syndrome(Option D) is characterized by mild to moderate intellectual disability or learning problems, unique personality characteristics, distinctive facial features, and heart and blood vessel (cardiovascular) problems.

References:

https://www.ncbi.nlm.nih.gov/books/NBK459243/

↑ *Back to this question in Part A*

@Neet_pg_bot

Q12: The following clinical examination was performed. What lesion would cause an exaggerated reflex? (Q855348)

A. Polyneuropathy

B. Radiculopathy

C. Upper motor neuron

D. Lower motor neuron

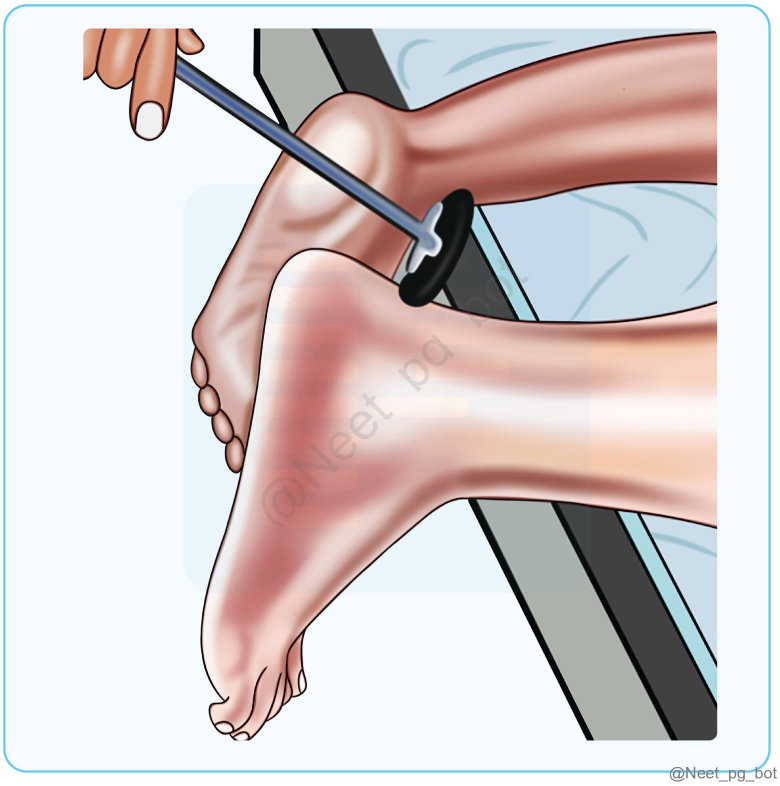

Correct Answer: C. Upper motor neuron

Explanation: An exaggerated reflex , also known as hyperreflexia , is a clinical finding associated with dysfunction or pathology involving the upper motor neuron system . The weakness of upper motor neuron lesions is conversely more pronounced in the opposing muscle groups. Loss of inhibition leads to brisk reflexes and enhanced reflex patterns of movement, such as flexion withdrawal to noxious stimuli and spasms of extension. The increased tone is more apparent during rapid stretching (‘spastic catch’) but may quickly give way with sustained tension (the ‘clasp-knife’ phenomenon). Polyneuropathy (Option A) typically results in sensory and motor deficits rather than exaggerated reflexes. In polyneuropathy, reflexes may be diminished or absent due to the involvement of peripheral nerves. Although radiculopathy (Option B) can lead to abnormal reflexes, the reflexes are usually diminished or weakened rather than exaggerated. Upper Motor Neuron vs Lower Motor Neuron Sign Upper Motor Neuron Lower Motor Neuron Atrophy None Severe Fasciculations None Common Tone Spastic Decreased Distribution of Weakness Pyramidal/regional Distal/segmental Muscle Stretch Reflexes Hyperactive Hypoactive/absent (Option D) Babinski Sign Present Absent Upper Motor Neuron lesion signs: Oppenheim’s sign Babinski’s sign Gordon’s sign Chaddock’s sign {{caption_text}}



References:

Harrison’s Principles of Internal Medicine, 21st edition, Page 165, 166

Macleod’s clinical examination 15th edition, Page 150, 157

https://www.ncbi.nlm.nih.gov/books/NBK519555/

↑ *Back to this question in Part A*

@Neet_pg_bot

Q13: Which of the following is not characteristic of Brown Sequard syndrome? (Q855338)

A. Complete transection of spinal cord

B. Ipsilateral loss of vibration & touch

C. Contralateral loss of pain & temperature

D. Ipsilateral loss of proprioception

Correct Answer: A. Complete transection of spinal cord

Explanation: Complete transection of the spinal cord is not a feature of Brown-Séquard syndrome .
Brown-Séquard syndrome is a specific pattern of spinal cord injury characterized by a hemisection of the spinal cord (one-half of the spinal cord is damaged or severed). {{caption_text}} Hemisection of the spinal cord (as shown in the image) results in I/L loss of Dorsal and Pyramidal column tracts and C/L loss of Spinothalamic tract (STT) 2 segments below the level of lesion is known as Brown-Sequard syndrome , as STT (specifically Lateral STT) relays at the dorsal root ganglion and crosses over at 1-2 segments above the level of that spinal cord. {{caption_text}} Presentation of Brown-Sequard syndrome: Ipsilateral (I/L) Contralateral (C/L) At the level of lesion CST: LMN paralysis Dorsal column: loss of vibration (Option D) and proprioception (Option B) Radicular pain + Muscles- fasciculation, areflexia - Below the level of lesion CST: UMN paralysis Dorsal column: Loss of vibration and proprioception Spinothalamic tract: Loss of Pain and Temperature (Option C) {{caption_text}}

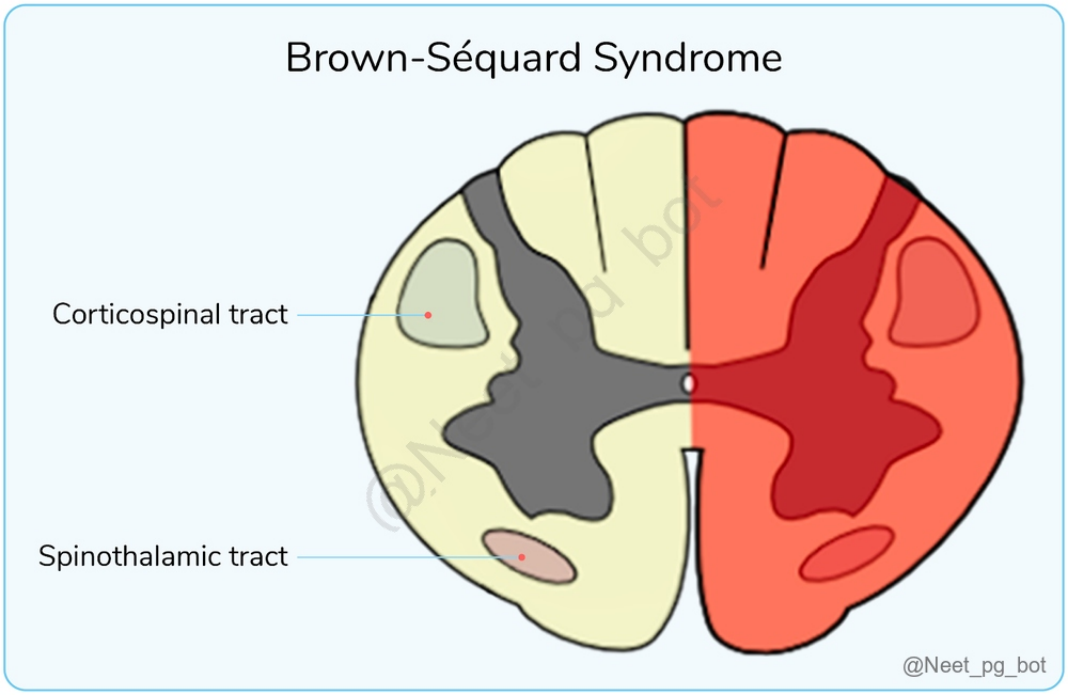

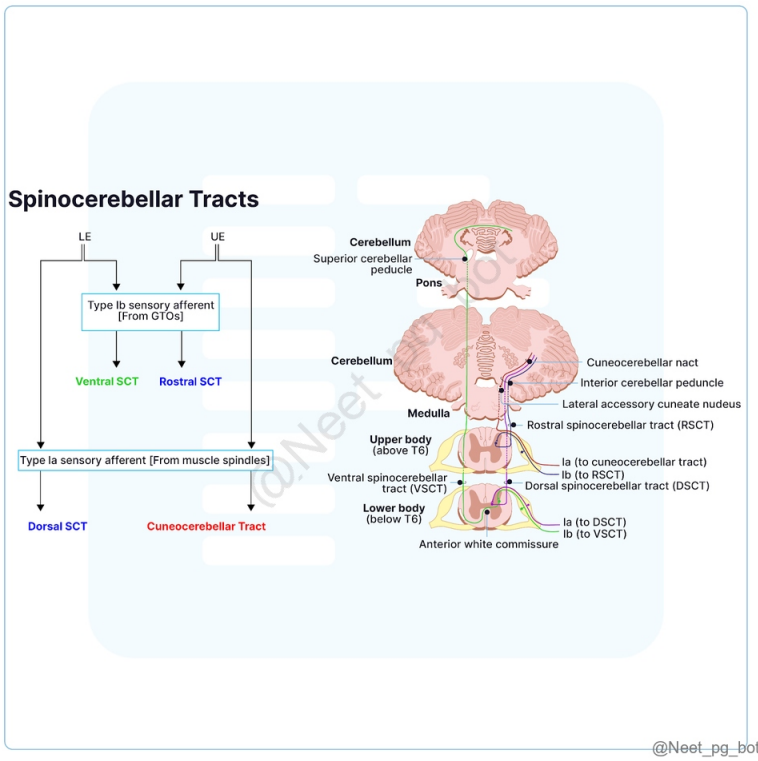

@Neet_pg_bot

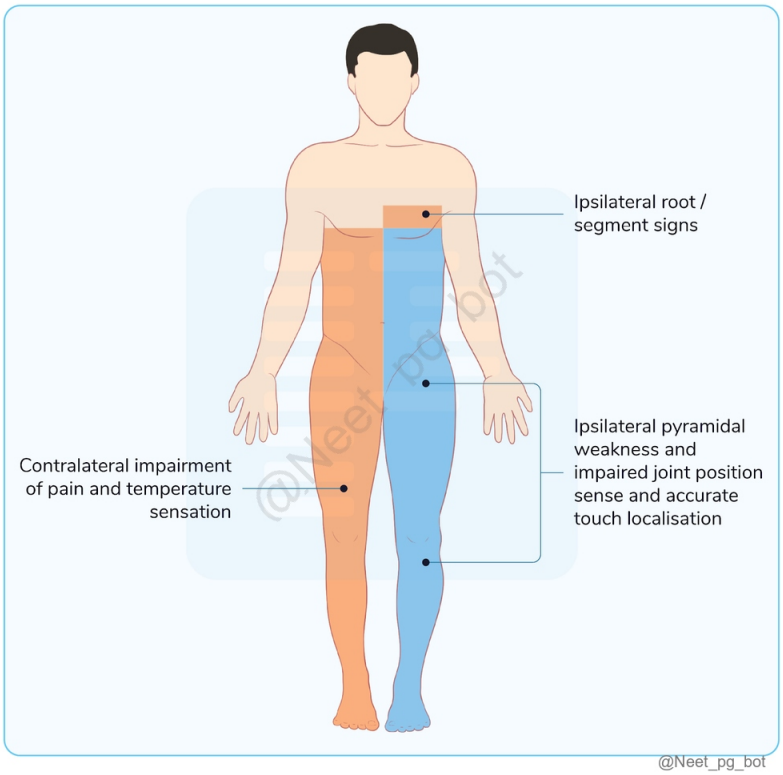

@Neet_pg_bot

References:

Harrison’s Principles of Internal Medicine, 21st edition, Page 3446

↑ *Back to this question in Part A*

@Neet_pg_bot

Q14: A 37-year-old woman presents with headaches for 6 months. She has been taking analgesics regularly. The headache recently increased in severity for 3 days but was reduced by stopping the analgesic. What is the likely diagnosis? (Q856148)

A. Medication overuse headache

B. Tension headache

C. Chronic migraine

D. Cluster headache

Correct Answer: A. Medication overuse headache

Explanation: The scenario here suggests overuse of analgesics and hence the diagnosis of medication overuse headache. Medication overuse headache (MOH) is a secondary headache because it results from the frequent use of headache medication, unlike tension-type headaches, migraines, and primary stabbing headaches, which are all primary headaches. This develops due to the overuse of analgesics for already-existing headaches. This overuse induces MOH, which leads the patient to take more analgesics, thereby increasing the frequency of headaches, thus forming a vicious cycle. Main Risk Factors for MOH: Demographic Age (less than 50 years) Female Low educational level Self-reported complaints Chronic musculoskeletal complaints Gastrointestinal complaints Anxiety or depression Lifestyle Smoking Physical inactivity Metabolic syndrome High daily caffeine intake (greater than 540mg versus less than 240mg) Medication Tranquillizers Aspirin Ibuprofen Opioids Treatment of Medication Overuse Headache (MOH) Patient Education and Prevention Educate on appropriate medication use and risks of MOH. Emphasize the importance of limiting acute headache medications to ≤2 days per week. Medication Discontinuation Strategies Stop overused medication abruptly (preferred for most patients) and start/optimize preventive therapy, titrated based on individual factors. Gradual tapering: Useful for Opioids, Barbiturates, or Benzodiazepines (2-4 weeks for high doses; transdermal clonidine or phenobarbital may help with withdrawal). Preventive Medications Beta-blockers, calcium channel blockers, TCAs, and anticonvulsants. Topiramate and OnabotulinumtoxinA (useful, especially in chronic migraine with MOH). Bridge Therapy NSAIDs: Naproxen, Indomethacin, Ketorolac Adjuncts: Tizanidine with NSAIDs, antiemetics (Prochlorperazine, Metoclopramide), and dihydroergotamine (DHE) for severe cases. Raskin protocol: IV DHE + Metoclopramide every 8 hours. Alternative Approaches Withdrawal symptoms management: NSAIDs, hydration, antiemetics, magnesium, and lidocaine infusions. Discontinuation first approach: Avoid starting preventive therapy for 2 months post-medication discontinuation (less tolerated). Incorrect Options: In tension headaches (Option B) , the pain is described as a dull, bilateral ache, often associated with neck tension, stress, and fatigue. Migraine (Option C) sufferers describe a prodrome of fatigue, neck discomfort, mood changes, increased urination and thirst, and cognitive impairment. Typical migraine symptoms include a strong, throbbing headache, photophobia, phonophobia, osmophobia, allodynia and vomiting. Cluster headaches (Option D) are known for their unilateral, severe pain typically located around the eye, often described as retro-orbital pain. They are more common in males and can be associated with other symptoms such as nasal congestion and watering of the eyes.

References:

Harrison’s Principles of Internal Medicine, 21st Edition, Page 3358

Davidson’s Principles and Practice of Medicine, 24th Edition, Page 185

Medication-Overuse Headache - StatPearls - NCBI Bookshelf

Types of Headaches: Symptoms, Causes, Treatments, and More

↑ *Back to this question in Part A*

@Neet_pg_bot

Q15: A 50-year-old male patient presented with left-sided hemiparesis. Damage to which part of the internal capsule leads to this presentation? (Q855714)

A. Retrolentiform

B. Sublentiform

C. Anterior limb

D. Posterior limb

Correct Answer: D. Posterior limb

Explanation: The posterior limb of the internal capsule contains the corticospinal tract, which is responsible for motor control of the limbs . Damage to this area can lead to contralateral hemiparesis, as seen in the patient's left-sided weakness. Lacunar Strokes Lacunar Syndrome Location of Infarct Supplying Vessel Clinical Features Pure Motor Hemiparesis Posterior limb of internal capsule or basis pontis Lenticulostriate arteries or paramedian pontine arteries Face, arm, and leg weakness on one side without sensory, visual, or cognitive deficits Pure Sensory Stroke Ventral posterolateral nucleus of thalamus Thalamogeniculate arteries Hemisensory loss affecting face, arm, and leg without motor weakness Ataxic Hemiparesis Posterior limb of internal capsule or basis pontis Lenticulostriate arteries or paramedian pontine arteries Ipsilateral ataxia with contralateral pyramidal signs Dysarthria-Clumsy Hand Pons or internal capsule (genu) Penetrating branches of basilar artery or lenticulostriate arteries Dysarthria and dyspraxia of hand without significant weakness Damage to the retrolentiform part (Option A) of the internal capsule would typically result in sensory deficits, such as loss of sensation or abnormal sensation, rather than hemiparesis. Similar to the retrolentiform part, damage to the sublentiform part (Option B) of the internal capsule is more likely to produce sensory deficits rather than hemiparesis. Damage to the anterior limb (Option C) of the internal capsule can cause a variety of symptoms, including contralateral weakness, but it usually affects the face more than the limbs.

References:

Harrison’s Principle of Internal Medicine, 21st Edition, Page 3326, 3327, 3341

https://www.ncbi.nlm.nih.gov/books/NBK563216/

↑ *Back to this question in Part A*

@Neet_pg_bot

Q16: Bell's palsy involves: (Q858357)

A. Ipsilateral upper and lower halves of the face

B. Contralateral upper and lower halves of the face

C. Ipsilateral lower half of the face

D. Contralateral lower half of the face

Correct Answer: A. Ipsilateral upper and lower halves of the face

Explanation: Correct Option A - Ipsilateral upper and lower halves of the face: Bell’s palsy is a lower motor neuron (LMN) lesion of the facial nerve (VII nerve), usually idiopathic and often viral in etiology. In LMN facial nerve palsy, there is paralysis of all muscles of facial expression on the same side, including both the upper face (forehead, eye closure) and lower face (mouth). Hence, the involvement is the ipsilateral upper and lower halves of the face. Incorrect Options: Option B - Contralateral upper and lower halves of the face: This pattern is not seen in facial nerve lesions. No common neurological lesion causes complete contralateral facial paralysis involving both the upper and lower face. Option C - Ipsilateral lower half of the face: Isolated involvement of the lower half of the face is typical of an upper motor neuron (UMN) lesion, such as a stroke, not Bell’s palsy. Option D - Contralateral lower half of the face: This is the classic pattern of a supranuclear (UMN) facial palsy, where the upper face is spared due to bilateral cortical innervation.

References:

Harrison's Principles of Internal Medicine, 20th Edition, Page 3439-3441

↑ *Back to this question in Part A*

@Neet_pg_bot

Q17: A young male patient presents with ptosis and muscle weakness which reportedly worsens in the evening and improves in the morning. This is relieved by neostigmine. What is the likely diagnosis? (Q858354)

A. Myasthenia gravis

B. Huntington chorea

C. Amyotrophic lateral sclerosis

D. External ophthalmoplegia

Correct Answer: A. Myasthenia gravis

Explanation: drophonium (Tensilon) test: 2mg + 8mg IV Ice pack test for ptosis Fatigue testing (repeated muscle activation) Huntington chorea (Option B) is a genetic condition characterized by involuntary movements, cognitive decline, and psychiatric symptoms. It does not present with ptosis or show diurnal variation, nor does it respond to neostigmine. Amyotrophic lateral sclerosis (Option C) presents with progressive muscle weakness, but lacks the characteristic diurnal variation seen in myasthenia gravis. ALS does not typically begin with ptosis and shows no improvement with neostigmine. External ophthalmoplegia (Option D) can cause ptosis but does not demonstrate the distinctive pattern of fatigue and improvement with rest. Additionally, external ophthalmoplegia does not respond to neostigmine and lacks the diurnal variation characteristic of myasthenia gravis.

References:

Davidson’s Principles and Practice of Medicine, 24th Edition, Page 1141-1143

Harrison's Principles of Internal Medicine, 21st Edition, Page 3510-3513

↑ *Back to this question in Part A*

@Neet_pg_bot

Q18: A young male patient presents with ptosis and muscle weakness which reportedly worsens in the evening and improves in the morning. This is relieved by neostigmine. What is the likely diagnosis? (Q858037)

A. Myasthenia gravis

B. Huntington chorea

C. Amyotrophic lateral sclerosis

D. External ophthalmoplegia

Correct Answer: A. Myasthenia gravis

Explanation: drophonium (Tensilon) test: 2mg + 8mg IV Ice pack test for ptosis Fatigue testing (repeated muscle activation) Huntington chorea (Option B) is a genetic condition characterized by involuntary movements, cognitive decline, and psychiatric symptoms. It does not present with ptosis or show diurnal variation, nor does it respond to neostigmine. Amyotrophic lateral sclerosis (Option C) presents with progressive muscle weakness, but lacks the characteristic diurnal variation seen in myasthenia gravis. ALS does not typically begin with ptosis and shows no improvement with neostigmine. External ophthalmoplegia (Option D) can cause ptosis but does not demonstrate the distinctive pattern of fatigue and improvement with rest. Additionally, external ophthalmoplegia does not respond to neostigmine and lacks the diurnal variation characteristic of myasthenia gravis.

References:

Davidson’s Principles and Practice of Medicine, 24th Edition, Page 1141-1143

Harrison's Principles of Internal Medicine, 21st Edition, Page 3510-3513

↑ *Back to this question in Part A*

@Neet_pg_bot

Q19: A woman presents with a history of headaches for the past 9 months that worsen in a recumbent position and improves as the day progresses. She also gives a history of taking oral contraceptives. Fundal examination shows papilledema. There are no focal neurological deficits. What is the probable cause of her headaches? (Q858028)

A. Myasthenia gravis

B. Temporal arteritis

C. Chronic migraine

D. Pseudotumor cerebri

Correct Answer: D. Pseudotumor cerebri

Explanation: is characterized by headaches occurring on 15 or more days per month for at least three months. While the timeframe is similar, the presence of papilledema and positional nature of the headache are not typical features of migraine.

References:

Harrison's Principles of Internal Medicine, 20th Edition, Page 116

↑ *Back to this question in Part A*

@Neet_pg_bot

Q20: A 26-year-old male with a history of respiratory tract infection 4 weeks ago is unable to stand or walk for the past 2 weeks and the weakness is progressive, ascending, and symmetrical in nature. The lower limbs were involved before and gradually the upper limbs were also affected. On examination you note areflexia. Pain and proprioception are preserved. Which of the following could be the diagnosis? (Q858017)

A. Guillain-Barré syndrome

B. Myasthenia gravis

C. Polymyositis

D. Multiple sclerosis

Correct Answer: A. Guillain-Barré syndrome

Explanation: : Weakness in myasthenia gravis typically worsens with repeated use of the affected muscles and improves with rest. Additionally, it often affects the muscles of the face and eyes before involving the limbs. The ascending pattern and areflexia are not typical features of myasthenia gravis. Polymyositis (Option C): Polymyositis presents with symmetric proximal muscle weakness primarily affecting the shoulder and hip girdle muscles, making activities like climbing stairs or raising arms above the head difficult. Patients maintain normal reflexes and have no sensory involvement. The absence of proximal muscle pattern, presence of areflexia, and absence of ascending weakness pattern make polymyositis unlikely. Multiple sclerosis (Option D): Multiple sclerosis typically follows a relapsing-remitting course with scattered neurological manifestations. Common presentations include visual symptoms like optic neuritis and sensory symptoms such as paresthesias and numbness. Patients often demonstrate hyperreflexia rather than areflexia.

References:

Harrison’s Principle of Internal Medicine, 21st Edition, Page 3501

↑ *Back to this question in Part A*

@Neet_pg_bot

Q21: A young patient presents with a severe headache. He has never experienced a headache of this severity before. He has hypertension and nuchal rigidity on examination. Which of the following could be the diagnosis? (Q858014)

A. Cluster headache

B. Subarachnoid haemorrhage

C. Encephalitis

D. Meningitis



Correct Answer: B. Subarachnoid haemorrhage

Explanation: lood accumulation in the subarachnoid space. Causes: Often due to aneurysm rupture (~85%) or trauma . Non-traumatic SAH is most commonly caused by the rupture of a saccular aneurysm . Clinical Impact: High mortality and morbidity; often presents with a sudden, severe headache (worst headache of life). Complications: Seizures, vasospasm, hydrocephalus, and delayed cerebral ischemia (DCI). Epidemiology Age: Most aSAH occurs between ages 40-60, mean rupture age 50-55 and slightly more prevalent in females. Risk Factors: Smoking and history of ruptured aneurysms increase SAH risk. Etiology Aneurysmal SAH (aSAH): Risk Factors: Hypertension , smoking , family history, alcohol use, sympathomimetic drugs , and estrogen deficiency . Rupture Risk: (Option D) Age >60 Posterior circulation aneurysms Atherosclerosis Aneurysm size Aneurysms <10 mm: ~0.1% annual rupture risk. Aneurysms ≥10 mm: 0.5–1% annual rupture risk. Giant aneurysms (>2.5 cm): ~6% rupture risk in first year. Family history Previous SAH ADPKD Nonaneurysmal SAH (NASAH): Perimesencephalic NASAH : Localized blood in perimesencephalic cisterns, normal angiography, benign course. Occult Aneurysm : Small aneurysms missed on initial angiography, detectable on repeat imaging. Vascular Malformations: Includes arteriovenous malformations (AVM) and dural arteriovenous fistulae. Treated with surgery or endovascular interventions. Intracranial Arterial Dissection: Diagnosed by angiography, causes severe bleeding, treated with surgery or endovascular methods. Other Causes: Cocaine abuse, cerebral amyloid angiopathy, cerebral venous thrombosis, sickle cell disorders, moyamoya disease, cerebral vasculitis, bleeding disorders. Pathophysiology Hemodynamic Stress : Central to intracranial aneurysm formation, especially at arterial bifurcations. Aneurysm Rupture: Causes neurological damage through compression of adjacent brain tissue and ischemia from reduced blood flow. Mechanisms: Hemodynamic stress and inflammation (matrix metalloproteinase (MMP)-mediated degradation of extracellular matrix) weaken the arterial wall, promoting aneurysm formation and rupture. Inflammatory Response: Macrophages and smooth muscle cells drive these degenerative processes. Clinical Presentation "Thunderclap headache" - worst headache of life Sudden onset severe headache Vomiting Variable LOC Meningismus Retinal hemorrhages Focal neurologic deficits Nuchal

rigidity Diagnosis {{caption_text}} CT Head Non-contrast CT is first-line "Star sign" - blood in basal cisterns Sensitivity: 98-100% in first 12 hours Lumbar Puncture If CT negative Xanthochromia (takes 12h to develop) Elevated opening pressure Cluster headache (Option A): Cluster headaches are characterized by severe, unilateral pain centered around the eye often described as retro-orbital pain along with associated autonomic symptoms. They typically occur in clusters or cycles and do not present with nuchal rigidity or “Star sign” on CT findings. Encephalitis (Option C): Encephalitis typically presents with fever, altered mental status, seizures, and focal neurological deficits. The absence of fever and presence of classic SAH findings on CT make encephalitis unlikely. Meningitis (Option D): While meningitis can present with headache and nuchal rigidity, it typically includes fever and photophobia. The CT findings are not consistent with meningitis. Also, the characteristic "Star of Death" appearance on CT is pathognomonic of SAH.



References:

Harrison's Principles of Internal Medicine 21st Edition, Page 3353, 3354

Subarachnoid Hemorrhage - StatPearls - NCBI Bookshelf

↑ *Back to this question in Part A*

@Neet_pg_bot

Q22: A patient presented with a fever for 11 days with neck rigidity. A lumbar puncture was done, and it showed predominantly lymphocytes, sugar- 50mg, and

protein- 3000mg/dl. Cobweb coagulum was noted. Gram-staining was negative. The patient's chest X-ray shows upper lobe involvement with hilar lymph node enlargement. (Q858012)

A. Tuberculous meningitis

B. Bacterial meningitis

C. Fungal meningitis

D. Viral meningitis

Correct Answer: A. Tuberculous meningitis

Explanation: linical Features: Headache , slight mental changes , and low-grade fever can develop over weeks, often accompanied by malaise , anorexia , and irritability . More severe cases present with confusion , lethargy , neck rigidity , and altered sensorium . Disease progression: evolves over 1–2 weeks, longer than bacterial meningitis. Cranial nerve palsies , especially ocular nerves, are common due to inflammation at the base of the brain. May result in coma , hydrocephalus , and intracranial hypertension if untreated. Cerebral ischemia can result from the involvement of cerebral arteries. Tuberculoma (space-occupying lesion) may cause seizures and focal neurological signs. CSF Findings: Elevated leukocyte count (up to 1000/µL, predominantly lymphocytes). High protein content (1–8 g/L). Cobweb Coagulum: Clear fluid in a test tube with a cobweb at the bottom Low glucose concentration . Investigation of Choice: Culture of CSF (gold standard, takes 4–8 weeks, positive in ~50%). Smear for acid-fast bacilli (AFB) (low sensitivity, positive in 10–40%). PCR for Mycobacterium tuberculosis DNA (variable sensitivity). Imaging: CT/MRI may show hydrocephalus and abnormal enhancement of basal cisterns or ependyma. Tuberculomas appear as contrast-enhanced ring lesions on imaging. {{caption_text}} MRI showing ring-enhanced lesions -tuberculoma Treatment: Empirical therapy is often initiated based on suspicion. Initial drug regimen : isoniazid, rifampin, pyrazinamide, ethambutol, and pyridoxine. Duration : 6–12 months depending on response. Dexamethasone (12–16 mg/day) for 3 weeks, tapered for 3 more weeks (recommended for HIV-negative patients). Tuberculoma may require a biopsy for diagnosis. Bacterial meningitis (Option B): Bacterial meningitis typically presents with acute onset (<24-48 hours), neutrophilic predominance in CSF, and positive Gram stain. The subacute presentation and lymphocytic CSF make bacterial meningitis unlikely. Fungal meningitis (Option C): While fungal meningitis can present with similar CSF findings, including low glucose and high protein, it typically occurs in immunocompromised patients and does not usually present with characteristic upper lobe chest X-ray findings. The presence of pulmonary involvement strongly suggests tuberculosis. Viral meningitis (Option D): Viral meningitis typically presents with normal to mildly elevated protein levels, normal glucose levels, and absence of cobweb coagulum. The markedly elevated protein (3000mg/dl) and low glucose are inconsistent with viral etiology.



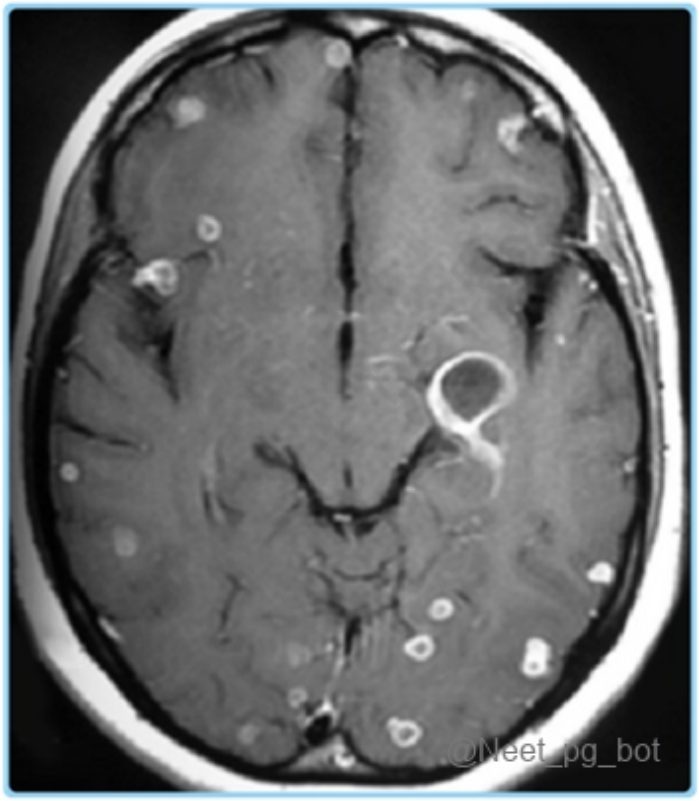

References:

Harrison’s Principles of Internal Medicine, 21st Edition, Page 3503

Davidson’s Principles and Practice of Medicine, 24th Edition, Page 1078, 1140

↑ *Back to this question in Part A*

@Neet_pg_bot

Q23: A 78-year-old woman presents with a progressive decline in daily activity. She gives a history of convulsions and visual hallucinations. She does not talk to anyone and keeps looking at the sky. Pathological examination shows the presence of Lewy bodies within the neurons. What is the most probable diagnosis? (Q855496)

A. Parkinson's disease

B. Prion disease

C. Huntington's chorea

D. Alzheimer's disease

Correct Answer: A. Parkinson's disease

Explanation: This patient's symptoms, including progressive decline in daily activities, convulsions, visual hallucinations, and the presence of Lewy bodies on pathological examination, point toward Parkinson's disease. Classification of Dementia Type of Dementia Description Clinical Findings Alzheimer's Disease (AD) (Option D) Most common type of dementia, characterized by amyloid plaques and tau tangles in the brain. Memory loss, especially short-term memory Disorientation Language difficulties Impaired judgment and reasoning Personality changes Progressive cognitive decline2 Vascular Dementia Results from damage to blood vessels in the brain, leading to reduced blood flow. Often follows a stroke or series of small strokes. Stepwise progression of cognitive decline Memory loss Impaired executive function Gait disturbances Personality and mood changes Signs of previous strokes (e.g., hemiparesis) Lewy Body Dementia Caused by abnormal protein deposits (Lewy bodies) in the brain, affecting cognitive and motor functions. Visual hallucinations Parkinsonism (e.g., tremor, rigidity) Cognitive fluctuations Memory impairment REM sleep behavior disorder Frontotemporal Dementia (FTD) Characterized by degeneration in the frontal and temporal lobes, often with personality and behavioral changes. Personality and behavior changes (e.g., disinhibition, apathy) Language difficulties (e.g., aphasia) Lack of empathy Impulsive behaviors Social withdrawal Parkinson's Disease Dementia Occurs in patients with Parkinson's disease, typically years after motor symptoms begin. Memory loss Cognitive impairment Attention deficits Executive dysfunction Visual hallucinations Parkinsonism (e.g., bradykinesia, tremor) Huntington's Disease (Option C) Genetic disorder characterized by progressive motor, cognitive, and psychiatric decline. Involuntary movements (chorea) Memory impairment Personality changes (e.g., irritability, depression) Impaired coordination and motor function Progressive dementia Creutzfeldt-Jakob Disease (CJD) (Option B) Rare prion disease causing rapid neurodegeneration, often with fatal progression. Rapid onset of dementia Motor symptoms (e.g., ataxia, myoclonus) Visual disturbances Psychiatric symptoms (e.g., depression) Death usually within 1-2 years Wernicke-Korsakoff Syndrome Caused by thiamine deficiency, often due to alcohol abuse. Can lead to brain damage and dementia. Amnesia (anterograde and retrograde) Confabulation Ataxia Nystagmus Neurological abnormalities due to thiamine deficiency Normal Pressure Hydrocephalus (NPH) A condition where excess

cerebrospinal fluid accumulates in the brain ventricles, leading to cognitive decline. Gait disturbances (shuffling walk) Urinary incontinence Dementia Enlargement of the ventricles on brain imaging

References:

https://pmc.ncbi.nlm.nih.gov/articles/PMC5771416/
https://www.nia.nih.gov/health/alzheimers-and-dementia/understanding-different-types-dementia Harrison's Principles of Internal Medicine, 21st Edition, Page: 3385-3390.

↑ *Back to this question in Part A*

@Neet_pg_bot

Q24: A young female presents with ptosis showing diurnal variation. CT chest shows an anterior mediastinal mass identified as thymus gland cancer. Which receptor is affected in this patient? (Q866790)

A. Presynaptic ACh Receptor

B. Post-synaptic ACh Receptor

C. Voltage-gated calcium channels at the NMJ

D. Acetylcholinesterase

Correct Answer: B. Post-synaptic ACh Receptor

Explanation: Myasthenia gravis (MG) is an autoimmune disorder in which antibodies target post-synaptic nicotinic acetylcholine receptors at the neuromuscular junction, impairing neuromuscular transmission. Thymic abnormalities (hyperplasia or thymoma) are common in MG. In MG, antibody-mediated blockade and destruction of post-synaptic ACh receptors reduce the number of available receptors, leading to muscle weakness. Weakness worsens with activity and improves with rest (diurnal variation). The association with thymoma is due to aberrant immune activation in the thymus. Key features: Ptosis, diplopia, dysphagia, proximal muscle weakness, preserved reflexes, and response to acetylcholinesterase inhibitors. Myasthenia Gravis: Epidemiology: More common in young women and older men. Pathophysiology : Autoantibodies against post-synaptic nicotinic ACh receptors at NMJ → impaired depolarization of muscle fibers. Association: Thymic hyperplasia (65%) and thymoma (15%). Diagnosis: Edrophonium (Tensilon) test, anti-AChR antibody assay, repetitive nerve stimulation showing decremental response. Treatment: Acetylcholinesterase inhibitors (pyridostigmine), immunosuppressants, thymectomy (if thymoma present), plasmapheresis/IVIG for crisis. NMJ disorders: Disorder Site of defect Antibody target / mechanism Myasthenia gravis Post-synaptic membrane Nicotinic ACh receptor Lambert–Eaton syndrome Presynaptic terminal Voltage-gated calcium channels Botulism Presynaptic terminal Inhibits ACh release (toxin action) Incorrect Options: Presynaptic ACh receptor (Option A) – No such pathology in MG; presynaptic issues are rare in autoimmune NMJ disease. Voltage-gated calcium channels at NMJ (Option C) – Targeted in Lambert–Eaton myasthenic syndrome, not MG. Acetylcholinesterase (Option D) – This enzyme breaks down ACh in synaptic cleft; it is inhibited pharmacologically in MG treatment, not attacked by antibodies.

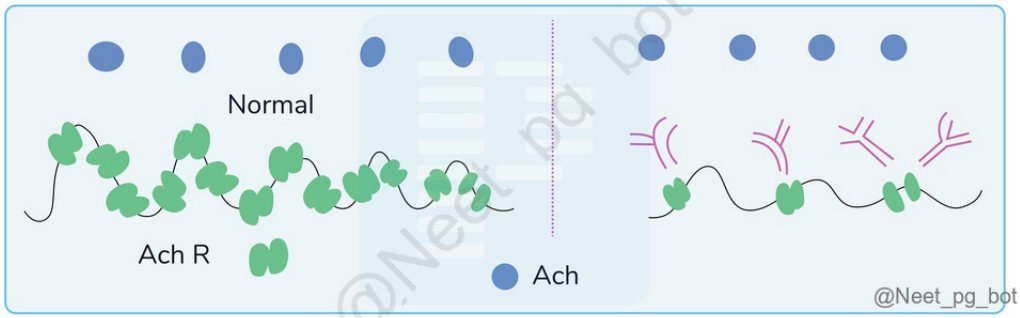



References:

.

↑ *Back to this question in Part A*

@Neet_pg_bot

Q25: A male patient presented to the emergency room with seizures. He has a history of fever, headache, and confusion. An MRI brain was done, and it showed inflammation involving the bitemporal lobe. What is the most likely etiology for this presentation? (Q855465)

A. Cytomegalovirus

B. Toxoplasma gondii

C. Herpes simplex virus

D. Mycobacterium tuberculosis

Correct Answer: C. Herpes simplex virus

Explanation: - Herpes simplex virus The patient presents with fever, headache, confusion, and seizures, symptoms highly suggestive of encephalitis. Neurological examination reveals personality changes and altered consciousness, raising suspicion for focal neurological involvement. MRI: Shows bitemporal lobe hyperintensities, a hallmark feature of HSV encephalitis. Focal Neurological Signs: Symptoms linked to temporal lobe pathology, such as behavioral changes and impaired mental status. HSV Encephalitis HSV encephalitis is a rapidly progressive, life-threatening condition, often presenting with: Seizures: Focal or generalized. Neurological symptoms: Aphasia, ataxia, cranial nerve deficits. Behavioral and cognitive changes: Altered sensorium, memory impairment, personality changes (sometimes misdiagnosed as personality disorders). Additional Features: Urinary/fecal incontinence. Aseptic meningitis. Dermatomal rashes. Rarely, Guillain-Barré syndrome. Diagnosis CSF Analysis: Lymphocytic pleocytosis, normal glucose, mild protein elevation. CSF PCR for HSV: Gold standard with 96% sensitivity, 99% specificity. Neuroimaging (MRI): T2-weighted/DWI: Hyperintensities in temporal and orbitofrontal lobes. {{caption_text}} EEG: Periodic slow-wave activity in the temporal lobes, highly suggestive of HSV encephalitis. Management Antiviral Therapy: Early initiation of IV acyclovir to prevent permanent neurological damage. CSF findings in meningitis Glucose (mg/dL) Protein (mg/dL) WBC (per µL) Bacterial <40 >45 >1000 (PMNs) Viral Normal 20-80 25-500 (Predominantly lymphocytes) TB <50 in 75% cases 100-200 25-100 (Predominantly lymphocytes) Fungal ↓ to normal 150-300 40-600 (Lymphocytes or PMNs, depending on the causative organism) Parasitic Normal 50-200 150-2000 (↑↑ Eosinophils) (≥50%) Cytomegalovirus (Option A): CMV encephalitis typically occurs in immunocompromised individuals (e.g., HIV, organ transplant recipients). On MRI, CMV encephalitis often shows enlarged ventricles and periventricular calcifications, not the typical temporal lobe findings seen in HSV encephalitis. Toxoplasma gondii (Option B): Toxoplasmosis primarily affects immunocompromised patients (e.g., HIV/AIDS). It usually presents with multiple brain lesions, commonly affecting the basal ganglia and corticomedullary junction, which would be visible on MRI. Mycobacterium tuberculosis (TB) (Option D): TB encephalitis, which is more common in children or immunocompromised individuals, can present with cerebral edema, seizures, and decreased consciousness. However, TB typically affects the cerebral cortex more diffusely and is less likely to cause bitemporal lobe involvement, as seen in HSV encephalitis.

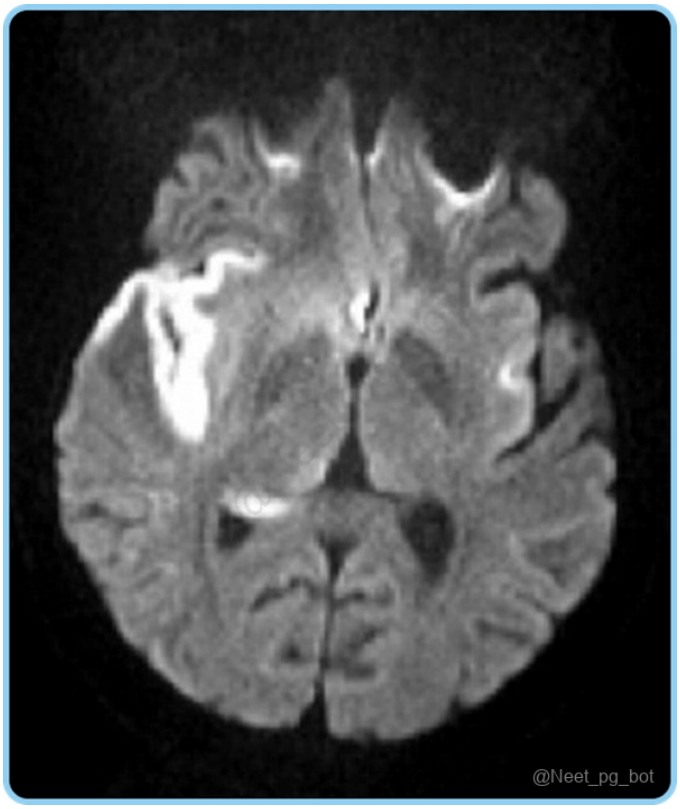

↑ *Back to this question in Part A*

@Neet_pg_bot

Q26: Visual field testing of a patient revealed the following type of loss. Where is the likely site of lesion in the optic pathway? (Q859569)

A. Frontal visual field

B. Occipital lobe

C. Optic radiation

D. Optic chiasma

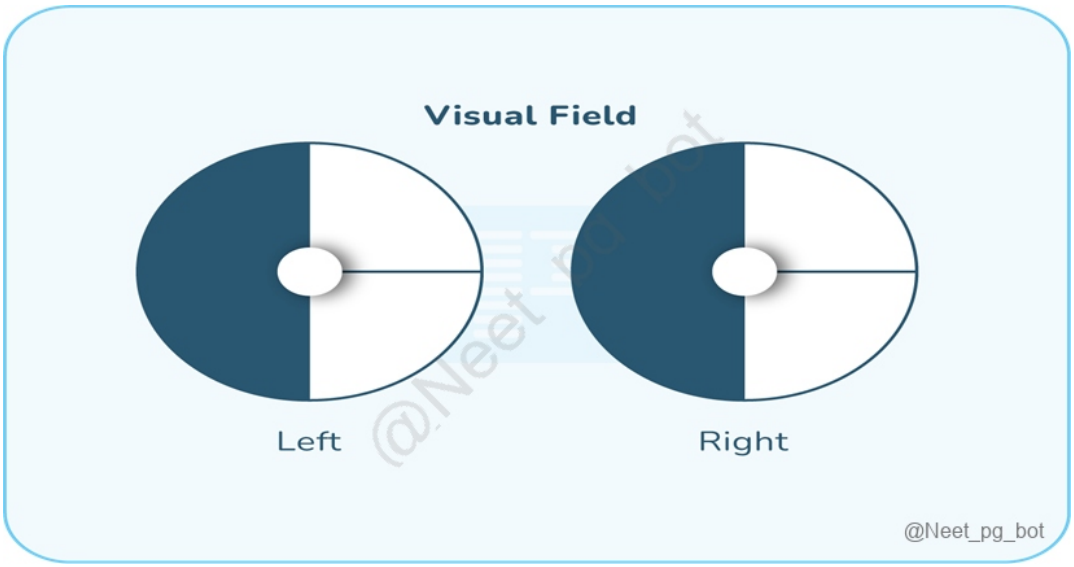

Correct Answer: B. Occipital lobe

Explanation: A lesion in the occipital lobe , specifically in the Posterior Cerebral Artery (PCA) territory affecting the calcarine cortex, typically causes congruous homonymous hemianopia with macular sparing. This characteristic defect arises because the posterior cerebral artery (PCA) is the major artery supplying the primary visual cortex, while the macula is protected by its blood supply from the middle cerebral artery (MCA). Lesions in Visual Cortex: Typically present as congruous homonymous hemianopia (visual field loss is consistent in both eyes). {{caption_text}} Visual Pathway Lesions and Defects Site of Lesion Fibers Affected Field Defect Optic Nerve Ipsilateral Temporal + Nasal Fibers {{caption_text}} Anopia Optic Chiasma (Option D) Bilateral Nasal Fibers {{caption_text}} Bitemporal Hemianopia (Heteronymous Hemianopia) Optic Tract Lateral Geniculate Body (LGB Lesion) Optic Radiation (Option C) Ipsilateral Temporal Fibers + Contralateral Nasal Fibers {{caption_text}} Homonymous Hemianopia Visual Cortex without the involvement of tip (Post. Cerebral Artery) Ipsilateral Temporal Fibers + Contralateral Nasal Fibers except for macular representation {{caption_text}} Homonymous Hemianopia with Macular Sparing Tip of Visual Cortex (Middle Cerebral Artery) Macular Representation of Ipsilateral Temporal and Contralateral Nasal Fibers. {{caption_text}} Macular Homonymous Hemianopia The frontal visual field (Option A) is incorrect since a lesion in this area affects functions like attention, visual scanning, and decision-making. The image in the given scenario is not associated with this area.

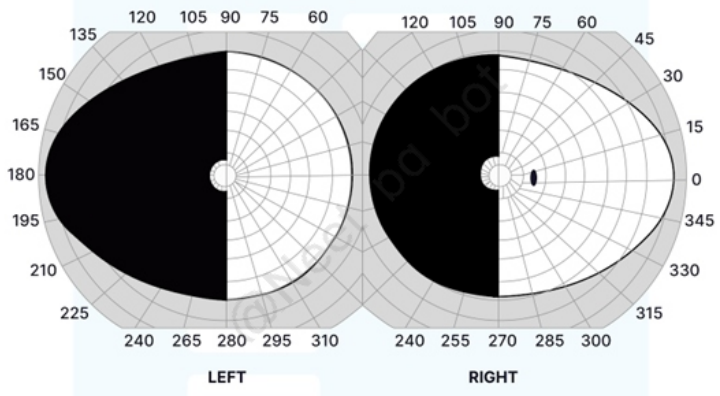

@Neet_pg_bot



@Neet_pg_bot

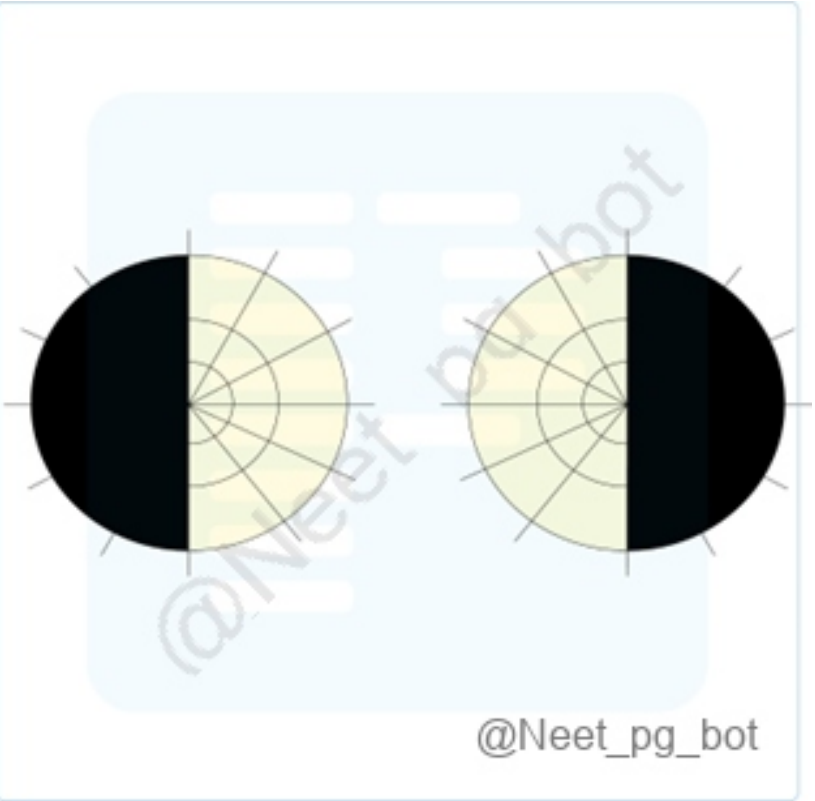

@Neet_pg_bot



@Neet_pg_bot

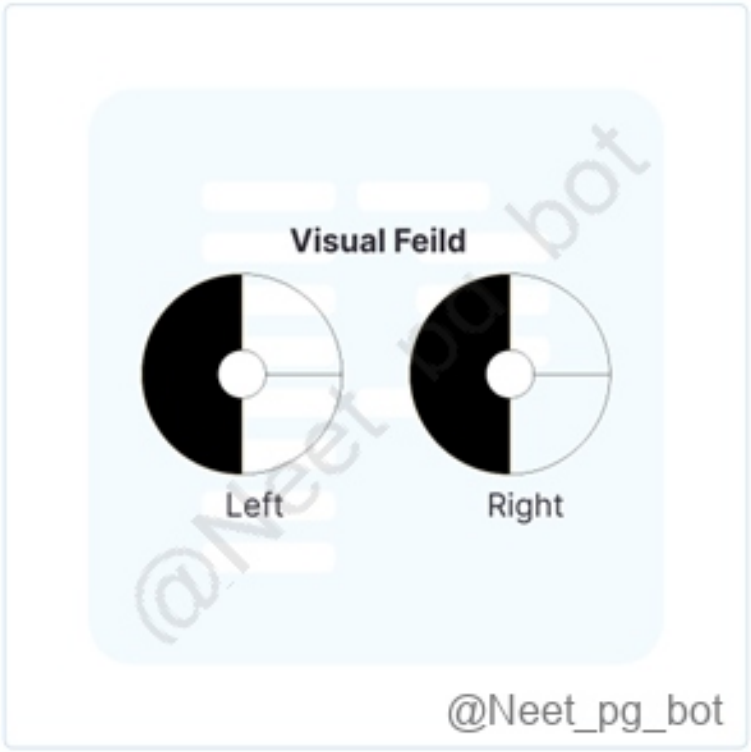

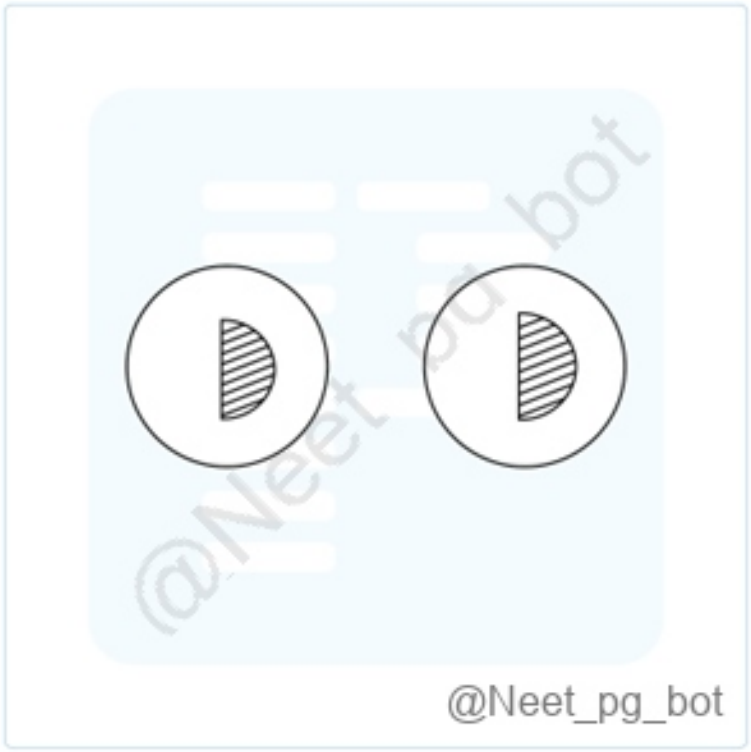

References:

Parsons Diseases of the eye, 23rd Edition, Page: 1184, 1213. Yanoff & Duker Ophthalmology, 5th edition, Page: 913, 919.

↑ *Back to this question in Part A*

@Neet_pg_bot

Q27: A Patient presents with progressive back pain and weakness in both lower limbs. Which findings would support the diagnosis of compressive myelopathy? (Q879162)

A. Hypotonia

B. Absent Babinski sign

C. Knee clonus

D. Normal cremasteric reflex

Correct Answer: C. Knee clonus

Explanation: In this scenario of Compressive Myelopathy , knee clonus supports the diagnosis because it is an upper motor neuron sign seen below the level of spinal cord compression. Compressive myelopathy is spinal cord compression, commonly from a mass, disc herniation, tumor, or degeneration → Produce upper motor neuron signs below the lesion . Upper motor neuron signs include: Spasticity (increased tone, not hypotonia) Hyperreflexia (exaggerated deep tendon reflexes) Positive Babinski sign (Option B ruled out) Clonus (e.g., knee clonus) (Option C) Lower motor neuron signs (hypotonia, hyporeflexia, muscle wasting) are typically seen at the level of the lesion , not below it. (Option A ruled out) Normal cremasteric reflex (Option D) is not typically affected in compressive myelopathy.

References:

The screening process of a patient with low back pain and suspected thoracic myelopathy: a case report

↑ *Back to this question in Part A*

@Neet_pg_bot

Q28: Which one of the following drugs is NOT indicated in the management of status epilepticus? Valproate Ethosuximide Fosphenytoin Levetiracetam (Q879159)

A. 1, 2

B. 2, 3

C. 2, 4

D. 1, 3, 4

Correct Answer: C. 2, 4

Explanation: Ethosuximide is not indicated in status epilepticus; it is used only for absence (petit mal) seizures. Levetiracetam , though effective as an adjunct or alternative agent in seizure control, is not included in standard first- or second-line emergency protocols for status epilepticus in major guidelines (it may be used off-label in refractory cases). Valproate and Fosphenytoin are approved intravenous options for the management of status epilepticus after benzodiazepines.

References:

Harrison’s Principles of Internal Medicine, 21st Edition, Page 3263-3264.

↑ *Back to this question in Part A*

@Neet_pg_bot

Q29: A female patient presents to you with a unilateral headache. It is associated with nausea, photophobia, and phonophobia. What is the drug of choice for acute management? (Q855890)

A. Flunarizine

B. Sumatriptan

C. Propranolol

D. Topiramate

Correct Answer: B. Sumatriptan

Explanation: The clinical features of unilateral headache, nausea, photophobia, and phonophobia are classic signs of an acute migraine attack. Migraine is a common episodic headache disorder, more frequent in females, and often triggered by stimuli such as bright lights, hunger, or stress. Drug of Choice: Triptans (e.g., Sumatriptan) (5-HT1B/1D receptor agonist) Mechanism of Action: It reduces nociceptive signaling in the trigeminovascular system and causes cranial vasoconstriction, effectively alleviating migraine symptoms. Indication: First-line treatment for acute migraine attacks. Side Effects: Can cause transient myocardial ischemia, coronary vasospasm, and rarely, serotonin syndrome when combined with SSRIs or TCAs. Migraine Management: Acute Treatment: First-Line: NSAIDs, Triptans (e.g., Sumatriptan). Alternatives: Gepants (e.g., Rimegepant), Ditans (e.g., Lasmiditan). Supportive measures: Dopamine receptor antagonists (e.g., Domperidone) for associated nausea. Prophylaxis (for frequent attacks): Flunarizine (Option A): Calcium channel blocker Propranolol (Option C): Non-selective β-blocker Topiramate (Option D): Anticonvulsant Amitriptyline: Tricyclic antidepressant (TCA) Triggers to Avoid: Bright lights, stress, hunger, sleep deprivation.

References:

Harrison's Principles of Internal Medicine, 21st Edition, Page: 3357, 3359, 3361, 3363, 3364, 3365.

Goodman & Gillman's The Pharmacological Basis of Therapeutics, 13th Edition, Page: 211, 214, 215, 232, 233, 318, 319.

K.D. Tripathi - Essentials of Medical Pharmacology, 8th Edition, Page: 155, 191, 192.

↑ *Back to this question in Part A*

@Neet_pg_bot

Q30: The cerebrospinal fluid (CSF) specimen of a patient is shown below, along with microscopy. The report shows mononuclear cytosis, elevated proteins, and low sugars. What is the likely etiology? (Q855849)

A. Tuberculous meningitis

B. Aseptic meningitis

C. Bacterial meningitis

D. Chemical meningitis



@Neet_pg_bot

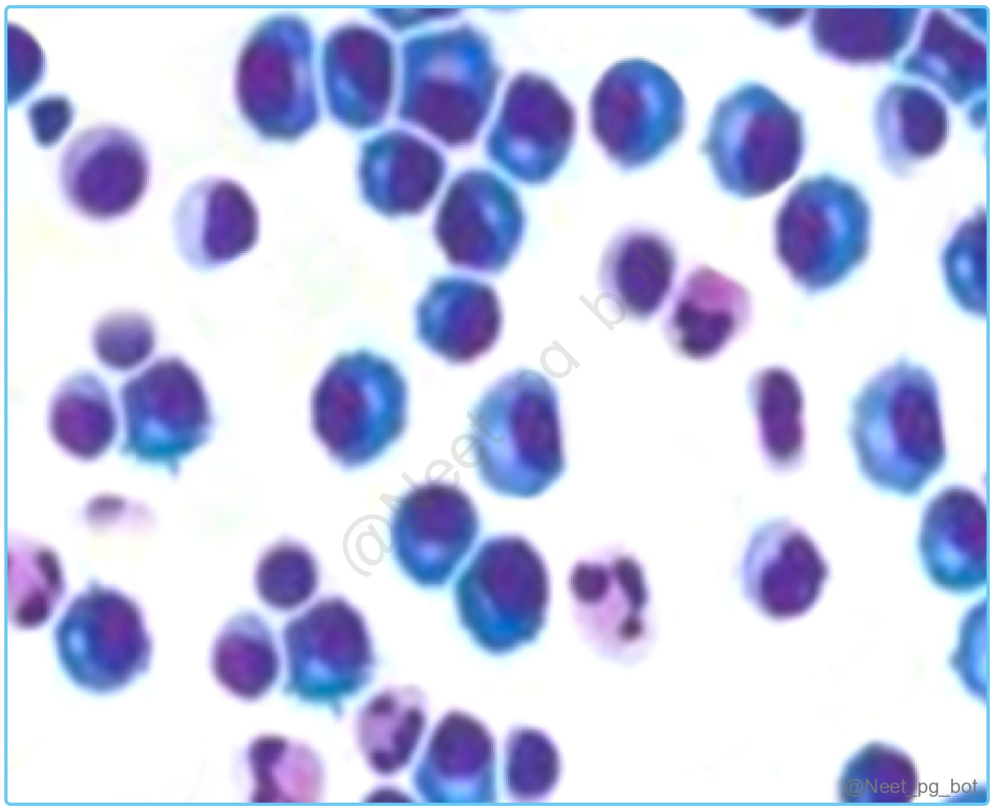

Correct Answer: A. Tuberculous meningitis

Explanation: The given clinical scenario, along with CSF findings of mononuclear cytosis, elevated proteins, low sugars, and the characteristic cobweb-like clot, strongly suggests tuberculous meningitis (TBM). Features of Tuberculous Meningitis (TBM): Etiology: Caused by Mycobacterium tuberculosis, spreading hematogenously or via rupture of subependymal tubercles into the subarachnoid space. Presentation: Subacute infection with fever, headache, neck stiffness, and cranial nerve palsies (commonly ocular nerves due to basal meningeal involvement). Complications: Hydrocephalus, raised intracranial pressure (ICP), and infarcts. CSF Findings: Lymphocytic predominance. Elevated protein levels. Low glucose levels. Cobweb-like pellicle formation. Diagnosis: Gold Standard: CSF culture for Mycobacterium tuberculosis. Supportive Tests: Acid-fast bacilli (AFB) stain, PCR for tuberculosis, or CSF ADA levels. Management: Initiation of antitubercular therapy (ATT). Steroids to reduce inflammation. CSF Findings in Different Types of Meningitis Parameter Bacterial Meningitis (Option C) Viral Meningitis (Aseptic Meningitis) (Option B) Fungal Meningitis Tuberculous Meningitis Appearance Turbid/cloudy Clear Clear/slightly cloudy Cobweb appearance Opening Pressure Elevated Normal or slightly elevated Elevated Elevated WBC Count 100–10,000/µL (predominantly neutrophils) 10–500/µL (predominantly lymphocytes) 20–500/µL (predominantly lymphocytes) 50–500/µL (predominantly lymphocytes) Protein Elevated (>100 mg/dL) Normal or slightly elevated (50–100 mg/dL) Elevated (50–200 mg/dL) Elevated (100–500 mg/dL) Glucose Decreased (<40 mg/dL or <40% of serum glucose) Normal (>40 mg/dL or >50% of serum glucose) Decreased (<40 mg/dL or <50% of serum glucose) Decreased (<40 mg/dL or <50% of serum glucose) Chemical meningitis (Option D): This occurs due to the rupture of tumor contents (e.g., from a dermoid cyst or glioma) into the CSF. CSF Findings: Variable inflammatory response, often with elevated proteins but no infective organisms.

References:

Harrison's Principles of Internal Medicine, 21st Edition, Page: 1100, 1102, 1103, 1104, 1106, 1108, 1109, 1110, 1267, 1366

NCBI Article on Meningitis

PubMed Article

↑ *Back to this question in Part A*

@Neet_pg_bot

Q31: Which of the following is the most important pathophysiological mechanism for Berry aneurysm? (Q859807)

A. Endothelial injury of vessel due to HTN

B. Muscle intimal elastic lamina layer defect

C. Endothelial layer defect

D. Adventitia defect

Correct Answer: B. Muscle intimal elastic lamina layer defect

Explanation: Berry aneurysms primarily develop due to disruption of the internal elastic lamina of cerebral blood vessels. The internal elastic lamina is a critical structural component that provides tensile strength and elasticity to blood vessels. When this layer is compromised, the vessel wall becomes weakened and less able to withstand normal hemodynamic stresses , leading to outward bulging and eventual aneurysm formation. Berry Aneurysm Definition Saccular outpouching of intracranial arterial wall Represents 90% of cerebral aneurysms Primary location: Circle of Willis Most common sites: Anterior communicating/anterior cerebral junction Posterior communicating/internal carotid junction Middle cerebral artery bifurcation Basilar apex Pathophysiological Mechanisms Structural Changes: Most important- Internal elastic lamina disruption Media layer thinning Adventitial layer remodeling Molecular Mechanisms: Inflammatory mediator activation Matrix metalloproteinase upregulation Vessel wall extracellular matrix degradation Hemodynamic Factors: Wall shear stress elevation Flow-related endothelial injury Intramural stress distribution alterations Histopathological Classification 1. Mycotic: Infectious arterial wall damage Distal vessel predilection Inflammatory cell infiltration 2. Arteriosclerotic: Intimal hyperplasia Media degeneration Elastic fiber fragmentation 3. Traumatic: Transmural disruption False lumen formation Adventitial hemorrhage Rupture Risk Stratification Morphological Criteria: Size >7mm: high risk Aspect ratio >1.6 Daughter sac presence Wall irregularity Hemodynamic Factors: Systolic BP >140 mmHg Flow pattern alterations Intrasaccular pressure gradients Genetic Markers: Collagen deficiency Elastic fiber abnormalities Matrix metalloproteinase polymorphisms Clinical Manifestations Subarachnoid Hemorrhage: Hunt-Hess grading scale correlation Fisher scale for CT findings Modified Rankin Scale outcomes Mass Effect: Cranial nerve compression syndromes Brainstem compression sequelae Hydrocephalus development Thromboembolic Events: Watershed infarction patterns Perforator occlusion syndromes Distal embolization phenomena Endothelial injury due to HTN (Option A) while hypertension can exacerbate aneurysm formation and increase rupture risk, it is not the primary underlying cause of berry aneurysms. Hypertension acts as a

contributing factor rather than the initiating defect. Endothelial layer defect (Option C) although the endothelium can be involved in aneurysm progression, the primary defect occurs in the internal elastic lamina rather than the endothelial layer. The endothelial dysfunction is usually secondary to the underlying structural abnormality. Adventitia defect (Option D) the adventitial layer is the outer layer of blood vessels and is not the primary site of berry aneurysm formation. The key pathology begins in the internal elastic lamina and medial layer of the vessel wall.

References:

Harrison's Principles of Internal Medicine, 21st Edition, Page: 3353-3355

https://www.ncbi.nlm.nih.gov/books/NBK557480/

↑ *Back to this question in Part A*

@Neet_pg_bot

Q32: Which of the following statements about tremors are true? PD is characterized by resting tremor Tremor consist of alternate contraction of agonist and antagonist muscle in an oscillating rhythmic manner Essential tremor is an uncommon movement disorder. Normal individuals can have physiologic tremors that manifest as mild high frequency, postural or action tremors (Q859801)

A. 1,2,3 only

B. 2,3,4 only

C. 1,2,4 only

D. All of the above

Correct Answer: C. 1,2,4 only

Explanation: Essential tremor is the most common movement disorder , affecting approximately 5-10% of the general population, with increasing prevalence in older age groups. It usually presents as a bilateral postural 6 to 12 Hz tremor of the hands and head . The Movement Disorders Society diagnostic criteria include: Tremor is bilateral, symmetrical, and postural The tremor involves the forearms and hand Is persistent and visible It may be associated with isolated head tremor Causes and characteristics of tremors Type of Tremor Cause Characteristics Exacerbating Factors Alleviating Factors Resting Tremor Parkinson's disease Occurs at rest Pill-rolling movement Asymmetrical Emotional stress Fatigue Voluntary movement Action Tremor Cerebellar disorders Multiple sclerosis Tremor occurs with voluntary movement Intention tremor (worsens near target) Movement initiation Rest Postural Tremor Essential tremor Physiologic tremor Tremor when maintaining posture against gravity Fine or coarse oscillations Anxiety Fatigue Caffeine Alcohol Beta-blockers Intention Tremor Cerebellar damage Increases in amplitude as the target is approached Goal-directed movements Rest Physiologic Tremor Normal individuals Fine, rapid, low-amplitude tremor Anxiety Caffeine Hyperthyroidism Rest Sleep Essential Tremor (Most Common Tremors) Unknown (often familial) Bilateral, symmetric Affects hands, head, voice Stress Fatigue

Alcohol Beta-blockers Dystonic Tremor Dystonia Irregular tremor Associated with abnormal postures Movement or sustained posture Sensory tricks (geste antagonists) Drug-induced Tremor Lithium Valproate SSRIs Symmetric, postural, or action tremor Drug use Dose reduction or discontinuation Psychogenic Tremor Functional neurologic disorder Sudden onset Inconsistent tremor Disappears with distraction Psychological stress Distraction Psychotherapy Parkinson's Disease (PD) is characterized by a classic resting tremor (Statement 1 Ruled Out) which occurs at rest and decreases with intentional movement. Tremor physiology involves the alternating contraction of opposing muscle groups (agonist and antagonist) in a rhythmic pattern. (Statement 2 Ruled Out) Physiologic tremors are a normal phenomenon that can occur in healthy individuals, particularly during certain postures or actions. (Statement 4 Ruled Out) Statement 3 regarding essential tremor being uncommon and affecting 5% of the population is incorrect.

References:

Harrison's Principles of Internal Medicine, 21st Edition, Page: 3400,3401.

Davidson's Principles and Practice of Medicine, 24th Edition, Page: 1082.

↑ *Back to this question in Part A*

@Neet_pg_bot

Q33: A 60-year-old woman presents with weakness in right arm for 6 hours. The weakness gradually became lesser and later resolved. She is a known case of diabetes and hypertension and is obese. Which of the following is the probable diagnosis of this case? (Q859797)

A. Compressive neuropathy

B. Transient ischaemic attack

C. Ischaemic stroke

D. Diabetic neuropathy

Correct Answer: B. Transient ischaemic attack

Explanation: Based on the given clinical presentation, the probable diagnosis in this case is Transient Ischaemic Attack (TIA). Transient Ischaemic Attack (TIA) Defined as a transient episode of neurologic dysfunction due to the focal brain, spinal cord, or retinal ischemia without acute infarction or tissue injury. A TIA typically lasts less than an hour, more often minutes. Usually resolves within 24 hours. Risk is highest in the first 48 hours following a transient ischemic attack. Etiology: Common risk factors for all TIA include diabetes, hypertension, age, smoking, obesity, alcoholism, unhealthy diet, psychosocial stress, and lack of regular physical activity. A previous history of stroke or TIA will increase substantially the subsequent risk of recurrent stroke or TIA. Pathophysiology: TIA subtypes, classified according to the pathophysiological mechanisms Large artery atherothrombosis (M/C): This may be intracranial or extracranial atherothrombosis. The mechanism may be a lack of blood flow distal to the site of arterial stenosis or an artery-to-artery embolism. Small vessel ischemic diseases:

The underlying pathology is either lipohyalinosis or small vessel arteriolosclerosis. The commonest risk factor is hypertension, followed by diabetes and age. Cardiac embolism: A clot in the cardiac chamber, most commonly in the left atrium , is secondary to atrial fibrillation. Cryptogenic : This is usually a cortical pattern of ischemia without any identifiable large artery atherothrombosis or cardiac source of emboli. More recently it is often referred to as ESUS (embolic stroke of unknown source). Other uncommon causes such as arterial dissection or vasculitis. ABCD2 Score for TIA (Transient Ischemic Attack): The Risk of Stroke Parameter Criteria Points Age > 60 years 1 point Blood Pressure BP ≥ 140/90 1 point Clinical Features Speech disturbance without weakness 1 point Unilateral weakness 2 points Duration 10–59 minutes 1 point ≥ 60 minutes 2 points Diabetes Presence of diabetes 1 point Stroke Risk Based on Score: Score Stroke Risk Day 2 Day 7 Day 90 0–3 1% 1.2% 3.1% 4–5 4.1% 5.9% 9.8% 6–7 8.1% 11.7% 17.8% Compressive neuropathy typically (Option A) results in persistent symptoms rather than transient symptoms as described in the case. Ischaemic stroke (Option C) involves a more prolonged disruption of blood flow to a specific area of the brain, leading to persistent neurological deficits that do not resolve within 24 hours. Diabetic neuropathy (Option D) is unlikely to cause transient weakness limited to one side of the body, as seen in this case.

References:

TIA

↑ *Back to this question in Part A*

@Neet_pg_bot

Q34: A patient who is 66 years old and has a history of chronic hypertension, arrives at the emergency room with changes in mental state and high blood pressure measuring 210/110 mm Hg. A brain CT scan shows bleeding within the brain tissue. The typical location of this bleeding in similar cases is? (Q859794)

A. Putamen

B. Thalamus

C. Pons

D. Cerebellum

Correct Answer: A. Putamen

Explanation: The features are of intraparenchymal hemorrhage due to hypertension which occurs in the deep tissues of the brain. The most common site of this is putamen . The sudden elevation in blood pressure can overwhelm cerebral autoregulation Most commonly affects small penetrating arteries (lenticulostriate arteries) Common causes of intracerebral haemorrhage include: Hypertension (most common - affecting basal ganglia, thalamus, pons, cerebellum) Drug use (cocaine, methamphetamine) - especially in young patients Cerebral amyloid angiopathy (elderly, lobar haemorrhages) Coagulopathy Vascular malformations Head trauma Hemorrhagic transformation of ischemic stroke Direct vessel wall damage: While cocaine can cause endothelial dysfunction over time Direct vessel wall damage is more associated with chronic use Acute haemorrhage is

primarily due to pressure effects More relevant in chronic vasculopathy Vasculitis: This can occur with chronic cocaine use Usually presents with multiple vascular territories More commonly causes ischemic events Takes time to develop and isn't the acute mechanism Amyloid deposition: Typically occurs in the elderly (>60 years) Associated with lobar haemorrhages Caused by β-amyloid deposition in vessel walls Feature Cerebral Amyloid Angiopathy (CAA) Berry Aneurysm Rupture Hypertensive Crisis Venous Sinus Thrombosis Age Group Elderly (>60 years) Younger Older, with chronic HTN Younger, hypercoagulable states Hypertension None None Chronic HTN None Hemorrhage Type Multiple lobar haemorrhages Subarachnoid, single-event Deep (e.g., putamen , thalamus) Hemorrhagic infarction Hemorrhage Location Cortical-subcortical regions Subarachnoid space Deep brain structures Venous infarction Imaging Lobar haemorrhages, microbleeds Single, subarachnoid bleed Deep hemorrhage Venous infarction pattern Symptoms Acute neurological symptoms Thunderclap headache Often no symptoms Seizures, focal deficits Onset Acute neurological presentation Sudden, thunderclap headache Acute, with chronic HTN Acute, gradual progression Distribution Spares deep structures Focal Deep brain Venous infarction While intraparenchymal haemorrhage can occur in other brain regions, such as the thalamus (Option B) , pons (Option C) , or cerebellum (Option D) , the putamen is the most commonly affected site in cases of chronic hypertension-associated haemorrhage.

References:

Harrison’s Principles of Internal Medicine, 21st Edition, Volume I, Page: 3349, 3350.

↑ *Back to this question in Part A*

@Neet_pg_bot

Q35: A patient was asked to copy the face of a clock and his drawing is shown below. What is the correct term to be used here? (Q859790)

A. Confabulation

B. Hemispatial neglect

C. Kinetic apraxia

D. Asterixis

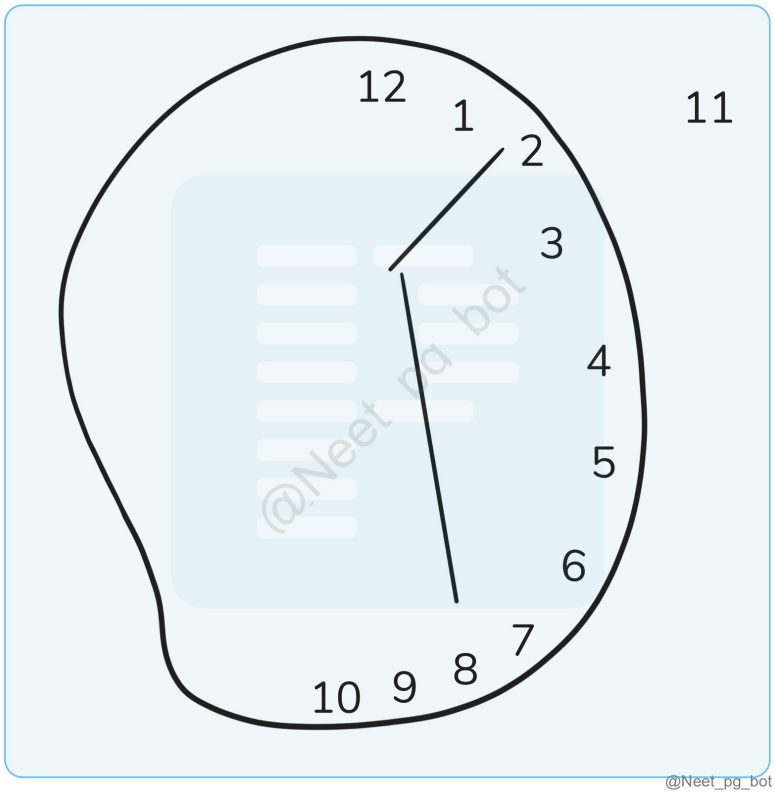

Correct Answer: B. Hemispatial neglect

Explanation: The given image represents the patient suffering from hemispatial neglect where there are missing details in the left side of the line drawing. Hemispatial Neglect : Hemispatial neglect is the inability to report, respond, and orient to stimuli in one-half of the space despite having no motor or sensory deficits. Types and location of lesions: Contralesional Hemispatial Neglect: Result of damage to cortical or subcortical components of the spatial attention network. Not always caused by parietal lobe lesions, as traditionally believed. Spatial Attention Model: Right hemisphere: Directs attention to the entire extrapersonal space. Left hemisphere: Directs attention mostly to the right hemispace (contralateral). Left hemisphere lesions: Minor neglect, as the right hemisphere compensates. Right hemisphere lesions: Severe neglect of the left hemispace due to lack of ipsilateral attentional mechanisms in the left hemisphere. Clinical Examination: Patients may neglect grooming, eating, and reading on the left side. Line drawing and writing often have missing details on the left side. Tests for neglect: Simultaneous Bilateral Stimulation: Patients fail to detect bilateral stimuli and experience extinction (only detecting stimuli from the right side). Target Detection Task: Difficulty detecting targets on the left side, reflecting a motor and attentional deficit rather than sensory input loss (hemianopia). Some patients may deny the existence of hemiparesis or even the paralyzed limb (anosognosia). Clinical Observation: Neglect is more common, severe, and long-lasting after right hemisphere damage. Severe neglect of the right hemispace is rare even with left hemisphere lesions. Confabulation (Option A) is a phenomenon in which the patient fills in memory gaps with made-up stories and inaccurate facts. Kinetic apraxia (Option C) is the inability to perform a fine movement or task despite having the desire and physical capability to do it. The lesion lies in the paracentral cortex. Asterixis (Option D) is a type of negative myoclonus where irregular lapses of the posture of body parts are noted.

References:

Harrison’s Principles of Internal Medicine, 21st Edition, Page: 199, 200.

↑ *Back to this question in Part A*

@Neet_pg_bot

Q36: A 28-year-old patient develops rapid-onset psychiatric symptoms such as anxiety, depression, and personality changes, which are soon followed by ataxia and cognitive decline. The FLAIR MRI (shown below) demonstrates characteristic findings. What is the most likely diagnosis? (Q859752)

A. Alzheimer's disease

B. Vascular dementia

C. Sporadic CJD

D. Variant CJD

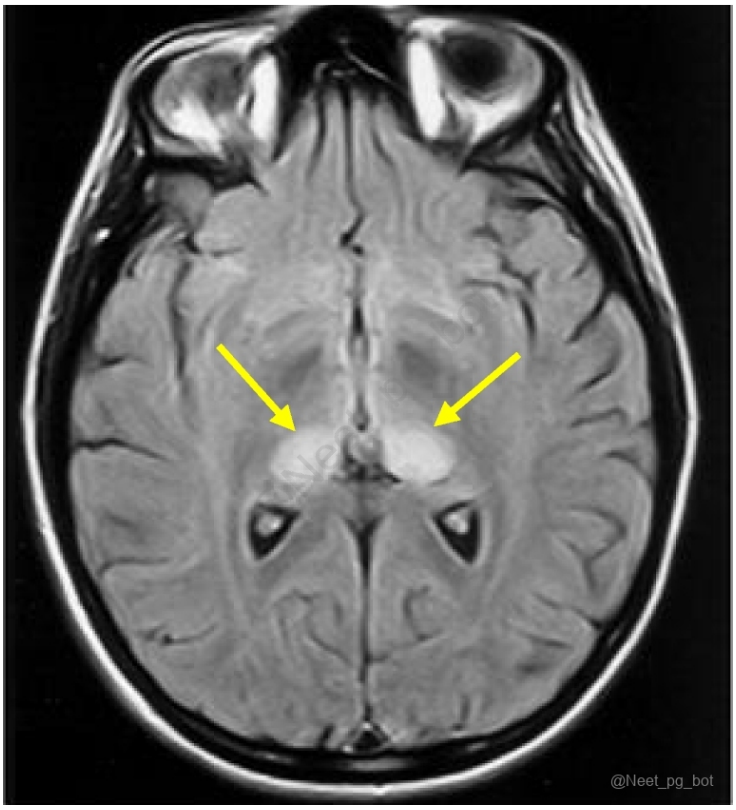

Correct Answer: D. Variant CJD

Explanation: The clinical scenario and the FLAIR MRI in the scenario showing the “ hockey stick ” sign is found in variant type Creutzfeldt-Jakob disease (CJD). Creutzfeldt-Jakob Disease (CJD) is a rare, rapidly progressing brain disorder affecting coordination, memory, and mental functions. Creutzfeldt-Jakob disease (CJD) findings Electroencephalography (EEG) Periodic sharp wave complexes (PSWC) These can be either lateralized in earlier

stages or generalized in later stages. {{caption_text}} MRI findings DWI or FLAIR MRI has a sensitivity of 98% and specificity of 93% DWI: Increased intensity in the basal ganglia, thalamus, and cortex Cortical ribboning {{caption_text}} Hockey stick or pulvinar sign is seen in variant , infectious, or acquired CJD In the initial stages, the MRI is normal in Alzheimer's (Option A) , and in the later stages shows temporal and parietal atrophy. There is no history of stroke; hence vascular dementia (Option B) is unlikely to be the diagnosis The hockey stick sign is not and indicator of sporadic CJD (Option C) .



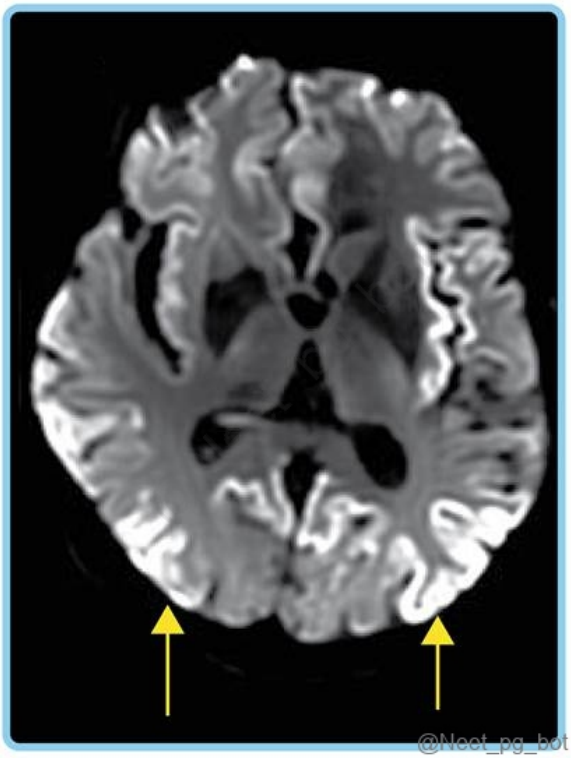

References:

https://pubmed.ncbi.nlm.nih.gov/16442343/

Harrison’s Principles of Internal Medicine, 21st edition, page 3421

https://www.ncbi.nlm.nih.gov/books/NBK507860/

↑ *Back to this question in Part A*

@Neet_pg_bot

Q37: What is the most probable cause for a 22-year-old man who has a high-grade fever, a purpuric rash, and a CSF sample showing gram-negative diplococci? (Q859751)

A. Neisseria meningitidis

B. Pseudomonas aeruginosa

C. Streptococcus pneumoniae

D. E.coli



Correct Answer: A. Neisseria meningitidis

Explanation: The above image is that of a purpuric rash which is seen in meningococcemia caused by Neisseria meningitides. Neisseria meningitidis is a gram negative diplococci. Fulminant meningococcemia presents with a very high fever and hemorrhagic rash. Acute Bacterial Meningitis Definition: Acute purulent infection in the subarachnoid space (SAS) leading to CNS inflammation. Causes: Streptococcus pneumoniae and Neisseria meningitides are the primary causes. Listeria monocytogenes is a significant risk in adults over 50, especially in those with diabetes, alcoholism, or weakened immune systems. Presentation: Can be acute and fulminant or subacute, with the classic triad of symptoms: Fever Headache Nuchal rigidity (stiff neck) Clinical features Description Consciousness Decreased level of consciousness occurs in >75% of cases, ranging from lethargy to coma. Kernig's Sign Positive when passive extension of the knee elicits pain; indicative of meningeal irritation. Brudzinski's Sign Positive when passive flexion of the neck results in spontaneous flexion of the hips and knees; also indicative of meningeal irritation. Pupils May present as dilated and poorly reactive due to increased intracranial pressure (ICP). Posturing Possible decerebrate posturing as a sign of severe CNS dysfunction. Signs of Increased ICP Includes elevated CSF opening pressure (>180 mmH2O), papilledema, and potential cerebral herniation (1–8% incidence). Additional Symptoms Nausea, vomiting, photophobia; seizures in 15–40% (focal or generalized). Meningococcemia Rash Erythematous maculopapular rash that quickly becomes petechial, commonly on the trunk and lower extremities. Pseudomonas aeruginosa (Option B) is a gram-negative rod-shaped bacteria. Streptococcus pneumoniae (Option C) is a gram-positive, spherical bacteria. E. Coli (Option D) is a gram-negative rod-shaped bacteria.

References:

Harrison’s Principles of Internal Medicine, 21st Edition, Page: 1100,1102,1103, 975, 1104, 1105.

Davidson’s Principles and Practice of Medicine, 24th Edition, Page: 1119, 1120.

↑ *Back to this question in Part A*

Q38: A male patient presents with sensory loss and weakness of limbs for 3 months. He also has angular stomatitis. On examination, there is loss of proprioception, vibration sensations, UMN-type lower limb weakness, and absent ankle reflex. What is the most probable diagnosis? (Q855473)

A. Extradural cord compression

B. Amyotrophic lateral sclerosis

C. Multiple sclerosis

D. Subacute combined degeneration of the cord

Correct Answer: D. Subacute combined degeneration of the cord

Explanation: Subacute combined degeneration of the cord The clinical features described in this case—sensory loss, weakness of limbs, angular stomatitis, loss of proprioception and vibration sensation, UMN-type weakness, and absent ankle reflexes—are highly suggestive of subacute combined degeneration of the cord (SACD), which is a condition caused by vitamin B12 deficiency. Subacute Combined Degeneration of the Cord (SACD) Neurological disorder due to vitamin B12 deficiency, causing demyelination of the posterior columns and lateral corticospinal tracts. Etiology Vitamin B12 Deficiency: Pernicious anemia. Gastrectomy or ileal resection. Diphyllobothrium latum infestation. Long-term use of metformin or PPIs. Affected Areas Posterior columns: Loss of proprioception and vibration sense. Lateral corticospinal tracts: Spasticity and UMN-type weakness. {{caption_text}} Clinical Features Sensory Symptoms: Loss of proprioception and vibration sense: Begins in lower limbs, may progress to upper limbs. Sensory ataxia: Positive Romberg’s test (difficulty standing with eyes closed). Paresthesia: Tingling or numbness in extremities, typically in a glove-and-stocking distribution. Motor Symptoms: Upper motor neuron signs: Weakness, spasticity, and hyperreflexia. Spastic weakness: Due to lateral corticospinal tract involvement. Absent ankle reflex: A key finding, coexisting with UMN signs due to concurrent peripheral neuropathy. Signs: Lhermitte's Sign: Electric shock-like sensation down the spine on neck flexion. Angular stomatitis Optic neuropathy Non-neurological Features: Megaloblastic anemia: fatigue, pallor, glossitis, and jaundice. Psychiatric Symptoms: Irritability, dementia, psychosis. Depression and memory loss. Treatment Vitamin B12 Replacement: IM cyanocobalamin or hydroxocobalamin. Oral B12 for maintenance. Address underlying causes (e.g., anemia, parasitic infestation). Extradural cord compression (Option A), caused by a space-occupying lesion (e.g., tumor or abscess), typically presents with localized back pain, radicular symptoms, and bladder/bowel dysfunction. It typically causes asymmetric neurological deficits, unlike the symmetrical loss of proprioception, vibration, and UMN signs seen in subacute combined degeneration. Additionally, it does not cause angular stomatitis, which is indicative of vitamin B12 deficiency Amyotrophic lateral sclerosis (ALS) (Option B) primarily affects lower motor neurons and upper motor neurons. It presents with fasciculations, muscle cramps, muscle weakness, and atrophy, as well as bulbar palsy symptoms (dysarthria, dysphagia). Absence of sensory loss is a key differentiator here, as ALS does not typically affect sensory pathways. Multiple sclerosis (MS) (Option C): MS is an autoimmune demyelinating disease of the central nervous system, affecting both white matter in the brain and spinal cord. It commonly presents with symptoms like paresthesia, optical neuritis, weakness, and gait

disturbances. Lhermitte’s sign (pain down the back with neck flexion) and Uhthoff's sign (worsening of symptoms with heat) are classic, but the sensory loss and angular stomatitis here point more toward vitamin B12 deficiency rather than MS.

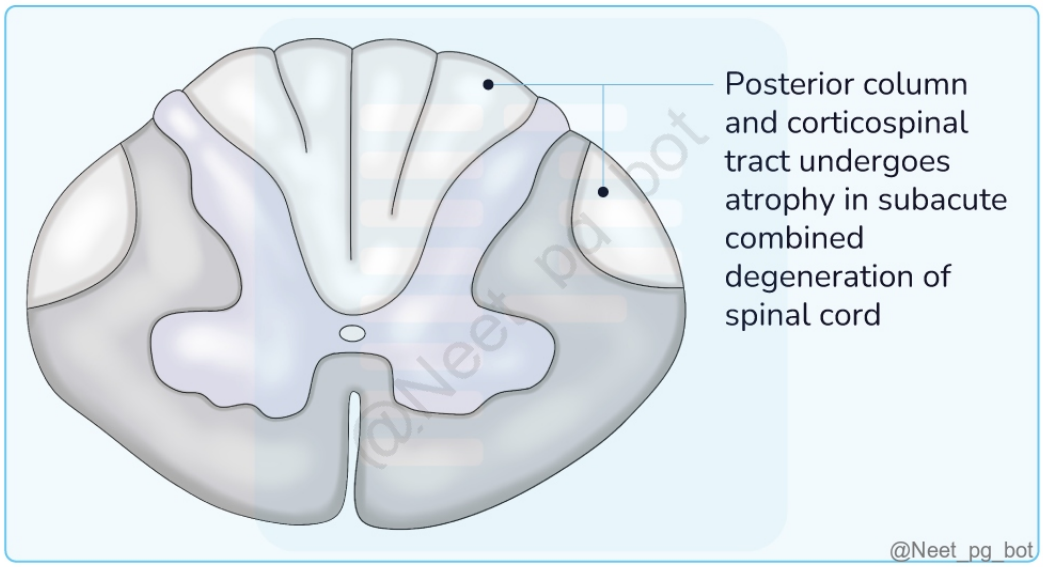

References:

Harrison's Principles of Internal Medicine, 21st Edition, Page: 3454, 568, 3411, 3412, 3462, 3463. Robbins and Cotran Pathologic Basis of Disease, 10th Edition, Page: 651.

↑ *Back to this question in Part A*

@Neet_pg_bot

Q39: A 28-year-old male was brought to the emergency room with a history of RTA. GCS progressively declines over hours and axial T2 MRI shows multiple small hypointense lesions at the corticomedullary junction and basal ganglia. What is the diagnosis? (Q859567)

A. Diffuse axonal injury

B. Extensive subarachnoid haemorrhage

C. Hypoxic cerebral injury

D. Multiple haemorrhagic contusion

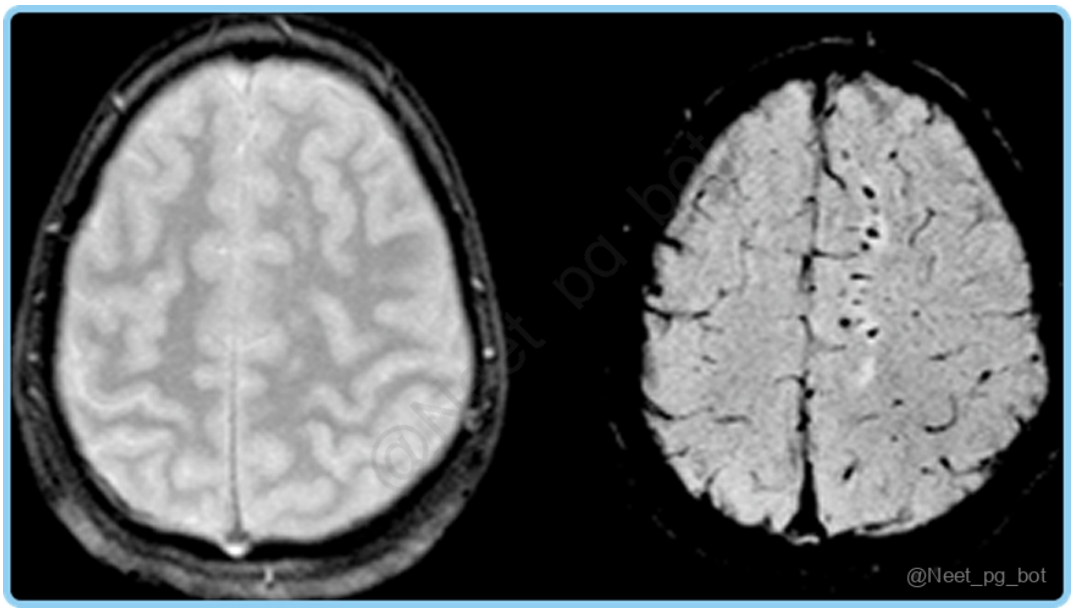

Correct Answer: A. Diffuse axonal injury

Explanation: Diffuse axonal injury (DAI) is a form of traumatic brain injury caused by a blunt force injury to the brain, often from high-speed motor vehicle accidents. Aetiology: Cause: High-speed accidents, where accelerating and decelerating forces cause shearing of axons in the white matter of the brain. Affected Areas: Primarily the corpus callosum, brainstem, and white matter tracts, especially at the junction of grey and white matter. Pathophysiology: Shearing forces disrupt neuronal connections, leading to brain dysfunction. Common Deficits: Affect frontal and temporal white matter, corpus callosum, and brainstem. Clinical Presentation: Diagnosis: Clinical diagnosis, typically with a GCS of less than 8 lasting over six hours. Symptoms: Mild: Headache, dizziness, nausea, and fatigue. Severe: Loss of consciousness, persistent vegetative state, potential long-term recovery for a few. Dysautonomia: Tachycardia, tachypnea, hyperthermia, abnormal muscle tone, and posturing. Evaluation: CT: Small punctate haemorrhages to white matter tracts. MRI: Investigation of choice Small areas of cerebral microbleeds at the grey-white matter junction, corpus callosum, or the brainstem. {{caption_text}} Treatment/Management: Goals: Prevent secondary injuries (e.g., hypoxia, hypotension, intracranial hypertension) and support recovery. Initial Treatment: Focus on stabilization, including resuscitation and prevention of complications like cerebral oedema and elevated ICP. ICP Monitoring: Recommended for GCS below 8 and for patients unable to be regularly evaluated neurologically. Anticonvulsants: Short-term use (7 days) to prevent early seizures. Emerging Therapies: Progesterone treatment shows promise but cannot be routinely recommended. Incorrect Options: Extensive subarachnoid haemorrhage (Option B) is a life-threatening condition due to the accumulation of blood between the arachnoid and pia mater. Hypoxic cerebral injury (Option C) refers to injury of the brain due to a lack of oxygen delivery enough to support metabolic needs. This is caused due to conditions like cardiac arrest, strangulation, severe anaemia, systemic hypotension, etc. Multiple hemorrhagic contusions (Option D) are traumatic brain injuries which are the most disabling type of traumatic phenomenon. These can be caused by falls, road traffic accidents, aggression, sports injuries, cyclists, etc. These appear as several localized areas of bleeding.

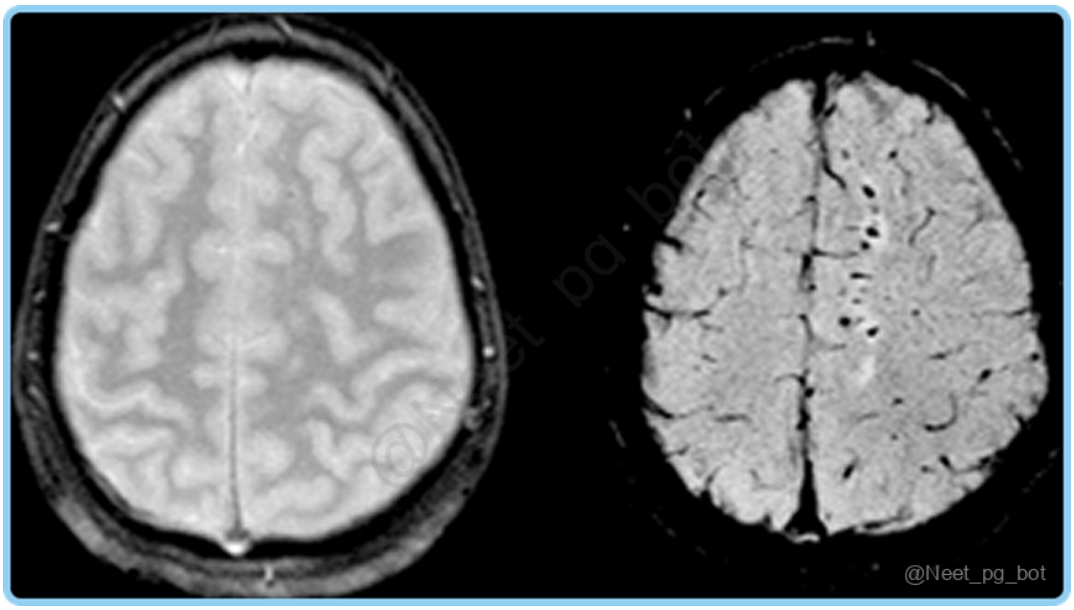

References:

https://www.ncbi.nlm.nih.gov/books/NBK448102/

↑ *Back to this question in Part A*

@Neet_pg_bot

Q40: Which type of aphasia is seen in the lesions of the posterior part of the superior temporal gyrus? (Q858441)

A. Fluent

B. Non-fluent

C. Anomic

D. Conduction

Correct Answer: A. Fluent

Explanation: Lesion of the posterior part of the superior temporal gyrus indicates Wernicke's aphasia . This condition is characterized by fluent speech. Feature Wernicke's Aphasia Broca's Aphasia (Option B) Global Aphasia Conduction Aphasia (Option D) Speech Output Fluent , but paraphasic and circumlocutious, jargon speech Nonfluent , labored, dysarthric, telegraphic Nonfluent, severely impaired Fluent, but many phonemic paraphasias Comprehension Impaired for spoken and written words Intact, except for syntactically complex sentences Severely impaired Intact for spoken language, impaired for reading aloud Repetition Impaired Impaired Severely impaired Severely impaired, with phonemic paraphasias Naming Impaired, leading to neologisms Impaired Severely impaired Impaired, with phonemic paraphasias Writing Impaired Impaired Severely impaired

Impaired, with phonemic paraphasias Motor Output (Facial and Limb) Often unremarkable (rare mild facial flattening) Right facial weakness, hemiparesis, buccofacial apraxia Right hemiplegia, hemisensory loss Varies depending on lesion site Cause (Common Lesions) Posterior part of superior temporal gyrus , inferior MCA branches Inferior frontal gyrus , superior MCA branches Involves entire MCA distribution Arcuate fasciculus , MCA branches Associated Features Severe agitation, paranoia, possible right hemianopia Right facial weakness, hemiparesis, emotional distress Right hemiplegia, hemisensory loss, homonymous hemianopia No significant associated features Anomic (Option C) aphasia is associated with lesions in areas such as the left temporal/ occipital lesions (area 37) and left thalamus, which disrupt the brain's ability to access words, especially nouns and verbs. This results in difficulty finding words, although comprehension and fluency are generally preserved.

References:

Harrison’s Principles of Internal Medicine, 21st Edition, Page 196,197

https://www.ncbi.nlm.nih.gov/books/NBK441951/

https://link.springer.com/referenceworkentry/10.1007/978-0-387-79948-3_856

↑ *Back to this question in Part A*

@Neet_pg_bot

Q41: An elderly woman is brought to the OPD with complaints of behavioural change, a history of multiple falls, urinary incontinence, and dementia. What is your diagnosis? (Q858429)

A. Normal pressure hydrocephalus

B. Frontotemporal dementia

C. Parkinson disease

D. Creutzfeldt-Jakob disease

Correct Answer: A. Normal pressure hydrocephalus

Explanation: The patient's symptoms of behavioral changes, falls, urinary incontinence, and dementia are indicative of Normal Pressure Hydrocephalus (NPH) , which is commonly associated with the classic triad of gait disturbance, urinary incontinence, and cognitive decline . Normal Pressure Hydrocephalus (NPH) NPH is often idiopathic but can result from prior injuries affecting cerebrospinal fluid (CSF) dynamics, such as subarachnoid hemorrhage. Clinical Triad Gait disturbance : Progressive difficulties in walking Urinary issues : Urgency or incontinence Cognitive impairment : Decline in cognitive functions Imaging Characteristics Ventriculomegaly is typically seen Evans ratio : the ratio of the maximum width of frontal horns to inner table width of more than 0.31 is often used for evaluation but has low diagnostic accuracy. An acute callosal angle (less than 90°) on coronal MR images is another measurement used, also with limited accuracy. A disproportionately enlarged subarachnoid space hydrocephalus is seen having ventriculomegaly combined with sulcal effacement at the vertex and scattered

enlarged sulci. CSF flow study shows hyper-dynamism with a streak of flow void through cerebral aqueduct. {{caption_text}} {{caption_text}} Frontotemporal dementia (Option B) (FTD) primarily affects personality, behavior, and language, often presenting with early changes such as disinhibition, apathy, and loss of empathy. Urinary incontinence is not a typical early feature of FTD, and gait disturbances or falls are also not commonly seen at the onset, making it less likely in this case. Parkinson's disease (Option C) primarily presents with motor symptoms such as bradykinesia, resting tremor, rigidity, and postural instability. While dementia and falls can occur in the later stages, urinary incontinence is not a typical early feature, and the behavioral changes in Parkinson's disease are usually associated with the later stages or due to medication effects, which makes it less consistent with the initial presentation. Creutzfeldt-Jakob disease (Option D) (CJD) is a rapidly progressive neurodegenerative disorder caused by prions, characterized by rapidly progressing dementia, myoclonus, ataxia, and other neurological signs. While behavioral changes can occur, urinary incontinence and multiple falls are not typical presenting features of CJD.

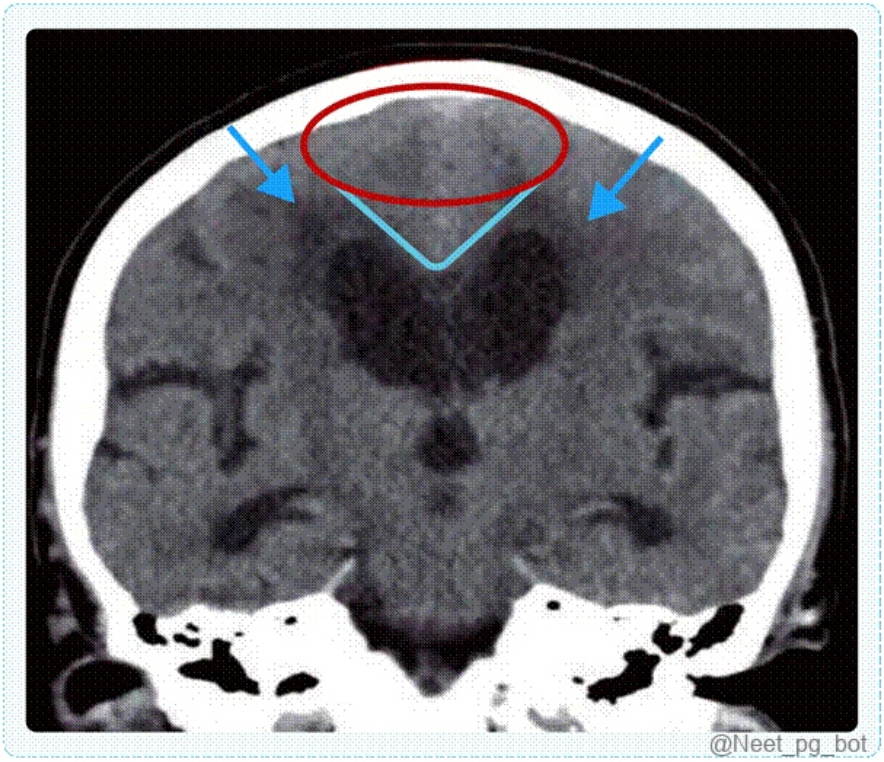

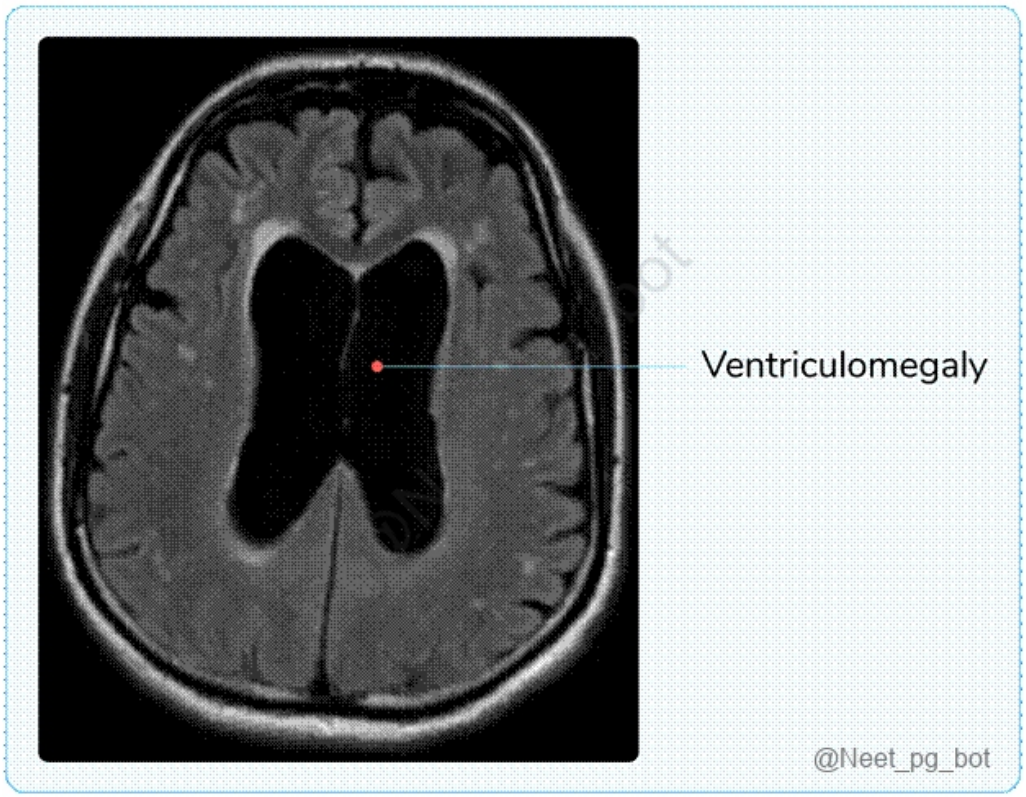

References:

David Sutton Textbook of Radiology and Imaging, Volume 2, 8th Edition, Page 2083

↑ *Back to this question in Part A*

@Neet_pg_bot

Q42: A lesion at which level produces incongruous homonymous hemianopia with Wernicke's pupil? (Q855068)

A. Optic tract

B. Visual cortex

C. Optic radiation

D. Optic nerve

Correct Answer: A. Optic tract

Explanation: - Optic tract Wernicke's pupil occurs due to a lesion at the optic tract , leading to incongruous homonymous hemianopia. Wernicke’s Hemianopic Pupil: Indicates a lesion in the optic tract. Light Reflex:

Ipsilateral direct and contralateral consensual light reflexes are both absent in the affected areas. Absent when light is shone on the temporal half of the retina of the affected side and the nasal half of the opposite side. Present when light is shone on the nasal half of the affected side and the temporal half of the opposite side. Visual cortex (Option B): Lesions in the visual cortex, located in the occipital lobe, cause congruous homonymous hemianopia (same field defect in both eyes) and do not produce Wernicke's pupil, which is specific to lesions in the optic tract. Optic radiations (Option C): Lesions in the optic radiations also result in congruous homonymous hemianopia but do not lead to Wernicke's pupil. Optic nerve (Option D): Lesions in the optic nerve cause monocular vision loss (loss of vision in one eye), not homonymous hemianopia, and therefore do not result in Wernicke's pupil.

References:

Reference: A.K. Khurana Comprehensive Ophthalmology, 7th Edition, Page 328

↑ *Back to this question in Part A*

@Neet_pg_bot

Q43: Which of the following causes the slowing of conduction in multiple sclerosis? (Q855012)

A. Gliosis

B. Loss of myelin sheath

C. Defect at node of Ranvier

D. Leaky Na + channel

Correct Answer: B. Loss of myelin sheath

Explanation: The slowing of conduction in multiple sclerosis is due to the loss of myelin sheath. Multiple sclerosis Multiple sclerosis (MS) is an autoimmune disease of the central nervous system characterized by chronic inflammation, demyelination , gliosis (plaques or scarring), and neuronal loss. The course can be relapsing or progressive. Pathophysiology: Immune hypothesis: Increased T lymphocytes in cerebrospinal fluid (CSF) and higher immunoglobulin synthesis in the CNS Blood-brain barrier (BBB) injury: Activated T lymphocytes cross the blood-brain barrier, recognize myelin antigens on nervous system antigen-presenting cells (microglia) and proliferate Demyelination: Inflammatory cascade releases cytokines, leading to oligodendrocyte - myelin destruction by macrophages Lesions: disintegration of myelin , lymphocyte/macrophage infiltration, and perivascular inflammation Ectopic lymphoid follicles are linked to demyelination and neuronal loss in the cerebral cortex Diffusible factors from these lymphoid cells may cause demyelination and neurodegeneration Axonal damage: Demyelination reduces trophic support for axons, redistributes ion channels, and destabilizes action potential membrane potentials Neuronal and axonal death may result from glutamate excitotoxicity, oxidative injury, iron accumulation, and mitochondrial failure Inflammatory mediators like nitric oxide initiate and worsen axonal damage Axons can adapt initially to these injuries, but over time, distal and retrograde degeneration (“dying-back” axonopathy) occurs Axonal loss accumulates over time due to repeated attacks and lack of neurotrophic factors from oligodendrocytes Plaque formation: After acute attacks, gliosis occurs by astrocyte cells,

forming scars. Surviving oligodendrocytes partially remyelinate axons causing shadow plaques. Oligodendrocyte precursor cells often fail to differentiate into myelin-producing cells. Long-term myelin loss leads to reduced impulse propagation and conduction block, impairing CNS functions. {{caption_text}} Gliosis (Option A): This refers to the proliferation of glial cells (especially astrocytes) in response to central nervous system injury. While gliosis occurs in MS as part of the tissue response to demyelination and inflammation, it is not the primary cause of slowed conduction. Instead, it is a secondary effect resulting from the damage. Defect at the Node of Ranvier (Option C): Nodes of Ranvier are small gaps in the myelin sheath where voltage-gated sodium channels are concentrated, allowing for the rapid "jumping" of action potentials (saltatory conduction). Although defects at these nodes can disrupt impulse propagation, in multiple sclerosis the main problem is the loss of myelin rather than a defect in the nodes themselves. Leaky Na■ Channels (Option D): In demyelinated axons, the redistribution or abnormal functioning of sodium channels can occur, which may contribute to conduction issues. However, this change is a consequence of myelin loss rather than a primary cause of conduction slowing. The loss of the insulating myelin sheath is the key factor impairing the proper function of these channels.

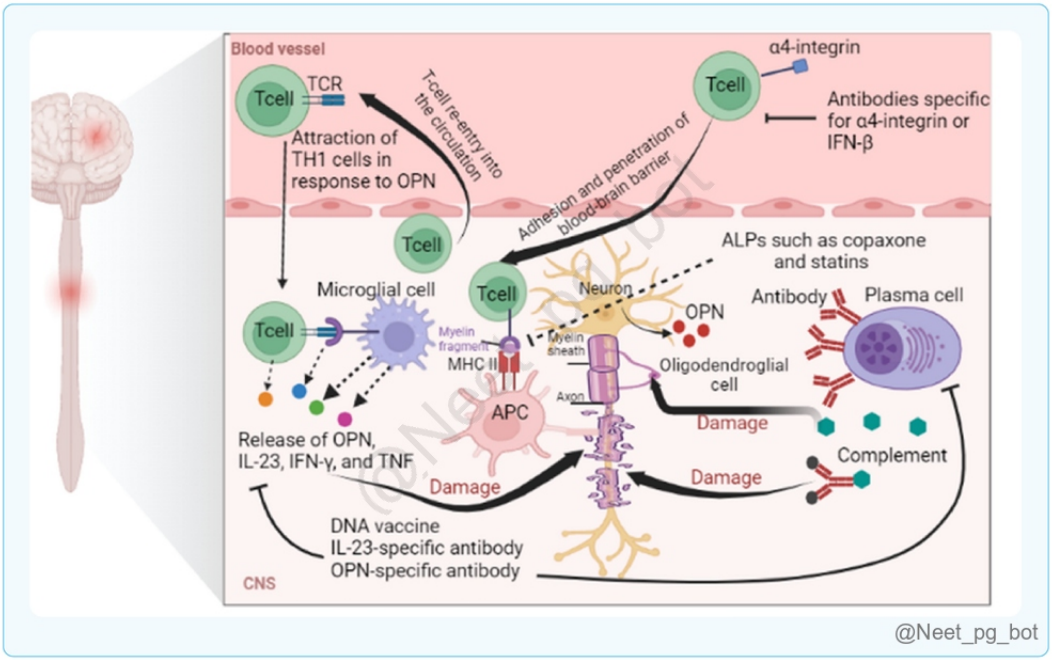

References:

Harrison’s Principle of Internal Medicine, 21st Edition, Page 3462, 3464, 3465

↑ *Back to this question in Part A*

@Neet_pg_bot

Q44: In hemiplegia caused by an ischemic stroke, which region of the internal capsule is impacted? (Q856288)

A. Retrolentiform

B. Sublentiform

C. Anterior limb

D. Posterior limb

Correct Answer: D. Posterior limb

Explanation: When an ischemic stroke occurs in the area supplied by the blood vessels surrounding the posterior limb of the internal capsule, the motor fibers within this region can be damaged. This results in hemiplegia on the opposite side of the body from the affected internal capsule. Small vessel stroke: Cause Lacunar infarct (affecting penetrating branches) secondary to atherosclerotic occlusion/lipohyalinosis Risk factors Hypertension: Most common Diabetes Atrial fibrillation Smoking Hyperlipidemia Sites & manifestations Posterior limb of internal capsule Pure motor hemiparesis Genu of internal capsule Clumsy hand dysarthria lacunar syndrome (facial weakness) Cortical pontocerebellar tract I/L ataxia + C/L hemiparesis Ventroposterolateral thalamus Dejerine-Roussy syndrome Tracts Passing Through Internal Capsule: Genu : Corticonuclear tract (motor fibres to cranial nerve motor nuclei) Posterior Limb : Corticospinal tract (motor fibres to the contralateral spinal cord) Corticopontine fibres from the parietal, temporal, and occipital lobes Fibres for the upper limb (anteriorly) and trunk/lower limbs (posteriorly) Superior Thalamic Peduncle (through anterior and posterior limbs): From ventral posterior and lateral posterior thalamic nuclei to parietal cortex (sensory areas). Other Tracts Passing Through the Internal Capsule: Anterior limb Retrolentiform part Sublentiform part Frontopontine fibres (Arnold's bundle) Corticorubral fibres Parietopontine,occipitopontine, and occipitotectal fibres Optic radiation Temporopontine fibres Auditory radiation (fibres from the medial geniculate body to the auditory cortex) Thalamic fibres to the temporal cortex and amygdala.

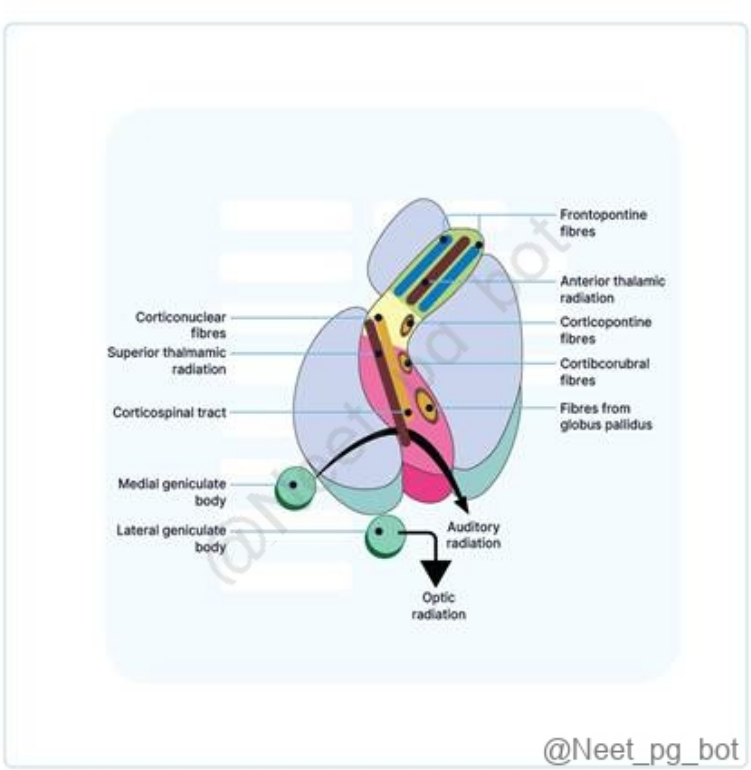

References:

Harrison’s Principles of Internal Medicine, 21st Edition, 173, 3326-3328, 3341

Gray’s Anatomy, 42nd Edition, Page 538

↑ *Back to this question in Part A*

@Neet_pg_bot

Q45: A 32-year-old woman who visits the clinic with complaints of frequent falls and walking difficulties. She also has a history of smoking and type-1 diabetes but no history of hypertension or coronary artery disease. During examination, the patient exhibits weakness in both lower limbs, absent DTR, as well as an unsteady gait. But, there is a decrease in proprioception and vibration sense in both lower limbs. Which of the following statements is correct about the above condition? (Q856263)

A. Only the dorsal column is involved

B. All these patients with a neurological impairment will show macrocytosis

C. Vitamin B12 supplements do not improve this condition

D. Copper deficiency may produce similar symptoms

Correct Answer: D. Copper deficiency may produce similar symptoms

Explanation: The patient's clinical presentation is consistent with subacute combined degeneration (SCD) of the spinal cord, which is commonly caused by vitamin B12 deficiency . SCD primarily affects the posterior (dorsal) and lateral columns (Option A) of the spinal cord. Vitamin B12 supplements (Option C) are the mainstay of treatment for vitamin B12 deficiency, and they can improve the patient's condition. And Copper deficiency may also produce similar symptoms. SACD however, occurs secondary to Vitamin B12 deficiency, can present without macrocytosis (Option B). Subacute combined degeneration Description Reversible myelopathy mainly involving Dorsal column and Pyramidal column tracts Etiology Vitamin B12 deficiency: Nutritional (vegetarians) Pernicious anemia, post-gastrectomy, Diphyllobothrium infection Clinical features Weakness: Corticospinal tract (CST)/Pyramidal tract involvement Loss of vibration and proprioception: Dorsal column tract involvement Ataxia: Romberg sign positive DTR: Absent (Peripheral neuropathy), Babinski sign: Positive (CST involvement) Dementia: reversible with therapy Hyperpigmentation of interphalangeal joints Investigations Vitamin B12 assay: Methyl malonate/Homocysteine levels estimation Peripheral blood smear: may reveal macrocytosis with hypersegmented neutrophils NOTE: SACD can occur without macrocytosis as well Management Vitamin B12 supplements Differential diagnosis Hypocupric myelopathy: Serum Cu2+ levels should be checked

References:

Harrison’s Principles of Internal Medicine, 21st edition, Page 3425, 3446, 3454.

↑ *Back to this question in Part A*

@Neet_pg_bot

Q46: Calculate the GCS Score in an intubated patient, with findings of eye movements to pain and abnormal flexion? (Q857028)

A. E2VTM4

B. E2VTM3

C. E2VIM3

D. E2VNTM3

Correct Answer: D. E2VNTM3

Explanation: The GCS score for this patient is E2VNTM3. It is calculated as: Eye response (E): The patient opens their eyes to pain, so it's E2 . Verbal response (V): The patient is intubated, so the verbal response is not testable (NT), represented as VNT. Motor response (M): The patient exhibits abnormal flexion, which corresponds to M3. Thus, the overall GCS score for this patient is E2VNTM3. Glasgow Coma Scale: Glasgow coma scale Eye-opening Verbal (non-intubated) Verbal (intubated) Motor activity 4 Spontaneous 5 Oriented & talks 5 Seems able to talk 6 Verbal command 3 Verbal stimuli 4 Disoriented & talks 3 Questionable ability to talk 5 Localizes to pain 2 Painful stimuli 3 Inappropriate words 1 Generally unresponsive 4 Withdraws from pain 1 No response 2 Incomprehensible sounds 3 Decorticate/ Abnormal flexion 1 No response 2 Decerebrate/ Abnormal extension 1 No response Used to assess the level of consciousness in a patient with a head injury. Best total score: 15 Mild injury: 13 to 15 Moderate injury: 9 to 12 Severe injury: 3 to 8 GCS-P is calculated by subtracting the pupil reactivity score (PRS) from the GCS score (ranges from 15 to 1). GCS-P = GCS - PRS The GCS-P score uses a score of 8 or fewer to mean a coma. Pupil reactivity score: Pupils unreactive to light PRS Both pupils 2 One pupil 1 Neither pupil 0

References:

Harrison's Principles of Internal Medicine, 21st Edition, Page 2218

↑ *Back to this question in Part A*

@Neet_pg_bot

Q47: Which of the following arteries could have been involved in a patient who presents with vertigo, diplopia, hoarseness, dysphagia, left Horner's syndrome, and numbness in the left face and right side limbs? (Q856941)

A. Posterior inferior cerebellar artery

B. Superior cerebellar artery

C. Anterior inferior cerebellar artery

D. Basilar artery

Correct Answer: A. Posterior inferior cerebellar artery

Explanation: Wallenberg syndrome presents with pain, numbness, impaired sensation over one half of the face, horner syndrome, diplopia, numbness of the ipsilateral arm, trunk and leg. Occlusion of the posterior inferior cerebral artery is responsible for Wallenberg syndrome as it supplies the lateral medulla. Blood Supply of the Brain: The brain is primarily supplied by two systems: the anterior circulation from the internal carotid arteries and the posterior circulation from the vertebral arteries . These arteries anastomose to form the Circle of Willis , providing collateral circulation between the anterior and posterior blood supplies. {{caption_text}} 1. Internal Carotid Artery (ICA) Branches : Ophthalmic artery : Supplies the eye and orbital structures. Posterior communicating artery (PCoA) : Connects the internal carotid artery with the posterior cerebral artery. Anterior cerebral artery (ACA) : Supplies medial portions of the frontal and parietal lobes. Middle cerebral artery (MCA) : The largest branch, supplies the lateral aspect of the brain. Internal carotid artery occlusion can cause ischemia in MCA or ACA territory or a watershed (border zone) infarct between these areas. 2. Anterior Cerebral Artery (ACA) Supply : Medial portions of the frontal and parietal lobes, including the superior portion of the motor and sensory cortices (leg area). ACA Stroke : Contralateral weakness and sensory loss, primarily affecting the lower limb (leg > arm). Frontal lobe symptoms, including abulia (lack of initiative) and personality changes. Urinary incontinence due to damage to the medial frontal lobes. 3. Middle Cerebral Artery (MCA) Supply : Lateral surface of the frontal, parietal, and temporal lobes; basal ganglia; and internal capsule. MCA Stroke : Contralateral hemiparesis and hemisensory loss (face and arm > leg). Aphasia if the dominant hemisphere (usually left) is affected. Hemineglect if the non-dominant hemisphere is involved. Homonymous hemianopia due to optic radiation involvement. 4. Posterior Cerebral Artery (PCA) Supply : Occipital lobe (visual cortex), inferior temporal lobe, thalamus, and parts of the midbrain. PCA Stroke : Contralateral homonymous hemianopia (loss of the same side of the visual field in both eyes). Thalamic pain syndrome (Dejerine-Roussy syndrome) if the thalamus is involved, leading to contralateral sensory loss followed by chronic pain. Memory disturbances if the temporal lobe is affected. 5. Vertebral Arteries Branches : Posterior inferior cerebellar artery (PICA) : Supplies the cerebellum and lateral medulla. PICA Stroke : Wallenberg syndrome (lateral medullary syndrome): Causes ipsilateral facial numbness, contralateral body numbness, ataxia, vertigo, and dysphagia. 6. Basilar Artery (Option D) Supply : Pons, midbrain, occipital lobes, and cerebellum. Branches : Anterior inferior cerebellar artery (AICA) : Supplies the cerebellum and parts of the brainstem. Superior cerebellar artery (SCA) : Supplies the superior cerebellum and parts of the midbrain. Posterior cerebral arteries (PCA) : Terminal branches that supply the occipital lobe. Basilar Artery Stroke : Locked-in syndrome : Quadriplegia with preserved consciousness and vertical eye movements due to damage to the pons. Cranial nerve palsies (especially those involving eye movements like the oculomotor nerve). Ataxia , vertigo, and dysarthria due to cerebellar involvement. 7. Anterior Inferior Cerebellar Artery (AICA) (Option C) Supply : Anterior inferior portion of the cerebellum, the lateral pons, and parts of the internal auditory canal. AICA Stroke : Ipsilateral ataxia, vertigo, hearing loss (due to involvement of the inner ear via the labyrinthine artery), facial weakness, and contralateral sensory loss. 8. Superior Cerebellar Artery (SCA) (Option B) Supply : Superior part of the cerebellum and parts of the midbrain. SCA Stroke : Ipsilateral cerebellar ataxia, nausea, vomiting, and dysarthria. 9. Anterior Spinal Artery Supply : Anterior two-thirds of the spinal cord and parts of the medulla. Anterior Spinal Artery Syndrome : Medial medullary syndrome : Results in contralateral hemiparesis, loss of proprioception, and ipsilateral hypoglossal nerve dysfunction (tongue deviation).

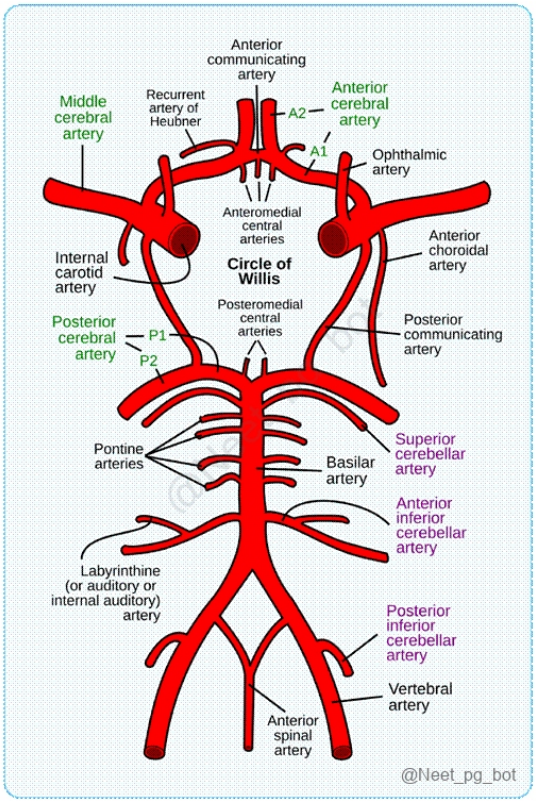

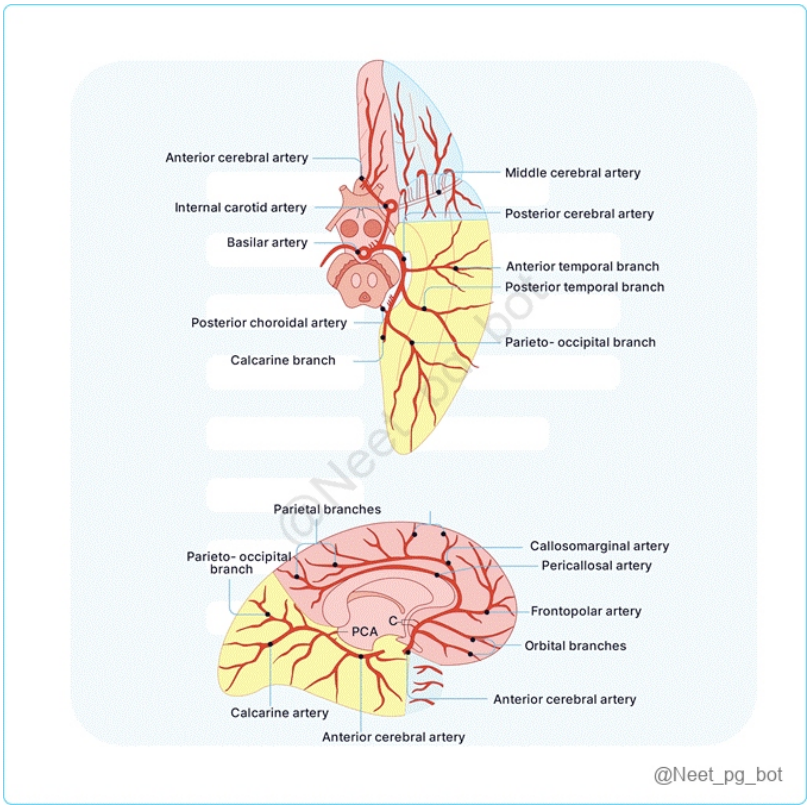

References:

Harrison’s Principles of Internal Medicine, 21st edition, Page 3324- 3335

https://www.ncbi.nlm.nih.gov/books/NBK534861/

↑ *Back to this question in Part A*

@Neet_pg_bot

Q48: Which of the following options has not been used as treatment for Guillain Barre syndrome? (Q856925)

A. Steroids

B. Plasmapheresis

C. IVIG

D. Ventilator support

Correct Answer: A. Steroids

Explanation: Glucocorticoids have not been found to be effective in the treatment of Guillain-Barre syndrome. Treatment of Guillain-Barre syndrome (GBS): Treatment Details IVIG (Option C) Treatment of choice (TOC) Plasmapheresis (Plex) (Option B) Equally effective as IVIG; use either Functional improvement may occur >1 week after treatment or show delayed response Monitoring Frequent assessment of maximal negative inspiratory force (NIF) and vital capacity determines need for ICU admission and ventilatory support (Option D) due to impending respiratory failure Rehabilitation Aggressive physical rehabilitation is imperative

References:

Harrison’s Principle of Internal Medicine, 21st edition, Page 3504

https://pmc.ncbi.nlm.nih.gov/articles/PMC4950094/

https://www.ncbi.nlm.nih.gov/books/NBK507717/

↑ *Back to this question in Part A*

@Neet_pg_bot

Q49: A 30-year-old man presented with excessive fatiguability towards the end of the day that improved with rest. He also gives a history of ptosis and difficulty in speech and swallowing. What is the most likely diagnosis? (Q856190)

A. Myasthenia gravis

B. Lambert-Eaton syndrome

C. Duchenne muscular dystrophy

D. Systemic lupus erythematosus

Correct Answer: A. Myasthenia gravis

Explanation: The clinical manifestations of excessive fatiguability towards the end of the day, ptosis and difficulty in speech and swallowing point to the diagnosis of myasthenia gravis . Clinical Features of Myasthenia Gravis Fatigable muscle weakness : Muscle strength decreases with continued use, especially: Later in the day After exercise No sensory or CNS involvement , distinguishing it from other neurological disorders. Common Initial Symptoms Ptosis (drooping eyelid) Diplopia (double vision) Weakness can spread to: Chewing, swallowing, and speaking muscles Limb muscles Muscle Weakness Patterns Affected Muscles Key Features Ocular muscles Mimics central eye movement disorders. Cogan's lid twitch sign The upper eyelid rises briefly after looking down for some time. Shoulder girdle muscles Difficulty in overhead activities like combing hair. Respiratory muscles Weakness may cause respiratory failure and aspiration risks. Ventilatory support : Essential for severe respiratory weakness. Ineffective coughing : Increases aspiration risk. Incorrect Options: Lamberton-Eaton syndrome (Option B) involves muscle weakness and autonomic dysfunctions like a dry mouth. The muscle weakness improves with use in contrast to myasthenia gravis. Duchenne muscular dystrophy (Option C) presents with weakness, difficulty in walking, fractures in ambulatory patients, lumbar lordosis, episodes of aspiration, nasal regurgitation, etc. The weakness does not improve on resting or exercise. It is also associated with intellectual disability and often presents in the first few years of life. Systemic lupus erythematosus (Option D) presents with a characteristic malar rash with musculoskeletal symptoms like joint pain with synovitis of more than 2 joints leading to deformities.

References:

Davidson’s Principles and Practice of Medicine, 24th Edition, Page: 1141, 1142, 1143.

Harrison’s Principles of Internal Medicine, 21st Edition, Page: 2740.

https://www.ncbi.nlm.nih.gov/books/NBK482346/

↑ *Back to this question in Part A*

@Neet_pg_bot

Q50: Patient came with fever headache and nuchal rigidity. LP shows gram negative diplococci in gram stain. Which of the following will be used for chemoprophylaxis in close contacts of a patient with meningococcal meningitis? (Q866451)

A. Amoxicillin

B. Doxycycline

C. Ethambutol

D. Rifampicin

Correct Answer: D. Rifampicin

Explanation: Rifampicin Rifampicin is the drug of choice for chemoprophylaxis of close contacts of patients with Neisseria meningitidis meningitis. It eradicates nasopharyngeal carriage and prevents secondary cases. Alternatives for those intolerant to rifampicin include ciprofloxacin (adults) and ceftriaxone (pregnancy). Amoxicillin (Option A): DOC for Listeria meningitis & used for certain bacterial infections, but ineffective for eradicating meningococcal carriage. Doxycycline (Option B): Tetracycline antibiotic, not used for meningococcal chemoprophylaxis. Ethambutol (Option C): Anti-tubercular drug, no role in meningococcal prophylaxis.

↑ *Back to this question in Part A*

@Neet_pg_bot

Q51: A patient had features of resting tremors, bradykinesia, and postural instability. He became bedridden and died due to respiratory failure. A brain biopsy is likely to show which of the following? (Q860433)

A. Lewy bodies

B. Hirano bodies

C. Guarneri bodies

D. Negri bodies

Correct Answer: A. Lewy bodies

Explanation: The clinical presentation of resting tremors, bradykinesia, and postural instability is characteristic of Parkinson's disease. Lewy bodies are the pathological hallmark of this condition, representing eosinophilic cytoplasmic inclusions containing both neurofilaments and α-synuclein . The disease is characterized by degeneration of dopaminergic neurons in the substantia nigra pars compacta , leading to reduced striatal dopamine. These pathological changes manifest as the classic motor symptoms seen in this patient. Pathophysiology of Parkinson’s Disease Initial Damage Damage to substantia nigra Consequence Loss of dopaminergic neurons in substantia nigra (pars compacta) Effect Decrease in dopamine production Autopsy findings Depigmentation of substantia nigra Microscopic findings Inclusion bodies called Lewy bodies Composition of Lewy Bodies Composed of α-synuclein (intracellular eosinophilic inclusions) Hirano bodies (Option B): These inclusions are typically observed in ALS and Parkinsonism-dementia complex, not in classic Parkinson's disease. Guarneri bodies (Option C): These are cytoplasmic inclusions found specifically in cells infected with smallpox or vaccinia virus. They have no association with movement disorders or neurological conditions like Parkinson's disease. Negri bodies (Option D) : These are eosinophilic cytoplasmic inclusions found in neurons infected with rabies virus, containing viral proteins and RNA. They are diagnostic of rabies infection.

References:

Harrison’s Principles of Internal Medicine, 21st Edition, Page 3392

↑ *Back to this question in Part A*

@Neet_pg_bot

Q52: Seizures are seen in what percentage of RTA patients with brain contusion/loss of consciousness? (Q860388)

A. Development of seizures in 17%

B. Development of seizures in 45%

C. Development of seizures in 75%

D. No relation between trauma and seizures

Correct Answer: A. Development of seizures in 17%

Explanation: Post-traumatic seizures occur in approximately 17% of patients with brain contusion , subdural hematoma, or prolonged loss of consciousness . Convulsions are uncommon immediately after traumatic brain injury, though brief tonic extensor posturing or clonic movements may occur at impact. Penetrating injuries carry a particularly high risk of subsequent epilepsy development. 45% (Option B) , 75% (Option C) & No relation (Option D) are incorrect values for seizures in RTA patients with brain contusion/loss of consciousness.

References:

Harrison's Principles of Internal Medicine, 20th Edition, Page 3118

↑ *Back to this question in Part A*

@Neet_pg_bot

Q53: What is the confirmatory test for the above condition? (Q844325)

A. CBNAAT of CSF

B. PET Scan

C. NMR Spectroscopy

D. MRI aerial scan

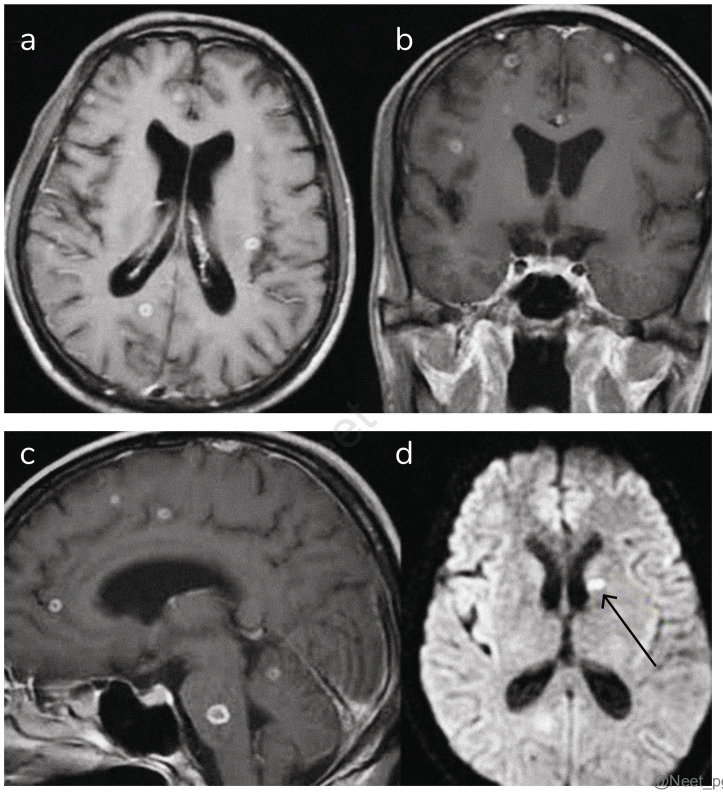

Correct Answer: C. NMR Spectroscopy

Explanation: Correct Option C - NMR Spectroscopy: When differentiating between tuberculoma and neurocysticercosis in cases of ring-enhancing lesions, NMR Spectroscopy (Nuclear Magnetic Resonance Spectroscopy) provides detailed metabolic and chemical information about the brain lesions. This technique can help differentiate between various types of lesions based on their biochemical signatures, making it valuable in distinguishing between tuberculomas (due to Mycobacterium tuberculosis) and neurocysticercosis (due to Taenia solium). NMR Spectroscopy analyzes the metabolic byproducts and chemical composition of the lesions, which can help in differentiating between conditions like tuberculoma and neurocysticercosis. It can provide information about the presence of specific metabolites and biochemical changes associated with each condition. Incorrect Options: Option A - CBNAAT of CSF: While CBNAAT is excellent for detecting Mycobacterium tuberculosis DNA and is very useful in diagnosing CNS tuberculosis, it is not typically used to distinguish between tuberculoma and neurocysticercosis directly. It confirms the presence of tuberculosis but does not provide biochemical information about the lesion itself. Option B - PET Scan: PET scans show metabolic activity in tissues and can be helpful in assessing lesions, but they do not provide detailed biochemical or chemical information specific to tuberculoma vs. neurocysticercosis. They are more used for overall lesion characterization rather than definitive diagnosis. Option D - MRI aerial scan: This term is not a standard diagnostic modality in clinical practice. MRI is used to visualize lesions and their characteristics but does not provide specific confirmation of tuberculoma or neurocysticercosis. It helps in lesion assessment but is not confirmatory for distinguishing between these two conditions.

References:

.

↑ *Back to this question in Part A*

@Neet_pg_bot

Q54: Patient is having a headache and confusion. A brain tumor diagnosis is made. Family history reveals brain and kidney tumors. Choose the correct option: (Q844242)

A. Neurofibromatosis

B. Li fraumeni syndrome

C. VHL Syndrome

D. Churg strauss syndrome

Correct Answer: C. VHL Syndrome

Explanation: Correct Option C - VHL syndrome: Von Hippel-Lindau (VHL) syndrome is a genetic condition characterized by the development of various tumors, including brain tumors (often hemangioblastomas), kidney tumors (renal cell carcinoma), and other tumors like pheochromocytomas. The family history of both brain and kidney tumors aligns with VHL syndrome. This condition is due to mutations in the VHL gene. Incorrect Options: Option A - Neurofibromatosis: Neurofibromatosis (NF) has two main types: NF1 and NF2. NF1 is associated with cutaneous neurofibromas, café-au-lait spots, and optic nerve tumors, while NF2 is associated with bilateral vestibular schwannomas (acoustic neuromas) and other central nervous system tumors. Although brain tumors are present, NF does not typically present with kidney tumors. Option B - Li-Fraumeni syndrome: Li-Fraumeni syndrome is a hereditary condition associated with a higher risk of several cancers, including breast cancer, sarcomas, brain tumors, and adrenal cortex tumors. While it is associated with brain tumors, it is not typically associated with kidney tumors. The syndrome is caused by mutations in the TP53 gene. Option D - Churg-Strauss syndrome: Churg-Strauss syndrome, now known as eosinophilic granulomatosis with polyangiitis (EGPA), is an autoimmune condition that affects small and medium-sized blood vessels. It primarily involves respiratory symptoms, asthma, and vasculitis, but it is not associated with brain and kidney tumors.

↑ *Back to this question in Part A*

@Neet_pg_bot

Q55: A 62-year-old patient presents with left-sided arm and leg weakness, right-sided facial paralysis, and difficulty with horizontal eye movements. Based on the clinical presentation, which of the following syndromes is most consistent with these symptoms? (Q844211)

A. Foville syndrome

B. Benedict's syndrome

C. Millard-Gubler syndrome

D. Wallenberg syndrome

Correct Answer: C. Millard-Gubler syndrome

Explanation: Millard-Gubler syndrome is caused by a ventral pontine lesion . Ipsilateral CN VI palsy → inability to abduct the eye Ipsilateral CN VII palsy → facial droop Contralateral hemiplegia → corticospinal tract involvement This “crossed” pattern of cranial nerve deficit on one side and limb weakness on the opposite side is characteristic. Foville syndrome(Option A): Pontine lesion affecting pontine tegmentum , may cause conjugate gaze palsy, not isolated CN VI/VII with contralateral hemiplegia. Benedict's syndrome (Option B): Midbrain lesion → ipsilateral CN III palsy + contralateral ataxia/tremor; CN VI/VII unaffected. Wallenberg syndrome (Option D): Lateral medulla lesion → sensory deficits, vertigo, dysphagia; no CN VI/VII palsy or contralateral hemiplegia.

References:

.

↑ *Back to this question in Part A*

@Neet_pg_bot

Q56: A 35-year-old woman presents with fluctuating muscle weakness, especially affecting her speech and swallowing. Repetitive nerve stimulation shows a decremental response. Her blood tests are negative for acetylcholine receptor (AChR) antibodies. Which of the following antibodies is most likely responsible for her symptoms? (Q852752)

A. Anti-dsDNA antibodies

B. Anti-MuSK antibodies

C. Anti-TPO antibodies

D. Anti-Ro antibodies

Correct Answer: B. Anti-MuSK antibodies

Explanation: MuSK is essential for clustering AChRs at the neuromuscular junction. Anti-MuSK antibodies are found in AChR-negative patients, often presenting with bulbar muscle weakness (affecting speech and swallowing). Autoantibodies in Myasthenia Gravis Myasthenia gravis is an autoimmune disorder characterized by muscle weakness due to disrupted neuromuscular transmission. Types of Autoantibodies Autoantibody Target Effects Associated Features AChR antibodies Acetylcholine receptors (AChR) on the postsynaptic membrane Blocks signal transmission, leading to muscle weakness Most common MuSK antibodies Muscle-specific kinase

(MuSK) Impairs AChR clustering and maintenance Found in AChR-negative patients; associated with bulbar muscle weakness (speech, swallowing, chewing issues) Diagnostic Tests Repetitive Nerve Stimulation : Shows a decremental response (decline in muscle activity with repeated stimulation), indicating faulty neuromuscular transmission. Blood Tests : Detect the presence of AChR and MuSK antibodies . Anti-dsDNA antibodies (Option A) : Seen in systemic lupus erythematosus (SLE) , not associated with neuromuscular transmission issues. Anti-TPO antibodies (Option C) : Linked with autoimmune thyroid disorders (e.g., Hashimoto's thyroiditis). Anti-Ro antibodies (Option D) : Found in Sjogren's syndrome and neonatal lupus , not relevant to myasthenia gravis.

References:

Davidson's Principles and Practice of Medicine, 24th Edition, Page 1141-1143

↑ *Back to this question in Part A*

@Neet_pg_bot

Q57: The CSF findings in bacterial meningitis would include which of the following? (Q852676)

A. Elevated protein and decreased glucose

B. Normal white blood cell count

C. Decreased protein and elevated glucose

D. Elevated WBC count with normal glucose

Correct Answer: A. Elevated protein and decreased glucose

Explanation: In bacterial meningitis , there is characteristic elevation of CSF protein due to blood-brain barrier disruption and decreased CSF glucose due to increased glucose utilization by bacteria and white blood cells. The typical CSF glucose level in bacterial meningitis is less than 40% of serum glucose. The protein elevation is typically marked, often greater than 100 mg/dL, reflecting significant inflammation and blood-brain barrier dysfunction . CSF Findings in various types of meningitis: Type Opening Pressure Predominant Cell Type Protein Glucose Gross Appearance Bacterial Meningitis Elevated Polymorphonuclear Neutrophils (PMNs) Elevated Decreased Turbid Fungal/Tubercular Meningitis Elevated Lymphocytes Elevated Decreased Straw-colored (TB meningitis) Viral Meningitis Normal or Slightly Elevated Lymphocytes Normal or Slightly Elevated Normal Normal or Turbid

References:

Harrison's Principles of Internal Medicine, 21st Edition, Page 975, 1104, 1105

Davidson's Principles and Practice of Medicine, 24th Edition, Page 1119, 1120

↑ *Back to this question in Part A*

Q58: In children with Guillain-Barré Syndrome (GBS), all are true except? (Q853356)

A. Areflexia of the affected limb is a mandatory diagnostic criteria

B. Plasmapheresis is not preferred in refractory cases

C. Intravenous immunoglobulin is the first line of management

D. Albuminocytological dissociation in CSF is characteristic

Correct Answer: B. Plasmapheresis is not preferred in refractory cases

Explanation: Plasmapheresis is actually preferred in refractory cases of Guillain-Barré Syndrome (GBS), especially when the condition does not improve after initial treatment with intravenous immunoglobulin (IVIG). The standard treatment for GBS involves the use of either IVIG or plasmapheresis, depending on the patient's condition and response to initial therapy. Guillain-Barré Syndrome (GBS) Guillain-Barré Syndrome (GBS) is a n acute autoimmune disorder that affects the peripheral nervous system . It often leads to ascending paralysis , starting from the lower limbs and spreading upwards. GBS is considered a neurological emergency due to its potential to cause respiratory failure, autonomic dysfunction, and death without timely treatment. Incidence: GBS occurs in 1–2 cases per 100,000 individuals annually. Preceding Infections: In about two-thirds of AIDP cases , a preceding infection triggers an autoimmune response. Common infections include: Campylobacter jejuni Cytomegalovirus (CMV) Epstein-Barr virus (EBV) Zika virus Influenza These infections lead to molecular mimicry , where the immune system attacks nerve structures , particularly the myelin sheath , causing demyelination. Variants of Guillain-Barré Syndrome: Variant Description Autoantibodies Acute Inflammatory Demyelinating Polyneuropathy (AIDP) Most common in Europe and North America, marked by segmental demyelination . IgG Anti-GM1 , IgG Anti-GQ1b Axonal Variants (AMAN/AMSAN) More prevalent in China and Japan, often linked with Campylobacter jejuni infection. IgG Anti-GM1 Miller Fisher Syndrome Characterized by a triad of ophthalmoplegia, ataxia, and areflexia , the best-recognized variant. Anti-GQ1b Autoantibodies in Guillain-Barré Syndrome: Diversity: GBS patients exhibit a range of autoantibodies targeting nerve cells and structures. Common Antibodies: The most common are anti-ganglioside antibodies , which appear in up to 50% of GBS cases . Prognostic Implications: The presence of anti-GM1 antibodies correlates with poorer clinical outcomes , especially in pure motor variants and Miller Fisher Syndrome . Clinical Features: Motor Symptoms Progressive ascending paralysis (distal to proximal) Areflexia Weakness in legs, causing rubbery legs and instability to stand Truncal paralysis, quadriplegia Difficulty handling secretions leading to aspiration pneumonia Diaphragmatic paralysis or bulbar palsy leading to respiratory failure within hours, Ventilatory support required in 30% of cases Sensory Symptoms Glove-and-stocking distribution paresthesias Loss of proprioception Pain in neck/shoulders similar to over-exercised muscles Autonomic Symptoms Orthostatic hypotension Wide fluctuations of blood pressure Arrhythmias Neurogenic shock Diagnostic Findings: Category Findings Lumbar Puncture Elevated CSF protein (100-1000 mg/dL) with normal WBC count (albuminocytologic dissociation) CSF Timing Normal findings (<48 hours), protein rise seen by 7 days Electrodiagnostic Testing Prolonged F-wave latencies, indicating demyelination (early in AIDP) Brighton Criteria for Diagnosis of GBS: Mnemonic: FAME F laccid Bilateral Weakness Areflexia (Option A) CytoAlbuminologic dissociation (Elevated CSF protein, normal WBC) (Option D) M onophasic Illness (Symptoms develop over 12 hours to 28 days) E lectrodiagnostic findings

consistent with demyelination Treatment: IVIG (Intravenous Immunoglobulin) (Option C): First-line treatment. It modulates the immune response and helps reduce inflammation. Plasmapheresis (Plasma Exchange): ■■■■■■■ Equally effective as IVIG. It removes harmful antibodies from the blood; preferred in refractory cases. Glucocorticoids: Not useful in GBS treatment, as they do not improve outcomes.

References:

Harrison's Principles of Internal Medicine, 21st Edition, Page 3504

↑ *Back to this question in Part A*

@Neet_pg_bot

Q59: LMN (Lower Motor Neuron) lesions are associated with which of the following? Decrease in muscle tone Spastic paralysis Babinski positive Fasciculations (Q853351)

A. 1, 2

B. 1, 4

C. 1, 2, 3, 4

D. 1, 2, 3

Correct Answer: B. 1, 4

Explanation: Lower Motor Neuron (LMN) lesions result from damage to the motor neurons in the anterior horn of the spinal cord or cranial nerve nuclei, leading to the following hallmark features. Decreased muscle tone (hypotonia) Fasciculations Muscle atrophy Absent Babinski reflex Absent or reduced reflexes (hyporeflexia) Flaccid paralysis UMN vs LMN lesion Category Upper Motor Neuron (UMN) Lesion Lower Motor Neuron (LMN) Lesion Lesion Location Motor cortex, connection from motor cortex to facial nucleus in pons Facial nucleus, anywhere along CN VII Affected Side Contralateral Ipsilateral Muscles Involved Lower muscles of facial expression Upper and lower muscles of facial expression Forehead Involvement Spared, due to bilateral UMN innervation Affected Other Symptoms Variable; depends on size of lesion Incomplete eye closure (dry eyes, corneal ulceration), hyperacusis, loss of taste on anterior tongue Motor Neuron Signs UMN Lesion LMN Lesion Weakness + + Atrophy - + Fasciculations - + Rigidity - + Reflexes ↑ ↓ Tone ↑ ↓ Babinski sign + - Spastic paresis + - Flaccid paralysis - + Clasp knife spasticity + -

References:

Harrison's Principles of Internal Medicine, 21st Edition, Pages 165, 166.

https://www.ncbi.nlm.nih.gov/books/NBK537305/

https://www.sciencedirect.com/topics/neuroscience/lower-motor-neuron-lesion

↑ *Back to this question in Part A*

@Neet_pg_bot

Q60: A patient presented with a blood pressure of 220/120 mmHg in an altered sensorium. He also had an episode of vomiting and a history of weakness on the left side of his body. Which of the following is incorrect regarding hypertensive management in this case? (Q853346)

A. In hemorrhagic stroke, reduce the BP to less than 160/100 mmHg with antihypertensives to prevent rebleed

B. In hemorrhagic stroke, aggressive use of IV antihypertensive if SBP > 220

C. In the ER, multiple blood pressure readings should be taken before starting antihypertensive therapy

D. In ischemic stroke, BP should be reduced to <140/90 mmHg immediately

Correct Answer: D. In ischemic stroke, BP should be reduced to <140/90 mmHg immediately

Explanation: In ischemic stroke, BP should not be reduced to <140/90 mmHg immediately. The correct management includes reducing the BP to <185/110 mmHg before administering thrombolytic therapy. Lowering BP too aggressively could compromise cerebral perfusion, potentially worsening the ischemia and increasing infarct size. Hemorrhagic Stroke: BP should be lowered to <160/100 mmHg with antihypertensives to reduce the risk of rebleeding (Option A). If SBP > 220 mmHg, aggressive use of IV antihypertensives is recommended (Option B). Ischemic Stroke: BP should only be reduced to <185/110 mmHg before thrombolysis. If the BP is above this threshold and thrombolysis is considered, lowering it is necessary, but a reduction to <140/90 mmHg can worsen cerebral perfusion. Emergency Management: In a hypertensive emergency, multiple BP readings should be taken to ensure accurate assessment before starting antihypertensive therapy (Option C). This is important to avoid over- or under-treatment.

References:

Harrison's Principles of Internal Medicine, 21st Edition, Pages 2086, 2087.

↑ *Back to this question in Part A*

@Neet_pg_bot

Q61: A patient presents with sudden-onset aphasia and right-sided arm weakness for the past 4 hours. After stabilizing the patient and confirming the diagnosis of ischemic stroke with urgent neuroimaging, which investigation is most appropriate to determine the etiology of this stroke? (Q866491)

A. Transthoracic echocardiography (TTE)

B. Carotid doppler

C. Transesophageal echocardiography (TEE)

D. MRI brain

Correct Answer: C. Transesophageal echocardiography (TEE)

Explanation: Sudden-onset neurological deficits in left MCA territory suggest acute ischemic stroke . Purpose of TEE: Identify cardioembolic sources , especially in young patients or non-lacunar strokes . It detects : Left atrial appendage thrombus Patent foramen ovale (PFO) / atrial septal defect (ASD) Valvular vegetations (endocarditis) Aortic arch atheroma Why TEE over TTE: Superior visualization of posterior cardiac structures, left atrial appendage, and aortic arch. Transthoracic echocardiography (Option A): Detects some cardiac sources but less sensitive than TEE for left atrial appendage or PFO. Carotid Doppler (Option B): Useful for carotid artery stenosis , more relevant in older patients; cardioembolic sources are more common in younger patients. MRI brain (Option D): Confirms diagnosis and location , but does not identify etiology .

References:

↑ *Back to this question in Part A*

@Neet_pg_bot

Q62: Patient came with severe headache and seizures. Sodium on admission was 98 meq/L. We have started correction with 3% saline and now after 24 hours of infusion sodium is 110 meq/L. Patient develops mutism and altered sensorium. Which investigation will you perform now? (Q866483)

A. MRI Head

B. LP for CSF biochemistry

C. Brainstem evoked potentials

D. EEG

Correct Answer: A. MRI Head

Explanation: MRI Head is done because this patient likely developed Osmotic Demyelination Syndrome (Central Pontine Myelinolysis) due to rapid correction of chronic hyponatremia . Safe correction: ≤ 8–10 mEq/L in 24 hours. Here, sodium increased by 12 mEq/L in 24 hrs → high risk of demyelination. Symptoms of ODS: mutism, quadriparesis, pseudobulbar palsy, altered consciousness. MRI brain is the investigation of choice LP for CSF biochemistry (Option B): Not useful; ODS is not an infectious/inflammatory process and CSF is typically normal. Brainstem evoked potentials (Option C): May detect conduction abnormalities but is not first-line for diagnosis.

EEG (Option D): May show nonspecific slowing in encephalopathy, but will not confirm ODS.

↑ *Back to this question in Part A*

@Neet_pg_bot

Q63: The patient is having the following hand movements. In which of the following conditions would this be seen? (Q860476)

A. Thyrotoxicosis

B. Hypercarbia

C. Hemiballismus

D. Hypoxia

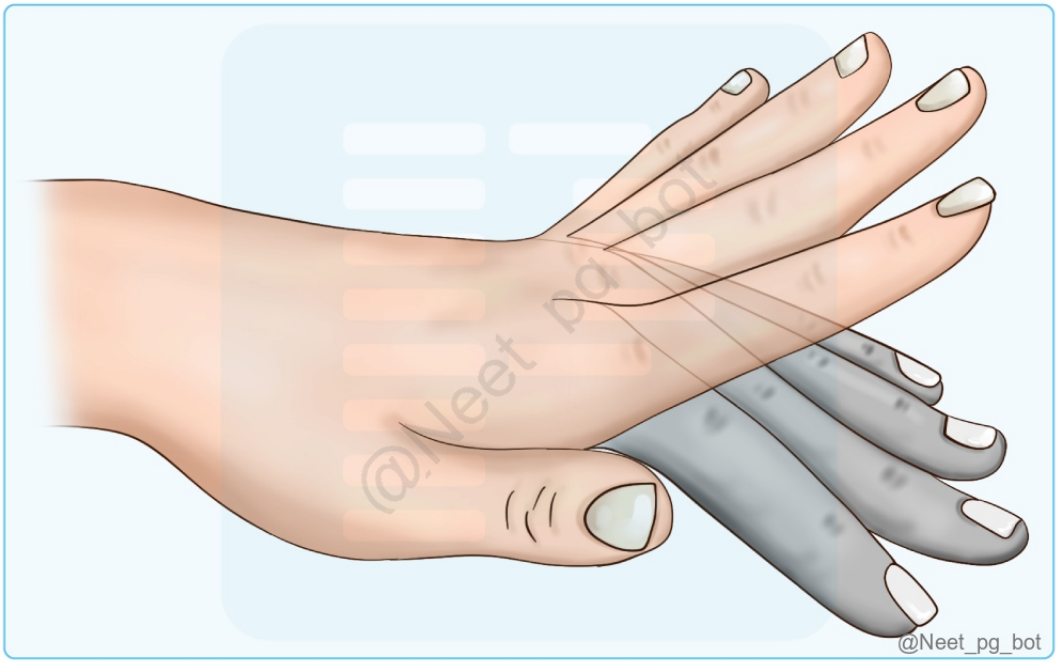

Correct Answer: B. Hypercarbia

Explanation: The typical hand movements shown in the image are known as asterixis or "flapping tremors. These characteristic hand movements are seen in patients of toxic-metabolic encephalopathy, potentially due to hypercarbia. The 3 causes of toxic-metabolic encephalopathy include: Hepatic encephalopathy (Increased level of ammonia) Uremic encephalopathy (Increased level of urea) Hypercarbia (Increased level of CO2) This condition occurs frequently in patients with chronic CO2 retention , particularly those receiving oxygen therapy for emphysema or chronic pulmonary disease. The flapping movement is elicited by having patients extend their arms and bend their wrists back. Thyrotoxicosis (Option A) presents with fine tremors. The tremor pattern is distinctly different from the coarse flapping movements seen in asterixis. Hemiballismus (Option C) manifests with wild,

flinging movements at the shoulder joint. These movements are abrupt and unilateral compared to the bilateral wrist movements seen in asterixis. Hypoxia (Option D) typically causes disorientation and mental status changes with O2 saturation <90%. While it can cause neurological symptoms, it does not specifically produce the characteristic flapping tremor seen in this case.

References:

https://www.ncbi.nlm.nih.gov/books/NBK535445/#:~:text=Definition%2FIntroduction,lapses%20during%20a%20sustained%20posture .

↑ *Back to this question in Part A*

@Neet_pg_bot

Q64: A 30-year-old female with seizures was prescribed carbamazepine & erythromycin. A few days later, she developed ataxia. What is the most likely cause of her symptoms? (Q865385)

A. Carbamazepine toxicity

B. Erythromycin toxicity

C. Worsening of the underlying disease

D. A separate, unrelated neurological condition

Correct Answer: A. Carbamazepine toxicity

Explanation: Erythromycin inhibits CYP3A4, the enzyme that metabolizes Carbamazepine , leading to elevated carbamazepine levels and resulting in toxicity, with ataxia being a common symptom. MOA: Inhibits high-frequency neuronal discharges and modulates voltage-gated sodium channels. Uses: Trigeminal neuralgia GTCS (generalized tonic clonic seizures) Partial seizures Bipolar disorder. Interactions: Metabolism of carbamazepine is induced by phenobarbitone, phenytoin, and vice versa. Erythromycin, fluoxetine, and isoniazid inhibit the metabolism of carbamazepine. (Option A) Adverse Effects Description Neurotoxicity Sedation, dizziness, vertigo, diplopia, and ataxia Gastrointestinal Effects Vomiting and diarrhoea occur with higher doses. Acute Intoxication Coma, convulsions, cardiovascular collapse. Haematological Agranulocytosis, aplastic anaemia. Hypersensitivity Reactions Rashes, photosensitivity, hepatitis, lupus-like syndrome. Water Retention and Hyponatremia Due to enhanced antidiuretic hormone (ADH) action, it is more common in the elderly. Teratogenicity Increased incidence of minor fetal malformations. Incorrect Options: Erythromycin toxicity (Option B) is not the cause, as it rarely causes ataxia. Its main role here is as a CYP3A4 inhibitor, which increases carbamazepine levels and leads to toxicity. Worsening of the underlying disease (Option C) can cause ataxia, but the timing after starting erythromycin points to a drug interaction, making this less likely. A separate, unrelated neurological condition (Option D) is unlikely, as the timing with carbamazepine and erythromycin use suggests a drug interaction rather than a new, unrelated diagnosis.

References:

K D Tripathi, Essentials of Medical Pharmacology, 8th Edition, Page 442.

↑ *Back to this question in Part A*

@Neet_pg_bot

Q65: Which of the following statements about Multiple Sclerosis (MS) is incorrect? (Q865373)

A. 70% of patients with MS develop optic neuritis during course of illness

B. Oral steroids are given for acute relapses

C. Loss of color perception and depth perception is proportional to visual loss

D. Examination of fundus can be normal and can show papillitis

Correct Answer: C. Loss of color perception and depth perception is proportional to visual loss

Explanation: In optic neuritis (often seen in MS), color vision (especially red) and depth perception can be disproportionately affected compared to overall visual acuity. A patient may have mild visual acuity loss but significant dyschromatopsia (color desaturation) or depth perception difficulties . Multiple sclerosis (MS) Clinical features: Abrupt or insidious onset of symptoms Sensory symptoms Paresthesias: tingling, prickling sensations, “pins and needles,” or painful burning. Hypesthesia: reduced sensation, numbness, or a “dead” feeling. Unpleasant sensations: feelings that body parts are swollen, wet, raw, or tightly wrapped. Pain is a common symptom of MS. Optic neuritis (ON) Diminished visual acuity. Decreased colour perception in the central field of vision. May progress to severe visual loss. Periorbital pain. Fundoscopic examination: normal or optic disc swelling (papillitis), pallor of the optic disc (optic atrophy). Weakness of the limbs Loss of strength, speed, dexterity, and gait disturbance. Exercise-induced weakness is a characteristic symptom of MS. Upper motor neuron type weakness accompanied by other pyramidal signs. Facial weakness Lesion in the pons may resemble idiopathic Bell’s palsy. Spasticity Spontaneous and movement-induced muscle spasms. Painful spasms. Visual blurring Due to ON (optic neuritis) or diplopia. Diplopia is caused by internuclear ophthalmoplegia (INO) or palsy of the sixth cranial nerve. Bilateral INO is particularly suggestive of MS. Other gaze disturbances in MS: Horizontal gaze palsy One-and-a-half syndrome (horizontal gaze palsy plus an INO) Acquired pendular nystagmus Ataxia Cerebellar tremors. Cerebellar dysarthria. Vertigo Lesion in the brainstem. Ancillary symptoms Paroxysmal symptoms Brief duration (10s to 2 min), high frequency (5–40 episodes per day), no change of consciousness or change in background electroencephalogram during episodes, and a self-limited course. Lhermitte’s symptom An electric shock-like sensation that radiates down the back into the legs. Typically induced by flexion or other movements of the neck. Trigeminal neuralgia, hemifacial spasm, and glossopharyngeal neuralgia Demyelinating lesions involve the root entry or exit zone of the fifth, seventh, and ninth cranial nerve, respectively. Facial myokymia Persistent rapid flickering contractions of the facial musculature Slow spread of contraction across the face. Heat sensitivity Uthoff symptoms: Neurological symptoms develop from heat exposure, such as steam baths and saunas. Bladder dysfunction Present in >90% of MS patients. Detrusor hyperreflexia. Detrusor sphincter dyssynergia - hesitancy, urinary retention, overflow incontinence, and recurrent infection. Bowel dysfunction Constipation, faecal urgency or bowel incontinence. Cognitive dysfunction Memory loss. Impaired attention. Psychiatric symptom Depression. Fatigue 90% of patients experience fatigue. It causes work-related disability. Incorrect Options: 70% of patients

with MS develop optic neuritis during course of illness (Option A): Optic neuritis is a common presenting symptom and complication of MS. Around 70% of patients develop it at some point during the disease. It often causes painful vision loss, especially on eye movement. Oral steroids are given for acute relapses (Option B): High-dose intravenous steroids (e.g., methylprednisolone) are preferred for acute relapses, but oral steroids (like oral prednisolone or tapering doses after IV) can also be used in certain cases. So, oral steroids are indeed part of acute relapse management, especially during recovery or tapering phases. Examination of fundus can be normal and can show papillitis (Option D): In optic neuritis, retrobulbar neuritis often shows a normal fundus because the inflammation is behind the globe. However, in some cases, papillitis (optic disc swelling) may be seen. Both scenarios are possible in MS-related optic neuritis.

References:

Harrison’s Principle of Internal Medicine, 21st Edition, Page 3462, 3463, 3468-3474.

↑ *Back to this question in Part A*

@Neet_pg_bot

Q66: A 65-year-old known case of Parkinson's disease presents with oropharyngeal dysphagia and recurrent episodes of aspiration pneumonitis, complaints of excessive respiratory secretions. Chest imaging reveals bilateral bronchiectasis. What is the most appropriate long-term management for this patient? (Q865367)

A. High-frequency chest wall oscillation therapy

B. Nebulized N-acetylcysteine (NAC) to reduce secretions

C. PEG tube placement

D. Macrolide therapy

Correct Answer: C. PEG tube placement

Explanation: In Parkinson's disease, oropharyngeal dysphagia is common due to impaired coordination of swallowing muscles. This leads to aspiration of food, liquids, and saliva, resulting in recurrent pneumonitis and long-term complications like bronchiectasis . PEG (Percutaneous Endoscopic Gastrostomy) tube helps bypass the oropharyngeal route for nutrition, reducing the risk of aspiration pneumonia and supporting nutritional status. It serves as a long-term management strategy that directly addresses the underlying cause—oropharyngeal dysfunction and aspiration. Incorrect Options: High-frequency chest wall oscillation therapy (Option A) is useful in conditions like cystic fibrosis or bronchiectasis to help clear mucus, but it does not address aspiration or dysphagia, which are the primary issues in this patient. Nebulized N-acetylcysteine (NAC) (Option B) may help thin mucus, but it can irritate the airways and potentially increase secretions, without addressing the core problem of aspiration. Macrolide therapy (Option D) can be used in non-CF bronchiectasis for its anti-inflammatory effects; however, it targets only secondary inflammation and not the primary issue of aspiration.

References:

Percutaneous Transesophageal Gastro■Tubing as an Alternative Procedure of Levodopa Administration in Parkinson's Disease - PMC

↑ *Back to this question in Part A*

@Neet_pg_bot

Q67: A 20-year-old male presents with severe headache, vomiting & photophobia. On examination, neck rigidity and Brudzinski's sign are positive. A CT scan of the brain shows hydrocephalus and no haemorrhage. CSF examination is normal. What is the most likely diagnosis? (Q865322)

A. Normal Pressure Hydrocephalus

B. Bacterial Meningitis

C. Viral Encephalitis

D. Subarachnoid Haemorrhage

Correct Answer: D. Subarachnoid Haemorrhage

Explanation: SAH often presents with sudden severe headache, vomiting, photophobia, and meningeal signs. CT may miss early or small bleeds, and CSF can be normal if bleeding is minimal or delayed. Hydrocephalus suggests impaired CSF drainage due to subarachnoid blood. Subarachnoid hemorrhage Subarachnoid Hemorrhage (SAH): Blood accumulation in the subarachnoid space. Causes: Often due to aneurysm rupture (~85%) or trauma . Non-traumatic SAH is most commonly caused by the rupture of a saccular aneurysm . Clinical Impact: High mortality and morbidity; often presents with a sudden, severe headache (worst headache of life). Complications: Seizures, vasospasm, hydrocephalus, and delayed cerebral ischemia (DCI). Epidemiology: Age/ Gender: Most of the SAH occurs between age of 40-60, mean rupture age 50-55 and slightly more prevalent in females. Risk Factors: Smoking and history of ruptured aneurysms increase SAH risk. Etiology: Aneurysmal SAH (aSAH): Risk Factors: Hypertension , smoking , family history, alcohol use, sympathomimetic drugs , and estrogen deficiency . Rupture Risk: (Option D) Age >60 Posterior circulation aneurysms Atherosclerosis Aneurysm size Aneurysms <10 mm: ~0.1% annual rupture risk. Aneurysms ≥10 mm: 0.5–1% annual rupture risk. Giant aneurysms (>2.5 cm): ~6% rupture risk in first year. Family history Previous SAH ADPKD Nonaneurysmal SAH (NASAH): Perimesencephalic NASAH : Localized blood in perimesencephalic cisterns, normal angiography, benign course. Occult Aneurysm : Small aneurysms missed on initial angiography, detectable on repeat imaging. Vascular Malformations: Includes arteriovenous malformations (AVM) and dural arteriovenous fistulae. Treated with surgery or endovascular interventions. Intracranial Arterial Dissection: Diagnosed by angiography, causes severe bleeding, treated with surgery or endovascular methods. Other Causes: Cocaine abuse, cerebral amyloid angiopathy, cerebral venous thrombosis, sickle cell disorders, moyamoya disease, cerebral vasculitis, bleeding disorders. Pathophysiology: Hemodynamic Stress : Central to intracranial aneurysm formation, especially at arterial bifurcations. Aneurysm Rupture: Causes neurological damage through compression of adjacent brain tissue and ischemia from reduced blood flow. Mechanisms: Hemodynamic stress and inflammation (matrix metalloproteinase (MMP)-mediated degradation of extracellular matrix) weaken the arterial wall, promoting

aneurysm formation and rupture. Inflammatory Response: Macrophages and smooth muscle cells drive these degenerative processes. Clinical features: Sudden, severe "thunderclap" headache (hallmark) Loss of consciousness: Increase in intracranial pressure. It presses the reticular activating system. Leads to the development of stupor and coma. Worst headache of the life Nuchal rigidity is due to blood but no fever. Vomiting Sentinel bleed: microbleeds from the berry Aneurysm Investigations: Non-contrast CT head: "Hyperdense" blood in the subarachnoid space ("SAH star") Lumbar puncture: Xanthochromia (yellowish discoloration) of CSF after 12 hours Cerebral angiography: Identifies aneurysms or AVMs CT angiography or MR angiography: Non-invasive methods to detect vascular abnormalities Incorrect Options: Normal Pressure Hydrocephalus (NPH) (Option A): Presents with triad: dementia, gait disturbance, urinary incontinence—not acute meningeal symptoms. Bacterial Meningitis (Option B): Would show abnormal CSF: high protein, low glucose, and neutrophilic pleocytosis. Viral Encephalitis (Option C): Presents with altered sensorium, seizures, and abnormal CSF (lymphocytic pleocytosis), not just headache and normal CSF.

References:

Harrison's Principles of Internal Medicine 21st Edition, Page 3353, 3354

↑ *Back to this question in Part A*

@Neet_pg_bot

Q68: Which of the following is one of the earliest presenting symptoms in a patient with Multiple Sclerosis? (Q865298)

A. Sensory disturbances

B. Ataxia

C. Vertigo

D. Facial palsy

Correct Answer: A. Sensory disturbances

Explanation: Sensory disturbances such as paresthesias (tingling, “pins and needles”), hypesthesia (numbness), and dysesthetic sensations (e.g., burning, swelling, tight wrapping) are among the most common and earliest symptoms in MS. They reflect demyelination in the sensory pathways and can appear abruptly or insidiously. Multiple sclerosis (MS) Clinical features: Abrupt or insidious onset of symptoms Sensory symptoms Paresthesias: tingling, prickling sensations, “pins and needles,” or painful burning. Hypesthesia: reduced sensation, numbness, or a “dead” feeling. Unpleasant sensations: feelings that body parts are swollen, wet, raw, or tightly wrapped. Pain is a common symptom of MS. Optic neuritis (ON) (Option C ruled out) Diminished visual acuity. Decreased colour perception in the central field of vision. May progress to severe visual loss. Periorbital pain. Fundoscopic examination: normal or optic disc swelling (papillitis), pallor of the optic disc (optic atrophy). Weakness of the limbs Loss of strength, speed, dexterity, and gait disturbance. Exercise-induced weakness is a characteristic symptom of MS. Upper motor neuron type weakness accompanied by other pyramidal signs. Facial weakness Lesion in the pons may resemble idiopathic Bell’s palsy. Spasticity Spontaneous and movement-induced muscle

spasms. Painful spasms. Visual blurring Due to ON (optic neuritis) or diplopia. Diplopia is caused by internuclear ophthalmoplegia (INO) or palsy of the sixth cranial nerve. (Option D ruled out) Bilateral INO is particularly suggestive of MS. Other gaze disturbances in MS: Horizontal gaze palsy One-and-a-half syndrome (horizontal gaze palsy plus an INO) Acquired pendular nystagmus Ataxia Cerebellar tremors. Cerebellar dysarthria. Vertigo Lesion in the brainstem. Ancillary symptoms Paroxysmal symptoms Brief duration (10s to 2 min), high frequency (5–40 episodes per day), no change of consciousness or change in background electroencephalogram during episodes, and a self-limited course. Lhermitte's symptom (Option A ruled out) An electric shock-like sensation that radiates down the back into the legs. Typically induced by flexion or other movements of the neck. Trigeminal neuralgia, hemifacial spasm, and glossopharyngeal neuralgia Demyelinating lesions involve the root entry or exit zone of the fifth, seventh, and ninth cranial nerve, respectively. Facial myokymia Persistent rapid flickering contractions of the facial musculature Slow spread of contraction across the face. Heat sensitivity Uthoff symptoms: Neurological symptoms develop from heat exposure, such as steam baths and saunas. Bladder dysfunction Present in >90% of MS patients. Detrusor hyperreflexia. Detrusor sphincter dyssynergia - hesitancy, urinary retention, overflow incontinence, and recurrent infection. Bowel dysfunction Constipation, faecal urgency or bowel incontinence. Cognitive dysfunction Memory loss. Impaired attention. Psychiatric symptom Depression. Fatigue 90% of patients experience fatigue. It causes work-related disability. Incorrect Options: Ataxia (Option B): Usually appears later due to cerebellar involvement, not a common early symptom. Vertigo (Option C): Caused by brainstem lesions, but not an early presenting symptom in MS. Facial palsy (Option D): Results from pontine lesions, but is rare as an initial symptom.

References:

Harrison's Principle of Internal Medicine, 21st Edition, Page: 3462, 3463.

↑ *Back to this question in Part A*

@Neet_pg_bot

Q69: A patient presents with contralateral face, arm, and leg weakness. NCCT shows intracerebral hemorrhage (ICH). What is the most likely location of the CNS bleed? (Q866823)

A. Basal ganglia

B. Midbrain

C. Pons

D. Medulla

Correct Answer: A. Basal ganglia

Explanation: Intracerebral hemorrhages causing contralateral hemiparesis (weakness of face, arm, and leg) most commonly occur in the basal ganglia , especially the putamen. The basal ganglia hemorrhage compresses the internal capsule where corticospinal fibers run, causing dense contralateral motor deficits. Incorrect Options: Midbrain (Option B): Lesions here often cause oculomotor nerve palsy and contralateral weakness but are less

common sites for primary ICH. Pons (Option C): Hemorrhages can cause "locked-in" syndrome or quadriplegia, often accompanied by cranial nerve signs, but less isolated hemiparesis. Medulla (Option D): Hemorrhages here are rare; symptoms include contralateral limb weakness with ipsilateral cranial nerve deficits (Wallenberg syndrome) but not classic hemiparesis alone.



@Neet_pg_bot

References:

.

↑ *Back to this question in Part A*

@Neet_pg_bot

Q70: The infant is being evaluated for recurrent episodes of seizures. ECG shows Hypsarrhythmia. Which drug is preferred for management? (Q866822)

A. ACTH

B. Vigabatrin

C. Valproate

D. Carbamazepine

Correct Answer: A. ACTH

Explanation: Hypsarrhythmia on EEG is characteristic of infantile spasms (West syndrome) , a severe epileptic encephalopathy in infants. The first-line treatment is adrenocorticotropic hormone (ACTH) , which helps reduce spasms and improve developmental outcomes. Incorrect Options: Vigabatrin (Option B): Also effective, especially in infantile spasms associated with tuberous sclerosis, but ACTH remains the preferred initial therapy in most cases. Valproate (Option C): Used for other seizure types, but less effective for infantile spasms. Carbamazepine (Option D): Not effective and may worsen infantile spasms.

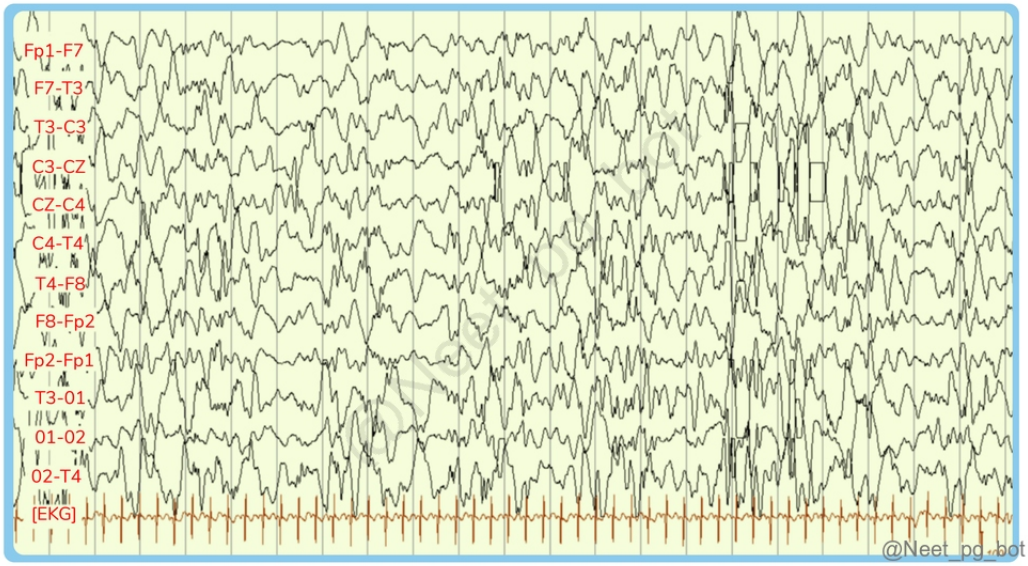

References:

.

↑ *Back to this question in Part A*

@Neet_pg_bot

Q71: A patient had a road traffic accident (RTA). NCCT head was normal on admission. The patient later died after several days in the ICU due to coma. Brain biopsy revealed multiple punctate hemorrhages. What is the diagnosis? (Q866814)

A. Ischemic injury

B. Diffuse axonal injury

C. Intraventricular bleeding

D. Subdural hemorrhage

Correct Answer: B. Diffuse axonal injury

Explanation: Diffuse axonal injury is a primary brain injury caused by shearing forces during high-velocity trauma (e.g., RTA). These forces disrupt axons in the white matter , corpus callosum, and brainstem. On initial imaging, NCCT may be normal or show only tiny petechial hemorrhages ; the condition is often diagnosed clinically or via MRI . Histopathology (or biopsy) reveals multiple punctate hemorrhages in deep white matter tracts. DAI often leads to immediate or prolonged coma without a lucid interval and carries a high mortality rate. Incorrect Options: Ischemic injury (Option A): Usually presents with territorial infarcts and hypoxic changes, not punctate hemorrhages in white matter. Intraventricular bleeding (Option C): Would be evident on CT and localized to ventricular system, not diffuse white matter punctate hemorrhages. Subdural hemorrhage (Option D): Characterized by crescent-shaped collection on CT, caused by tearing of bridging veins — not microscopic hemorrhages.

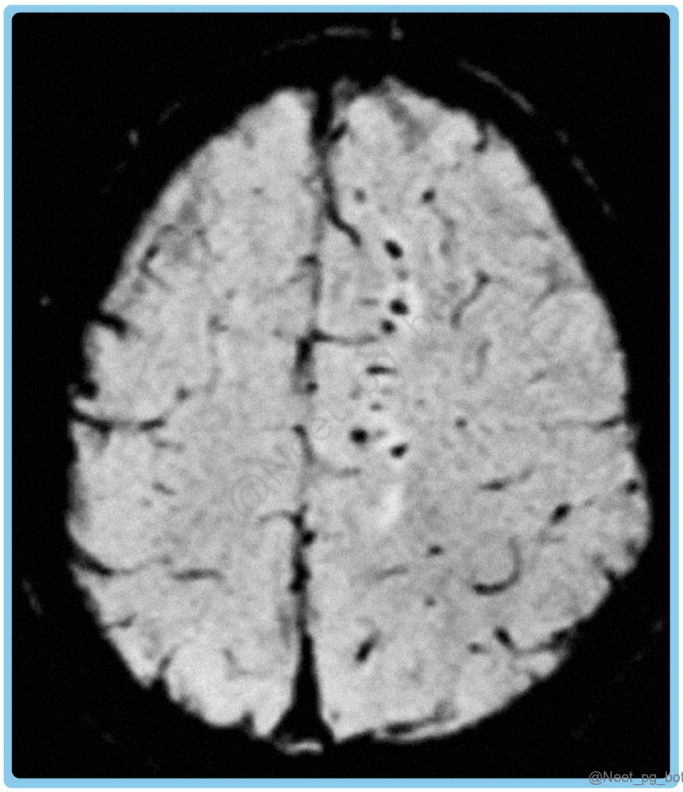

References:

.

↑ *Back to this question in Part A*

@Neet_pg_bot

Q72: What is the probable diagnosis for a patient who exhibits miosis, anhidrosis, mild ptosis, and a persistent small pupil even in low light conditions? (Q866808)

A. Adie’s tonic people

B. Horner syndrome

C. Marcus Gunn pupil

D. Argyll Robertson pupil

Correct Answer: B. Horner syndrome

Explanation: The clinical presentation of miosis, anhidrosis, mild ptosis, and a persistent small pupil even in low light is suggestive of Horner syndrome. Ptosis is a result of the weakness of Müller muscle and miosis due to the unopposed action of the sphincter pupillae with resultant anisocoria. Pancoast tumor can compress the sympathetic nerves, leading to the classic triad of symptoms seen in Horner syndrome: ptosis, miosis (constricted pupil), and ipsilateral facial anhidrosis (lack of sweating). Acquired Neurogenic Ptosis: Acquired ptosis with drooping of the upper eyelid caused by a disruption in the nerve supply to the muscles responsible for elevating the eyelid. Causes: Third Cranial (Oculomotor) Nerve Palsy: The third nerve can be damaged by trauma, ischemia, infection, tumor, or compression, causing ptosis and diplopia.Oculomotor nerve palsy causes ptosis as it supplies the levator palpebrae superioris muscle. The ptotic eyelid can be elevated with a frontalis sling or levator aponeurosis advancement. Horner's Syndrome: Involves a lesion in the sympathetic pathway , affecting the Müller’s muscle, leading to mild ptosis accompanied by miosis (pupil constriction) and anhidrosis (loss of sweating). Ophthalmoplegic migraine Multiple Sclerosis Diagnosis: Topical apraclonidine test is now considered the test of choice. Apraclonidine is an alpha-2 adrenergic agonist that also acts as a very weak alpha 1-adrenergic agonist; when topically applied in Horner’s syndrome, it causes dilation of the affected pupil and possibly lid elevation, without change to the normal pupil. Incorrect Options: Adie’s tonic people (Option A) It is a unilateral condition and is characterized by anisocoria (different size of pupil) and direct light reflex is sluggish or absent. Marcus gunn pupil (Option C) Aka relative afferent pupillary defect is characterized by paradoxical dilatation of both the pupil when light is flashed on the diseased eye. Argyll Robertson pupil (Option D) It is a specific sign of late-stage syphilis. The bilaterally small pupils do not constrict when exposed to bright light.

↑ *Back to this question in Part A*

@Neet_pg_bot

Q73: A 30-year-old male presents with deep-seated retro-orbital pain of cluster headache. What is the best management? (Q866802)

A. Verapamil

B. Oxygen

C. Lithium

D. Topiramate

Correct Answer: B. Oxygen

Explanation: High-flow 100% oxygen is the most effective acute abortive therapy for cluster headaches, rapidly relieving pain within 15–20 minutes in most cases. It is safe, well-tolerated, and works faster than most medications. Cluster headaches are severe unilateral headaches with autonomic features. Acute attacks require rapid-acting treatment — high-flow oxygen via a non-rebreather mask or subcutaneous sumatriptan are first-line. Oxygen relieves pain by causing vasoconstriction and possibly modulating trigeminal-autonomic reflexes. Prophylaxis (e.g., verapamil, lithium) is started later to prevent recurrences, but during an acute attack, oxygen is the gold standard. Cluster Headache: Feature Cluster Headache Pain Severe, unilateral, retro-orbital/temporal Duration 15–180 minutes per attack Frequency Up to 8/day during cluster periods Autonomic signs Lacrimation, conjunctival injection, nasal congestion, ptosis, miosis Triggers Alcohol, histamine, nitroglycerin during cluster period Acute treatment 100% O■ (12–15 L/min), subcutaneous sumatriptan Prophylaxis Verapamil (drug of choice), lithium, topiramate Incorrect Options: Verapamil (Option A): Used for prophylaxis, not acute attack. Lithium (Option C): Alternative prophylactic agent in refractory cases. Topiramate (Option D): Used in prophylaxis for migraine and sometimes cluster headache, not acute management.

↑ *Back to this question in Part A*

@Neet_pg_bot

Q74: A patient presents with symmetrical leg weakness and areflexia. He had developed diarrhoea 2 weeks ago. He was diagnosed as having GBS. What is the cause? (Q866792)

A. Demyelination of A, B-fibers

B. Demyelination of B-fibers

C. Demyelination of the spinal cord

D. Cord inflammation

Correct Answer: A. Demyelination of A, B-fibers

Explanation: Guillain–Barré Syndrome (GBS) is an acute immune-mediated polyneuropathy, most often triggered by infections like Campylobacter jejuni. It primarily affects myelinated large-diameter motor and sensory fibers (A and B fibers) , leading to weakness and areflexia. A- and B-fibers are myelinated nerve fibers responsible for motor function and some sensory modalities. In GBS, autoantibodies and immune cells attack the myelin sheath, impairing conduction. This demyelination disrupts both motor signals (causing weakness) and reflex arcs (causing areflexia). Guillain–Barré Syndrome: Trigger: Often post-infectious (e.g., Campylobacter jejuni, CMV, EBV, Mycoplasma). Pathophysiology: Autoimmune-mediated demyelination of peripheral nerves and nerve roots. Clinical features: Symmetrical ascending weakness, areflexia, minimal sensory loss; may involve cranial nerves (bilateral facial palsy). Complications: Respiratory muscle involvement → respiratory failure; autonomic instability. Diagnosis: CSF shows albuminocytologic dissociation (↑ protein, normal cell count); NCS shows slowed conduction velocity. Treatment : IVIG or plasmapheresis; avoid steroids. Prognosis: Most recover fully, but some have residual deficits. Fiber types affected in GBS: Fiber Type Myelination Function A fibers Myelinated Motor + sensory B fibers Myelinated Preganglionic autonomic C fibers Unmyelinated Pain +

temperature Incorrect Options: Demyelination of B-fibers (Option B) – B-fibers are affected, but not in isolation; A-fibers are also involved. Demyelination of the spinal cord (Option C) – GBS is a peripheral neuropathy, not a central spinal cord disorder. Cord inflammation (Option D) – Suggestive of myelitis, which presents with UMN signs and sensory level, not typical in GBS.

↑ *Back to this question in Part A*

@Neet_pg_bot

Q75: A 35-year-old female with progressive limb weakness for the past 1 year. On examination, muscle fasciculations and hypertonia are noted, and the sensory system is intact. What is the diagnosis? (Q866791)

A. ALS

B. Spinal muscular atrophy

C. Multifocal motor neuropathy

D. Becker muscular dystrophy

Correct Answer: A. ALS

Explanation: ALS is a progressive neurodegenerative disorder involving both upper motor neurons (UMN) and lower motor neurons (LMN) , leading to weakness, hypertonia, and fasciculations, while sparing the sensory system. The presence of UMN signs (hypertonia) and LMN signs (fasciculations) together is characteristic. ALS affects motor neurons in the motor cortex, brainstem, and spinal cord. UMN involvement → spasticity, hyperreflexia LMN involvement → muscle atrophy, fasciculations, weakness. Sensory pathways are usually preserved, helping differentiate from other neuropathies. Onset is insidious and relentlessly progressive, leading to respiratory failure. ALS: Epidemiology: Usually presents in middle age; more common in men. Pathophysiology: Degeneration of corticospinal tracts (UMN) and anterior horn cells (LMN). Clinical features : Combination of UMN + LMN signs in multiple regions, no sensory loss. Diagnosis: Clinical (exclusion of mimics), EMG shows denervation and reinnervation. Prognosis: Progressive; most patients die within 3–5 years from respiratory failure. Treatment: Riluzole (glutamate inhibitor) modestly prolongs survival; supportive care is key. LMN and UMN signs in ALS: Feature UMN signs LMN signs Tone Spasticity Hypotonia Reflexes Hyperreflexia, Babinski+ Hyporeflexia Muscle bulk Normal initially Atrophy Fasciculations Rare Common Incorrect Options: Spinal muscular atrophy (Option B) – Pure LMN disease; no UMN signs like hypertonia. Multifocal motor neuropathy (Option C) – Pure LMN weakness, usually asymmetric, often with conduction block on nerve studies. Becker muscular dystrophy (Option D) – Genetic myopathy with proximal weakness, no UMN signs or fasciculations, and onset typically in adolescence or early adulthood.

↑ *Back to this question in Part A*

@Neet_pg_bot

Q76: A 60 year old man present with sudden onset of right sided hemiparesis for last 3 hours. BP is 200/100 mmHg. NCCT Head showed brain bleed and right hemiparesis. All of the following are to be done for management, Except? (Q820357)

A. Thrombolysis

B. BP Control

C. Edema management

D. Elective hyperventilation

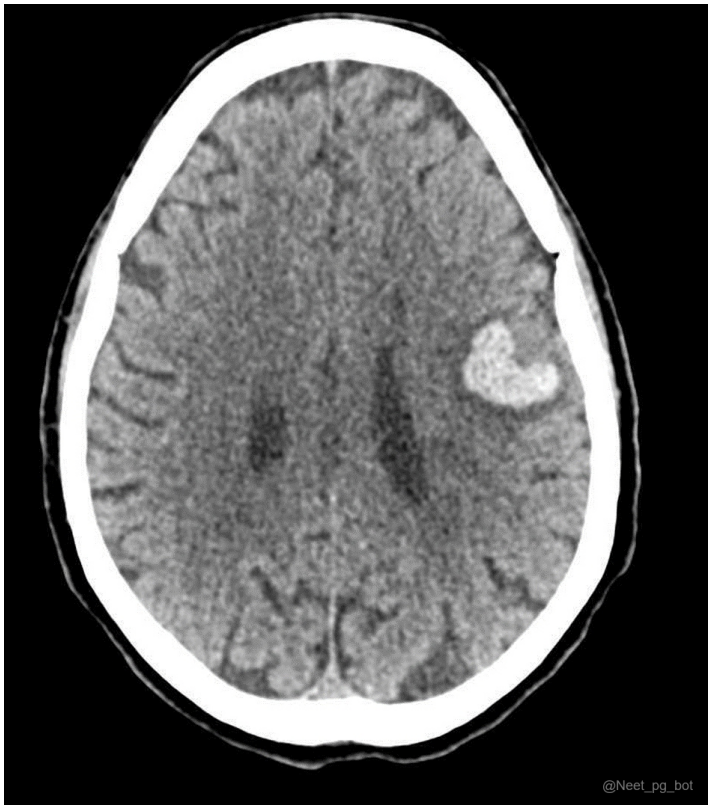

Correct Answer: A. Thrombolysis

Explanation: Correct Option A - Thrombolysis: Thrombolysis, also known as clot-busting therapy, involves administering medications to dissolve blood clots. It is typically used in the treatment of ischemic strokes (caused by a blood clot blocking a blood vessel in the brain). However, in this case, the patient's presentation and brain imaging findings suggest a hemorrhagic stroke, which is characterized by bleeding into the brain tissue. Administering thrombolytic therapy in a hemorrhagic stroke could exacerbate the bleeding and worsen the patient's condition, which is why thrombolysis is contraindicated in this scenario. Incorrect Options: Option B - BP Control: High blood pressure (hypertension) is a risk factor for both ischemic and hemorrhagic strokes. In the context of a hemorrhagic stroke, controlling blood pressure is crucial to prevent further bleeding and manage the patient's overall condition. So, BP control is an essential part of the management. Option C - Edema Management:

Brain edema (swelling) can occur following a stroke, and it can lead to increased intracranial pressure, potentially causing further damage. Edema management might involve measures such as elevating the head of the bed, using osmotic agents, and closely monitoring the patient's neurological status. This is an important aspect of stroke management. Option D - Elective Hyperventilation: Elective hyperventilation, which involves intentionally increasing breathing rate, can lead to a decrease in carbon dioxide levels in the blood. This can lead to constriction of blood vessels in the brain (vasoconstriction) and reduction of cerebral blood flow. While it was previously used in the management of elevated intracranial pressure, it is generally not recommended due to the risk of worsening cerebral ischemia. Instead, other methods for intracranial pressure control are preferred.

References:

.

↑ *Back to this question in Part A*

@Neet_pg_bot

Q77: A stroke patient presents with an inability to identify objects but can determine the colour, texture, and shape of objects. Which of the following lobes is involved? (Q854720)

A. Frontal lobe

B. Parietal lobe

C. Temporal lobe

D. Occipital lobe

Correct Answer: C. Temporal lobe

Explanation: The inability to identify objects and the ability to determine the colour, texture, and shape of objects refer to visual agnosia, which is caused by lesions involving the temporal lobe. Features of Left Temporal Lobe Stroke Features of Right Temporal Lobe Stroke Impaired language and memory: Difficulty with spoken language and remembering verbal information. Fluent (Wernicke’s) aphasia: Fluent speech with incorrect words, affecting language comprehension. Poor visual memory and spatial awareness: Difficulty recognizing visual patterns and spatial information. Prosopagnosia : Inability to recognize faces, including familiar ones. General Features of Temporal Lobe Stroke Poor memory: Difficulty recalling memories and learning new information. Prosopagnosia: Trouble recognizing faces and objects. Fluent aphasia: Specifically in left-sided strokes, affecting speech fluency but with incorrect word use. Visual perception difficulties: Challenges with interpreting the visual field and surroundings. Trouble processing sound: Inability to differentiate or process sounds correctly. Visual agnosia: Inability to recognize visually presented objects despite otherwise normal visual field, acuity, colour vision, brightness, discrimination, language, and memory. Emotional and behavioural changes: Varying behaviours due to damage to the amygdala, such as aggression, passiveness, or difficulty interpreting facial cues. Incorrect Options: Lesions in a patient's Frontal lobe (Option A) can lead to certain symptoms such as trouble with learning, deficits in visual-motor function, executive dysfunction and problems with attention (planning, focusing, and inhibition).

Parietal lobe (Option B) : Right - Damage to this area can cause visuospatial deficits (e.g., the patient may have difficulty finding their way around new, or even familiar, places). Parietal Lobe, Left: Damage to this area may disrupt a person's ability to understand spoken and/or written language. Unilateral Occipital lobe (Option D) lesion causes contralateral homonymous hemianopia. It is a visual field defect on the same side of both eyes contralateral to the site of the lesion - lesions of the occipital lobe due to the posterior cerebral artery infarct cause homonymous hemianopia with macular sparing.

References:

Harrison’s Principles of Internal Medicine, 21st Edition, Page: 201.

https://www.ncbi.nlm.nih.gov/books/NBK493156/

↑ *Back to this question in Part A*

@Neet_pg_bot

Q78: A 30-year-old patient presents with high-grade fever for the past week. On examination neck stiffness and Kernig's sign were positive. CSF analysis showed lymphocytosis protein - 8 g/L, glucose - 20 mg/dl while RBS = 140 mg/dl. What is your diagnosis? (Q854684)

A. Tubercular meningitis

B. Coxsackie meningitis

C. Bacterial meningitis

D. HSV -1 encephalitis

Correct Answer: A. Tubercular meningitis

Explanation: The CSF shows lymphocytic predominance , very high protein (8 g/L = 800 mg/dL) , and markedly low glucose (20 mg/dL) with a normal RBS, classic for tubercular meningitis . The subacute course (1 week fever) and meningeal signs also support TBM. Type Opening Pressure Predominant Cell Type Protein Glucose Gross Appearance Bacterial Meningitis (Option C) Elevated Polymorphonuclear Neutrophils (PMNs) Elevated Decreased Turbid Fungal/ Tubercular Meningitis Elevated Lymphocytes Elevated Decreased Straw-colored (TB meningitis) Viral Meningitis (Option B & D) Normal or Slightly Elevated Lymphocytes Normal or Slightly Elevated Normal Normal or Turbid

References:

Harrison’s Principles of Internal Medicine, 21st Edition, Page: 1108,1109,1366.

↑ *Back to this question in Part A*

@Neet_pg_bot

Q79: Antibody seen in Acute Inflammatory Demyelinating Polyneuropathy will belong to which class? (Q820419)

A. Ig G

B. Ig M

C. Ig E

D. Ig A

Correct Answer: A. Ig G

Explanation: Correct Option A - (IgG): Acute Inflammatory Demyelinating Polyneuropathy (AIDP) is commonly known as Guillain-Barré Syndrome (GBS). GBS is an autoimmune disorder where the immune system mistakenly attacks the peripheral nervous system, leading to inflammation and demyelination of nerves. In the context of GBS, the antibodies produced against components of peripheral nerves belong primarily to the IgG class. IgG is the correct answer because IgG antibodies are the most involved immunoglobulins in GBS. These antibodies target myelin, which is the protective covering of nerve fibers, leading to impaired nerve conduction and the characteristic symptoms of muscle weakness, tingling, and paralysis seen in GBS patients. Incorrect Options: Option B - IgM: While IgM antibodies can be involved in certain autoimmune diseases, they are not typically associated with GBS. IgM antibodies are usually associated with early immune responses and are not as commonly found in autoimmune disorders affecting the nervous system. Option C - IgE: IgE antibodies are primarily associated with allergic reactions and parasitic infections. They are not a characteristic component of the immune response seen in GBS. Option D - IgA: IgA antibodies are mainly found in mucosal secretions and play a role in defending mucous membranes. They are not typically associated with the immune response involved in GBS.

↑ *Back to this question in Part A*

@Neet_pg_bot

Q80: In a patient diagnosed with Dialysis Dementia, what deposition is seen in the cerebral cortex? (Q820411)

A. Amyloid β■

B. Amyloid β■ microglobulin

C. Amyloid transthyretin

D. Amyloid β

Correct Answer: B. Amyloid β■ microglobulin

Explanation: Amyloid beta microglobulin Dialysis dementia (also called dialysis encephalopathy) shows deposition of β2-microglobulin amyloid in the cerebral cortex and basal ganglia Long-term hemodialysis patients develop β2-microglobulin amyloidosis because dialysis membranes fail to adequately clear this middle molecule (mw ~11.8 kDa) These amyloid deposits cause the characteristic neuropsychiatric symptoms: speech dysfunction, myoclonus, seizures, and progressive dementia Amyloid β■ (Option A): Not a recognized pathological entity . Amyloid transthyretin (Option C): Transthyretin amyloidosis is a separate condition where transthyretin protein deposits as amyloid in various organs, causing systemic organ dysfunction eg) cardiac amyloidosis. It is not specifically associated with dialysis dementia. Amyloid β (Option D): Amyloid beta is a protein that is well-known for its involvement in Alzheimer's disease, where it forms plaques in the brain. However, in the context of dialysis dementia, the protein of concern is beta-2 microglobulin, as explained in option A.

References:

https://pmc.ncbi.nlm.nih.gov/articles/PMC3136063/

↑ *Back to this question in Part A*

@Neet_pg_bot

Q81: Scissoring gait will occur due to increases firing of Which of the following nerve? (Q820407)

A. Superior gluteal nerve

B. Inferior gluteal nerve

C. Obturator nerve

D. Femoral nerve

Correct Answer: C. Obturator nerve

Explanation: Correct Option C - Obturator Nerve: The obturator nerve innervates the muscles of the medial thigh, including the adductors (adductor magnus, adductor longus, adductor brevis, gracilis, and obturator externus). Increased firing or overactivity of the adductor muscles innervated by the obturator nerve can result in a scissoring gait. A scissoring gait is characterized by the legs crossing over each other during walking due to excessive adduction of the hip and thigh muscles. Incorrect Options: Correct A - Superior Gluteal Nerve: The superior gluteal nerve primarily innervates the gluteus medius and gluteus minimus muscles. Increased firing of this nerve would lead to weakness or overactivity of these muscles, resulting in a Trendelenburg gait (characterized by excessive lateral pelvic tilt and hip drop on the unsupported side during the stance phase of gait), not a scissoring gait. Option B - Inferior Gluteal Nerve: The inferior gluteal nerve innervates the gluteus maximus muscle. An increase in firing of this nerve would affect the function of the gluteus maximus, potentially leading to altered hip extension, but it wouldn't directly cause a scissoring gait. Option D - Femoral Nerve: The femoral nerve innervates the muscles of the anterior thigh, including the quadriceps femoris muscle group. Increased firing of the femoral

nerve and subsequent overactivity of the quadriceps muscles might affect knee extension, but it wouldn't directly lead to a scissoring gait.

↑ *Back to this question in Part A*

@Neet_pg_bot

Q82: 65-year-old man is brought to the hospital with complaints of suddenly not making any sense while speaking using non-sensical grammar though he can speak quickly. He could communicate effectively prior to this. Which of the following defect is present in this patient? (Q820399)

A. Motor aphasia

B. Anomic aphasia

C. Fluent aphasia

D. Conduction aphasia

Correct Answer: C. Fluent aphasia

Explanation: The patient speaks rapidly and fluently but with meaningless, nonsensical grammar - classic of Wernicke’s (fluent) aphasia. In this condition, speech production is smooth but lacks meaningful content due to impaired language comprehension. Patients often produce paraphasias and neologisms, making speech sound like jargon. Comprehension is severely impaired, so they cannot understand spoken language well. Repetition is typically impaired because the comprehension pathway is disrupted. The lesion is in the Wernicke area of the dominant hemisphere (posterior superior temporal gyrus). Incorrect Options: Option A - Motor aphasia: Motor aphasia, also known as Broca's aphasia, is characterized by difficulty in producing speech, with limited vocabulary, slow speech, and impaired grammar. People with motor aphasia struggle to form coherent sentences and might experience frustration due to their communication difficulties. Option B - Anomic aphasia: Anomic aphasia is characterized by word-finding difficulties. People with this type of aphasia have trouble recalling specific words, which leads to pauses and substitutions in their speech. However, their grammar and fluency are relatively intact. Option D - Conduction aphasia: Conduction aphasia is characterized by difficulty in repeating words and phrases, even though comprehension and spontaneous speech might be relatively intact. People with conduction aphasia have trouble bridging the gap between understanding and speaking, leading to errors in repeating what they have just heard.

References:

.

↑ *Back to this question in Part A*

@Neet_pg_bot

Q83: A 50-year-old man presents with movement disorder and tremors in hand, along with the development of cognitive and emotional problems. Which of the following medical disorders is the likely diagnosis? (Q820387)

A. Parkinson's disease

B. Frederich's ataxia

C. Alzheimer’s disease

D. Huntington's disease

Correct Answer: D. Huntington's disease

Explanation: Correct Option D - Huntington's disease: Huntington's disease is a genetic disorder caused by a mutation in the HTT gene, leading to the accumulation of abnormal protein in the brain. It presents with movement problems (chorea, which are involuntary, random, and brief movements), cognitive decline, and emotional disturbances such as depression and anxiety. The onset usually occurs in adulthood, typically between the ages of 30 and 50. The mutation involves a trinucleotide repeat expansion (CAG repeats) on the HTT gene. Incorrect Options: Option A - Parkinson's disease: While Parkinson's disease can present with movement disorders and tremors, it typically develops in older individuals (usually after the age of 60). Additionally, cognitive and emotional problems are more characteristic of other conditions like Lewy body dementia, which can be associated with parkinsonism. Option B - Friedreich's ataxia: Friedreich's ataxia is a genetic disorder that primarily affects the nervous system, causing progressive damage to the spinal cord and peripheral nerves. It is characterized by problems with coordination, balance, and muscle control. While it can lead to movement problems, cognitive and emotional issues are not prominent features of this disorder. Option C - Alzheimer's disease: Alzheimer's disease primarily affects memory, thinking, and behavior. It does not typically present with movement disorders and tremors. Cognitive and emotional problems are central to Alzheimer's, but the movement disorder symptoms described (tremors, chorea) are not characteristic of this disorder.

References:

.

↑ *Back to this question in Part A*

@Neet_pg_bot

Q84: A 60-year-old patient weighing 80 kilograms has been diagnosed with an acute ischemic stroke and is recommended for thrombolysis with alteplase. What should the initial stat dose in milligrams be? (Q820359)

A. 8

B. 10

C. 12

D. 15

Correct Answer: A. 8

Explanation: Correct Option A - 8 Streptokinase is always given in the form of an infusion over 1 hour but alteplase, some part of it can be given as a bolus shot and the remaining can be given as infusion. 10% of the total dose need to be given in the form of a bolus. Calculation of the Total Dose: The standard dose of alteplase for acute ischemic stroke is 0.9 mg per kilogram of body weight, with a maximum total dose of 90 mg. For an 80 kg patient: Total dose=80 kg×0.9 mg/kg=72 mg Administration of the Dose: Bolus Dose: 10% of the total dose is administered as an initial bolus over 1 minute. Bolus dose=10%×72 mg=7.2 mg Infusion Dose: The remaining 90% of the total dose is administered as an intravenous infusion over 60 minutes. Infusion dose=90%×72 mg=64.8 mg Since the maximum dose of alteplase is 90 mg, and the calculated dose is 72 mg, the patient will receive the calculated dose of 72 mg. The 10 % of this will be 7.2 and the closest option is 8 so the answer is Option A Incorrect Options: Option B - 10 Option C - 12 Option D - 15

References:

..

↑ *Back to this question in Part A*

@Neet_pg_bot

Q85: A patient is brought to the OPD by his wife complaining about difficulty in expressing emotions and not taking part in daily activities. On examination, resting tremors and rigidity are noted. Given the possible diagnosis, which part of the brain is affected in this patient? (Q855454)

A. Basal ganglia

B. Hippocampus

C. Cerebellum

D. Premotor cortex

Correct Answer: A. Basal ganglia

Explanation: isease: Rigidity: Increased muscle tone causing resistance to passive movement. Resting tremors: Involuntary, rhythmic shaking that occurs when the muscles are relaxed. Bradykinesia: Slowness of movement, making daily tasks more difficult. Postural instability: Difficulty maintaining balance, leading to falls. Hippocampus (Option B): The hippocampus is primarily involved in memory formation, learning, and spatial

navigation, and lesions here can lead to issues with memory and emotional behavior. However, it is not primarily associated with the motor symptoms seen in Parkinson's disease. Cerebellum (Option C): The cerebellum is responsible for coordinating voluntary movement and balance. Lesions in the cerebellum typically cause ataxia, intention tremors, and gait disturbances, but not the resting tremors or rigidity characteristic of Parkinson's disease. Premotor cortex (Option D): The premotor cortex is involved in the planning and preparation of movements, particularly in coordinating postural adjustments for voluntary movements. While damage here can affect motor planning, it is not typically associated with the specific motor symptoms seen in Parkinson's disease.

References:

Harrison's Principles of Internal Medicine, 21st Edition, Page: 3387. Guyton and Hall Textbook of Medical Physiology, 14th Edition, Page: 719–725. Ganong's Review of Medical Physiology, 26th Edition, Page: 698. https://journals.plos.org/ploscompbiol/article?id=10.1371/journal.pcbi.1000408 https://academic.oup.com/brain/article/138/10/3061/2468715

↑ *Back to this question in Part A*

@Neet_pg_bot

Q86: An elderly patient was brought to the OPD with complaints of tremors, stoop posture and slow movements. His son also gives a history of the patient forgetting day to day activities. What is the possible cause of this condition? (Q857283)

A. Normal pressure hydrocephalus (NPH)

B. Hypothyroidism

C. Lewy body

D. Vitamin B12 deficiency

Correct Answer: C. Lewy body

Explanation: - Lewy body: The scenario here points to the diagnosis of Lewy body dementia which is a neurodegenerative disorder characterised by dementia and signs of Parkinson’s disease. Lewy Body Dementia (LBD) includes Parkinson's disease dementia (PDD) and dementia with Lewy bodies (DLB), which are the second most common cause of neurodegenerative dementia after Alzheimer’s disease. Prevalence: The incidence of DLB is approximately 7 per 100,000 person-years, with both PDD and DLB becoming more common with age and affecting men more often than women. Cognitive Features: Common in both PDD and DLB : Severe executive, attentional, and visuospatial deficits with preserved episodic memory. Fluctuating cognition, visual hallucinations, and parkinsonism are key features, especially in DLB. Day-to-day variations in cognitive function are often seen, with periods of confusion or lethargy that resolve quickly. Motor Symptoms: Parkinsonism in DLB often includes postural instability, which can emerge early or later. Other Symptoms: REM sleep behavior disorder (RBD) is a common and early sign. Symptoms like anosmia, constipation, depression, and anxiety may precede or accompany the cognitive decline. Diagnostic Features: PDD typically develops after long-standing Parkinson’s disease with cognitive decline, visual hallucinations, and fluctuating attention. DLB involves early dementia and

neuropsychiatric symptoms like hallucinations and fluctuating cognition, occurring alongside or before parkinsonism. Pathology: Lewy bodies and Lewy neurites are present in key brain areas, including the brainstem, substantia nigra, amygdala, and cortex. These inclusions are composed of α-synuclein aggregates, making LBD a synucleinopathy. The progression follows three stages: brainstem predominant, transitional limbic, and diffuse neocortical. Pathogenesis: Both genetic factors (e.g., α-synuclein duplications, mutations in the glucocerebrosidase gene) and environmental factors, such as toxins, may contribute to LBD development. LBD might spread via a prion-like mechanism, propagating from peripheral areas like the gastrointestinal system or olfactory bulb to the brain. Cholinergic and Adrenergic Deficits: DLB shows a profound cholinergic deficit, contributing to cognitive fluctuations and hallucinations. Adrenergic deficits, especially from the locus coeruleus, further impair alertness and arousal. Normal Pressure Hydrocephalus (NPH) (Option A) can cause a triad of symptoms known as Hakim's triad, which includes gait disturbances, urinary incontinence, and cognitive impairment. The triad is not present in the given scenario. Hypothyroidism (Option B) can lead to various symptoms, including cognitive impairment, depression, and memory problems. But the given scenario does not provide any relation to it. Vitamin B12 deficiency (Option D) can lead to neurological symptoms, including cognitive impairment and dementia-like symptoms. However, the given scenario is not associated with this.

References:

Harrison’s Principles of Internal Medicine, 21st Edition, Page: 3385, 3386.

↑ *Back to this question in Part A*

@Neet_pg_bot

Q87: A 35-year-old male patient suffers from schizophrenia. He is currently receiving clozapine treatment. Why does he require frequent blood monitoring? (Q857278)

A. Agranulocytosis

B. Myocarditits

C. Cerebral bleed

D. Seizures

Correct Answer: A. Agranulocytosis

Explanation: lozapine primarily works as a dopamine D2 receptor antagonist , but it also has significant effects on serotonin receptors (5-HT2A and 5-HT2C), which helps reduce symptoms in treatment-resistant cases. Side Effects: Severe risks: Agranulocytosis: Occurs in approximately 0.3% of users, necessitating regular monitoring of white blood cell counts. Seizures (Option D) : Affects up to 5% of patients on doses exceeding 600 mg. Common side effects: Hypersalivation Sedation Tachycardia Weight gain Postural hypotension Rare side effects include myocarditis (Option B) . Cerebral bleeding (Option C) is not a commonly reported side effect of clozapine nor does regular blood tests help in assessing the risk or occurrence of one.

References:

Kaplan & Sadock’s Synopsis of Psychiatry, 12th Edition, Page: 1141.

Chapter - 5, Hospitalisation, Clozapine

↑ *Back to this question in Part A*

@Neet_pg_bot

Q88: What is observed in the case of an abnormal accumulation of misfolded protein? (Q857270)

A. Creutzfeldt jakob disease

B. Nephritic syndrome

C. Sickle cell anemia

D. Megaloblastic anemia

Correct Answer: A. Creutzfeldt jakob disease

Explanation: JD is caused by prions , which are abnormally folded proteins that induce other normal prion proteins to adopt the same harmful shape. These abnormal prion proteins accumulate in the brain, leading to nerve cell damage and the characteristic spongiform appearance (brain tissue with holes). The prion proteins disrupt normal brain functions, causing progressive neurological degeneration. Main symptoms: Severe mental deterioration (dementia) Involuntary muscle jerks (myoclonus) Early symptoms: Lack of coordination, walking/balance problems Impaired thinking, memory, judgment, mood changes, anxiety Confusion, insomnia, vision changes, unusual sensations Progression symptoms: Weakness, blindness, loss of movement or speech Pneumonia, infections, coma CJD types: Sporadic (unknown cause, 85% of cases) Hereditary (gene mutation, 10-15% of cases) Acquired (rare, from medical procedures or contaminated tissue) Variant CJD (linked to "mad cow" disease, affects younger people) Diagnosis: EEG, cerebrospinal fluid tests (14-3-3 protein), MRI Brain biopsy or autopsy for confirmation Treatment: No cure Symptom management (pain relief, muscle jerk control, comfort care) Nephritic syndrome (Option B) is primarily associated with immune-mediated damage and not the accumulation of misfolded proteins. In sickle cell anaemia (Option C) , while there is an abnormality in the structure of haemoglobin, it does not involve the accumulation of misfolded proteins as seen in CJD. Megaloblastic anaemia (Option D) is a type of anaemia characterized by the presence of large, immature red blood cells (megaloblasts) in the bone marrow. Megaloblastic anaemia does not involve the accumulation of misfolded proteins.

References:

https://www.ninds.nih.gov/health-information/disorders/creutzfeldt-jakob-disease

↑ *Back to this question in Part A*

@Neet_pg_bot

Q89: A 30-year-old woman presents with ptosis, diplopia, and generalized muscle weakness that worsens with activity and improves with rest. She has difficulty chewing and swallowing, especially in the evening. A Tensilon test is positive. Which investigation is most likely to confirm the diagnosis? (Q860245)

A. CT scan of the chest

B. SFEMG

C. Anti-acetylcholine receptor antibody test

D. MRI of the brain

Correct Answer: C. Anti-acetylcholine receptor antibody test

Explanation: The clinical presentation strongly suggests Myasthenia Gravis (MG) based on the classic triad of symptoms : ptosis, diplopia, and fatigable muscle weakness. The hallmark pattern of weakness that worsens with activity and improves with rest , along with diurnal variation (symptoms worsening in the evening), is pathognomonic for MG. The positive Tensilon test further supports this diagnosis. Myasthenia gravis is most definitively confirmed by the presence of anti–AChR antibodies , which are highly specific for the disease. A positive Tensilon (edrophonium) test supports the diagnosis, but antibody testing provides the confirmatory laboratory evidence. Diagnosing Myasthenia Gravis (MG) Diagnosis involves a comprehensive approach integrating clinical evaluation and specific diagnostic tests. Clinical Evaluation: Recognizing the Signs History: Focus on the onset, progression, diurnal variation and fluctuating muscle weakness. Physical Examination: Assess muscle strength. Identify characteristic signs: Ptosis Diplopia Cogan's lid twitch sign Rule out other neurological conditions. Diagnostic Tests: Confirming the Suspicion Test Description Tensilon Test Administers edrophonium bromide intravenously. May show transient muscle function improvement; not highly reliable. Repetitive Nerve Stimulation (RNS) Specialized nerve conduction study. Reveals a decremental response in muscle strength with repeated stimulation, indicating impaired neuromuscular transmission. Single Fiber Electromyography (SFEMG) SFEMG techniques allow assessment of two important features of the motor unit: jitter and fiber density (FD). SFEMG is the most sensitive clinical test for neuromuscular junction disease and is often abnormal in clinically unaffected muscles in patients with myasthenia gravis (MG) and Lambert-Eaton myasthenia (LEM). Antibody Testing Detects auto-antibodies related to MG. Acetylcholine Receptor (AChR) Antibodies: Most common, block AChR function. Muscle-Specific Kinase (MuSK) Antibodies: Disrupt AChR clustering and stabilization. Thoracic CT Scan Essential to rule out thymoma, especially in patients with negative AChR antibody tests. CT scan of the chest (Option A) is used for evaluating thymus gland abnormalities such as thymoma, which occurs in approximately 10-15% of MG patients. While important in the overall evaluation, it is not the primary diagnostic test for confirming MG diagnosis. SFEMG (Single-Fiber EMG) (Option B): The most sensitive test for MG but not the primary confirmatory test; used when antibodies are negative. MRI of the brain (Option D) may be useful in ruling out other neurological conditions that can present with similar symptoms, such as multiple sclerosis or brainstem lesions. However, it does not provide specific diagnostic information for MG and is primarily used to exclude other conditions.

References:

Davidson’s Principles and Practice of Medicine, 24th Edition, Page 1141-1143

↑ *Back to this question in Part A*

@Neet_pg_bot

Q90: 25 year old HIV positive patient presents with autonomic dysreflexia and flaccid quadriplegia. The results of a lumbar puncture are as follows Opening Pressure: 150 mm water Cells: 5 lymphocytes/ cu.mm Sugar: 85 mg/dl (RBS 120 mg/dl) Protein: 100 mg/dl Color: normal Based on these findings, which of the following is the most likely diagnosis? (Q860235)

A. Cryptococcal meningitis

B. Transverse myelitis

C. Tuberculosis Meningitis

D. Acute inflammatory demyelinating polyneuropathy

Correct Answer: D. Acute inflammatory demyelinating polyneuropathy

Explanation: cute inflammatory demyelinating polyneuropathy (Guillain–Barré syndrome) classically presents with acute flaccid quadriplegia and autonomic dysfunction. CSF shows albuminocytologic dissociation, i.e., markedly elevated protein with normal or very low cell count, as seen here (protein 100 mg/dL, cells 5/mm³). Normal CSF glucose and opening pressure further support this diagnosis. Incorrect Options: Option A - Cryptococcal meningitis: Typically seen in HIV patients but presents with raised opening pressure, lymphocytic pleocytosis, low or normal glucose, and raised protein. Flaccid quadriplegia with albuminocytologic dissociation is not typical. Option B - Transverse myelitis: Characterized by acute spinal cord dysfunction with sensory level and bladder involvement. CSF usually shows pleocytosis and inflammatory changes, not isolated protein elevation. Option C - Tuberculous meningitis: Shows lymphocytic pleocytosis, very high protein, and low CSF glucose, often with raised opening pressure. The CSF profile here is inconsistent.

References:

Harrison’s Principles of Internal Medicine, 21st Edition, Page 975, 1104, 1105

Davidson’s Principles and Practice of Medicine, 24th Edition, Page 1119, 1120

↑ *Back to this question in Part A*

@Neet_pg_bot

Q91: A 30-year-old man experiences initial paralysis in both legs, which then progresses to affect both upper limbs as well. Over time, he shows slight improvement in upper limbs but no improvement in his lower trunk and both legs. Based on this description, what is the most likely diagnosis? (Q860213)

A. Diplegia

B. Quadriplegia

C. Paraplegia

D. Monoplegia

Correct Answer: A. Diplegia

Explanation: The clinical manifestations indicate diplegia , a condition characterized by symmetric paralysis that predominantly affects the lower body while sparing or minimally affecting the upper limbs. The patient's clinical course shows an initial widespread paralysis that improved to primarily affect the lower trunk and legs, and only slight involvement of upper limbs, which is characteristic of diplegia. Quadriplegia (Option B) refers to paralysis of all four limbs and typically includes the torso. While the patient initially experienced widespread involvement, the final clinical picture with predominant lower body involvement does not correlate with quadriplegia. Paraplegia (Option C) involves complete paralysis of the lower half of the body, including both legs, but does not affect the arms. The patient's history of upper limb involvement and subsequent improvement makes paraplegia an incorrect diagnosis. Monoplegia (Option D) refers to paralysis affecting only one limb. The patient's presentation with bilateral leg and lower trunk involvement clearly indicates a more extensive pattern of paralysis than monoplegia.

References:

https://www.ncbi.nlm.nih.gov/books/NBK132431/table/introduction.t1/

↑ *Back to this question in Part A*

@Neet_pg_bot

Q92: A lumbar puncture was performed on a patient in a sitting position, and the patient is now experiencing a very severe headache. Which of the following is NOT a recommended management strategy for a post-lumbar puncture headache? (Q860155)

A. Lie in a supine position

B. Administer intravenous caffeine

C. Restrict water intake

D. Perform a low-volume blood patch

Correct Answer: C. Restrict water intake

Explanation: The clinical manifestations indicate a post-lumbar puncture headache (PDPH). Restricting fluid intake is not a standard approach used in the management of PDPH Postdural puncture headache (PDPH) is a potential complication of a lumbar puncture, with symptoms caused by traction on pain-sensitive structures from low cerebrospinal fluid pressure (intracranial hypotension) following a leak of cerebrospinal fluid at the puncture site. Traumatic needles like Quincke, Babcock and also needles with lower gauge can cause PDPH. Definitive treatment with an epidural blood patch is recommended when symptoms persist even after conservative treatment. Management of PDPH: Bed rest for 8-12 hours Analgesics Intravenous caffeine Despite symptomatic treatment, if the headache persists: Low Volume Blood patch: For this procedure, 10 ml to 30 ml of autologous venous blood is injected by an anesthesiologist into the epidural space at the level of the prior procedure. This is thought to create a "patch" over the dural puncture and decrease CSF leak, or simply increase the intracranial pressure. Lie in a supine position (Option A) is a recommended first-line management strategy for post-lumbar puncture headaches. The supine position helps reduce cerebrospinal movement and fluid leakage through gravity and allows the dura to seal. Administer intravenous caffeine (Option B) is an appropriate intervention for post-lumbar puncture headaches. Caffeine acts as a vasoconstrictor, which can help reduce the headache by decreasing cerebral vessel dilation and improving cerebrospinal fluid production. Perform a low-volume blood patch (Option D) is a definitive treatment option for persistent post-lumbar puncture headaches that don't respond to conservative measures. This procedure involves injecting autologous blood into the epidural space to seal the CSF leak and provide headache relief.

References:

Davidson’s Principles and Practice of Medicine, 24th Edition, Page 1077

Postdural puncture headache

↑ *Back to this question in Part A*

@Neet_pg_bot

Q93: A 30-year-old woman presents with a unilateral throbbing headache that worsens with exposure to bright light. She occasionally skips breakfast. What is the most likely diagnosis? (Q860148)

A. Hunger headache

B. Migraine

C. Tension headache

D. Cluster headache

Correct Answer: B. Migraine

Explanation: The clinical manifestations indicate a migraine headache . According to Diagnostic Criteria for Migraine by International Headache Society, criteria includes features such as unilateral location , throbbing quality , and photophobia (sensitivity to bright light). The condition is characterized by recurrent episodes that can be triggered by various factors, including missed meals , as noted in the patient's history of occasionally skipping breakfast. Migraines typically last between 4-72 hours and may be accompanied by nausea and other sensory sensitivities. Clinical Features of Migraine Premonitory (Prodromal) Phase Neck discomfort Cognitive impairment (brain “fog”) Mood changes Fatigue Yawning/sleepiness Increased urination and thirst Food cravings Aura Neurologic disturbances (e.g., visual disturbances like scintillating scotoma) Due to Cerebral vasoconstriction. Therefore prevention is by Vasodilators. Headache Phase Pain Nausea/vomiting Sensory sensitivities: Photophobia (sensitivity to light) Phonophobia (sensitivity to sound) Osmophobia (sensitivity to smells) Allodynia (pain from non-painful stimuli) Vertigo Due to cerebral vasodilation. So treatment is Vasoconstrictors Postdrome Tiredness Weariness Impaired concentration Simplified Diagnostic Criteria for Migraine by International Headache Society: Criteria: Repeated attacks of headache lasting 4–72h in patients with a normal physical examination, no other reasonable cause for the headache, and: At least 2 of the following features: Unilateral pain Throbbing pain Aggravation by movement Moderate or severe intensity Plus at least 1 of the following features: Nausea/vomiting Photophobia and phonophobia Hunger headache (Option A) is typically bilateral rather than unilateral and does not present with photophobia or throbbing pain. These headaches are generally diffuse and associated with hypoglycemia due to missed meals, improving rapidly with food intake. Tension headache (Option C) presents with bilateral, steady, pressing pain rather than unilateral throbbing pain. These headaches typically feel like a tight band around the head and are not characteristically aggravated by light or accompanied by photophobia. Cluster headache (Option D) presents with severe, strictly unilateral pain centered around the eye, often accompanied by autonomic symptoms such as lacrimation and nasal congestion. These headaches occur in clusters lasting weeks to months, with multiple short-duration attacks per day, and typically do not have the strong association with photophobia seen in this case.

References:

Harrison’s Principles of Internal Medicine, 21st Edition, Page 3359- 3365

Migraine: Symptoms, Causes, and Treatment

Migraine Medications - StatPearls - NCBI Bookshelf

↑ *Back to this question in Part A*

@Neet_pg_bot

Q94: A 16-year-old girl presents with generalized muscle weakness and protrusion of the eyelids (ptosis) that worsens as the day progresses. What is the most likely diagnosis? (Q860120)

A. Myasthenia Gravis

B. Fibromyalgia

C. Myotonic Dystrophy

D. Guillain-Barré Syndrome

Correct Answer: A. Myasthenia Gravis

Explanation: The clinical manifestations indicate Myasthenia Gravis (MG) , an autoimmune disorder affecting the neuromuscular junction. Clinical Features of Myasthenia Gravis: Fatigable muscle weakness : Muscle strength decreases with continued use , especially: Later in the day as day progresses After exercise No sensory or CNS involvement , distinguishing it from other neurological disorders. Common Initial Symptoms Ptosis (drooping eyelid) Diplopia (double vision) Weakness can spread to: Chewing, swallowing, and speaking muscles Limb muscles Muscle Weakness Patterns: Affected Muscles Key Features Ocular muscles Mimics central eye movement disorders. Cogan's lid twitch sign Upper eyelid rises briefly after looking down for some time. Shoulder girdle muscles Difficulty in overhead activities like combing hair. Respiratory muscles Weakness may cause respiratory failure and aspiration risks. Fibromyalgia (Option B): This chronic condition is characterized by widespread musculoskeletal pain, fatigue, and tender points rather than true muscle weakness. It does not present with ptosis or demonstrate diurnal variation in symptoms. Myotonic Dystrophy (Option C): This genetic disorder causes progressive muscle weakness with myotonia (delayed muscle relaxation) and primarily affects distal muscles. The absence of myotonia and presence of generalized muscular weakness points away from this diagnosis. Guillain-Barré Syndrome (Option D): Guillain-Barré syndrome (GBS), the acute inflammatory demyelinating polyneuropathy, cardinally presents with acute-onset symmetric flaccid limb weakness. This acute ascending paralysis typically begins in the lower extremities and progresses upward.

References:

Davidson’s Principles and Practice of Medicine, 24th Edition, Page 1141-1143

↑ *Back to this question in Part A*

@Neet_pg_bot

Q95: All of the following is a risk factor for secondary headache and need further workup except? (Q840124)

A. 50 years old with first severe headache

B. Presence of cord-like vessels in the temporal area

C. Cocaine abuse

D. Subacute worsening of headache symptoms

Correct Answer: C. Cocaine abuse

Explanation: Correct Option C - Cocaine abuse: Cocaine usage is not a factor of concern as cocaine itself contributes to the development of headaches as it causes vasoconstriction and increases blood pressure. Incorrect Options: Option A - 50 years old with first severe headache: In an elderly new onset headache is a cause of

concern and needs further investigation. Option B - Presence of cord-like vessels in the temporal area: Cord-like vessels are a feature of giant cell arteritis. Hence, the presence of cord-like vessels in the temporal area is a risk factor. Option D - Subacute worsening of headache symptoms: Subacute worsening of headache symptoms is suggestive of intracranial space-occupying lesions. Therefore, it is a risk factor for secondary headaches.

↑ *Back to this question in Part A*

@Neet_pg_bot

Q96: A 45-year-old male presents to the outpatient department with complaints of daytime sleepiness and nighttime sleeplessness. His wife reports that he snores at night. Which of the following statements about his condition is incorrect? (Q840105)

A. The tone of the pharyngeal muscles is increased

B. Low oxygen saturation triggers waking up at night

C. Episodes of apnea increase stress on the heart

D. Low oxygen stimulates respiratory effort

Correct Answer: A. The tone of the pharyngeal muscles is increased

Explanation: Correct Option A - The tone of the pharyngeal muscles is increased: The scenario depicts obstructive sleep apnea (OSA). In individuals with a collapsible airway, reduced muscle tone leads to brief pharyngeal collapse (apneas) or near-collapse (hypopneas). These episodes typically end with ventilatory reflexes prompting arousal, increasing muscle activity, and reopening the airway. Collapse can occur at various sites, including the soft palate (most common), tongue base, lateral pharyngeal walls, and/or epiglottis. Incorrect Options: Option B - Low oxygen saturation triggers waking up at night: Apneic episodes are related to stress on the heart and waking up at night. Option C - Episodes of apnea increase stress on the heart: Intensified snoring can lead to apneic episodes, stressing the heart. Rapid fluctuations in heart rate due to hypoxia induce peripheral vasoconstriction. Option D - Low oxygen stimulates respiratory effort: Hypoxia is the trigger that stimulates respiratory effort in a patient with obstructive sleep apnea.

↑ *Back to this question in Part A*

@Neet_pg_bot

Q97: Which of the following type of hypersensitivity reactions is seen in myasthenia gravis? (Q793907)

A. Type 1 hypersensitivity reaction

B. Type 2 hypersensitivity reaction

C. Type 3 hypersensitivity reaction

D. Type 4 hypersensitivity reaction

Correct Answer: B. Type 2 hypersensitivity reaction

Explanation: Correct Option B - Type 2 hypersensitivity reaction: The type of hypersensitivity reaction seen in myasthenia gravis is a type 2 hypersensitivity reaction. Hypersensitivity reactions are exaggerated immune responses that can cause tissue damage and disease. Myasthenia gravis is an autoimmune disease, most commonly (80% of cases) caused by antibodies to acetylcholine receptors in the post-junctional membrane of the neuromuscular junction. The autoantibodies in myasthenia gravis are primarily of the IgG subtype and lead to complement-mediated destruction of the acetylcholine receptors. Incorrect Options: Option A - Type 1 hypersensitivity reaction: These reactions typically occur within minutes of exposure and can cause symptoms such as hives, itching, and anaphylaxis. Option C - Type 3 hypersensitivity reaction: Examples of type 3 hypersensitivity reactions include systemic lupus erythematosus (SLE) and rheumatoid arthritis. Option D - Type 4 hypersensitivity reaction: Examples of type 4 hypersensitivity reactions include contact dermatitis and some forms of drug reactions.

References:

Prepladder Notes

↑ *Back to this question in Part A*

@Neet_pg_bot

Q98: What is the diagnosis for a 24-year-old female patient who presents with fever, headache, ataxia, nausea, and vomiting for the past 3 days? The patient exhibits neck rigidity and hip and knee flexion upon passive flexion of the neck. A lumbar puncture was performed, and the CSF findings are provided below. Opening pressure – increased Color – cloudy white WBCs – 7000/µl; neutrophil predominant Sugar – 15 mg/dl CSF/serum glucose ratio – 0.2 Protein – 70 mg/dl Latex agglutination – positive Limulus lysate test – negative (Q793904)

A. Bacterial meningitis

B. Tubercular meningitis

C. Viral meningitis

D. Fungal meningitis

Correct Answer: A. Bacterial meningitis

Explanation: Correct Option A - Bacterial meningitis: The clinical presentation of the patient, including fever, headache, ataxia, nausea, vomiting, and neck rigidity, suggests meningitis. The findings from the CSF analysis also support this diagnosis. The presence of increased opening pressure, cloudy white color, neutrophil-predominant leukocytosis, low CSF/serum glucose ratio, and elevated protein levels are all indicative of meningitis. The positive latex agglutination test and negative Limulus lysate test suggest bacterial etiology. Incorrect Options: Option B - Tubercular meningitis. The positive latex agglutination test is suggestive of tuberculosis, and the presence of neutrophil-predominant leukocytosis is typical of early-stage tubercular meningitis. The low CSF/serum glucose ratio is also a characteristic finding in tubercular meningitis. But it is not the correct option. Option C - Viral meningitis: In viral meningitis, the CSF typically shows lymphocytic pleocytosis, with normal or slightly elevated protein levels and normal glucose levels. Option D - Fungal meningitis can also present with similar symptoms and CSF findings, including increased opening pressure, low glucose, and elevated protein. However, fungal meningitis is rare and usually occurs in immunocompromised individuals.

↑ *Back to this question in Part A*

@Neet_pg_bot

Q99: A patient with a unilateral hypoglossal nerve (CN XII) lesion is asked to protrude the tongue. What finding is expected? (Q793874)

A. Tongue deviation to the contralateral side

B. Tongue deviation to the same side

C. Falling of the tongue

D. Inability in tongue protrusion

Correct Answer: B. Tongue deviation to the same side

Explanation: Correct Option B - Tongue deviation to the same side: The hypoglossal nerve is the 12th cranial nerve that controls the movement of the tongue. When the hypoglossal nerve is injured, tongue deviation to the same side as the injury is the most common symptom. This is because the muscles on the affected side of the tongue become weak or paralyzed while the muscles on the unaffected side remain functional. Incorrect Options: Option A - Tongue deviation to the contralateral side: Tongue deviation to the contralateral side is incorrect as it suggests that the tongue would move towards the opposite side of the injury. However, this is not a typical presentation of hypoglossal nerve injury. Option C - Falling of the tongue: Falling back of the tongue" (airway obstruction) occurs mainly in bilateral hypoglossal palsy , not unilateral Option D - Inability in tongue protrusion: In unilateral hypoglossal nerve injury, tongue protrusion is still possible but deviated. Complete inability to protrude occurs only in bilateral lesions.

References:

Prepladder Notes

↑ *Back to this question in Part A*

@Neet_pg_bot

Q100: A child is brought with a 2-week history of not feeding well and excessive irritability. History of TB for sister is present and is taking treatment for it. In workup, LP was performed. Which of the following is likely to be found in CSF? (Q820371)

A. Lymphocytosis, low sugar, and high protein

B. Lymphocytosis, high sugar, and high protein

C. Neutrophils, low sugar and low protein

D. Neutrophils, low sugar and high protein

Correct Answer: A. Lymphocytosis, low sugar, and high protein

Explanation: Correct Option A - Lymphocytosis, low sugar and high protein: This option is the most likely finding in the CSF of a child with a suspected tuberculous meningitis, which is caused by the bacterium Mycobacterium tuberculosis. The history of TB in the sister raises the suspicion of an infectious etiology. Examination of cerebrospinal fluid (CSF) reveals a high leukocyte count (up to 1000/μL), usually with a predominance of lymphocytes but sometimes with a predominance of neutrophils in the early stage; a protein content of 1–8 g/L (100–800 mg/dL); and a low glucose concentration. Incorrect Options: Option B - Lymphocytosis, high sugar and high protein: While lymphocytosis and high protein levels are expected in a CNS infection, high sugar levels (hyperglycorrhachia) are not typical. Viruses and certain bacteria tend to decrease CSF glucose levels due to increased consumption. Therefore, this option is less likely. Option C - Neutrophils, low sugar, and low protein: Neutrophils are a type of white blood cell associated with bacterial infections. The combination of low sugar and low protein levels is not characteristic of most CNS infections, as infections typically lead to increased protein levels due to the inflammatory response. This pattern is not consistent with the clinical presentation and history provided. Option D - Neutrophils, low sugar, and high protein: While neutrophils could be present in the CSF in cases of acute bacterial meningitis, the combination of low sugar and high protein levels is not typical. Acute bacterial infections tend to lower CSF glucose levels due to consumption, but they also lead to an increase in protein levels. This option does not match the expected pattern for the given clinical scenario.

↑ *Back to this question in Part A*

@Neet_pg_bot

• [08_Rheumatology] 060 Vasculitis Syndromes - I

« Back to Folder Directory

[08_Rheumatology] 060 Vasculitis Syndromes - I — Quick Jump

Q1 (p. 2548) *Q2 (p. 2549)* *Q3 (p. 2550)* *Q4 (p. 2553)* *Q5 (p. 2553)* *Q6 (p. 2554)*
Q7 (p. 2555) *Q8 (p. 2555)* *Q9 (p. 2556)* *Q10 (p. 2557)* *Q11 (p. 2558)* *Q12 (p. 2559)*
Q13 (p. 2560) *Q14 (p. 2561)* *Q15 (p. 2562)*

Q1: A 68-year-old female presents with a new-onset severe headache, scalp tenderness, and jaw pain while chewing. Laboratory investigations reveal ESR 85 mm/hr, CRP 45 mg/L, and mild normochromic anemia. A biopsy of the temporal artery shows panarteritis with inflammatory mononuclear cell infiltrates and giant cell formation. In the analysis of T cells from the arterial lesion, which cytokines are primarily produced and play a crucial role in disease progression? (Q851671)

A. IL-4 and IL-5

B. IL-2 and IFN-γ

C. IL-10 and TGF-β

D. IL-6 and TNF-α

Correct Answer: B. IL-2 and IFN-γ

Explanation: Giant cell arteritis (temporal arteritis) is a Th1-mediated vasculitis , where CD4■ T cells infiltrate the vessel wall and produce IL-2 and IFN-γ , driving macrophage activation, granuloma formation, and vascular inflammation. {{caption_text}} IL-4 and IL-5 (Option A): Th2 cytokines; not dominant in GCA. IL-10 and TGF-β (Option C): Regulatory cytokines; involved in immune suppression, not pathogenic inflammation. IL-6 and TNF-α (Option D): Produced by macrophages; contribute to systemic symptoms and acute phase response, but not the primary T-cell–derived cytokines driving lesion formation.

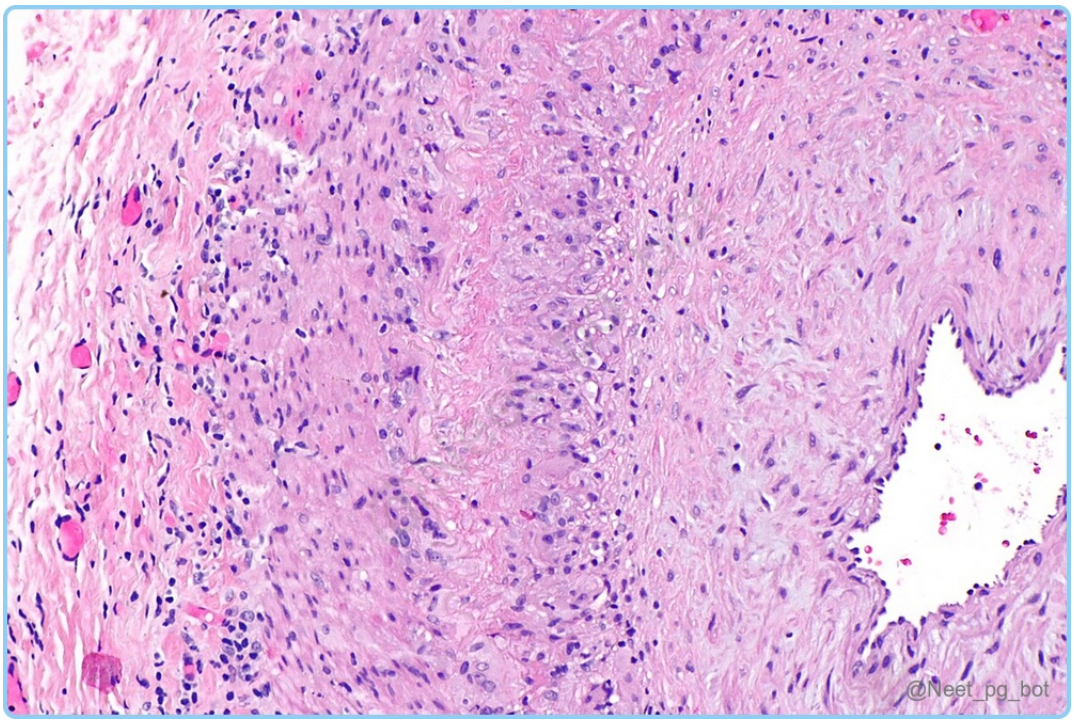

References:

Harrison's Principles of Internal Medicine, 21st Edition, Volume I, Page. 2811, 2812

↑ *Back to this question in Part A*

@Neet_pg_bot

Q2: A 72-year-old female presents with a new-onset headache, jaw claudication, and visual symptoms. Her ESR is 92 mm/hr and CRP is elevated. Temporal artery biopsy is planned, but immediate treatment is necessary. Which of the following is the most appropriate initial management strategy? (Q851675)

A. Wait for biopsy results before starting any treatment

B. Start prednisone 40-60 mg/day immediately

C. Begin methotrexate and low-dose aspirin

D. Start tocilizumab alone

Correct Answer: B. Start prednisone 40-60 mg/day immediately

Explanation: The symptoms of new-onset headache, jaw claudication, and visual symptoms point towards Giant Cell Arteritis Treatment should not be delayed pending diagnostic studies Initial therapy is prednisone 40-60

mg/day for ~1 month Early treatment is crucial to prevent vision loss Temporal artery biopsy can remain positive for ~14 days after starting steroids Waiting for a biopsy before starting any treatment (Option A) is associated with risks of permanent vision loss Begin methotrexate and low-dose aspirin (Option C): Methotrexate is not first-line therapy; it's used as a steroid-sparing agent in select cases Start Tocilizumab alone (Option D) is used in combination with steroids, not as monotherapy

References:

Harrison's Principles of Internal Medicine, 21st Edition, Volume I, Page. 2812

↑ *Back to this question in Part A*

@Neet_pg_bot

Q3: A 6-year-old boy presents with a bilateral lower extremity rash that appeared 2 weeks after an upper respiratory tract infection. He also complains of abdominal pain and joint pain. On examination, there is a symmetrically distributed palpable purpuric rash present over both lower extremities, predominantly on the extensor surfaces. Which of the following is the most likely diagnosis based on the clinical presentation and image findings? (Q851678)

A. Immune thrombocytopenic purpura (ITP)

B. IgA vasculitis (Henoch-Schönlein purpura)

C. Meningococcemia

D. Kawasaki disease

Correct Answer: B. IgA vasculitis (Henoch-Schönlein purpura)

Explanation: From the clinical scenario, IgA vasculitis is the most likely diagnosis. IgA vasculitis (Henoch-Schönlein purpura): Age & Presentation: Common in children 4–7 years; palpable purpura on lower extremities, often post-upper respiratory infection; symmetric rash, abdominal pain, arthralgias. Pathogenesis: IgA immune complex deposition in small vessels (skin, GI tract, kidneys, joints) → complement activation → inflammation with neutrophil recruitment. Clinical Tetrad: Palpable purpura (100%), arthralgia (75%), abdominal pain (70%), renal involvement (10–50%) with hematuria/proteinuria. Course: Usually self-limiting but requires monitoring for renal complications. Epidemiology: More common in males (1.5:1), peak incidence in spring. {{caption_text}} ITP (Option A): It presents with non-palpable purpura, mucosal bleeding, low platelet count, and no systemic symptoms like joint pain or abdominal pain. Meningococcemia (Option C): It presents acutely with a toxic appearance, rapidly progressive petechiae/purpura, associated with high fever and meningeal signs, not symmetric in distribution. Kawasaki disease (Option D): It presents with polymorphous rash (not purpuric), characteristic mucosal changes, cervical lymphadenopathy, and coronary artery involvement.


@Neet_pg_bot

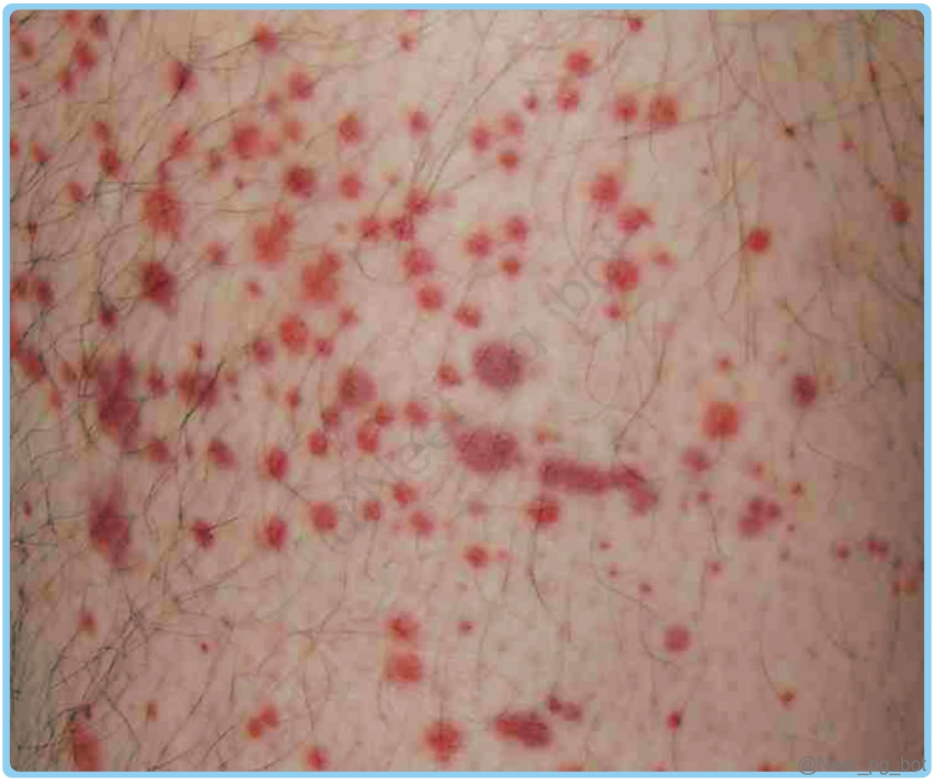





References:

Harrison’s Principles of Internal Medicine, 21st Edition, Volume I, Page. 2813, 2814

↑ *Back to this question in Part A*

@Neet_pg_bot

Q4: A 7-year-old boy presents with palpable purpura, abdominal pain, and joint pain. Laboratory studies show normal platelet count with elevated IgA levels. Which of the following statements about this condition is incorrect? (Q851680)

A. Renal biopsy is essential for confirming the diagnosis

B. Glucocorticoids help reduce arthralgias and abdominal discomfort

C. Glucocorticoids have not proven benefit in treating skin and renal manifestations

D. Complement levels are typically normal in this condition

Correct Answer: A. Renal biopsy is essential for confirming the diagnosis

Explanation: IgA vasculitis (Henoch-Schönlein purpura) is primarily a clinical diagnosis based on palpable purpura, abdominal pain, arthralgias, and renal involvement . Renal biopsy is reserved for severe or atypical cases . Glucocorticoids help reduce arthralgias and abdominal discomfort (Option B): They relieve pain and GI symptoms. Glucocorticoids have not proven benefit in treating skin and renal manifestations (Option C): Steroids do not significantly alter purpura or long-term renal outcomes . Complement levels are typically normal in this condition (Option D): C3 and C4 are usually normal in IgA vasculitis.

References:

Harrison’s Principles of Internal Medicine, 21st Edition, Volume I, Page. 2813, 2814

↑ *Back to this question in Part A*

@Neet_pg_bot

Q5: A 19-year-old Asian female presents with persistent malaise, fever, night sweats, and unequal blood pressure readings in both arms (right arm 130/80 mmHg, left arm 100/70 mmHg). ESR is elevated at 85 mm/hr, and MR angiography shows ostial narrowing of the left subclavian artery with pan-arteritis. Which statement describes the pathogenesis and initial management? (Q851682)

A. Primarily intimal disease; start anti-TNF therapy

B. Panarteritis; tocilizumab superior to steroids

C. Adventitial inflammation; methotrexate first-line

D. Panarteritis with intimal proliferation; start prednisone

Correct Answer: D. Panarteritis with intimal proliferation; start prednisone

Explanation: Takayasu arteritis is a granulomatous panarteritis affecting all layers of large arteries, leading to intimal proliferation and stenosis . High-dose glucocorticoids (prednisone) are the first-line therapy to control inflammation. Management: First Line: Steroids (40-60mg prednisone/day) Second Line: Methotrexate (up to 25mg/week) for steroid-refractory cases Primarily intimal disease; start anti-TNF therapy (Option A): The disease affects all layers, not just intima. Anti-TNF therapy isn't first-line and lacks randomized trial validation. Panarteritis; tocilizumab superior to steroids (Option B): While panarteritis is correct, Tocilizumab failed to show superiority in randomized trials. Adventitial inflammation; methotrexate first-line (Option C): Not limited to adventitia; affects all vessel layers. Methotrexate is the second-line for steroid-refractory cases.

References:

Harrison’s Principles Of Internal Medicine, 21st Edition, Volume I, Page. 2813

↑ *Back to this question in Part A*

@Neet_pg_bot

Q6: A 4-year-old child presents with fever, rash, and strawberry tongue. The child has circumoral pallor and a sandpaper-like rash. Laboratory investigations reveal elevated inflammatory markers. Which of the following statements is most likely to be true regarding this presentation? (Q851684)

A. IVIG with high-dose aspirin is the first-line treatment

B. The rash begins over the face and shows circumoral erythema

C. Throat culture is essential for diagnosis and Penicillin is the treatment of choice

D. Coronary artery involvement is seen in the majority of untreated cases

Correct Answer: C. Throat culture is essential for diagnosis and Penicillin is the treatment of choice

Explanation: The clinical presentation suggests scarlet fever with classic features like circumoral pallor, strawberry tongue, and sandpaper rash. Throat culture for group A streptococcus is diagnostic Penicillin is the treatment of choice to prevent complications This is primarily a toxin-mediated process from GAS (Group A Streptococci) infection IVIG with high-dose aspirin (Option A): This is treatment for Kawasaki disease , which presents with conjunctivitis, extremity changes, and lymphadenopathy, not a sandpaper rash. Rash begins over the face with circumoral erythema (Option B): Scarlet fever rash typically starts on the trunk and groin , sparing the perioral area (circumoral pallor), not beginning on the face. Coronary artery involvement in the majority of untreated cases (Option D): Occurs in Kawasaki disease , not scarlet fever.

References:

Harrison’s Principles Of Internal Medicine, 21st Edition, Volume I, Page. 137, 253, 1191, 2816

↑ *Back to this question in Part A*

@Neet_pg_bot

Q7: Match the markers (Column B) with the correct vasculitis (Column A). a. Granulomatosis with Polyangiitis (GPA) 1. C-ANCA b. Polyarteritis Nodosa (PAN) 2. P-ANCA 3. Proteinase-3 4. Myeloperoxidase (Q851686)

A. a → 1,3 b → 2,4

B. a → 2,4 b → 1,3

C. a → 1,3 b → None

D. a → None b → 1,3

Correct Answer: C. a → 1,3 b → None

Explanation: a → C-ANCA, PR3 Granulomatosis with polyangiitis (GPA) is classically associated with C-ANCA directed against Proteinase-3 (PR3) . b → No ANCA association Polyarteritis nodosa (PAN) is a medium-vessel vasculitis and is not ANCA-associated . It typically shows negative ANCA .

References:

www.ncbi.nlm.nih.gov/books/NBK482157/#:~:text=Polyarteritis%20nodosa%20(PAN)%20is%20a,affect%20small%2Dsized%20arterial%20vessels.

↑ *Back to this question in Part A*

@Neet_pg_bot

Q8: A 45-year-old patient presents with fever, purpura, and arthralgias. Biopsy shows small vessel vasculitis with absent immune deposits. Lab tests reveal C-ANCA antibodies. Which of the following is most consistent with this clinical picture? (Q851688)

A. Microscopic polyangiitis with segmental necrotizing glomerulonephritis

B. Granulomatosis with polyangiitis with pauci-immune glomerulonephritis

C. Churg-Strauss syndrome with peripheral eosinophilia

D. Mixed cryoglobulinemia with Hepatitis-C

Correct Answer: B. Granulomatosis with polyangiitis with pauci-immune glomerulonephritis

Explanation: The presence of C-ANCA (anti-PR3) along with small vessel vasculitis and systemic symptoms (fever, purpura, arthralgias) is characteristic of Granulomatosis with Polyangiitis (GPA) . GPA often causes pauci-immune glomerulonephritis . Microscopic polyangiitis with segmental necrotizing glomerulonephritis (Option A): Usually P-ANCA (anti-MPO) positive; lacks granulomatous inflammation. Churg-Strauss syndrome with peripheral eosinophilia (Option C): Associated with asthma and eosinophilia, often P-ANCA positive. Mixed cryoglobulinemia with Hepatitis-C (Option D): Immune complex-mediated vasculitis; not ANCA-associated.

References:

Harrison’s Principle of Internal Medicine 21st Edition Page 2340

↑ *Back to this question in Part A*

@Neet_pg_bot

Q9: A 25-year-old man from Turkey presents with recurrent painful oral ulcers, genital ulcers, and bilateral red eyes. Examination reveals bilateral anterior uveitis and erythema nodosum on his legs. After the needle prick, he develops an erythematous papule in 48 hours. Laboratory studies show elevated IL-1, TNF-α, and increased neutrophil activity. Which of the following best describes the pathogenesis and clinical features of this condition? (Q851690)

A. ANCA-mediated vasculitis with small vessel involvement

B. Auto-inflammatory vasculitis with T-cell mediated immunity and neutrophilic inflammation

C. Antibody-mediated disease with preferential renal involvement

D. IgA-mediated vasculitis with predominant GI manifestations

Correct Answer: B. Auto-inflammatory vasculitis with T-cell mediated immunity and neutrophilic inflammation

Explanation: This patient presents with classic features of Behcet's Disease. The pathogenesis of Behcet’s Disease involves auto-inflammatory vasculitis with T-cell mediated immunity and neutrophilic inflammation. Clinical Features: {{caption_text}} ANCA-mediated vasculitis with small vessel involvement (Option A): ANCA-associated vasculitides, such as granulomatosis with polyangiitis , typically involve the respiratory tract and kidneys and do not present with recurrent oral and genital ulcers or a positive pathergy test. Antibody-mediated disease with preferential renal involvement (Option C): This option suggests diseases like lupus nephritis, which involves antibody-mediated kidney damage. However, renal involvement is not a primary

feature of Behçet's disease. IgA-mediated vasculitis with predominant GI manifestations (Option D): IgA vasculitis (Henoch-Schönlein purpura) often presents with palpable purpura, GI symptoms, and renal involvement, which are inconsistent with the features seen in this patient.

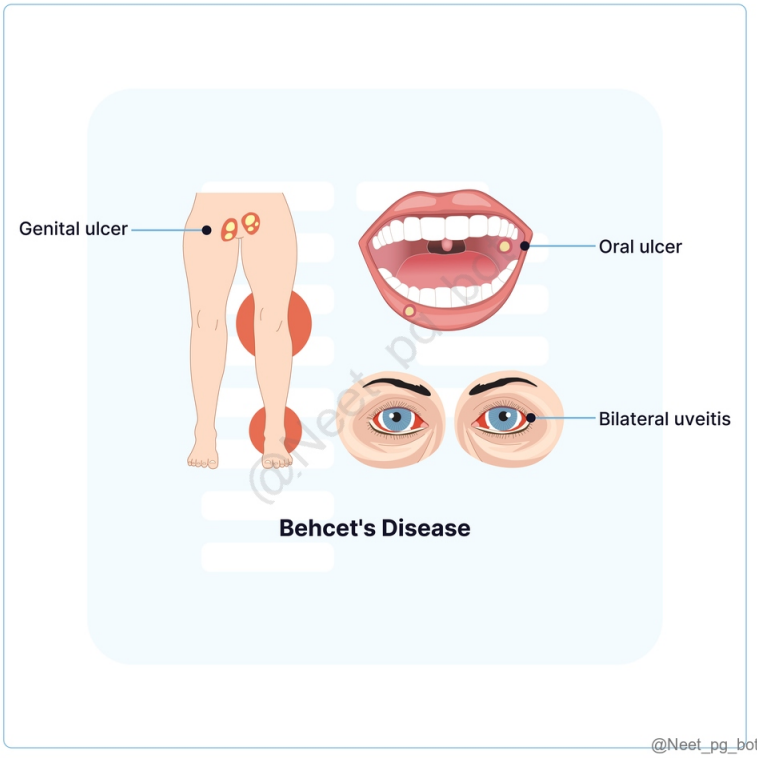

References:

www.ncbi.nlm.nih.gov/books/NBK470257/

Harrison’s Principle of Internal Medicine 21st Edition Page 2817, 2818

↑ *Back to this question in Part A*

@Neet_pg_bot

Q10: A 30-year-old man presents with recurrent oral ulcers, genital ulcers, and bilateral uveitis. He develops pustules 48 hours after the needle prick. Further examination reveals erythema nodosum and non-erosive arthritis of the knees. Based on clinical criteria, Behcet's Disease is diagnosed. Which of the following represents the most appropriate initial management strategy? (Q851692)

A. High-dose steroids alone for all manifestations

B. Targeted therapy based on organ involvement: colchicine for mucocutaneous, topical steroids for anterior uveitis

C. Immediate cyclophosphamide for all patients

D. Anticoagulation alone for all manifestations

Correct Answer: B. Targeted therapy based on organ involvement: colchicine for mucocutaneous, topical steroids for anterior uveitis

Explanation: This patient presents with various manifestations of Behcet's Disease requiring organ-specific management. Targeted therapy based on organ involvement: Mucocutaneous Treatment Colchicine 1-2mg/day Topical steroids Topical sucralfate Refractory: Systemic steroids, azathioprine Ocular Treatment Anterior: Topical steroids Posterior: Steroids + azathioprine Refractory: TNF inhibitors Major Organ Involvement Vascular: High-dose steroids + cyclophosphamide Neurologic: High-dose steroids + immunosuppression Requires aggressive therapy and monitoring High-dose steroids alone for all manifestations (Option A) is incorrect because treatment needs to be targeted to specific organ involvement rather than blanket steroid therapy. Immediate cyclophosphamide for all patients (Option C) is incorrect because cyclophosphamide is reserved for severe manifestations like neurologic or major vascular involvement. Anticoagulation alone for all manifestations (Option D) is incorrect because anticoagulation alone is insufficient and immunosuppression is the mainstay of therapy.

References:

www.ncbi.nlm.nih.gov/books/NBK470257/

Harrison’s Principle of Internal Medicine 21st Edition Page 2817, 2818

↑ *Back to this question in Part A*

@Neet_pg_bot

Q11: A 4-year-old Asian boy presents with 6 days of fever, bilateral conjunctival injection without exudate, strawberry tongue, and cervical lymphadenopathy >1.5 cm. On day 7, he develops erythema of palms and soles. Laboratory studies show elevated TNF-α and pro-BNP. Which of the following best describes the pathogenesis of this condition? (Q851694)

A. Direct viral invasion of coronary vessels with late thrombosis

B. Immune-mediated medium vessel vasculitis with coronary artery predilection

C. Bacterial toxin-mediated endothelial damage with early thrombosis

D. Primary autoimmune arteritis with small vessel involvement

Correct Answer: B. Immune-mediated medium vessel vasculitis with coronary artery predilection

Explanation: This patient's clinical features are highly suggestive of Kawasaki Disease, presenting with prolonged fever for 6 days accompanied by classic mucocutaneous findings including bilateral non-exudative conjunctivitis, strawberry tongue, unilateral cervical lymphadenopathy >1.5cm, and erythema of palms and soles. Pathogenesis: Respiratory pathogen → Immune cascade activation → ↑TNF-α, ↑IL-1/4/6 → MMP3 & MMP9 release → Oligoclonal IgA plasma cells → Medium-vessel vasculitis (coronary arteries) → Arteritis & aneurysm formation Direct viral invasion of coronary vessels with late thrombosis (Option A) is incorrect because Kawasaki disease is not a direct viral invasion, but rather an immune response to a possible infectious trigger. Bacterial toxin-mediated endothelial damage with early thrombosis (Option C) is incorrect because it's not bacterial toxin-mediated and early thrombosis isn't typical. Primary autoimmune arteritis with small vessel involvement (Option D) is incorrect because it primarily affects medium vessels, not small vessels.

References:

www.ncbi.nlm.nih.gov/books/NBK537163/

Harrison's Principle of Internal Medicine 21st Edition Page 393, 2816

↑ *Back to this question in Part A*

@Neet_pg_bot

Q12: A 3-year-old boy presents with 6 days of fever, bilateral conjunctivitis, strawberry tongue, and polymorphous rash. Initial labs show elevated CRP, ESR, and thrombocytosis. Which of the following represents the most appropriate initial diagnostic test and treatment strategy? (Q851695)

A. Blood culture and broad-spectrum antibiotics

B. Echocardiogram and IVIG 2g/kg plus high-dose aspirin

C. Throat culture and penicillin

D. Viral panel and supportive care

Correct Answer: B. Echocardiogram and IVIG 2g/kg plus high-dose aspirin

Explanation: This patient presents with classic features of Kawasaki Disease (KD) including: Fever for >= 5 days + 4 out of 5 criteria (CREAM) C : Conjunctivitis (bilateral, non-purulent) R : Rash (polymorphous) E : Extremity changes (swelling, redness, peeling) A : Adenopathy (cervical >1.5cm) M : Mucosal changes (strawberry tongue) Echocardiogram and IVIG 2g/kg plus high-dose aspirin (Option B) is the correct treatment because: Echocardiogram is essential for baseline assessment of coronary arteries and identifying any early aneurysm formation IVIG 2g/kg must be given within 10 days of fever onset to reduce risk of coronary artery aneurysms from 25% to 3-5% High-dose aspirin (80-100mg/kg/day) is indicated during the acute phase for its anti-inflammatory effects This combined approach represents the standard of care that has been proven to reduce

cardiac complications Blood culture and broad-spectrum antibiotics (Option A) is incorrect because bacterial infection is not the primary concern and antibiotics are not indicated. Throat culture and penicillin (Option C) is incorrect because streptococcal infection is not the likely diagnosis given the constellation of findings. Viral panel and supportive care (Option D) is incorrect because Kawasaki disease requires specific treatment, not just supportive care.

References:

www.ncbi.nlm.nih.gov/books/NBK537163/

Harrison's Principle of Internal Medicine 21st Edition Page 393, 2816

↑ *Back to this question in Part A*

@Neet_pg_bot

Q13: A 40-year-old man with a history of asthma presents with worsening dyspnea, peripheral neuropathy, and palpable purpura on his lower limbs. He also has a history of sinusitis. Blood tests reveal marked eosinophilia and a positive p-ANCA. What is the most likely diagnosis? (Q851696)

A. Wegener's Granulomatosis

B. Churg-Strauss Syndrome

C. Microscopic Polyangiitis

D. Polyarteritis Nodosa

Correct Answer: B. Churg-Strauss Syndrome

Explanation: Churg-Strauss Syndrome aka Eosinophilic Granulomatosis with Polyangiitis (EGPA) is most commonly associated with a history of asthma , marked eosinophilia , and systemic vasculitis involving the skin, lungs, nerves, and sinuses. The positive p-ANCA result further supports the diagnosis Management: Acute : High-dose glucocorticoids and cyclophosphamide. Maintenance : Low-dose glucocorticoids and azathioprine, methotrexate, or mycophenolate mofetil (MMF). Wegener's Granulomatosis (Granulomatosis with Polyangiitis) (Option A) : This vasculitis affects the upper and lower respiratory tract and kidneys but is more commonly associated with c-ANCA positivity, rather than p-ANCA. Additionally, patients with Wegener's typically do not have prominent eosinophilia, which is a hallmark of EGPA. Microscopic Polyangiitis (MPA) (Option C): This small-vessel vasculitis is typically associated with p-ANCA and necrotizing vasculitis, affecting organs like the kidneys and lungs. However, MPA does not present with the asthma or eosinophilia characteristic of EGPA. It is also not typically associated with palpable purpura. Polyarteritis Nodosa (PAN) (Option D) : PAN is a medium-vessel vasculitis that affects arteries, commonly leading to renal, gastrointestinal, and musculoskeletal involvement, but PAN does not typically present with eosinophilia, asthma, or p-ANCA. It is also not associated with the characteristic findings of pulmonary infiltrates seen in EGPA.

References:

Davidson's Principles and Practice of Medicine, 24th edition, Page 1043.

↑ *Back to this question in Part A*

@Neet_pg_bot

Q14: Which of the following vasculitis syndromes is not classified as an ANCA-associated vasculitis according to the Chapel Hill Classification? (Q851697)

A. Granulomatosis with Polyangiitis (GPA)

B. Microscopic Polyangiitis (MPA)

C. Eosinophilic Granulomatosis with Polyangiitis (EGPA)

D. Polyarteritis Nodosa (PAN)

Correct Answer: D. Polyarteritis Nodosa (PAN)

Explanation: Polyarteritis Nodosa is a medium vessel vasculitis, according to the Revised Chapel Hill classification of vasculitis syndromes {{caption_text}}

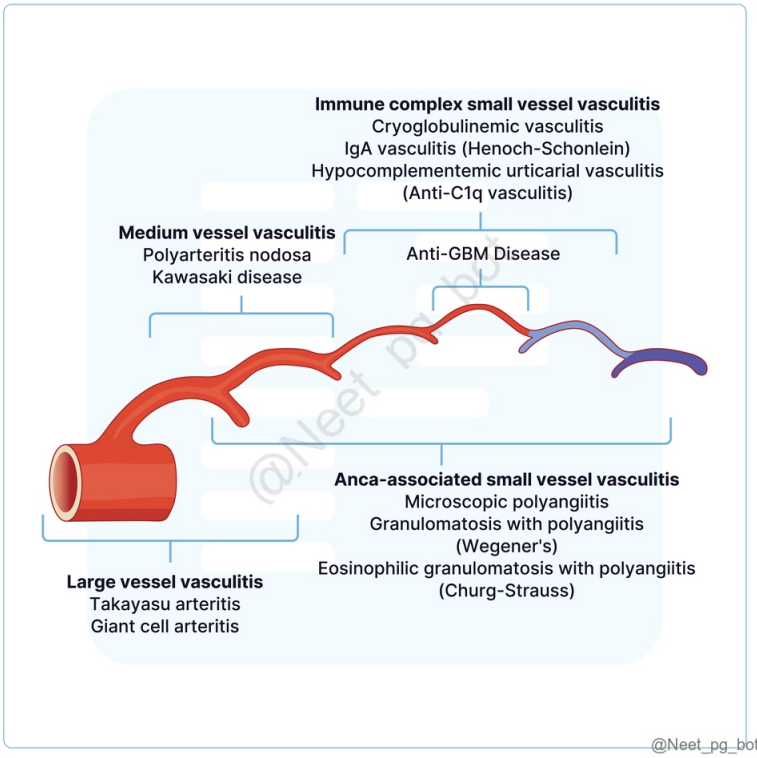

References:

https://pmc.ncbi.nlm.nih.gov/articles/PMC4029362/

↑ *Back to this question in Part A*

@Neet_pg_bot

Q15: A 4-year-old kid comes to your clinic with his mother. His mother complains that he has had an acute fever and abdominal pain for 2 days. You examine the child and find out that the skin on the buttocks and extensor surfaces of arms and legs are covered with small round patches of blue-purple discoloration. You also find out that the kid has hematuria. You have diagnosed it as a case of Henoch Schonlein Purpura. Henoch-Schonlein purpura, a vasculitis, is characterized by which of the following symptoms? (Q882172)

A. Erythromelalgia

B. Glomerulonephritis, hematochezia and palpable purpura

C. Lhermitte’s sign

D. Virchow’s triad

Correct Answer: B. Glomerulonephritis, hematochezia and palpable purpura

Explanation: Option B: Glomerulonephritis, hematochezia and palpable purpura Henoch – schonlein purpura: Henoch- Schonlein Purpura is a type of vasculitis that affects small vessels. It is also called Non-thrombocytopenic purpura. Henoch Schonlein purpura is the most prevalent form of childhood systemic vasculitis. It affects males more than females. Children are affected more than adults. Symptoms: The following features characterize it: It is a form of vasculitis with glomerulonephritis as a key feature. Glomerulonephritis can present as proteinuria, hematuria, and acute renal failure . Gastrointestinal presentation of HSP includes intermittent, colicky abdominal pain and hemorrhage into the bowels, which presents as hematochezia. Skin involvement in HSP presents as blotchy purple spots on the skin, the purpura. Purpura on the skin is palpable. There is also non-deforming polyarthritis, marked at the hips, knees, and ankles. Diagnosis: On skin biopsy , there is leukocytoclastic vasculitis with IgA and C3 deposition in the vessel wall. Treatment: Treatment for Henoch Schonlein purpura is usually supportive. Steroids are also used for severe or renal diseases. Option A: Erythromelalgia Erythromelalgia is a very rare condition. It has features of severe, burning pain in the limbs it affects. It has diffuse red discolouration but does not necessarily have a pattern. There is no rash of Erythromelalgia. Erythromelalgia is seen in conditions such as thrombocythemia and polycythemia Vera. In some cases, it can be treated with Aspirin. Option C: Lhermitte's sign Lhermitte's sign is also called Lhermitte's phenomenon. It is a feeling of a gradient-like electric sensation that goes down the spine upon flexion of the neck. It is seen in cases of Multiple sclerosis. It is a sequela of neurologic disorders. Multiple sclerosis is a chronic relapsing and remitting type of autoimmune disease. In multiple sclerosis, the myelin destruction and destruction of oligodendrocytes are the main pathologies. Option D:

Virchow's triad Virchow's triad includes three factors: Intravascular damage of vessels, stasis in blood flow, hypercoagulable state. It may lead a person to develop thrombosis of veins Thrombosis means there is a formation of clots in blood vessels. Virchow's triad determines whether a person is at risk of developing thrombotic disorders. Thromboembolic events could include cerebrovascular disorders, pulmonary embolism and deep vein thrombosis.

References:

Harrison 20th edition page no : 2586

↑ *Back to this question in Part A*

@Neet_pg_bot

• [08_Rheumatology] 061 Sle Anti Phospholipid Syndrome

« Back to Folder Directory

[08_Rheumatology] 061 Sle Anti Phospholipid Syndrome — Quick Jump

Q1 (p. 2564) *Q2 (p. 2565)* *Q3 (p. 2568)* *Q4 (p. 2569)* *Q5 (p. 2570)* *Q6 (p. 2570)*
Q7 (p. 2571) *Q8 (p. 2576)* *Q9 (p. 2576)* *Q10 (p. 2577)* *Q11 (p. 2578)* *Q12 (p. 2579)*
Q13 (p. 2580) *Q14 (p. 2581)*

Q1: A 25-year-old woman presents with fatigue, joint pain, and a photosensitive rash. She reports mouth ulcers and hair loss. Laboratory tests show positive ANA and elevated anti-ds DNA antibodies. Further examination reveals elevated levels of IFN-α. Which of the following is a consequence of elevated IFN-α in this condition? (Q851381)

A. Decreased B cell activation

B. Enhanced clearance of apoptotic cells

C. Suppression of T cell activity

D. Increased antibodies production

Correct Answer: D. Increased antibodies production

Explanation: The clinical presentation of fatigue, joint pain, photosensitive rash, mouth ulcers, hair loss, positive ANA and anti-dsDNA antibodies suggest systemic lupus erythematosus (SLE). Elevated levels of IFN-α play a crucial role in SLE pathogenesis by promoting B cell activation and increasing antibody production , particularly autoantibodies such as anti-dsDNA. Decreased B cell activation (Option A): IFN-α promotes B cell activation and survival, not decreases it . This contributes to autoantibody production in SLE. Enhanced clearance of apoptotic cells (Option B) : In SLE, clearance is defective , contributing to accumulation of nuclear debris → triggers autoimmunity. Suppression of T cell activity (Option C): IFN-α activates dendritic cells and promotes T cell activation , not suppression.

References:

Harrison’s Principles of Internal Medicine, 21st Edition, Page 2737

Davidson’s Principles and Practice of Medicine, 24th Edition, Page 1034

↑ *Back to this question in Part A*

@Neet_pg_bot

Q2: A 30-year-old woman presents with a history of recurrent fever, myalgia, photosensitivity, and joint pain. On examination, multiple erythematous plaques with adherent scales are noted on her face and scalp. What is the most likely diagnosis? (Q851385)

A. Urticarial eruptions

B. Malar rash

C. Subacute cutaneous lupus erythematosus (SCLE)

D. Discoid lupus erythematosus

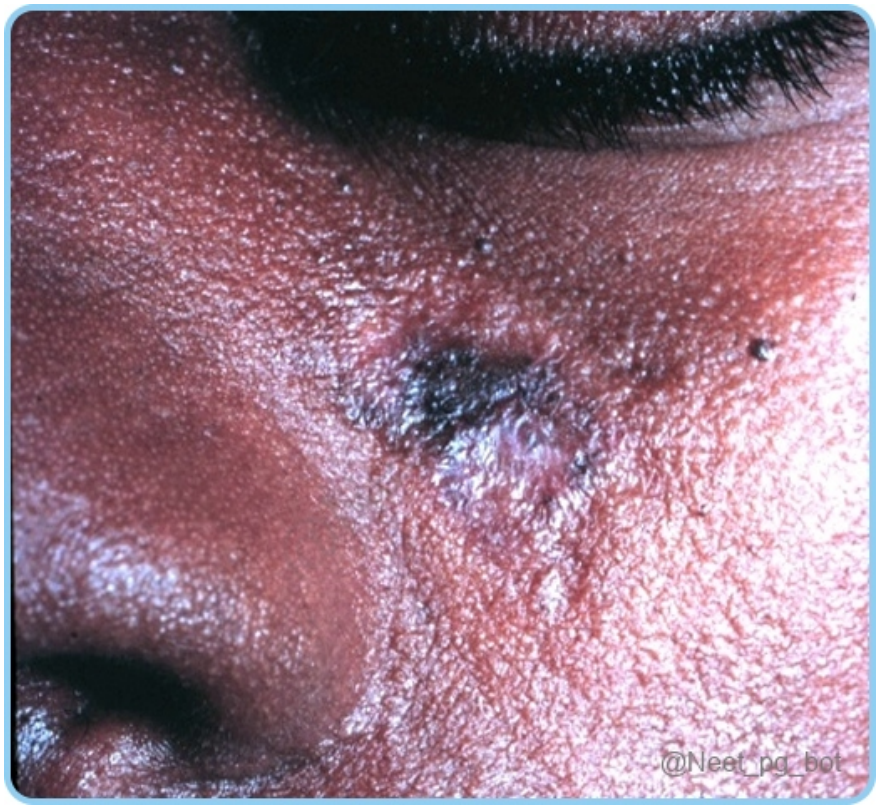

Correct Answer: D. Discoid lupus erythematosus

Explanation: The patient's symptoms of recurrent fever, myalgia, photosensitivity, and joint pain, along with erythematous plaques with adherent scales on the face and scalp, suggest Discoid Lupus Erythematosus (DLE), a chronic cutaneous form of lupus. It is characterised by round, scaly, slightly raised, erythematous plaques with hyperpigmented rims and depigmented centres that occur due to damage to all the dermal appendages. Mucocutaneous symptoms of SLE Malar rash/ Butterfly rash is photosensitive and involves the cheeks and nose, sparing the nasolabial folds. (Option B) {{caption_text}} Discoid lupus erythematosus {{caption_text}} Subacute cutaneous lupus erythematosus are scaly, red, circular or flat, annular lesions, similar to psoriasis (Option C) {{caption_text}} Ulcers Lichen planus {{caption_text}} Urticarial eruptions are red or skin-coloured, raised, and

surrounded by a halo of redness (Option A) {{caption_text}}






@Neet_pg_bot


@Neet_pg_bot



References:

Harrison’s Principles of Internal Medicine, 21st Edition, Page 2740

Davidson’s Principles and Practice of Medicine, 24th Edition, Page1035

↑ *Back to this question in Part A*

@Neet_pg_bot

Q3: A 26-year-old woman presents with chest pain worsened by deep breathing, shortness of breath, fatigue, joint pain, and a photosensitive facial rash. Physical examination reveals tenderness over the chest wall and mild joint swelling. Laboratory tests show positive ANA and elevated anti-dsDNA antibodies. A chest X-ray shows mild pleural effusion. Which of the following pulmonary complications is most likely associated with her condition? (ARDS: Acute Respiratory Distress Syndrome) (Q851390)

A. ARDS

B. Shrinking lung syndrome

C. Pulmonary hypertension

D. Pleuritis

Correct Answer: D. Pleuritis

Explanation: The patient's presentation of chest pain that worsens with deep breathing, along with a history of fatigue, joint pain, photosensitivity, and positive autoimmune markers (ANA, anti-dsDNA), suggests Systemic Lupus Erythematosus (SLE) . Pleuritis is the most common pulmonary manifestation of SLE, and it can present with or without effusion. Pulmonary Systemic Involvement in SLE Pleuritis (most common): Prevalence (30 - 50%) Pneumonitis Atelectasis Reduced lung volume and Pulmonary ■brosis Shrinking lung syndrome, (< 5%) (Option B ruled out) Intra-alveolar hemorrhage Pulmonary HTN (< 5 %) (Option C ruled out) Acute Respiratory Distress Syndrome (ARDS) (< 5%) (Option A ruled out)

References:

Harrison’s Principles of Internal Medicine, 21st Edition, Page 2740, 2741, 2742, 2743.

↑ *Back to this question in Part A*

@Neet_pg_bot

Q4: A 28-year-old woman presents with joint pain and skin rashes after being treated with trimethoprim-sulfamethoxazole for a recent infection. She has a history of Systemic lupus erythematosus. Laboratory tests reveal positive anti-dsDNA antibodies. Which of the following antibodies would be more specific for diagnosing the cause of her symptoms? (Q851392)

A. Anti-Ro

B. Anti-RNP

C. Anti-C1q

D. Antihistone

Correct Answer: D. Antihistone

Explanation: Antihistone antibodies are the most specific antibodies for diagnosing drug-induced lupus. Antibodies Clinical significance Anti-C1q (Option C ruled out) Associated with active lupus nephritis , it is non-specific for SLE and can be used to correlate with disease activity. Deficiency predisposes SLE. Anti-RNP (Option B ruled out) Non-specific to SLE and is associated with syndromes that overlap with rheumatic syndromes Anti-Ro (SS-A) (Option A ruled out) Not very specific , it is associated with sicca syndrome and neonatal lupus (congenital heart block)

References:

Harrison’s Principles of Internal Medicine, 21st Edition, Page 2738

↑ *Back to this question in Part A*

@Neet_pg_bot

Q5: A 27-year-old woman presents with joint pain, fatigue, and a malar rash. Laboratory tests reveal positive ANA and anti-dsDNA antibodies. According to the EULAR/ACR classification criteria, which of the following criteria is not required for diagnosis? (Q851394)

A. Antiphospholipid antibodies

B. Serositis

C. Neuropsychiatric symptoms

D. Ocular symptoms

Correct Answer: D. Ocular symptoms

Explanation: Though GI and ocular symptoms are part of SLE manifestations, they aren't included in the EULAR/ACR Classification Criteria for SLE. This classification includes both clinical & immunological criteria; the patient must fulfil at least one clinical criterion, and ≥10 points are classified. ANA positive (titer of ≥ 1:80 on Hep-2 cells) is the required entry criteria to classify SLE.

References:

Harrison’s Principles of Internal Medicine, 21st Edition, Page 2741, 2740.

↑ *Back to this question in Part A*

@Neet_pg_bot

Q6: A 25-year-old woman presents with fatigue, a malar rash, and joint pain. Laboratory tests show positive anti-dsDNA, anti-Smith antibodies, and a positive ANA. She undergoes a renal biopsy that reveals features consistent with lupus nephritis. Based on the SLICC criteria, which of the following statements is true? (Q851395)

A. Four clinical criteria must be met to confirm SLE

B. Renal biopsy indicating lupus with lupus autoantibodies is sufficient

C. At least 2 clinical criteria with one antibody confirms SLE

D. Presence of Anti-ds, Anti-Sm and ANA confirms SLE

Correct Answer: B. Renal biopsy indicating lupus with lupus autoantibodies is sufficient

Explanation: The SLICC (Systemic Lupus International Collaborating Clinics) criteria state that SLE can be diagnosed if a patient meets 4 criteria, including at least 1 clinical and 1 immunological criterion. However, SLE can also be diagnosed if a renal biopsy shows lupus nephritis and the patient has positive ANA or anti-dsDNA antibodies, regardless of meeting other clinical or immunological criteria. Systemic Lupus International Collaborating Clinic (SLICC) Criteria Clinical Manifestations Immunological Manifestations Skin: Acute cutaneous lupus erythematosus (photosensitive, malar, maculopapular, bullous) Chronic cutaneous lupus erythematosus (discoid lupus, panniculitis, lichen planus-like, hypertrophic verrucous, chill blains) ANA > reference negative value Anti-dsDNA > reference (if by ELISA, 2× reference) Anti-Sm Antiphospholipid antibodies Lupus anticoagulant Anticardiolipin Anti–β2-glycoprotein1 Low serum complement (C3, C4, or CH50) Positive direct Coombs test Oral or nasal ulcers Nonscarring alopecia Synovitis involving ≥2 joints Serositis (Pleurisy or pericarditis) Renal: Protein-to-creatinine ratio (Prot/Cr) ≥0.5 RBC casts Renal biopsy indicating lupus (Wire-loop lesions) Neurologic: Seizures Psychosis Mononeuritis & myelitis Peripheral/Cranial neuropathies Acute confusional state Hematology: Hemolytic anemia Leukopenia (<4000/μL) Lymphopenia (<1000/μL) Thrombocytopenia (<100,000/μL) Classification Criteria: At least 4 criteria must be present , with at least 1 from the clinical manifestations and 1 from the immunologic manifestations. (Option A, C and D ruled out) A renal biopsy indicating lupus nephritis qualifies as systemic lupus erythematosus (SLE) if any lupus autoantibodies are present, even if the total criteria are < 4. (Option B)

References:

Harrison’s Principles of Internal Medicine, 21st Edition, Page 2739, 2740

↑ *Back to this question in Part A*

@Neet_pg_bot

Q7: A 32-year-old woman with known systemic lupus erythematosus presents with new-onset hypertension and elevated creatinine. Urinalysis shows hematuria and proteinuria. Renal biopsy reveals glomerular inflammation involving >50% of glomeruli. Which class of lupus nephritis does this most likely represent? (Q851398)

A. Class V

B. Class II

C. Class III

D. Class IV

Correct Answer: D. Class IV

Explanation: The patient's renal biopsy shows diffuse glomerular inflammation involving over 50% of glomeruli corresponds to Class IV lupus nephritis. Classification of Lupus nephritis Class II: Mesangial Proliferative Lupus Nephritis (Option B ruled out) Light microscopy : Mesangial hypercellularity (or) matrix expansion Mesangial immune deposits Subepithelial or subendothelial deposits may be present. {{caption_text}} {{caption_text}} Class III: Focal Lupus Nephritis Class III (A): Active lesions—focal proliferative lupus nephritis. Class III (C): Chronic inactive lesions—focal sclerosing lupus nephritis. Class III (A/C): Active and chronic lesions (Option C ruled out) Active or inactive glomerulonephritis involving ≤50% of all glomeruli. Focal subendothelial immune deposits and possible mesangial alterations {{caption_text}} Class IV: Diffuse Lupus Nephritis Class IV-S: Diffuse segmental lupus nephritis (≥50% of involved glomeruli have segmental lesions). Class IV-G: Diffuse global lupus nephritis (≥50% of involved glomeruli have global lesions). Class IV (A): Active lesion Class IV (A/C): Active and chronic lesion Class IV (C): Chronic inactive lesions with scars (Option D) Active or inactive glomerulonephritis involving ≥50% of all glomeruli. Diffuse subendothelial immune deposits and possible mesangial alterations. Wire-loop lesions in IF {{caption_text}} Class V: Membranous Lupus Nephritis (Option A ruled out) Global or segmental subepithelial immune deposits. Morphologic sequelae are observable by light microscopy, immunofluorescence, or electron microscopy, with or without mesangial alterations. It may coexist with class III or IV LN. {{caption_text}} {{caption_text}}

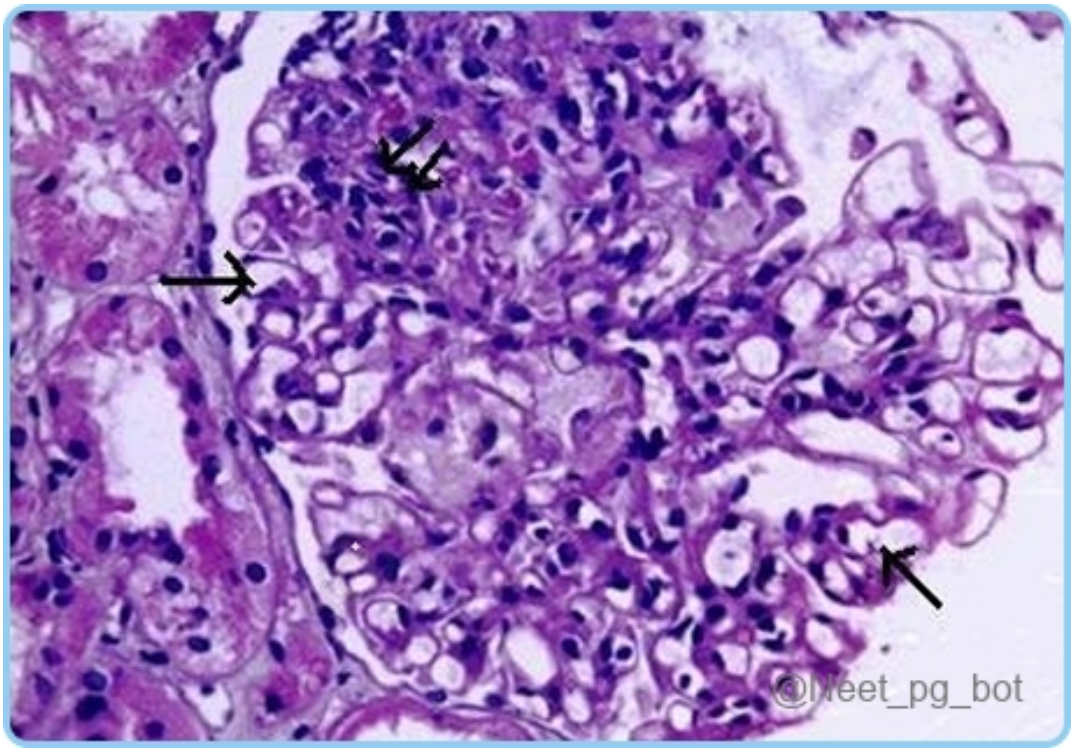

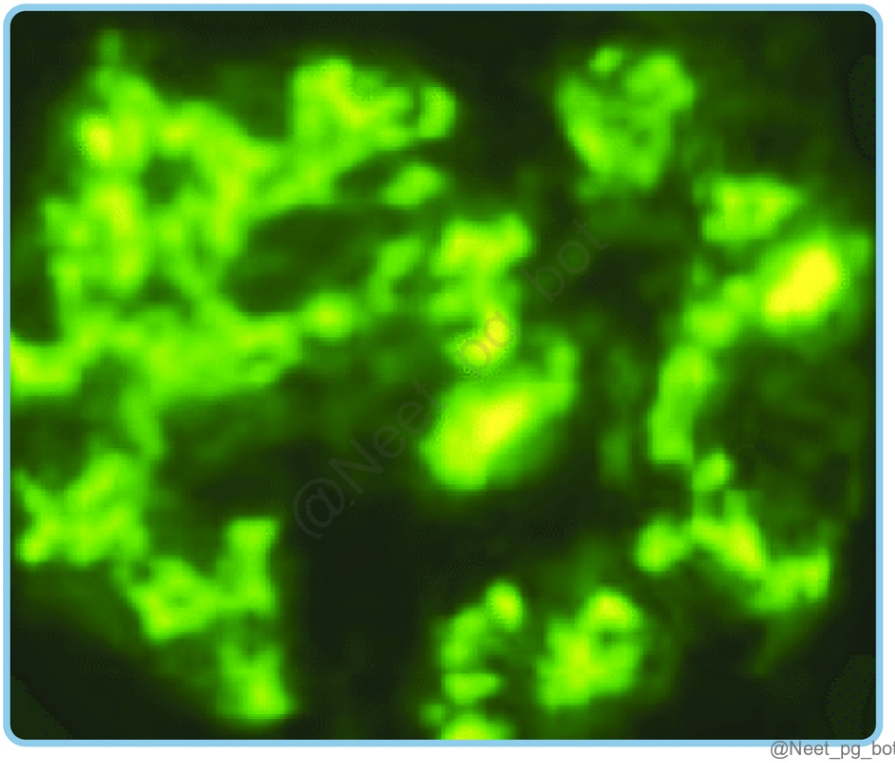

@Neet_pg_bot

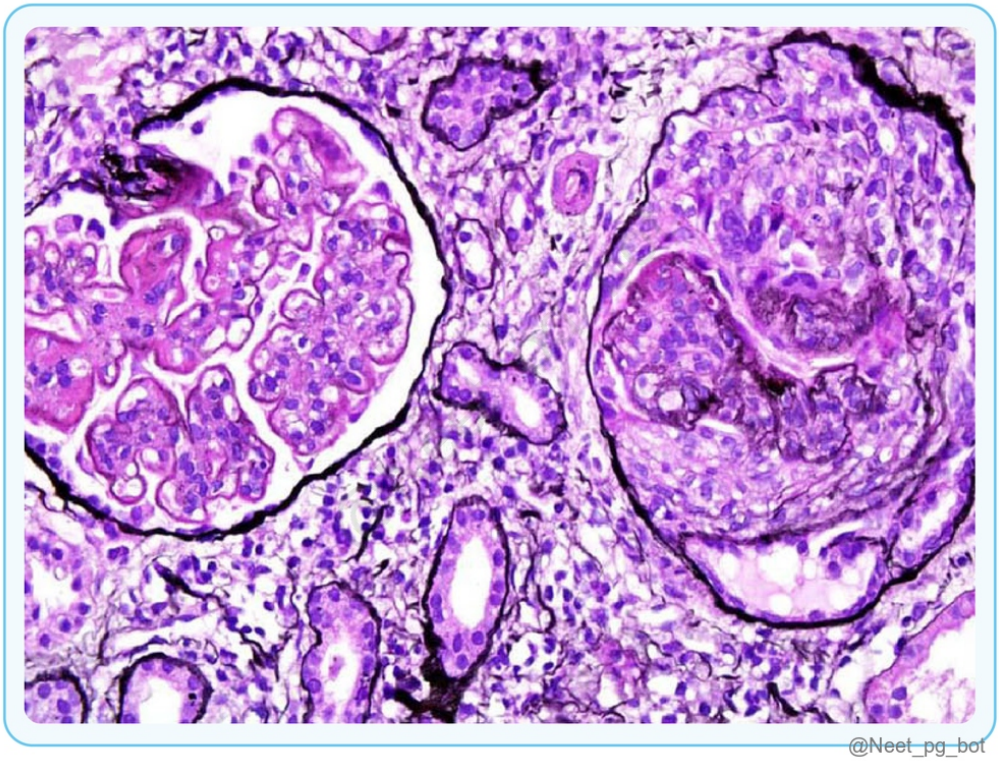

@Neet_pg_bot

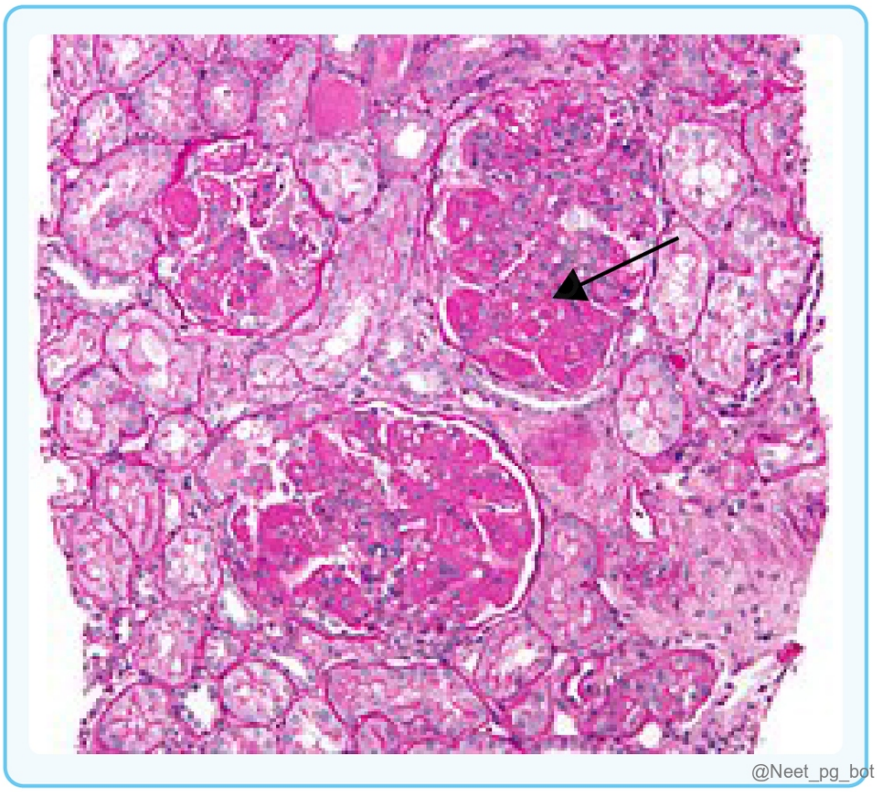
@Neet_pg_bot

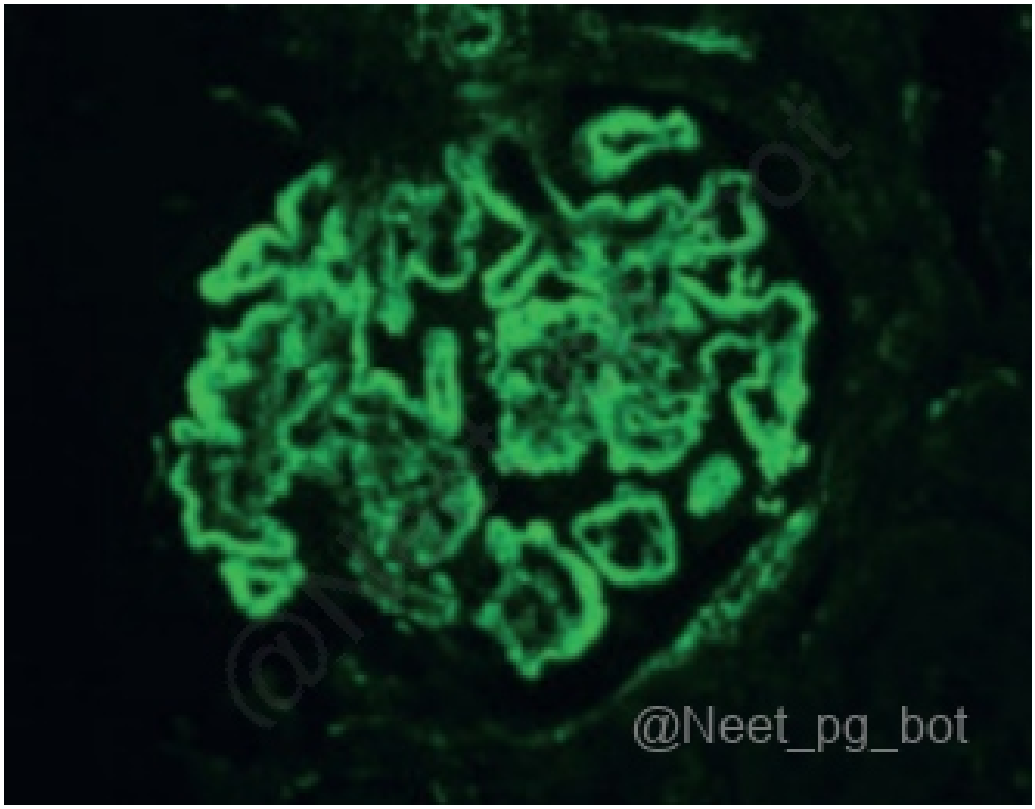
@Neet_pg_bot

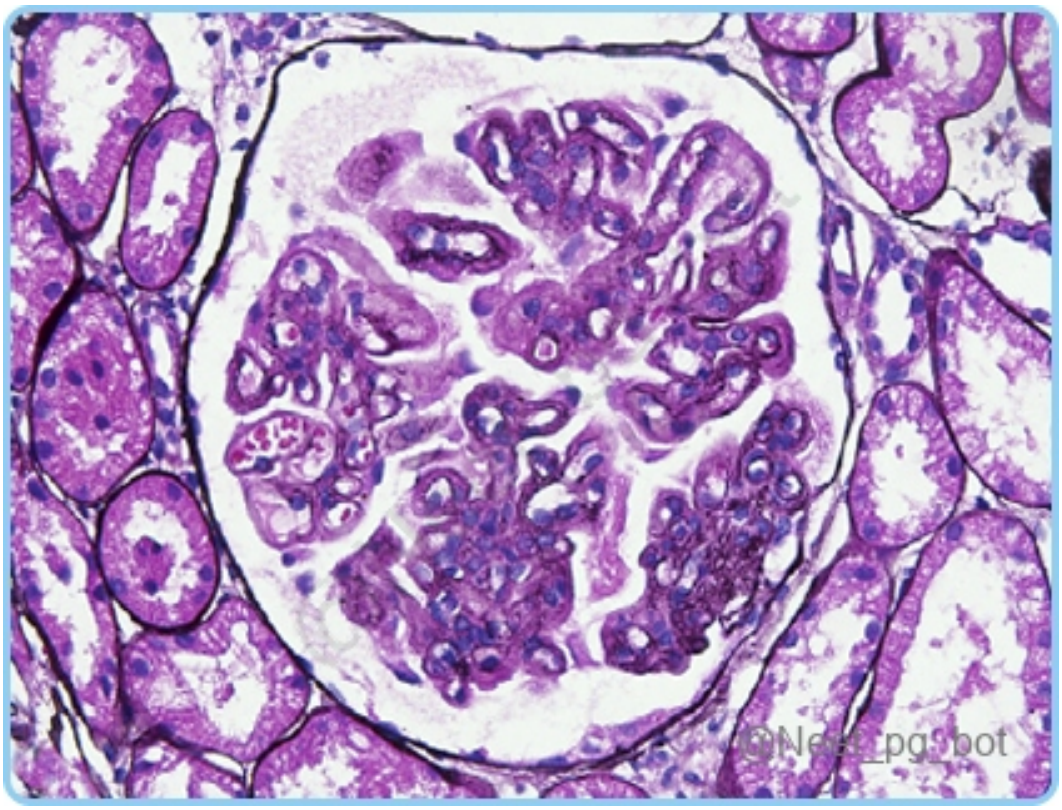

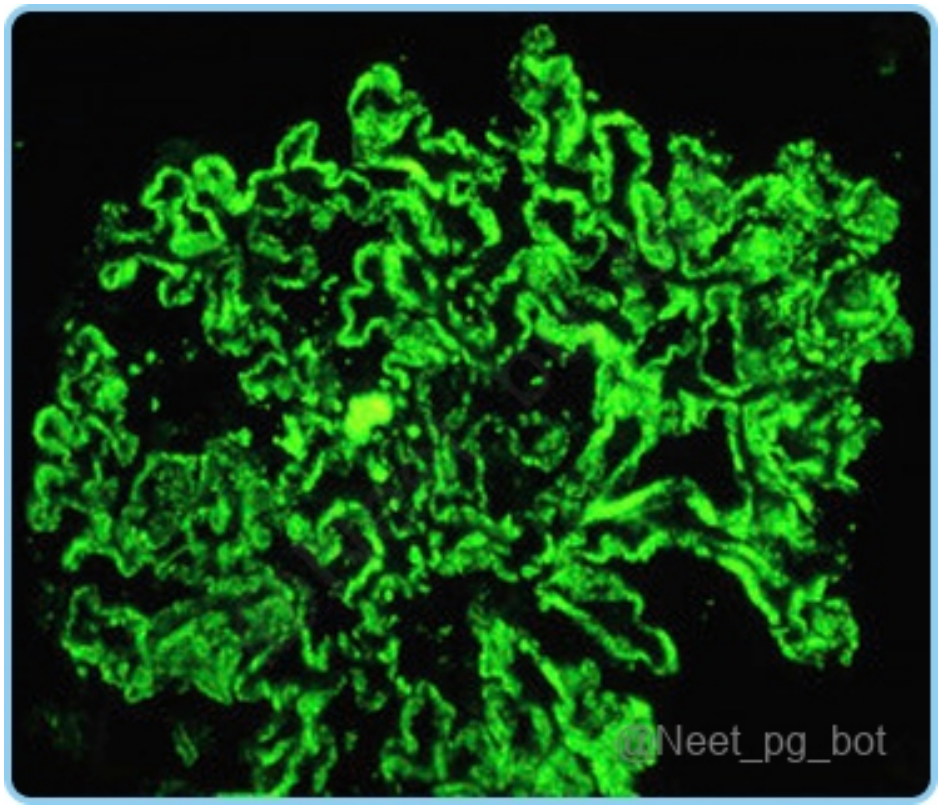

References:

Harrison’s Principles of Internal Medicine, 21st Edition, Page 2739

↑ *Back to this question in Part A*

@Neet_pg_bot

Q8: A 28-year-old woman with a history of SLE presents with increased fatigue, severe joint pain and pleuritis with features suggestive of coronary artery disease. Laboratory tests indicate elevated serum creatinine. Which of the following management strategies is most appropriate for this patient? (Q851403)

A. High-dose glucocorticoids and Cyclophosphamide

B. Hydroxychloroquine and NSAIDs for symptom relief

C. Low-dose glucocorticoids, along with azathioprine

D. Conservative management with close monitoring and supportive care

Correct Answer: A. High-dose glucocorticoids and Cyclophosphamide

Explanation: For SLE patients with severe disease presenting with significant organ involvement, the most appropriate management strategy is high-dose glucocorticoids and cyclophosphamide . Hydroxychloroquine and NSAIDs (Option B): Appropriate for mild, non–organ-threatening SLE , not adequate here. Low-dose glucocorticoids + azathioprine (Option C): Used for maintenance or moderate disease , not strong enough for acute severe disease. Conservative management (Option D): Unsafe, as supportive care alone risks progression and organ failure.

References:

Harrison’s Principles of Internal Medicine, 21st Edition, Page 2746, 2747 Davidson’s Principles and Practice of Medicine, 24th Edition, Page 1036, 1037

↑ *Back to this question in Part A*

@Neet_pg_bot

Q9: A 35-year-old woman with a history of hypertension presents with fever, rash, and joint pain. Laboratory tests show positive ANA and anti-histone antibodies. She has no signs of renal or neurological involvement. Which of the following medications is most likely responsible for her symptoms? (Q851405)

A. Metoprolol

B. Hydrochlorothiazide

C. Hydralazine

D. Amlodipine

Correct Answer: C. Hydralazine

Explanation: Hydralazine is a known trigger for drug-induced lupus, especially in patients with a history of hypertension. It is associated with positive anti-histone antibodies and symptoms consistent with lupus erythematosus. Common offending agents for drug-induced lupus: (Options A, B and D ruled out) Antiarrhythmics: Procainamide, disopyramide, propafenone Antihypertensives: Hydralazine Antithyroid: Propylthiouracil Antipsychotics: Chlorpromazine, lithium Anticonvulsants: Carbamazepine, phenytoin Antibiotics: Isoniazid, minocycline, nitrofurantoin, dapsone Antirheumatics: Sulfasalazine Diuretics: Hydrochlorothiazide Antihyperlipidemic: Lovastatin, Simvastatin

References:

Harrison's Principles of Internal Medicine, 21st Edition, Page 2748, 2749

↑ *Back to this question in Part A*

@Neet_pg_bot

Q10: A 45-year-old man with TB on ATT isoniazid therapy presents with fatigue, fever, joint pain, and a rash. Laboratory tests reveal a positive antinuclear antibody (ANA) test, and anti-histone antibodies are detected. Which of the following ANA staining patterns is most likely found in this patient? (Q851407)

A. Diffuse

B. Speckled

C. Nucleolar

D. Centromere

Correct Answer: A. Diffuse

Explanation: The clinical presentation, along with positive anti-histone antibodies, suggests drug-induced lupus erythematosus associated with isoniazid. Homogeneous (Diffuse) pattern is the typical ANA pattern seen in Drug-induced lupus, which corresponds with anti-histone antibodies. ANA patterns of SLE ANA pattern Antibody identifies Clinical significance Speckled pattern (Option B ruled out) Anti U1-RNP Associated with mixed connective tissue disease (MCTD) Anti Sm Is specific for Lupus Anti Ro (SS-A) Associated with Sjögren's, SCLE & neonatal lupus. Anti La (SS-B) Associated with Anti-Ro Anti Scl-70 Associated with diffuse scleroderma Anti Jo-1 Associated with polymyositis with pneumonitis and arthritis Nucleolar pattern (Option C ruled out)

RNA polymerase Associated with progressive systemic sclerosis Centromere (Option D ruled out) Kinetochore Associated with CREST, Sjogren's & thyroiditis {{caption_text}}

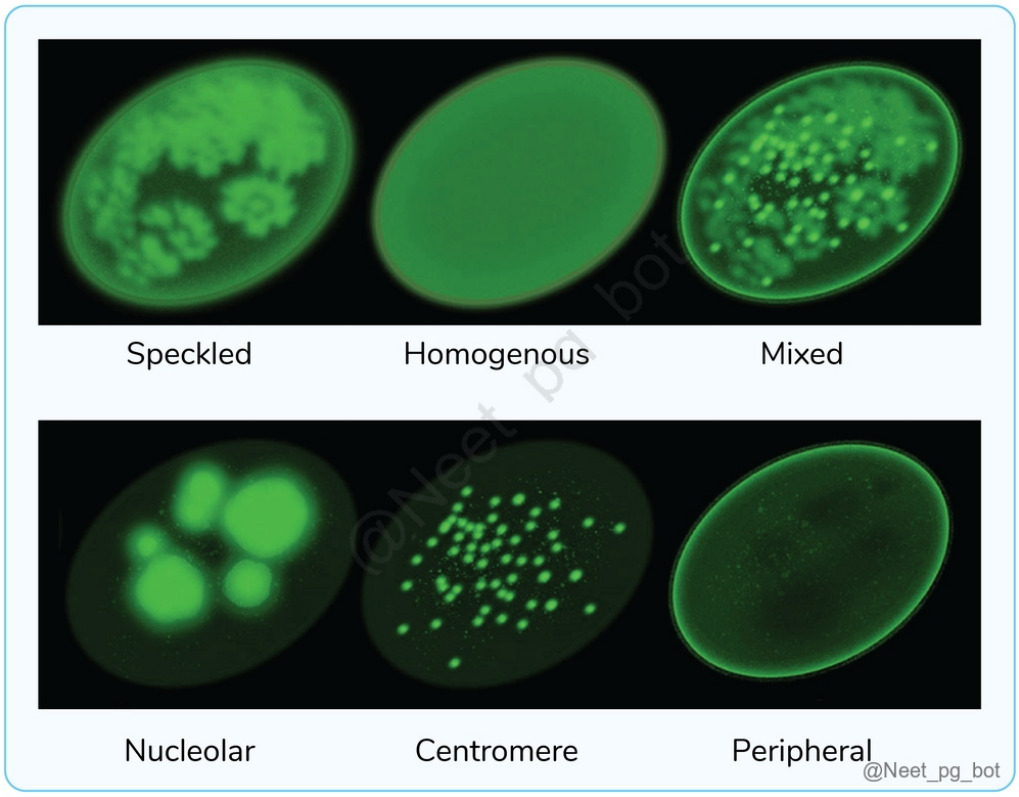

References:

Harrison's Principles of Internal Medicine, 21st Edition, Page 2852

↑ *Back to this question in Part A*

@Neet_pg_bot

Q11: A 35-year-old woman with a history of recurrent miscarriages and recent episodes of deep vein thrombosis is found to have elevated anti-β2-glycoprotein I antibodies. Which of the following pathophysiological mechanisms is primarily responsible for her condition? (Q851410)

A. Deactivation of the complement pathway

B. Increased apoptosis of endothelial cells

C. Decreased platelet activation

D. Impaired fibrinolysis

Correct Answer: B. Increased apoptosis of endothelial cells

Explanation: The clinical scenario of a woman with recurrent miscarriages and deep vein thrombosis (DVT), along with elevated anti-β2-glycoprotein I antibodies, suggests antiphospholipid syndrome (APS). In APS, increased endothelial cell apoptosis exposes negatively charged phospholipids, promoting the formation of antiphospholipid antibodies. Deactivation of the complement pathway (Option A): APS is primarily associated with antiphospholipid antibodies that activate the coagulation cascade rather than deactivate the complement pathway. Impaired fibrinolysis (Option C) : APS is mainly characterised by increased coagulation and platelet activation rather than a failure to break down clots. Decreased platelet activation (Option D) : In APS, the presence of antiphospholipid antibodies leads to increased platelet activation, contributing to thrombus formation.

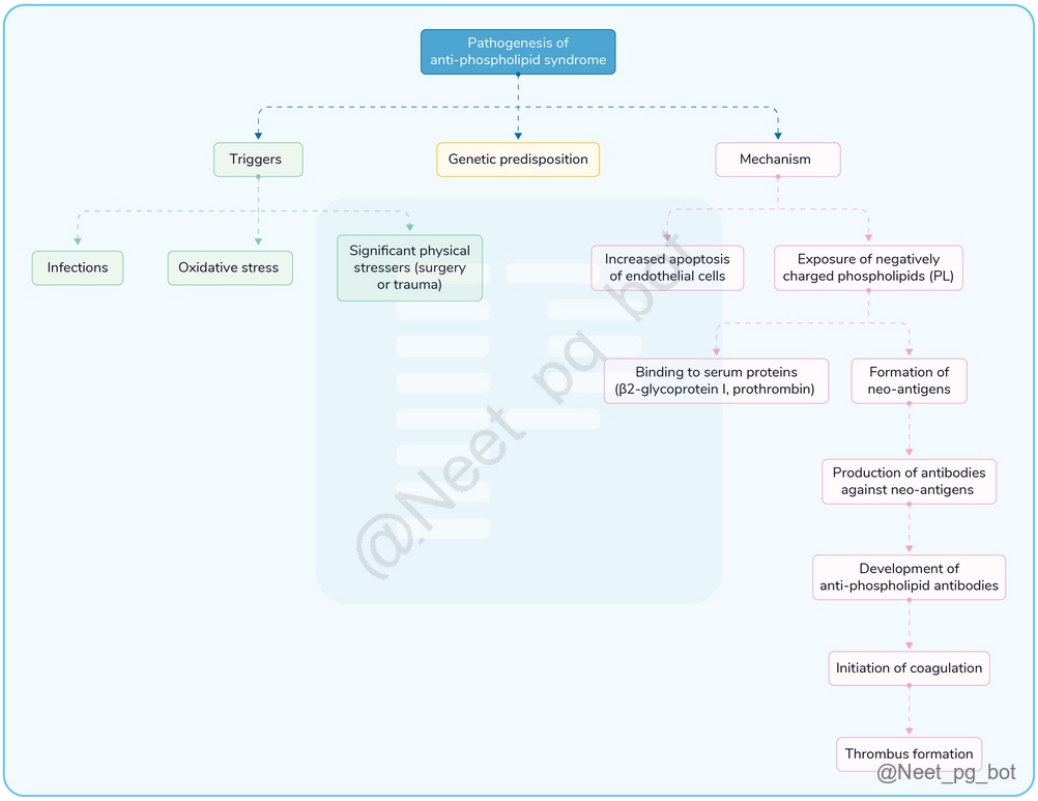

References:

Harrison’s Principles of Internal Medicine, 21st Edition, Page 2749, 2750 Davidson’s Principles and Practice of Medicine, 24th Edition, Page 977, 978

↑ *Back to this question in Part A*

@Neet_pg_bot

Q12: A 30-year-old woman presents with a history of recurrent miscarriages, having experienced three miscarriages before 10 weeks of gestation and an unprovoked deep vein thrombosis (DVT) in her left leg six months ago, which required anticoagulation

therapy. She is diagnosed with antiphospholipid syndrome. Which of the following is not a diagnostic criterion of antiphospholipid syndrome? (Q851413)

A. Vascular thrombosis of artery, vein or any small vessel

B. 3 or more unexplained consecutive miscarriages before 10 weeks of gestation

C. Positive titer for APLA antibodies on a single occasion

D. One or more unexplained deaths of a normal fetus at or after 10 weeks

Correct Answer: C. Positive titer for APLA antibodies on a single occasion

Explanation: Laboratory criteria for diagnosing Antiphospholipid antibody syndrome (APLA) include the presence of a positive titer for APLA antibodies on two occasions 12 weeks apart. APLA antibodies include Lupus antibody Anticardiolipin Anti-beta-2-glycoprotein-I Diagnosis of antiphospholipid syndrome Clinical criteria Vascular thrombosis - one or more clinical episodes of arterial, venous or small vessel thrombosis (Option A ruled out) Pregnancy morbidity (anyone) One or more unexplained deaths of a normal fetus at or after 10 weeks of gestation (Option D ruled out) One or more premature births of a normal neonate before 34 weeks of gestation due to eclampsia , severe pre-eclampsia or placental insufficiency Three or more unexplained consecutive miscarriages before 10 weeks of gestation (Option B ruled out) Lab criteria Intermediate or high titer of any one of the following antibodies on two occasions 12 weeks apart. (Option C) Lupus antibody Anticardiolipin Anti-beta-2-glycoprotein-I Diagnosis of APLA: One clinical + one laboratory criterion in the absence of other thrombophilia

References:

Harrison’s Principles of Internal Medicine, 21st Edition, Page 2750

↑ *Back to this question in Part A*

@Neet_pg_bot

Q13: A 32-year-old woman with a known history of antiphospholipid syndrome (APS) was admitted to the hospital due to arterial thrombosis. She had a history of deep vein thrombosis (DVT) one year ago, for which she was treated with warfarin. She has been adherent to her warfarin therapy, with a target INR of 2.5. Investigations show the following reports. INR: 2.1 Lupus antibody: Positive Anticardiolipin antibody: Positive Anti-β2 glycoprotein I antibodies: Positive What would be the most appropriate adjustment to her treatment after this arterial thrombosis episode? (Q851418)

A. Administration of oral hydroxychloroquine

B. Increase the dose of warfarin with a target INR of 3.0 to 4.0

C. Switch to direct oral thrombin inhibitor

D. Switch to low-dose aspirin with prophylactic dose low molecular weight heparin.

Correct Answer: B. Increase the dose of warfarin with a target INR of 3.0 to 4.0

Explanation: Since this patient has experienced arterial thrombosis, the target INR should be raised from the standard range of 2.0-3.0 to 3.0-4.0. This adjustment can be achieved by increasing the dosage of warfarin. Treatment of antiphospholipid syndrome After the first venous thrombosis Warfarin - Lifelong with a target INR 2.0-3.0 Consider Direct thrombin inhibitors if there is a contraindication to warfarin or failure to achieve target INR * Arterial thrombosis Increase warfarin dose with target INR 3.0-4.0 or (Option B) Maintain INR 2.0-3.0 and low-dose aspirin (LDA) 70-100 mg/day Pregnant woman with APLA LDA + Prophylactic dose of LMWH (Option D ruled out) If thrombosis occurs - LDA + therapeutic dose of LMWH Recurrent obstetric complications, even after standard treatment LDA + therapeutic dose of LMWH Oral hydroxychloroquine 400 mg / day (Option A ruled out) IV immunoglobulin 400 mg/kg for 5 days Asymptomatic patients with high-risk antiphospholipid profile Prophylactic low-dose aspirin Catastrophic antiphospholipid syndrome (CAPS) Combination therapy Glucocorticoid Heparin Plasmapheresis or IV immunoglobulin Refractory CAPS B-cell depletion therapy with rituximab Complement inhibition with Eculizumab * Avoid direct thrombin inhibitors in cases of prior arterial thrombosis or triple positive APLA (Option C ruled out)

References:

Harrison’s Principles of Internal Medicine, 21st Edition, Page 2750-2751

↑ *Back to this question in Part A*

@Neet_pg_bot

Q14: Which of the following assay tests cannot detect lupus anticoagulant antibodies? (Q851421)

A. Enzyme-linked immunosorbent assay

B. Activated thromboplastin time

C. Kaolin clotting time

D. Dilute Russell viper venom test

Correct Answer: A. Enzyme-linked immunosorbent assay

Explanation: The enzyme-linked immunosorbent assay cannot detect lupus anticoagulants; instead, it detects anticardiolipin antibodies (gives false positive RPR for syphilis) and Anti-beta-2-glycoprotein-I, which aids in the diagnosis of antiphospholipid syndrome. Tests for detecting lupus anticoagulant: Test Interpretation Dilute Russell Viper Venom Time (DRVVT) Test (Option D ruled out) Presence of lupus anticoagulant inhibits factor X

activation , leading to prolonged clotting time (no clot formation). Kaolin Clotting Time (Option C ruled out) Increased kaolin clotting time indicates the presence of lupus anticoagulant, impairing normal coagulation. Activated Partial Thromboplastin Time (aPTT) (Option B ruled out) Prolonged aPTT suggests the presence of lupus anticoagulant, as it binds to β2-glycoprotein I or prothrombin and interferes with clotting.

References:

Davidson’s Principles and Practice of Medicine, 24th Edition, Page 977-978

↑ *Back to this question in Part A*

@Neet_pg_bot

• [08_Rheumatology] 062 Rheumatoid Arthritis

« Back to Folder Directory

[08_Rheumatology] 062 Rheumatoid Arthritis — Quick Jump

Q1 (p. 2583) *Q2 (p. 2583)* *Q3 (p. 2584)* *Q4 (p. 2585)* *Q5 (p. 2586)* *Q6 (p. 2588)*
Q7 (p. 2589) *Q8 (p. 2590)* *Q9 (p. 2591)* *Q10 (p. 2592)* *Q11 (p. 2593)*

Q1: A 45-year-old female complains of morning stiffness lasting over an hour and pain in her hands and wrists. On examination, there is swelling and tenderness of multiple small joints in her hands. Laboratory results show a positive rheumatoid factor (RF) and anti-cyclic citrullinated peptide (anti-CCP) antibodies. X-ray reveals soft tissue swelling and early joint space narrowing. Which of the following joint involvement patterns is most characteristic of this condition? (Q851422)

A. Symmetrical involvement of small joints, particularly the MCP and PIP joints

B. Asymmetrical involvement of small joints, particularly the MCP and PIP joints

C. Symmetrical involvement of the DIP joints

D. Asymmetrical involvement of the DIP joints

Correct Answer: A. Symmetrical involvement of small joints, particularly the MCP and PIP joints

Explanation: Rheumatoid arthritis typically presents with symmetrical polyarthritis of small joints , especially the metacarpophalangeal (MCP) and proximal interphalangeal (PIP) joints , along with morning stiffness >1 hour. Asymmetrical involvement of small joints, particularly the MCP and PIP joints (Option B): More typical of psoriatic arthritis . Symmetrical involvement of the DIP joints (Option C): Characteristic of osteoarthritis , not RA. Asymmetrical involvement of the DIP joints (Option D): Suggestive of psoriatic arthritis or osteoarthritis , not RA.

References:

Davidson’s Principles and Practice of Medicine 24 th Edition, Page 993-10034

↑ *Back to this question in Part A*

@Neet_pg_bot

Q2: A 52-year-old woman presents with joint pain and swelling, particularly in her hands and wrists, over the past 6 months. She has a family history of autoimmune

diseases, and laboratory tests show positive rheumatoid factor (RF) and anti-citrullinated protein antibodies (anti-CCP). Which of the following statements is true regarding the etiopathogenesis of this patient's condition? (Q851424)

A. Crystal disposition in the joint spaces leads to joint inflammation

B. Presence of HLA-DR β 1 is strongly associated with this condition

C. Joint destruction occurs due to mechanical damage to the articular cartilage

D. Pregnancy can aggravate the symptoms of this condition

Correct Answer: B. Presence of HLA-DR β 1 is strongly associated with this condition

Explanation: Rheumatoid arthritis has a strong genetic association with HLA-DRB1 alleles, which contribute to autoimmune activation and chronic synovial inflammation. Crystal deposition in the joint spaces leads to joint inflammation (Option A): Characteristic of gout or pseudogout, not RA. Joint destruction occurs due to mechanical damage to the articular cartilage (Option C): Seen in osteoarthritis, RA destruction is immune-mediated. Pregnancy can aggravate the symptoms of this condition (Option D): Symptoms often improve during pregnancy due to immunomodulation.

References:

Harrison’s Principles of Internal Medicine, 21st Edition, Page 2751, 2754

Davidson’s Principles and Practice of Medicine, 24th Edition, Page 1022

↑ *Back to this question in Part A*

@Neet_pg_bot

Q3: A 32-year-old woman with long-standing rheumatoid arthritis presents with difficulty extending the DIP joint and flexing the PIP joint of her middle finger. On examination, the PIP joint is flexed while the DIP joint is hyperextended. Which of the following deformities best matches this presentation? (Q851426)

A. Boutonniere deformity

B. Swan neck deformity

C. Z-line deformity

D. Mallet finger deformity

Correct Answer: A. Boutonniere deformity

Explanation: Boutonniere deformity : Flexion of the PIP and hyperextension of the DIP joint. Swan neck deformity (Option B) Shows PIP hyperextension with DIP flexion. Z-line deformity (Option C) Seen in rheumatoid arthritis but affects the thumb , not the fingers. Mallet finger deformity (Option D) Involves DIP flexion due to extensor tendon avulsion, but the PIP joint remains normal.

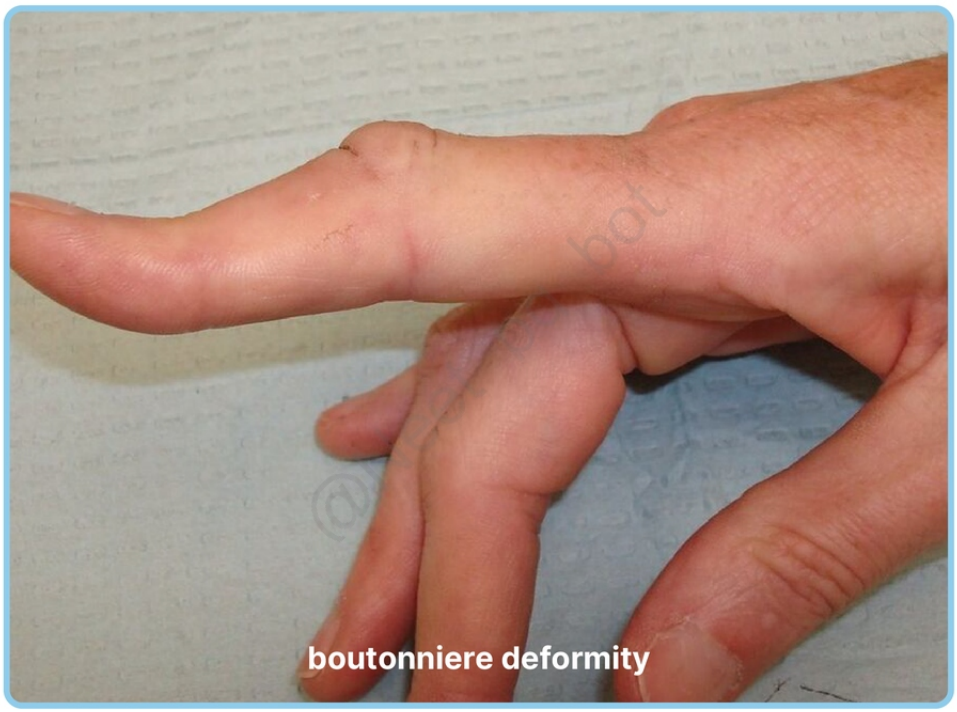

@Neet_pg_bot

References:

Harrison's Principles of Internal Medicine, 21st Edition, Page 2751-2752

↑ *Back to this question in Part A*

@Neet_pg_bot

Q4: A 45-year-old male presents to the clinic with joint pain and morning stiffness lasting more than one hour. Based on the EULAR classification criteria for rheumatoid arthritis, which of the following combinations of clinical, serological, and laboratory findings is most likely to lead to a definitive diagnosis of rheumatoid arthritis? (Q851428)

A. Swelling in 3 small joints, positive anti-citrullinated protein antibodies (ACPA) at high titers, and elevated C-reactive protein (CRP), symptoms for 8 weeks

B. Swelling in 1 large joint, positive rheumatoid factor at low titers, normal ESR, and symptoms for 4 weeks

C. Swelling in 6 small joints, negative ACPA, elevated ESR, and symptoms for 5 weeks

D. Swelling in 4 large joints, positive ACPA at low titers, normal CRP, and symptoms for 12 weeks

Correct Answer: A. Swelling in 3 small joints, positive anti-citrullinated protein antibodies (ACPA) at high titers, and elevated C-reactive protein (CRP), symptoms for 8 weeks

Explanation: According to EULAR/ACR 2010 criteria , definitive RA diagnosis requires a combination of joint involvement, serology (RF/ACPA), acute phase reactants, and symptom duration . Swelling in multiple small joints, high-titer ACPA , elevated CRP, and symptoms ≥6 weeks meet criteria for RA. To meet the EULAR classification criteria for rheumatoid arthritis, a score of 6 or more points is required, based on a combination of joint involvement, serology, acute-phase reactants, and symptom duration: A. Joint Involvement Score 1 large joint 2-10 large joints 1-3 small joints (with or without involvement of large joints) 4-10 small joints (with or without involvement of large joints) >10 joints (at least 1 small joint) 0 1 2 3 5 B. Serology Negative RF and negative ACPA Low-positive RF or low-positive ACPA High-positive RF or high-positive ACPA 0 2 3 C. Acute-phase reactants Normal CRP and normal ESR Abnormal CRP or abnormal ESR 0 1 D. Duration of symptoms <6 weeks ≥6 weeks 0 1

References:

Davidson’s Principles and Practice of Medicine, 24th Edition, Page 1023

rheumatology.org/criteria#:~:text=Rheumatoid%20Arthritis%20Classification

↑ *Back to this question in Part A*

@Neet_pg_bot

Q5: A 60-year-old male with a history of working in coal mines presents with progressive shortness of breath and a chronic cough. He reports that years ago, he was diagnosed with a joint condition that caused swelling and stiffness, particularly in his hands and wrists. Laboratory testing reveals he is positive for HLA-DR4. A chest X-ray shows multiple rounded opacities in both lung fields. A lung biopsy showed the following picture. What is the most likely diagnosis? (Q851430)

A. Caplan syndrome

B. Secondary Sjögren's syndrome

C. Felty syndrome

D. Lofgren syndrome

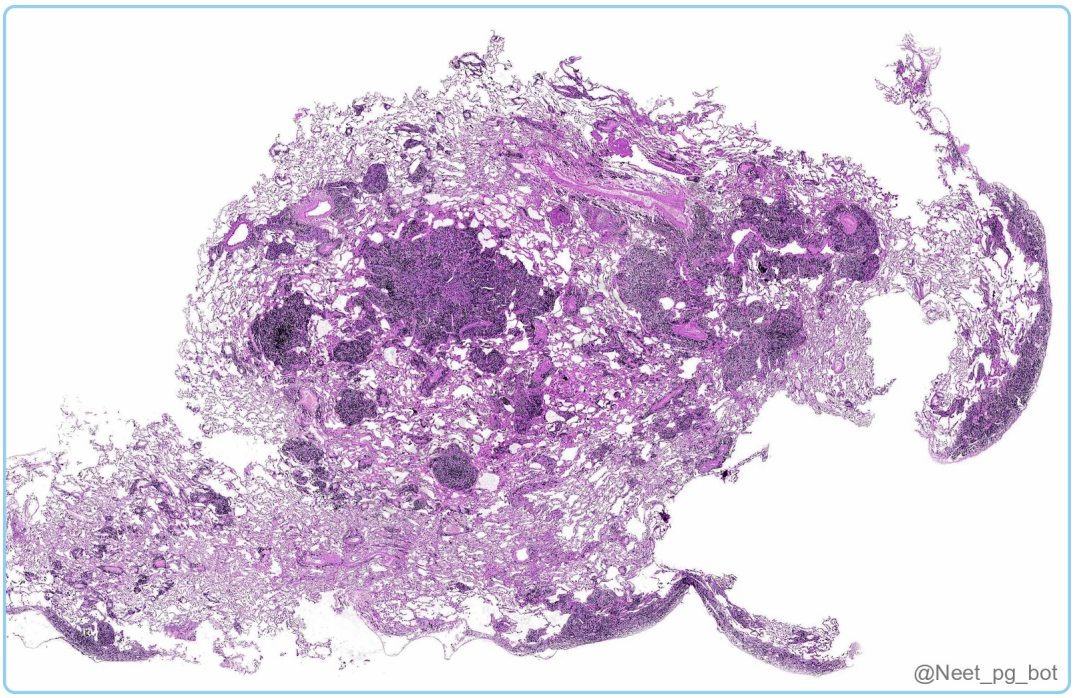

Correct Answer: A. Caplan syndrome

Explanation: The patient's history of a joint condition, likely rheumatoid arthritis (given the positive HLA-DR4), combined with long-term occupational exposure to coal dust and the presence of rounded lung nodules on X-ray and biopsy, suggests Caplan syndrome. It is characterised by the formation of multiple well-defined pulmonary nodules , with pathological features similar to rheumatoid nodules, including central necrosis, surrounding palisading histiocytes, and a peripheral rim of lymphocytes and plasma cells. {{caption_text}} Secondary Sjögren's Syndrome (Option B) occurs in individuals with a pre-existing autoimmune disease, such as rheumatoid arthritis or lupus. It primarily involves dryness of the eyes and mouth (sicca symptoms) due to autoimmune destruction of the lacrimal and salivary glands. Felty syndrome (Option C) is a rare complication of longstanding rheumatoid arthritis, characterised by the triad of RA, splenomegaly, and neutropenia. It does not involve pulmonary opacities or occupational exposure, pulmonary nodules, or occupational lung exposure. Lofgren syndrome (Option D) is an acute presentation of sarcoidosis, marked by the triad of erythema nodosum, bilateral hilar lymphadenopathy, and arthritis (usually in the ankles). It is not related to the patient’s coal mining history or lung opacities.

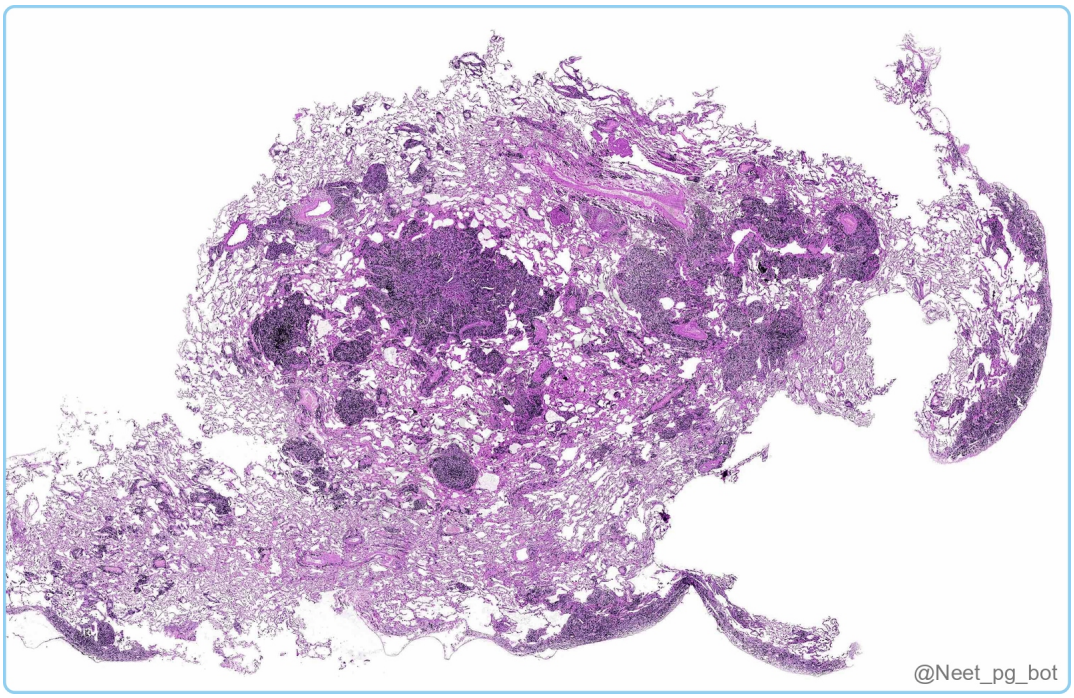

References:

Harrison’s Principles of Internal Medicine, 21st Edition, Page 2753

Davidson’s Principles and Practice of Medicine, 24th Edition, Page 611, 615, 1023, 1025

↑ *Back to this question in Part A*

@Neet_pg_bot

Q6: A 32-year-old male presents with multiple subcutaneous nodules on his arms and back, along with joint pain and stiffness primarily affecting his hands and knees. He has erythema nodosum and a positive family history of similar conditions. Which of the following is a common ocular extra-articular manifestation associated with this condition? (Q851432)

A. Keratoconjunctivitis sicca

B. Uveitis

C. Iritis

D. Iridocyclitis

Correct Answer: A. Keratoconjunctivitis sicca

Explanation: This patient’s presentation suggests a diagnosis of rheumatoid arthritis (RA). Common extra-articular manifestations of rheumatoid arthritis include subcutaneous nodules, erythema nodosum, and ocular complications (keratoconjunctivitis sicca due to secondary Sjögren’s syndrome). Rheumatoid/subcutaneous nodules are the most common extra-articular manifestation of RA. Uveitis (Option B): More commonly seen in seronegative spondyloarthropathies, not RA. Iritis (Option C): Typically associated with ankylosing spondylitis or juvenile idiopathic arthritis. Iridocyclitis (Option D): Also more common in spondyloarthropathies, not RA.

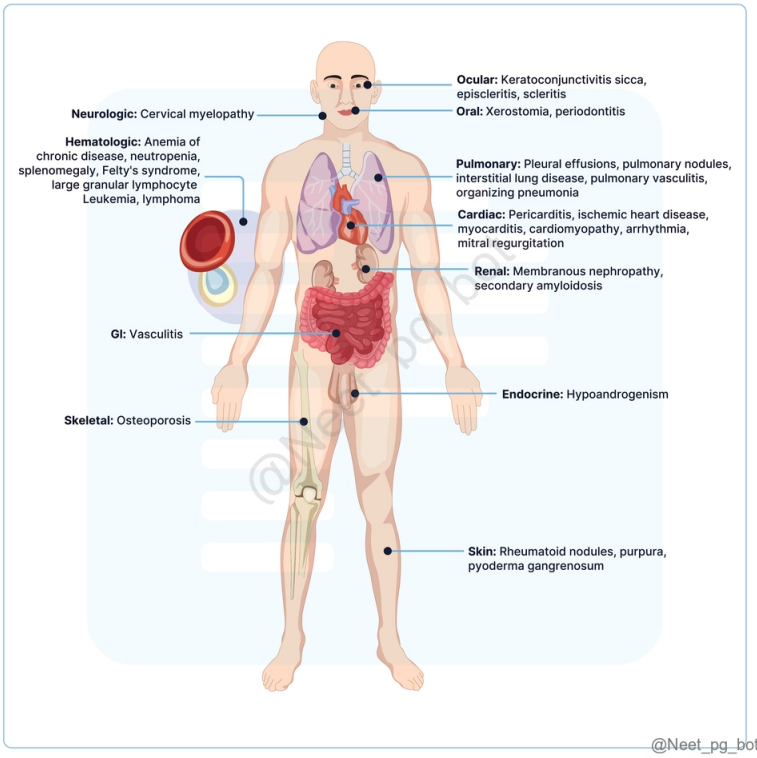

References:

Harrison’s Principles of Internal Medicine, 21st Edition, Page 2752

↑ *Back to this question in Part A*

@Neet_pg_bot

Q7: A 52-year-old man presents with bilateral pain, swelling, and stiffness in his hands and wrists for the past 4 months. His symptoms are worse in the morning and improve throughout the day. The physical exam shows synovitis in the metacarpophalangeal joints. Considering the high specificity for rheumatoid arthritis, which initial investigation is most appropriate to confirm the diagnosis in this patient? (Q851434)

A. Anti-nuclear antibody test

B. Anti-cyclic citrullinated peptide antibody

C. Synovial fluid analysis

D. MRI of the affected joints

Correct Answer: B. Anti-cyclic citrullinated peptide antibody

Explanation: The clinical presentation suggests rheumatoid arthritis (RA) , characterised by morning stiffness, symmetrical joint involvement, and synovitis in the hands. The most appropriate initial investigation to support this diagnosis is the anti-cyclic citrullinated peptide (anti-CCP) antibody test, which is highly specific for rheumatoid arthritis. Anti-nuclear antibody (ANA) test (Option A) is primarily used to diagnose systemic lupus erythematosus (SLE) and other connective tissue diseases, not RA. Although ANA can occasionally be positive in RA, it is not a specific or reliable test for this condition. Synovial fluid analysis (Option C) helps rule out other conditions, such as infection or crystal arthropathy but is not the initial investigation for rheumatoid arthritis . Ultrasound or magnetic resonance imaging (Option D): To establish diagnosis

References:

Harrison’s Principles of Internal Medicine, 21st Edition, Page 2759, 2760

Davidson’s Principles and Practice of Medicine, 24th Edition, Page 1025

↑ *Back to this question in Part A*

@Neet_pg_bot

Q8: A 55-year-old female patient presents with significant joint pain, stiffness, and swelling affecting multiple joints. Her Disease Activity Score (DAS28) is 5.4, indicating high disease activity. She has not responded adequately to lifestyle modifications and NSAIDs. Which medication is considered this patient's first-line disease-modifying antirheumatic drug (DMARD)? (Q851435)

A. Sulfasalazine

B. Methotrexate

C. Leflunomide

D. Hydroxychloroquine

Correct Answer: B. Methotrexate

Explanation: Methotrexate is the first-line DMARD for rheumatoid arthritis, especially in patients with high disease activity (DAS28 >5.1) who have not responded to NSAIDs or lifestyle measures. Sulfasalazine (Option A): Used in mild to moderate RA or in combination therapy. Leflunomide (Option C): Alternative to methotrexate

if contraindicated, not first-line. Hydroxychloroquine (Option D): Typically used in mild RA or combination therapy, not in high disease activity alone.

References:

Harrison's Principles of Internal Medicine, 21st Edition, Page 2761-2763

www.sciencedirect.com/science/article/pii/S1297319X24000435#:~:text=There%20are%20various%20combination%20conventional

↑ *Back to this question in Part A*

@Neet_pg_bot

Q9: A 45-year-old female patient with rheumatoid arthritis presents with persistent joint pain and swelling despite being on methotrexate and low-dose prednisolone for the past six months. Her Disease Activity Score (DAS28) is 5.4, indicating high disease activity. What is the most appropriate next step in her management? (Q851437)

A. Increase the dose of methotrexate

B. Initiate oral triple therapy

C. Switch from methotrexate to leflunomide

D. Continue methotrexate for 3 more months

Correct Answer: B. Initiate oral triple therapy

Explanation: In patients with high disease activity despite methotrexate monotherapy, oral triple DMARD therapy (methotrexate + sulfasalazine + hydroxychloroquine) is recommended before considering biologic agents. Management Algorithm of Rheumatoid Arthritis: Increase the dose of methotrexate (Option A): May help, but patient is already on an adequate dose for 6 months. Switch from methotrexate to leflunomide (Option C): Considered if methotrexate intolerance or contraindication, not first step. Continue methotrexate for 3 more months (Option D): Not appropriate for persistent high disease activity; requires escalation.

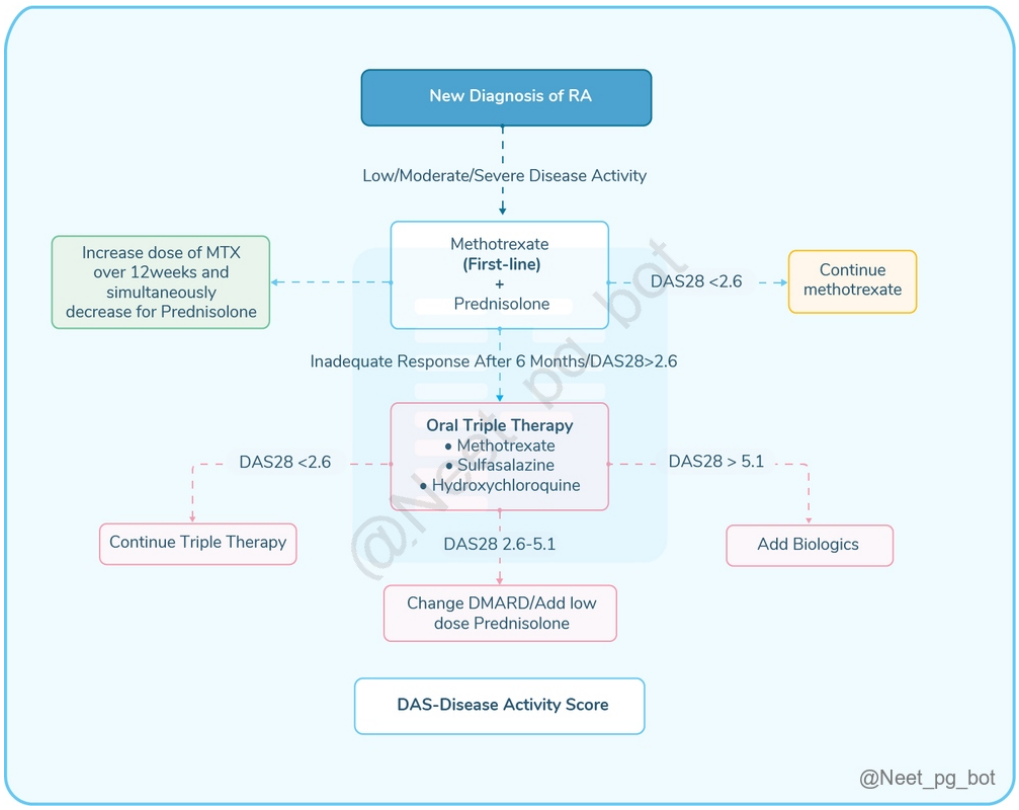

References:

Harrison's Principles of Internal Medicine, 21st Edition, Page 2764

Davidson's Principles and Practice of Medicine, 24th Edition, Page 1024

↑ *Back to this question in Part A*

@Neet_pg_bot

Q10: A 60-year-old man with rheumatoid arthritis is being evaluated for remission after 6 months of treatment. According to the ACR/EULAR remission criteria, which of the following is NOT correct? (Q851438)

A. Tender joint count ≤1

B. Simplified Disease Activity Index (SDAI) score of ≤ 3.2

C. CRP ≤1 mg/dL

D. Patient global assessment ≤ 1

Correct Answer: B. Simplified Disease Activity Index (SDAI) score of ≤ 3.2

Explanation: The correct cut-off for SDAI remission is ≤ 3.3 , not ≤ 3.2. At any time point, the patient must satisfy all of the following: ACR/EULAR Provisional Definition of Remission in RA Tender joint count ≤1 (Option A) Swollen joint count ≤1 C-reactive protein ≤1 mg/dL (Option C) Patient global assessment ≤1 (on a 0–10 scale) (Option D) OR At any time point, the patient must have a Simplified Disease Activity Index score of ≤3.3

References:

Harrison’s Principles of Internal Medicine, 22nd Edition, Page 2852

↑ *Back to this question in Part A*

@Neet_pg_bot

Q11: Match the following: 1. Swan neck deformity a) {{caption_text}} 2. Boutonniere deformity b) 3. Z-line deformity c) 4. Mallet finger deformity d) {{caption_text}} (Q851440)

A. 1-c, 2-b, 3-d, 4-a

B. 1-b, 2-d, 3-a, 4-c

C. 1-a, 2-c, 3-b, 4-d

D. 1-d, 2-a, 3-c, 4-b

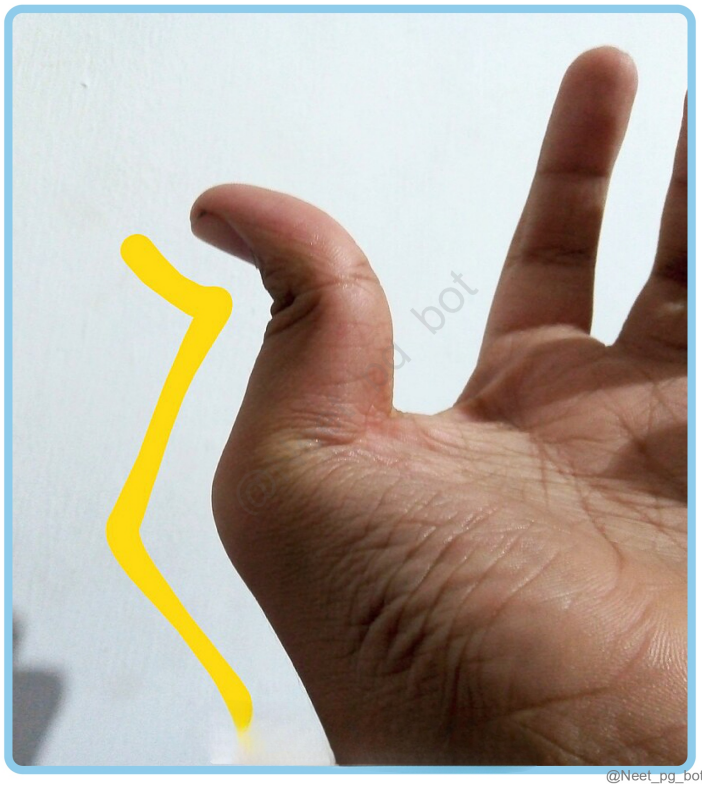

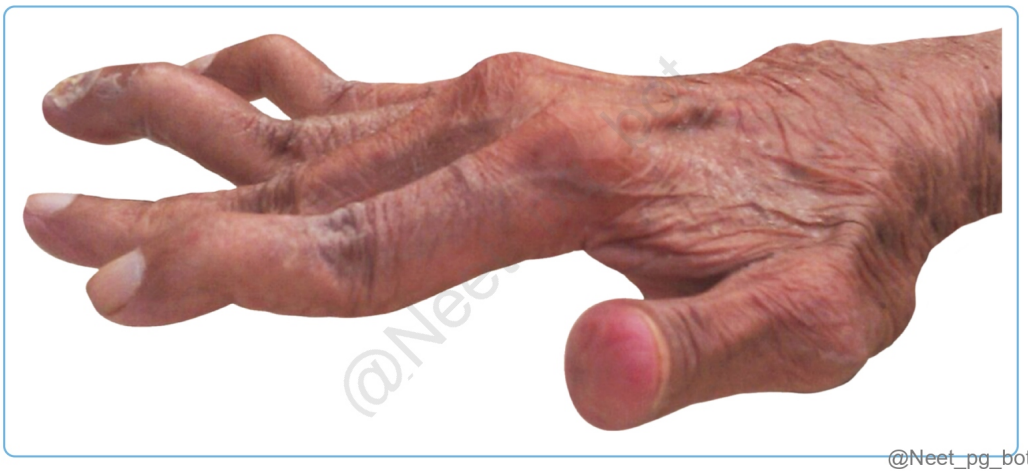
@Neet_pg_bot


@Neet_pg_bot



@Neet_pg_bot

Correct Answer: B. 1-b, 2-d, 3-a, 4-c

Explanation: Deformities Images Swan neck deformity Extension at proximal interphalangeal joint (PIP) Flexion at the distal interphalangeal joint (DIP): The DIP joint is not involved; flexion occurs due to tension on the tendons attached to the base of Distal phalanges Boutonniere deformity Flexion at PIP and extension at DIP Both swan neck and boutonniere deformity can occur in different fingers of the same hand. Z-line deformity Subluxation of the first metacarpophalangeal joint. Hyperextension of interphalangeal joint. Mallet finger deformity Inability to extend the DIP joint due to a tendon injury without affecting the PIP joint. It is usually a sports injury and is not seen in rheumatoid arthritis.

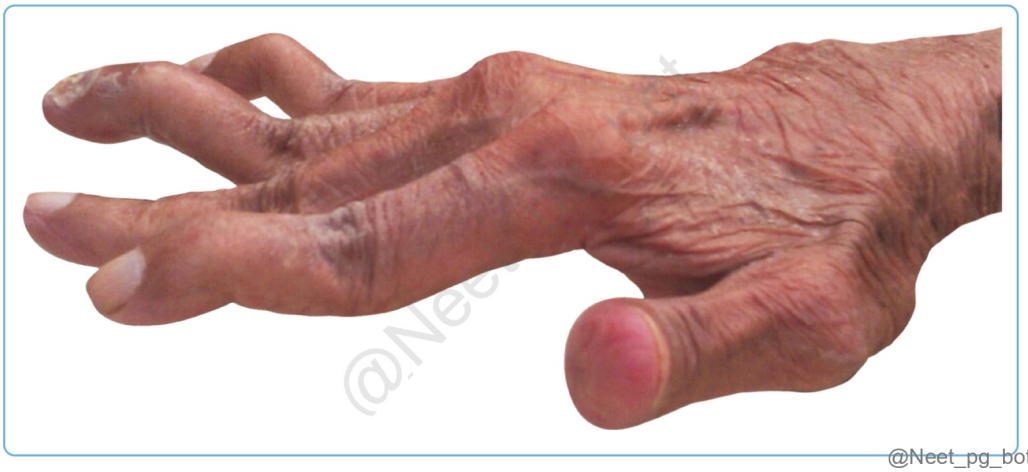

@Neet_pg_bot

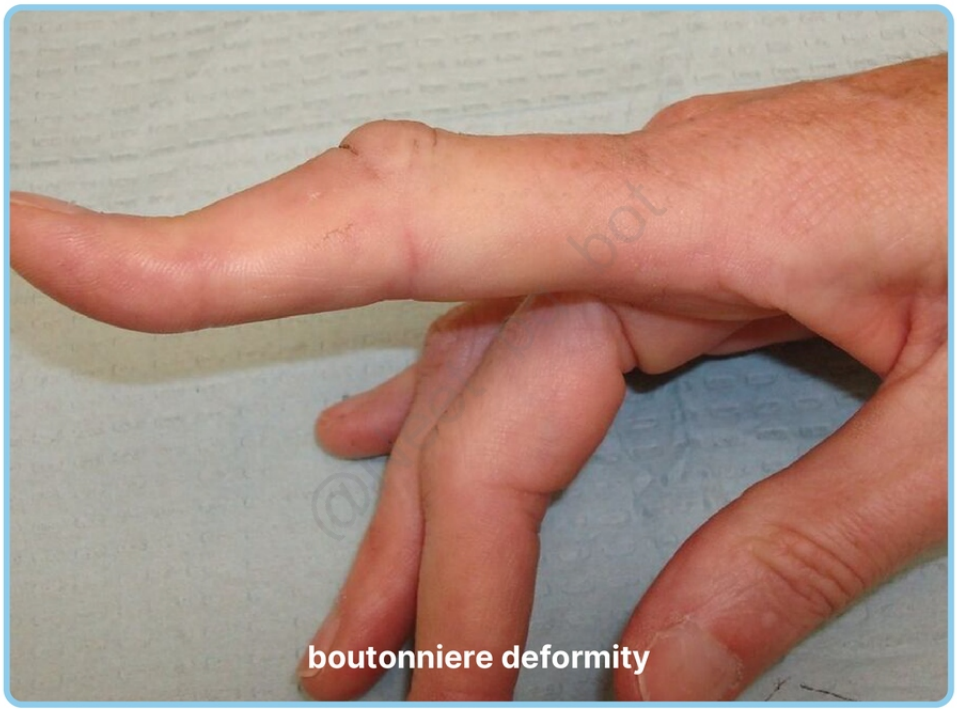

@Neet_pg_bot

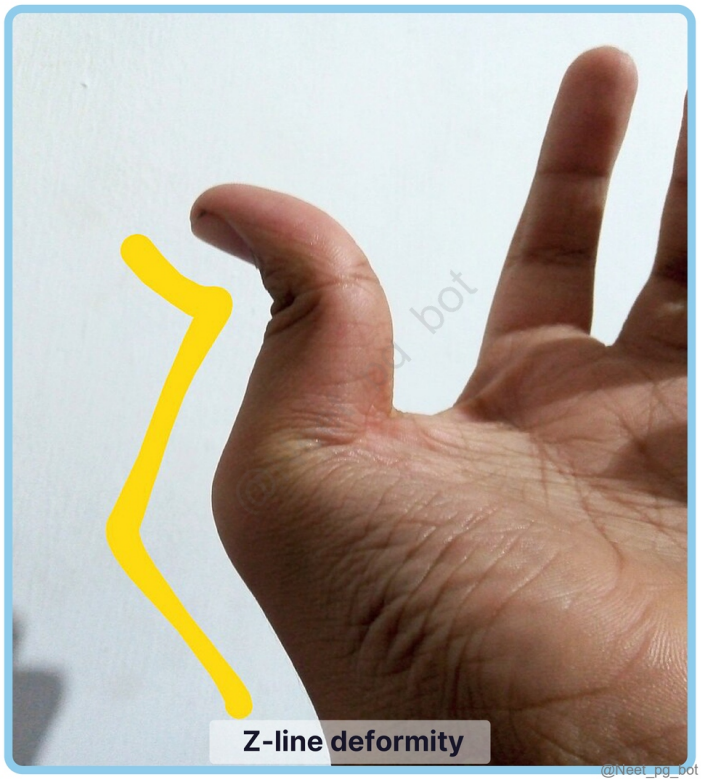

@Neet_pg_bot



References:

Harrison’s Principles of Internal Medicine, 21st Edition, Page 2751-2752

↑ *Back to this question in Part A*

@Neet_pg_bot

• [08_Rheumatology] 063 Crystal Arthropathy

« Back to Folder Directory

[08_Rheumatology] 063 Crystal Arthropathy — Quick Jump

Q1 (p. 2598) *Q2 (p. 2599)* *Q3 (p. 2601)* *Q4 (p. 2602)* *Q5 (p. 2603)* *Q6 (p. 2603)*
Q7 (p. 2605) *Q8 (p. 2605)* *Q9 (p. 2608)* *Q10 (p. 2611)*

Q1: A 62-year-old man presents with sudden, severe pain in his right big toe, waking him from sleep. The joint is swollen, red, and extremely tender. He has a history of high uric acid levels and recently consumed protein-rich meals. What is the most likely diagnosis? (Q851618)

A. Pseudogout

B. Saturnine gout

C. Podagra

D. Psoriatic arthritis

Correct Answer: C. Podagra

Explanation: Podagra refers to an acute gout attack specifically affecting the metatarsophalangeal joint of the big toe . The sudden, severe pain, swelling, and tenderness in this joint, along with the patient's history of hyperuricemia and recent high-protein meals, strongly suggest this diagnosis. Pseudogout (Option A): Typically involves larger joints like the knee or wrist and results from calcium pyrophosphate deposition , not urate crystals. Saturnine gout (Option B) refers to gout associated with chronic lead exposure. Psoriatic arthritis (Option D) often involves multiple joints, particularly distal interphalangeal joints, and is associated with psoriasis.



References:

Harrison’s Principles of Internal Medicine, 21st Edition, Page 2863

Davidson’s Principles and Practice of Medicine, 24th Edition, Page 1014

↑ *Back to this question in Part A*

@Neet_pg_bot

Q2: A 43-year-old man presents with severe pain in his right big toe, redness, and swelling, as shown in the image. He has a history of hypertension and recently increased her consumption of red meat. Which of the following best explains the pathophysiological process leading to her condition? (Q851620)

A. Increased renal tubular secretion of uric acid

B. Decreased production of purines

C. Impaired renal excretion of uric acid

D. Increased breakdown of uric acid



Correct Answer: C. Impaired renal excretion of uric acid

Explanation: The clinical presentation, along with an increased intake of red meat, suggests gouty arthritis due to increased uric acid levels. Impaired renal excretion is a common cause of hyperuricemia, which can lead to the formation of monosodium urate crystals and gout attacks. Etiopathogenesis of Gout: Increased renal tubular secretion of uric acid (Option A), Decreased production of purines (Option B), Increased breakdown of uric acid (Option D): All of these will lead to lower uric acid levels and decrease gout risk formation. Hence, incorrect options.

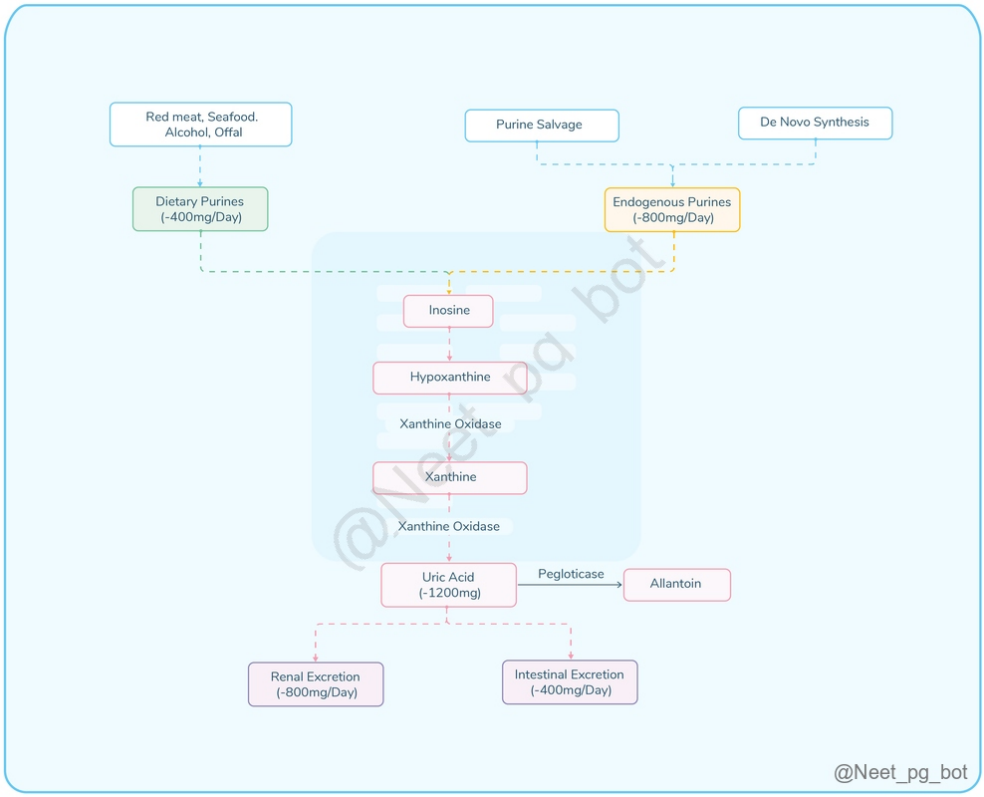

References:

Harrison’s Principles of Internal Medicine, 21st Edition, Page 2862, 2863

Davidson’s Principles and Practice of Medicine, 24th Edition, Page 1013

↑ *Back to this question in Part A*

@Neet_pg_bot

Q3: A 60-year-old woman with a history of elevated uric acid levels reports that she experienced a painful episode in her right big toe two months ago. Since that time, she has had no symptoms and feels completely normal. She is concerned about the possibility of future attacks. What stage of the associated condition is this patient most likely experiencing now? (Q851621)

A. Asymptomatic Hyperuricemia

B. Acute Gout Attack

C. Intercritical Gout

D. Chronic Gouty Arthritis

Correct Answer: C. Intercritical Gout

Explanation: The clinical presentation with increased uric acid levels points towards gout. The patient is currently symptom-free after her previous acute attack, indicating she is in the intercritical stage of gout , characterised by intervals between episodes of acute gout. Stages of Gout Progression: Stage 1: Asymptomatic Hyperuricemia (Option A ruled out) Elevated serum uric acid levels without any symptoms. It can last for years & individuals may be unaware of their condition. Stage 2: Acute Gout Attack (Option B ruled out) A sudden onset of severe pain, redness, and swelling in a joint , most commonly the MTP join t, typically lasts 1–2 weeks . Symptoms usually resolve spontaneously. Stage 3: Intercritical Gout (Option C) Periods between acute attacks when the patient is symptom-free & intervals vary from weeks to years. No symptoms, but the risk of future attacks remains. Stage 4: Chronic Gouty Arthritis (Option D ruled out) Persistent joint inflammation and damage due to repeated attacks. Chronic pain and swelling, joint deformities & formation of tophi (urate crystal deposits)

References:

https://www.ncbi.nlm.nih.gov/books/NBK546606/

Harrison's Principles of Internal Medicine, 21st Edition, Page 2863

↑ *Back to this question in Part A*

@Neet_pg_bot

Q4: A 58-year-old man presents with a sudden onset of severe pain in his left knee, accompanied by swelling and redness. He has a history of elevated uric acid levels. The physician suspects gout and plans to perform a joint aspiration for diagnostic purposes. Which of the following findings would most likely confirm the diagnosis of gout? (Q851622)

A. The presence of rhomboid-shaped crystals under polarised light

B. Elevated white blood cell count with neutrophilic predominance

C. Needle-shaped crystals exhibiting negative birefringence

D. Thickened synovial fluid with a high percentage of lymphocytes

Correct Answer: C. Needle-shaped crystals exhibiting negative birefringence

Explanation: Gout is characterized by the identification of needle-shaped monosodium urate (MSU) crystals exhibiting negative birefringence under polarised light. Rhomboid-shaped crystals (Option A) are characteristic of calcium pyrophosphate dihydrate (CPPD) crystals , which are associated with pseudogout, not gout. Elevated white blood cell count with neutrophilic predominance (Option B) can occur in gout due to inflammation, but it is not specific to gout. Thickened synovial fluid with a high percentage of lymphocytes (Option D) is more indicative of conditions like rheumatoid arthritis o r other inflammatory arthritis rather than the acute inflammatory process

typically seen in gout.

References:

Harrison’s Principles of Internal Medicine, 21st Edition, Page 2863,2864

↑ *Back to this question in Part A*

@Neet_pg_bot

Q5: A 46-year-old man presents to the OPD with severe pain, redness, and swelling in his right knee. Examination reveals tender swelling and redness at the base of the right 1st toe. Serum urate levels are normal, but arthrocentesis reveals negatively birefringent needle-shaped crystals under polarised light. Which of the following is the drug of choice for this acute attack? (Q851623)

A. Canakinumab

B. Oral colchicine

C. Intra-articular glucocorticoid injection

D. Allopurinol

Correct Answer: B. Oral colchicine

Explanation: Oral colchicine is the drug of choice for the management of acute gout attacks. Canakinumab (Option A) is an IL-1 β inhibitor. Glucocorticoids (Option C): It can be used as an intramuscular injection for multi-articular involvement or intra-articular injection for mono-articular involvement, or orally. Allopurinol (Option D) is a urate-lowering agent that is not recommended during active gout flares, as it can exacerbate the attack.

References:

Harrison’s Principles of Internal Medicine, 21st Edition, Page 2864-2865

Davidson’s Principles and Practice of Medicine, 24th Edition, Page 1015

Anakinra - LiverTox - NCBI Bookshelf

Colchicine - StatPearls - NCBI Bookshelf

↑ *Back to this question in Part A*

@Neet_pg_bot

Q6: A 48-year-old man had an acute gout attack treated successfully with NSAIDs. His labs show markedly elevated serum uric acid and high 24-hour urinary uric acid excretion. Which drug is the best choice for long-term management? (Q851624)

A. Pegloticase

B. Allopurinol

C. Febuxostat

D. Anakinra

Correct Answer: B. Allopurinol

Explanation: Allopurinol is the first-line treatment for the prevention of gouty arthritis, particularly in patients who are overproducers of uric acid. The initial dose is typically 100 mg daily, with a target urate level of <5-6 mg/dL and can be titrated up to 800 mg as needed. Febuxostat (Option C) is a newer xanthine oxidase inhibitor administered for patients who cannot tolerate allopurinol. Pegloticase (Option A) : Recombinant uricase enzyme used in cases resistant to standard therapy. Anakinra (Option D): For resistant cases

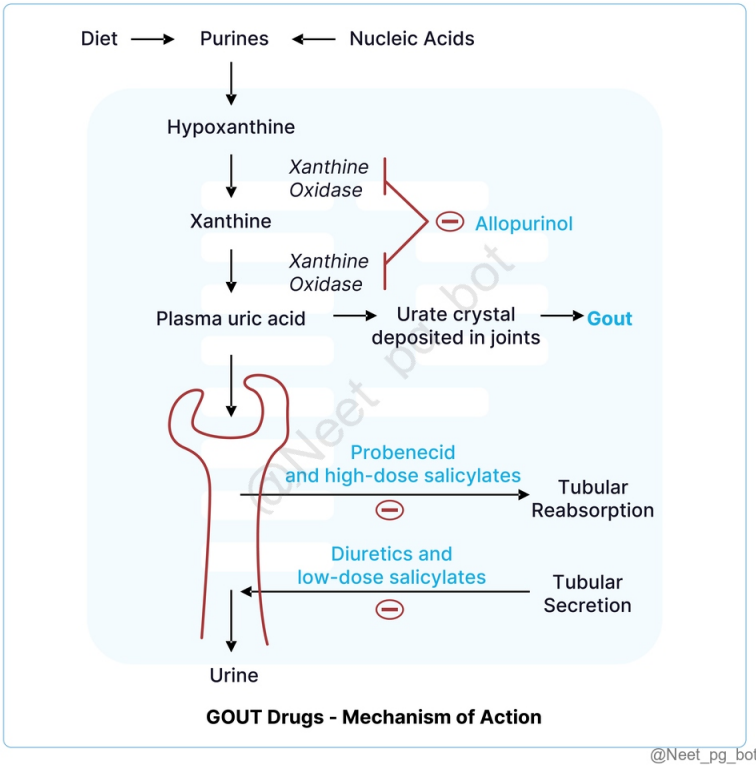

References:

Harrison’s Principles of Internal Medicine, 21st Edition, Page 2864-2865 Davidson’s Principles and Practice of Medicine, 24th Edition, Page 1016

↑ *Back to this question in Part A*

@Neet_pg_bot

Q7: A 45-year-old male with stage 2 chronic kidney disease presents with painful swelling at the base of his left big toe. He was diagnosed with an acute gouty attack and treated with oral glucocorticoids. Which anti-gout medication can be used to reduce the risk of another attack without dose modification? (Q851625)

A. Probenecid

B. Allopurinol

C. Febuxostat

D. Lesinurad

Correct Answer: C. Febuxostat

Explanation: Febuxostat is a xanthine oxidase inhibitor that undergoes hepatic metabolism; thus, no dose adjustment is required for renal impairment. Probenecid (Option A) is a uricosuric second-line agent for gout . It can be used as monotherapy or in combination with allopurinol. But it is ineffective in patients with renal insufficiency. Allopurinol (Option B) is a xanthine oxidase inhibitor and the first-line treatment for gout prevention. However, it is not safe for renal insufficiency due to its renal excretion, which increases the risk of severe cutaneous adverse reactions, including Stevens-Johnson syndrome and toxic epidermal necrolysis. Lesinurad (Option D) is a renal urate transporter inhibitor that targets URAT1 and OAT4 However, it is associated with elevated serum creatinine levels, making it contraindicated in patients with renal insufficiency.

References:

Harrison’s Principles of Internal Medicine, 21st Edition, Page 2864-2865

Davidson’s Principles and Practice of Medicine, 24th Edition, Page 1016

www.sciencedirect.com/science/article/abs/pii/S1471489222000686

www.sciencedirect.com/topics/pharmacology-toxicology-and-pharmaceutical-science/lesinurad

pmc.ncbi.nlm.nih.gov/articles/PMC3937145/

↑ *Back to this question in Part A*

@Neet_pg_bot

Q8: A 65-year-old man presents to the emergency department with sudden swelling, redness, and severe pain in both knees. He has experienced intermittent joint pain for the past few months. Polarised light microscopy of joint aspiration reveals rhomboid-shaped crystals exhibiting positive birefringence. Which statement best explains the pathogenesis of his condition? (Q851627)

A. Excessive mechanical wear and tear of the articular cartilage

B. Deposition of calcium pyrophosphate crystals in cartilage matrix vesicles

C. Excess purine production causes crystal deposition in the joints

D. Autoimmune reaction leading to pannus formation in the joint



Correct Answer: B. Deposition of calcium pyrophosphate crystals in cartilage matrix vesicles

Explanation: The clinical presentation and polarised light microscopy findings of rhomboid-shaped crystals with positive birefringence indicate Calcium pyrophosphate deposition disease (CPPD) or 'Pseudogout' in which deposition of calcium pyrophosphate crystals in cartilage matrix vesicles is seen. Calcium pyrophosphate deposition disease Aetiology Ageing Osteoarthritis Post Meniscectomy or joint trauma Familial-genetic Hemochromatosis Hypophosphatasia Hypomagnesemia Certain drugs: Thiazide and loop diuretics Malabsorption Gitelman's syndrome Gout X-linked hypophosphatemic rickets Familial hypocalciuric hypercalcemia Pathogenesis Mutation in ANKH gene ➜ Increased extracellular transportation of pyrophosphate. Decreased levels of glycosaminoglycans in the cartilage, which results in Increased inorganic pyrophosphate in the cartilage

matrix. Calcium combines with this pyrophosphate to form excess CCP. Phagocytosis of CCP crystals by neutrophils and macrophage inflammation. Clinical features Acute attack may follow surgery (especially parathyroidectomy) and trauma Systemic signs can occur during the attack, such as fever and chills. Joint swelling, redness and pain. Most commonly affected joint: Knees . Rarely affected: First metatarsophalangeal joint. Chronic : Symmetrical Polyarticular arthritis with severe joint damage. Chondrocalcinosis can occur. Diagnosis X-ray: Punctate or linear radiodense deposits within fibrocartilaginous joint meniscus or articular hyaline cartilage. {{caption_text}} Arthrocentesis: Positively birefringent rhomboid-shaped crystals under polarised light Excessive mechanical wear and tear of the articular cartilage (Option A) is seen with osteoarthritis , leading to cartilage degradation, bone spurs, and reduced joint space. It typically presents with asymmetrical joint involvement and does not usually show any crystal deposition in the joints. Excess purine production causes crystal deposition in the joints (Option C), which causes gout. Urate crystals are strongly negatively birefringent needle-shaped crystals under polarised light. Autoimmune reaction leading to pannus formation in the joint (Option D) is seen in rheumatoid arthritis , a CD4+ mediated autoimmune condition. RA presents with symmetrical small joint pain and stiffness, especially in the morning, which improves during the day. During microscopy of synovial fluid, it does not show any form of crystal.





References:

Harrison’s Principles of Internal Medicine, 21st Edition, Page 2865-2866

↑ *Back to this question in Part A*

@Neet_pg_bot

Q9: A 75-year-old woman presents to the clinic with chronic pain and swelling in her shoulder joint. Radiographs reveal calcific tendinitis in the rotator cuff. A joint aspiration is performed, and the synovial fluid is analysed. If this patient has calcium apatite deposition disease, what type of crystal is most likely to be seen in the patient's synovial fluid? (Q851629)

A. Positively birefringent rhomboid-shaped crystals

B. Strong birefringent bipyramidal crystals

C. Negatively birefringent needle-shaped crystals

D. Microcrystals with no birefringence

Correct Answer: D. Microcrystals with no birefringence

Explanation: Calcium apatite (basic calcium phosphate) crystals are very small, non-birefringent microcrystals that cannot be seen clearly under polarised light microscopy. They often appear as “shiny, broad, clumped aggregates” (also called calcific debris). This is characteristic of calcific tendinitis and calcium apatite deposition disease . Microscopy of synovial fluid Gout (Monosodium urate) Negatively birefringent needle-shaped crystals (Option C ruled out) {{caption_text}} Pseudogout (Calcium pyrophosphate) Positively birefringent rhomboid-shaped crystals (Option A ruled out) Calcium Apatite deposition disease Microcrystals of apatite in the synovial fluid show no birefringence under polarised light. Calcium oxalate deposition disease Variable shape and variable birefringence The most easily recognisable crystals are strong birefringent bipyramidal crystals. (Option B ruled out)







References:

Harrison's Principles of Internal Medicine, 21st Edition, Page 2864-2867

↑ *Back to this question in Part A*

@Neet_pg_bot

Q10: Match each condition with its corresponding key synovial fluid characteristics: Conditions Key Characteristics 1. Normal a. Yellow, Cloudy, >50,000 WBC 2. Non-inflammatory b. Colorless, Clear, <200 WBC 3. Inflammatory c. Yellow, Opaque, Positive Gram Stain 4. Septic d. Xanthochromic or Red, Bloody 5. Hemarthrosis e. Straw-like, Clear, 200 - 2000 WBC (Q851630)

A. 1 - b, 2 - e, 3 - a, 4 - c, 5 - d

B. 1 - a, 2 - b, 3 - e, 4 - d, 5 - c

C. 1 - c, 2 - d, 3 - b, 4 - e, 5 - a

D. 1 - b, 2 - c, 3 - a, 4 - d, 5 - e

Correct Answer: A. 1 - b, 2 - e, 3 - a, 4 - c, 5 - d

Explanation: Colour Clarity Viscosity WBC(mm3) Neutrophils Gram stain Crystals Normal Colorless Clear High <200 <25% Negative Negative Non - inflammatory Straw like Clear High 200-2000 <25% Negative Negative Inflammatory Yellow Cloudy Low 2000-50000 >50% Negative Positive Septic Yellow Opaque Low >50,000 >75% Positive Negative Hemarthrosis Xanthochromic or red Bloody Variable 200-2000 50-75% Negative Negative

References:

Synovial Fluid Analysis - StatPearls - NCBI Bookshelf

Arthrocentesis - StatPearls - NCBI Bookshelf

↑ *Back to this question in Part A*

@Neet_pg_bot

• [08_Rheumatology] 064 Scleroderma And Sjogren Syndrome

« Back to Folder Directory

[08_Rheumatology] 064 Scleroderma And Sjogren Syndrome — Quick Jump

Q1 (p. 2612) *Q2 (p. 2613)* *Q3 (p. 2617)* *Q4 (p. 2617)* *Q5 (p. 2619)* *Q6 (p. 2621)*
Q7 (p. 2622) *Q8 (p. 2623)* *Q9 (p. 2623)* *Q10 (p. 2624)* *Q11 (p. 2625)* *Q12 (p. 2627)*

Q1: A 45-year-old lady presents with skin changes, reporting that her fingers have become thick and tight. She has developed painful ulcers on her fingertips that heal slowly. The physician notes shiny, taut skin on her face and limited neck extension. The given image shows the patient's facial features. Which of the following findings is not typically associated with the skin changes observed in this patient? {{caption_text}} (Q851373)

A. Bilateral symmetrical skin thickening

B. Hyperpigmentation in sun-exposed areas

C. Fixed flexion contractures of the fingers

D. Telangiectasia on the face and hands



Correct Answer: B. Hyperpigmentation in sun-exposed areas

Explanation: The patient’s symptoms - thickened and tight skin on the fingers, painful fingertip ulcers, shiny facial skin, and limited neck extension - are characteristic of systemic sclerosis (scleroderma). The given image shows the shiny facial skin with Mauskopf or mouse-like facies typically seen in scleroderma. Hyperpigmentation in sun-exposed areas is not typically associated with systemic sclerosis. Instead, patients often exhibit early diffuse tanning without sun exposure or a "salt-and-pepper" appearance , particularly in darker-skinned individuals. Dermal Manifestations of Systemic Sclerosis (SSc): Bilateral Symmetrical Skin Thickening : Begins distally in the fingers and progresses proximally. (Option A ruled out) Fixed Contractures : Affects wrists, elbows, and knees due to skin and tendon fibrosis. (Option C ruled out) Facial Changes ("Mauskopf") Telangiectasia : Dilated capillaries on face, hands, lips, and oral mucosa; correlated with microvascular disease severity. (Option D ruled out)

References:

Harrison’s Principles of Internal Medicine, 21st Edition, Page 2779, 2780

Systemic Sclerosis (Scleroderma) - StatPearls - NCBI Bookshelf

↑ *Back to this question in Part A*

@Neet_pg_bot

Q2: Which of the following statements about the histopathological examination (HPE) of the images is correct? A) {{caption_text}} B) {{caption_text}} Image A shows a

thickened dermis with collagen accumulation and loss of adipose tissue. Image B demonstrates normal glomerular architecture with no signs of injury. Image B shows vascular lesions and ischemic glomerular changes. Image A is characterized by alveolar septal fibrosis leading to gas exchange impairment. (Q851375)

A. 3 and 4

B. 2 and 4

C. Only 2

D. 1 and 3

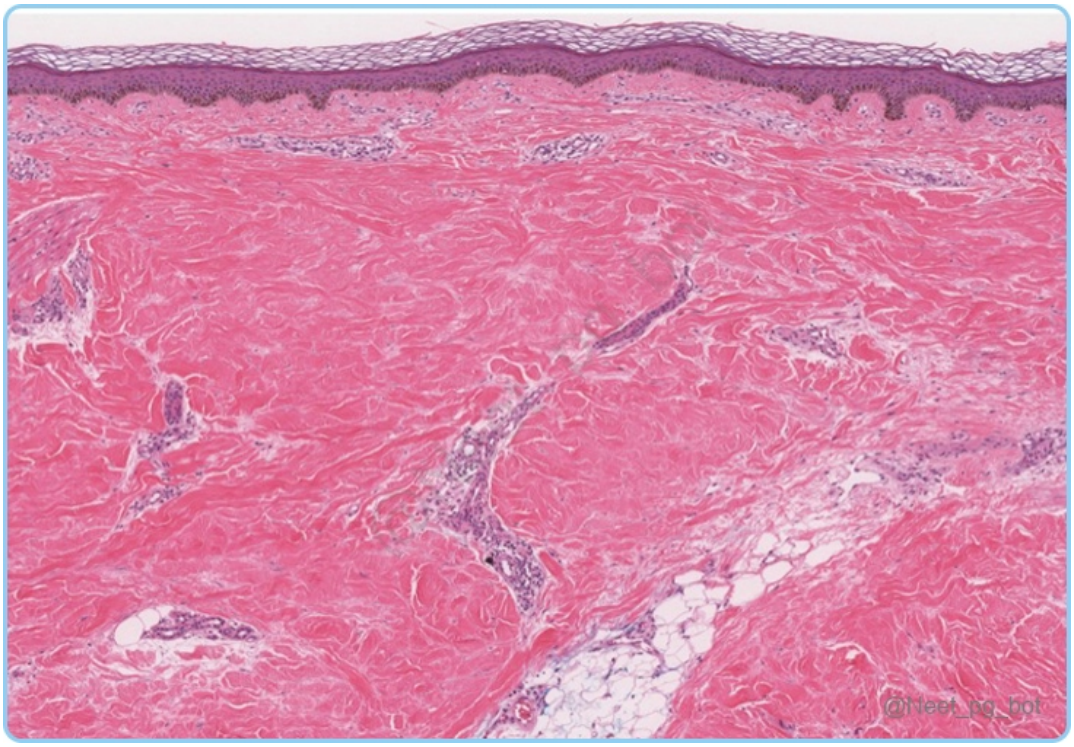

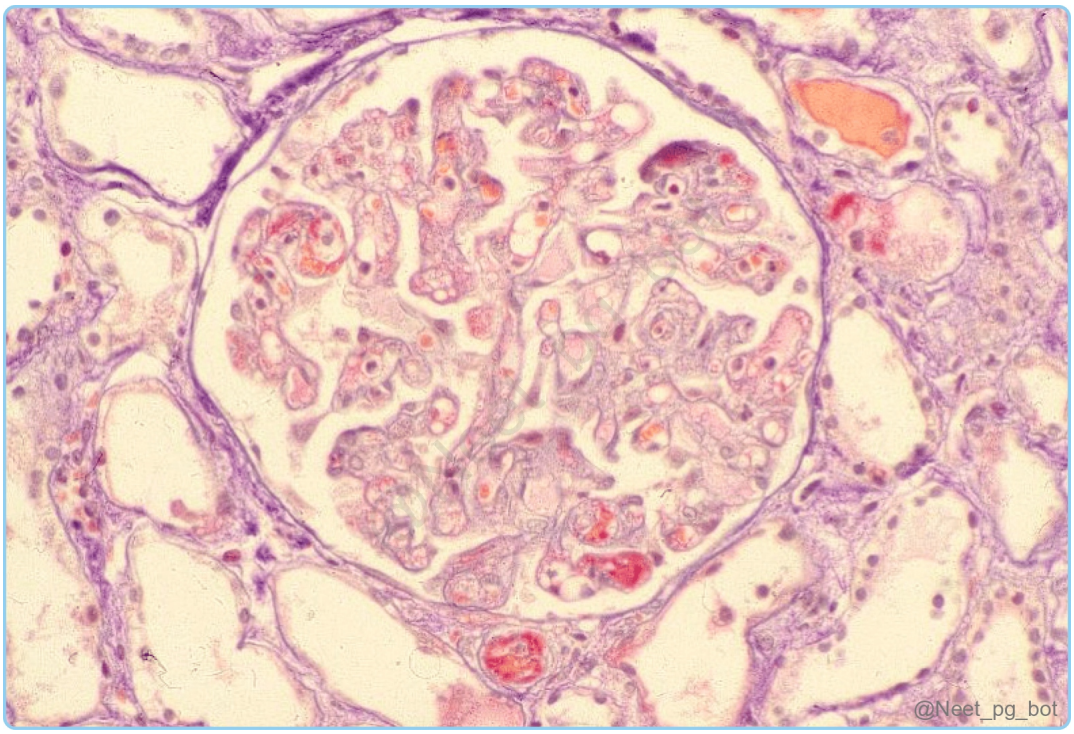

Correct Answer: D. 1 and 3

Explanation: Statement 1 correctly describes the pathologic findings in the skin (Image A) , which include thickened dermis and loss of subcutaneous adipose tissue due to collagen accumulation. Statement 3 accurately reflects the findings in the kidneys (Image B) , which include vascular lesions and ischemic changes. Systemic Sclerosis: Organ/System Pathologic Findings Skin Thickened dermis due to collagen accumulation and atrophic adnexal glands. Loss of subcutaneous adipose tissue replaced by collagen. {{caption_text}} Kidneys Vascular lesions in interlobular and arcuate arteries; ischemic glomerular changes. Scleroderma renal crisis shows fibrinoid necrosis of arterioles, intimal proliferation, and thrombotic microangiopathy-like changes. {{caption_text}}

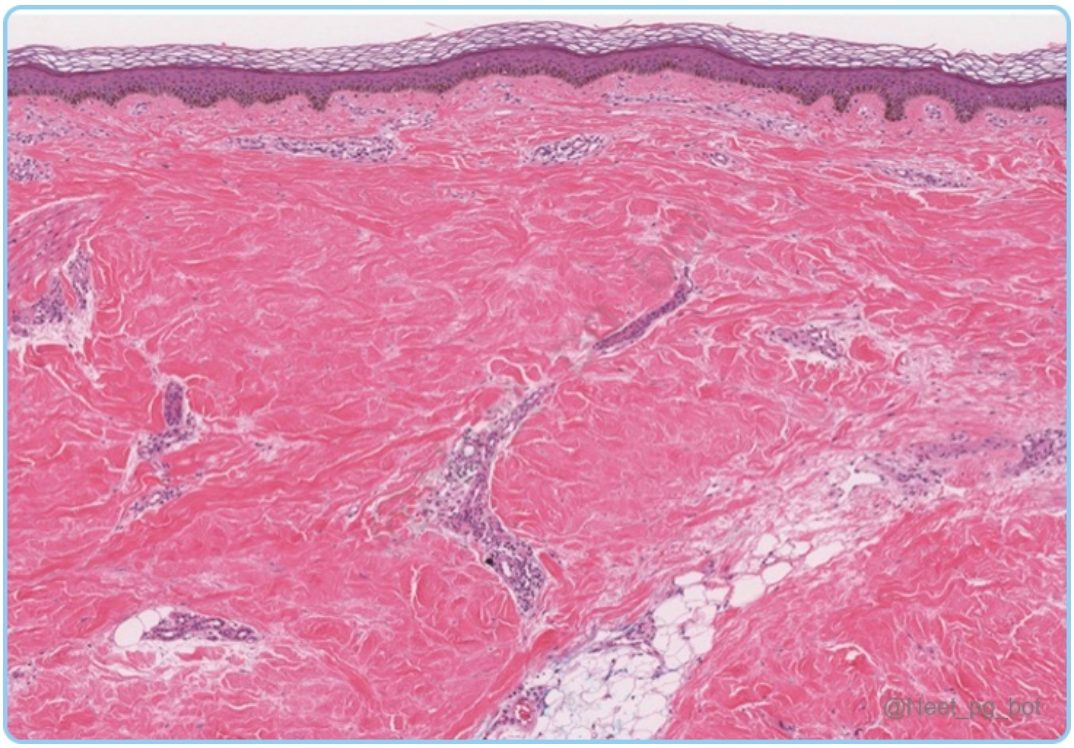

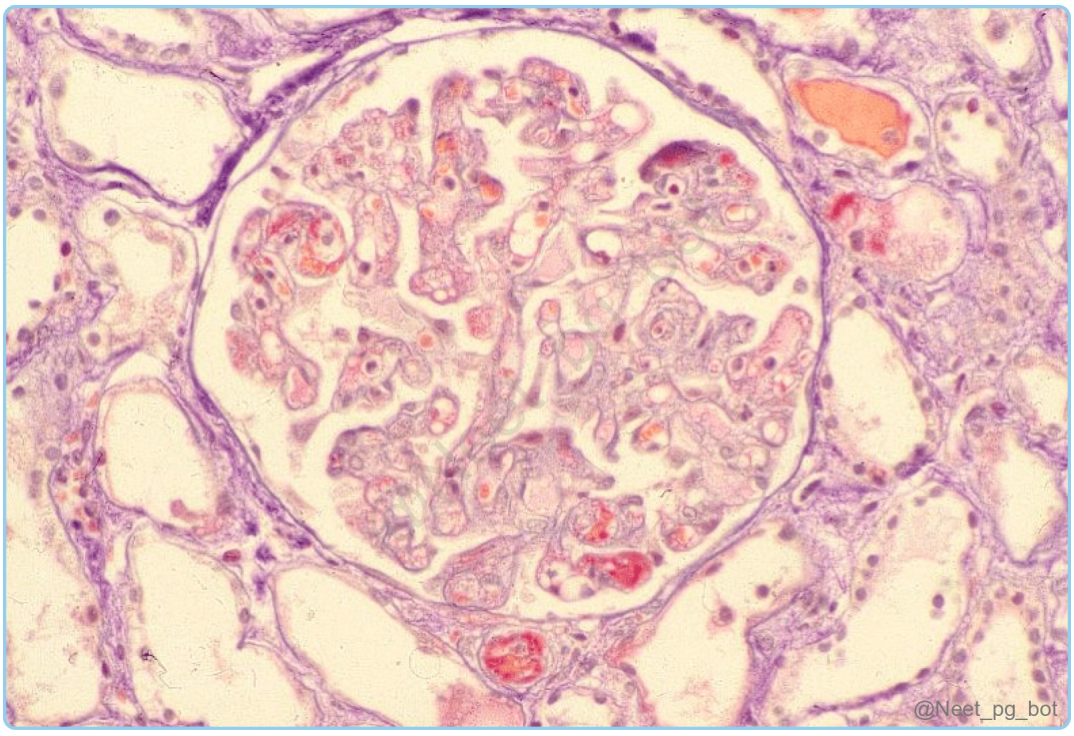

References:

Harrison’s Principles of Internal Medicine, 21st Edition, Page 2776, 2777

↑ *Back to this question in Part A*

@Neet_pg_bot

Q3: A 52-year-old woman presents with skin changes, including thickened and tight skin on her fingers, as well as pain and ulcerations at the fingertips. On examination, she has a shiny appearance to her skin and visible telangiectasia on her face. Which of the following options includes one pulmonary and one cardiac manifestation correctly associated with her clinical features? (Q851376)

A. Tuberculosis; Congestive cardiac failure

B. Cavitation; Pericarditis

C. Pulmonary arterial hypertension; Constrictive pericarditis

D. Non-caseating granuloma; Atrial myxoma

Correct Answer: C. Pulmonary arterial hypertension; Constrictive pericarditis

Explanation: The patient's skin changes, including thickened skin and telangiectasia, suggest systemic sclerosis , which often leads to pulmonary arterial hypertension (PAH) and constrictive pericarditis due to vascular involvement and fibrosis. Tuberculosis; Congestive cardiac failure (Option A): Tuberculosis is not associated with systemic sclerosis (SSc). Congestive cardiac failure can occur due to various conditions but is not specific to SSc. Cavitation; Pericarditis (Option B): Cavitation is linked to infections, not SSc. Pericarditis can occur in SSc, but this option does not represent a key pulmonary feature. Non-caseating granuloma; Atrial myxoma (Option D): Non-caseating granulomas are associated with sarcoidosis, not SSc. Atrial myxoma is unrelated to SSc, making this option incorrect.

References:

Harrison’s Principles of Internal Medicine, 21st Edition, Page 2780-2782

↑ *Back to this question in Part A*

@Neet_pg_bot

Q4: A 45-year-old woman with systemic sclerosis presents with new-onset hypertension and episodes of cold-induced finger discoloration. Which statement about her renal and vascular manifestations is false? (Q851377)

A. Scleroderma renal crisis presents with accelerated hypertension and can cause renal failure.

B. Raynaud's phenomenon is the most common extracutaneous feature and can lead to ulcers.

C. Anti-centromere antibodies increase the risk of scleroderma renal crisis.

D. Nailfold capillaroscopy distinguishes between primary and secondary Raynaud’s.

Correct Answer: C. Anti-centromere antibodies increase the risk of scleroderma renal crisis.

Explanation: Anti-centromere antibodies are associated with a lower risk of scleroderma renal crisis. Commonly presents with severe accelerated hypertension (>150/90 mmHg) and oliguric acute renal failure; ~10% are normotensive but have poor outcomes. (Option A ruled out) Raynaud’s Phenomenon is the m ost common extracutaneous feature in SSc. (Option B ruled out) Nailfold Capillaroscopy (Option D ruled out) : Primary Raynaud’s : Evenly spaced parallel capillary loops. Secondary Raynaud’s : Distorted, widened, irregular capillary loops, dilated lumen, microhemorrhages, and vascular dropout. {{caption_text}} {{caption_text}}



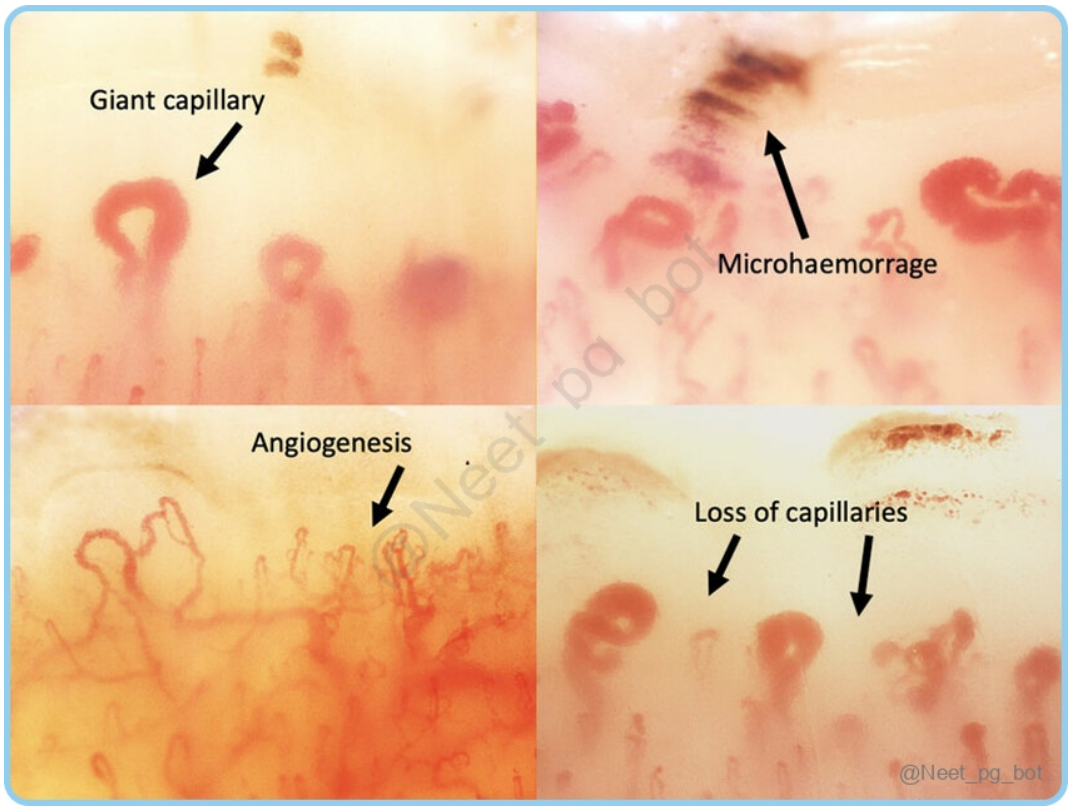

References:

Harrison’s Principles of Internal Medicine, 21st Edition, Page 2778, 2782

Davidson’s Principles and Practice of Medicine, 24th Edition, Page 1037, 1038

↑ *Back to this question in Part A*

@Neet_pg_bot

Q5: A 45-year-old woman presents with symptoms including skin thickening on her fingers, fatigue, and shortness of breath with episodes of painful swelling in her fingertips and difficulty swallowing. During her examination, a specific immunofluorescence test is performed, revealing the presence of several autoantibodies. Which of the following auto-antibodies is most likely associated with severe skin involvement and interstitial lung disease in this patient? (Q851378)

A. Centromere Proteins

B. Topoisomerase I (Scl-70)

C. RNA Polymerase III

D. U1-RNP

Correct Answer: B. Topoisomerase I (Scl-70)

Explanation: The patient's symptoms, including skin thickening, fatigue, and shortness of breath, suggest systemic sclerosis with severe skin and pulmonary involvement. Topoisomerase I (Scl-70) is associated with diffuse cutaneous SSc and linked to severe skin involvement, interstitial lung disease (ILD), and renal crisis. Auto-Antibody Prominent Characteristic Topoisomerase I (Scl-70) Speckled pattern {{caption_text}} Tendon friction rubs, digital ischemic ulcers, scleroderma, extensive skin involvement, early ILD, cardiac involvement, scleroderma renal crisis Centromere proteins Discrete speckled (centromere) pattern {{caption_text}} Digital ischemic ulcers, calcinosis cutis, isolated PAH; renal crisis rare (Option A ruled out) RNA polymerase III Speckled pattern Rapidly progressive skin involvement, tendon friction rubs, joint contractures, GAVE, renal crisis, contemporaneous cancers; digital ulcers rare (Option C ruled out) U1-RNP Speckled pattern PAH, inflammatory arthritis, myositis overlap (Option D ruled out)

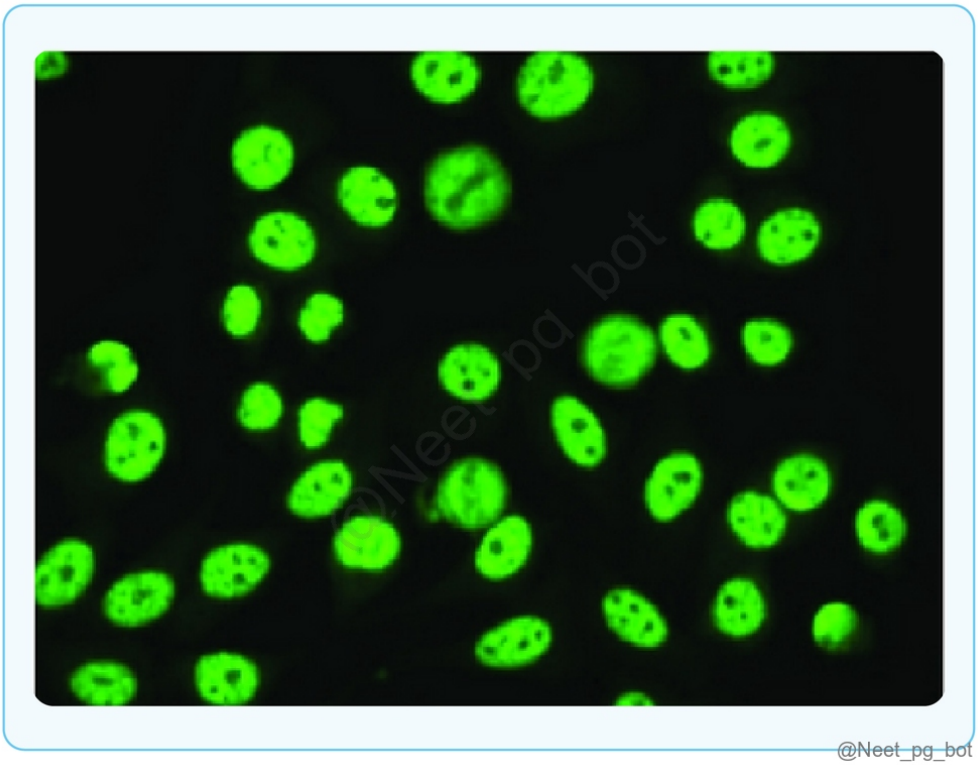

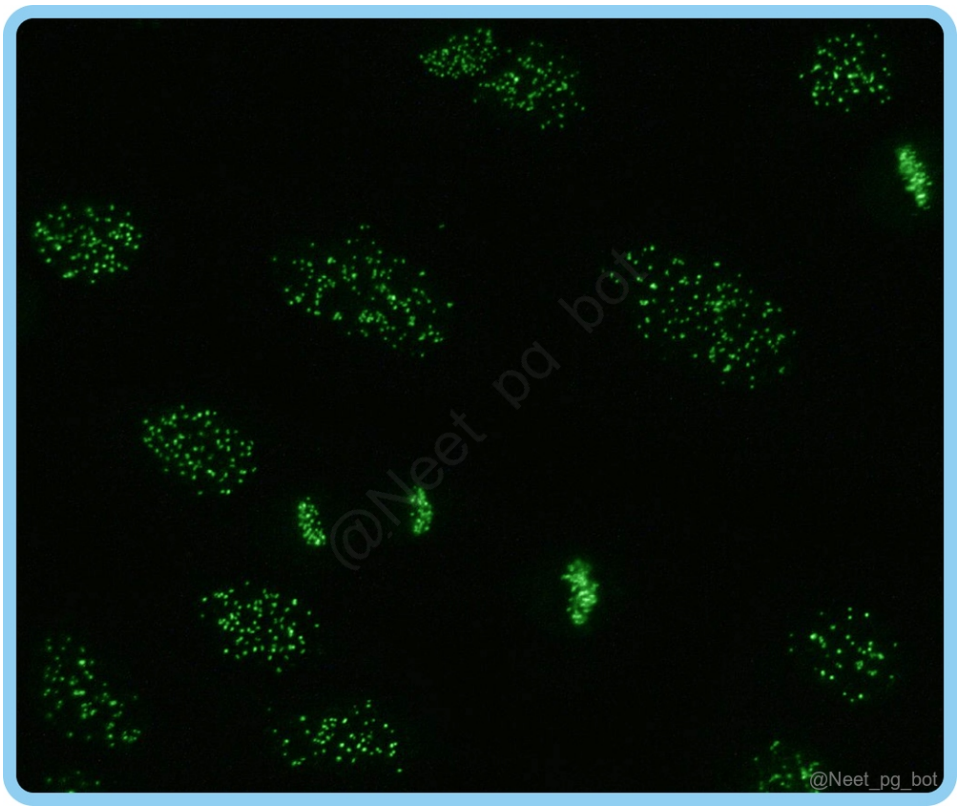

References:

Harrison’s Principles of Internal Medicine, 21st Edition, Page 2776

↑ *Back to this question in Part A*

@Neet_pg_bot

Q6: A 60-year-old woman presents with severe fatigue, dry mouth, difficulty swallowing, and episodes of coldness and color changes in her fingers. She reports dyspnea on exertion and has a history of gastrointestinal reflux. There is no visible skin thickening. Laboratory tests show positive anti-nuclear antibodies and anti-Scl-70 antibodies. Which condition is she most likely experiencing? (Q851379)

A. Limited Scleroderma

B. Diffuse Scleroderma

C. Sine Sclerosis

D. Sjögren's Syndrome

Correct Answer: C. Sine Sclerosis

Explanation: Given the patient's presentation (including symptoms of Raynaud's phenomenon , dyspnea on exertion , and gastrointestinal issues such as heartburn) and positive anti-Scl-70 antibodies with no visible skin thickening , the most likely diagnosis is Sine Sclerosis . Limited Scleroderma (Option A ruled out): Most common type of scleroderma. Skin thickening is usually limited to fingers, hands, forearms, or face. Diffuse Scleroderma (Option B): Skin thickening over large body areas (fingers, hands, arms, anterior trunk, legs, and face). Sjögren's Syndrome (Option D) is an autoimmune disorder primarily affecting moisture-producing glands, leading to dry mouth and eyes.

References:

www.hopkinsmedicine.org/health/conditions-and-diseases/scleroderma/types-of-scleroderma

www.uofmhealth.org/conditions-treatments/rheumatology/classification-scleroderma

↑ *Back to this question in Part A*

@Neet_pg_bot

Q7: A 25-year-old female presents with episodes of sequential color changes in her fingers (white, blue, and red) triggered by cold exposure. She has no underlying conditions, normal nail fold capillaroscopy, and symmetric involvement. Which of the following is the most likely diagnosis (Q851380)

A. Secondary Raynaud's Due To Scleroderma

B. Primary Raynaud's Phenomenon

C. Acrocyanosis

D. Secondary Raynaud's Due To SLE

Correct Answer: B. Primary Raynaud's Phenomenon

Explanation: This patient has Primary Raynaud's phenomenon because: Young female (age 20-40 years, female: male ratio 5:1) Classic triphasic color changes No underlying condition Normal nail fold capillaroscopy showing regular hairpin loops Symmetric involvement Cold trigger Secondary Raynaud's Due To Scleroderma (Option A): There are no signs of scleroderma-like skin tightening, sclerodactyly, or internal organ involvement, and is associated with digital ulcers and tissue loss Acrocyanosis (Option C): Acrocyanosis is persistent rather than episodic, does not show triphasic color changes, discoloration extends proximally from digits, and no blanching occurs. Secondary Raynaud's Due To SLE (Option D): Only about 20% of SLE patients develop Raynaud's, other systemic symptoms of SLE would be present, and may have associated antibodies.

References:

Harrison's Principles Of Internal Medicine, 21st Edition, Volume I, Page. 2112, 2113

↑ *Back to this question in Part A*

@Neet_pg_bot

Q8: A 42-year-old female with diffuse cutaneous systemic sclerosis presents with severe headache, blurred vision, and blood pressure of 180/100 mmHg. Laboratory findings show creatinine of 2.8 mg/l, without thrombocytopenia or fragmented RBCs in peripheral smear. She has recently started on prednisolone 20mg daily for severe skin involvement. Which of the following is the most appropriate immediate management? (Q851382)

A. Start calcium channel blockers and taper steroids

B. Immediate initiation of short-acting ACE inhibitors

C. Start plasmapheresis for suspected TTP

D. Increase steroid dose to control inflammation

Correct Answer: B. Immediate initiation of short-acting ACE inhibitors

Explanation: Short-acting ACE inhibitors are the first-line treatment for scleroderma renal crisis. This is a medical emergency requiring: Immediate hospitalization Prompt initiation of ACE inhibitors Rapid blood pressure normalization Start calcium channel blockers and taper steroids (Option A) : While useful for Raynaud's phenomenon, calcium channel blockers are not the first-line treatment for scleroderma renal crisis. Start plasmapheresis for suspected TTP (Option C) : While the presentation might mimic TTP with microangiopathic hemolysis and thrombocytopenia, this is characteristic of Scleroderma renal crisis. Increase steroid dose to control inflammation (Option D): This would worsen the condition as glucocorticoids are a risk factor for scleroderma renal crisis. high-dose steroids (>10 mg/day) should be avoided in high-risk patients.

References:

Harrison’s Principles Of Internal Medicine, 21st Edition, Volume I, Page 2782, 2786

https://www.researchgate.net/figure/UKSSG-guidelines-on-the-diagnosis-and-management-of-scleroderma-renal-crisis-Reproduced_fig3_361015939

↑ *Back to this question in Part A*

@Neet_pg_bot

Q9: A 42-year-old female with diffuse cutaneous systemic sclerosis presents with worsening dyspnea and reduced lung function tests showing a restrictive pattern.

Which of the following is the most appropriate treatment choice? (Q851383)

A. High-dose oral glucocorticoids

B. Cyclophosphamide

C. Hydroxychloroquine

D. Thalidomide

Correct Answer: B. Cyclophosphamide

Explanation: Cyclophosphamide has been shown to reduce the progression of SSC-associated interstitial lung disease (ILD). It can stabilize and provide modest improvement in pulmonary function, HRCT findings, respiratory symptoms, and skin induration. High-dose oral glucocorticoids (Option A) : While glucocorticoids may help with early inflammatory symptoms, they do not influence the progression of skin or internal organ involvement. Hydroxychloroquine and Thalidomide (Option C and D): It lacks evidence for efficacy in treating SSC-associated ILD.

References:

Harrison's Principles Of Internal Medicine, 21st Edition, Volume I, Page 2783, 2784

↑ *Back to this question in Part A*

@Neet_pg_bot

Q10: A 45-year-old woman presents with dry eyes and a dry mouth that has been persistent for the past 8 months. She also reports joint stiffness, fatigue, and recent dental caries. Histology reveals lymphocytic infiltration in the salivary glands. Which of the following factors is most directly implicated in the pathogenesis of her condition? (Q851386)

A. CD8+ T cell infiltration in exocrine glands

B. Hypergammaglobulinemia with elevated B-cell activation

C. Mutations in the CFTR gene

D. Eosinophilic infiltration in minor salivary glands

Correct Answer: B. Hypergammaglobulinemia with elevated B-cell activation

Explanation: Sjogren Syndrome pathogenesis involves hyperactivity of B-cells, resulting in hypergammaglobulinemia and the production of autoantibodies (e.g., anti-Ro and anti-La). This autoimmune

activity leads to chronic lymphocytic infiltration in the exocrine glands, causing dryness and inflammation of the lacrimal and salivary glands■. CD8+ T cell infiltration in exocrine glands (Option A): CD4+ T cells predominantly infiltrate the glands in Sjogren Syndrome, not CD8+ T cells. Mutations in CFTR gene (Option C): CFTR gene mutations are associated with cystic fibrosis, not Sjogren Syndrome. Eosinophilic infiltration in minor salivary glands (Option D): Sjogren Syndrome typically shows lymphocytic rather than eosinophilic infiltration.

References:

Harrison's Principles Of Internal Medicine, 21st Edition, Volume I, Page 2788, 2789.

↑ *Back to this question in Part A*

@Neet_pg_bot

Q11: A 47-year-old female presents with a history of persistent dry mouth and a gritty sensation in her eyes. Her clinical evaluation is significant for dry mucous membranes and parotid gland swelling. A labial salivary gland biopsy is performed, and the histopathological examination reveals inflammatory infiltration. Based on the histopathological findings in the provided image, which of the following features would most specifically support a diagnosis? (Q851391)

A. Presence of multiple non-caseating granulomas

B. Lymphocytic foci surrounding ducts with a focus score ≥ 1 per 4 mm^2 area

C. Diffuse infiltration predominantly by neutrophils

D. Eosinophilic infiltration with periductal fibrosis

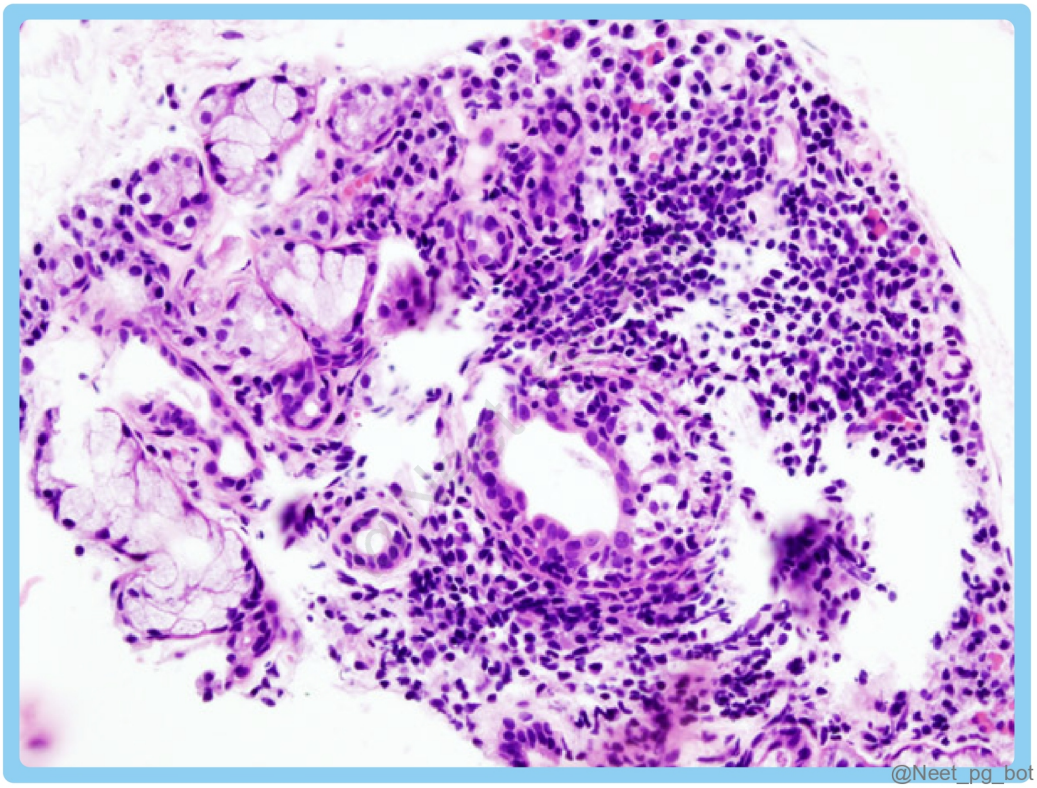

Correct Answer: B. Lymphocytic foci surrounding ducts with a focus score ≥ 1 per 4 mm² area

Explanation: The most characteristic histologic feature of Sjogren Syndrome is the presence of lymphocytic infiltration in the minor salivary glands, quantified by a focus score. This infiltration is organized into lymphocytic foci surrounding ducts and acini. Unlike other glandular conditions, the presence of these lymphocytic clusters, in patients with sicca symptoms, is highly suggestive of Sjögren syndrome, distinguishing it from conditions like sarcoidosis or IgG4-related disease. The focus score —a measure of the number of lymphocyte clusters per 4 mm² area—helps in diagnosing Sjögren syndrome when it meets or exceeds 1. {{caption_text}} Fig: Focal lymphoid infiltration in the minor salivary gland associated with Sjögren syndrome Presence of multiple non-caseating granulomas (Option A): Non-caseating granulomas are not characteristic of Sjögren syndrome; they are more commonly associated with conditions like sarcoidosis. Diffuse infiltration predominantly by neutrophils (Option C): Neutrophilic infiltration is indicative of an acute inflammatory or infectious process, not chronic autoimmune conditions like Sjögren syndrome. Eosinophilic infiltration with periductal fibrosis (Option D): Eosinophilic infiltration is more commonly seen in allergic reactions or certain parasitic infections.

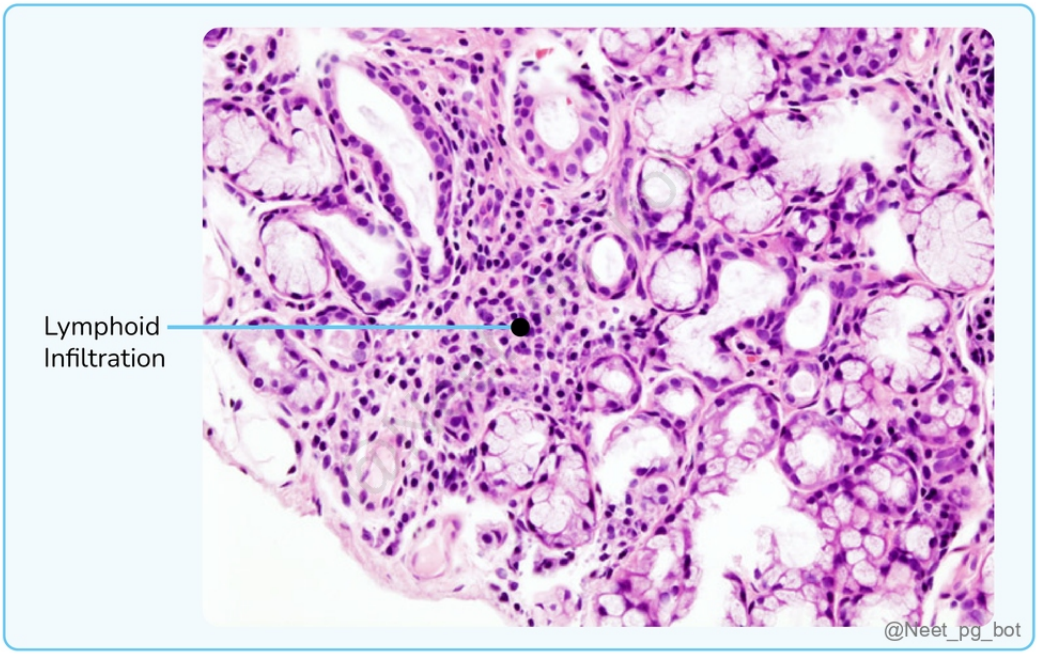

References:

Harrison's Principles Of Internal Medicine, 21st Edition, Volume I, Page 2787-2790.

↑ *Back to this question in Part A*

@Neet_pg_bot

Q12: A patient diagnosed with Sjogren Syndrome reports persistent dry eyes, despite using artificial tears. Which of the following treatments would be considered next to alleviate the ocular symptoms? (Q851397)

A. Oral corticosteroids

B. Antihistamines

C. Topical cyclosporine eye drops

D. NSAIDs

Correct Answer: C. Topical cyclosporine eye drops

Explanation: Topical cyclosporine eye drops are used to reduce inflammation and increase tear production in patients with Sjogren Syndrome. This treatment is effective for patients who do not respond adequately to artificial tears■. Oral corticosteroids (Option A) : While corticosteroids can reduce systemic inflammation, they are not typically used for local ocular symptoms in Sjogren Syndrome, especially as a next-line therapy for dry eyes.

Antihistamines (Option B) : Antihistamines are more likely to worsen dryness as they reduce tear production, so they are inappropriate for treating dry eyes in Sjogren Syndrome. NSAIDs (Option D) : NSAIDs do not directly address the underlying inflammatory mechanisms of dry eyes in Sjogren Syndrome and are not typically used for this indication.

References:

Harrison’s Principles Of Internal Medicine, 21st Edition, Volume I, Page 2789, 2790.

↑ *Back to this question in Part A*

@Neet_pg_bot

• [08_Rheumatology] 065 Autoimmune And Inflammatory Diseases In Medicine

« Back to Folder Directory

[08_Rheumatology] 065 Autoimmune And Inflammatory Diseases In Medicine — Quick Jump

Q1 (p. 2629)	*Q2 (p. 2631)*	*Q3 (p. 2633)*	*Q4 (p. 2635)*	*Q5 (p. 2636)*	*Q6 (p. 2636)*
Q7 (p. 2637)	*Q8 (p. 2639)*	*Q9 (p. 2640)*	*Q10 (p. 2641)*	*Q11 (p. 2641)*	*Q12 (p. 2642)*
Q13 (p. 2643)	*Q14 (p. 2644)*	*Q15 (p. 2644)*	*Q16 (p. 2646)*		

Q1: A 30 y/o woman presents with a persistent cough, fatigue, and painful red nodules on her lower legs. Her ACE levels were found to be elevated and her chest x-ray findings are given below. She has a family history of autoimmune diseases and carries the HLA-DRB1*03 haplotype. What pathophysiological feature is most likely contributing to her condition? (Q851419)

A. Accumulation of neutrophils and eosinophils in lung tissue.

B. Interaction between antigen-presenting cells and T-helper cells leading to granuloma formation.

C. Decreased production of cytokines such as IL-2 and IFN-γ.

D. High levels of cyclosporine in the serum affecting T-cell activity.



Correct Answer: B. Interaction between antigen-presenting cells and T-helper cells leading to granuloma formation.

Explanation: The patient's presentation of persistent cough, fatigue, and erythema nodosum, along with bilateral hilar lymphadenopathy on chest x-ray and elevated serum ACE levels, is indicative of sarcoidosis. Interaction between antigen-presenting cells and T-helper cells leads to granuloma formation which is the hallmark feature in sarcoidosis. Pathophysiology of Sarcoidosis : Accumulation of neutrophils and eosinophils in lung tissue (Option A): Sarcoidosis primarily involves macrophages and T-helper cells, not neutrophils or eosinophils. Decreased production of cytokines such as IL-2 and IFN-γ (Option C): Sarcoidosis is associated with increased levels of these cytokines, not decreased. High levels of cyclosporine in the serum affect T-cell activity (Option D): Cyclosporine has minimal impact on sarcoidosis treatment and is not typically involved in the disease process.

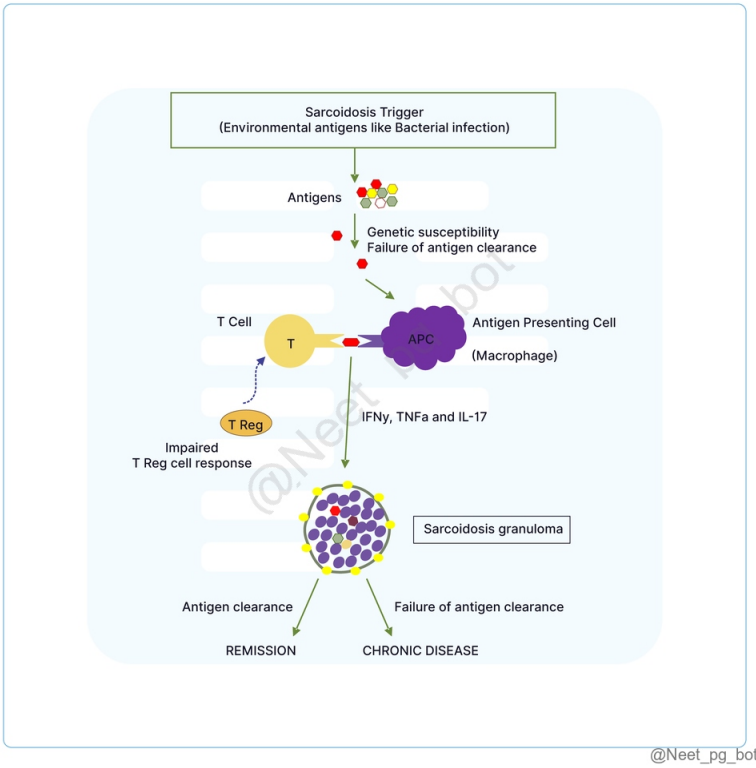

@Neet_pg_bot

References:

Harrison’s Principles of Internal Medicine, 21st Edition, Page 2830

↑ *Back to this question in Part A*

@Neet_pg_bot

Q2: A 35-year-old woman presents to the ED with severe chest pain and palpitations. She has a history of recurrent cough and fatigue over the past year. O/E, she has slight oedema in her lower extremities and a heart murmur. The chest X-ray of the patient is given below. Which of the following features is least likely associated with this patient's condition? (Q851423)

A. Anterior uveitis leading to vision changes.

B. Elevated alkaline phosphatase and portal hypertension.

C. Hypocalcemia and hypocalciuria with increased PTH.

D. Congestive heart failure



Correct Answer: C. Hypocalcemia and hypocalciuria with increased PTH.

Explanation: The patient's symptoms, including severe chest pain, palpitations, recurrent cough, and the chest X-ray showing bilateral hilar lymphadenopathy, are indicative of sarcoidosis . Sarcoidosis typically causes hypercalcemia and suppressed PTH due to increased 1,25-dihydroxyvitamin D. System Features Eye Anterior uveitis, posterior eye involvement (retinitis, pars planitis), sicca, photophobia and blurred vision; can lead to blindness, more common in African Americans. (Option A) Liver Granulomatous involvement in >50%, symptomatic in 5%, can lead to portal hypertension. (Option B) Cardiac Congestive heart failure, arrhythmias, AV block, ventricular tachycardia, left ventricular dysfunction, heart block. (Option D ruled out)

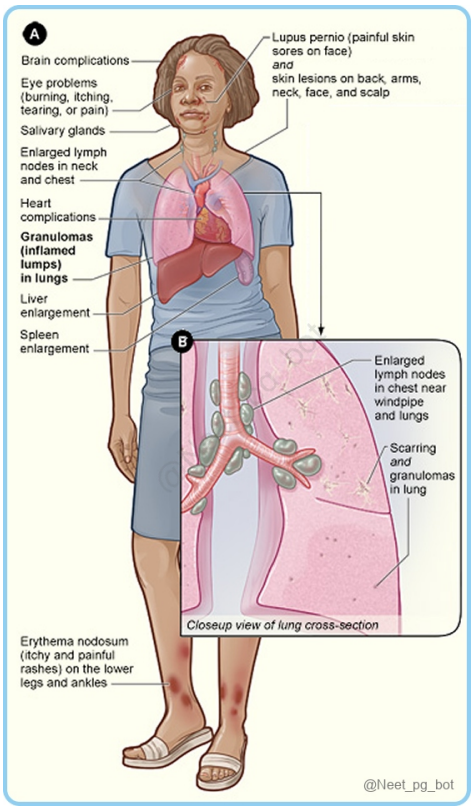

References:

Harrison’s Principles of Internal Medicine, 21st Edition, Page 2830- 2833

Davidson’s Principles and Practice of Medicine, 24th Edition, Page 608, 609

↑ *Back to this question in Part A*

@Neet_pg_bot

Q3: A 40-year-old woman has been suffering from a persistent cough, progressive shortness of breath, and fatigue for the past several months. A chest X-ray shows bilateral hilar lymphadenopathy. The patient also has a skin rash, as shown in the image below. Which of the following statements regarding this patient's diagnosis is false? (Q851425)

A. HRCT scan shows reticulonodular opacities.

B. PET scan indicates increased metabolic activity.

C. CD4:CD8 T-cell ratio in BAL < 3.5.

D. Biopsy shows non-caseating granulomas.

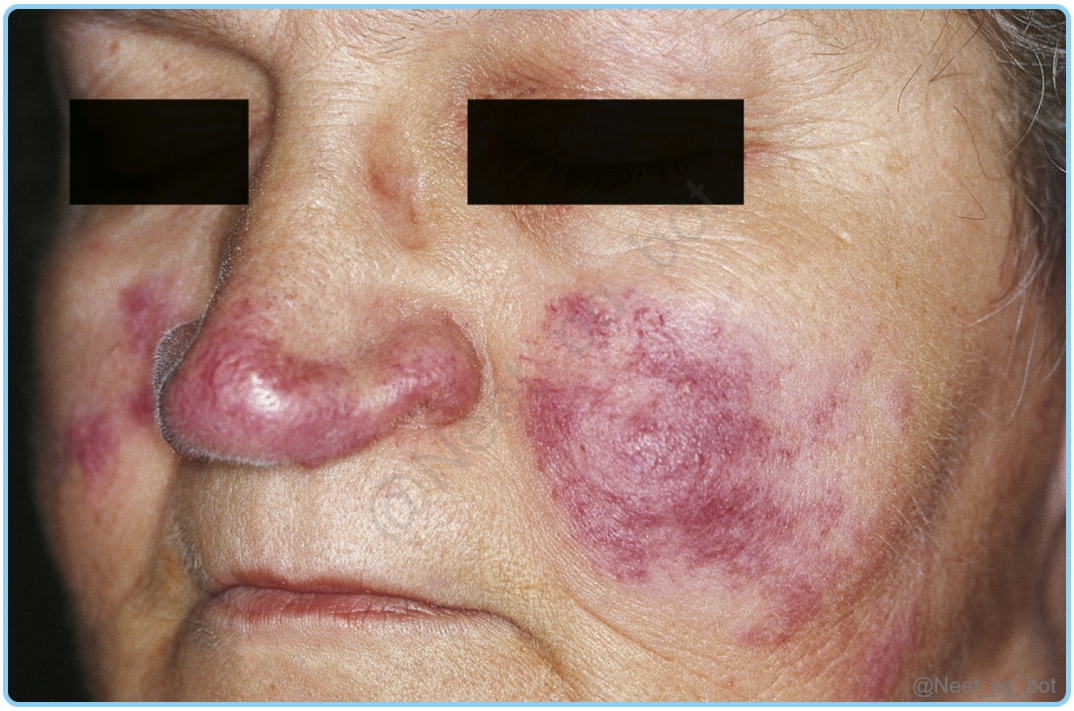

Correct Answer: C. CD4:CD8 T-cell ratio in BAL < 3.5.

Explanation: The patient's presentation of persistent cough, shortness of breath, bilateral hilar lymphadenopathy, and a skin rash resembling lupus pernio is consistent with sarcoidosis. Sarcoidosis typically presents with an increased CD4:CD8 T-cell ratio in bronchoalveolar lavage (BAL) , often greater than 3.5 , indicating a skewed immune response. Investigation Features HRCT Reticulonodular opacities (galaxy sign) in a perilymphatic distribution, often centred on broncho-vascular bundles and subpleural areas (Option A) ■■■ {{caption_text}} PET scan > MRI > Gallium-67 scan For diagnosis of extra pulmonary sarcoidosis PET scan reveals increased metabolic activities in areas of inflammation. (Option B) Biopsy Non-caseating granulomas seen in biopsies from pulmonary or extrapulmonary organs confirm the diagnosis . (Option D ruled out)

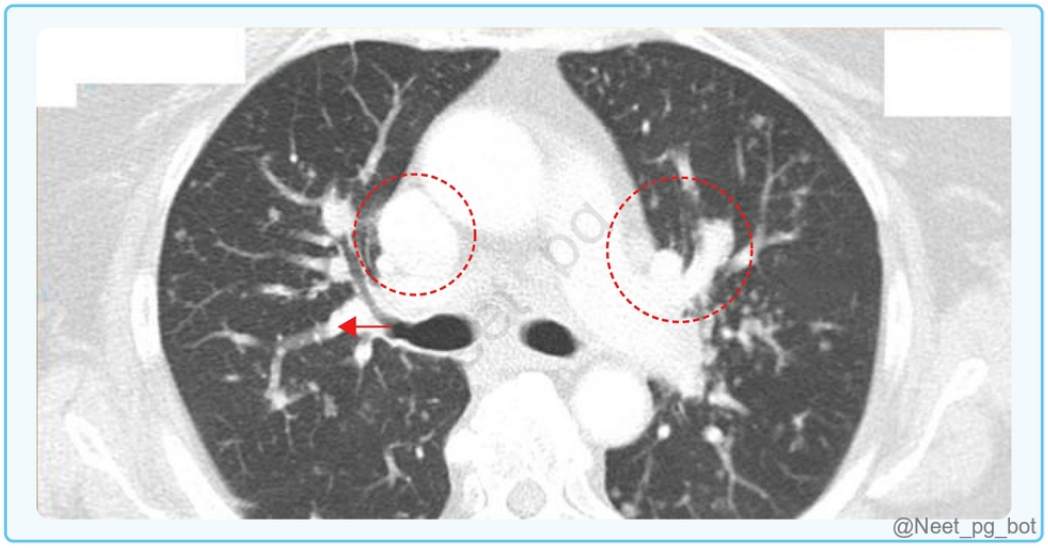

References:

Harrison’s Principles of Internal Medicine, 21st Edition, Page 2834, 2835

Davidson’s Principles and Practice of Medicine, 24th Edition, Page 609, 610

↑ *Back to this question in Part A*

@Neet_pg_bot

Q4: A 45 y/o woman diagnosed with sarcoidosis presents with worsening pulmonary symptoms, including shortness of breath and a persistent dry cough. She has also developed erythema nodosum on her legs. After a thorough evaluation, her physician decides that treatment is necessary to improve her quality of life and prevent complications. Which of the following treatment options is considered first-line for this patient's condition? (Q851427)

A. Methotrexate 10–20 mg/week.

B. Prednisolone 20–40 mg/day.

C. Infliximab at higher doses.

D. Hydroxychloroquine 200 mg/day.

Correct Answer: B. Prednisolone 20–40 mg/day.

Explanation: The patient is a 45 y/o woman with sarcoidosis, presenting with worsening pulmonary symptoms and erythema nodosum, indicating a severe form of the disease. Glucocorticoids like prednisolone are the first-line treatment for sarcoidosis, particularly for worsening pulmonary symptoms. Treatment of Sarcoidosis: Glucocorticoids: First-line treatment . Higher doses for neurosarcoidosis and lower for cutaneous sarcoidosis. Start with prednisolone (20–40 mg/day) for cases of hypercalcemia, pulmonary/renal impairment, and uveitis. Inhaled/Topical glucocorticoids: For mild lung or eye involvement to reduce systemic glucocorticoid use. Steroid-Sparing Agents: Methotrexate : Steroid-sparing agent , commonly used for lung and other systemic involvement (Option A) . Azathioprine : Used in place of methotrexate. Hydroxychloroquine/Chloroquine: Effective for skin lesions and less severe pulmonary disease. (Option D) Minocycline : This may be useful in cutaneous sarcoidosis. Biologic Agents: Infliximab : Improves lung function in chronic cases, effective due to its action on TNF (Option C) . Adalimumab : Effective in sarcoidosis when used in higher doses. Etanercept : Limited role; less effective compared to infliximab. Severe Disease: Methotrexate, azathioprine, and TNF-α inhibitors for extensive disease. Lung Transplantation: Considered in selected severe cases.

References:

Harrison’s Principles of Internal Medicine, 21st Edition, Page 2835-2837

Davidson’s Principles and Practice of Medicine, 24th Edition, Page 610

↑ *Back to this question in Part A*

@Neet_pg_bot

Q5: Which of the following organs is least commonly involved in sarcoidosis? (Q851429)

A. Spleen

B. Heart

C. Skin

D. Brain

Correct Answer: B. Heart

Explanation: The heart is the least commonly involved organ in sarcoidosis, with involvement occurring in only about 2% of cases. When it is affected, it can lead to serious complications like arrhythmias. The most common organ involved is: the Lung Lung > Skin > Liver/Eye > Spleen > Neurologic > Cardiac

References:

Harrison’s Principles of Internal Medicine, 21st Edition, Page 2831, 2833, 2835

↑ *Back to this question in Part A*

@Neet_pg_bot

Q6: A 45 y/o woman presents with progressive muscle weakness and a distinctive rash on her eyelids and knuckles. She also exhibits a rash like in the given image. She reports difficulty swallowing and has experienced some joint pain. Which of the following statements about this patient's condition is false? (Q851431)

A. The rash may precede or accompany the muscle weakness.

B. Weakness is typically asymmetric, affecting distal muscles more than proximal.

C. Nail bed telangiectasias are a common finding.

D. Patients may present with only a rash and no muscle weakness.



Correct Answer: B. Weakness is typically asymmetric, affecting distal muscles more than proximal.

Explanation: The patient's symptoms, such as progressive muscle weakness and distinctive rashes, including the heliotrope rash on the eyelids and the V-sign on the anterior neck and chest, as shown in the image, are characteristic of dermatomyositis . The presence of dysphagia further supports this diagnosis. Clinical Features of Dermatomyositis Nail bed telangiectasias: Dilated capillaries at nail beds. (Option C ruled out) Weakness and rash can appear together or be separated by months. (Option A ruled out) Some patients may present with only a rash (amyopathic DM), while others may show mainly weakness. (Option D ruled out)

References:

Harrison's Principles of Internal Medicine, 21st Edition, Page 2820

Davidson's Principles and Practice of Medicine, 24th Edition, Page 1039

↑ *Back to this question in Part A*

@Neet_pg_bot

Q7: A 50 y/o woman presents with muscle weakness that has progressively worsened over the last 2 months. She also reports a red rash on her knuckles and upper eyelids. The histopathology image of muscle biopsy is given below. MxA staining is positive. Which of the following statements regarding her condition is false? (Q851433)

A. Serum CK is elevated

B. Anti-TIF1 antibodies are associated with a favourable prognosis.

C. Perifascicular atrophy is characteristic of dermatomyositis.

D. Anti-MDA5 antibodies are linked to a higher risk of rashes, ulcers and ILD.

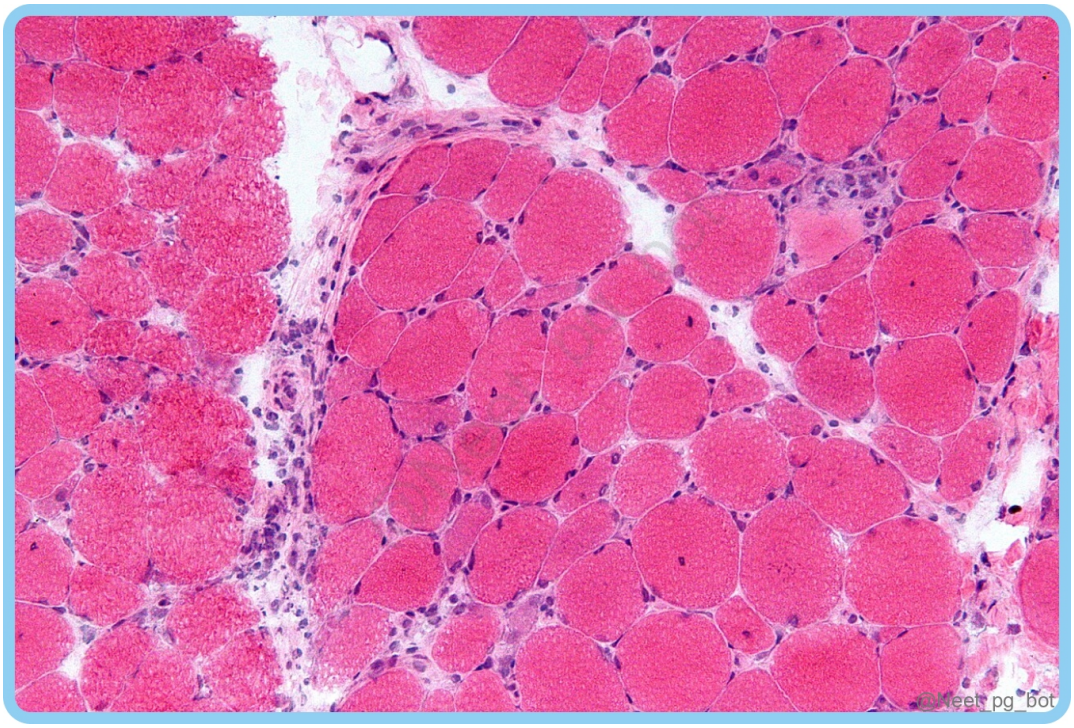

Correct Answer: B. Anti-TIF1 antibodies are associated with a favourable prognosis.

Explanation: The given clinical history is indicative of dermatomyositis . Histopathological findings of perifascicular atrophy in the muscle biopsy support the diagnosis. Anti-TIF1 antibodies are actually associated with an increased risk of cancer, making this statement false. Serum CK is elevated, but if normal, serum aldolase may be increased in 10% of the cases. (Option A) Myositis-Specific Antibodies (MSA): Anti-MDA5: Linked to rash, ulcers, and interstitial lung disease (ILD). (Option D ruled out) Anti-TIF1: Associated with cancer risk. Anti-Mi-2: Highly specific , associated with a favourable prognosis and specific skin features. Perifascicular atrophy: A characteristic finding in dermatomyositis (DM), where muscle fibres near the perimysium are atrophic. (Option C ruled out) {{caption_text}}

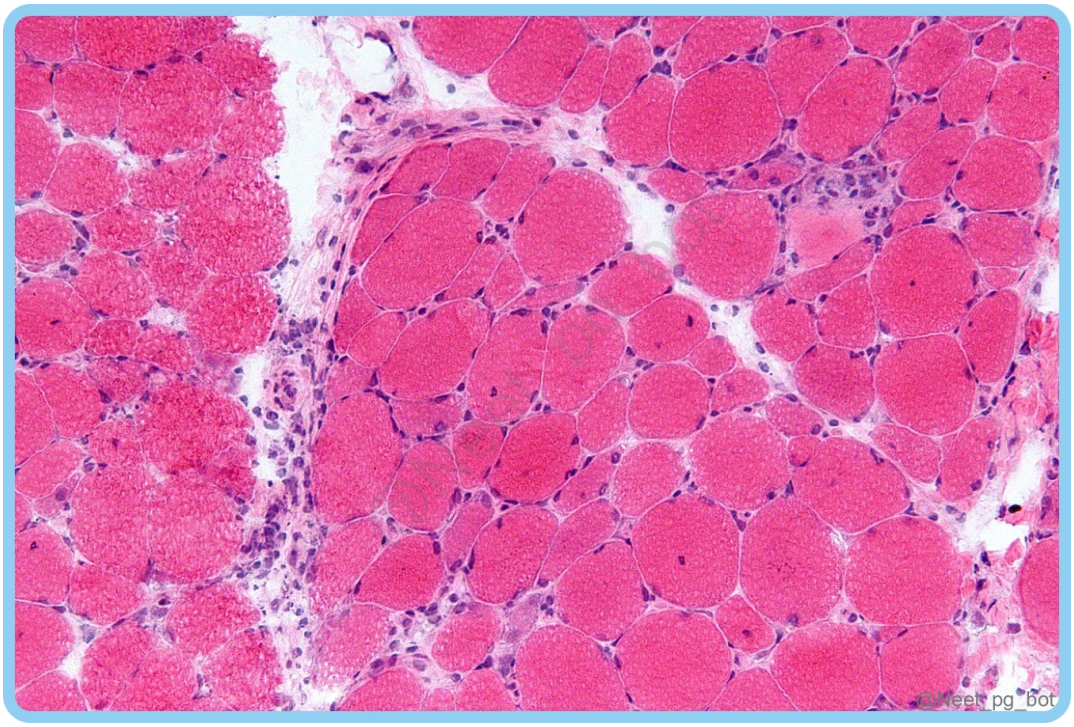

References:

Harrison’s Principles of Internal Medicine, 21st Edition, Page 2820, 2821

Davidson’s Principles and Practice of Medicine, 24th Edition, Page 1039

↑ *Back to this question in Part A*

@Neet_pg_bot

Q8: A 45-year-old woman has 3 months of progressive proximal muscle weakness, difficulty climbing stairs, and elevated creatine kinase (CK) levels. EMG indicates inflammatory myopathy, and a muscle biopsy shows endomysial infiltration with CD8+ T cells. What is the most likely diagnosis? (Q851436)

A. Polymyositis

B. Antisynthetase syndrome

C. Dermatomyositis

D. Overlap syndrome

Correct Answer: A. Polymyositis

Explanation: Polymyositis (PM) is characterized by symmetric, proximal muscle weakness, primarily affecting muscle groups closer to the centre of the body, such as the shoulders and hips, with elevated CK levels. The muscle biopsy showing endomysial infiltration with CD8+ T cells supports this diagnosis. The absence of skin involvement differentiates it from dermatomyositis. Dermatomyositis (Option C) presents with muscle weakness similar to PM but is associated with characteristic skin rashes such as Gottron's papules and heliotrope rash, which are not present in this case. Overlap syndrome (Option D) involves myositis coexisting with another connective tissue disease, such as systemic lupus erythematosus or scleroderma. This patient's presentation is isolated to muscle weakness, making overlap syndrome less likely.

References:

Harrison's Principles of Internal Medicine, 21st Edition, Page 2822, 2821

www.webmd.com/arthritis/polymyositis

↑ *Back to this question in Part A*

@Neet_pg_bot

Q9: A 35 y/o male presents with painful, recurrent oral ulcers lasting around 20 days. He also reports a history of genital ulcers and occasional skin lesions resembling erythema nodosum. Recently, he has developed blurred vision and redness in both eyes. Examination reveals anterior uveitis and multiple deep oral ulcers. A pathergy test is positive. What is the most likely diagnosis? (Q851439)

A. Behçet's disease

B. Cogan syndrome

C. Overlap syndrome

D. Antisynthetase syndrome

Correct Answer: A. Behçet's disease

Explanation: The patient's recurrent oral and genital ulcers, skin lesions (erythema nodosum), ocular involvement (anterior uveitis), and positive pathergy test are characteristic of Behçet's disease. Cogan Syndrome (Option B): The Cogan syndrome is an autoimmune disease involving inflammation of the inner ears and eyes, characterized by vestibule-auditory dysfunction and interstitial keratitis. Overlap Syndrome (Option C) occurs when dermatomyositis (DM) or polymyositis (PM) coexists with other connective tissue diseases (CTDs), such as scleroderma, mixed connective tissue disease (MCTD), Sjögren's syndrome, systemic lupus erythematosus (SLE), or rheumatoid arthritis. Antisynthetase syndrome (Option D) is characterized by myositis, interstitial lung disease (ILD), arthritis, and "mechanic's hands," often associated with anti-Jo-1 antibodies.

References:

Harrison’s Principles of Internal Medicine, 21st Edition, Page 2821, 2822

Davidson’s Principles and Practice of Medicine, 24th Edition, Page 1043, 1044

Cogan Syndrome - StatPearls - NCBI Bookshelf

↑ *Back to this question in Part A*

@Neet_pg_bot

Q10: A 34 y/o male presents with a 2-year history of lower back stiffness and pain that improves with activity. He also has occasional knee and hip pain. Examination reveals reduced lumbar spine mobility and tenderness over the sacroiliac joints. What additional clinical feature is most likely associated with this condition? (Q851441)

A. High fever and night sweats

B. Symmetrical small joint swelling

C. Generalized muscle weakness

D. Recurrent anterior uveitis

Correct Answer: D. Recurrent anterior uveitis

Explanation: The clinical presentation and the examination findings point to Ankylosing Spondylitis. Anterior uveitis is the m ost common extra articular manifestation. Presents with sudden unilateral eye pain, redness, and light sensitivity, often preceding joint symptoms. (Option D) High fever and night sweats (Option A): High fever and night sweats are more indicative of infectious diseases. In ankylosing spondylitis, systemic symptoms are usually mild and are generally limited to fatigue and occasional weight loss. Symmetrical small joint swelling (Option B): Symmetrical involvement of the small joints, particularly in the hands and wrists, is more characteristic of rheumatoid arthritis rather than ankylosing spondylitis. Generalized muscle weakness (Option C): It is not a feature associated with ankylosing spondylitis. The condition primarily affects the spine and joints rather than causing widespread muscle weakness.

References:

Harrison’s Principles of Internal Medicine, 21st Edition, Page 2791, 2792, 2793

Davidson’s Principles and Practice of Medicine, 24th Edition, Page 1030

↑ *Back to this question in Part A*

@Neet_pg_bot

Q11: A 26 year old male is evaluated for long-standing back pain and stiffness. Modified Schober's test shows restricted lumbar flexion. Physical examination reveals limited chest expansion. Which additional finding would most likely be present? (Q851442)

A. Free lateral bending of the spine

B. Loss of lumbar lordosis

C. Hypermobile cervical spine

D. Absence of tenderness over the sacroiliac joints

Correct Answer: B. Loss of lumbar lordosis

Explanation: The examination findings of limited chest expansion and restricted lumbar flexion on Modified Schober's test point to Ankylosing Spondylitis . Loss of lumbar lordosis is a common postural change seen in ankylosing spondylitis. As the disease progresses, the normal inward curvature of the lower back diminishes due to chronic inflammation and spinal rigidity. Free lateral bending of the spine (Option A): In ankylosing spondylitis, lateral bending of the spine is often reduced or painful due to inflammation of the spinal joints. Hypermobile cervical spine (Option C): Cervical spine involvement in ankylosing spondylitis results in stiffness and reduced mobility, rather than hypermobility. Absence of tenderness over the sacroiliac joints (Option D): Tenderness over the sacroiliac joints is a hallmark of ankylosing spondylitis, as these joints are frequently affected by inflammation.

References:

Harrison's Principles of Internal Medicine, 21st Edition, Page 2793

↑ *Back to this question in Part A*

@Neet_pg_bot

Q12: A 20 y/o male presents with persistent back pain that improves with physical activity. He has a family history of inflammatory arthritis and shows HLA-B27 positivity. Imaging reveals sacroiliiitis. Which of the following combinations fulfils the diagnostic criteria for axial spondyloarthritis? (Q851443)

A. History of joint pain plus normal X-ray findings

B. HLA-B27 positivity plus a history of allergic rhinitis

C. HLA-B27 positivity plus two other spondyloarthritis features

D. Elevated CRP levels plus a positive Schober's test

Correct Answer: C. HLA-B27 positivity plus two other spondyloarthritis features

Explanation: Diagnostic Criteria for Axial Spondyloarthritis Imaging Arm Clinical Arm (Option C) Requires evidence of sacroiliitis on imaging Acute inflammation on MRI and/or Definite radiographic sacroiliitis according to Modified New York criteria (Bilateral sacroiliitis on X-ray if changes are mild or Unilateral sacroiliitis on X-ray if changes are definite) HLA-B27 positivity plus at least two other spondyloarthritis features. Spondyloarthritis features: Inflammatory back pain, arthritis, enthesitis, anterior uveitis, dactylitis, psoriasis, inflammatory bowel disease (Crohn's or ulcerative colitis), family history of spondyloarthritis, elevated CRP and good response to NSAIDs If X-ray evidence of sacroiliitis is present in the patient's history or examination, one other feature is required for the diagnosis of ankylosing spondylitis.

References:

Harrison’s Principles of Internal Medicine, 21st Edition, Page 2791, 2793, 2794

Davidson’s Principles and Practice of Medicine, 24th Edition, Page 1028, 1030

↑ *Back to this question in Part A*

@Neet_pg_bot

Q13: A 35 y/o female with ankylosing spondylitis is experiencing episodes of uveitis. Which would be the most appropriate drug to address both her uveitis and her underlying condition? (Q851444)

A. Anakinra

B. Adalimumab

C. Sulfasalazine

D. Tofacitinib

Correct Answer: B. Adalimumab

Explanation: Treatment of Ankylosing Spondylitis Non-Pharmacological Measures Exercises for improving posture, flexibility, and muscle strength. Pharmacological Therapy Non-steroidal anti-inflammatory Drugs (NSAIDs) First-line treatment to treat pain and inflammation. Disease-Modifying Anti-Rheumatic Drugs (DMARDs) Sulfasalazine (Option C) is used for peripheral arthritis Methotrexate is less effective in ankylosing spondylitis. TNF Inhibitors It reduces inflammation and is effective for both axial and peripheral symptoms. Examples: Infliximab, Etanercept, Adalimumab, Golimumab, Certolizumab Pegol. Adalimumab has been FDA-approved for managing uveitis . It can control both spinal symptoms and uveitis episodes in the patient. IL-17A Inhibitors Secukinumab Effective in patients who have not tolerated anti-TNF therapy Glucocorticoids Can be used in attacks of uveitis. Janus Kinase (JAK) Inhibitors Tofacitinib (Option D) , Upadacitinib, and Filgotinib show efficacy in clinical trials.

References:

Harrison’s Principles of Internal Medicine, 21st Edition, Page 2794, 2795, 2796

Davidson’s Principles and Practice of Medicine, 24th Edition, Page 1030

↑ *Back to this question in Part A*

@Neet_pg_bot

Q14: Which organ is most commonly associated with inflammatory pseudotumour in children? (Q851445)

A. Lungs

B. Liver

C. Brain

D. Kidneys

Correct Answer: A. Lungs

Explanation: Inflammatory pseudotumor (IPT) is a rare, benign condition identified by tumour-like masses of inflammatory cells. In children, inflammatory pseudotumor is most frequently found in the lungs, often presenting as a benign mass. It has an aggressive presentation in the sinonasal cavity and is the third most common orbital disease. It occurs rarely in the mediastinum, trachea, heart, brain, liver, spleen, biliary tree, gastrointestinal tract, mesentery, urinary bladder, kidneys and adrenals.

References:

Harrison’s Principles of Internal Medicine, 21st Edition, Page 2838

ajronline.org/doi/10.2214/AJR.11.7288

↑ *Back to this question in Part A*

@Neet_pg_bot

Q15: A 65 y/o male presents with abdominal pain, jaundice, and weight loss. Imaging reveals a mass in the liver, and laboratory tests show elevated IgG4 levels. A biopsy is performed to confirm the diagnosis. What is most likely associated with IgG4-related inflammatory pseudotumor? (Q851446)

A. Epithelioid cell granulomas

B. Caseating granulomas

C. Necrotising vasculitis

D. Storiform fibrosis

Correct Answer: D. Storiform fibrosis

Explanation: Storiform fibrosis refers to a distinctive whorled or cartwheel-like pattern of collagen deposition and is commonly seen in IgG4-related inflammatory pseudotumor (IPT) . It is associated with fibroblastic and myofibroblastic proliferation, which gives rise to this unique arrangement. It also has lymphoplasmacytic infiltrate, where plasma cells show positivity for IgG4. Epithelioid cell granulomas (Option A): These are generally found in sarcoidosis and are not characteristic of IgG4-related inflammatory pseudotumors. Caseating granulomas (Option B): These granulomas are associated with tuberculosis and certain fungal infections, not typically seen in IgG4-related conditions. Necrotising vasculitis (Option C): This refers to inflammation of blood vessels with necrosis, often seen in conditions like polyarteritis nodosa, rather than in IgG4-related diseases.

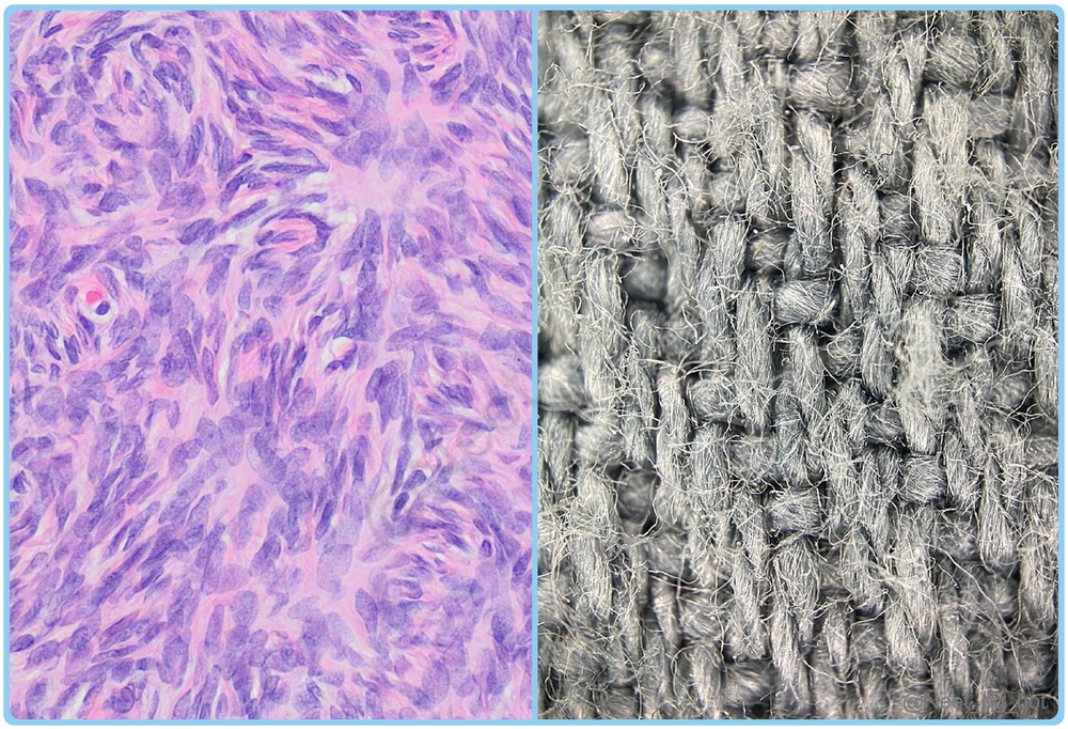

References:

Harrison’s Principles of Internal Medicine, 21st Edition, Page 2837

ajronline.org/doi/10.2214/AJR.11.7288#

pmc.ncbi.nlm.nih.gov/articles/PMC3343246/

↑ *Back to this question in Part A*

@Neet_pg_bot

Q16: A 45 y/o patient presents with mild abdominal pain, weight loss, and obstructive jaundice. Imaging reveals a "sausage-shaped" pancreas and a subsequent CT scan shows diffuse pancreatic enlargement. The patient's condition is suspected to be related to an inflammatory process rather than malignancy. Which of the following is the most appropriate first-line treatment for this condition? (Q851447)

A. Rituximab

B. Surgical resection

C. Glucocorticoids

D. Antibiotics

Correct Answer: C. Glucocorticoids

Explanation: The patient mostly has a diagnosis of inflammatory pseudotumor which is supported by the "sausage-shaped" pancreatic enlargement on imaging, along with symptoms of abdominal pain, weight loss, and obstructive jaundice. The diagnosis of inflammatory pseudotumor is best managed with glucocorticoids. Inflammatory pseudotumour Treatment: First-line therapy: Glucocorticoids Initial dose: Prednisone 40 mg/day Taper to 5 mg/day within 2-3 months The response is typically rapid, but long-term steroid-free remission is uncommon. Second-line therapy: Rituximab Used for relapsing or glucocorticoid-resistant disease. Dosing: Two 1 g IV doses, 15 days apart Benefits: Swift IgG4 reduction, impacts B and T cell functions Can be first-line in patients at high risk for steroid toxicity or organ-threatening disease

References:

Harrison’s Principles of Internal Medicine, 21st Edition, Page 2838, 2840

↑ *Back to this question in Part A*

@Neet_pg_bot

• [08_Rheumatology] 066 Previous Year Questions

« Back to Folder Directory

[08_Rheumatology] 066 Previous Year Questions — Quick Jump

Q1 (p. 2647)	*Q2 (p. 2648)*	*Q3 (p. 2649)*	*Q4 (p. 2650)*	*Q5 (p. 2650)*	*Q6 (p. 2653)*
Q7 (p. 2656)	*Q8 (p. 2657)*	*Q9 (p. 2658)*	*Q10 (p. 2661)*	*Q11 (p. 2662)*	*Q12 (p. 2663)*
Q13 (p. 2664)	*Q14 (p. 2664)*	*Q15 (p. 2665)*	*Q16 (p. 2668)*	*Q17 (p. 2670)*	*Q18 (p. 2672)*
Q19 (p. 2673)	*Q20 (p. 2676)*	*Q21 (p. 2676)*	*Q22 (p. 2677)*	*Q23 (p. 2678)*	*Q24 (p. 2679)*
Q25 (p. 2680)	*Q26 (p. 2681)*	*Q27 (p. 2683)*	*Q28 (p. 2684)*	*Q29 (p. 2688)*	*Q30 (p. 2689)*
Q31 (p. 2691)	*Q32 (p. 2692)*	*Q33 (p. 2694)*	*Q34 (p. 2694)*	*Q35 (p. 2695)*	*Q36 (p. 2695)*
Q37 (p. 2696)	*Q38 (p. 2697)*	*Q39 (p. 2699)*	*Q40 (p. 2703)*	*Q41 (p. 2707)*	

Q1: Which among the following is more common in limited cutaneous systemic sclerosis when compared to diffuse cutaneous systemic sclerosis? (Q855000)

A. Esophageal dysmotility

B. Myopathy

C. Interstitial lung disease

D. Scleroderma renal crisis

Correct Answer: A. Esophageal dysmotility

Explanation: Esophageal dysmotility is more common in limited cutaneous systemic sclerosis compared to diffuse cutaneous systemic sclerosis. Limited v/s Diffuse Cutaneous Systemic Sclerosis (SSc): Feature Limited Cutaneous SSc Diffuse Cutaneous SSc Skin involvement Indolent onset Limited to fingers, distal to elbows, face Slow progression Rapid onset Diffuse: fingers, extremities, face, trunk Rapid progression Raynaud's phenomenon Antedates skin involvement, sometimes by years May be associated with critical ischemia in the digits Onset coincident with skin involvement Critical ischemia less common Musculoskeletal (Option B) Mild arthralgia Severe arthralgia Carpal tunnel syndrome Tendon friction rubs Frequent, early onset and progression, can be severe Esophageal dysmotility 90% of cases 80% of cases Interstitial lung disease (Option C) Slowly progressive Generally mild Frequent, early onset and progression, can be severe Pulmonary arterial hypertension Frequent, late, may occur as an isolated complication Often occurs in association with interstitial lung disease Scleroderma renal crisis (Option D) Very rare Occurs in 15%; generally early (<4 years from disease onset) Calcinosis cutis Frequent, prominent Less common, mild Characteristic autoantibodies Anti-centromere Anti-topoisomerase (Scl-70), anti-RNA polymerase III

References:

Harrison’s Principle of Internal Medicine, 21st Edition, Page 2773, 2778

↑ *Back to this question in Part A*

@Neet_pg_bot

Q2: A young patient presents to the clinic with erythematous lesions over the exposed areas of the skin, like hands, arms, and chest. He also complains of arthralgia and breathlessness. Measuring which among the following antibodies will be useful in diagnosing the underlying conditions? (Q855716)

A. Antihistone antibodies

B. Anti-dsDNA antibodies

C. Anticentromere antibodies

D. Antinuclear antibodies

Correct Answer: B. Anti-dsDNA antibodies

Explanation: The likely diagnosis in this patient is systemic lupus erythematosus, and anti-dsDNA antibodies are specific to systemic lupus erythematosus (SLE), a chronic autoimmune disease. These antibodies target double-stranded DNA and are found in a significant number of patients with SLE. Their presence is highly specific to SLE and is associated with lupus nephritis (kidney involvement) and other manifestations of the disease. Autoantibodies of SLE Antibodies Antigen recognised Clinical significance ANA (Option D) Multiple nuclear antigens Best screening test for diagnosis, it is highly sensitive but not very specific for SLE. Anti-dsDNA DNA (double-stranded) High titers are specific for SLE Used to correlate with disease severity Anti-C1q Collagen-like determinants on C1q Associated with active lupus nephritis , it is non-specific for SLE and can be used to correlate with disease activity. Deficiency predisposes SLE. Anti-Sm Protein complexes to 6 species of nuclear U1 RNA. It is highly specific for SLE. Anti-RNP Protein complexed to U1 RNA Non-specific to SLE and is associated with syndromes that overlap with rheumatic syndromes Anti-Ro (SS-A) Protein complexed to hY RNA 9 (primarily 60 kDa and 52 kDa) Not very specific , it is associated with sicca syndrome and neonatal lupus (congenital heart block) Anti-La (SS-B) 47-kDa protein complexed to hY RNA Commonly associated with Anti-Ro antibody Antihistone (Option A) Histones associated with DNA Associated with drug-induced lupus. Antiphospholipid Phospholipids, β2-glycoprotein 1 cofactor, prothrombin Usually predisposes to clotting, fetal loss and thrombocytopenia. Anti Erythrocyte Erythrocyte membrane Causes autoimmune hemolytic anemia. Antiplatelet Surface and altered cytoplasmic antigens on platelets It contributes to thrombocytopenia, is not very specific or sensitive, and is not used in regular practice. Antineuronal antibody Neuronal and lymphocyte surface antigens Occasionally, it shows a positive correlation with active CNS lupus. Anti Ribosomal P Protein in ribosomes Associated with neuropsychiatric manifestations. Anticentromere antibodies (Option C) are associated with a distinct autoimmune disease called limited cutaneous systemic sclerosis, also known as CREST syndrome. This condition primarily affects the skin, blood vessels, and internal organs.

References:

Harrison’s Principles of Internal Medicine, 21st Edition, Page 2738

↑ *Back to this question in Part A*

@Neet_pg_bot

Q3: A patient presents with severe pain and swelling in his knee joint for 10 days. He also complains of pain and discomfort during urination. He says that he had diarrhea one month ago and he has been unwell since then. What is the most likely diagnosis? (Q857037)

A. Reactive arthritis

B. Enteropathic arthritis

C. Rheumatoid arthritis

D. Psoriatic arthritis

Correct Answer: A. Reactive arthritis

Explanation: The most likely diagnosis is reactive arthritis . It is a post-infectious autoimmune disease. The most common systems affected would be the gastrointestinal or urinary tract. Joint involvement in different types of arthritis Characteristics Rheumatoid Arthritis (RA) Osteoarthritis (OA) Psoriatic Arthritis Gout Reactive Arthritis Joint Involvement Pattern Symmetrical involvement of small joints (MCP, PIP) Asymmetrical involvement, especially DIP joints Asymmetrical involvement, often DIP joints Typically involves a single joint (e.g., big toe) Asymmetrical involvement, often larger joints Morning Stiffness Lasts over 1 hour Resolves within 30 minutes Varies, often significant Rarely significant Variable often follows infection Key Symptoms Swelling, tenderness, deformities (e.g., ulnar deviation) Pain and stiffness with use Dactylitis, nail changes Sudden, severe pain and swelling Joint pain following an infection Affected Joints MCP, PIP, wrists, knees Knees, hips, hands (DIP, PIP) MCP, PIP, and can include spine and tendons Typically big toe (1st MTP joint) Larger joints (knees, ankles) Radiographic Findings Soft tissue swelling, joint space narrowing Osteophytes, joint space narrowing Erosions, possible nail changes Erosions and tophi possible Similar to RA but typically larger joints Enteropathic arthritis (Option B) Is a spondyloarthropathy that is associated with inflammatory bowel diseases like Crohn’s and ulcerative colitis. It typically causes sacroiliitis and spondylitis and involves peripheral joints. Rheumatoid arthritis (Option C) is seen in mostly young females and presents with painful tender joints. PIP and MCP are affected symmetrically in bilateral limbs. Patients experience morning stiffness and the hallmark feature is flexor tenosynovitis. Swan neck deformity and Boutonnière deformity is also seen. Psoriatic arthritis (Option D) is associated with a chronic inflammatory skin disorder. Psoriasis causes inflammatory arthritis and primarily affects the hands, feet, or spine.

References:

Davidson’s Principles and Practice of Medicine, 24th edition, Page 1031

↑ *Back to this question in Part A*

@Neet_pg_bot

Q4: Takayasu arteritis most commonly involves: (Q857628)

A. Pulmonary artery

B. Coronary arteries

C. Abdominal aorta

D. Arch of aorta

Correct Answer: D. Arch of aorta

Explanation: Takayasu arteritis most commonly affects the aorta and its major branches , particularly the branches arising from the arch of the aorta. The disease leads to inflammation, thickening, and narrowing of these arteries, which can result in reduced blood flow to various organs and tissues.. Takayasu Arteritis ("Pulseless disease"): General features: Predominantly affects young females (<20 years) Vascular Involvement: Most commonly affects the aorta and its major branches , particularly the branches arising from the arch of the aorta like brachiocephalic trunk, left common carotid artery, and left subclavian artery. Characteristic ostial narrowing vs. diffuse involvement in atherosclerosis A leading cause of renal artery stenosis in India Clinical Features: a) Early Phase (Pre-pulseless): Systemic symptoms: fever, malaise, night sweats Arthralgias, anorexia, weight loss b) Vascular Phase: Arm claudication Unequal blood pressure between arms Pulseless disease (difficult to appreciate radial artery) Hypertension (32-93%) Differential Diagnosis: Young female with renal artery stenosis: India: Takayasu arteritis USA: fibromuscular dysplasia (FMD) Arm claudication: Rule out neurogenic claudication (cervical disc disease) Investigations: ESR/CRP elevation Mild anemia Elevated immunoglobulins Investigation of choice: MR angiography (MRA) Complete imaging of the aorta and major branches needed Management: First Line: Steroids (40-60mg prednisone/day) Second Line: Methotrexate (up to 25mg/week) for steroid-refractory cases Important Points for Differential Blood Pressure: Normal difference between arm-leg BP: <20 mmHg Conditions with unequal arm BPs: Takayasu arteritis Supravalvular aortic stenosis with Coanda effect Preductal coarctation of aorta Major complications: Heart failure, stroke, MI, aneurysm rupture, renal failure Pulmonary artery, Coronary arteries, Abdominal aorta (Option A, B, C) are also affected in takayasu Arteritis but less common than arch of aorta and its branches

References:

Harrison’s Principles Of Internal Medicine, 21st edition, Page 2813

↑ *Back to this question in Part A*

@Neet_pg_bot

Q5: Identify the deformity depicted in the image: (Q857669)

A. Swan neck deformity

B. Boutonniere deformity

C. Z line deformity

D. Mallet finger deformity

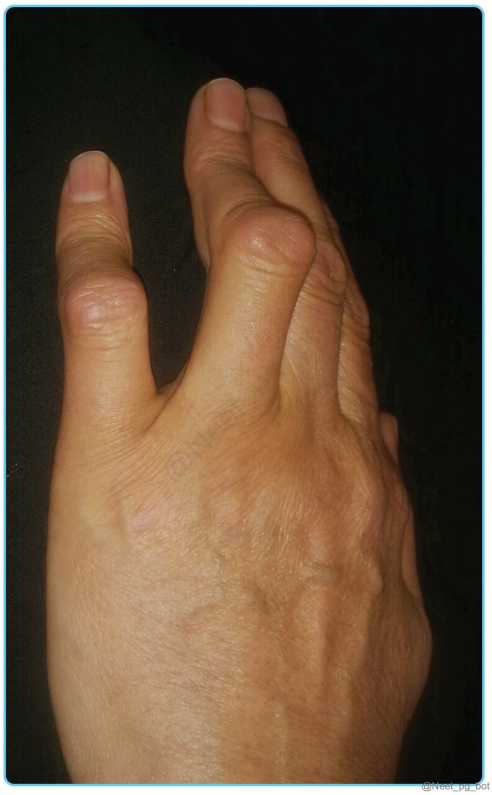

Correct Answer: B. Boutonniere deformity

Explanation: Boutonniere deformity is associated with rheumatoid arthritis, and it presents with Proximal interphalangeal joint flexion (PIP). Distal interphalangeal flexion (DIP) hyperextension. Resulting in a finger with a bent appearance at the middle joint and extended at the end joint. Articular deformity and changes in rheumatoid arthritis Articular changes Autoimmune inflammation mediates pannus formation, eroding the articular cartilage and bone. Metacarpophalangeal joint (MCP) , proximal interphalangeal (PIP) joint and wrist joint are involved Deformities Swan neck deformity (Option A) Extension at proximal interphalangeal joint (PIP) Flexion at the distal interphalangeal joint (DIP): The DIP joint is not involved; flexion occurs due to tension on the tendons attached to the base of Distal phalanges Boutonniere deformity Flexion at PIP and extension at DIP Both swan neck and boutonniere deformity can occur in different fingers of the same hand. Z-line deformity (Option C) Subluxation of the first metacarpophalangeal joint. Hyperextension of interphalangeal joint. {{caption_text}} {{caption_text}} Mallet finger deformity (Option D) involves an inability to extend the DIP joint due to a tendon injury without affecting the PIP joint. It is usually a sports injury and is not seen in rheumatoid arthritis. {{caption_text}}

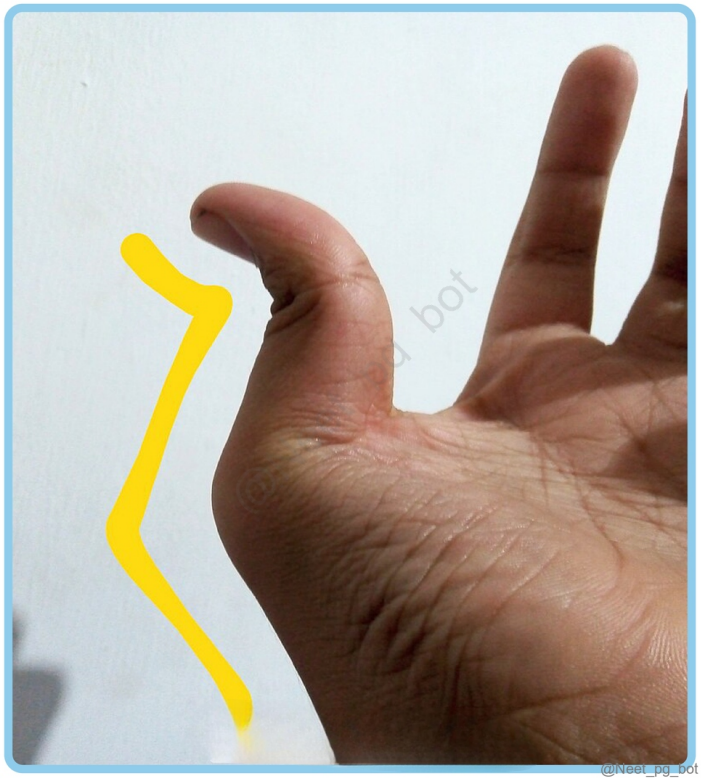
@Neet_pg_bot

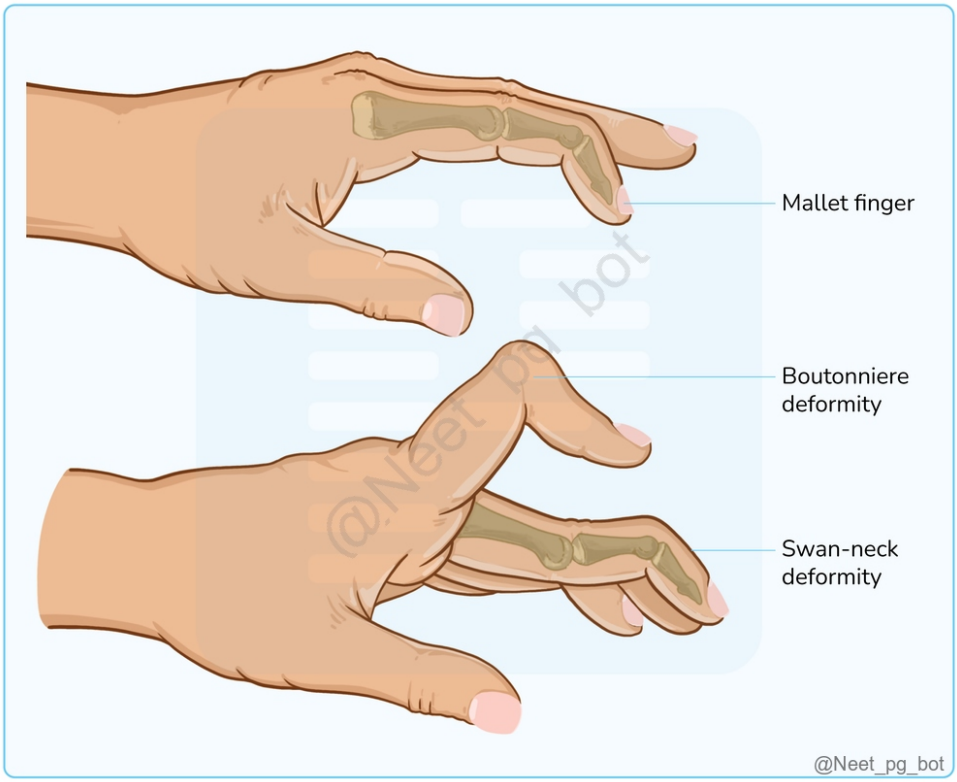
Mallet finger
Boutonniere deformity
Swan-neck deformity
@Neet_pg_bot



References:

Harrison’s Principles of Internal Medicine, 21st edition, Page 2751-2752

↑ *Back to this question in Part A*

@Neet_pg_bot

Q6: A patient presents with flaccid bullous lesions as shown in the image below involving the entire trunk and oral cavity. Acantholytic cells are seen on Tzank smear. What is the most probable diagnosis? (Q857670)

A. Pemphigus foliaceus

B. Pemphigus vulgaris

C. Dermatitis herpetiformis

D. Bullous pemphigoid



Correct Answer: B. Pemphigus vulgaris

Explanation: As the patient is presenting with flaccid bullous lesions involving the entire trunk and oral cavity, along with the presence of acantholytic cells on Tzanck smear, the most probable diagnosis would be Pemphigus vulgaris. However, a definitive diagnosis would require additional clinical evaluation, including a biopsy and direct immunofluorescence testing. Pemphigus vulgaris (PV): PV is the most common chronic autoimmune blistering disease caused by antibodies against desmosomal adhesion proteins. They are characterized by the presence of flaccid blisters filled with clear fluid present on normal skin or an erythematous base. The blisters rupture producing painful erosion. Mucosal involvement is a very important and one of the distinguishing features of PV. Histopathology: Intraepidermal cleavage with acantholysis (detached keratinocytes) primarily localized to the suprabasal region Separation of basal keratinocytes along the basement membrane zone, resulting in an appearance that resembles a "row of tombstones" The target antigens for PV are most commonly Desmoglein 3 and sometimes Desmoglein 1. The image below shows the common target antigen in Intraepidermal Immunobullous Disorders. {{caption_text}} {{caption_text}} {{caption_text}} Antigen affected Immunobullous disease-associated Desmoglein 1 Pemphigus foliaceous (Subcorneal split) Desmoglein 3 > 1 Pemphigus Vulgaris (Suprabasal split) Desmocolin IgA pemphigus Desmoplakin Paraneoplastic pemphigus Pemphigus vulgaris Pemphigus foliaceus Suprabasal split Subcorneal splits DSG 3> 1 is target antigen DSG 1 is target antigen Mucosa involved Mucosa not involved Pemphigus vegetans is the variant Pemphigus Erythematosus (Senear Usher Syndrome) is a variant (a/w SLE) Clinically present with flaccid blisters and erosions Clinically present with erosions and rarely blisters Although pemphigus foliaceous may present with similar features it does not classically involve the mucous membranes. Dermatitis herpetiformis is a chronic, intensely itchy skin condition that is associated with celiac disease caused by gluten insensitivity. . It is characterized by clusters of small, intensely itchy vesicles and papules on the extensor surfaces of the elbows, knees, and buttocks. Bullous pemphigoid is an autoimmune blistering disorder that primarily affects the elderly. It is characterized by tense bullae that typically occur on the flexural surfaces of the body, such as the armpits and groin.

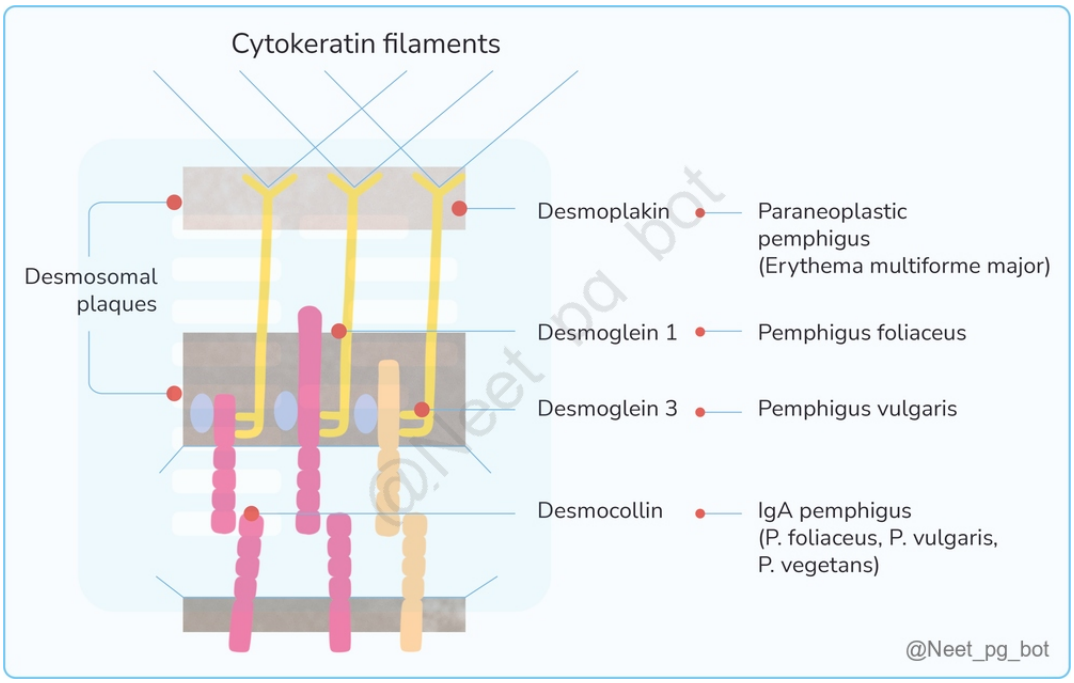
Cytokeratin filaments
Desmosomal plaques
Desmoplakin
Paraneoplastic pemphigus (Erythema multiforme major)
Desmoglein 1
Pemphigus foliaceus
Desmoglein 3
Pemphigus vulgaris
Desmocollin
IgA pemphigus (P. foliaceus, P. vulgaris, P. vegetans)
@Neet_pg_bot

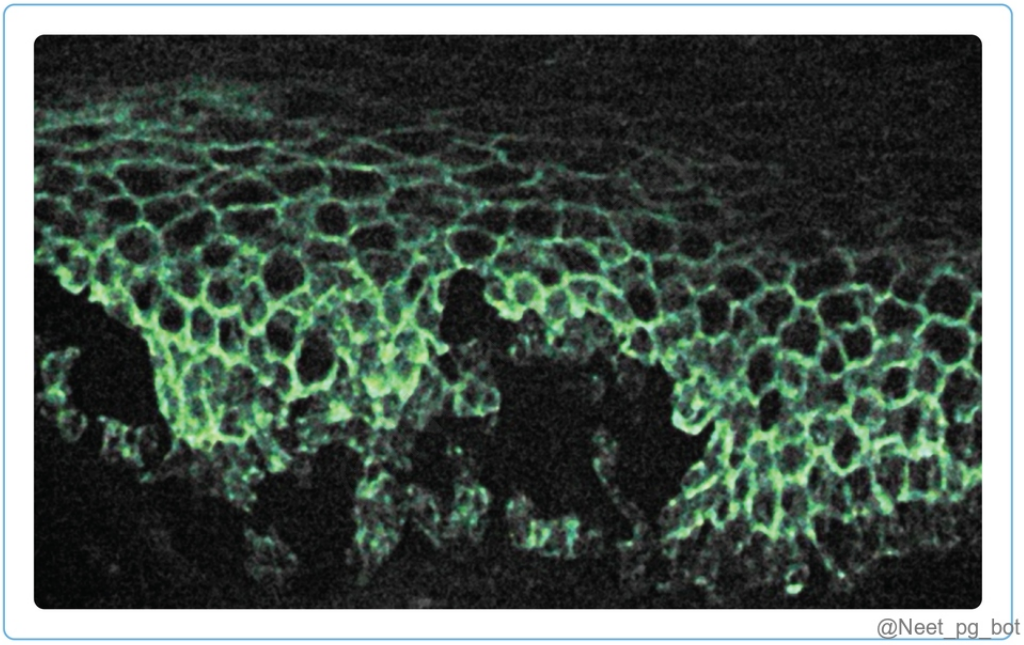
@Neet_pg_bot

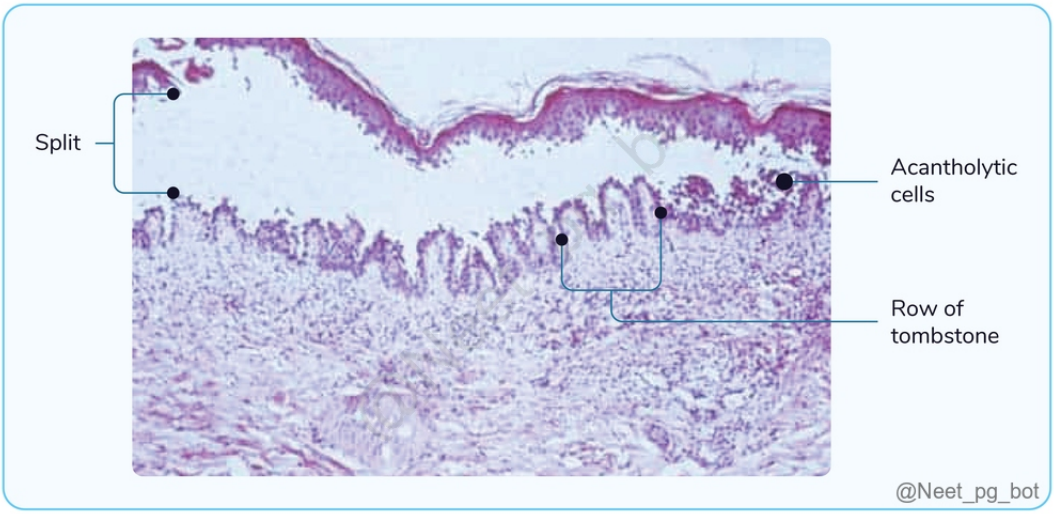

References:

Pathogenesis, clinical manifestations, and diagnosis of pemphigus - UpToDate

Rooks textbook of dermatology, 9th edition, Page 50.1 - 50.4

https://pmc.ncbi.nlm.nih.gov/articles/PMC

↑ *Back to this question in Part A*

@Neet_pg_bot

Q7: A patient presented with sinusitis, ulcerative lesions on the nasopharynx, nodular lesions with cavitations of the lung, and renal failure. Which of the following is the most useful investigation in this patient? (Q855703)

A. Test for ANCA

B. Biopsy to show granuloma

C. AFB staining of sputum

D. BAL

Correct Answer: A. Test for ANCA

Explanation: The clinical scenario of sinusitis, ulcerative lesions on the nasopharynx (upper respiratory tract), nodular lesions with cavitation in the lungs (lower respiratory tract), and renal failure strongly suggests granulomatosis with polyangiitis . The most useful investigation in this case is a test for ANCA. Granulomatosis with Polyangiitis (GPA): GPA is a vasculitic disorder characterized by granulomatous inflammation of the upper and lower respiratory tracts , small vessel vasculitis, and pauci-immune glomerulonephritis. Pathology and

Pathogenesis: Hallmarks: Necrotizing vasculitis and granuloma formation in affected organs. Organs involved: Lungs: Nodular cavitary infiltrates ; necrotizing granulomatous vasculitis. Kidneys: Pauci-immune glomerulonephritis with minimal immune complex deposition. Upper airway: Granulomatous inflammation , necrosis, nasal septal perforation, and saddle nose deformity. Immune imbalance: Predominantly Th1-mediated cytokine response with elevated IFN-γ, TNF-α, and IL-12. Clinical Features: Respiratory tract: Paranasal sinus pain , nasal discharge (purulent/bloody), subglottic stenosis, cough, hemoptysis, and dyspnea. Renal: Proteinuria, hematuria, red blood cell casts, and progressive renal failure. Skin: Palpable purpura, ulcers, or nodules with vasculitis. Ocular: Conjunctivitis, episcleritis, retro-orbital masses, and proptosis. Neurological: Mononeuritis multiplex, cranial neuritis, or cerebral vasculitis. Systemic symptoms: Malaise, fever, weight loss, arthralgia, and fatigue. Diagnosis: Biopsy: Lung biopsy: High diagnostic yield, showing granulomatous vasculitis. Renal biopsy: Pauci-immune glomerulonephritis. Serology: Antiproteinase-3 ANCA positivity (~90%). Treatment: Induction Therapy: Glucocorticoids, cyclophosphamide or rituximab Maintenance Therapy: Azathioprine, mycophenolate mofetil or methotrexate Biopsy to show granuloma (Option B) : While granulomas may be seen in granulomatosis with polyangiitis (GPA), their absence does not exclude the diagnosis. Biopsy findings are supportive but not definitive, and testing for ANCA is less invasive and provides earlier diagnostic information. AFB staining of sputum (Option C) is primarily used for diagnosing tuberculosis, which does not match the clinical presentation of combined upper and lower respiratory tract involvement with renal failure seen in GPA. BAL (Bronchoalveolar Lavage) (Option D) can help evaluate lung involvement and detect inflammatory cells but is not specific for GPA. ANCA testing is more specific and less invasive for confirming the diagnosis in this case.

References:

Harrison’s Principles of Internal Medicine, 21st Edition, Page 2806-2809

↑ *Back to this question in Part A*

@Neet_pg_bot

Q8: A patient with giant cell arteritis presented with headache, jaw claudication, polymyalgia rheumatica, and mononeuritis multiplex. What should be the first-line treatment for this patient? (Q856110)

A. Abatacept

B. Tocilizumab

C. Steroids

D. Aspirin

Correct Answer: C. Steroids

Explanation: The symptoms suggest the diagnosis of Giant Cell Arteritis (GCA), for which the first line of treatment is administering steroids . Giant Cell Arteritis (GCA): GCA is an inflammatory condition of medium and large-sized arteries Earlier called temporal arteritis due to temporal artery involvement It's a systemic vasculitis affecting carotid artery branches and the aorta and its major branches It occurs almost exclusively in people over

50 years Shows strong female predominance Genetic associations: HLA-DR4 and HLA-DRB1*04 variants Strong association with polymyalgia rheumatica (PMR): 40-50% of GCA patients have PMR 10-20% of PMR patients later develop GCA Clinical Manifestations: Common Symptoms: Fever Headaches Malaise and fatigue Anorexia and weight loss Sweats Arthralgias Scalp pain Jaw claudication Complications: Ischemic optic neuropathy leading to blindness Strokes Scalp/tongue infarction Large vessel complications (in up to 1/3rd of patients): Subclavian artery stenosis Aortic aneurysms (thoracic > abdominal) Risk of aortic rupture or dissection Treatment Protocol: Initial Management: Prednisone 40-60 mg/day for 1 month IV methylprednisolone 1000 mg daily for 3 days if ocular symptoms Aspirin (Option D) 81 mg daily to reduce cranial ischemic complications Additional Therapies: Tocilizumab (anti-IL-6) FDA approved (Option B) Given as 162 mg SC weekly/biweekly with steroids Methotrexate as alternative steroid-sparing agent Monitoring: Treatment typically needed for ≥2 years ESR/CRP is useful for monitoring 60-85% have symptom recurrence during tapering Watch for glucocorticoid toxicity (35-65% of patients) Abatacept (Option A) can be used to treat giant cell arteritis along with prednisolone to reduce the risk of relapse. However, it is not the first-line treatment. Aspirin (Option D) is not the first-line treatment for giant cell arteritis and is only prescribed for cases with high ischemic risks.

References:

Harrison’s Principles of Internal Medicine, 21st Edition, Volume I, Page: 2811, 2812.

↑ *Back to this question in Part A*

@Neet_pg_bot

Q9: A woman presents with numbness of her fingertips. On examination, her face is tightened. The antinuclear antibody(ANA) is found to be positive and immunofluorescence shows the nucleolar pattern. What is the likely diagnosis? (Q856134)

A. Systemic sclerosis

B. Sjogren’s syndrome

C. Systemic lupus erythematosus

D. Rheumatoid arthritis

Correct Answer: A. Systemic sclerosis

Explanation: Numbness in fingertips (due to digital ischemia) and a tightened face with an ANA finding positive and nucleolar pattern in immunofluorescence suggest systemic sclerosis. Dermal Manifestations of Systemic Sclerosis (SSc): Bilateral Symmetrical Skin Thickening : Begins distally in the fingers and progresses proximally. Skin Pigmentation Changes : Early diffuse tanning without sun exposure. Hypopigmentation with a "salt-and-pepper" appearance on the scalp, upper back, and chest is common in dark-skinned individuals. Sclerosis of Skin and Loss of Appendages : Leads to hair loss, reduced sweating, xerosis, and itching. Disappearance of transverse finger creases and fixed flexion contractures, causing muscle atrophy. Fixed Contractures : Affects wrists, elbows, and knees due to skin and tendon fibrosis. Neck Skin Ridges : Firm adherence to the platysma

muscle limits neck extension. Facial Changes ("Mauskopf") : Taut, shiny skin with loss of wrinkles and reduced mobility. Thinned lips, prominent perioral radial furrows, and microstomia. Pinched, beak-like nose. {{caption_text}} Telangiectasia : Dilated capillaries on face, hands, lips, and oral mucosa; correlated with microvascular disease severity. Skin Ulcerations : Chronic ulcers on fingertips, PIP joints, and bony prominences heal slowly and may become infected. Fingertip ischemia leaves fixed digital "pits." Acro-Osteolysis: Resorption of terminal phalanges due to ischemia. {{caption_text}} Calcinosis Cutis : Dystrophic calcifications in the skin and soft tissues, commonly in patients with anti-centromere antibody–positive lcSSc. Calcific deposits vary in size and may ulcerate, causing pain, infections, or nerve compression. {{caption_text}} Immunofluorescence: The nucleolar ANA is associated with multiple SSc-specific antibodies . {{caption_text}} Incorrect Options: Sjögren's Syndrome (Option B) is an autoimmune disorder primarily affecting moisture-producing glands, leading to dry mouth and eyes, gritty eye sensation, fatigue, joint pain, etc. Systemic lupus erythematosus (SLE) (Option C) is a multisystem autoimmune disease that can affect many organs. Common manifestations include a malar (butterfly) rash, joint pain, kidney problems, and blood abnormalities. While SLE may cause numbness or tingling due to nerve involvement, its ANA pattern is typically homogeneous or speckled, not nucleolar. Rheumatoid arthritis (Option D) primarily affects the joints, causing inflammation, pain, and stiffness. It does not typically involve numbness of the fingertips or the tightening of the face seen in systemic sclerosis. Additionally, the nucleolar pattern on ANA immunofluorescence testing is not associated with rheumatoid arthritis.





@Neet_pg_bot



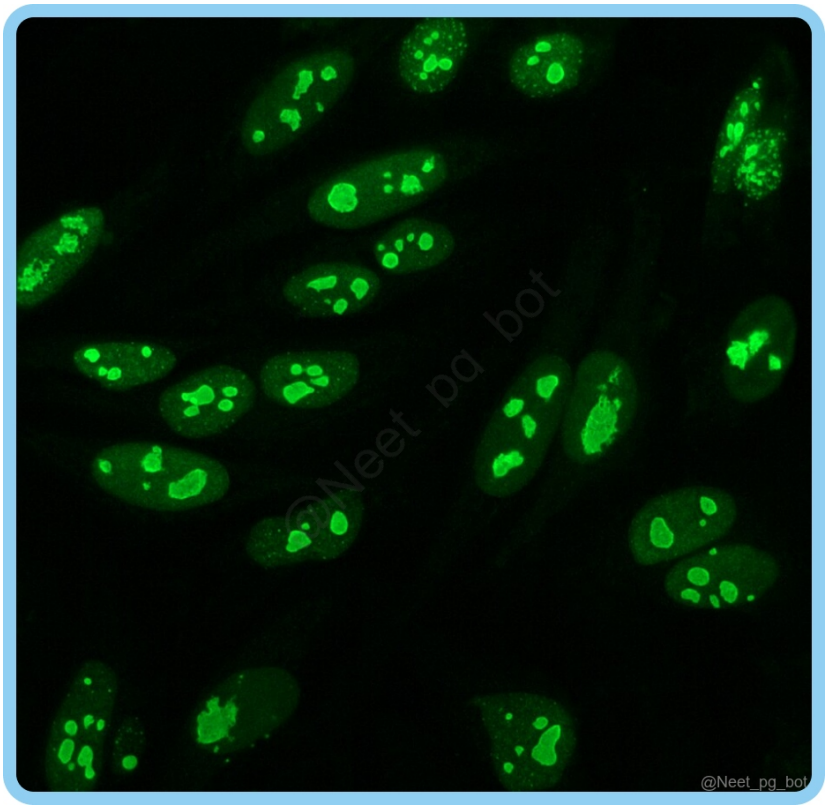

References:

Harrison’s Principles of Internal Medicine, 21st Edition, Page: 2776, 2779, 2780.

Systemic Sclerosis (Scleroderma) - StatPearls - NCBI Bookshelf

↑ *Back to this question in Part A*

@Neet_pg_bot

Q10: A 36-year-old woman presented with claudication in the forearm, transient loss of vision, and abdominal pain. Femoral pulses were weak. Fundus examination revealed retinal haemorrhages. What is the likely diagnosis? (Q856162)

A. Polyarteritis nodosa

B. Thromboangitis obliterans

C. Takayasu arteritis

D. Microscopic polyangiitis

Correct Answer: C. Takayasu arteritis

Explanation: The clinical scenario of forearm claudication, transient loss of vision, and abdominal pain with weak femoral pulses point to the diagnosis of Takayasu arteritis. Takayasu Arteritis ("Pulseless disease"): General features: Predominantly affects young females (<20 years) Vascular Involvement: A leading cause of renal artery stenosis in India Most commonly affects the left subclavian artery Characteristic ostial narrowing vs. diffuse involvement in atherosclerosis Clinical Features: a) Early Phase (Pre-pulseless): Systemic symptoms: fever, malaise, night sweats Arthralgias, anorexia, weight loss b) Vascular Phase: Arm claudication Unequal blood pressure between arms Pulseless disease (difficult to appreciate radial artery) Hypertension (32-93%) Differential Diagnosis: Young female with renal artery stenosis: India: Think Takayasu arteritis USA: Think fibromuscular dysplasia (FMD) Arm claudication: Rule out neurogenic claudication (cervical disc disease) Investigations: ESR/CRP elevation Mild anaemia Elevated immunoglobulins Investigation of choice: MR angiography (MRA) Complete imaging of the aorta and major branches is needed Management: First Line: Steroids (40-60mg prednisone/day) Second Line: Methotrexate (up to 25mg/week) for steroid-refractory cases Important Points for Differential Blood Pressure: Normal difference between arm-leg BP: <20 mmHg Conditions with unequal arm BPs: Takayasu arteritis Supravalvular aortic stenosis with Coanda effect Preductal coarctation of aorta Major complications: Heart failure, stroke, MI, aneurysm rupture, renal failure. Incorrect Options: Polyarteritis nodosa (Option A) presents non-specific symptoms like weakness, malaise, headache, abdominal pain, and myalgia. These symptoms do not align with the given scenario. Thromboangitis obliterans (Option B) or Buerger disease affects the small to medium arteries and veins and presents with ischemic signs and symptoms in the regions of the distal arteries of the upper and lower limbs. In this condition, claudication is seen in the arch of the foot and calf and is also called the Raynauds phenomenon. Microscopic polyangiitis (Option D) is a rare autoimmune disease where there is small vessel necrotizing vasculitis that manifests as systemic symptoms involving the kidneys (rapidly progressive glomerulonephritis), lungs (diffuse alveolar haemorrhage, chronic interstitial fibrosis), skin (palpable purpura, urticaria, nodules, etc), GIT (bleeding), and CNS (peripheral neuropathy).

References:

Harrison’s Principles of Internal Medicine, 21st Edition, Page: 2810, 2813.

https://www.ncbi.nlm.nih.gov/books/NBK430858/

https://www.ncbi.nlm.nih.gov/books/NBK531484/

↑ *Back to this question in Part A*

@Neet_pg_bot

Q11: Which of the following conditions is not associated with Iritis ? (Q856936)

A. SLE

B. Behcet’s disease

C. Ulcerative colitis

D. Rheumatoid arthritis

Correct Answer: D. Rheumatoid arthritis

Explanation: Iritis, also known as anterior uveitis, is inflammation of the iris and ciliary body. Rheumatoid Arthritis – primarily affects joints; ocular involvement usually affects conjunctiva or sclera (scleritis), not the iris. Systemic Associations and Masquerades of Anterior Uveitis: Infectious Causes : Herpes Infections: Varicella Zoster, Herpes Simplex Virus (HSV) Tuberculosis (TB) Syphilis Leprosy Non-Infectious Causes : With Systemic Association : Sarcoidosis Behçet's Disease (Option B) HLA-B27 Associated Arthritis Inflammatory Bowel Disease: Ulcerative Colitis (UC) (Option C) > Crohn's Disease SLE (Option A) Without Systemic Association : Drug-Induced: Pilocarpine, prostaglandin analogues Masquerade Syndromes : Definition : Conditions that mimic the symptoms of anterior uveitis but are not primarily inflammatory in nature. Neoplastic Masquerades : Lymphomas Anterior Segment Melanoma Retinoblastoma Metastasis Non-Neoplastic Masquerades : Intraocular Foreign Body Old Retinal Detachment Pigment Dispersion Syndrome Coats' Disease

References:

Kanski’s Clinical Ophthalmology, 9th edition, Page 424

↑ *Back to this question in Part A*

@Neet_pg_bot

Q12: Which of the following is not a first-line drug for the management of a patient with rheumatoid arthritis? (Q855602)

A. Sulfasalazine

B. Hydroxychloroquine

C. Methotrexate

D. Azathioprine

Correct Answer: D. Azathioprine

Explanation: Azathioprine is not a first-line DMARD for RA due to lower efficacy and higher toxicity . It is primarily used as an immunosuppressant in organ transplantation and certain autoimmune conditions. Sulfasalazine (Option A) It helps reduce inflammation and joint damage and is considered a first-line treatment option for RA. Hydroxychloroquine (Option B) It has anti-inflammatory properties and can help control symptoms and slow disease progression. It is often prescribed as a first-line treatment option, especially in mild to moderate RA. Methotrexate (Option C) It is highly effective in reducing symptoms, preventing joint damage, and improving long-term outcomes. Methotrexate is considered the anchor drug and is often prescribed as the initial treatment for most patients with RA.

References:

Harrison’s Principles of Internal Medicine, 21st Edition, Page 2752, 2759, 2760, 2761, 2762

↑ *Back to this question in Part A*

@Neet_pg_bot

Q13: Which of the following is true about polyarteritis nodosa? (Q855005)

A. Necrotising inflammation of large vessels

B. Patient has hypogammaglobulinemia

C. 90% is associated with ANCA positivity

D. 30% is associated with Hepatitis B

Correct Answer: D. 30% is associated with Hepatitis B

Explanation: 30% of polyarteritis nodosa is associated with Hepatitis B. Polyarteritis Nodosa: A multisystem, necrotizing vasculitis of small- and medium-sized muscular arteries. (Option A) Characteristically involves renal and visceral arteries. Kidneys: Arteritis without glomerulonephritis; glomerulosclerosis may be seen in hypertensive patients. Polyarteritis nodosa-like vasculitis may be seen in 30% of patients with hepatitis B , with circulating immune complexes composed of hepatitis B antigen and immunoglobulin. Pathology and Pathogenesis: Vascular lesion: Necrotizing inflammation of small- and medium-sized arteries. Lesions are segmental, involving bifurcations and branches of arteries. In acute stages: Polymorphonuclear neutrophils infiltrate vessel walls and perivascular areas, causing intimal proliferation and degeneration. In subacute and chronic stages: Mononuclear cells infiltrate, leading to fibrinoid necrosis, lumen compromise, thrombosis, infarction, and hemorrhage. Aneurysmal dilations up to 1 cm in size are characteristic. Clinical Manifestations: Nonspecific symptoms: Fever, weight loss, malaise, weakness, headache, abdominal pain, myalgias. Renal involvement: Hypertension, renal insufficiency, hemorrhage due to microaneurysms. Laboratory findings: Leukocytosis with neutrophil predominance (eosinophilia is rare). Anemia of chronic disease. Elevated ESR and CRP. Hypergammaglobulinemia may be present. (Option B) Hepatitis B and C screening is essential. ANCA is rarely present. (Option C) Diagnosis: Based on biopsy of involved organs (e.g., nodular skin lesions, painful testes, nerve/muscle) for vasculitis findings. Treatment: Prednisone and cyclophosphamide significantly improve survival. In patients with hepatitis B or C, antiviral therapy should be included along with glucocorticoids and plasma exchange.

References:

Harrison’s Principles of Internal Medicine, 21st Edition, Page 2810,2811

https://www.sciencedirect.com/science/article/abs/pii/S089684110090502X

↑ *Back to this question in Part A*

@Neet_pg_bot

Q14: Which of the following is associated with pauci-immune glomerulonephritis? (Q855062)

A. SLE nephritis

B. Anti-GBM glomerulonephritis

C. IgA nephropathy

D. Granulomatosis with polyangiitis (GPA)

Correct Answer: D. Granulomatosis with polyangiitis (GPA)

Explanation: : Granulomatosis with polyangiitis (GPA) is associated with pauci-immune glomerulonephritis. Microvascular Vasculitis: Disease Key Features Antibodies/Labs Pathology Granulomatosis with Polyangiitis (GPA) Pauci-immune vasculitis Upper/lower respiratory Glomerulonephritis PR3-ANCA c-ANCA pattern Granulomatous inflammation Small vessel vasculitis Microscopic Polyangiitis Pulmonary-renal syndrome No granulomas Segmental necrotizing GN MPO-ANCA p-ANCA pattern Necrotizing vasculitis No granulomas Churg-Strauss Syndrome/ Eosinophilic Granulomatosis with Polyangitis (EGPA) Asthma Peripheral eosinophilia Allergic rhinitis MPO-ANCA p-ANCA pattern Eosinophilic granulomas Vasculitis Mixed Cryoglobulinemia Often HCV-associated Purpura Arthralgias Cryoglobulins HCV antibodies Immune complex deposits Small vessel vasculitis SLE nephritis (Option A): Systemic lupus erythematosus (SLE) nephritis involves immune complex deposition in the glomeruli, leading to kidney inflammation. This is not pauci-immune glomerulonephritis. Anti-GBM glomerulonephritis (Option B) is characterized by antibodies directed against the glomerular basement membrane (GBM), resulting in linear immune complex deposition, not pauci-immune. IgA nephropathy (Option C): In IgA nephropathy, immunoglobulin A (IgA) is deposited in the glomeruli, causing inflammation. This is an immune complex-mediated disorder and not pauci-immune.

References:

Harrison’s Principle of Internal Medicine, 21st Edition, Page 2340

↑ *Back to this question in Part A*

@Neet_pg_bot

Q15: A 54-year-old female patient visits you with symptoms of finger swelling, heartburn, and occasional joint pain. During the examination, her hands appeared shiny, tight, and thickened with non-pitting oedema. Additionally, she has interstitial lung disease and tests positive for ANA antibodies, topoisomerase I antibodies, and anti-RNA polymerase III antibodies. What is the likely diagnosis? (Q859521)

A. Limited cutaneous systemic sclerosis

B. Diffuse cutaneous systemic sclerosis

C. Raynaud's phenomenon

D. Peutz-jeghers syndrome

Correct Answer: B. Diffuse cutaneous systemic sclerosis

Explanation: Diffuse Scleroderma Skin thickening over large body areas (fingers, hands, arms, anterior trunk, legs, and face). Significant risk of organ damage (GI tract, kidneys, lungs, heart). Associated with skin dryness, itching, and musculoskeletal pain. Life-threatening when lungs or heart are severely involved. Acute, severe high blood pressure can lead to kidney damage. Dermal Manifestations of Systemic Sclerosis (SSc) Bilateral Symmetrical Skin Thickening : Begins distally in the fingers and progresses proximally. Skin Pigmentation Changes : Early diffuse tanning without sun exposure. Hypopigmentation with a "salt-and-pepper" appearance on the scalp, upper back, and chest is common in dark-skinned individuals. Sclerosis of Skin and Loss of Appendages : Leads to hair loss, reduced sweating, xerosis, and itching. Disappearance of transverse finger creases and fixed flexion contractures causing muscle atrophy. Fixed Contractures : Affects wrists, elbows, and knees due to skin and tendon fibrosis. Neck Skin Ridges : Firm adherence to platysma muscle limits neck extension. Facial Changes ("Mauskopf") : Taut, shiny skin with loss of wrinkles and reduced mobility. Thinned lips, prominent perioral radial furrows, and microstomia. Pinched, beak-like nose. {{caption_text}} Telangiectasia : Dilated capillaries on face, hands, lips, and oral mucosa; correlated with microvascular disease severity. Skin Ulcerations : Chronic ulcers on fingertips, PIP joints, and bony prominences heal slowly and may become infected. Fingertip ischemia leaves fixed digital "pits." Acro-Osteolysis: Resorption of terminal phalanges due to ischemia. {{caption_text}} Calcinosis Cutis : Dystrophic calcifications in the skin and soft tissues, commonly in patients with anti-centromere antibody–positive lcSSc. Calcific deposits vary in size and may ulcerate, causing pain, infections, or nerve compression. {{caption_text}} Incorrect Options: Limited cutaneous systemic sclerosis (Option A) is positive for anti-centromere antibody or ACA. Raynaud’s phenomenon (Option C) is one of the characteristic presentations of diffuse cutaneous systemic sclerosis. Some body parts, like the fingers and nose, feel numb and cool in response to cold temperatures or stress. Peutz-jeghers syndrome (Option D) is an inherited condition that increases the risk of hamartomatous polyps in the GIT and cancers in the GIT and that of the breast, testicles, and ovaries. Since there are no polyps, PJS is unlikely to be the diagnosis.


@Neet_pg_bot

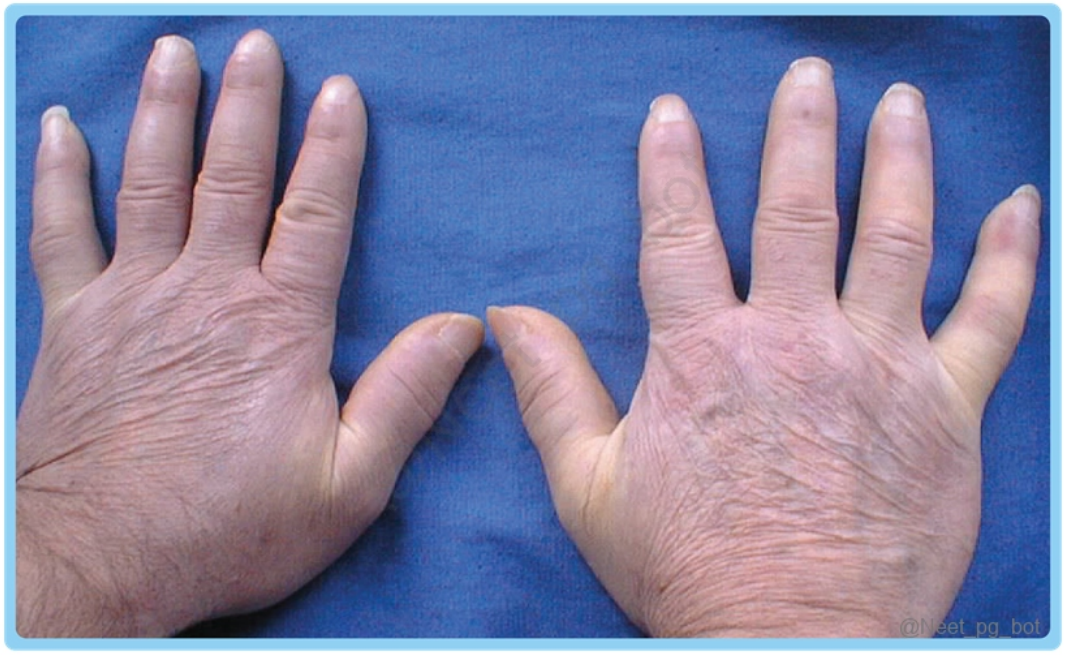
@Neet_pg_bot



References:

Types of Scleroderma | Johns Hopkins Medicine

Classification of Scleroderma | University of Michigan Health

Harrison’s Principles of Internal Medicine, 21st Edition, Page: 2779, 2780.

Systemic Sclerosis (Scleroderma) - StatPearls - NCBI Bookshelf

↑ *Back to this question in Part A*

@Neet_pg_bot

Q16: A 45-year-old woman complains of dryness in her mouth and eyes and has positive anti-Ro and anti-La antibodies. The image below shows a positive test result with a score of less than 5 mm in 5 minutes without anaesthesia. What is the probable diagnosis? (Q859562)

A. Scleroderma

B. Dehydration

C. Lacrimal duct stones

D. Sjogren syndrome

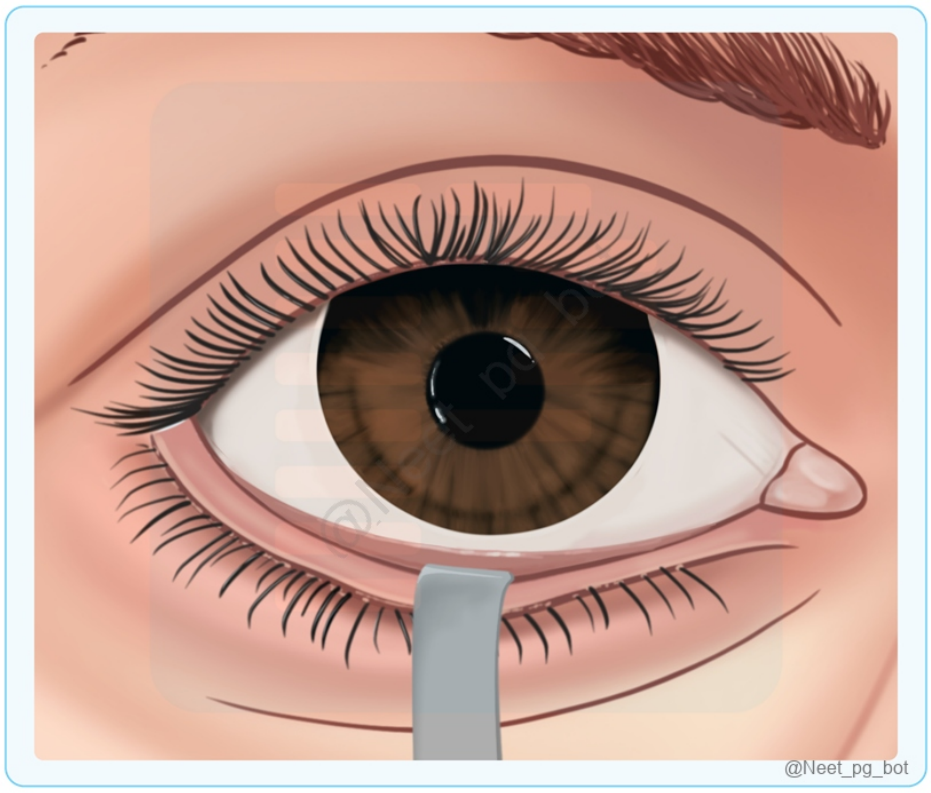

Correct Answer: D. Sjogren syndrome

Explanation: The clinical features of dry eyes and mouth with a Schirmer's test ≤5 mm/5 min and positive anti-Ro and anti-La antibodies suggest the diagnosis of Sjogren syndrome. Sjogren syndrome Pathogenesis: Sjogren Syndrome is an autoimmune disorder primarily affecting the exocrine glands. The pathogenesis involves lymphocytic infiltration (mainly T and B cells) into exocrine glands, especially the salivary and lacrimal glands. A complex interaction of genetic predisposition, environmental factors, and abnormal immune response triggers this infiltration. B-cell hyperactivity: Characterized by hypergammaglobulinemia and autoantibody production (e.g., anti-Ro/SSA and anti-La/SSB). Epithelial cell role: Exocrine gland epithelial cells may express autoantigens (Ro, La), produce pro-inflammatory cytokines, and express Toll-like receptors, facilitating immune activation■. Genetic predisposition: Certain HLA alleles (e.g., HLA-DQA1*0501) and immune-regulatory genes (IRF5, STAT4) increase susceptibility. Clinical Features: {{caption_text}} The hallmark symptoms are xerostomia (dry mouth) and keratoconjunctivitis sicca (dry eyes). Other symptoms include: Oral symptoms: Dry mouth, difficulty swallowing, increased dental caries, and parotid gland enlargement. Ocular symptoms: Gritty sensation, burning, decreased tear production. Systemic involvement: Fatigue, joint pain, Raynaud's phenomenon, and increased risk of lymphoma, particularly marginal zone B-cell lymphoma■. Diagnosis of Sjogren Syndrome: Diagnosis involves clinical features supported by specific tests. Tests: Any of the following is present: Unstimulated whole saliva flow rate ≤0.1 mL/min Schirmer's test ≤5 mm/5 min on at least one eye Ocular staining score ≥5 (or van Bijsterveld's score ≥4) on at least one eye And, any of the following: Serum antibodies - Anti-Ro/SSA and anti-La/SSB Minor salivary gland biopsy (A labial biopsy showing lymphocytic infiltration with a focus score ≥1). Treatment: Treatment is largely symptomatic and involves: Ocular symptoms: Artificial tears and, if needed, topical cyclosporine for inflammation. Xerostomia: Regular sips of water and pilocarpine or cevimeline to stimulate

saliva. Systemic disease: Hydroxychloroquine for mild symptoms and in severe cases, immunosuppressants like rituximab■. Scleroderma (Option A) antibodies are anti-Scl-70 and anti-centromere. Hence this is not the diagnosis here. Dehydration & Lacrimal duct stones (Option B & C) : Dehydration & Lacrimal duct stones are unlikely since this patient tested positive for anti-Ro and anti-La antibodies which are characteristic of Sjogren syndrome.

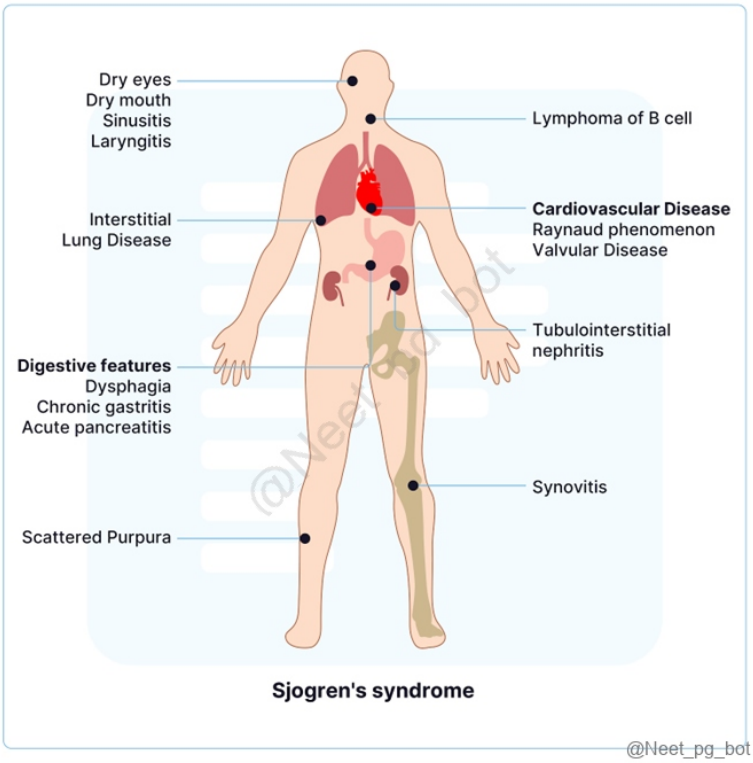

References:

Harrison’s Principles Of Internal Medicine, 21st Edition, Volume I, Page: 2789, 2790.

↑ *Back to this question in Part A*

@Neet_pg_bot

Q17: A 21-year-old woman with no comorbidities presented with numbness and paraesthesia of the fingers of both hands along with the characteristic finding as shown in the image below. She has no other illnesses and she says these episodes occur when she is under excess stress or during cold climates. What is the most likely diagnosis? (Q859563)

A. Primary Raynaud’s phenomenon

B. Secondary Raynaud’s phenomenon

C. Cold sores

D. Scleroderma



Correct Answer: A. Primary Raynaud’s phenomenon

Explanation: This patient has Primary Raynaud's phenomenon because: Young female (age 20-40 years, female: male ratio 5:1) No underlying condition Symmetric involvement Cold trigger Raynaud's Phenomenon Primary Raynaud's: Young female (age 20-40 years, female: male ratio 5:1) No underlying disease Normal nail fold capillaries showing regular hairpin loops Accounts for >50% of cases Better prognosis Improves in 15%, progresses in 30% Classic triphasic colour changes Secondary Raynaud's: (Option B) Common causes include: Connective tissue diseases (especially scleroderma: 80-90%) (Option D) Arterial occlusive diseases Blood dyscrasias Drugs (ergot, beta-blockers, bleomycin) Occupational (vibrating tools) Clinical Features: Sequential colour changes: White (Ischemia) → Blue (Deoxygenation) → Red (Reperfusion) Triggered by cold exposure or emotional stress It may affect fingers, toes, nose, ears It can be associated with pain, numbness, or paresthesias Treatment: Conservative: Warm clothing, avoid cold temperatures, smoking cessation Medications for severe cases: Dihydropyridine Calcium Channel Blockers Alpha-1 Blockers- Prazosin Phosphodiesterase-5 Inhibitors Topical Nitroglycerin Digital sympathectomy in refractory cases Cold sores (Option C) are caused by the virus Herpes and present as small, fluid-filled blisters that appear on the lips, mouth, nose, or cheeks. Given the absence of any comorbidities or underlying diseases, the association of symptoms with cold temperatures or stress, and the characteristic colour changes during episodes, the most likely diagnosis, in this case, is primarily Raynaud's phenomenon.

References:

Harrison’s Principles Of Internal Medicine, 21st Edition, Volume I, Page: 2112, 2113.

↑ *Back to this question in Part A*

@Neet_pg_bot

Q18: A 65-year-old man is experiencing chronic pain in his hands, knees, and hips, with increased pain in the hands during writing or typing. Additionally, he has morning stiffness in his joints that lasts for about 30 minutes. On examination, Heberden's and Bouchard's nodes are visible in the hands, and an X-ray of the knee shows narrowed joint space with osteophytes. What is the most likely diagnosis? (Q859786)

A. Osteoporosis

B. Osteoarthritis

C. Rheumatoid arthritis

D. Bone tumour

Correct Answer: B. Osteoarthritis

Explanation: The clinical manifestations in the given scenario and the presence of Heberden’s and Bouchard’s nodes point to the diagnosis of osteoarthritis . Joint involvement in different types of arthritis: Characteristic Rheumatoid Arthritis (RA) (Option C) Osteoarthritis (OA) (Option B) Psoriatic Arthritis Gout Reactive Arthritis Joint Involvement Pattern Symmetrical involvement of small joints (MCP, PIP) Asymmetrical involvement, especially DIP joints Asymmetrical involvement, often DIP joints Typically involves a single joint (e.g., big toe) Asymmetrical involvement, often larger joints Morning Stiffness Lasts over 1 hour Resolves within 30 minutes Varies, often significant Rarely significant Variable often follows infection Key Symptoms Swelling, tenderness, deformities (e.g., ulnar deviation) Pain and stiffness with use Dactylitis, nail changes Sudden, severe pain and swelling Joint pain following an infection Affected Joints MCP, PIP, wrists, knees Knees, hips, hands (DIP, PIP) MCP, PIP, and can include spine and tendons Typically big toe (1st MTP joint) Larger joints (e.g., knees, ankles) Radiographic Findings Soft tissue swelling, joint space narrowing Osteophytes, joint space narrowing Erosions, possible nail changes Erosions and tophi possible Similar to RA but typically larger joints Osteoporosis (Option A) is a condition where there is a reduction in bone mineral density and mass or a change in the quality and structure of bone. This results in weakened bones, making them more prone to fractures. Heberden’s and Bouchard’s nodes are not seen in osteoporosis. Bone tumour (Option D): The clinical presentation is unlikely of a bone tumour.

References:

Harrison’s Principles of Internal Medicine, 21st Edition, Page: 2751, 2754.

Davidson’s Principles and Practice of Medicine, 24th Edition, Page: 1022.

↑ *Back to this question in Part A*

@Neet_pg_bot

Q19: A 52-year-old woman presented with changes in the hand as shown below. There is decreased motion in the small joints and loss of wrinkle lines on the facial skin. Her chest radiograph showed prominent bilateral lower lobe infiltrates. Which of the following is the most likely diagnosis? (Q859796)

A. Rheumatoid arthritis

B. Scleroderma

C. Systemic lupus Erythematosus

D. Pneumonia



Correct Answer: B. Scleroderma

Explanation: The changes in the hand as given below and the absence of wrinkles on face and other features point to the diagnosis of scleroderma or systemic sclerosis showing its dermal manifestations. Dermal Manifestations of Systemic Sclerosis (SSc) Bilateral Symmetrical Skin Thickening : Begins distally in the fingers and progresses proximally. Skin Pigmentation Changes : Early diffuse tanning without sun exposure. Hypopigmentation with a

"salt-and-pepper" appearance on the scalp, upper back, and chest is common in dark-skinned individuals. Sclerosis of Skin and Loss of Appendages : Leads to hair loss, reduced sweating, xerosis, and itching. Disappearance of transverse finger creases and fixed flexion contractures causing muscle atrophy. Fixed Contractures : Affects wrists, elbows, and knees due to skin and tendon fibrosis. Neck Skin Ridges : Firm adherence to platysma muscle limits neck extension. Facial Changes ("Mauskopf") : Taut, shiny skin with loss of wrinkles and reduced mobility. Thinned lips, prominent perioral radial furrows, and microstomia. Pinched, beak-like nose. {{caption_text}} Telangiectasia : Dilated capillaries on face, hands, lips, and oral mucosa; correlated with microvascular disease severity. Skin Ulcerations : Chronic ulcers on fingertips, PIP joints, and bony prominences heal slowly and may become infected. Fingertip ischemia leaves fixed digital "pits." Acro-Osteolysis: Resorption of terminal phalanges due to ischemia. {{caption_text}} Calcinosis Cutis : Dystrophic calcifications in the skin and soft tissues, commonly in patients with anti-centromere antibody–positive lcSSc. Calcific deposits vary in size and may ulcerate, causing pain, infections, or nerve compression. {{caption_text}} Rheumatoid arthritis (Option A) has symmetrical involvement of small joints, morning stiffness lasting for more than 1 hour, and classical deformities in severe cases. The given scenario does not include symptoms of rheumatoid arthritis. Systemic lupus erythematosus (Option C) presents with fatigue, joint pain, photosensitive rash, mouth ulcers, and hair loss. The given clinical scenario is not of SLE. Pneumonia (Option D) is an infection of the pulmonary parenchyma, classified into community-acquired (CAP), hospital-acquired (HAP) and ventilator-associated (VAP). It does not present as the given scenario. It presents with fever, cough with characteristic sputum, chest pain, headache, chills, etc.







References:

Harrison’s Principles of Internal Medicine, 21st Edition, Page: 2779, 2780.

Systemic Sclerosis (Scleroderma) - StatPearls - NCBI Bookshelf

↑ *Back to this question in Part A*

@Neet_pg_bot

Q20: A woman presents with fever, arthralgia, ulcers, fatigue for the past six months, and new-onset hematuria. Urine examination reveals RBC casts and proteinuria. What is the likely diagnosis? (Q855963)

A. Acute interstitial nephritis

B. Post-streptococcal glomerulonephritis

C. Lupus nephritis

D. IgA nephropathy

Correct Answer: C. Lupus nephritis

Explanation: The clinical presentation, including fever, arthralgia, ulcers, fatigue, hematuria, RBC casts, and proteinuria, is consistent with Lupus Nephritis, a common renal complication of Systemic Lupus Erythematosus (SLE). Lupus Nephritis Pathophysiology: Immune complex deposition in glomeruli involving anti-dsDNA and other antibodies. Clinical Features: Proteinuria (may reach nephrotic range). Hematuria with RBC casts. Systemic symptoms of SLE: fever, arthralgia, oral/nasal ulcers, fatigue, and photosensitivity. May progress to hypertension or end-stage renal disease if untreated. Diagnosis: Urine findings: RBC casts, proteinuria. Serology: Positive ANA, anti-dsDNA, and anti-Sm antibodies. Renal biopsy: Helps classify lupus nephritis into six histological classes. Management: Immunosuppressants: Corticosteroids, cyclophosphamide, mycophenolate mofetil. Hydroxychloroquine is used to manage SLE and is safe during pregnancy. Acute Interstitial Nephritis (Option A): Presents with oliguria, fever, rash, eosinophilia; urine shows WBC casts and granular casts, not RBC casts; common causes include NSAIDs, infections, or drugs. Post-streptococcal Glomerulonephritis (Option B): Common in children aged 2–14; occurs after streptococcal skin or pharyngeal infection; presents with hematuria, edema, hypertension, RBC casts, but lacks systemic features like arthralgia and ulcers. IgA Nephropathy (Option D): Follows upper respiratory infections; characterized by recurrent hematuria with mesangial IgA deposition; does not include systemic symptoms such as fever, ulcers, or arthralgia.

References:

Harrison's Principles of Internal Medicine, 21st Edition, Page: 2296, 2299, 2337, 2338, 2339, 2736-2747.

↑ *Back to this question in Part A*

@Neet_pg_bot

Q21: A 40-year-old female patient presents with dry mouth and a gritty sensation in the eyes. She has normal anion gap metabolic acidosis and hypokalemia. She also has enlarged salivary glands. What is the best investigation to arrive at a diagnosis? (Q879214)

A. Serum ACE levels and chest x-ray

B. Improvement on trial with methylprednisolone

C. Schirmer test and auto-antibody measurement

D. Salivary gland scintigraphy

Correct Answer: C. Schirmer test and auto-antibody measurement

Explanation: A 40-year-old woman presenting with xerostomia, keratoconjunctivitis sicca, enlarged salivary glands, and distal RTA (Type I), points towards the diagnosis of Primary Sjögren Syndrome. It usually presents with: Sicca symptoms (dry eyes, dry mouth) Bilateral parotid swelling Renal involvement, especially distal RTA due to autoimmune damage to intercalated cells Positive anti-SSA (Ro) , anti-SSB (La) , ANA, RF Schirmer test positive (<5 mm in 5 minutes) Serum ACE levels and chest x-ray (Option A): These investigations are used primarily for diagnosing sarcoidosis , not Sjögren syndrome. Serum ACE : Elevated in ~60% of sarcoidosis cases. Chest X-ray : For detecting bilateral hilar lymphadenopathy or pulmonary infiltrates.. Improvement on trial with methylprednisolone (Option B): The corticosteroid trial is not diagnostic for autoimmune diseases. Clinical response to steroids is non-specific and can occur in vasculitides, sarcoidosis, lymphoma, connective tissue diseases and infections. Moreover, Sjögren syndrome often shows a limited response to steroids unless there is extra-glandular systemic involvement. Salivary gland scintigraphy (Option D): Although it can demonstrate reduced salivary gland function, it is not the first-line investigation. It has low specificity (reduced uptake can occur in dehydration, ageing, radiation exposure, sarcoidosis), is less accessible and more expensive. It is not included as a major component of modern ACR-EULAR criteria.

References:

Sjögren’s syndrome - Autoimmunity - NCBI Bookshelf

↑ *Back to this question in Part A*

@Neet_pg_bot

Q22: After confirming a diagnosis of gout, which of the following drugs is a purine analog that would be most appropriate for management? (Q860474)

A. Allopurinol

B. Capecitabine

C. Cytarabine

D. Febuxostat

Correct Answer: A. Allopurinol

Explanation: Allopurinol is the first-line choice for gout management. It is a purine analog that acts as a xanthine oxidase inhibitor, effectively reducing uric acid production. The drug works through dual mechanisms : direct inhibition of xanthine oxidase and competition with phosphoribosylpyrophosphate in the salvage pathway. Allopurinol: Allopurinol is the first-line treatment for the prevention of gouty arthritis, particularly in patients who are overproducers of uric acid. The initial dose is typically 100 mg daily, with a target urate level of <5-6 mg/dL and can be titrated up to 800 mg as needed. In patients with renal impairment, dose adjustments are essential. Adverse effects : Stevens-Johnson syndrome Toxic epidermal necrolysis Acute gout flare-up, which may occur due to rapid urate level reduction To prevent flare-ups, anti-inflammatory therapy should be continued until the patient is normouricemic and has not had an attack for 3-6 months. Capecitabine (Option B) is a pyrimidine analog used in breast cancer treatment. This medication has no role in gout management and does not affect uric acid metabolism. Cytarabine (Option C) is a cytosine arabinoside and pyrimidine analog used in chemotherapy. It is not indicated for gout treatment and does not influence uric acid levels. Febuxostat (Option D) is also a xanthine oxidase inhibitor. While effective for gout, it is not a purine analog.

References:

Harrison’s Principles of Internal Medicine, 21st Edition, Page 2864-2865

Davidson’s Principles and Practice of Medicine, 24th Edition, Page 1016

↑ *Back to this question in Part A*

@Neet_pg_bot

Q23: A child presents with kawasaki disease with multiple small coronary artery aneurysms. Treatment is? (Q866821)

A. Aspirin lifelong

B. Aspirin for 4 weeks

C. Aspirin for 6 weeks

D. Aspirin and clopidogrel for 6 weeks

Correct Answer: C. Aspirin for 6 weeks

Explanation: In Kawasaki disease with multiple small coronary artery aneurysms , the recommended management is: Low-dose aspirin for 6–8 weeks , Continue only if aneurysms persist on follow-up echocardiography. This duration covers the period of highest thrombosis risk while the coronary arteries remodel, and small aneurysms often regress. IVIG is given in the acute phase to reduce the risk of aneurysm formation. Aspirin lifelong (Option

A): Reserved for large or giant aneurysms with persistent risk of thrombosis. Aspirin for 4 weeks (Option B): Typically used when no coronary involvement is present. Aspirin and clopidogrel for 6 weeks (Option D): Dual antiplatelet therapy is usually reserved for larger aneurysms or specific thrombosis risk cases, not routine small aneurysms.

References:

.

↑ *Back to this question in Part A*

@Neet_pg_bot

Q24: Which of the following is the most common clinical feature observed during the progression of systemic lupus erythematosus (SLE)? (Q865303)

A. Photosensitivity

B. Nephrotic syndrome

C. Arthralgia & myalgia

D. Anemia and thrombocytopenia

Correct Answer: C. Arthralgia & myalgia

Explanation: Musculoskeletal involvement is the most common clinical feature in Systemic Lupus Erythematosus (SLE). Arthralgia (joint pain) and myalgia (muscle pain) occur in the majority of patients, often as initial symptoms. SLE commonly presents with polyarthritis or polyarthralgia that resembles rheumatoid arthritis, but is typically non-erosive. Systemic Involvement in SLE System Manifestations Pulmonary system Pleuritis (most common): Prevalence (30 - 50%) Pneumonitis Atelectasis Reduced lung volume and Pulmonary ■brosis Shrinking lung syndrome, (< 5%) Intra-alveolar hemorrhage Pulmonary HTN (< 5 %) Acute Respiratory Distress Syndrome (ARDS) (< 5%) Musculoskeletal system It is the most commonly involved system Polyarthritis (symmetrical) Polyarthralgia Rheumatoid arthritis Myositis Jaccoud arthropathy is a reversible deformity caused by ligament laxity, capsule fibrosis, and muscular imbalance. Axial skeletal involvement is uncommon. ■ Renal system Lupus nephritis (most common) Proteinuria Nephrotic syndrome Rarely End-stage Renal Disease (ESRD) Nervous system Headache, Seizures, Stroke, Polyneuropathy, TIA, Acute confusional state, Movement disorder, Aseptic meningitis, Myelopathy, Psychosis and Mood disorders. Cardiovascular system Coronary artery disease - common cause of death Pericarditis Coronary vasculitis Myocarditis Libman sacks endocarditis Accelerated atherosclerosis Hematological manifestations Anemia of chronic disease Leucopenia Lymphopenia Thrombocytopenia Autoimmune Hemolytic anemia-MCC of anemia in SLE Splenomegaly GI involvement Abdominal pain Nausea, diarrhoea Abnormal liver enzymes Ocular manifestation Sicca syndrome: Dry eyes (keratoconjunctivitis sicca) and dry mouth (xerostomia). Conjunctivitis Episcleritis Vasculitis



References:

Harrison’s Principles of Internal Medicine, 21st Edition, Page 2740, 2741, 2742, 2743.

↑ *Back to this question in Part A*

@Neet_pg_bot

Q25: A patient presents with morning stiffness and tests positive for anti-CCP antibodies. Which of the following histological features is most characteristic of the underlying disease? (Q866467)

A. Pannus formation and erosive joint damage

B. Non-caseating granulomas

C. Subepidermal blister with IgA deposits

D. Tophi with monosodium urate crystals

Correct Answer: A. Pannus formation and erosive joint damage

Explanation: Pannus formation and erosive joint damage Anti-CCP antibodies are highly specific for rheumatoid arthritis (RA) . The hallmark histopathological finding in RA is pannus formation - a hyperplastic granulation tissue composed of inflammatory cells, fibroblasts, and synovial cells, which invades cartilage and bone, leading to erosive joint damage and deformities. Rheumatoid arthritis Epidemiology Male to female ratio - 1:3 Peaks between 25 and 55 years Remains constant between 55 and 75 Genetics Strongly associated with the HLA-DRβ1 gene Higher concordance in monozygotic twins Triggers and suppressors Cigarette smoking and infections can trigger RA in genetically predisposed individuals by citrullination of proteins. RA may remit during pregnancy and can first appear postpartum due to immune suppression and hormonal changes. Non-caseating granulomas (Option B): Characteristic of sarcoidosis, not RA. Subepidermal blister with IgA deposits (Option C): Seen in dermatitis herpetiformis, associated with celiac disease. Tophi with monosodium urate crystals (Option D): Pathognomonic for chronic gout, not RA.

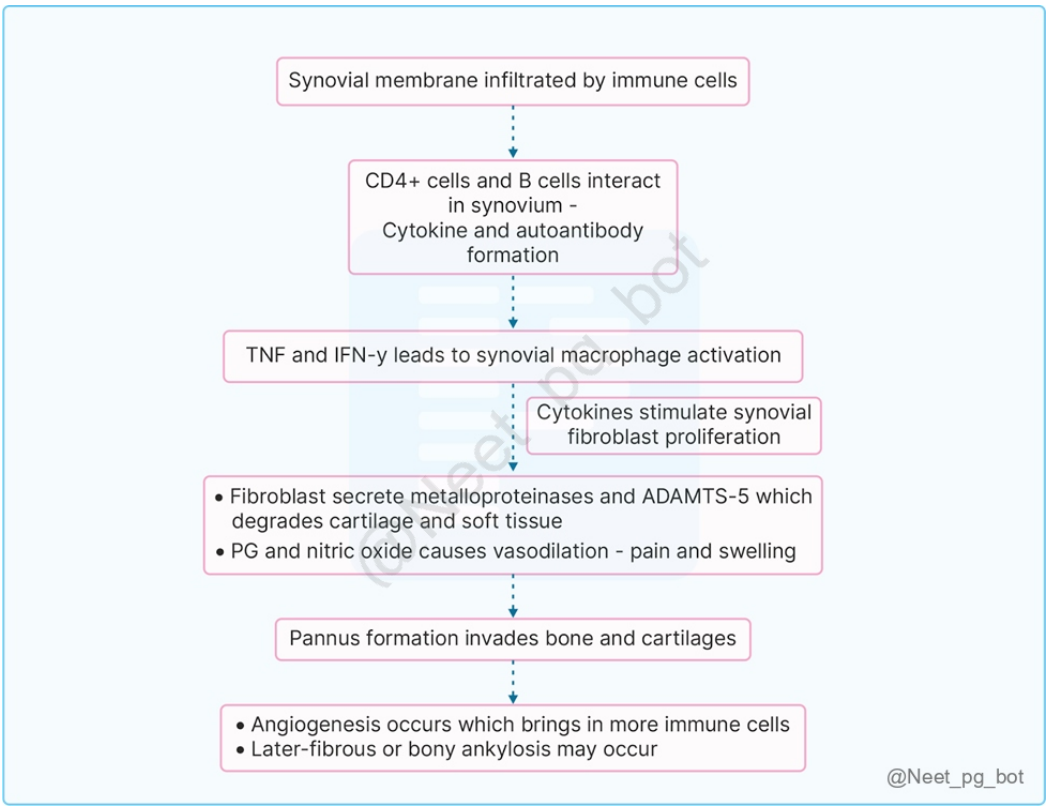

References:

.

↑ *Back to this question in Part A*

@Neet_pg_bot

Q26: Patient presents with dry cough, dyspnea and stridor since 1 month. HPE of hilar LN shows stellate granulomas with giant cells and circular lamellated concretions on histopathology. Which of the following is the most likely diagnosis?

(Q866484)

A. Sarcoidosis

B. Tuberculosis

C. GPA

D. Hypersensitivity pneumonitis

Correct Answer: A. Sarcoidosis

Explanation: The presence of stellate granulomas with giant cells and lamellated concretions (Schaumann bodies) in hilar lymph nodes is characteristic of sarcoidosis . Sarcoidosis is a multisystem granulomatous disease of unknown etiology, often involving the lungs and intrathoracic lymph nodes. Non-caseating granulomas, giant cells, asteroid bodies, and Schaumann bodies are typical histopathological findings. The patient's respiratory symptoms, stridor, and mediastinal lymphadenopathy support this diagnosis. Asteroid Bodies: Asteroid bodies are stellate or star-shaped structures seen within the cytoplasm of giant cells. They are composed of aggregated proteinaceous material consisting primarily of fibrin. Schaumann Bodies: They are concentrically laminated, basophilic structures found within the cytoplasm of giant cells. They comprise calcium and proteinaceous material, such as mucopolysaccharides and immunoglobulins. Schaumann bodies Schaumann bodies- magnified Tuberculosis (Option B): Shows caseating granulomas with central necrosis, not the non-caseating granulomas with Schaumann bodies seen in sarcoidosis. GPA (Option C): Characterized by necrotizing granulomas and vasculitis affecting the upper/lower respiratory tract and kidneys; histology does not show lamellated concretions. Hypersensitivity pneumonitis (Option D): Features loosely formed interstitial granulomas without Schaumann bodies; usually history of antigen exposure (e.g., mold, bird droppings).



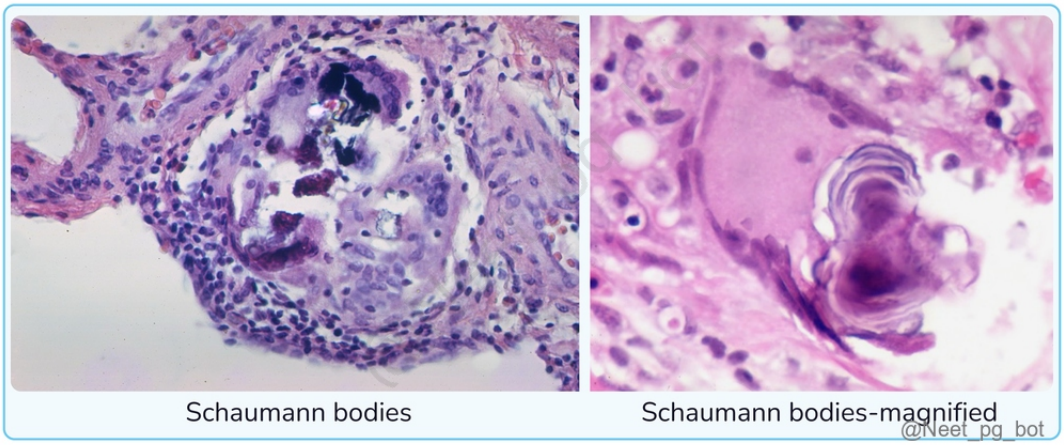

References:

.

↑ *Back to this question in Part A*

@Neet_pg_bot

Q27: Anti-Scl-70 (anti-topoisomerase I) antibody in systemic sclerosis is most commonly associated with which of the following manifestations? (Q866490)

A. Interstitial Lung Disease

B. Raynaud's phenomenon

C. Calcinosis cutis

D. Gastric Antral Vascular Ectasia

Correct Answer: A. Interstitial Lung Disease

Explanation: Anti-Scl-70 (anti-topoisomerase I) antibody is strongly associated with diffuse cutaneous systemic sclerosis and a high risk of developing interstitial lung disease (ILD) , particularly pulmonary fibrosis. This antibody is both a marker of disease severity and a predictor of poorer prognosis in systemic sclerosis. Pulmonary Features in Systemic Sclerosis (SSc): Major Forms of Lung Involvement: Interstitial Lung Disease (ILD) and Pulmonary Arterial Hypertension (PAH) are the primary lung issues and leading causes of SSc-related death. The coexistence of ILD and PAH worsens survival rates significantly. Interstitial Lung Disease (ILD) : Evidence of ILD on HRCT in up to 65% of patients, with clinically significant ILD in 16–43%. Risk factors: Male sex, African-American race, diffuse skin involvement, severe GERD, and presence of Scl-70 autoantibodies. Progressive early decline in FVC (within 3–5 years). Symptoms: Exertional dyspnea, fatigue, dry cough, and Velcro crackles at lung bases. HRCT shows lower lobe subpleural reticular opacities and ground-glass opacities;

the extent of ILD on HRCT predicts progression and mortality. PFTs show restrictive defects and reduced DLCO, often with exercise desaturation. Pulmonary Arterial Hypertension (PAH) : Affects 8–12% of SSc patients as a late complication, often coexisting with ILD. Defined by elevated mean pulmonary artery pressure (≥20 mmHg) with normal pulmonary capillary wedge pressure (≤15 mmHg). Risk factors: Limited cutaneous disease, older age at onset, and certain autoantibodies (e.g., anti-centromere). Symptoms progress from exertional dyspnea to angina, syncope, and right heart failure. Exam findings: Loud pulmonic component of S2, tricuspid regurgitation murmur, elevated JVP, peripheral edema. Screening: Annual echocardiography; cardiac catheterization for definitive diagnosis. Other Pulmonary Complications : Includes aspiration pneumonitis, pulmonary hemorrhage, obliterative bronchiolitis, pleural reactions, chest wall fibrosis, spontaneous pneumothorax, and increased risk of lung cancer. Cardiac Manifestations of Systemic Sclerosis (SSc): Detected in 10–50% of SSc patients, more common in diffuse cutaneous SSc (dcSSc) than limited cutaneous SSc (lcSSc). Cardiac involvement correlates with worse outcomes in SSc. Types of Involvement : Pericardial : Includes pericarditis, pericardial effusions, constrictive pericarditis, and rarely, cardiac tamponade. Myocardial : Patchy myocardial fibrosis due to microvascular involvement, vasospasm, and ischemia-reperfusion injury leading to left ventricular systolic or diastolic dysfunction and potentially heart failure. Endocardial : Often silent but may contribute to overall dysfunction. Conduction Abnormalities : Common conduction system fibrosis, with potential heart block, premature ventricular contractions, atrial fibrillation, and supraventricular tachycardia. Myocarditis : Acute or subacute myocarditis may lead to left ventricular dysfunction, best detected by cardiac MRI or endomyocardial biopsy. Raynaud's phenomenon (Option B): Common in systemic sclerosis, but it is not specifically linked to anti-Scl-70; seen in both limited and diffuse types, often associated with anti-centromere antibodies in limited cutaneous form. Calcinosis cutis (Option C): More often linked to the limited form of systemic sclerosis and the CREST variant, not to anti-Scl-70. Gastric Antral Vascular Ectasia (Option D): “Watermelon stomach” occurs in systemic sclerosis but is not specifically correlated with anti-Scl-70; more frequent in limited disease.

↑ *Back to this question in Part A*

@Neet_pg_bot

Q28: A 42-year-old woman presents with recurrent bluish discoloration of her fingers on exposure to cold, tightening of the skin over her hands and face, difficulty swallowing, and shortness of breath. On examination, she has shiny, taut skin over her fingers and visible telangiectasias. What does this ANA pattern indicate, and what is the most likely diagnosis? {{caption_text}} (Q853354)

A. Speckled pattern, SLE

B. Nuclear pattern, SLE

C. Anti-centromere pattern, CREST

D. Homogeneous pattern, systemic sclerosis

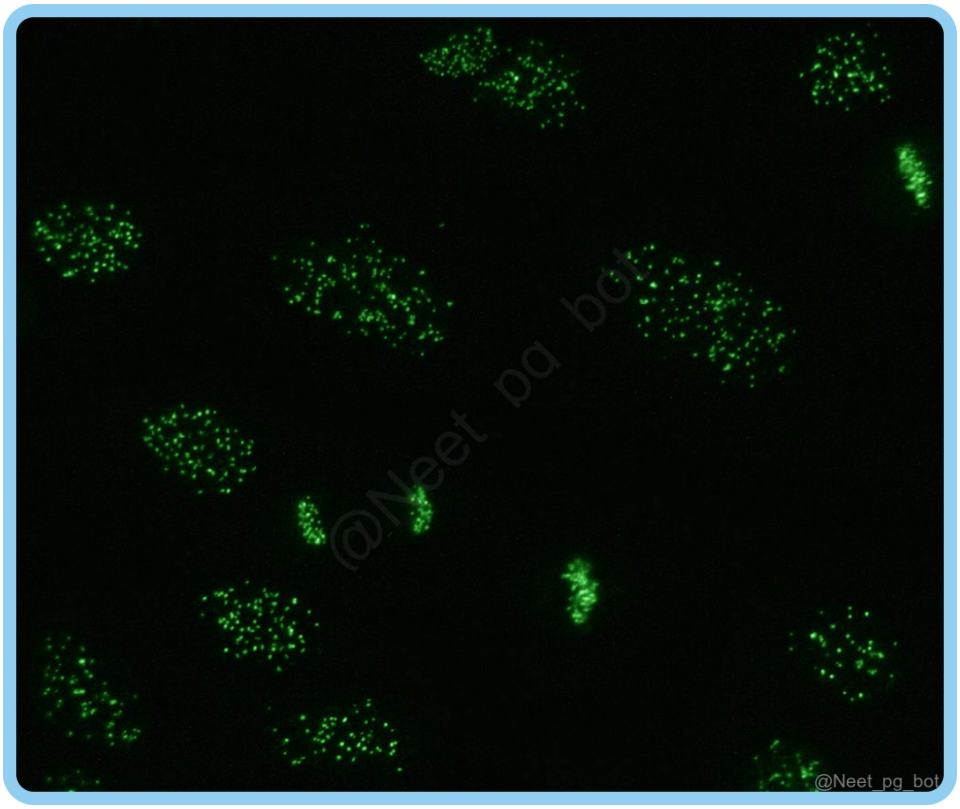

Correct Answer: C. Anti-centromere pattern, CREST

Explanation: The patient’s Raynaud’s phenomenon, sclerodactyly, esophageal dysmotility, and telangiectasias are classic for CREST syndrome (limited systemic sclerosis) . Anti-centromere antibodies (ACA) are highly specific, producing a centromeric ANA pattern with fine, discrete speckles at chromosome centromeres . Mnemonic – “CREST” : C: Calcinosis cutis R: Raynaud’s phenomenon E: Esophageal dysmotility S: Sclerodactyly T: Telangiectasias ANA Immunofluorescence Patterns in Autoimmune Diseases Pattern Image Clinical Associations Centromeric (Fine, discrete speckling of the centromere of chromosomes) {{caption_text}} Systemic Sclerosis (especially limited form, CREST syndrome) Mixed Connective Tissue Disease (MCTD). Nucleolar (Option B) (Large, prominent nucleoli within the cell nucleus) {{caption_text}} Systemic Sclerosis (particularly in patients with interstitial lung disease) Polymyositis Sjögren's Syndrome. Homogeneous (Option D) Smooth, uniform staining of the entire nucleus) {{caption_text}} Systemic Lupus Erythematosus (SLE) Drug-induced lupus Rheumatoid Arthritis (RA). Peripheral/Rim (Intense staining of the nuclear membrane or periphery) {{caption_text}} Systemic Lupus Erythematosus (SLE), highly suggestive of SLE, especially with associated anti-dsDNA antibodies. Speckled (Option A) (Fine or coarse speckling throughout the nucleus) {{caption_text}} SLE Sjogren’s Syndrome Scleroderma Polymyositis Rheumatoid Arthritis Mixed Connective Tissue Speckled pattern can be nonspecific.

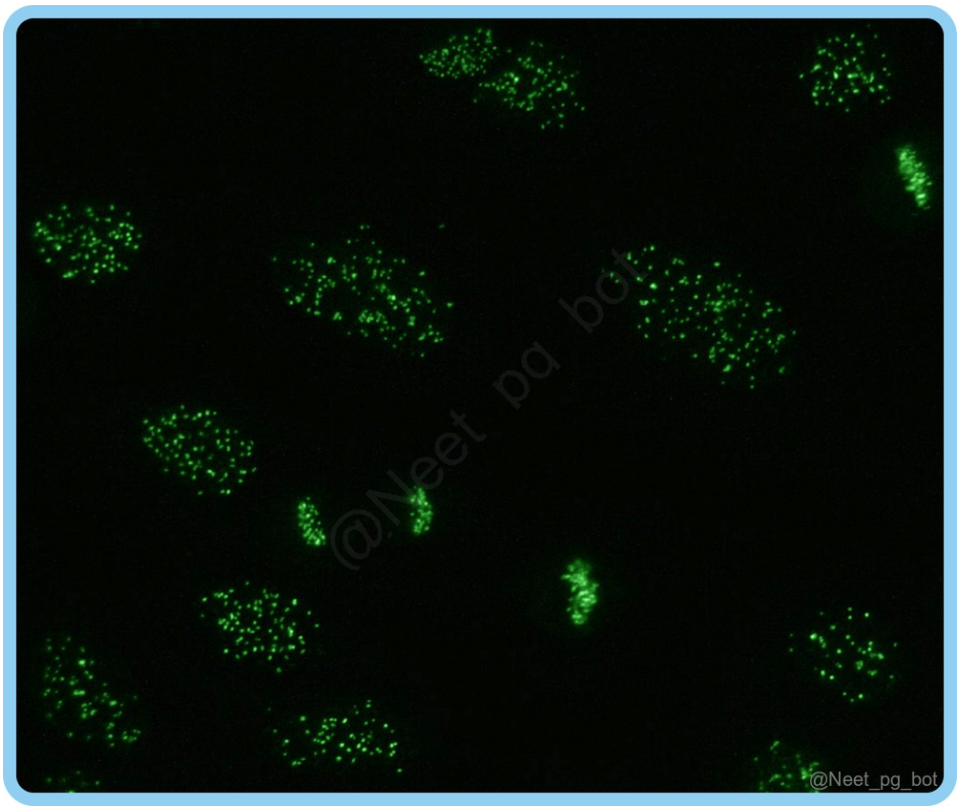
@Neet_pg_bot

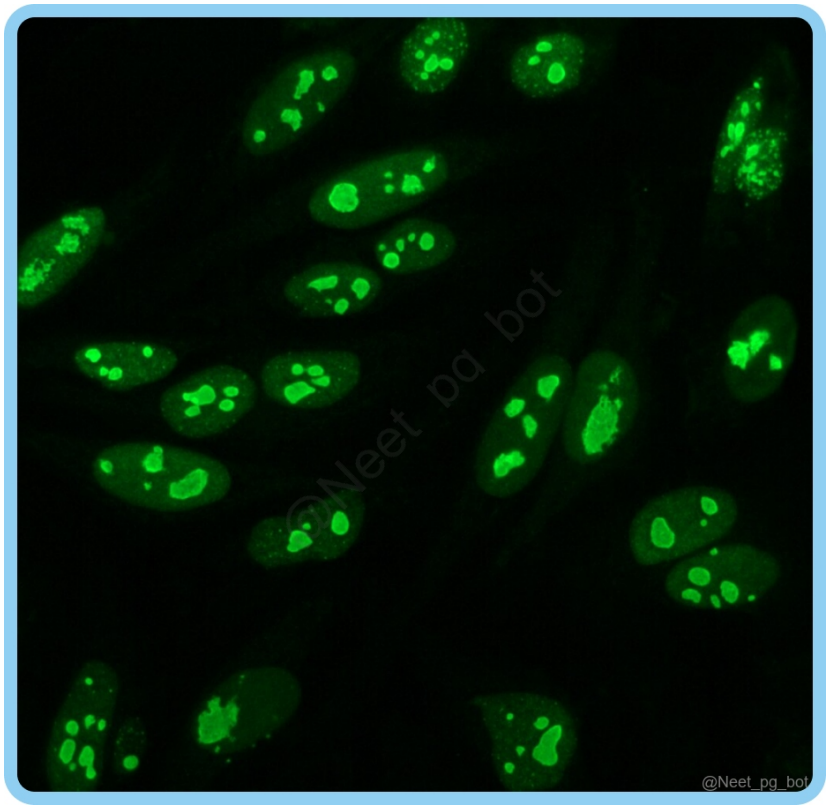
@Neet_pg_bot

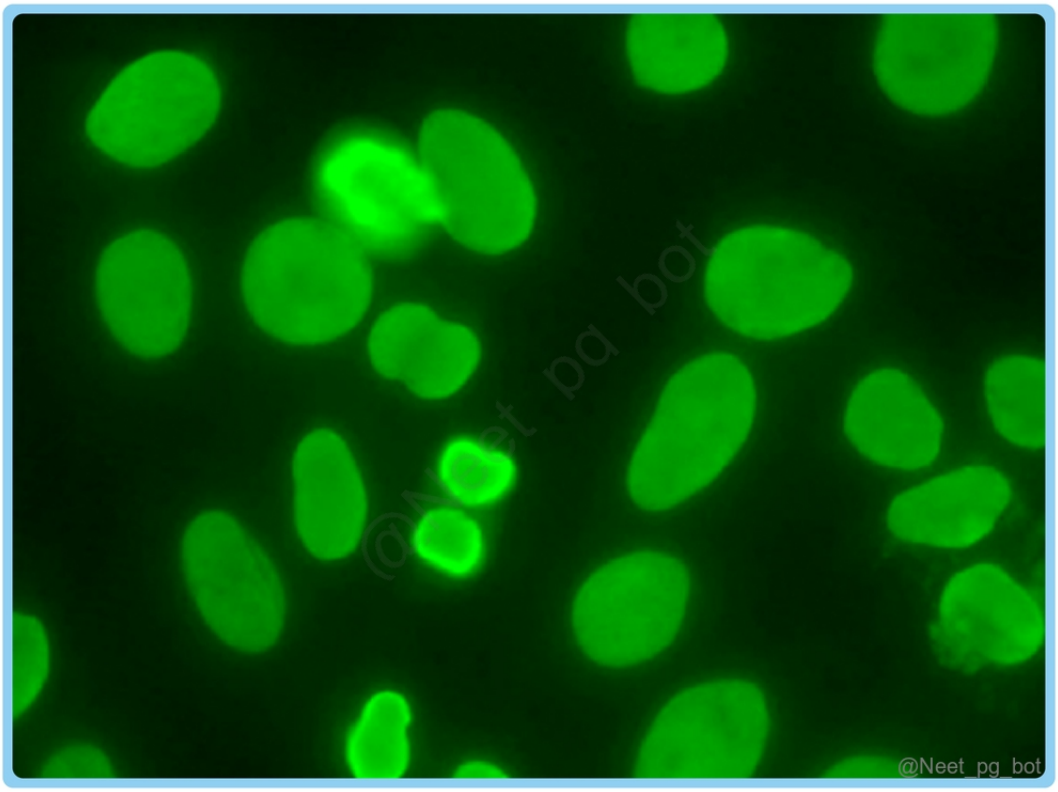

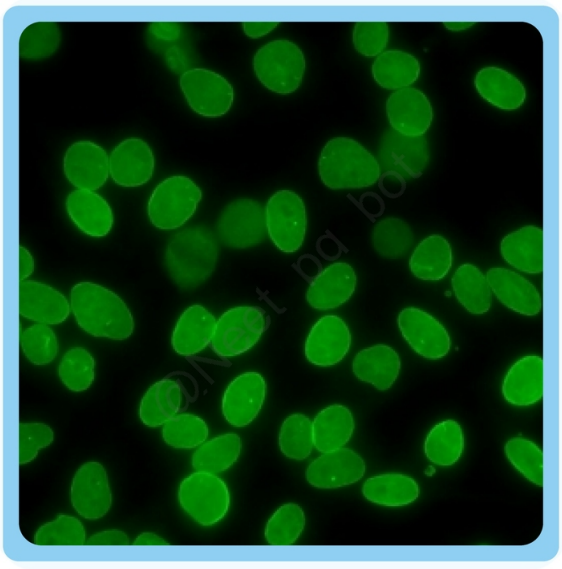

@Neet_pg_bot

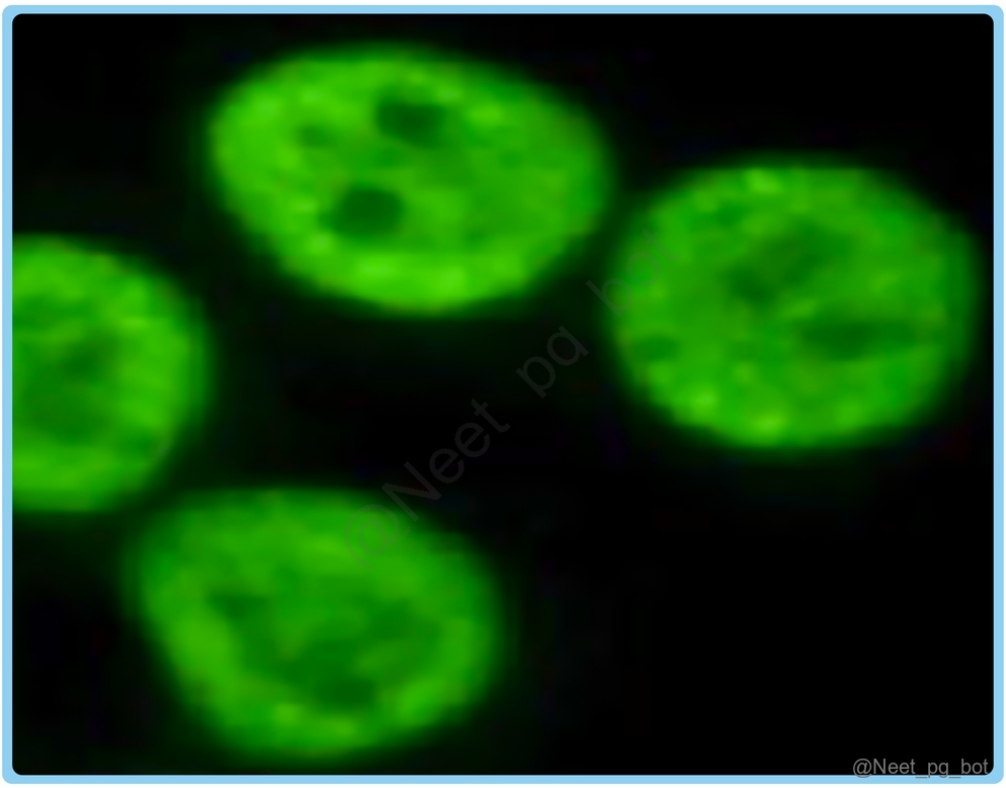

References:

Robbins and Cotran Pathologic Basis of Disease, 10th Edition, Pages 223, 231.

https://pmc.ncbi.nlm.nih.gov/articles/PMC7263989/

↑ *Back to this question in Part A*

@Neet_pg_bot

Q29: A patient presented with uveitis, enthesitis, and sacroiliitis. Which of the following is most likely associated with this condition? (Q853359)

A. HLA-B27

B. HLA-B57

C. HLA-B51

D. HLA-B5

Correct Answer: A. HLA-B27

Explanation: The combination of uveitis, enthesitis, and sacroiliitis is characteristic of ankylosing spondylitis (AS) and other spondyloarthropathies, which are strongly associated with HLA-B27. Ankylosing Spondylitis Clinical Features General Features Spine and Joint involvement Extra-articular manifestations Inflammatory back pain : Gradual onset, worse with inactivity, improves with movement and is often associated with early morning stiffness. Fatigue : A common and significant symptom. Postural changes : Loss of lumbar lordosis, increased thoracic kyphosis, and forward stooping of the neck. Enthesitis : Inflammation at tendon or ligament attachment sites, often mistaken for fibromyalgia. Peripheral joint involvement : Affects large joints like hips, knees , and shoulders and is usually asymmetrical. Sacroiliac joint involvement : B/L and asymmetrical; pain may radiate to the buttocks or posterior thighs. Reduced spinal mobility: Limited movement in the lumbar region due to inflammation and pain, often accompanied by muscle spasms. Anterior uveitis: Most common extra articular manifestation. Presents with sudden unilateral eye pain, redness, and light sensitivity, often preceding joint symptoms. Anaemia, prostatitis, inflammatory bowel disease, aortic valve disease, and very rare cases of amyloidosis or upper lobe pulmonary fibrosis Osteoporosis : This can lead to vertebral fractures, especially with spinal fusion. Investigations of Ankylosing Spondylitis Tests X-rays MRI HLA-B27: The presence of the HLA-B27 gene is a strong indicator of AS. The prevalence of AS in the general population is less than 0.5%. Inflammatory Markers : Elevated ESR and CRP levels may indicate active disease. Faecal Calprotectin : Helps screen for associated inflammatory bowel disease. Show characteristic changes in sacroiliac joints , such as: Blurred cortical margins Erosions and sclerosis "Pseudowidening" of joint space (early stages) Joint space narrowing and fusion (later stages) Bamboo spine - Vertebral body fusion by syndesmophytes Dagger sign - Calcification appears as a single radiodense line vertically running down the spine on frontal radiographs. Investigation of choice – more sensitive than X-rays for detecting early inflammatory changes. Can reveal bone marrow oedema, enthesitis, synovitis, and erosions. HLA Types & Conditions Associated HLA Type Associated Conditions HLA-A1 Reiter's syndrome Ankylosing spondylitis Juvenile rheumatoid arthritis Primary sclerosing cholangitis HLA-A2 Systemic lupus erythematosus (SLE) Autoimmune hepatitis Multiple sclerosis Type 1 diabetes Melanoma HLA-B8 Celiac disease Autoimmune hepatitis Addison's disease Myasthenia gravis Primary sclerosing cholangitis Dermatitis herpetiformis HLA-B27 Ankylosing spondylitis Reiter's syndrome (Reactive arthritis) Psoriatic arthritis Crohn's disease Ulcerative colitis Acute anterior uveitis HLA-B35 Ulcerative colitis Psoriasis Chronic active hepatitis Rheumatoid arthritis Subacute thyroiditis HLA-B51 (Option C) Behçet’s disease Uveitis HLA-B5 (Option D) Behçet’s disease HLA-B57 (Option B) Slower progression of HIV infection HLA-DR1 Rheumatoid arthritis Systemic lupus erythematosus (SLE) Vasculitis Pemphigus vulgaris HLA-DR2 Multiple sclerosis Allergic rhinitis Narcolepsy Systemic lupus erythematosus (SLE) Goodpasture's syndrome Leprosy HLA-DR3 Type 1 diabetes Systemic lupus erythematosus (SLE) Graves' disease Hashimoto’s thyroiditis Sjögren's syndrome Primary biliary cholangitis (PBC) HLA-DR4 Rheumatoid arthritis Juvenile arthritis Insulin-dependent diabetes mellitus (Type 1 diabetes) Giant cell arteritis Pemphigus vulgaris HLA-DR5 Graves' disease Hashimoto's thyroiditis Chronic active hepatitis Pernicious anemia HLA-DQ2 Celiac disease Dermatitis herpetiformis HLA-DQ8 Celiac disease Type 1 diabetes

References:

Harrison's Principles of Internal Medicine, 21st Edition, Page 2687.

www.ncbi.nlm.nih.gov/books/NBK459459/

↑ *Back to this question in Part A*

@Neet_pg_bot

Q30: A male patient presents with oral ulcers and ulcers in the anal canal. He is diagnosed with Behçet's disease. Which of the following is not seen in this condition? (Q853361)

A. Ulcer over the dorsum of the penis

B. It is more similar to Crohn's disease than ulcerative colitis

C. Bilateral panuveitis

D. Pathergy test positive is a criterion of ISG diagnostic criteria

Correct Answer: A. Ulcer over the dorsum of the penis

Explanation: Ulcers over the dorsum of the penis are not typically associated with Behçet’s disease, which more commonly presents with genital ulcers on the scrotum or glans penis, rather than the dorsum. Behçet’s Disease is a chronic, multisystemic vasculitis characterized by recurrent oral and genital ulcers, uveitis, and systemic involvement. It is an immune-mediated disorder that primarily affects small and medium-sized blood vessels. Behcet’s Disease- Pathogenesis and Clinical Features Category Features Clinical Significance Pathogenesis T-cell mediated immunity Th1 cell activation Elevated cytokines (IL-1, TNF-α) Neutrophilic vasculitis No specific autoantibodies Auto-inflammatory rather than autoimmune Affects vessels of all sizes Treatment targets inflammation Mucocutaneous Oral ulcers (97-99%) Genital ulcers (>80%) Erythema nodosum Pathergy reaction Often initial presentation Oral ulcers heal without scarring Genital ulcers leave scars Major Organ Involvement B/L uveitis (>50%) (Option C) Vascular (25%) Neurologic (5-10%) Arthritis (non-erosive) More severe in males Ocular disease can cause blindness Vascular involvement can be fatal Presents similar to IBD (Crohn's disease > Ulcerative colitis) (Option B) {{caption_text}} Behcet’s Disease- Diagnosis and Management Diagnosis Diagnostic Criteria (ITR-ICBD) Two Points Each: Genital aphthosis Ocular lesions One Point Each: Oral aphthosis Skin lesions Vascular manifestations Positive pathergy (Option D) ≥3 points needed for diagnosis Laboratory Findings Non-specific inflammation markers No specific autoantibodies ESR, CRP elevation Leukocytosis Helps rule out other conditions Required Investigations Ophthalmologic examination Pathergy test Skin biopsy if needed Imaging, based on symptoms Confirms involvement and monitors complications Treatment Mucocutaneous Treatment Colchicine 1-2mg/day Topical steroids Topical sucralfate Refractory: Systemic steroids, azathioprine Ocular Treatment Anterior: Topical steroids Posterior: Steroids + azathioprine Refractory: TNF inhibitors Major Organ Involvement Vascular: High-dose steroids + cyclophosphamide Neurologic: High-dose steroids + immunosuppression Requires aggressive therapy and monitoring

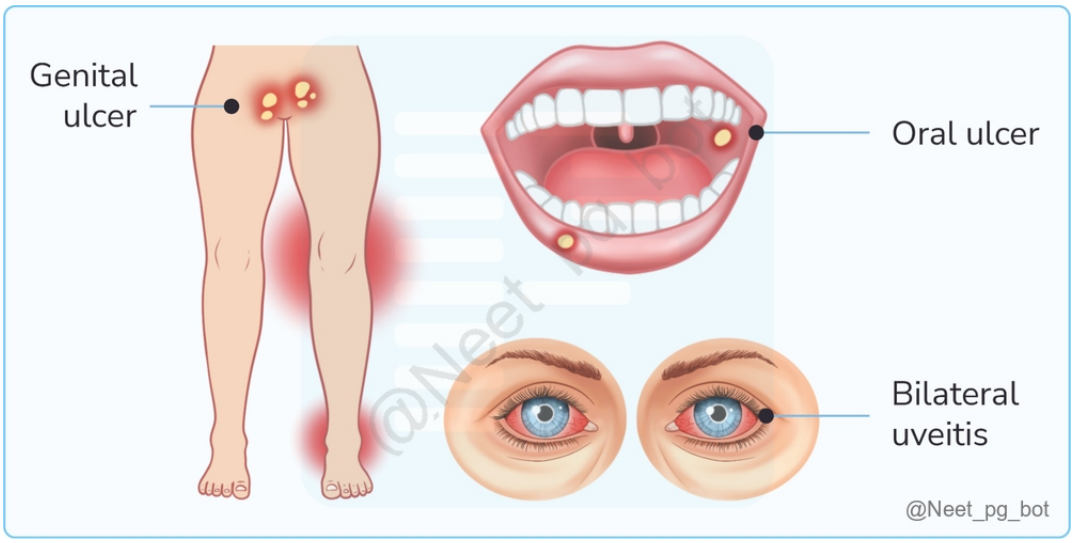

References:

Harrison's Principles of Internal Medicine, 21st Edition, Pages 2817, 2818.

Pubmed

↑ *Back to this question in Part A*

@Neet_pg_bot

Q31: A patient presents with joint swelling, a pan systolic murmur, negative rheumatoid factor (RF), and elevated ESR. What is the most likely diagnosis? (Q844177)

A. Acute rheumatic fever

B. Seronegative rheumatoid arthritis (RA)

C. Juvenile spondyloarthropathy

D. Ankylosing spondylitis

Correct Answer: A. Acute rheumatic fever

Explanation: Correct Option A - Acute rheumatic fever: Acute Rheumatic Fever (ARF): ARF is an inflammatory disease that can develop after a Streptococcus pyogenes infection (such as strep throat). It commonly presents with migratory arthritis (joint swelling), carditis (which can present as a pan-systolic murmur), and other systemic symptoms. The elevated ESR indicates inflammation, and the negative rheumatoid factor helps distinguish it from rheumatoid arthritis. Joint Swelling and Murmur: The presence of joint swelling and a pan-systolic murmur (suggestive of mitral regurgitation due to carditis) is characteristic of ARF. The negative RF and elevated ESR further support this diagnosis. Incorrect Options: Option B - Seronegative rheumatoid arthritis (RA): Although RA

can present with joint swelling and an elevated ESR, a pan-systolic murmur is not typical of RA. Additionally, RA would usually involve symmetrical joint involvement and is less likely to cause heart murmurs. Option C - Juvenile spondyloarthropathy: This condition typically affects the spine and sacroiliac joints, not typically presenting with a pan-systolic murmur or significant joint swelling in the way described. Option D - Ankylosing spondylitis: Ankylosing spondylitis primarily affects the axial skeleton and does not usually present with joint swelling or a pan-systolic murmur.

↑ *Back to this question in Part A*

@Neet_pg_bot

Q32: A 35-year-old male has had chronic hypercalcemia for the last 1.5 years, but PTH levels are normal. Which of the following is most likely the cause? (Q866804)

A. Malignancy

B. Sarcoidosis

C. Parathyroid hyperplasia

D. C.K.D

Correct Answer: B. Sarcoidosis

Explanation: From the given history, the patient has chronic hypercalcemia but PTH is normal. This means the hypercalcemia is PTH-independent. Sarcoidosis, due to extra-renal production of calcitriol by activated macrophages, presents with hypercalcemia. Sarcoidosis: Multisystem granulomatous disease of unknown etiology, characterized by non-caseating granulomas. In sarcoidosis, activated macrophages inside the granulomas express 1-α-hydroxylase, converting 25-hydroxyvitamin D into 1,25-dihydroxyvitamin D (calcitriol). This leads to increased intestinal calcium absorption and persistent hypercalcemia. Because the calcium level is high, the parathyroid gland decreases PTH secretion, explaining the normal or low PTH levels in such cases. Feature Details Pathology Non-caseating granulomas in multiple organs Common Sites Lungs, lymph nodes, skin, eyes Lab Findings ↑ Serum ACE, ↑ calcium, normal/low PTH CXR Bilateral hilar lymphadenopathy Diagnosis Clinical + radiological + biopsy confirmation Treatment Glucocorticoids for symptomatic disease Incorrect Options: Malignancy (Option A) – Can cause hypercalcemia via PTHrP or bone metastasis, but presentation is usually acute and associated with systemic symptoms like weight loss; chronic stable picture is less likely. Parathyroid hyperplasia (Option C) – Would cause elevated PTH, not normal PTH. Chronic Kidney Disease (CKD) (Option D) – Causes hypocalcemia initially due to phosphate retention and decreased calcitriol synthesis; later may cause secondary/tertiary hyperparathyroidism with raised PTH, not normal.

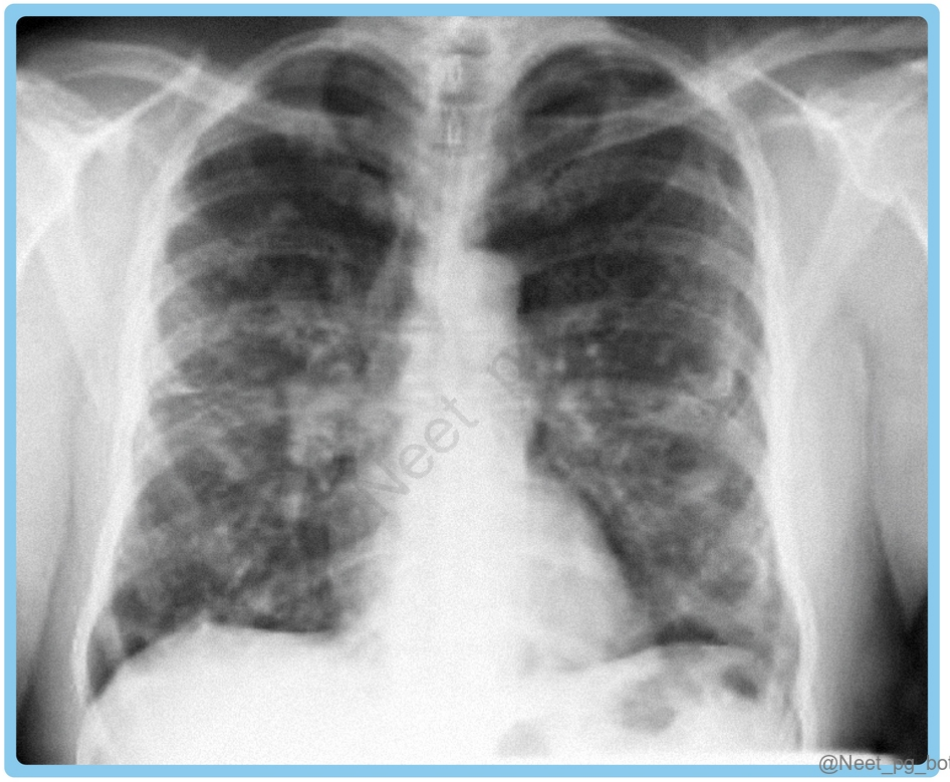

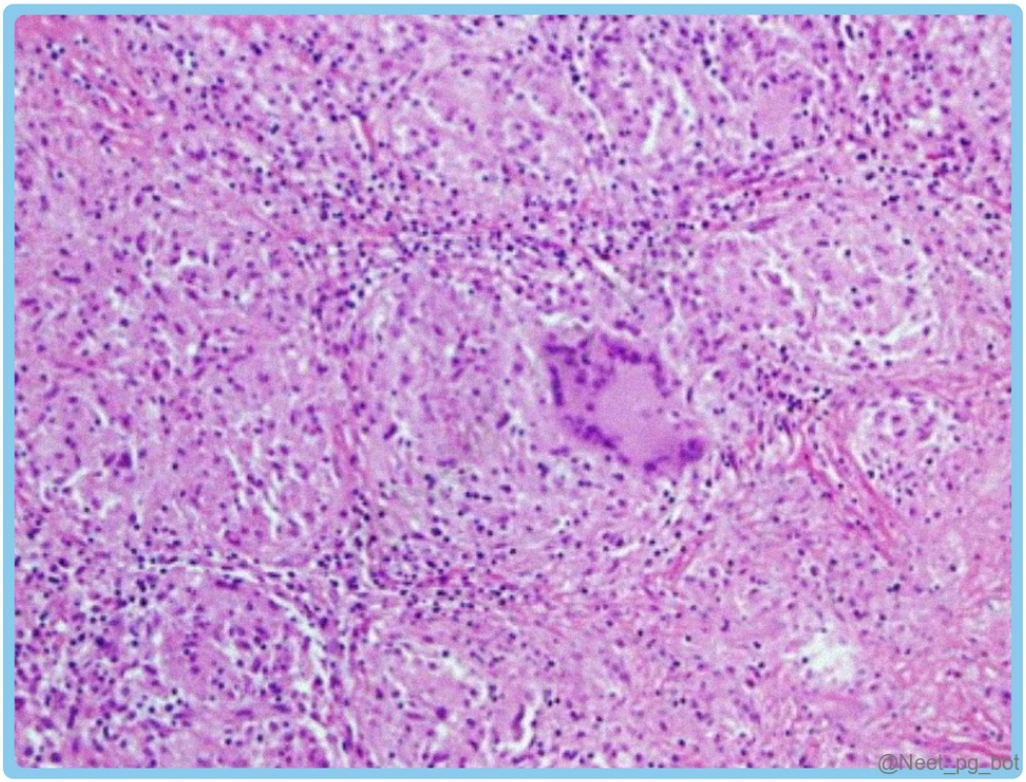

References:

.

↑ *Back to this question in Part A*

@Neet_pg_bot

Q33: Which of the following is not true about ankylosing spondylitis? (Q840125)

A. Affect males more than females

B. HLA B27 associated

C. Involvement of sacroiliac joints

D. Its non erosive and only joints are affected

Correct Answer: D. Its non erosive and only joints are affected

Explanation: Correct Option D - Its non erosive and only joints are affected: Ankylosing spondylitis involves erosive arthritis, where the vertebrae can be affected, leading to erosion at their margins. Also, it is the spine that is affected leading to the fusion of vertebrae and not the joints. Incorrect Options: Option A - Affect males more than females: Ankylosing spondylitis is more common in males than females contrary to rheumatoid arthritis. Option B - HLA B27 associated: 85-90% shows HLA positivity in ankylosing spondylitis Option C - Involvement of sacroiliac joints: The Sacroiliac joint is the first joint to be involved in ankylosing spondylitis

↑ *Back to this question in Part A*

@Neet_pg_bot

Q34: A 35-year-old woman experiences skin thickening, muscle weakness, and pale peripheries upon cold exposure. Her creatine kinase is increased with positive ANA, and biopsy revealed scl-70 positivity and perifascicular infiltration. What is the antibody linked to this condition? (Q857284)

A. Anti PM /Scl antibody

B. Anti Jo1 antibody

C. Anti centromere antibody

D. Antinuclear antibody

Correct Answer: A. Anti PM /Scl antibody

Explanation: is positive in many autoimmune disorders and already provided in the scenario.

References:

Harrison’s Principles of Internal Medicine, 21st Edition, Page: 2776, 2821, 2822.

Polymyositis: Causes, Symptoms, and Treatment

↑ *Back to this question in Part A*

@Neet_pg_bot

Q35: 40 year lady presents with difficulty in eating due to persistent dry mouth. She also has grittiness in eyes due to dry eyes. On examination, dental caries is noted with enlarged cervical lymph nodes. Possible diagnosis is: (Q820431)

A. MCTD

B. Sarcoidosis

C. Sjogren syndrome

D. Wegener’s granulomatosis

Correct Answer: C. Sjogren syndrome

Explanation: Correct Option C - Sjogren syndrome: Sjogren syndrome is an autoimmune disorder that primarily affects the salivary and lacrimal glands, leading to dry mouth (xerostomia) and dry eyes (keratoconjunctivitis sicca). Dental caries are common due to the lack of saliva's protective effects. Enlarged cervical lymph nodes can occur due to immune system activity. This syndrome often presents with these classic symptoms. Incorrect Options: Option A - MCTD (Mixed Connective Tissue Disease): MCTD is an autoimmune disorder that shares features of multiple other connective tissue diseases, such as systemic lupus erythematosus, scleroderma, and polymyositis. While dry mouth and dry eyes can occur in autoimmune disorders, the specific symptoms described (grittiness in eyes, dental caries, and enlarged cervical lymph nodes) are more characteristic of Sjogren syndrome. Option B - Sarcoidosis: Sarcoidosis is a disease characterized by the growth of tiny collections of inflammatory cells (granulomas) in different parts of the body. While it can affect various organs, including the lungs, skin, and eyes, the primary symptoms described (dry mouth, dry eyes, dental caries, and enlarged cervical lymph nodes) are not typically associated with sarcoidosis. Sarcoidosis would more likely involve lung issues and skin lesions. Option D - Wegener's Granulomatosis (Granulomatosis with Polyangiitis): Wegener's granulomatosis is a type of vasculitis that primarily affects the respiratory tract and kidneys. It usually presents with symptoms related to those organs, such as sinusitis, lung problems, and kidney dysfunction. The symptoms mentioned in the scenario (dry mouth, dry eyes, dental caries, and enlarged cervical lymph nodes) are not typical of Wegener's granulomatosis.

↑ *Back to this question in Part A*

@Neet_pg_bot

Q36: A 38-year-old male patient complains of paranasal sinus pain and bloody nasal discharge over the past few days. He has a history of previous hemoptysis and hematuria. Imaging studies reveal multiple bilateral nodular cavitary infiltrates. Which of the following antibodies is likely to be positive in this patient? (Q830817)

A. c-ANCA

B. ANA

C. Anti-histone antibodies

D. Anti-Jo 1 antibodies

Correct Answer: A. c-ANCA

Explanation: Correct Option A - c-ANCA: These antibodies are associated with granulomatosis with polyangiitis (Wegener's granulomatosis), a vasculitis that can involve multiple organs, including the respiratory tract (paranasal sinus involvement), lungs (nodular cavitary infiltrates), and kidneys (hematuria). Incorrect Options: Option B - ANA: ANA (antinuclear antibodies) is more commonly associated with systemic lupus erythematosus (SLE). Option C - Anti-histone antibodies: Anti-histone antibodies are associated with drug-induced lupus. Option D - Anti-Jo 1 antibodies: Anti-Jo 1 antibodies are associated with polymyositis and dermatomyositis.

↑ *Back to this question in Part A*

@Neet_pg_bot

Q37: A 40-year-old woman presents with bilateral symmetrical tenderness in the joints of her hands and wrists. She also complains of early morning stiffness of > 1 hour. On examination, no erythema or redness was found. What could be the diagnosis? (Q854728)

A. Osteoarthritis

B. Psoriatic Arthritis

C. Gout

D. Rheumatoid arthritis

Correct Answer: D. Rheumatoid arthritis

Explanation: The clinical presentation suggests Rheumatoid arthritis (RA) , which typically presents with symmetrical polyarthritis, primarily affects the small joints of the hands, particularly the metacarpophalangeal (MCP) and proximal interphalangeal (PIP) joints. Symmetrical joint involvement is a hallmark of RA,

distinguishing it from other forms of arthritis. Joint involvement in different types of arthritis: Characteristic Rheumatoid Arthritis (RA) Osteoarthritis (OA) (Option A) Psoriatic Arthritis (Option B) Gout (Option C) Reactive Arthritis Joint Involvement Pattern Symmetrical involvement of small joints (MCP, PIP) Asymmetrical involvement, especially DIP joints Asymmetrical involvement, often DIP joints Typically involves a single joint (e.g., big toe) Asymmetrical involvement, often larger joints Morning Stiffness Lasts over 1 hour Resolves within 30 minutes Varies, often significant Rarely significant Variable often follows infection Key Symptoms Swelling, tenderness, deformities (e.g., ulnar deviation) Pain and stiffness with use Dactylitis, nail changes Sudden, severe pain and swelling Joint pain following an infection Affected Joints MCP, PIP, wrists , knees Knees, hips, hands (DIP, PIP) MCP, PIP, and can include spine and tendons Typically big toe (1st MTP joint) Larger joints (e.g., knees, ankles) Radiographic Findings Soft tissue swelling, joint space narrowing Osteophytes, joint space narrowing Erosions, possible nail changes Erosions and tophi possible Similar to RA but typically larger joints

References:

Harrison’s Principles of Internal Medicine, 21st Edition, Page: 2751, 2754

Davidson’s Principles and Practice of Medicine, 24th Edition, Page: 1022

↑ *Back to this question in Part A*

@Neet_pg_bot

Q38: A young man came to the medical OPD with complaints of early morning backache and stiffness, which improves on exercise, and persistent red eyes. On examination, lung expansion was less than 3 cm. X-ray is shown in the image given below. What is the most probable diagnosis? (Q855417)

A. Ankylosing Spondylitis

B. Paget's Disease

C. Healed Tuberculosis

D. Osteopetrosis



Correct Answer: A. Ankylosing Spondylitis

Explanation: xtra-articular manifestations Inflammatory back pain : Gradual onset, worse with inactivity, improves with movement and is often associated with early morning stiffness. Fatigue : A common and significant symptom. Postural changes : Loss of lumbar lordosis, increased thoracic kyphosis, and forward stooping of the neck. Enthesitis : Inflammation at tendon or ligament attachment sites, often mistaken for fibromyalgia. Peripheral joint involvement : Affects large joints like hips, knees , and shoulders and is usually asymmetrical. Sacroiliac joint involvement : B/L and asymmetrical; pain may radiate to the buttocks or posterior thighs. Reduced spinal mobility: Limited movement in the lumbar region due to inflammation and pain, often accompanied by muscle spasms. Anterior uveitis: Most common extra articular manifestation. Presents with sudden unilateral eye pain, redness, and light sensitivity, often preceding joint symptoms. Anaemia, prostatitis, inflammatory bowel disease, aortic valve disease, and very rare cases of amyloidosis or upper lobe pulmonary fibrosis Osteoporosis : This can lead to vertebral fractures, especially with spinal fusion. Investigations of Ankylosing Spondylitis Tests X-rays MRI HLA-B27: The presence of the HLA-B27 gene is a strong indicator of AS. The prevalence of AS in the general population is less than 0.5%. Inflammatory Markers : Elevated ESR and CRP levels may indicate active disease. Faecal Calprotectin : Helps screen for associated inflammatory bowel disease. Show characteristic changes in sacroiliac joints , such as: Blurred cortical margins Erosions and sclerosis "Pseudowidening" of joint space (early stages) Joint space narrowing and fusion (later stages) Bamboo spine - Vertebral body fusion by syndesmophytes Dagger sign - Calcification appears as a single radiodense line vertically running down the spine on frontal radiographs. Investigation of choice – more sensitive than X-rays for detecting early inflammatory changes. Can reveal bone marrow oedema, enthesitis, synovitis, and erosions. {{caption_text}} Paget's Disease (Option B): Paget's disease involves abnormal bone remodeling, resulting in enlarged, weakened bones. X-rays typically show areas of osteolysis and cortical thickening, not fusion of the spine as seen in AS. Paget's disease also does not commonly cause back stiffness, lung expansion abnormalities, or persistent red eyes. Healed Tuberculosis (Option C): Healed tuberculosis of the spine (Pott’s disease) can cause back pain, deformity, and

stiffness due to vertebral destruction. However, it typically presents with visible vertebral collapse or destruction on X-ray rather than the bamboo spine seen in AS. Additionally, uveitis and lung expansion limitations are not characteristic features of healed TB. Osteopetrosis (Option D): Osteopetrosis is a genetic disorder resulting in excessively dense bones due to defective osteoclast function. It does not present with symptoms of back stiffness, red eyes, or lung expansion abnormalities. X-rays would typically show bones that are unusually dense, but there would be no evidence of vertebral fusion or characteristic spine changes as seen in AS.

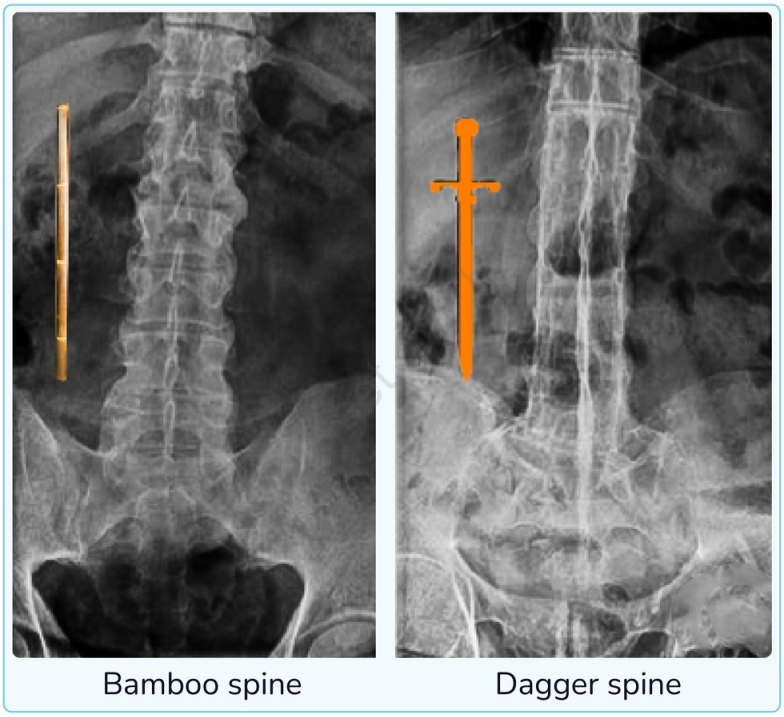

References:

Harrison's Principles of Internal Medicine, 21st Edition, Page: 2791-796. Apley's System of Orthopaedics and Fractures, 10th Edition, Page: 72-76. Davidson's Principles and Practice of Medicine, 24th Edition, Page: 988, 1028, 1030.

↑ *Back to this question in Part A*

@Neet_pg_bot

Q39: A 50-year-old woman presented with difficulty in activities like climbing stairs, getting up from a chair, and combing hair. Violaceous erythema of the upper eyelids was noted. What is the most probable diagnosis? (Q858036)

A. Inclusion body myositis

B. Dermatomyositis

C. Polymyositis

D. Scleroderma

Correct Answer: B. Dermatomyositis

Explanation: linical features It presents as symmetrical muscle weakness (proximal > distal) Gottron’s papules (erythematous scaly papules over knuckles) are pathognomonic of the disease. {{caption_text}} Gottron’s sign : Symmetric, confluent, violaceous macular erythema (CMVE) on the back of fingers, on the extensor surfaces of joints of the elbows, knees, or ankles CMVE is seen over other sites too, and is named accordingly. Heliotrope rash: CMVE over the periorbital skin {{caption_text}} V-Sign: CMVE over the anterior aspect of the neck {{caption_text}} Shawl sign: Involvement of upper back {{caption_text}} Holster sign: Rash over the lateral aspect of the thigh {{caption_text}} Mechanic’s hand: Hyperkeratosis and fissuring on the edges of the fingers {{caption_text}} Inclusion body myositis (Option A) primarily affects older people and typically presents with distal muscle weakness and asymmetric involvement. Unlike dermatomyositis, it does not have associated skin manifestations and tends to affect finger flexors and quadriceps preferentially. Polymyositis (Option C) is an autoimmune inflammatory muscle disease that presents with symmetric proximal muscle weakness. However, it lacks the characteristic skin manifestations seen in dermatomyositis, particularly the heliotrope rash and Gottron's papules. Scleroderma (Option D) is a connective tissue disorder primarily affecting the skin and internal organs. While it can cause muscle weakness, its hallmark features are skin thickening and fibrosis, not the violaceous rash characteristic of dermatomyositis. It also presents with Raynaud's phenomenon and internal organ involvement.




@Neet_pg_bot


@Neet_pg_bot


@Neet_pg_bot


@Neet_pg_bot



References:

Harrison's Principles of Internal Medicine, 21st Edition, Page 2820-2821

Rook’s Textbook of Dermatology. 9th Edition Page. 53.2-53.10

↑ *Back to this question in Part A*

@Neet_pg_bot

Q40: A 50-year-old woman presented with difficulty in activities like climbing stairs, getting up from a chair, and combing hair. Violaceous erythema of the upper eyelids was noted. What is the most probable diagnosis? (Q858351)

A. Inclusion body myositis

B. Dermatomyositis

C. Polymyositis

D. Scleroderma

Correct Answer: B. Dermatomyositis

Explanation: linical features It presents as symmetrical muscle weakness (proximal > distal) Gottron’s papules (erythematous scaly papules over knuckles) are pathognomonic of the disease. Gottron’s sign : Symmetric, confluent, violaceous macular erythema (CMVE) on the back of fingers, on the extensor surfaces of joints of the elbows, knees, or ankles CMVE is seen over other sites too, and is named accordingly. Heliotrope rash: CMVE over the periorbital skin V-Sign: CMVE over the anterior aspect of the neck Shawl sign: Involvement of upper back Holster sign: Rash over the lateral aspect of the thigh Mechanic’s hand: Hyperkeratosis and fissuring on the edges of the fingers Inclusion body myositis (Option A) primarily affects older people and typically presents with distal muscle weakness and asymmetric involvement. Unlike dermatomyositis, it does not have associated skin manifestations and tends to affect finger flexors and quadriceps preferentially. Polymyositis (Option C) is an autoimmune inflammatory muscle disease that presents with symmetric proximal muscle weakness. However, it lacks the characteristic skin manifestations seen in dermatomyositis, particularly the heliotrope rash and Gottron's papules. Scleroderma (Option D) is a connective tissue disorder primarily affecting the skin and internal organs. While it can cause muscle weakness, its hallmark features are skin thickening and fibrosis, not the violaceous rash characteristic of dermatomyositis. It also presents with Raynaud's phenomenon and internal organ involvement.






@Neet_pg_bot


@Neet_pg_bot





References:

Harrison's Principles of Internal Medicine, 21st Edition, Page 2820-2821

Rook’s Textbook of Dermatology. 9th Edition Page. 53.2-53.10

↑ *Back to this question in Part A*

@Neet_pg_bot

Q41: What is the most probable diagnosis for a young male patient who experiences drooping eyelids that worsens as the day progresses, along with increased fatigue towards the end of the day which improves with rest? Additionally, the patient notices a significant decrease in drooping when placing an ice pack over their eyes. (Q793852)

A. Myasthenia gravis

B. Huntington chorea

C. Amyotrophic lateral sclerosis

D. External ophthalmoplegia

Correct Answer: A. Myasthenia gravis

Explanation: Correct Option A - Myasthenia gravis: Myasthenia gravis is an autoimmune disorder that affects the neuromuscular junction, causing muscle weakness and fatigue. It is caused by antibodies that attack the acetylcholine receptors on the muscle, leading to a decrease in the number of available receptors and impaired nerve transmission. Ptosis, or drooping of the eyelid, is a common symptom. The ptosis tends to worsen through the day as more acetylcholine receptors are involved. Patients may also experience double vision, difficulty speaking or swallowing, and weakness in the limbs. Incorrect Options: Options B, C and D are incorrect.

References:

.

↑ *Back to this question in Part A*

@Neet_pg_bot

• [09_Hepatobiliary System] 067 Viral Hepatitis Nafld Ali

« Back to Folder Directory

[09_Hepatobiliary System] 067 Viral Hepatitis Nafld Ali — Quick Jump

Q1 (p. 2708)	*Q2 (p. 2708)*	*Q3 (p. 2709)*	*Q4 (p. 2710)*	*Q5 (p. 2711)*	*Q6 (p. 2711)*
Q7 (p. 2712)	*Q8 (p. 2713)*	*Q9 (p. 2713)*	*Q10 (p. 2714)*	*Q11 (p. 2715)*	*Q12 (p. 2716)*
Q13 (p. 2716)	*Q14 (p. 2717)*	*Q15 (p. 2718)*	*Q16 (p. 2718)*	*Q17 (p. 2719)*	*Q18 (p. 2720)*
Q19 (p. 2720)	*Q20 (p. 2721)*	*Q21 (p. 2722)*	*Q22 (p. 2722)*	*Q23 (p. 2723)*	*Q24 (p. 2724)*
Q25 (p. 2725)	*Q26 (p. 2725)*	*Q27 (p. 2726)*			

Q1: A 45-year-old patient presents with elevated liver enzymes and is suspected to have Hepatitis C. Which of the following statements regarding the investigations for Hepatitis C is correct? (Q851477)

A. Antibodies appear within 1-2 weeks.

B. Hepatitis C RNA confirms active infection.

C. Biopsy is essential for all diagnoses.

D. Genotype 1 has higher spontaneous clearance.

Correct Answer: B. Hepatitis C RNA confirms active infection.

Explanation: The presence of Hepatitis C RNA in an antibody-positive patient confirms an active infection. Anti-HCV antibodies appear 6–12 weeks after acute infection. (Option A ruled out) Serum transaminase levels do not reliably predict fibrosis, requiring liver biopsy for staging. (Option C ruled out) Genotype 1 (common in Northern Europe) was harder to treat with pegylated interferon/ribavirin than genotypes 2 and 3. (Option D ruled out) arkers are now preferred, with biopsy reserved for unclear cases.

References:

Davidson’s Principles and Practice of Medicine, 24th Edition, Page 877, 878.

↑ *Back to this question in Part A*

@Neet_pg_bot

Q2: Hepatitis C Virus is most commonly associated with which of the following? (Q851491)

A. SLE

B. Scleroderma

C. Cryoglobulinemia

D. Polyarteritis Nodosa

Correct Answer: C. Cryoglobulinemia

Explanation: Essential Mixed Cryoglobulinemia is characterized by arthritis, cutaneous vasculitis, occasionally glomerulonephritis and serologically by presence of circulating cryoprecipitate immune complexes. Extra Hepatic Associations of Hepatitis C: Mixed Cryoglobulinemia Autoimmune thyroiditis Membranoproliferative glomerulonephritis (MPGN) Sjogren's syndrome B cell non-hodgkins lymphoma Type 2 Diabetes mellitus Lichen planus Porphyria cutanea tarda

References:

Harrison's Principles of Internal Medicine, 21st Edition, Page 2570, 2578

https://pmc.ncbi.nlm.nih.gov/articles/PMC9657147/

https://pmc.ncbi.nlm.nih.gov/articles/PMC3754772/#:~:text=Clinical%20manifestations%20include%20fever%20

https://pmc.ncbi.nlm.nih.gov/articles/PMC6609844

↑ *Back to this question in Part A*

@Neet_pg_bot

Q3: Which of the following statements regarding Occult Hepatitis B Infection is false? (Q851490)

A. OBI can lead to hepatitis B transmission through blood products.

B. Individuals with seropositive OBI have detectable HBsAg in their serum

C. OBI may lead to reactivation of HBV in immunocompromised patients.

D. OBI can contribute to the development of HCC.

Correct Answer: B. Individuals with seropositive OBI have detectable HBsAg in their serum

Explanation: Occult Hepatitis B Infection (OBI) is defined as the presence of replication-competent HBV DNA in the liver of individuals who test negative for HBsAg, regardless of HBV DNA levels in the blood. Seropositive OBI : Presence of anti-HBc and/or anti-HBs antibodies. (Option B) Occur after the resolution of acute HBV or following chronic infection. Seronegative OBI : HBV DNA is the only detectable marker, either in the liver or

rarely in circulation. This type may occur from the beginning of the infection or due to the progressive loss of anti-HBV antibodies. Clinical significance of OBI: OBI can be transmitted via blood transfusion or organ transplantation. (Option A ruled out) It may lead to viral reactivation during immunosuppression. (Option C ruled out) It plays a significant role in the development of hepatocellular carcinoma. (Option D ruled out)

References:

https://pmc.ncbi.nlm.nih.gov/articles/PMC9318873/

↑ *Back to this question in Part A*

@Neet_pg_bot

Q4: A 45-year-old patient presents with gas gangrene and signs of acute liver injury. Which of the following management strategies is most appropriate for this patient? (Q851489)

A. Initiate antiviral therapy with acyclovir and provide supportive care.

B. Start high-dose intravenous penicillin and perform aggressive surgical débridement.

C. Administer a combination of ampicillin, gentamicin, and metronidazole.

D. Implement hyperbaric oxygen therapy and monitor for bleeding complications.

Correct Answer: B. Start high-dose intravenous penicillin and perform aggressive surgical débridement.

Explanation: Gas gangrene is primarily treated with high-dose intravenous penicillin to combat the Clostridium species causing the infection, alongside aggressive surgical débridement to remove necrotic tissue. This approach is crucial for controlling the infection and preventing further complications, making it the most appropriate management strategy in this scenario. Treatment Options for Acute Liver Injury: Condition/Treatment Details Antibiotics Gas Gangrene : High-dose intravenous penicillin, clindamycin; alternatives: cephalosporins, metronidazole Pyogenic Liver Abscess : Initial regimen of ampicillin, gentamicin, and metronidazole; aspiration or drainage for large/unresponsive abscesses (Option C ruled out) Surgical Débridement Recommended for gas gangrene alongside antibiotic therapy. Antiviral Therapy (Option A ruled out) Acyclovir for severe herpes simplex virus (HSV) infections; immediate treatment for HSV encephalopathy Foscarnet for acyclovir-resistant cases Other Treatments Hyperbaric oxygen for gas gangrene (efficacy debated) (Option D ruled out) Avoid aspirin in dengue fever due to bleeding risk

References:

Davidson’s Principles and Practice of Medicine, 24th Edition, Page 858, 859

↑ *Back to this question in Part A*

@Neet_pg_bot

Q5: A 45-year-old male presents to the emergency department with jaundice, fatigue, and right upper quadrant pain. He has a history of heavy alcohol use, and reports increased consumption over the past month. Laboratory tests show elevated aminotransferases and bilirubin levels. Which of the following investigations is most appropriate to determine the cause of his acute liver injury? (Q851488)

A. Liver Biopsy

B. Ultrasound of the abdomen

C. Toxicology Screen

D. Viral Hepatitis Serology

Correct Answer: D. Viral Hepatitis Serology

Explanation: Viral Hepatitis Serology is the most appropriate initial investigation to determine the cause of acute liver injury, as viral hepatitis is a common cause that needs to be ruled out in patients with jaundice and elevated liver enzymes. Ultrasound (Option B) : Non-invasive, detects fatty liver, cirrhosis, or tumours but has limitations in early disease. Liver Biopsy (Option A): Confirms diagnosis, identifies cause, and assesses liver damage. Toxicology Screen (Option C) can help identify drug-induced liver injury but may not be the most effective first step compared to assessing for viral hepatitis, especially considering the patient's alcohol use history.

References:

Davidson’s Principles and Practice of Medicine, 24th Edition, Page 858, 859

↑ *Back to this question in Part A*

@Neet_pg_bot

Q6: A 40-year-old woman presents to the emergency department with complaints of fatigue, nausea, and right upper quadrant discomfort. O/E, she appears mildly jaundiced with yellowing of the sclera. She is drowsy but can be easily aroused. Her family reports that she has been more irritable than usual, displaying some behavioural changes. She denies any recent travel or known infections but admits to consuming alcohol excessively over the past month. Which of the following signs or symptoms is most characteristic of the severity of her condition? (Q851487)

A. Elevated serum bilirubin levels

B. Normal liver function tests

C. Increased appetite

D. Significant weight loss

Correct Answer: A. Elevated serum bilirubin levels

Explanation: The clinical presentation is suggestive of acute liver injury , likely due to excessive alcohol consumption, resulting in jaundice and alterations in mental status. The combination of fatigue, irritability, and jaundice, alongside her alcohol history, points towards possible alcoholic hepatitis or acute liver failure. Elevated serum bilirubin levels are indicative of liver dysfunction, leading to jaundice and are characteristic of acute liver injury severity. Increased appetite (Option C) is not typically associated with liver injury and may actually decrease due to nausea and malaise. Significant weight loss (Option D) could occur in chronic conditions but is less specific for acute liver injury, where patients might experience nausea and decreased intake instead.

References:

Davidson’s Principles and Practice of Medicine, 24th Edition, Page 856, 857, 858

↑ *Back to this question in Part A*

@Neet_pg_bot

Q7: A 60-year-old male with a history of cirrhosis presents to the hospital with confusion and altered mental status. On examination, he is disoriented to time and space, exhibits lethargy, is somnolent but arousable, and displays bizarre behavior. According to the West Haven Criteria, what is the appropriate grade of his hepatic encephalopathy? (Q851486)

A. Grade 1

B. Grade 2

C. Grade 3

D. Grade 4

Correct Answer: C. Grade 3

Explanation: Grade III includes disorientation to both time and space, somnolence to semi-stupor, responsiveness to stimuli, confusion, and bizarre behavior. West Haven Grading of Hepatic Encephalopathy: West Haven Criteria Description Minimal Abnormal results of established psychometric or neuropsychological tests without clinical manifestations Grade I (Option A ruled out) Oriented in time and space Trivial lack of awareness Euphoria or anxiety Shortened attention span Impairment of addition or subtraction Grade II (Option B ruled out) Disorientation for time Lethargy or apathy Obvious personality change Inappropriate behavior Grade III (Option

C) Disoriented also for space Somnolence to semi-stupor Responsive to stimuli Confused Bizarre behavior Grade IV (Option D ruled out) Do not respond even to pain stimuli Coma

References:

Davidson's Principles and Practice of Medicine, 24th Edition, Page 864, 865

↑ *Back to this question in Part A*

@Neet_pg_bot

Q8: A 45-year-old male with a history of heavy alcohol consumption presents to the emergency department with fatigue, jaundice, and right upper quadrant abdominal pain. Laboratory tests reveal elevated direct bilirubin, alkaline phosphatase, and lactate dehydrogenase levels. His reticulocyte count is high, and the Coombs test is negative. The clinical features are consistent with Zieve syndrome. Which of the following is the most appropriate management for this patient? (Q851485)

A. Initiate corticosteroid therapy

B. Recommend immediate liver transplantation

C. Advise complete abstinence from alcohol

D. Start intravenous fluids and monitor in the hospital

Correct Answer: C. Advise complete abstinence from alcohol

Explanation: Complete abstinence from alcohol is the most appropriate treatment for Zieve syndrome, as it typically leads to the resolution of symptoms, including hemolytic anaemia and hyperlipidemia. Corticosteroid therapy (Option A) is not indicated, as Zieve syndrome is not an autoimmune condition. Liver transplantation (Option B) is unnecessary in this context; the syndrome is usually reversible with abstinence. Intravenous fluids and monitoring (Option D) may be supportive but do not address the underlying issue of alcohol consumption, which is central to the condition.

References:

https://pmc.ncbi.nlm.nih.gov/articles/PMC9465572/

↑ *Back to this question in Part A*

@Neet_pg_bot

Q9: A 48-year-old woman with a BMI of 32 kg/m² presents to the clinic with fatigue and mild abdominal discomfort. Laboratory tests reveal elevated liver transaminases, and an abdominal ultrasound shows hepatic steatosis. To further evaluate her condition, it is essential to exclude other potential causes of liver disease. Which of the following investigations should be performed first to rule out other liver diseases? (Q851484)

A. Liver biopsy

B. Blood tests for viral hepatitis markers

C. CT scan of the abdomen

D. NAFLD Fibrosis Score

Correct Answer: B. Blood tests for viral hepatitis markers

Explanation: Blood tests for viral hepatitis markers should be performed first to rule out viral hepatitis (such as Hepatitis B and C), as these are common causes of liver abnormalities and must be excluded before diagnosing NAFLD. Liver biopsy (Option A) is invasive and is not the first step; it is used later for definitive diagnosis and staging of liver disease. CT scan of the abdomen (Option C) may help identify liver abnormalities but is not the first-line investigation for excluding other liver diseases. NAFLD Fibrosis Score (Option D) is useful for assessing fibrosis but does not help in ruling out other liver diseases.

References:

Davidson's Principles and Practice of Medicine, 24th Edition, Page 884, 885

↑ *Back to this question in Part A*

@Neet_pg_bot

Q10: A 50-year-old male with a history of obesity and type 2 diabetes presents for a routine check-up. His liver function tests show mildly elevated transaminases, and an ultrasound of the abdomen reveals fatty infiltration of the liver. He denies any alcohol consumption. His BMI is 35 kg/m², and his blood pressure is 145/90 mmHg. Based on these findings, he is diagnosed with non-alcoholic fatty liver disease (NAFLD). Which of the following is the most likely initiating factor in the pathogenesis of NAFLD in this patient? (Q851483)

A. Hepatitis C infection

B. Alcohol consumption

C. Insulin resistance

D. Autoimmune hepatitis

Correct Answer: C. Insulin resistance

Explanation: Insulin resistance is a key initiating factor in the development of NAFLD, especially in individuals with metabolic syndrome, including obesity and type 2 diabetes. It leads to increased free fatty acid flow to the liver, resulting in fat accumulation (hepatic steatosis). Hepatitis C infection (Option A) and autoimmune hepatitis (Option D) are causes of liver disease but are not related to NAFLD. Alcohol consumption (Option B) is excluded by the patient's history, and NAFLD is by definition not related to alcohol use.

References:

Davidson’s Principles and Practice of Medicine, 24th Edition, Page 882, 883, 884

↑ *Back to this question in Part A*

@Neet_pg_bot

Q11: A 35-year-old male with chronic Hepatitis B presents with symptoms of fatigue, jaundice, and abdominal discomfort. Laboratory tests reveal elevated liver transaminases and the presence of Hepatitis D virus (HDV). His viral load is moderately elevated, and liver biopsy shows moderate fibrosis. The patient has no contraindications to antiviral therapy. Which of the following is the most appropriate treatment option for Hepatitis D in this patient? (Q851482)

A. Entecavir

B. Lamivudine

C. Pegylated Interferon-α

D. Hepatitis B Immunoglobulin

Correct Answer: C. Pegylated Interferon-α

Explanation: Pegylated Interferon-α is the preferred treatment for Hepatitis D, especially in patients with a low to moderate viral load and elevated transaminases. It works by enhancing the immune response against the virus. Entecavir (Option A) is a nucleoside analogue used to treat Hepatitis B, but it has limited efficacy against Hepatitis D. Lamivudine (Option B) is less commonly used due to resistance issues and is not the treatment of choice for Hepatitis D. Hepatitis B Immunoglobulin (Option D) is used for post-exposure prophylaxis but does not treat active HDV infection.

References:

Davidson’s Principles and Practice of Medicine, 24th Edition, Page 876, 877

↑ *Back to this question in Part A*

@Neet_pg_bot

Q12: A 45-year-old man with a history of chronic Hepatitis B virus (HBV) infection presents to the clinic with new-onset fatigue and abdominal discomfort. Laboratory tests reveal the presence of high titers of IgM antibodies against Hepatitis D virus (HDV). Based on the information provided, which of the following statements is true regarding the serological response to HDV infection in this patient? (Q851481)

A. The delta antigen is consistently present in the blood during the infection.

B. The presence of IgM anti-HDV indicates a simultaneous infection with HBV and HDV.

C. Anti-HDV antibodies are not necessary for diagnosing HDV infection.

D. The patient will develop IgG anti-HDV antibodies immediately after infection.

Correct Answer: B. The presence of IgM anti-HDV indicates a simultaneous infection with HBV and HDV.

Explanation: IgM anti-HDV reflects a recent HDV infection , which can occur only in the presence of HBV , as HDV requires HBsAg for replication. In a patient already infected with HBV, IgM anti-HDV typically indicates HDV co-infection (simultaneous acute HBV + HDV infection). Hepatitis D Antigens and Antibodies: The Hepatitis D virus (HDV) has one primary antigen known as delta antigen . Infection with HDV leads to the production of anti-HDV antibodies . Delta antigen is transiently present in the bloodstream; diagnosis relies on anti-HDV detection . (Options A & C ruled out)

References:

Davidson’s Principles and Practice of Medicine, 24th Edition, Page 877

↑ *Back to this question in Part A*

@Neet_pg_bot

Q13: A 35-year-old intravenous drug user presents to the clinic with fatigue and jaundice. Testing reveals infection with Hepatitis D virus (HDV). Which of the following statements about HDV transmission is true? (Q851480)

A. HDV is an independent RNA virus.

B. HDV is commonly transmitted via close personal contact in non-endemic regions.

C. Effective Hepatitis B vaccination indirectly prevents HDV infection.

D. Mother-to-child transmission is the primary route of HDV spread globally.

Correct Answer: C. Effective Hepatitis B vaccination indirectly prevents HDV infection.

Explanation: HDV relies on HBV for replication. Preventing HBV infection with vaccination also prevents HDV transmission. Hepatitis D Transmission: Dependent on Hepatitis B Virus (HBV) HDV is a defective RNA virus requiring HBV for replication. (Option A ruled out) Transmission of HDV occurs only in individuals infected with HBV. Transmission Routes of Hepatitis D: Route Details Blood Exposure through infected blood, especially via shared needles (e.g., injection drug use). Close personal contact Significant in endemic regions (Mediterranean basin, Africa, South America). (Option B ruled out) Vertical transmission Mother-to-child transmission is possible but less frequent. (Option D ruled out) Sexual transmission Possible in HBV-infected individuals due to shared transmission routes with HBV.

References:

Davidson's Principles and Practice of Medicine, 24th Edition, Page 877

↑ *Back to this question in Part A*

@Neet_pg_bot

Q14: A 50-year-old patient with Hepatitis C genotype 1 seeks treatment. Which statement about Hepatitis C therapy is correct? (Q851479)

A. Pre-2011 therapy achieved an SVR of 70% for genotype 1 after 6 months.

B. DAAs offer effective, well-tolerated interferon-free regimens.

C. Ribavirin is free of major side effects like anemia or teratogenicity.

D. Liver transplantation eliminates the risk of reinfection and cirrhosis in grafts.

Correct Answer: B. DAAs offer effective, well-tolerated interferon-free regimens.

Explanation: DAAs allow for interferon-free regimens, significantly improving treatment efficacy and tolerance. Treatment Options for Hepatitis C: Comparison Table Aspect Before 2011 Since 2011 Standard Treatment Pegylated interferon-alfa + Ribavirin Direct-Acting Antiviral Agents (DAAs) Efficacy (SVR) 40% for genotype 1 (12 months) (Option A ruled out) 70%+ for genotypes 2/3 (6 months) 99% for genotype 1 in 12 weeks Side Effects Interferon: flu-like symptoms, irritability, depression Ribavirin: hemolytic anemia, teratogenic (Option C ruled out) Generally well-tolerated, oral administration Reinfection Risk After Transplant (Option D ruled out) Up to 15% may develop cirrhosis in graft within 5 years Post-transplant DAAs reduce reinfection risk

References:

Davidson’s Principles and Practice of Medicine, 24th Edition, Page 877, 878.

↑ *Back to this question in Part A*

@Neet_pg_bot

Q15: A 32-year-old man presents with fatigue and mild abdominal discomfort. He reports that he recently experienced nausea and dark urine. Laboratory tests reveal elevated liver enzymes. Which of the following is the most likely finding in this patient’s blood tests? (Q851448)

A. Positive HBsAg

B. Positive anti-HBs

C. Negative HBsAg

D. Positive IgG anti-HBc

Correct Answer: A. Positive HBsAg

Explanation: HBsAg (Hepatitis B surface antigen) is the most reliable marker for an active Hepatitis B virus infection. In this case, the patient's symptoms—fatigue, mild abdominal discomfort, nausea, dark urine, and elevated liver enzymes—strongly suggest an ongoing infection. HBsAg typically appears 2-6 weeks before the onset of jaundice, aligning with the timeline of symptoms.

References:

Davidson’s Principles and Practice of Medicine, 24th Edition, Page 873-875

↑ *Back to this question in Part A*

@Neet_pg_bot

Q16: A 30-year-old male presents to the outpatient clinic for routine screening. He admits to a history of injection drug use. Which of the following is the most likely mode of Hepatitis C transmission in this patient? (Q851476)

A. Sexual contact

B. Vertical transmission from mother to child

C. Sharing needles and injecting equipment

D. Blood transfusion with screened blood products

Correct Answer: C. Sharing needles and injecting equipment

Explanation: Injection drug use and sharing of needles are the primary modes of Hepatitis C transmission. Mode of Transmission Details Blood transfusions (historical) (Option D ruled out) Unscreened blood products (pre-screening era) Vertical transmission (Option B ruled out) From mother to child Sexual transmission (Option A ruled out) Less common Needlestick injuries Healthcare-related exposure Sharing personal items Razors, toothbrushes (contact with blood)

References:

Davidson's Principles and Practice of Medicine, 24th Edition, Page 877, 878.

↑ *Back to this question in Part A*

@Neet_pg_bot

Q17: A 35-year-old male presents with symptoms of nausea, jaundice, and abdominal pain after returning from a trip to a region with poor sanitation. He has no significant medical history. His liver function tests show elevated bilirubin, ALT, and AST levels. HEV IgM antibodies are positive. What is the most appropriate treatment plan for this patient? (Q851475)

A. Ribavirin therapy

B. Peginterferon

C. Supportive care with hydration and rest

D. Both A and C

Correct Answer: C. Supportive care with hydration and rest

Explanation: Based on the clinical manifestation and laboratory results, the most probable diagnosis is acute hepatitis E virus infection. In immunocompetent patients, Hepatitis E is typically a self-limiting disease, and supportive care is the standard treatment. In immunocompromised and chronic HEV infection: anti-viral drugs (Options A & B ruled out) Ribavirin Peginterferon

References:

Harrison's Principle of Internal Medicine, 21st Edition, Page 2568,2569, 2570, 2571

Hepatitis A - StatPearls - NCBI Bookshelf

↑ *Back to this question in Part A*

@Neet_pg_bot

Q18: A 40-year-old male presents with nausea, fatigue, and mild abdominal pain for the past week. He recently returned from a camping trip in a developing country. On examination, he has mild jaundice and tender hepatomegaly. His lab tests show elevated liver enzymes (ALT, AST), and positive anti-HAV IgM antibodies. What is the most likely mode of transmission for his condition? (Q851474)

A. Sharing needles

B. Fecal-oral route

C. Sexual contact

D. Respiratory droplets

Correct Answer: B. Fecal-oral route

Explanation: Based on the clinical manifestation, the most probable diagnosis is hepatitis A virus infection. It is primarily transmitted via the fecal-oral route, which is common in areas with poor sanitation, making it the most likely mode of transmission in this case. Hepatitis A Pathogenesis: HAV is typically acquired through ingestion (through fecal-oral transmission) and replicates in the liver. After 10 to 12 days, virus is present in blood and is excreted via the biliary system into the feces. Peak titers occur during the 2 weeks before onset of illness. Although virus is present in serum, its concentration is several orders of magnitude less than in feces. Virus excretion begins to decline at the onset of clinical illness and decreases significantly by 7 to 10 days after onset of symptoms. Most infected persons no longer excrete virus in the feces by the third week of illness.

References:

Harrison’s Principle of Internal Medicine, 21st Edition, Page 2562, 2563, 2569, 2570, 2571

https://www.ncbi.nlm.nih.gov/books/NBK459290/

https://www.cdc.gov/pinkbook/hcp/table-of-contents/chapter-9-hepatitis-a.html#cdc_report_pub_study_section_3-pathogenesis

↑ *Back to this question in Part A*

@Neet_pg_bot

Q19: A newborn infant is delivered to an HBsAg-positive mother. What is the most appropriate post-exposure prophylaxis for this infant? (Q851473)

A. Hepatitis B vaccine only

B. Hepatitis B Immune Globulin (HBIG) only

C. HBIG and Hepatitis B vaccine

D. No intervention is necessary

Correct Answer: C. HBIG and Hepatitis B vaccine

Explanation: Infants born to HBsAg-positive mothers should receive both HBIG and the Hepatitis B vaccine within 12 hours of birth to prevent infection. Hepatitis B virus vaccination Post-exposure prophylaxis: HBIG (Hepatitis B Immune Globulin) + Hepatitis B vaccine Indications: Perinatal exposure - infants of HBsAg-positive mothers (Option C) Percutaneous or transmucosal exposure - needle stick, mucosal penetration Sexual contact exposure Note: HBIG and vaccine: Can be administered at the same time but at separate injection sites.

References:

Harrison's Principle of Internal Medicine, 21st Edition, Page 2582

↑ *Back to this question in Part A*

@Neet_pg_bot

Q20: A 38-year-old female with a 5-year history of chronic Hepatitis B presents for evaluation. Her most recent lab results show HBsAg positive, HBeAg positive, ALT at 200 IU/L, and total bilirubin at 1.2 mg/dL. She is experiencing fatigue and mild abdominal discomfort. She has a history of taking herbal supplements for liver health and consumes alcohol occasionally. Which of the following is not an appropriate treatment plan for this patient? (Q851472)

A. Start tenofovir or entecavirir

B. Consider lamivudine as a second-line treatment

C. Stop alcohol completely

D. Continue herbal supplements for liver support

Correct Answer: D. Continue herbal supplements for liver support

Explanation: Continuing herbal supplements for liver support is not appropriate, especially in patients with chronic liver disease, as these supplements can potentially be hepatotoxic or interact with antiviral therapies. Chronic Hepatitis B treatment: First-line: entecavir, tenofovir (Option A ruled out) Second-line: lamivudine, adefovir, telbivudine (Option B ruled out) Duration of therapy 48 to 52 weeks Lifestyle modifications include reducing the intake of agents with the potential for liver damage such as alcohol (Option C ruled out) , hepatotoxic medications,

herbal medications, and herbal supplements (Option D)

References:

Harrison’s Principle of Internal Medicine, 21st Edition, Page 2592, 2595

Hepatitis B - StatPearls - NCBI Bookshelf

↑ *Back to this question in Part A*

@Neet_pg_bot

Q21: A 50-year-old male presents to the emergency department with acute jaundice, fever, fatigue, and right upper quadrant pain. He has a history of heavy alcohol use. On examination, he has icterus of the sclera and tenderness in the right upper. His laboratory results are as follows: HBsAg: Positive HBeAg: Positive ALT: 150 IU/L AST: 120 IU/L Total Bilirubin: 3.0 mg/dL Alkaline Phosphatase: 100 IU/L Which management strategy is most appropriate? (Q851469)

A. Start entecavir therapy immediately

B. Begin tenofovir therapy immediately

C. Supportive care and stop alcohol

D. Both A and C

Correct Answer: C. Supportive care and stop alcohol

Explanation: The patient's clinical manifestation and elevated ALT and AST levels, along with the positive HBsAg and HBeAg, indicate an acute Hepatitis B infection. The ALT and AST levels are elevated but not excessively high, and total bilirubin is moderately elevated. In this scenario of mild to moderate acute Hepatitis B, supportive care with fluids and rest combined with advice to stop alcohol consumption is the most appropriate step in management. Antiviral therapy is recommended for severe acute hepatitis B (Option A & B ruled out)

References:

Harrison’s Principle of Internal Medicine, 21st Edition, Page 2579

www.ncbi.nlm.nih.gov/books/NBK555945/

↑ *Back to this question in Part A*

@Neet_pg_bot

Q22: A 45-year-old male with acute Hepatitis B presents with the following lab results: ALT 4100 IU/L AST 3900 IU/L Total bilirubin 60 μmol/L (3.5 mg/dL) Despite the very high aminotransferase levels, his bilirubin remains moderately elevated. What does this suggest about the severity of liver cell damage? (Q851466)

A. Severe liver cell damage causing acute liver failure

B. The severity of damage cannot be determined from ALT levels alone

C. Mild liver cell damage causing fulminant hepatitis

D. Transition to chronic Hepatitis B with moderate liver damage

Correct Answer: B. The severity of damage cannot be determined from ALT levels alone

Explanation: ALT/AST levels do not correlate directly with the extent of liver cell damage in Hepatitis B. While ALT and AST levels are very high, bilirubin remains moderately elevated, indicating that although hepatocyte damage is ongoing, the liver is still functioning well enough to manage bilirubin clearance. Severe liver cell damage causing acute liver failure (Option A): In acute liver failure, there is significant impairment in liver function, leading to much higher bilirubin levels in serum. Mild liver cell damage causing fulminant hepatitis (Option C): Fulminant hepatitis is characterised by massive liver damage and severe impairment of liver function, which would lead to very high bilirubin levels and signs of liver failure (e.g., coagulopathy, encephalopathy). Transition to chronic Hepatitis B with moderate liver damage (Option D): It is often associated with fluctuating or mildly elevated ALT/AST levels rather than the acute, severe spike seen here.

References:

Harrison’s Principle of Internal Medicine, 21st Edition, Page 2575

↑ *Back to this question in Part A*

@Neet_pg_bot

Q23: A 30-year-old male presents to the clinic for routine screening. He reports no recent illness but has a history of multiple sexual partners. He is concerned about Hepatitis B infection due to a friend’s recent diagnosis. Laboratory tests are conducted to assess his Hepatitis B status. Test Result HBsAg Negative Anti-HBs Positive HBeAg Negative Anti-HBe Negative Anti-HBc Negative What does this lab profile indicate about the patient’s Hepatitis B status? (Q851464)

A. Has an active acute Hepatitis B infection.

B. Has recovered from a previous Hepatitis B infection.

C. Is a healthy carrier of Hepatitis B.

D. Has been immunized against Hepatitis B.

Correct Answer: D. Has been immunized against Hepatitis B.

Explanation: The presence of positive anti-HBs and negative HBsAg, HBeAg, and anti-HBc indicates that the patient has been successfully immunized against Hepatitis B, with no evidence of current or past infection. Phase/Condition HBsAg Anti-HBs HBeAg Anti-HBe Anti-HBc Acute HBV (Option A) + Nil + Nil IgM Chronic HBV/Healthy carrier (Low infectivity) (Option C) + Nil Nil + IgG Recovery (Option B) Nil + Nil + IgG Immunized Nil + Nil Nil Nil

References:

https://www.researchgate.net/publication/354997816_Hepatitis_B_Vaccines

↑ *Back to this question in Part A*

@Neet_pg_bot

Q24: A public health nurse is conducting an educational session on Hepatitis B transmission in a community with a high prevalence of the virus. During the session, she discusses various transmission routes and their associated risks for chronic infection. Which of the following statements about Hepatitis B transmission is incorrect? (Q851462)

A. Vertical transmission occurs from an HBsAg-positive mother to her infant.

B. Risk of chronic infection is higher in individuals infected at a younger age.

C. Sharing needles among drug users is a common mode of transmission.

D. Chronic infection is primarily associated with sexual transmission in adults.

Correct Answer: D. Chronic infection is primarily associated with sexual transmission in adults.

Explanation: Chronic Hepatitis B infection is primarily associated with perinatal transmission and infections acquired at a younger age, rather than sexual transmission in adults. Transmission Type Details Horizontal Transmission Injection drug use/Needle stick injury (most common) (Option C) Infected unscreened blood products Tattoos/acupuncture needles Sexual transmission Close living quarters/playground play Especially in toddlers Higher rates in Africa) Vertical Transmission HBsAg-positive mother (Option A) Risk of chronic infection is higher in individuals infected at a younger age (Option B) is correct because infants and young children are particularly vulnerable due to their immature immune response.

References:

Davidson’s Principles and Practice of Medicine, 24th Edition, Page 873

↑ *Back to this question in Part A*

@Neet_pg_bot

Q25: A 26-year-old man presents with complaints of fatigue, loss of appetite, and mild abdominal discomfort. His partner recently tested positive for Hepatitis B. Laboratory tests reveal mildly elevated liver enzymes. Which of the following findings would you least likely find in this patient? (Q851460)

A. Mild splenomegaly

B. Cervical lymphadenopathy

C. Tender liver

D. Caput medusae

Correct Answer: D. Caput medusae

Explanation: In this case, the patient presents with symptoms consistent with acute Hepatitis B, including fatigue, loss of appetite, and mild abdominal discomfort. Caput medusae , which refers to the appearance of engorged superficial epigastric veins, is typically associated with chronic liver disease and portal hypertension rather than acute Hepatitis B. Physical signs of acute Hepatitis B Few physical signs The liver may be tender and minimally enlarged (Option C) Occasional mild splenomegaly and cervical lymphadenopathy (Option A, B) more common in children or with EBV infection.

References:

Davidson’s Principles and Practice of Medicine, 24th Edition, Page 871-872

↑ *Back to this question in Part A*

@Neet_pg_bot

Q26: A 30-year-old man presents to the clinic for evaluation of elevated liver enzymes. He reports feeling fatigued and has noticed some jaundice. His medical history is significant for recent unprotected sexual contact with a partner who is Hepatitis B positive. Laboratory tests reveal that HBsAg is positive, and further testing shows the presence of HBeAg. Which of the following does the presence of HBeAg indicate in this patient? (Q851457)

A. Low viral replication and reduced infectivity

B. Active viral replication and high infectivity

C. Recovery from a previous Hepatitis B infection

D. Chronic infection with no active viral replication

Correct Answer: B. Active viral replication and high infectivity

Explanation: HBeAg is a marker that appears shortly after HBsAg and is secreted by infected hepatocytes, reflecting the level of viral activity in the body. Its presence is associated with a higher rate of viral replication, indicating that the patient is more infectious and potentially at greater risk for complications. Recovery from a previous Hepatitis B infection (Option C): Recovery is indicated by anti-HBs and absence of HBsAg/HBeAg . Chronic infection with no active viral replication (Option D): This would show HBsAg positive and HBeAg negative (with or without anti-HBe), indicating a low replicative phase.

References:

Davidson's Principles and Practice of Medicine, 24th Edition, Page 873-875

↑ *Back to this question in Part A*

@Neet_pg_bot

Q27: A 28-year-old woman presents to the clinic with fatigue, loss of appetite, and mild jaundice. She reports that she had a recent exposure to a friend who was diagnosed with Hepatitis B. Laboratory tests reveal that HBsAg is negative, but her liver enzymes are elevated. Which of the following is the most likely finding in this patient's blood tests? (Q851455)

A. Positive anti-HBs only

B. Positive IgM anti-HBc

C. Positive IgG anti-HBc

D. Positive HBcAg

Correct Answer: B. Positive IgM anti-HBc

Explanation: This patient has symptoms of acute Hepatitis B (fatigue, anorexia, jaundice) following recent exposure . Although HBsAg is negative , this can occur during the window period , when both HBsAg and anti-HBs are undetectable. During this period, the only positive marker is IgM anti-HBc , which is the most reliable indicator of a recent HBV infection . It confirms early acute Hepatitis B even when other markers are not

yet detectable. Positive anti-HBs only (Option A): Indicates recovery or vaccination , not an acute infection; cannot appear during symptoms or the window period. Positive IgG anti-HBc (Option B): Indicates a past, resolved infection or chronic infection; not a marker of recent exposure. Positive HBcAg (Option D): The core antigen is intracellular and never detected in serum ; only antibodies to it (IgM/IgG anti-HBc) are measurable.

References:

Davidson’s Principles and Practice of Medicine, 24th Edition, Page 873-875

↑ *Back to this question in Part A*

@Neet_pg_bot

• [09_Hepatobiliary System] 068 Hepatorenal And Hepatopulmonary Syndrome And Alcoholic Hepatitits

« Back to Folder Directory

[09_Hepatobiliary System] 068 Hepatorenal And Hepatopulmonary Syndrome And Alcoholic Hepatitits — Quick Jump

Q1 (p. 2728)	*Q2 (p. 2729)*	*Q3 (p. 2729)*	*Q4 (p. 2730)*	*Q5 (p. 2730)*	*Q6 (p. 2731)*
Q7 (p. 2732)	*Q8 (p. 2733)*	*Q9 (p. 2733)*	*Q10 (p. 2734)*	*Q11 (p. 2737)*	*Q12 (p. 2739)*
Q13 (p. 2739)	*Q14 (p. 2742)*	*Q15 (p. 2742)*	*Q16 (p. 2743)*		

Q1: Give the correct sequencing of the pathophysiology of hepatorenal syndrome. Renal vasoconstriction Systemic vasodilation Vasopressin release Cytokine release (Q851281)

A. 1,2,3,4

B. 4,3,2,1

C. 4,2,3,1

D. 3,4,2,1

Correct Answer: C. 4,2,3,1

Explanation: Hepatorenal syndrome Definition Acute kidney injury in advanced liver disease Pathophysiology

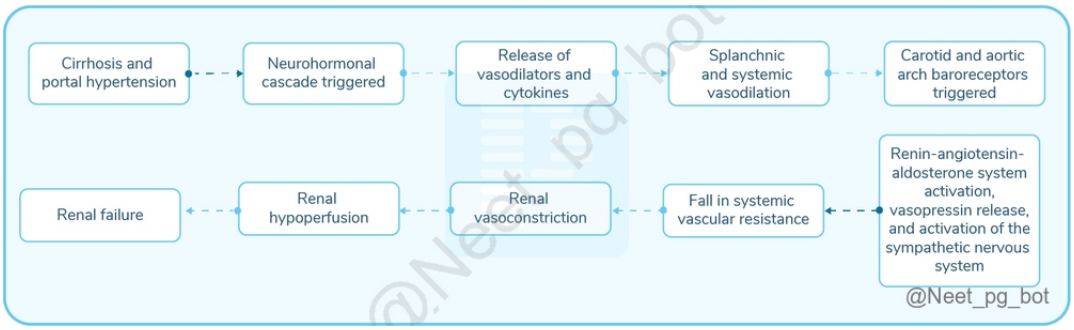

References:

https://www.ncbi.nlm.nih.gov/books/NBK430856/

↑ *Back to this question in Part A*

@Neet_pg_bot

Q2: Which of the following is not a feature of hepatorenal syndrome? (Q851282)

A. Stepwise decrease in serum creatinine

B. Jaundice which begins in the sclera

C. Altered mental status

D. Increased risk of bleeding

Correct Answer: A. Stepwise decrease in serum creatinine

Explanation: Hepatorenal syndrome is characterized by a progressive increase in creatinine. Clinical features of Hepatorenal syndrome: Jaundice Begins in the sclera and progresses from head-to-toe. (Option B ruled out) Coagulopathy Impaired liver synthetic function, increasing the risk of bleeding. (Option D ruled out) Hepatic encephalopathy Confusion and altered mental status (Option C ruled out) as the liver fails to metabolize toxins. Creatinine Stepwise progressive increase in creatinine (Option A)

References:

https://www.ncbi.nlm.nih.gov/books/NBK430856/

Harrison’s Principles of Internal Medicine, 21st Edition , Page 2632

↑ *Back to this question in Part A*

@Neet_pg_bot

Q3: A 56-year-old man with a history of cirrhosis due to chronic hepatitis C presents with worsening ascites, oliguria, and fatigue. Physical examination reveals tense ascites, mild jaundice, and peripheral edema. Laboratory investigations show: Serum creatinine: 2.3 mg/dL (baseline: 0.9 mg/dL) Serum sodium: 126 mEq/L Urine sodium: <10 mEq/L Albumin infusion is planned as part of his management. What is the recommended dosage of albumin infusion for this patient? (Q851283)

A. 1g/kg per day

B. 5g/kg per day

C. 2g/kg per day

D. 3g/kg per day

Correct Answer: A. 1g/kg per day

Explanation: The patient likely has Hepatorenal Syndrome (HRS), a complication of advanced liver disease characterized by renal dysfunction due to splanchnic vasodilation and reduced renal perfusion. HRS is diagnosed based on clinical features, including worsening renal function, low urine sodium (<10 mEq/L), and exclusion of other causes of acute kidney injury (e.g., hypovolemia, nephrotoxicity). The recommended dosage of albumin infusion in HRS is 1 g/kg per day, up to a maximum of 100 g/day, to expand intravascular volume and improve renal perfusion. Treatment is with vasoconstrictors such as terlipressin or, if not available, low-dose norepinephrine, which requires intensive care unit monitoring. Higher doses (e.g., 2-5 g/kg/day) are avoided due to risks such as pulmonary edema.

References:

Harrison's Principles of Internal Medicine, 21st edition, Page 2632

↑ *Back to this question in Part A*

@Neet_pg_bot

Q4: Which of the following is not a characteristic feature of Type 1 hepatorenal syndrome? (Q851284)

A. Doubling of serum creatinine over 2 weeks

B. Urine output less than 500mL/day

C. Normal urine sediment

D. High urinary sodium

Correct Answer: D. High urinary sodium

Explanation: In Type 1 HRS, urinary sodium excretion is low. Types of Hepatorenal syndrome (HRS) : Type 1 HRS Doubling of the serum creatinine to at least greater than 2.5 or a decrease in the creatinine clearance by half or more over a two-week period. (Option A ruled out) Urine output of less than 500mL/day (Option B ruled out) Normal urine sediment (Option C ruled out) Low urinary sodium excretion (Option D)

References:

https://www.ncbi.nlm.nih.gov/books/NBK430856/

↑ *Back to this question in Part A*

@Neet_pg_bot

Q5: A 52-year-old male with a long history of cirrhosis presents to the clinic with worsening shortness of breath over the past few months. He reports that his breathlessness worsens when standing and improves when lying down. Physical examination reveals spider angiomas. Pulse oximetry shows an oxygen saturation of 85% on room air. A contrast-enhanced echocardiogram (bubble study) is performed, and delayed bubbles are seen in the left atrium. What is the most likely diagnosis? (Q851285)

A. Hepatopulmonary syndrome

B. Atelectasis

C. Chronic obstructive pulmonary disease (COPD)

D. Recurrent pulmonary emboli

Correct Answer: A. Hepatopulmonary syndrome

Explanation: The patient's history of chronic liver disease(cirrhosis), positional dyspnea (platypnea-orthodeoxia), the presence of spider angiomas, and hypoxemia are classic findings in hepatopulmonary syndrome (HPS). Hepatopulmonary Syndrome (HPS): It is defined as reduced arterial oxygen saturation due to dilated pulmonary vasculature in the presence of advanced liver disease or portal hypertension. Atelectasis (Option B): Presents with localized lung findings such as decreased breath sounds, dullness to percussion and potentially an opaque area on a chest X-ray. There is no positional dyspnea or bubble study findings associated with atelectasis. Chronic obstructive pulmonary disease (COPD) (Option C): Present with a history of smoking, chronic cough, and progressive shortness of breath without the positional changes described in this patient. The bubble study result is inconsistent with COPD. Recurrent pulmonary emboli (Option D): Present with sudden-onset shortness of breath, pleuritic chest pain and sometimes hemoptysis. A bubble study would not show the delayed appearance of bubbles in the left atrium seen in HPS.

References:

www.ncbi.nlm.nih.gov/books/NBK562169/

↑ *Back to this question in Part A*

@Neet_pg_bot

Q6: Which of the following conditions causes intrapulmonary shunting? (Q851286)

A. Hepatopulmonary syndrome (HPS)

B. Portopulmonary hypertension

C. Recurrent pulmonary emboli

D. Pneumonia

Correct Answer: A. Hepatopulmonary syndrome (HPS)

Explanation: HPS leads to intrapulmonary shunting due to intrapulmonary vascular dilations, where blood bypasses the alveoli, resulting in poor oxygen exchange and hypoxemia. Hepatopulmonary Syndrome (HPS): It is defined as reduced arterial oxygen saturation due to dilated pulmonary vasculature in the presence of advanced liver disease or portal hypertension. Portopulmonary hypertension (Option B): Causes elevated pulmonary artery pressures but does not result in intrapulmonary shunting. The pathology is related to increased vascular resistance, not shunting. Recurrent pulmonary emboli (Option C): Causes vascular obstruction, leading to ventilation-perfusion mismatch (dead space), not intrapulmonary shunting. Pneumonia (Option D): Can cause impaired gas exchange and fluid accumulation in alveoli, but this results in ventilation-perfusion mismatch, not the intrapulmonary shunting seen in HPS.

References:

www.ncbi.nlm.nih.gov/books/NBK562169/

↑ *Back to this question in Part A*

@Neet_pg_bot

Q7: A 45-year-old male with a history of cirrhosis presents with worsening dyspnea.Physical examination reveals clubbing and cyanosis, which worsen when the patient sits upright and decrease in oxygen saturation when the patient changes position from supine to upright.Which of the following is considered the gold standard diagnostic method for confirming this condition? (Q851287)

A. Pulmonary angiography

B. Transesophageal echocardiogram (TEE)

C. Radioactive lung perfusion scan

D. Bubble contrast echocardiography

Correct Answer: D. Bubble contrast echocardiography

Explanation: Bubble contrast echocardiography is the gold standard diagnostic test for hepatopulmonary syndrome (HPS). Hepatopulmonary Syndrome (HPS): It is defined as reduced arterial oxygen saturation due to dilated pulmonary vasculature in the presence of advanced liver disease or portal hypertension. Pulmonary Angiography (Option A): Visualizes lung blood vessels; not specific for HPS. Transesophageal Echocardiogram (TEE) (Option B): Evaluates heart structures; may miss pulmonary vascular changes. Radioactive Lung Perfusion Scan (Option C): Assesses lung blood flow; does not identify intrapulmonary shunts.

References:

www.ncbi.nlm.nih.gov/books/NBK562169/

↑ *Back to this question in Part A*

@Neet_pg_bot

Q8: Which of the following laboratory findings does not typically indicate alcoholic hepatitis? (Q851288)

A. Serum bilirubin more than 3 mg/dL

B. Elevated aspartate aminotransferase (AST) to 50 U/L - 400 U/L

C. AST:ALT (alanine aminotransferase) ratio of more than 1.5

D. Absolute value of AST/ALT greater than 600 U/L

Correct Answer: D. Absolute value of AST/ALT greater than 600 U/L

Explanation: An AST/ALT level greater than 600 U/L is typically more indicative of acute liver failure or other severe liver conditions, rather than alcoholic hepatitis alone. The National Institute on Alcohol Abuse and Alcoholism (NIAAA) defines alcoholic hepatitis to include the following: The onset of jaundice within 60 days of heavy alcohol consumption Serum bilirubin more than 3 mg/dL (Option A ruled out) Elevated aspartate aminotransferase (AST) to 50 U/L - 400 U/L (Option B ruled out) AST:ALT (alanine aminotransferase) ratio of more than 1.5 (Option C ruled out) Absolute value of AST/ALT typically never exceeding 500 U/L. (Option D)

References:

http://www.ncbi.nlm.nih.gov/books/NBK470217

↑ *Back to this question in Part A*

@Neet_pg_bot

Q9: What amount of alcohol consumption is generally considered to significantly increase the risk of developing alcoholic hepatitis? (Q851289)

A. More than 10 grams per day

B. More than 20 grams per day

C. More than 30 grams per day

D. More than 50 grams per day

Correct Answer: D. More than 50 grams per day

Explanation: Patients with alcohol- associated hepatitis have been drinking heavily (>40 g/d for women and >50–60 g/d for men) for >6 months with <60 days of abstinence before onset of symptoms. They present with rapid onset of jaundice (serum bilirubin >3 mg/dL), often accompanied by fever, malaise, tender hepa- tomegaly, and clinical signs of hepatic decompensation, such as ascites, bacterial infection, variceal bleeding, and hepatic encephalopathy.

References:

www.ncbi.nlm.nih.gov/books/NBK470217/

↑ *Back to this question in Part A*

@Neet_pg_bot

Q10: A 52-year-old man with a history of heavy alcohol consumption presents with jaundice, abdominal pain, and fatigue. A liver biopsy is performed to assess the extent of liver damage. Which of the following findings is most characteristic of this condition? Histopathology image given below: (Q851290)

A. Russell bodies

B. Dutcher bodies

C. Mallory-Denk bodies

D. Kamino bodies

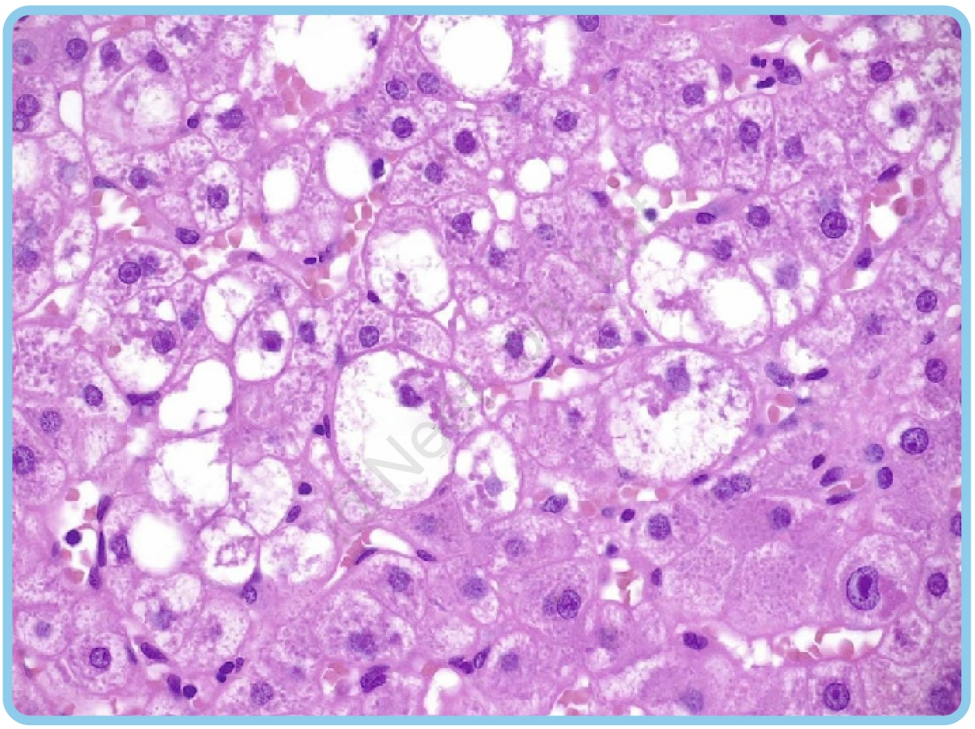

Correct Answer: C. Mallory-Denk bodies

Explanation: Mallory-Denk bodies: These are characteristic of alcoholic hepatitis. Histopathology: The classical histological features include: Mallory-Denk bodies: Cytoplasmic inclusions composed of aggregated intermediate filaments particularly keratin (CK8/18) and other proteins. Steatosis Hepatocellular ballooning representing steatohepatitis Cholestasis Chicken-wire fibrosis Cirrhosis in severely cases Neutrophilic and lymphocytic infiltration Russell bodies (Option A): These are eosinophilic globules found in plasma cells, associated with conditions like multiple myeloma and chronic inflammatory states, not alcoholic hepatitis Dutcher bodies (Option B): These are found in the nuclei of plasma cells and are associated with multiple myeloma. They are not related to liver pathology. Kamino bodies (Option D) : These are found in the liver and are associated with conditions like Wilson’s disease. They are not characteristic of alcoholic hepatitis.

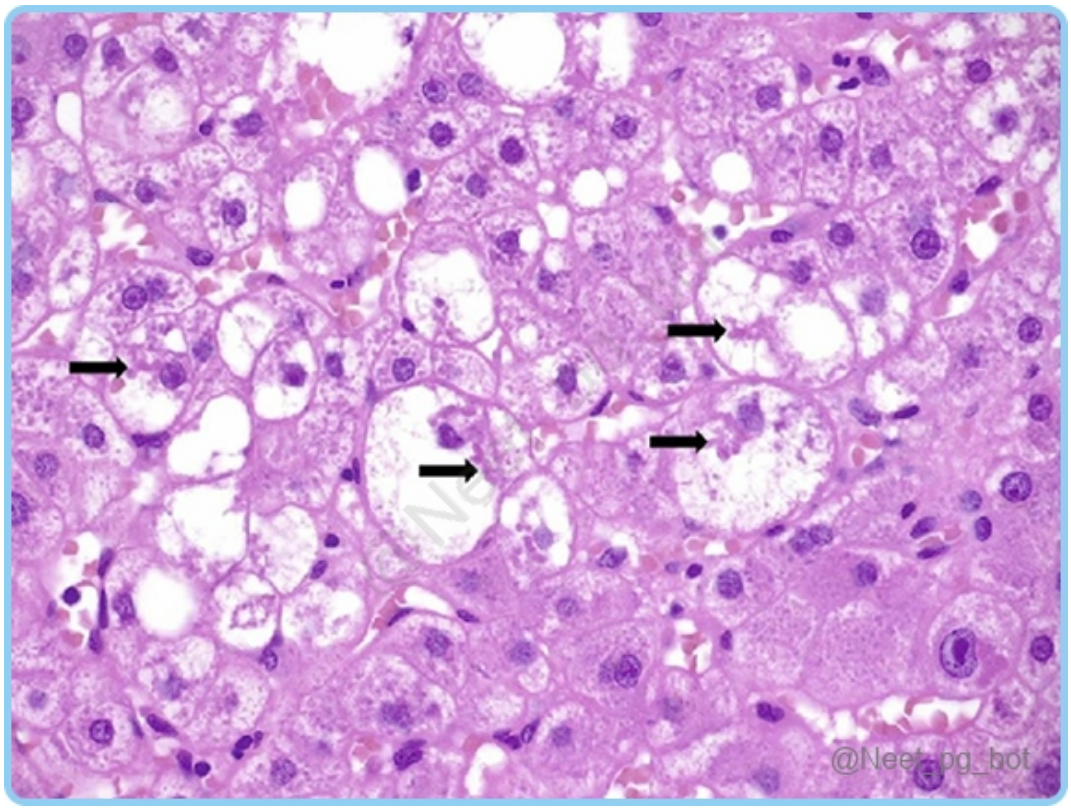
@Neet_pg_bot

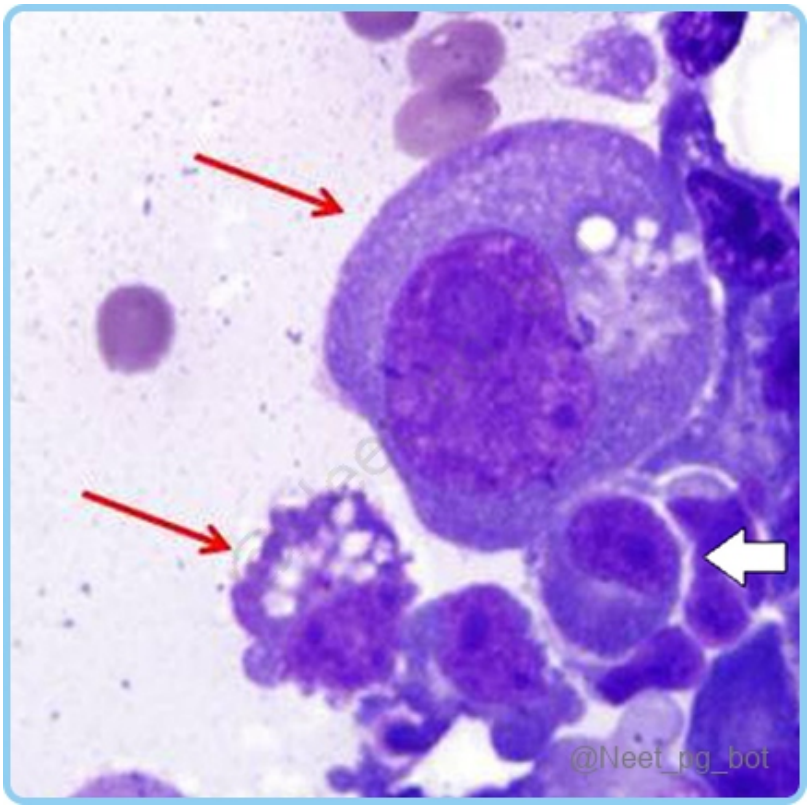
@Neet_pg_bot

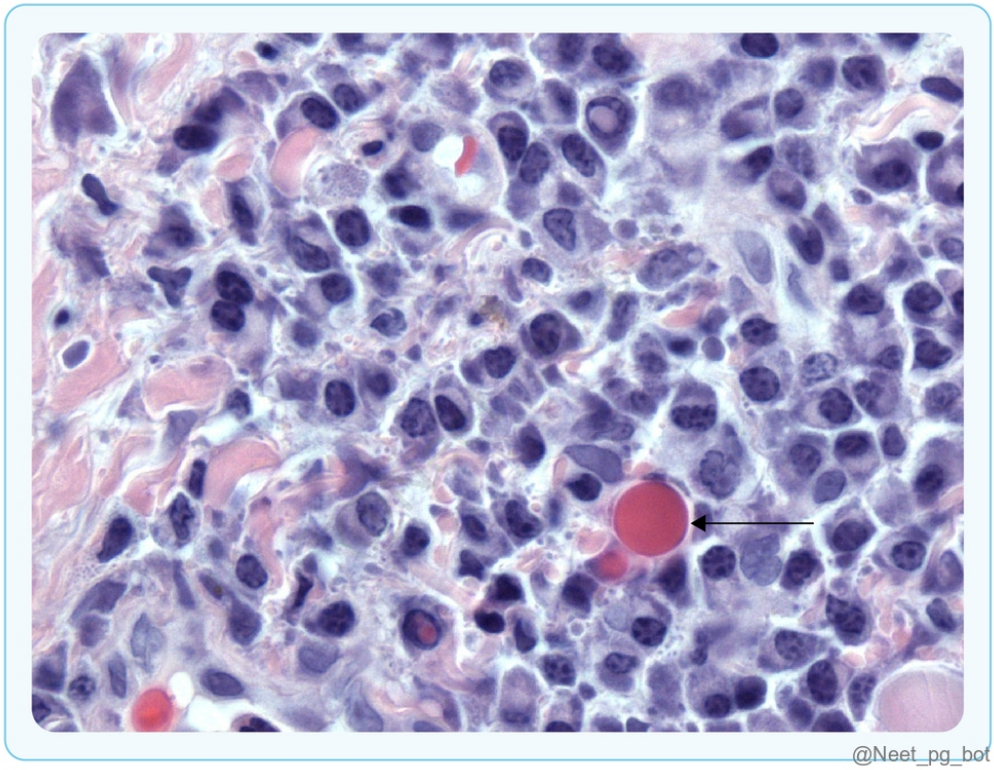

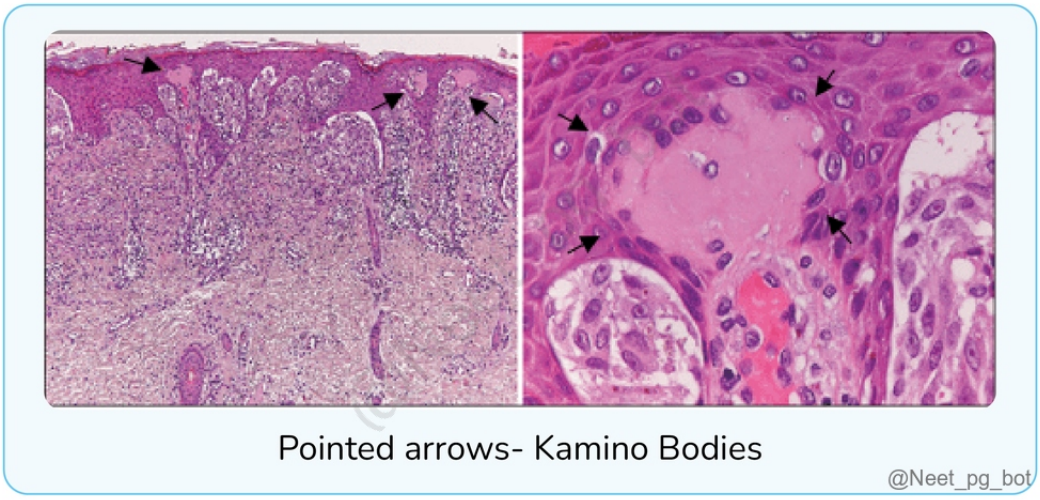

References:

www.ncbi.nlm.nih.gov/books/NBK470217/

↑ *Back to this question in Part A*

@Neet_pg_bot

Q11: A 50-year-old male with a history of heavy alcohol use presents with jaundice and altered sensorium. Laboratory tests reveal elevated bilirubin, AST > ALT, hypoalbuminemia, and prolonged PT/INR. Which of the following findings is most suggestive of the presence of hepatic encephalopathy in this patient? (Q851291)

A. Asterixis

B. Hyperbilirubinemia

C. Ascites

D. Gynaecomastia

Correct Answer: A. Asterixis

Explanation: Asterixis (flapping tremors) is a classical physical examination finding highly suggestive of hepatic encephalopathy . Hepatic encephalopathy: Portosystemic encephalopathy is a serious complication of chronic liver disease and is broadly defined as an alteration in mental status and cognitive function occurring in the presence of liver failure. Symptoms include confusion, personality changes, violent behavior, or excessive sleepiness, making the patient difficult to manage or rouse. Asterixis : A flapping tremor seen in hepatic encephalopathy. Elicited by having the patient extend arms and bend wrists back (producing a “liver flap”). Other features like hyperbilirubinemia, ascites or gynaecomastia are suggestive of a liver pathology but not indicative of Hepatic encephalopathy.

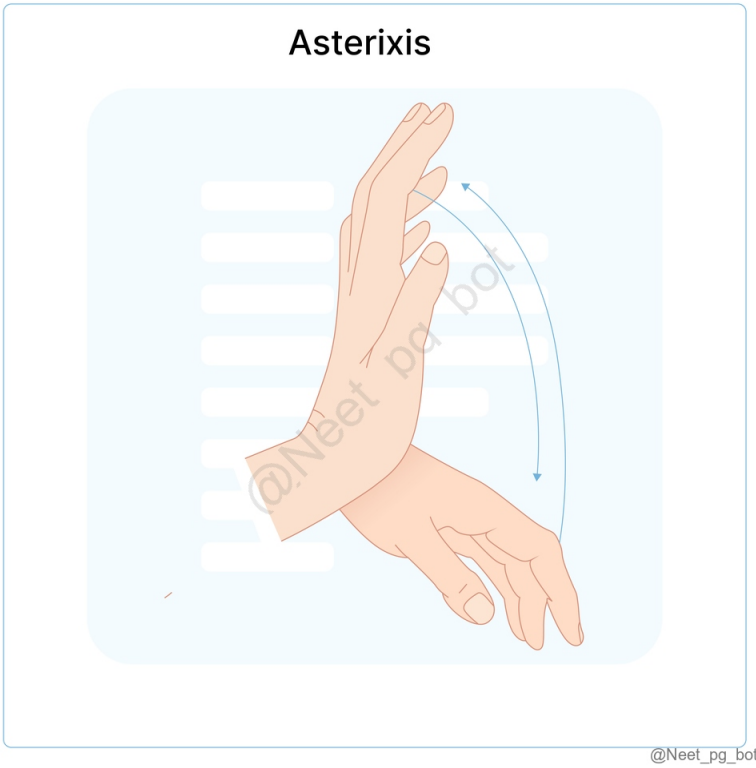

References:

Harrison’s Principles of Internal Medicine, 21st Edition, Pages 2618, 2632

↑ *Back to this question in Part A*

@Neet_pg_bot

Q12: A 45-year-old man with a long history of heavy alcohol use presents with fatigue, jaundice, and abdominal distension. Physical examination reveals hepatomegaly, spider angiomas, and ascites. What is the most specific investigation to diagnose his condition? (Q851292)

A. γ-glutamyl transferase assay (GGT)

B. PT/INR

C. Serum bilirubin

D. AST/ALT ratio

Correct Answer: D. AST/ALT ratio

Explanation: The AST/ALT ratio is the most specific biochemical marker for alcoholic liver disease among the options. A ratio >2:1 is highly suggestive of alcohol-induced injury, and a ratio >3:1 is even more specific. This occurs because alcoholics often have a deficiency of pyridoxal-5'-phosphate (Vitamin B6) , which is a necessary co-factor for ALT synthesis, causing ALT to be disproportionately lower than AST. γ-glutamyl transferase assay (Option A): While GGT is a sensitive marker for alcohol ingestion due to enzyme induction, it is not specific . It is frequently elevated in NAFLD, cholestasis, and with the use of various medications. PT/INR (Option B): This is a marker of liver synthetic function and is used to calculate the MELD score, but it does not identify the specific cause of liver disease. Serum bilirubin (Option C): Indicates the degree of cholestasis or hepatocellular failure and is used for prognostic scoring (e.g., Maddrey’s Discriminant Function), but it is not etiology-specific. PT/INR (Option B): Reflects liver synthetic failure but is not specific for alcoholic liver disease. Serum bilirubin (Option C): Indicates cholestasis or hepatocellular dysfunction but not specific to alcohol. AST/ALT ratio (Option D): Suggestive when >2, but still not specific , as it can be seen in other liver diseases.

References:

Harrison’s Principles of Internal Medicine, 21st Edition, Page 2618

↑ *Back to this question in Part A*

@Neet_pg_bot

Q13: A 30-year-old male patient succumbed to death, history revealed that the patient was admitted for liver failure 1 week back. Biopsy done is as shown below. What type of inclusions are seen in the biopsy, and what is the likely diagnosis? {{caption_text}} (Q851293)

A. Intracytoplasmic - ALD

B. Intranuclear - ALD

C. Intracytoplasmic - Viral hepatitis

D. Intranuclear - Viral hepatitis

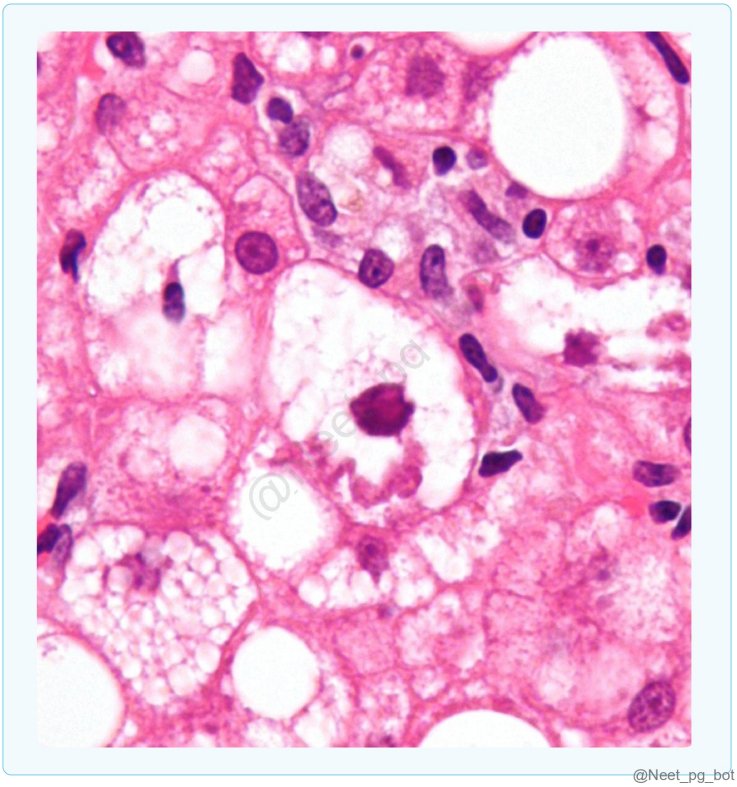

Correct Answer: A. Intracytoplasmic - ALD

Explanation: Biopsy shows intracytoplasmic hyaline inclusions known as Malory-Denk bodies - characteristic of Alcoholic liver disease. Biopsy findings in ALD Neutrophils infiltration with ballooned hepatocytes Malory-Denk bodies: Intracytoplasmic hyaline inclusions Bilirubin Stasis & ductular reaction Chicken wire fibrosis (later stages) {{caption_text}} Viral hepatitis (Option C): Councilman bodies (apoptotic cytoplasmic bodies) are seen. {{caption_text}}

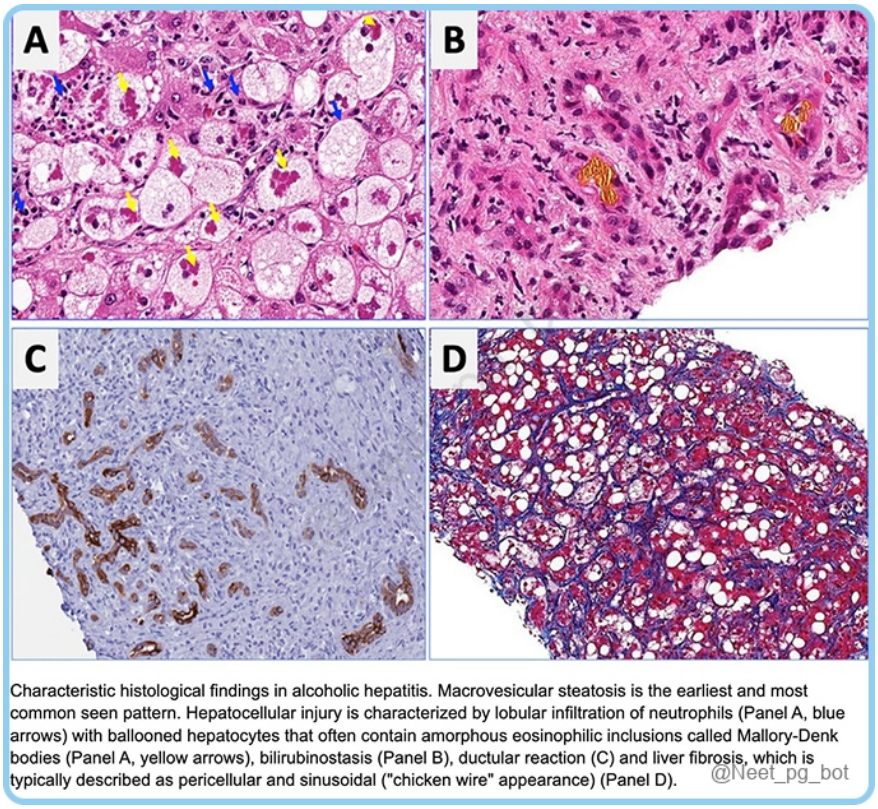

Characteristic histological findings in alcoholic hepatitis. Macrovesicular steatosis is the earliest and most common seen pattern. Hepatocellular injury is characterized by lobular infiltration of neutrophils (Panel A, blue arrows) with ballooned hepatocytes that often contain amorphous eosinophilic inclusions called Mallory-Denk bodies (Panel A, yellow arrows), bilirubinostasis (Panel B), ductular reaction (C) and liver fibrosis, which is typically described as pericellular and sinusoidal ("chicken wire" appearance) (Panel D).

@Neet_pg_bot

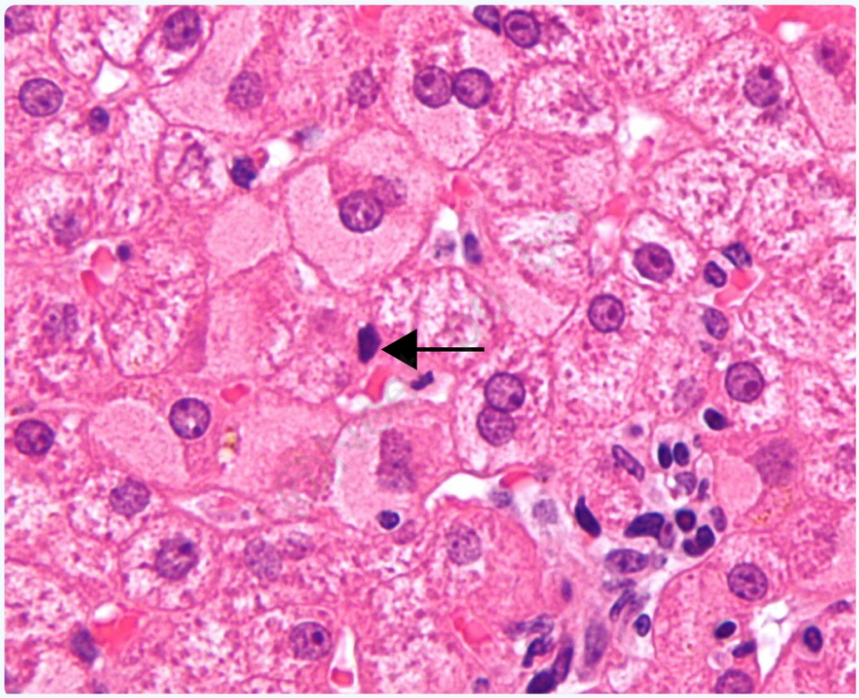

@Neet_pg_bot

References:

Harrison’s Principles of Internal Medicine, 21st Edition, Page 2618.

↑ *Back to this question in Part A*

@Neet_pg_bot

Q14: Which among the following are components of the MELD 3.0 score? 1) Male sex 2) Albumin 3) Creatinine 4) AST 5) INR 6) Serum Na+ (Q851294)

A. 1,2,3,5,6

B. 2,3,5,6

C. 1,3,4,5,6

D. 2,3,4,5

Correct Answer: B. 2,3,5,6

Explanation: Female sex is a component of MELD 3.0 (NOT the male sex). Scorings used for ALD: MELD: (Model of End-stage Liver Disease) Creatinine (3) Bilirubin INR (5) MELD 3.0 : Female sex S. Bilirubin S. Albumin (2) S.Sodium (6) INR S.Creatinine (mnemonic: FBASIC)

References:

Harrison’s Principles of Internal Medicine, 21st Edition, Pages 2618, 2626, 2636

https://pmc.ncbi.nlm.nih.gov/articles/PMC1856360/

https://pmc.ncbi.nlm.nih.gov/articles/PMC8608337/

↑ *Back to this question in Part A*

@Neet_pg_bot

Q15: A female patient who is a known alcoholic presented to OPD with jaundice and malaise. Her initial reports were PT: 24 sec (N: 11-14sec); AST: 70 Units/L (N: 10-40 U/L) ; ALT: 70 Units/L (N: 8-55 U/L); Bilirubin: 2 mg/dL (N: 0.2-1.3 mg/dL). What is the preferred management of choice? (Q851295)

A. Only lifestyle modifications

B. Oral steroids

C. Zinc + Vit-E supplements

D. Liver transplant

Correct Answer: B. Oral steroids

Explanation: History is suggestive of Alcoholic liver disease ,with Maddrey's discriminant function score ≥ 32 is an indication to start Steroid s. Maddrey's Discriminant function (DF) score: 4.6 (PT PATIENT - PT CONTROL) + S.bilirubin Here, the score is 4.6 * (10) + 2 = 48 (≥ 32) and hence Steroids must be started along with lifestyle modifications (alcohol abstinence + dietary changes)

References:

Harrison's Principles of Internal Medicine, 21st Edition, Pages 2618, 2619, 2626.

↑ *Back to this question in Part A*

@Neet_pg_bot

Q16: Which among the following is not a component of Liver FibroTest? (Q851297)

A. Haptoglobin

B. Hyaluronic acid

C. γ-GT (GGT)

D. Total bilirubin

Correct Answer: B. Hyaluronic acid

Explanation: Hyaluronic acid is not a component of FibroTest; it is included in the Enhanced Liver Fibrosis (ELF) assay. FibroTest Haptoglobin (Option A) α2- macroglobulin Apolipoprotein A1 γ-GT (GGT) (Option C) Total bilirubin (Option D) > 0.63

References:

Harrison's Principles of Internal Medicine, 21st Edition, Pages 2556, 2618.

↑ *Back to this question in Part A*

@Neet_pg_bot

• [09_Hepatobiliary System] 069 Autoimmune Liver Disease Cholestasis Hepatotoxicity

« Back to Folder Directory

[09_Hepatobiliary System] 069 Autoimmune Liver Disease Cholestasis Hepatotoxicity — Quick Jump

Q1 (p. 2744)	*Q2 (p. 2745)*	*Q3 (p. 2745)*	*Q4 (p. 2746)*	*Q5 (p. 2747)*	*Q6 (p. 2748)*
Q7 (p. 2749)	*Q8 (p. 2749)*	*Q9 (p. 2750)*	*Q10 (p. 2751)*	*Q11 (p. 2751)*	*Q12 (p. 2752)*
Q13 (p. 2753)	*Q14 (p. 2754)*	*Q15 (p. 2755)*	*Q16 (p. 2755)*	*Q17 (p. 2756)*	*Q18 (p. 2757)*
Q19 (p. 2758)	*Q20 (p. 2760)*	*Q21 (p. 2761)*	*Q22 (p. 2762)*	*Q23 (p. 2763)*	

Q1: A 12 y/o girl has elevated liver enzymes. She has vitiligo and is asymptomatic. Labs show ALT 320 U/L, AST 280 U/L, negative ANA and ASMA, and polyclonal hypergammaglobulinemia. Viral hepatitis serologies are negative. Which of the following autoantibodies is most specific for this subtype? (Q890466)

A. Antimitochondrial antibody (AMA)

B. Anti-liver kidney microsome type 1 (anti-LKM1)

C. Anti-soluble liver antigen (anti-SLA)

D. Perinuclear antineutrophil cytoplasmic antibody (pANCA)

Correct Answer: B. Anti-liver kidney microsome type 1 (anti-LKM1)

Explanation: This 12-year-old girl has marked transaminase elevation with polyclonal hypergammaglobulinemia , negative viral hepatitis markers, and an association with another autoimmune condition (vitiligo), pointing toward autoimmune hepatitis . The absence of ANA and ASMA makes type 1 AIH unlikely . In children and adolescents, this pattern is characteristic of type 2 autoimmune hepatitis , for which anti-liver kidney microsome type 1 (anti-LKM1) antibodies are the most specific. Type II autoimmune hepatitis is classically associated with anti-LKM1 antibodies, which target cytochrome P450 2D6 and are most commonly seen in children and adolescents, often with concurrent autoimmune diseases. Autoimmune hepatitis (AIH) is diagnosed using a combination of criteria, not a single test: Hepatocellular pattern of liver injury with markedly elevated AST and ALT Elevated serum IgG or polyclonal hypergammaglobulinemia Characteristic autoantibodies (ANA, ASMA, anti-LKM1, anti-SLA, depending on subtype) Exclusion of viral hepatitis, drug-induced, and metabolic liver disease Compatible liver histology showing interface hepatitis with plasma cell-rich infiltrates Subtype distinction: Type I AIH: ANA, ASMA, anti-SLA; all ages Type II AIH: anti-LKM1; predominantly pediatric population AMA (Option A): Marker of primary biliary cholangitis, not AIH. Anti-SLA (Option C) : Seen in Type I AIH, often severe disease. pANCA (Option D) : Nonspecific; seen in Type I AIH and PSC.

References:

Harrison’s Principles of Internal Medicine, 22nd Edition, Pages 2694, 2695.

↑ *Back to this question in Part A*

@Neet_pg_bot

Q2: Which of the following autoantibodies is found in approximately 65% of patients with primary sclerosing cholangitis (PSC) and can aid in distinguishing it from other cholestatic liver diseases? (Q890481)

A. Antimitochondrial antibody (AMA)

B. Anti-smooth muscle antibody (ASMA)

C. Perinuclear antineutrophil cytoplasmic antibody (pANCA)

D. Anti-liver kidney microsome type 1 (anti-LKM1)

Correct Answer: C. Perinuclear antineutrophil cytoplasmic antibody (pANCA)

Explanation: pANCA is positive in approximately 60-70% of patients with PSC, making it the most commonly associated autoantibody and a useful supportive marker in the correct clinical context. Key features of Primary Sclerosing Cholangitis: Chronic cholestatic liver disease affecting intrahepatic and extrahepatic bile ducts Strong association with ulcerative colitis Cholestatic enzyme pattern (↑ ALP, ↑ GGT) pANCA positivity (supportive, not diagnostic) Diagnosis confirmed by cholangiography showing multifocal strictures (“beading”) Increased risk of cholangiocarcinoma and colorectal cancer AMA (Option A): Hallmark antibody of primary biliary cholangitis, not PSC. ASMA (Options B): Associated with Type I autoimmune hepatitis. Anti-LKM1 (Option D) : Marker of Type II autoimmune hepatitis, usually pediatric.

References:

Harrison’s Principles of Internal Medicine, 22nd Edition, Pages 2711, 2712.

↑ *Back to this question in Part A*

@Neet_pg_bot

Q3: A 48 y/o woman has 6 months of fatigue and nocturnal pruritus and has Hashimoto thyroiditis. The exam shows excoriations and xanthelasma. Ultrasound reveals a normal biliary tree. Labs show: Alkaline phosphatase: 450 U/L (↑↑), AST: 55 U/L, ALT: 60 U/L, Total bilirubin: 1.0 mg/dL, ANA: positive (1:40). What is the

most appropriate next step to confirm the diagnosis? (Q890480)

A. Endoscopic retrograde cholangiopancreatography (ERCP)

B. Serum antimitochondrial antibody (AMA) titer

C. Percutaneous liver biopsy

D. Serum IgG4 level

Correct Answer: B. Serum antimitochondrial antibody (AMA) titer

Explanation: In a middle-aged woman with pruritus, fatigue, cholestatic enzymes (↑ ALP), and normal biliary imaging, testing for AMA is the key next step; AMA is present in ~90-95% of PBC cases and establishes the diagnosis when combined with cholestatic labs. Diagnostic framework for PBC: Persistent elevation of alkaline phosphatase Positive AMA (diagnostic in the appropriate clinical setting) Exclusion of extrahepatic biliary obstruction (normal ultrasound) Liver biopsy not required if AMA is positive and labs are typical; reserved for AMA-negative PBC or overlap syndromes Associated features supporting PBC: Female predominance; association with other autoimmune diseases Mild AST/ALT elevation; bilirubin often normal early Possible ANA positivity (nonspecific). ERCP (Option A): Invasive; used for obstruction or PSC, not first-line in suspected PBC. Percutaneous liver biopsy (Options C): Reserved for AMA-negative cases or diagnostic uncertainty. IgG4 level (Option D) : Evaluates IgG4-related cholangitis, not typical PBC.

References:

Harrison’s Principles of Internal Medicine, 22nd Edition, Page 2711.

↑ *Back to this question in Part A*

@Neet_pg_bot

Q4: A patient with primary biliary cholangitis (PBC) fails to achieve an adequate biochemical response to first-line therapy with ursodeoxycholic acid (UDCA). Which of the following agents is an established second-line treatment shown to produce significant biochemical improvement in this subset of patients? (Q890479)

A. Azathioprine

B. Prednisone

C. Obeticholic acid

D. Ribavirin

Correct Answer: C. Obeticholic acid

Explanation: Obeticholic acid is a validated second-line therapy for PBC patients who have an inadequate biochemical response to UDCA, with studies showing significant improvement in cholestatic markers in a substantial proportion of nonresponders. Stepwise management of PBC: First-line therapy: Ursodeoxycholic acid (UDCA) Treatment goal: Reduction in alkaline phosphatase and bilirubin to improve transplant-free survival UDCA-refractory PBC (30-40% of patients): Add or switch to obeticholic acid Emerging alternatives include PPAR agonists (e.g., elafibranor, seladelpar) These agents target bile acid metabolism and cholestatic injury pathways Azathioprine (Option A) and Prednisone (Option B): Core therapies for autoimmune hepatitis, not standard treatment for PBC. Ribavirin (Option D) : Antiviral used in hepatitis C/E, not cholestatic liver disease.

References:

Harrison's Principles of Internal Medicine, 22nd Edition, Pages 2711, 2712.

↑ *Back to this question in Part A*

@Neet_pg_bot

Q5: A 52 y/o woman presents with progressive fatigue and generalised pruritus, worse in the evening. Examination shows excoriations and xanthelasma. Laboratory results are as follows: Total bilirubin: 1.2 mg/dL, Alkaline phosphatase: 580 U/L (↑↑), AST: 65 U/L, ALT: 72 U/L, GGT: 350 U/L. Which of the following serologic markers is most likely to be positive? (Q890478)

A. Antinuclear antibody (ANA)

B. Antimitochondrial antibody (AMA)

C. Anti-smooth muscle antibody (ASMA)

D. Perinuclear antineutrophil cytoplasmic antibody (pANCA)

Correct Answer: B. Antimitochondrial antibody (AMA)

Explanation: A middle-aged woman with pruritus, xanthelasma, and a cholestatic enzyme pattern (marked ↑ ALP and GGT with mild AST/ALT elevation) is classic for PBC, and AMA is the hallmark serologic marker, present in ~90-95% of cases. Characteristic laboratory findings in PBC: Cholestatic pattern: Disproportionate ↑ alkaline phosphatase and GGT Mild to moderate AST and ALT elevation Antimitochondrial antibody (AMA) positivity Elevated IgM levels Hyperlipidemia → xanthelasma/xanthomas Bilirubin is often normal early; it rises late with disease progression Primary Biliary Cholangitis (PBC) Chronic, progressive autoimmune cholestatic liver disease causes destruction of intrahepatic bile ducts. Epidemiology: Middle-aged women (female predominance) Pathogenesis: Immune-mediated bile duct injury → cholestasis → fibrosis → cirrhosis Autoantibody: Antimitochondrial antibody (AMA) in ~90-95% (diagnostic hallmark) Biochemistry: ↑ ALP and GGT (cholestatic pattern), mild ↑ transaminases Clinical features: Often asymptomatic early, detected via cholestatic labs Fatigue - the most common and debilitating symptom Pruritus - due to chronic cholestasis and bile acid retention Associated conditions: Other autoimmune diseases (Sjögren syndrome, autoimmune thyroid disease) Complications:

Fat-soluble vitamin deficiency, osteoporosis, portal hypertension Treatment: Ursodeoxycholic acid (UDCA) first-line; obeticholic acid if UDCA is inadequate Prognosis: Variable; untreated disease may progress to cirrhosis and liver failure ANA (Option A) and ASMA(Option C): Typical of Type I autoimmune hepatitis, not PBC. pANCA (Option D) : Associated with primary sclerosing cholangitis and ulcerative colitis.

References:

Harrison's Principles of Internal Medicine, 22nd Edition, Page 2711.

↑ *Back to this question in Part A*

@Neet_pg_bot

Q6: Which of the following pairs of symptoms represents the most prominent and characteristic clinical manifestations in symptomatic patients with primary biliary cholangitis? (Q890477)

A. Right upper quadrant pain and fever

B. Fatigue and pruritus

C. Arthralgias and skin rash

D. Nausea and vomiting

Correct Answer: B. Fatigue and pruritus

Explanation: Symptomatic PBC is classically characterised by profound fatigue (often disproportionate to disease severity) and pruritus, which is present in approximately half of patients at diagnosis and may precede jaundice. Primary Biliary Cholangitis (PBC) Chronic, progressive autoimmune cholestatic liver disease causing destruction of intrahepatic bile ducts Epidemiology: Middle-aged women (female predominance) Pathogenesis: Immune-mediated bile duct injury → cholestasis → fibrosis → cirrhosis Autoantibody: Antimitochondrial antibody (AMA) in ~90-95% (diagnostic hallmark) Biochemistry: ↑ ALP and GGT (cholestatic pattern), mild ↑ transaminases Clinical features: Often asymptomatic early, detected via cholestatic labs Fatigue - the most common and debilitating symptom Pruritus - due to chronic cholestasis and bile acid retention Jaundice - typically a late manifestation Associated with hyperlipidemia, leading to xanthelasma/xanthomas Strong association with other autoimmune diseases (e.g., Sjögren syndrome, thyroid disease) Associated conditions: Other autoimmune diseases (Sjögren syndrome, autoimmune thyroid disease) Complications: Fat-soluble vitamin deficiency, osteoporosis, portal hypertension Diagnosis: Cholestatic labs + AMA (biopsy if unclear) Treatment: Ursodeoxycholic acid (UDCA) first-line; obeticholic acid if UDCA is inadequate Prognosis: Variable; untreated disease may progress to cirrhosis and liver failure RUQ pain & fever (Option A): Suggest acute cholangitis (Charcot triad), not chronic PBC. Arthralgias & rash (Option C): More typical of autoimmune hepatitis or viral prodromes. Nausea & vomiting (Option D) : Nonspecific; no defining features of PBC.

References:

Harrison’s Principles of Internal Medicine, 22nd Edition, Page 2711.

↑ *Back to this question in Part A*

@Neet_pg_bot

Q7: Which of the following autoantibodies detected in patients with autoimmune hepatitis is specifically associated with a worse prognosis? (Q890476)

A. Antinuclear antibody (ANA)

B. Anti-smooth muscle antibody (ASMA)

C. Anti-soluble liver antigen (anti-SLA)

D. Anti-liver kidney microsome type 1 (anti-LKM1)

Correct Answer: C. Anti-soluble liver antigen (anti-SLA)

Explanation: Anti-SLA antibodies identify a subset of autoimmune hepatitis patients who are reported to have a more aggressive disease course and worse prognosis, even when classified within the Type I AIH spectrum. Poor prognostic markers in AIH include: Anti-SLA positivity High aminotransferase and IgG levels at presentation Advanced fibrosis or cirrhosis on biopsy Delayed response or nonresponse to immunosuppressive therapy Younger age at onset in aggressive subtypes Role of serologic markers in AIH prognosis: Autoantibodies help with classification and risk stratification Anti-SLA is highly specific for AIH and associated with severe disease, frequent relapse, and poorer long-term outcomes ANA and ASMA are useful diagnostically, but do not independently predict prognosis ANA (Option A) and ASMA (Option B): Common in Type I AIH; not linked to worse prognosis. Anti-LKM1 (Option D) : Marker of Type II AIH; subtype distinction, not prognostic severity.

References:

Harrison’s Principles of Internal Medicine, 22nd Edition, Page 2695.

↑ *Back to this question in Part A*

@Neet_pg_bot

Q8: A patient with autoimmune hepatitis is treated with standard first-line therapy, including corticosteroids and azathioprine, but fails to achieve biochemical remission. The clinician plans to escalate immunosuppressive therapy. Which of the following agents is the next drug of choice in this setting? (Q890475)

A. Methotrexate

B. Cyclosporine

C. Mycophenolate mofetil

D. Ursodeoxycholic acid

Correct Answer: C. Mycophenolate mofetil

Explanation: Mycophenolate mofetil (MMF) is the recommended second-line agent and the next drug of choice in patients with AIH who are nonresponsive to or intolerant of azathioprine. Stepwise management approach in AIH: First-line induction: Prednisone (or budesonide in mild disease) ± azathioprine Maintenance: Azathioprine-based immunosuppression Steroid-refractory or azathioprine-intolerant disease: Mycophenolate mofetil MMF suppresses lymphocyte proliferation and has a favourable efficacy-toxicity profile Role of MMF: Effective in inducing and maintaining remission Preferred before calcineurin inhibitors due to better tolerability Commonly used when azathioprine causes cytopenias or hepatotoxicity Methotrexate (Option A): Limited evidence; not standard second-line therapy in AIH. Cyclosporine (Option B): Reserved for refractory cases; higher toxicity burden. Ursodeoxycholic acid (Option D) : Used in primary biliary cholangitis, not AIH.

References:

Harrison's Principles of Internal Medicine, 22nd Edition, Page 2696.

↑ *Back to this question in Part A*

@Neet_pg_bot

Q9: A patient with mild autoimmune hepatitis (aminotransferases <2× the upper limit of normal) requires initial corticosteroid therapy with minimal systemic effects. Which of the following corticosteroids is an alternative first-line option in this setting? (Q890474)

A. Dexamethasone

B. Methylprednisolone

C. Budesonide

D. Hydrocortisone

Correct Answer: C. Budesonide

Explanation: Budesonide is recommended as an alternative first-line corticosteroid for mild AIH because its extensive hepatic first-pass metabolism limits systemic glucocorticoid exposure while maintaining intrahepatic anti-inflammatory activity. Principles of first-line therapy in AIH: Goal: Induce remission (normalise aminotransferases and IgG, improve histology) Standard first-line regimen: Prednisone (or prednisolone) ± azathioprine Mild disease (low transaminase elevation, no cirrhosis): Budesonide can substitute for prednisone to

reduce steroid-related adverse effects Contraindication: Budesonide should not be used in patients with cirrhosis or portal hypertension due to reduced first-pass metabolism Dexamethasone (Option A): Potent systemic steroid; not recommended as first-line AIH therapy. Methylprednisolone (Option B): Used IV when oral therapy isn't possible; not preferred for mild AIH. Hydrocortisone (Option D) : Short-acting; not standard for AIH induction therapy.

References:

Harrison's Principles of Internal Medicine, 22nd Edition, Page 2696.

↑ *Back to this question in Part A*

@Neet_pg_bot

Q10: A patient with acute hepatitis is HBsAg positive with anti-HDV antibodies. To represent HDV superinfection on chronic hepatitis B rather than HBV-HDV coinfection. Which antibody profile confirms HDV superinfection? (Q890472)

A. IgM anti-HBc positive

B. IgG anti-HBc positive

C. Anti-HBs positive

D. IgM anti-HAV positive

Correct Answer: B. IgG anti-HBc positive

Explanation: IgG anti-HBc indicates chronic hepatitis B infection; when HDV infection occurs on this background, it confirms HDV superinfection, not coinfection. Key serologic principle in hepatitis differentiation: HBsAg indicates active HBV infection IgM anti-HBc → acute HBV infection IgG anti-HBc → chronic HBV infection HDV requires HBV (HBsAg) for replication HDV infection patterns: Coinfection: Acute HBV + acute HDV → IgM anti-HBc positive Superinfection: Chronic HBV + acute HDV → IgG anti-HBc positive Superinfection is associated with more severe disease and a higher risk of chronic liver failure. IgM anti-HBc (Option A): Indicates acute HBV, consistent with coinfection, not superinfection. Anti-HBs (Option C): Marker of recovery or immunity, not present with active HBsAg positivity. IgM anti-HAV (Option D) : Indicates acute hepatitis A, unrelated to HBV/HDV.

References:

Harrison's Principles of Internal Medicine, 22nd Edition, Pages 2657, 2658.

↑ *Back to this question in Part A*

@Neet_pg_bot

Q11: Which of the following autoantibodies is considered the serologic hallmark of Type II autoimmune hepatitis? (Q890470)

A. Antinuclear antibody (ANA)

B. Anti-smooth muscle antibody (ASMA)

C. Anti-liver kidney microsome type 1 antibody (anti-LKM1)

D. Anti-soluble liver antigen (anti-SLA)

Correct Answer: C. Anti-liver kidney microsome type 1 antibody (anti-LKM1)

Explanation: Type II autoimmune hepatitis is defined by the presence of anti-LKM1 antibodies, which target cytochrome P450 2D6 and are most commonly seen in children and adolescents, often with negative ANA and ASMA. Serologic markers are central to the diagnosis and subtyping of AIH, alongside elevated aminotransferases, increased IgG levels, exclusion of viral hepatitis, and compatible histology. Key serologic patterns in AIH: Type I AIH: ANA and/or ASMA (most common form; all age groups) Type II AIH: anti-LKM1 (pediatric predominance; more aggressive disease) Anti-SLA: Highly specific for AIH, usually grouped with Type I, often associated with severe disease ANA (Option A) and ASMA (Option B): Hallmark antibodies of Type I AIH, not Type II. Anti-SLA (Option D) : Seen in a subset of Type I AIH, especially ANA/ASMA-negative cases.

References:

Harrison’s Principles of Internal Medicine, 22nd Edition, Pages 2694, 2695.

↑ *Back to this question in Part A*

@Neet_pg_bot

Q12: A patient on long-term antibiotic therapy develops chronic hepatitis with elevated aminotransferases. Serologic testing reveals positive ANA and anti-smooth muscle antibodies. Which antimicrobial agent is associated with this pattern of hepatotoxicity? (Q890468)

A. Amoxicillin-clavulanate

B. Erythromycin estolate

C. Ciprofloxacin

D. Nitrofurantoin

Correct Answer: D. Nitrofurantoin

Explanation: Nitrofurantoin is a classic cause of drug-induced autoimmune hepatitis, producing a chronic hepatocellular injury with ANA and ASMA positivity and histology identical to idiopathic AIH, particularly with prolonged use. Drug-induced autoimmune hepatitis (DIAIH) is characterised by: Chronic hepatocellular enzyme elevation (AST/ALT predominant) Development of autoantibodies (ANA, ASMA) Hypergammaglobulinemia Interface hepatitis with plasma cells on biopsy Clinical and histologic indistinguishability from idiopathic AIH Improvement after drug withdrawal ± immunosuppression Nitrofurantoin and minocycline are the most strongly implicated drugs in DIAIH, especially with long-term exposure. Amoxicillin-clavulanate (Option A): Common cause of DILI, but typically cholestatic or mixed injury, not autoimmune hepatitis. Erythromycin estolate (Option B) : Causes inflammatory cholestasis, not an autoimmune phenotype. Ciprofloxacin (Option C) : Produces idiosyncratic hepatocellular injury, usually acute and non-autoimmune.

References:

Harrison's Principles of Internal Medicine, 22nd Edition, Pages 2670, 2671.

↑ *Back to this question in Part A*

@Neet_pg_bot

Q13: A 30-year-old woman presents to the clinic with fatigue, jaundice, and abdominal discomfort. Lab tests show elevated liver enzymes (AST and ALT). Further testing reveals positive antinuclear antibodies (ANA) and anti-smooth muscle antibodies (ASMA). A liver biopsy demonstrates interface hepatitis with plasma cell infiltration . Given the specific autoantibody profile and the histological findings, which of the following options is associated with the condition and is most relevant to consider in this patient? (Q851299)

A. Type 1 Autoimmune Hepatitis

B. Type 2 Autoimmune Hepatitis

C. Primary Biliary Cholangitis

D. Drug-Induced Liver Injury

Correct Answer: A. Type 1 Autoimmune Hepatitis

Explanation: Type 1 Autoimmune Hepatitis is characterized by the presence of ANA and ASMA antibodies, along with the typical histological findings of interface hepatitis and plasma cell infiltration. It is the most common form of autoimmune hepatitis and is often seen in women. Types of Autoimmune hepatitis: Type 1 Autoimmune Hepatitis (Option A) Type 2 Autoimmune Hepatitis (Option B) More common in females (2nd-3rd decade) More common in children Associated with: ANA (also seen in SLE) - hence, lupoid hepatitis Anti SMA (Anti smooth muscle antibody) - against actin Anti-soluble liver antigen Atypical p-ANCA (x-ANCA) Associated with: ANA absent Anti LKM1 (Liver kidney microsome type 1) Anti-liver cytosol - 1 antibody Primary Biliary Cholangitis (Option C): It is a chronic disease that targets the small intrahepatic bile ducts rather than the hepatocytes. The

diagnostic hallmark is the Anti-Mitochondrial Antibody (AMA) . Florid duct lesions and granulomas are seen on biopsy, which differ significantly from the plasma cell-rich inflammation seen in AIH. Drug-Induced Liver Injury (Option D): While it can cause interface hepatitis, it is a diagnosis of exclusion. The presence of specific high-titer ASMA/ANA strongly favors a primary autoimmune etiology over a transient drug reaction.

References:

Harrison's Principles of Internal Medicine, 21st Edition, Pages 2613, 2614, 2615

↑ *Back to this question in Part A*

@Neet_pg_bot

Q14: A 7-year-old girl presents 20 hours after accidentally ingesting a large amount of iron supplements. Initially, she had abdominal pain, vomiting, and diarrhea, but these symptoms have resolved. Her vital signs are stable. What stage of iron toxicity is she experiencing? (Q851309)

A. Stage I

B. Stage II

C. Stage III

D. Stage IV

Correct Answer: B. Stage II

Explanation: The patient is in the latent phase (Stage II) , where gastrointestinal symptoms resolve despite significant iron absorption, occurring 6 to 24 hours post-ingestion. Stage Phase Time Frame Clinical Features Stage I (Option A) Gastrointestinal 30 mins to 6 hrs Primarily gastrointestinal (GI) symptoms such as abdominal pain, vomiting, diarrhea, hematemesis, and hematochezia. Stage II (Option B) Latent 6 to 24 hrs Apparent recovery phase where GI symptoms may resolve despite significant iron absorption. Stage III (Option C) Metabolic Acidosis & Shock 6 to 72 hrs Recurrence of GI symptoms, shock, metabolic acidosis, and complications like cardiomyopathy, and renal failure. Stage IV (Option D) Hepatotoxicity 12 to 96 hrs Development of acute liver failure. Coma & coagulopathy. Stage V Bowel Obstruction 2 to 8 weeks Consequences of healing, including scarring and obstruction of the pylorus or proximal bowel.

References:

VV Pillay Modern Medical Toxicology, 4th Edition, Pages 97, 98

https://www.uptodate.com/contents/acute-iron-poisoning

https://www.ncbi.nlm.nih.gov/books/NBK459224/

↑ *Back to this question in Part A*

@Neet_pg_bot

Q15: A 35-year-old man presents with complaints of nausea and abdominal pain after ingesting 20 paracetamol tablets approximately 8 hours ago. His vital signs are stable, but he has mild jaundice. Which of the following is the most appropriate next step in management? (Q851308)

A. Administer activated charcoal orally.

B. Start intravenous N-acetylcysteine therapy.

C. Perform a liver biopsy to assess damage.

D. Refer for liver transplantation.

Correct Answer: B. Start intravenous N-acetylcysteine therapy.

Explanation: N-acetylcysteine is the specific antidote for paracetamol poisoning , effective when administered within 8 hours to replenish hepatic glutathione and neutralize toxic metabolites. Timely NAC therapy is crucial in preventing further liver injury, especially given the patient's mild jaundice. Management of Paracetamol poisoning Management Aspect Details Initial Treatment Gastric Lavage Administer activated charcoal or cholestyramine (effective within 30 minutes of ingestion) (Option A) N-acetylcysteine (NAC) Therapy Initiate within 8 hours of ingestion; may be partially effective up to 24–36 hours post-overdose. (Option B) Administration : IV: 140 mg/kg loading dose over 1 hour, followed by 70 mg/kg every 4 hours for 15–20 doses. Liver Transplantation (Option D) Considered in cases of hepatic failure (jaundice, coagulopathy, confusion). A liver biopsy (Option C) is not an immediate management step in acute poisoning cases; treatment is prioritized.

References:

Harrison’s Principles of Internal Medicine, 21st Edition, Pages 2588, 2589

https://litfl.com/liver-transplantation-for-paracetamol-toxicity/

↑ *Back to this question in Part A*

@Neet_pg_bot

Q16: A 28-year-old woman presents with a 2-day history of fatigue, jaundice, and dark urine after taking high doses of acetaminophen for headaches over the past week. Laboratory tests reveal elevated aminotransferases (>10,000 IU/L) and an INR of 2.5. What is the most likely underlying cause of her clinical presentation? (Q851307)

A. Glutathione depletion with NAPQI buildup

B. Enhanced glucuronidation of acetaminophen

C. Increased glutathione levels leading to liver injury

D. Inhibition of CYP2E1 by acetaminophen

Correct Answer: A. Glutathione depletion with NAPQI buildup

Explanation: Acetaminophen is metabolized in the liver to form the toxic metabolite NAPQI, which is normally detoxified by glutathione . In overdose situations, excessive NAPQI depletes glutathione , leading to its accumulation and binding to hepatocyte proteins. This results in oxidative stress, mitochondrial dysfunction, and hepatocyte necrosis. The patient's symptoms of fatigue, jaundice, and elevated aminotransferases indicate significant liver injury. Metabolism of Acetaminophen Acetaminophen is mainly metabolized via phase II reactions into harmless sulfate and glucuronide metabolites. (Option B) A small portion undergoes phase I metabolism by CYP2E1 (Option D) , forming the hepatotoxic metabolite N-acetyl-p-benzoquinone-imine (NAPQI) . Detoxification of NAPQI NAPQI is neutralized by binding to glutathione, forming water-soluble mercapturic acid, which is excreted via the kidneys. Glutathione Depletion (Option C) When excessive NAPQI is produced, or glutathione is depleted (Option A) , NAPQI binds to hepatocyte macromolecules, forming acetaminophen-protein adducts, causing hepatocyte necrosis.

References:

Harrison’s Principles of Internal Medicine, 21st Edition, Page 2588

https://www.msdmanuals.com/professional/injuries-poisoning/poisoning/acetaminophen-poisoning

↑ *Back to this question in Part A*

@Neet_pg_bot

Q17: A 26-year-old patient is treated with a combination of oxycodone and acetaminophen (325 mg per tablet). The patient has a history of opioid tolerance. What is a potential risk associated with this combination? (Q851306)

A. Increased risk of renal toxicity.

B. Decreased effectiveness of acetaminophen.

C. Greater likelihood of unintentional acetaminophen overdose.

D. Development of opioid dependency.

Correct Answer: C. Greater likelihood of unintentional acetaminophen overdose.

Explanation: Patients with opioid tolerance may need higher doses of opioids for pain relief, leading them to take more tablets or medication than prescribed. This can increase their acetaminophen intake beyond the recommended daily limit, raising the risk of unintentional overdose and hepatotoxicity due to acetaminophen's well-defined toxic threshold. Increased risk of renal toxicity (Option A) : Acetaminophen is primarily associated with hepatotoxicity, not renal toxicity. Decreased effectiveness of acetaminophen (Option B) : Opioid tolerance affects the efficacy of opioids, not acetaminophen. The effectiveness of acetaminophen remains unchanged. Development of opioid dependency (Option D) : While chronic use of opioids can lead to dependency, this risk is not specifically tied to the combination with acetaminophen and can occur independently.

References:

Harrison’s Principles of Internal Medicine, 21st Edition, Page 2588

https://emedicine.medscape.com/article/820200-workup#c8

↑ *Back to this question in Part A*

@Neet_pg_bot

Q18: A 30-year-old woman presents with progressive jaundice and pruritus. She has a past medical history of ulcerative colitis. Her LFT revealed an elevated alkaline phosphatase & gamma-glutamyl transferase (GGT) and a prolonged prothrombin time. The liver biopsy is shown below. Which of the following serologic findings is most likely to be present in this patient? {{caption_text}} (Q851305)

A. Anti-liver kidney microsomal-1 antibodies (Anti-LKM-1)

B. Anti-mitochondrial antibody (AMA)

C. Perinuclear anti-neutrophil cytoplasmic antibody (pANCA)

D. Anti-centromere antibody

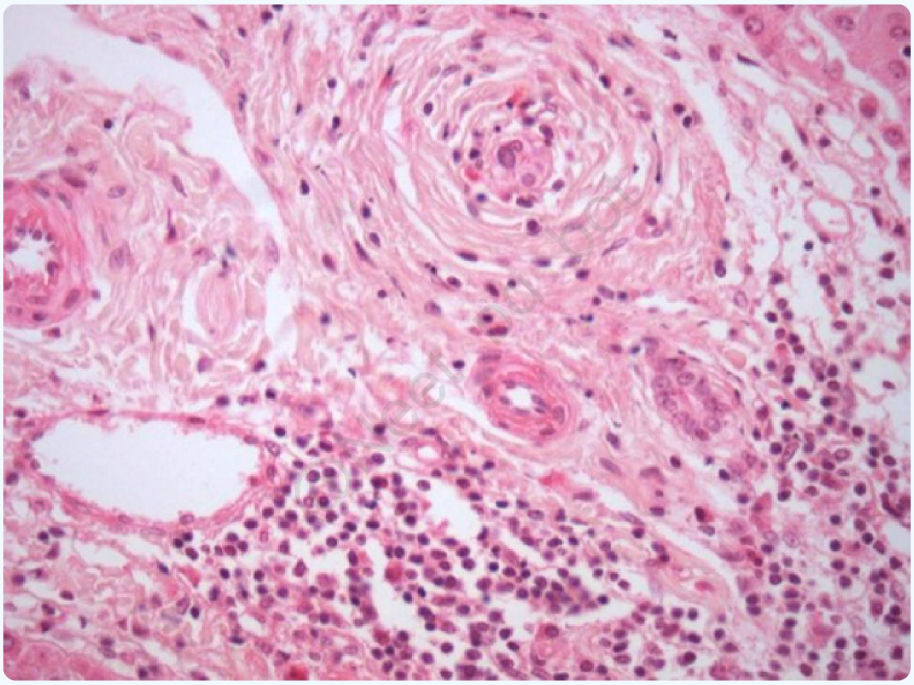

Correct Answer: C. Perinuclear anti-neutrophil cytoplasmic antibody (pANCA)

Explanation: pANCA is positive in about 65% of patients with Primary Sclerosing Cholangitis (PSC) and is often associated with ulcerative colitis . The clinical presentation of cholestasis, a history of ulcerative colitis, and the liver biopsy show periductal "onion-skin" fibrosis point towards PSC. Anti-liver kidney microsomal-1 antibodies (Option A) are associated with autoimmune hepatitis type 2. Anti-mitochondrial antibody (Option B) is found in Primary Biliary Cirrhosis (PBC), which affects small bile ducts, whereas PSC affects large intrahepatic and extrahepatic bile ducts. Anti-centromere antibody (Option D) is related to limited cutaneous systemic sclerosis (CREST syndrome)

References:

Davidson’s Principle and Practice of Medicine, 24th Edition,Pages 889, 890

https://pmc.ncbi.nlm.nih.gov/articles/PMC1994832/

↑ *Back to this question in Part A*

@Neet_pg_bot

Q19: A 40-year-old male presents with a 6-month history of progressive fatigue and pruritus. He reports a recent onset of jaundice. His past medical history is significant for ulcerative colitis. Laboratory tests reveal elevated serum alkaline phosphatase and

bilirubin, and atypical pANCA are positive. An MRCP is given below. Which of the following is the most likely diagnosis? {{caption_text}} (Q851304)

A. Primary Biliary Cholangitis

B. Primary Sclerosing Cholangitis

C. Choledocholithiasis

D. Chronic Pancreatitis

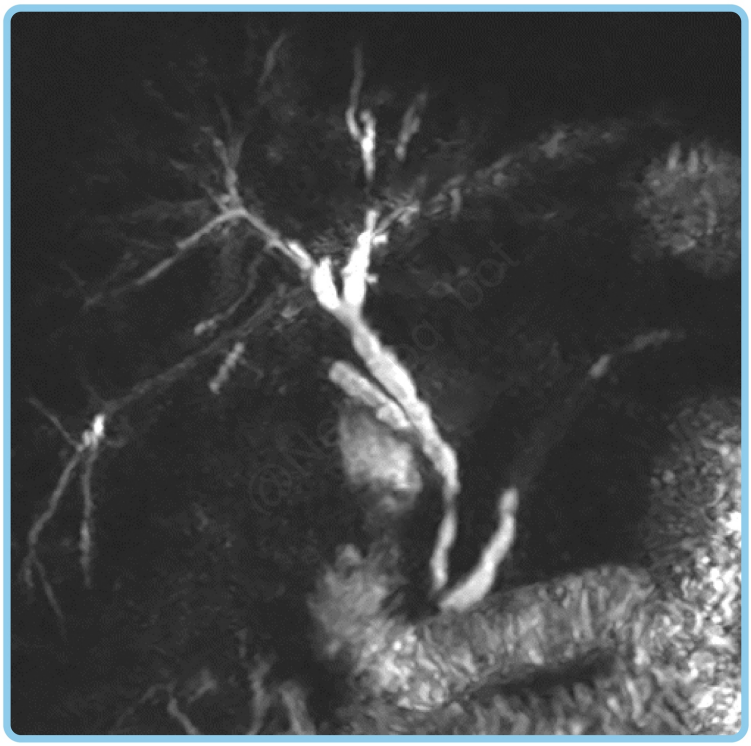

Correct Answer: B. Primary Sclerosing Cholangitis

Explanation: The patient's age, male predominance, history of ulcerative colitis, and positive pANCA are key indicators of Primary Sclerosing Cholangitis . The MRCP shows (beading) multiple irregular stricturing and dilatations of the bile duct, further support the diagnosis. PSC is commonly associated with inflammatory bowel diseases such as ulcerative colitis , and pANCA positivity is often seen in PSC patients. Primary Biliary Cholangitis (Option A) primarily affects middle-aged women and is characterized by autoimmune destruction of small bile ducts and AMA +ve. The male predominance and association with ulcerative colitis point towards PSC. Choledocholithiasis (Option C) typically presents with acute symptoms and is less likely in this case due to the chronicity of symptoms (6 months) and specific MRCP findings suggestive of PSC. Chronic Pancreatitis (Option D) can cause jaundice, and chronic pancreatitis usually presents with abdominal pain, steatorrhea, and diabetes. The MRCP findings of bile duct strictures align more with PSC than chronic pancreatitis.

References:

Robbins & Cotran Pathologic basis of disease, 10th Edition, Pages 858, 859

↑ *Back to this question in Part A*

@Neet_pg_bot

Q20: A 50-year-old woman presents with fatigue and pruritus. Laboratory tests show elevated alkaline phosphatase and positive antimitochondrial antibodies (AMAs). Which of the following is the most appropriate next step in the management of this patient? (Q851303)

A. Initiate ursodeoxycholic acid therapy

B. Schedule for liver transplantation evaluation

C. Start antiviral therapy for hepatitis

D. Refer for endoscopic retrograde cholangiopancreatography (ERCP)

Correct Answer: A. Initiate ursodeoxycholic acid therapy

Explanation: The patient’s presentation—fatigue, pruritus, elevated alkaline phosphatase, and positive antimitochondrial antibodies (AMAs)—is highly suggestive of Primary Biliary Cholangitis (PBC). Ursodeoxycholic acid (UDCA) is the standard first-line treatment for PBC. It helps to improve liver function, reduce alkaline phosphatase levels, and alleviate symptoms such as pruritus. Initiating therapy with UDCA can help manage the disease and improve the patient's quality of life. Treatment algorithm:

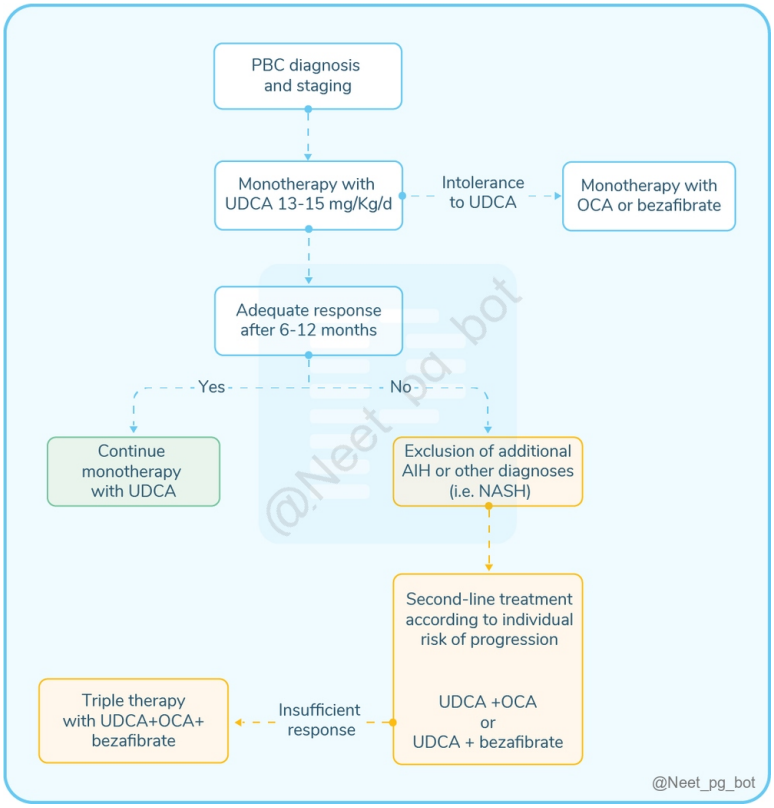

References:

Harrison's Principles of Internal Medicine, 21st Edition, Page 2627

↑ *Back to this question in Part A*

@Neet_pg_bot

Q21: Which of the following best describes the primary underlying mechanism of injury in Primary Biliary Cholangitis (PBC)? (Q851302)

A. Autoimmune-mediated destruction of bile ducts

B. Genetic mutation affecting bile acid metabolism

C. Viral infection leading to bile duct inflammation

D. Cholestasis due to gallstone obstruction

Correct Answer: A. Autoimmune-mediated destruction of bile ducts

Explanation: PBC is characterized by autoimmune-mediated portal inflammation and necrosis of cholangiocytes in small- and medium-sized bile ducts. Antimitochondrial antibodies (AMAs) are present in ~95% of patients with

PBC. Histopathologic analyses of liver biopsies reveal 4 stages: Staging: Stages I - Portal stage of Ludwig Stage II - Peri portal damage/inflammation {{caption_text}} Stage III - Septal damage Stage IV - Cirrhosis

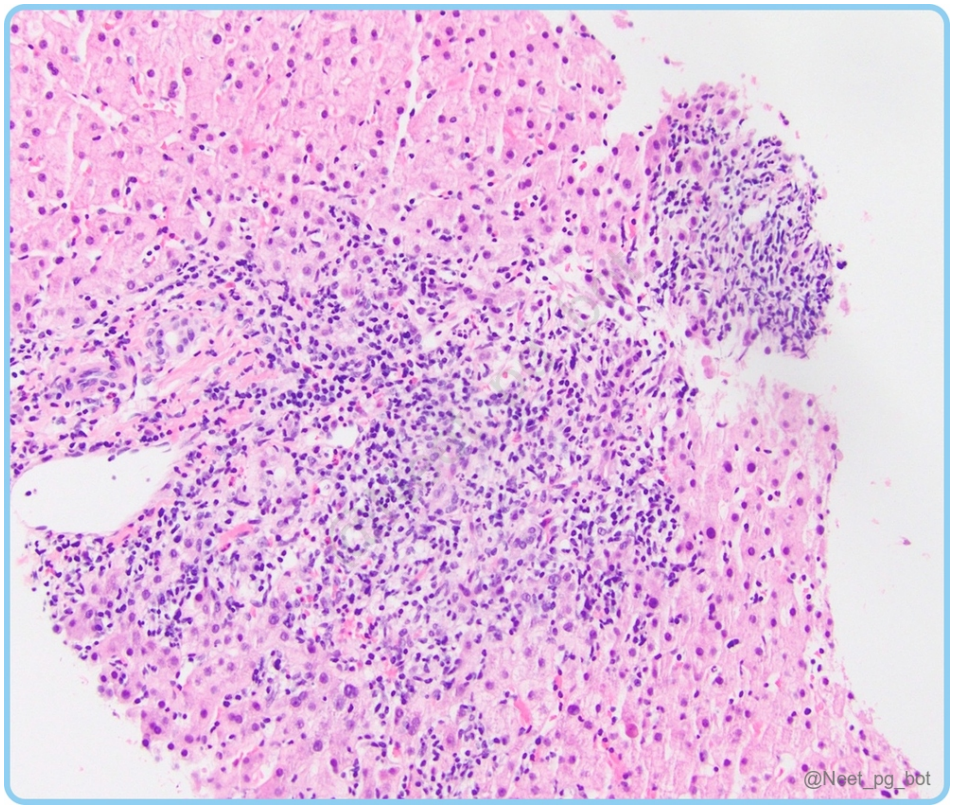

References:

Harrison’s Principles of Internal Medicine, 21st Edition, Page 2627

↑ *Back to this question in Part A*

@Neet_pg_bot

Q22: Which of the following statements regarding Autoimmune Hepatitis is False? (Q851301)

A. SGPT is significantly raised

B. Albumin ↓ and γ-globulin ↑↑

C. It is a diagnosis of exclusion

D. RA factor is negative

Correct Answer: D. RA factor is negative

Explanation: Rheumatoid factor (RF) is an autoantibody that is primarily associated with rheumatoid arthritis but can also be found in various autoimmune conditions, including Autoimmune Hepatitis (AIH). In AIH, the presence of RF may indicate a broader autoimmune process rather than being specific to liver disease. SGPT : Significantly raised. (Option A ruled out) Albumin ↓ and γ-globulin ↑↑ (Option B ruled out) (change in albumin globulin ratio), as no catabolism of this protein occurs, it keeps elevating. It is a diagnosis of exclusion (Option C ruled out)

References:

Harrison's Principles of Internal Medicine, 21st Edition, Pages 2613, 2614, 2615

↑ *Back to this question in Part A*

@Neet_pg_bot

Q23: A 45-year-old woman presents with fatigue, jaundice, abdominal discomfort, and significant weight loss for three months. She reports itchy skin. Laboratory tests show elevated liver enzymes and positive antinuclear antibodies (ANA) and anti-smooth muscle antibodies (ASMA). She has a family history of autoimmune diseases. Which of the following clinical features is most commonly associated with the above scenario? (Q851300)

A. Splenomegaly

B. Weight gain

C. Presence of anti-mitochondrial antibodies (AMA)

D. Elevated alkaline phosphatase levels

Correct Answer: A. Splenomegaly

Explanation: Splenomegaly is commonly associated with autoimmune hepatitis due to portal hypertension and liver dysfunction. Weight gain (Option B) : Weight gain is not typical; patients usually experience weight loss due to anorexia and systemic symptoms. Presence of anti-mitochondrial antibodies (AMA) (Option C) : AMA is primarily associated with primary biliary cholangitis, not autoimmune hepatitis. Elevated alkaline phosphatase levels (Option D) : Elevated alkaline phosphatase is usually indicative of cholestatic liver disease and is not a common feature of autoimmune hepatitis.

References:

Harrison's Principles of Internal Medicine, 21st Edition, Pages 2614, 2615

https://www.ncbi.nlm.nih.gov/books/NBK413/

↑ *Back to this question in Part A*

• [09_Hepatobiliary System] 070 Liver Cirrhosis And Its Complications

« Back to Folder Directory

[09_Hepatobiliary System] 070 Liver Cirrhosis And Its Complications — Quick Jump

Q1 (p. 2765)	*Q2 (p. 2766)*	*Q3 (p. 2767)*	*Q4 (p. 2768)*	*Q5 (p. 2768)*	*Q6 (p. 2769)*
Q7 (p. 2770)	*Q8 (p. 2771)*	*Q9 (p. 2774)*	*Q10 (p. 2775)*	*Q11 (p. 2775)*	*Q12 (p. 2778)*
Q13 (p. 2779)	*Q14 (p. 2779)*	*Q15 (p. 2781)*	*Q16 (p. 2782)*	*Q17 (p. 2782)*	*Q18 (p. 2783)*
Q19 (p. 2784)	*Q20 (p. 2785)*	*Q21 (p. 2786)*			

Q1: A 55-year-old male with a history of liver cirrhosis presents to the emergency department with hematemesis and signs of shock. He is diagnosed with acute variceal bleeding. What is the most appropriate initial management? (Q851351)

A. Administer intravenous terlipressin followed by prophylactic intravenous antibiotics

B. Start intravenous antibiotics and perform urgent endoscopy for band ligation

C. Administer intravenous vasopressin and initiate fresh frozen plasma transfusion

D. Begin intravenous corticosteroids and monitor for signs of hepatic encephalopathy

Correct Answer: A. Administer intravenous terlipressin followed by prophylactic intravenous antibiotics

Explanation: First step in acute variceal bleeding with shock: Initial resuscitation with fluids and blood products is also crucial to stabilize the patient. Terlipressin : A vasopressin analog that reduces portal pressure and controls variceal bleeding. Prophylactic antibiotics : Prevent spontaneous bacterial peritonitis and sepsis , which are common in cirrhotic patients with GI bleeding. Start intravenous antibiotics and perform urgent endoscopy for band ligation (Option B): Endoscopy is therapeutic, but hemodynamic stabilization and vasoactive therapy should come first in a patient with shock. Administer intravenous vasopressin and initiate fresh frozen plasma transfusion (Option C): Vasopressin is less preferred due to systemic side effects; FFP is reserved for coagulopathy. Begin intravenous corticosteroids and monitor for signs of hepatic encephalopathy (Option D): Not indicated in acute variceal bleeding.

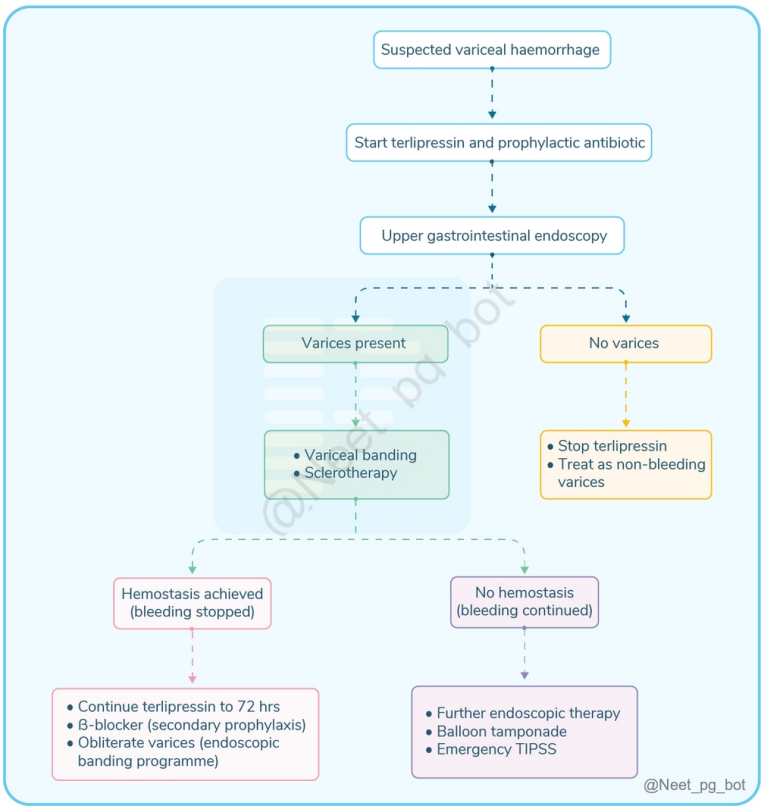

References:

Harrison’s Principles of Internal Medicine, 21st Edition, Volume I, Pages 2630-2631.

Davidson’s Principles and Practice of Medicine, 24th Edition, Pages 869-871.

↑ *Back to this question in Part A*

@Neet_pg_bot

Q2: A 50-year-old male with a history of alcohol abuse and long-term hypertension presents with hematemesis, abdominal distension, and splenomegaly. He is hypotensive and tachycardic, with elevated liver enzymes, low platelets, and a high INR. Endoscopy reveals esophageal varices. Which of the following most likely explains the development of this condition? (Q851361)

A. Portal venous thrombosis leads to increased collateral circulation

B. Increased portal blood flow to the liver

C. Increased portal pressure forcing blood into collateral vessels

D. Reduced portal vascular resistance

Correct Answer: C. Increased portal pressure forcing blood into collateral vessels

Explanation: The patient appears to have cirrhosis resulting from chronic alcohol use, complicated by the development of esophageal varices. The pathophysiology of esophageal varices in this context is mainly due to portal hypertension associated with cirrhosis. Pathophysiology of esophageal:

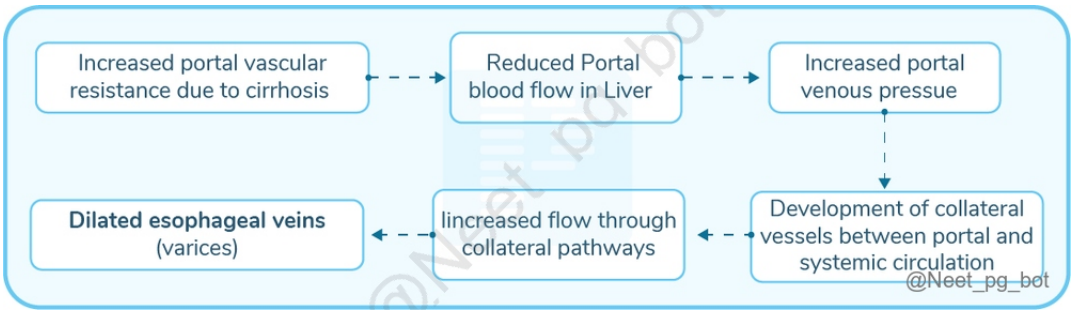

References:

Davidson's Principles and Practice of Medicine, 24th Edition, Page 869.

↑ *Back to this question in Part A*

@Neet_pg_bot

Q3: A 62-year-old man with alcoholic cirrhosis presents to the emergency department with confusion, disorientation, and asterixis. His family reports increasing drowsiness and difficulty concentrating over the past few days. Investigations reveal normal electrolytes and elevated ammonia levels. What is the most appropriate initial treatment to lower ammonia? (Q851360)

A. Increase the protein intake

B. Zinc supplementation

C. Rifaximin

D. Lactulose

Correct Answer: D. Lactulose

Explanation: In this clinical scenario, the patient is likely experiencing hepatic encephalopathy due to elevated ammonia levels associated with alcoholic cirrhosis. The most appropriate initial treatment to lower ammonia is Lactulose. It is a nonabsorbable disaccharide that acidifies the colon , converting ammonia (NH3) into ammonium (NH4+). It aids in removing nitrogenous products from the gut that contribute to encephalopathy and acts as a laxative. Management of Hepatic Encephalopathy: Lactulose Rifaximin (Option C) reduces ammonia production; it is an adjunctive therapy in patients who do not tolerate lactulose. Neomycin is an alternative to Rifaximin.

Branched-chain amino acids and probiotics Zinc supplementation (Option B) , used as adjunct therapy Restricted protein intake (Option A) was used in the past but is not commonly used due to its risk of malnutrition outweighing the benefits IV hydration is a vital supportive measure

References:

Harrison’s Principles of Internal Medicine, 21st Edition, Pages 2632, 2633

my.clevelandclinic.org/health/diseases/21220-hepatic-encephalopathy

↑ *Back to this question in Part A*

@Neet_pg_bot

Q4: A 60-year-old woman with decompensated cirrhosis due to hepatitis B presents for evaluation of liver transplantation. All the following are indications for liver transplantation except? (Q851359)

A. Autoimmune hepatitis

B. Caroli’s disease

C. Fulminant hepatitis

D. Portal vein thrombosis

Correct Answer: D. Portal vein thrombosis

Explanation: Portal vein thrombosis is considered a relative contraindication for liver transplantation as it can affect the viability of the donor's liver and complicate the transplantation process by disrupting the normal blood flow to the liver. It is not an absolute contraindication because portal vein thrombosis can be managed by grafting the donor's portal vein to the recipient's superior mesenteric vein , ensuring adequate venous drainage. Absolute Contraindications Relative Contraindications Active sepsis Substance abuse Severe cardiopulmonary disease Extra-hepatobiliary malignancy / metastasis AIDS / severe systemic disorders Elderly age (>70) Renal failure not due to liver disease Portal vein thrombosis Severe obesity or malnutrition Non-compliance with medications Uncontrolled psychiatric disorder Autoimmune hepatitis (Option A) , Caroli’s disease (Option B) , and Fulminant hepatitis (Option C) are all indications of liver transplant.

References:

Harrison’s Principles of Internal Medicine, 21st Edition, Pages 2634, 2635, 2636, 2537.

↑ *Back to this question in Part A*

@Neet_pg_bot

Q5: A 62-year-old male with a history of cirrhosis due to chronic hepatitis C presents with worsening abdominal distension, jaundice, and decreased urine output over the past week. He exhibits signs of confusion and ascites resistant to diuretics. Laboratory tests reveal a serum creatinine level of 2.5 mg/dL. Given this presentation, which of the following is the most definitive management of this condition? (Q851358)

A. Hemodialysis

B. Liver transplantation

C. Vasoconstrictor therapy with Terlipressin

D. Albumin infusion

Correct Answer: B. Liver transplantation

Explanation: The patient's condition is hepatorenal syndrome (HRS). While it is initially managed with albumin infusion and vasoconstrictors (such as terlipressin, octreotide, or midodrine), liver transplantation remains the most definitive and effective treatment for HRS. Management of hepatorenal Syndrome (HRS): Definitive treatment: Orthoptic liver transplant (OLT) Pharmacological treatment: Following drugs can be used Albumin infusion with vasoconstrictors (terlipressin, octreotide, midodrine) (Option C & D) Norepinephrine can also be used. Hemodialysis is not used mostly as it does not improve the outcome of the condition (Option A)

References:

Harrison’s Principles of Internal Medicine, 21st Edition, Volume I, Page 2632.

Davidson’s Principles and Practice of Medicine, 24th Edition, Page 864.

↑ *Back to this question in Part A*

@Neet_pg_bot

Q6: A 54-year-old female with diabetes, obesity, and recent laparoscopic surgery presents to the emergency department with high fever, chills, rapid heart rate, extreme fatigue, and worsening abdominal pain. The physician suspects Systemic Inflammatory Response Syndrome (SIRS) and decides to perform an investigation as part of the diagnostic criteria. Which investigation should be performed? (Q851357)

A. Blood culture

B. Urine culture

C. Urine routine microscopy

D. Complete blood count

Correct Answer: D. Complete blood count

Explanation: A Complete Blood Count (CBC) is essential in evaluating Systemic Inflammatory Response Syndrome (SIRS) as it helps identify leukocytosis (elevated white blood cell count), which is one of the diagnostic criteria for SIRS. SIRS (Systemic Inflammatory Response Syndrome): A sepsis-like condition associated with systemic inflammation that can be triggered by various non-microbial factors (burns, trauma, infections). Criteria for diagnosis: 2 or more of the following components should be present to confirm the diagnosis of SIRS. Temperature (fever): Hyperthermia (fever) >38°C (>100.4°F) or Hypothermia <36°C (<96.8°F) Leukocyte (white blood cell) count: Leukocytosis >12,000/µL or Leukopenia <4000/µL Respiratory rate or ABG showing: Tachypnea (>20 beats per minute) or partial pressure of CO2 less than 32 mmHg, respectively. Heart rate: Tachycardia (>90 beats per minute) Blood culture (Option A) is performed to check for sepsis. If SIRS is left untreated, it can progress to sepsis, indicated by a positive blood culture in addition to SIRS. Urine culture (Option B) and Urine routine microscopy (Option C) can also be helpful in management, but they are not included in the criteria for SIRS.

References:

Harrison's Principles of Internal Medicine, 21st Edition, Volume I, Page 2242.

Robbins and Cotran's Pathologic Basis of Diseases, 10th Edition, Page 135.

↑ *Back to this question in Part A*

@Neet_pg_bot

Q7: A 62-year-old male with malnutrition and alcoholic liver disease presents with increasing abdominal distension, shortness of breath, fever, and significant weight loss. The ascitic fluid shows a neutrophil count greater than 250/µL. Which of the following statements about this condition are true? 1. Ascitic fluid appears transparent 2. Most commonly caused by Escherichia coli 3. Cefotaxime can be used for treatment 4. Norfloxacin administration may help to prevent it (Q851356)

A. 1, 2, 3

B. 1, 2, 4

C. 2, 3, 4

D. 1, 2, 3, 4

Correct Answer: C. 2, 3, 4

Explanation: In this scenario, a malnourished patient with a history of alcoholic liver disease presents with ascites, fever, and ascitic fluid showing a neutrophil count greater than 250/µL, indicating a diagnosis of Spontaneous Bacterial Peritonitis (SBP) , with the ascitic fluid appearing turbid due to pus. Ascitic fluid analysis shows: Turbid appearance (Statement 1) {{caption_text}} Causative organism: Escherichia coli (most common) and other gut bacteria (Statement 2) Management: IV 3rd generation cephalosporins (cefotaxime) for 5 days (Statement 3) Prevention: Norfloxacin administration (cirrhotic patients with an episode of SBP) (Statement 4)



References:

Harrison’s Principles of Internal Medicine, 21st Edition, Volume I, Pages 324, 2632.

Davidson’s Principles and Practice of Medicine, 24th Edition, Page 864.

↑ *Back to this question in Part A*

@Neet_pg_bot

Q8: A 70-year-old male with a history of congestive heart failure, hypertension, and chronic kidney disease is scheduled for a procedure as depicted in the image below. What is the name of the procedure? {{caption_text}} (Q851355)

A. Pericardiocentesis

B. Thoracentesis

C. Paracentesis

D. Diagnostic peritoneal lavage



Correct Answer: C. Paracentesis

Explanation: In this case, the patient with a history of congestive heart failure, hypertension, and chronic kidney disease is undergoing Paracentesis (the removal of fluid from the abdominal cavity), as shown in the image. It is a bedside procedure in which a needle or small catheter is inserted transcutaneously to extract ascitic fluid from the peritoneal cavity. It is both diagnostic and therapeutic. Site: Left lower quadrant Procedure: The needle is inserted (USG guided) at a 45-degree angle using the Z-track technique (minimise leakage following the procedure). Pericardiocentesis (Option A) is a medical procedure that involves inserting a needle into the pericardial cavity for therapeutic and diagnostic purposes. It is typically performed in conditions like cardiac tamponade. {{caption_text}} Thoracentesis (Option B) is a medical procedure that involves inserting a needle or catheter into the pleural space of the chest to remove fluid or air for diagnostic or therapeutic reasons. {{caption_text}} Diagnostic peritoneal lavage (Option D) is used to assess intra-abdominal bleeding, typically in trauma cases, not for chronic fluid accumulation like ascites.



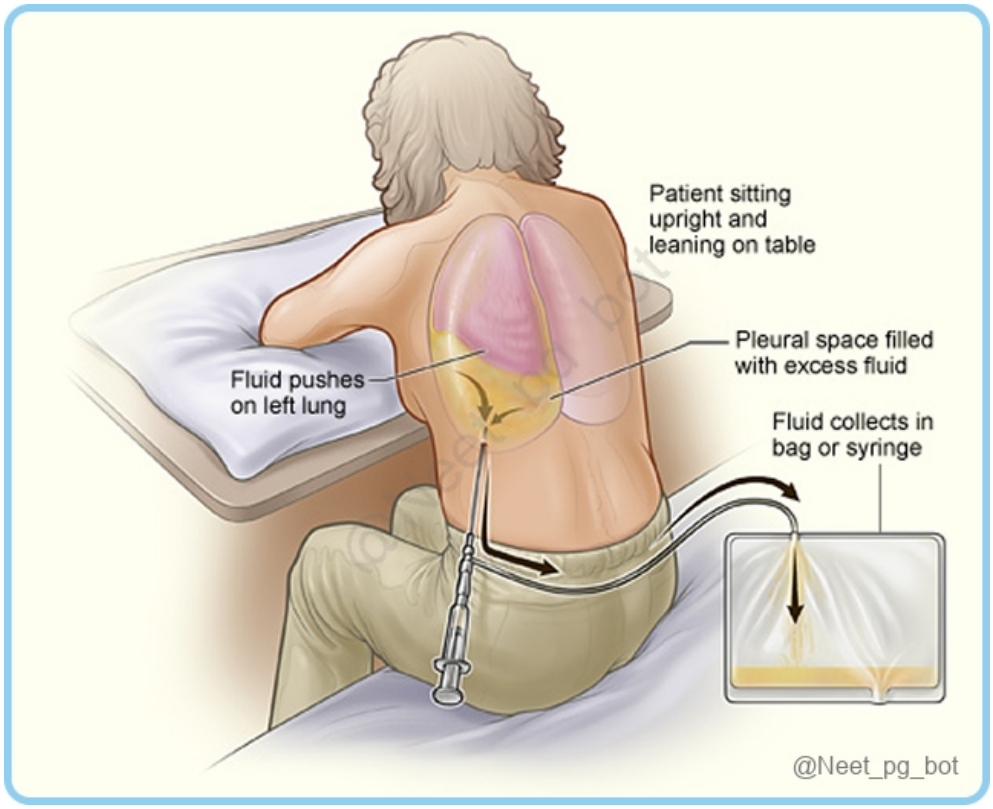

References:

Harrison's Principles of Internal Medicine, 21st Edition, Volume I, Page 323.

Davidson’s Principles and Practice of Medicine, 24th Edition, Page 863.

↑ *Back to this question in Part A*

@Neet_pg_bot

Q9: A 58-year-old female with chronic alcoholism, hepatitis C, and hypertension presents with abdominal distension, shortness of breath while lying flat, and fatigue. Ultrasound shows splenomegaly and an increased amount of peritoneal fluid. What are the expected serum-ascites albumin gradient (SAAG) and ascitic protein levels in this case? (Q851354)

A. <1.1 g/dL and <2.5 g/dL

B. ≥1.1 g/dL and <2.5 g/dL

C. <1.1 g/dL and ≥2.5 g/dL

D. ≥1.1 g/dL and ≥2.5 g/dL

Correct Answer: B. ≥1.1 g/dL and <2.5 g/dL

Explanation: The patient likely has ascites due to portal hypertension , commonly associated with cirrhosis from chronic alcoholism and hepatitis C. In such cases, the serum-ascites albumin gradient (SAAG) is typically ≥1.1 g/dL, indicating portal hypertension. The ascitic protein level is usually <2.5 g/dL, reflecting low protein transudative fluid associated with cirrhosis. The SAAG reflects hepatic sinusoidal pressure and correlates with the hepatic venous pressure gradient, calculated by subtracting the ascitic albumin from the serum albumin (there is no effect of diuresis).

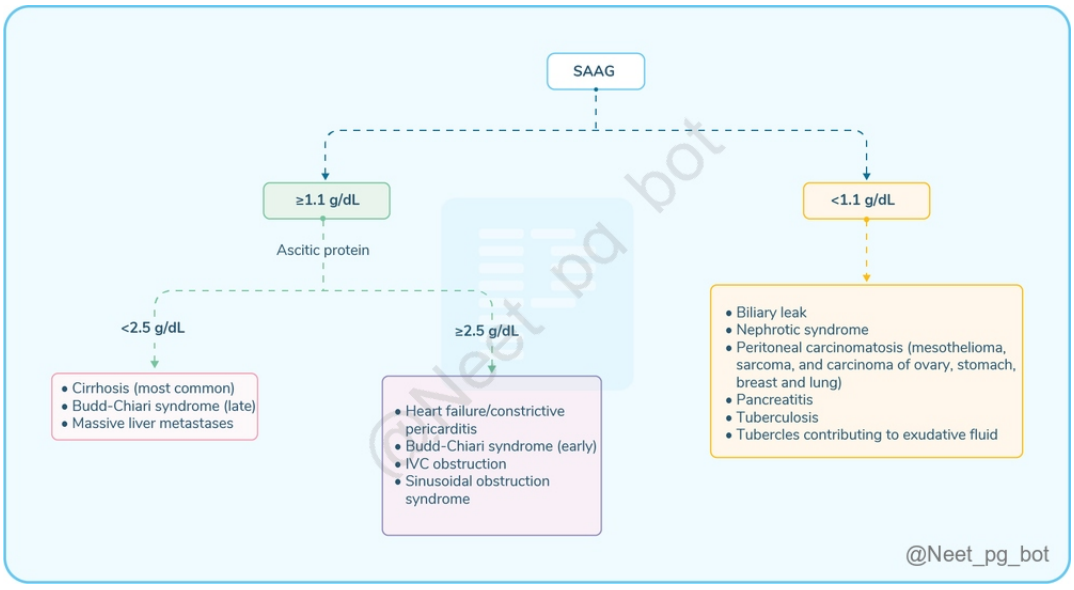

References:

Harrison’s Principles of Internal Medicine, 21st Edition, Volume I, Page 323.

Davidson’s Principles and Practice of Medicine, 24th Edition, Page 863.

↑ *Back to this question in Part A*

@Neet_pg_bot

Q10: A 62-year-old male with chronic liver disease, hepatitis C, and diabetes presents to the emergency department with worsening abdominal distension, shortness of breath, and fatigue. His swelling has worsened despite cutting sodium intake and increasing diuretics, and a fluid thrill is noted on examination. Which of the following medications is contraindicated in this case? (Q851353)

A. Clonidine

B. Amiloride

C. Midodrine

D. Propranolol

Correct Answer: D. Propranolol

Explanation: The scenario describes refractory ascites that is unresponsive to sodium restriction and increased diuretics. Propranolol , a non-selective beta-blocker, is contraindicated as it can reduce cardiac output and worsen outcomes by negatively affecting hemodynamics. Management of r efractory ascites: Amiloride (Option B): diuretic Midodrine (Option C) : alpha-1 agonist, vasoconstrictor, causes vasoconstriction of the splanchnic artery Clonidine (Option A): alpha-2 agonist, vasoconstrictor

References:

Harrison’s Principles of Internal Medicine, 21st Edition, Volume I, Pages 2631, 2632.

Davidson’s Principles and Practice of Medicine, 24th Edition, Pages 863, 864.

↑ *Back to this question in Part A*

@Neet_pg_bot

Q11: A 58-year-old man with chronic hepatitis and alcohol use presents with abdominal distension, discomfort, shortness of breath, and a weight gain of 5 kg over

two weeks. Physical examination reveals thrombocytopenia, splenomegaly, and ascites. With approximately 120 mL of peritoneal fluid, which physical examination sign is most likely to be observed? (Q851352)

A. Fluid thrill

B. Shifting dullness

C. Puddle sign

D. All of the above

Correct Answer: C. Puddle sign

Explanation: The puddle sign is most sensitive for detecting small volumes of ascitic fluid (~100–500 mL) . In this patient with ~120 mL of fluid, it is the physical exam maneuver most likely to detect ascites. Shifting dullness (peritoneal fluid >500ml) (Option B) In a supine position, a healthcare provider percusses the abdomen to identify dullness (fluid) and resonance (air). When the patient turns to one side, the fluid shifts, causing dullness to move to the dependent side and resonance to appear on the upper side, indicating ascitic fluid. Fluid thrill or fluid wave test (Option A) The fluid thrill is a sign of large abdominal fluid volumes (more than 1.5 Liters). It occurs when a provider taps one side of the abdomen while feeling the opposite, creating a wave indicating ascites.
{{caption_text}}

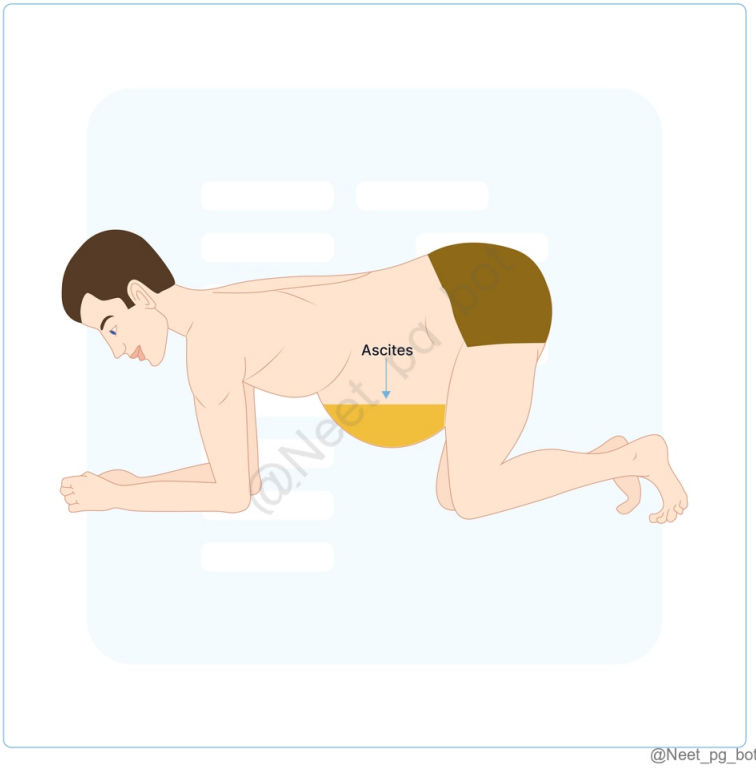





References:

Harrison’s Principles of Internal Medicine, 21st Edition, Volume I, Page 2631.

Davidson’s Principles and Practice of Medicine, 24th Edition, Pages 862, 863

↑ *Back to this question in Part A*

@Neet_pg_bot

Q12: A 52-year-old male presents with progressive fatigue, abdominal distension, and worsening jaundice over the past three months. Examination reveals ascites, spider angiomata, and palmar erythema. Laboratory tests show elevated liver enzymes with a significantly elevated AST/ALT ratio, and an ultrasound indicates a nodular liver. What role do kupffer cells play in the pathogenesis of this condition? (Q851339)

A. Activate CYP2E1

B. Increase the fatty acid uptake

C. Convert acetaldehyde to acetate

D. Induce cytokine production

Correct Answer: D. Induce cytokine production

Explanation: The clinical presentation suggests alcoholic cirrhosis , indicated by symptoms, an elevated AST/ALT ratio, and nodular liver on ultrasound. In alcoholic liver disease , Kupffer cells (liver macrophages) are activated by gut-derived endotoxins (LPS) and alcohol, leading to release of pro-inflammatory cytokines such as TNF-α, IL-1, and IL-6 , which drive hepatocyte injury, inflammation, and fibrosis. {{caption_text}} Activate CYP2E1 (Option A): CYP2E1 is primarily a hepatocyte enzyme, not Kupffer cell–mediated. Increase the fatty acid uptake (Option B): Mediated by hepatocytes and stellate cells, not Kupffer cells. Convert acetaldehyde to acetate (Option C): Done by hepatocyte aldehyde dehydrogenase, not Kupffer cells.

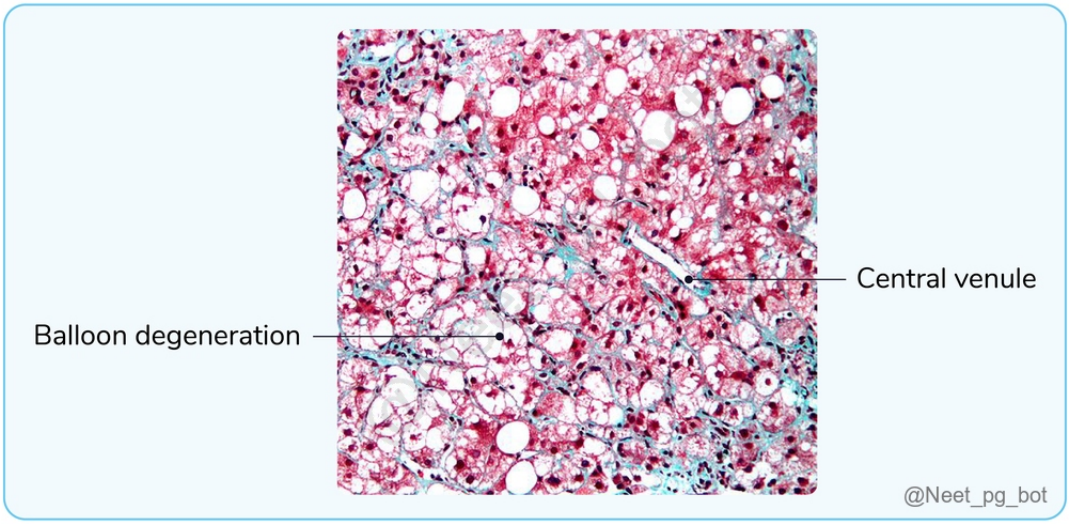

References:

Harrison’s Principles of Internal Medicine, 21st Edition, Pages 2624, 2625

↑ *Back to this question in Part A*

@Neet_pg_bot

Q13: A 60-year-old male with a history of alcohol use and chronic hepatitis presents with abdominal swelling, fatigue, difficulty eating, dark stools, and black vomitus. Examination shows splenomegaly, ascites and dilated veins around the umbilicus. Which of the following is the investigation of choice for this condition? (Q851348)

A. CT imaging

B. Blood counts

C. Endoscopy

D. Doppler ultrasound

Correct Answer: D. Doppler ultrasound

Explanation: This patient has classic features of portal hypertension due to chronic liver disease. The investigation of choice to diagnose portal hypertension and assess portal venous flow is Doppler Ultrasound. CT and MRI Scan (Option A): Assess the extent of portal vein thrombosis and evaluate hepatic vein patency. Blood Counts (CBC) (Option B): First biochemical sign is thrombocytopenia (due to hypersplenism). It also shows leukopenia and anaemia. Endoscopy (Option C): Used to check for gastro-oesophageal varices.

References:

Harrison’s Principles of Internal Medicine, 21st Edition, Volume I, Pages 2629, 2630.

Davidson’s Principles and Practice of Medicine, 24th Edition, Page 870.

↑ *Back to this question in Part A*

@Neet_pg_bot

Q14: A 58-year-old obese female with a history of DVT and recent appendectomy presents with worsening abdominal pain, swelling, fatigue, dark stools, and leg swelling. Examination reveals splenomegaly and findings, which are shown in the image below. Which of the following pathologies is most likely responsible for this

condition? (Q851347)

A. Constrictive pericarditis

B. Veno-occlusive disease

C. Portal vein thrombosis

D. Inferior vena caval webs



Correct Answer: C. Portal vein thrombosis

Explanation: The scenario presented, featuring a history of DVT and recent appendectomy, along with splenomegaly, dark stools (hematochezia), and caput medusae (above image), indicates a diagnosis of Portal Hypertension , most likely due to portal vein thrombosis. Causes of Portal Hypertension Pre-hepatic causes Hepatic causes Post-hepatic causes Portal vein thrombosis (Option C) Splenic vein thrombosis Banti syndrome Pre-sinusoidal Schistosomiasis Congenital hepatic fibrosis Sinusoidal Cirrhosis Alcoholic hepatitis Post-sinusoidal Veno-occlusive disease (Option B) Radiation Herbal tea Endemic ascites Budd Chiari Syndrome Inferior vena cava webs (Option D) Restrictive cardiomyopathy Constrictive pericarditis (Option A) Severe congestive heart failure

References:

Harrison’s Principles of Internal Medicine, 21st Edition, Volume I, Page 2629.

Davidson’s Principles and Practice of Medicine, 24th Edition, Page 868.

↑ *Back to this question in Part A*

@Neet_pg_bot

Q15: A 55-year-old male with a history of chronic alcohol use presents with worsening abdominal swelling, fatigue, dizziness, increased abdominal size, and loss of appetite. Examination shows a hepatic venous pressure gradient (HVPG) of over 5 mm Hg. What is one of the earliest signs of this condition? (Q851346)

A. Puddle sign

B. Splenomegaly

C. Coffee ground vomitus

D. Caput medusae

Correct Answer: B. Splenomegaly

Explanation: The patient’s history of chronic alcohol use, along with symptoms like abdominal swelling and an HVPG over 5 mm Hg, suggests portal hypertension , which occurs when there is increased pressure within the portal venous system. Splenomegaly is one of the earliest signs of portal hypertension , caused by congestion in the splenic vein due to increased portal pressure. {{caption_text}} Puddle sign (Option A): Detects ascites, a later manifestation. Coffee ground vomitus (Option C): Suggests upper GI bleeding, a complication of portal hypertension. Caput medusae (Option D): Dilated abdominal veins, appears in advanced portal hypertension.

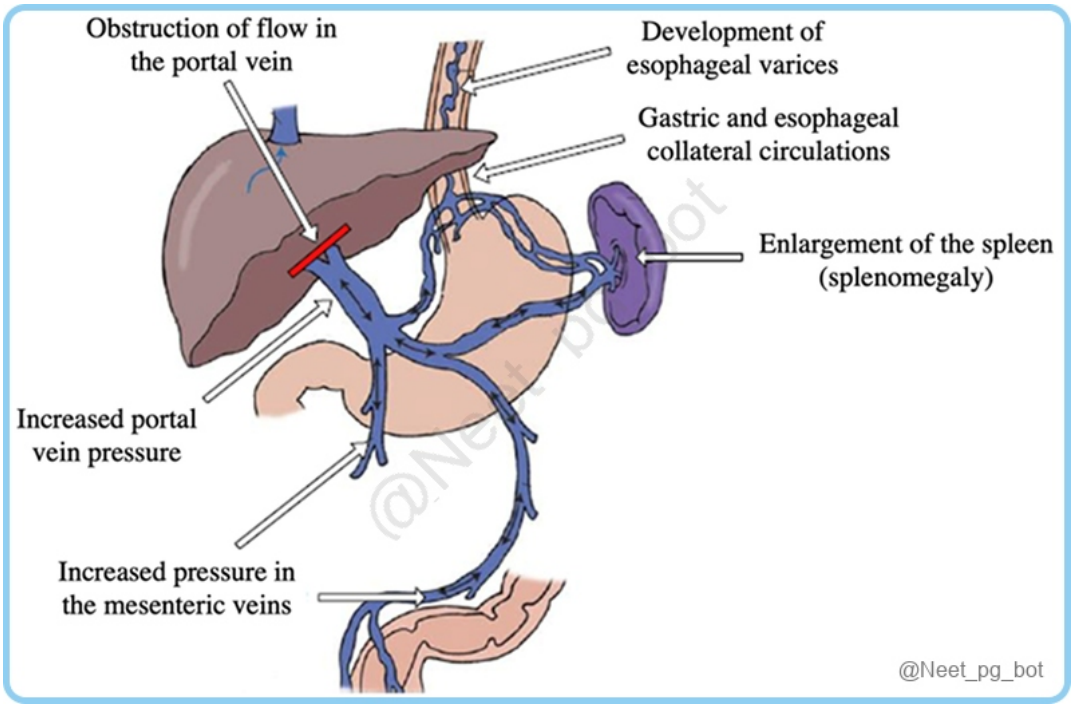

References:

Harrison’s Principles of Internal Medicine, 21st Edition, Volume I, Page 2629.

Davidson’s Principles and Practice of Medicine, 24th Edition, Pages 868, 869.

B.D. Chaurasia’s Textbook of Human Anatomy, 8th Edition, Volume II, Pages 332, 333.

↑ *Back to this question in Part A*

@Neet_pg_bot

Q16: A 52-year-old male with chronic hepatitis presents with fatigue, mild abdominal discomfort, decreased appetite, and occasional jaundice over the past few months but denies significant weight loss or night sweats. A liver biopsy showed fibrosis with expansion of most portal zones and occasional bridging. What Metavir fibrosis stage does this indicate? (Q851345)

A. F1

B. F2

C. F3

D. F4

Correct Answer: B. F2

Explanation: The Metavir fibrosis scoring system categorises stage F2 as fibrosis characterised by the expansion of most portal zones and occasional bridging. Fibrosis extent in liver biopsies is usually assessed using the METAVIR or Ishak scales. METAVIR fibrosis scale METAVIR score Stage of fibrosis F0 No fibrosis F1 (Option A) Portal zone fibrosis (few) F2 (Option B) Portal zone fibrosis and occasional (few) bridging. F3 (Option C) Portal zone fibrosis, marked bridging, and occasional nodules F4 (Option D) Cirrhosis

References:

Harrison’s Principles of Internal Medicine, 21st Edition, Volume I, Page 2593.

Davidson’s Principles and Practice of Medicine, 24th Edition, Page 878.

↑ *Back to this question in Part A*

@Neet_pg_bot

Q17: A 47-year-old woman with a history of non-alcoholic fatty liver disease (NAFLD) presents for routine follow-up. She reports mild fatigue but denies significant abdominal pain or jaundice. On examination, she has no stigmata of chronic liver disease. The physician wants to assess the degree of liver fibrosis. Which of the following is the best non-invasive test to evaluate liver stiffness? (Q851344)

A. Computed tomography

B. Abdominal ultrasound

C. Magnetic resonance imaging

D. Transient elastography

Correct Answer: D. Transient elastography

Explanation: Transient elastography, also called fibroscan , uses a specialised ultrasound device to measure liver stiffness by emitting a series of low-frequency vibrations (or shear waves) into the liver . Computed Tomography (Option A) can provide detailed images of liver morphology and help identify lesions; it does not measure liver stiffness directly. Its primary use is in detecting structural abnormalities rather than evaluating fibrosis. Ultrasound (Option B) is used as an initial investigation. It provides information on liver morphology and assesses complications like portal hypertension. It can provide general information about liver conditions but lacks the specificity for assessing fibrosis levels. Magnetic resonance imaging (Option C) is useful for visualising liver anatomy and detecting lesions; however, like CT scans, it does not directly measure liver stiffness.

References:

Harrison’s Principles of Internal Medicine, 21st Edition, Page 2556.

↑ *Back to this question in Part A*

@Neet_pg_bot

Q18: A 58-year-old female with a history of chronic hepatitis C and cirrhosis presents with increasing abdominal distension, jaundice, and fatigue. On examination, she has ascites and spider nevi. Laboratory tests reveal elevated bilirubin levels, low albumin, and elevated liver enzymes. All of the following are criteria for Child-Pugh score classification except? (Q851343)

A. Ascites

B. Albumin

C. Bilirubin

D. AST/ALT

Correct Answer: D. AST/ALT

Explanation: The Child-Pugh classification is employed to assess the severity of liver disease, predict prognosis for liver cirrhosis, and determine a patient's eligibility for liver transplantation. It does not include liver enzymes like AST/ALT under the criteria. Child-Pugh classification Parameters 1 2 3 Encephalopathy None Grade 1-2 (Minimal) Grade 3-4 (Advanced) Ascites None Mildly controlled Poorly controlled Bilirubin (mg/dL) < 2 2 - 3 > 3 Albumin (g/dL) > 3.5 3 - 3.5 < 3.5 INR < 1.7 1.7 - 2.3 > 2.3 The Child-Turcotte-Pugh Class is determined by summing the scores for each parameter. Category A : 5-6 (Compensated cirrhosis) Category B : 7-9 (Decompensated cirrhosis) Category C : > 10

References:

Harrison’s Principles of Internal Medicine, 21st Edition, Page 2552

↑ *Back to this question in Part A*

@Neet_pg_bot

Q19: A 62-year-old male with cirrhosis presents to the emergency department with upper gastrointestinal bleeding and a Child-Pugh score of 10. Which scoring system is most appropriate for assessing his mortality risk related to liver disease? (Q851342)

A. PELD score

B. Rockall risk score

C. Forrest classification system

D. MELD score

Correct Answer: D. MELD score

Explanation: The Model for End-Stage Liver Disease (MELD) system assesses the severity of chronic liver disease and predicts survival , particularly in patients with cirrhosis. The parameters are Serum bilirubin INR Serum creatinine ± sodium PELD score (Option A): Used for pediatric liver disease, not adults. The parameters used are: Bilirubin, INR, albumin, age, growth failure Rockall risk score (Option B): Predicts rebleeding/mortality risk in upper GI bleeding, not chronic liver disease prognosis. Forrest classification (Option C): Used for endoscopic risk stratification of peptic ulcer bleeding, not cirrhosis-related mortality.

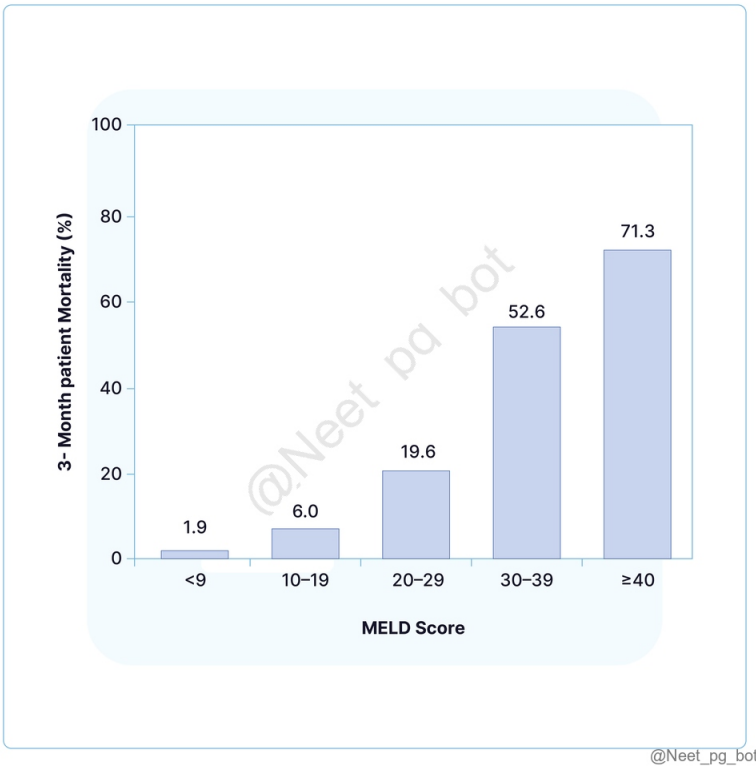

References:

Harrison’s Principles of Internal Medicine, 21st Edition, Page 2552

UptodateLink(Forrest classification)

MedscapeLink(Rockall risk score)

↑ *Back to this question in Part A*

@Neet_pg_bot

Q20: A 68-year-old man with a history of cirrhosis presents with increased fatigue, and examination reveals multiple vascular lesions on the skin. His liver function tests show significant elevations in AST and ALT. What is the primary pathophysiological mechanism responsible for the formation of these lesions in cirrhosis? (Q851341)

A. Due to engorged superficial veins

B. Chronic Hypoxia

C. Because of platelet-derived growth factor

D. Increased vascularity due to estrogen



Correct Answer: D. Increased vascularity due to estrogen

Explanation: The image depicts spider nevi , vascular lesions with a central arteriole and radiating small vessels, commonly seen in cirrhosis. Impaired liver function reduces estrogen metabolism, leading to increased estrogen levels, vasodilation, and increased vascularity, which form small, dilated blood vessels. Typically appear on the skin's surface in areas the superior vena cava supplies, such as the face, neck, and upper body. They can also be observed in conditions like pregnancy and rheumatoid arthritis. Engorged superficial veins (Option A): Describes caput medusae, not spider angiomas. Chronic hypoxia (Option B): Leads to clubbing, not vascular lesions. Platelet-derived growth factor (Option C): Involved in fibrogenesis, not vascular skin lesions.

References:

Harrison’s Principles of Internal Medicine, 21st Edition, Page 2625

Davidson’s Principles and Practice of Medicine, 24th Edition, Page 846

↑ *Back to this question in Part A*

@Neet_pg_bot

Q21: A 72-year-old male with chronic hepatitis C presents with severe fatigue, confusion, and increasing abdominal girth. Examination reveals jaundice, asterixis,

and bilateral oedema. Laboratory tests show elevated bilirubin, transaminases, prolonged prothrombin time, and thrombocytopenia. An endoscopy shows the presence of non-bleeding varices. What is the most likely diagnosis? (Q851340)

A. Compensated cirrhosis

B. Alcoholic hepatitis

C. Acute liver failure

D. Decompensated cirrhosis

Correct Answer: D. Decompensated cirrhosis

Explanation: Based on the clinical scenario provided, the most likely diagnosis is decompensated cirrhosis with portal hypertension, leading to the development of non-bleeding varices. Decompensated cirrhosis: Patients with cirrhosis who develop complications are considered decompensated, and prognosis is poor. Complications: Ascites, variceal bleed, jaundice, splenomegaly, portal hypertension, coagulopathy, bacterial peritonitis, hepatic encephalopathy, hepatorenal and hepatopulmonary syndromes. Compensated cirrhosis (Option A): Early stage; liver still functions, often asymptomatic or mild symptoms. Alcoholic hepatitis (Option B): Alcohol-induced inflammation with jaundice and liver dysfunction; less likely here due to chronic HCV. Acute liver failure (Option C): Rapid decline in a healthy liver (e.g., drugs, viral hepatitis); not consistent with chronic HCV.

References:

Harrison’s Principles of Internal Medicine, 21st Edition, Pages 321, 2624

www.uptodate.com/contents/cirrhosis-in-adults-overview-of-complications-general-management-and-prognosis#H52738093

↑ *Back to this question in Part A*

@Neet_pg_bot

• [09_Hepatobiliary System] 071 Wilson Disease And Hemochromatosis

« Back to Folder Directory

[09_Hepatobiliary System] 071 Wilson Disease And Hemochromatosis — Quick Jump

Q1 (p. 2788) *Q2 (p. 2790)* *Q3 (p. 2791)* *Q4 (p. 2791)* *Q5 (p. 2795)* *Q6 (p. 2795)*
Q7 (p. 2799) *Q8 (p. 2799)* *Q9 (p. 2800)* *Q10 (p. 2801)* *Q11 (p. 2802)* *Q12 (p. 2803)*
Q13 (p. 2804)

Q1: A 25-year-old male presents with fatigue, tremors, jaundice, and cognitive impairment. On examination, hepatomegaly is noted, and an ophthalmologic evaluation reveals a distinctive finding. Laboratory tests show elevated liver enzymes and increased copper levels. What is the underlying pathological mechanism causing this condition? (Q851384)

A. Reduced renal filtration of copper

B. Increased degradation of ceruloplasmin

C. Defective biliary excretion of copper

D. Impaired hepatic metabolism of ceruloplasmin



Correct Answer: C. Defective biliary excretion of copper

Explanation: Wilson's disease is a genetic disorder of copper metabolism due to defective biliary excretion of copper caused by mutations in the ATP7B gene. This leads to copper buildup, primarily in the liver, causing hepatocellular damage, as seen with elevated liver enzymes, hepatomegaly, and jaundice. Excess copper also deposits in the brain, resulting in neurological symptoms like tremors and cognitive impairment. Diagnosis is further supported by elevated copper levels, decreased ceruloplasmin levels and presence of Kayser-Fleischer rings, which are copper deposits found in the cornea. Pathogenesis: Genetic Defect (ATP7B mutation): autosomal recessive → Impaired biliary copper excretion → Copper accumulation in hepatocytes → Oxidative liver damage & inflammation → Exceeding liver storage capacity → Copper released into bloodstream → Systemic accumulation (Brain, Cornea, Kidneys, Joints) → Tissue damage (Oxidative stress, Lipid peroxidation, Enzyme inhibition) Reduced renal filtration of copper (Option A): Not the primary defect. The kidney helps excrete copper only after serum levels rise. It's a secondary effect, not the cause. Increased degradation of ceruloplasmin (Option B): Ceruloplasmin is low in Wilson’s disease, but not due to increased degradation—it's due to impaired incorporation of copper into ceruloplasmin. Impaired hepatic metabolism of ceruloplasmin (Option D): Ceruloplasmin production is affected indirectly , but the primary defect is copper transport , not metabolism of the protein itself.

References:

Harrison's principles of internal medicine, 21st Edition, Page 3235.

Davidson's principles and practice of medicine, 24th Edition, Page 896,897.

↑ *Back to this question in Part A*

@Neet_pg_bot

Q2: A 9-month-old pediatric patient presents with hypotonia, seizures, and delays in achieving developmental milestones. The child exhibits characteristic facial features, including a prominent forehead, sparse eyebrows, and distinct hair appearance. Laboratory results reveal decreased levels of copper and ceruloplasmin. What is the pattern of inheritance for this condition? (Q851387)

A. Autosomal recessive

B. Mitochondrial inheritance

C. X-linked recessive

D. Autosomal dominant



Correct Answer: C. X-linked recessive

Explanation: The patient exhibits hypotonia, seizures, and developmental delays, along with characteristic facial features such as a prominent forehead, sparse eyebrows, and kinky hair. Laboratory tests reveal low levels of copper and ceruloplasmin. These clinical signs are consistent with Menkes disease, an X-linked recessive disorder caused by mutations in the ATP7A gene , leading to impaired copper transport and significant neurological deficits, predominantly affecting males. Autosomal recessive (Option A): Incorrect because Menkes disease follows an X-linked , not autosomal, inheritance pattern. Mitochondrial inheritance (Option B): Incorrect because mitochondrial disorders are maternally inherited and do not match the copper metabolism defect seen here.

Autosomal dominant (Option D): Incorrect because there is no dominant transmission pattern in Menkes; it is transmitted via the X chromosome.

References:

Harrison's principles of internal medicine, 21st Edition, Page 3236.

https://www.ncbi.nlm.nih.gov/books/NBK560917/

↑ *Back to this question in Part A*

@Neet_pg_bot

Q3: A 22-year-old male presents with symptoms of fatigue, jaundice, and abdominal pain. He also exhibits neurological manifestations, including tremors, dystonia, and personality changes. Laboratory investigations reveal elevated free serum copper levels, and liver function tests show increased ALT and AST. Based on these findings, which area of the brain is primarily implicated in the neurological symptoms of this condition? (Q851388)

A. Corpus callosum

B. Basal ganglia

C. Cerebellum

D. Hippocampus

Correct Answer: B. Basal ganglia

Explanation: The clinical scenario described is consistent with Wilson's disease, affecting the liver and brain. The neurological symptoms, such as tremors, dystonia, and personality changes, are primarily due to copper deposition in the basal ganglia, involved in the regulation of movement and coordination. The basal ganglia's dysfunction leads to the movement disorders and psychiatric symptoms observed in affected individuals, while the liver damage results in elevated liver enzymes and jaundice.

References:

Harrison's principles of internal medicine, 21st Edition, Page 3235,3236. Davidson's principles and practice of medicine, 24th Edition, Page 896,897. https://tinyurl.com/3ek9r4ym

↑ *Back to this question in Part A*

@Neet_pg_bot

Q4: During an eye camp, an elderly patient presented with a distinct ring around the cornea, as given below. The patient was referred to a higher centre for further evaluation. Several weeks later, the patient returned from the higher centre, reporting a progressive loss of vision. Upon examination, it was noted that a cataract had developed. Based on the initial observation and the current condition. Which of the following types of cataracts is most likely to be observed in this patient? (Q851389)

A. Stellate cataract

B. Snowflake cataract

C. Oil droplet cataract

D. Sunflower cataract



Correct Answer: D. Sunflower cataract

Explanation: The initial observation of a distinct ring around the cornea in an elderly patient is suggestive of a Kayser-Fleischer ring, which is typically associated with Wilson's disease. Upon the patient's return, the development of cataracts, particularly in the context of Wilson's disease, is most likely to present as a sunflower cataract. This type of cataract is characterised by a specific pattern of opacification that resembles the appearance of a sunflower and is associated with copper deposition in the lens. Type of Cataract Associated Conditions Sunflower Cataract (Option D) {{caption_text}} Wilson's disease (copper accumulation) Rosette/ Stellate Cataract (Option A) {{caption_text}} Trauma Snowflake Cataract (Option B) {{caption_text}} Diabetes mellitus, certain metabolic disorders Oil Droplet Cataract (Option C) {{caption_text}} Galactosemia

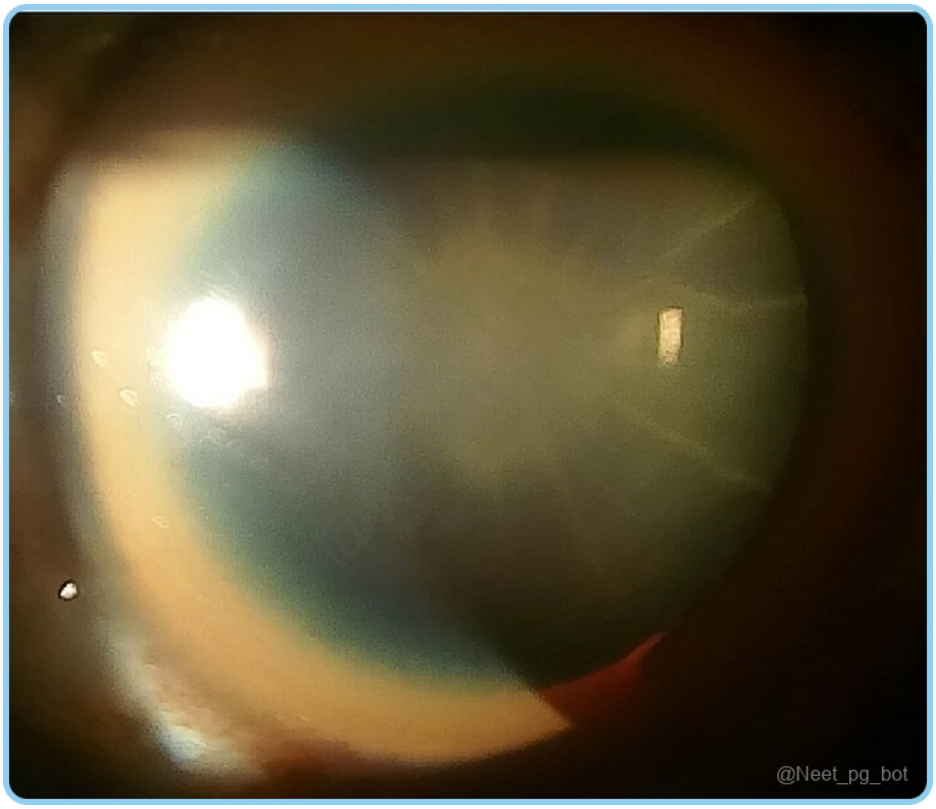
@Neet_pg_bot

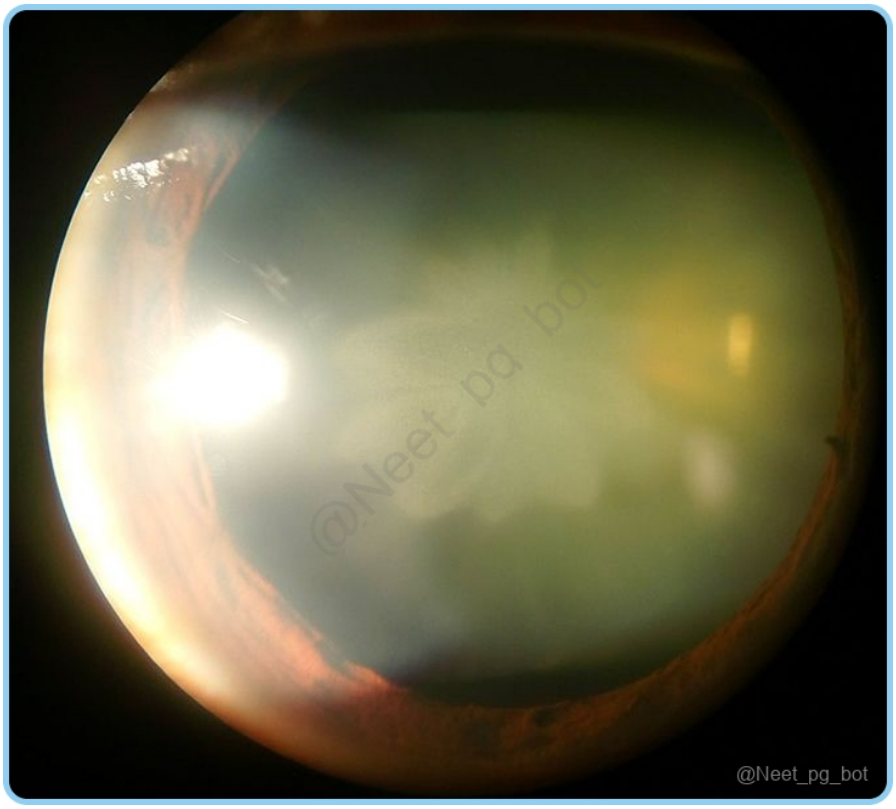
@Neet_pg_bot

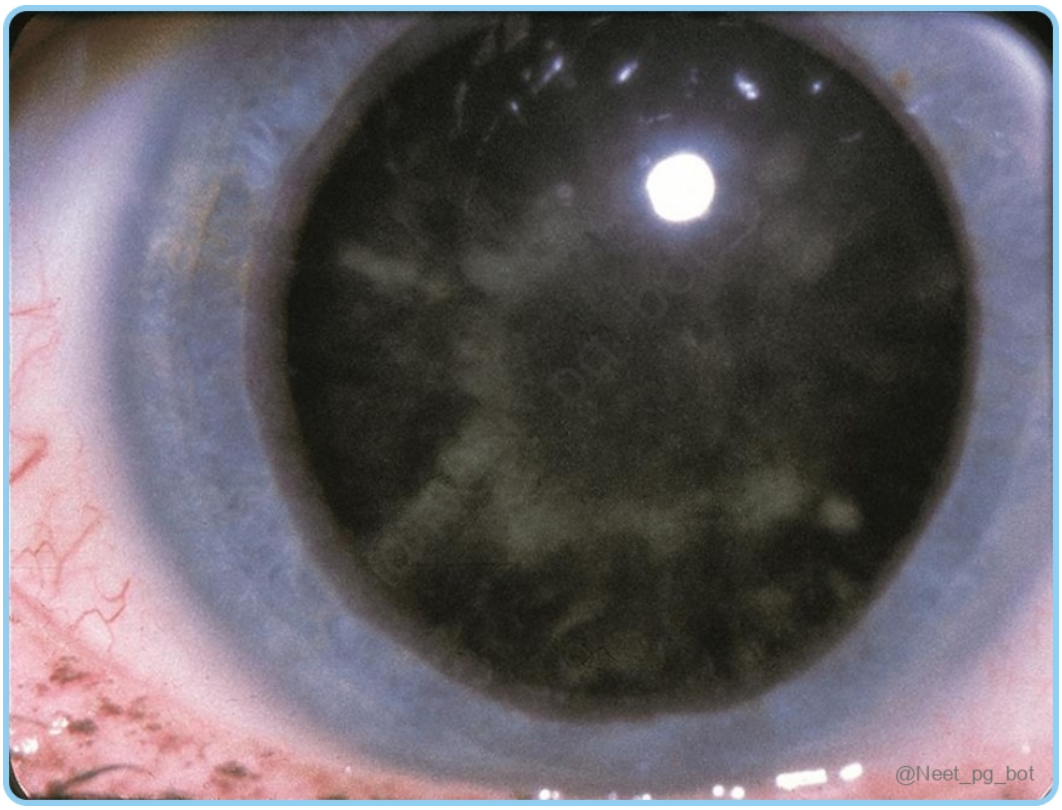

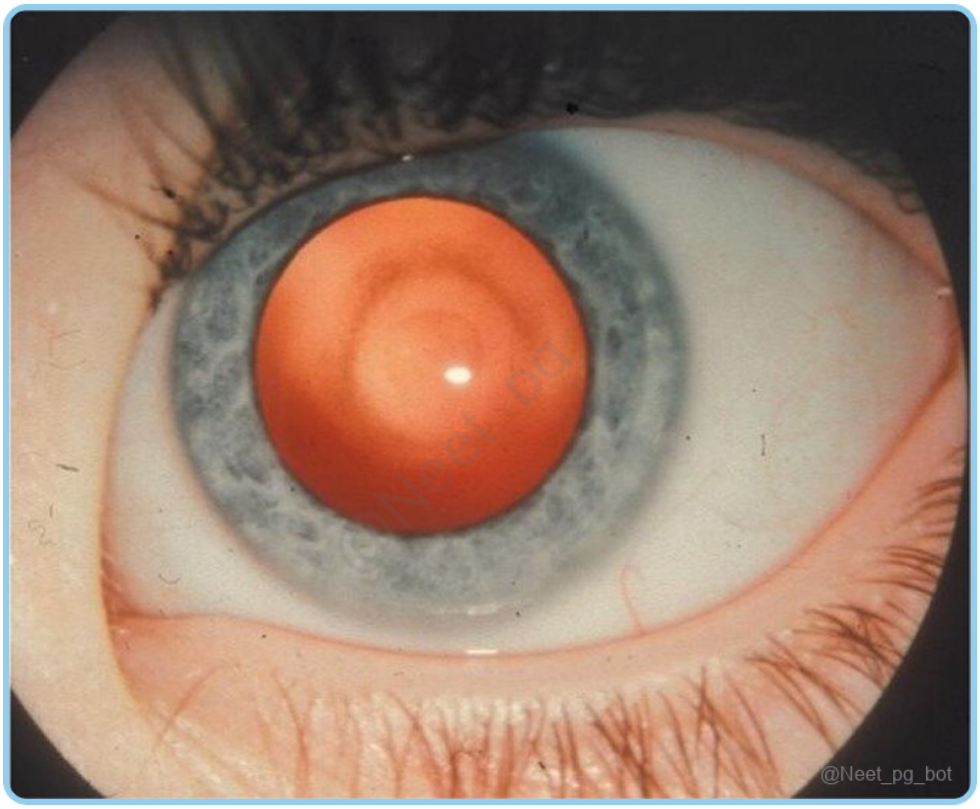

References:

Harrison's principles of internal medicine, 21st Edition, Page 3236. Davidson's principles and practice of medicine, 24th Edition, Page 896, 897 https://tinyurl.com/3ek9r4ym
https://www.nei.nih.gov/learn-about-eye-health/eye-conditions-and-diseases/cataracts/types-cataract
https://cataracteyesurgery.co/types/types-of-cataracts/

↑ *Back to this question in Part A*

@Neet_pg_bot

Q5: Which of the following investigation parameters is not generally considered definitive for the evaluation of Wilson's disease? (Q851393)

A. Serum copper levels

B. MRI of the brain

C. Liver biopsy

D. 24-hour urine excretion of copper

Correct Answer: A. Serum copper levels

Explanation: In Wilson's disease, the accumulation of copper in organs like the liver and brain leads to its characteristic symptoms. Serum copper levels are often low due to reduced ceruloplasmin (the copper-carrying protein), but this is not a reliable diagnostic marker as it can be affected by other conditions such as liver disease or acute inflammation. MRI Brain (Option B): Shows copper accumulation in the basal ganglia, often with the "face of the giant panda" sign - Typical finding associated with neurological manifestations due to copper deposition. Copper Content in Liver biopsy (Option C): Elevated (>250 µg/g dry weight), Definitive test for Wilson's disease, measuring accumulated copper in hepatocytes. 24-Hour Urinary Copper Excretion (Option D): Elevated (>100 µg/24h), A reliable indicator of copper overload, often used for diagnosis and monitoring treatment.

References:

Harrison's principles of internal medicine, 21st Edition, Page 3236,3237. Davidson's principles and practice of medicine, 24th Edition, Page 897. https://tinyurl.com/3ek9r4ym

↑ *Back to this question in Part A*

@Neet_pg_bot

Q6: A 22-year-old patient presents with neurological symptoms such as tremors, dysarthria, and gait disturbances. An MRI of the brain is performed and reveals hyperintensities at the sites given below. Based on these findings and the clinical presentation, what is the most likely diagnosis? (Q851396)

A. Huntington's disease

B. Multiple sclerosis

C. Wilson’s disease

D. Parkinson’s disease



Correct Answer: C. Wilson’s disease

Explanation: Imaging finding in Wilson’s disease, particularly on MRI, is the "giant panda sign" . This is characterized by hyperintensities in the midbrain, specifically in the tectum, tegmentum, and red nucleus, with sparing of the substantia nigra, creating a pattern resembling a panda’s face on axial T2-weighted MRI. Disease Radiograph Wilson’s Disease: Face of the Giant Panda Sign {{caption_text}} Multiple Sclerosis (MS) (Option B): Dawson’s Fingers {{caption_text}} Huntington’s Disease (OPtion A): Boxcar Ventricles {{caption_text}} Parkinson’s Disease (Option D) : Swallow Tail Sign {{caption_text}}

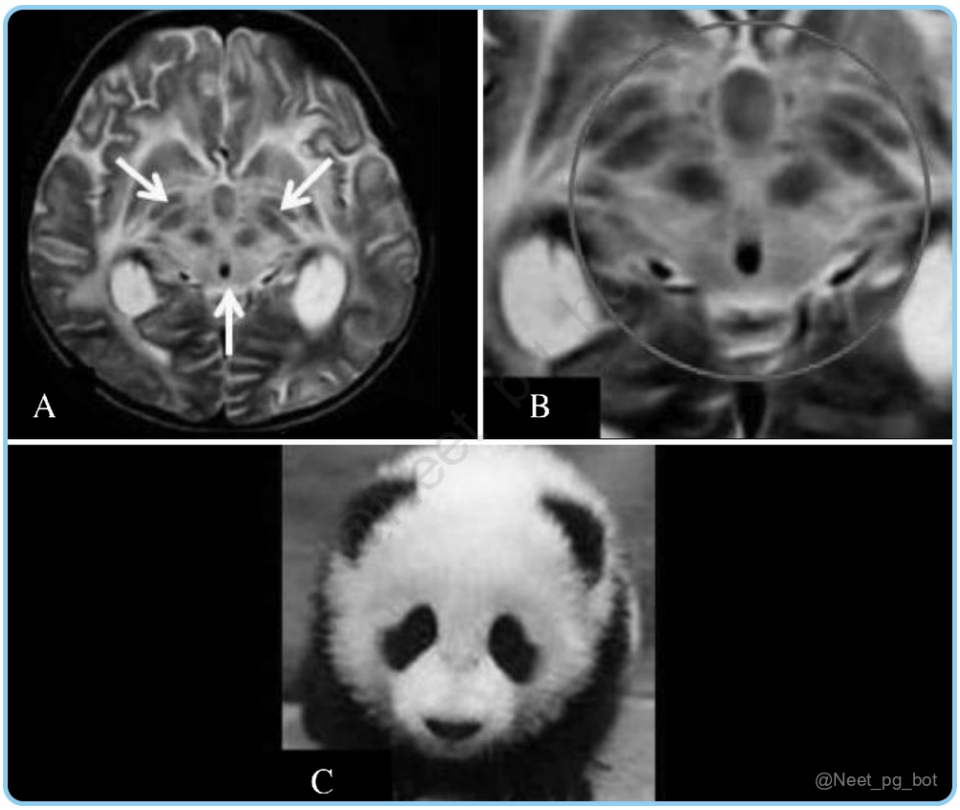
A
B
C
@Neet_pg_bot


@Neet_pg_bot

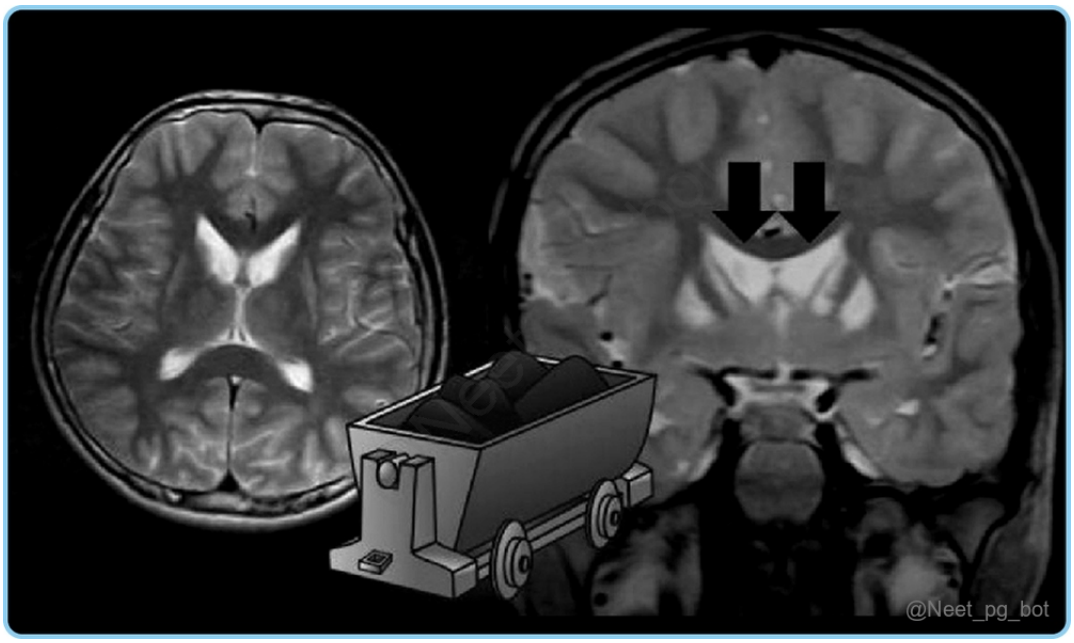

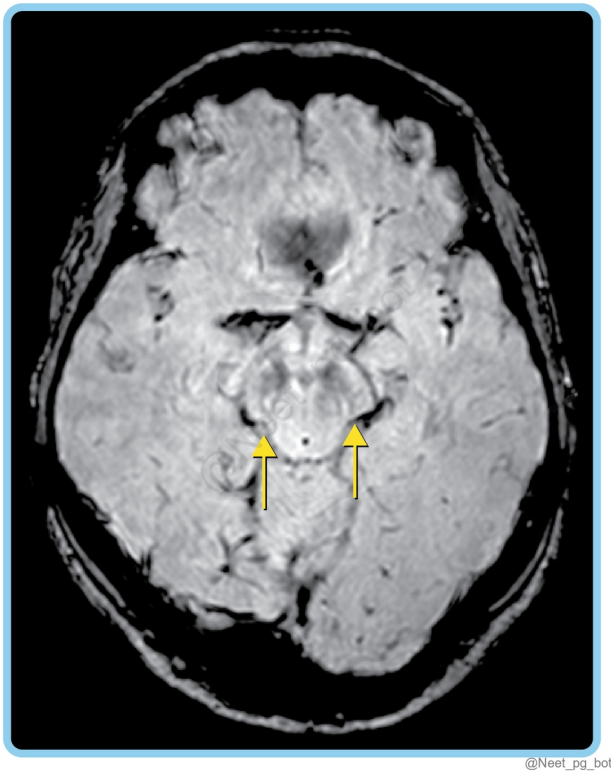

References:

Harrison's principles of internal medicine, 21st Edition, Page 3236,3237.

Davidson's principles and practice of medicine, 24th Edition, Page 897.

https://www.ncbi.nlm.nih.gov/books/NBK441990/

↑ *Back to this question in Part A*

@Neet_pg_bot

Q7: A 24-year-old patient presents with the following symptoms: tremors, dysarthria, irritability, and impulsive behavior, along with jaundice and the presence of Kayser-Fleischer rings on slit-lamp examination. What is the best treatment approach for this condition? (Q851399)

A. Penicillamine

B. Trientine

C. Zinc acetate

D. Dimercaprol

Correct Answer: B. Trientine

Explanation: This patient has Wilson's disease (copper accumulation affecting the liver, brain, and eyes). In the past, penicillamine was used as the oral chelator- which increases urinary copper excretion. However, penicillamine has significant drawbacks : nephrotoxicity, hematologic abnormalities, elastosis perforans serpiginosa, and paradoxical worsening of neurologic symptoms in some patients. (Option A ruled out) Therefore, in patients with neurological presentations (such as in this case) , Trientine (triethylenetetramine dihydrochloride) is preferred. It has a better side-effect profile and is effective in reducing copper overload. Zinc Acetate (Option C): Inhibits copper absorption from the gastrointestinal tract and is often used for maintenance therapy after initial chelation. Dimercaprol (Option D): Although a chelating agent, it is primarily used for the treatment of heavy metal poisoning (e.g., lead, mercury)

References:

Harrison's Principles of Internal Medicine, 22nd Edition, Page 3340.

↑ *Back to this question in Part A*

@Neet_pg_bot

Q8: A 28-year-old patient who is a known case of Wilson's disease presents to the emergency department with acute liver failure. He has neurological symptoms and liver dysfunction. Upon evaluation, laboratory results reveal the following: Serum bilirubin: 12 mg/dL. Serum aspartate transferase (AST): 250 IU/L. Prothrombin time prolongation: 15 seconds. Based on these results, calculate the NAZER prognostic

score for this patient and the next step in treatment accordingly. (Q851401)

A. NAZER score of 5; no need for transplantation

B. NAZER score of 8; medical management is sufficient

C. NAZER score of 9; liver transplantation is indicated

D. NAZER score of 11; monitor the patient without intervention

Correct Answer: C. NAZER score of 9; liver transplantation is indicated

Explanation: The NAZER index in the above scenario is calculated as follows: Serum bilirubin: 12 mg/dL = score 3 Serum aspartate transferase (AST): 250 IU/L = score 3 Prothrombin time prolongation: 15 seconds = score 3 Total score = 9. A score of 9 or more indicates the need for liver transplantation in this patient. NAZER prognostic index: This index is used to calculate the prognosis of the liver disease and determine the need for liver transplantation. Laboratory measurement Score (in points) Normal value 0 1 2 3 4 Serum bilirubin 0.2-1.2 mg/dL <5.8 5.8-8.8 8.8-11.7 11.7-17.5 >17.5 Serum aspartate transferase 10-35 IU/L <100 100-150 151-200 201-300 >300 Prolongation of prothrombin time (seconds) <4 4-8 9-12 13-20 >20

References:

Harrison's Principles of Internal Medicine, 21st edition, Page 648, 2552.
https://pubmed.ncbi.nlm.nih.gov/38899966/
https://www.researchgate.net/figure/Prognostic-Index-of-Nazer-10_tbl2_273568259 https://www.researchgate.net/publication/273568259_Wilson_Disease_in_Children_-_a_Rare_but_Treatable_Autosomal_Recessive_Metabolic_Disorder#pf6 https://www.ncbi.nlm.nih.gov/books/NBK542308/
https://pmc.ncbi.nlm.nih.gov/articles/PMC10278970/

↑ *Back to this question in Part A*

@Neet_pg_bot

Q9: A 38-year-old woman presents with symptoms of fatigue, arthralgia, and new-onset diabetes. Her family history reveals that her father was diagnosed with hemochromatosis. Further evaluations show significantly elevated serum ferritin and transferrin saturation levels and that she carries both the C282Y and H63D mutations in the HFE gene. Based on her clinical presentation and genetic findings, which type of hemochromatosis is she most likely experiencing? (Q851402)

A. Type 1

B. Type 2

C. Type 3

D. Type 4

Correct Answer: A. Type 1

Explanation: The clinical scenario points to the diagnosis of Type 1 hereditary hemochromatosis as the patient has both C282/H63D mutations along with a family history . Types of Hereditary hemochromatosis: Hereditary hemochromatosis Type 1 (Option A) HFE-related C282Y homozygosity C282/H63D compound heterozygosity Type-2 (Option B) Non-HFE related Juvenile hemochromatosis Type-3 (Option C) Mutated transferrin receptor 2 (TRF2) Type-4 (Option D) Mutated ferroportin 1 gene

References:

Harrison’s Principles of Internal Medicine, 21st edition, Page: 3230, 3232.

↑ *Back to this question in Part A*

@Neet_pg_bot

Q10: A 45-year-old male presents to the clinic with complaints of fatigue, joint pain, and a noticeable change in skin color, described as a slate-gray hue. He reports a family history of liver disease and diabetes. Blood tests reveal elevated serum ferritin and transferrin saturation levels. Which of the following clinical features, once developed, progresses even after successful treatment of the condition? (Q851404)

A. Hepatomegaly

B. Cardiac arrhythmia

C. Arthropathy

D. Hypogonadism

Correct Answer: C. Arthropathy

Explanation: The scenario here is of hemochromatosis where excess iron is seen in the blood and as deposits in the tissues and also in joints, leading to arthropathy, which is progressive and continues to progress even after normalization of the iron levels by treatment. {{caption_text}} Hepatomegaly (Option A) may regress with phlebotomy and iron reduction. Cardiac arrhythmia (Option B) often improves after iron removal. Hypogonadism (Option D) can partially improve if diagnosed early.



References:

Harrison’s Principles of Internal Medicine, 21st edition, Page 3233.

↑ *Back to this question in Part A*

@Neet_pg_bot

Q11: A 45-year-old man presents with fatigue, joint pain, and new-onset diabetes. He has a family history of liver disease and reports high alcohol intake. Which biochemical test would be a strong indicator of hemochromatosis in this patient? (Q851406)

A. Plasma iron levels

B. Serum ferritin levels

C. Fasting serum transferrin saturation

D. Liver biopsy

Correct Answer: C. Fasting serum transferrin saturation

Explanation: Fasting transferrin saturation is the earliest and most sensitive biochemical indicator of hereditary hemochromatosis. Serum ferritin is also important, but alone it's not enough , as it can be elevated due to liver disease, alcohol, or inflammation. In practice, both TSAT and ferritin are checked together , but if you must pick one single "strong indicator" , it's fasting TSAT . While high, an elevated ferritin is less specific than a high fasting TSAT as a primary indicator of iron overload due to hemochromatosis. The initial diagnostic strategy is usually to check both, but the consistently elevated fasting TSAT often becomes abnormal first and is a stronger indicator of the regulatory defect. Plasma iron level (Option A): Elevated (not reliable) Serum ferritin levels (Option B): Reflect iron stores, but can be elevated in inflammation, liver disease, or alcohol use , so less specific. Liver biopsy (Option D) is a very important method for diagnosing the level of damage to the organ and measures the liver iron concentration in a patient, helping in detecting fibrosis and cirrhosis, but it is not a biochemical test as asked in this scenario. It is used in cases of non-HFE hemochromatosis and those with dual pathology.
{{caption_text}}

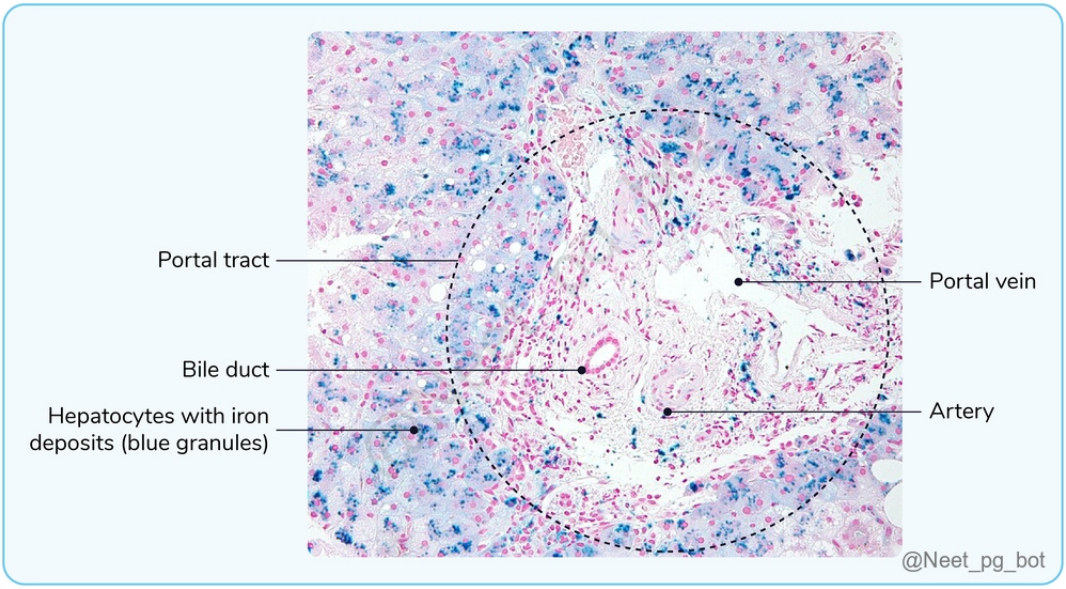

References:

Harrison's Principles of Internal Medicine, 21st edition, Page 3233, 3234.

https://pubmed.ncbi.nlm.nih.gov/21716156/

↑ *Back to this question in Part A*

@Neet_pg_bot

Q12: A 25-year-old female comes with fatigue, joint pains, and a slate-gray appearance of the skin. After evaluation and detailed history, the physician suspects hemochromatosis. Which of the following statements about screening for hemochromatosis is false? (Q851408)

A. All adult first-degree relatives should be tested for C282Y and H63D mutations.

B. Genetic testing for the C282Y and H63D mutations is recommended if screening tests are abnormal.

C. Children of diagnosed individuals under 18 years old should always be screened for hemochromatosis.

D. Screening is done using transferrin saturation and ferritin levels.

Correct Answer: C. Children of diagnosed individuals under 18 years old should always be screened for hemochromatosis.

Explanation: In the case of a parent with hemochromatosis, the testing of children is generally not necessary until they are 18 or if the other parent's HFE mutation is confirmed , as disease manifestations occur later. Screening for hemochromatosis: Done once the diagnosis of hemochromatosis is made. Counseling and testing of all adult first-degree relatives of diagnosed individuals is recommended, as asymptomatic carriers often show increased transferrin saturation and ferritin levels, and should be tested for C282Y and H63D mutations (Option A). Genetic testing for the C282Y and H63D mutations is recommended if screening tests are abnormal (Option B). Screening using transferrin saturation and ferritin levels is effective for detecting hemochromatosis and iron deficiency (Option D).

References:

Harrison's Principles of Internal Medicine, 21st edition, Page: 3233, 3234.

https://www.sciencedirect.com/science/article/abs/pii/S001650851500935X

↑ *Back to this question in Part A*

@Neet_pg_bot

Q13: A 45-year-old male patient with a confirmed diagnosis of hereditary hemochromatosis presents with symptoms of fatigue, diabetes, and joint pain. Laboratory tests reveal elevated serum ferritin levels of 2000 μg/dl. Which of the following is the most appropriate initial treatment for this patient? (Q851411)

A. Deferoxamine parenteral chelation therapy

B. Liver transplantation

C. Deferiprone oral chelation therapy

D. Phlebotomy

Correct Answer: D. Phlebotomy

Explanation: The first and foremost treatment modality for effective removal of excessive iron from the blood is phlebotomy, which can effectively remove 200-250 mg of iron from 500 ml of blood in one sitting of the procedure. Management of Hemochromatosis 1) Iron removal Phlebotomy (preferred): Weekly/biweekly 500 mL until ferritin ≤100 µg/L. Transferrin saturation may remain elevated. Chelation therapy: Used if phlebotomy not feasible (anemia/hypoproteinemia). Deferoxamine (Option A): parenteral Deferasirox, Deferiprone (Option C): oral, used in thalassemia/secondary iron overload). 2) Lifestyle: Avoid alcohol, vitamin C, and iron supplements; no routine dietary restriction needed. 3) Complications: Manage cirrhosis, diabetes, cardiac failure conventionally; testosterone or gonadotropins for hypogonadism. 4) Liver transplantation (Option B): For end-stage disease; better outcomes if iron removed pre-procedure.

References:

Harrison’s Principles of Internal Medicine, 21st edition, Page 3234.

↑ *Back to this question in Part A*

@Neet_pg_bot

• [09_Hepatobiliary System] 072 Hereditary Hyperbilirubinemia Budd Chiari Syndrome

« Back to Folder Directory

[09_Hepatobiliary System] 072 Hereditary Hyperbilirubinemia Budd Chiari Syndrome — Quick Jump

Q1 (p. 2806) *Q2 (p. 2807)* *Q3 (p. 2808)* *Q4 (p. 2809)* *Q5 (p. 2810)* *Q6 (p. 2811)*
Q7 (p. 2812) *Q8 (p. 2812)* *Q9 (p. 2813)*

Q1: A 3-month-old infant presents with jaundice. Laboratory tests reveal elevated bilirubin levels, with a higher proportion of unconjugated bilirubin. The infant's mother mentions that the jaundice has been present since birth and that the infant has not shown any signs of hemolysis. What is the most likely underlying cause of this infant's condition related to bilirubin metabolism? (Q851561)

A. Impaired uptake of bilirubin by hepatocytes

B. Defective conjugation of bilirubin due to UGT1A1 mutation

C. Reduced biliary excretion of bilirubin due to MRP2 mutation

D. Increased production of bilirubin due to hemolysis

Correct Answer: B. Defective conjugation of bilirubin due to UGT1A1 mutation

Explanation: The infant's jaundice is primarily due to elevated unconjugated bilirubin levels , indicating a problem with bilirubin processing. The mutation in the UGT1A1 gene leads to Crigler Najjar syndrome which disrupts the conjugation process, leading to an accumulation of unconjugated bilirubin in the liver. {{caption_text}} Impaired uptake of bilirubin by hepatocytes (Option A) : This would lead to increased unconjugated bilirubin levels, not elevated conjugated bilirubin, as seen in this infant. Thus, uptake is not the primary issue. Reduced biliary excretion of bilirubin due to MRP2 mutation (Option C): While an MRP2 mutation could lead to elevated conjugated bilirubin, it's less likely here since the infant shows no signs of cholestasis, making defective conjugation a more probable cause. Mutations in the MRP2 (ABCC2) gene disrupt bilirubin glucuronide transport across the canalicular membrane, causing bilirubin accumulation in hepatocytes. Increased production of bilirubin due to hemolysis (Option D): Increased hemolysis would raise unconjugated bilirubin levels, but the absence of hemolysis signs in this infant makes this option inconsistent with the findings.

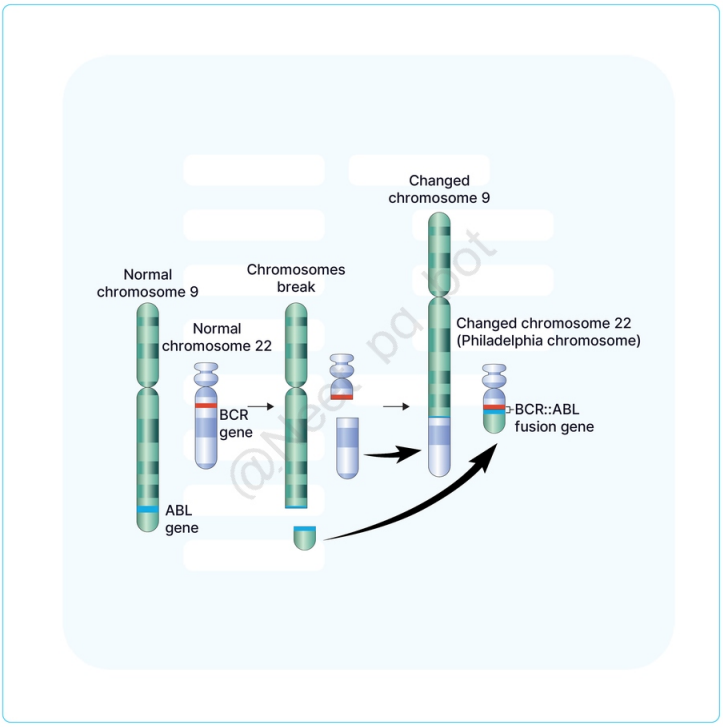

@Neet_pg_bot

References:

Harrison's Principles of Internal Medicine, 21st Edition, Page 2557

↑ *Back to this question in Part A*

@Neet_pg_bot

Q2: A 17-year-old male presents to the clinic for a routine check-up. His laboratory tests reveal serum bilirubin levels of 45 μmol/L (2.6 mg/dL) with normal liver function tests. He reports occasional mild jaundice, particularly after periods of stress and fasting. There is no history of hemolysis or liver disease. The patient has been asymptomatic otherwise. What is the most likely diagnosis for this patient based on the provided information? (Q851562)

A. Crigler-Najjar Syndrome Type I

B. Crigler-Najjar Syndrome Type II

C. Dubin-Johnson Syndrome

D. Gilbert Syndrome

Correct Answer: D. Gilbert Syndrome

Explanation: The patient's mildly elevated unconjugated bilirubin levels, normal liver function tests , and intermittent jaundice during stress and fasting incidentally diagnosed in adolescence are all characteristic of Gilbert Syndrome . Crigler-Najjar Syndrome Type I (Option A) is characterized by severe unconjugated hyperbilirubinemia (typically >20 mg/dL) due to the complete absence of UGT1A1 activity. Patients often exhibit significant jaundice from infancy and are at risk for kernicterus. The bilirubin levels in the scenario are too low for this diagnosis. Crigler-Najjar Syndrome Type II (Option B) occurs due to reduced UGT1A1 activity (10-20% of normal) leading to unconjugated hyperbilirubinemia; it still presents with higher bilirubin levels than in Gilbert Syndrome. Dubin-Johnson Syndrome (Option C) is characterized by conjugated hyperbilirubinemia due to defective biliary excretion of conjugated bilirubin due to multidrug resistance protein (MRP 2) defect leading to increased direct bilirubin in the serum. Liver function tests show abnormal results, which are not consistent with the normal findings in this case.

References:

Harrison's Principles of Internal Medicine, 21st Edition, Page 2559, 2560

↑ *Back to this question in Part A*

@Neet_pg_bot

Q3: A 2-week-old infant is brought to the emergency department due to jaundice. The mother reports that the infant's skin has become increasingly yellow since birth. Laboratory tests reveal a serum bilirubin level of 450 μmol/L (26 mg/dL), and the infant appears lethargic. There are no signs of hemolysis, and a physical examination shows no other abnormalities. What is the most likely diagnosis for this infant based on the provided information? (Q851563)

A. Crigler-Najjar Syndrome Type I

B. Crigler-Najjar Syndrome Type II

C. Dubin-Johnson Syndrome

D. Rotor Syndrome

Correct Answer: A. Crigler-Najjar Syndrome Type I

Explanation: The infant's extremely high unconjugated bilirubin level (450 μmol/L) is characteristic of Crigler-Najjar Syndrome Type I , which presents with severe, lifelong unconjugated hyperbilirubinemia, typically starting in the neonatal period. Kernicterus risk is high due to the bilirubin level, which aligns with CN-I features. Crigler-Najjar Type II would present with lower bilirubin levels and a reduced risk of kernicterus. Hyperbilirubinemia syndromes Crigler-Najjar Syndrome Type I (CN-I) Gene: UGT1A1 Pathology: Complete absence of bilirubin UDP-glucuronosyltransferase (UDPGT) activity; No bilirubin conjugation occurs, leading to

severe unconjugated hyperbilirubinemia. Clinical features Severe jaundice from birth extreme hyperbilirubinemia (>342 µmol/L or >20 mg/dL) high risk of kernicterus , with neurological damage. Often fatal without intervention. Investigations Increased unconjugated bilirubin + conjugated bilirubin absent No signs of excessive hemolysis No bilirubin UDPGT activity– no response to phenobarbital No bilirubin glucuronides in bile (bile is pale or colorless). Management Requires lifelong phototherapy; Liver transplantation is often definitive in preventing neurological damage. Crigler-Najjar Syndrome Type II (CN-II) Gene: UGT1A1 Pathology: Marked reduction (≤10% of normal) in bilirubin UDPGT activity partial conjugation of bilirubin occurs Clinical features Moderate jaundice with serum bilirubin levels of 103–428 µmol/L (6–25 mg/dL) kernicterus is possible under stress conditions (illness or surgery) Usually presents in infancy or childhood Investigations Increased unconjugated bilirubin + conjugated bilirubin present Reduced bilirubin UDPGT activity; Unconjugated bilirubin levels decrease significantly in response to phenobarbital; Bile contains bilirubin monoglucuronide Management Phenobarbital therapy to induce residual UDPGT activity Dubin-Johnson Syndrome (Option C) Gene: ABCC2 gene Pathology: Mutations in the MRP2 (ABCC2) gene disrupt bilirubin glucuronide transport across the canalicular membrane, causing bilirubin accumulation in hepatocytes. Clinical features Asymptomatic or with mild symptoms Mild to moderate jaundice that can darken with age Hepatocytes accumulate dark pigment but liver function is normal. Investigations Increased conjugated bilirubin Darkly pigmented liver on biopsy Positive urinary coproporphyrin I levels. Management Usually, no treatment is required; manage jaundice as needed Rotor syndrome (Option D) Gene: SLCO1B1 and SLCO1B3 gene Pathology: Affect the reuptake system (OATP1B1 and OATP1B3) for bilirubin glucuronides, causing some bilirubin to re-enter the circulation. Clinical features Mild to moderate jaundice; No dark liver pigmentation as in Dubin-Johnson Investigations Direct hyperbilirubinemia I ncreased urinary coproporphyrin I and III levels Liver is not pigmented on biopsy. Management Usually no treatment required; manage jaundice as needed

References:

Harrison’s Principles of Internal Medicine, 21st Edition, Page 2558, 2559

↑ *Back to this question in Part A*

@Neet_pg_bot

Q4: A 30-year-old woman presents to the clinic with intermittent jaundice that worsens during her menstrual cycle and when taking oral contraceptives. Laboratory tests reveal elevated conjugated bilirubin levels, but her liver function tests are otherwise normal. A liver ultrasound shows no significant abnormalities, and she has no history of significant liver disease. What is the most likely diagnosis for this patient based on the provided information? (Q851564)

A. Dubin-Johnson Syndrome

B. Rotor Syndrome

C. Budd-Chiari Syndrome

D. Crigler-Najjar Syndrome Type II

Correct Answer: A. Dubin-Johnson Syndrome

Explanation: The patient’s symptoms of intermittent jaundice, elevated conjugated bilirubin levels, and normal liver function tests are characteristic of Dubin-Johnson Syndrome. The exacerbation of symptoms during hormonal changes (menstrual cycle and oral contraceptives) aligns with known triggers for this benign condition. Rotor Syndrome (Option B) is similar to Dubin-Johnson but usually presents with less severe conjugated hyperbilirubinemia and does not have the characteristic black liver. The lab findings and clinical features in this case are more consistent with Dubin-Johnson. Budd-Chiari Syndrome (Option C) involves hepatic venous outflow obstruction, leading to abdominal pain, ascites, and liver dysfunction. The patient's normal liver function tests and lack of significant clinical symptoms do not support this diagnosis. Crigler-Najjar Syndrome Type II (Option D) is associated with moderate unconjugated hyperbilirubinemia, not conjugated. The patient’s elevated conjugated bilirubin levels and the presence of triggers (hormonal changes) do not fit with Crigler-Najjar Type II. Due to unconjugated hyperbilirubinemia, UDP-GT is severely deficient, condition improves with administration of phenobarbitone.

References:

Harrison’s Principles of Internal Medicine, 21st Edition, Page 2560, 2561

↑ *Back to this question in Part A*

@Neet_pg_bot

Q5: A 28-year-old man presents to the clinic with intermittent jaundice and dark urine. His laboratory tests show elevated conjugated bilirubin levels and urine tests reveal bilirubinuria. An ultrasound of the liver is unremarkable, and a cholecystography shows a normal gallbladder. The patient has no significant past medical history and is otherwise asymptomatic. What is the most likely diagnosis for this patient based on the provided information? (Q851565)

A. Crigler-Najjar Syndrome Type I

B. Gilbert Syndrome

C. Rotor Syndrome

D. Dubin-Johnson Syndrome

Correct Answer: C. Rotor Syndrome

Explanation: The patient’s elevated conjugated bilirubin levels, presence of bilirubinuria, and normal appearance of the liver with visualization of the gallbladder are characteristics of Rotor Syndrome. This condition is similar to Dubin-Johnson but lacks the liver pigmentation associated with Dubin-Johnson Syndrome. Crigler-Najjar Syndrome Type I (Option A) involves severe unconjugated hyperbilirubinemia due to absent UGT1A1 activity, which would not present with elevated conjugated bilirubin levels as seen in this patient. Gilbert Syndrome

(Option B) is characterized by mild unconjugated hyperbilirubinemia and is typically asymptomatic. The presence of elevated conjugated bilirubin and bilirubinuria in this case makes Gilbert Syndrome an unlikely diagnosis. Dubin-Johnson Syndrome (Option D) presents with elevated conjugated bilirubin and bilirubinuria but is associated with a characteristic black liver due to pigment accumulation, which is not noted in this patient. The gallbladder is also visualized, unlike in Dubin-Johnson.

References:

Harrison's Principles of Internal Medicine, 21st Edition, Page 2561

↑ *Back to this question in Part A*

@Neet_pg_bot

Q6: A 35-year-old woman presents to the emergency department with abdominal pain, severe ascites, and jaundice that developed over the past month. On examination, she has hepatomegaly and splenomegaly. Laboratory tests show elevated liver enzymes and bilirubin levels. A Doppler ultrasound of the abdomen reveals occlusion of multiple hepatic veins. What is the most likely diagnosis for this patient based on the provided information? (Q851566)

A. Dubin-Johnson Syndrome

B. Budd-Chiari Syndrome

C. Gilbert Syndrome

D. Rotor Syndrome

Correct Answer: B. Budd-Chiari Syndrome

Explanation: The patient's symptoms of abdominal pain, ascites, jaundice, and hepatomegaly, combined with the ultrasound findings of hepatic vein occlusion, are characteristic of Budd-Chiari Syndrome, which involves hepatic venous outflow obstruction. Dubin-Johnson Syndrome (Option A) is characterised by elevated conjugated bilirubin due to defective biliary excretion and typically presents with mild jaundice. The severe abdominal symptoms and hepatic vein occlusion in this case do not fit this diagnosis. Gilbert Syndrome (Option C) is associated with mild unconjugated hyperbilirubinemia and is usually asymptomatic. The acute symptoms of abdominal pain, ascites, and jaundice indicate a much more serious condition, not consistent with Gilbert Syndrome. Rotor Syndrome (Option D) presents with elevated conjugated bilirubin and bilirubinuria but does not involve significant abdominal pain or ascites. The findings of hepatic vein occlusion and severe liver symptoms are not characteristic of Rotor Syndrome.

References:

https://www.ncbi.nlm.nih.gov/books/NBK558941/

↑ *Back to this question in Part A*

@Neet_pg_bot

Q7: A 32-year-old woman presents with 2 months of progressive abdominal pain and distension. On examination, she has spider angiomas, hepatomegaly, and moderate ascites. Laboratory studies show haemoglobin 18.2 g/dL, WBC 13,000/μL, platelets 650,000/μL, and normal liver enzymes. Doppler ultrasound reveals hepatic vein thrombosis. Which of the following is the most common cause of the suspected condition? (Q851567)

A. Myeloproliferative disorders

B. Vitamin B12 deficiency

C. Inflammatory bowel disease

D. Chronic hepatitis C

Correct Answer: A. Myeloproliferative disorders

Explanation: The patient's clinical findings are suggestive of Budd-Chiari Syndrome: The most common causes of Budd-Chiari Syndrome by frequency: Myeloproliferative disorders: ~50% of cases Pregnancy/OCPs: ~20% of cases Malignancy: ~10% of cases Idiopathic: ~20% of cases Vitamin B12 deficiency (Option B): This condition, while sometimes associated with elevated haemoglobin and platelets, is not a typical cause of hepatic vein thrombosis or Budd-Chiari syndrome. Inflammatory bowel disease (Option C): Although inflammatory bowel disease affects the gastrointestinal tract, it is not directly linked to hepatic vein thrombosis or liver-specific complications like Budd-Chiari syndrome. Chronic hepatitis C (Option D): Chronic hepatitis C can lead to liver disease but is not a recognised cause of hepatic vein thrombosis or Budd-Chiari syndrome.

References:

https://www.ncbi.nlm.nih.gov/books/NBK558941/

Davidson’s Principle and Practice of Medicine Edition 24th Page 898, 899

↑ *Back to this question in Part A*

@Neet_pg_bot

Q8: A 35-year-old woman presents with 3 weeks of progressive abdominal pain and ascites. Laboratory studies show elevated LFTs and a prolonged PT. Doppler ultrasound reveals hepatic vein thrombosis. After initial diagnosis, which of the

following represents the most appropriate sequential management approach? (Q851568)

A. Proceed directly to liver transplantation

B. Initiate anticoagulation, followed by assessment for predisposing causes and TIPS if needed

C. Start diuretics alone and monitor symptoms

D. Perform surgical shunting as primary therapy

Correct Answer: B. Initiate anticoagulation, followed by assessment for predisposing causes and TIPS if needed

Explanation: The diagnosis of Budd-Chiari syndrome is supported by: Classic clinical triad: Severe abdominal pain Rapidly developing ascites Hepatomegaly Confirmatory imaging: hepatic vein thrombosis on Doppler Acute presentation (<2 weeks) Evidence of liver dysfunction (elevated INR and LFTs) Management follows a stepwise approach: Initial anticoagulation Evaluate underlying causes Consider TIPS if medical therapy fails Proceeding directly to liver transplantation (Option A) is typically reserved for cases with liver failure unresponsive to other treatments. Initial management generally includes anticoagulation and evaluation of underlying causes before considering transplantation. Starting diuretics alone and monitoring symptoms (Option C) may help manage ascites but do not address the underlying thrombosis or prevent further clotting. Anticoagulation is necessary to reduce clot progression in hepatic vein thrombosis. Performing surgical shunting as primary therapy (Option D) is not a first-line treatment; it's typically considered if anticoagulation and other interventions like TIPS fail to control symptoms or improve liver function.

References:

https://www.ncbi.nlm.nih.gov/books/NBK558941/

Davidson's Principle and Practice of Medicine Edition 24th Page 898, 899

↑ *Back to this question in Part A*

@Neet_pg_bot

Q9: Which of the following statements is true regarding how the Bromsulphthalein test helps distinguish between Rotor syndrome and Dubin-Johnson syndrome? (Q851569)

A. Dubin johnson syndrome - prolonged retention of BSP in the bloodstream Rotor syndrome - BSP is rapidly cleared.

B. Dubin Johnson syndrome - delayed excretion with prolonged retention of BSP occurs, Rotor syndrome - early excretion with no delayed retention.

C. Both Rotor syndrome and DJS show prolonged retention of BSP, making the test ineffective in differentiation.

D. Dubin Johnson syndrome - BSP is taken up slowly by the liver but is excreted rapidly, Rotor syndrome - BSP is taken up rapidly by the liver but is excreted slowly

Correct Answer: B. Dubin Johnson syndrome - delayed excretion with prolonged retention of BSP occurs, Rotor syndrome - early excretion with no delayed retention.

Explanation: BSP test shows prolonged retention of the dye in Dubin-Johnson syndrome due to impaired excretion, while in Rotor syndrome , the dye is excreted promptly without delayed retention. This difference in BSP handling helps in distinguishing between the two syndromes.

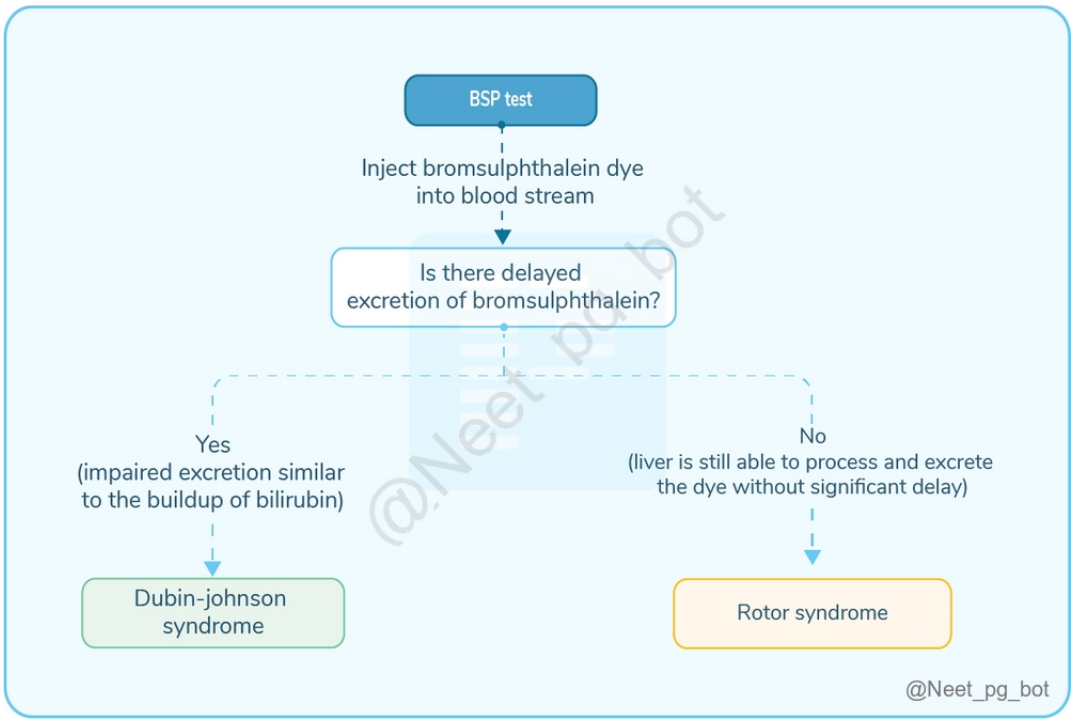

References:

Harrison’s Principles of Internal Medicine, 21st Edition, Page 2561, 2562

↑ *Back to this question in Part A*

@Neet_pg_bot

• [09_Hepatobiliary System] 073 Previous Year Questions

« Back to Folder Directory

[09_Hepatobiliary System] 073 Previous Year Questions — Quick Jump

Q1 (p. 2815)	*Q2 (p. 2816)*	*Q3 (p. 2816)*	*Q4 (p. 2819)*	*Q5 (p. 2820)*	*Q6 (p. 2821)*
Q7 (p. 2822)	*Q8 (p. 2826)*	*Q9 (p. 2828)*	*Q10 (p. 2829)*	*Q11 (p. 2832)*	*Q12 (p. 2832)*
Q13 (p. 2833)	*Q14 (p. 2834)*	*Q15 (p. 2835)*	*Q16 (p. 2836)*	*Q17 (p. 2836)*	*Q18 (p. 2837)*
Q19 (p. 2838)	*Q20 (p. 2840)*	*Q21 (p. 2840)*	*Q22 (p. 2841)*	*Q23 (p. 2842)*	

Q1: Which of the following conditions leads to the development of wing beating tremor? (Q857675)

A. Wilson’s disease

B. Huntington’s chorea

C. Parkinsonism

D. Sydenham’s chorea

Correct Answer: A. Wilson’s disease

Explanation: Wing-beating tremor is a coarse, rhythmic, proximal tremor classically seen in Wilson’s disease , a genetic disorder of copper metabolism caused by mutation in the ATP7B gene on chromosome 13. When the patient extends the arms forward with elbows flexed and forearms pronated , the shoulders and arms make a flapping or “wing-beating” motion — hence the name. This tremor occurs due to lesions involving the red nucleus and thalamus , caused by copper deposition in these brain regions. Clinical Features of Wilson's Disease Hepatic Symptoms Chronic Hepatitis: Jaundice, hepatomegaly, elevated liver enzymes due to copper accumulation in the liver. Cirrhosis: Portal hypertension, variceal bleeding as a result of long-term copper accumulation and fibrosis. Acute Liver Failure : Coagulopathy, jaundice, encephalopathy. Neurological Symptoms Movement Disorders: Tremors (flapping or wind-beating tremor), dystonia, ataxia, dysarthria due to copper accumulation in the basal ganglia. Parkinsonism-like symptoms : Rigidity, bradykinesia, cogwheel rigidity from copper accumulation in the basal ganglia. Psychiatric: Depression, personality changes, cognitive decline. Ocular Features Kayser-Fleischer Rings: Brown/greenish rings in the cornea due to copper deposition in Descemet's membrane . Sunflower Cataract: Rare, (copper deposition in the lens). Renal Features Renal Tubular Acidosis (Fanconi Syndrome): Due to copper accumulation in renal tubules. Hematologic Features Hemolytic Anemia: Copper-induced red cell damage. Skeletal Features Osteopenia, osteoporosis, joint arthropathy Huntington’s chorea (Option B): Involves chorea (irregular, jerky movements), not a rhythmic tremor. It is due to caudate nucleus degeneration, not midbrain involvement. Parkinsonism (Option C): Characterized by resting “pill-rolling” tremor, rigidity, and bradykinesia - not wing-beating tremor. Sydenham’s chorea (Option D): Post-streptococcal autoimmune chorea - movements are purposeless and irregular, not sustained or rhythmic like wing-beating.

References:

Harrison's principles of internal medicine, 21st edition, Page 3235, 3236

Davidson's principles and practice of medicine, 24th edition, Page 896, 897

↑ *Back to this question in Part A*

@Neet_pg_bot

Q2: A 45-year-old man with known alcoholic cirrhosis presents with confusion and 3 days of hematemesis. Examination reveals icterus, hepatosplenomegaly, tense ascites, and asterixis. Vitals: BP 100/60 mmHg, pulse 104/min. Which of the following is appropriate in the initial management of this patient? Start propranolol to stop variceal bleeding Perform a diagnostic ascitic tap to rule out spontaneous bacterial peritonitis (SBP) Start IV antibiotics and IV octreotide infusion Give IV albumin after large-volume paracentesis or if renal dysfunction develops (Q879181)

A. 1,2

B. 2,3,4

C. 1,2,3

D. 1,2,3,4

Correct Answer: B. 2,3,4

Explanation: In acute variceal bleeding, non-selective beta-blockers (e.g., propranolol) are contraindicated initially because they may worsen hypotension and interfere with compensatory tachycardia. Instead, IV octreotide and broad-spectrum antibiotics are started immediately to control bleeding and prevent infection. Diagnostic paracentesis is essential at presentation to rule out spontaneous bacterial peritonitis , and IV albumin is indicated after large-volume paracentesis or renal dysfunction.

References:

Harrison’s Principles of Internal Medicine, 21st ed., Vol. 2, Ch. 359: Cirrhosis and Its Complications.

↑ *Back to this question in Part A*

@Neet_pg_bot

Q3: A patient presents with fever, jaundice, and malaise. Based on the serology reports provided, what is the most likely diagnosis? Serology Reports: HBsAg: Positive Anti-HBc: Positive Anti-HCV: Negative (Q856023)

A. Acute hepatitis D

B. Acute hepatitis B

C. Chronic hepatitis B

D. Chronic hepatitis C

Correct Answer: B. Acute hepatitis B

Explanation: The patient presents with acute hepatitis symptoms — fever, jaundice, and malaise. The serology shows: HBsAg positive → indicates current hepatitis B infection Anti-HBc positive → indicates exposure to hepatitis B Anti-HCV: Negative in this case, which excludes hepatitis C, ruling out acute or chronic hepatitis C. (Option D ruled out) Although it is not specified whether this is IgM or IgG , the clinical presentation strongly supports an acute infection . In acute hepatitis B, Anti-HBc IgM is typically positive. Clinical Phases HBsAg Anti-HBs HBeAg Anti-HBe Anti-HBc HBV DNA Acute HBV - Early-phase, high infectivity + IgM +++ IgM + + Acute HBV - Window phase + IgM + + + + Acute HBV - Recovery phase + IgG + + + + Chronic HBV, high infectivity + + + IgG + + Chronic HBV, low infectivity + + + IgG + +/- HBV infection in the recent past + + +/- IgG + +/- HBV infection in the remote past +/- + +/- IgG + - Post-vaccination - IgG - - - - {{caption_text}} Acute HBV infection with recovery {{caption_text}} Chronic HBV infection Acute hepatitis D (Option A): Hepatitis D requires co-infection with hepatitis B to exist. It is not the correct answer here because anti-HBc (core antibody) is positive, but no other markers for hepatitis D (like HDV RNA) are provided. Chronic hepatitis B (Option C): Chronic hepatitis B would show HBsAg positive for more than 6 months, which is not suggested by the given clinical scenario or serology. Additionally, anti-HBc would typically be IgG (indicating a past infection or chronicity) rather than IgM.

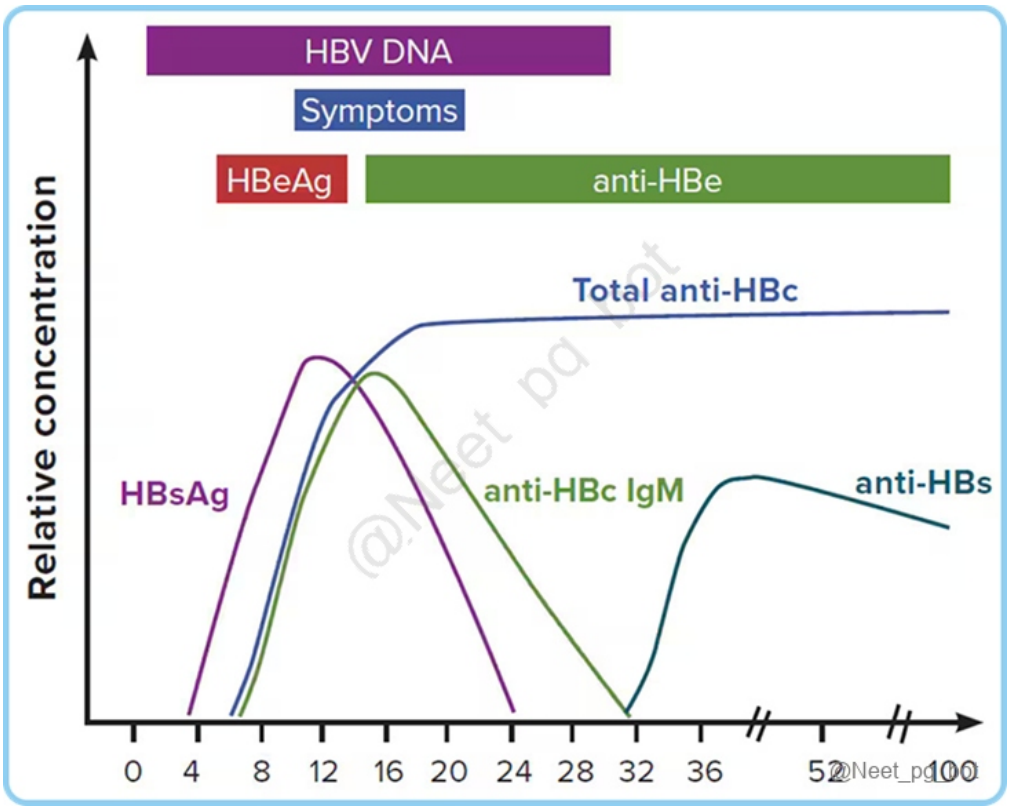

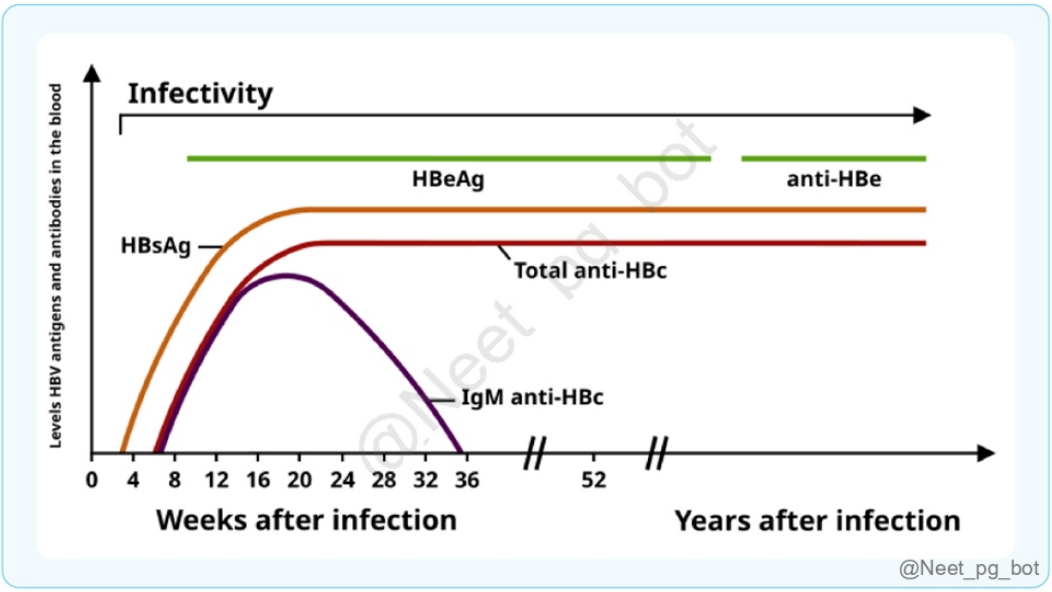

References:

Harrison's Principles of Internal Medicine, 21st Edition, Page: 643, 2652, 2563, 2564, 2568, 2573, 2574, 2575, 2576, 2577, 2578, 2579, 2581, 2592, 2594, 2603.

https://www.researchgate.net/publication/354997816_Hepatitis_B_Vaccines

↑ *Back to this question in Part A*

@Neet_pg_bot

Q4: Laboratory investigations of a patient being evaluated for jaundice show elevated bilirubin and alkaline phosphatase levels. Levels of the remaining liver enzymes are normal. What is the likely diagnosis? (Q855949)

A. Obstructive jaundice

B. Hemolytic jaundice

C. Hepatic jaundice

D. Prehepatic jaundice

Correct Answer: A. Obstructive jaundice

Explanation: The laboratory findings of elevated bilirubin and alkaline phosphatase (ALP) with normal liver enzyme levels (AST, ALT) strongly suggest obstructive jaundice. Feature Prehepatic Jaundice (Option D) Hepatic Jaundice (Option C) Posthepatic (Obstructive) Jaundice Etiology Hemolysis (e.g., hemolytic anemia, malaria) (Option B) Sickle cell disease G6PD deficiency Liver diseases (e.g., viral hepatitis, cirrhosis, alcoholic liver disease) Liver tumors Drug-induced liver injury Bile duct obstruction (e.g., gallstones, pancreatic cancer, cholangiocarcinoma, strictures, tumors) Mechanism Increased breakdown of red blood cells Excessive bilirubin production Impaired bilirubin conjugation and excretion due to liver dysfunction Blocked bile flow Accumulation of conjugated bilirubin in bloodstream Clinical Features Yellowing of skin and sclera Anemia Fatigue Splenomegaly Yellowing of skin and sclera Fatigue Nausea Hepatomegaly Pruritus Yellowing of skin and sclera Pale stools Dark urine Pruritus Hepatomegaly Bilirubin Elevated unconjugated (indirect) bilirubin Elevated unconjugated and conjugated (direct) bilirubin Elevated conjugated (direct) bilirubin Liver Enzyme Values AST, ALT: Normal or slightly elevated ALP: Normal GGT: Normal AST, ALT: Markedly elevated ALP: Elevated GGT: Elevated AST, ALT: Mildly elevated ALP: Markedly elevated GGT: Elevated Prothrombin time (PT) Normal Prolonged PT Prolonged PT Prolonged PT Urine Normal or slightly dark urine due to excess urobilinogen Dark urine (due to increased conjugated bilirubin) Dark urine (due to conjugated bilirubin) Pale stools (due to reduced bile excretion) Hemolytic jaundice (Option B) results from excessive breakdown of red blood cells. It typically leads to an increase in unconjugated bilirubin, while alkaline phosphatase and liver enzymes remain normal because there is no bile duct obstruction or hepatocellular damage.

References:

Harrison's Principles of Internal Medicine, 21st Edition, Page: 315-319.

Schwartz's Principles of Surgery - 11th Edition, Page: 1354.

Bailey & Love's Short Practice of Surgery - 27th Edition, Page: 135.

↑ *Back to this question in Part A*

@Neet_pg_bot

Q5: A patient with a history of chronic liver disease presents with abdominal distension, jaundice, and pruritis. Ascitic fluid analysis revealed a neutrophil count of 650 per cubic mm. What is the most likely diagnosis? (Q855935)

A. Spontaneous bacterial peritonitis

B. Malignant ascites

C. Tubercular ascites

D. Intestinal obstruction



Correct Answer: A. Spontaneous bacterial peritonitis

Explanation: The clinical scenario of abdominal distension, jaundice, pruritus, and a neutrophil count >250/mm³ in ascitic fluid strongly suggests Spontaneous Bacterial Peritonitis (SBP). Spontaneous Bacterial Peritonitis (SBP) Description A severe complication of ascites, characterised by spontaneous infection of the ascitic fluid without an intra-abdominal source. Causative organism Escherichia coli (most common) and other gut bacteria. Gram-positive bacteria (Streptococcus viridans, Staphylococcus aureus, and Enterococcus) Source of infection Clinical features Worsening of ascites Fever, nausea, vomiting Increase in abdominal girth Encephalopathy Diagnosis Ascitic fluid analysis shows: Turbid appearance {{caption_text}} Neutrophil count >250/µL Culture and gram satins reveal the causative organisms Management IV 3rd generation cephalosporins (cefotaxime) for 5 days Prevention Paracentesis within 12 hours of hospital admission Norfloxacin administration (cirrhotic patients

with an episode of SBP) Quinolone antibiotic prophylaxis (recurrent episodes of SBP in variceal bleeding). Malignant Ascites (Option B): Caused by abdominal or extra-abdominal malignancies, with ascitic fluid showing high levels of VEGF or tumor markers and a milky or bloody appearance. Tubercular Ascites (Option C): Associated with tuberculous peritonitis, with exudative ascitic fluid, high protein levels, and lymphocytic predominance. Intestinal Obstruction (Option D): Unlikely due to the absence of symptoms like vomiting or cessation of bowel movements.

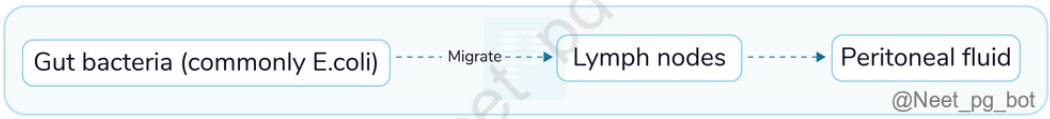



References:

Harrison’s Principles of Internal Medicine, 21st Edition, Page: 324, 2632.

Davidson’s Principles and Practice of Medicine, 24th Edition, Page 864.

↑ *Back to this question in Part A*

@Neet_pg_bot

Q6: A patient presents to the emergency department with a history of ingestion of ten tablets of paracetamol. He has developed oliguria, and liver function tests show

deranged values. Which of the following can be used in the management of this condition? (Q855921)

A. N-acetylcysteine

B. Dopamine

C. Ursodeoxycholic acid

D. Furosemide

Correct Answer: A. N-acetylcysteine

Explanation: The patient’s history of paracetamol ingestion, along with oliguria and deranged liver function tests, is highly suggestive of paracetamol toxicity. The treatment of choice is N-acetylcysteine (NAC). Acetaminophen (Paracetamol) Toxicity Leading cause of acute liver failure. Toxic Dose: ≥25g can be fatal. Clinical Presentation: Oliguria, deranged liver function tests. Mechanism of Toxicity: Metabolism: Acetaminophen is metabolized by cytochrome P450 (CYP2E1) to N-acetyl-p-benzoquinone-imine (NAPQI). Toxicity: In overdose, glutathione stores are depleted, preventing detoxification of NAPQI. Management: Antidote: N-acetylcysteine (NAC). Action: Replenishes glutathione stores. Timing: Most effective within 8 hours; partial protection up to 36 hours. Severe cases: Liver transplantation if hepatic failure persists despite NAC therapy.

References:

Harrison's Principles of Internal Medicine, 21st Edition, Page: 2586, 2588, 2589, 2623, 2627.

Goodman & Gillman's The Pharmacological Basis Of Therapeutics, 13th Edition, Page: 198, 241, 452, 453, 454.:https://www.ahajournals.org/doi/full/10.1161/CIRCULATIONAHA.107.728840

↑ *Back to this question in Part A*

@Neet_pg_bot

Q7: What clinical examination is being performed in the image? (Q859798)

A. Shifting dullness

B. Ascites

C. Puddle sign

D. Fluid thrill



Correct Answer: D. Fluid thrill

Explanation: The examination being done here is fluid thrill or fluid wave test which helps determine the presence of large volumes of fluid in the abdomen. Clinical manifestations Initially asymptomatic Approximately 1-2 litres of fluid show signs and symptoms, including: Abdominal distension, discomfort, pain. Weight gain (sudden) Nausea, vomiting Respiratory distress having shortness of breath, dyspnea Edema of body parts Everted umbilicus (due to an increase in ascitic fluid) {{caption_text}} Ascites (Option B) Clinical signs: Puddle sign (Peritoneal fluid >100ml) (Option C) The puddle sign detects small amounts of fluid in the abdomen. In a sitting position, tapping the abdomen produces a distinct sound over fluid, indicating ascites. Shifting dullness (peritoneal fluid >500ml) (Option A) In a supine position, a healthcare provider percusses the abdomen to identify dullness (fluid) and resonance (air). When the patient turns to one side, the fluid shifts, causing dullness to move to the dependent side and resonance to appear on the upper side, indicating ascitic fluid. Fluid thrill or fluid wave test (Option D) The fluid thrill is a sign of large abdominal fluid volumes (more than 1.5 Liters). It occurs when a provider taps one side of the abdomen while feeling the opposite, creating a wave indicating ascites. {{caption_text}} Hepatic hydrothorax Fluid from the abdomen, usually due to cirrhosis, accumulates in the pleural cavity, typically on the right side, causing shortness of breath and chest discomfort. {{caption_text}} Abdominal compartment syndrome (intra-abdominal hypertension) can occur if the pressure due to ascites is more than 25 mm Hg.


@Neet_pg_bot

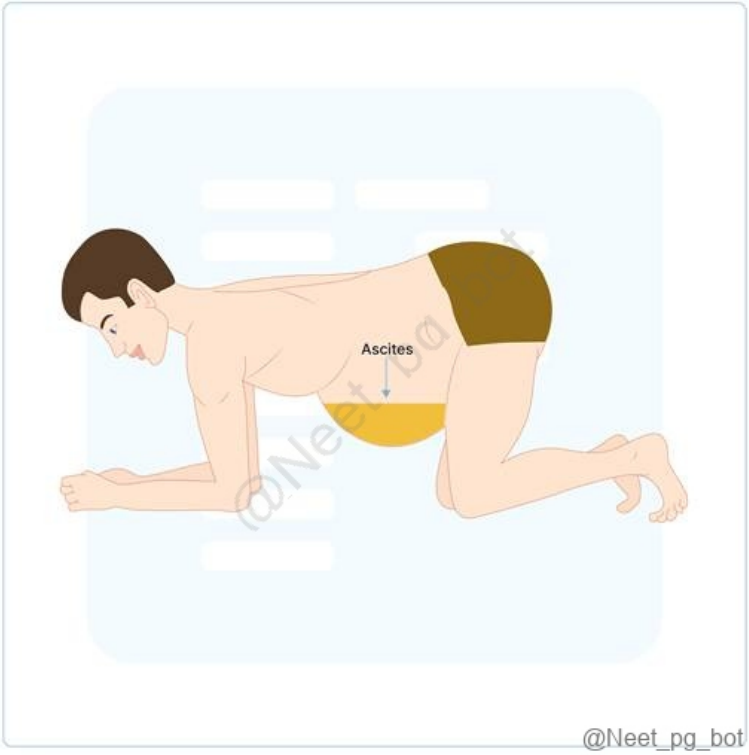

@Neet_pg_bot

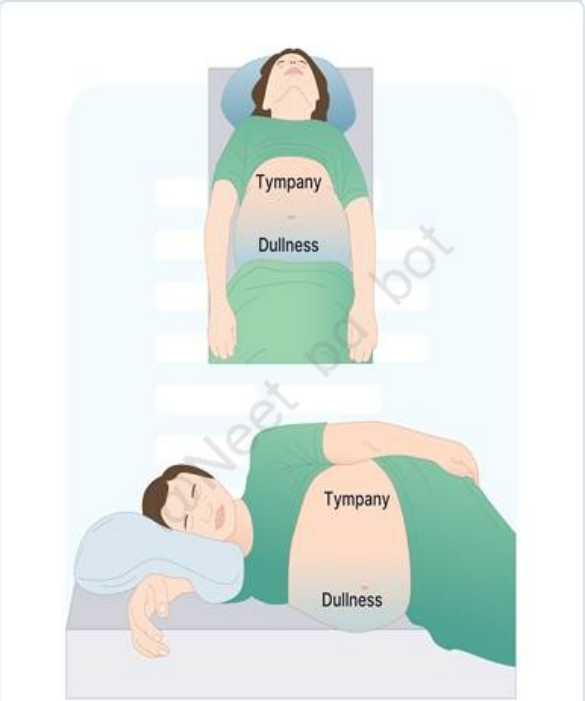

@Neet_pg_bot

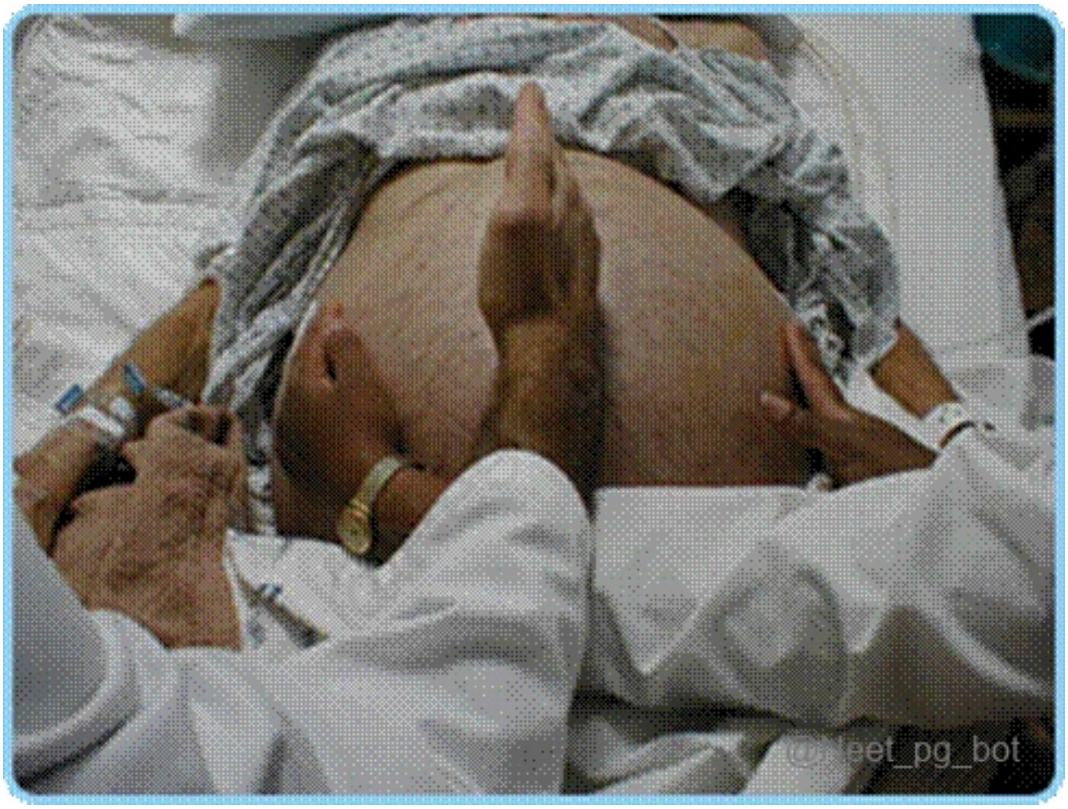
@Neet_pg_bot

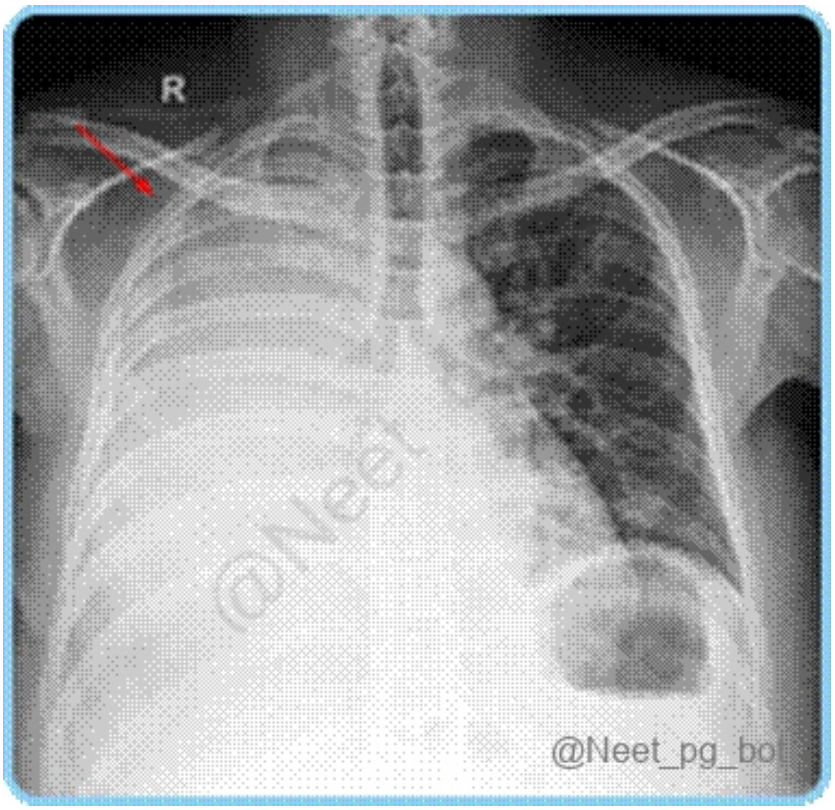

References:

Harrison’s Principles of Internal Medicine, 21st Edition, Volume I, Page: 2631.

Davidson’s Principles and Practice of Medicine, 24th Edition, Page: 862, 863.

↑ *Back to this question in Part A*

@Neet_pg_bot

Q8: What is the most probable diagnosis for a 40-year-old man whose lab reports indicate positive IgG Anti-HBc and negative HBsAg? (Q859795)

A. Recovering from hepatitis B

B. Hepatitis B in the remote past

C. Immunization with HBsAg

D. Both B & C

Correct Answer: B. Hepatitis B in the remote past

Explanation: The positive Anti-HBc and negative HBsAg indicate an infection in the near/ remote past but has resolved now. Phase/Condition HBsAg Anti-HBs HBeAg Anti-HBe Anti-HBc Acute HBV + Nil + Nil IgM Window Phase Nil Nil Nil + IgM Chronic HBV/ Infective carrier (High infectivity) + Nil + Nil IgG Chronic HBV/Healthy carrier (Low infectivity) + Nil Nil + IgG Remote infection Nil Nil Nil Nil IgG Recovery (Option A) Nil + Nil + IgG Immunised (Option C) Nil + Nil Nil Nil {{caption_text}} Acute HBV infection with recovery {{caption_text}} Chronic HBV infection

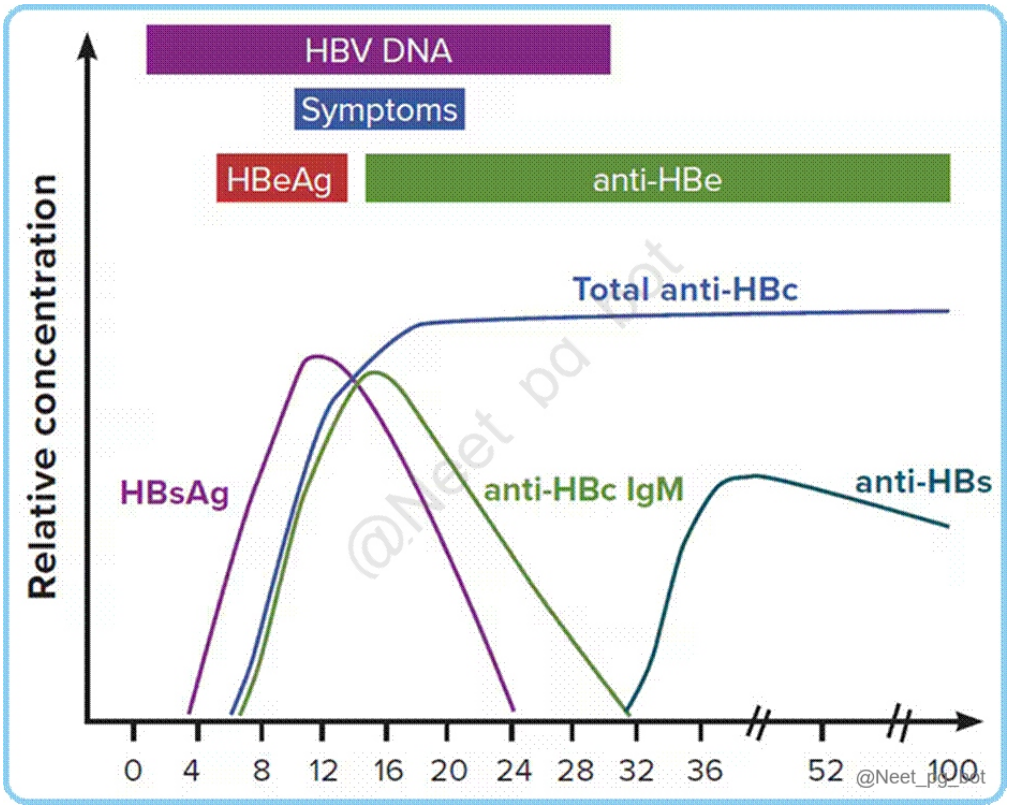

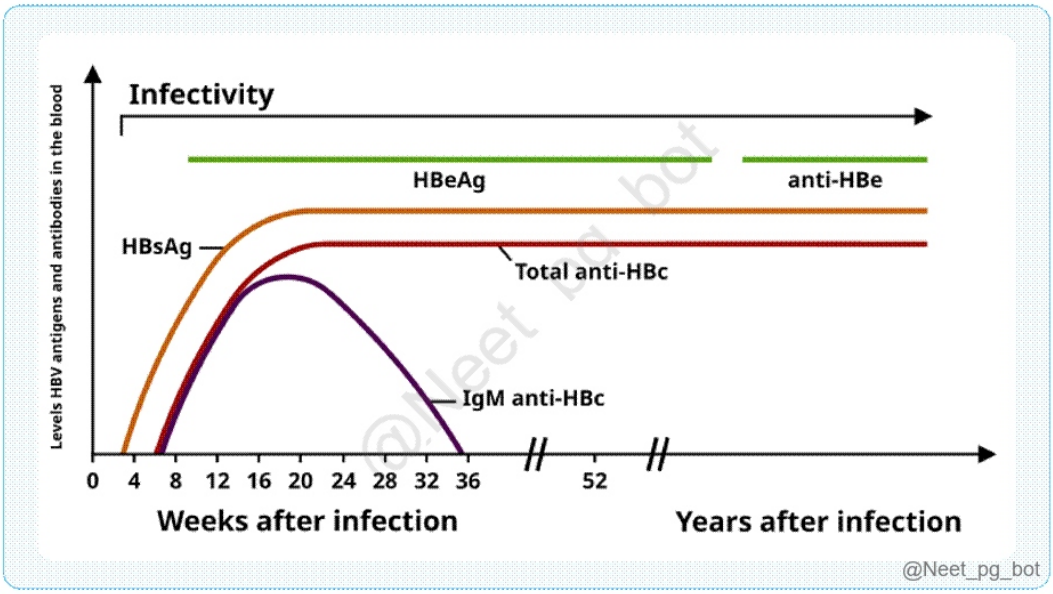

References:

https://www.researchgate.net/publication/354997816_Hepatitis_B_Vaccines

↑ *Back to this question in Part A*

@Neet_pg_bot

Q9: A 53-year-old patient was brought to the emergency room with a history of alcohol abuse, altered sensorium, and rapid shallow breathing. His abdomen is distended with palpable hepatomegaly and splenomegaly and sclerae are icteric. The other examination findings are given below. Laboratory tests show that the AST: ALT ratio is 3:1. What is the most likely cause of this patient's presentation? (Q859785)

A. Alcoholic liver disease

B. Acute viral hepatitis

C. Autoimmune hepatitis

D. Acetaminophen poisoning

Correct Answer: A. Alcoholic liver disease

Explanation: The clinical features along with the history of alcohol abuse point to the diagnosis of alcohol liver disease. Alcohol liver disease Pathophysiology Alcohol Metabolism Ethanol is primarily metabolized in the liver by enzymes, particularly alcohol dehydrogenase (ADH) and cytochrome P450 2E1 (CYP2E1). This metabolism produces acetaldehyde, a toxic intermediate, which can cause cellular damage. Oxidative Stress The metabolism of alcohol generates reactive oxygen species (ROS) and increases oxidative stress within liver cells. This oxidative damage leads to lipid peroxidation, protein modifications, and DNA damage, contributing to hepatocyte injury and inflammation. Inflammatory Response Alcohol consumption stimulates the activation of immune cells (e.g., Kupffer cells) leading to the release of pro-inflammatory cytokines (TNF-α, IL-6). These cytokines promote inflammation and can further damage hepatocytes. Altered Lipid Metabolism Alcohol disrupts normal lipid metabolism, leading to fat accumulation in liver cells (steatosis). This accumulation can progress to steatohepatitis, where inflammation and liver cell injury occur. Fibrosis and Cirrhosis Chronic inflammation and injury stimulate the activation of hepatic stellate cells, which produce collagen and lead to fibrosis. Over time, repeated injury can result in cirrhosis, characterized by scarring and loss of normal liver architecture. Clinical features: General Usually asymptomatic Fever, malaise, jaundice, history of alcohol intake + (at least within last 8 weeks before symptom onset) Abdominal Right upper quadrant pain, tender hepatomegaly, splenomegaly, ascites Caput medusae: enlarged veins radiating from the umbilicus Bleeding varices (portal hypertension) Dermatological Spider angioma , palmar erythema , ecchymosis Reproductive Gynaecomastia, gonadal atrophy, loss of libido, amenorrhea Neurological Peripheral neuropathy: tingling and numbness usually over feet Wernicke-Korsakoff syndrome: Ophthalmoplegia, confusion, ataxia + anterograde amnesia Hepatic encephalopathy: Asterixis (most prominent finding) , altered sensorium, sleep disturbances, lethargy Others Dupuytren's contracture , temporal muscle wasting, parotid gland enlargement Alcoholic liver disease LFT: AST (Aspartate aminotransferase) Non-specific ; ↑ (<300-400) ALT (Alanine aminotransferase) Specific for liver injury ; ↑ (<300-400) AST/ALT ratio: ≥ 2: 1 Specific for ALD ALP (Alkaline phosphatase) Elevated in bile duct pathologies GGT (γ-glutamyl

transferase) Non-specific marker of ALD 5’-Nucleotidase Specific marker for bile duct pathologies S.Bilirubin Usually normal/mildly ↑ S.Albumin ↓ in chronic liver disease (cirrhosis) Carbohydrate-deficient transferrin (CDT) Best serum marker for alcoholic liver disease. Hepatitis refers to the inflammation of the liver, which can be caused by various factors, including excessive alcohol consumption, autoimmune conditions, medications, or toxins. However, the most common cause of hepatitis is a viral infection, known as " viral hepatitis " (Option B) . Autoimmune hepatitis (Option C) is a condition characterized by chronic and progressive liver inflammation of unknown origin. It is believed to arise from a combination of genetic factors, environmental triggers, and a malfunction in the immune system, leading to ongoing inflammation of liver cells and eventual liver fibrosis. The primary symptoms of autoimmune hepatitis include fatigue, general discomfort, jaundice, abdominal pain, and occasionally joint pain. Acetaminophen poisoning (Option D) can present as asymptomatic or vomiting in the first stage, vomiting with right upper quadrant pain and hypotension in the second stage, or liver dysfunction, renal failure, coagulopathies, metabolic acidosis, and encephalopathy and reemergence of GI symptoms in the 3rd stage. The 4th stage is marked by recovery.

References:

Harrison’s Principles of Internal Medicine, 21st Edition, Page: 2618, 2632.

↑ *Back to this question in Part A*

@Neet_pg_bot

Q10: A 30-year-old female presents with unsteady gait, forgetfulness, and labile moods. During a physical exam, the neurologist notices the findings shown in the image below. The most likely diagnosis is: (Q859784)

A. Neurofibromatosis 2

B. Wilson’s disease

C. Neurofibromatosis 1

D. Cataract



Correct Answer: B. Wilson’s disease

Explanation: The above image shows fine pigmented and granular deposits, suggesting Wilson’s disease. These are Kayser-Fleischer rings due to copper deposits in the descemet’s membrane. Wilson's disease Wilson's disease, also known as hepatolenticular degeneration, is a rare autosomal recessive disorder caused by the abnormal accumulation of copper in the liver, brain, eyes, and other organs. This results in elevated free copper levels, along with increased copper levels in the liver and urine, while serum ceruloplasmin levels are decreased. Gene Affected: The disease is caused by mutations in the ATP7B gene on chromosome 13. This gene encodes a copper-transporting ATPase responsible for excreting copper from the liver into bile. Pathogenesis : Neurofibromatosis 2 (Option A) presents with juvenile cataracts in children, retinal hamartomas, etc. Neurofibromatosis 1 (Option C) presents with Lisch nodules that are small, raised brown spots in the iris. Cataracts (Option D) present as wedge-shaped opacity (cortical cataract) or as dark or black lenses (nuclear cataracts) with other specific findings. The given scenario is not associated with cataracts.

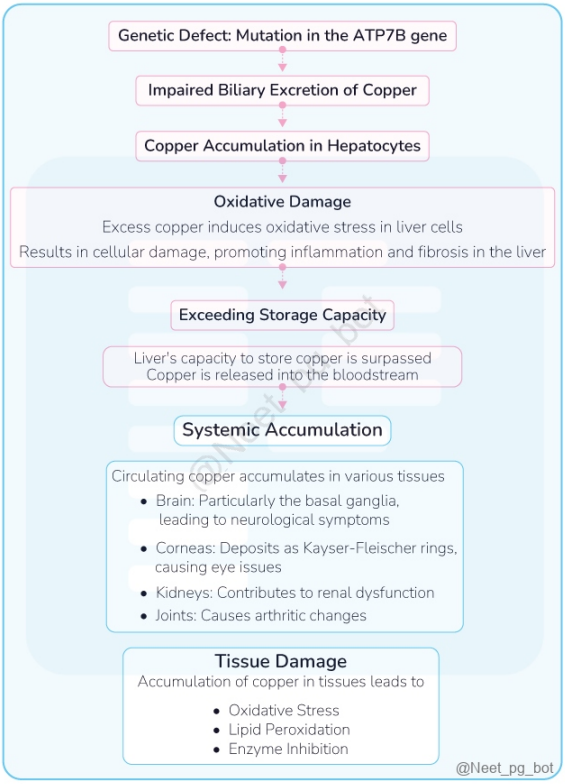

Lab parameters of Wilson's disease

Parameter	Change	Explanation
Free Copper	Increased	Unbound copper elevated due to impaired binding.
Liver Copper	Increased	Accumulation due to defective biliary excretion.
Urinary Copper	Increased	Overflow from the liver leads to high excretion
Total Copper	Decreased	Mainly composed of ceruloplasmin - bound copper.
Serum Ceruloplasmin	Decreased	Defective incorporation of copper into ceruloplasmin.

@Neet_pg_bot

References:

Harrison's principles of internal medicine, 21st Edition, Page 3235.

Davidson's principles and practice of medicine, 24th Edition, Page 896,897.

https://tinyurl.com/3ek9r4ym

↑ *Back to this question in Part A*

@Neet_pg_bot

Q11: What is the child-Turcotte-Pugh class for the patient who has a serum bilirubin 2.5 mg/dl, serum albumin 3 g/dl, prothrombin time 5 seconds (INR =2), no encephalopathy, and mild ascites? (Q854983)

A. Class A

B. Class B

C. Class C

D. Class D

Correct Answer: B. Class B

Explanation: This patient belongs to Child-Turcotte-Pugh Class B based on the following scoring: Serum Bilirubin: 2.5 mg/dL (2 points) Serum Albumin: 3 g/dL (2 points) Prothrombin Time (INR): 5 seconds (INR = 2) (2 points) Encephalopathy: None (1 point) Ascites: Mild (2 points) The total score is 9 points , which places the patient in Child-Pugh Class B. Child-Turcotte-Pugh Score: Employed to assess the severity of liver disease, predict prognosis for liver cirrhosis, and determine a patient's eligibility for liver transplantation, using a scoring system that incorporates parameters such as: Bilirubin INR Albumin Ascites Hepatic encephalopathy Child-Turcotte-Pugh Score Parameters 1 2 3 Encephalopathy None Grade 1-2 (Minimal) Grade 3-4 (Advanced) Ascites None Mildly controlled Poorly controlled Bilirubin (mg/dL) < 2 2 - 3 > 3 Albumin (g/dL) > 3.5 3 - 3.5 < 3.5 INR < 1.7 1.7 - 2.3 > 2.3 The Child-Turcotte-Pugh Score is determined by summing the scores for each parameter. Category A : 5-6 (Compensated cirrhosis) Category B : 7-9 (Decompensated cirrhosis) Category C : > 10 (Severely decompensated cirrhosis)

References:

Harrison’s Principles of Internal Medicine, 21st Edition, Page 2552

↑ *Back to this question in Part A*

@Neet_pg_bot

Q12: A chronic alcoholic male patient presented with abdominal distension, reduced urine output, and pedal oedema. His serum creatinine was 1.6 mg/dL. What is the next line of management for this patient? (Q856197)

A. Methylprednisolone

B. Heparin

C. Torsemide

D. Octreotide plus albumin

Correct Answer: D. Octreotide plus albumin

Explanation: The patient likely has Hepatorenal Syndrome (HRS), a complication of advanced liver disease characterized by renal dysfunction due to splanchnic vasodilation and reduced renal perfusion for which the best method of treatment is administering octreotide with albumin . HRS is diagnosed based on clinical features, including worsening renal function, low urine sodium (<10 mEq/L), and exclusion of other causes of acute kidney injury (e.g., hypovolemia, nephrotoxicity). Treatment of Hepatorenal syndrome Discontinue diuretics Albumin infusion- 1 g/kg per day Vasoconstrictors-Terlipressin, Low-dose Norepinephrine Midodrine (an α-agonist), along with octreotide and intravenous albumin The best therapy for HRS is liver transplantation; recovery of renal function is typical in this setting Octreotide is a synthetic analogue of somatostatin, a hormone that inhibits the release of various substances in the body. When combined with albumin , it can help manage hepatorenal syndrome (HRS). HRS occurs due to severe vasoconstriction of the renal blood vessels, leading to reduced renal blood flow and impaired kidney function. Octreotide helps alleviate vasoconstriction, while albumin improves intravascular volume and renal perfusion. The recommended dosage of albumin infusion in HRS is 1 g/kg per day, up to a maximum of 100 g/day, to expand intravascular volume and improve renal perfusion. Higher doses (e.g., 2-5 g/kg/day) are avoided due to risks such as pulmonary oedema. Incorrect Options: Methylprednisolone (Option A) is not used in hepatorenal syndrome due to the potential risk of worsening liver function in patients with cirrhosis. Heparin (Option B) is an anticoagulant and not helpful with HRS management as it raises the concern of haemorrhage. Torsemide (Option C) is a loop diuretic and not suitable for HRS management because diuretics lead to a depletion of effective circulating volume, which is already low in cirrhosis, further increasing the renal hypoperfusion.

References:

Harrison’s Principles of Internal Medicine, 21st Edition, Page: 2632.

↑ *Back to this question in Part A*

@Neet_pg_bot

Q13: A young male patient has the following serological status: HbsAg positive, IgM anti Hbc negative, IgG Anti-Hbc positive and HBeAg positive. Select the best treatment for this patient? (Q866810)

A. Lamivudine

B. Ombitasvir

C. Ritonavir

D. Abacavir

Correct Answer: A. Lamivudine

Explanation: The serology indicates chronic active hepatitis B infection : HBsAg positive → Ongoing HBV infection. IgM anti-HBc negative, IgG anti-HBc positive → Chronic (not acute) phase. HBeAg positive → High viral replication and infectivity. Patients with chronic active HBV and high viral load (HBeAg positive) require antiviral therapy to suppress viral replication and reduce liver inflammation, fibrosis, and hepatocellular carcinoma risk. Lamivudine , an oral nucleoside analog, inhibits HBV DNA polymerase and is one of the older but effective drugs in HBV management (though tenofovir and entecavir are now preferred first-line due to less resistance). Incorrect Options: Ombitasvir (Option B): NS5A inhibitor used in hepatitis C virus (HCV) infection — not active against HBV. Ritonavir (Option C): Protease inhibitor booster used in HIV therapy — no role in HBV monoinfection treatment. Abacavir (Option D): NRTI used in HIV therapy — not effective against HBV.

↑ *Back to this question in Part A*

@Neet_pg_bot

Q14: A 20-year-old male presented with a history of yellowing of the skin and eyes for last one week after trekking on weekend. He had experienced a similar episode of yellowing 2 years ago for 2 weeks. Labs shows S. bilirubin level 2.4 mg/dL, unconjugated bilirubin at 2.1 mg/dL and conjugated bilirubin at 0.3 mg/dL. His AST and ALT levels are normal. What is the most likely diagnosis for this patient? (Q857009)

A. Dubin-Johnson syndrome

B. Crigler-Najjar type 1 syndrome

C. Gilbert syndrome

D. Rotor syndrome

Correct Answer: C. Gilbert syndrome

Explanation: - Gilbert syndrome: Gilbert Syndrome is a benign condition characterized by mild, isolated unconjugated hyperbilirubinemia due to reduced activity of the enzyme UGT1A1. Jaundice is typically intermittent and triggered by stressors like fasting, physical exertion (as seen in this patient after trekking), or illness. Since liver enzymes (AST/ALT) and hemoglobin are normal, this rules out hepatitis and hemolysis, respectively. Incorrect Options: Option A - Dubin-Johnson syndrome: This condition presents with isolated conjugated hyperbilirubinemia (rather than unconjugated) due to a defect in the MRP2 transporter, often resulting in a characteristic "black liver" on biopsy. Option B - Crigler-Najjar type 1 syndrome: This is a severe, life-threatening condition presenting in neonates with extremely high levels of unconjugated bilirubin (>20 mg/dL), leading to kernicterus if untreated. Option D - Rotor syndrome: Similar to Dubin-Johnson, this involves a defect in organic anion transport (OATP1B1/B3) leading to conjugated hyperbilirubinemia, but without the hepatic pigmentation seen in Dubin-Johnson.

References:

Harrison’s Principles of Internal Medicine, 21st Edition, Page 2559, 2560

↑ *Back to this question in Part A*

@Neet_pg_bot

Q15: Which benzodiazepine is suitable for the safe administration to a 40-year-old chronic alcoholic experiencing withdrawal symptoms, based on the liver function tests that indicated AST levels of 140 IU/L, ALT levels of 110 IU/L, and GGT levels of 500 IU/L? (Q855317)

A. Diazepam

B. Alprazolam

C. Clonazepam

D. Lorazepam

Correct Answer: D. Lorazepam

Explanation: The elevated AST and ALT levels suggest possible liver dysfunction, which is common in chronic alcoholics. Lorazepam is not extensively metabolized by the liver , and its clearance is less affected by liver dysfunction compared to other benzodiazepines. It has a shorter half-life than diazepam, making it a suitable option for managing alcohol withdrawal symptoms in patients with liver disease. The patient with symptoms of delirium tremens (DTs), which is a severe form of alcohol withdrawal characterized by confusion, agitation, hallucinations, and tremors, are commonly treated by Lorazepam. DTs can be life-threatening and require prompt treatment to manage symptoms and prevent complications. Lorazepam: Lorazepam is a benzodiazepine used to manage alcohol withdrawal symptoms, including delirium tremens. Mechanism of Action: Enhances the effects of GABA , an inhibitory neurotransmitter, which calms the central nervous system and alleviates withdrawal symptoms. Advantages: Relatively long half-life Effective in controlling severe withdrawal symptoms Suitable for patients with liver impairment Metabolism: Primarily through conjugation, which is less affected by liver dysfunction compared to other benzodiazepines. Lorazepam is the drug of choice for the management of status epilepticus due to its rapid onset of action and effectiveness in terminating seizures. Diazepam, Alprazolam, Clonazepam (Option A, B and C) are extensively metabolized by the liver and are not recommended in patients with liver disease.

References:

K D Tripathi, Essentials of Medical Pharmacology, 8th edition,Page 450

Delirium Tremens

Acamprosate for the treatment of alcohol dependence

↑ *Back to this question in Part A*

@Neet_pg_bot

Q16: Which of the following is not a component of Child-Pugh scoring? (Q858010)

A. Albumin

B. Bilirubin

C. Prothrombin Time

D. Serum Creatinine

Correct Answer: D. Serum Creatinine

Explanation: - Serum Creatinine: The Child–Pugh score is used to assess the severity and prognosis of chronic liver disease and cirrhosis. It includes serum bilirubin, serum albumin, prothrombin time (or INR), ascites, and hepatic encephalopathy. Serum creatinine is not a component of this scoring system; it is instead included in the MELD score. Incorrect Options: Option A – Albumin: Serum albumin reflects hepatic synthetic function and is a key laboratory parameter in Child–Pugh scoring. Lower levels indicate more severe liver dysfunction. Option B – Bilirubin: Serum bilirubin assesses the excretory function of the liver and is an essential component of the Child–Pugh score. Higher levels correlate with a worse prognosis. Option C - Prothrombin Time: Prothrombin time (or INR) reflects coagulation factor synthesis by the liver and is a core parameter in Child–Pugh classification.

References:

Harrison’s Principles of Internal Medicine, 21st Edition, Page 2552

↑ *Back to this question in Part A*

@Neet_pg_bot

Q17: A 30-year-old male is found to be positive for HBsAg and HBeAg and is diagnosed with chronic hepatitis B. The viral load of the patient was 2 × 10■ IU/mL, and SGPT is found to be doubled. What is the appropriate management in this patient? (Q855436)

A. Lamivudine for 30+ weeks

B. Tenofovir for >40 weeks

C. Pegylated interferon for 52 weeks

D. Combined pegylated interferon with lamivudine

Correct Answer: B. Tenofovir for >40 weeks

Explanation: treatment: It needs antiviral therapy Drugs: Interferons (peginterferon alfa-2a, interferon alfa-2b) Nucleoside analogs (entecavir, lamivudine, telbivudine) Nucleotide analogs (adefovir, tenofovir) Oral agents: First-line: entecavir, tenofovir Second-line: lamivudine, adefovir, telbivudine Duration of therapy 48 to 52 weeks Lifestyle modifications include reducing the intake of agents with the potential for liver damage such as alcohol, hepatotoxic medications, herbal medications, and herbal supplements. Lamivudine for 30+ weeks (Option A): Lamivudine is an older nucleoside analog and, although effective in inhibiting HBV replication, it is no longer the preferred treatment due to the risk of resistance and lower efficacy compared to tenofovir. Pegylated interferon for 52 weeks (Option C): Pegylated interferon is another option for hepatitis B, often used when there is a desire to achieve sustained virologic response without long-term antiviral therapy. However, it is associated with poor tolerability, subcutaneous administration, and has lower effectiveness compared to oral agents like tenofovir. Combined pegylated interferon with lamivudine (Option D): This combination may provide a more profound suppression of HBV DNA during therapy, but studies show it does not offer significant advantages over monotherapy with either drug. The combination therapy also increases the risk of side effects, making it less preferred.

References:

Harrison's Principles of Internal Medicine, 21st Edition, Page: 2592-2599, 2565-2566, 2576. Hepatitis B - StatPearls - NCBI Bookshelf

↑ *Back to this question in Part A*

@Neet_pg_bot

Q18: A 40-year-old patient presents with right upper quadrant discomfort and grade Il steatohepatitis of the liver. He has a history of regular intake of 2-3 alcoholic drinks daily and has a BMI of 29. What will be the most appropriate advice to the patient? (Q854719)

A. Lifestyle modification + Regular exercise

B. Lifestyle modification + vitamin E + Ursodeoxycholic acid

C. Lifestyle modification + Pioglitazone

D. Lifestyle modification

Correct Answer: A. Lifestyle modification + Regular exercise

Explanation: The treatment of choice in this case of alcoholic hepatitis is lifestyle modification (stop alcohol intake) and regular exercise. Management of Alcoholic Liver Disease (ALD): Steatosis Only lifestyle modifications: Alcohol abstinence Dietary changes Exercise Steato-Hepatitis Oral Prednisolone 32 mg/day for 4 weeks Check S.Bilirubin levels 1 week after starting steroids Other drugs: N-acetyl cysteine, Pentoxifylline, anti-TNFα agents Cirrhosis (Organ failure/ Portal hypertension) Liver transplant Incorrect Options: Lifestyle modification + Vitamin E + Ursodeoxycholic acid (Option B) and Lifestyle modification + Pioglitazone (Option C) are treatment modalities for non-alcoholic steatohepatitis and not for alcohol hepatitis. Lifestyle modification (Option D) like stopping alcohol intake is helpful but would be more efficient with exercise and dietary changes.

References:

Harrison's Principles of Internal Medicine, 21st Edition, Page: 2618, 2619, 2626.

↑ *Back to this question in Part A*

@Neet_pg_bot

Q19: The work-up of a 25-year-old hotel worker shows the following profile: HbsAg = Negative Anti HBsAg= Negative HBeAg = Negative Anti Hbe = Negative Total anti-HBc = IgG positive What is the diagnosis? (Q854667)

A. Chronic hepatitis B

B. Inactive carrier

C. Hepatitis B in remote past

D. Window period/ Gap period

Correct Answer: C. Hepatitis B in remote past

Explanation: The negative hepatitis B profile except for the anti-HBc (IgG positive) shows a hepatitis B infection in the remote past. Phase/Condition HBsAg Anti-HBs HBeAg Anti-HBe Anti-HBc Acute HBV + Nil + Nil IgM Window Phase (Option D) Nil Nil Nil + IgM Chronic HBV (Option A) / Infective carrier (High infectivity) + Nil + Nil IgG Chronic HBV/ Healthy carrier (Low infectivity) (Option B) + Nil Nil + IgG Remote infection Nil Nil Nil Nil IgG Recovery Nil + Nil + IgG Immunized Nil + Nil Nil Nil {{caption_text}} Acute HBV infection with recovery {{caption_text}} Chronic HBV infection

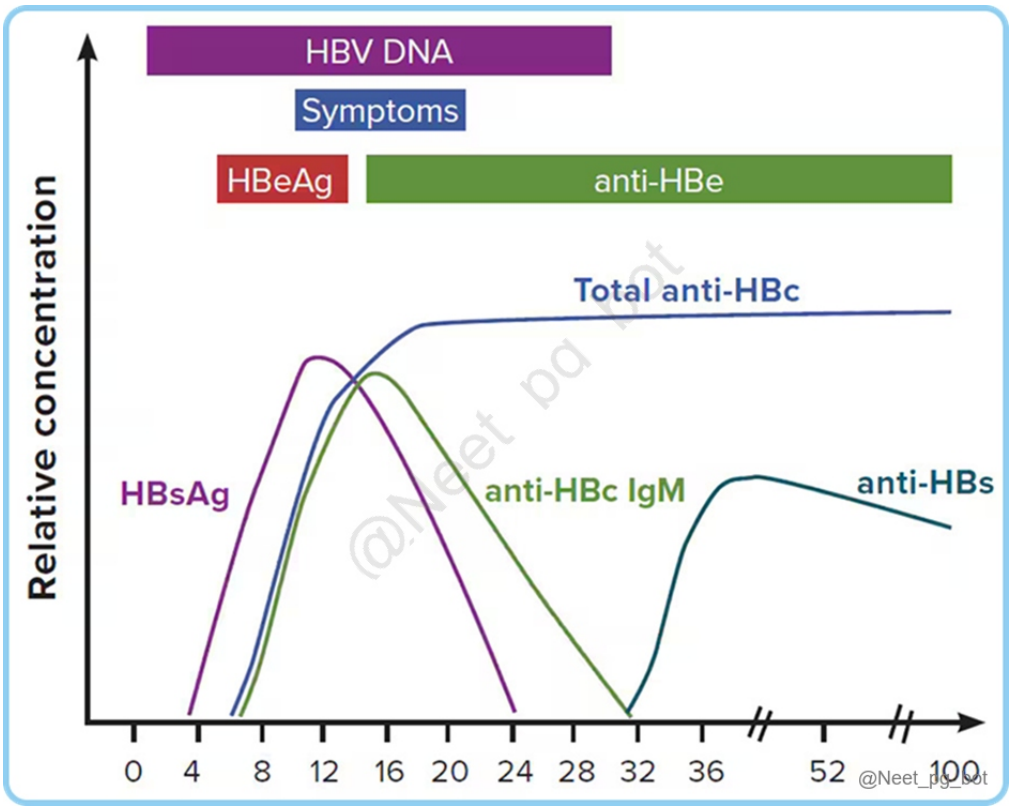

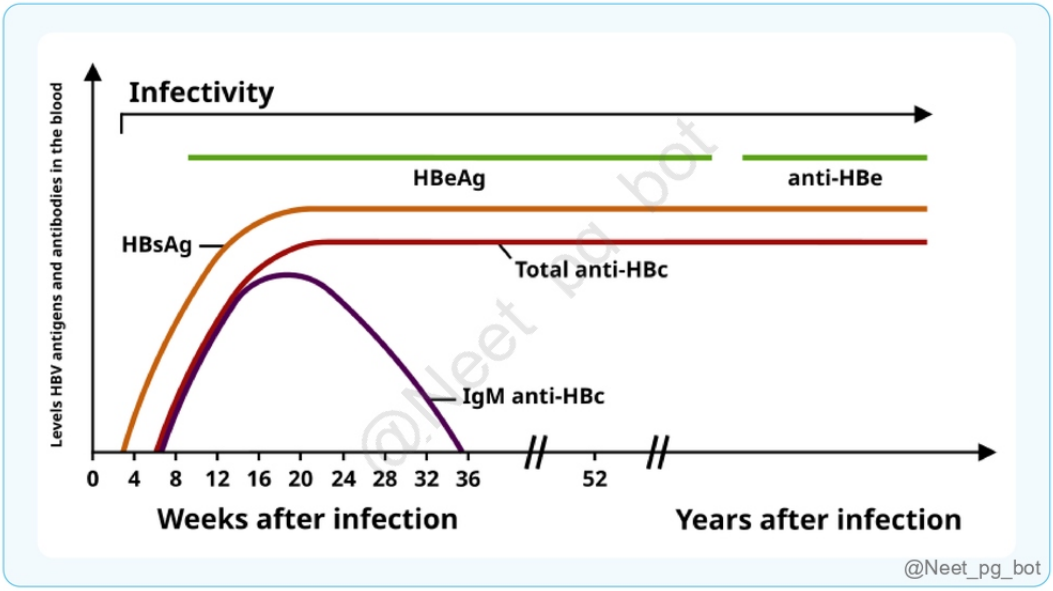

References:

https://www.researchgate.net/publication/354997816_Hepatitis_B_Vaccines

↑ *Back to this question in Part A*

@Neet_pg_bot

Q20: A 55-year-old man with a history of chronic alcoholism presents unconscious and hypotensive. He stopped drinking 7 days ago. Ultrasound shows coarse liver echotexture and mild portal vein dilatation. There is no history of recent alcohol withdrawal symptoms. What is the most appropriate next step in management? (Q840114)

A. Administer lactulose and wait for stool passage.

B. Perform emergency endoscopy to assess for varices.

C. Initiate treatment with thiamine and chlordiazepoxide.

D. Conduct a CT scan of the brain.

Correct Answer: A. Administer lactulose and wait for stool passage.

Explanation: Correct Option A - Administer lactulose and wait for stool passage: The patient is an unconscious chronic alcoholic with ultrasound findings suggestive of chronic liver disease . No recent alcohol intake + altered sensorium + portal hypertension features → strongly suggest hepatic encephalopathy (HE) . Lactulose is the first-line treatment for hepatic encephalopathy: Acts as an osmotic laxative → increased stool frequency removes nitrogenous waste. Acidifies colonic contents → converts NH■ to NH■■ (non-absorbable). Promotes growth of non-urease-producing bacteria → reduces ammonia production. Goal: 2–3 soft stools/day . Perform emergency endoscopy to assess for varices (Option B): Endoscopy is reserved for suspected active variceal bleeding . Initiate treatment with thiamine and chlordiazepoxide (Option C): Thiamine and chlordiazepoxide are prescribed to manage delirium tremens, which may manifest as rage episodes, elevated blood pressure, and increased heart rate. Conduct a CT scan of the brain (Option D): A CT scan is done to look for cerebral edema in hepatic encephalopathy but it is not the immediate next step in this case.

References:

.

↑ *Back to this question in Part A*

@Neet_pg_bot

Q21: Patient presents with fatigue, pruritus and jaundice. Examination reveals hepatomegaly. LFT shows gross SAP elevation and elevated conjugated bilirubin. What is the most specific test to support diagnosis of PBC? (Q866508)

A. Anti-mitochondrial antibody

B. Antinuclear antibody

C. Anti-smooth muscle antibody

D. Anti L.K.M-1

Correct Answer: A. Anti-mitochondrial antibody

Explanation: Primary Biliary Cholangitis (PBC) is an autoimmune cholestatic liver disease characterized by destruction of intrahepatic bile ducts. The hallmark lab features are: Markedly elevated alkaline phosphatase (SAP) Conjugated hyperbilirubinemia in later stages Positive anti-mitochondrial antibodies (AMA) — present in >90% of cases and highly specific for PBC. Antinuclear antibody (Option B): Can be positive in PBC but is nonspecific; also seen in autoimmune hepatitis and other autoimmune disorders. Anti-smooth muscle antibody (Option C): Seen in autoimmune hepatitis type 1, not PBC. Anti-L.K.M-1 (Option D): Seen in autoimmune hepatitis type 2, especially in children.

↑ *Back to this question in Part A*

@Neet_pg_bot

Q22: A 5 year old boy presented with hematemesis and was found to have splenomegaly, on examination. There was a past history of exchange transfusion in this child for neonatal jaundice. What is the probable diagnosis? (Q866830)

A. Splenic vein thrombosis

B. Portal vein thrombosis

C. Budd chiari syndrome

D. Liver cirrhosis

Correct Answer: B. Portal vein thrombosis

Explanation: The presentation of hematemesis and splenomegaly, along with the significant history of exchange transfusion in the neonatal period, strongly suggests portal vein thrombosis. This condition is a common cause of portal hypertension in children and can result from umbilical vein catheterization during exchange transfusion. Incorrect Options: Splenic vein thrombosis (Option A) is also a possibility in a case of splenomegaly, but the history of exchange transfusion suggests a more generalized thrombotic event involving the portal vein. Budd-Chiari syndrome (Option C) is a condition characterized by the obstruction of hepatic veins, leading to liver congestion. It is less likely in this case, as the presentation of hematemesis and splenomegaly is more suggestive of portal vein involvement. Liver cirrhosis (Option D): Although it can cause portal hypertension, cirrhosis is uncommon in a 5-year-old without a history of chronic liver disease.

↑ *Back to this question in Part A*

@Neet_pg_bot

Q23: A 20-year-old male presented with a 1 weak history of yellow skin and sclerae but is otherwise asymptomatic . He gives a history of viral upper respiratory infection 10 days ago, which resolved 2 days back. There is a history of a similar episode of icterus 2 years back when the patient had long hours of basketball practice . The current serum bilirubin is 2.4 mg/dl, unconjugated bilirubin is 2.1mg/dl, and conjugated bilirubin is 0.3mg/dl. Serum AST and ALT levels are normal . Which of the following is the most likely diagnosis ? (Q793887)

A. Dubin-Johnson syndrome

B. Criggler-Najar type 1 syndrome

C. Gilbert syndrome

D. Rotor syndrome

Correct Answer: C. Gilbert syndrome

Explanation: Correct Option C - Gilbert syndrome: Based on the given history and laboratory findings, the most likely diagnosis is Gilbert syndrome. The patient's age, male gender, and history of recent viral infection suggest an acute episode of unconjugated hyperbilirubinemia, which is common in Gilbert syndrome. The normal levels of serum AST and ALT exclude the possibility of liver injury or hepatitis. The elevated levels of unconjugated bilirubin and normal levels of conjugated bilirubin are consistent with the diagnosis of Gilbert syndrome. Gilbert syndrome is a common genetic disorder that causes mild unconjugated hyperbilirubinemia due to reduced activity of UDPGT enzyme. It is usually asymptomatic, but patients may present with intermittent episodes of mild jaundice triggered by fasting, dehydration, and stress. In Gilbert syndrome, serum levels of unconjugated bilirubin are elevated, while conjugated bilirubin levels are usually normal. Serum AST and ALT levels are also normal. Incorrect Options: Option A - Dubin-Johnson syndrome: Dubin-Johnson syndrome is a rare genetic disorder that causes chronic conjugated hyperbilirubinemia (increased levels of bilirubin conjugated with glucuronic acid) due to impaired excretion of bilirubin from hepatocytes. It is usually asymptomatic, but patients may present with mild jaundice and dark urine. In Dubin-Johnson syndrome, serum levels of both conjugated and unconjugated bilirubin are elevated. Serum AST and ALT levels may also be elevated. Option B - Criggler-Najar type 1 syndrome: Criggler-Najar type 1 syndrome is another rare genetic disorder that causes severe unconjugated hyperbilirubinemia due to impaired activity of uridine diphosphate glucuronyl transferase (UDPGT) enzyme. The condition is characterized by recurrent episodes of jaundice and kernicterus (a type of brain damage caused by bilirubin deposition in the brain) in infancy. In Criggler-Najar type 1 syndrome, serum levels of unconjugated bilirubin are significantly elevated, while conjugated bilirubin levels are usually normal. Option D - Rotor syndrome: Rotor syndrome is a rare genetic disorder that causes chronic conjugated hyperbilirubinemia due to impaired uptake and storage of bilirubin in hepatocytes. It is usually asymptomatic, but patients may present with mild jaundice and dark urine. In Rotor syndrome, serum levels of conjugated bilirubin are elevated, while unconjugated bilirubin levels are usually normal. Serum AST and ALT levels may also be elevated.

References:

Prepladder Notes

↑ *Back to this question in Part A*

@Neet_pg_bot

• [10_Pulmonology] 074 Cystic Fibrosis Obstructive Sleep Apnea

« Back to Folder Directory

[10_Pulmonology] 074 Cystic Fibrosis Obstructive Sleep Apnea — Quick Jump

Q1 (p. 2844) *Q2 (p. 2845)* *Q3 (p. 2845)* *Q4 (p. 2846)* *Q5 (p. 2847)* *Q6 (p. 2847)*
Q7 (p. 2848) *Q8 (p. 2849)* *Q9 (p. 2849)* *Q10 (p. 2850)* *Q11 (p. 2851)* *Q12 (p. 2852)*
Q13 (p. 2852) *Q14 (p. 2853)* *Q15 (p. 2854)* *Q16 (p. 2855)*

Q1: A 16-year-old female with cystic fibrosis presents with increased productive cough, fever, and worsening shortness of breath. Her sputum culture grows Pseudomonas aeruginosa. Which of the following best explains why this organism commonly causes respiratory infections in cystic fibrosis patients? (Q851570)

A. Defective neutrophil chemotaxis to the site of infection

B. Abnormal periciliary fluid layer leading to impaired mucociliary clearance

C. Direct immunosuppressive effect of the CFTR protein mutation

D. Increased expression of bacterial adhesion molecules on respiratory epithelium

Correct Answer: B. Abnormal periciliary fluid layer leading to impaired mucociliary clearance

Explanation: In cystic fibrosis, mutations in the CFTR gene lead to dysfunction of the chloride channel, which results in abnormal ion transport across epithelial surfaces. This causes depletion of the periciliary fluid layer (PCL). The abnormal PCL prevents proper ciliary function and mucus clearance, creating an environment where bacteria like P. aeruginosa can thrive and establish chronic infections. Pathogenesis of Cystic Fibrosis: CFTR Defect (F508del) → Defective chloride/bicarbonate transport → Airway Changes: ↓ PCL, mucus accumulation, impaired mucociliary clearance → Increased risk of infection → Clinical features: Progressive lung damage Neutrophil chemotaxis is not defective in CF (Option A): There is an aggressive neutrophilic inflammatory response in CF airways. CFTR mutations don't cause immunosuppression (Option C): The immune system remains active and responsive, with ongoing innate and adaptive immune reactivity While bacterial adhesion may occur, the primary pathogenic mechanism is the mechanical failure of mucus clearance due to abnormal PCL, not increased adhesion molecules (Option D)

References:

Harrison’s Principles of Internal Medicine, 21st Edition, Volume I, Page. 2176, 2177

↑ *Back to this question in Part A*

@Neet_pg_bot

Q2: A 3-month-old infant presents with failure to thrive, recurrent respiratory infections, and elevated sweat chloride. Genetic testing reveals two copies of the F508del mutation in the CFTR gene. This mutation results in a protein that fails to reach the cell surface due to degradation in the endoplasmic reticulum. Which class of CFTR mutation does this represent, and what percentage of CF patients carry at least one copy of this mutation? (Q851571)

A. Class I mutation; ~30% of patients

B. Class II mutation; ~70% of patients

C. Class III mutation; ~50% of patients

D. Class IV mutation; ~40% of patients

Correct Answer: B. Class II mutation; ~70% of patients

Explanation: F508del is a Class II CFTR mutation characterized by protein processing defects. It is the most common mutation class in Cystic fibrosis , with 70% of CF patients carrying at least one copy of the F508del mutation Genetic basis of CFTR Mutation- Cystic Fibrosis Mutation Class Severity Protein Effect Clinical Impact Class I & II Severe No functional protein or severe processing defect Pancreatic insufficiency, severe lung disease Class III & IV Moderate Defective channel function or conductance Variable pancreatic status, moderate lung disease Class V Mild to Moderate Reduced amount of normal protein Lower incidence of pancreatic insufficiency compared to class I and II, milder lung disease Class VI Variable Decreased protein stability Variable severity based on protein turnover rate

References:

Harrison’s Principles of Internal Medicine, 21st Edition, Volume I, Page. 2176, 2177

↑ *Back to this question in Part A*

@Neet_pg_bot

Q3: A 3-year-old boy comes to the emergency department with difficulty breathing and a productive cough. He has a history of recurrent sinusitis and otitis media and usually responds well to antibiotics. Crackles and wheezing are heard on pulmonary auscultation and CVS examination shows the cardiac point of maximum impulse on the right 5th intercostal space. Which of them is not seen in this condition? (Q851572)

A. Dynein arm defect

B. Normal sweat chloride test

C. CFTR mutation

D. Defective mucociliary clearance

Correct Answer: C. CFTR mutation

Explanation: The presentation (recurrent sinusitis/otitis, bronchiectasis, and situs inversus: dextrocardia) fits Kartagener/primary ciliary dyskinesia , which is not caused by CFTR mutation . Classic triad of Kartagener Syndrome: Bronchiectasis → recurrent respiratory infections, productive cough Chronic sinusitis & otitis media Situs inversus → apex beat on right side Dynein arm defect (Option A) causes i mpaired ciliary motility and is seen in primary ciliary dyskinesia. Normal sweat chloride test (Option B) is typical in primary ciliary dyskinesia (distinguishes it from cystic fibrosis). Defective mucociliary clearance (Option D) leads to recurrent sinopulmonary infections and bronchiectasis in this condition.

References:

Harrison's Principles of Internal Medicine, 21st Edition, Volume I, Page. 2176, 2177

journals.lww.com/lungindia/fulltext/2012/29040/kartagener_s_syndrome__a_case_series.13.aspx

↑ *Back to this question in Part A*

@Neet_pg_bot

Q4: A 7-year-old child presents with a chronic productive cough, nasal polyps, and poor weight gain despite normal appetite. Which of the following is the most likely associated condition? (Q851573)

A. Primary ciliary dyskinesia

B. Asthma

C. Cystic fibrosis

D. Bronchopulmonary dysplasia

Correct Answer: C. Cystic fibrosis

Explanation: Chronic productive cough, nasal polyps, and failure to thrive despite good appetite are classic for cystic fibrosis , caused by a CFTR gene mutation leading to thick secretions and malabsorption. Primary ciliary dyskinesia (Option A): Causes recurrent sinopulmonary infections and situs inversus, but weight gain is usually normal. Asthma (Option B): Causes wheezing and cough, but not nasal polyps with malabsorption/poor weight gain. Bronchopulmonary dysplasia (Option D): Seen in premature infants on prolonged oxygen/ventilation, not in this scenario.

References:

Harrison’s Principles Of Internal Medicine, 21st Edition, Volume I, Page 2202, 2203

↑ *Back to this question in Part A*

@Neet_pg_bot

Q5: A 2-month-old infant presents with recurrent respiratory infections and failure to thrive. Physical examination reveals digital clubbing and productive cough. A sweat test shows elevated chloride levels, but the genotype analysis for common CFTR mutations is inconclusive. Which of the following investigations is the next best step for confirming the diagnosis of cystic fibrosis in this patient? (Q851574)

A. Bronchoalveolar lavage

B. Nasal potential difference measurement

C. Chest X-ray

D. Genetic panel including rare CFTR mutations

Correct Answer: B. Nasal potential difference measurement

Explanation: When sweat chloride is elevated but common CFTR mutations are not detected , the next best test for confirming cystic fibrosis is nasal potential difference measurement , which assesses abnormal chloride transport across respiratory epithelium. Cystic fibrosis (CF) is primarily diagnosed through a combination of clinical presentation, sweat chloride testing, genetic testing, and other tests such as nasal potential difference measurement. Bronchoalveolar lavage (Option A): Used for infection sampling, not diagnostic for CF. Chest X-ray (Option C): May show bronchiectasis or hyperinflation, but findings are nonspecific. Genetic panel including rare CFTR mutations (Option D): Can help later, but nasal potential difference is the confirmatory functional test when initial genetic testing is inconclusive.

References:

Harrison’s Principles Of Internal Medicine, 21st Edition, Volume I, Page 2176-2179.

https://www.researchgate.net/publication/5507809_Cystic_fibrosis_in_adults_Diagnostic_and_therapeutic_aspects

↑ *Back to this question in Part A*

@Neet_pg_bot

Q6: A newborn screening for CF shows elevated immunoreactive trypsinogen (IRT) levels. What is the next best step in the diagnostic process? (Q851575)

A. Repeat the IRT test in 6 months

B. Genetic testing for CFTR mutations

C. Chest X-ray

D. Fecal elastase levels

Correct Answer: B. Genetic testing for CFTR mutations

Explanation: Elevated IRT on newborn screening warrants follow-up with genetic testing for common CFTR mutations to confirm the diagnosis of CF in neonates■. Neonatal Screening of CF: Initial IRT Screening: Elevated immunoreactive trypsinogen (IRT) in a newborn suggests pancreatic stress and is a marker for CF. Genetic Testing Follow-up: If IRT is elevated, common CFTR mutations are checked. If the child tests positive for CFTR mutations, further diagnostic confirmation is pursued. Early detection allows for prompt initiation of treatments, improving growth and reducing the frequency of pulmonary exacerbations, which can delay lung disease progression. Repeat the IRT test in 6 months (Option A) : Waiting without confirmatory testing may delay diagnosis. Chest X-ray (Option C) : Chest X-ray does not confirm CF. Fecal elastase (Option D) is used to assess pancreatic function in CF, but it is not a diagnostic test for CF in newborns with elevated IRT.

References:

https://www.ias.ac.in/article/fulltext/jbsc/049/0064

https://www.researchgate.net/publication/340652214_Newborn_Screening_for_Cystic_Fibrosis_in_Russia_A_Catalyst_for_Improved_Care

↑ *Back to this question in Part A*

@Neet_pg_bot

Q7: Which of the following therapies directly targets the basic molecular defect in cystic fibrosis for a patient with a G551D mutation? (Q851576)

A. Pancreatic enzyme supplements

B. Lumacaftor

C. Ivacaftor

D. Hypertonic saline nebulization

Correct Answer: C. Ivacaftor

Explanation: Ivacaftor is a CFTR modulator that potentiates the CFTR channel, especially in patients with G551D mutations, enhancing chloride ion transport across cell membranes■. Pancreatic enzyme supplements (Option A) help digestion but do not address the CFTR defect. Lumacaftor (Option B) is used for F508del mutations. Hypertonic saline nebulization (Option D) aids mucus clearance but does not modify CFTR function.

References:

Harrison's Principles Of Internal Medicine, 21st Edition, Volume I, Page 2178-2180.

↑ *Back to this question in Part A*

@Neet_pg_bot

Q8: A 45-year-old obese male (BMI- 40) presents with complaints of loud snoring and daytime sleepiness. His wife reports that he complains of disturbed sleep due to waking up out of breath because of an obstruction of the airway. Polysomnography reveals repetitive episodes showing: Sharp inspiratory uptake Flattened/plateau wave Scooped out breathing pattern Flow limitation Oxygen desaturation What is the correct sequence of pathophysiologic events leading to his symptoms? (Q851577)

A. REM sleep → Hypoxia → Pharyngeal dilator muscle relaxation → Airway narrowing → snoring

B. Pharyngeal dilator muscle relaxation → Airway narrowing → Flow limitation → Hypoxia → Cortical arousal

C. Obesity → Flow limitation → Airway collapse → Snoring → Bradycardia → Hypoxia

D. Hypoxia → Airway collapse → Flow limitation → Bradycardia → Cortical arousal

Correct Answer: B. Pharyngeal dilator muscle relaxation → Airway narrowing → Flow limitation → Hypoxia → Cortical arousal

Explanation: The pathophysiologic sequence in obstructive sleep apnea (OSA) begins with: Pharyngeal dilator muscle tone decreases during REM sleep This leads to the narrowing of the airway Flow limitation occurs, causing characteristic breathing pattern Resultant hypoxia develops Finally, cortical arousal occurs to restore airway patency

References:

Harrison's Principles Of Internal Medicine, 21st Edition, Volume I, Page 2204-2208.

↑ *Back to this question in Part A*

@Neet_pg_bot

Q9: A 45-year-old man presents with complaints of daytime sleepiness and morning headaches, and his wife reports loud snoring with episodes of gasping during sleep. His BMI is 32 kg/m², neck circumference is 44 cm, and he has retrognathia. His blood pressure is 148/92 mmHg. Which of the following combinations of additional clinical features and diagnostic findings would not be seen with obstructive sleep apnea in this patient? (Q851578)

A. Fragmented sleep on PSG

B. Central obesity, elevated sweat chloride, pancreatic insufficiency

C. Nondipping nocturnal blood pressure pattern

D. Frequent arousals with oxygen desaturation

Correct Answer: B. Central obesity, elevated sweat chloride, pancreatic insufficiency

Explanation: Obstructive sleep apnea (OSA) is associated with obesity, retrognathia, daytime sleepiness, fragmented sleep, nocturnal oxygen desaturation, and nondipping blood pressure , but elevated sweat chloride and pancreatic insufficiency are features of cystic fibrosis, not OSA . Fragmented sleep on PSG (Option A): Typical in OSA due to repeated arousals. Nondipping nocturnal blood pressure pattern (Option C): Common in OSA, related to sympathetic activation. Frequent arousals with oxygen desaturation (Option D): Characteristic PSG finding in OSA.

References:

Harrison's Principles of Internal Medicine, 21st Edition, Volume I, Page. 2206, 2207

↑ *Back to this question in Part A*

@Neet_pg_bot

Q10: Which of the following statements is incorrect regarding risk factors of Obstructive Sleep Apnea? (Q851579)

A. Premenopausal women have the same risk for OSA as postmenopausal women

B. A 10% increase in body weight is associated with a >30% increase in apnea-hypopnea index (AHI)

C. Approximately 40-60% of OSA cases are attributable to excess body weight

D. Men have approximately twice the risk of developing OSA compared to women

Correct Answer: A. Premenopausal women have the same risk for OSA as postmenopausal women

Explanation: Premenopausal women have a lower risk of OSA compared to postmenopausal women due to protective effects of estrogen and progesterone; the risk increases after menopause. Risk factors for Obstructive sleep apnea Category Key Risk Factors Notes / Impact Demographic Male, Older age, Post-menopause, Family history Men 2x risk (Option D) ; risk ↑ with age; premenopause partly protective Anatomical Retrognathia/micrognathia, Large neck, Nasal obstruction, Enlarged tonsils ↑ airway collapsibility, ↓ airway diameter Body Composition Obesity (BMI>30), Central adiposity, Weight gain, Large waist 40–60% OSA due to weight (Option C); 10% weight gain → AHI ↑ >30% (Option B) Medical Conditions Hypothyroid, Acromegaly, DM, HTN, Down syndrome ↑ susceptibility; may affect treatment; bidirectional

References:

Harrison's Principles of Internal Medicine, 21st Edition, Volume I, Page. 2205, 2206

↑ *Back to this question in Part A*

@Neet_pg_bot

Q11: A 52-year-old man presents to his primary care physician with complaints of excessive daytime sleepiness and his spouse reports loud snoring with disturbed sleep due to breathing pauses during sleep. His BMI is 34 kg/m² and neck circumference is 43 cm. Which of the following should be the INITIAL step in evaluating this patient? (Q851580)

A. Order an overnight polysomnography immediately

B. Start CPAP therapy based on symptoms

C. Obtain detailed sleep history with standardized sleepiness questionnaires and perform focused physical examination

D. Order overnight home oximetry

Correct Answer: C. Obtain detailed sleep history with standardized sleepiness questionnaires and perform focused physical examination

Explanation: The initial evaluation of suspected OSA involves a comprehensive sleep history , assessment of daytime sleepiness (e.g., Epworth Sleepiness Scale) , and a focused physical exam to identify risk factors (obesity, neck circumference, craniofacial features). Order an overnight polysomnography immediately (Option A): PSG is the definitive diagnostic test, but not the first step. Start CPAP therapy based on symptoms (Option B): Treatment should be guided by confirmed diagnosis. Order overnight home oximetry (Option D): Can be used for screening or follow-up, but initial step is clinical assessment.

References:

Harrison's Principles of Internal Medicine, 21st Edition, Volume I, Page. 2205, 2206, 2207

↑ *Back to this question in Part A*

@Neet_pg_bot

Q12: A 45-year-old man is diagnosed with moderate obstructive sleep apnea (AHI=22/hour) based on polysomnography. He has daytime sleepiness, BMI of 35 kg/m², and hypertension. Which of the following is the most appropriate initial treatment approach for this patient? (Q851581)

A. Prescribe oral appliance therapy as first-line treatment

B. Initiate CPAP therapy with appropriate pressure titration and provide supportive care

C. Recommend uvulopalatopharyngoplasty without trying conservative measures

D. Lifestyle modification and weight loss

Correct Answer: B. Initiate CPAP therapy with appropriate pressure titration and provide supportive care

Explanation: For moderate OSA with symptoms and comorbidities (e.g., hypertension), CPAP is the first-line therapy , as it reduces apnea-hypopnea index, improves daytime sleepiness, and lowers cardiovascular risk. Prescribe oral appliance therapy as first-line treatment (Option A): Typically reserved for mild OSA or CPAP-intolerant patients. Recommend uvulopalatopharyngoplasty without trying conservative measures (Option C): Surgery is not first-line; considered if CPAP/oral appliance fail. Lifestyle modification and weight loss (Option D): Important adjunct therapy, but insufficient as sole treatment in symptomatic moderate OSA.

References:

Harrison’s Principles of Internal Medicine, 21st Edition, Volume I, Page. 2208, 2209

↑ *Back to this question in Part A*

@Neet_pg_bot

Q13: A 45-year-old male reports persistent daytime sleepiness, often dozing off during meetings and while watching television. He completes the Epworth Sleepiness Scale (ESS) and scores 12. What does a score of 12 indicate? (Q851583)

A. Unlikely to be abnormally sleepy.

B. Average daytime sleepiness.

C. Possibly excessively sleepy; consider medical attention.

D. Excessively sleepy; seek immediate medical attention.

Correct Answer: C. Possibly excessively sleepy; consider medical attention.

Explanation: An ESS score of 12 falls in the 10–12 range , indicating possible excessive daytime sleepiness , so the patient should be evaluated for causes such as obstructive sleep apnea or other sleep disorders. Epworth Sleepiness Scale: 0-7 : Unlikely to be abnormally sleepy. (Option A) 8-9 : Average daytime sleepiness. (Option B) 10-15 : Possibly excessively sleepy; consider medical attention. 16-24 : Excessively sleepy; seek medical attention. (Option D)

References:

Harrison’s Principles of Internal Medicine, 21st Edition, Page 2203

nasemso.org/wp-content/uploads/neuro-epworthsleepscale.pdf

www.cdc.gov/niosh/work-hour-training-for-nurses/longhours/mod2/09.html

↑ *Back to this question in Part A*

@Neet_pg_bot

Q14: A 52-year-old obese male presents to the clinic with excessive daytime sleepiness hypoventilation and difficulty breathing at night. His BMI is 32 kg/m², and arterial blood gas analysis shows a Paco2 of 48 mmHg recorded during the day. The patient reports loud snoring and episodes of gasping during sleep. He has a history of severe obesity and is suspected of having obstructive sleep apnea. Based on the scenario, which of the following diagnoses is most likely? (Q851594)

A. Central Hypoventilation Syndrome

B. Obesity Hypoventilation Syndrome

C. Congenital Central Hypoventilation Syndrome

D. Simple Obstructive Sleep Apnea

Correct Answer: B. Obesity Hypoventilation Syndrome

Explanation: This patient has obesity (BMI >30 kg/m²), daytime hypercapnia (PaCO■ >45 mmHg), and symptoms of sleep-disordered breathing , which are diagnostic criteria for Obesity Hypoventilation Syndrome (OHS) . Central Hypoventilation Syndrome (Option A): Usually congenital or idiopathic, not associated with obesity. Congenital Central Hypoventilation Syndrome (Option C): Presents from birth, rare, unrelated to adult obesity. Simple Obstructive Sleep Apnea (Option D): Typically does not cause daytime hypercapnia; PaCO■ is usually normal.

References:

Harrison’s Principles of Internal Medicine, 21st Edition, Page 2203, 2204

↑ *Back to this question in Part A*

@Neet_pg_bot

Q15: A 25-year-old tall male presents to the emergency department with acute retrosternal chest pain and difficulty breathing after a vigorous bout of coughing. He reports having experienced frequent coughing spells over the past week due to a respiratory infection. On physical examination, subcutaneous emphysema is noted in the neck region. The chest X-ray of the patient is given below. Which of the following statements best describes a potential cause of this patient’s condition? (Q851595)

A. The condition is likely caused by a foreign body in the airway.

B. Increased intra-alveolar pressure from excessive coughing can lead to alveolar rupture.

C. This condition is primarily associated with high BMI individuals.

D. Always a result of blunt trauma.

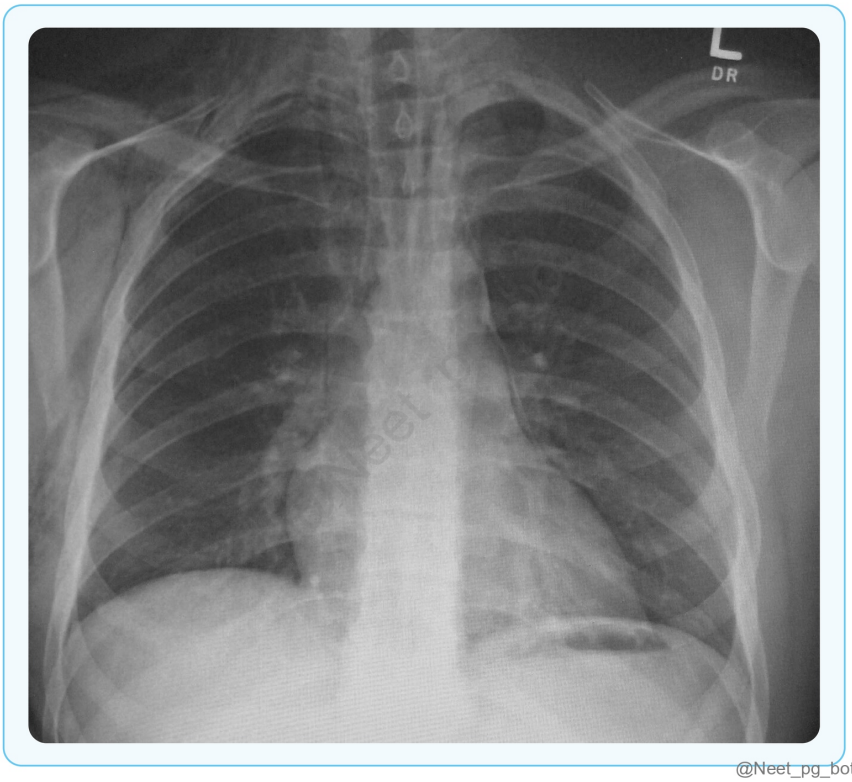

@Neet_pg_bot

Correct Answer: B. Increased intra-alveolar pressure from excessive coughing can lead to alveolar rupture.

Explanation: Pneumomediastinum is suggested by acute chest pain and dyspnea after vigorous coughing, causing increased intra-alveolar pressure and alveolar rupture. Chest X-ray shows air outlining mediastinal structures and subcutaneous emphysema, confirming the diagnosis. The condition is likely caused by a foreign body in the airway. (Option A): This is incorrect because the scenario does not mention any foreign body and the symptoms align more closely with increased intra-alveolar pressure due to coughing. This condition is primarily associated with high BMI individuals. (Option C): This is incorrect; pneumomediastinum is more commonly observed in individuals with low BMI, especially tall males. Always a result of blunt trauma. (Option D): This is incorrect because pneumomediastinum can occur from various causes, including spontaneous events and increased intra-alveolar pressure from coughing, not solely from trauma.

References:

Harrison's Principles of Internal Medicine, 21st Edition, Page 2201

Pneumomediastinum - StatPearls - NCBI Bookshelf

↑ *Back to this question in Part A*

@Neet_pg_bot

Q16: A 7-year-old boy presents to the emergency department with chest pain and difficulty breathing after experiencing a severe coughing fit. A chest X-ray is performed and is given below. Which of the following statements is true regarding the management of this condition? (Q851597)

A. The primary diagnostic tool for this condition is a CT scan.

B. Surgical intervention is always required for treatment.

C. Conservative management is usually sufficient for most patients with this condition.

D. Prophylactic antibiotics are necessary for all patients diagnosed.

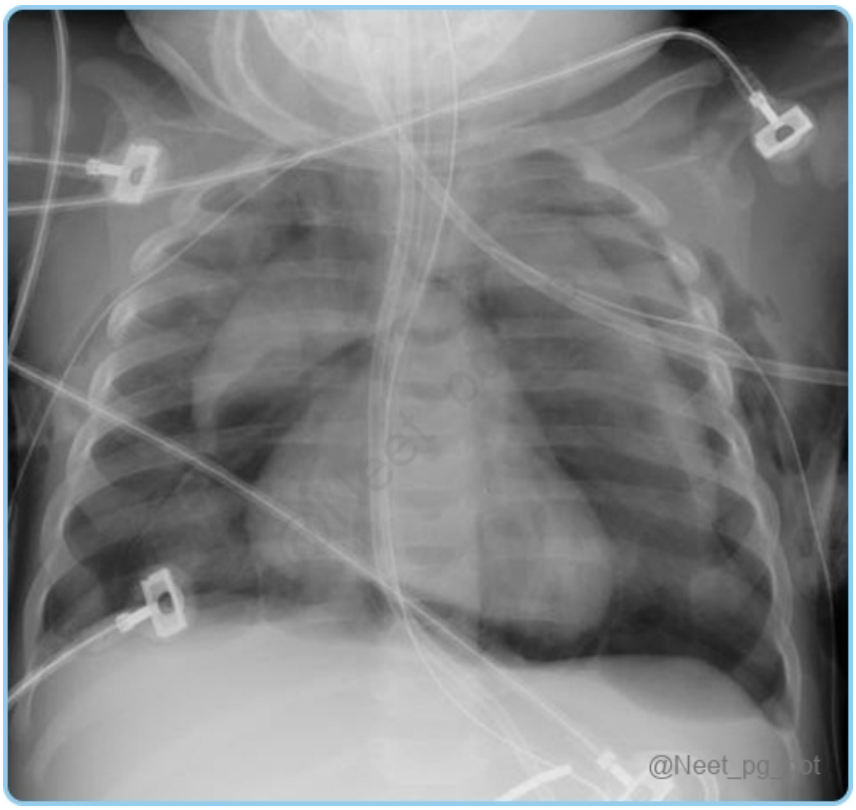

Correct Answer: C. Conservative management is usually sufficient for most patients with this condition.

Explanation: In this scenario, the 7-year-old boy presents with chest pain and difficulty breathing following a severe coughing fit. The chest X-ray reveals air outlining the mediastinal structures, which is characteristic of pneumomediastinum. Most cases of pneumomediastinum in pediatric patients are self-limited and can be managed conservatively with symptomatic treatment. The primary diagnostic tool for this condition is a CT scan (Option A): Chest X-ray is usually sufficien {{caption_text}} Surgical intervention is always required for treatment (Option B): Surgery is rarely needed, only if complications occur. Prophylactic antibiotics are necessary for all patients diagnosed (Option D): Not routinely indicated, only if secondary infection is suspected.

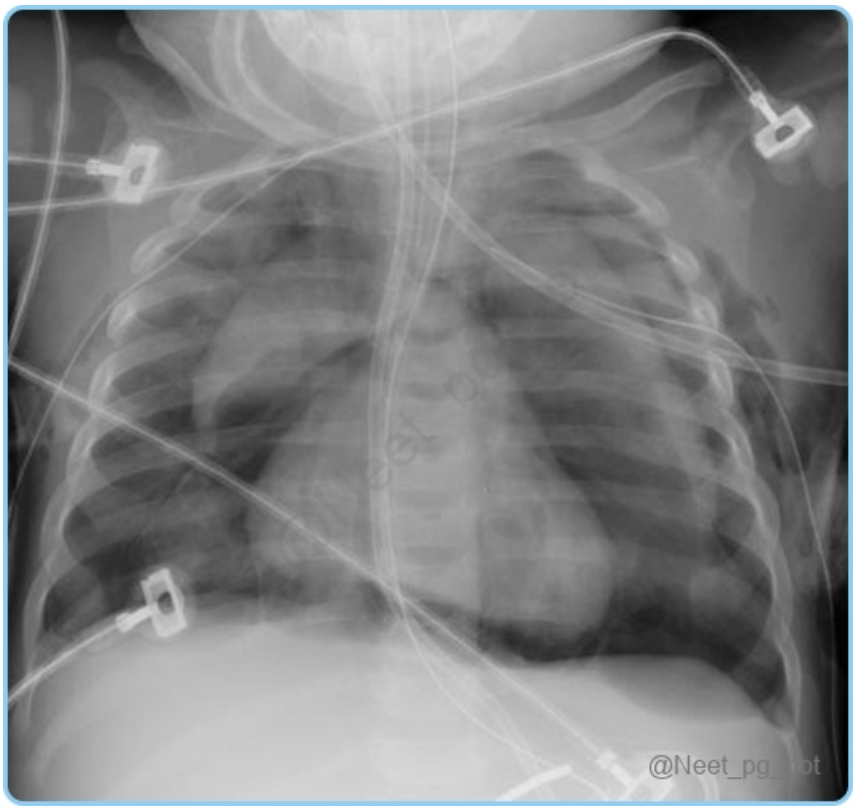

References:

Harrison’s Principles of Internal Medicine, 21st Edition, Page 2201

Pneumomediastinum - StatPearls - NCBI Bookshelf

radiopaedia.org/articles/pneumomediastinum

↑ *Back to this question in Part A*

@Neet_pg_bot

• [10_Pulmonology] 075 Pulmonary Embolism Dvt And Fat Embolism

« Back to Folder Directory

[10_Pulmonology] 075 Pulmonary Embolism Dvt And Fat Embolism — Quick Jump

Q1 (p. 2858) *Q2 (p. 2858)* *Q3 (p. 2859)* *Q4 (p. 2860)* *Q5 (p. 2861)* *Q6 (p. 2861)*
Q7 (p. 2862) *Q8 (p. 2863)* *Q9 (p. 2864)* *Q10 (p. 2864)* *Q11 (p. 2867)* *Q12 (p. 2868)*
Q13 (p. 2869) *Q14 (p. 2870)* *Q15 (p. 2871)*

Q1: A 30-year-old male develops respiratory distress, confusion, and a chest petechial rash two days after surgery for multiple long bone fractures from a motor vehicle accident. Suspecting Fat Embolism Syndrome (FES), which diagnostic test is used to detect fat in this condition? (Q851917)

A. Chest CT

B. Bronchoalveolar lavage (BAL)

C. Intracranial Doppler ultrasonography

D. Head CT

Correct Answer: B. Bronchoalveolar lavage (BAL)

Explanation: Bronchoalveolar lavage (BAL) is the modality specifically used to detect fat in the form of lipid-laden macrophages, which is important for the diagnosis of Fat Embolism Syndrome (FES). Chest CT (Option A): Detects lung damage from emboli, but not fat specifically. Intracranial Doppler ultrasonography (Option C): Detects cerebral emboli but not fat specifically. Head CT (Option D): Identifies brain injury from emboli, not fat directly.

References:

https://emedicine.medscape.com/article/460524-workup#showall

↑ *Back to this question in Part A*

@Neet_pg_bot

Q2: A 60 y/o woman presents with sudden shortness of breath and pleuritic chest pain. She had a total hip replacement 10 days ago. O/E, she is tachycardic with low oxygen

levels. What is the most likely cause of her symptoms? (Q851892)

A. Fat embolism

B. Tumor emboli

C. Air emboli

D. Pulmonary embolism

Correct Answer: D. Pulmonary embolism

Explanation: Pulmonary embolism (PE) resulting from Deep Vein Thrombosis (DVT) is the likely cause in this case. Blood clot from the deep veins can travel to the lungs, causing sudden symptoms such as dyspnea, chest pain, tachycardia, and hypoxemia. The patient's recent hip surgery and post-operative immobility significantly increase the risk of developing DVT in the lower limbs. Post-operative DVT and subsequent PE are common complications of joint replacement surgeries. Fat embolism (Option A): Occurs 24–72 hours after long-bone trauma—not 10 days post-surgery; presents with petechiae and neurological signs. Tumor emboli (Option B): Seen in advanced malignancies, not in a postoperative orthopedic patient. Air emboli (Option C): Associated with central line placement or trauma; does not match this clinical context.

References:

Harrison's Principles of Internal Medicine, 21st Edition, Page 2094, 2095

Davidson's Principles and Practice of Medicine, 24th Edition, Page 619

Venous Gas Embolism

↑ *Back to this question in Part A*

@Neet_pg_bot

Q3: Which of the following statements regarding causes of DVT is true? (Q851893)

A. Factor V Leiden increases the effectiveness of activated protein C.

B. Prothrombin gene mutation decreases the concentration of prothrombin in the blood.

C. Cancer increases the risk of DVT fourfold compared to the general population.

D. Pregnancy reduces the risk of venous stasis.

Correct Answer: C. Cancer increases the risk of DVT fourfold compared to the general population.

Explanation: Inherited Thrombophilia Acquired Risk Factors Additional Factors Factor V Leiden (Option A) – Activated protein resistance Antiphospholipid antibody syndrome Age – risk ↑ with advancing age Prothrombin

gene mutation (Option B) – ↑ prothrombin concentration Cancer (Option C) – ~15% of DVT cases; risk 4X than general population Sex – females higher risk (pregnancy, hormones) Antithrombin / Protein C / Protein S deficiency Surgery – major ortho/abdominal/neurological Ethnicity – may influence risk Pregnancy (Option D) – venous stasis, hypercoagulable state Immobility – prolonged bedrest or travel Other – obesity, smoking, hypertension, COPD, kidney disease, estrogen therapy, trauma

References:

Harrison's Principles of Internal Medicine, 21st Edition, Page 726, 922, 923, 2092

Davidson's Principles and Practice of Medicine, 24th Edition, Page 975

↑ *Back to this question in Part A*

@Neet_pg_bot

Q4: A 62 y/o hypertensive woman with a history of recent surgery presents with sudden onset of dyspnea and chest pain. ABG analysis reveals hypoxemia. A CT angiogram confirms the presence of a pulmonary embolism. What describes changes in the lung in this condition? (Q851895)

A. Increased pulmonary compliance

B. Decreased alveolar-arterial oxygen gradient

C. Increased physiologic dead space

D. Improved gas exchange efficiency

Correct Answer: C. Increased physiologic dead space

Explanation: Pulmonary Embolism leads to hypoxemia (low oxygen levels) due to disrupted gas exchange. It leads to the following: Increased anatomic dead space : Air cannot reach functional alveoli. Increased physiologic dead space : Air reaches alveoli, but there is inadequate blood flow for gas exchange . This leads to areas of the lung where air is present, but no corresponding blood flow is available to facilitate oxygen and carbon dioxide transfer. Increased pulmonary compliance (Option A): In a pulmonary embolism, there is decreased lung compliance due to loss of surfactant and lung edema. Decreased alveolar-arterial oxygen gradient (Option B): PE results in an increased alveolar-arterial oxygen gradient. While oxygen levels in the alveoli may remain high, the obstruction prevents adequate blood flow, leading to impaired gas exchange, and causing a significant difference between alveolar and arterial blood oxygen levels. Improved gas exchange efficiency (Option D): The presence of a pulmonary embolism impairs gas exchange efficiency due to the obstruction of blood flow, resulting in impaired oxygenation of the blood and diminished overall lung function. There is airway resistance distal to the bronchi.

References:

Harrison's Principles of Internal Medicine, 21st Edition, Page 2094

Davidson’s Principles and Practice of Medicine, 24th Edition, Page 620

↑ *Back to this question in Part A*

@Neet_pg_bot

Q5: A 45 y/o man presents with chest pain and dyspnea. A CT scan shows multiple pulmonary emboli. He is diagnosed with right ventricular dysfunction secondary to the emboli. Which of the following best explains the cause of the same? (Q851896)

A. Left ventricular failure

B. Microinfarctions of the right ventricle

C. Decreased pulmonary vascular resistance

D. Improved coronary perfusion

Correct Answer: B. Microinfarctions of the right ventricle

Explanation: Pulmonary Embolism → Mechanical blockage by embolus + vasoconstriction due to serotonin → Increased pulmonary artery resistance → Increased strain on right ventricle → Right ventricular wall tension rises → RV dilation → Microinfarctions in right ventricle (Option B) → Acute right ventricular dysfunction. Left ventricular failure (Option A): Right ventricular dysfunction is due to increased resistance in the pulmonary arteries and microinfarctions caused by the emboli, rather than left heart issues. There is reduced cardiac output as the blood reaching the left ventricle decreases. Decreased pulmonary vascular resistance (Option C): Pulmonary embolism leads to increased vascular resistance. The obstruction from the emboli causes an increase in RV wall tension and dilation resulting in strain and dysfunction. Improved coronary perfusion (Option D): Pulmonary embolism results in reduced coronary perfusion. The strain on the right ventricle causes reduced blood flow to the coronary arteries, worsening the right ventricular function.

References:

Harrison’s Principles of Internal Medicine, 21st Edition, Page 2094

Davidson’s Principles and Practice of Medicine, 24th Edition, Page 461

↑ *Back to this question in Part A*

@Neet_pg_bot

Q6: A 58 y/o woman with a history of DVT presents to the hospital with sudden onset chest pain, tachycardia, and cyanosis. She is diagnosed with a massive pulmonary embolism. What is the most likely clinical finding that indicates acute cor pulmonale?

(Q851898)

A. Loud S1 heart sound

B. Jugular venous distention

C. Bradycardia

D. Elevated blood pressure

Correct Answer: B. Jugular venous distention

Explanation: Elevated jugular venous pressure (JVP) is a classic sign of right heart failure or acute cor pulmonale. It indicates fluid overload and pressure changes in the right atrium due to the inability of the right ventricle to handle the increased pulmonary artery pressure. Acute Cor Pulmonale in Massive Pulmonary Thromboembolism: Acute cor pulmonale refers to right ventricular dysfunction due to a sudden rise in pulmonary artery pressure, often triggered by massive pulmonary embolism (PE). Clinical features: Sudden collapse or syncope Severe shortness of breath Hypotension and tachycardia (Options C and D) Elevated jugular venous pressure (JVP) Cyanosis Signs of right heart failure and a prominent pulmonic component of the second heart sound (P2). (Option A)

References:

Harrison’s Principles of Internal Medicine, 21st Edition, Page 1838, 2094

Davidson’s Principles and Practice of Medicine, 24th Edition, Page 200, 461, 619

↑ *Back to this question in Part A*

@Neet_pg_bot

Q7: A 62 y/o male presents to the emergency with a history of prolonged immobility after recent hip surgery. His vital signs are as follows: respiratory rate of 28 bpm, heart rate of 110 bpm, and blood pressure of 90/60 mmHg. The D-dimer level is 900 mg/dL, and the CTPA scan shows filling defects. What is the most common symptom associated with this condition at the initial stage of presentation? (Q851900)

A. Syncope

B. Pleuritic chest pain

C. Unexplained dyspnea

D. Hemoptysis

Correct Answer: C. Unexplained dyspnea

Explanation: The vital signs and imaging findings point to pulmonary embolism. When patients with pulmonary embolism (PE) first present, their symptom is s udden shortness of breath with no obvious cause. Unexplained dyspnea, or shortness of breath without an apparent cause , is the most common symptom reported in patients with pulmonary embolism. It occurs due to impaired gas exchange and increased pulmonary artery pressure, making it a critical indicator of the condition. Syncope (Option A), Pleuritic chest pain (Option B), Hemoptysis (Option D): Although all are features of pulmonary embolism, they occur less frequently than unexplained dyspnea.

References:

Harrison’s Principles of Internal Medicine, 21st Edition, Page 101, 2094, 2095

Davidson’s Principles and Practice of Medicine, 24th Edition, Page 11, 192, 619

↑ *Back to this question in Part A*

@Neet_pg_bot

Q8: A 62 y/o woman with a history of breast cancer is treated with chemotherapy. She presents with swelling and localised tenderness in her right leg. She was recently hospitalised for surgery and has been bedridden for the past three weeks. Examination shows pitting edema confined to the right leg, but no collateral veins and no previous DVT history. What is the patient's risk for DVT based on the Wells Criteria? (Q851901)

A. DVT unlikely

B. Low probability

C. Moderate probability

D. High probability

Correct Answer: D. High probability

Explanation: In the above patient: Active cancer (1 point) Recently bedridden (1 point) Localized tenderness (1 point) Entire leg swelling (1 point) Pitting oedema (1 point) Total Score = 5 (High probability for DVT Score 3-8). Criteria Points Active cancer (treatment ongoing, within 6 months, or palliative) 1 Paralysis, paresis, or recent immobilization of lower extremities 1 Recently bedridden ≥3 days or major surgery within 12 weeks 1 Localized tenderness along deep venous system 1 Entire leg swollen 1 Calf swelling ≥3 cm compared to other leg 1 Pitting edema confined to symptomatic leg 1 Collateral superficial veins (non-varicose) 1 Previous DVT 1 Alternative diagnosis at least as likely as DVT –2 Interpretation: High probability: ≥3 points Moderate probability: 1–2 points Low probability: 0 points

References:

https://pmc.ncbi.nlm.nih.gov/articles/PMC4898382/

https://pmc.ncbi.nlm.nih.gov/articles/PMC3948465/

↑ *Back to this question in Part A*

@Neet_pg_bot

Q9: A 65y/o man presents to the emergency department with a sudden onset of pleuritic chest pain, dyspnea, and mild hypotension. His echocardiogram shows right ventricular (RV) dysfunction, but his systemic arterial pressure remains normal. Which of the following is the most appropriate next step in management? (Q851904)

A. Immediate anticoagulation and observation

B. Fibrinolytic therapy

C. Catheter-directed thrombolysis

D. Surgical embolectomy

Correct Answer: C. Catheter-directed thrombolysis

Explanation: The patient presents with sudden pleuritic chest pain, dyspnea, and echocardiographic evidence of right ventricular (RV) dysfunction , all pointing toward submassive pulmonary embolism . Catheter-directed thrombolysis is preferred in such patients because it delivers a lower dose of thrombolytic drug directly into the clot , resulting in effective reperfusion with significantly lower bleeding risk Immediate anticoagulation and observation (Option A): While anticoagulation is necessary, observation alone may not be sufficient to address RV dysfunction, which could worsen without further intervention. Fibrinolytic therapy (Option B): Systemic fibrinolysis is generally reserved for massive PE with hemodynamic collapse and carries higher bleeding risks, particularly intracranial haemorrhage. Surgical embolectomy (Option D): Typically reserved for massive PE or cases refractory to thrombolysis, surgical embolectomy is too invasive for submassive PE with stable systemic pressure.

References:

Harrison’s Principles of Internal Medicine, 21st Edition, Page 102,105,110, 2071,2094, 2095, 2100, 2239

Davidson’s Principles and Practice of Medicine, 24th Edition, Page 563

↑ *Back to this question in Part A*

@Neet_pg_bot

Q10: A 60 y/o male with a history of recent surgery presents with acute onset dyspnea and pleuritic chest pain. His ECG findings show sinus tachycardia. Which of the following investigations would most directly confirm the diagnosis of pulmonary embolism (PE)? (Q851906)

A. Chest X-ray

B. Ventilation-perfusion (V/Q) scan

C. CT pulmonary angiogram

D. D-Dimer

Correct Answer: C. CT pulmonary angiogram

Explanation: CT pulmonary angiogram is the gold standard for diagnosing pulmonary embolism , as it allows direct visualization of the pulmonary arteries and identification of any occlusions. Chest X-ray (Option A): A chest X-ray can show indirect signs of PE, such as Westermark's sign or Hampton's hump, but it cannot definitively confirm the diagnosis of pulmonary embolism. Ventilation-perfusion (V/Q) scan (Option B): A V/Q scan can suggest the likelihood of PE by showing mismatched perfusion defects, but it is not as definitive as other imaging modalities. D-Dimer : A sensitive but nonspecific test for PE. Elevated levels indicate possible PE but can also occur with conditions like MI, pneumonia, or sepsis. Normal d-dimer helps rule out PE.

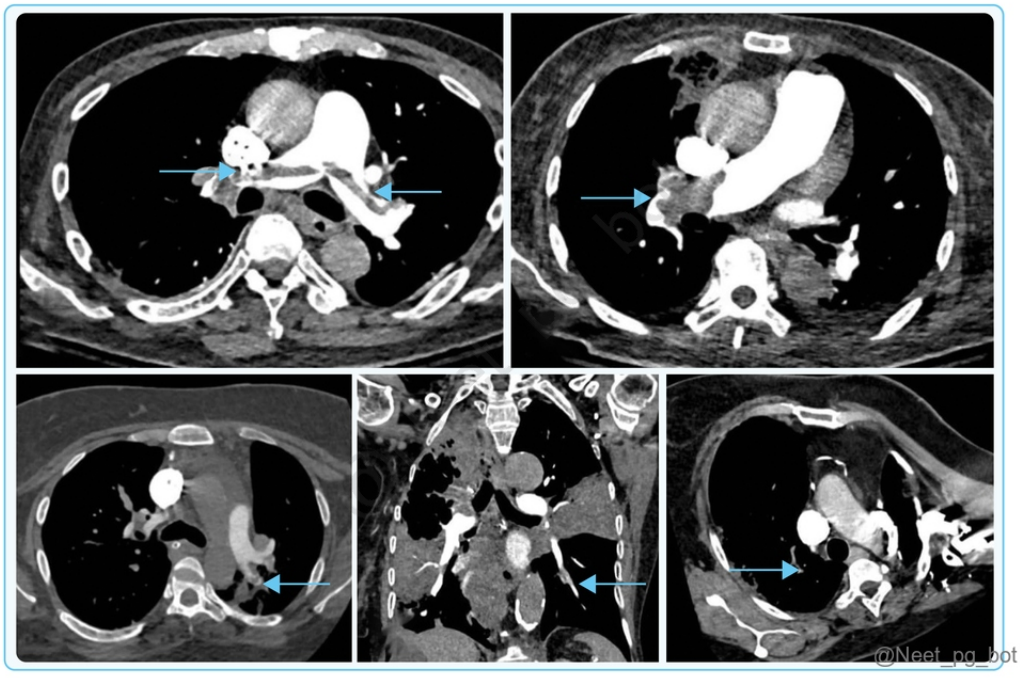

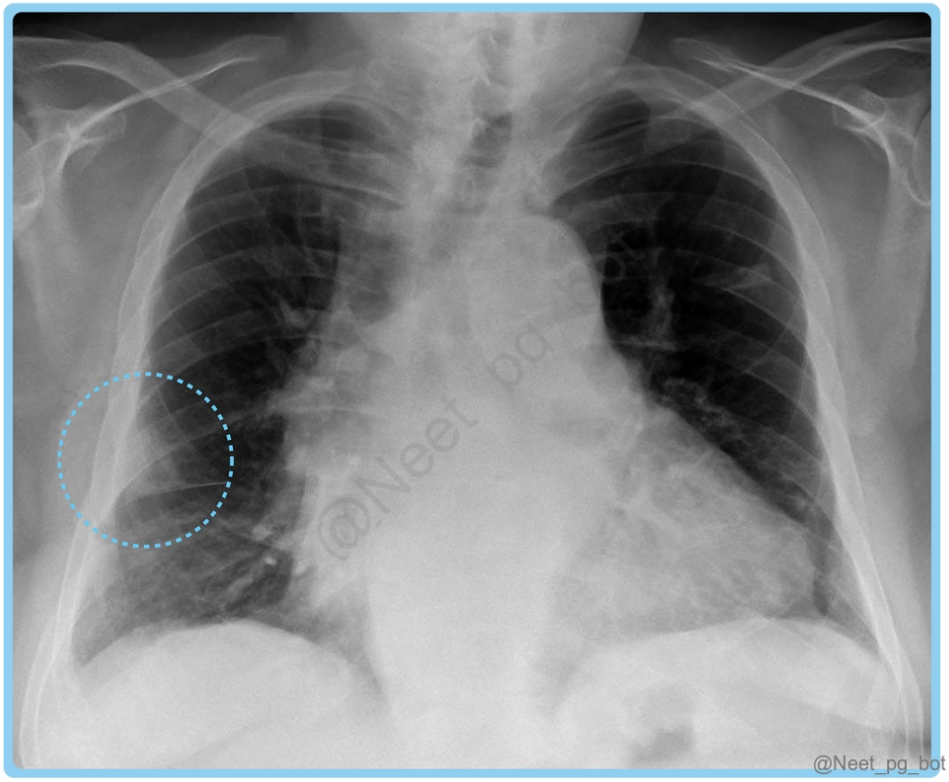

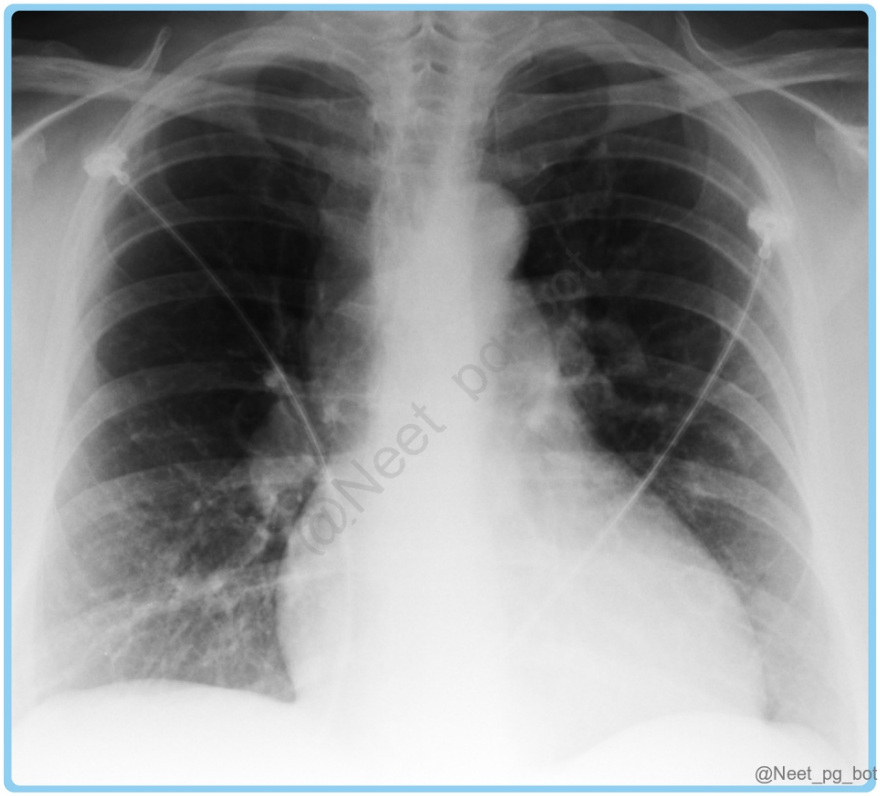

References:

Harrison’s Principles of Internal Medicine, 21st Edition, Page 2094-2097

↑ *Back to this question in Part A*

@Neet_pg_bot

Q11: A 70-year-old woman with atrial fibrillation presents with sudden-onset dyspnea and pleuritic chest pain. She is hypotensive, tachycardic, and confused. Chest X-ray shows a wedge-shaped opacity in the right lung as shown in image. What is the most appropriate initial management? {{caption_text}} (Q851909)

A. Initiation of oral anticoagulation

B. Starting her on intravenous unfractionated heparin

C. Administration of thrombolytic therapy

D. Performing a surgical embolectomy

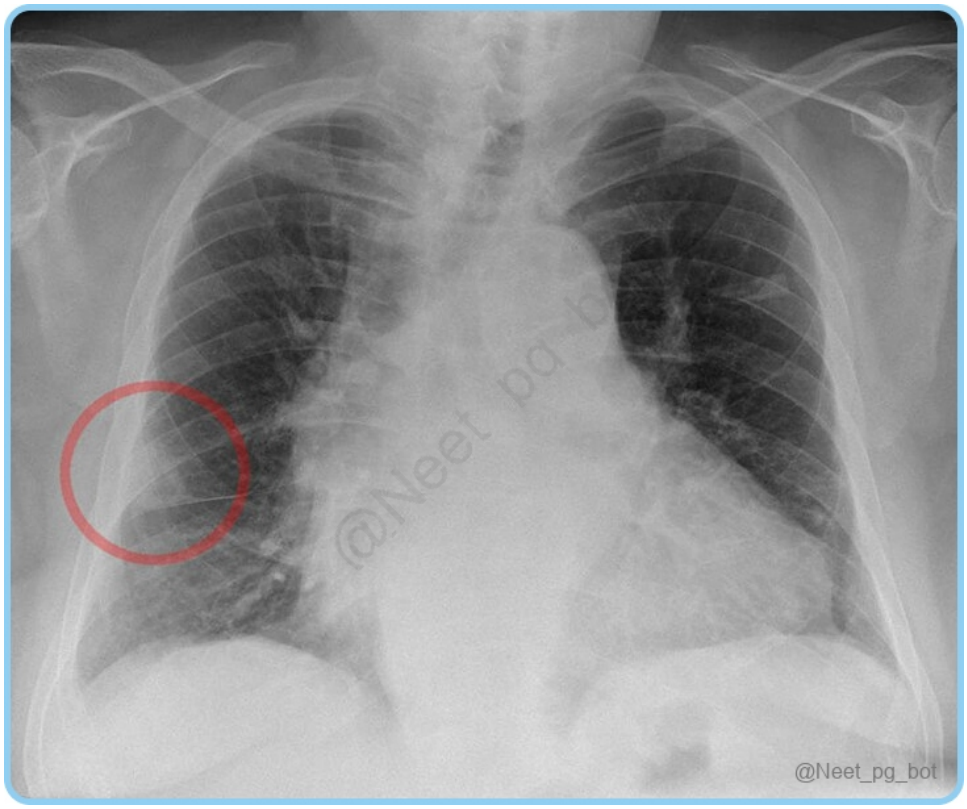

Correct Answer: C. Administration of thrombolytic therapy

Explanation: The patient has massive pulmonary embolism , suggested by: Sudden dyspnea and chest pain Hypotension and altered mental status (hemodynamic instability) Hampton’s hump on chest X-ray (pulmonary infarction) Thrombolytic therapy is indicated in massive PE with shock or hypotension , as it rapidly dissolves the clot and improves survival. Initiation of oral anticoagulation (Option A): Oral anticoagulation is inappropriate for

acute management in the setting of significant clinical instability; immediate treatment is necessary to stabilize the patient. Starting her on intravenous unfractionated heparin (Option B): While unfractionated heparin is effective in managing pulmonary embolism, it is not the first-line treatment in a patient showing signs of hemodynamic instability, where rapid intervention is crucial. Surgical Embolectomy (Option D) : Indicated for patients with massive PE when other treatments fail.

References:

Harrison's Principles of Internal Medicine, 21st Edition, Page 2098-2100

Thrombolysis

↑ *Back to this question in Part A*

@Neet_pg_bot

Q12: A 72 y/o woman presents to the ED with sudden onset dyspnea and chest pain. On examination, she is hypotensive (systolic BP 85 mm Hg), has tachycardia, and exhibits signs of altered consciousness. An echocardiogram shows right ventricular (RV) dysfunction. What is the most likely diagnosis? (Q851910)

A. Submassive pulmonary embolism

B. Massive pulmonary embolism

C. Pneumonia

D. Myocardial infarction

Correct Answer: B. Massive pulmonary embolism

Explanation: The patient demonstrates systemic hypotension, altered consciousness, and echocardiographic evidence of RV dysfunction, all indicating massive PE. Massive PE: Defined by systemic hypotension (systolic arterial pressure < 90 mm Hg or a drop of ≥40 mm Hg for at least 15 minutes). Associated with shock (evidence of tissue hypoperfusion, altered consciousness, oliguria, cold/clammy extremities). High mortality despite advances in diagnosis and therapy. Echocardiography shows RV dysfunction . Submassive pulmonary embolism (Option A): This option is unlikely because the patient is hypotensive and exhibits altered consciousness, which is more characteristic of massive PE rather than submassive PE, which generally lacks hemodynamic instability. Pneumonia (Option C): While pneumonia can cause chest pain and dyspnea, the hypotension and altered mental status in this scenario point away from this diagnosis, as pneumonia typically does not lead to significant hemodynamic instability. Myocardial infarction (Option D): Although myocardial infarction can present with chest pain and hypotension, the echocardiographic findings of RV dysfunction align more closely with massive pulmonary embolism rather than MI.

References:

https://pmc.ncbi.nlm.nih.gov/articles/PMC3542486/

↑ *Back to this question in Part A*

@Neet_pg_bot

Q13: A 28 y/o man is admitted to the ED following a motorcycle accident resulting in multiple fractures of the right femur and left humerus. Two days post-injury, he developed sudden onset dyspnea, altered mental status, and a petechial rash around his neck and conjunctiva. What is the most likely diagnosis? (Q851911)

A. Acute Respiratory Distress Syndrome (ARDS)

B. Fat Embolism Syndrome (FES)

C. Pulmonary Embolism (PE)

D. Deep Vein Thrombosis (DVT)

Correct Answer: B. Fat Embolism Syndrome (FES)

Explanation: Fat Embolism Syndrome (FES) is the most likely diagnosis, given the recent trauma, respiratory distress, altered mental status, and petechial rash, which are characteristic signs of FES. Symptoms often develop within 24-72 hours following fat emboli entering circulation. {{caption_text}} Acute Respiratory Distress Syndrome (ARDS) (Option A): While the patient shows respiratory failure, the combination of recent trauma, neurologic symptoms, and the petechial rash is more indicative of Fat Embolism Syndrome rather than ARDS alone, which does not typically present with a rash. Pulmonary Embolism (PE) (Option C): Though PE can present with sudden dyspnea and hypoxia, it does not typically cause neurologic symptoms or petechial rash, making FES a more fitting diagnosis in this case. Deep Vein Thrombosis (DVT) (Option D): While DVT is a risk in trauma patients, it usually presents with leg swelling and pain rather than respiratory symptoms and altered mental status, which are not typical manifestations of DVT.

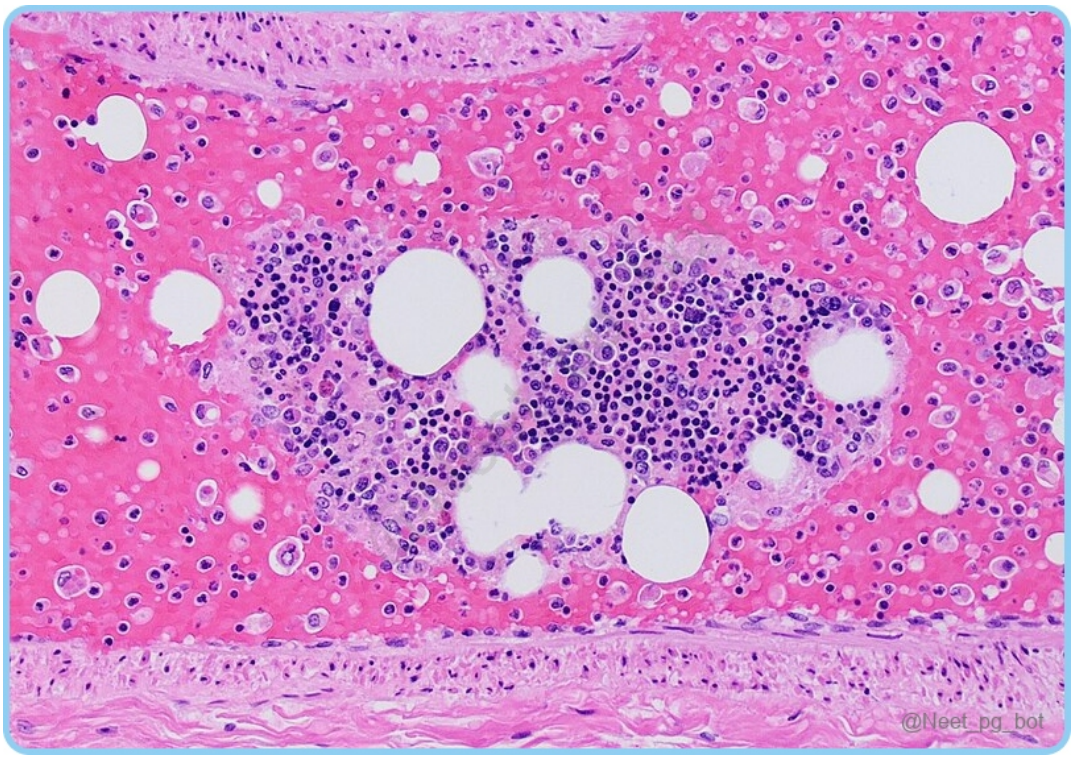

References:

https://emedicine.medscape.com/article/460524-overview#a7

↑ *Back to this question in Part A*

@Neet_pg_bot

Q14: A 28 y/o male presents to the ED after sustaining multiple long bone fractures in a motorcycle accident. Two days post-injury, he exhibits tachypnea, confusion, and a petechial rash on his torso. Which of the following is NOT a part of the diagnostic criteria for the patient's likely condition? (Q851913)

A. Sudden thrombocytopenia

B. Elevated white blood cell count

C. Elevated erythrocyte sedimentation rate (ESR)

D. Petechial rash

Correct Answer: B. Elevated white blood cell count

Explanation: The patient's recent history of long-bone fractures, along with the characteristic clinical features of tachypnea, confusion, and a petechial rash that developed 24-36 hours post-injury indicates Fat embolism syndrome. While an elevated white blood cell count may indicate an inflammatory response, it is not included in the major or minor diagnostic criteria for FES. Gurd and Wilson's Diagnostic Criteria : One major criterion + four minor criteria + macroglobulinemia are required for the diagnosis. Major criteria Minor criteria Respiratory insufficiency (symptoms and radiologic evidence) Cerebral dysfunction not caused by head injury or other conditions Petechial rash Tachycardia (>110 beats/min) Pyrexia (temperature >38.5°C) Retinal changes (fat or petechiae) Renal dysfunction Jaundice Acute drop in haemoglobin Sudden thrombocytopenia Elevated ESR Fat macroglobulinemia.

References:

https://emedicine.medscape.com/article/460524-clinical#showall

↑ *Back to this question in Part A*

@Neet_pg_bot

Q15: A 40-year-old male presents to the emergency department after sustaining multiple long bone fractures in a car accident. Two days later, he developed respiratory distress, confusion, and a petechial rash. His oxygen saturation is dropping, and the medical team begins supportive care, including fluid resuscitation and monitoring. Which of the following is the best option for expanding plasma volume and potentially limiting lung injury in this patient with FES? (Q851918)

A. Normal saline

B. Ringer lactate solution

C. Albumin

D. Corticosteroids

Correct Answer: C. Albumin

Explanation: The diagnosis is Fat Embolism Syndrome (FES) due to the patient's history of multiple long-bone fractures followed by respiratory distress, confusion, and a petechial rash, all occurring within a typical time frame post-injury. Albumin provides greater plasma volume expansion and may help limit lung injury by binding fatty acids, making it the best choice for managing fluid resuscitation in FES. There is no definitive treatment for fat embolism syndrome Normal saline (Option A): While effective for initial fluid resuscitation, it does not provide the oncotic support necessary to limit lung injury compared to colloids. Ringer lactate solution (Option B): This isotonic crystalloid is useful for fluid resuscitation but lacks the specific properties to bind fatty acids and expand plasma volume as effectively as albumin. Corticosteroids (Option D): Although they may reduce inflammation, they do not specifically expand plasma volume or directly address fluid resuscitation needs.

References:

https://emedicine.medscape.com/article/460524-medication#showall

↑ *Back to this question in Part A*

@Neet_pg_bot

• [10_Pulmonology] 076 Bronchiectasis Pneumonia

« Back to Folder Directory

[10_Pulmonology] 076 Bronchiectasis Pneumonia — Quick Jump

Q1 (p. 2873)	*Q2 (p. 2873)*	*Q3 (p. 2877)*	*Q4 (p. 2878)*	*Q5 (p. 2879)*	*Q6 (p. 2879)*
Q7 (p. 2880)	*Q8 (p. 2882)*	*Q9 (p. 2883)*	*Q10 (p. 2884)*	*Q11 (p. 2885)*	*Q12 (p. 2887)*
Q13 (p. 2888)	*Q14 (p. 2888)*	*Q15 (p. 2889)*	*Q16 (p. 2890)*	*Q17 (p. 2893)*	*Q18 (p. 2893)*
Q19 (p. 2894)	*Q20 (p. 2895)*				

Q1: Which of the following statements are false regarding primary lung abscesses? (Q851712)

A. Most cases are polymicrobial infections.

B. Hematologic dissemination is one of the causes

C. Poor dental hygiene is an independent risk factor for developing lung abscesses

D. Staphylococcus aureus can cause lung abscesses in individuals with alcohol use disorder.

Correct Answer: B. Hematologic dissemination is one of the causes

Explanation: Hematogenous dissemination does not cause primary lung abscesses. It is a characteristic cause of secondary lung abscesses , typically arising from septic emboli (e.g., endocarditis). Causes of Primary Lung abscesses: In the majority of cases, the pathogen responsible is polymicrobial , often consisting of anaerobic bacteria such as (Option A ruled out) Bacteroides Prevotella Peptostreptococcus Fusobacterium In individuals with alcohol use disorder , the most frequently identified organisms responsible for lung abscesses are Staphylococcus aureus, Klebsiella pneumoniae, Streptococcus pyogenes, and Actinomyces. (Option D ruled out) Additionally, poor dental hygiene is a significant independent risk factor for the formation of lung abscesses. (Option C ruled out)

References:

pmc.ncbi.nlm.nih.gov/articles/PMC4543327/

www.ncbi.nlm.nih.gov/books/NBK555920/

↑ *Back to this question in Part A*

@Neet_pg_bot

Q2: A 55-year-old patient presents with fever, productive cough, and pleuritic chest pain. A chest CT scan reveals a fluid collection in the pleural space with a thickened pleura. Which of the following is the most likely diagnosis? (Q851740)

A. Empyema

B. Lung abscess

C. Pneumonia

D. Pulmonary edema

Correct Answer: A. Empyema

Explanation: Empyema is a collection of pus in the pleural space, which can vary in consistency, as thin as serous fluid or so thick that it is impossible to aspirate. Microscopically, it shows a high number of leukocytes. It can be unilateral or loculated/encysted, usually secondary to infection in neighboring structures (commonly the lung) , most often due to bacterial pneumonia or tuberculosis. Chest X-ray may resemble pleural effusion, but pleural adhesions may create a 'D'-shaped shadow. {{caption_text}} Lung abscess (Option B): A lung abscess is a localized pus collection within the lung parenchyma, typically >2 cm, containing necrotic debris or fluid. Chest radiographs show a thick-walled cavity with an air-fluid level; CT imaging offers better definition and earlier detection of cavitation. {{caption_text}} Pneumonia (Option C) typically affects the lung parenchyma and may show consolidation on a chest X-ray or CT. However, it does not usually involve a fluid collection in the pleural space. Pneumonia can lead to pleural effusion, but it would not typically show the thickened pleura and loculated fluid collection. Pulmonary edema (Option D) involves abnormal accumulation of extravascular fluid in the lung parenchyma. Cardiogenic pulmonary edema shows central edema, pleural effusions, Kerley B lines, peribronchial cuffing, and an enlarged heart. In noncardiogenic pulmonary edema, the pattern is typically patchy and peripheral, with ground-glass opacities and consolidations with air bronchograms.

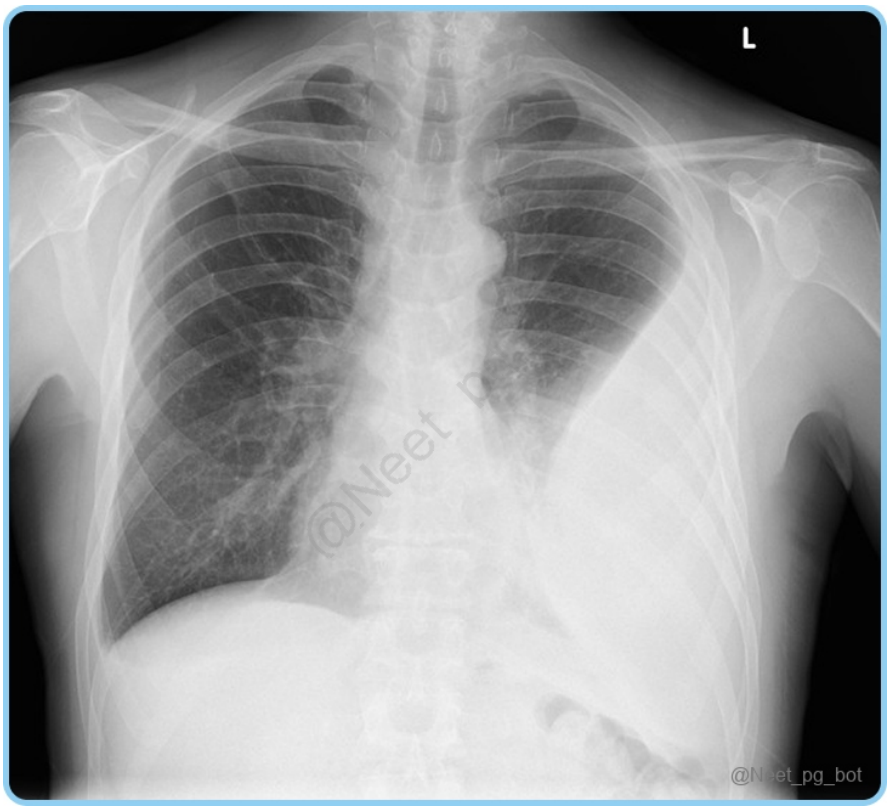
L
@Neet_pg_bot

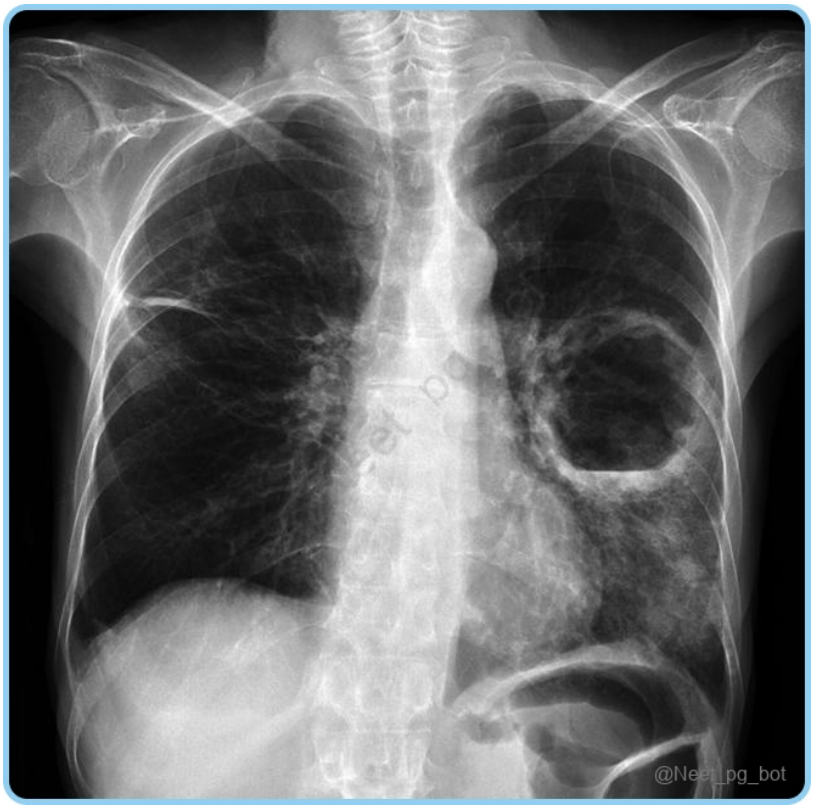
@Neet_pg_bot

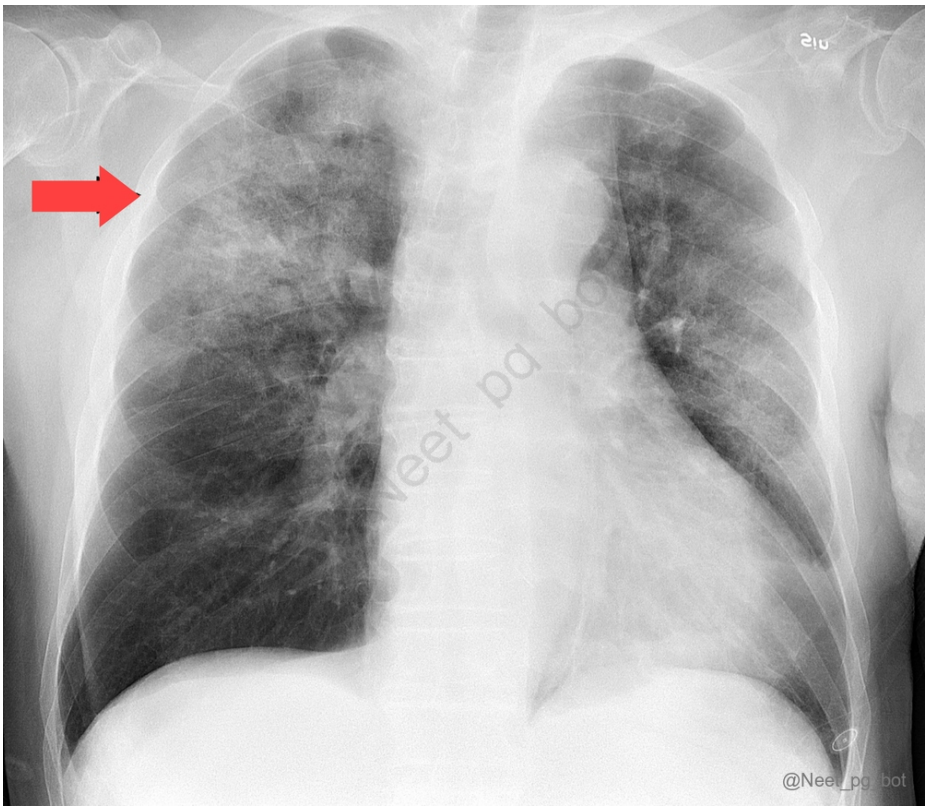

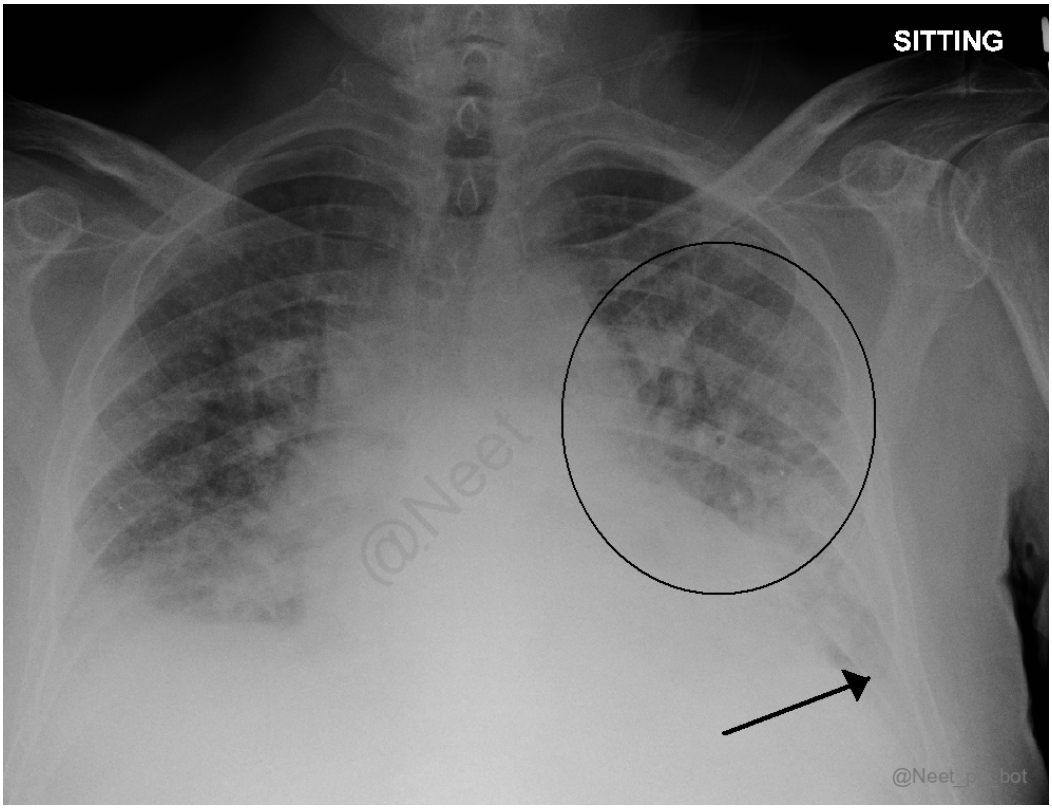

References:

Harrison’s Principles of Internal Medicine, 21st Edition, Page 1020

Davidson’s Principles and Practice of Medicine, 24th Edition, Page 564, 565

https://www.ncbi.nlm.nih.gov/books/NBK555920/#:~:text=A%20lung%20abscess%20is%20a,fluid%20due%20to%20microbial%20infection.

https://www.ncbi.nlm.nih.gov/books/NBK557611/

↑ *Back to this question in Part A*

@Neet_pg_bot

Q3: A 55-year-old patient presents with a productive cough, fever, and shortness of breath. A chest X-ray reveals a lobar consolidation. Which of the following is the most likely causative organism of community-acquired pneumonia in this patient? (Q851739)

A. Klebsiella pneumoniae

B. Haemophilus influenzae

C. Streptococcus pneumoniae

D. Pseudomonas aeruginosa

Correct Answer: C. Streptococcus pneumoniae

Explanation: The symptoms of productive cough, fever, shortness of breath and lobar consolidation on a chest x-ray is suggestive of community-acquired pneumonia . The most common causative organism of CAP is Streptococcus pneumoniae. Community-acquired pneumonia: Causative organisms: Streptococcus pneumoniae (most common) , Mycoplasma, Legionella, Chlamydia, Haemophilus influenzae (Option B ruled out) , etc. Hospital-acquired pneumonia: Causative organisms: Aerobic gram-negative bacilli (e.g. Pseudomonas aeruginosa (Option D ruled out) , Escherichia coli, Klebsiella pneumoniae (Option A ruled out) , Enterobacter spp, Acinetobacter spp) and gram-positive cocci (e.g., Staphylococcus aureus, which includes methicillin-resistant S. aureus, Streptococcus spp).

References:

Harrison’s Principles of Internal Medicine, 21st Edition, Page 1010-1020

Davidson’s Principles and Practice of Medicine, 24th Edition, Page 582-585

https://www.ncbi.nlm.nih.gov/books/NBK430749/

https://www.ncbi.nlm.nih.gov/books/NBK535441/

↑ *Back to this question in Part A*

@Neet_pg_bot

Q4: A 35-year-old HIV-positive patient presents with a non-productive cough, dyspnea, and low-grade fever. A Gomori methenamine silver stain of a bronchoalveolar lavage specimen was done. What is the most appropriate treatment for this patient? (Q851738)

A. Azithromycin

B. Amphotericin B

C. Co-trimoxazole

D. Itraconazole

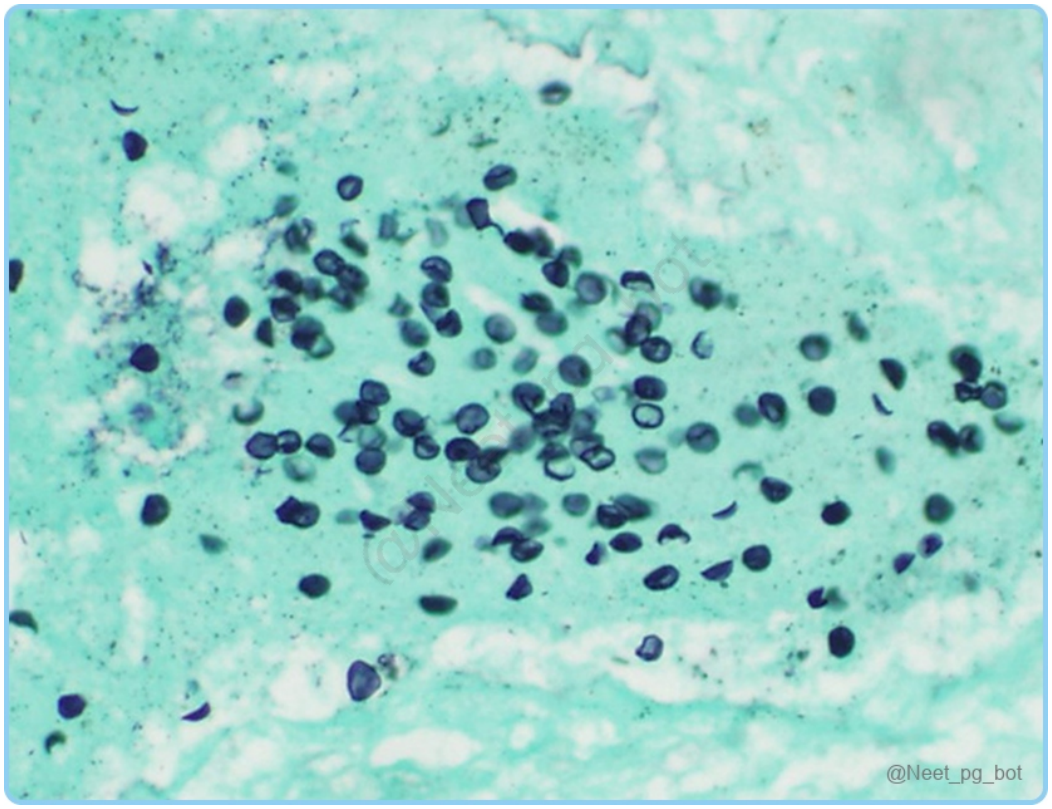

Correct Answer: C. Co-trimoxazole

Explanation: The " crushed ping-pong ball " appearance on Gomori methenamine silver stain is characteristic of Pneumocystis jirovecii pneumonia (PCP) , a common opportunistic infection in HIV patients. HRCT scans reveal characteristic diffuse ground-glass opacities . Prophylaxis and treatment involves high-dose co-trimoxazole (trimethoprim-sulfamethoxazole), with systemic glucocorticoids added if the patient is hypoxic.

References:

Harrison’s Principles of Internal Medicine, 21st Edition, Page 1691-1695

Davidson’s Principles and Practice of Medicine, 24th Edition, Page 315, 318

↑ *Back to this question in Part A*

@Neet_pg_bot

Q5: A 60-year-old male presents with fever, cough, and chest discomfort. His chest X-ray reveals right lower lobe consolidation. Which of the following features would be more consistent with atypical pneumonia? (Q851737)

A. Gradual onset with a dry cough

B. High-grade fever

C. Lobar consolidation on chest X-ray

D. Productive cough with purulent sputum

Correct Answer: A. Gradual onset with a dry cough

Explanation: Atypical pneumonia presents with a gradual onset, dry cough, low-grade fever, and diffuse interstitial infiltrates on chest X-ray. It is commonly caused by Mycoplasma pneumoniae , Chlamydophila pneumoniae , Legionella , or viral pathogens. High-grade fever (Option B): More typical of bacterial (typical) pneumonia. Lobar consolidation on chest X-ray (Option C): Classic feature of typical pneumonia such as pneumococcal pneumonia. Productive cough with purulent sputum (Option D): Suggests bacterial pneumonia rather than atypical pathogens.

References:

Harrison’s Principles of Internal Medicine, 21st Edition, Page 1253, 1441, 1452

https://www.ncbi.nlm.nih.gov/books/NBK532239/

https://www.ncbi.nlm.nih.gov/books/NBK534295/

↑ *Back to this question in Part A*

@Neet_pg_bot

Q6: A 70 y/o man with COPD presents with 3 days of worsening shortness of breath, fever, and productive cough. He appears confused and has a respiratory rate of 32/min, BP of 85/55 mmHg, and BUN of 25 mg/dL. What is the most appropriate management? (Q851736)

A. Outpatient treatment with azithromycin

B. Inpatient treatment with levofloxacin and azithromycin

C. ICU admission with piperacillin-tazobactam and vancomycin

D. Inpatient treatment with amoxicillin alone

Correct Answer: C. ICU admission with piperacillin-tazobactam and vancomycin

Explanation: The patient with symptoms like worsening shortness of breath, fever, and productive cough along with tachypnea and hypotension all align with the diagnosis of Pneumonia. This patient has a CURB-65 score of 4 (confusion, uremia, respiratory rate > 30, and hypotension), indicating the need for ICU admission and more intensive therapy. Given his comorbid condition (COPD) and the potential for aspiration and Pseudomonas infection, the recommended treatment is a combination of anti-pseudomonal beta-lactam (piperacillin-tazobactam) and vancomycin for MRSA coverage. Outpatient treatment with azithromycin (Option A): Not appropriate for this patient due to his high CURB-65 score of 4, indicating he requires more intensive treatment. Outpatient therapy is suitable for lower-risk patients without significant comorbidities. Inpatient treatment with levofloxacin and azithromycin (Option B): While this option provides effective coverage for pneumonia, it does not account for the patient's need for ICU admission due to the severity of his condition (confusion, hypotension, elevated BUN). Inpatient treatment with amoxicillin alone (Option D): Inadequate for this patient due to the severity of his illness and the risk of resistant organisms. Monotherapy with amoxicillin does not provide sufficient coverage for his condition, especially considering the possibility of Pseudomonas and MRSA.

References:

Harrison’s Principles of Internal Medicine, 21st Edition, Page 1012

Typical Bacterial Pneumonia - StatPearls - NCBI Bookshelf

↑ *Back to this question in Part A*

@Neet_pg_bot

Q7: A 65 y/o woman is admitted to the hospital with a high fever, productive cough, and pleuritic chest pain. A physical examination reveals diminished breath sounds on the right side, and she appears confused. The chest X-ray is given below. Despite this, the physician considers further testing. Which of the following investigations should be prioritized next to confirm the causative organism of the suspected diagnosis? (Q851725)

A. Sputum Gram stain and culture

B. Complete Blood Count

C. CT chest

D. Influenza testing

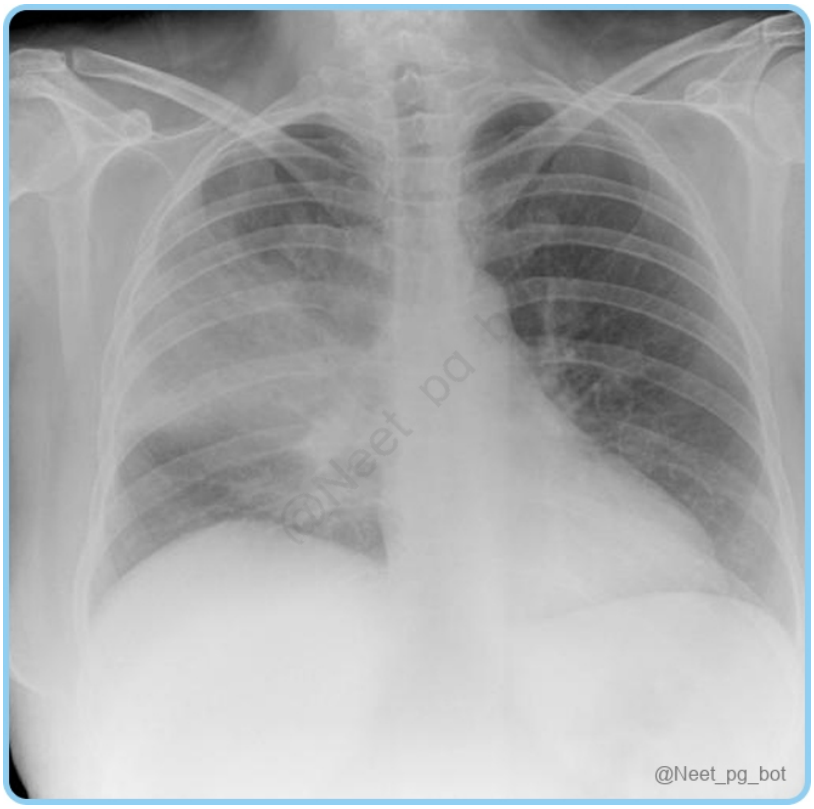

Correct Answer: A. Sputum Gram stain and culture

Explanation: Given this patient's high fever, productive cough, pleuritic chest pain, and diminished breath sounds on the right side, along with her confusion, the presentation strongly suggests pneumonia. The sputum Gram stain and culture are critical for identifying the causative organism in suspected lobar pneumonia. Complete Blood Count (Option B): While a CBC can provide valuable information about infection (e.g., leukocytosis), it does not identify the causative organism. It is more useful for assessing the overall severity of the infection. CT scan of the chest (Option C): A CT scan is more accurate than a chest X-ray but is not the first-line test for confirming pneumonia. It is typically reserved for cases with high suspicion and a negative X-ray due to its cost and radiation exposure. Influenza testing (Option D) is important during winter months, especially if co-infection with pneumonia is suspected. However, it does not directly identify the causative organism of lobar pneumonia, making it less relevant in this immediate context.

References:

www.ncbi.nlm.nih.gov/books/NBK534295/

radiopaedia.org/articles/lobar-pneumonia

↑ *Back to this question in Part A*

@Neet_pg_bot

Q8: Which of the following statements are true regarding breath sounds? (Q851724)

A. Vesicular breath sounds are soft, low-pitched sounds heard at the bronchus

B. Bronchial sounds are loud, high-pitched best heard at lung bases of normal lung

C. Egophony is the increased resonance of voice sounds heard when auscultating the lungs

D. Whispered pectoriloquy rules out the presence of lung consolidation

Correct Answer: C. Egophony is the increased resonance of voice sounds heard when auscultating the lungs

Explanation: Egophony refers to the abnormal transmission of sounds through lung tissue, leading to a change in the quality of voice sounds when auscultating the lungs, typically heard in areas of consolidation. Breath sounds: Feature Bronchial Sounds (Option B ruled out) Vesicular Sounds (Option A ruled out) Origin Tracheobronchial tree Finer lung parenchyma Characteristics Loud, harsh, high-pitched Soft, low-pitched Timing Predominantly expiratory Predominantly inspiratory Location Heard over the trachea or right apex Best appreciated at posterior lung bases Abnormality Abnormal if heard in other areas Normal in healthy lung areas {{caption_text}} Egophony is the increased resonance of voice sounds heard when auscultating the lungs. A solid (consolidated), fluid-filled, or compressed lung decreases the amplitude and only allows select frequencies to pass through. (Option C) This changes the sound of the vowel “E” to "A. Whispering Petriloquy: Whispered vocal sounds (“one, two, three” whispered repeatedly) are also used to detect a change in sound transmission (whispered pectoriloquy) and are more sensitive than voice sound transmission for early detection of pulmonary consolidation. (Option D ruled out)

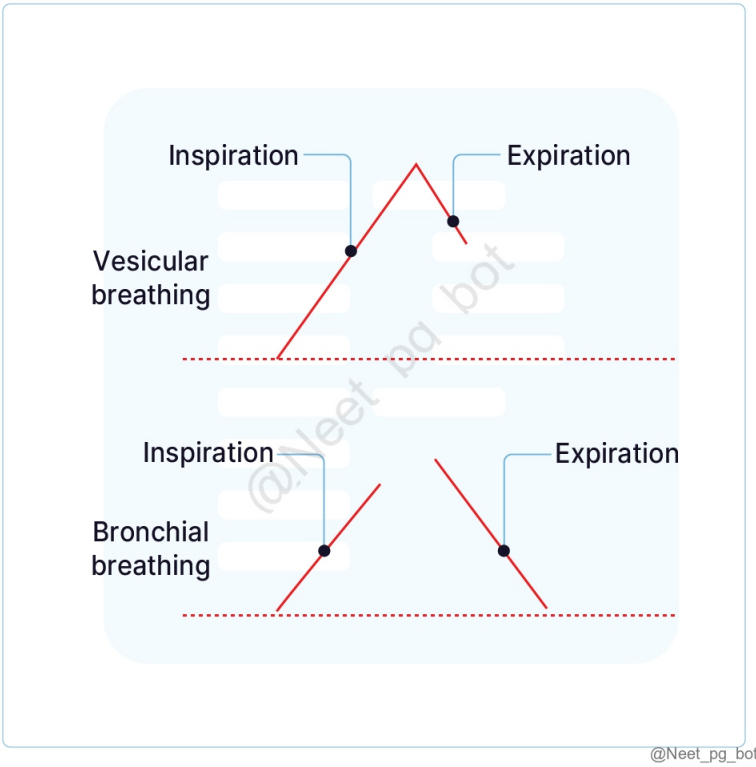

References:

Egophony - StatPearls - NCBI Bookshelf

Lung Sounds - StatPearls - NCBI Bookshelf

taylorandfrancis.com/knowledge/Medicine_and_healthcare/Pulmonary_medicine/Whispered_pectoriloquy/

↑ *Back to this question in Part A*

@Neet_pg_bot

Q9: A 65 year old man presents to the ED with a 5-day history of fever, productive cough, and worsening shortness of breath. On examination, he exhibits tachypnea, and his sputum is thick and yellowish. He complains of sharp pleuritic chest pain when taking deep breaths. The physician notes increased vocal fremitus and egophony on examination. Based on the clinical features presented, which of the following findings is most likely to be noted upon auscultation of this patient's lungs? (Q851723)

A. Absence of breath sounds

B. Wheezing

C. Ronchi

D. Presence of crackles and bronchial breath sounds

Correct Answer: D. Presence of crackles and bronchial breath sounds

Explanation: The patient's symptoms of fever, productive cough with mucopurulent sputum, pleuritic chest pain, and signs of consolidation (increased vocal fremitus and egophony) suggest lobar pneumonia . Auscultation is likely to reveal crackles and bronchial breath sounds, which are characteristic of this condition. Absence of breath sounds (Option A): This is unlikely in lobar pneumonia. While there may be decreased breath sounds in the presence of significant pleural effusion, the scenario suggests consolidation rather than fluid accumulation. Ronchi (Option B) are a low pitched sound usually associated with secretions or obstructions in larger airways, like in bronchitis or COPD. Dullness to percussion (Option C) may be noted if there is pleural effusion, but it is not the primary finding in lobar pneumonia, where increased vocal fremitus and localized signs of consolidation are more typical.

References:

Typical Bacterial Pneumonia - StatPearls - NCBI Bookshelf

↑ *Back to this question in Part A*

@Neet_pg_bot

Q10: Match the following conditions of pneumonia to their respective causative organisms: 1. Alcoholic patient with Pneumonia a) Legionella pneumophila 2. Pneumonia due to contact with Bats b) Coxiella burnetii 3. Pneumonia after Hotel/cruise c) Pneumococcus pneumonia 4. Pneumonia due to contact with Goat/sheep d) Histoplasmosis (Q851722)

A. 1-c, 2-d, 3-a, 4-b

B. 1-d, 2-b, 3-a, 4-c

C. 1-a, 2-b, 3-d, 4-a

D. 1-b, 2-c, 3-d, 4-a

Correct Answer: A. 1-c, 2-d, 3-a, 4-b

Explanation: 1. Alcoholic patient with Pneumonia c) Pneumococcus pneumonia 2. Pneumonia due to contact with Bats d) Histoplasmosis 3. Pneumonia after Hotel/cruise a) Legionella pneumophila 4. Pneumonia due to contact with Goat/sheep b) Coxiella burnetii Alcoholic patient with Pneumonia: (c) Pneumococcus pneumonia While Klebsiella pneumoniae is the "classic" association for alcoholics (currant jelly sputum), Streptococcus pneumoniae (Pneumococcus) remains the most common cause of community-acquired pneumonia in this population. Pathophysiology: Alcohol impairs the gag reflex (increasing aspiration risk) and inhibits neutrophil chemotaxis.

Key Finding: "Rusty" colored sputum and lobar consolidation on X-ray. Pneumonia due to contact with Bats: (d) Histoplasmosis Histoplasma capsulatum is a dimorphic fungus found in soil contaminated with bat or bird droppings (guano). This is common in cave explorers (spelunkers) or those cleaning attics/chicken coops. Clinical Presentation: Can mimic tuberculosis with hilar lymphadenopathy and granulomas. In immunocompromised patients, it can disseminate to the liver and spleen. Diagnosis: Urinary or serum antigen test is the fastest method. Pneumonia after Hotel/cruise: (a) Legionella pneumophila Legionella thrives in water cooling towers , air conditioning systems, and cruise ship plumbing. It often presents with "atypical" symptoms like diarrhea, hyponatremia, confusion/headache, and Faget sign (High fever with relative bradycardia). Pneumonia due to contact with Goat/sheep $\rightarrow$ (b) Coxiella burnetii This is the causative agent of Q Fever . It is highly infectious and transmitted via aerosols from birth products, feces, or urine of infected livestock (sheep, goats, cattle). Clinical Presentation: Often presents as a "culture-negative" pneumonia or hepatitis. Complication: If it becomes chronic, it is a leading cause of culture-negative endocarditis .

References:

www.ncbi.nlm.nih.gov/pmc/articles/PMC7120951/

Klebsiella Pneumonia - StatPearls - NCBI Bookshelf

academic.oup.com/femspd/article/75/4/ftx042/3753446

www.thieme-connect.com/products/ejournals/pdf/10.1055/s-0042-1758732.pdf

Psittacosis Pneumonia - StatPearls - NCBI Bookshelf.

www.adfg.alaska.gov/index.cfm?adfg=livingwithbats.disease

www.ncbi.nlm.nih.gov/books/NBK430905/

pubmed.ncbi.nlm.nih.gov/20171543/

wwwnc.cdc.gov/travel/yellowbook/2024/infections-diseases/legionnaires-disease-and-pontiac-fever4

↑ *Back to this question in Part A*

@Neet_pg_bot

Q11: A 60 y/o woman presents with the characteristic fingers as shown in the image, along with chronic cough, daily production of large amounts of purulent sputum and a history of recurrent lung infections over the past several years. Her CT scan revealed the following findings. A biopsy of the affected lung tissue is performed. Which of the following histopathological findings is most likely present? (Q851702)

A. Chronic inflammatory destruction of bronchial walls with loss of smooth muscle and elastic tissue

B. Presence of caseating granulomas

C. Extensive alveolar damage

D. Bronchiectatic cavities lined exclusively by ciliated epithelium



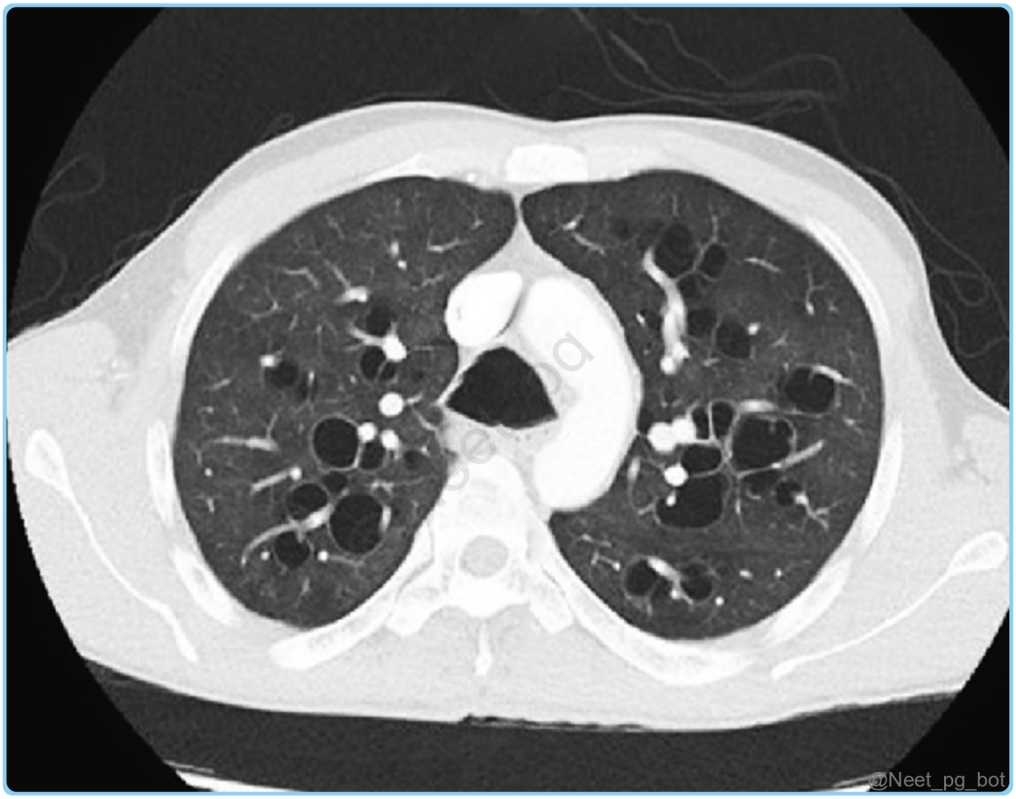

Correct Answer: A. Chronic inflammatory destruction of bronchial walls with loss of smooth muscle and elastic tissue

Explanation: Bronchiectasis is a condition characterized by permanent, irreversible dilation of bronchi and bronchioles , resulting from chronic necrotizing inflammation and destruction of the bronchial wall . Histopathology: Loss of smooth muscle, elastic fibers, and sometimes cartilage Chronic inflammatory infiltrate (neutrophils, lymphocytes, plasma cells) Mucosal ulceration + squamous metaplasia (loss of normal ciliated epithelium) Characteristic CT Findings: Tram-track sign – parallel thickened bronchial walls Signet-ring sign – dilated bronchus larger than nearby artery Presence of caseating granulomas (Option B): Caseating granulomas are a hallmark of tuberculosis, not bronchiectasis. Extensive alveolar damage (Option C): Extensive damage to the alveoli is more characteristic of acute conditions such as ARDS (Acute Respiratory Distress Syndrome). Bronchiectatic cavities lined by intact ciliated epithelium (Option D): In bronchiectasis, ciliated epithelium is destroyed and replaced by squamous metaplasia or granulation tissue

References:

Harrison’s Principles of Internal Medicine, 21st Edition, Page 2173

Davidson’s Principles and Practice of Medicine, 24th Edition, Page 578

↑ *Back to this question in Part A*

@Neet_pg_bot

Q12: A 25-year-old student presents with a 10-day history of dry cough, mild fever, and fatigue, but has been able to attend daily activities. Chest X-ray shows patchy infiltrates and a physical exam reveals mild crackles. Which of the following is the least likely causative agent of this patient's condition? (Q851711)

A. Mycoplasma pneumoniae

B. Chlamydia pneumoniae

C. Legionella pneumophila

D. Klebsiella pneumoniae

Correct Answer: D. Klebsiella pneumoniae

Explanation: The clinical scenario points to a diagnosis of Atypical pneumonia or walking pneumonia due to the mild symptoms and the ability to continue daily activities despite the infection. Klebsiella pneumoniae is least likely as it typically causes more severe, hospital-acquired pneumonia, unlike the mild presentation of walking pneumonia. Atypical Pneumonia (Walking Pneumonia) Etiologic Agents : Atypical pneumonia is caused by organisms that don't grow on standard cultures or appear on Gram stain , such as: Mycoplasma pneumonia (Option A ruled out) Chlamydia pneumoniae (Option B ruled out) Legionella species (Option C ruled out) Respiratory viruses: Influenza, adenoviruses, respiratory syncytial virus (RSV), human metapneumoviruses, and coronaviruses

(e.g., SARS-CoV-2)

References:

Harrison’s Principles of Internal Medicine, 21st Edition, Page 1010,1011

www.lung.org/blog/what-is-walking-pneumonia

↑ *Back to this question in Part A*

@Neet_pg_bot

Q13: A 70 y/o male with a h/o DM presents to the ER with a persistent cough, high fever, and shortness of breath. He recently returned from a week-long cruise in the Caribbean. O/E, he has decreased breath sounds on one side, and a chest X-ray reveals infiltrates that are suggestive of pneumonia. Given the patient's history and recent travel, which of the following is the most likely causative organism for his pneumonia? (Q851710)

A. Streptococcus pneumoniae

B. Legionella species

C. Haemophilus influenzae

D. Mycoplasma pneumoniae

Correct Answer: B. Legionella species

Explanation: The patient's recent travel on a cruise ship, combined with his age and diabetes, puts him at a higher risk for Legionella species . Streptococcus pneumoniae (Option A): Although a common cause of pneumonia, it does not have a specific association with recent travel or cruise ship outbreaks. Haemophilus influenzae (Option C): Generally causes respiratory infections but is not typically associated with outbreaks linked to cruise ships or recent travel. Mycoplasma pneumoniae (Option D): More prevalent in younger populations with mild respiratory symptoms, making it unlikely in this older patient with significant comorbidities.

References:

Harrison’s Principles of Internal Medicine, 21st Edition, Page 1010,1011

↑ *Back to this question in Part A*

@Neet_pg_bot

Q14: Which of the following represents the correct order of pathological stages in classic pneumonia? (Q851709)

A. Edema Stage → Gray Hepatization → Red Hepatization → Resolution Stage

B. Edema Stage → Red Hepatization → Gray Hepatization → Resolution Stage

C. Gray Hepatization → Red Hepatization → Edema Stage → Resolution Stage

D. Red Hepatization → Resolution Stage → Edema Stage → Gray Hepatization

Correct Answer: B. Edema Stage → Red Hepatization → Gray Hepatization → Resolution Stage

Explanation: Stages of Pneumonia: Pathophysiology of Pneumonia: Microbial Proliferation : Pneumonia arises from the growth of pathogens in the alveoli and the host's immune response. Lung Microbiota : The lungs harbour a complex microbiota; pneumonia can occur when this balance is disrupted. Infection Mechanisms : Pathogens reach the lower respiratory tract via inhalation, micro aspiration, or direct mucosal dispersion, bypassing immune defences. Triggers and Feedback : Viral infections or macro aspiration can initiate pneumonia; inflammatory responses may promote bacterial growth, worsening the condition. Immune Response : While the immune system typically contains infections, persistent inflammation can lead to full-blown pneumonia. Respiratory Effects : Inflammatory mediators cause fever and neutrophil accumulation, leading to capillary leaks, hypoxemia, and impaired oxygenation, which can worsen dyspnea and cause respiratory failure.

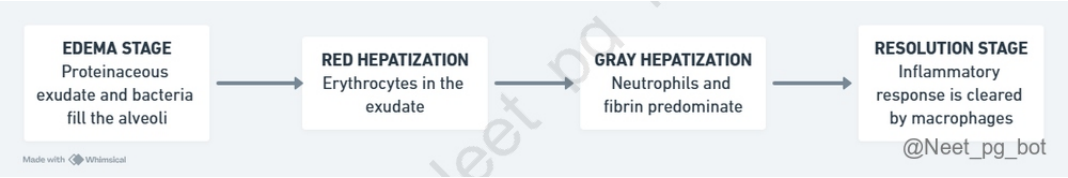

References:

Harrison’s Principles of Internal Medicine, 21st Edition, Page 1009,1010

↑ *Back to this question in Part A*

@Neet_pg_bot

Q15: A 45 y/o man with a history of bronchiectasis presents for follow-up after sputum analysis reveals Mycobacterium avium complex (MAC) infection. What is the recommended treatment regimen for this patient's infection? (Q851708)

A. Itraconazole + Rifampin + Ethambutol

B. Macrolide + Rifampin + Ethambutol

C. Macrolide + Isoniazid + Ethambutol

D. Rifampin + Isoniazid + Pyrazinamide

Correct Answer: B. Macrolide + Rifampin + Ethambutol

Explanation: The standard treatment regimen for MAC infection includes a macrolide (such as azithromycin or clarithromycin), rifampin, and ethambutol. This combination is essential for effectively treating MAC infections and preventing the development of drug resistance. Itraconazole + Rifampin + Ethambutol (Option A): Itraconazole is an antifungal. While some fungal infections (like Aspergillus) can complicate bronchiectasis, it has no activity against Mycobacteria. Macrolide + Isoniazid + Ethambutol (Option C): Isoniazid is a cornerstone of Mycobacterium tuberculosis (TB) treatment, but it has minimal to no clinical activity against MAC. Rifampin + Isoniazid + Pyrazinamide (Option D): This is the "RIPE" regimen (minus Streptomycin/Ethambutol) used for Latent or Active Tuberculosis . MAC is naturally resistant to Pyrazinamide, making this regimen ineffective here.

References:

Harrison’s Principles of Internal Medicine, 21st Edition, Page 2175, 2176

↑ *Back to this question in Part A*

@Neet_pg_bot

Q16: A 35 y/o male presents with a chronic productive cough, dyspnea, and occasional hemoptysis. A chest radiograph of the patient is given. Which investigation would be most appropriate for confirming the provisional diagnosis? (Q851707)

A. Sputum analysis

B. Chest computed tomography (CT)

C. Pulmonary function tests (PFTs)

D. Bronchoscopy



Correct Answer: B. Chest computed tomography (CT)

Explanation: The clinical features and the presence of a “tram track sign” on the chest radiograph point to a diagnosis of Bronchiectasis. Chest computed tomography (CT) is the imaging technique of choice for confirming bronchiectasis. Bronchiectasis - Tram track sign X-ray HRCT {{caption_text}} Black arrows pointing to the tram track sign {{caption_text}} Red arrows pointing to the tram track sign Sputum analysis (Option A): Although sputum analysis can help identify specific pathogens responsible for infections in bronchiectasis, it does not establish the diagnosis of bronchiectasis itself. Pulmonary function tests (PFTs) (Option C): PFTs are important for evaluating overall lung function; however, it is not specific to diagnosing bronchiectasis. Bronchoscopy (Option D): Bronchoscopy can be useful for identifying obstructions or taking biopsies, however it is not the primary investigation for diagnosing bronchiectasis.

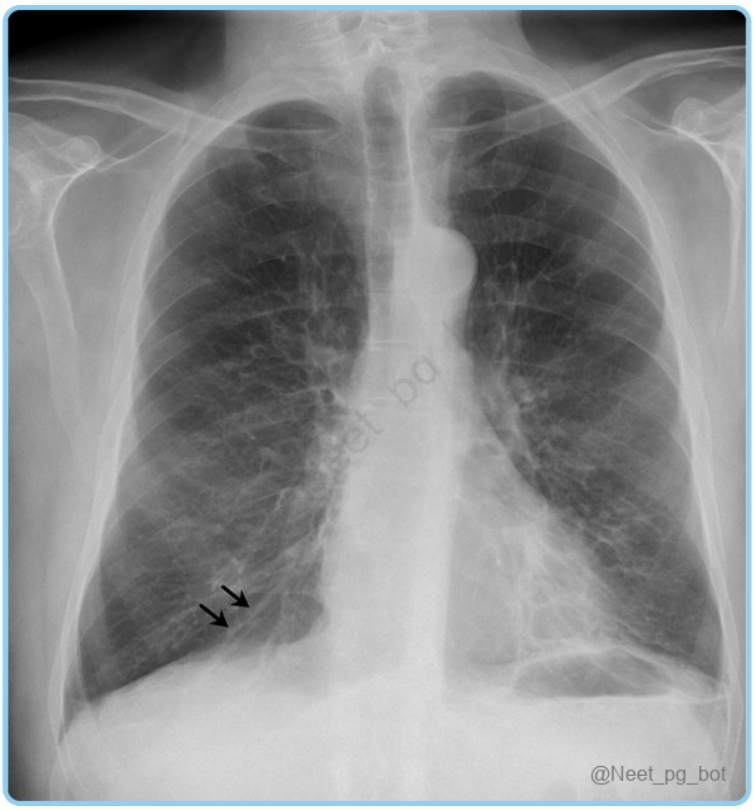

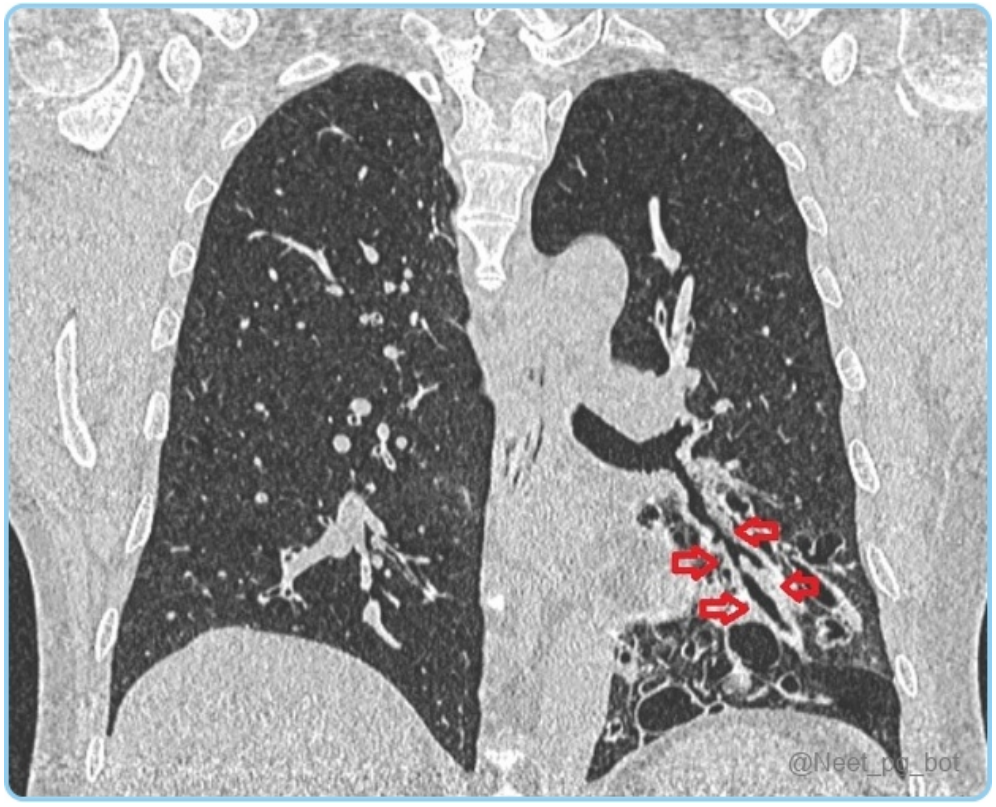

References:

Harrison’s Principles of Internal Medicine, 21st Edition, Page 2174, 2175

↑ *Back to this question in Part A*

@Neet_pg_bot

Q17: A 30 y/o woman with a history of recurrent lung infections presents to the emergency. She reports increased sputum volume and a change in sputum colour. O/E, she demonstrates wheezing and crackles. What does the change in sputum production most likely indicate? (Q851706)

A. Initiation of effective airway clearance therapy

B. Worsening infection and inflammation

C. The onset of remission in chronic lung disease

D. Onset of allergic reaction

Correct Answer: B. Worsening infection and inflammation

Explanation: An increase in the volume of sputum, accompanied by a change like sputum production , suggests a deterioration of the underlying condition . This change indicates an exacerbation of bronchiectasis due to heightened infection and inflammation. Symptoms like fever, malaise and anorexia can also occur. Initiation of effective airway clearance therapy (Option A) : While airway clearance can increase sputum production temporarily, it does not change the sputum's colour significantly, nor is it associated with new wheezing and crackles. The onset of remission in chronic lung disease (Option C) : Remission would generally result in improved symptoms, not an increase in sputum or change in colour. Onset of allergic reaction (Option D): While allergic reactions can lead to respiratory symptoms, they do not present with increased purulent sputum.

References:

Harrison’s Principles of Internal Medicine, 21st Edition, Page 2132, 2174

Davidson’s Principles and Practice of Medicine, 24th Edition, Page 579

↑ *Back to this question in Part A*

@Neet_pg_bot

Q18: Which of the following is commonly associated with bronchiectasis affecting the lower lobes? (Q851705)

A. Cystic Fibrosis

B. Allergic Bronchopulmonary Aspergillosis

C. Nontuberculous mycobacterial infection

D. Chronic Recurrent Aspiration

Correct Answer: D. Chronic Recurrent Aspiration

Explanation: Chronic recurrent aspiration is commonly associated with bronchiectasis affecting the lower lobes because aspirated material (especially when lying down) tends to settle in the posterior segments of the lower lobes due to gravity. Repeated aspiration causes chronic inflammation and infection , leading to permanent bronchial dilation (bronchiectasis). Lobe Involvement in Bronchiectasis Upper Lung Fields Mid Lung Fields Lower Lung Fields Central Airways Cystic Fibrosis (Option A ruled out) Post-radiation Fibrosis Nontuberculous Mycobacterial (NTM) Infection (Option C ruled out) Dyskinetic/ Immotile Cilia Syndrome. AAT-1 deficiency Brocks syndrome Yellow nail syndrome Chronic Recurrent Aspiration : Conditions like esophageal motility disorders result in aspiration. (Option D) End-stage Fibrotic Lung Disease: Traction bronchiectasis as a result of parenchymal distortion and fibrosis. Hypogammaglobulinemia Allergic Bronchopulmonary Aspergillosis (ABPA) (Option B ruled out) Congenital conditions that primarily impact the central airways: Tracheobronchomegaly (Mounier-Kuhn Syndrome) and Williams-Campbell Syndrome

References:

Harrison’s Principles of Internal Medicine, 21st Edition, Page 2173

↑ *Back to this question in Part A*

@Neet_pg_bot

Q19: A 40 y/o man, a non-smoker, presents with shortness of breath, chronic cough, and repeated respiratory infections. His chest CT shows emphysema and bronchiectasis. Lab results indicate low alpha-1 antitrypsin levels. What is the most likely reason for the bronchiectasis seen in this patient? (Q851704)

A. Idiopathic airway dilation

B. Recurrent infections due to defective chloride transport

C. Impaired ciliary function leading to mucus retention

D. Increased neutrophil elastase activity causing damage

Correct Answer: D. Increased neutrophil elastase activity causing damage

Explanation: It has been studied that inflammatory cells in small airways release proteases that damage the walls of larger airways. In alpha-1 antitrypsin deficiency , there is a lack of antiprotease , which normally inhibits neutrophil elastase , an enzyme that breaks down elastin in lung tissue. Without sufficient alpha-1 antitrypsin,

neutrophil elastase can damage the lung parenchyma, leading to emphysema (Panacinar) and bronchiectasis as the airway walls become dilated. Idiopathic airway dilation (Option A): While idiopathic causes occur in significant bronchiectasis cases, low alpha-1 antitrypsin levels in this patient point toward an underlying mechanism related to protease-antiprotease imbalance. Recurrent infections due to defective chloride transport (Option B): It is seen in cystic fibrosis, where mutations in the CFTR gene lead to the production of thick mucus due to abnormal chloride and sodium transport across epithelial cells. This thick mucus obstructs the airways leading to chronic infections and bronchiectasis. Impaired ciliary function leading to mucus retention (Option C): This mechanism occurs in primary ciliary dyskinesia (eg. Kartagener's syndrome), where dysfunctional cilia fail to clear mucus, resulting in mucus buildup and recurrent infections that can lead to bronchiectasis.

References:

Harrison's Principles of Internal Medicine, 21st Edition, Page 2174

Davidson's Principles and Practice of Medicine, 24th Edition, Page 550

↑ *Back to this question in Part A*

@Neet_pg_bot

Q20: A 35 y/o female with asthma presents with worsening cough, wheezing, and episodes of hemoptysis. Chest imaging reveals central bronchiectasis, and blood tests show elevated total IgE levels and eosinophil count. What is the most likely cause of the bronchiectasis? (Q851703)

A. Cystic fibrosis

B. Primary ciliary dyskinesia

C. Allergic bronchopulmonary aspergillosis (ABPA)

D. Idiopathic bronchiectasis

Correct Answer: C. Allergic bronchopulmonary aspergillosis (ABPA)

Explanation: Allergic bronchopulmonary aspergillosis (ABPA) is an immune-mediated condition commonly seen in patients with asthma. It results from a hypersensitivity (Type 1) reaction to Aspergillus species, leading to central bronchiectasis . The features of increased IgE levels, eosinophilic count and asthma in the patient point to ABPA as the cause. Cystic fibrosis (Option A): It causes widespread bronchiectasis, particularly affecting the upper lung lobes, and is commonly associated with thick mucus production, malabsorption, and other systemic signs. Primary ciliary dyskinesia (Option B): It leads to diffuse bronchiectasis and is often associated with recurrent sinusitis and situs inversus (Kartagener's syndrome). It is not linked to central bronchiectasis, asthma or elevated IgE. Idiopathic bronchiectasis (Option D): Idiopathic bronchiectasis is diagnosed when no cause is identified after a thorough investigation. Since the patient has asthma and tests point toward ABPA, idiopathic bronchiectasis is ruled out.

References:

Harrison’s Principles of Internal Medicine, 21st Edition, Page 1679, 2165, 2173, 2174

Davidson’s Principles and Practice of Medicine, 24th Edition, Page 578

↑ *Back to this question in Part A*

@Neet_pg_bot

• [10_Pulmonology] 077 Bronchial Asthma And Copd

« Back to Folder Directory

[10_Pulmonology] 077 Bronchial Asthma And Copd — Quick Jump

Q1 (p. 2897)	*Q2 (p. 2898)*	*Q3 (p. 2898)*	*Q4 (p. 2899)*	*Q5 (p. 2900)*	*Q6 (p. 2900)*
Q7 (p. 2901)	*Q8 (p. 2902)*	*Q9 (p. 2903)*	*Q10 (p. 2904)*	*Q11 (p. 2904)*	*Q12 (p. 2905)*
Q13 (p. 2906)	*Q14 (p. 2907)*	*Q15 (p. 2908)*	*Q16 (p. 2909)*	*Q17 (p. 2910)*	*Q18 (p. 2911)*
Q19 (p. 2912)	*Q20 (p. 2912)*	*Q21 (p. 2913)*	*Q22 (p. 2914)*	*Q23 (p. 2915)*	*Q24 (p. 2915)*
Q25 (p. 2916)	*Q26 (p. 2917)*	*Q27 (p. 2918)*	*Q28 (p. 2919)*		

Q1: A 55-year-old male with a history of heavy smoking presents with a cough and sputum production for 4 months. Which statement is true regarding his condition? (Q851771)

A. Diagnosis requires symptoms for at least 2 consecutive months.

B. Smoking cessation is the only intervention that positively impacts COPD

C. Inhaled bronchodilators are the primary treatment for chronic bronchitis.

D. Hemoptysis is the initial symptom indicative of chronic bronchitis.

Correct Answer: C. Inhaled bronchodilators are the primary treatment for chronic bronchitis.

Explanation: Chronic bronchitis is defined clinically as a productive cough for ≥3 months per year for 2 consecutive years . It is characterized pathologically by increased Reid index (>0.5) due to mucous gland hypertrophy. Inhaled bronchodilators (specifically long-acting muscarinic antagonists - LAMAs and long-acting beta-agonists - LABAs) are the cornerstone/primary treatment for symptomatic COPD, including chronic bronchitis. They relax the smooth muscle around the airways, helping to open them up, which improves symptoms and exercise tolerance. The established clinical definition of chronic bronchitis is a persistent cough and sputum production for at least 3 months (Option A) in each of two consecutive years, in the absence of other underlying diseases. While smoking cessation (Option B) is the single most effective and crucial intervention that modifies the disease's progression (i.e., slows the decline of FEV1, it is not the only positive intervention . Other therapies like pulmonary rehabilitation , vaccinations (influenza and pneumococcal), and inhaled bronchodilators/corticosteroids all improve symptoms, exercise tolerance, and quality of life. Hemoptysis (Option D) is not a typical or initial symptom of chronic bronchitis. The classic, defining initial symptom is a chronic productive cough and sputum production . Hemoptysis, when it occurs in a heavy smoker with COPD, is a red flag that raises suspicion for bronchial carcinoma (lung cancer), which is a differential diagnosis that must be ruled out.

References:

Davidson’s Principles and Practice of Medicine, 24th Edition, Page 574. 575, 576.

↑ *Back to this question in Part A*

@Neet_pg_bot

Q2: A 68-year-old male patient with COPD presents with severe respiratory distress. Before initiating Non-Invasive Ventilation (NIV), which of the following conditions would be considered as absolute contraindication? (Q852141)

A. Severe hypoxemia with pH < 7.1

B. Lack of spontaneous breathing or gasping

C. Post upper gastrointestinal surgery

D. Massive retention of secretions despite bronchoscopy

Correct Answer: B. Lack of spontaneous breathing or gasping

Explanation: This condition indicates the patient cannot initiate breaths independently, making NIV inappropriate and potentially leading to respiratory failure. Contraindications for Non-Invasive Ventilation (NIV): Absolute Contraindications Relative Contraindications Lack of spontaneous breathing or gasping (Option B) Coma Anatomical/functional airway obstruction Massive agitation Gastrointestinal bleeding or ileus Massive retention of secretions (Option D) Severe hypoxemia or acidosis (pH < 7.1) (Option A) Hemodynamic instability Anatomical/subjective difficulty accessing airway Status post upper GI surgery (Option C)

References:

Davidson’s Principles and Practice of Medicine, 24th Edition, Page 578

https://www.ncbi.nlm.nih.gov/books/NBK554178/

↑ *Back to this question in Part A*

@Neet_pg_bot

Q3: Which of the following statements regarding the management of COPD is correct ? (Q852140)

A. Inhaled corticosteroids (ICS) should be used as monotherapy in all COPD patients

B. Long-acting bronchodilators are the mainstay of treatment for moderate to severe COPD

C. Antibiotics are routinely prescribed for the prevention of COPD exacerbations

D. Pulmonary rehabilitation is only recommended for patients with mild COPD

Correct Answer: B. Long-acting bronchodilators are the mainstay of treatment for moderate to severe COPD

Explanation: Long-acting bronchodilators(LABA/LAMA) are recommended for moderate to severe COPD because they help improve lung function, reduce symptoms like breathlessness, and decrease the frequency of exacerbations. They form the cornerstone of maintenance therapy in these patients. Inhaled corticosteroids (ICS) as monotherapy (Option A) is incorrect because ICS should not be used alone in COPD management. They are typically used in combination with bronchodilators in patients with frequent exacerbations. Antibiotics for prevention of exacerbations (Option C) is incorrect because antibiotics are reserved for acute exacerbations and not used routinely for prevention. Pulmonary rehabilitation only for mild COPD (Option D) is incorrect as pulmonary rehabilitation is recommended for patients with moderate to severe COPD, not just mild cases.

References:

Davidson's Principles and Practice of Medicine, 24th Edition, Page 564, 569, 570, 576, 583, 584, 620, 621, 622

↑ *Back to this question in Part A*

@Neet_pg_bot

Q4: A 62-year-old male with chronic obstructive pulmonary disease (COPD) reports increasing breathlessness over the past few months. He now has to stop for breath after walking about 100 metres on level ground. According to the modified Medical Research Council (mMRC) dyspnoea scale, which grade best describes his level of breathlessness? (Q852139)

A. Grade 1

B. Grade 2

C. Grade 3

D. Grade 4

Correct Answer: C. Grade 3

Explanation: s: The patient reports needing to stop for breath after walking about 100 m on the level, which corresponds to mMRC Grade 3. mMRC Scale Grades: Grade Description of Breathlessness 0 Not troubled by breathlessness except on strenuous exertion. 1 (Option A) Short of breath when hurrying on the level or walking up a slight hill. 2 (Option B) Walks slower than others of the same age or stops for breath when walking. 3 (Option C) Stops for breath after walking 100 metres or after a few minutes on the level. 4 (Option D) Too breathless to leave the house or breathless while dressing/undressing.

References:

Davidson’s Principles and Practice of Medicine, 24th Edition, Page 575

↑ *Back to this question in Part A*

@Neet_pg_bot

Q5: Which of the following interventions has been shown to significantly improve survival in patients with chronic obstructive pulmonary disease (COPD)? (Q852138)

A. Pulmonary rehabilitation

B. Smoking cessation

C. Oral glucocorticoids during exacerbations

D. Pneumococcal vaccination

Correct Answer: B. Smoking cessation

Explanation: Smoking cessation is the most effective intervention for improving survival in COPD patients. It slows the decline in lung function (FEV1) and alters the natural progression of the disease, significantly reducing mortality. Interventions for Improved Survival in COPD: Smoking Cessation (Option B): Most effective Long-Term Oxygen Therapy (LTOT): Improves survival in severe hypoxemia (PaO■ < 7.3 kPa) Pulmonary Rehabilitation (Option A) Management of Exacerbations: Controlled oxygen therapy: 24%-28% to maintain PaO■ > 8 kPa Nebulised bronchodilators: Salbutamol + ipratropium Oral glucocorticoids (Option C): Prednisolone 30 mg × 10 days Antibiotics: For increased sputum purulence/volume or breathlessness Vaccination (Option D): Annual influenza & pneumococcal Multidisciplinary management

References:

Davidson’s Principles and Practice of Medicine, 24th Edition, Page 576, 577, 578

↑ *Back to this question in Part A*

@Neet_pg_bot

Q6: A 65-year-old male with a history of chronic obstructive pulmonary disease (COPD) presents for routine follow-up. He reports increased breathlessness while walking on level ground and has experienced two exacerbations in the past year. According to the 2023 GOLD classification, which group does this patient belong to? (Q852137)

A. Group A: Low risk, low symptoms

B. Group B: Low risk, high symptoms

C. Group C: High risk, low symptoms

D. Group D: High risk, high symptoms

Correct Answer: D. Group D: High risk, high symptoms

Explanation: GOLD classification uses symptom burden (assessed by mMRC or CAT) and exacerbation history to group COPD patients: Group A: Low symptoms + ≤1 exacerbation (not leading to hospitalization). Group B: High symptoms + ≤1 exacerbation (not leading to hospitalization). Group C: Low symptoms + ≥2 exacerbations or ≥1 hospitalization. Group D: High symptoms + ≥2 exacerbations or ≥1 hospitalization. In this patient: He has increased breathlessness while walking on level ground → high symptoms. He had 2 exacerbations in the past year → high risk. Therefore, he falls into Group D. Note: The 2023 GOLD update, Groups C and D were removed and replaced with a new category: Group E . Group E: High exacerbation risk , regardless of symptom level Defined as ≥2 moderate exacerbations or ≥1 hospitalization in the past year

References:

https://pmc.ncbi.nlm.nih.gov/articles/PMC10111975/

https://pmc.ncbi.nlm.nih.gov/articles/PMC6375483/

↑ *Back to this question in Part A*

@Neet_pg_bot

Q7: A 68-year-old woman with a history of Chronic Obstructive Pulmonary Disease (COPD) is evaluated for her BODE Index score. Her current Body Mass Index (BMI) is 20 kg/m², her post-bronchodilator FEV1 is 42% of the predicted value, she reports a mMRC dyspnoea score of 3, and she walks 340 metres during a 6-minute walk test. What is her total BODE Index score? (Q852136)

A. 4

B. 5

C. 6

D. 7

Correct Answer: C. 6

Explanation: The BODE Index score is calculated by summing the scores from each component: Body Mass Index (BMI) : 1 point (BMI < 21 scores 1). Obstruction (FEV1) : 2 points (FEV1 35-49% scores 2). Dyspnea (mMRC scale) : 2 points (mMRC score of 3 scores 2). Exercise Capacity : 1 point (walking 250-349 metres scores 1).

Therefore, the total Therefore, her BODE score is 1 (BMI) + 2 (Obstruction) + 2 (Dyspnoea) + 1 (Exercise Capacity) = 6. BODE Index in COPD : A multidimensional scoring system predicting mortality in COPD patients. {{caption_text}} Prognosis : Score 0-2: ~10% mortality rate over 52 months. Score 7-10: ~80% mortality rate over the same period.

Variable	BODE score			
	0	1	2	3
Body mass index body weight (in kg)/ height (in meters)	> 21	≤21	-	-
Airway obstruction: forced expiratory Volume at 1 s (as percentage of predicted)	>65	50-65	35-49	<35
Dyspnea: MMRC	0 or 1	2	3	4
Exercise capacity: 6 min walk test distance (meters)	≥350	250-349	150-249	≤149

@Neet_pg_bot

References:

Davidson’s Principles and Practice of Medicine, 24th Edition, Page 577

↑ *Back to this question in Part A*

@Neet_pg_bot

Q8: A 70-year-old male with a long-standing history of chronic obstructive pulmonary disease (COPD) presents to the clinic with worsening breathlessness and cough. His smoking history is significant for 45 pack-years. O/E, he has bilateral wheezes and a respiratory rate of 24 breaths per minute. His oxygen saturation is 89% on room air, and spirometry confirms a post-bronchodilator FEV1/FVC ratio of 60%. Which of the following is the most appropriate first-line treatment to improve his breathlessness and reduce the risk of exacerbations? (Q852135)

A. Oral theophylline combined with ICS

B. Long-acting bronchodilator (LABA) combined with an inhaled glucocorticoid

C. Long-term oxygen therapy

D. Pulmonary rehabilitation

Correct Answer: B. Long-acting bronchodilator (LABA) combined with an inhaled glucocorticoid

Explanation: In moderate to severe COPD (post-bronchodilator FEV1/FVC <70% with persistent symptoms), the preferred first-line treatment is a long-acting bronchodilator (LABA or LAMA) , and in patients with frequent exacerbations, an ICS + LABA combination helps reduce symptoms and exacerbation risk. It improves lung function, reduces breathlessness, and decreases the frequency and severity of exacerbations. Combination therapy is more effective than bronchodilators alone. Oral theophylline combined with ICS (Option A): Theophylline is not recommended as first-line due to narrow therapeutic window and side effects. Long-term oxygen therapy (Option C): Indicated only in severe chronic hypoxemia (PaO■ ≤55 mmHg or SpO■ ≤88%), not as first-line here. Pulmonary rehabilitation (Option D): Very useful in COPD management, but it is adjunct therapy after pharmacological treatment initiation, not the immediate first-line for breathlessness control.

References:

Davidson’s Principles and Practice of Medicine, 24th Edition, Page 576, 577

↑ *Back to this question in Part A*

@Neet_pg_bot

Q9: A 62-year-old woman with a history of chronic obstructive pulmonary disease (COPD) presents with increased breathlessness, cough, and sputum production over the last two days. She appears distressed and has a respiratory rate of 28 breaths per minute. Her oxygen saturation is 88% on room air. Which of the following management strategies is most appropriate for her immediate treatment? (Q852134)

A. Initiate high-flow oxygen therapy to maintain oxygen saturation above 95%

B. Start nebulised bronchodilator therapy with salbutamol and ipratropium

C. Begin intravenous glucocorticoids immediately

D. Order a chest X-ray before any treatment is provided

Correct Answer: B. Start nebulised bronchodilator therapy with salbutamol and ipratropium

Explanation: In an acute COPD exacerbation, the first-line immediate management is nebulised bronchodilators (SABA + SAMA) to relieve airflow obstruction. This therapy helps relieve bronchospasm and improve airflow, which is critical given her increased breathlessness and distress. Oxygen should be titrated later to maintain SpO■ 88–92% , not high-flow, to avoid CO■ retention. Initiate high-flow oxygen therapy to maintain oxygen saturation above 95% (Option A): Not appropriate, as excessive oxygen worsens hypercapnia in COPD. Begin intravenous glucocorticoids immediately (Option C) is not the first-line treatment in the acute setting; while glucocorticoids are important in managing exacerbations, nebulised bronchodilators are prioritised for immediate relief of symptoms. Order a chest X-ray before any treatment is provided (Option D): Imaging is important but should not delay immediate bronchodilator therapy.

References:

Davidson’s Principles and Practice of Medicine, 24th Edition, Page 577, 578

↑ *Back to this question in Part A*

@Neet_pg_bot

Q10: A 55-year-old man presents with a 6-month history of worsening breathlessness, chronic cough, and occasional sputum production. He has a 30-pack-year smoking history. On examination, there is no finger clubbing, and pulse oximetry shows oxygen saturation of 92% on room air. Spirometry reveals an FEV1/FVC ratio of 60% post-bronchodilator. What is the most appropriate next investigation to assess the severity of his condition? (Q851777)

A. Chest X-ray

B. Blood gas analysis

C. High-resolution computed tomography (HRCT)

D. Spirometry with post-bronchodilator FEV1%

Correct Answer: D. Spirometry with post-bronchodilator FEV1%

Explanation: The patient already meets the diagnostic criteria for COPD (FEV1/FVC < 70%). The next step is to grade severity , which is done only by post-bronchodilator FEV■% predicted , according to GOLD guidelines. This determines whether the patient has mild, moderate, severe, or very severe airflow limitation. Chest X-ray (Option A): Useful to rule out other causes (e.g., lung cancer, TB) but not for severity assessment. Blood gas analysis (Option B): Helpful in advanced disease with suspected respiratory failure, not for routine severity grading. High-resolution computed tomography (HRCT) (Option C): More sensitive than a chest X-ray for detecting emphysema, but it is not routinely used for severity assessment unless surgical intervention is being considered.

References:

Davidson’s Principles and Practice of Medicine, 24th Edition, Page 575, 576

↑ *Back to this question in Part A*

@Neet_pg_bot

Q11: A 65-year-old man with a 40-pack-year smoking history presents with chronic productive cough, worsening breathlessness. Physical examination shows hoover sign with drowsiness. ABG shows PC02 =70 mm Hg and PO2= 70 mm Hg. Which of the following is best for immediate management of this patient? (Q851776)

A. Long term of oxygen therapy

B. Non invasive ventilation

C. LABA + LAMA

D. LABA + LAMA + ICS

Correct Answer: B. Non invasive ventilation

Explanation: - Non-invasive ventilation (NIV): The patient presents with acute on chronic hypercapnic respiratory failure (PCO■ = 70 mmHg, drowsiness) on a background of COPD (smoking history, chronic productive cough, hoover sign). NIV is the first-line treatment in acute hypercapnic respiratory failure to improve ventilation, reduce CO■ retention, and avoid intubation. Incorrect Options: Option A - Long-term oxygen therapy : LTOT is indicated for chronic hypoxemia (PaO■ ≤ 55 mmHg or SpO■ ≤ 88%) but cannot correct acute CO■ retention or drowsiness in hypercapnic respiratory failure. Option C - LABA + LAMA: Long-acting bronchodilators are used for chronic maintenance therapy in stable COPD, not for acute hypercapnic decompensation. Option D - LABA + LAMA + ICS: Triple inhaler therapy is for stable COPD with frequent exacerbations or severe airflow limitation, not for immediate correction of acute respiratory failure.

References:

Davidson’s Principles and Practice of Medicine, 24th Edition, Page 574, 575

↑ *Back to this question in Part A*

@Neet_pg_bot

Q12: A 65-year-old male patient presents with a history of chronic cough and sputum production for the past several years. He is thin and exhibits significant breathlessness primarily during physical activity, but he reports minimal symptoms at rest. Arterial blood gas analysis shows a normal PaCO2. Which of the following is the most likely diagnosis for this patient? (Q851775)

A. Chronic bronchitis

B. Asthma

C. Emphysema

D. Interstitial lung disease

Correct Answer: C. Emphysema

Explanation: Emphysema (Pink Puffer) is characterized by a thin body habitus, significant breathlessness with normal PaCO2 until late stages, and chronic cough/sputum production. This aligns with the patient's presentation. Features of COPD: Arterial Blood Gasses Normal PaCO2 (35-45 mmHg) until late-stage Increased PaCO2 leads to respiratory acidosis as the disease progresses Pulmonary Function Tests Airflow obstruction Reduced FEV1/FVC ratio <70% (key indicator of COPD) Chronic bronchitis (Option A) : Typical chronic bronchitis (“blue bloater”) presents with overweight/body swelling, early hypoxemia and often elevated PaCO2 from CO2 retention, not a normal PaCO2. These patients usually have prominent chronic productive cough with less severe dyspnea relative to the degree of airflow obstruction, unlike the severe exertional breathlessness highlighted here. Asthma (Option B) : Asthma usually has episodic wheeze and dyspnea with symptom■free intervals, not a long history of chronic cough and sputum over years in an older heavy■smoker. Between attacks, blood gases are often normal and there is usually a strong element of reversibility with bronchodilators, which is not the classic picture described here.■ Interstitial lung disease (Option D) : ILD typically causes dry cough with minimal sputum, restrictive pattern, and often fine end■inspiratory crackles, not chronic productive cough and sputum over years. ILD patients develop marked resting dyspnea relatively early; this case stresses dyspnea mainly on exertion, plus a COPD■like history, which fits emphysema better.

References:

Davidson’s Principles and Practice of Medicine, 24th Edition, Page 557, 558, 575, 576, 577.

↑ *Back to this question in Part A*

@Neet_pg_bot

Q13: A 65-year-old patient with a history of chronic obstructive pulmonary disease (COPD) presents with worsening shortness of breath and edema. Right heart catheterization reveals a mean pulmonary artery pressure of 30 mmHg. Which of the following statements about pulmonary hypertension (PH) in this patient is most accurate? (Q851773)

A. Pulmonary hypertension in COPD is primarily caused by increased left atrial pressure.

B. The prognosis of COPD is directly proportional to age.

C. Right ventricular hypertrophy may be observed on an electrocardiogram (ECG).

D. Treatment options for pulmonary hypertension in COPD primarily include corticosteroids.

Correct Answer: C. Right ventricular hypertrophy may be observed on an electrocardiogram (ECG).

Explanation: In patients with pulmonary hypertension (PH) due to chronic obstructive pulmonary disease (COPD), the right ventricle often hypertrophies as it works harder to pump blood against elevated pulmonary artery pressures. This hypertrophy can be detected on an ECG, typically presenting as right axis deviation ,increased QRS voltage and tall, peaked P wave. Due to enlarged right atrium (P pulmonale). Pulmonary hypertension in COPD is not primarily caused by increased left atrial pressure (Option A). The prognosis of COPD depends on lung function, comorbidities, and exacerbation frequency , not just age (Option B). Corticosteroids do not primarily treat pulmonary hypertension in COPD (Option D).

References:

Davidson's Principles and Practice of Medicine, 24th Edition, Page 621, 622.

↑ *Back to this question in Part A*

@Neet_pg_bot

Q14: A 60-year-old male with a long history of smoking presents to the clinic with chronic cough and wheezing. He mentions that he had multiple respiratory infections during childhood and was born with low birth weight. Which of the following factors is most likely to have the greatest impact on the progression of his Chronic Obstructive Pulmonary Disease (COPD)? (Q851772)

A. Airway hyper-reactivity

B. Tobacco smoke

C. Recurrent infections

D. Impaired lung growth

Correct Answer: B. Tobacco smoke

Explanation: Tobacco smoke is the primary and most significant risk factor for COPD progression, directly accelerating lung function decline. Airway hyper-reactivity (Option A) may worsen symptoms but does not drive progression. Recurrent infections (Option C) contribute to exacerbations but have less impact on long-term decline. Impaired lung growth (Option D) can lower baseline lung function but smoking has a greater effect on disease progression.

References:

Davidson's Principles and Practice of Medicine, 24th Edition, Page 574. 575, 576.

↑ *Back to this question in Part A*

@Neet_pg_bot

Q15: A 10-year-old boy presents with wheezing and shortness of breath, worsening at night. His symptoms are triggered by dust and pet dander. Spirometry shows an obstructive pattern that improves with a bronchodilator. What is the underlying mechanism? (Q851755)

A. IgG-mediated immune complexes.

B. IgE-mediated mast cell degranulation.

C. Bronchial irritation from pollutants.

D. Viral infection causing airway remodeling.

Correct Answer: B. IgE-mediated mast cell degranulation.

Explanation: This aligns with the characteristics of atopic asthma, where allergens trigger a TH2 response leading to IgE production and subsequent mast cell activation (Type 1 hypersensitivity reaction) Allergen Exposure/Sensitization → TH2 Differentiation (IL-4: IgE switch, IL-5: eosinophils, IL-13: mucus, IL-10: TH2 stimulation) → Re-exposure to Allergen → IgE-Mediated Mast Cell Activation → Early Phase (Histamine, LTC■/D■/E■ → bronchoconstriction, edema, inflammation) → Late Phase (Eosinophils, MBP → tissue damage, persistent bronchoconstriction) {{caption_text}} IgG-mediated immune complexes (Option A): is associated with type III hypersensitivity reactions, often seen in conditions like autoimmune diseases, rather than the immediate response seen in asthma. Bronchial irritation from pollutants (Option C): While pollutants can exacerbate asthma symptoms, they do not account for the specific IgE-mediated mechanism triggered by allergens like dust and pet dander. Viral infection causing airway remodeling (Option D): Viral infections can trigger asthma exacerbations, but they are not the primary mechanism in this case, especially given the clear allergic triggers and the characteristic response to bronchodilators.

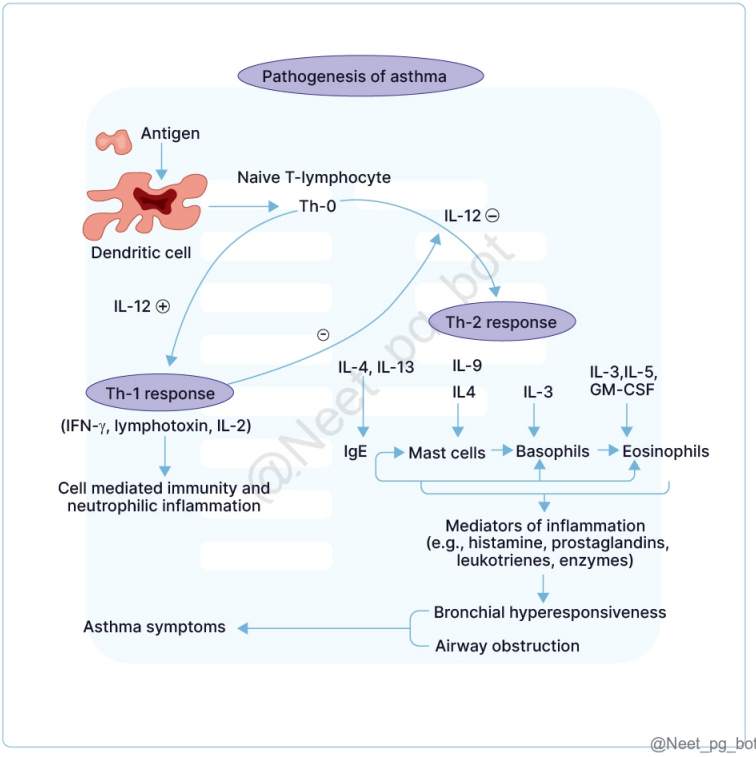

References:

Robbins Pathology 10th Edition, Page 684-686

↑ *Back to this question in Part A*

@Neet_pg_bot

Q16: A 65-year-old male presents with progressive dyspnea and a history of smoking for 25 years. Imaging studies reveal abnormal enlargement of air spaces distal to the terminal bronchioles. Which of the following types of emphysema is most likely seen in this patient? (Q851770)

A. Panacinar emphysema

B. Paraseptal emphysema

C. Centriacinar emphysema

D. Bullous emphysema

Correct Answer: C. Centriacinar emphysema

Explanation: Centriacinar emphysema is characterized by the enlargement of air spaces primarily in the central part of the acinus , often associated with smoking and chronic bronchitis. Types of Emphysema : Type Description Centriacinar Enlarged air spaces primarily in the central part of the acinus. Seen in chronic smokers, upper lobe of lungs are predominantly affected. Panacinar (Option A) Uniform enlargement of air spaces throughout the acinus. Seen in the younger age group with congenital alpha-1 antitrypsin deficiency. Lower lobes of lung are commonly involved. Associated with liver failure. Paraseptal (Option B) Enlargement occurs near the pleura or septa. Increased risk of spontaneous pneumothorax. {{caption_text}} Bullous emphysema (Option D) : Refers to the formation of large air-filled spaces (bullae) but is not a distinct type based on acinar structure. It can occur in various forms of emphysema.

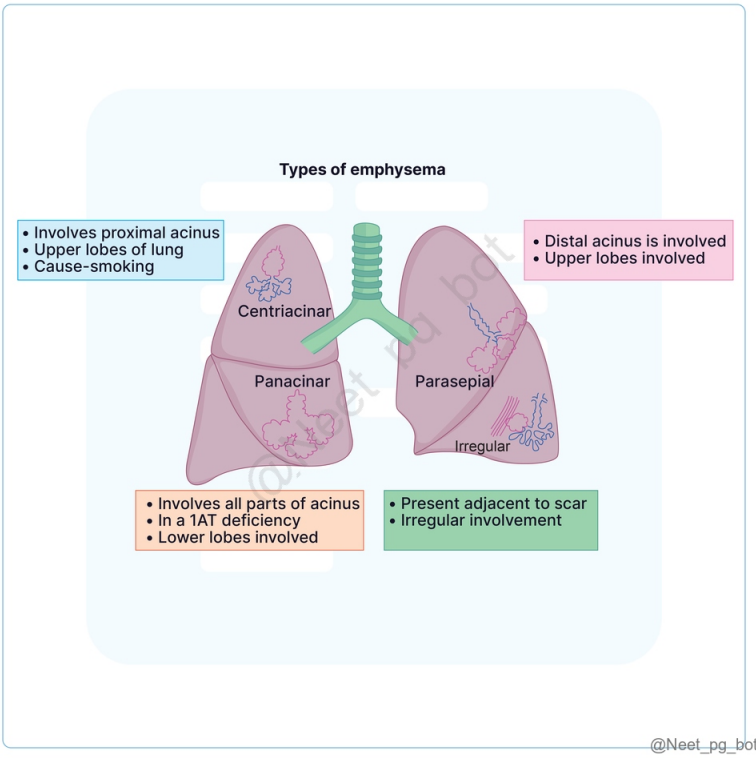

References:

Davidson’s Principles and Practice of Medicine, 24th Edition, Page 574. 575.

↑ *Back to this question in Part A*

@Neet_pg_bot

Q17: A 58-year-old male, with a 30-year history of smoking, presents with a chronic productive cough for the last 2 years, worsening shortness of breath, and recent weight loss. Examination reveals bilateral wheezing and peripheral edema imaging shows alveolar wall destruction beyond terminal bronchiole. Which of the following pathophysiological mechanisms is primarily responsible for his condition? (Q851768)

A. Pulmonary vascular remodeling

B. Alpha-1 antitrypsin deficiency

C. Airflow limitation due to loss of elastic tissue

D. Hypersecretion of mucus from goblet cells

Correct Answer: C. Airflow limitation due to loss of elastic tissue

Explanation: The patient presents with emphysema , characterized by destruction of alveolar walls beyond the terminal bronchioles, leading to loss of elastic recoil and airflow limitation, which is the primary mechanism of airflow obstruction. Pulmonary vascular remodeling (Option A) primarily contributes to pulmonary hypertension, not emphysema. Alpha-1 antitrypsin deficiency (Option B) is a genetic cause of early-onset emphysema, usually panacinar and in younger patients. Hypersecretion of mucus from goblet cells (Option D) is characteristic of chronic bronchitis, not emphysema.

References:

Davidson's Principles and Practice of Medicine, 24th Edition, Page 574. 575, 576

↑ *Back to this question in Part A*

@Neet_pg_bot

Q18: A 42-year-old woman presents to the emergency department with worsening asthma symptoms, fever, and a rash consisting of purpura on her lower extremities. Laboratory findings reveal eosinophilia (1200 cells/μL) and elevated inflammatory markers. A biopsy of the skin lesion shows extravascular granulomas. Which of the following statements about her condition is false? (Q851767)

A. Patients often present with systemic symptoms like malaise and weight loss.

B. The condition typically involves necrotizing vasculitis affecting small and medium-sized blood vessels.

C. Cardiac involvement may lead to complications such as myocarditis and pericarditis.

D. It primarily affects large blood vessels, leading to significant vascular occlusion.

Correct Answer: D. It primarily affects large blood vessels, leading to significant vascular occlusion.

Explanation: Eosinophilic Granulomatosis with Polyangiitis (EGPA) is a small-to-medium vessel necrotizing vasculitis often associated with asthma, eosinophilia, and systemic symptoms. Cardiac, renal, and neurological involvement can occur, but large vessels are typically spared . Patients often present with systemic symptoms like

malaise and weight loss (Option A) is true. The condition typically involves necrotizing vasculitis affecting small and medium-sized blood vessels (Option B) is true. Cardiac involvement may lead to complications such as myocarditis and pericarditis (Option C) is true.

References:

Harrison's Principle of Internal Medicine, 21st Edition, Page 2809-10

↑ *Back to this question in Part A*

@Neet_pg_bot

Q19: A 45-year-old male presents with chronic shortness of breath, dry cough, fatigue, and weight loss for the past six months. He works in a pigeon breeding facility and reports worsening symptoms over time. High-resolution CT (HRCT) of the chest reveals reticular changes, ground-glass opacities, and traction bronchiectasis. Which of the following statements about his condition is true? (Q851766)

A. It is caused by a Type I hypersensitivity reaction mediated by IgE antibodies.

B. Pulmonary fibrosis is a known complication of chronic HP.

C. Acute HP presents with symptoms several days after antigen exposure.

D. HRCT is typically normal in hypersensitivity pneumonitis.

Correct Answer: B. Pulmonary fibrosis is a known complication of chronic HP.

Explanation: Chronic hypersensitivity pneumonitis (HP) can lead to progressive pulmonary fibrosis , especially with long-term exposure to inhaled antigens such as bird proteins. HRCT shows reticular changes, ground-glass opacities, and traction bronchiectasis . It is caused by a Type I hypersensitivity reaction mediated by IgE antibodies (Option A): HP is primarily a Type III (immune complex) and Type IV (T-cell mediated) hypersensitivity, not IgE-mediated. Acute HP presents with symptoms several days after antigen exposure (Option C): acute HP develops within hours of exposure. HRCT is typically normal in hypersensitivity pneumonitis (Option D): HRCT usually shows parenchymal abnormalities consistent with inflammation and fibrosis.

References:

Harrison's Principle of Internal Medicine, 21st Edition, Page 2160-62.

↑ *Back to this question in Part A*

@Neet_pg_bot

Q20: Which of the following statements best characterizes brittle asthma? (Q851765)

A. Symptoms develop gradually over a few days, allowing time for preventive action.

B. It is characterized by sudden exacerbations with little or no warning.

C. Patients with brittle asthma typically have heightened awareness of airway narrowing.

D. The primary cause of brittle asthma is well understood and easily managed.

Correct Answer: B. It is characterized by sudden exacerbations with little or no warning.

Explanation: Brittle asthma is marked by sudden, unpredictable exacerbations with little or no warning, making early detection and preventive action difficult. Many patients also have a blunted perception of airway narrowing , leading to delayed diagnosis and severe outcomes. Symptoms develop gradually over a few days, allowing time for preventive action. (Option A) : Unlike typical asthma, where symptoms develop gradually, brittle asthma progresses suddenly. Patients with brittle asthma typically have heightened awareness of airway narrowing . (Option C) : Many patients with brittle asthma have blunted perception of airway narrowing, contributing to delayed treatment. The primary cause of brittle asthma is well understood and easily managed. (Option D) : The underlying causes of brittle asthma are not well understood, and management remains challenging due to its unpredictability.

References:

Davidson’s Principles and Practice of Medicine, 24th Edition, Page 570

↑ *Back to this question in Part A*

@Neet_pg_bot

Q21: A 35-year-old male with a history of asthma presents with symptoms occurring four times a week, occasional nighttime awakenings, and the need for rescue inhaler use three times a week. His post-bronchodilator FEV1 is 72% of the predicted value. According to the asthma classification guidelines, how would you categorize the severity and control of his asthma? (Q851764)

A. Mild asthma, controlled

B. Moderate asthma, partly controlled

C. Severe asthma, uncontrolled

D. Moderate asthma, uncontrolled

Correct Answer: B. Moderate asthma, partly controlled

Explanation: The patient has symptoms >2 days/week but < daily , FEV1 60–80% predicted, and occasional nighttime symptoms, which classifies as moderate persistent asthma . Since he still uses a rescue inhaler multiple times per week, it is partly controlled . Classification of Asthma Severity Post-bronchodilator FEV1 : Air exhaled in one second after bronchodilator use. FEV1/FVC Ratio : Indicates obstruction if <0.7. Severity Categories: Mild : FEV1 ≥ 80% of predicted (Option A) Moderate : FEV1 50-79% of predicted (Option B) Severe : FEV1 30-49% of predicted (Option C) Very Severe : FEV1 < 30% of predicted Moderate asthma, uncontrolled (Option D): some symptoms remain, but criteria for uncontrolled asthma (daily symptoms, frequent exacerbations) are not met.

References:

Davidson’s Principles and Practice of Medicine, 24th Edition, Page 570, 576

↑ *Back to this question in Part A*

@Neet_pg_bot

Q22: A 30-year-old patient with a history of asthma presents with symptoms occurring more than three times a week and nocturnal awakenings at least once a week. After evaluating the patient's condition, the physician decides to initiate treatment. Which of the following is the most appropriate initial step in the management of this patient? (Q851763)

A. Increase the dose of short-acting β2-agonist.

B. Start regular inhaled glucocorticoids (ICS).

C. Start prednisolone at the lowest effective dose.

D. Add a long-acting β2-agonist (LABA).

Correct Answer: B. Start regular inhaled glucocorticoids (ICS).

Explanation: Starting regular inhaled glucocorticoids (ICS) is the correct answer. The patient’s symptoms indicate a need for preventive therapy with ICS, which is the first-line treatment for patients experiencing frequent asthma symptoms. Increase the dose of short-acting β2-agonist (Option A): SABA only relieves symptoms and does not treat underlying inflammation. Start prednisolone at the lowest effective dose (Option C): systemic steroids are not first-line for routine asthma management. Add a long-acting β2-agonist (LABA) (Option D): LABA is used only as an add-on to ICS, not as initial therapy.

References:

Davidson’s Principles and Practice of Medicine, 24th Edition, Page 569, 570, 571, 572

↑ *Back to this question in Part A*

@Neet_pg_bot

Q23: A 24-year-old male presents with recurrent episodes of chest tightness, wheezing, and shortness of breath 10 minutes after running. The symptoms usually resolve within 30 minutes. Which of the following is the most appropriate pre-exercise treatment? (Q851762)

A. Long-acting beta agonist (LABA) taken daily

B. Short-acting beta agonist (SABA) used 15 minutes before exercise

C. Inhaled corticosteroid (ICS) used immediately after exercise

D. Leukotriene receptor antagonist (LTRA) taken during an acute episode

Correct Answer: B. Short-acting beta agonist (SABA) used 15 minutes before exercise

Explanation: SABAs (e.g., albuterol) are first-line for preventing symptoms of EIA when taken shortly before exercise. They relax bronchial smooth muscle and increase the threshold for bronchoconstriction. Exercise-Induced Asthma (EIA) It is a transient and reversible bronchial smooth muscle contraction after physical exertion. Exercise can induce bronchoconstriction in both asthmatics and non-asthmatics. Management: SABA (Short-Acting Beta Agonist): Pre-exercise use increases the threshold for bronchoconstriction LABA (Long-Acting Beta Agonist) (Option A): May extend the period of protection, but their use alone in asthma is to be discouraged ICS/LABA (Inhaled Corticosteroid/LABA) (Option C): Can be used occasionally for exercise but not recommended for regular use due to ICS overexposure. LTRAs (Leukotriene Receptor Antagonists) (Option D): regularly used for exercise-induced asthma to reduce the frequency of symptoms, not effective for pre-exercise treatment.

References:

Harrison’s Principle of Internal Medicine, 21st Edition, Page 2153, 2158, 2159 Exercise-Induced Bronchoconstriction - StatPearls - NCBI Bookshelf

↑ *Back to this question in Part A*

@Neet_pg_bot

Q24: A 28-year-old woman presents with a history of recurrent wheezing and shortness of breath, particularly during the winter months. She reports that her symptoms worsen with cold air and after respiratory infections. She does not have any known allergies, and her skin prick tests for common allergens are negative. What is the most likely diagnosis? (Q851761)

A. Atopic asthma

B. Occupational asthma

C. Intrinsic asthma

D. Cough-variant asthma

Correct Answer: C. Intrinsic asthma

Explanation: The patient exhibits symptoms consistent with intrinsic asthma, characterized by a lack of allergen sensitization (negative skin tests) and triggers primarily related to respiratory infections and environmental factors. Atopic asthma (Option A): This type typically presents with positive allergen sensitization, which is not the case here. Occupational asthma (Option B): There is no indication of specific workplace-related triggers mentioned in the vignette. Cough-variant asthma (Option D): While this condition is characterized by severe coughing, the predominant symptoms of wheezing and shortness of breath align more with intrinsic asthma.

References:

Robbins and Cotran Pathologic Basis of Disease, South Asian Edition, 10th Edition, Page 683

↑ *Back to this question in Part A*

@Neet_pg_bot

Q25: A 10-year-old girl presents with recurrent wheezing and difficulty breathing, especially during spring. Her symptoms worsen at night and with exercise. She has a family history of asthma. Physical examination reveals wheezing and a skin prick test shows positive reactions to grass pollen. What is the most likely diagnosis? (Q851760)

A. Exercise-induced asthma

B. Extrinsic asthma

C. Intrinsic Asthma

D. Non-atopic asthma

Correct Answer: B. Extrinsic asthma

Explanation: The girl's symptoms, including recurrent wheezing triggered by seasonal allergens (grass pollen), and her positive skin prick test indicate that she has extrinsic asthma (also known as allergic asthma). It is IgE-mediated (Type I) hypersensitivity reaction Exercise-induced asthma (Option A): While her symptoms worsen with exercise, this option does not encompass the allergic component indicated by the skin prick test.Drug of choice in excercise induced asthma:Leukotriene antagonist-montelukast , zafirlukast Intrinsic asthma /Non atopic asthma(Options C & D): This form of asthma is not related to allergies and typically occurs in adults, making it

less likely in this pediatric case.

References:

Robbins and Cotran Pathologic Basis of Disease, 10th Edition, Page 683

↑ *Back to this question in Part A*

@Neet_pg_bot

Q26: A 40-year-old man presents to the clinic with a history of asthma. He reports that he has been using his rescue inhaler (SABA) more frequently, experiencing symptoms on most days and waking up at least twice a week due to shortness of breath. His current management includes as-needed SABA but no regular controller medication. What is the most appropriate next step in his asthma management? (Q851758)

A. Continue current treatment and monitor symptoms.

B. Start low-dose inhaled corticosteroids for daily control.

C. Increase the dosage of the SABA.

D. Add a leukotriene receptor antagonist for better control.

Correct Answer: B. Start low-dose inhaled corticosteroids for daily control.

Explanation: The patient has persistent asthma (symptoms most days, nocturnal symptoms ≥2 times/week), so the next step is to start low-dose inhaled corticosteroids (ICS) as a controller medication. Continue current treatment and monitor symptoms (Option A): Patient's asthma is not well-controlled, so step-up therapy is needed. Increase the dosage of the SABA (Option C): SABA alone does not address airway inflammation and overuse increases mortality risk. Add a leukotriene receptor antagonist (Option D): LTRAs may be used as add-on therapy but ICS is first-line for persistent asthma. {{caption_text}}

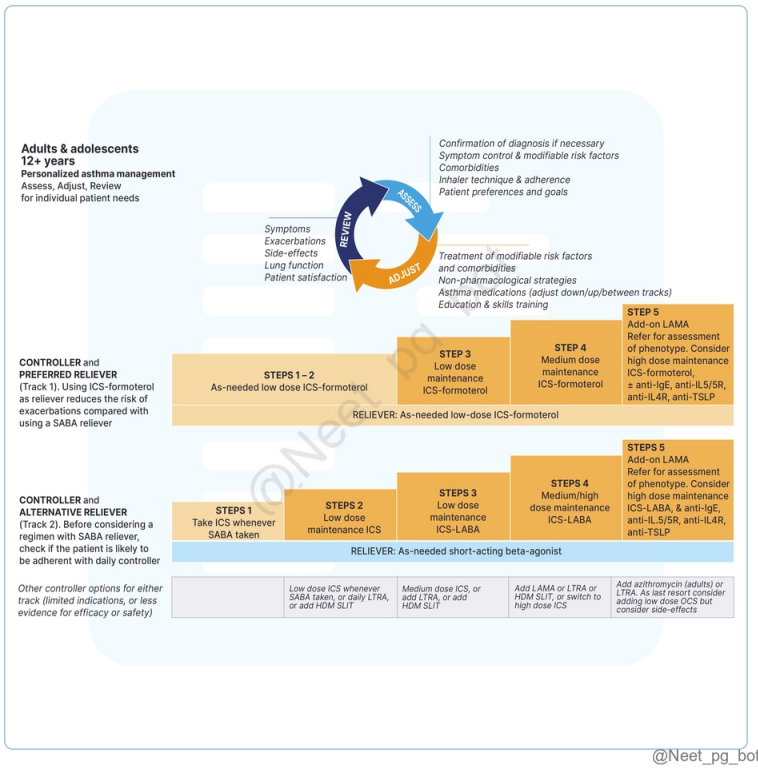

@Neet_pg_bot

References:

ginasthma.org/gina-reports/

↑ *Back to this question in Part A*

@Neet_pg_bot

Q27: A 35-year-old man presents with complaints of wheezing and shortness of breath that have worsened over the past few weeks. He notes that his symptoms often occur at night and are triggered by exposure to dust and exercise. Spirometry shows a FEV1/FVC ratio of 65%. After using a short-acting β2-agonist, his FEV1 increases by 20%. Which of the following findings would most likely be observed in this patient? (Q851757)

A. Increased total lung capacity

B. Decreased DLCO

C. Increased forced vital capacity

D. Decreased residual volume

Correct Answer: A. Increased total lung capacity

Explanation: This presentation is typical of asthma (reversible obstructive disease) which causes air trapping and hyperinflation, leading to an increased TLC. Reversibility on bronchodilator supports asthma rather than restrictive disease. Spirometry/PFTs findings in asthma: FEV1/FVC < 70% ↓ FEV1 Normal or ↓ FVC (Option C) ↑ Residual Volume (RV) (Option D) ↑ Total Lung Capacity (TLC) Normal or ↑ Diffusing Capacity of Lung for Carbon Monoxide (DLCO) (Option B)

References:

Harrison's Principle of Internal Medicine, 21st Edition, Page 2154

↑ *Back to this question in Part A*

@Neet_pg_bot

Q28: Which of the following statements about the Hygiene hypothesis is incorrect? (Q851756)

A. Clean environments may impair immune system maturation in children.

B. Endotoxin exposure is essential for proper immune development.

C. Fetal immune system is suppressed to prevent rejection of maternal tissue.

D. Lack of exposure to germs is linked to a decreased risk of developing asthma.

Correct Answer: D. Lack of exposure to germs is linked to a decreased risk of developing asthma.

Explanation: The hygiene hypothesis states that lack of early-life microbial exposure increases the risk of asthma and allergies, not decreases it. Clean environments may impair immune system maturation in children (Option A): True, reduced microbial exposure hampers immune maturation. Endotoxin exposure is essential for proper immune development (Option B): True, helps regulate Th1/Th2 balance. Fetal immune system is suppressed to prevent rejection of maternal tissue (Option C): True, maintains maternal-fetal tolerance.

References:

pmc.ncbi.nlm.nih.gov/articles/PMC8012489/

↑ *Back to this question in Part A*

@Neet_pg_bot

• [10_Pulmonology] 078 Tuberculosis

« Back to Folder Directory

[10_Pulmonology] 078 Tuberculosis — Quick Jump

Q1 (p. 2920)	*Q2 (p. 2920)*	*Q3 (p. 2921)*	*Q4 (p. 2922)*	*Q5 (p. 2923)*	*Q6 (p. 2925)*
Q7 (p. 2925)	*Q8 (p. 2926)*	*Q9 (p. 2926)*	*Q10 (p. 2927)*	*Q11 (p. 2928)*	*Q12 (p. 2929)*
Q13 (p. 2930)	*Q14 (p. 2931)*	*Q15 (p. 2931)*	*Q16 (p. 2932)*		

Q1: What is the duration of the longer MDR-TB regimen? (Q851824)

A. 18-20 months

B. 12 months

C. 6-10 months

D. 24-36 months

Correct Answer: A. 18-20 months

Explanation: The duration of the longer MDR-TB regimen is 18-20 months or more. Multidrug-resistant (MDR) TB- Patients who are infected with strains resistant to isoniazid and rifampicin. Longer MDR-TB regimen: Indications: Additional resistance (e.g., fluoroquinolones) Severe pulmonary/extrapulmonary disease Previous treatment with second-line drugs Recommended Drugs (Group A): Bedaquiline, Linezolid, Fluoroquinolone (levofloxacin or moxifloxacin) Additional Drugs (Group B): Clofazimine, Cycloserine Alternative Drugs (Group C): Used to replace Group A or B agents when necessary

References:

https://pmc.ncbi.nlm.nih.gov/articles/PMC4561400/

Harrison’s Principles of Internal Medicine, 21st Edition, Page 1376

↑ *Back to this question in Part A*

@Neet_pg_bot

Q2: A 35-year-old woman presents with a enlarged cervical lymph nodes on left side with matted consistency. CXR and excision lymph node biopsy report is shown below . What is the most likely diagnosis? (Q851779)

A. Hodgkin’s lymphoma

B. Metastatic carcinoma

C. Tuberculous lymphadenitis

D. Sarcoidosis

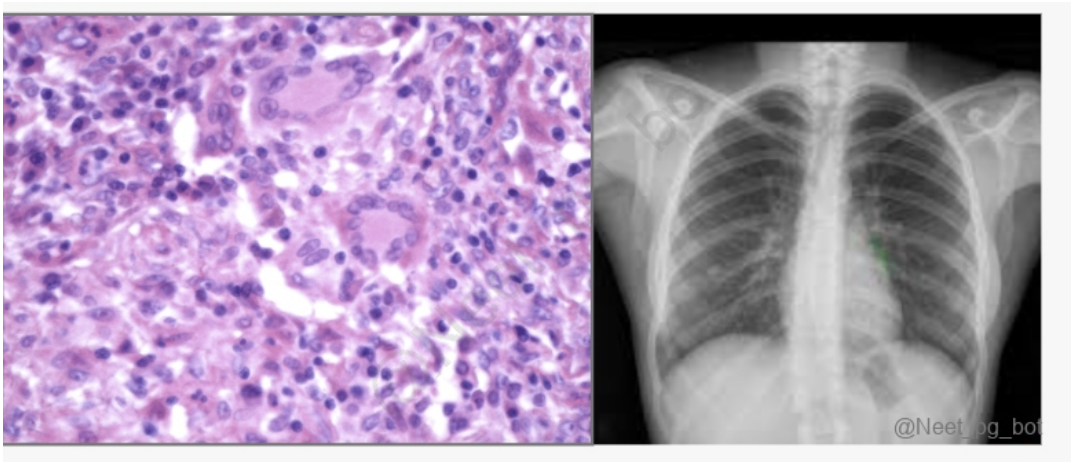

Correct Answer: C. Tuberculous lymphadenitis

Explanation: The patient has cervical lymphadenopathy with matted nodes, which is classical for tuberculous lymphadenitis (scrofula). Excision biopsy in TB shows caseating granulomas, and chest X-ray may show pulmonary TB changes or may be normal. Systemic symptoms (fever, night sweats, weight loss) may be present. Hodgkin’s lymphoma (Option A): Hodgkin’s usually presents with painless, firm, rubbery lymph nodes, often in the supraclavicular region, and may have B symptoms. Nodes are typically discrete, not matted. Metastatic carcinoma (Option B): Metastatic nodes are usually hard, non-tender, irregular, and often associated with a primary tumor elsewhere, unlike the matted nodes seen in TB. Sarcoidosis (Option D): It presents with non-caseating granulomas, often bilateral hilar lymphadenopathy, and is usually painless; matted cervical nodes are uncommon.

References:

Harrison’s Principles of Internal Medicine, 21st Edition, Page 1364

pmc.ncbi.nlm.nih.gov/articles/PMC6848329/

↑ *Back to this question in Part A*

@Neet_pg_bot

Q3: A 40-year-old man presents with fever, pleuritic chest pain, and dyspnea. Physical examination revealed dullness to percussion and absent breath sounds on the left side. Chest X-ray shows a left-sided pleural effusion. Thoracentesis reveals straw-coloured

fluid with a protein concentration of 5 g/dL and a WBC count of 1500/μL with lymphocyte predominance. The acid-fast bacilli (AFB) smear is negative. What is the most likely diagnosis? (Q851780)

A. Parapneumonic effusion

B. Tuberculous pleuritis

C. Malignant pleural effusion

D. Congestive heart failure

Correct Answer: B. Tuberculous pleuritis

Explanation: Tuberculous pleuritis presents with pleuritic chest pain, fever, and dyspnea, along with straw-coloured pleural fluid that is exudative (high protein concentration) and lymphocyte-predominant. AFB smear is often negative in pleural effusions and diagnosis may rely on adenosine deaminase (ADA) levels or pleural biopsy. Parapneumonic effusion (Option A): Usually associated with bacterial pneumonia and more commonly presents with neutrophil predominance in the pleural fluid. Malignant pleural effusion (Option C): Would show atypical cells in the pleural fluid and often be hemorrhagic, with high LDH levels. Congestive heart failure (Option D): Typically causes a transudative pleural effusion with low protein levels, not lymphocyte predominance.

References:

Harrison's Principles of Internal Medicine, 21st Edition, Page 1364, 1365

↑ *Back to this question in Part A*

@Neet_pg_bot

Q4: A 25-year-old man presents with a 2-week history of headaches, low-grade fever, irritability, and confusion. On examination, he has neck stiffness and cranial nerve VI palsy. Lumbar puncture reveals a CSF leukocyte count of 800/μL (lymphocyte predominance), protein of 400 mg/dL, and low glucose. AFB smear is negative. What is the most likely diagnosis? (Q851782)

A. Viral meningitis

B. Bacterial meningitis

C. Tuberculous meningitis

D. Cryptococcal meningitis

Correct Answer: C. Tuberculous meningitis

Explanation: Tuberculous meningitis presents with a subacute course of headaches, mental changes, and fever over weeks, with CSF findings of lymphocyte predominance, elevated protein, and low glucose. Cobweb coagulum seen in CSF. Cranial nerve palsies and hydrocephalus can occur. AFB smear is often negative, and diagnosis may rely on culture or Xpert MTB/RIF assay. Cobweb coagulum Viral meningitis (Option A): Typically presents with milder symptoms and normal glucose in CSF, with lymphocyte predominance but lower protein levels. Bacterial meningitis (Option B): Has a more rapid onset with neutrophil predominance in the CSF, elevated protein, and very low glucose. Cryptococcal meningitis (Option D) : Common in immunocompromised patients, typically with low glucose and lymphocytic pleocytosis, but diagnosis is confirmed with cryptococcal antigen testing or India ink stain.



References:

Harrison’s Principles of Internal Medicine, 21st Edition, Page 1109, 1365, 1366

↑ *Back to this question in Part A*

@Neet_pg_bot

Q5: A 30-year-old man presents with chronic back pain, fatigue, and weight loss. MRI of the spine reveals destruction of the lower thoracic vertebrae with a paravertebral abscess tracking into the psoas muscle. What is the most likely diagnosis? (Q851785)

A. Pyogenic bacterial osteomyelitis

B. Spinal tuberculosis

C. Vertebral metastasis

D. Disc herniation

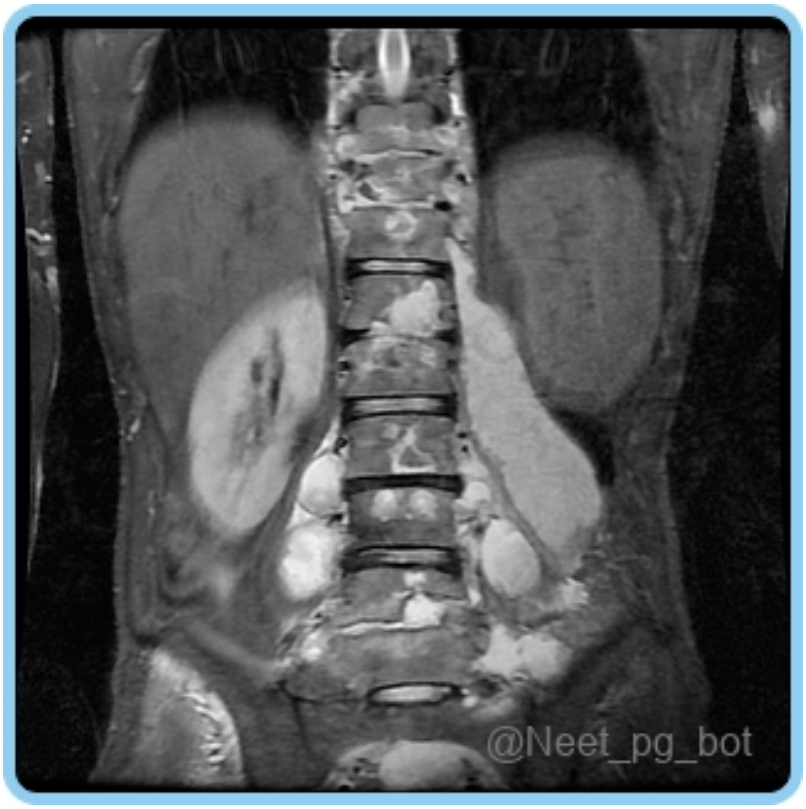

Correct Answer: B. Spinal tuberculosis

Explanation: Spinal tuberculosis (Pott's disease) involves the lower thoracic and upper lumbar vertebrae in adults, with paravertebral abscess formation that can track to distant regions (e.g., psoas abscess). Paraplegia can occur due to abscess or spinal cord compression Pyogenic bacterial osteomyelitis (Option A): Also causes vertebral destruction, but progresses more rapidly with severe systemic symptoms like fever. Vertebral metastasis (Option C) : More common in older patients with known malignancies, typically lacks abscess formation, and shows different patterns on imaging. Disc herniation (Option D): Presents with radicular pain but does not cause vertebral destruction or abscess formation.

References:

Harrison's Principles of Internal Medicine, 21st Edition, Page 1365

pmc.ncbi.nlm.nih.gov/articles/PMC10251269/

↑ *Back to this question in Part A*

@Neet_pg_bot

Q6: A 40-year-old woman presents with a history of pelvic pain, menstrual irregularities, and frequent urination over the past few months. She reports that her symptoms have worsened and she experiences occasional hematuria. Urinalysis shows pyuria, but urine cultures are negative. A pelvic ultrasound reveals abnormalities in the fallopian tubes. What is the most likely diagnosis? (Q851786)

A. Urinary tract infection

B. Genitourinary tuberculosis

C. Pelvic inflammatory disease (PID)

D. Can be either B or C

Correct Answer: B. Genitourinary tuberculosis

Explanation: Genitourinary tuberculosis is a condition commonly affecting the fallopian tubes and endometrium, leading to infertility, pelvic pain, and urinary symptoms like dysuria and hematuria. The negative urine cultures and presence of pyuria are suggestive of TB, especially in an individual with a history of pelvic symptoms. Urinary tract infection (Option A): Typically presents with positive cultures, and symptoms are usually more acute and can include urgency and burning. Pelvic inflammatory disease (PID) (Option C): Could cause similar symptoms but usually presents with acute pain, fever, and more prominent systemic signs. Culture would often show infection.

References:

Harrison's Principles of Internal Medicine, 21st Edition, Page 1365, 1366

↑ *Back to this question in Part A*

@Neet_pg_bot

Q7: A 9-year-old boy presents with fever and pleuritic chest pain. Chest X-ray shows a small calcified lesion in the lower right lung and enlarged hilar lymph nodes. He also has a rash on his legs resembling erythema nodosum. What is the most likely diagnosis? (Q851793)

A. Acute bacterial pneumonia

B. Primary pulmonary tuberculosis

C. Cystic fibrosis

D. Viral lower respiratory tract infection

Correct Answer: B. Primary pulmonary tuberculosis

Explanation: Primary pulmonary tuberculosis occurs shortly after initial TB infection, especially in children. The presence of fever, pleuritic chest pain, calcified Ghon focus, hilar lymphadenopathy and erythema nodosum points towards primary TB. Acute bacterial pneumonia (Option A): Often presents with fever and productive cough, but calcified lesions and lymphadenopathy are uncommon. Cystic fibrosis (Option C): Usually presents with chronic respiratory symptoms, poor growth, and family history, but it doesn't typically cause lymphadenopathy or a Ghon focus. Viral lower respiratory tract infection (Option D): Can present with wheezing and fever but does not cause calcified lesions or hilar lymphadenopathy.

References:

Harrison's Principles of Internal Medicine, 21st Edition, Page 1362, 1363

↑ *Back to this question in Part A*

@Neet_pg_bot

Q8: Which finding is not typically present in primary tuberculosis? (Q851795)

A. Hilar lymphadenopathy

B. Perihilar infiltrate

C. Non-caseating granuloma

D. Pleural effusion

Correct Answer: C. Non-caseating granuloma

Explanation: Non-caseating granulomas are characteristic of conditions like sarcoidosis , not tuberculosis , which usually presents with caseating granulomas. A unique feature differentiating tuberculous granulomas from other infectious granulomatous conditions is caseation or central necrosis. Primary tuberculosis typically shows hilar lymphadenopathy (Option A), perihilar infiltrates (Option B) and pleural effusion (Option D).

References:

www.ncbi.nlm.nih.gov/books/NBK567737/

↑ *Back to this question in Part A*

@Neet_pg_bot

Q9: In the pathophysiology of postprimary tuberculosis, which of the following immunological events is most critical for the development of cavitary lesions in the lung apices and how does it contribute to tissue destruction? (Q851798)

A. Activation of B cells leads to antibody production, which facilitates phagocytosis of M. tuberculosis.

B. Release of IL-4 and IL-10 from T-helper cells, promoting a Th2 response that leads to fibrosis and walling off of the infection.

C. Secretion of TNF-α and IFN-γ by activated T cells, resulting in macrophage activation and the subsequent formation of caseous necrosis.

D. Induction of a robust innate immune response mediated by neutrophils, resulting in rapid clearance of bacteria and prevention of necrosis.

Correct Answer: C. Secretion of TNF-α and IFN-γ by activated T cells, resulting in macrophage activation and the subsequent formation of caseous necrosis.

Explanation: Reactivation of Latent TB – Dormant bacilli within granulomas can reactivate when host immunity weakens (e.g., HIV, diabetes, malnutrition). Immune Response – Reactivation triggers a T-cell–mediated response (CD4+, CD8+) with IFN-γ–activated macrophages, but bacteria often escape control and continue replicating. Granuloma and Caseous Necrosis – Reactivated bacilli cause caseous necrosis in granulomas, destroying lung tissue and forming necrotic centres. Cavitation and Spread – Liquefaction of necrotic tissue forms apical lung cavities, promoting bacterial growth, lung damage, and possible hematogenous spread to extrapulmonary sites (kidney, bone, CNS). Activation of B cells leads to antibody production, which facilitates phagocytosis of M. tuberculosis. (Option A) : While B cells and antibodies play a role in immune defence, the primary mechanism for tissue destruction and cavitation in postprimary TB is not through antibody-mediated phagocytosis. Release of IL-4 and IL-10 from T-helper cells, promoting a Th2 response that leads to fibrosis and walling off of the infection. (Option B): IL-4 and IL-10 promote a Th2 response, which is generally associated with allergic responses and may lead to fibrosis but does not facilitate the formation of cavitary lesions in postprimary TB. Induction of a robust innate immune response mediated by neutrophils, resulting in rapid clearance of bacteria and prevention of necrosis. (Option D): Neutrophils primarily respond to acute infections. In postprimary TB, the chronic immune response involving T cells and macrophages is crucial for the pathogenesis of cavitary lesions.

References:

pmc.ncbi.nlm.nih.gov/articles/PMC3215852/

pmc.ncbi.nlm.nih.gov/articles/PMC4226026/

↑ *Back to this question in Part A*

@Neet_pg_bot

Q10: Which of the following matches the type of tuberculosis focus with its correct location? Type of TB Focus Location 1. Assman Focus a. Subpleural 2. Ghon Focus b.

Infraclavicular 3. Puhl Lesion c. Supraclavicular 4. Rich Focus d. Brain (Q851800)

A. 1-b, 2-a, 3-c, 4-d

B. 1-a, 2-c, 3-d, 4-b

C. 1-c, 2-d ,3-a, 4-b

D. 1-d, 2-b, 3-c, 4-a

Correct Answer: A. 1-b, 2-a, 3-c, 4-d

Explanation: Type of TB Focus Location Assman Focus Location : Infraclavicular It is prone to cavitation, leading to potential bacterial spread and transmission. Ghon Focus Location : Lower part of the upper lobe or upper part of the lower lobe of the lung, typically subpleural. The initial area of infection in primary TB appears as a granulomatous lesion. When combined with lymph node involvement, it forms the Ghon complex. Puhl Lesion Location : Most commonly found in the supraclavicular region, which is significant as this location can indicate the spread of TB from the lungs or other primary sites of infection. Rich Focus Location : Brain or meninges. A site of TB infection within the central nervous system, which can rupture, leading to tuberculous meningitis.

References:

www.ncbi.nlm.nih.gov/books/NBK441916/

pmc.ncbi.nlm.nih.gov/articles/PMC6156532/

↑ *Back to this question in Part A*

@Neet_pg_bot

Q11: What is the primary purpose of Interferon-gamma release assays (IGRAs) to tuberculosis? (Q851801)

A. To confirm active TB disease

B. To diagnose latent TB infection

C. To monitor treatment response

D. To assess the severity of lung disease

Correct Answer: B. To diagnose latent TB infection

Explanation: The primary use of IGRAs is to identify individuals with latent tuberculosis infection (LTBI) . Tuberculin Skin Test (TST) and Interferon-gamma Release Assays (IGRAs) are specific for latent tuberculosis infection. To confirm active TB disease (Option A): IGRAs cannot distinguish between latent infection and active

disease. A positive result only means the person has been infected at some point. Active TB requires "the triad": clinical symptoms (fever, weight loss, night sweats), positive sputum culture/smear, and suggestive chest X-ray findings. To monitor treatment response (Option C): Once a person is infected, their T-cells remain "sensitized." Therefore, IGRAs often remain positive even after successful treatment. We do not re-test with IGRAs to see if a patient is "cured"; we monitor clinical improvement and sputum conversion (negative cultures). To assess the severity of lung disease (Option D): IGRAs are immunological markers, not structural ones. They provide no information on the extent of lung damage or "cavitation." Lung severity is assessed via Chest X-ray or CT Scan to look for infiltrates and cavities.

References:

www.ncbi.nlm.nih.gov/books/NBK560585/

Bailey & Scott's Diagnostic Microbiology, 14th Edition, Page 534, 546

↑ *Back to this question in Part A*

@Neet_pg_bot

Q12: Which of the following best describes the principle behind the LAMP test? (Q851805)

A. Amplifying RNA to detect TB

B. Isothermal amplification of DNA at a constant temperature

C. PCR amplification with thermal cycling

D. Culture growth of Mycobacterium tuberculosis

Correct Answer: B. Isothermal amplification of DNA at a constant temperature

Explanation: The LAMP (Loop-Mediated Isothermal Amplification) test amplifies DNA at a constant temperature (usually 60–65°C), eliminating the need for thermal cycling. Amplifying RNA to detect TB (Option A): Describes RT-PCR , not LAMP. PCR amplification with thermal cycling (Option C): Refers to conventional PCR , which requires cyclic temperature changes. Culture growth of Mycobacterium tuberculosis (Option D): Refers to traditional microbiological culture , not a molecular diagnostic test.

References:

www.sciencedirect.com/science/article/abs/pii/S1567134820300629

pubmed.ncbi.nlm.nih.gov/10222213/

www.ncbi.nlm.nih.gov/books/NBK441916/

↑ *Back to this question in Part A*

@Neet_pg_bot

Q13: A 34-year-old man with advanced HIV infection (CD4 count of 50 cells/mm³) is diagnosed with pulmonary tuberculosis (TB) and started on anti-tuberculosis treatment. Two weeks later, he initiated antiretroviral therapy (ART). After 3 weeks on ART, he returns to the clinic complaining of worsening cough, fever and night sweats. Physical examination reveals enlarged cervical lymph nodes and increased lung crackles on auscultation. His viral load has dropped significantly, but his CD4 count remains low. What is the most likely diagnosis? (Q851807)

A. Drug-resistant TB

B. Immune reconstitution inflammatory syndrome (IRIS)

C. ART toxicity

D. New opportunistic infection

Correct Answer: B. Immune reconstitution inflammatory syndrome (IRIS)

Explanation: This patient likely has TB-associated immune reconstitution inflammatory syndrome (IRIS), a paradoxical worsening of TB symptoms after starting HAART. Common symptoms include fever, worsening cough, and enlarged lymph nodes. It often presents 2-12 weeks after starting ART. Management : Mild IRIS cases are managed symptomatically with paracetamol and NSAID. For more severe cases , corticosteroids may be used to control inflammation while continuing both TB and ART medications. Drug-resistant TB (Option A): While drug-resistant TB can cause persistent or worsening symptoms, it usually presents with poor clinical response despite appropriate treatment over several weeks. In this case, the patient initially improved and symptoms worsened after ART initiation , making resistance less likely . Also, there's no mention of treatment non-compliance or contacts with resistant TB. ART toxicity (Option C): ART side effects usually manifest as GI upset, liver enzyme abnormalities, or specific organ toxicities (e.g., neuropathy, nephropathy). They don't typically cause fever, lymphadenopathy, or worsening cough . Plus, the symptoms described are more inflammatory than toxic. New opportunistic infection (Option D): While patients with low CD4 counts are susceptible to new infections, the timing , nature of symptoms , and coinciding ART initiation are more characteristic of IRIS. Also, IRIS can look like a new infection but is actually an immune-mediated unmasking of a latent or partially treated one.

References:

www.ncbi.nlm.nih.gov/books/NBK567803/

www.ncbi.nlm.nih.gov/pmc/articles/PMC3280977/

pmc.ncbi.nlm.nih.gov/articles/PMC3290133/

↑ *Back to this question in Part A*

@Neet_pg_bot

Q14: Match the drugs used in the initial treatment of tuberculosis with their dosage. Drugs Dosage (mg/kg) a.Isoniazid i.10 b.Rifampicin ii.15 c.Pyrazinamide iii.5 d.Ethambutol iv.25 (Q851819)

A. a-iii,b-i,c-iv,d-ii

B. a-i,b-ii,c-iii,d-iv

C. a-iv,b-iii,c-ii,d-i

D. a-ii,b-iii,c-iv,d-i

Correct Answer: A. a-iii,b-i,c-iv,d-ii

Explanation: Initial Treatment of Tuberculosis: Drug Dose Mechanism of action Isoniazid 5 mg/kg Inhibiting the biosynthesis of mycolic acid. Rifampicin 10 mg/kg Inhibiting DNA-dependent RNA polymerase, which further inhibits bacterial protein synthesis and transcription. Pyrazinamide 25 mg/kg Inhibiting trans-translation and possibly coenzyme A synthesis is needed for the bacteria to survive. Ethambutol 15 mg/kg Inhibits the enzyme arabinosyltransferases and prevents the biosynthesis of the mycobacterial cell wall.

References:

Harrison’s Principles of Internal Medicine, 21st Edition, Page 1372

https://www.ncbi.nlm.nih.gov/books/NBK557666/

↑ *Back to this question in Part A*

@Neet_pg_bot

Q15: Which of the following is not a component of the shorter MDR-TB regimen? (Q851822)

A. 6 months of levofloxacin

B. 5 months of clofazimine

C. 5 months of ethambutol

D. 5 months of isoniazid

Correct Answer: D. 5 months of isoniazid

Explanation: High-dose isoniazid is given for 6 months in the shorter MDR-TB regimen Multidrug-resistant (MDR) TB- Patients who are infected with strains resistant to isoniazid and rifampicin Shorter MDR-TB regimen: 6 months of bedaquiline, levofloxacin (or moxifloxacin) (Option A ruled out) , ethionamide, ethambutol, pyrazinamide, high-dose isoniazid (Option D) , clofazimine Followed by 5 months of levofloxacin (or moxifloxacin), clofazimine (Option B ruled out) , pyrazinamide, and ethambutol (Option C ruled out)

References:

Harrison’s Principles of Internal Medicine, 21st Edition, Pages 1376-1377

https://pmc.ncbi.nlm.nih.gov/articles/PMC4561400/

↑ *Back to this question in Part A*

@Neet_pg_bot

Q16: A 41-year-old man with a history of night sweats, fever, and weight loss presents with anal fistulae. Physical examination and imaging suggest an abscess near the rectum. Which diagnostic step should be prioritized to investigate a possible cause? (Q851825)

A. Evaluation for rectal tuberculosis

B. Screening for Crohn’s disease

C. Colonoscopy with biopsy for malignancy

D. Culture and sensitivity of fistula discharge

Correct Answer: A. Evaluation for rectal tuberculosis

Explanation: The presence of anal fistulae, particularly in a patient with systemic symptoms such as night sweats, fever, and weight loss, points to rectal tuberculosis (TB) . Anal fistulae can be a manifestation of gastrointestinal TB. Evaluating for rectal TB is important, as this condition may mimic other gastrointestinal diseases but requires specific anti-tubercular treatment for effective management. Screening for Crohn’s disease (Option B): While Crohn's disease can cause anal fistulae and presents with chronic abdominal pain and weight loss, this patient's night sweats and fever are more indicative of an infectious cause like TB. Crohn's disease also does not present with systemic symptoms making TB a more likely diagnosis. Colonoscopy with biopsy for malignancy (Option C): Although malignancy could present with weight loss and other systemic symptoms, it is less likely to cause anal fistulae. Culture and sensitivity of fistula discharge (Option D): While culturing the fistula discharge may identify pathogens, the yield for diagnosing TB from such samples is low, as mycobacteria may not be easily detected in superficial cultures. A targeted evaluation for TB would be more beneficial in this case.

References:

Harrison’s Principles of Internal Medicine, 21st Edition, Page 1366

↑ *Back to this question in Part A*

@Neet_pg_bot

• [10_Pulmonology] 079 Respiratory Physiology And Failure

« Back to Folder Directory

[10_Pulmonology] 079 Respiratory Physiology And Failure — Quick Jump

Q1 (p. 2934) *Q2 (p. 2934)* *Q3 (p. 2935)* *Q4 (p. 2937)* *Q5 (p. 2940)* *Q6 (p. 2946)*
Q7 (p. 2946) *Q8 (p. 2948)*

Q1: A 72 y/o male, a k/c/o COPD presents to the ED with shortness of breath and confusion. He has been experiencing increased fatigue and worsening dyspnea over the past few days. O/E he has a respiratory rate of 30 bpm. Arterial blood gas analysis shows: PaO2: 58 mmHg, PaCO2: 52 mmHg and pH: 7.2. Which type of respiratory failure is most likely in this patient? (Q852142)

A. Type 1 Respiratory Failure

B. Type 2 Respiratory Failure

C. Type 3 Respiratory Failure

D. Type 4 Respiratory Failure

Correct Answer: B. Type 2 Respiratory Failure

Explanation: Type 2 respiratory failure is characterized by hypercapnia (PaCO2 >45 mmHg) with or without hypoxemia, indicating ventilatory failure , commonly seen in COPD exacerbations. Type 1 Respiratory Failure (Option A): Defined by hypoxemia without hypercapnia; not consistent with this patient. Type 3 Respiratory Failure (Option C): Associated with perioperative hypoxemia; not applicable here. Type 4 Respiratory Failure (Option D): Due to shock-related tissue hypoperfusion; not the primary issue in COPD exacerbation.

References:

Davidson’s Principles and Practice of Medicine, 24th Edition, Page 565

www.ncbi.nlm.nih.gov/books/NBK526127/

pmc.ncbi.nlm.nih.gov/articles/PMC7946379/#s0050

↑ *Back to this question in Part A*

@Neet_pg_bot

Q2: A 65 y/o female undergoes elective hip replacement surgery. Postoperatively, she develops shortness of breath and a decreased oxygen saturation level. She reports significant pain at the surgical site and is reluctant to take deep breaths due to discomfort. O/E, her respiratory rate is elevated, and auscultation reveals diminished breath sounds at the bases. A chest X-ray shows areas of atelectasis. What type of respiratory failure is most likely in this patient? (Q852143)

A. Type 1 Respiratory Failure

B. Type 2 Respiratory Failure

C. Type 3 Respiratory Failure

D. Type 4 Respiratory Failure

Correct Answer: C. Type 3 Respiratory Failure

Explanation: The patient exhibits respiratory failure due to atelectasis, which is common after surgery, especially with pain and sedation affecting her ability to breathe deeply. This scenario aligns with Type 3 Respiratory Failure. Type 3 respiratory failure, also called perioperative or atelectasis-related hypoxemia , occurs due to alveolar collapse after surgery, pain-limited breathing, or shallow respirations, leading to hypoxemia without hypercapnia . Type Definition ABG Pattern Key Etiologies Type 1 (Hypoxemic) Low O■ without high CO■ PaO■ < 50 mmHg, PaCO■ < 60 mmHg Alveolar hypoventilation, low FiO■, diffusion defects, V/Q mismatch, R→L shunt Type 2 (Hypercapnic) Inadequate ventilation → high CO■ PaO■ < 50 mmHg, PaCO■ > 60 mmHg CNS dysfunction, sedatives, chest wall/respiratory muscle problems, diaphragm dysfunction Type 3 (Peri-Operative) Post-surgical impaired breathing PaO■ < 50 mmHg, PaCO■ < 60 mmHg General anesthesia, supine position, depressed cough, abdominal incision, ascites, airway secretions Type 4 (Shock/Hypoperfusion) Due to shock & high metabolic demand PaO■ < 50 mmHg, PaCO■ > 60 mmHg High metabolic demand (sepsis, fever), reduced cardiac output (cardiogenic/hypovolemic shock)

References:

www.unboundmedicine.com/washingtonmanual/view/Washington-Manual-of-Medical-Therapeutics/602550/all/Respiratory_Failure

my.clevelandclinic.org/health/diseases/24835-respiratory-failure

pmc.ncbi.nlm.nih.gov/articles/PMC7946379/#s0060

↑ *Back to this question in Part A*

@Neet_pg_bot

Q3: A 55 y/o male with h/o pneumonia is admitted to the hospital with severe shortness of breath. O/E, his oxygen saturation is 85%, and arterial blood gas analysis

shows: PaO2: 55 mmHg PaCO2: 40 mmHg pH: 7.38 He is anxious and struggling to breathe. What is the most appropriate initial treatment for this patient's respiratory failure? (Q852144)

A. Intubation and mechanical ventilation

B. Noninvasive ventilation (NIV)

C. Oxygen therapy via a nonrebreathing mask

D. Continuous positive airway pressure (CPAP)

Correct Answer: C. Oxygen therapy via a nonrebreathing mask

Explanation: The patient has type 1 respiratory failure (hypoxemia without hypercapnia). Supplemental oxygen is the first-line treatment to improve oxygenation, while monitoring for response. Intubation and mechanical ventilation (Option A): This is typically reserved for severe respiratory failure with indications such as apnea, severe hypoxemia, or respiratory acidosis. In this case, the patient may not yet require such invasive measures. Noninvasive ventilation (NIV) (Option B): Primarily indicated for type 2 respiratory failure with hypercapnia. Continuous positive airway pressure (CPAP) (Option D): CPAP can help in certain cases of respiratory failure but is not the first-line treatment for hypoxemic respiratory failure. It is more suited for patients with obstructive sleep apnea or cardiogenic pulmonary oedema.



References:

www.ncbi.nlm.nih.gov/books/NBK526127/

pmc.ncbi.nlm.nih.gov/articles/PMC7946379/#s0060

↑ *Back to this question in Part A*

@Neet_pg_bot

Q4: A 30 y/o female presents with h/o wheezing and shortness of breath. A pulmonary function test shows a flow-volume loop with a distinct "scooped" appearance during expiration, particularly at lower lung volumes. Which condition does this flow-volume loop most likely represent? (Q852145)

A. Pulmonary Fibrosis

B. Asthma

C. Retrosternal Goiter

D. Normal

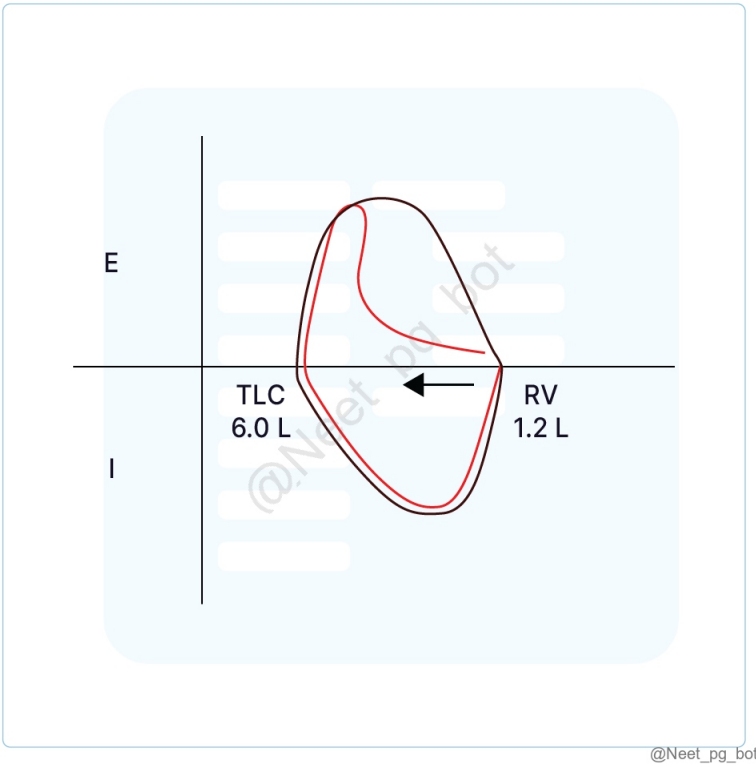

Correct Answer: B. Asthma

Explanation: The “scooped” appearance of the expiratory limb on the flow-volume loop is characteristic of obstructive airway diseases like asthma, indicating airflow limitation during exhalation. Pulmonary Fibrosis (Option A): High lung recoil pressure increases expiratory flow for any given lung volume, producing a loop that is shifted to lower volumes and shows high maximal flow relative to volume. Overall lung volumes (TLC, FRC) are reduced due to increased stiffne Retrosternal Goiter (Option C): Extrathoracic airway narrowing can limit inspiratory flow, causing flattening of the inspiratory portion of the loop. Normal Flow volume loop (Option D): A normal flow-volume loop displays airflow (in L/second) related to lung volume (in L) during maximal inspiration from complete exhalation residual volume (RV) and maximum expiration from total lung capacity (TLC).

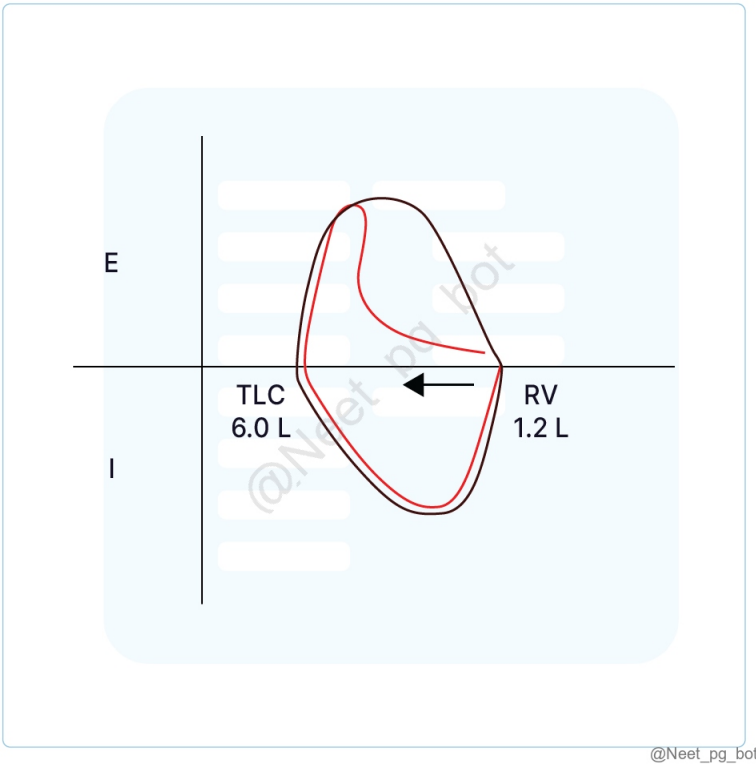

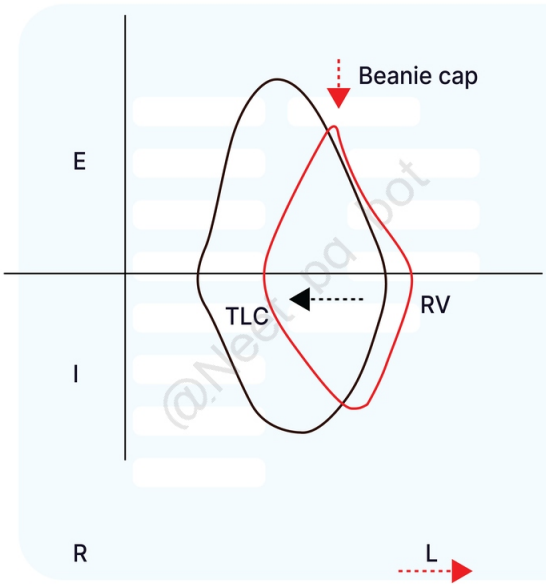

@Neet_pg_bot

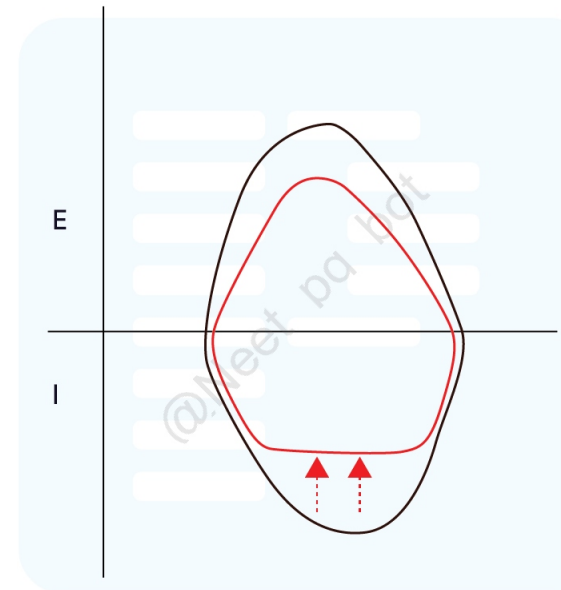

@Neet_pg_bot

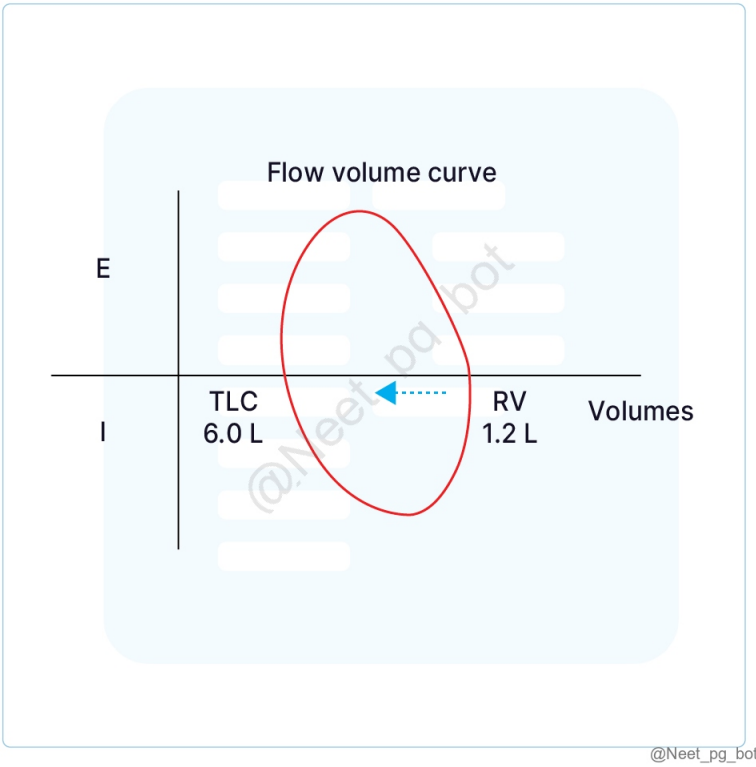

References:

Harrison's Principles of Internal Medicine, 21st Edition, Page 2135-2138 www.msdmanuals.com/professional/pulmonary-disorders/tests-of-pulmonary-function-pft/airflow-lung-volumes-and-flow-volume-loop

↑ *Back to this question in Part A*

@Neet_pg_bot

Q5: Match the following diseases with their respective flow volume curves: 1. Asthma a) 2. Extrathoracic Obstruction b) 3. Fixed Obstruction c) 4. Restrictive Airway Disorders d) (Q852146)

A. 1-d, 2-a, 3-c, 4-b

B. 1-a, 2-c, 3-d, 4-b

C. 1-b, 2-d, 3-a, 4-c

D. 1-c, 2-b, 3-d, 4-a

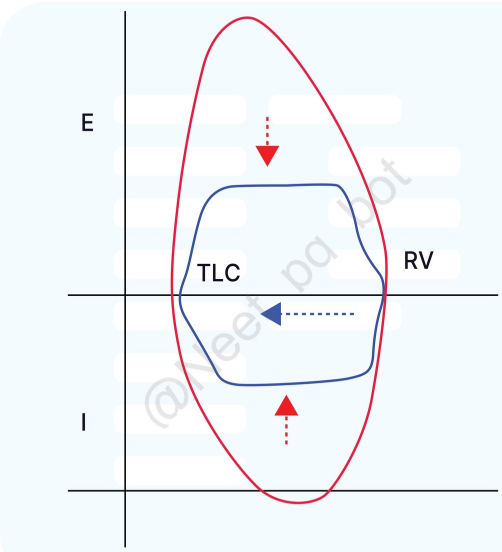

@Neet_pg_bot

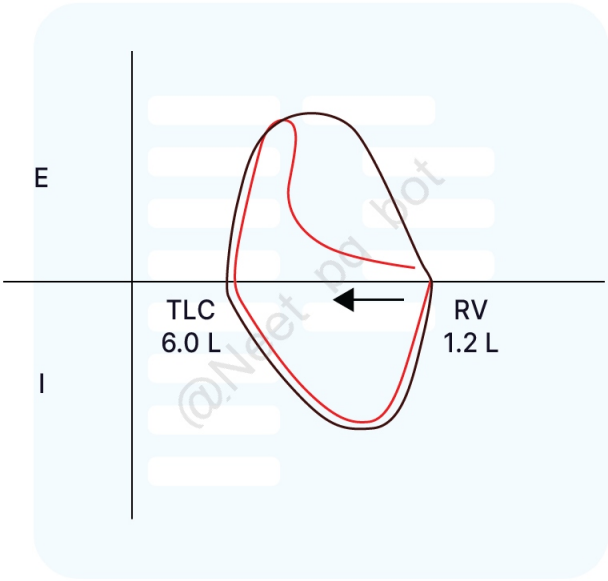

@Neet_pg_bot

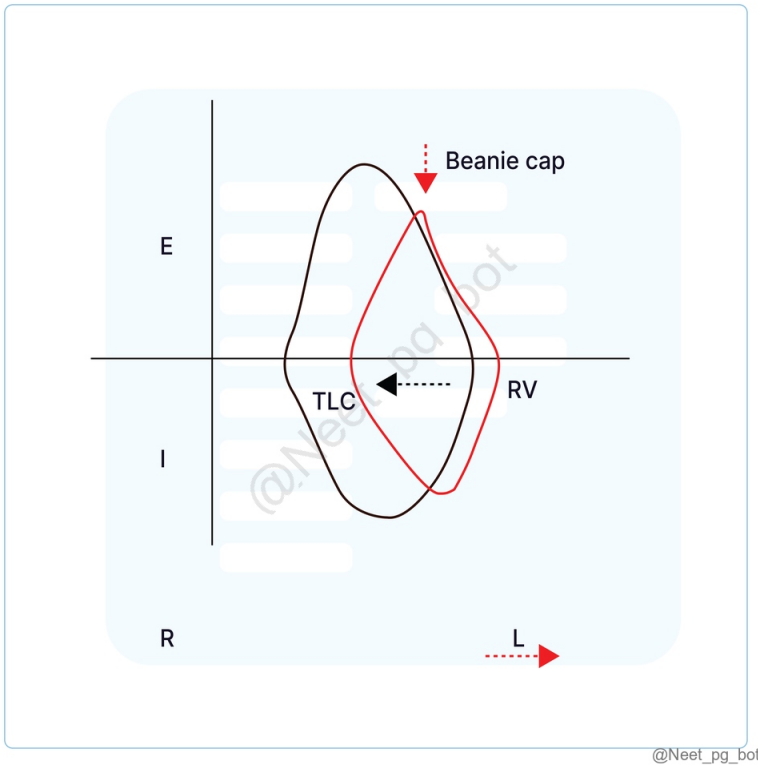

@Neet_pg_bot

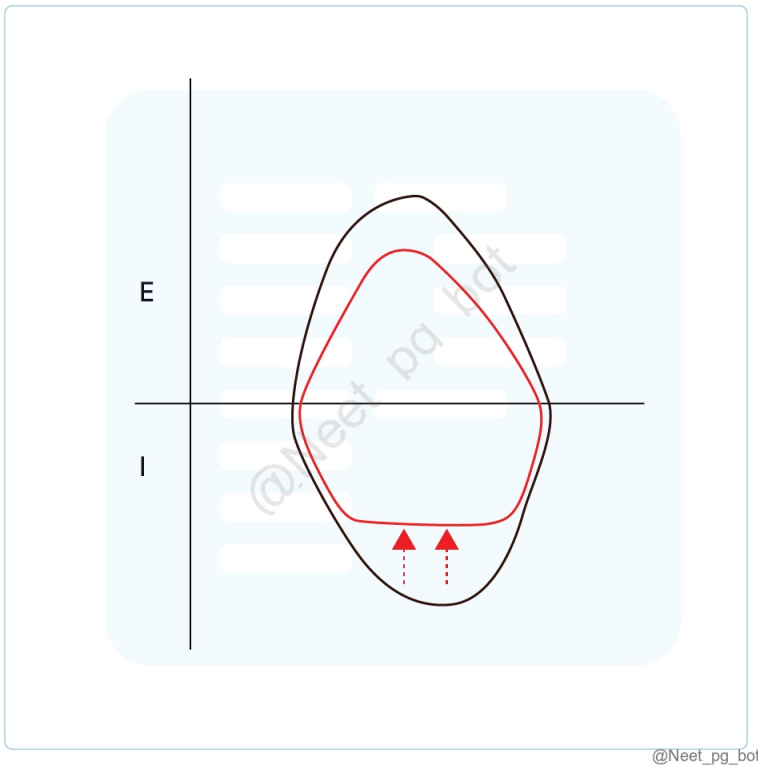

@Neet_pg_bot

Correct Answer: C. 1-b, 2-d, 3-a, 4-c

Explanation: Conditions Flow Volume Loops Normal A normal flow-volume loop displays airflow (in L/second) related to lung volume (in L) during maximal inspiration from residual volume (RV) and maximum expiration from total lung capacity (TLC). Asthma (Airflow Obstruction): Narrowed airways due to smooth muscle constriction and inflammation reduce expiratory airflow, causing a “scooped” appearance, especially at lower lung volumes. Flow may improve after bronchodilator use. Retrosternal Goiter (Extrathoracic Obstruction): Extrathoracic airway narrowing can limit inspiratory flow, causing flattening of the inspiratory portion of the loop. Intrathoracic Fixed Obstruction: Fixed airway obstruction within the chest affects both inspiration and expiration, resulting in flattened, plateaued loops on both sides of the flow-volume curve. Restrictive Airway Disorders (e.g., Pulmonary Fibrosis): High lung recoil pressure increases expiratory flow for any given lung volume, producing a loop that is shifted to lower volumes and shows high maximal flow relative to volume. Overall lung volumes (TLC, FRC) are reduced due to increased stiffness.

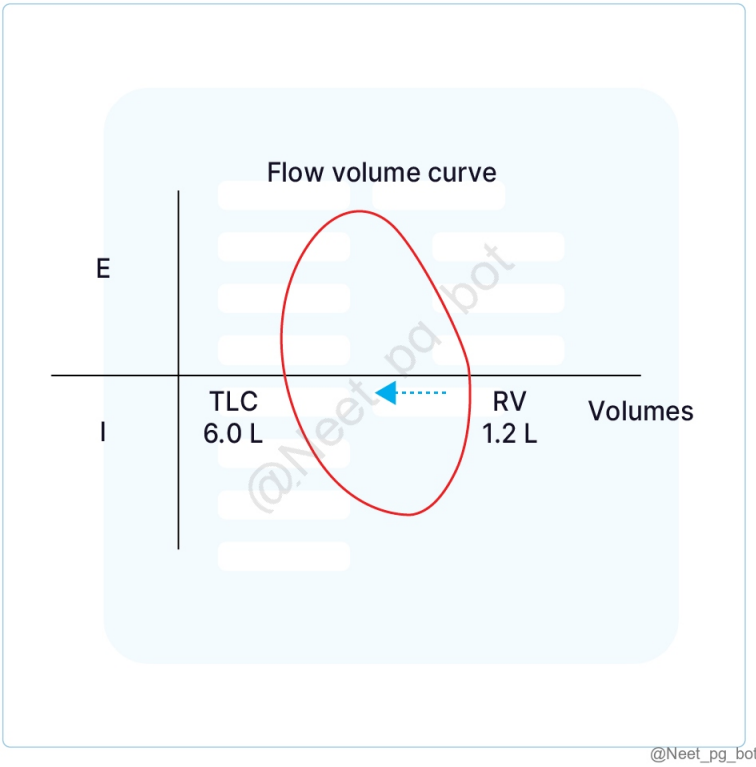

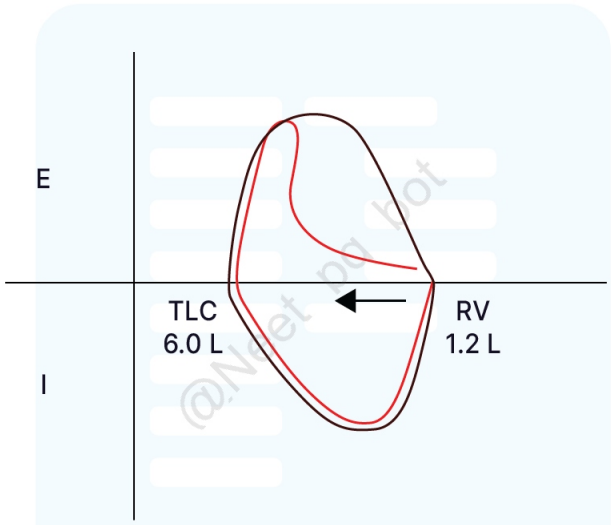

@Neet_pg_bot

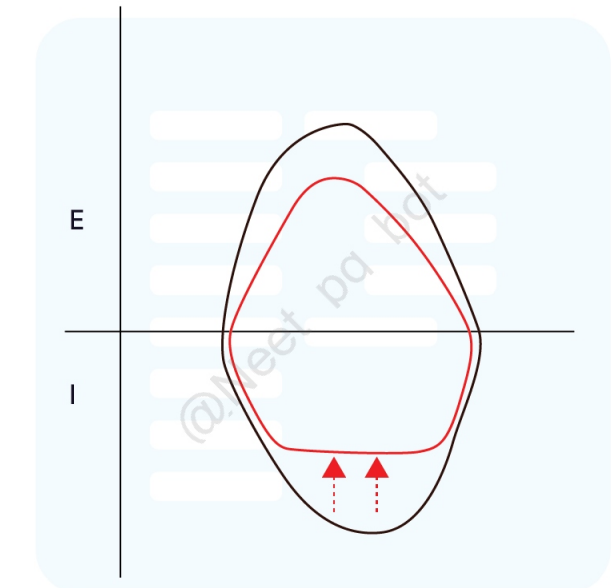

@Neet_pg_bot

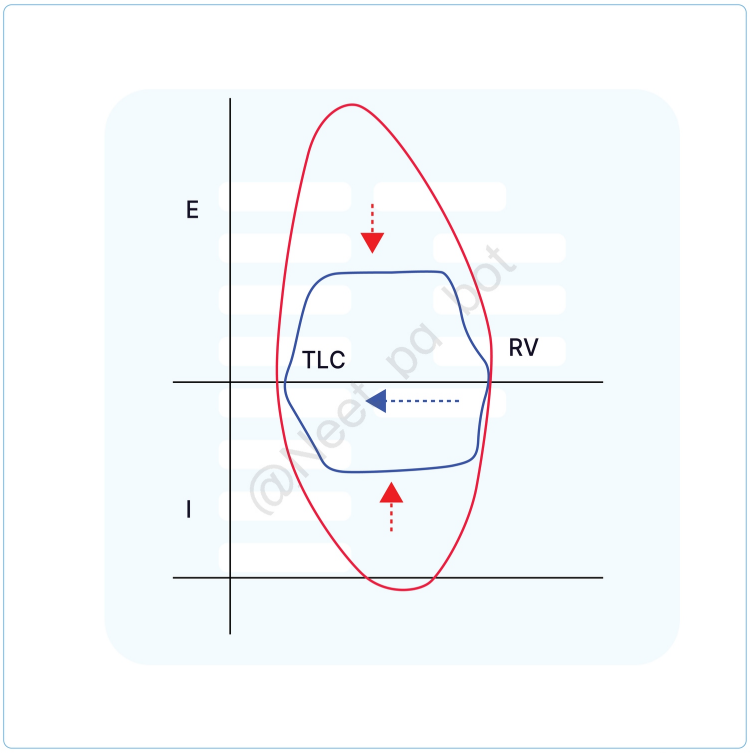

@Neet_pg_bot

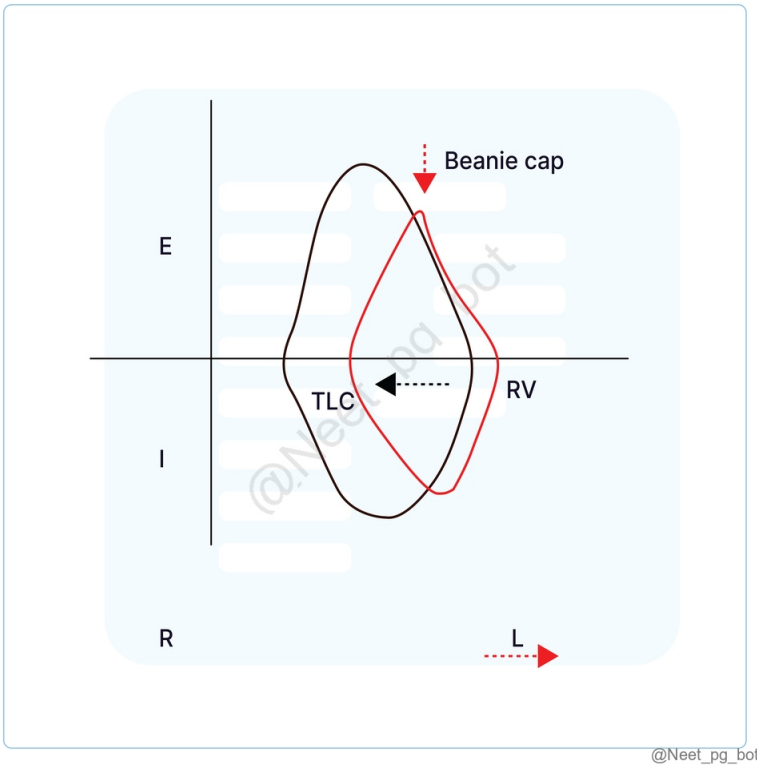

@Neet_pg_bot

References:

Harrison’s Principles of Internal Medicine, 21st Edition, Page 2135- 2138
thoracickey.com/physiology-of-fixed-airway-obstruction/

↑ *Back to this question in Part A*

@Neet_pg_bot

Q6: A 72-year-old female patient presents with progressive shortness of breath and a persistent dry cough. She has a history of pulmonary fibrosis diagnosed two years ago. Spirometry shows reduced lung volumes. Which of the following is most likely true regarding this patient’s spirometry results? (Q852147)

A. FVC is likely to be increased.

B. FEV1/FVC ratio is likely > 80%.

C. TLC is likely normal or increased.

D. RV is likely normal or increased.

Correct Answer: B. FEV1/FVC ratio is likely > 80%.

Explanation: This patient likely has restrictive lung disease due to pulmonary fibrosis, characterized by reduced lung volumes and an increased FEV1/FVC ratio on spirometry. Spirometric parameters are essential for evaluating lung function and diagnosing respiratory conditions. Restrictive Lung Disease: Decreased : Total Lung Capacity (TLC) < 80% of predicted value (Option C) Forced Vital Capacity (FVC) (Option A) FEV1 (but FVC decreases more than FEV1) (Option B) Increased : FEV1/FVC ratio > 80% RV is likely normal or increased. (Option D): RV is generally normal or decreased in restrictive lung disease.

References:

www.ncbi.nlm.nih.gov/books/NBK560526/

↑ *Back to this question in Part A*

@Neet_pg_bot

Q7: A 45 y/o man with a history of COPD presents with shortness of breath, cough, and increased sputum production. His arterial blood gas (ABG) analysis shows hypoxemia, and his calculated A-a gradient is elevated. Which of the following is the most likely cause for the elevated A-a gradient in this patient? (Q852148)

A. Ventilation-perfusion mismatch

B. Hypoventilation

C. Reduced cardiac output

D. Low-inspired oxygen (FiO2)

Correct Answer: A. Ventilation-perfusion mismatch

Explanation: COPD causes a mismatch between ventilation and blood flow in the lungs, leading to hypoxemia and an elevated A-a gradient. Alveolar-Arterial Gradient (A-a Gradient): The A-a gradient measures the difference in oxygen pressure between alveoli (PAO2) and arterial blood (PaO2). It is useful in assessing hypoxemia origins, and differentiating between alveolar-capillary unit dysfunction and extrapulmonary causes. A-a Gradient = PAO■ - PaO■ Normal A-a gradient = (Age in years + 10) / 4 Hypoventilation (Option B): Pure hypoventilation (e.g., opioid overdose, neuromuscular disease) causes hypoxemia with normal A-a gradient because alveolar PO2 falls proportionally with arterial PO2. COPD exacerbations can involve hypercapnia from hypoventilation, but the elevated A-a here points to a primary lung parenchymal/perfusion issue like V/Q mismatch. Reduced cardiac output (Option C): Low cardiac output contributes to hypoxemia via increased oxygen extraction (wider CvO2-CaO2), but it typically does not elevate A-a gradient significantly; it's more of a systemic issue. Low-inspired oxygen (FiO2) (Option D): Low FiO2 (e.g., high altitude) causes hypoxemia with normal A-a gradient, as alveolar and arterial PO2 both drop equally. This patient is likely on room air or standard O2, not hypoxic environment.

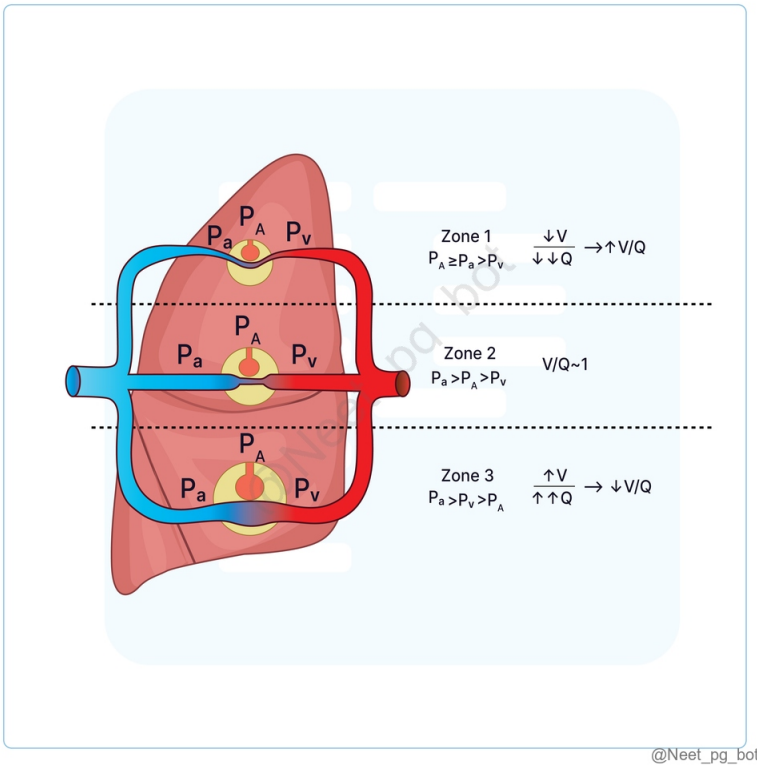

@Neet_pg_bot

References:

Harrison’s Principles of Internal Medicine, 21st Edition, Page 2133, 2137

www.ncbi.nlm.nih.gov/books/NBK545153/

www.ncbi.nlm.nih.gov/books/NBK526127/

jdc.jefferson.edu/cgi/viewcontent.cgi?article=1519&context=tmf

www.ncbi.nlm.nih.gov/books/NBK482268/

↑ *Back to this question in Part A*

@Neet_pg_bot

Q8: A 50 y/o male presents with worsening dyspnea. His pulmonary function test reveals a significant reduction in DLCO. Which of the following is the most likely cause for the low DLCO? (Q852149)

A. Pulmonary hemorrhage

B. Obesity

C. Pulmonary fibrosis

D. Acute Congestive Heart Failure

Correct Answer: C. Pulmonary fibrosis

Explanation: Pulmonary fibrosis involves scarring and thickening of the alveolar-capillary membrane , which impairs gas exchange and reduces the diffusion capacity of the lung (DLCO). It is one of the causes of low DLCO . Patients typically present with progressive dyspnea, especially on exertion, and have reduced DLCO on PFTs. Increased DLCO: Increases with increased availability of surface area and haemoglobin in capillaries Decreased DLCO: Due to the thickened or destruction of the alveolar membrane and factors affecting vasculature. Asthma Polycythemia Acute congestive heart failure (Option D) Exercise Obesity (Option B) Pulmonary haemorrhage (Option A) Altitude Bronchodilator usage Pulmonary fibrosis (Option C) Emphysema Pulmonary hypertension Anaemia COPD Bronchiolitis Cystic fibrosis Pleural effusion

References:

Harrison’s Principles of Internal Medicine, 21st Edition, Page 2139

www.ncbi.nlm.nih.gov/books/NBK556149/

↑ *Back to this question in Part A*

@Neet_pg_bot

• [10_Pulmonology] 080 Interstitial Lung Disease Pulmonary Alveolar Protienosis Pneumoconiosis

« Back to Folder Directory

[10_Pulmonology] 080 Interstitial Lung Disease Pulmonary Alveolar Protienosis Pneumoconiosis — Quick Jump

Q1 (p. 2949) *Q2 (p. 2950)* *Q3 (p. 2951)* *Q4 (p. 2952)* *Q5 (p. 2953)* *Q6 (p. 2954)*
Q7 (p. 2954) *Q8 (p. 2956)* *Q9 (p. 2957)* *Q10 (p. 2957)* *Q11 (p. 2958)* *Q12 (p. 2959)*
Q13 (p. 2960)

Q1: A 50-year-old man who has worked in the glass manufacturing industry for over 20 years presents with progressive dyspnea, a chronic dry cough, and fatigue. On examination, he has bilateral crackles on auscultation. A high-resolution CT scan reveals a crazy-paving pattern in the lungs. What is the most likely cause of his condition? (Q851836)

A. Hypersensitivity pneumonitis

B. Idiopathic pulmonary fibrosis

C. Asbestosis

D. Silicosis



Correct Answer: D. Silicosis

Explanation: Silicosis is the most likely cause, given the patient's long history of working in the glass manufacturing industry, exposing him to silica dust. Radiological features: The chest radiograph may show profuse military infiltration or consolidation, and there is a characteristic HRCT pattern known as "crazy paving" . Multiple well-circumscribed 3–5 mm nodular opacities predominantly in the mid-and upper zones. Enlargement of the hilar glands with an "egg-shell" pattern of calcification (seen in 20% of cases). As the disease progresses, progressive massive fibrosis (PMF) may develop. Hypersensitivity pneumonitis (Option A): Inhalation of various organic antigens can trigger a widespread immune complex reaction in the walls of the alveoli and bronchioles. Idiopathic pulmonary fibrosis (Option B): It is defined as a progressive fibrosing interstitial pneumonia of unknown cause, occurring in older adults. Asbestosis (Option C): Asbestos exposure commonly occurs during activities like demolition work, ship breaking, and the manufacturing of fireproof insulating materials.

References:

Harrison's Principles of Internal Medicine, 21st Edition, Page 2169, 2191

Davidson's Principles and Practice of Medicine, 24th Edition, Page 615

↑ *Back to this question in Part A*

@Neet_pg_bot

Q2: A 45-year-old man with a history of working in mining for over 20 years presents with chronic cough, shortness of breath, and fatigue. Chest X-ray reveals nodular

opacities, primarily in the upper lobes. Which of the following complications is he at an increased risk of? (Q851837)

A. Pulmonary embolism

B. Pneumothorax

C. Tuberculosis

D. Pleural effusion

Correct Answer: C. Tuberculosis

Explanation: The given clinical presentation is suggestive of Silicosis , a form of pneumoconiosis caused by the inhalation of silica dust, and is associated with an increased risk of developing tuberculosis (TB). Pulmonary embolism (Option A): It is usually associated with immobility, surgery, or hypercoagulable states , not occupational lung diseases. While anyone can develop PE, silicosis does not specifically increase the risk for PE. Pneumothorax (Option B): It is more commonly associated with diseases like emphysema, tuberculosis, or cystic lung diseases , especially when there's alveolar rupture . Silicosis doesn't commonly cause pneumothorax, so this is not a typical complication . Pleural effusion (Option D): While it can occur with various lung diseases, they are not a classic feature or complication of silicosis . Unless there's an underlying infection or malignancy, effusions are uncommon in this context.

References:

Harrison's Principles of Internal Medicine, 21st Edition, Page 2169

Davidson's Principles and Practice of Medicine, 24th Edition, Page 615

↑ *Back to this question in Part A*

@Neet_pg_bot

Q3: A 70-year-old retired shipyard worker presents with exertional dyspnea and a persistent dry cough. Pulmonary function tests reveal a restrictive pattern. Which of the following radiographic findings is most characteristic of asbestosis? (Q851838)

A. Upper lobe nodular opacities

B. Cavitary lesions

C. Bilateral pleural plaques

D. Hyperinflated lungs

Correct Answer: C. Bilateral pleural plaques

Explanation: Workers in the shipbuilding and construction trades, including pipe fitters and boilermakers, are occupationally exposed to asbestos. Asbestosis is a diffuse interstitial fibrosing disease of the lung . Past exposure to asbestos is specifically indicated by pleural plaques on chest radiographs, which are characterized by either thickening or calcification along the parietal pleura, particularly along the lower lung fields. Pulmonary function testing in asbestosis reveals a restrictive pattern with a decrease in both lung volumes and diffusing capacity. Complications include carcinoma of lung and mesothelioma . Upper lobe nodular opacities (Option A): These suggest silicosis or coal worker's pneumoconiosis (upper lobe predominant), not asbestosis which favors lower lobe reticular/subpleural fibrosis. Cavitary lesions (Option B): Cavitation indicates necrosis (e.g., TB, fungal, or necrotizing pneumonia), absent in asbestosis which shows fibrosis without cavities.■ Hyperinflated lungs (Option D): Hyperinflation signals obstructive disease (COPD/emphysema), while asbestosis causes restrictive physiology with normal/small lung volumes.

References:

Harrison’s Principles of Internal Medicine, 21st Edition, Page 2168

Davidson’s Principles and Practice of Medicine, 24th Edition, Page 615

↑ *Back to this question in Part A*

@Neet_pg_bot

Q4: A 45-year-old man with a long history of smoking presents with worsening dyspnea and a recent diagnosis of lung cancer. A lung biopsy reveals changes consistent with interstitial lung disease. Which type of ILD is most commonly associated with smoking? (Q851839)

A. Lymphangioleiomyomatosis

B. Lymphocytic interstitial pneumonitis

C. Pulmonary Alveolar Proteinosis

D. Langerhans cell histiocytosis

Correct Answer: D. Langerhans cell histiocytosis

Explanation: Langerhans cell histiocytosis is a rare disorder caused by Langerhans cell proliferation, leading to lung involvement, especially in smokers. It commonly affects young males with cystic and nodular abnormalities in the upper lobes. Lesions extend to broncho-vascular structures, forming characteristic stellate lesions, and there is an increased risk of spontaneous pneumothorax. Other Conditions Causing Smoking Related ILD Respiratory bronchiolitis with ILD (RB-ILD) Desquamative interstitial pneumonia (DIP) Lymphangioleiomyomatosis (Option A) is a rare lung disease primarily affecting women of childbearing age , characterised by cystic changes on HRCT; however, it is not usually associated with smoking. Lymphocytic interstitial pneumonitis (Option B) is often linked to autoimmune disorders or infections, particularly in immunocompromised individuals, rather than smoking. Pulmonary Alveolar Proteinosis (Option C): It can be associated with autoimmune diseases, secondary

conditions, or toxin exposure but is not primarily linked to smoking.

References:

Harrison’s Principles of Internal Medicine, 21st Edition, Page 2190, 294, 2195

www.uptodate.com/contents/lymphoid-interstitial-pneumonia

↑ *Back to this question in Part A*

@Neet_pg_bot

Q5: A 42-year-old woman presents with worsening asthma, shortness of breath, and wheezing. She has a history of recurrent sinusitis and recent purpuric skin lesions on her legs. Lab tests show eosinophilia and positive p-ANCA. A chest CT reveals ground-glass opacities and lower lobe consolidation. What is the most likely diagnosis? (Q851840)

A. Wegener Granulomatosis

B. Sarcoidosis

C. Hypersensitivity pneumonia

D. Churg Strauss Syndrome

Correct Answer: D. Churg Strauss Syndrome

Explanation: Churg Strauss Syndrome , called Eosinophilic granulomatosis with polyangiitis (EG), is a small-medium vessel vasculitis. It often presents with respiratory symptoms like chronic sinusitis, asthma, peripheral eosinophilia, and positive perinuclear ANCA antibodies. Imaging reveals peripheral consolidative opacities (can be migratory) and small pleural effusions in the lungs. It is an example of granulomatous vasculitis causing ILD ; another example is Wegener Granulomatosis (Granulomatosis with polyangiitis). Wegener Granulomatosis (Option A) It commonly affects the ear, nose, throat, and kidneys, presenting with upper respiratory symptoms, pulmonary nodules, and renal dysfunction (glomerulonephritis). Imaging often shows nodules, ground-glass opacities, consolidations (sometimes migratory), and hilar lymphadenopathy. Hemoptysis is a common feature, as seen in both Wegener's granulomatosis (c-ANCA positive) and Churg-Strauss syndrome (p-ANCA positive), which also involves multiple organs. Sarcoidosis (Option B): It is a granulomatous lung disease without vasculitis. It is an inflammatory condition marked by granuloma formation, primarily affecting the lungs but sometimes involving the eyes or skin. It typically presents with bilateral hilar lymphadenopathy and pulmonary infiltrates, causing cough and dyspnea. Hypersensitivity pneumonia (Option C) It is caused by an immune reaction to inhaled triggers such as barn hay (Farmer's lung), sugar cane dust (Bagassosis), or cotton dust (Byssinosis). It involves an immune response to inhaled organic antigens, forming granulomas in the lung tissue (granulomatous lung disease). Symptoms resolve when the trigger is removed, but repeated exposure can lead to pulmonary fibrosis.

References:

Harrison’s Principles of Internal Medicine, 21st Edition, Page 2196

↑ *Back to this question in Part A*

@Neet_pg_bot

Q6: A 55-year-old man presents with worsening dyspnea on exertion and a dry cough. Examination reveals finger clubbing. Which findings might be observed during an interstitial lung disease (ILD) evaluation? Wheeze Inspiratory crackles Dullness to percussion Pigeon Breeder's Lung Increased tactile fremitus (Q851841)

A. 1,3,5

B. 2,3,4

C. 3,4,5

D. 1,2,4

Correct Answer: D. 1,2,4

Explanation: Clinical signs and symptoms of ILD Pigeon Breeder's Lung Seen in occupational history and hypersensitivity pneumonitis Examination Findings Bilateral inspiratory crackles are heard at the base of the lungs Wheeze can be appreciated in conditions like sarcoidosis , Hypersensitivity pneumonitis and Churg Strauss Syndrome. Dullness to percussion (Statement 3) occurs due to increased density or fluid in the lung or pleural space , disrupting normal resonance. While associated with pleural effusion, consolidation, or masses , it is generally not seen in interstitial lung disease, which involves thickening and scarring of lung tissue rather than fluid accumulation . Increased tactile fremitus (Statement 5) is not true because tactile fremitus is usually decreased in ILD due to thickened interstitial tissue and reduced lung compliance, leading to impaired vibration conduction.

References:

Harrison’s Principles of Internal Medicine, 21st Edition, Page 2190, 2191, 2192

↑ *Back to this question in Part A*

@Neet_pg_bot

Q7: A 55-year-old male presents with a 6-week history of cough, dyspnea, fever, and fatigue. Respiratory examination reveals inspiratory rales and pulmonary function tests reveal restrictive lung features. HRCT of the thorax shows patchy subpleural

consolidative opacities with a ground-glass appearance and a reversed halo sign. A lung biopsy shows a uniform appearance of granulation tissue within the alveolar sac. What is the most likely diagnosis? (Q851842)

A. Atypical pneumonia

B. Cryptogenic organising pneumonia

C. Interstitial pulmonary fibrosis

D. Acute respiratory distress syndrome

Correct Answer: B. Cryptogenic organising pneumonia

Explanation: The patient's subacute clinical presentation, HRCT findings, and lung biopsy showing granulation tissue within alveolar sacs indicate Cryptogenic organising pneumonia. Cryptogenic Organising Pneumonia Clinical features Patients are usually 50-60 years of age Subacute onset with symptoms like cough, fever, malaise, fatigue and dyspnea. Respiratory examination: Inspiratory rales Investigations Pulmonary function tests: Restrictive lung deficits + hypoxemia HRCT thorax Patchy subpleural consolidative opacities Localised ground glass opacities Reversed halo sign - rim of subpleural sparing HPE: Patchy region of organising pneumonia with the uniform appearance of granulation tissue Atypical pneumonia (Option A) is caused by Mycoplasma, Chlamydia, and Legionella, with an insidious onset and non-specific symptoms like fever, headache, dry cough, myalgia, and malaise. Chest imaging may show diffuse or patchy infiltrates, but the reversed halo sign is absent. Interstitial pulmonary fibrosis (Option C) is a chronic, progressive, non-reversible lung disease characterised by fibrosis and scarring of the lung parenchyma. It presents with exertional dyspnea and a chronic dry cough. HRCT reveals reticular opacities, honeycombing, and traction bronchiectasis, particularly in the lung bases. Histopathology shows interstitial fibrosis. Acute respiratory distress syndrome (Option D) is a life-threatening lung condition triggered by severe infections, trauma, or systemic insults. It presents with sudden respiratory failure and hypoxemia. Chest imaging typically shows diffuse bilateral infiltrates or ground-glass opacities.

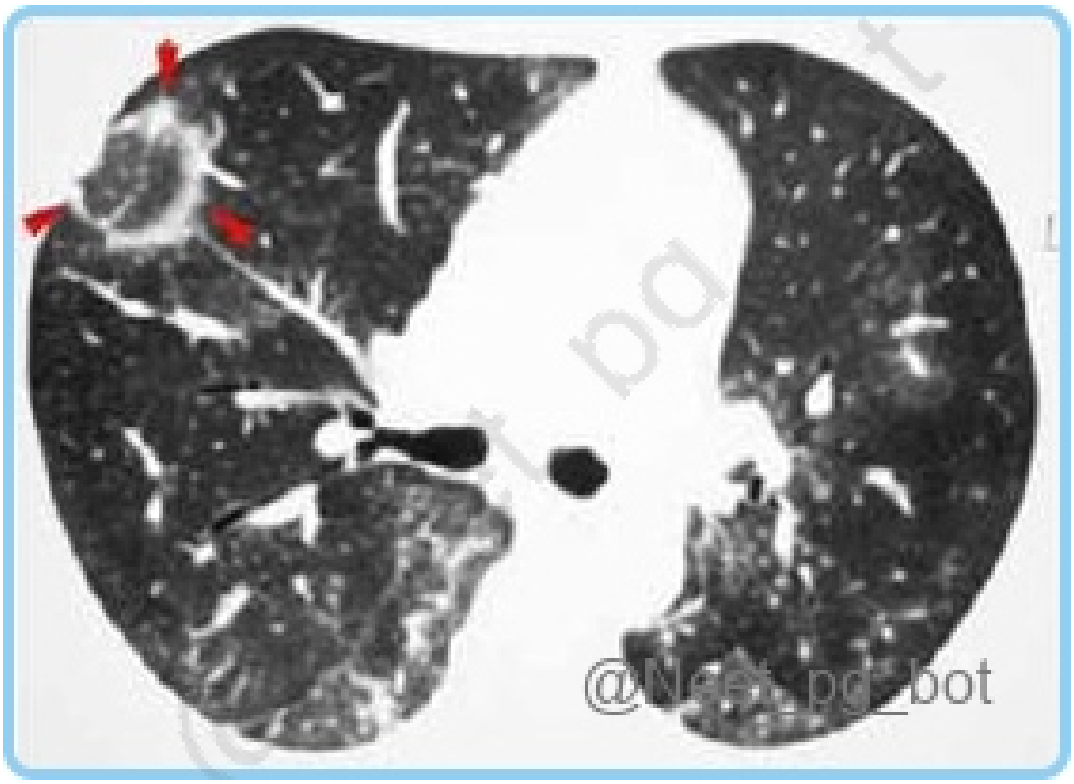

References:

Harrison’s Principles of Internal Medicine, 21st Edition, Page 2195

www.ncbi.nlm.nih.gov/books/NBK507874/

↑ *Back to this question in Part A*

@Neet_pg_bot

Q8: Match the following types of hypersensitivity pneumonitis with their respective causative antigen. Disease Antigen 1. Farmer’s lungs A. Mycobacterium Avium complex 2. Tobacco grower’s lungs B. Isocyanates 3. Hot tub lungs C. Thermophilic actinomyces 4. Chemical worker lungs D. Penicillium casei 5. Cheese washer’s lungs E. Aspergillus clavatus (Q851843)

A. 1-E, 2-A, 3-D, 4-C, 5-B

B. 1-C, 2-E, 3-A, 4-B, 5-D

C. 1-D, 2-C, 3-B, 4-E, 5-A

D. 1-A, 2-B, 3-E, 4-D, 5-C

Correct Answer: B. 1-C, 2-E, 3-A, 4-B, 5-D

Explanation: Hypersensitivity pneumonitis can be caused by several potential inhaled antigens, such as Disease Antigen 1. Farmer's lungs Thermophilic actinomyces 2. Tobacco grower's lungs Aspergillus clavatus 3. Hot tub lungs Mycobacterium Avium complex 4. Chemical worker lungs Isocyanates 5. Cheese washer's lungs Penicillium casei

References:

Harrison's Principles of Internal Medicine, 21st Edition, Page 2160

↑ *Back to this question in Part A*

@Neet_pg_bot

Q9: A 60-year-old male with a history of smoking presents with progressively worsening dyspnea and a non-productive cough for the past 6 months. HRCT findings, including subpleural reticulation, honeycombing, and traction bronchiectasis, suggest idiopathic pulmonary fibrosis (IPF). What is the treatment of choice for this condition? (Q851844)

A. Monotherapy with Corticosteroid

B. Pirfenidone + Nintedanib

C. Prednisolone + Rituximab

D. Lung transplantation

Correct Answer: B. Pirfenidone + Nintedanib

Explanation: Pirfenidone + Nintedanib, an antifibrotic therapy used to slow the decline in pulmonary function, is the treatment of choice in idiopathic pulmonary fibrosis. Disease Treatment Idiopathic pulmonary fibrosis Pirfenidone + Nintedanib (Option B) Nonspecific interstitial pneumonitis Prednisolone + cyclophosphamide or rituximab (Option C) Lung transplantation (Option D) was once the only treatment option for idiopathic pulmonary fibrosis (IPF).

References:

Harrison's Principles of Internal Medicine, 21st Edition, Page 2193, 2194, 2195

↑ *Back to this question in Part A*

@Neet_pg_bot

Q10: A 62-year-old woman with a history of progressive dyspnea and a chronic dry cough is being evaluated for suspected interstitial lung disease (ILD). She denies any history of smoking or exposure to environmental toxins. Physical examination reveals fine bibasilar inspiratory crackles. Which of the following is the investigation of choice for confirming the diagnosis? (Q851845)

A. Pulmonary function test

B. Bronchoalveolar lavage

C. Fiberoptic bronchoscopy with cryo biopsy

D. HRCT of thorax

Correct Answer: C. Fiberoptic bronchoscopy with cryo biopsy

Explanation: Fiberoptic bronchoscopy With Cryobiopsy: Investigation of choice to confirm diagnosis of interstitial lung disease. (Option C) With Bronchoalveolar lavage: can be helpful for cellular examination (Option B) Pulmonary Function Tests (Option A): Helps differentiate between obstructive and restrictive lung disease but cannot confirm the diagnosis of interstitial lung disease HRCT (Option D) : Can suggest the type and degree of lung pathology but cannot confirm it.

References:

Harrison's Principles of Internal Medicine, 21st Edition, Page 2192

↑ *Back to this question in Part A*

@Neet_pg_bot

Q11: A 59-year-old man presents with recurrent cough, dyspnea, and fatigue for 8 months. His occupation as a bird breeder with exposure to bird droppings suggests hypersensitivity pneumonitis. Pulmonary function testing (PFT) reveals a restrictive pattern. Which of the following disorders should be considered in the differential diagnosis based on the PFT restrictive pattern? (Q851846)

A. COPD

B. Idiopathic interstitial pneumonia

C. Asthma

D. Bronchiectasis

Correct Answer: B. Idiopathic interstitial pneumonia

Explanation: Idiopathic interstitial pneumonia shows a restrictive pattern on PFT, similar to hypersensitivity pneumonitis, with reduced lung volumes and preserved or increased FEV1/FVC ratio due to fibrosis. Disorder Pulmonary function test Hypersensitivity pneumonitis Restrictive pattern Total lung capacity ↓ FEV1/FVC is normal or ↑ Idiopathic interstitial pneumonia (Option B) Initially Only diffusion is impaired; thus, DLCO is reduced Normal FVC and FEV As diseases progresses Restrictive pattern Total lung capacity ↓ due to lung fibrosis FEV1/FVC is normal, or ↑ a reduction in FVC is proportionally greater than a fall in FEV1. COPD (Option A) Obstructive pattern. Total lung capacity ↑ due to trapping of air - lung hyperinflation. FEV1/FVC ↓ due to significant air outflow obstruction. Bronchiectasis (Option D) Obstructive pattern. Total lung capacity ↑ is due to the trapping of air. FEV1/FVC ↓ due to significant air outflow obstruction due to mucus plugging. Asthma (Option C) Obstructive pattern Total lung capacity ↑ due to trapping of air FEV1/FVC ↓ due to significant air outflow obstruction Peak expiratory flow rate ↓ It is reversible with bronchodilator use

References:

Harrison's Principles of Internal Medicine, 21st Edition, Page no. 2138, 2154, 2182, 2192

www.ncbi.nlm.nih.gov/books/NBK482339/

↑ *Back to this question in Part A*

@Neet_pg_bot

Q12: A 50-year-old woman presents with worsening shortness of breath and cough, producing copious sputum containing gelatinous material. Laboratory tests reveal no evidence of infectious processes. The physician suspects pulmonary alveolar proteinosis. Which mechanism is most responsible for her condition? (Q851847)

A. Deficiency of surfactant proteins due to genetic mutation

B. Autoimmune response leading to GM-CSF blockade

C. Exposure to silica dust causing alveolar damage

D. Allergic reaction to environmental pollutants

Correct Answer: B. Autoimmune response leading to GM-CSF blockade

Explanation: In pulmonary alveolar proteinosis (PAP), autoantibodies against GM-CSF impair the function of alveolar macrophages, preventing them from clearing surfactant and leading to its accumulation in the lungs, resulting in the patient's symptoms. Deficiency of surfactant proteins due to genetic mutation (Option A): While genetic mutations (such as in the SFTPB or SFTPC genes) can cause PAP, this is almost exclusively seen in neonates and infants . It leads to surfactant dysfunction and respiratory failure shortly after birth. In a 50-year-old patient, a primary genetic protein deficiency is highly unlikely. Exposure to silica dust causing alveolar damage (Option C): Secondary PAP can occur with silica or other dusts (inhalation), but requires documented heavy

exposure history; this is less common than autoimmune PAP and typically has additional findings. Allergic reaction to environmental pollutants (Option D): While environmental pollutants can trigger asthma or hypersensitivity pneumonitis, they do not cause the specific accumulation of surfactant proteins seen in PAP.

References:

Robbins & Cotran Pathologic Basis of Diseases, 10th Edition, Page 700

www.ncbi.nlm.nih.gov/books/NBK482308/

↑ *Back to this question in Part A*

@Neet_pg_bot

Q13: A 52-year-old male presents with progressive dyspnea and a chronic cough with gelatinous sputum. Pulmonary function tests show a restrictive pattern and a normal FEV1/FVC ratio. A chest X-ray reveals bilateral patchy opacifications and a high-resolution CT shows a crazy paving pattern with no signs of infection. What is the most characteristic finding of this condition? (Q851848)

A. Increased neutrophilic infiltration

B. Positive Periodic Acid-Schiff (PAS) staining

C. Granuloma formation

D. Honeycombing fibrosis

Correct Answer: B. Positive Periodic Acid-Schiff (PAS) staining

Explanation: The given clinical scenario, with patchy opacifications, a crazy paving pattern, restrictive findings, and a cough with gelatinous sputum without signs of infection, most probably indicates Pulmonary Alveolar Proteinosis. The most characteristic finding is positive PAS staining, which indicates the presence of surfactant components in the alveolar spaces. Increased neutrophilic infiltration (Option A) is more characteristic of acute inflammatory processes, such as infections, than PAP, which typically shows a minimal inflammatory response. Granuloma formation (Option C) indicates conditions like sarcoidosis or infections like TB and is not a feature of PAP. Honeycombing fibrosis (Option D) is associated with advanced interstitial lung diseases, such as idiopathic pulmonary fibrosis, rather than the surfactant accumulation seen in PAP.

References:

Harrison’s Principles of Internal Medicine, 21st Edition, Page 2169 Davidson’s Principles and Practice of Medicine, 24th Edition, Page 613

↑ *Back to this question in Part A*

@Neet_pg_bot

• [10_Pulmonology] 081 Pleural Effusion And Pneumothorax

« Back to Folder Directory

[10_Pulmonology] 081 Pleural Effusion And Pneumothorax — Quick Jump

Q1 (p. 2962) *Q2 (p. 2964)* *Q3 (p. 2964)* *Q4 (p. 2965)* *Q5 (p. 2966)* *Q6 (p. 2967)*
Q7 (p. 2967) *Q8 (p. 2968)* *Q9 (p. 2971)* *Q10 (p. 2973)* *Q11 (p. 2974)* *Q12 (p. 2975)*
Q13 (p. 2976) *Q14 (p. 2976)* *Q15 (p. 2977)* *Q16 (p. 2978)* *Q17 (p. 2979)*

Q1: A 35-year-old male presents with fever, left-sided chest pain, and dyspnea. Upon physical examination, decreased breath sounds are noted on the left side. A chest X-ray reveals the findings presented below. A thoracentesis is performed, yielding a milky white fluid with elevated lactate dehydrogenase (LDH) and the presence of cholesterol crystals. Considering these findings, what underlying agent could be responsible for this presentation? (Q851878)

A. Pneumococcus

B. Staphylococcus aureus

C. Malignancy

D. Mycobacterium tuberculosis

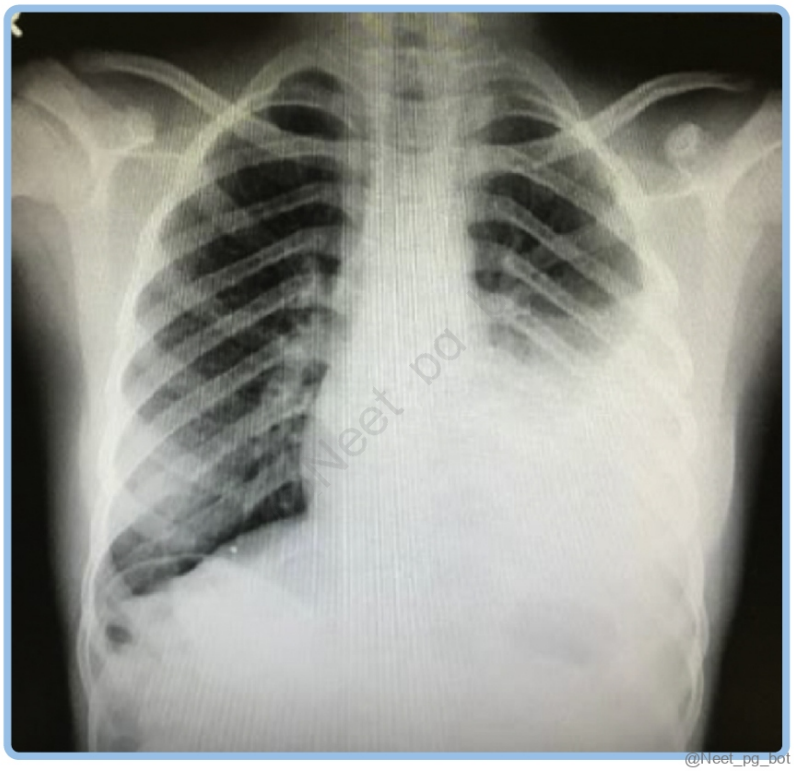

Correct Answer: D. Mycobacterium tuberculosis

Explanation: This clinical scenario suggests a case of pleural effusion , likely exudative in nature, characterized by symptoms of fever, chest pain, and dyspnea, along with diminished breath sounds on the left side. A chest X-ray confirms a significant left-sided pleural effusion. Pleural fluid analysis reveals elevated lactate dehydrogenase (LDH) levels and the presence of cholesterol crystals, indicative of pseudo chylothorax . This condition is often associated with tuberculosis (caused by Mycobacterium tuberculosis). Pneumococcus (Option A): Typically causes an acute parapneumonic effusion or empyema , which is purulent and not milky. Pneumococcal effusions are often neutrophil-predominant and occur rapidly with pneumonia - less likely to show cholesterol crystals or be chronic. Staphylococcus aureus (Option B): Another cause of empyema , usually from post-pneumonic infections, especially in children or hospitalized patients. Like pneumococcus, it causes acute pus-filled effusions, not the chronic, milky fluid seen in pseudochylothorax. Malignancy (Option C): Can cause chylothorax , which may appear milky, but that is due to triglyceride-rich lymphatic fluid , not cholesterol. Also, cholesterol crystals are not typically found in malignant effusions.

References:

Harrison's principles of internal medicine, 21st Edition, Page: 2198,2199.

Davidson's principles and practice of medicine, 24th Edition, Page: 563.

Robbins & Cotran Pathologic Basis of Disease, 10th Edition, Page:

www.ncbi.nlm.nih.gov/books/NBK448189/

↑ *Back to this question in Part A*

@Neet_pg_bot

Q2: Match the ABG values in Column A with their corresponding acid-base disorders in Column B. Column A Column B 1. pH 7.48, pCO2 45, HCO3 35 A. Fully compensated respiratory acidosis 2. pH 7.32, pCO2 28, HCO3 14 B. Partially compensated metabolic alkalosis 3. pH 7.40, pCO2 30, HCO3 20 C. Partially compensated metabolic acidosis 4. pH 7.38, pCO2 68, HCO3 32 D. Fully compensated respiratory alkalosis (Q851993)

A. 1-B, 2-C, 3-D, 4-A

B. 1-C, 2-B, 3-A, 4-D

C. 1-A, 2-D, 3-C, 4-B

D. 1-D, 2-A, 3-B, 4-C

Correct Answer: A. 1-B, 2-C, 3-D, 4-A

Explanation: ABG Values Disorder

References:

Harrison’s Principles Of Internal Medicine, 21st Edition, Volume I, Page. 359-368.

↑ *Back to this question in Part A*

@Neet_pg_bot

Q3: A 35-year-old male presents with severe substernal chest pain, difficulty breathing, and puffy swelling of the chest wall after multiple episodes of vomiting due to binge drinking. Upon examination, auscultation reveals a characteristic crunching sound. A chest X-ray demonstrates the presence of subcutaneous emphysema. Based on the clinical presentation, what is the next best step in managing this patient? (Q851890)

A. Administer intravenous antibiotics

B. Perform an urgent thoracotomy

C. Provide supplemental oxygen

D. Obtain a CT scan of the chest

Correct Answer: B. Perform an urgent thoracotomy

Explanation: This patient's presentation suggests oesophagal rupture (Boerhaave syndrome), indicated by severe chest pain, respiratory distress, subcutaneous emphysema, and Hamman's sign (crunching sound). The presence of pneumomediastinum and respiratory distress aligns with Mackler's triad. Immediate surgical intervention via urgent thoracotomy is necessary to prevent complications like mediastinitis and sepsis. Administer intravenous antibiotics (Option A): Antibiotics should be started, but definitive surgical repair is the priority . Provide supplemental oxygen (Option C): This is supportive care and may relieve hypoxia, but it does not address the underlying perforation or prevent complications like mediastinitis or sepsis. Obtain a CT scan of the chest (Option D): The presentation is classic and diagnosis is obvious , surgical exploration should not be delayed for confirmatory imaging— "time is tissue" in Boerhaave syndrome.

References:

Harrison's principles of internal medicine, 21st Edition, Page 2201,2433

Davidson's principles and practice of medicine, 24th Edition, Page 797

Robbins & Cotran Pathologic Basis of Disease, 10th Edition, Page 758

↑ *Back to this question in Part A*

@Neet_pg_bot

Q4: A 35-year-old male presents to the emergency department after experiencing sudden chest pain and shortness of breath. He is a long-time smoker with no history of lung disease. A chest X-ray confirms a right-sided pneumothorax. Which type of pneumothorax is this patient most likely experiencing? (Q851889)

A. Secondary spontaneous pneumothorax

B. Traumatic pneumothorax

C. Primary spontaneous pneumothorax

D. Tension pneumothorax

Correct Answer: C. Primary spontaneous pneumothorax

Explanation: Primary spontaneous pneumothorax occurs without underlying lung disease , usually from rupture of apical blebs , and is common in young smokers . Types of Pneumothorax: Primary spontaneous pneumothorax: Occurs without underlying lung disease Caused by rupture of apical blebs (common in smokers) Treated with simple aspiration; thoracoscopy if recurrent Secondary spontaneous pneumothorax (Option A): Occurs in patients with underlying lung disease (e.g., COPD) More severe due to reduced pulmonary reserve Managed with tube

thoracostomy; pleurodesis if needed Traumatic pneumothorax (Option B): Due to chest trauma or iatrogenic injury May be associated with hemopneumothorax Requires tube thoracostomy (dual tubes if hemopneumothorax) Tension pneumothorax (Option D): Caused by trauma leading to high intrapleural pressure and hemodynamic compromise Emergency management: needle decompression → chest tube placement

References:

Harrison's Principles of Internal Medicine, 21st Edition, Page 2200

↑ *Back to this question in Part A*

@Neet_pg_bot

Q5: A 55-year-old female with a history of COPD presents to the emergency department with sudden onset left-sided chest pain. A chest X-ray reveals a small left-sided pneumothorax with a depth of 0.5 cm. The patient is otherwise stable, with no significant respiratory distress and a normal vital sign profile. What is the most appropriate management for this patient? (Q851887)

A. Administer high-flow oxygen and observe for 24 hours

B. Perform needle aspiration

C. Discharge with follow-up in 2-4 weeks

D. Thoracoscopy with pleural abrasion

Correct Answer: A. Administer high-flow oxygen and observe for 24 hours

Explanation: In this case, the secondary pneumothorax is small and has only mild symptoms but no dyspnea; hence, the best treatment modality is to administer high-flow oxygen and observe for 24 hours . Secondary pneumothoraces are only treated conservatively if the size is very small (1 cm or less air rim) and there are limited symptoms. Oxygen given at a high flow rate may accelerate resorption as much as fourfold. Perform needle aspiration (Option B) is usually reserved for larger or symptomatic pneumothoraces. Discharge with follow-up in 2–4 weeks (Option C) without observation may miss progression. Thoracoscopy with pleural abrasion (Option D) is reserved for recurrent or persistent pneumothorax, not initial small episodes.

References:

Harrison's Principles of Internal Medicine, 21st edition, Page: 2200.

https://www.ncbi.nlm.nih.gov/books/NBK441885/

↑ *Back to this question in Part A*

@Neet_pg_bot

Q6: A 28-year-old male presents to the emergency department after a motorcycle accident. He is experiencing severe shortness of breath and sharp left-sided chest pain. On examination, he has tachycardia and low oxygen saturation. A chest X-ray confirms a large left-sided pneumothorax. Vitals are HR: 120 bpm, BP: 70/40. What would be the most appropriate first step in the management of this patient? (Q851886)

A. Insert a thoracostomy tube

B. Administer supplemental oxygen

C. Perform needle decompression

D. Schedule video-assisted thoracoscopic surgery (VATS)

Correct Answer: C. Perform needle decompression

Explanation: The first step in managing a pneumothorax is the insertion of a wide-bore needle in the 2nd intercostal space to evacuate the air, especially in a tension pneumothorax, which is considered an emergency. Insert a thoracostomy tube (Option A) is definitive management but only after needle decompression stabilizes the patient. Administer supplemental oxygen (Option B) helps but does not relieve life-threatening pressure buildup. Schedule VATS (Option D) is not an emergency step and is reserved for recurrent or complicated pneumothorax.

References:

Harrison's Principles of Internal Medicine, 21st edition, Page: 2200.

https://www.ncbi.nlm.nih.gov/books/NBK441885/

https://pmc.ncbi.nlm.nih.gov/articles/PMC4771244/

https://pmc.ncbi.nlm.nih.gov/articles/PMC4356865/

↑ *Back to this question in Part A*

@Neet_pg_bot

Q7: A patient with chest pain and shortness of breath with a heart rate of 145 beats per minute is being examined in the casualty. Which of the following clinical features is not seen in a pneumothorax? (Q851885)

A. Absent breath sounds

B. Hamman's sign

C. Jugular venous distension

D. Hypotension

Correct Answer: B. Hamman’s sign

Explanation: Hamman’s sign is a crunching/clicking sound heard over the precordium synchronous with the heartbeat , and it occurs in pneumomediastinum , not pneumothorax. Absent breath sounds (Option A) are a classical finding in pneumothorax due to collapsed lung. Jugular venous distension (Option C) can occur in tension pneumothorax from impaired venous return. Hypotension (Option D) is seen in tension pneumothorax due to obstructive shock.

References:

Harrison’s Principles of Internal Medicine, 21st Edition, Page 2200

Hartmann’s sign

SRB's Manual of Surgery, 6th Edition, Page 793

↑ *Back to this question in Part A*

@Neet_pg_bot

Q8: A child was brought to the hospital with noticeable difficulty in breathing. On examination, he has tachycardia, tachypnea, and asymmetrical lung expansion. A supine chest X-ray is taken and shown below. Identify the marked sign/structure in this patient's chest radiograph. (Q851883)

A. Collapsed lung

B. Visceral pleura

C. Hemidiapraghm depression

D. Deep sulcus sign

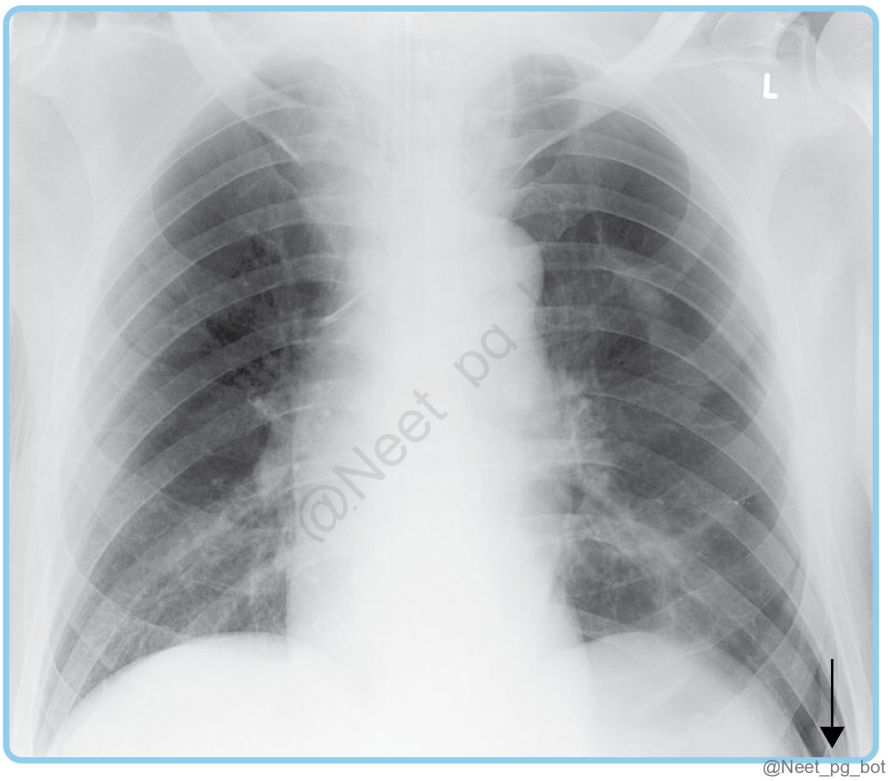

Correct Answer: D. Deep sulcus sign

Explanation: The diagnosis here is left-sided pneumothorax as per the chest radiograph and clinical symptoms where the arrow points to the deep costophrenic angle called the “ deep sulcus sign ”. Visible visceral pleural edge (Option B) as a thin white line. Absent lung markings peripheral to this line. The affected side is radiolucent compared to the opposite side. Collapsed lung (Option A) on the affected side. The diaphragm of the affected side is pushed down. (Option C)

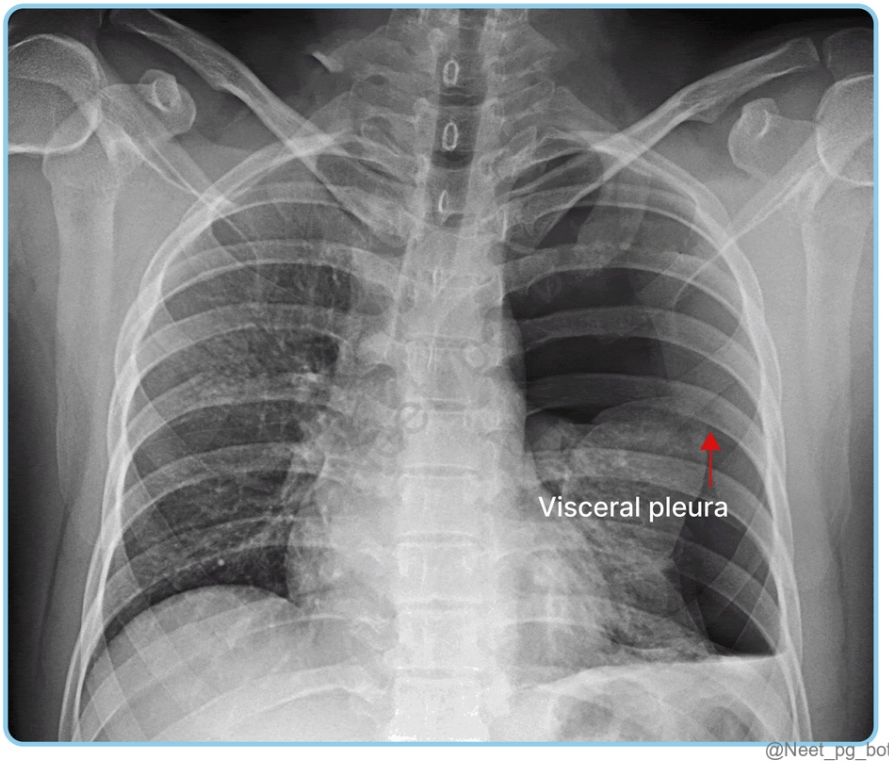

@Neet_pg_bot

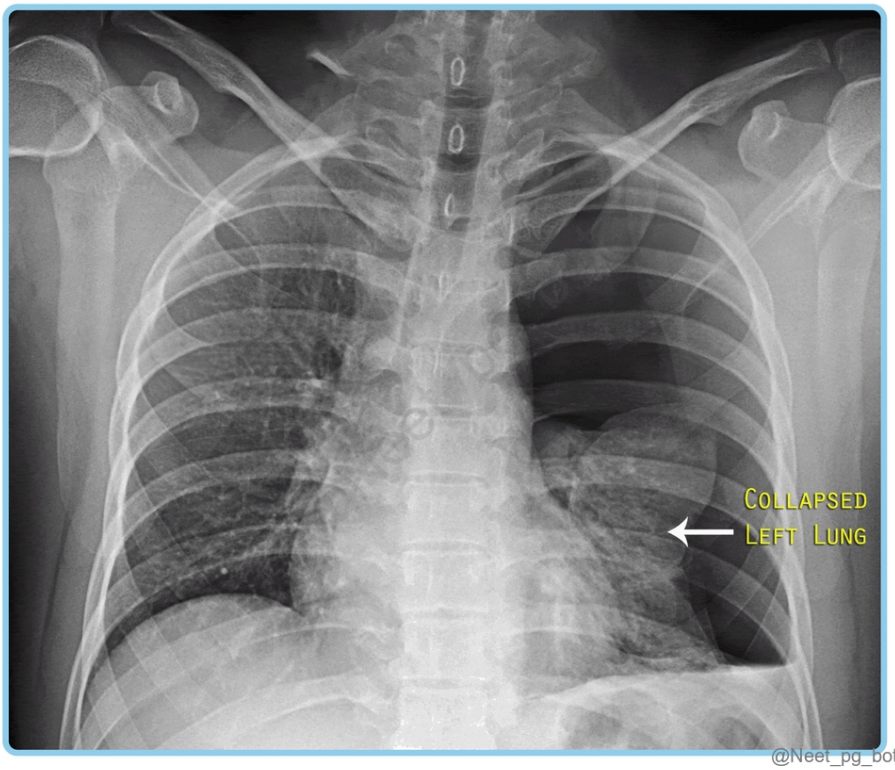

@Neet_pg_bot

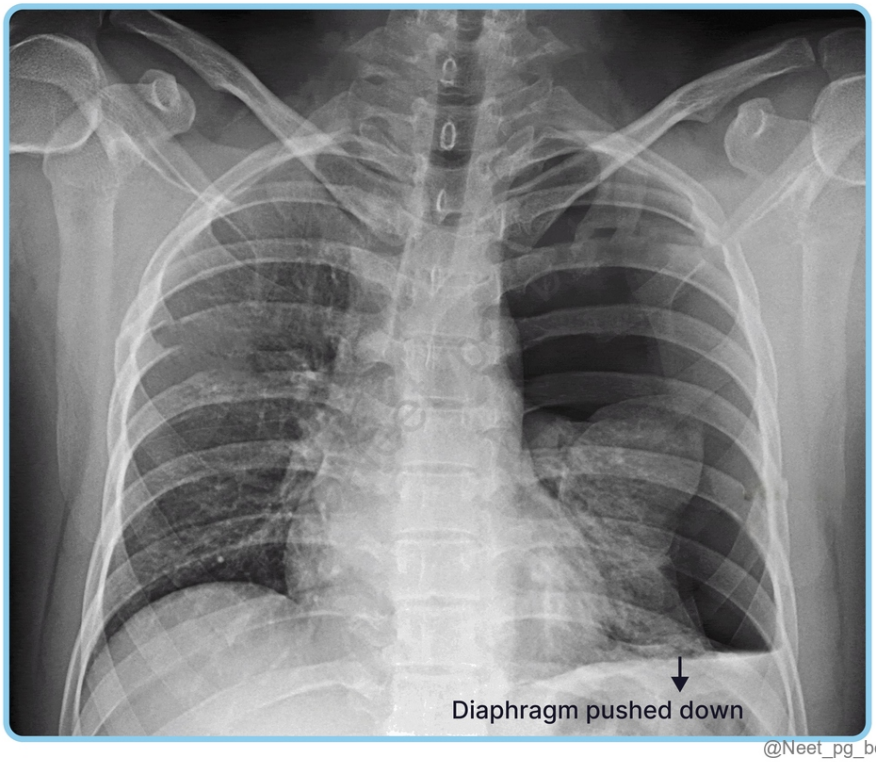

References:

https://pubs.rsna.org/doi/abs/10.1148/radiol.2282020524?journalCode=radiology

https://radiopaedia.org/articles/pneumothorax

https://pubmed.ncbi.nlm.nih.gov/17419871/

https://pubmed.ncbi.nlm.nih.gov/11464087/

https://pmc.ncbi.nlm.nih.gov/articles/PMC5849448/

↑ *Back to this question in Part A*

@Neet_pg_bot

Q9: A 45-year-old male comes to the emergency department after a fall from height. He developed shortness of breath, tachypnea, and chest pain since the fall. A chest X-ray was taken shown below. What would be the pathophysiology for the development of this condition? (Q851882)

A. Rupture of apical pleural blebs

B. Preexisting COPD

C. Blunt trauma to the chest

D. Iatrogenic injury

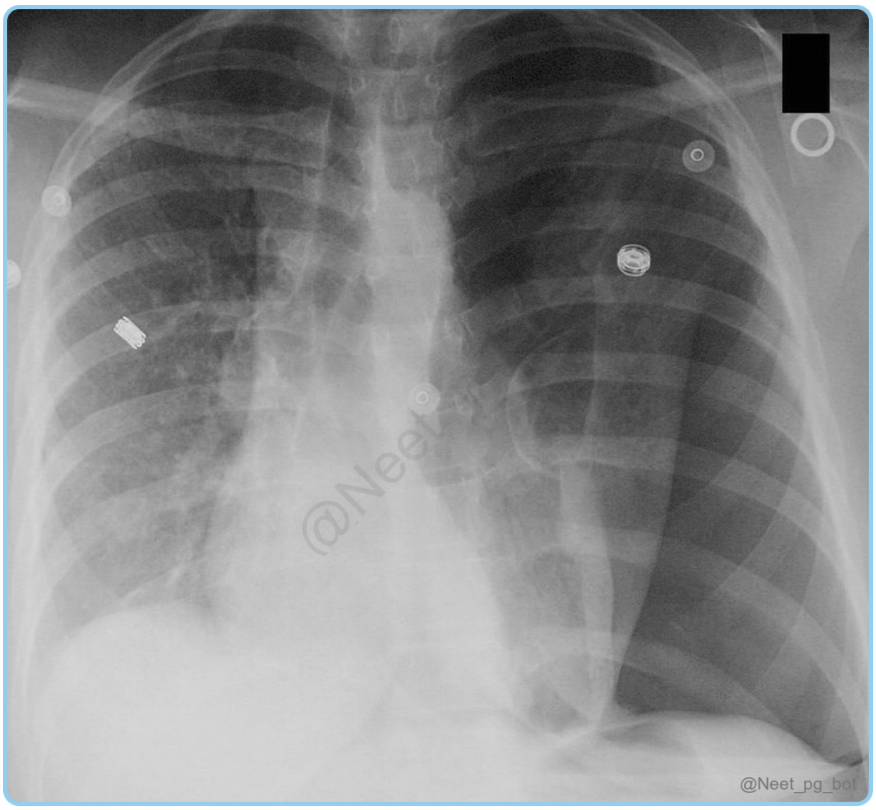

Correct Answer: C. Blunt trauma to the chest

Explanation: In a post-trauma setting, tension pneumothorax develops due to blunt chest trauma causing alveolar or pleural rupture with air leakage into the pleural cavity. Pneumothorax is characterized by the presence of air in the pleural space, disrupting normal respiratory mechanics. Types: Primary spontaneous pneumothorax : occurs without underlying lung disease, often due to the rupture of apical pleural blebs (Option A). It is more common in males with tall and thin build and smokers, indicating potential subclinical lung pathology. Secondary spontaneous pneumothorax : associated with pre-existing lung conditions (Option B) , such as COPD, making it more dangerous due to reduced pulmonary reserve. Traumatic pneumothorax: results from physical injury to the chest, which can be penetrating or non-penetrating. Includes iatrogenic causes (Option D) from medical procedures like transthoracic needle aspiration, thoracocentesis, and insertion of central IV catheters. Tension pneumothorax : a critical condition where air enters the pleural space and cannot escape, leading to increased intrathoracic pressure, mediastinal shift, and compromised cardiovascular function. Pathophysiology of tension pneumothorax:

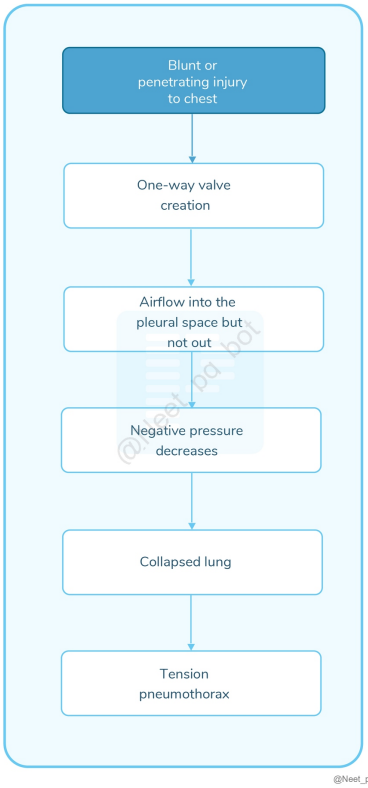

References:

www.ncbi.nlm.nih.gov/books/NBK441885/

Harrison's Principles of Internal Medicine, 21st edition, Page 2200

↑ *Back to this question in Part A*

@Neet_pg_bot

Q10: Which of the following statements regarding normal pleural fluid characteristics is accurate? (Q851855)

A. Normal pleural fluid typically contains over 3,000 WBCs/mm³.

B. The glucose level in normal pleural fluid is typically lower than that of plasma.

C. Normal pleural fluid pH ranges from 7.60 to 7.64.

D. Lactate dehydrogenase (LDH) levels in normal pleural fluid are similar to those in plasma.

Correct Answer: C. Normal pleural fluid pH ranges from 7.60 to 7.64.

Explanation: Normal pleural fluid has a slightly alkaline pH in the range of 7.60 to 7.64 , which helps to maintain proper lung function and lubrication between the pleural layers. Appearance : Clear ultrafiltrate of plasma from the parietal pleura. pH Level : Ranges from 7.60 to 7.64. (Option C) Protein Content : Less than 2% (1-2 g/dl). White Blood Cells : Fewer than 1,000 WBCs per cubic mm. (Option A) Glucose Level : Comparable to that of plasma. (Option B) Lactate Dehydrogenase (LDH) : Less than 50% of plasma levels. (Option D)

References:

https://emedicine.medscape.com/article/299959-overview

↑ *Back to this question in Part A*

@Neet_pg_bot

Q11: A 65-year-old male patient with Parkinson's disease has been experiencing fluctuations in his motor function, To help manage these "on-off" features, new medication to his treatment regimen. However, the patient later presented with respiratory distress, chest discomfort, and diminished breath sounds on examination. Which medication is likely to be the possible cause of these respiratory symptoms? (Q851876)

A. Amantadine

B. Levodopa

C. Bromocriptine

D. Pramipexole

Correct Answer: C. Bromocriptine

Explanation: In this scenario, the addition of Bromocriptine , a dopamine agonist, to the patient's treatment regimen is likely responsible for the respiratory symptoms he is experiencing. Bromocriptine has been associated with complications such as pleural effusion, leading to respiratory distress and diminished breath sounds due to its effects on fluid retention and vasodilation. Amantadine (Option A) is primarily used for dyskinesias and has side effects like livedo reticularis , edema , and confusion, but not typically cause pleuropulmonary toxicity. Levodopa (Option B) is the cornerstone of Parkinson’s treatment. While it can cause motor fluctuations ("on-off" effects) and dyskinesias, it is not associated with pleuropulmonary side effects . Pramipexole (Option D) is a non-ergot dopamine agonist , pramipexole is less likely to cause pulmonary complications. It is generally better tolerated in terms of pleuropulmonary side effects compared to ergot derivatives like bromocriptine.

References:

Harrison's principles of internal medicine, 21st Edition, Page: 2199, 3394,3395.

www.ncbi.nlm.nih.gov/books/NBK448189/

↑ *Back to this question in Part A*

@Neet_pg_bot

Q12: A 55-year-old male who has worked in the shipyard industry presents with shortness of breath and persistent pain in the right lower chest. On examination, there is dullness to percussion and decreased breath sounds on the right side. A CT scan reveals diffuse pleural thickening and nodular masses. A biopsy is performed to confirm the diagnosis. Which immunohistochemical marker is most likely to be positive? (Q851873)

A. CD-117

B. Chromogranin

C. Calretinin

D. Vimentin

Correct Answer: C. Calretinin

Explanation: The patient's history of shipyard work suggests asbestos exposure , a primary cause of malignant pleural mesothelioma (MPM). Symptoms include shortness of breath and persistent right lower chest pain. MPM often presents with exudative pleural effusion, leading to dullness to percussion and decreased breath sounds. CT findings typically show diffuse pleural thickening and nodular masses. Immunohistochemistry is essential for diagnosis, with calretinin being a key positive marker that distinguishes mesothelioma from other cancers, such as adenocarcinomas. CD-117 (Option A): Also known as c-KIT , this marker is commonly positive in gastrointestinal stromal tumors (GISTs) and some leukemias , but it is not associated with mesothelioma . Chromogranin (Option B): It is used to identify tumors of neuroendocrine origin - not relevant in pleural-based mesothelioma. Vimentin (Option D): While vimentin is a general marker for mesenchymal cells and can be positive in mesothelioma, it is nonspecific . It is found in many sarcomas and some carcinomas, making it less useful for definitive diagnosis.

References:

Harrison's principles of internal medicine, 21st Edition, Page: 718,2198

Davidson's principles and practice of medicine, 24th Edition, Page: 618.

Robbins & Cotran Pathologic Basis of Disease, 10th Edition, Page: 726,727,593

www.ncbi.nlm.nih.gov/books/NBK448189/

↑ *Back to this question in Part A*

@Neet_pg_bot

Q13: A 63-year-old female with metastatic adenocarcinoma of the lung presents with worsening dyspnea and a moderate-sized left-sided pleural effusion. After therapeutic thoracentesis reveals exudative fluid with low glucose levels and positive cytology for malignant cells, her symptoms improve, but the effusion is expected to reaccumulate. What is the most appropriate next step for long-term symptomatic relief? (Q851870)

A. Insertion of a small indwelling pleural catheter

B. Serial therapeutic thoracentesis

C. Tube thoracostomy without a sclerosing agent

D. Initiation of diuretics and oxygen therapy

Correct Answer: A. Insertion of a small indwelling pleural catheter

Explanation: In malignant pleural effusion with recurrent accumulation, the best long-term symptomatic relief is provided by an indwelling pleural catheter or pleurodesis, with the catheter often preferred for moderate to large recurrent effusions. Serial therapeutic thoracentesis (Option B) only provides temporary relief and requires repeated procedures. Tube thoracostomy without a sclerosing agent (Option C) is not effective for long-term palliation. Initiation of diuretics and oxygen therapy (Option D) does not address malignant effusions since they are not due to fluid overload.

References:

Harrison's Principles of Internal Medicine, 21st Edition, Page 2198

↑ *Back to this question in Part A*

@Neet_pg_bot

Q14: A resident physician is preparing to perform a thoracentesis on a patient with a large pleural effusion. The patient is seated, and the procedure is to be performed under ultrasound guidance. Which of the following steps is crucial for the correct execution of the thoracentesis procedure? (Q851868)

A. Insert the needle below the lower rib to avoid injury

B. Perform the procedure at the 2nd intercostal space in the midclavicular line

C. Ensure the patient is in a supine position for optimal access

D. Insert the needle above the upper border of the lower rib in the targeted intercostal space

Correct Answer: D. Insert the needle above the upper border of the lower rib in the targeted intercostal space

Explanation: To avoid injury to the intercostal vessels and nerves , the needle should be inserted above the upper border of the lower rib . Sterile environment → Select 6th–8th intercostal space (Option B) → Choose site (midaxillary for supine / posterior mid-scapular for seated) → Needle inserted above upper border of lower rib (Option A) → Use ultrasound guidance for accuracy & safety → Skin prep → Local anaesthesia → Catheter insertion → Fluid drainage (diagnosis/relief) → Avoid supine as default (Option C: seated/leaning forward or lateral preferred for safety).

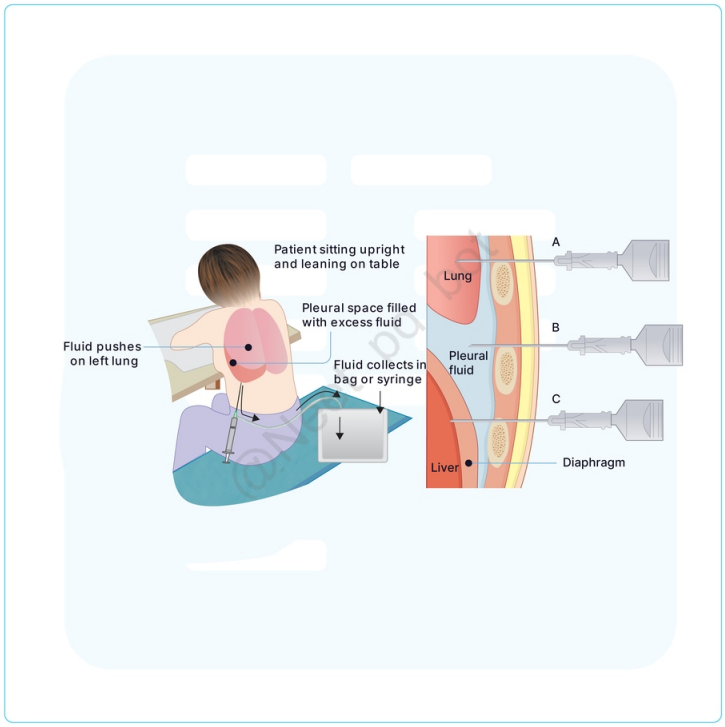

@Neet_pg_bot

References:

Thoracentesis

Pleural effusion

Thoracentesis technique

Harrison’s Principles of Internal Medicine 21st edition Page 2198

↑ *Back to this question in Part A*

@Neet_pg_bot

Q15: A 55-year-old woman presents with shortness of breath and cough. Chest X-ray shows a left-sided pleural effusion. Thoracentesis reveals the following findings. Using Light's criteria, which statement is true regarding this pleural effusion? Pleural fluid protein: 4.0 g/dL Serum protein: 6.8 g/dL Pleural fluid LDH: 280 U/L Serum LDH: 450 U/L (Q851865)

A. It is definitely transudative.

B. It meets the criteria for an exudative effusion.

C. It cannot be classified without further testing.

D. It is likely due to congestive heart failure.

Correct Answer: B. It meets the criteria for an exudative effusion.

Explanation: To classify the effusion as transudative or exudative , we apply Light's criteria: Pleural fluid protein/serum protein > 0.5 → 4 / 6.8 = 0.588 : >0.5 Pleural fluid LDH/serum LDH > 0.6 → 280 / 240 = 0.622 : >0.6 Pleural fluid LDH exceeds two-thirds of the normal upper limit for serum LDH → 280U/L > ■ x 250U/L ≈166.67U/L Since the effusion meets criteria for exudative classification, the correct statement is that it meets the criteria for an exudative effusion. NOTE: ~25% of transudates may be misidentified as exudates. If exudative criteria are met but a transudative condition is suspected, measure protein difference; if >31 g/L (3.1 g/dL), likely transudative.

References:

Harrison’s Principles of Internal Medicine 21st edition Page 2198, 2199.

://pmc.ncbi.nlm.nih.gov/articles/PMC4753987/#sec4

↑ *Back to this question in Part A*

@Neet_pg_bot

Q16: A 60-year-old female with a known diagnosis of metastatic mesothelioma presents with worsening dyspnea and right-sided chest pain that is constant. Chest imaging is given below. What clinical finding is most likely to be present? (Q851861)

A. Hyperresonance to percussion

B. Egophony at the superior aspect of the effusion

C. Increased tactile fremitus

D. Bronchial breath sounds over the effusion

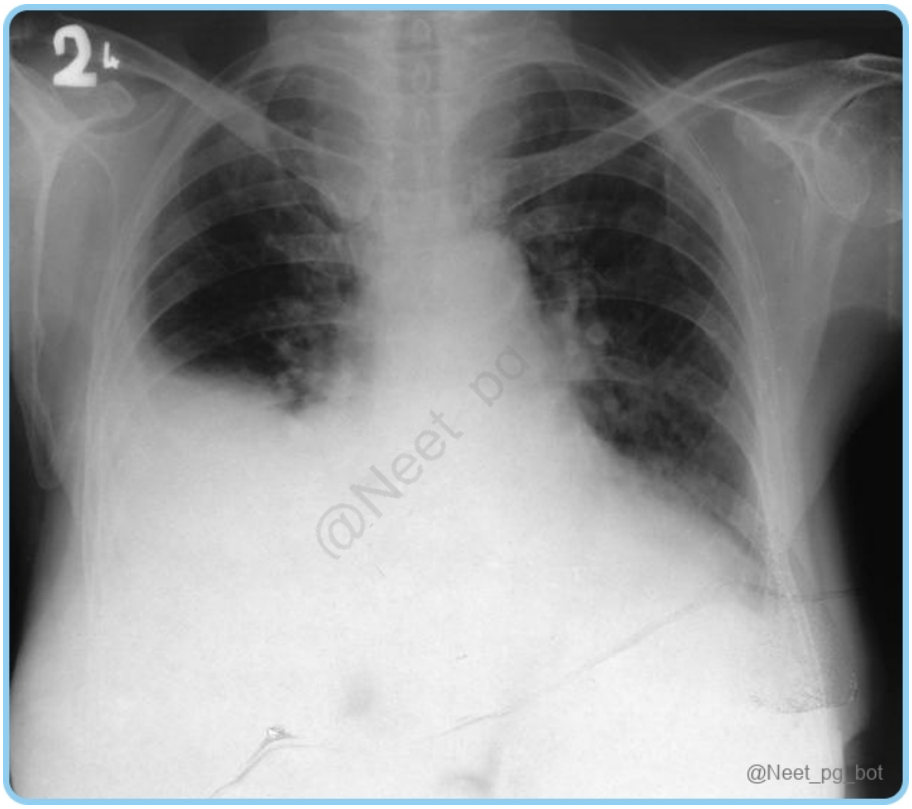

Correct Answer: B. Egophony at the superior aspect of the effusion

Explanation: Egophony is a key sign of pleural effusion, particularly noted at the upper boundary of the fluid. The chest X-ray shows a right-sided pleural effusion , indicated by blunting of the costophrenic angle and increased opacity. The fluid compresses adjacent lung tissue, altering sound transmission. When the patient says "E," it may be heard as "A" over the effusion, helping to locate its upper limit. In pleural effusion (common in mesothelioma), fluid collects in the pleural space, causing dullness, decreased breath sounds, and egophony just above the fluid level due to compressed lung. Hyperresonance to percussion (Option A): Seen in pneumothorax, not pleural effusion. Increased tactile fremitus (Option C): Decreased in effusion, increased in consolidation. Bronchial breath sounds over the effusion (Option D): Breath sounds are reduced/absent over effusion, not bronchial.

References:

https://www.ncbi.nlm.nih.gov/books/NBK448189/#

https://www.ncbi.nlm.nih.gov/books/NBK559322/#

↑ *Back to this question in Part A*

@Neet_pg_bot

Q17: A patient presents with dyspnea and pleuritic chest pain. A chest X-ray shows a pleural effusion. Pleural fluid analysis reveals elevated protein and LDH levels. Which

of the following conditions is the likely cause of this exudative pleural effusion? (Q851857)

A. Urinothorax

B. Esophageal rupture

C. Congestive heart failure

D. Nephrotic syndrome

Correct Answer: B. Esophageal rupture

Explanation: Esophageal rupture can lead to exudative pleural effusions due to the leakage of gastrointestinal contents into the pleural space, resulting in inflammation and elevated protein and LDH levels. Causes of pleural effusion Transudative Exudative Both Congestive heart failure (Option C) Cirrhosis Nephrotic syndrome (Option D) Peritoneal dialysis SVC obstruction Myxedema Urinothorax (Option A) Malignancies Tuberculosis Pneumonia Esophageal perforation (Option B) Pancreatic disease Collagen vascular diseases: Rheumatoid pleuritis Systemic lupus erythematosus Sjögren syndrome Wegener Granulomatosis Pulmonary embolism Drugs induced Nitrofurantoin Dantrolene Methysergide Bromocriptine Procarbazine Amiodarone Dasatinib

References:

Harrison’s Principles of internal medicine 21st edition Page 2199

Pleural effusion

↑ *Back to this question in Part A*

@Neet_pg_bot

• [10_Pulmonology] 082 Abg Analysis - I

« Back to Folder Directory

[10_Pulmonology] 082 Abg Analysis - I — Quick Jump

Q1 (p. 2981)	*Q2 (p. 2981)*	*Q3 (p. 2982)*	*Q4 (p. 2983)*	*Q5 (p. 2985)*	*Q6 (p. 2986)*
Q7 (p. 2987)	*Q8 (p. 2987)*	*Q9 (p. 2988)*	*Q10 (p. 2989)*	*Q11 (p. 2990)*	*Q12 (p. 2991)*
Q13 (p. 2991)	*Q14 (p. 2992)*	*Q15 (p. 2993)*	*Q16 (p. 2993)*	*Q17 (p. 2994)*	*Q18 (p. 2995)*
Q19 (p. 2997)	*Q20 (p. 2997)*	*Q21 (p. 2998)*	*Q22 (p. 2999)*		

Q1: A 45-year-old woman presents to the emergency department with diarrhea for the past three days. She reports fatigue and mild abdominal cramping. Laboratory tests show the following: Arterial blood gas pH 7.30 HCO■■ 15 mmol/L PaCO■ 38 mmHg Serum electrolytes Na■ 140 mmol/L Cl■ 115 mmol/L K■ 4.5 mmol/L What is the type of acidosis? (Q851932)

A. Normal Anion Gap Metabolic Acidosis

B. High Anion Gap Metabolic Acidosis

C. Respiratory Acidosis

D. None of the above

Correct Answer: A. Normal Anion Gap Metabolic Acidosis

Explanation: The anion gap (AG) is calculated as follows: AG = Na■ - (Cl■ + HCO■■) AG = 140 - (115 + 15) = 140 - 130 = 10 mmol/L. This indicates a normal anion gap metabolic acidosis (NAGMA), commonly seen in conditions where bicarbonate is lost. The normal Anion Gap value ranges from 6-12 mmol/L. This distinguishes it from elevated anion gap metabolic acidosis (HAGMA), which is associated with conditions that produce unmeasured anions. High Anion Gap Metabolic Acidosis (Option B): Would require AG > 12; this patient's AG = 10. Respiratory Acidosis (Option C): PaCO■ would be elevated; here PaCO■ is normal.

References:

Harrison's Principles of Internal Medicine, 21st Edition, Page 364, 361

↑ *Back to this question in Part A*

@Neet_pg_bot

Q2: A 35-year-old male presents to the emergency complaining of chronic pain. He was diagnosed with lymphoma 6 months back. His HR is 96/min, and his RR is 38/min. An ABG sample is withdrawn, which shows pH 7.42, pCO 2 =25 mmHg, and HCO3=18 mmHg. What is the likely acid-base disorder? (Q882164)

A. Metabolic acidosis, partially compensated

B. Respiratory acidosis, partially compensated

C. Respiratory acidosis, fully compensated

D. Respiratory alkalosis, fully compensated

Correct Answer: D. Respiratory alkalosis, fully compensated

Explanation: Option D: Respiratory alkalosis, fully compensated The ABGs show pH 7.42 (normal), pCO 2 =25 mmHg (low), and HCO3=18 mmHg (low). Since the pH value is towards the alkaline side, the primary change is caused by low pCO2. The patient has chronic pain and tachypnea, which explains the low pCO2. The serum level of HCO3 decreases to maintain the pH. The pH is in the normal range. So, the patient has a fully compensated respiratory alkalosis. Option A: Metabolic acidosis, partially compensated In metabolic acidosis, the pH should be towards the acidic side. Also, normal pH indicates that the acid-base abnormality is fully compensated. Option B: Respiratory acidosis, partially compensated The patient has low pCO2 and a normal pH. He has respiratory alkalosis, not respiratory acidosis. Also, normal pH indicates that the acid-base abnormality is fully compensated. Option C: Respiratory acidosis, fully compensated The patient has low pCO2 and a normal pH. He has respiratory alkalosis, not respiratory acidosis. Normal pH indicates that respiratory alkalosis is fully compensated.

References:

Harrison’s Principles Of Internal Medicine, 20th Edition, Volume I, Page. 315

↑ *Back to this question in Part A*

@Neet_pg_bot

Q3: Match the acid base disorder with their respective etiology Condition Acid - base disorder 1. Ureterostomy a. High anion gap Metabolic acidosis 2. Opium poisoning b. Normal anion gap metabolic acidosis 3. Prolonged NG suction c. Respiratory acidosis 4. Salicylate poisoning d. Metabolic alkalosis (Q851995)

A. 1-b, 2-a, 3-c, 4-d

B. 1-b , 2-c ,3-d, 4-a

C. 1-c, 2-d, 3-a, 4-b

D. 1-d, 2-b, 3-a, 4-c

Correct Answer: B. 1-b , 2-c ,3-d, 4-a

Explanation: Condition Acid - base disorder Reasoning Ureterostomy Normal anion gap metabolic acidosis Urine enters the bowel, where the mucosa reabsorbs urinary chloride and exchanges it for bicarbonate. This leads to a net increase in chloride in body fluids, causing a decrease in the strong ion difference. The loss of bicarbonate also contributes to a normal anion gap metabolic acidosis (NAGMA). Opium poisoning Respiratory acidosis Opium poisoning depresses the respiratory center, leading to hypoventilation and an increase in CO■, causing respiratory acidosis. Prolonged NG suction Metabolic alkalosis NG suction removes stomach acid (HCl), causing a relative excess of bicarbonate and leading to metabolic alkalosis. Salicylate poisoning High anion gap Metabolic acidosis Salicylate poisoning leads to accumulation of organic acids, causing a high anion gap metabolic acidosis

References:

https://pmc.ncbi.nlm.nih.gov/articles/PMC3822347/

https://www.ncbi.nlm.nih.gov/books/NBK507807/

↑ *Back to this question in Part A*

@Neet_pg_bot

Q4: A 28-year-old woman at 32 weeks gestation presents with severe abdominal pain, vomiting, and rapid breathing. Vitals: BP 110/70 mmHg, HR 112/min, RR 28/min. Based on the Davenport diagram, which areas represent her acid-base status initially and after 12 hours if untreated? (Q851994)

A. Initially: Area C, After 12 hours: Area F

B. Initially: Area D, After 12 hours: Area F

C. Initially: Area A, After 12 hours: Area B

D. Initially: Area F, After 12 hours: Area C

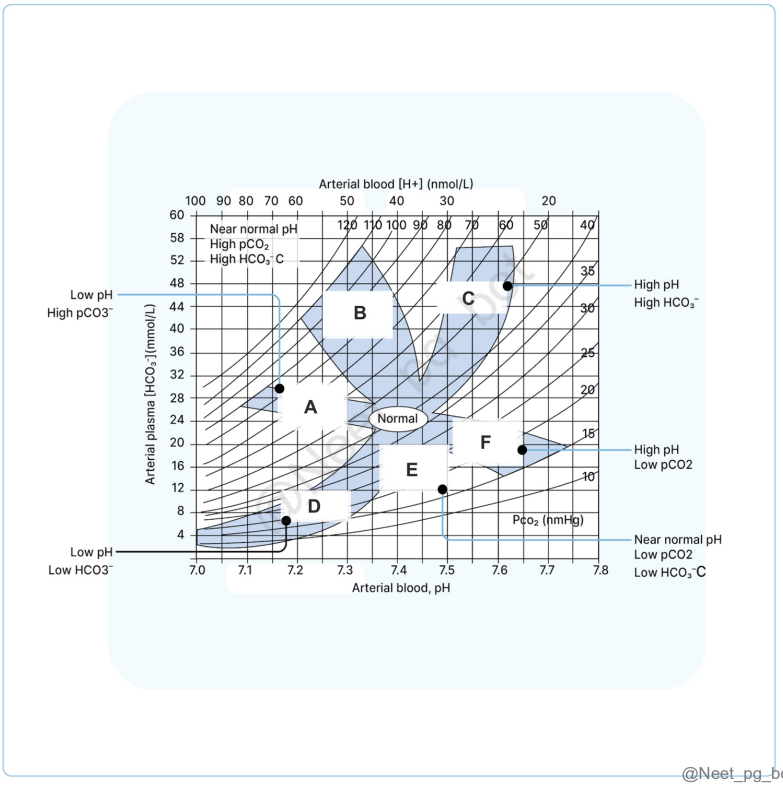

@Neet_pg_bot

Correct Answer: A. Initially: Area C, After 12 hours: Area F

Explanation: Initial Presentation: Severe abdominal pain and vomiting → loss of gastric acid (HCl) → metabolic alkalosis . Rapid breathing (RR 28/min) → hyperventilation → respiratory alkalosis can coexist initially. Tachycardia and elevated BP → compensatory response to pain, dehydration, and alkalosis. {{caption_text}} Acid-Base Status Over Time: Initially (Area C): Metabolic alkalosis predominates due to vomiting-induced HCl loss . After 12 hours (Area F): Persistent vomiting and dehydration worsen alkalosis, and respiratory compensation (hyperventilation) becomes more pronounced, leading to a mixed picture with respiratory alkalosis . Key Point: Vomiting → metabolic alkalosis. Hyperventilation → respiratory alkalosis. Over time, the body may show combined metabolic and respiratory alkalosis depending on compensatory mechanisms.

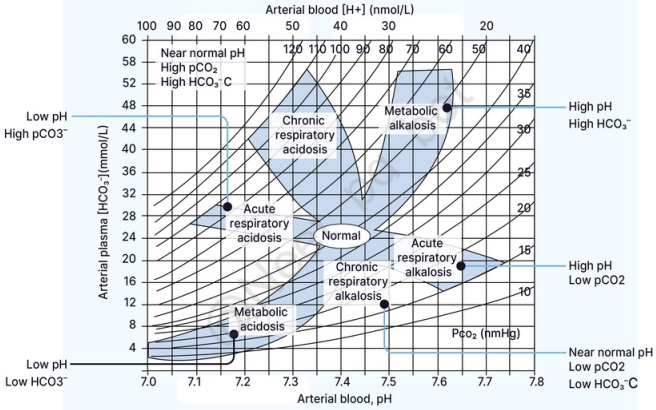

@Neet_pg_bot

References:

Harrison's Principles Of Internal Medicine, 21st Edition, Volume I, Page. 359.

↑ *Back to this question in Part A*

@Neet_pg_bot

Q5: A 50-year-old alcoholic presents with severe abdominal pain. His ABG shows pH: 7.20 HCO3: 12 mEq/L Na+: 140 mEq/L Cl-: 98 mEq/L. Which of the following options correctly justifies the diagnosis? (Q851992)

A. Delta ratio 0.4 - Pure NAGMA

B. Delta ratio 1.5 - Pure HAGMA

C. Delta ratio 0.6 - Mixed HAGMA and NAGMA

D. Delta ratio 2.2 - HAGMA with metabolic alkalosis

Correct Answer: B. Delta ratio 1.5 - Pure HAGMA

Explanation: Calculation: Normal Anion Gap = 12 mEq/L Normal HCO3 = 24 mEq/L Patient's Anion Gap = Na■ - (Cl■ + HCO3■) = 140 - (98 + 12) = 30 mEq/L Delta Calculation: ΔAG = Patient's AG - Normal AG = 30 - 12 = 18 ΔHCO3 = Normal HCO3 - Patient's HCO3 = 24 - 12 = 12 Delta Ratio = ΔAG/ΔHCO3 = 18/12 = 1.5 Delta ratio interpretation: < 0.4 → Pure NAGMA 0.4–0.8 → Mixed HAGMA + NAGMA 0.8–2.0 → Pure HAGMA > 2.0 → HAGMA + metabolic alkalosis

References:

Harrison’s Principles Of Internal Medicine, 21st Edition, Volume I, Pages 360, 361.

↑ *Back to this question in Part A*

@Neet_pg_bot

Q6: A 45-year-old diabetic patient presents to the emergency department with nausea and vomiting for 2 days. ABG shows: pH: 7.28 pCO■: 35 mmHg HCO■■: 12 mEq/L Na■: 138 mEq/L Cl■: 102 mEq/L What is the most likely acid-base disorder? (Q851991)

A. Simple metabolic acidosis

B. Metabolic acidosis with respiratory alkalosis

C. Metabolic acidosis with respiratory acidosis

D. Metabolic alkalosis and respiratory alkalosis

Correct Answer: C. Metabolic acidosis with respiratory acidosis

Explanation: Step-by-Step Interpretation: 1. Identify the primary disorder — Metabolic Acidosis: Low HCO■■ (12 mEq/L) with acidemia (pH 7.28) confirms metabolic acidosis . Anion Gap = 138 - [102 + 12] = 24 → elevated. Suggests high anion gap metabolic acidosis , most likely diabetic ketoacidosis in this diabetic patient 2. Evaluate Compensation (Winter’s Formula): Expected pCO■=(1.5×12)+8=26±2 → Range:24–28mmHg. Observed pCO■ = 35 mmHg , which is higher than expected . Indicates inadequate respiratory compensation , or a co-existing primary respiratory acidosis . 3. Final Interpretation — Mixed Disorder: Metabolic acidosis (primary) due to DKA. Respiratory acidosis from hypoventilation or impaired compensation. Together, this is a mixed metabolic and respiratory acidosis .

References:

Harrison’s Principles Of Internal Medicine, 21st Edition, Volume I, Page. 359

↑ *Back to this question in Part A*

@Neet_pg_bot

Q7: A 68-year-old woman with a history of chronic kidney disease and recent severe pneumonia is admitted to the intensive care unit. She has been experiencing increased shortness of breath, confusion, and fatigue. Laboratory tests reveal the following: Arterial blood gas: pH 7.28, HCO■■ 18 mmol/L, PaCO■ 50 mmHg Serum electrolytes: Na■ 140 mmol/L, K■ 4.2 mmol/L, Cl■ 100 mmol/L Based on the laboratory results and clinical presentation, what type of acid-base disorder is this patient experiencing? (Q851990)

A. Metabolic acidosis—respiratory alkalosis

B. Metabolic acidosis—respiratory acidosis

C. Metabolic alkalosis—respiratory acidosis

D. Metabolic acidosis—metabolic alkalosis

Correct Answer: B. Metabolic acidosis—respiratory acidosis

Explanation: The patient's lab results indicate a mixed disorder of metabolic acidosis and respiratory acidosis, consistent with her clinical condition of severe pneumonia and chronic kidney disease. Understanding the Values: pH : 7.28 (Acidemic) HCO■■ : 18 mmol/L (Low, indicating metabolic acidosis) PaCO■ : 50 mmHg (High, indicating respiratory acidosis) Assessment: The low pH indicates acidemia. The decreased bicarbonate level suggests a metabolic acidosis. The elevated PaCO■ indicates that the respiratory system is not effectively eliminating carbon dioxide, contributing to respiratory acidosis. Classification: Since both metabolic acidosis (low HCO■■) and respiratory acidosis (high PaCO■) are present, this condition is classified as metabolic acidosis—respiratory acidosis . Mixed Acid-Base Disorders Examples Mixed Metabolic and Respiratory Metabolic acidosis—respiratory alkalosis (Option A ruled out) Lactic acidosis, sepsis in ICU Metabolic acidosis—respiratory acidosis Severe pneumonia, pulmonary edema Metabolic alkalosis—respiratory alkalosis Liver disease and diuretics Metabolic alkalosis—respiratory acidosis (Option C ruled out) COPD on diuretics Mixed Metabolic Disorders Metabolic acidosis—metabolic alkalosis (Option D ruled out) Uremia with vomiting Metabolic acidosis—metabolic acidosis Diarrhea and lactic acidosis, toluene toxicity, treatment of diabetic ketoacidosis

References:

Harrison’s Principles of Internal Medicine, 21st Edition, Page 360

↑ *Back to this question in Part A*

@Neet_pg_bot

Q8: A 72-year-old man with a history of chronic kidney disease and COPD presents to the emergency department with confusion, shortness of breath, and fatigue. He has

been experiencing increased nausea and vomiting over the past week. Laboratory tests reveal: Arterial blood gas: pH 7.29, HCO■■ 18 mmol/L, PaCO■ 60 mmHg Serum electrolytes: Na■ 138 mmol/L, K■ 4.8 mmol/L, Cl■ 102 mmol/L Based on the provided laboratory results, what type of acid-base disorder is this patient experiencing? (Q851989)

A. Respiratory acidosis

B. Metabolic acidosis

C. Mixed respiratory and metabolic acidosis

D. Fully compensated metabolic acidosis

Correct Answer: C. Mixed respiratory and metabolic acidosis

Explanation: The patient's laboratory results indicate a mixed respiratory and metabolic acidosis due to the combination of elevated PaCO■ and decreased bicarbonate levels, resulting in a significantly low pH. Understanding the Values: pH: 7.29 (Acidemic) HCO■■: 18 mmol/L (Low, indicating metabolic acidosis) PaCO■: 60 mmHg (High, indicating respiratory acidosis) Assessment: The low pH indicates acidosis. The decreased bicarbonate level suggests a metabolic component. The elevated PaCO■ indicates that the respiratory system is not effectively eliminating carbon dioxide, contributing to respiratory acidosis. Classification: Since both the metabolic acidosis (low HCO■■) and respiratory acidosis (high PaCO■) are present, this is classified as a mixed acid-base disorder.

References:

Harrison’s Principles of Internal Medicine, 21st Edition, Page 360

https://medilib.ir/uptodate/show/2352

↑ *Back to this question in Part A*

@Neet_pg_bot

Q9: A 65-year-old man with a history of chronic obstructive pulmonary disease presents to the emergency department with light-headedness and confusion along with tingling sensation of his limbs. He has also been experiencing persistent vomiting for the past three days due to food poisoning. Arterial blood gas shows the following findings pH - 7.48 HCO3- - 38 mEq/L PaCO2 - 40 mm hg Which of the following is correct about this patient? (Q851988)

A. Fully compensated metabolic alkalosis

B. Partially compensated metabolic alkalosis

C. Uncompensated metabolic alkalosis

D. Normal acid-base balance

Correct Answer: C. Uncompensated metabolic alkalosis

Explanation: pH : 7.48 (Alkalosis) HCO■■ : 38 mmol/L (Elevated, indicating metabolic alkalosis PaCO■ : 40 mmHg (Normal) Applying modified winter formula, expected pCO2 = HCO3 plus 15 = 38 + 15 = 53 mm Hg. Convential winter formula , expected pCO2 = 0.7 (HCO3) + 20 mmHg +/- 5 0.7 (38) + 20 +/- 5 46.6 (+/- 5) which is higher and does not match with actual pCO2 This implies that compensation process has not started and patient is having uncompensated metabolic alkalosis Severe vomitting due to food poisoning explains metabolic alkalosis. The resultant redistribution of calcium explains the tingling sensation percieved by the patient.

References:

Harrison's Principles of Internal Medicine, 21st Edition, Page 259

↑ *Back to this question in Part A*

@Neet_pg_bot

Q10: A 50-year-old woman with a history of hypertension presents to the emergency department with confusion and muscle cramps. She reports having persistent vomiting for the last two days after taking an over-the-counter medication for indigestion. On examination, she has a blood pressure of 130/85 mmHg and shows signs of mild dehydration. Laboratory results reveal: Arterial blood gas: pH 7.48, HCO■■ 30 mmol/L, PaCO■ 45 mmHg Serum electrolytes: Na■ 140 mmol/L, K■ 3.0 mmol/L, Cl■ 88 mmol/L What is the most likely diagnosis for this patient based on the laboratory findings? (Q851987)

A. Respiratory acidosis

B. Metabolic acidosis

C. Metabolic alkalosis

D. Respiratory alkalosis

Correct Answer: C. Metabolic alkalosis

Explanation: The arterial blood gas shows an elevated pH (7.48) and increased bicarbonate (30 mmol/L), indicating metabolic alkalosis. Hypochloremia and hypokalemia further support this diagnosis. Respiratory acidosis (Option A) is characterized by a low pH and elevated PaCO■, which is not present in this scenario.

Metabolic acidosis (Option B) would show a low pH and low bicarbonate levels, which is contrary to the findings here. Respiratory alkalosis (Option D) would show a high pH with low PaCO■, which does not fit the lab results provided.

References:

Harrison's Principles of Internal Medicine, 21st Edition, Page 365-367

https://www.physio-pedia.com/Arterial_Blood_Gases

↑ *Back to this question in Part A*

@Neet_pg_bot

Q11: 60-year-old man with a history of chronic kidney disease presents to the emergency department with fatigue and extreme shortness of breath. Laboratory tests reveal: Arterial blood gas: pH 7.30, HCO■■ 12 mmol/L, PaCO■ 30 mmH Serum electrolytes: Na■ 140 mmol/L, Cl■ 104 mmol/L, K■ 5.0 mmol/L Which of the following is correct about this patient's status? (Q851933)

A. Metabolic acidosis with respiratory alkalosis

B. Metabolic acidosis with respiratory acidosis

C. Uncompensated metabolic acidosis

D. Metabolic acidosis with metabolic alkalosis

Correct Answer: B. Metabolic acidosis with respiratory acidosis

Explanation: Primary metabolic acidosis is present (HCO■■ 12 mmol/L); by Winter's formula expected PaCO■ ≈ 26 mmHg, but measured PaCO■ is 30 mmHg (higher), indicating inadequate respiratory compensation → concurrent respiratory acidosis. Given ABG pH = 7.30 → Acidemia HCO■■ = 12 → Metabolic acidosis (primary) PaCO■ = 30 mmHg Step 1: Expected respiratory compensation (Winter's formula) Expected PaCO■ = 1.5 × HCO■ + 8 ± 2 = 1.5 × 12 + 8 = 18 + 8 = 26 ± 2 → (24–28 mmHg) Actual PaCO■ = 30 mmHg This is higher than expected → lungs are under-compensating → superimposed respiratory acidosis. Therefore: Correct answer is Metabolic acidosis with respiratory acidosis Metabolic acidosis with respiratory alkalosis (Option A): PaCO■ is not lowered more than expected, so there is no additional respiratory alkalosis. Uncompensated metabolic acidosis (Option C): Some respiratory compensation is present (PaCO■ < 40 mmHg). Metabolic acidosis with metabolic alkalosis (Option D): HCO■■ is low, so no coexisting metabolic alkalosis.

References:

Harrison's Principles of Internal Medicine, 21st Edition, Page 359

↑ *Back to this question in Part A*

@Neet_pg_bot

Q12: A 62-year-old female with known COPD presents with increased muscle weakness and difficulty in breathing. On examination she appears confused and her arterial blood gas (ABG) results are as follows: pH: 7.29 PaCO■: 65 mm Hg HCO■■: 26 mEq/L PaO■: 65 mm Hg. Which of the following best describes the underlying mechanism for this patient's presentation? (Q851791)

A. Increased metabolic rate leading to excess CO■ production

B. Impaired ventilatory control due to central respiratory depression

C. Impaired responsiveness of the respiratory reflexes to states of hypoxia and hypercapnia

D. Decreased oxygen-carrying capacity of the blood

Correct Answer: C. Impaired responsiveness of the respiratory reflexes to states of hypoxia and hypercapnia

Explanation: This patient with COPD is likely experiencing respiratory acidosis due to impaired ventilation leading to ventilation-perfusion mismatch from chronic lung disease and impaired responsiveness of the respiratory reflexes to states of hypoxia and hypercapnia Increased metabolic rate leading to excess CO■ production (Option A) : While increased metabolic rate can elevate CO■ levels, this patient has chronic obstructive pulmonary disease (COPD), indicating ventilatory issues rather than metabolic overproduction. Impaired ventilatory control due to central respiratory depression (Option B) : This could cause respiratory acidosis , but the scenario suggests that the patient’s COPD is primarily leading to ventilation-perfusion mismatch from chronic lung disease and impaired responsiveness of the respiratory reflexes Decreased oxygen-carrying capacity of the blood (Option D) is seen in conditions like anemia or carbon monoxide poisoning , results in reduced oxygen delivery to tissues but would not necessarily cause elevated PaCO2 levels or respiratory acidosis.

References:

Harrison’s Principles of Internal Medicine, 21st Edition, Page 367, 368

↑ *Back to this question in Part A*

@Neet_pg_bot

Q13: A 30-year-old male presents with: ABG: pH: 7.20, PaCO2: 25 mmHg, HCO3-: 10 mEq/L, Na+: 140 mEq/L, Cl-: 100 mEq/L, and Blood lactate: 12 mmol/L. Calculate: Anion gap Expected PaCO2 compensation (Q851931)

A. AG=30, Expected PaCO2=25±2

B. AG=30, Expected PaCO2=30±2

C. AG=25, Expected PaCO2=25±2

D. AG=25, Expected PaCO2=30±2

Correct Answer: A. AG=30, Expected PaCO2=25±2

Explanation: Anion Gap = [Na+] - ([Cl-] + [HCO3-]) = 140 - (100 + 10) = 30 mEq/L Based on Winters formula Expected PaCO2 = (1.5 × HCO3-) + 8 ± 2 = (1.5 × 10) + 8 = 23 ± 2 Actual PaCO2 (25) matches expected Delta ratio = (AG increase)/(HCO3- decrease) = (30-12)/(24-10) = 18/14 ≈ 2

References:

Harrison's Principles Of Internal Medicine, 21st Edition, Volume I, Page. 360, 361.

↑ *Back to this question in Part A*

@Neet_pg_bot

Q14: A 75-year-old man presents to the emergency department with severe abdominal pain, vomiting, frequent urination, confusion, and labored, deep breathing and he is difficult to arouse. Lab investigations reveal the following findings Na+ - 135 mEq/L K+ - 5.2 mEq/L Cl - 100 mEq/L HCO3 - 15 mEq/L Serum pH - 7.15 What is the least likely cause of these findings? (Q851930)

A. Methanol poisoning

B. Diabetic ketoacidosis

C. Renal tubular acidosis

D. Renal failure

Correct Answer: C. Renal tubular acidosis

Explanation: This patient has: Severe metabolic acidosis → pH 7.15 Low bicarbonate → HCO■■ 15 mEq/L Kussmaul breathing (deep, labored) Confusion, abdominal pain, vomiting Normal sodium and slightly high potassium These features point toward a high anion gap metabolic acidosis (HAGMA) . Calculate Anion Gap Anion Gap =Na+ – (Cl– + HCO3–■) = 135 - (100 + 15) = 20 mEq/L (high anion gap) (Normal AG - 6-12 mEq/L) RTA causes normal anion gap metabolic acidosis not high AG acidosis. Therefore, it cannot explain this patient's presentation. Methanol poisoning (Option A): Produces high-anion-gap metabolic acidosis due to formic acid accumulation. Causes abdominal pain, confusion, and Kussmaul breathing → fits the presentation. Diabetic ketoacidosis (Option B): Classic high-anion-gap metabolic acidosis from ketone accumulation. Symptoms:

vomiting, abdominal pain, dehydration, deep rapid breathing → matches this case. Renal failure (Option D): Uremia causes retention of organic acids → high-anion-gap metabolic acidosis . Also leads to hyperkalemia and confusion → consistent with findings.

References:

Harrison’s Principles Of Internal Medicine, 21st Edition, Volume I, Page. 361, 362, 364.

↑ *Back to this question in Part A*

@Neet_pg_bot

Q15: An intern reviews the following electrolyte levels for a patient: Sodium (Na■): 140 mEq/L Chloride (Cl■): 100 mEq/L Bicarbonate (HCO■■): 24 mEq/L Potassium (K■): 4.0 mEq/L What is the calculated anion gap for this patient? (Q851929)

A. 12 mEq/L

B. 16 mEq/L

C. 20 mEq/L

D. 24 mEq/L

Correct Answer: B. 16 mEq/L

Explanation: The anion gap is the difference between the unmeasured anion and cation in the serum which cannot be calculated directly thus we use the formula: Anion Gap = [Na+] - ([Cl-] + [HCO3-]) = 140 - (100 + 24) = 16 mEq/L Normal range - Normal anion gap: 12 ± 4 mEq/L

References:

Harrison’s Principles Of Internal Medicine, 21st Edition, Volume I, Page. 360, 361.

↑ *Back to this question in Part A*

@Neet_pg_bot

Q16: A 28-year-old anxious female presents with hyperventilation during a panic attack. ABG shows: pH: 7.48 PaCO2: 20 mmHg HCO3-: 22 mEq/L Which acid-base disorder is present? (Q851919)

A. Uncompensated respiratory alkalosis

B. Partially compensated respiratory alkalosis

C. Fully compensated respiratory alkalosis

D. Mixed respiratory and metabolic alkalosis

Correct Answer: B. Partially compensated respiratory alkalosis

Explanation: pH 7.48 → Alkalosis PaCO■ 20 mmHg → Low → Respiratory cause HCO■■ 22 mEq/L → Slightly decreased, meaning kidneys have begun compensating. Expected compensation (Acute respiratory alkalosis): For every 10 mmHg ↓ PaCO■ , → pH ↑ by 0.08 → HCO■■ ↓ by 2 mEq/L Here, PaCO■ fall = 20 mmHg → Expected pH ↑ 0.16 and HCO■■ ↓ 4 mEq/L What we see: pH ↑ only ~0.08 HCO■■ ↓ only ~2 mEq/L This means compensation has begun but is incomplete , so correct answer will be partially compensated respiratory alkalosis.

References:

Harrison's Principles Of Internal Medicine, 21st Edition, Volume I, Page. 359, 360, 361, 368.

https://medschool.cuanschutz.edu/docs/librariesprovider60/education-docs/heartbeat-im-res/suggested-read/evaluation-of-acid-base-disorders.pdf

↑ *Back to this question in Part A*

@Neet_pg_bot

Q17: A 65-year-old male with severe COPD presents with worsening breathlessness. His ABG shows: pH: 7.28, PaCO2: 65 mmHg, HCO3-: 30 mEq/L Which stage of respiratory acidosis does this represent? (Q851915)

A. Uncompensated respiratory acidosis

B. Partially compensated respiratory acidosis

C. Fully compensated respiratory acidosis

D. Mixed respiratory and metabolic acidosis

Correct Answer: B. Partially compensated respiratory acidosis

Explanation: This is a case of partially compensated respiratory acidosis because: In acute respiratory acidosis, HCO3- will ↑ by 1 mEq/L for every 10 mmHg ↑ in PCO2 In chronic respiratory acidosis, HCO3- will ↑ by 4 mEq/L for every 10 mmHg ↑ in PCO2 In this patient ABG shows: pH: 7.28 PaCO2: 65 mmHg HCO3-: 30 mEq/L Normal PaCO2 - 38-42 mm hg Thus difference in PaCO2 = 65-42 = 23 mm hg As this patient has COPD which is the most likely cause of respiratory acidosis in this patient, it is chronic respiratory acidosis We know for every 10 mmHg ↑ in PCO2, HCO3- should ↑ by 4 mEq/L for 1 mmHg ↑ in PCO2, HCO3- should ↑ by 4 / 10 mEq/L Thus for 23 mm hg ↑ in PCO2 , HCO3- should ↑ by 9.2 mEq/L In this patient HCO3- should be approx 35 mEq/L, but

it is only 30 mEq/L, hence it is only partially compensated respiratory acidosis.

References:

Harrison’s Principles Of Internal Medicine, 21st Edition, Volume I, Page. 359, 360, 361, 367.

https://www.ncbi.nlm.nih.gov/books/NBK482430/

↑ *Back to this question in Part A*

@Neet_pg_bot

Q18: Which of the following statements regarding the test shown in the image, done prior to arterial blood sampling is not true? (Q851905)

A. Preferred site for arterial sampling is the radial artery between the flexor carpi radialis tendon and the styloid process

B. Both ulnar and radial arteries should be released simultaneously after occlusion

C. The presence of collaterals is confirmed if the hand becomes flushed after releasing one artery

D. Pressure should be applied to the site for 5 minutes after blood sampling to prevent hematoma



Correct Answer: B. Both ulnar and radial arteries should be released simultaneously after occlusion

Explanation: Simultaneous release of vessels after occlusion in Modified Allen's test is not the appropriate technique to assess collateral circulation cannot evaluated if both arteries are released together. Modified Allen Test Preferred Site for arterial sampling Radial artery between flexor carpi radialis tendon and styloid process (Option A) Technique {{caption_text}} {{caption_text}} Sequential release allows assessment of individual collateral flow Cannot evaluate collateral circulation if both are released together (Option B) Examines one hand at a time Avoid elbow overextension Palm should initially blanch Normal color should return quickly Interpretation Positive Test: (Option C) • Color returns within 10 seconds → Adequate collateral flow Negative Test: • Persistent pallor after release → inadequate collateral flow →May need additional testing • Consider temperature effects Precaution Pressure applied on blood sampling site for 5 minutes after sampling is done (Option D) to prevent hematoma

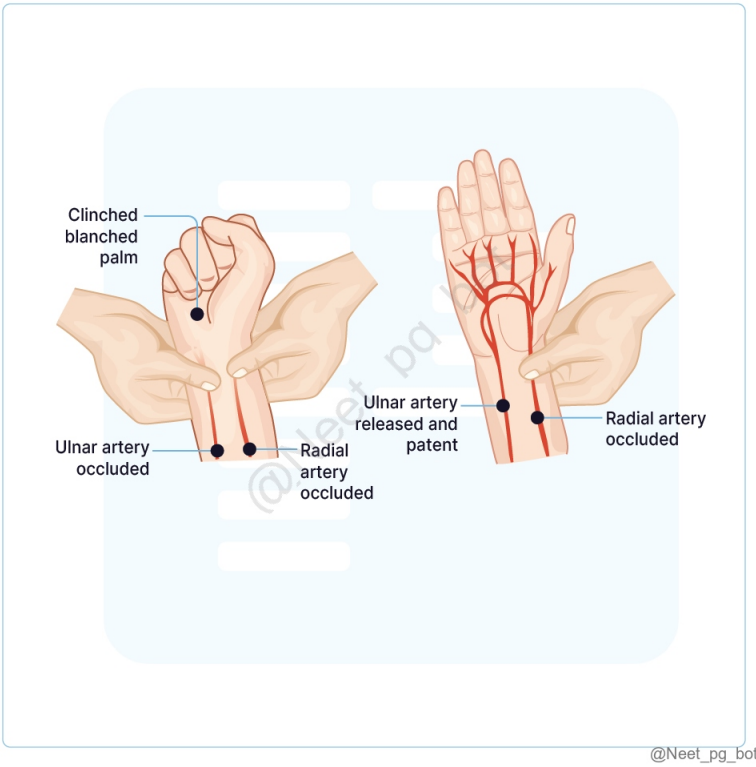

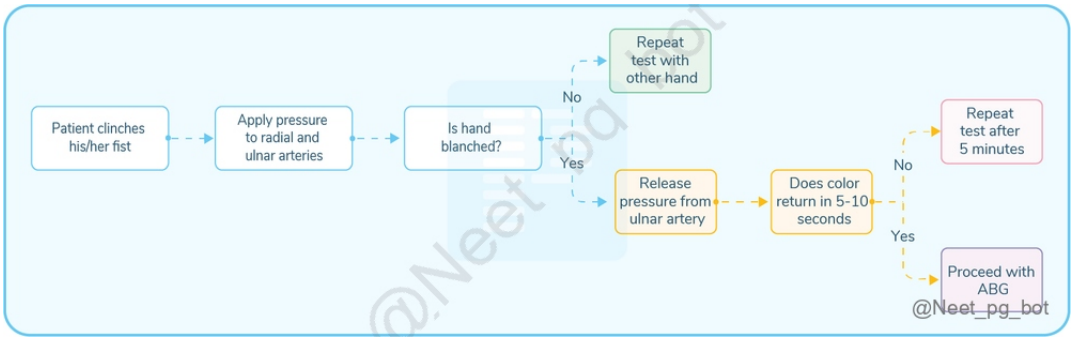

References:

https://www.ncbi.nlm.nih.gov/books/NBK507816/

↑ *Back to this question in Part A*

@Neet_pg_bot

Q19: A 28-year-old woman presents to the emergency department with anxiety, dizziness, and circumoral numbness. She also reports chest tightness and difficulty taking a deep breath. Physical examination reveals tachypnea and carpopedal spasms. Arterial blood gas shows pH: 7.48, PaCO2: 28 mmHg, HCO3: 22 mEq/L, PaO2: 98 mmHg. Which of the following sets of additional findings would be most consistent with this acid-base disorder? (Q851902)

A. Hypoxemia, cyanosis, and metabolic acidosis

B. Paresthesias, reduced cerebral blood flow and decreased ionized calcium

C. Hypertension, pulmonary edema, and increased ionized calcium

D. Somnolence, asterixis, and increased cerebral blood flow

Correct Answer: B. Paresthesias, reduced cerebral blood flow and decreased ionized calcium

Explanation: Diagnosis of respiratory alkalosis is supported by: Elevated pH (7.48) - indicates alkalemia Low PaCO2 (28 mmHg) - indicates primary respiratory disorder Slightly decreased HCO3- (22 mEq/L) - appropriate renal compensation Clinical features of respiratory alkalosis will include: Tachypnea Symptoms of hypocapnia Paresthesias from decreased ionized calcium due to alkalemia Reduced cerebral blood flow from hypocapnia Decreased ionized calcium causing tetany/carpopedal spasms Hypoxemia, cyanosis, and metabolic acidosis (Option A): This is incorrect because the patient's PaO■ is normal (98 mmHg), and metabolic acidosis would show a decreased HCO■■. Hypertension, pulmonary edema, and increased ionized calcium (Option C): This is incorrect as these findings are not associated with respiratory alkalosis. Increased ionized calcium does not occur in alkalotic states. Somnolence, asterixis, and increased cerebral blood flow (Option D): This would be more consistent with hypercapnia and respiratory acidosis, not respiratory alkalosis.

References:

Harrison's Principles of Internal Medicine, 21st Edition, Volume I, Page. 368

↑ *Back to this question in Part A*

@Neet_pg_bot

Q20: A 25-year-old pregnant woman at 28 weeks gestation presents with light-headedness and tingling sensations in her fingers. Her respiratory rate is 24/min.

Arterial blood gas shows: pH: 7.46 PaCO■: 32 mmHg HCO■■: 23 mEq/L Which of the following best explains the pathogenesis of her acid–base disturbance? (Q851802)

A. Direct CNS depression causing decreased respiratory drive

B. Progesterone-mediated increase in ventilatory response

C. Compensatory hyperventilation from metabolic acidosis

D. Increased tidal volume due to mechanical pressure of the gravid uterus

Correct Answer: B. Progesterone-mediated increase in ventilatory response

Explanation: During pregnancy, rising levels of progesterone stimulate the central respiratory centers , increasing sensitivity to CO■. As a result, the woman hyperventilates , blowing off more CO■ than usual. This leads to a chronic, mild respiratory alkalosis , characterized by: pH↑ (alkalemia) PaCO■↓ (hypocapnia) HCO■■ normal or mildly decreased due to renal compensation The patient's ABG (pH 7.46, PaCO■ 32, HCO■■ 23) matches this pattern perfectly. Symptoms such as light-headedness and tingling occur because hypocapnia causes cerebral vasoconstriction and increases calcium binding to albumin → transient paresth Direct CNS depression causing decreased respiratory drive (Option A): This would cause hypoventilation leading to respiratory acidosis , not alkalosis. Compensatory hyperventilation from metabolic acidosis (Options C): These suggest respiratory compensation for a primary metabolic acidosis . However, in this case, the HCO■■ is normal , and the pH is alkalemic , not acidemic. Therefore, the primary disturbance is respiratory , not metabolic. Increased tidal volume due to mechanical pressure of the gravid uterus (Options D) : Mechanical pressure from the uterus elevates the diaphragm, but does not directly cause hyperventilation or decreased CO■.

References:

Harrison's Principles of Internal Medicine, 21st Edition, Volume I, Page. 368

↑ *Back to this question in Part A*

@Neet_pg_bot

Q21: A 65-year-old man with severe COPD presents with worsening confusion and somnolence. Arterial blood gas shows: pH: 7.25 PaCO2: 70 mmHg HCO3: 32 mEq/L PaO2: 55 mmHg. Which of the following represents the most appropriate initial management approach? (Q851796)

A. Rapidly normalize PaCO2 with mechanical ventilation

B. Provide controlled oxygen therapy and treat underlying COPD exacerbation

C. Give sodium bicarbonate to correct acidemia

D. Observe and monitor without intervention

Correct Answer: B. Provide controlled oxygen therapy and treat underlying COPD exacerbation

Explanation: Diagnosis of Respiratory Acidosis is supported by: 1. ABG findings: Low pH (7.25) indicates acidemia Elevated PaCO2 (70 mmHg) indicates respiratory component Elevated HCO3- (32 mEq/L) indicates chronic compensation (HCO3- rises by 4 mEq/L per 10 mmHg rise in PaCO2 in chronic cases) 2. Clinical features matching chronic respiratory acidosis: Confusion and somnolence (due to chronic CO2 retention) Underlying COPD (common cause) Pattern suggests chronic respiratory acidosis with acute decompensation 3. Supporting factors: Age and COPD history appropriate for chronic respiratory acidosis Hypoxemia (PaO2 55 mmHg) common in COPD with respiratory acidosis The appropriate initial management would include controlled oxygen therapy and treating COPD exacerbation because: Controlled oxygen to avoid worsening hypercapnia Addresses underlying COPD exacerbation Balancing the risk of hypoxemia and hypercapnia Allows gradual correction of acidosis Rapidly normalize PaCO■ with mechanical ventilation (Option A): Rapid normalization of PaCO■ in COPD patients can risk respiratory alkalosis and severe electrolyte shifts, which may worsen confusion and cardiovascular stability. Non-invasive ventilation (e.g., BiPAP) may be used if needed for ventilatory support, but CO■ reduction is typically gradual. Give sodium bicarbonate to correct acidemia (Option C): Sodium bicarbonate is usually avoided in COPD exacerbations with respiratory acidosis because it can worsen CO■ retention by buffering the acid and driving CO■ production, which would be counterproductive in this case. Observe and monitor without intervention (Option D): This is not appropriate given the patient's confusion, somnolence, and significant hypercapnia, which require immediate medical intervention to prevent further deterioration.

References:

Harrison's Principles of Internal Medicine, 21st Edition, Volume I, Page.367, 368

↑ *Back to this question in Part A*

@Neet_pg_bot

Q22: A 68-year-old man with severe COPD presents with progressive confusion, daytime sleepiness, and morning headaches over the past month. On examination, he has a coarse tremor and asterixis. Arterial blood gas shows pH 7.32, PaCO2 68 mmHg, HCO3- 34 mEq/L. Which combination of additional findings would be most consistent with this patient's acid-base disorder? (Q851794)

A. Acute anxiety, hallucinations, and respiratory distress

B. Sleep disorders, personality changes, and polycythemia

C. Acute dyspnea, psychosis, and normal bicarbonate

D. Muscle weakness, confusion, and metabolic acidosis

Correct Answer: B. Sleep disorders, personality changes, and polycythemia

Explanation: This patent demonstrates the features of chronic respiratory acidosis: Elevated PaCO2 (68 mmHg) Compensatory HCO3- elevation (34 mEq/L) Compatible with chronic compensation (4 mEq/L rise in HCO3- per 10 mmHg rise in PaCO2) Gradual onset of symptoms Clinical features match chronic presentation: Neurological: Confusion Daytime somnolence Asterixis Tremor Systemic: Morning headaches Sleep disorders Personality changes Polycythemia (compensatory to chronic hypoxemia) Acute anxiety, hallucinations, and respiratory distress (Option A): These are more typical of acute respiratory alkalosis , not chronic compensated acidosis. Acute dyspnea, psychosis, and normal bicarbonate (Option C): Suggests acute respiratory acidosis without renal compensation (normal HCO■■), which doesn't fit this patient's compensated picture. Muscle weakness, confusion, and metabolic acidosis (Option D): These findings align with metabolic , not respiratory, acidosis—and this patient has respiratory acidosis .

References:

Harrison's Principles of Internal Medicine, 21st Edition, Volume I, Page.367, 368

↑ *Back to this question in Part A*

@Neet_pg_bot

• [10_Pulmonology] 083 Images In Pulmonology

« Back to Folder Directory

[10_Pulmonology] 083 Images In Pulmonology — Quick Jump

Q1 (p. 3001) *Q2 (p. 3002)* *Q3 (p. 3005)* *Q4 (p. 3006)* *Q5 (p. 3008)* *Q6 (p. 3009)*
Q7 (p. 3010) *Q8 (p. 3011)* *Q9 (p. 3013)* *Q10 (p. 3016)* *Q11 (p. 3017)*

Q1: A 62-year-old male with a history of smoking presents with chronic cough, weight loss, and recent hemoptysis. A chest X-ray is done and is provided below. Which of the following is the most likely primary source of this lesion? (Q851891)

A. Renal cell carcinoma

B. Breast carcinoma

C. Gastric adenocarcinoma

D. Thyroid carcinoma

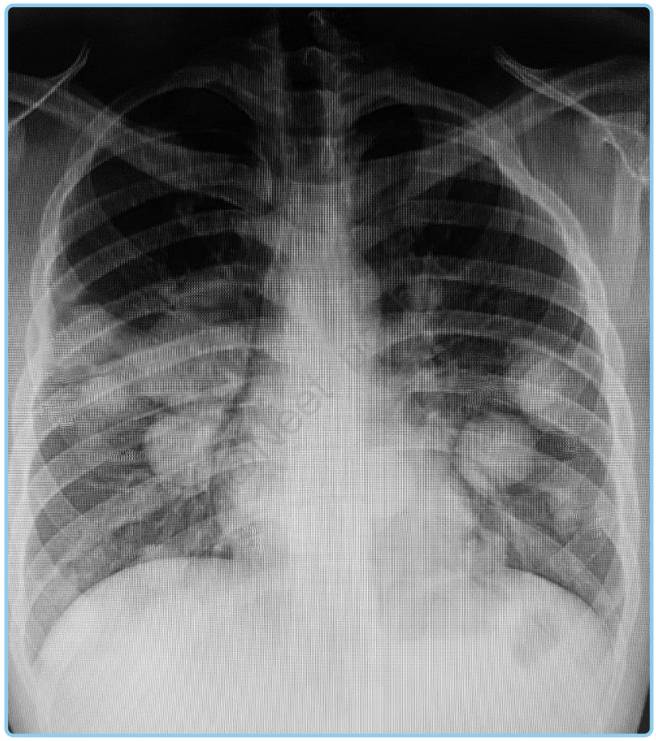

Correct Answer: A. Renal cell carcinoma

Explanation: Renal cell carcinoma is a common cause of cannonball metastases due to its vascular nature and tendency for hematogenous spread. It presents as large, well-defined pulmonary nodules. Patients with RCC commonly have associated symptoms such as hematuria, flank pain, or palpable mass, but lung metastases can often be the initial presentation in advanced cases. The cannonball appearance is characteristic of metastatic RCC on chest imaging. Breast Carcinoma (Option B): Breast carcinoma is one of the most common malignancies to metastasize to the lungs, but its pulmonary metastases often present as ill-defined or pleural-based lesions rather than as large, well-circumscribed nodules. Gastric Adenocarcinoma (Option C): Gastric cancer can spread to the lungs, but this usually occurs as lymphangitic spread or multiple small nodules rather than large, rounded lesions. Cannonball metastases are atypical for gastric cancer as this more frequently spreads through peritoneal seeding or involves lymph nodes. Thyroid Carcinoma (Option D): Thyroid carcinoma, particularly follicular type, can metastasize to the lungs and other distant organs; however, it generally presents with smaller, less distinct pulmonary nodules rather than cannonball lesions. Cannonball metastases are not typical of thyroid malignancies.

References:

https://radiopaedia.org/articles/cannonball-metastasis-mnemonic-1

https://radiopaedia.org/articles/cannonball-metastases-lungs

↑ *Back to this question in Part A*

@Neet_pg_bot

Q2: A 65-year-old male with a history of chronic liver disease presents with progressive shortness of breath, fatigue, and mild chest discomfort over the past few weeks. On examination, there is decreased bilateral breath sound intensity with dullness on percussion at the lung bases. A chest X-ray shows the following features. What is the most likely diagnosis? (Q851894)

A. Bilateral Hydrothorax

B. Empyema Thoracis

C. Hydropneumothorax

D. Congestive Heart Failure with Pleural Effusion

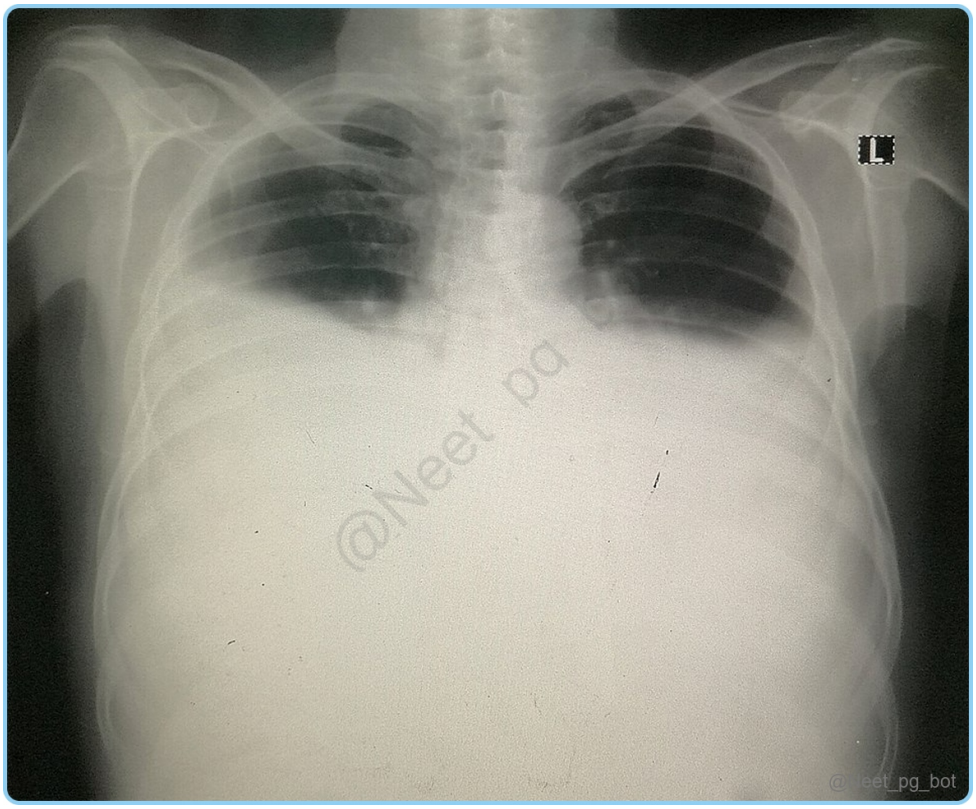

Correct Answer: A. Bilateral Hydrothorax

Explanation: In this case, the clinical picture and imaging findings suggest a diagnosis of bilateral hydrothorax, particularly given the patient's background of chronic liver disease. Hepatic hydrothorax can develop in patients with advanced liver disease due to transudative fluid accumulation, often through diaphragmatic defects, into the pleural spaces. The absence of air-fluid levels, along with bilaterally homogeneous pleural fluid without signs of infection, supports the diagnosis of hydrothorax over other options. {{caption_text}} Fig: Left-sided biconvex pleural collection along the lateral chest wall. The obtuse angle with the chest wall indicates this arising from the pleural space. Hydropneumothorax (Option C): Hydropneumothorax shows an air-fluid level on upright imaging, with a clear demarcation between air and fluid in the pleural cavity . {{caption_text}} Congestive Heart Failure with Pleural Effusion (Option D): Pleural effusions in CHF are often accompanied by features of pulmonary edema, including perihilar congestion, interstitial markings, and cardiomegaly . {{caption_text}}

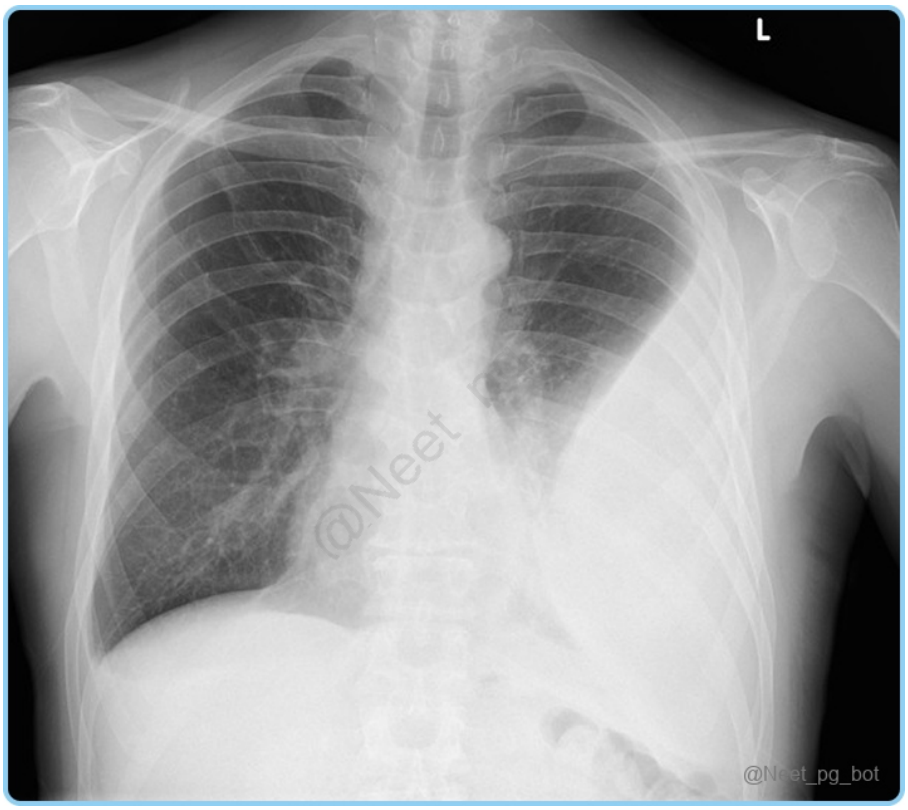
L
@Neet_pg_bot

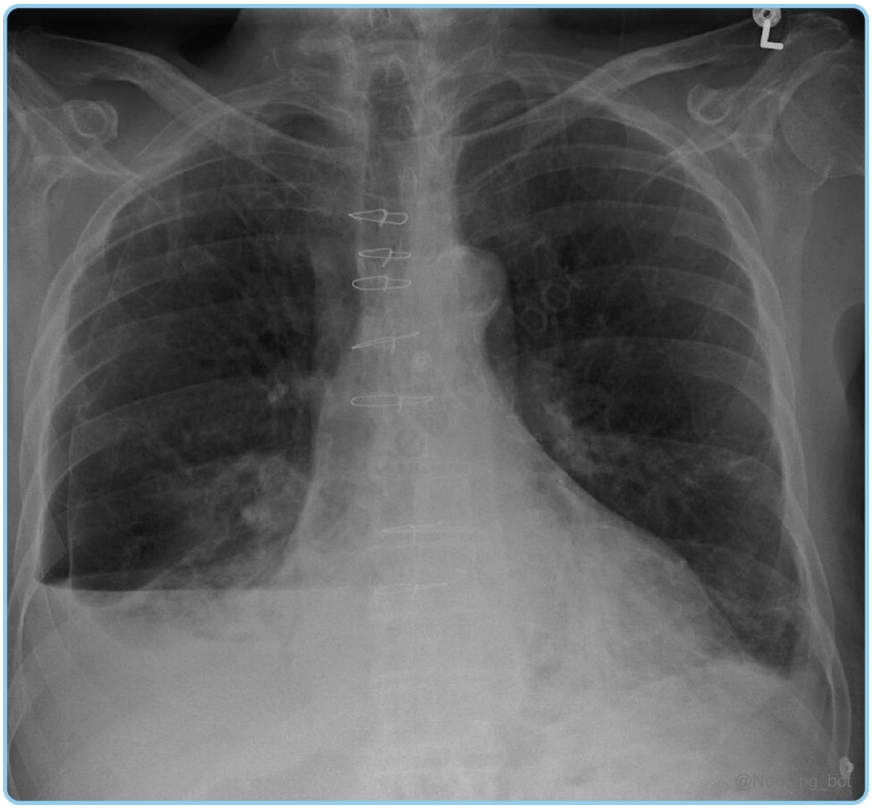
L

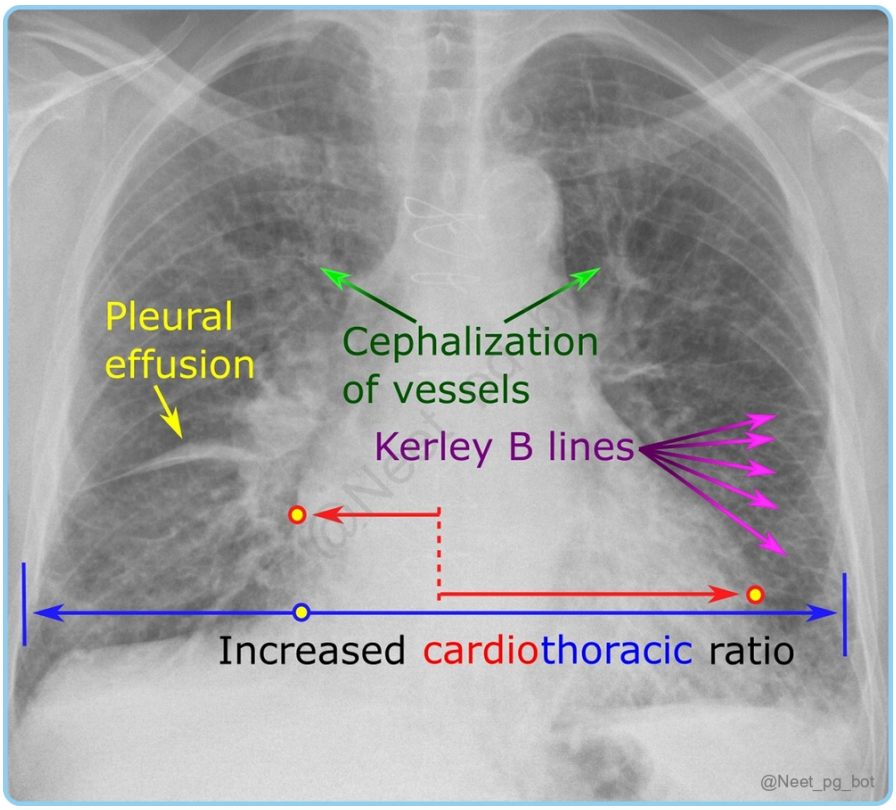

References:

https://www.ncbi.nlm.nih.gov/books/NBK448189/#article-20929.s9

https://www.ncbi.nlm.nih.gov/books/NBK544279/

https://radiopaedia.org/articles/hydropneumothorax

↑ *Back to this question in Part A*

@Neet_pg_bot

Q3: A 65-year-old man visits OPD with the following presentation as shown in the image. His chest CT shows bronchiectasis. Which of the following statements is incorrect regarding this patient's digital finding? (Q851897)

A. The condition involves proliferation of connective tissue at the nail base

B. It can be associated with cystic fibrosis and lung cancer

C. The condition always indicates irreversible tissue changes

D. The pathogenesis involves platelet-derived growth factors

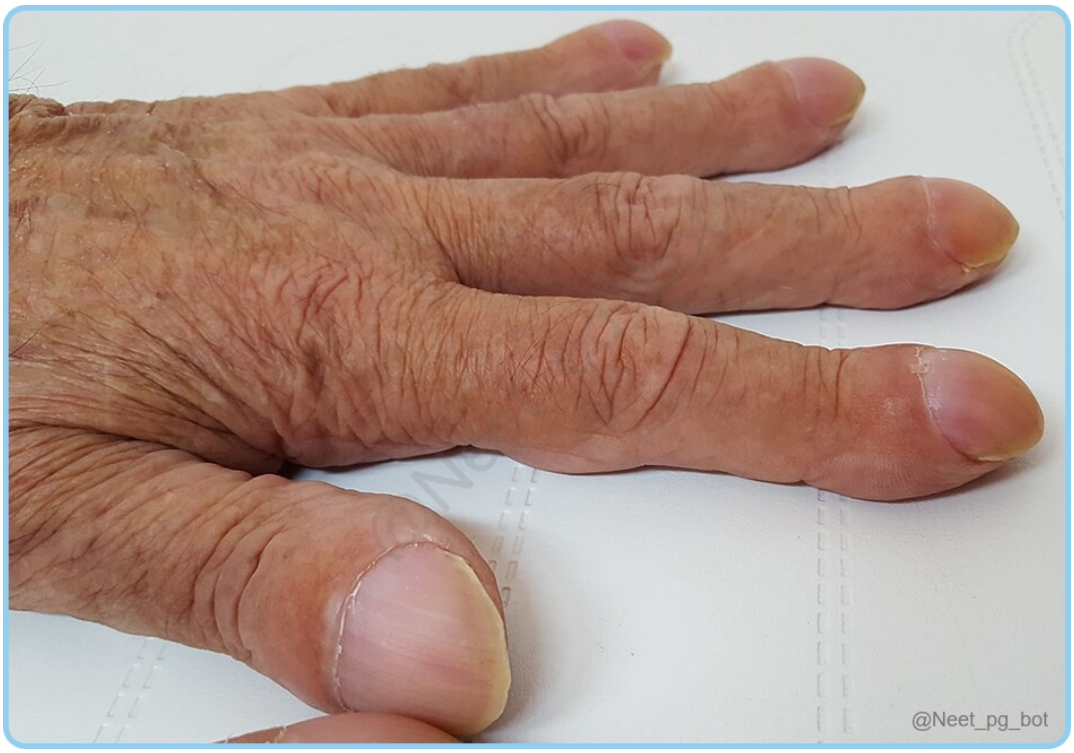

Correct Answer: C. The condition always indicates irreversible tissue changes

Explanation: The image shows typical findings of clubbing of fingers, seen in various cardiopulmonary conditions. Clubbing is not always irreversible and can be reversible in certain conditions. Clubbing of Fingers Definition • Enlargement of distal segments of fingers and toes • Proliferation of connective tissue (Option A) • Particularly on dorsal surface • Changes at base of clubbed nail Pathophysiology • Connective tissue proliferation • Exact mechanism unknown • Platelet-derived growth factors implicated (Option D) Associated Conditions • Cyanotic congenital heart disease • Infective endocarditis • Bronchiectasis • Cystic Fibrosis (Option B) • Lung cancer • Tuberculosis • Inflammatory bowel disease

References:

Harrison's Principles of Internal Medicine, 21st Edition, Volume I, Page. 275

↑ *Back to this question in Part A*

@Neet_pg_bot

Q4: A 25-year-old male presents to the emergency department with sudden onset of right-sided chest pain and mild shortness of breath. He is tall, thin, and a smoker. Physical examination reveals decreased breath sounds on the right side with hyperresonance on percussion. Chest X-ray is given below. The patient is hemodynamically stable with oxygen saturation of 96% on room air. What is the most appropriate initial management? (Q851899)

A. Discharge with follow-up in 2-4 weeks

B. Needle aspiration

C. Immediate tube thoracostomy

D. High-flow oxygen and observation for 24 hours

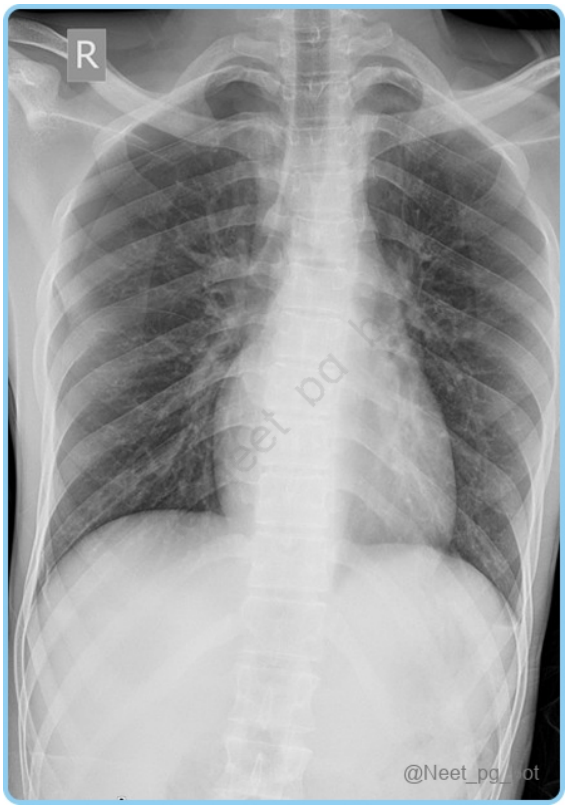

Correct Answer: B. Needle aspiration

Explanation: This case presents a primary spontaneous pneumothorax (PSP) in a typical patient (young, tall, thin male who smokes). According to management guidelines, in PSP: If size > 2 cm and patient is symptomatic, needle aspiration is the initial step If after aspiration the residual depth is < 2 cm and patient improves, they can be discharged If aspiration fails, tube thoracostomy is indicated Discharge with follow-up in 2-4 weeks (Option A): Discharge with follow-up is only appropriate for asymptomatic patients with small (<2 cm) pneumothorax Immediate tube thoracostomy (Option C) is too aggressive as first-line treatment for a stable PSP; it's reserved for failed needle aspiration or unstable patients High-flow oxygen and observation for 24 hours (Option D): High-flow oxygen and observation is more appropriate for small (<1 cm) secondary spontaneous pneumothorax

References:

www.ncbi.nlm.nih.gov/books/NBK441885/

↑ *Back to this question in Part A*

@Neet_pg_bot

Q5: A 28-year-old male is brought to the emergency department after a motor vehicle accident with chest trauma. He is in severe respiratory distress with BP 80/50 mmHg, HR 142/min, RR 32/min. Physical examination reveals absent breath sounds. The X-ray is attached below. What is the most appropriate next step in management? (Q851903)

A. CT Head for identifying possible cerebral injury

B. Start high-flow oxygen

C. Immediate needle decompression

D. Intercostal tube

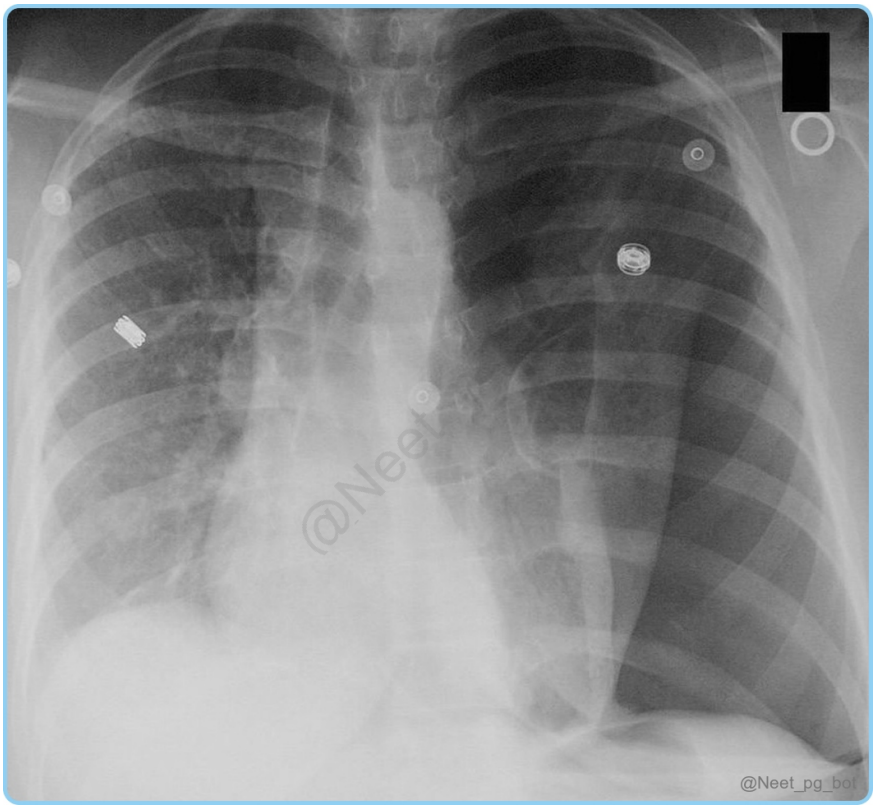

Correct Answer: C. Immediate needle decompression

Explanation: The case presents a classic presentation of tension pneumothorax, characterized by: Severe respiratory distress Hypotension (BP 80/50) Tachycardia (HR 142) Absent breath sounds and hyperresonance Tracheal deviation to contralateral side History of trauma {{caption_text}} Management • Immediate: Needle decompression • Definitive: Tube thoracostomy • Follow-up: Pleurodesis consideration CT Head for identifying possible cerebral injury (Option A): Although CT head is to be done according to the protocol, the clinically

obvious tension pneumothorax with hemodynamic compromise is a medical emergency and needs to be treated promptly. High-flow oxygen (Option B): Insufficient treatment for tension pneumothorax with hemodynamic compromise Tube thoracostomy (Option D): While this is the definitive treatment, immediate needle decompression should be performed first in an unstable patient as it's quicker and can provide immediate relief of the tension component

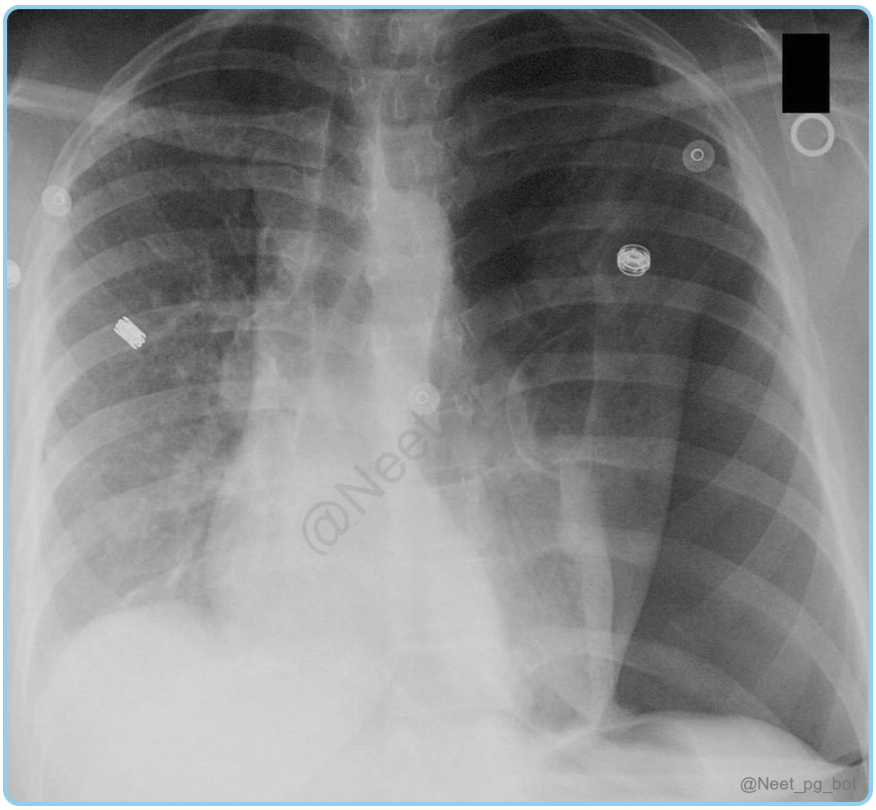

References:

Davidson's Principles and Practice of Medicine, 24th Edition, Page 625, 626, 627

↑ *Back to this question in Part A*

@Neet_pg_bot

Q6: A 68-year-old female receiving a blood transfusion for severe anemia develops acute dyspnea, tachypnea, and hypertension 30 minutes into the transfusion. Her blood pressure is 168/95 mmHg, and chest auscultation reveals bilateral crackles. Which of the following represents the most appropriate immediate management? (Q851908)

A. Continue transfusion but at a slower rate

B. Stop transfusion and administer diuretics

C. Administer acetaminophen and continue transfusion

D. Stop transfusion and start steroids

Correct Answer: B. Stop transfusion and administer diuretics

Explanation: This case presents classic symptoms of Transfusion-Associated Circulatory Overload (TACO) : TACO is a common and underrecognized transfusion adverse reaction Clinical features include dyspnea, hypertension, bilateral crackles Management explicitly requires stopping the transfusion and administration of O2 and diuretics Continue transfusion but at a slower rate (Option A): Continuing transfusion even at a slower rate would worsen fluid overload Administer acetaminophen and continue transfusion (Option C): Acetaminophen would not address the underlying fluid overload Stop transfusion and start steroids (Option D): Steroids are not indicated in the management of TACO according to the provided information

References:

Harrison’s Principles of Internal Medicine, 21st Edition, Volume I, Page. 895

↑ *Back to this question in Part A*

@Neet_pg_bot

Q7: A 65-year-old male presents to the emergency department with acute dyspnea and bilateral crackles. His blood pressure is 160/90 mmHg, heart rate 110/min, and respiratory rate 28/min. Physical examination reveals jugular venous distention, bilateral pedal edema, and an S3 gallop. Chest X-ray is given below. His pulmonary capillary wedge pressure (PCWP) is 25 mmHg. Which of the following is the most appropriate initial management? (Q851914)

A. High-flow oxygen and observation

B. Immediate intubation

C. IV furosemide and nitrates

D. Antibiotics and steroids

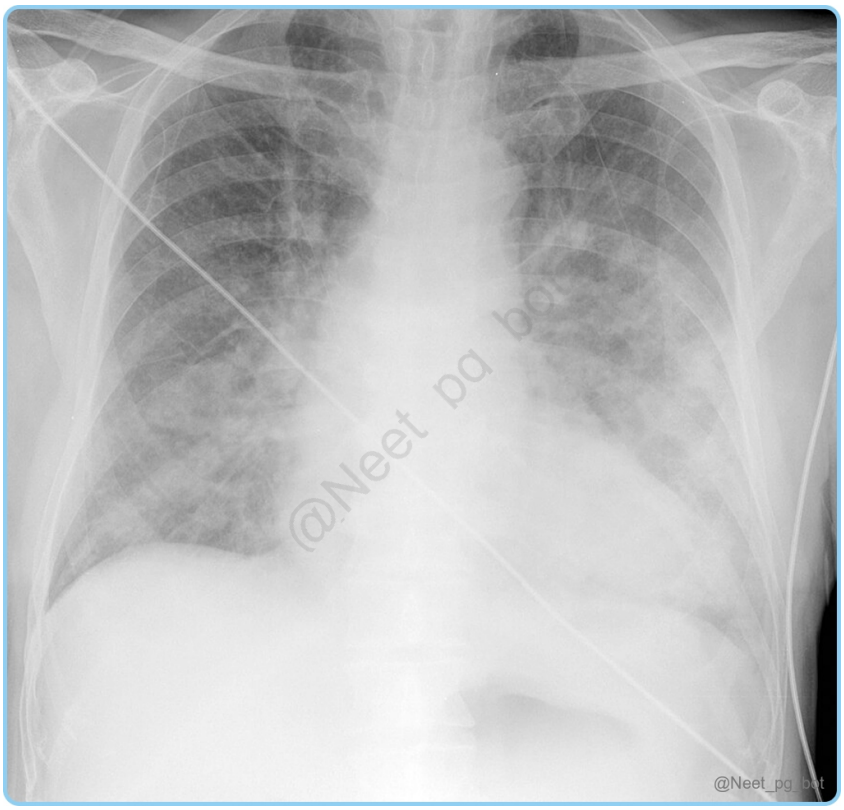

Correct Answer: C. IV furosemide and nitrates

Explanation: The case presents classic cardiogenic pulmonary edema with characteristic features including elevated PCWP (>18 mmHg), JVD, pedal edema, and S3 gallop. Also the chest X-ray shows cardiomegaly and mild pulmonary edema with widening of the vascular pedicle (red arrow) and interstitial prominence. High-flow oxygen and observation (Option A): High-flow oxygen alone is insufficient for cardiogenic pulmonary edema requiring preload reduction Immediate intubation (Option B) is not necessary unless non-invasive measures fail Antibiotics and steroids (Option D): Antibiotics and steroids are more appropriate for certain types of non-cardiogenic pulmonary edema, but not in cardiogenic pulmonary edema.

References:

1. www.ncbi.nlm.nih.gov/books/NBK544260/ 2. www.ncbi.nlm.nih.gov/books/NBK542230/

↑ *Back to this question in Part A*

@Neet_pg_bot

Q8: A 65-year-old male with a 40-pack-year smoking history presents with progressive dyspnea, productive cough, and weight loss. Physical examination reveals a barrel chest, decreased breath sounds, and prolonged expiration. Chest X-ray is given below. His FEV1/FVC ratio is 0.65 and doesn't improve with bronchodilators. Which of the following is the most likely pathological finding in this patient?

(Q851921)

A. Inflammation of bronchial walls with mucus hypersecretion

B. Permanent enlargement of airspaces distal to terminal bronchioles

C. Bronchial wall thickening with reversible airway obstruction

D. Interstitial fibrosis with restrictive pattern

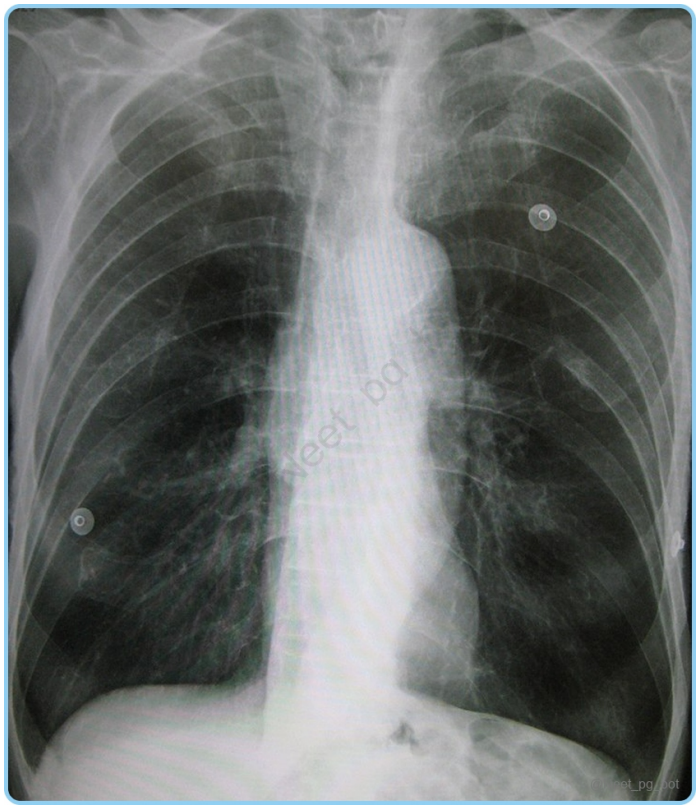

Correct Answer: B. Permanent enlargement of airspaces distal to terminal bronchioles

Explanation: The clinical scenario of a smoker with dyspnea, cough, weight loss along with barrel chest and reduced FEV1/FVC ratio with an x-ray image showing hyperinflation & increased lung volume suggests classic emphysema where Permanent enlargement of airspaces distal to terminal bronchioles are seen. Inflammation of bronchial walls with mucus hypersecretion (Option A): This describes chronic bronchitis , characterised by a productive cough for at least 3 months over 2 consecutive years. While this patient has a productive cough, the key radiographic and clinical signs (barrel chest, hyperinflation, decreased breath sounds) are more consistent with emphysema , not bronchitis alone. Bronchial wall thickening with reversible airway obstruction (Option C): This describes asthma , which is characterized by reversible bronchoconstriction, often improving with bronchodilators. However, this patient's airflow obstruction is not reversible , and his age, smoking history, and imaging are more consistent with COPD. Interstitial fibrosis with restrictive pattern (Option D): This describes interstitial lung disease (ILD) , which leads to a restrictive pattern on spirometry (reduced FEV1 and FVC, but normal or increased FEV1/FVC). This patient instead has an obstructive pattern (low FEV1/FVC), making ILD unlikely.

References:

www.ncbi.nlm.nih.gov/books/NBK482217/

↑ *Back to this question in Part A*

@Neet_pg_bot

Q9: A 55-year-old man with a history of deep vein thrombosis is brought to the emergency department by his wife after he suddenly developed sharp, stabbing chest pain and shortness of breath while at home. He describes the pain as worse when taking a deep breath. The X-ray taken is displayed below. What is the most likely diagnosis? (Q851924)

A. Pneumonia

B. Atelectasis

C. Pulmonary infarction due to pulmonary embolism

D. Lung abscess

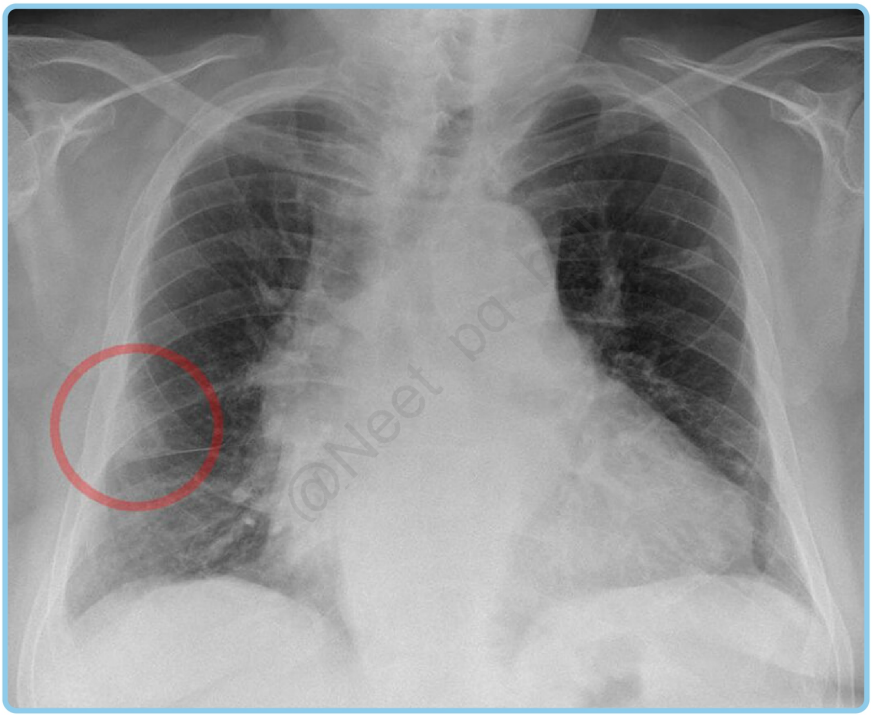

Correct Answer: C. Pulmonary infarction due to pulmonary embolism

Explanation: The wedge-shaped opacity pointing toward the hilum is characteristic of Hampton's Hump , a classic radiologic finding associated with pulmonary infarction due to pulmonary embolism (PE). The sudden onset of pleuritic chest pain and the patient's history of DVT make PE the most likely diagnosis. Hampton's Hump is a radiologic sign seen in cases of pulmonary embolism (PE) and is indicative of a pulmonary infarction. {{caption_text}} Pneumonia Pneumonia (Option A), is incorrect as pneumonia usually presents on X-ray as a patchy or lobar consolidation , often not triangular or pleural-based . {{caption_text}} Atelectasis Atelectasis (Option B), is incorrect as atelectasis usually presents on X-ray as linear or wedge-shaped opacities but tends to involve volume loss or shifting of adjacent structures , such as the trachea or mediastinum, toward the affected area. {{caption_text}} Lung abscess Lung Abscess (Option D), is incorrect as a lung abscess usually presents on x-ray as a localized cavity with an air-fluid level if communicating with an airway .

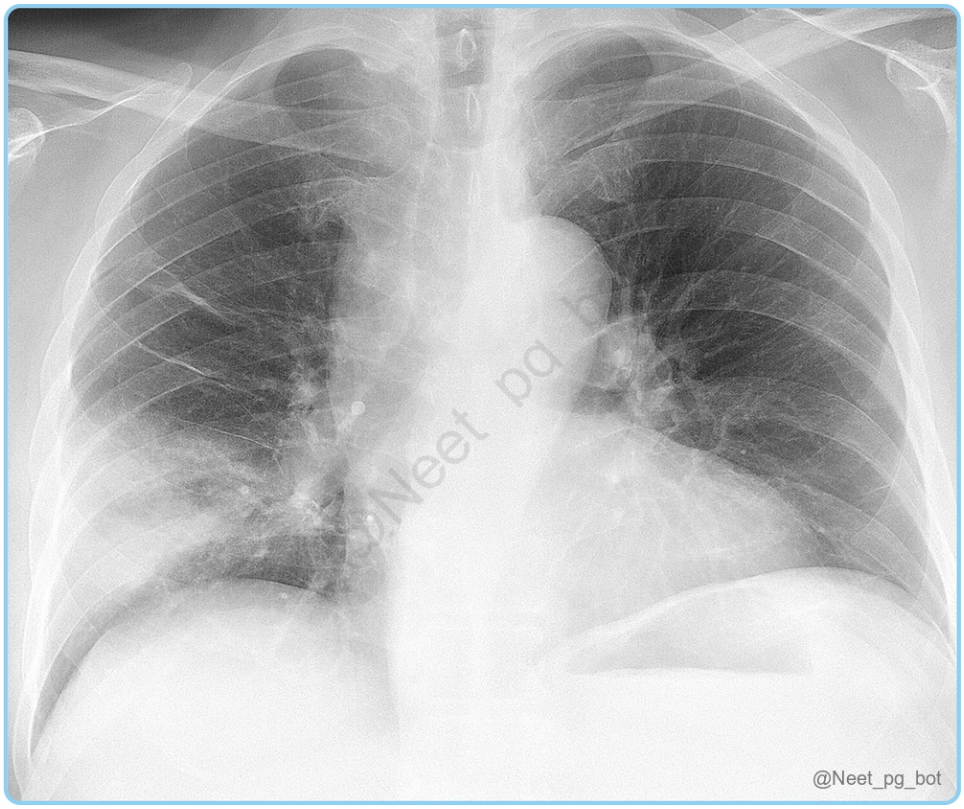

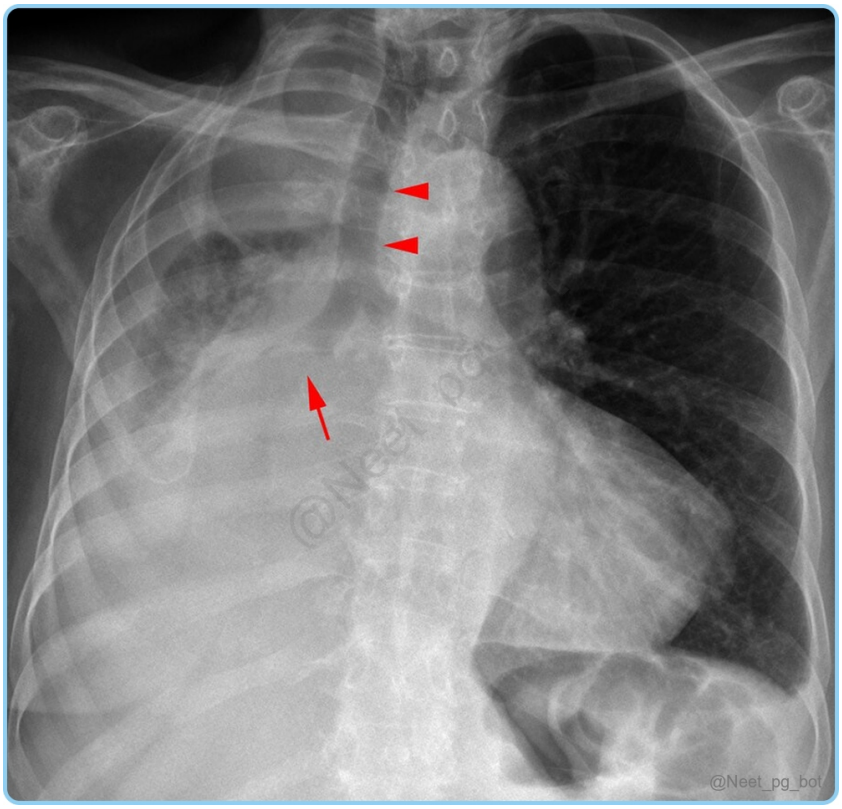

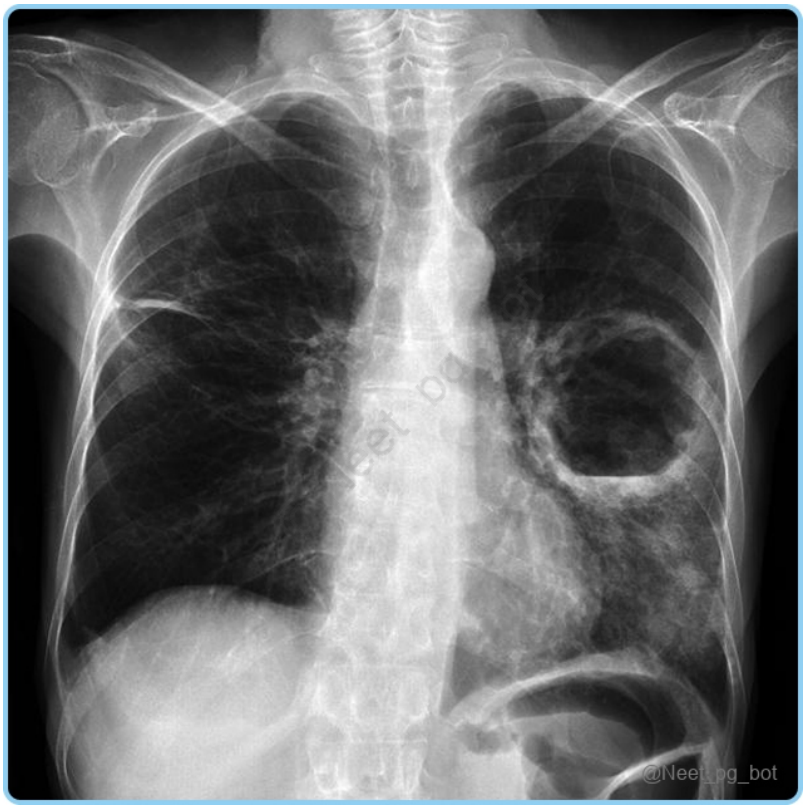

References:

Grainger & Allison's Diagnostic Radiology, 7th Edition, Page 412

↑ *Back to this question in Part A*

@Neet_pg_bot

Q10: A 65-year-old male patient presents to the pulmonary clinic with a history of progressive shortness of breath and a chronic cough. He is a long-term smoker and has a family history of respiratory diseases. A spirometry test is performed, and the flow-volume loop is plotted. What is the most likely diagnosis based on the patient's symptoms and the shape of his flow-volume loop? (Q851927)

A. Restrictive lung disease

B. Obstructive lung disease

C. Normal lung function

D. Fixed upper airway obstruction

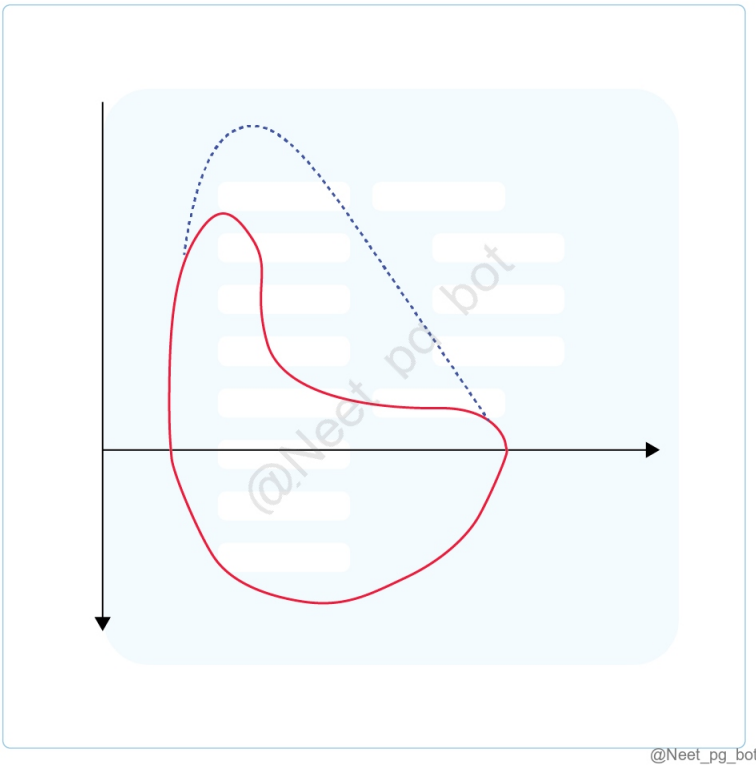

Correct Answer: B. Obstructive lung disease

Explanation: The scooped-out pattern on expiration is a classic finding in obstructive diseases like COPD, which often presents in smokers with chronic symptoms like the patient. Flow-volume loops can display distinct patterns,

each associated with different types of respiratory conditions. Types of Flow-Volume Loops: {{caption_text}} Flow volume curve loop types and examples: Loop Type Expiratory Curve Inspiratory Curve Example Conditions Normal Symmetrical, peaked Symmetrical, rounded Healthy lungs (Option C ruled out) Restrictive Narrow, peaked Narrow, peaked Pulmonary fibrosis, pleural effusion (Option A ruled out) Fixed Upper Airway Obstruction Flattened (box-like) Flattened (box-like) Tracheal stenosis, large goiter (Option D ruled out)

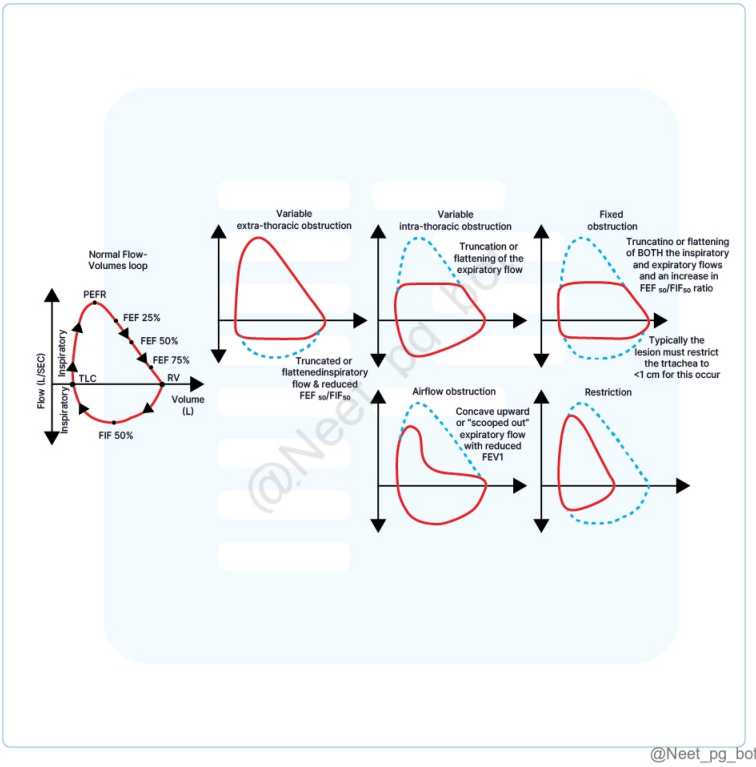

@Neet_pg_bot

References:

Harrison's Principles of Internal Medicine, 21st Edition, Page 2134 to 2138

↑ *Back to this question in Part A*

@Neet_pg_bot

Q11: Match the Condition with the Correct Description on X-ray: 1. Pneumatocele a. 2. Tuberculosis (TB) b. 3. Miliary TB c. 4. Lung Abscess d. (Q851928)

A. 1 - b, 2 - c, 3 - a, 4 - d

B. 1 - a, 2 - b, 3 - c, 4 - d

C. 1 - d, 2 - c, 3 - b, 4 - a

D. 1 - c, 2 - b, 3 - d, 4 - a



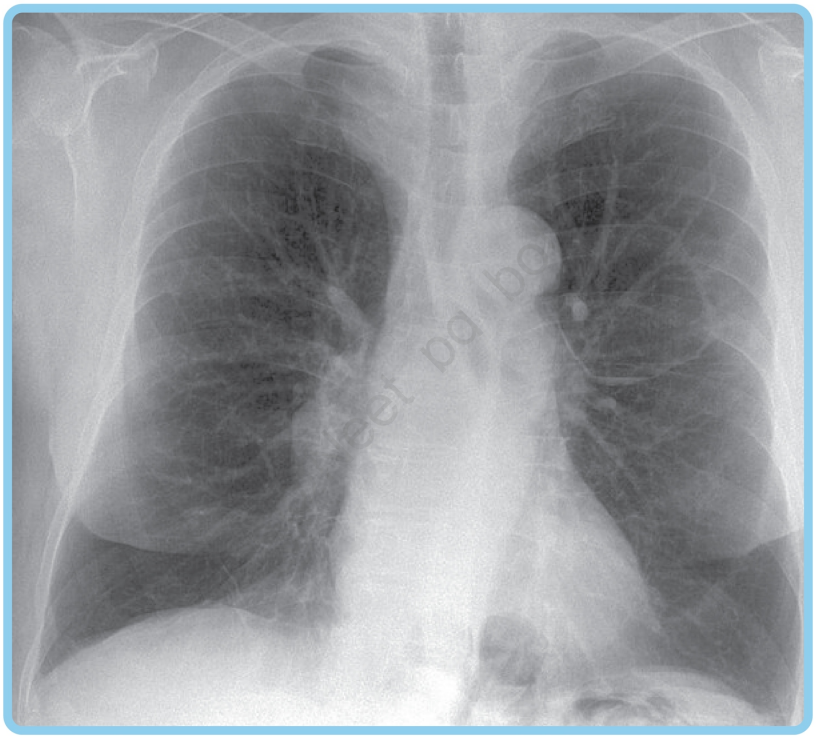

@Neet_pg_bot



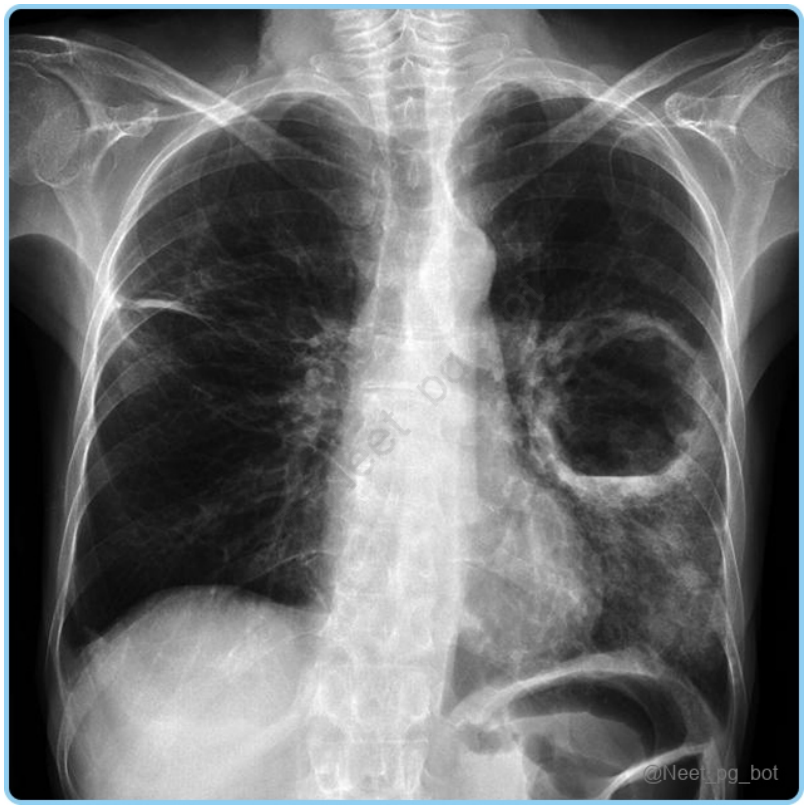

Correct Answer: A. 1 - b, 2 - c, 3 - a, 4 - d

Explanation: Pneumatocele - Image (b) Tuberculosis (TB) - Image (c) Miliary TB - Image (a) Lung Abscess - Image (d) Pneumatocele (Image b): Appears as a thin-walled, air-filled cyst in the lung, often resulting from trauma, infection (like staphylococcal pneumonia), or positive pressure ventilation. It usually resolves on its own but can occasionally rupture, leading to pneumothorax. {{caption_text}} Tuberculosis (Image c): Presents as a localized area of lung consolidation , often in the upper lobe . Miliary TB (Image a): Appears as multiple small, uniformly distributed nodules throughout both lungs . It is a severe, disseminated form of TB where the bacteria spread through the bloodstream, leading to numerous tiny nodules scattered across the lungs and other organs. It gets its name because the nodules resemble millet seeds on imaging . Miliary TB is often seen in immunocompromised individuals. {{caption_text}} Lung Abscess (Image d): It often appears as a thick-walled cavity with air-fluid levels on imaging. {{caption_text}}

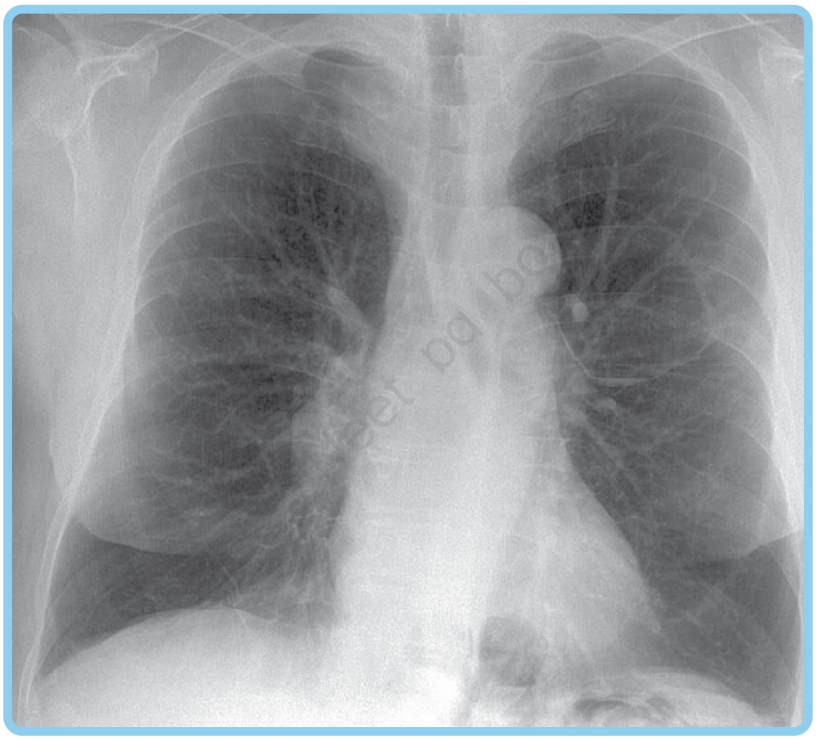

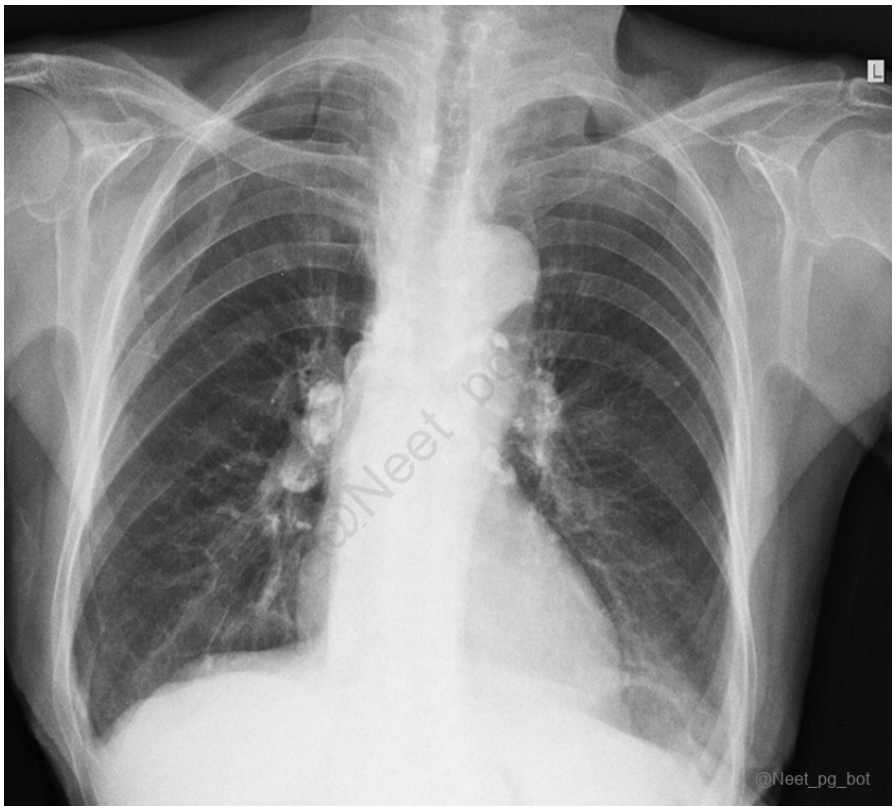
L
@Neet_pg_bot

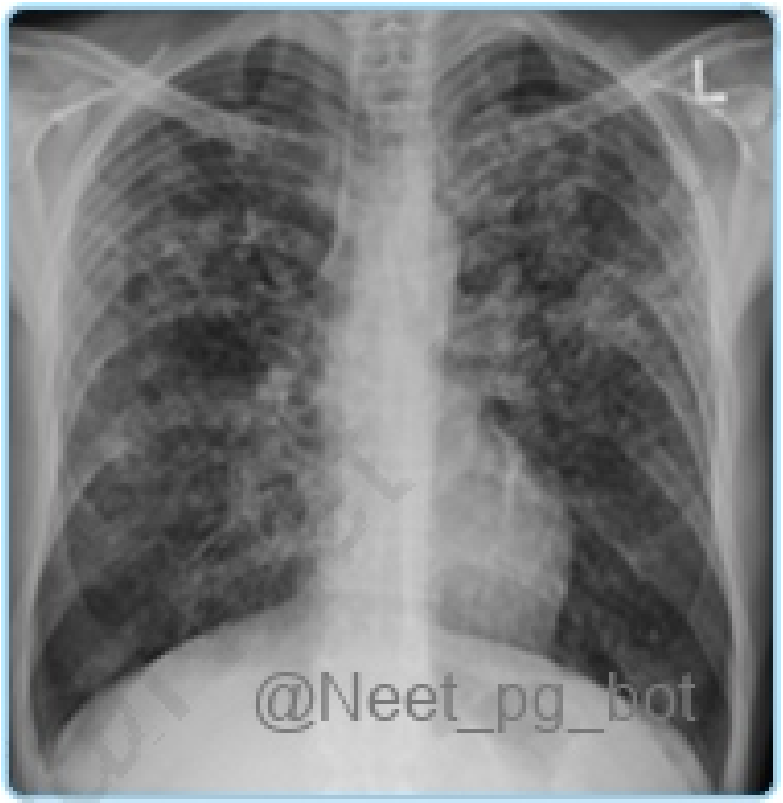
L
@Neet_pg_bot

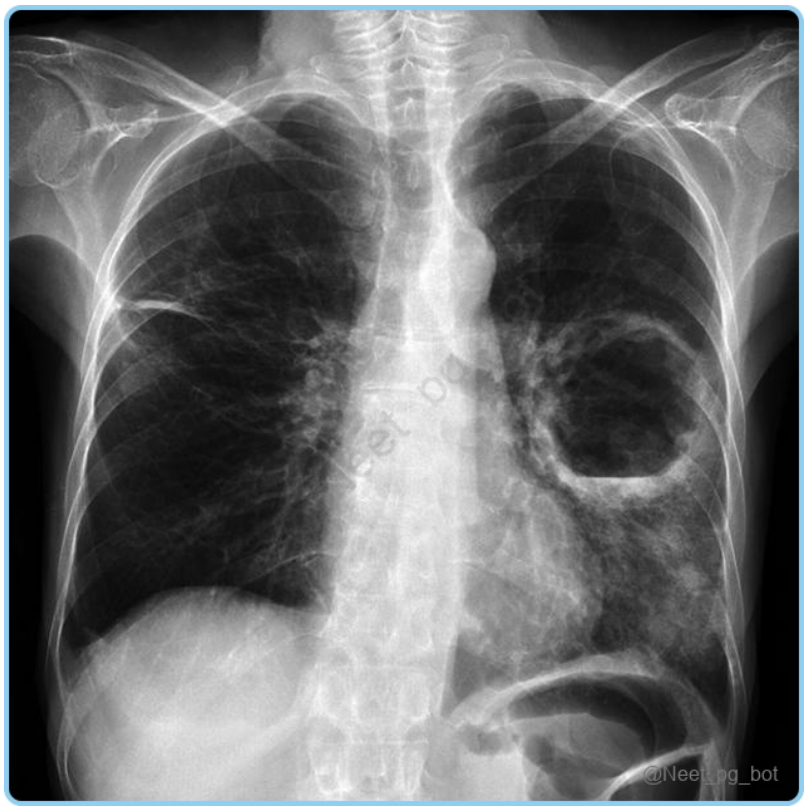

References:

Grainger & Allison’s Diagnostic Radiology, 7th Edition, Page 107, 1787, 1788

↑ *Back to this question in Part A*

@Neet_pg_bot

• [10_Pulmonology] 084 Previous Year Questions

« Back to Folder Directory

[10_Pulmonology] 084 Previous Year Questions — Quick Jump

Q1 (p. 3023)	*Q2 (p. 3025)*	*Q3 (p. 3026)*	*Q4 (p. 3027)*	*Q5 (p. 3028)*	*Q6 (p. 3030)*
Q7 (p. 3030)	*Q8 (p. 3031)*	*Q9 (p. 3032)*	*Q10 (p. 3033)*	*Q11 (p. 3034)*	*Q12 (p. 3035)*
Q13 (p. 3037)	*Q14 (p. 3038)*	*Q15 (p. 3038)*	*Q16 (p. 3040)*	*Q17 (p. 3041)*	*Q18 (p. 3042)*
Q19 (p. 3043)	*Q20 (p. 3045)*	*Q21 (p. 3046)*	*Q22 (p. 3047)*	*Q23 (p. 3048)*	*Q24 (p. 3051)*
Q25 (p. 3052)	*Q26 (p. 3053)*	*Q27 (p. 3054)*	*Q28 (p. 3055)*	*Q29 (p. 3055)*	*Q30 (p. 3056)*
Q31 (p. 3057)	*Q32 (p. 3057)*	*Q33 (p. 3058)*	*Q34 (p. 3059)*	*Q35 (p. 3059)*	*Q36 (p. 3060)*
Q37 (p. 3062)	*Q38 (p. 3066)*	*Q39 (p. 3071)*	*Q40 (p. 3072)*	*Q41 (p. 3073)*	*Q42 (p. 3075)*
Q43 (p. 3079)	*Q44 (p. 3080)*	*Q45 (p. 3080)*	*Q46 (p. 3082)*	*Q47 (p. 3083)*	*Q48 (p. 3084)*
Q49 (p. 3085)	*Q50 (p. 3086)*	*Q51 (p. 3087)*	*Q52 (p. 3088)*	*Q53 (p. 3089)*	*Q54 (p. 3090)*
Q55 (p. 3091)	*Q56 (p. 3092)*	*Q57 (p. 3093)*	*Q58 (p. 3095)*	*Q59 (p. 3096)*	*Q60 (p. 3098)*
Q61 (p. 3098)	*Q62 (p. 3100)*	*Q63 (p. 3100)*	*Q64 (p. 3102)*	*Q65 (p. 3102)*	*Q66 (p. 3103)*
Q67 (p. 3104)	*Q68 (p. 3105)*	*Q69 (p. 3106)*	*Q70 (p. 3106)*	*Q71 (p. 3108)*	*Q72 (p. 3108)*
Q73 (p. 3109)	*Q74 (p. 3110)*	*Q75 (p. 3112)*	*Q76 (p. 3115)*	*Q77 (p. 3117)*	*Q78 (p. 3118)*
Q79 (p. 3119)	*Q80 (p. 3119)*	*Q81 (p. 3120)*	*Q82 (p. 3123)*	*Q83 (p. 3125)*	*Q84 (p. 3126)*
Q85 (p. 3127)	*Q86 (p. 3128)*	*Q87 (p. 3130)*	*Q88 (p. 3130)*	*Q89 (p. 3132)*	*Q90 (p. 3132)*
Q91 (p. 3133)					

Q1: A chronic smoker presented with shortness of breath, bilateral pitting pedal edema, and abdominal distension. On examination, jugular venous pulse was found to be elevated and liver was palpable 8 cm below the costal margin. An abnormality in which of the following structures is responsible for the patient's symptoms? (Q856629)

A. 1

B. 2

C. 3

D. 4

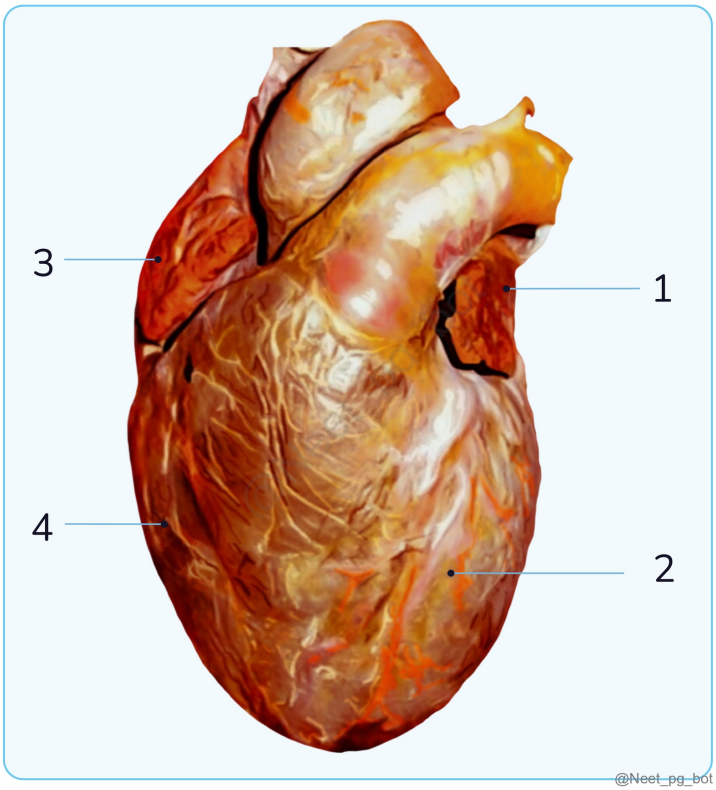

Correct Answer: D. 4

Explanation: lteration in the structure and function of the right ventricle (RV) caused by a primary respiratory disorder leading to pulmonary hypertension. Etiology: Lung Diseases : COPD, interstitial lung disease, scleroderma, cystic fibrosis, obesity hypoventilation syndrome. Vascular Disorders : Idiopathic pulmonary arterial hypertension. Upper Airway : Obstructive sleep apnea. Chest Wall Disorders : Kyphoscoliosis. Massive Pulmonary Embolism : Leading cause of acute cor pulmonale, may mimic myocardial infarction with elevated troponins and chest pain. COPD : Most common cause of chronic cor pulmonale. Pathophysiology: Chronic hypoxemia leads to pulmonary vasoconstriction and smooth muscle proliferation in small pulmonary arteries. Increased pulmonary vascular resistance causes right ventricular enlargement (thickening, dilation). Symptoms: Dyspnea on exertion , fatigue, lethargy, exertional syncope, chest pain, abdominal edema, and lower extremity edema. Clinical signs appear later, after pulmonary hypertension develops Physical Findings: Jugular Venous Distension : Prominent jugular V wave (tricuspid regurgitation). Peripheral Edema : Non-specific but common in right heart failure. Cardiovascular : Parasternal lift, loud S2, narrow S2 splitting, holosystolic murmur of tricuspid regurgitation, right-sided S4 heart sound. Abdomen : Hepatomegaly , ascites. Investigations: Chest Radiograph : Pulmonary artery enlargement, right ventricular cardiomegaly. ECG : Right ventricular hypertrophy/enlargement. Chest CT Angiography : Rules out pulmonary embolism, pulmonary artery diameter >29 mm. Management: Oxygen Therapy : Improves oxygenation, reduces pulmonary vasoconstriction, enhances cardiac output. Diuretics : Reduces RV filling volume in chronic cor pulmonale.

References:

https://www.ncbi.nlm.nih.gov/books/NBK430739/

↑ *Back to this question in Part A*

@Neet_pg_bot

Q2: A 60-year-old male patient who is a known case of COPD presented with acute exacerbation and is admitted to the ICU. Which of the following statements is correct with regards to the initial management of this patient? (Q854995)

A. Non-invasive PPV should be given

B. Invasive PPV should be given

C. IV corticosteroids should be administered

D. Permissive hypercapnia is allowed

Correct Answer: A. Non-invasive PPV should be given

Explanation: The initial management for acute exacerbation of COPD is non-invasive positive pressure ventilation (PPV) , as it helps reduce the work of breathing and improves gas exchange, leading to better outcomes, including reduced hospital duration and improved overall survival outcomes. Management of Acute Exacerbation of COPD: Initial Management and Assessment: Home management: Increased bronchodilator therapy, short course of oral glucocorticoids, and possibly antibiotics. Hospital referral indicators: Cyanosis Peripheral oedema Altered consciousness Comprehensive assessment upon admission: Level of consciousness (response to commands, ability to cough) Signs of CO_2 retention (warm peripheries, bounding pulse, flapping tremor) Airway obstruction assessment (wheeze, prolonged expiration) Signs of cor pulmonale (peripheral oedema, raised JVP) Background functional status and quality of life Precipitating causes (e.g., infection, environmental factors) Investigations: Investigation Purpose/Findings Arterial blood gases Assess severity of hypoxaemia, hypercapnia, acidaemia; guide oxygen therapy and ventilation. Chest X-ray Identify complications such as pneumonia, pneumothorax, or pleural effusion. Management Strategies: Management Details Oxygen Therapy Administer controlled oxygen at 24% or 28% to maintain PaO_2 > 8 kPa (60 mmHg) or SaO_2 > 90%. Regular arterial blood gas monitoring to adjust therapy. Non-Invasive Ventilation (NIV) Safe for mild to moderate respiratory acidosis; helps reduce intubation need and mortality. Not suitable for patients unable to protect their airway. Bronchodilators Use nebulised short-acting β2-agonists (e.g., salbutamol, terbutaline) with anticholinergics (e.g., ipratropium). If oxygen sensitivity is a concern, use compressed air for nebulisation. Glucocorticoids Administer oral prednisolone (30 mg for 10 days) to reduce symptoms and improve lung function.Reduces frequency and severity of exacerbations. Consider osteoporosis prophylaxis for repeated courses. Antibiotic Therapy Indicated for increased sputum purulence, volume, or breathlessness. Use simple regimens (aminopenicillin, tetracycline, macrolide); co-amoxiclav in areas with β-lactamase organisms. Mechanical Ventilation (Option B) Consider if there is a reversible cause, no prior respiratory failure, or if NIV has failed/contraindicated. Decisions should involve the patient, family, and GP. Additional Therapy Diuretics for peripheral oedema. Limited evidence for intravenous aminophylline; consider arrhythmia risk. Doxapram may be used short-term for low respiratory rates. Discharge and Follow-Up: Discharge criteria: Clinically stable on maintenance medication. Off nebulised therapy for at least 24 hours. PEF reaches 75% of predicted or personal best. Post-exacerbation follow-up: Identify and avoid trigger factors. Provide asthma education and a written self-management plan. IV corticosteroids should be administered (Option C): Systemic corticosteroids are helpful in treating acute COPD exacerbations by reducing airway inflammation and improving lung function over time, but their effects are not immediate. Non-invasive positive

pressure ventilation (NIPPV), on the other hand, provides immediate respiratory support, reducing the work of breathing and stabilizing the patient's condition, making it the priority in the initial management. Permissive hypercapnia is allowed (Option D): Permissive hypercapnia involves allowing elevated carbon dioxide levels to avoid lung injury from over-ventilation, but this is not an approach used in the initial management of acute COPD exacerbations. The goal during the acute phase is to normalize blood gases and relieve respiratory distress, which is best achieved with NIPPV. Permissive hypercapnia is typically considered only after NIPPV fails and invasive positive pressure ventilation (IPPV) is required.

References:

Davidson's Principles and Practice of Medicine, 24th Edition, Page 577, 578

↑ *Back to this question in Part A*

@Neet_pg_bot

Q3: When you are posted as an intern in the emergency department, a 67 year old man with a known case of diabetic and CKD for 15 yrs is brought to you with complaints of persistent cough, shortness of breath, fever, fatigue, and chest pain. He has been tested positive for COVID 19. Which of the following features will prompt you to get this patient admitted to a dedicated COVID health center? A. Respiratory rate of 33/min B. SpO 2 88% C. Multiple comorbidities D. Chest pain E. Age (Q856965)

A. A & B only

B. A, B, C & E only

C. A, B, & C only

D. None of the above

Correct Answer: B. A, B, C & E only

Explanation: A 67 year old patient with multiple comorbidities presenting with clinical signs of persistent cough, shortness of breath, fever, fatigue and oxygen saturation of 88% (below 90%) and a respiratory rate of 33 (above 30), is diagnosed as COVID-19 Stage 2, needs admission of patient to dedicated COVID health center. Clinical features: Asymptomatic or Presymptomatic No symptoms SARS-CoV-2 test positive Mild disease Symptoms like fever, cough, taste or smell changes No dyspnea Moderate disease LRTI (lower respiratory tract infection) Oxygen saturation: >94% Severe disease Oxygen saturation: <94% Respiratory rate: >30/min Lung infiltrate >50% Critical disease Respiratory failure Shock Multi-organ failure Timeline Taking the day of onset of symptoms as zero, it involves: Presymptomatic stage Stage I (early infection) Stage II (pulmonary phase) Stage III (hyperinflammatory phase) Stage Clinical features Respiratory rate Oxygen saturation Stage I Mild cough, throat pain, fever, diarrhoea, anosmia or taste changes. Normal Normal Stage II Shortness of breath (dyspnea) Coagulation starts (heparin has to be started) >24 breaths per min >30 breaths per minute (severe illness) <94% <90% (severe illness) Stage III

ARDS (Acute respiratory distress syndrome) Sepsis MODS (multi-organ dysfunction syndrome) Cardiogenic shock Intubation needed Intubation needed Happy Hypoxia: A phase (6-10 days) during stage II Hypoxia without any symptoms of respiratory distress (shortness of breath or confusion). Ensure monitoring of oxygen saturation levels, even when patients seem stable or asymptomatic.

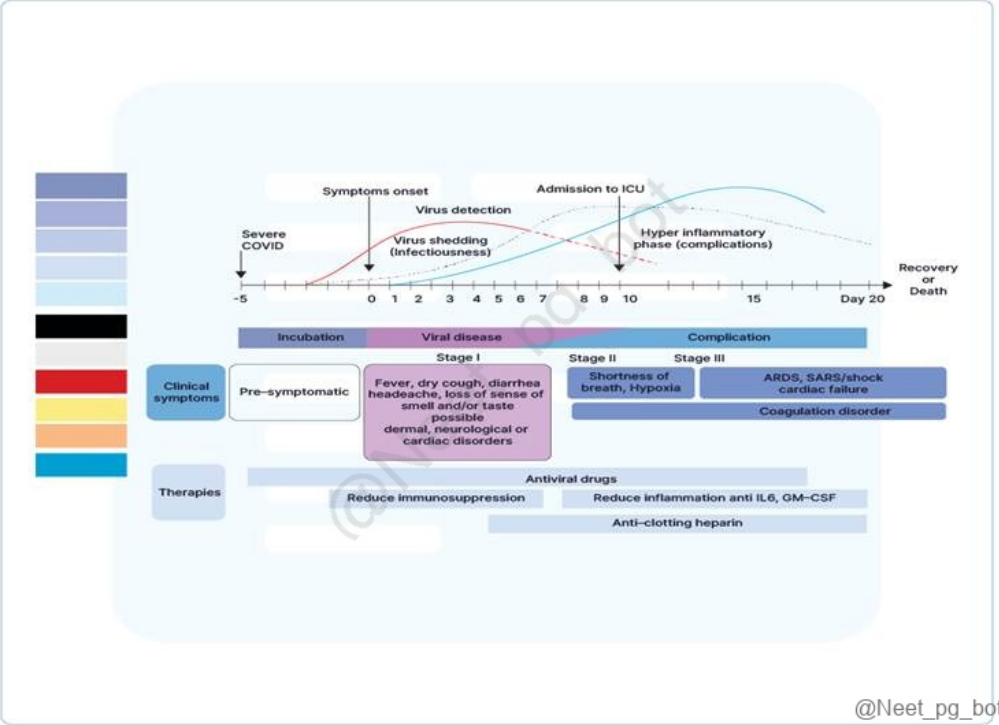

References:

Harrison’s Principles of Internal Medicine, 21st edition, Page 1508, 1509

Park’s Preventive and Social Medicine Textbook, 26th edition, Page 194

https://www.idsociety.org/practice-guideline/covid-19-guideline-treatment-and-management/#HowtoApproachaPatientWhenConsideringPharmacologicTreatmentsforCOVID-19

↑ *Back to this question in Part A*

@Neet_pg_bot

Q4: High anion gap acidosis with low bicarbonate levels is seen in all of the following conditions except: (Q856957)

A. Renal tubular acidosis

B. Diabetic ketoacidosis

C. Lactic acidosis

D. Salicylate poisoning

Correct Answer: A. Renal tubular acidosis

Explanation: Metabolic acidosis High anion gap (MUDPILES) Non-anion gap (USED PART) M ethanol poisoning U remia: AKI, CKD D iabetic ketoacidosis (Option B) P aracetamol poisoning I ron and isoniazid L actic acidosis (Option C) E thylene glycol poisoning S alicylate poisoning (Option D) U : Urinary diversion / Ureterenterostomy S : Small Bowel Fistula, S pironolactone and K-sparing diuretics, S aline infusion (rapid infusion) E : Extra Chloride D : Diarrhea P : Pancreatic fistula A : Addison, Acetazolamide R: RTA (Renal tubular acidosis) T : Tenofovir, Topiramate Reduced anion gap: Multiple myeloma and nephrotic syndrome

References:

Harrison’s Principle of Internal Medicine, 21st edition, Page 359 - 361, 364

↑ *Back to this question in Part A*

@Neet_pg_bot

Q5: What should be your subsequent course of action for the patient, who has been intubated and his X-ray as depicted in the radiograph? (Q856937)

A. Suction

B. Chest physiotherapy

C. Start antibiotics and send and samples for culture

D. Ultrasound-guided aspiration

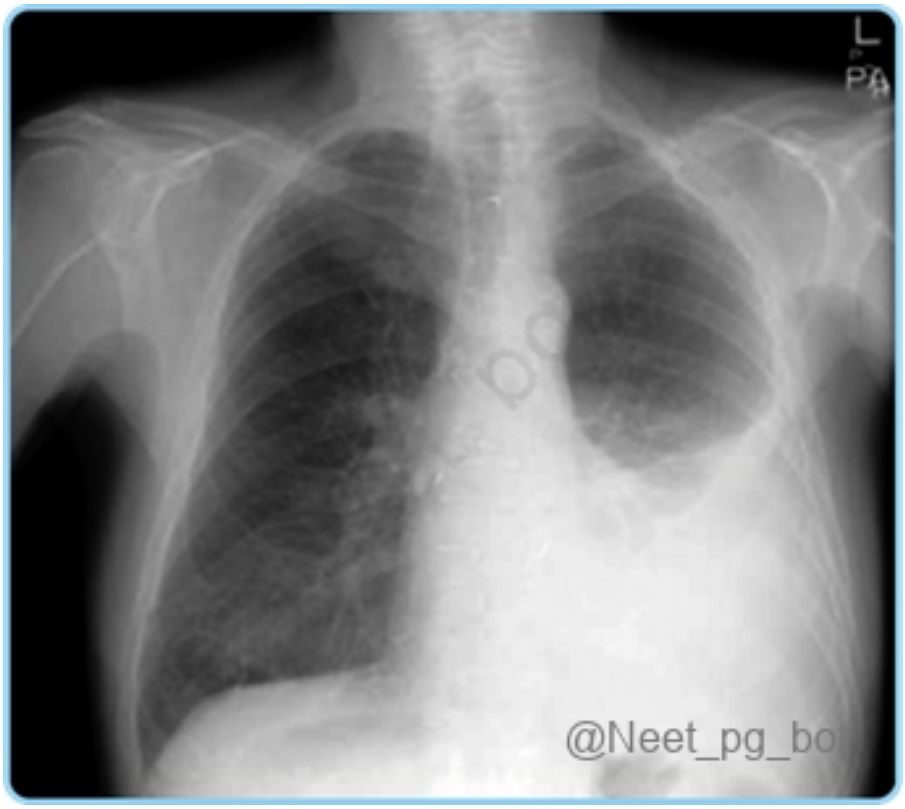

Correct Answer: D. Ultrasound-guided aspiration

Explanation: As the patient's chest X-ray reveals a significant amount of fluid accumulation on the left thorax and as the patient is also intubated, ultrasound-guided aspiration may be a reasonable next step. It is often done to improve respiratory function and prevent complications associated with accumulation of fluid in the lungs. Ultrasound serves a complementary role in chest imaging, particularly in evaluating fluid collections. Applications of Ultrasound: Pleural Effusion: Used for detection and guiding the drainage of fluid collections. Pericardial Effusion: Evaluates the presence of fluid around the heart and for assessing cardiac function. Suctioning (Option A) is a routine procedure used to clear the airway of secretions or foreign material. While suctioning may be necessary for some intubated patients, it is not a next specific step . The appropriateness of suctioning would depend on the patient's clinical condition and the presence of indications for suctioning. Chest physiotherapy (Option B) techniques, such as postural drainage, percussion, and vibration, are often used to help mobilize secretions and improve airway clearance. While these techniques may be beneficial in certain cases, they are not the next specific steps for this patient . Starting antibiotics and sending samples for culture (Option C) may be appropriate in certain situations, such as suspected or confirmed respiratory infection. However, the decision to start antibiotics and send samples for culture should be based on a comprehensive evaluation of the patient's clinical presentation, including signs and symptoms of infection. It cannot be determined solely based on the information of an X-ray finding.

References:

Grainger & Allison's Diagnostic Radiology, 7th edition, Page 27-31,43

↑ *Back to this question in Part A*

@Neet_pg_bot

Q6: A 50-year-old individual who is a chronic smoker came with complaints of recurrent episodes of coughing up blood without any accompanying symptoms of fever or weight loss. On chest x-ray there were no abnormalities seen, and the sputum test is also negative for acid-fast bacilli (AFB). Which of the following options could be the next effective diagnostic test? (Q856926)

A. MRI

B. CT

C. Fiberoptic bronchoscopy

D. Bronchography

Correct Answer: B. CT

Explanation: CT chest (computed tomography) is the next most useful diagnostic investigation. CT scan provides detailed imaging of the lungs and can help identify subtle abnormalities that may not be visible on a chest X-ray. It can detect small nodules, bronchial wall thickening, or other structural changes in the lungs that could be contributing to the hemoptysis. CT scan is commonly used in the evaluation of hemoptysis, especially when the chest X-ray is normal or inconclusive. MRI (Option A): Poor for lung parenchyma and not recommended for evaluating hemoptysis. Fiberoptic bronchoscopy (Option C): Useful after CT or in massive hemoptysis; CT has better sensitivity when X-ray is normal. Bronchography (Option D): Outdated technique replaced completely by CT and bronchoscopy.

References:

Grainger & Allison's Diagnostic Radiology, 7th edition, Page 27-31,43

↑ *Back to this question in Part A*

@Neet_pg_bot

Q7: A 68-year-old man presents with a cough with yellowish sputum. Auscultation revealed bronchial breath sounds. He is hemodynamically stable and not confused. On examination, his respiratory rate is 20/min, and his blood pressure is 110/70 mmHg. Lab reports show urea levels of 44 mg/dL. What is the next best step in the management of this patient? (Q856194)

A. Given antibiotics and send the patient home

B. Admit to ICU without mechanical ventilation

C. Admit to ICU with invasive mechanical ventilation

D. Consider admission in a non-ICU setting

Correct Answer: D. Consider admission in a non-ICU setting

Explanation: The patient's symptoms, such as productive cough, tachypnea, and hypotension, align with the diagnosis of pneumonia. The CURB-65 score of this patient is 2 (age >/= 65 and urea > 19mg/dl); hence, the patient can be considered for admission to a non-ICU setting for further management. Treatment for Lobar Pneumonia Treatment depends on severity; assess if inpatient or outpatient management is needed. CURB-65 Score: Used to stratify patients with the following factors: CURB-65 Symptom Score (C) Confusion 1 (U) Urea: BUN >19mg/dL (>7 mmol/L) 1 (R) Respiratory rate ≥30/min 1 (B) Blood Pressure – Systolic BP ≤90 mmHg or diastolic BP ≤60 mmHg 1 (65) Age ≥65 years 1 Hospitalization Criteria: CURB-65 score 1 or 2: Indicates hospitalization A score ≥3 : Indicates ICU admission and more intensive therapy . (Option B and C) Empiric Therapy: Outpatient: (Option A) When no symptoms in the CURB-65 scoring system are present. No comorbidities: Monotherapy with macrolides (Azithromycin, Clarithromycin). With comorbidities (chronic lung/heart disease, diabetes, smoking, HIV): Newer Fluoroquinolones (Levofloxacin, Moxifloxacin, Gemifloxacin) or a combination of beta-lactam (e.g., Amoxicillin) and a macrolide. Inpatient Non-ICU: Newer Fluoroquinolones (Levofloxacin, Moxifloxacin) alone or a combination of beta-lactam (e.g., Ampicillin, Ceftriaxone) and a macrolide. Inpatient ICU: Combination of macrolide (Azithromycin) or newer fluoroquinolone (Levofloxacin) with beta-lactam (e.g., Ampicillin-sulbactam, Ertapenem). If risk of aspiration, consider ampicillin-sulbactam or ertapenem; for Pseudomonas infection, use anti-pseudomonal beta-lactam (e.g., Piperacillin-tazobactam) with anti-pseudomonal fluoroquinolone (e.g., Ciprofloxacin). For MRSA, add vancomycin or linezolid. Duration of Therapy: Typically 5 to 7 days, extended if clinical response is delayed. Influenza Treatment: All hospitalized patients testing positive for influenza should receive Oseltamivir, regardless of illness onset.

References:

Harrison’s Principles of Internal Medicine, 21st Edition, Page: 1012.

Typical Bacterial Pneumonia - StatPearls - NCBI Bookshelf

↑ *Back to this question in Part A*

@Neet_pg_bot

Q8: A woman with hysteria who was hyperventilating developed carpo-pedal spasms. What could be the likely cause for this? (Q856163)

A. Respiratory acidosis

B. Metabolic acidosis

C. Respiratory alkalosis

D. Metabolic alkalosis

Correct Answer: C. Respiratory alkalosis

Explanation: The clinical features of hyperventilation leading to carpal spasm are caused due to respiratory alkalosis . Respiratory alkalosis occurs when there is a decrease in carbon dioxide (CO 2) levels in the blood, leading to an increase in alkalinity . Hyperventilation causes excessive elimination of carbon dioxide, leading to decreased blood CO 2 levels. This results in respiratory alkalosis Clinical features of respiratory alkalosis will include: Tachypnea Symptoms of hypocapnia Paresthesias from decreased ionized calcium due to alkalemia Reduced cerebral blood flow from hypocapnia Decreased ionized calcium causing tetany/carpopedal spasms Respiratory alkalosis- Clinical Features & Management Category Features Cause Neurological Dizziness Mental confusion Paresthesias Circumoral numbness Seizures (severe cases) Due to reduced cerebral blood flow From rapid ↓ PaCO 2 May occur without hypoxemia Cardiovascular Chest tightness/pain Palpitations Arrhythmias Possible ECG changes Due to coronary vasoconstriction ↓ ionized calcium effects Bohr effect on O 2 delivery Neuromuscular Carpopedal spasms Tetany Muscle twitching Weakness From ↓ ionized calcium Enhanced nerve excitability Similar to hypocalcemia Laboratory ↑ pH ↓ PaCO 2 ↓ Ionized calcium ↓ K+, ↓ PO 4 Acute: ↓ HCO 3 - by 2 mEq/L per 10 mmHg ↓ PaCO 2 Chronic: ↓ HCO 3 - by 4-5 mEq/L per 10 mmHg ↓ PaCO 2 Electrolyte shifts into cells Management Underlying Disease: Treat primary condition Address anxiety if present Manage sepsis if present Hyperventilation Syndrome: Reassurance Rebreathing techniques Paper bag breathing if needed β-blockers if needed Primary focus on the underlying cause Avoid sedatives for anxiety Monitor during mechanical ventilation Adjust ventilator settings if needed Regular monitoring of blood gases Address psychological factors Incorrect Options: Respiratory acidosis (Option A) results from impaired ventilation due to pulmonary disease, respiratory muscle fatigue, or abnormalities in ventilatory control. Some examples of these are drugs, alcohol, motor neuron diseases, skeletal muscle disease, etc. Metabolic acidosis (Option B) is caused by methanol, uremia, diabetic ketoacidosis, iron tablets, isoniazid, etc and not by hyperventilation. Metabolic alkalosis (Option D) is caused by exogenous bicarbonate loads, hypertension, K + deficiency, mineralocorticoid excess, etc.

References:

Harrison’s Principles of Internal Medicine, 21st Edition, Page: 368.

↑ *Back to this question in Part A*

@Neet_pg_bot

Q9: A diabetic woman presents with persistent vomiting after eating outside food. Her BP is 90/60 mmHg. ABG shows: pH: 7.52 HCO■■: 30 mEq/L PaCO■: 20 mmHg Na■: 123 mEq/L K■: 3.2 mEq/L Cl■: 67 mEq/L What is the most likely cause of these ABG findings? (Q856157)

A. Isolated vomiting induced metabolic alkalosis

B. Diabetic ketoacidosis (DKA)

C. Septic shock

D. Mixed disorder: Vomiting + Early DKA

Correct Answer: D. Mixed disorder: Vomiting + Early DKA

Explanation: ABG shows alkalemia (pH 7.52) with high HCO■■ (30) → metabolic alkalosis from vomiting . However: PaCO■ = 20 mmHg is too low for compensation → separate respiratory alkalosis . Anion gap = 26 (high) → presence of high-anion-gap metabolic acidosis , most consistent with early DKA in a diabetic. Vomiting causes metabolic alkalosis, but it cannot cause low PCO■ or high AG. Thus, this is a triple acid–base disorder : Metabolic alkalosis – from vomiting High-anion-gap metabolic acidosis – from early DKA Respiratory alkalosis – from tachypnea due to dehydration This combination is classic for "ketoalkalosis," where DKA is masked by vomiting. Isolated vomiting induced metabolic alkalosis (Option A): Vomiting explains metabolic alkalosis but cannot account for the high anion gap (36 mEq/L) . Pure vomiting causes normal AG metabolic alkalosis , not mixed disorders. Diabetic ketoacidosis (DKA) (Option B): DKA causes high anion gap metabolic acidosis , so pH is low or near-normal if compensated . But this patient has alkalemia (pH 7.52) and elevated HCO■■ , which DKA alone cannot produce. Septic shock (Option C) can lead to multiple organ dysfunction and a state of metabolic acidosis . The pH of 7.52 in the ABG report suggests alkalosis rather than acidosis, so septic shock is unlikely to be the cause.

References:

Harrison's Principles of Internal Medicine, 21st Edition, Page: 365, 366, 367.

Arterial Blood Gases - Physiopedia

↑ *Back to this question in Part A*

@Neet_pg_bot

Q10: A middle-aged man with chronic renal failure on dialysis presents with sudden collapse to the casualty with laboured breathing. ECG shows tall, tented T waves. What is the most likely acid-base imbalance that can be seen in this patient? (Q856141)

A. pH-7.14, pCO2-20 mmHg, HCO3- 5 mEq/L

B. pH-7.14, pCO2-20 mmHg, HCO3- 34 mEq/L

C. pH-7.54, pCO2- 34 mmHg, HCO3- 27 mEq/L

D. pH-7.4, pCO2- 40 mmHg, HCO3- 27 mEq/L

Correct Answer: A. pH-7.14, pCO2-20 mmHg, HCO3- 5 mEq/L

Explanation: The low pH and HCO 3 levels in the blood show metabolic acidosis . Metabolic acidosis Definition Primary decrease in HCO 3 ■ or increase in H■ ions Characterized by ↓ pH and ↓ HCO 3 ■ Compensatory mechanism: ↓ PaCO 2 through hyperventilation (Kussmaul breathing) Types High anion gap (AG > 12 mEq/L) Normal anion gap (AG 6-12 mEq/L) Causes (Mnemonic: MUDPILES) M : Methanol U : Uremia (Renal failure) D : Diabetic ketoacidosis (DKA) P : Paraldehyde, Phenformin, Propylene glycol I : Iron tablets, Isoniazid L : Lactic acidosis E : Ethylene glycol S : Salicylates (late phase) (Mnemonic: HARD UP) H : Hyperalimentation (TPN) A : Acetazolamide R : Renal Tubular Acidosis D : Diarrhea U : Ureteral diversion P : Pancreatic fistula GIT fistulas Clinical Features General Features: Lethargy Confusion Fatigue Nausea/vomiting Deep, rapid breathing (Kussmaul) Specific Features: DKA: Fruity breath, polyuria, polydipsia Uremia: Itching, volume overload Lactic acidosis: Shock, hypotension Toxic ingestion: Visual disturbances (methanol), oxalate crystals (ethylene glycol) Incorrect Options: pH-7.14, pCO 2 -20 mmHg, HCO 3 - 34 mEq/L (Option B) : Although the pH and pCO■ suggest acidemia with respiratory compensation, the high HCO■■ (34 mEq/L) is inconsistent with metabolic acidosis. A high bicarbonate would be seen in metabolic alkalosis, which does not fit this clinical picture. pH-7.54, HCO 3 - 27 mEq/L, pCO 2 - 34 mmHg (Option C) : This option shows a high pH (7.54), indicating alkalosis. The pCO■ is slightly low, suggesting respiratory alkalosis, while the HCO■■ is near normal. This acid-base picture does not match the metabolic acidosis expected in a dialysis patient with hyperkalemia. pH-7.4, HCO 3 - 27 mEq/L, pCO 2 - 40 mmHg (Option D) : This combination of normal pH, normal pCO 2 , and normal HCO 3 - does not indicate any significant acid-base imbalance. Therefore, this option is less likely to be the correct acid-base imbalance in this case.

References:

Harrison’s Principles Of Internal Medicine, 21st Edition, Volume I, Page: 361, 362, 364.

↑ *Back to this question in Part A*

@Neet_pg_bot

Q11: A 10-year-old child with AIDS presented with a fever and productive cough. On auscultation, bronchial breath sounds and crepitations were heard in the right infra-scapular region. Chest x-ray showed right lower lobe consolidation. The CD4 count was 55 cells/mm3. What is the most common causative organism for this condition? (Q856122)

A. Pneumocystis jirovecii

B. Streptococcus pneumonia

C. Staphylococcus aureus

D. Mycoplasma

Correct Answer: B. Streptococcus pneumonia

Explanation: The given scenario is of pneumonia in an AIDS-infected child. The most common organism causing fever, and productive cough , with given examination findings, is Streptococcus pneumonia . Pneumonia Etiology and Common Pathogens Main Pathogens : Bacteria, viruses, fungi, and protozoa. Typical Bacteria : Streptococcus pneumoniae , Haemophilus influenzae , Staphylococcus aureus (including MRSA). Atypical Bacteria : Mycoplasma pneumoniae , Chlamydia pneumoniae , Legionella species Viruses : Influenza, respiratory syncytial virus (RSV), coronaviruses (e.g., SARS-CoV-2). Community-Acquired Pneumonia (CAP) Atypical Pneumonia Outpatients Hospitalised Patients Includes M.pneumoniae C.pneumoniae, and Legionella species. Common causes: S.pneumoniae , M.pneumoniae H. influenzae, C.pneumoniae, Respiratory viruses (influenza, RSV). Non-ICU ICU Patients Similar pathogens to outpatients, plus Legionella species. Pathogens include S.pneumoniae, S. aureus (including MRSA), Legionella species, gram-negative bacilli, and H. influenzae. Specific Pathogens in Certain Conditions: Staphylococcus aureus (MRSA) : It can cause CAP, often complicating influenza infections. Community-acquired MRSA (CA-MRSA) has emerged as a significant cause of necrotizing pneumonia. Pneumococcal Pneumonia : Higher risk in elderly patients, and those with comorbidities like dementia, heart failure, cerebrovascular disease, alcoholism, smoking, COPD, and HIV infection. CA-MRSA Pneumonia : More likely in patients with prior skin infections or following viral illnesses. Enterobacteriaceae : Common in patients recently hospitalized, those treated with antibiotics, or those with comorbidities like alcoholism, heart failure, or renal failure. Pseudomonas aeruginosa : Found in patients with severe structural lung diseases such as bronchiectasis, cystic fibrosis, or advanced COPD. Legionella Infection : Associated with risk factors like diabetes, hematologic malignancies, cancer, severe renal disease, HIV, smoking, male gender, and recent travel (air conditioners, showers, hotels, cruise ships). It is an important cause of atypical pneumonia. Pneumocystis jirovecii (Option A) pneumonia (PJP) is a common opportunistic infection in patients with AIDS. However, it typically presents with non-productive cough, shortness of breath, and bilateral diffuse infiltrates on chest X-ray. Staphylococcus aureus (Option C) is another bacterium that can cause pneumonia in immunocompromised individuals, including those with AIDS. It is known for causing severe infections, including necrotizing pneumonia, but not the most common cause. Mycoplasma pneumoniae (Option D) is an atypical bacterium that can cause pneumonia, particularly in children and young adults. It often presents with a milder respiratory illness, including a persistent cough, headache, sore throat, and patchy infiltrates rather than lobar consolidation in the chest X-ray.

References:

Harrison’s Principles of Internal Medicine, 21st Edition, Page: 1010, 1011.

↑ *Back to this question in Part A*

@Neet_pg_bot

Q12: A patient presents with fever, nocturnal cough, breathlessness, and wheezing for 4 weeks. The absolute eosinophil count is >5000/µL. Chest x-ray shows a miliary pattern. What is the likely diagnosis? (Q856099)

A. Bronchial asthma

B. Miliary tuberculosis

C. Tropical pulmonary eosinophilia

D. Hypersensitivity pneumonitis

Correct Answer: C. Tropical pulmonary eosinophilia

Explanation: The nocturnal cough, fever, breathlessness, and wheezing with eosinophilia of >5000/µL and miliary pattern in chest X-ray all point to the diagnosis of tropical pulmonary eosinophilia. Tropical pulmonary eosinophilia (TPE) TPE is a pulmonary hyperreactive condition triggered by trapped microfilariae in lung tissue, leading to symptoms like nocturnal cough, dyspnea, and wheezing. Pathophysiology: Eosinophils are key in the pathogenesis, triggered by microfilariae released from the lymphatic system that become trapped in pulmonary microcirculation. Eosinophils degranulate, releasing proteins to clear microfilariae and cause lung damage. IL-4 promotes airway hyperactivity, while IFN-gamma suppresses it. An overactive TH2 response increases IL-4, IL-5, and specific IgG, IgM, and IgE antibodies, leading to eosinophilia. Clinical features: History of travel or residence in filarial endemic areas. Symptoms: Dry, paroxysmal, nocturnal cough Dyspnea Systemic signs (fever, malaise, weight loss) Peripheral eosinophilia (>3,000/mm^3) Extrapulmonary signs: Lymphadenopathy, hepatosplenomegaly Physical Findings: Wheezing, crepitations, organomegaly, enlarged lymph nodes. Investigations: Blood Tests: Leukocytosis with eosinophilia, elevated IgE, filarial antibody titers. Stool Test: Rule out other parasitic causes. Imaging: Chest X-ray: Reticulonodular opacities, miliary mottling, or normal in 20-30% of cases. Chest CT: Bronchiectasis, lymphadenopathy, pleural effusion in unclear cases. Pulmonary Function Tests (PFTs): Mixed restrictive and mild to moderate obstructive patterns. {{caption_text}} Management: First-line : Diethylcarbamazine (DEC) for 21 days. It targets both microfilariae and adults, leading to dramatic symptom improvement. Adjunctive : Corticosteroids reduce airway inflammation, particularly in chronic cases. Alternative Drugs : Ivermectin and albendazole target microfilariae and adult worms, though there is limited data. Incorrect Options: Bronchial asthma (Option A) is a chronic respiratory condition characterized by inflammation and narrowing of the airways, leading to symptoms such as wheezing, coughing (often nocturnal), breathlessness, and occasionally fever. However, the presence of a miliary pattern on chest X-ray is not typical of bronchial asthma. Miliary tuberculosis (Option B) is a severe form of tuberculosis (TB) in which the infection spreads throughout the body, including the lungs. It is characterized by the dissemination of tiny, millimetre-sized lesions throughout various organs, including the lungs, giving a miliary pattern on chest X-ray. The elevated absolute eosinophil count is not typical of miliary tuberculosis. Hypersensitivity pneumonitis (HP) (Option D) , also known as extrinsic allergic alveolitis, is an immune-mediated lung disease caused by the inhalation of various organic substances such as dust, moulds, or animal proteins. The absolute eosinophil count can be elevated in some cases. However, the presence of a miliary pattern on chest X-ray is not typical of HP.

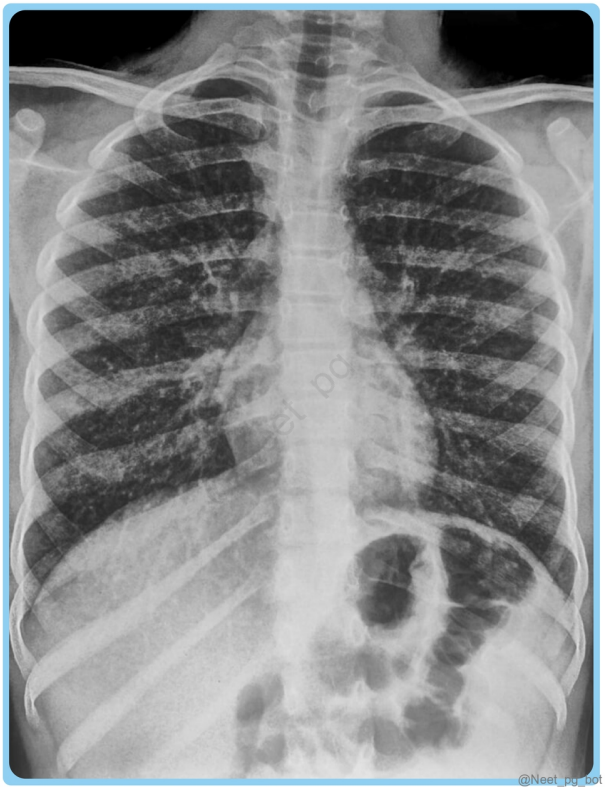

References:

https://www.ncbi.nlm.nih.gov/books/NBK557524/

↑ *Back to this question in Part A*

@Neet_pg_bot

Q13: The arterial blood gas analysis findings of a patient are as follows: pH=7.30, HCO3=10 mEq/L, paCO2= 30 mmHg, which is suggestive of a partially compensated metabolic acidosis. What is the mechanism for the secondary disorder? (Q855004)

A. Hypoventilation causing decreased CO2 washout

B. Hyperventilation causing decreased CO2 washout

C. Increased tubular reabsorption of HCO3-

D. Increased excretion of H+

Correct Answer: A. Hypoventilation causing decreased CO2 washout

Explanation: For metabolic acidosis with HCO■■ = 10 , the expected compensatory PaCO■ is: 1.5×10+8=23±2 mmHg (Using Winter's formula) Expected PaCO■ = 21–25 mmHg But the actual PaCO■ = 30 mmHg → higher than expected. If the patient were hyperventilating , PaCO■ would drop below the expected value. Instead, it is elevated , meaning CO■ is being retained . So the secondary disorder is a respiratory acidosis due to hypoventilation . Hyperventilation causing decreased CO■ washout (Option B): Would lower PaCO■, but here PaCO■ is elevated , so hyperventilation is ruled out. Increased tubular reabsorption of HCO■■ (Option C): Renal compensation for respiratory acidosis, not metabolic acidosis. Increased excretion of H■ (Option D) Slow renal compensation for metabolic acidosis and does not explain the elevated PaCO■.

References:

Harrison’s Principles of Internal Medicine, 21st Edition, Pages 359-367

↑ *Back to this question in Part A*

@Neet_pg_bot

Q14: Acid-base imbalance is suspected in a patient. Which of the following would you use to determine it? Arterial pH Venous pH Venous pO2 Venous pCO2 (Q856625)

A. 1,2

B. 1,2,3

C. 1,2,4

D. 1,2,3,4

Correct Answer: A. 1,2

Explanation: G pH is higher by 0.03), making venous pH values acceptable for clinical use. Venous pO2 (Option 3): Venous and arterial pO2 values are not comparable because arterial pO2 is typically 36.9 mmHg higher than venous pO■, with significant variability. Venous pCO2 (Option 4): Venous and arterial pCO2 are not directly comparable as the mean difference between them is approximately 4.8 mmHg, which limits its reliability in assessing acid-base imbalance.

References:

https://pmc.ncbi.nlm.nih.gov/articles/PMC5885755/

https://oxfordmedicaleducation.com/abgs/venous-blood-gas-vbg-interpretation/#

↑ *Back to this question in Part A*

@Neet_pg_bot

Q15: Identify the pathology from the given flow-volume loop: (Q856623)

A. Fixed distal airway obstruction

B. Fixed central airway obstruction

C. Variable intrathoracic obstruction

D. Variable extra thoracic obstruction

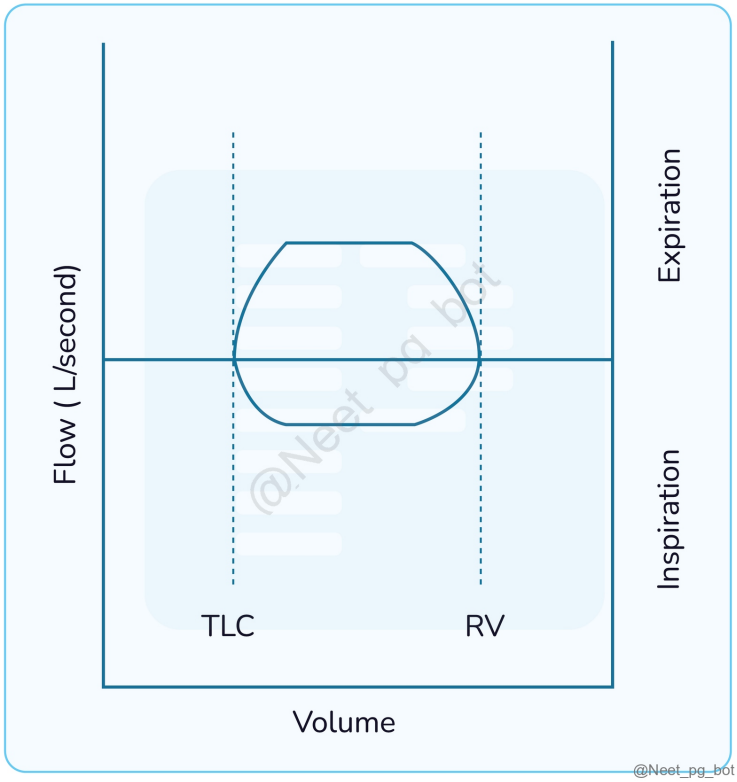

Correct Answer: B. Fixed central airway obstruction

Explanation: - Fixed central airway obstruction The given image demonstrates flattening of both the inspiratory and expiratory flow on the flow-volume loop, which is characteristic of fixed central or upper airway obstruction. Types of Flow-Volume Loops: Flow-Volume Loops and Their Examples: Loop Type Expiratory Curve Inspiratory Curve Example Conditions Normal Symmetrical, peaked Symmetrical, rounded Healthy lungs Obstructive (Option A) Scooped (concave) Normal COPD, asthma Restrictive Narrow, peaked Narrow, peaked Pulmonary fibrosis, pleural effusion Fixed Upper Airway Obstruction Flattened (box-like) Flattened (box-like) Tracheal stenosis, large goiter Variable Extrathoracic Obstruction (Option D) Normal Flattened Vocal cord dysfunction, laryngeal tumor Variable Intrathoracic Obstruction (Option C) Flattened Normal Tracheomalacia, bronchogenic tumor

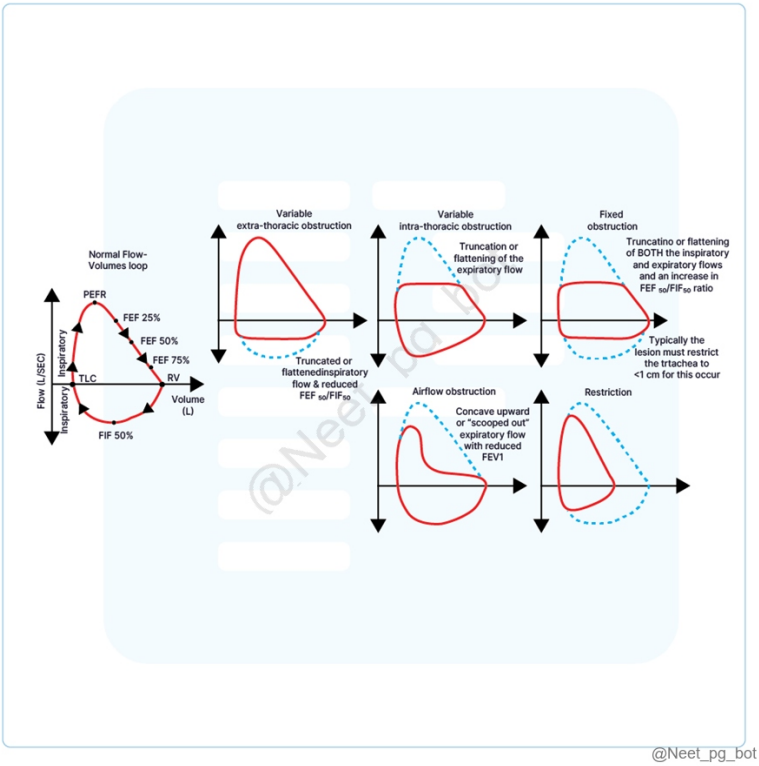

References:

Harrison's Principles of Internal Medicine, Twenty-First Edition by Loscalzo, pages 2134 to 2138

↑ *Back to this question in Part A*

@Neet_pg_bot

Q16: A 35-year-old female patient with class II pulmonary hypertension presents with a negative vasoreactive test. Which of the following is used in the next step of management? (Q856608)

A. Iloprost

B. Ambrisentan

C. Nifedipine

D. Epoprostenol

Correct Answer: B. Ambrisentan

Explanation: H: Indication: Vasoreactivity testing is primarily reserved for patients with idiopathic or hereditary PAH. Preferred Vasodilators: Short-acting vasodilators such as inhaled nitric oxide (NO) or inhaled epoprostenol are preferred for the test. Positive Response: A decrease in mean pulmonary arterial pressure (mPAP) by ≥10 mmHg to an absolute level of ≤40 mmHg without a decrease in cardiac output (CO) is considered a positive vasoreactivity response. Treatment for Responders: Patients with a positive vasoreactivity response are considered for long-term treatment with calcium channel blockers (nifedipine , diltiazem or amlodipine). (Option C) Negative Vasoreactivity : Treatment approach depends on clinical risk. Low- or Intermediate-Risk Patients (class II, III) : Initial treatment includes combination oral therapy, typically involving an endothelin receptor antagonist (ambrisentan , sitaxsentan or bosentan) and a phosphodiesterase type 5 inhibitor (sildenafil or tadalafil). High-Risk Patients (Class IV) : Patients with advanced heart failure or syncope are treated with combination drug therapy, which includes intravenous prostacyclin therapy (epoprostenol , treprostinil or iloprost). (Option A & D) Classification of PAH: Group 1: Pulmonary arterial hypertension (PAH) Group 2: Pulmonary hypertension due to left heart disease Group 3: Pulmonary hypertension due to lung disease or hypoxia Group 4: Chronic thromboembolic pulmonary hypertension Group 5: Pulmonary hypertension due to unclear and/multifactorial mechanisms

References:

Harrison's Principles of Internal Medicine 21st Edition, Page 2124,2128

https://www.msdmanuals.com/professional/multimedia/table/classification-of-pulmonary-hypertension

↑ *Back to this question in Part A*

@Neet_pg_bot

Q17: During the discharge of a COVID patient who was treated with steroids and remdesivir, which of the following will you inform him about? Repeat RT-PCR after 7 days of discharge Watch for the persistence of Anosmia Watch for headache and nasal discharge Monitor glucose levels Watch for Sinusitis like symptoms (Q856591)

A. 1, 3 and 4

B. 2, 3 and 4

C. 3, 4 and 5

D. 1,2,3,4 and 5

Correct Answer: C. 3, 4 and 5

Explanation: -19: Mild Cases of COVID-19: Discharge criteria: At least 7 days have passed since testing positive. No fever for 3 successive days. No testing is required prior to discharge. Moderate Cases Admitted to Dedicated COVID Health Centre Patients with resolved signs/symptoms and saturation >93% for 3 successive days: Discharge after resolution of symptoms and maintaining saturation above 93% for 3 successive days (without oxygen support). Stable comorbidities, if any, are required. No testing is required prior to discharge. Patients on

oxygen with unresolved signs/symptoms and ongoing oxygen therapy demand: Discharge only after the following criteria are met: Resolution of clinical symptoms. Ability to maintain prescribed oxygen saturation for 3 successive days without oxygen support. Stable comorbidities, if any. Severe Cases, Including Immunocompromised Patients (HIV, transplant recipients, malignancy, etc.) Discharge will be based on clinical recovery. The decision is at the discretion of the treating medical officer. Repeat RT-PCR after 7 days of discharge (Option 1): This is not recommended under the updated COVID-19 discharge criteria. Watch for persistence of anosmia (Option 2): Anosmia is a common post-COVID symptom that may persist for weeks to months in recovered patients. It is not considered a dangerous sign and does not require active monitoring during the discharge period.

References:

Harrison's Principles of Internal Medicine, 21st edition, Page 1509,1682

https://covid19dashboard.mohfw.gov.in/pdf/RevisedDischargePolicyforCOVID19updatedon9thJanuary2022.pdf

↑ *Back to this question in Part A*

@Neet_pg_bot

Q18: A patient came with hypoxemia and a normal alveolar-arterial oxygen gradient. What can be the cause? (Q855711)

A. Right-to-left shunt

B. Ventilation/perfusion mismatch

C. Hypoventilation

D. Alveolar membrane damage

Correct Answer: C. Hypoventilation

Explanation: Hypoventilation causes hypoxemia by reducing both alveolar and arterial oxygen levels equally, resulting in a normal alveolar-arterial (A-a) gradient. Alveolar-Arterial Oxygen Gradient (A-a Gradient): The A-a gradient measures the difference between the oxygen concentration in the alveoli (PAO2) and the oxygen concentration in the arterial system (PaO2). Helps narrow the differential diagnosis for hypoxemia. A-a Gradient Formula: A-a Gradient = PAO2 – PaO2 (PAO2 = Alveolar oxygen tension, PaO2 = Arterial oxygen tension). Hypoventilation and A-a Gradient: Hypoventilation occurs when there is inadequate ventilation of the lungs, leading to decreased oxygen levels in the arterial system. Causes of Hypoventilation: CNS depression. Neuromuscular diseases (e.g., myasthenia gravis). Poor chest elasticity (e.g., kyphoscoliosis). Vertebral fractures and other factors. Hypoventilation affects both arterial oxygen tension (PaO■) and alveolar oxygen tension (A■O■), resulting in decreased oxygen levels in both the respiratory and circulatory systems. The A-a gradient (the difference between alveolar and arterial oxygen tensions) remains normal in hypoventilation because both PaO■ and A■O■ decrease in proportion. Right to left shunt (Option A) : In a right-to-left shunt, oxygenated blood bypasses the alveoli, mixing with deoxygenated blood and causing hypoxemia. This leads to an increased

A-a gradient, as diffusion between capillaries and alveoli remains unaffected, but the lack of oxygenation of the shunted blood worsens the oxygenation process. Ventilation/perfusion (V/Q) mismatch (Option B) leads to a disparity between ventilation and perfusion in the lungs, resulting in an increased A-a gradient. This is because some areas of the lung are either under-ventilated or under-perfused, impairing the gas exchange process and increasing the gradient. Alveolar membrane damage (Option D) , seen in conditions like ARDS or pulmonary fibrosis, impairs the diffusion of oxygen across the alveolar-capillary barrier. This causes an increased A-a gradient as oxygen fails to transfer efficiently from the alveoli into the bloodstream, leading to hypoxemia.

References:

https://www.ncbi.nlm.nih.gov/books/NBK545153/#

↑ *Back to this question in Part A*

@Neet_pg_bot

Q19: A patient with a history of fever for the past 4 days and sudden onset of breathlessness was admitted to ICU as he was deteriorating. He was unresponsive to the incremental flow rate of oxygen and his oxygen saturation was progressively decreasing. A chest x-ray was ordered and the findings are shown in the image below. What is the most likely diagnosis? (Q857678)

A. Atelectasis

B. Mediastinitis

C. Pulmonary fibrosis

D. ARDS

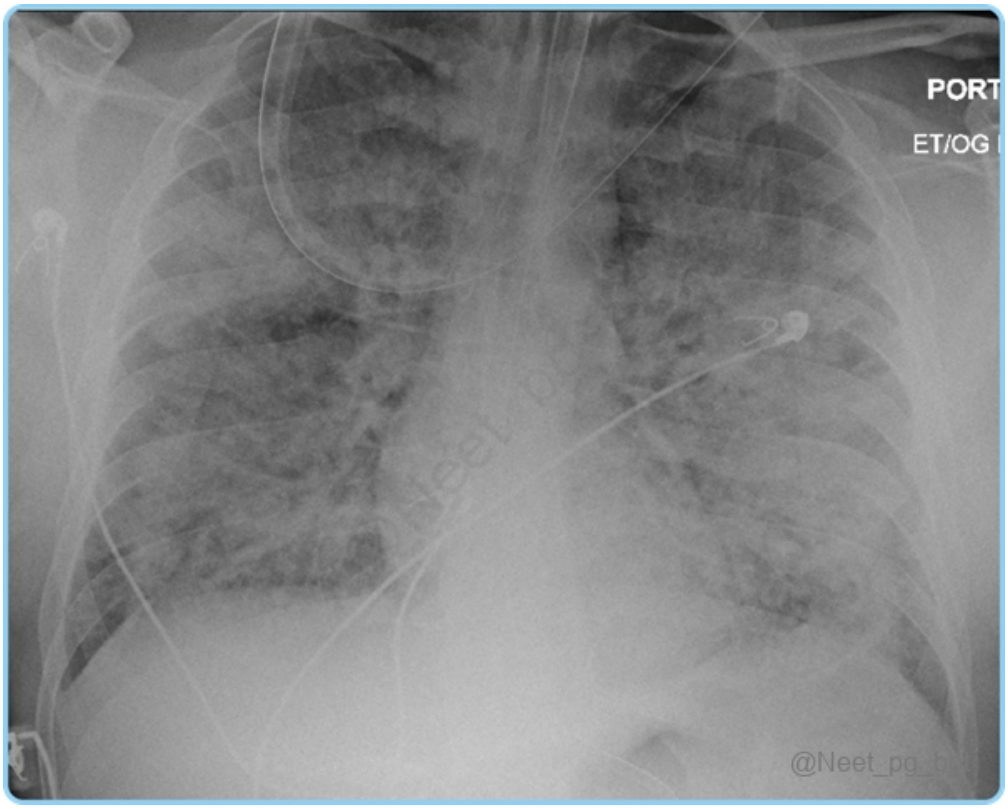

Correct Answer: D. ARDS

Explanation: The most likely diagnosis of this patient is Acute Respiratory Distress Syndrome (ARDS). ARDS is a severe lung condition characterized by widespread inflammation and damage to the alveoli (air sacs) in the lungs. It can be triggered by various factors, including infection, sepsis, trauma, or inhalation injury. The key features of ARDS include acute onset of severe hypoxemia (low oxygen levels) that is refractory to supplemental oxygen, bilateral pulmonary infiltrates on imaging (such as the chest X-ray), and impaired lung compliance. Acute Respiratory Distress Syndrome (ARDS): ARDS is a diffuse neutrophilic alveolitis caused by infective & non-infective triggers. Berlin definition of ARDS: Onset within 1 week of a known clinical insult, or new or worsening respiratory symptoms Bilateral opacities on chest X-ray, not fully explained by effusions, lobar/lung collapse or nodules Respiratory failure not fully explained by cardiac failure or fluid overload. Objective assessment (e.g. by echocardiography) must exclude hydrostatic oedema if no risk factor is present Impaired oxygenation Pathophysiology: Activated neutrophils & macrophages → capillary permeability ↑ → alveolar damage Protein-rich exudate accumulation → hyaline membrane formation Cytokine & chemokine release → inflammatory cell recruitment Surfactant loss → alveolar collapse & ↓ lung compliance Hypoxaemia & hypercapnia due to ventilation-perfusion mismatch ARDS Severity (PaO2/FiO2 Ratio in kPa): Mild: 40–26.6 kPa (300–200 mmHg) Moderate: 26.6–13.3 kPa (200–100 mmHg) Severe: ≤ 13.3 kPa (≤ 100 mmHg) (Measured on ≥5 cmH■O PEEP or CPAP) (CPAP = continuous positive airway pressure; PEEP = positive end-expiratory pressure) Management: Supportive care: Lung-protective mechanical ventilation, negative fluid balance, and treat underlying cause Severe ARDS: Requires prone positioning, extracorporeal membrane oxygenation (ECMO) Atelectasis (Option A) refers to the collapse or incomplete expansion of lung tissue. It can result from blockage of the airways, compression of the lung, or surfactant deficiency. While atelectasis can cause localized or segmental lung collapse, it typically does not lead to widespread bilateral infiltrates and severe hypoxemia. Pulmonary fibrosis (Option C) typically presents with a gradual onset of symptoms, such as shortness of breath and cough, and the chest X-ray findings would show a reticular or honeycomb pattern.

References:

Davidson's principles and practice of medicine, 24th edition, Page 198, 199

↑ *Back to this question in Part A*

@Neet_pg_bot

Q20: A 45-year-old female presents to the emergency department with the following arterial blood gas (ABG) results: pH 7.55, PaCO 2 40 mmHg, HCO 3 - 32 mEq/L. Which of the following conditions is most likely responsible for these findings? (Q857651)

A. Metabolic acidosis

B. Metabolic alkalosis

C. Respiratory acidosis

D. Respiratory alkalosis

Correct Answer: B. Metabolic alkalosis

Explanation: The elevated pH (>7.45) and increased bicarbonate (HCO 3 -) (32 mEq/L), indicates a primary metabolic alkalosis. Metabolic Alkalosis Metabolic alkalosis is characterized by an increase in arterial pH , elevated serum bicarbonate [HCO3–], and increased PaCO2 ■ due to compensatory hypoventilation. Often presents with hypochloremia and hypokalemia . Occurs as a mixed disorder with respiratory or metabolic acidosis or alkalosis. Causes Exogenous Bicarbonate Loads Acute alkali administration Milk-alkali syndrome Effective ECFV Contraction (Normotension, K+ Deficiency, Secondary Hyperreninemic Hyperaldosteronism) Gastrointestinal Origin: Vomiting, gastric aspiration, congenital chloridorrhea, gastrocystoplasty, villous adenoma Renal Origin: Diuretic use (thiazides, loop diuretics), posthypercapnic state, hypercalcemia/hypoparathyroidism, recovery from acidosis, non-resorbable anions (e.g., penicillin), Mg²■ deficiency, K■ depletion, Bartter's syndrome, Gitelman's syndrome ECFV Expansion, Hypertension, K+ Deficiency, and Mineralocorticoid Excess High Renin: Renal artery stenosis, accelerated hypertension, renin-secreting tumor, estrogen therapy Low Renin: Primary aldosteronism (adenoma, hyperplasia, carcinoma), adrenal enzyme defects (11β-hydroxylase, 17α-hydroxylase deficiency), Cushing’s syndrome, substances like licorice, carbenoxolone Genetic Sodium Channel Mutation (Liddle's Syndrome) Gain-of-function mutation in the distal convoluted tubule, causing ECFV expansion, hypertension, K■ deficiency, and hypo-reninemic-hypoaldosteronism Clinical Features Neurological: Mental confusion, obtundation, potential seizures Peripheral Nervous System: Paresthesias, muscle cramps, tetany (similar to hypocalcemia effects) Cardiovascular: Aggravation of arrhythmias, particularly in COPD patients Electrolyte Imbalances Potassium (K■): Hypokalemia, especially in cases involving secondary hyperaldosteronism or diuretic use. Chloride (Cl■): Hypochloremia, frequently accompanying alkalosis, especially in cases of vomiting or diuretic use. Calcium (Ca²■): Symptoms may mimic hypocalcemia despite normal levels. Metabolic acidosis (Option A) would show a low pH and low bicarbonate levels. Respiratory acidosis (Option C) is characterized by a low pH and elevated PaCO■ Respiratory alkalosis (Option D) would

show a high pH with low PaCO■.

References:

Harrison’s Principles of Internal Medicine, 21st edition, Page 365 - 367

Arterial Blood Gases - Physiopedia

↑ *Back to this question in Part A*

@Neet_pg_bot

Q21: Which of the following findings from a pleural fluid aspirate will suggest an exudative pleural effusion? Normal values Total S. Protein: 6-8 gm% S.LDH: 140-280 IU S. glucose: 140-200 (Q857644)

A. Pleural: Serum protein ratio > 0.5, pleural: Serum LDH ratio > 0.6 or pleural LDH > ■ of serum LDH

B. Pleural fluid protein = 4.5 gm% and glucose = 30 mg%

C. Pleural fluid LDH = 90IU and glucose = 30 mg%

D. Pleural fluid protein = 3.5gm% and glucose = 90 mg%

Correct Answer: A. Pleural: Serum protein ratio > 0.5, pleural: Serum LDH ratio > 0.6 or pleural LDH > ■ of serum LDH

Explanation: To classify the effusion as transudative or exudative, we apply Light's criteria: Pleural fluid protein/serum protein > 0.5 Pleural fluid LDH/serum LDH > 0.6 Pleural fluid LDH exceeds two-thirds of the normal upper limit for serum LDH Investigation of pleural fluid Radiological investigation X-ray: 200 mL of fluid is needed for detection on the posteroanterior (PA) view. 50 mL of fluid may lead to blunting of the costophrenic angle on the lateral view. A homogeneous opacity with obliteration of the costophrenic angle is typical. This appearance is marked by a curved upper border , known as the Ellis S-shaped curve . Obliteration of cardiophrenic angle . Ultrasound: More effective than X-ray in detecting fluid presence, showing a clear hypoechoic space indicative of transudate and moving densities suggesting exudate. Pleural fluid Analysis Light's Criteria Differentiates transudative from exudative pleural effusions based on LDH and protein levels in pleural fluid. An exudative pleural effusion meets at least one of the following: Pleural fluid protein/serum protein > 0.5 Pleural fluid LDH/serum LDH > 0.6 Pleural fluid LDH exceeds two-thirds of the normal upper limit for serum. ~25% of transudates may be misidentified as exudates. If exudative criteria are met but a transudative condition is suspected, measure protein difference; if >31 g/L (3.1 g/dL), likely transudative. Additional Tests for Exudative Effusions Appearance description Glucose level, If Glucose <60 mg/dL Consider: Malignancy Bacterial infections (empyema) Rheumatoid pleuritis Differential cell count Microbiologic studies Cytology Standard Peculiarities Heart Failure : NT-proBNP level > 1500 pg/mL indicates effusion due to congestive heart failure Parapneumonic Effusion : Key criteria include: Loculated pleural fluid Pleural fluid pH < 7.20 Pleural fluid glucose < 3.3 mmol/L (< 60 mg/dL) (Option B, C) Positive Gram stain or culture results Presence of visible pus Tuberculous Pleuritis :

Diagnosis confirmed by high TB markers in pleural fluid (adenosine deaminase > 40 IU/L or i nterferon γ > 140 pg/mL) Since the criteria suggest an exudate, which is often associated with other conditions like malignancy or infection rather than just congestive heart failure (Option D) .

References:

Harrison's Principles of Internal Medicine, 21st edition, Page 2198, 2199

https://pmc.ncbi.nlm.nih.gov/articles/PMC4753987/#sec4

↑ *Back to this question in Part A*

@Neet_pg_bot

Q22: The following patient has presented after chest trauma. On examination, crepitus is felt. The clinical diagnosis is? (Q857053)

A. Subcutaneous emphysema

B. Gas gangrene

C. Acute tubular necrosis

D. SVC syndrome

Correct Answer: A. Subcutaneous emphysema

Explanation: The presence of crepitus after chest trauma suggests air leakage into the subcutaneous tissue, indicating subcutaneous emphysema. Subcutaneous Emphysema: Air accumulation in the subcutaneous tissue, which lies beneath the dermis. Can spread into deeper tissues, leading to pneumomediastinum, pneumothorax, pneumoperitoneum, or pneumoretroperitoneum. Causes: Traumatic: Blunt or penetrating injuries, barotrauma, bowel perforation, pulmonary blebs. Iatrogenic: Ventilator circuit malfunction or disruption. Improper pop-off valve closure. Valsalva maneuvres that increase thoracic pressure. Trauma to the airway. Clinical Features: Crepitus on palpation (crackling sensation or sound). Swelling in the chest, neck, or face; distorted facial appearance; vocal changes; dysphagia. Severe cases: Hemodynamic or respiratory compromise due to extensive air spread. Investigation: X-ray: Shows radiolucent streaks, "ginkgo leaf sign" on chest radiograph. CT scan: Detects deeper air pockets and the source of air leakage. Ultrasound: May reveal hyperechoic scattered densities. Management: Mild cases: Observation, as resolution usually occurs within 10 days if the underlying cause is controlled. Oxygen therapy: Helps nitrogen washout and promotes reabsorption of gas, especially in pneumothorax/pneumomediastinum. Ventilated patients: Reduce tidal volume, PEEP, and avoid bronchospasm to minimize progression. Surgical intervention (for severe cases): Bilateral infraclavicular incisions (2 cm) to release air. Subcutaneous drains in extreme cases. Airway management: Consider tracheostomy if there is a tracheal tear with worsening subcutaneous emphysema. Antibiotics: If mucosal injury is suspected to prevent mediastinitis. Gas gangrene (Option B) is caused by Clostridium species and involves severe tissue destruction and infection, often in the context of deep wounds or surgical procedures. It typically leads to more systemic signs such as fever, shock, and tissue necrosis, which are not seen in this case. It is not directly related to chest trauma or the presence of

crepitus, making it an incorrect option. Acute tubular necrosis (Option C) refers to kidney damage due to ischemia, toxins, or infection, leading to renal dysfunction. It does not present with crepitus or air trapped in the subcutaneous tissue, and is unrelated to chest trauma. Therefore, it is not relevant to this clinical scenario. SVC syndrome (Option D) : Superior vena cava syndrome results from partial or complete obstruction of the SVC, usually due to thrombus formation or tumor infiltration. It presents with symptoms such as face/neck swelling, distended neck veins, cough, dyspnea, orthopnea, and upper extremity swelling. However, SVC syndrome does not involve crepitus, which is the hallmark of subcutaneous emphysema.

References:

https://www.ncbi.nlm.nih.gov/books/NBK542192/

https://www.ncbi.nlm.nih.gov/books/NBK441981/

↑ *Back to this question in Part A*

@Neet_pg_bot

Q23: Which of the following imaging tests should be performed to confirm a diagnosis of pulmonary embolism in a patient? (Q857034)

A. Doppler echocardiography

B. CT pulmonary angiography

C. Ventilation perfusion scan of lungs

D. MR pulmonary angiography

Correct Answer: B. CT pulmonary angiography

Explanation: CT pulmonary angiogram is the gold standard for diagnosing pulmonary embolism , as it allows direct visualization of the pulmonary arteries and identification of any occlusions. Investigations for Pulmonary Embolism (PE) Clinical Evaluation PE symptoms are nonspecific, often leading to excessive use of CT pulmonary angiograms. Age-adjusted d-dimer testing is recommended for patients over 50 years with low-to-moderate PE probability. D-Dimer A sensitive but nonspecific test for PE. Elevated levels indicate possible PE but can also occur with conditions like MI, pneumonia, or sepsis. Normal d-dimer helps rule out PE. Electrocardiogram (ECG) Common findings include sinus tachycardia(most common) and the S1Q3T3 sign (most specific) (S wave in lead I, Q wave in lead III, inverted T wave in lead III). T-wave inversion in V1 to V4 suggests RV strain or ischemia. {{caption_text}} Venous Ultrasonography Uses loss of vein compressibility as a key indicator for diagnosing DVT, which is associated with PE. Doppler imaging can assess blood flow dynamics. Chest X-ray Often normal but may show specific signs like Westermark’s sign (focal oligemia), Hampton’s hump (wedge-shaped pleural density), or Palla’s sign (enlarged pulmonary artery). {{caption_text}} Chest radiograph demonstrating focal oligemia (Westermark’s sign) in the right lung (area between white arrowheads) and a prominent right descending pulmonary artery (Palla’s sign) (black arrow). {{caption_text}} The chest radiograph demonstrates a wedge-shaped opacity (arrow) in the right middle lobe consistent with Hampton hump. Chest CT with Contrast

The primary imaging test. It offers high-resolution visualisation of pulmonary vasculature. RV enlargement on CT indicates a higher risk of mortality. Lung Scanning A second-line test, mostly for patients who can’t tolerate contrast. High-probability perfusion scans (two or more segmental perfusion defects) strongly suggest PE. Magnetic Resonance (MR) Imaging MR venography with gadolinium can diagnose DVT when ultrasound is inconclusive, though MR pulmonary angiography (Option D) is less reliable for smaller PEs. Echocardiography It is not reliable (Option A) for directly diagnosing PE but useful for detecting mimicking conditions. McConnell’s sign (RV-free wall hypokinesis) is an indirect sign of PE. {{caption_text}} CT Pulmonary Angiography Identifies intraluminal filling defects or abrupt vessel occlusion. Ventilation-perfusion (V/Q) scan (Option C) can suggest the likelihood of PE by showing mismatched perfusion defects, but it is not as definitive as other imaging modalities.

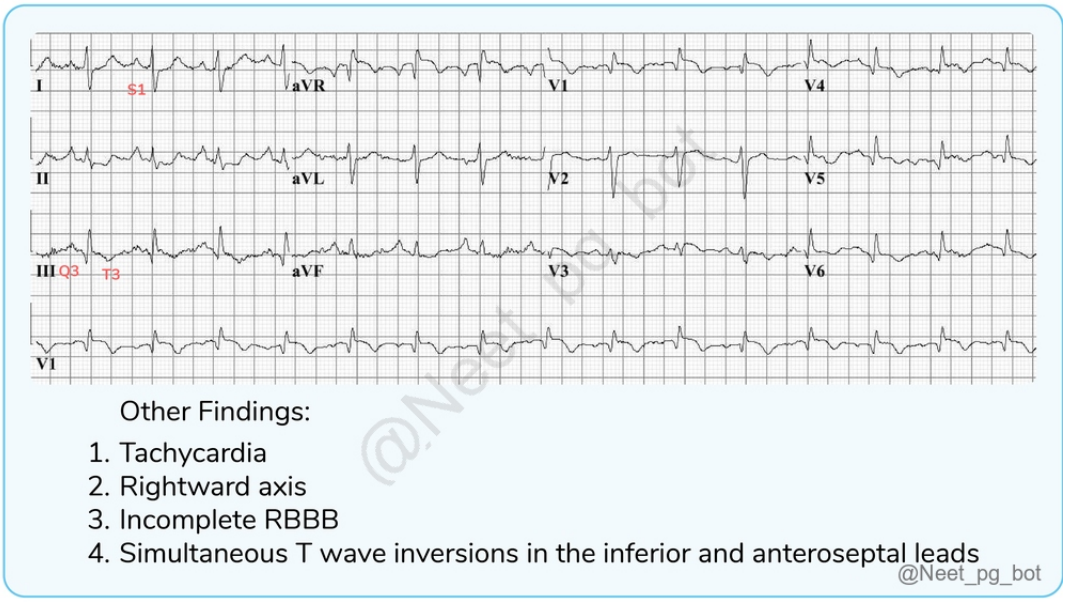

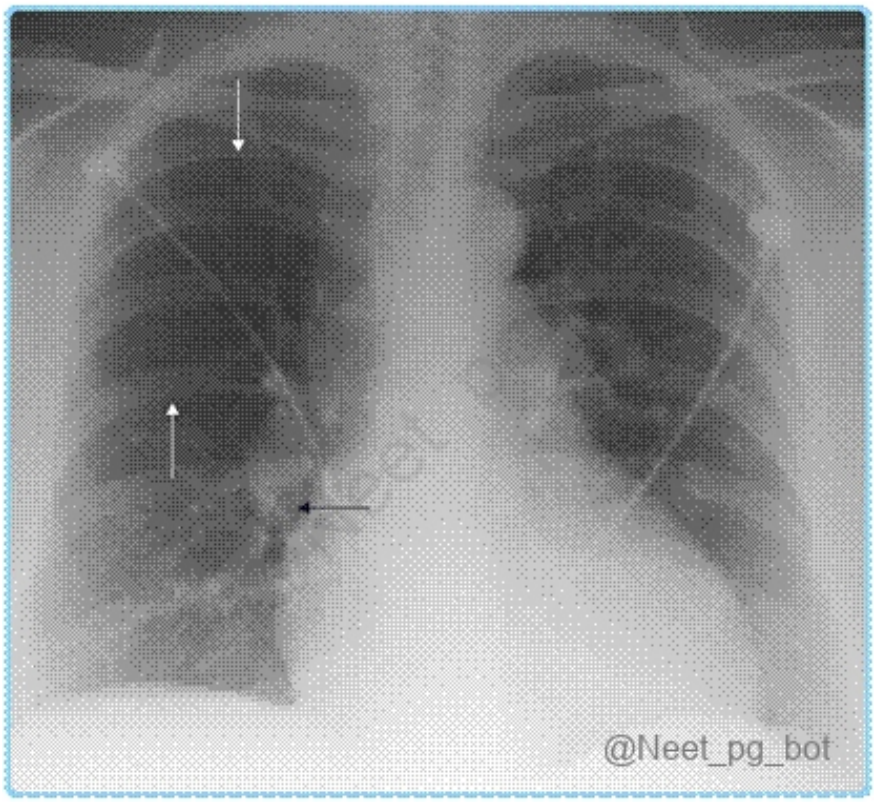
@Neet_pg_bot

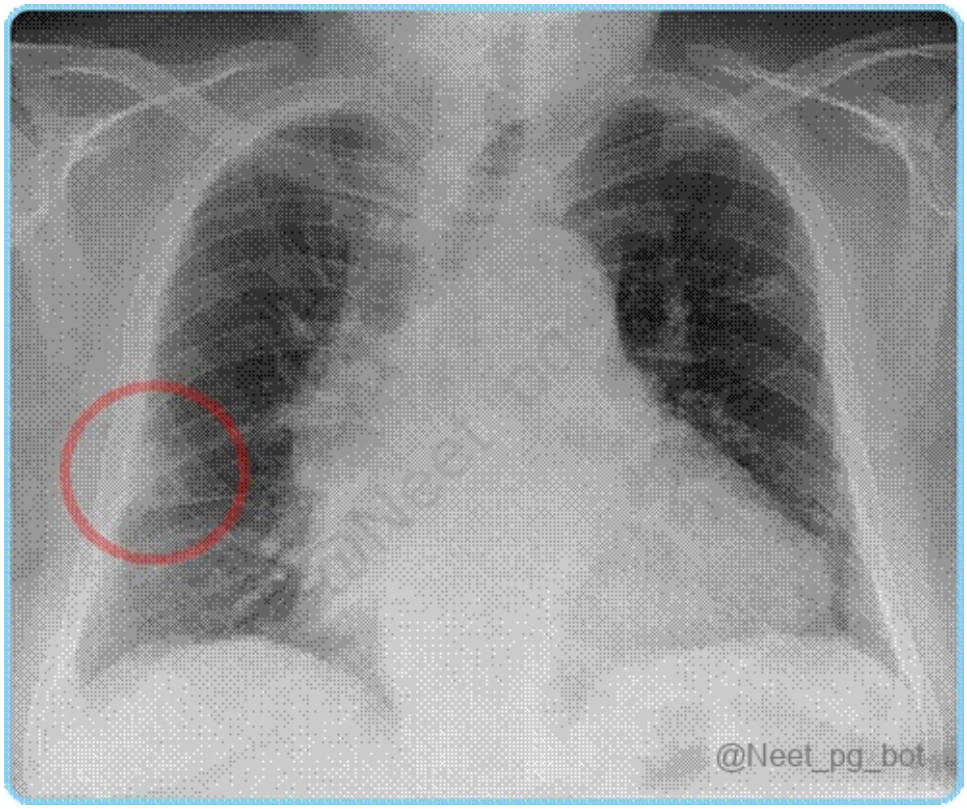
@Neet_pg_bot

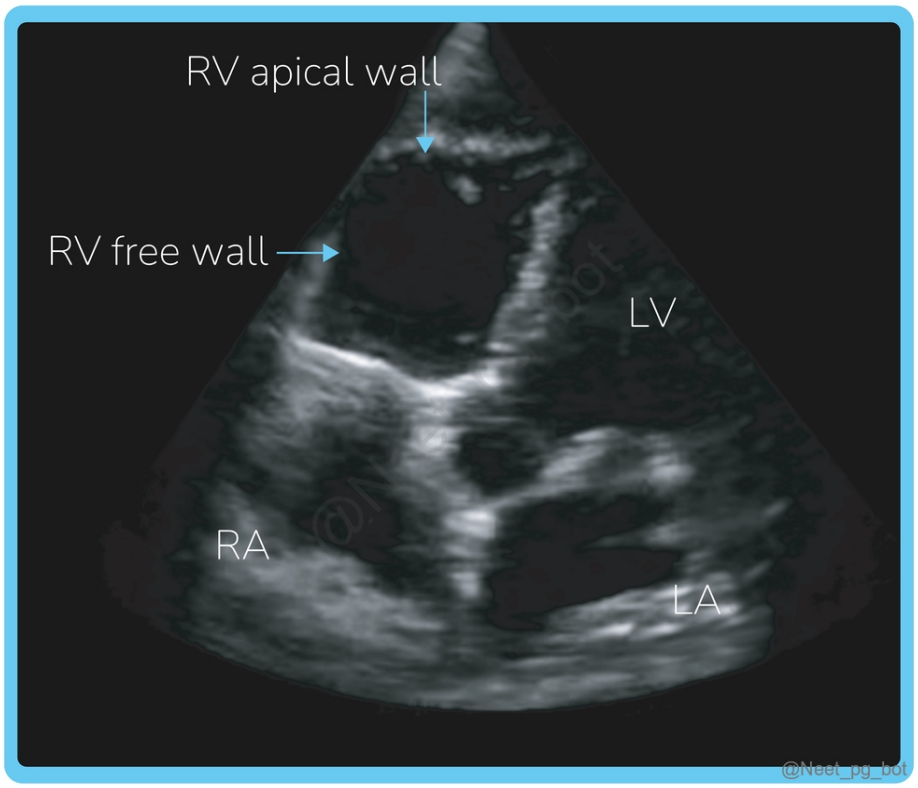

References:

Harrison's Principles of Internal Medicine, 21st edition, Page 2094-2097

↑ *Back to this question in Part A*

@Neet_pg_bot

Q24: A male patient presents to the emergency department with the following arterial blood gas (ABG) values: pH: 7.2 pCO2: 81 mmHg HCO3: 40 mEq/L What is the most likely diagnosis? (Q856014)

A. Respiratory alkalosis

B. Metabolic acidosis

C. Respiratory acidosis

D. Metabolic alkalosis

Correct Answer: C. Respiratory acidosis

Explanation: The arterial blood gas values point to respiratory acidosis, a condition characterized by: Decreased pH (<7.35): Indicates acidosis. Increased pCO2 (>45 mmHg): Suggests a respiratory cause for the acidosis. Elevated HCO3: Indicates partial metabolic compensation. Interpretation of ABG: Primary disorder: A high pCO2 and low pH confirm a primary respiratory acidosis. Compensation: The elevated HCO3 suggests renal compensation, which occurs as the kidneys retain bicarbonate to buffer the acidosis. Causes of Respiratory Acidosis: Acute Causes: Severe asthma or chronic obstructive pulmonary disease (COPD) exacerbations. Airway obstruction (e.g., foreign body, anaphylaxis). Neuromuscular disorders (e.g., Guillain-Barré syndrome). Central respiratory depression (e.g., from opioids or sedatives). Chronic Causes: COPD or other chronic lung diseases. Obesity hypoventilation syndrome. Sleep apnea. ABG Analysis Parameter Metabolic Acidosis (Option B) Metabolic Alkalosis (Option D) Respiratory Acidosis Respiratory Alkalosis (Option A) Primary Disturbance ↓ HCO■■ (Bicarbonate) ↑ HCO■■ (Bicarbonate) ↑ PaCO■ (Hypoventilation) ↓ PaCO■ (Hyperventilation) ABG Parameters pH ↓ (Acidemia) ↑ (Alkalemia) ↓ (Acidemia) ↑ (Alkalemia) HCO■■ (Bicarbonate) ↓ ↑ Normal or ↑ Normal or ↓ PaCO■ (Carbon dioxide) Normal or ↓ Normal or ↑ ↑ ↓ Compensation Mechanism Respiratory: Hyperventilation (↓ PaCO■) Respiratory: Hypoventilation (↑ PaCO■) Renal: ↑ HCO■■ reabsorption, ↑ H■ excretion Renal: ↓ HCO■■ reabsorption, ↓ H■ excretion Compensation Status Compensated Normal pH, ↓ HCO■■, ↓ PaCO■ Normal pH, ↑ HCO■■, ↑ PaCO■ Normal pH, ↑ PaCO■, ↑ HCO■■ Normal pH, ↓ PaCO■, ↓ HCO■■ Decompensated ↓ pH, ↓ HCO■■, inadequate ↓ PaCO■ ↑ pH, ↑ HCO■■, inadequate ↑ PaCO■ ↓ pH, ↑ PaCO■, inadequate ↑ HCO■■ ↑ pH, ↓ PaCO■, inadequate ↓ HCO■■ Common Causes ↑ Anion Gap: DKA, Lactic acidosis Normal Anion Gap: Diarrhea, Renal Tubular Acidosis (RTA) Vomiting Diuretics Antacid overuse COPD Respiratory depression Airway obstruction Anxiety Pain Fever High altitude Clinical Features Kussmaul breathing Confusion Hypotension Muscle cramps Tetany Hypokalemia Headache Confusion Dyspnea Dizziness Numbness Tetany

References:

Harrison's Principles of Internal Medicine, 21st Edition, Page: 359, 361, 365, 367, 368, 2011.

Ganong's Review Of Medical Physiology, 26th Edition Page: 630, 631.

https://www.ncbi.nlm.nih.gov/books/NBK536919/

https://www.thoracic.org/professionals/clinical-resources/critical-care/clinical-education/abgs.php

↑ *Back to this question in Part A*

@Neet_pg_bot

Q25: A 48-year-old woman presents with progressive shortness of breath and a dry cough for the past 6 months. HRCT chest is given below. All of the following are true about this condition except: (Q879457)

A. End inspiratory coarse crackles are heard

B. Honeycombing with reticular markings is visible on HRCT

C. Both pneumococcal and influenza vaccines are advised for such patients

D. Rheumatoid arthritis is associated with this condition

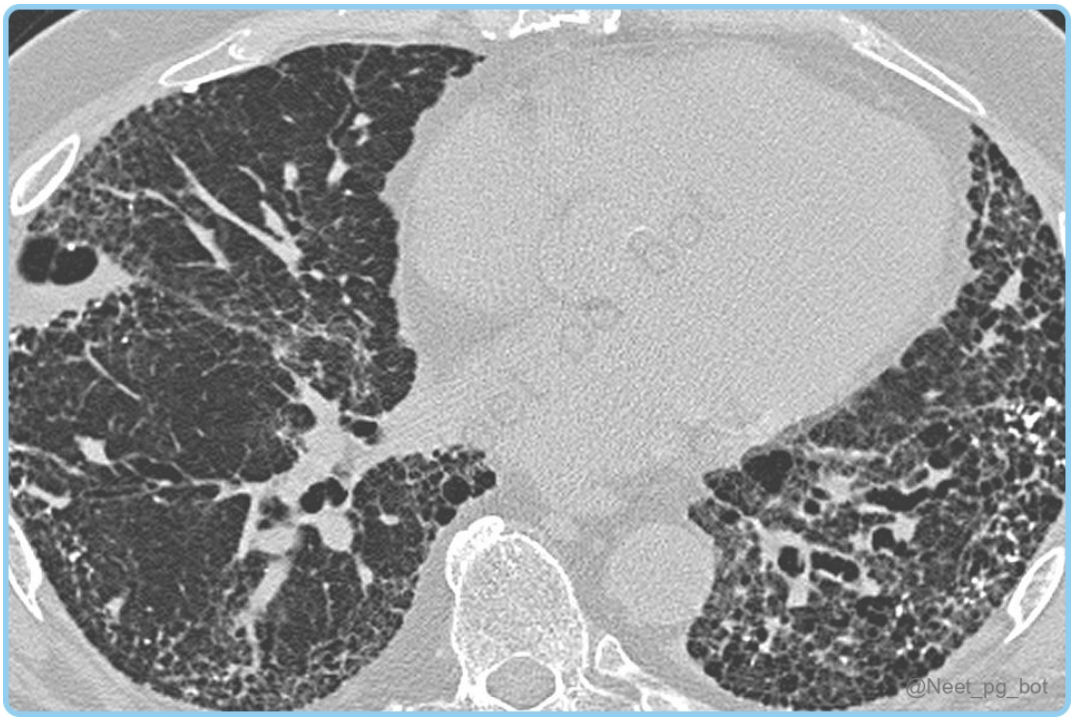

Correct Answer: A. End inspiratory coarse crackles are heard

Explanation: The HRCT demonstrates basal, subpleural honeycombing with reticular septal thickening , which is characteristic of a Usual Interstitial Pneumonia (UIP) pattern. UIP/IPF patients classically have fine, “Velcro-like” end-inspiratory crackles , not coarse ones. Incorrect Options: Honeycombing with reticular markings on HRCT (Option B): This is the defining radiologic feature of UIP. Both pneumococcal and influenza vaccines are advised (Option C): Standard management to reduce infection-related exacerbations in ILD patients. Rheumatoid arthritis is associated with this condition (Option D): RA commonly leads to ILD, and UIP is the most frequent pattern seen.

References:

.Harrison’s Principles of Internal Medicine, 22nd Edition, Pages 2262-2263.

↑ *Back to this question in Part A*

@Neet_pg_bot

Q26: A 58-year-old woman with rheumatoid arthritis, treated with methotrexate for 4 months, develops worsening shortness of breath and a nonproductive cough. Physical examination reveals bilateral fine crackles at the lung bases. Chest CT demonstrates bilateral ground-glass opacities consistent with interstitial lung involvement. What is the most likely diagnosis? (Q879212)

A. Methotrexate-induced pneumonitis

B. Bacterial pneumonia

C. Congestive heart failure

D. Sarcoidosis

Correct Answer: A. Methotrexate-induced pneumonitis

Explanation: Thus, the most consistent diagnosis based on presentation and investigations is methotrexate-induced pneumonitis. The patient has been on methotrexate therapy for 4 months and presents with subacute symptoms of cough, dyspnea, and bilateral ground-glass opacities on HRCT, which are characteristic of methotrexate pneumonitis.■ It is an immune-mediated reaction, often occurring within the first year of treatment, with symptoms including dry cough, dyspnea, fever, and nonspecific radiologic findings like ground-glass opacities. The hallmark of diagnosis includes clinical features, exclusion of infections, and improvement after discontinuation of methotrexate and corticosteroid therapy. Bacterial pneumonia (Option B): Usually presents acutely with fever, productive cough, and localized consolidation. Congestive heart failure (Option C): Features dyspnea, basal crepitations, cardiomegaly, pleural effusion, and often systemic edema. Sarcoidosis (Option D): Characterized by bilateral hilar lymphadenopathy and non-caseating granulomas, not acute basal ground-glass opacities.

References:

Methotrexate-induced pneumonitis in a patient of rheumatoid arthritis - PMC

↑ *Back to this question in Part A*

@Neet_pg_bot

Q27: Which of the following risk factors is most likely to be associated with invasive pulmonary aspergillosis? (Q879209)

A. HIV patient with CD4+ count < 50

B. Febrile neutropenia

C. Patient on steroids

D. Diabetes mellitus

Correct Answer: B. Febrile neutropenia

Explanation: Invasive pulmonary aspergillosis (IPA) most commonly occurs in patients with prolonged and severe neutropenia , such as those receiving cytotoxic chemotherapy for hematologic malignancies or post–bone marrow transplantation. Although steroids, diabetes, and HIV predispose to other fungal infections, Aspergillus requires neutrophil dysfunction rather than T-cell deficiency for invasive disease.

References:

Harrison’s Principles of Internal Medicine, 21st Edition, Pages 1424–1426.

↑ *Back to this question in Part A*

@Neet_pg_bot

Q28: According to GOLD guidelines, what is the approximate cutoff value of FEV■ (% predicted) associated with clinically significant resting hypoxemia in chronic COPD patients? (Q879208)

A. 20%

B. 30%

C. 40%

D. 50%

Correct Answer: B. 30%

Explanation: According to the GOLD (Global Initiative for Chronic Obstructive Lung Disease) guidelines, clinically significant resting hypoxemia (PaO■ ≤ 55 mm Hg or SaO■ ≤ 88%) in COPD patients generally occurs when FEV■ falls below about 30% of the predicted value. This level corresponds to very severe (GOLD 4) COPD, where gas exchange impairment due to alveolar destruction and ventilation–perfusion mismatch becomes pronounced.

References:

Harrison’s Principles of Internal Medicine, 21st Edition, Pages 1780–1782.

↑ *Back to this question in Part A*

@Neet_pg_bot

Q29: According to GOLD COPD classification, which of the following is/are correct? Mild - FEV1/FVC < 0.7 and FEV1 >80% Moderate - FEV1/FVC < 0.7 and FEV1 >50 % but < 80% Severe - FEV1/FVC < 0.7 and FEV1 > 40% but < 50% Very severe - FEV1/FVC < 0.7 and FEV1 < 40% (Q879176)

A. 1

B. 1, 2

C. 1, 2, 3

D. 2, 3, 4

Correct Answer: B. 1, 2

Explanation: According to GOLD spirometric classification , all stages have FEV■/FVC < 0.7 . The grading by FEV■ is: Mild (GOLD 1): FEV■ ≥ 80% predicted Moderate (GOLD 2): 50% ≤ FEV■ < 80% Severe (GOLD 3): 30% ≤ FEV■ < 50% Very severe (GOLD 4): FEV■ < 30%.

References:

Global Initiative for Chronic Obstructive Lung Disease. Global Strategy for the Diagnosis, Management, and Prevention of Chronic Obstructive Pulmonary Disease – 2025 Report, Page 25.

↑ *Back to this question in Part A*

@Neet_pg_bot

Q30: According to GOLD guidelines, which of the following are appropriate next steps in management of this acute COPD exacerbation in a smoker with RR 30/min, pulse 112/min, resting Sa02 87% room air and pCO2 60 mm Hg? a. Antibiotics b. Systemic corticosteroids c. Anti-virals d. Nebulized bronchodilators (Q879161)

A. a,c,d

B. a,b,d

C. b,c,d

D. a,b,c,d

Correct Answer: B. a,b,d

Explanation: According to the GOLD (Global Initiative for Chronic Obstructive Lung Disease) guidelines, management of acute exacerbation of COPD (AECOPD) includes: Nebulised bronchodilators (β■-agonists ± anticholinergics) are the first-line therapy to relieve bronchospasm. Systemic corticosteroids (e.g., prednisolone 40 mg/day for 5–7 days) to reduce inflammation and shorten recovery time. Antibiotics are indicated when there is increased sputum purulence, volume, or dyspnea, or when the patient requires mechanical ventilation. Antivirals are not routinely recommended, as bacterial infections or non-influenza viruses cause most exacerbations.

References:

GOLD 2025 Report: Global Initiative for Chronic Obstructive Lung Disease - Management of Exacerbations, Pages 87-90. Harrison’s Principles of Internal Medicine, 21st Edition, Page 1787-1789.

↑ *Back to this question in Part A*

@Neet_pg_bot

Q31: A 50-year-old male patient undergoing treatment for lung cancer complains of difficulty in breathing and dizziness. Upon examination, diminished breath sounds are noted over the left inferior-scapular region. What is the most probable diagnosis? (Q830830)

A. Constrictive pericarditis

B. Pleural effusion

C. Cardiac tamponade

D. Pneumothorax

Correct Answer: B. Pleural effusion

Explanation: Correct Option B - Pleural effusion: Pleural effusion involves the accumulation of fluid in the pleural space, leading to compression of the lung. Diminished breath sounds over the affected area are a characteristic finding. It is a common complication in lung cancer patients. Incorrect Options: Option A - Constrictive pericarditis: Constrictive pericarditis is characterized by the thickening and fibrosis of the pericardium, leading to impaired diastolic filling of the heart. It typically presents with symptoms such as dyspnea and fatigue, but it is not associated with diminished breath sounds over a specific lung region. Option C - Cardiac tamponade: Cardiac tamponade results from the accumulation of fluid in the pericardial sac, leading to impaired cardiac filling. This condition can cause symptoms such as dyspnea and dizziness, but it is not associated with diminished breath sounds in a specific lung region. Option D - Pneumothorax: Pneumothorax reduces breath sounds, but typically over the upper/anterior chest, not the lower posterior lung fields, which instead suggests fluid.

References:

.

↑ *Back to this question in Part A*

@Neet_pg_bot

Q32: In bronchial asthma, what is the minimum percentage increase in the FEV1/FVC ratio that indicates a reversible obstruction following the administration of bronchodilators? (Q830825)

A. >12%

B. >20%

C. >10%

D. >18%

Correct Answer: A. >12%

Explanation: Correct Option A - >12%: In the context of bronchial asthma, the FEV1/FVC ratio is a measure of airflow limitation. After the administration of bronchodilators, an improvement in airflow may be observed in reversible airway obstruction. The criterion for a significant response is usually defined as an increase in the FEV1/FVC ratio by more than 12%. This improvement indicates that the bronchodilator has effectively reversed the airflow limitation in the patient.

↑ *Back to this question in Part A*

@Neet_pg_bot

Q33: A male patient with infertility presents a disorder comprising the triad of situs inversus, chronic sinusitis, and bronchiectasis. Which of the following is the correct diagnosis? (Q860392)

A. Kartagener's syndrome

B. Cystic fibrosis

C. Mucovicidosis

D. Klinefelter syndrome

Correct Answer: A. Kartagener's syndrome

Explanation: Kartagener's syndrome is a rare genetic disorder characterized by primary ciliary dyskinesia affecting the respiratory tract and reproductive system. The condition is autosomal recessive and results from a defect in the dynein protein, which affects ciliary motility. The classical clinical presentation includes a diagnostic triad of situs inversus, chronic sinusitis, and bronchiectasis . Additional manifestations include male infertility due to impaired sperm motility and subfertility in females due to altered ciliary function in the fallopian tubes. Cystic fibrosis (Option B): While cystic fibrosis can cause respiratory symptoms and male infertility, it typically presents with productive cough, steatorrhea, and failure to thrive. The characteristic triad of situs inversus, chronic sinusitis, and bronchiectasis are not typical of cystic fibrosis. Mucovicidosis (Option C): This is another name for cystic fibrosis and is not a separate condition. The term is sometimes used interchangeably with cystic fibrosis. Klinefelter syndrome (Option D) : This is a chromosomal disorder characterized by an extra X chromosome in males, presenting with tall stature, small testes, gynecomastia, and azoospermia. It does not involve the respiratory manifestations described in the case.

References:

https://pmc.ncbi.nlm.nih.gov/articles/PMC3519024/

Shaw's Textbook of Gynaecology, 17th Edition, Page 205-206

↑ *Back to this question in Part A*

@Neet_pg_bot

Q34: A 55-year-old man presents with altered sensorium and deep labored breathing. ABG is given below. What is the most likely acid-base disorder? pH: 7.20 pCO■: 31 mmHg HCO■■:16 mEq/L Na■: 130 mEq/L Cl■: 84 mEq/L PaO■: 80 mmHg (Q866496)

A. Metabolic acidosis

B. Metabolic alkalosis

C. Respiratory acidosis

D. Respiratory alkalosis

Correct Answer: A. Metabolic acidosis

Explanation: This ABG shows low pH (acidemia) , low HCO■■ (16 mEq/L) , and compensatory low pCO■ (31 mmHg) - the primary process is metabolic acidosis with respiratory compensation. The sodium and chloride values suggest a high anion gap metabolic acidosis (AG = Na■ – (Cl■ + HCO■■) = 130 – (84 + 16) = 30 mEq/L), which could be due to causes like lactic acidosis, renal failure, ketoacidosis, or toxins. Metabolic acidosis Definition Primary decrease in HCO3■ or increase in H■ ions Characterized by ↓ pH and ↓ HCO3■ Compensatory mechanism: ↓ PaCO2 through hyperventilation (Kussmaul breathing) Types High anion gap (AG > 12 mEq/L) Normal anion gap (AG 6-12 mEq/L) Causes (Mnemonic: MUDPILES) M : Methanol U : Uremia (Renal failure) D : Diabetic ketoacidosis (DKA) P : Paraldehyde, Phenformin, Propylene glycol I : Iron tablets, Isoniazid L : Lactic acidosis E : Ethylene glycol S : Salicylates (late phase) (Mnemonic: HARD UP) H : Hyperalimentation (TPN) A : Acetazolamide R : Renal Tubular Acidosis (Option C) D : Diarrhea U : Ureteral diversion P : Pancreatic fistula GIT fistulas Clinical Features General Features : Lethargy Confusion Fatigue Nausea/vomiting Deep, rapid breathing (Kussmaul) Specific Features : DKA: Fruity breath, polyuria, polydipsia Uremia: Itching, volume overload Lactic acidosis: Shock, hypotension Toxic ingestion: Visual disturbances (methanol), oxalate crystals (ethylene glycol) Metabolic alkalosis (Option B): Would have elevated pH and high HCO■■, not low values. Respiratory acidosis (Option C): Would show high pCO■ and low pH, not low pCO■. Respiratory alkalosis (Option D): Would have high pH and low pCO■, but here pH is low.

↑ *Back to this question in Part A*

@Neet_pg_bot

Q35: Multidrug-resistant (MDR) tuberculosis shows resistance to which of the following drugs? (Q856022)

A. Isoniazid, rifampicin, and fluoroquinolone

B. Fluoroquinolones

C. Isoniazid and rifampicin

D. Isoniazid, rifampicin, and kanamycin

Correct Answer: C. Isoniazid and rifampicin

Explanation: Multidrug-resistant tuberculosis (MDR-TB) is defined by resistance to at least isoniazid and rifampicin, the two most potent first-line anti-TB drugs. Drug-Sensitive Tuberculosis (DSTB) Tuberculosis that is susceptible to the first-line anti-TB drugs, such as isoniazid and rifampin. Drug-Resistant Tuberculosis (DR-TB) TB caused by Mycobacterium tuberculosis strains that are resistant to at least one first-line anti-TB drug. Multidrug-Resistant Tuberculosis (MDR-TB) TB caused by Mycobacterium tuberculosis strains that are resistant to at least isoniazid and rifampin, the two most potent first-line anti-TB drugs. Extensively Drug-Resistant Tuberculosis (XDR-TB) A more severe form of MDR-TB resistant to isoniazid, rifampin, fluoroquinolones, and at least one of the second-line injectable drugs (e.g., amikacin, kanamycin, or capreomycin).

References:

Harrison’s Principles of Internal Medicine, 21st Edition, Pages 961, 1359, 1369, 1372, 1372, 1376-1378.

Goodman & Gillman's The Pharmacological Basis of Therapeutics, 13th Edition, Page: 761, 1068, 1070, 1071, 1072, 1073, 1074.

https://www.ncbi.nlm.nih.gov/books/NBK557666/

https://pmc.ncbi.nlm.nih.gov/articles/PMC4561400/

↑ *Back to this question in Part A*

@Neet_pg_bot

Q36: A patient was admitted to the ICU 48 hours after an accident in which he sustained a fracture of the femur. The oxygen saturation in the rebreathing unit was 100% but his SpO2 remained at 60%. The patient is in a state of confusion. Diffuse petechiae are noted on examination. Chest radiograph showed lung fields to be clear. What is the most likely diagnosis? (Q857033)

A. Pulmonary embolism

B. Fat embolism

C. ARDS

D. Occult pneumothorax

Correct Answer: B. Fat embolism

Explanation: Fat embolism is the most likely diagnosis, given the recent trauma, respiratory distress, altered mental status, and petechial rash, which are characteristic signs of Fat Embolism Syndrome (FES) . Symptoms often develop within 24-72 hours following fat emboli entering circulation. Fat Embolism Causes Blunt trauma : Accounts for 90% of cases, especially involving extremity fractures. Associated conditions : Acute pancreatitis Diabetes mellitus Burns Joint reconstruction surgeries Liposuction Cardiopulmonary bypass Decompression sickness Parenteral lipid infusion Sickle cell crisis Pathologic fractures Increased risk factors (in trauma patients): Age 30 years or younger Closed femur fracture Multiple long-bone fractures Pathophysiology of Fat Embolism Syndrome (FES): Mechanism : Not fully understood but involves fat emboli entering circulation, usually after major trauma or surgical procedures (intramedullary nailing). Pulmonary effects : Fat emboli occlude microvasculature, leading to inflammatory responses and endothelial injury. Pulmonary consequences mimic acute respiratory distress syndrome (ARDS), presenting within 24 hours with symptoms of respiratory failure. Fatty acids released from emboli increase vascular permeability, causing alveolar haemorrhage and oedema. Systemic effects : Involvement of the brain and kidneys, especially in patients with patent foramen ovale Neurologic symptoms include encephalopathy and cerebral oedema due to cerebral vasculature occlusion. Histopathological image Pulmonary Embolism (PE) (Options A) can present with sudden dyspnea and hypoxia.

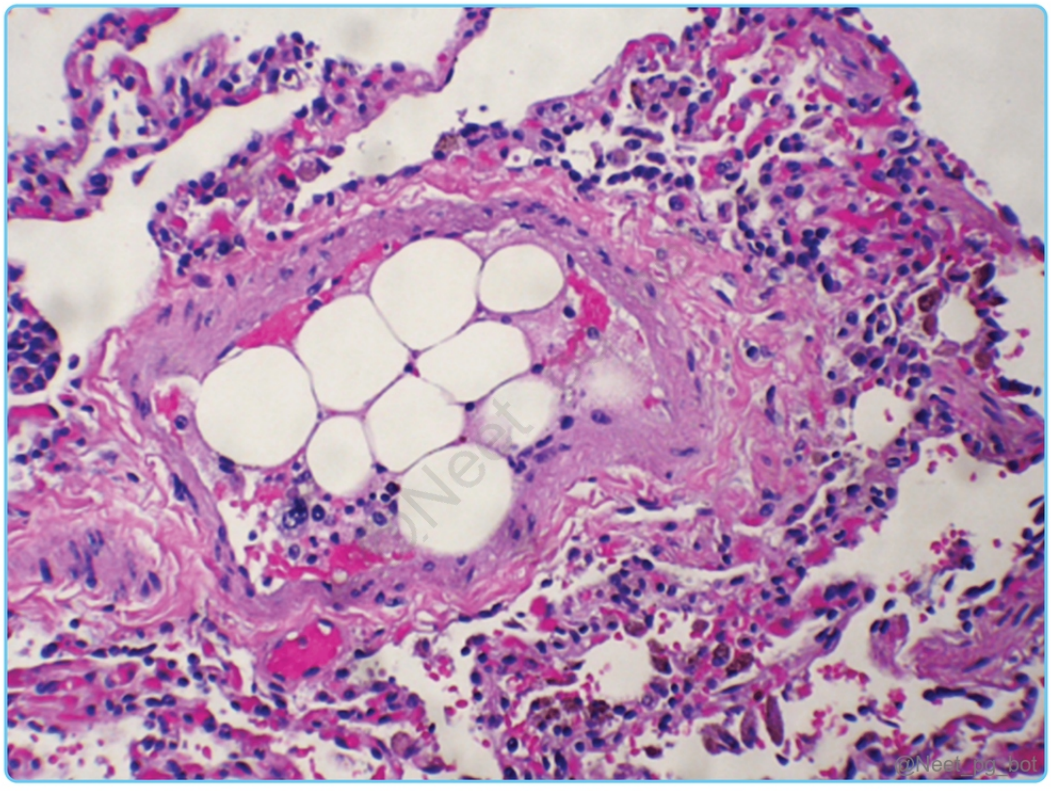

References:

https://emedicine.medscape.com/article/460524-overview#a7

↑ *Back to this question in Part A*

@Neet_pg_bot

Q37: A 35-year-old female patient presents with fever, breathlessness, and cough with expectoration. A CT scan was done, which is shown below. What is the most likely diagnosis? (Q855908)

A. Consolidation with air bronchogram

B. Mediastinal mass

C. Pleural effusion

D. Diaphragmatic hernia



Correct Answer: A. Consolidation with air bronchogram

Explanation: The patient's presentation with fever, breathlessness, cough with expectoration, and the CT scan findings of consolidation with an air bronchogram strongly suggest a pneumonic consolidation due to lobar pneumonia Clinical manifestations of Lobar pneumonia: Common Symptoms: Fever Cough Sputum production

(often mucopurulent) Pleuritic chest pain (Localized pleuritic pain is common, especially in lobar pneumonia) Constitutional Symptoms: Fatigue, headache, myalgia, and arthralgias may occur. Severe pneumonia can lead to: Dyspnea. Confusion, sepsis, and multi-organ failure. Clinical Signs: Tachypnea (increased respiratory rate) Increased vocal fremitus Egophony (E to A changes) Dullness to percussion Auscultation Findings: Presence of crackles or rales, and bronchial breath sounds (tubular type breathing). Investigation Findings Initial Evaluation Clinical suspicion based on patient history and physical examination. Chest Radiography The most important initial test for pneumonia diagnosis. Shows pulmonary infiltrate; indicates type (lobar, interstitial, unilateral, or bilateral). Cannot reliably differentiate between bacterial and non-bacterial causes. {{caption_text}} CT Scan More accurate than a chest X-ray. Focal dense opacification of an entire lobe occurs, with relative sparing of the large airways. Associated findings may include ground-glass opacities in a lobar or segmental pattern, indicating areas of partial involvement or atelectasis. {{caption_text}} Image shows left upper lung lobe consolidation of heterogenous density, with multiple air bronchograms, and small left pleural effusion Laboratory Tests Complete Blood Count (CBC): Look for leukocytosis (leftward shift) as a sign of infection. Leukopenia may indicate a poor prognosis. Inflammatory Biomarkers: ESR and acute phase reactants to assess severity. Sputum Analysis Sputum Gram stain and culture critical for suspected lobar pneumonia. Sputum culture is the most specific diagnostic test for identifying the causative organism. Influenza Testing Recommended during winter months due to the risk of co-infection with pneumonia. Patient Stratification Use CURB-65 and the pneumonia severity index to determine hospitalization needs. Additional Testing Hospitalized patients: sputum culture, blood culture, and/or urine antigen testing before antibiotics. Invasive Procedures Thoracocentesis, bronchoscopy, pleural biopsy, and pleural fluid culture are rarely performed. Open lung biopsy is the ultimate specific diagnostic test. Mediastinal mass (Option B): A mediastinal mass typically presents with symptoms like chest pain, dyspnea, and cough but not with classic symptoms of pneumonia like fever and cough with expectoration. On CT, a mediastinal mass appears as a localized area of mass effect in one of the mediastinal compartments. {{caption_text}} Pleural effusion (Option C): Pleural effusion would appear on CT as a fluid-filled space in the pleural cavity and does not cause consolidation with air bronchograms. Breathlessness is common in pleural effusion, but the characteristic CT finding would be a homogenous opacity in the pleural space. {{caption_text}} Diaphragmatic hernia (Option D): A diaphragmatic hernia would show up on CT as an abnormal position of abdominal organs (such as the stomach or bowel) in the thoracic cavity. {{caption_text}}

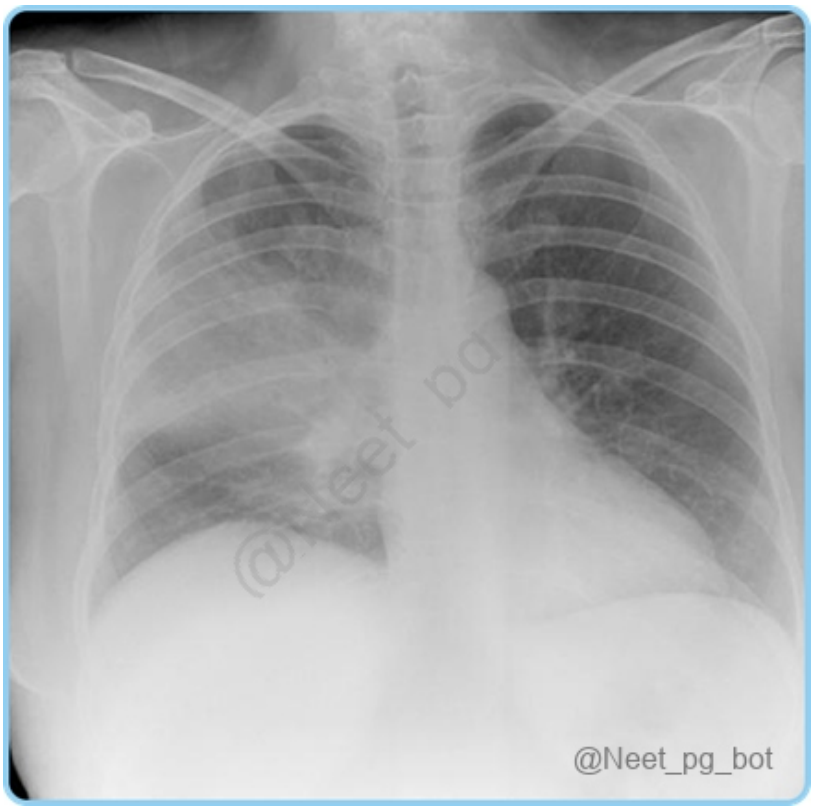
@Neet_pg_bot

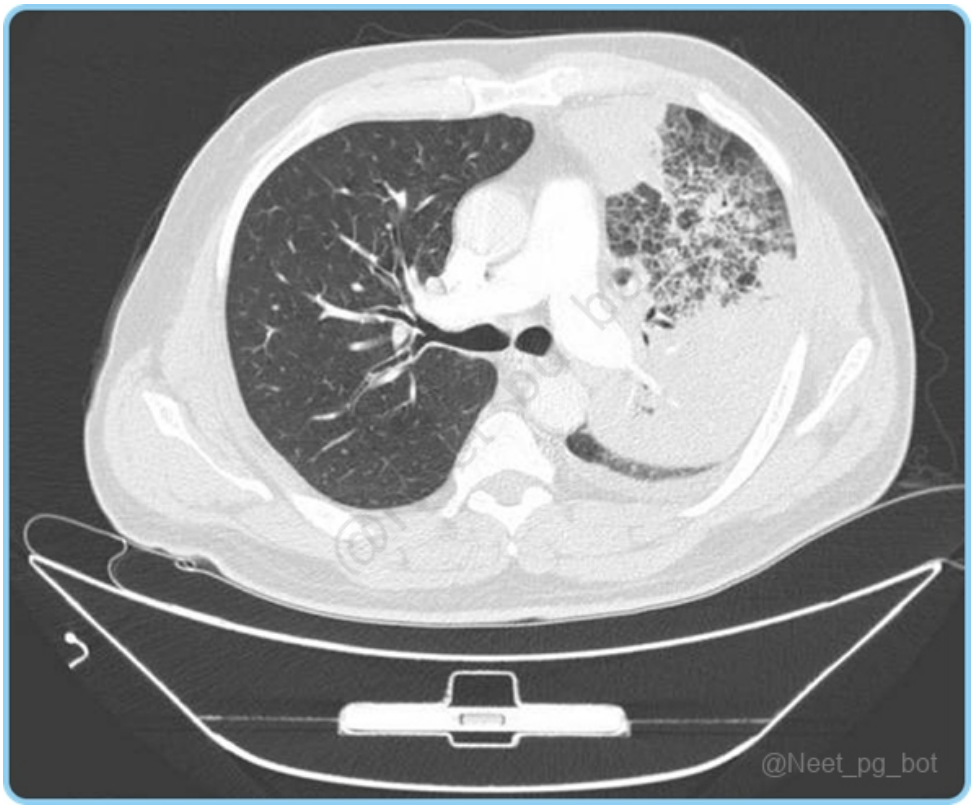
@Neet_pg_bot

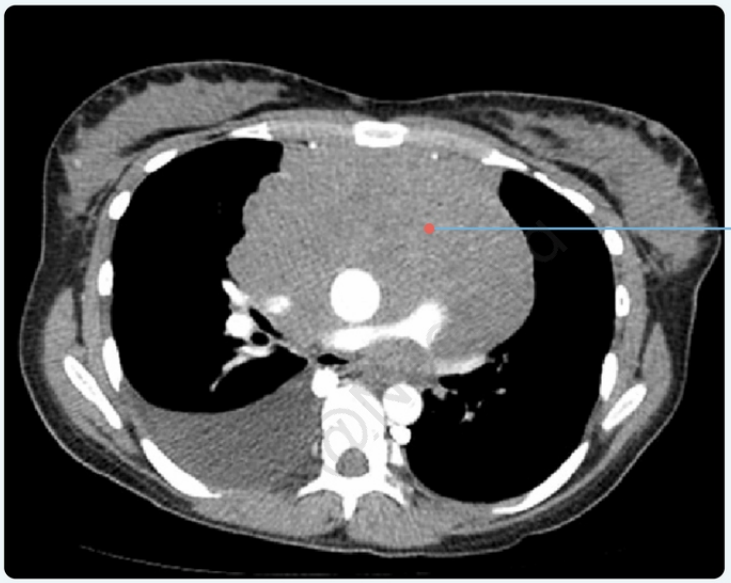

@Neet_pg_bot



CT scan of chest showing left-sided pleural effusion

@Neet_pg_bot

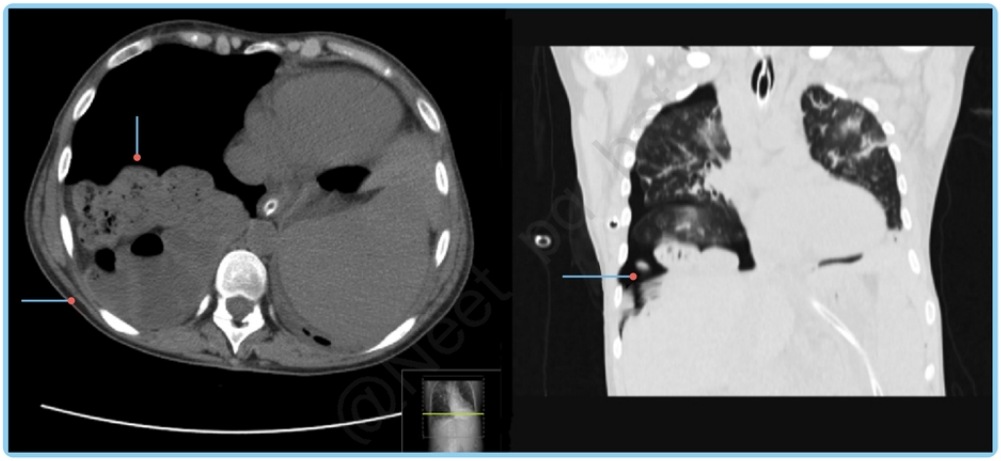

Right-sided Bochdalek hernia

@Neet_pg_bot

References:

Harrison's Principles of Internal Medicine, 21st Edition, Page: 1011, 1012, 2200.

Typical Bacterial Pneumonia - StatPearls - NCBI Bookshelf

Lobar pneumonia | Radiology Reference Article | Radiopaedia.org

↑ *Back to this question in Part A*

@Neet_pg_bot

Q38: A patient presents with fever, night sweats, ptosis, and bilateral facial nerve palsy. Investigations show leukocytosis and bilateral hilar lymphadenopathy. Which of the following is the most likely diagnosis? (Q855905)

A. Sarcoidosis

B. Tuberculosis

C. Lymphoma

D. Hypersensitive pneumonitis

Correct Answer: A. Sarcoidosis

Explanation: The clinical presentation of fever, night sweats, ptosis, and bilateral facial nerve palsy, along with leukocytosis and bilateral hilar lymphadenopathy, strongly points to sarcoidosis. Sarcoidosis: Sarcoidosis is a chronic multisystem inflammatory disorder of unknown cause, characterized by the accumulation of T lymphocytes and mononuclear phagocytes, leading to the formation of non-caseating granulomas in various

tissues of the body. Clinical Presentation Lungs (90%) Interstitial lung disease Pulmonary fibrosis Cavitation (Rare) Pleural involvement (1-5% cases) with occasional pleural effusion Pulmonary Symptoms: Dry cough, dyspnea, chest pain Lymph Nodes (75-90%) Bilateral hilar lymphadenopathy (hallmark) Parotid enlargement Extrapulmonary Symptoms: Skin Erythema nodosum (tender red nodules, often on shins) {{caption_text}} Lupus pernio (purple-blue shiny lesions on nose, cheeks, lips, and ears) {{caption_text}} Eyes: Anterior Uveitis Kidneys: Hypercalcemia with or without hypercalciuria Nervous System: Facial nerve palsy, Peripheral neuropathy Heart: Cor pulmonale (secondary to pulmonary fibrosis) Constitutional Symptoms: Fever, fatigue, night sweats, weight loss Syndromes Associated Lofgren's syndrome: Features include erythema nodosum (painful red nodules on the shins), hilar lymphadenopathy, and periarticular arthritis. Mikulicz syndrome: Involves bilateral enlargement of the parotid, submaxillary, and sublingual glands. Histopathological Features Presence of non-caseating granulomas in affected organs Granulomas are often composed of epithelioid histiocytes and giant cells (Langerhans or foreign body type) Inclusion Bodies in Giant Cells: Schaumann bodies (calcium-protein inclusions) {{caption_text}} Asteroid bodies (stellate-shaped inclusions) {{caption_text}} Initial Diagnostic Workup History and Physical Examination Assess for respiratory symptoms and extrapulmonary signs Check for bilateral hilar lymphadenopathy and skin lesions Chest Imaging Chest X-ray (Stage 1: bilateral hilar lymphadenopathy is a hallmark finding) Laboratory Investigations Serum Angiotensin-Converting Enzyme (ACE) Elevated in 60% of cases (non-specific but supportive) Calcium Levels Hypercalcemia due to increased 1,25-dihydroxyvitamin D production by macrophages in granulomas Bronchoalveolar Lavage (BAL) CD4/CD8 ratio > 3.5 supports sarcoidosis (not diagnostic alone) Pulmonary Function Tests (PFTs) Restrictive Pattern Decreased FVC and TLC Normal or increased FEV1/FVC ratio Decreased DLCO (diffusion capacity for carbon monoxide) Imaging Studies Chest X-Ray: Staging based on lung involvement Stage 0 Normal Stage 1 Bilateral hilar lymphadenopathy Stage 2 Bilateral hilar lymphadenopathy with pulmonary infiltrates Stage 3 Pulmonary infiltrates only Stage 4 Pulmonary fibrosis High-Resolution CT (HRCT): Ground-glass opacities Perilymphatic nodules Fibrotic changes Histopathology Tissue Biopsy (Gold Standard) {{caption_text}} Non-caseating granulomas in lung, lymph nodes, or skin Exclusion of other granulomatous diseases such as tuberculosis (caseating granulomas) and fungal infections Other Diagnostic Tests Gallium-67 Scintigraphy Panda Sign: Uptake in lacrimal and parotid glands {{caption_text}} Lambda Sign: Uptake in bilateral hilar and right paratracheal lymph nodes {{caption_text}} Positron Emission Tomography (PET) Identifies active inflammation and organ involvement Differential Diagnosis Infections: Tuberculosis, fungal infections Autoimmune Disorders: Lupus, rheumatoid arthritis Malignancies: Lymphoma, metastatic carcinoma Diagnostic Criteria Compatible clinical and radiographic presentation Non-caseating granulomas on histopathology Exclusion of other granulomatous diseases Tuberculosis (TB) (Option B): TB can cause fever, night sweats, and hilar lymphadenopathy but typically presents with cough and hemoptysis, which are not mentioned in this case. Facial nerve palsy is rare in TB unless there is extensive dissemination, which is unusual in early stages. Lymphoma (Option C): Lymphoma can present with fever, night sweats, and hilar lymphadenopathy. However, it is less likely to cause bilateral facial nerve palsy and ptosis as part of its presentation. Lymphoma would typically involve lymph node enlargement and may present with systemic symptoms, but it is usually not associated with granulomatous inflammation seen in sarcoidosis. Hypersensitive pneumonitis (Option D): Hypersensitivity pneumonitis (also known as extrinsic allergic alveolitis) is caused by an immune response to inhaled antigens and primarily affects the lungs, leading to symptoms like dyspnea, cough, and fever. However, it does not typically cause bilateral facial nerve palsy or hilar lymphadenopathy, as seen in this patient.


@Neet_pg_bot


@Neet_pg_bot

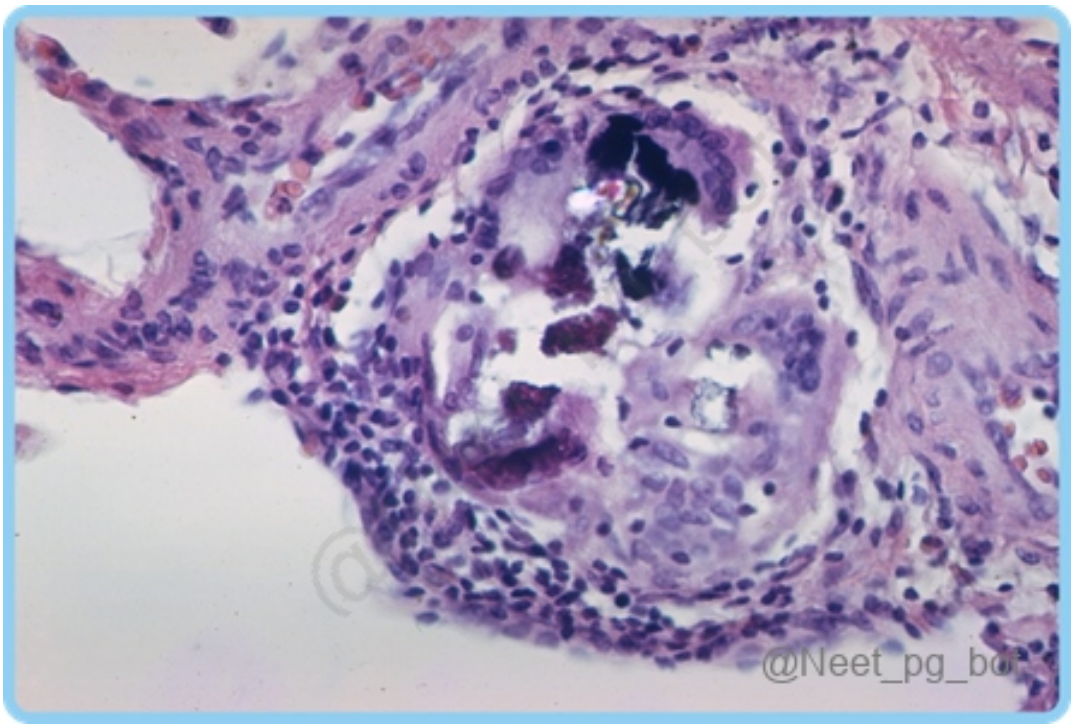
@Neet_pg_bot

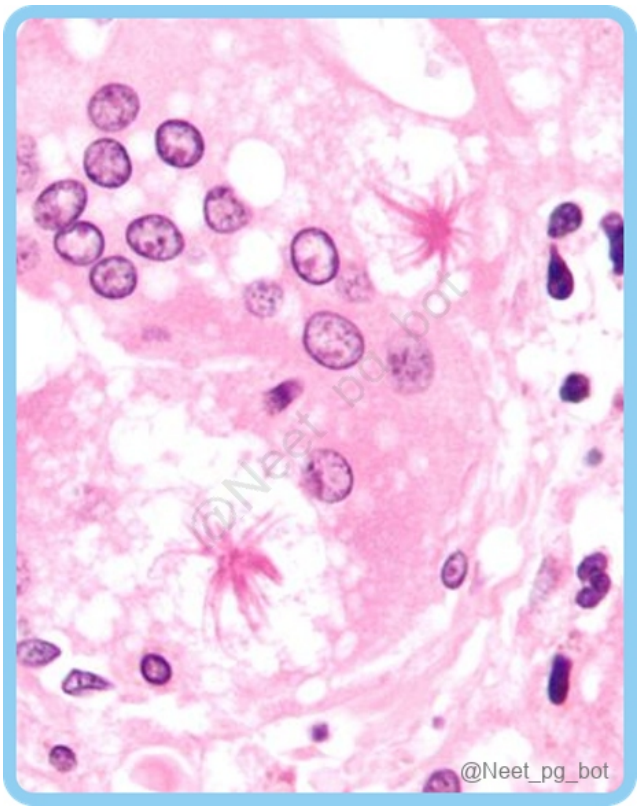
@Neet_pg_bot

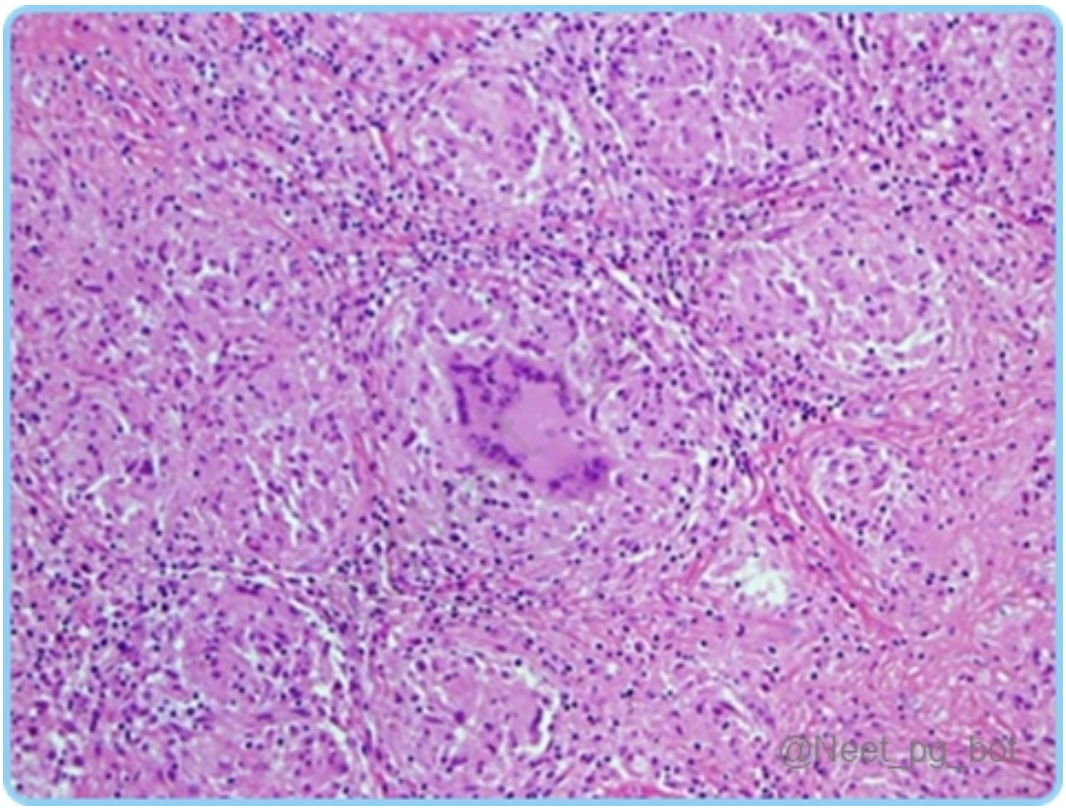

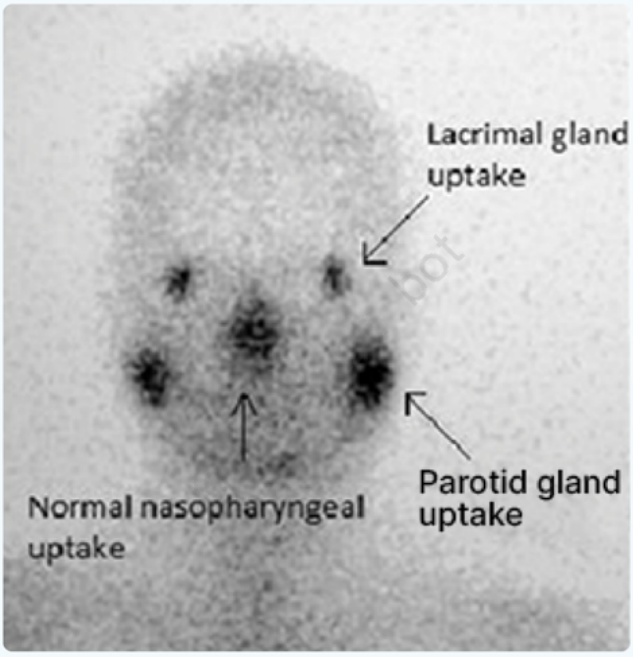

Scintigraphy

@Neet_pg_bot

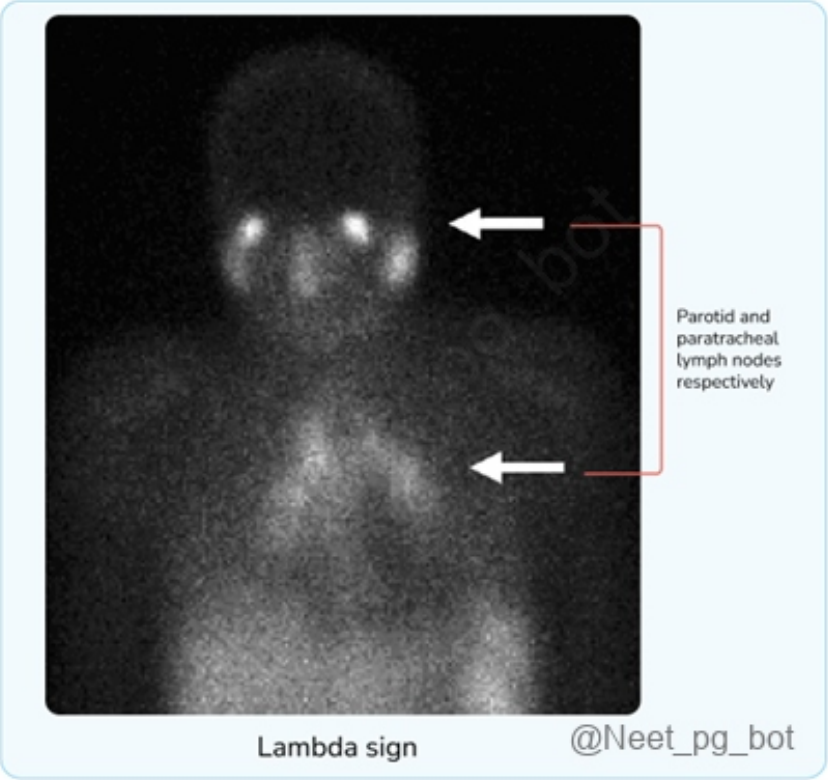

References:

Harrison's Principles of Internal Medicine, 21st Edition, Page: 461, 841, 844, 846, 852, 853, 1362, 1364, 1366, 1367, 2160, 2161, 2829-2835.

Davidson's Principles and Practice of Medicine, 24th Edition, Page: 608-610.

Robbins and Cotran Pathologic Basis of Disease, 10th Edition, Page: 214, 368, 371, 372, 696, 697.

↑ *Back to this question in Part A*

@Neet_pg_bot

Q39: A 45-year patient working in a factory for the past 20 years presents with breathlessness. HRCT chest shows pleural thickening and fibrosis. Diagnosis is? (Q859808)

A. Asbestosis

B. Coal worker pneumoconiosis

C. Silicosis

D. Berylliosis

Correct Answer: A. Asbestosis

Explanation: The clinical presentation indicates asbestosis , a form of pneumoconiosis caused by prolonged asbestos exposure. The key diagnostic features in this case include the patient's 20-year occupational exposure in a factory setting, presenting symptom of breathlessness, and most importantly, the HRCT findings of pleural thickening and fibrosis . Pleural involvement i s a characteristic feature of asbestos-related lung disease , distinguishing it from other occupational lung diseases. Workers in the shipbuilding and construction trades, including pipe fitters and boilermakers, are occupationally exposed to asbestos. Asbestosis is a diffuse interstitial fibrosing disease of the lung . Past exposure to asbestos is specifically indicated by pleural plaques on chest radiographs, which are characterized by either thickening or calcification along the parietal pleura, particularly along the lower lung fields. Pulmonary function testing in asbestosis reveals a restrictive pattern with a decrease in both lung volumes and diffusing capacity. Complications include carcinoma of lung and mesothelioma . Coal worker pneumoconiosis (Option B) is characterized by small nodules diffusely distributed throughout the lungs, with upper lobe predominance and eggshell calcification of hilar lymph nodes. The presence of pleural thickening rather than nodular opacities makes this diagnosis less likely. Silicosis (Option C) typically presents with multiple small nodules in the upper lung zones with a characteristic "ground-glass" appearance. The absence of these findings and the presence of pleural thickening make silicosis an unlikely diagnosis. Berylliosis (Option D) presents with early-stage parenchymal nodules and later develops lymphadenopathy and interstitial fibrosis. The prominent pleural involvement seen in this case is not typical of berylliosis, and the exposure history doesn't suggest beryllium exposure.

References:

Harrison’s Principles of Internal Medicine, 21st Edition, Page 2168

Davidson’s Principles and Practice of Medicine, 24th Edition, Page 615

↑ *Back to this question in Part A*

@Neet_pg_bot

Q40: The flow-volume curve of a patient after spirometry is given below. The most likely diagnosis in this patient is: (Q859564)

A. Asbestosis

B. COPD

C. Myasthenia gravis

D. Vocal cord paralysis

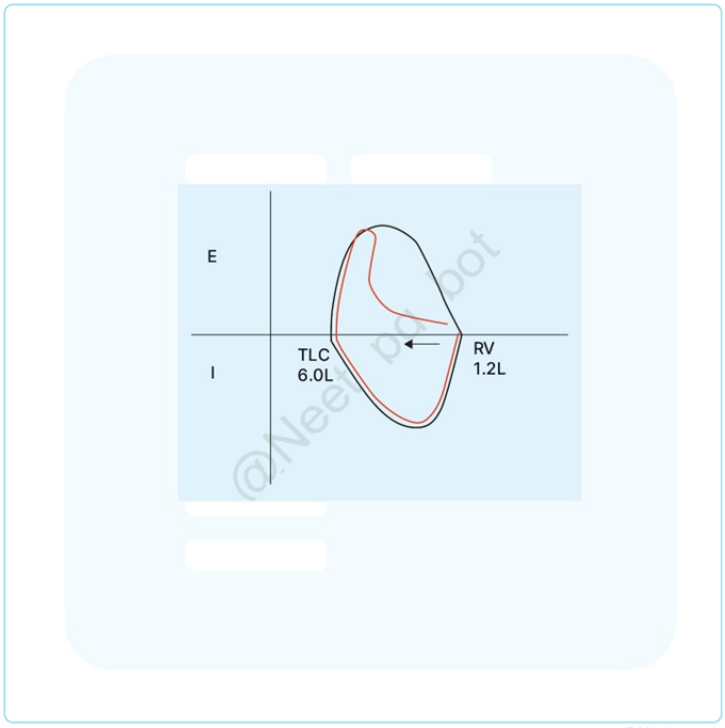

@Neet_pg_bot

Correct Answer: B. COPD

Explanation: The vignette depicts the characteristic flow volume loop seen in patients with COPD (Chronic Obstructive Pulmonary Disease) . Test Details Spirometry/PFTs Best initial test IOC Obstructive pattern Reversible with short-acting β2-agonists (SABAs) Findings: FEV1/FVC < 70% ↓ FEV1 Normal or ↓ FVC ↑ Residual Volume (RV) ↑ Total Lung Capacity (TLC) Normal or ↑ Diffusing Capacity of Lung for Carbon Monoxide (DLCO) Reversibility: Increase in FEV1 ≥ 12% and >200 mL with SABA (albuterol) PFTs between exacerbations: Often normal Methacholine Challenge Tests for bronchial hyperresponsiveness Positive if ≥20% decrease in FEV1 Sensitive but not specific Arterial blood gas Early Respiratory alkalosis (↓ PaCO2, ↑ pH) due to hyperventilation Late Respiratory acidosis due to muscle fatigue (normalizing PaCO2, normalizing pH, ↓ PaO2) Chest X-ray Normal appearance to hyperinflation with flattening of the diaphragm Options A, C and D are incorrect.

References:

Harrison's Principle of Internal Medicine, 21st Edition, Page: 2154.

↑ *Back to this question in Part A*

@Neet_pg_bot

Q41: A 46-year-old chronic alcoholic male presents to the OPD with fever, headache, shortness of breath, chest pain, and productive cough with red currant jelly sputum

for the last two days. On examination, there was bronchial breathing on the right side, increased vocal fremitus, increased vocal resonance, and a dull note on percussion. The patient's radiograph is shown below. Which is the most likely causative agent? (Q859561)

A. Streptococcus pneumoniae

B. Klebsiella pneumoniae

C. Pseudomonas aeruginosa

D. Haemophilus influenza

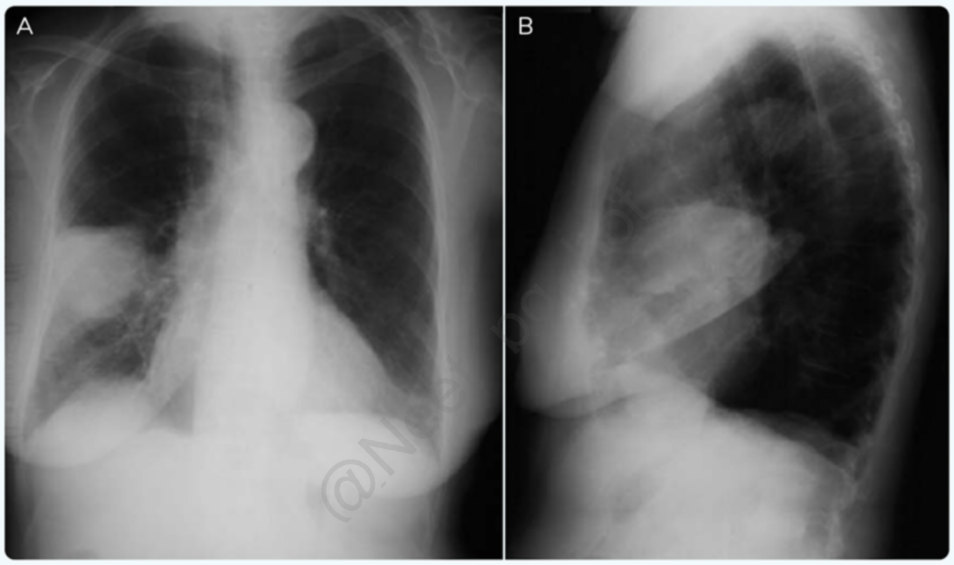

@Neet_pg_bot

Correct Answer: B. Klebsiella pneumoniae

Explanation: The patient's risk factor (chronic alcoholism) and clinical presentation suggests pneumonia caused by Klebsiella pneumoniae . Alcoholism predisposes to aspiration of oropharyngeal secretions containing Klebsiella, leading to necrotizing pneumonia. Specific aetiology of pneumonia: Alcoholic patient with Pneumonia: Pneumococcus pneumonia. Alcoholic with Red currant jelly sputum: Klebsiella pneumonia /Friedlander pneumonia. COPD & smokers end up with Hemophilus influenzae . (Option D) Structural lung disease Eg. Cystic fibrosis where mucus plugs thickened present - Pseudomonas aeruginosa (Option C) /Burkholderia cepacia Contact with Birds: Chlamydia psittaci Contact with Bats: Histoplasmosis Contact with Rabbits: Francisella tularensis (Tularemia) Contact with Goat/sheep: Coxiella burnetii can cause Q fever. Hotel/cruise: Legionella pneumophila Streptococcus pneumoniae (Option A) Most common cause of community-acquired pneumonia, but

typically presents with rust-colored sputum and less necrotizing disease.

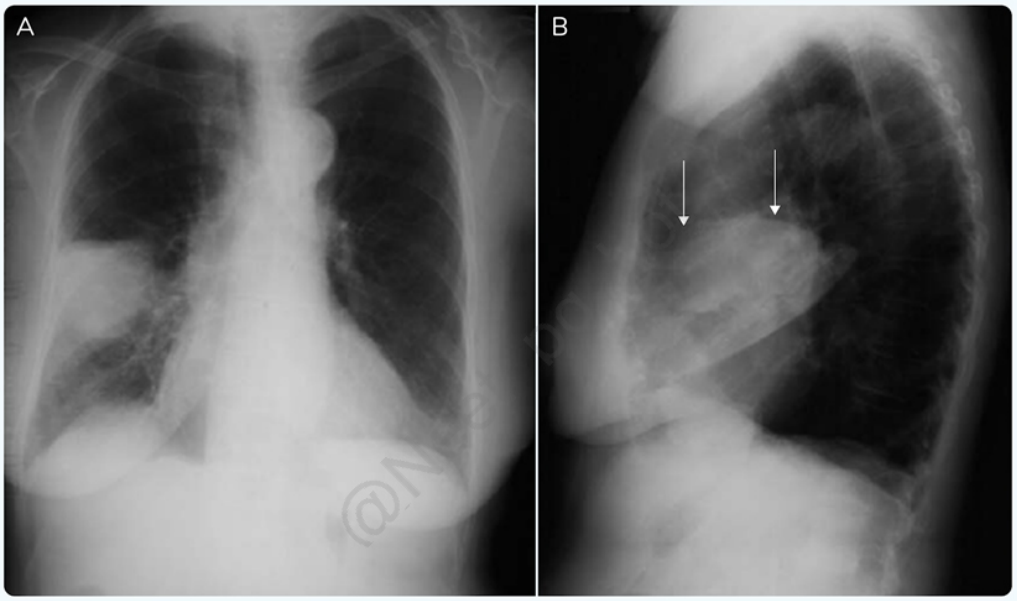

Bulging fissure sign. PA (A) and lateral (B) radiographs of the chest show dense consolidation of the right middle lobe secondary to Klebsiella pneumoniae.

@Neet_pg_bot

References:

The Epidemiology of Alcohol Abuse and Pneumonia - PMC

Klebsiella Pneumonia - StatPearls - NCBI Bookshelf

Haemophilus influenzae in chronic obstructive pulmonary disease

Microbial Epidemiology of the Cystic Fibrosis Airways: Past, Present, and Future

Psittacosis Pneumonia - StatPearls - NCBI Bookshelf.

Living With Bats

Tularemia - StatPearls - NCBI Bookshelf

Q fever pneumonia - PubMed

Legionnaires' Disease & Pontiac Fever | CDC Yellow Book 2024

↑ *Back to this question in Part A*

@Neet_pg_bot

Q42: Identify the condition in the following X-ray. (Q859538)

A. Hydropneumothorax

B. Pleural effusion

C. Pericardial effusion

D. Pneumothorax

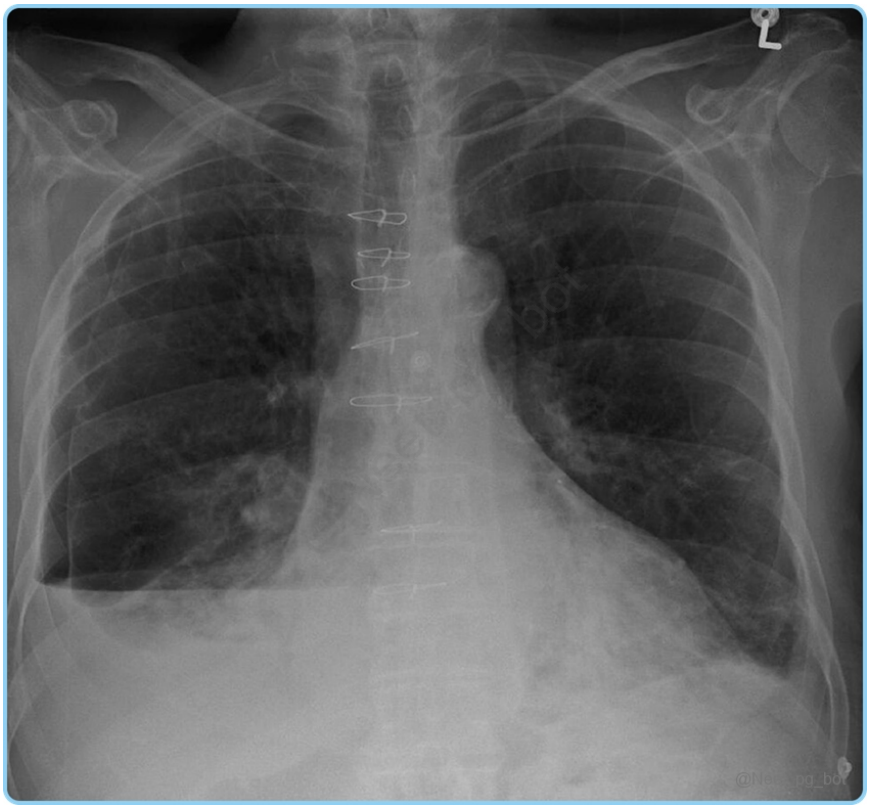

Correct Answer: A. Hydropneumothorax

Explanation: The chest x-ray shows air-fluid levels with clear demarcation signifying hydropneumothorax. Hydropneumothorax Hydropneumothorax is characterized by the presence of both air and fluid within the pleural space , usually due to trauma, rupture of a lung abscess, or after thoracic interventions. Hydropneumothorax shows an air-fluid level on upright imaging, with a clear demarcation between air and fluid in the pleural cavity . {{caption_text}} Pleural effusion (Option B) has the following features in the x-ray as given below: {{caption_text}} Pericardial effusion (Option C) shows a large cardiac silhouette in the chest X-ray. {{caption_text}} Pneumothorax (Option D) has a readily apparent visceral pleural line seen without distal lung markings. The following image shows a right sided pneumothorax. {{caption_text}}

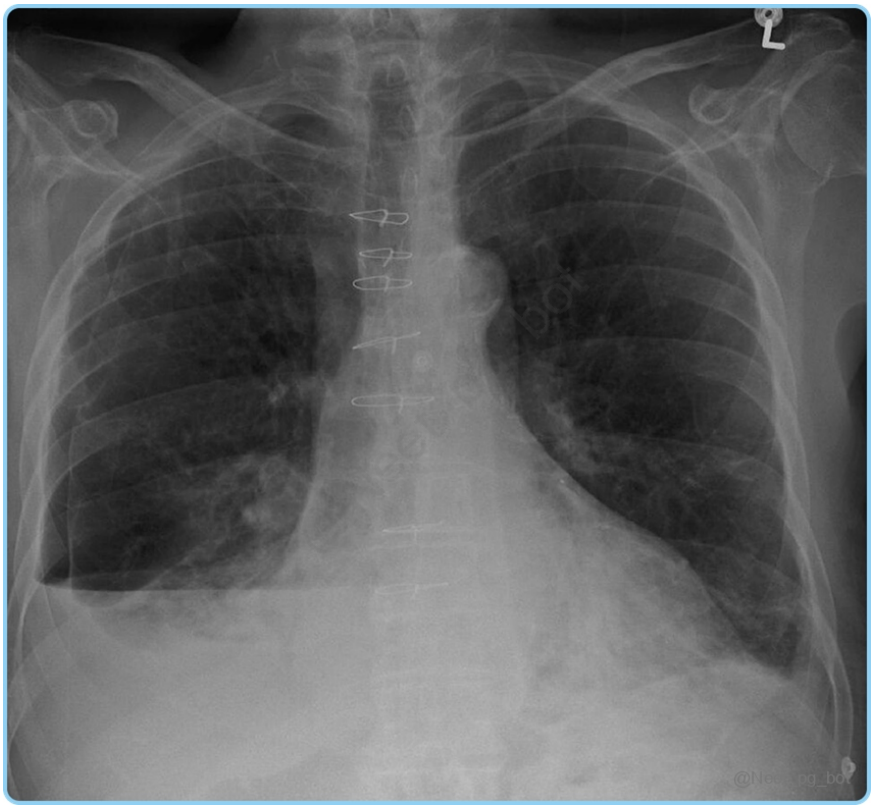

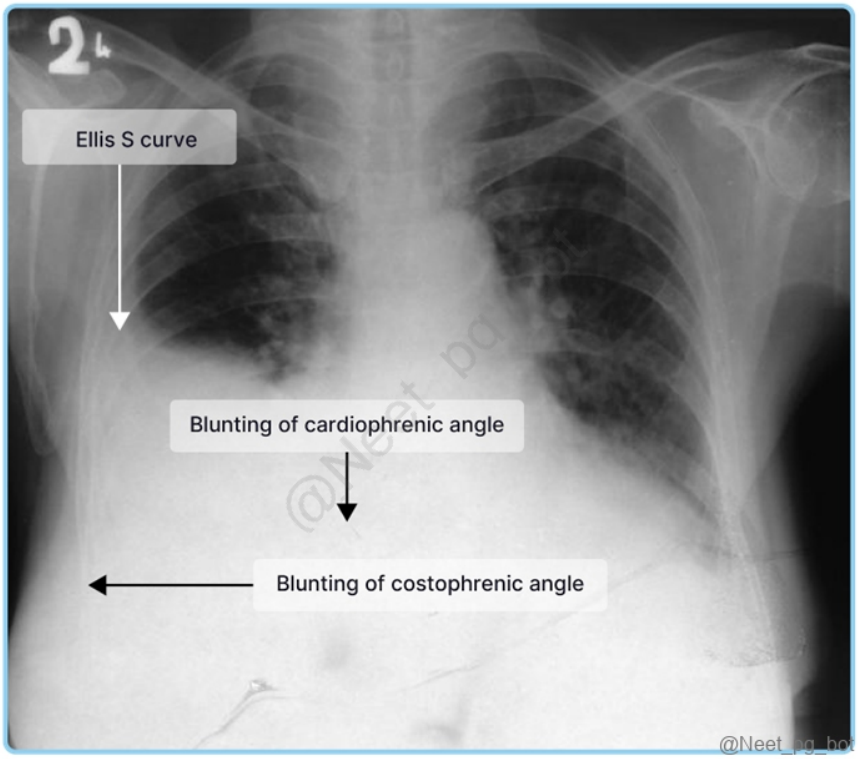
Ellis S curve
Blunting of cardiophrenic angle
Blunting of costophrenic angle

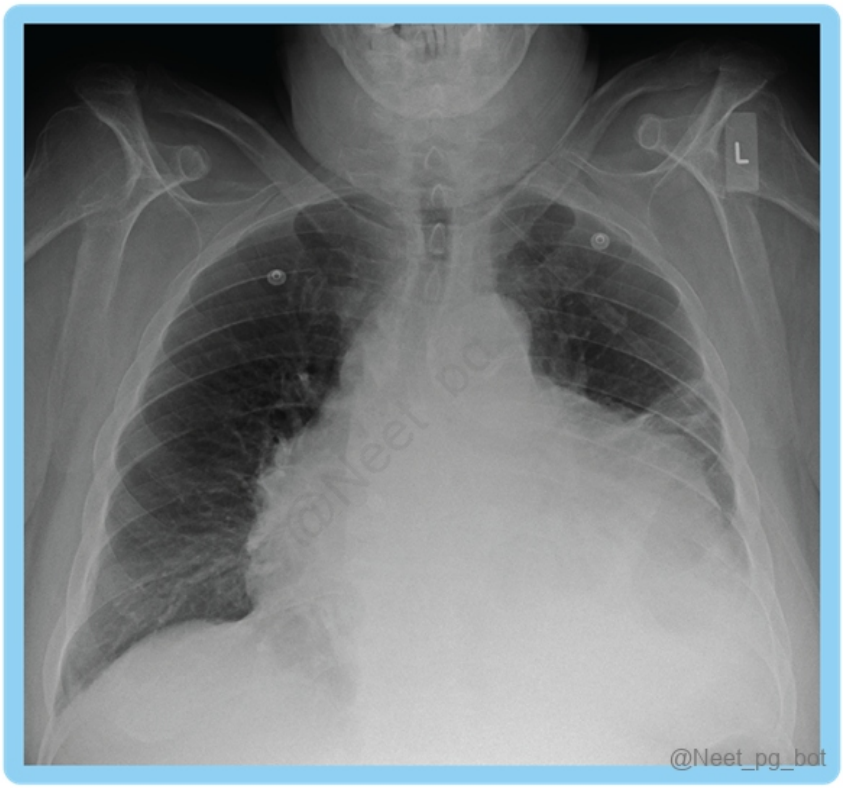

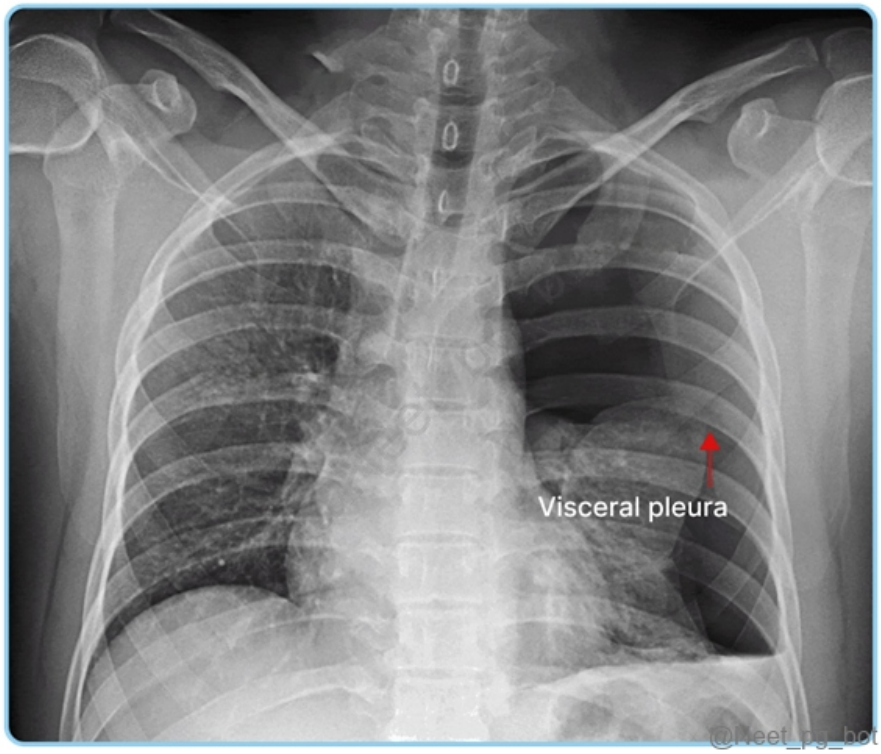

References:

Harrison’s Principles of Internal Medicine 21st edition Page 2198, 2199.

https://radiopaedia.org/articles/hydropneumothorax

://pmc.ncbi.nlm.nih.gov/articles/PMC4753987/#sec4

↑ *Back to this question in Part A*

@Neet_pg_bot

Q43: A 55-year-old patient presented with chronic projectile vomiting and weight loss. What is the expected metabolic abnormality to be seen here? (Q859530)

A. Hypokalemic hypochloremic metabolic alkalosis with hyponatremia

B. Hypokalemic hypochloremic metabolic alkalosis with hypernatremia

C. Hypokalemic hypochloremic metabolic alkalosis with hypercalcemia

D. Hypokalemic hypochloremic metabolic acidosis with hyponatremia

Correct Answer: A. Hypokalemic hypochloremic metabolic alkalosis with hyponatremia

Explanation: Chronic vomiting leads to hypokalemic hypochloremic metabolic alkalosis with hyponatremia . Development of metabolic Alkalosis due to vomiting Occurs due to a net gain of bicarbonate (HCO3–) or loss of nonvolatile acid (usually HCl) from the extracellular fluid, commonly caused by vomiting. Generation Stage: Vomiting leads to the loss of HCl from the stomach, preventing HCO3– secretion in the small intestine. As a result, HCO3– gets retained in the extracellular fluid, leading to the development of metabolic alkalosis . Maintenance Stage: After vomiting ceases, the kidneys fail to appropriately excrete the excess HCO3–, maintaining the alkalosis. This failure is influenced by factors such as volume deficiency, chloride deficiency , and potassium deficiency , combined with a reduced glomerular filtration rate (GFR). Saline-Responsive Metabolic Alkalosis: In cases of volume, chloride, and potassium deficiency, the alkalosis can be corrected by restoring extracellular fluid volume through intravenous administration of NaCl and KCl. Saline-Unresponsive Metabolic Alkalosis: In cases of hypokalemia due to hyperaldosteronism, the alkalosis may require pharmacologic or surgical treatment, rather than saline correction. Metabolic Alkalosis: Metabolic alkalosis is characterized by an increase in arterial pH , elevated serum bicarbonate [HCO3–], and increased PaCO2 ■ due to compensatory hypoventilation. Often presents with hypochloremia and hypokalemia . Occurs as a mixed disorder with respiratory or metabolic acidosis or alkalosis. Clinical Features Neurological: Mental confusion, obtundation, potential seizures Peripheral Nervous System: Paresthesias, muscle cramps, tetany (similar to hypocalcemia effects) Cardiovascular: Aggravation of arrhythmias, particularly in COPD patients Electrolyte Imbalances Potassium (K■): Hypokalemia , especially in cases involving secondary hyperaldosteronism or diuretic use. Chloride (Cl■): Hypochloremia , frequently accompanying alkalosis, especially in cases of vomiting or diuretic use. Calcium (Ca^{2}■): Symptoms may mimic hypocalcemia despite normal levels. Options B, C, and D are incorrect .

References:

Harrison’s Principles of Internal Medicine, 21st Edition, Page 365-367

Arterial Blood Gases - Physiopedia

↑ *Back to this question in Part A*

@Neet_pg_bot

Q44: A 55-year-old male presented with tachypnea and mental confusion. His blood sugar is 350mg/dl, pH-7.2, HCO3-10, pCO2-30. What is the metabolic abnormality? (Q858450)

A. Metabolic alkalosis

B. Metabolic acidosis

C. Respiratory alkalosis

D. Respiratory acidosis

Correct Answer: B. Metabolic acidosis

Explanation: The patient has primary metabolic acidosis with partial respiratory compensation. Stepwise Acid-Base Diagnosis: Step 1: The patient's pH is 7.2 (normal: 7.35-7.45), indicating acidosis. Step 2: The bicarbonate (HCO■■) level is 10 mmol/L, lower than the normal range (22-30 mmol/L), suggesting metabolic acidosis. Step 3: Use Winter's formula to calculate the expected pCO■ compensation for metabolic acidosis: Expected pCO■ = (1.5 × HCO■■) + 8 ± 2 For HCO■■ = 10, Expected pCO■ = (1.5 × 10) + 8 ± 2 = 21-25 mmHg. Step 5: The patient’s actual pCO■ is 30 mmHg. This is higher than the expected range (21-25 mmHg), indicating partially respiratory compensation.

References:

Harrison’s Principle of Internal Medicine, 21st Edition, Page 360

↑ *Back to this question in Part A*

@Neet_pg_bot

Q45: A 20-year-old man presents to the emergency department with respiratory distress and hypotension following a trauma. He has subcutaneous emphysema, and there is an absence of air entry into the right side of the lungs. What is the next best step? (Q858434)

A. Start IV fluids with a large bore cannula

B. Needle decompression into the 5 th intercostal space anterior to the midaxillary line

C. Take the patient to the ICU and intubate him

D. Start positive pressure ventilation

Correct Answer: B. Needle decompression into the 5 th intercostal space anterior to the midaxillary line

Explanation: The clinical scenario of a patient with respiratory distress, hypotension, subcutaneous emphysema, and absent air entry on the right side following a trauma, indicating tension pneumothorax. The next best step is needle decompression at the 5th intercostal space, anterior to the midaxillary line . TENSION PNEUMOTHORAX Pathophysiology D/t 'one-way valve' air leaks from the lung or chest wall. Air is sucked into the thoracic cavity without any escape, collapsing and compressing the affected lung. The mediastinum shifts to the opposite side, reducing venous return and compressing the opposite lung, leading to decreased cardiac output and function. This can result in sudden death. Causes Penetrating Chest Trauma. Blunt Chest Trauma with parenchymal lung injury and persistent air leak. Iatrogenic Lung Injury (e.g., central venepuncture) Mechanical Positive-Pressure Ventilation. Clinical Features Tachypnea and Tachycardia Hyper-resonance and Decreased/Absent Breath Sounds Resonant Percussion with severe mediastinal/tracheal shift Cyanosis and Hypotension Chest Pain Distended Neck Veins Subcutaneous emphysema Emergency Management Tension pneumothorax is a clinical diagnosis, and treatment should never be delayed by waiting for radiological confirmation. Immediate Thoracocentesis (needle): Wide bore needle (typically a 20- or 22-gauge) in the 5th intercostal space in the safety triangle. Decompression should be performed in the "safe triangle." Safe Triangle Boundaries : Posterior: Latissimus dorsi Anterior: Lateral border of the pectoralis major Inferior: A line drawn perpendicularly from the nipple to the back, just anterior to the mid-axillary line. In critical situations, a finger thoracostomy can be done in the same location. Nasal Oxygen for support. Intercostal Tube Placement (ICT) once stable and confirmed by chest X-ray. Additional Care Antibiotics and analgesics for treatment. Ventilator Support with IPPV in severe cases. Start IV fluids with a large bore cannula (Option A): While IV fluids are important in managing hypotension, they do not address the underlying problem of tension pneumothorax, which is the primary cause of the patient's instability. Take the patient to the ICU and intubate him (Option C): Intubation and ICU care may be necessary later, but delaying decompression can lead to rapid deterioration. Positive pressure ventilation without prior decompression could worsen the tension pneumothorax. Start positive pressure ventilation (Option D): This is contraindicated in tension pneumothorax because it can further increase intrathoracic pressure and exacerbate the condition, leading to cardiovascular collapse

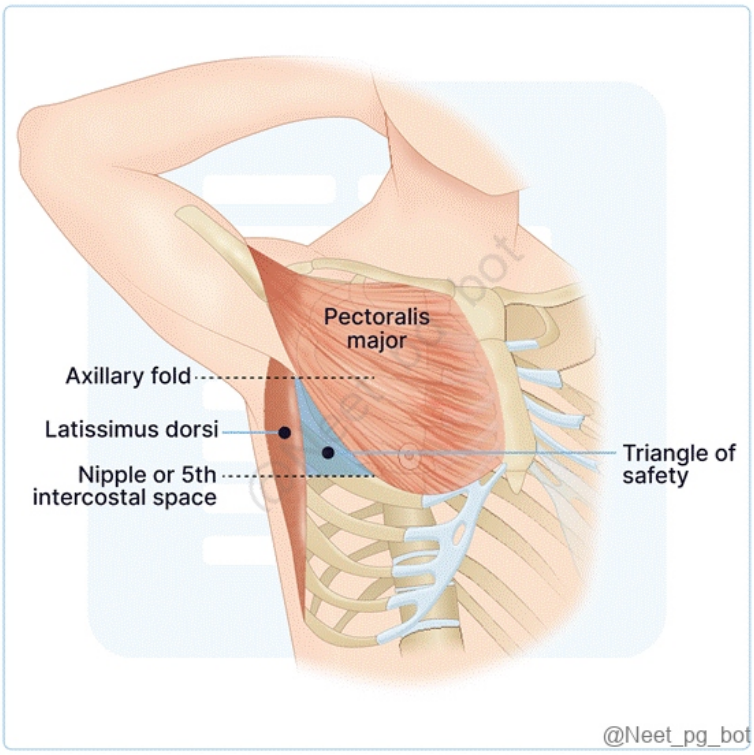

References:

Bailey & Love's Short Practice of Surgery, 28th Edition, Page 374

Sabiston Textbook of Surgery, 21st Edition, Page 404, 405,1632

Tension Pneumothorax - StatPearls - NCBI Bookshelf.

↑ *Back to this question in Part A*

@Neet_pg_bot

Q46: A 53-year-old woman underwent hip replacement surgery. A week after the surgery, the patient developed swelling of the legs associated with pain on palpation. Her heart rate is 70 beats per min. There is no history of hemoptysis or significant weight loss. There is no previous history of pulmonary embolism. What is the risk of developing pulmonary embolism in the patient based on Well's score? (Q855016)

A. Low

B. High

C. Moderate

D. Cannot comment without d-dimer values

Correct Answer: B. High

Explanation: The risk of developing pulmonary embolism in the patient, according to the Well’s score, is high. Based on the Well's Clinical Prediction Rule for Pulmonary Embolism (PE) in the given patient scenario: Clinical signs of deep-vein thrombosis (patient has swelling in the legs, pain on palpation) = 3 points Alternative diagnosis is less likely than PE = 3 points Heart rate >100 beats/min (heart rate is 70 beats per minute) = 0 points Immobilization >3 days or surgery in previous 4 weeks (patient had hip replacement surgery one week ago) = 1.5 points History of deep-vein thrombosis or pulmonary embolism = 0 points Hemoptysis (no hemoptysis) = 0 points Malignancy (with treatment within 6 months) or palliative = 0 points Total score = 7.5 , indicating high risk for pulmonary embolism. Well’s Clinical Prediction Rule for Pulmonary Embolism (PE): Clinical Feature Points Clinical signs of deep-vein thrombosis 3 Alternative diagnosis is less likely than PE 3 Heart rate >100 beats/min 1.5 Immobilization >3 days or surgery in previous 4 weeks 1.5 History of deep-vein thrombosis or pulmonary embolism 1.5 Hemoptysis 1 Malignancy (with treatment within 6 months) or palliative 1 Interpretation Score Range Risk High >6.0 High Intermediate 2.0 - 6.0 Intermediate Low <2.0 Low

References:

Harrison’s Principles of Internal Medicine, 21st Edition, Page 27

↑ *Back to this question in Part A*

@Neet_pg_bot

Q47: Patient presents with recurrent lung infections and CXR is given below. What is the most likely diagnosis? (Q844230)

A. Kartagener syndrome

B. Cystic fibrosis

C. Digeorge syndrome

D. Down syndrome

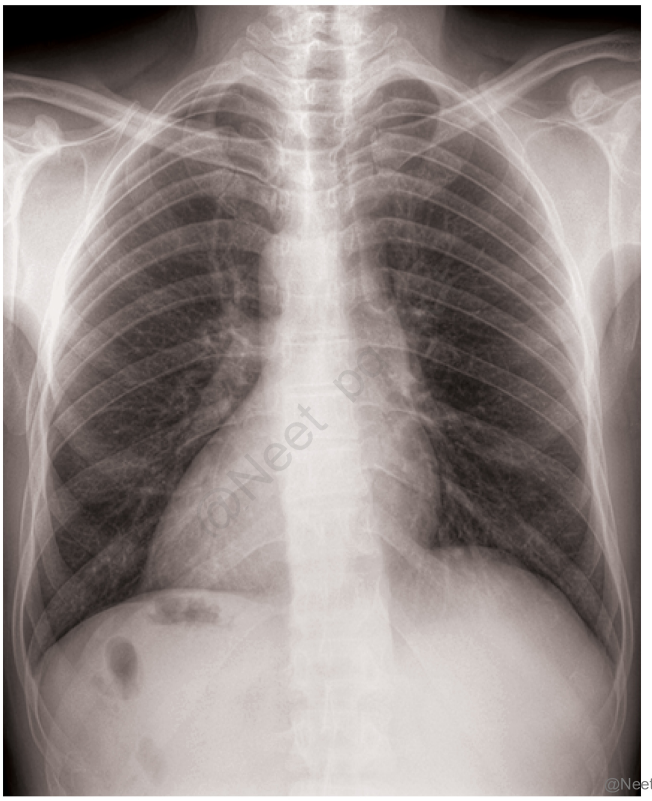

Correct Answer: A. Kartagener syndrome

Explanation: Correct Option A - Kartagener syndrome: Kartagener syndrome is characterized by a triad of symptoms: situs inversus (dextrocardia seen on CXR), chronic sinusitis, and bronchiectasis. The recurrent lung infections in this case are consistent with the chronic respiratory issues seen in Kartagener syndrome. The dextrocardia noted in the CXR supports this diagnosis. Incorrect Options: Option B - Cystic fibrosis: Cystic fibrosis primarily presents with thick, sticky mucus leading to lung infections, pancreatic insufficiency, and other issues. While it causes recurrent lung infections, it is not associated with dextrocardia. The diagnosis is typically supported by sweat chloride tests and genetic testing. Option C - DiGeorge syndrome: DiGeorge syndrome includes a range of congenital defects, including heart defects, thymic hypoplasia, and hypoparathyroidism. It does not typically present with dextrocardia or recurrent lung infections as a primary feature. Option D - Down syndrome: Down syndrome is associated with a variety of congenital heart defects and may include respiratory issues. However, it is not specifically associated with dextrocardia or a particular pattern of recurrent lung infections that would align with Kartagener syndrome.

References:

.

↑ *Back to this question in Part A*

@Neet_pg_bot

Q48: A 33-year-old woman is being evaluated for daytime sleepiness and memory loss which have been present for the past 1 year. Her BMI is 43, her BP is 170/98 mmHg. In an awake state, ABG shows pO2 70 mmHg, pCO2 53 mmHg, HCO3 33 mmol/L. What is the most likely diagnosis? (Q820347)

A. Obesity Hypoventilation Syndrome

B. Central Sleep Apnea

C. Narcolepsy

D. Obstructive sleep Apnea

Correct Answer: A. Obesity Hypoventilation Syndrome

Explanation: Correct Option A - Obesity Hypoventilation Syndrome (OHS): This disorder occurs in severely obese individuals who experience hypoventilation (inadequate breathing) during sleep and wakefulness. The elevated BMI, daytime sleepiness, and memory loss are consistent with OHS. The elevated pCO2 (53 mmHg) and elevated HCO3 (33 mmol/L) on the ABG indicate chronic respiratory acidosis and compensation, which is a characteristic feature of OHS. The high blood pressure (BP) also supports this diagnosis as OHS is associated with increased cardiovascular risks. In summary given the patient's severe obesity, daytime sleepiness, memory loss, high BMI, elevated BP, and the ABG results showing chronic respiratory acidosis, the most likely diagnosis is Obesity Hypoventilation Syndrome Incorrect Options: Option B - Central Sleep Apnea (CSA): CSA involves a dysfunction in the central nervous system's control of breathing during sleep, leading to temporary cessation of breathing. While CSA can cause daytime sleepiness, the ABG values (elevated pCO2 and HCO3) suggest a respiratory-related issue rather than a primary central nervous system problem. Option C - Narcolepsy: Narcolepsy is a neurological disorder characterized by excessive daytime sleepiness, often accompanied by sudden muscle weakness (cataplexy), sleep paralysis, and vivid dream-like hallucinations. It doesn't typically involve significant respiratory disturbances as seen in this case. Option D - Obstructive Sleep Apnea (OSA): OSA is a condition where the airway becomes partially or completely blocked during sleep, leading to repeated pauses in breathing. While OSA can cause daytime sleepiness and memory issues, the ABG findings of elevated pCO2 and HCO3 are more indicative of a chronic respiratory problem like OHS.

References:

.

↑ *Back to this question in Part A*

@Neet_pg_bot

Q49: A 40-year-old man presents with daytime sleepiness and impaired concentration and memory. On examination his BMI is 41 kg/m2, BP is 160/100 mm Hg. His awake ABG analysis is given: PaO 2 = 66mm Hg PaCO 2 = 50 mm Hg HCO 3 = 28 mEq/L

What is the most likely diagnosis? (Q857285)

A. Obstructive sleep apnea

B. Narcolepsy

C. Obesity hypo-ventilation syndrome

D. Central sleep apnea

Correct Answer: C. Obesity hypo-ventilation syndrome

Explanation: ody mass index (BMI) ≥30 kg/m². Chronic daytime alveolar hypoventilation, defined as Paco2 ≥45 mmHg in the absence of other causes. Evidence of sleep-disordered breathing, usually in the form of obstructive sleep apnea (OSA). Risk Factors: Severe obesity (BMI >40 kg/m²) and severe obstructive sleep apnea (AHI >30 events/hour) are considered risk factors for OHS. Pathophysiology: Hypoventilation is caused by factors like OSA, increased work of breathing, respiratory muscle impairment due to excess adiposity, and poor ventilatory response to hypoxemia and hypercapnia. These issues can improve with the treatment of sleep-disordered breathing (CPAP or NIPPV), suggesting that impaired ventilatory drive is a consequence, not the cause, of OHS. Treatment: Weight reduction : Significant weight loss (20–25% of body weight) can normalize Paco2, but weight loss alone is challenging without bariatric surgery. Positive airway pressure: CPAP or NIPPV (Non-invasive positive pressure ventilation) during sleep is the primary treatment. CPAP is effective in improving daytime hypercapnia and hypoxemia, especially in patients with severe OSA. Bilevel positive airway pressure (BiPAP) should be used for those who cannot tolerate CPAP or if obstructive events persist. Bilevel PAP with a backup rate (BiPAP ST or volume-assured pressure support) is suggested for persistent hypercapnia or acute decompensated OHS. Management of Comorbidities: Other conditions that impair ventilation, such as COPD, should be treated concurrently with OHS. Obstructive sleep apnea (OSA) (Option A) is a disorder that is characterized by obstructive apneas and hypopneas due to repetitive collapse of the upper airway during sleep. The clinical features against OSA include hypercapnia and hypoxemia in an awake individual . Narcolepsy (Option B) is characterized by excessive daytime sleepiness, sudden loss of muscle tone (cataplexy), and disrupted sleep patterns. While impaired concentration and memory can be seen in narcolepsy, the ABG is normal. Central sleep apnea (Option D) is a condition in which there is a lack of respiratory effort during sleep, leading to pauses in breathing. Impaired concentration and memory can occur in central sleep apnea.

References:

Harrison’s Principles of Internal Medicine, 21st Edition, Page: 2203, 2204.

↑ *Back to this question in Part A*

@Neet_pg_bot

Q50: Match the following medical conditions with their corresponding descriptions: A Caplan syndrome 1 Initially observed in coal workers B Asbestosis 2 Presents with a characteristic "crazy pavement" appearance C Mesothelioma 3 Affects the pleura D

Sarcoidosis 4 Exhibits the presence of pleural effusion (Q857279)

A. A-1, B-4, C-3, D-2

B. A-4, B-2, C-3, D-1

C. A-3, B-4, C-2, D-1

D. A-2, B-4, C-3, D-1

Correct Answer: A. A-1, B-4, C-3, D-2

Explanation: Caplan syndrome 1 Initially observed in coal workers B Asbestosis 4 Exhibits the presence of pleural effusion C Mesothelioma 3 Affects the pleura D Sarcoidosis 2 Presents with a characteristic "crazy pavement" appearance Caplan syndrome: It is characterised by the formation of multiple well-defined pulmonary nodules, typically located in the lung periphery, in individuals with rheumatoid arthritis who have been exposed to inorganic dust. This syndrome is specifically associated with coal worker's pneumoconiosis but can also occur in other forms of pneumoconiosis. Asbestosis is a lung disease caused by the inhalation of asbestos fibres. Pleural effusion can be seen in the advanced stages of the disease. Mesothelioma is a rare and aggressive malignant tumour originating from the mesothelial cells lining the pleura (the thin membrane surrounding the lungs). Sarcoidosis is a systemic inflammatory disease that can affect multiple organs, but it most commonly involves the lungs and lymph nodes. The term "crazy pavement" is not specifically associated with sarcoidosis. It is a radiographic appearance seen in certain lung conditions, particularly pulmonary alveolar proteinosis, where the lung tissue exhibits a mosaic pattern resembling crazy paving.

References:

Harrison’s Principles of Internal Medicine, 21st Edition, Page: 2753.

Davidson’s Principles and Practice of Medicine, 24th Edition, Page 611, 615, 1023, 1025.

↑ *Back to this question in Part A*

@Neet_pg_bot

Q51: Which membrane channel is mainly affected in Cystic fibrosis? (Q857260)

A. Sodium

B. Chloride

C. Calcium

D. Potassium

Correct Answer: B. Chloride

Explanation: ommon pathogens: P. aeruginosa, S. aureus Chronic bacterial colonization Progressive bronchiectasis Clinical Impact Recurrent pneumonia Progressive lung damage Requires aggressive antibiotic therapy

References:

Harrison's Principles of Internal Medicine, 21st Edition, Volume I, Page. 2176, 2177.

↑ *Back to this question in Part A*

@Neet_pg_bot

Q52: A 45-year-old woman with obstructive lung disease is currently using salmeterol and tiotropium but continues to experience breathlessness and frequent exacerbations. Given her current situation, which of the following treatments would be most appropriate? (Q860154)

A. Nebulization with LAMA-LABA

B. Long-Term Oxygen Therapy (LTOT)

C. Positive Pressure Ventilation (PPV)

D. Pneumococcal Vaccine

Correct Answer: B. Long-Term Oxygen Therapy (LTOT)

Explanation: The clinical manifestations indicate persistent symptoms of obstructive lung disease despite optimal bronchodilator therapy with salmeterol (LABA) and tiotropium (LAMA). Long-Term Oxygen Therapy (LTOT) is the most appropriate next step in management as it addresses potential hypoxemia , which is often present in patients with chronic obstructive lung disease experiencing persistent symptoms. This therapy can improve survival and quality of life in patients who are already on bronchodilator therapy, by increasing oxygen levels in the blood and reducing the strain on the cardiopulmonary system. Interventions for Improved Survival in COPD: Smoking Cessation: Most crucial intervention for improving survival. Slows decline in lung function (FEV1), altering disease progression. Long-Term Oxygen Therapy (LTOT): Improves survival in severe hypoxaemia ($PaO_2 < 7.3$ kPa). Recommended use: at least 15 hours/day, with greater benefit at >20 hours/day. Pulmonary Rehabilitation: Improves symptoms, exercise tolerance, and health status. May contribute to better survival, though direct link needs more research. Management of Exacerbations: Crucial for reducing mortality. Key components: Controlled oxygen therapy (24%-28%) to maintain $PaO_2 > 8$ kPa. Nebulised bronchodilators: salbutamol + ipratropium. Oral glucocorticoids: prednisolone 30 mg for 10 days. Antibiotics for increased sputum purulence/volume, breathlessness. Non-invasive ventilation (NIV) for mild-moderate acidosis ($pH < 7.35$). Vaccination: Annual influenza and pneumococcal vaccinations to prevent infections and exacerbations. Multidisciplinary Management: Address comorbidities (e.g., obesity, malnutrition, depression, social isolation). These factors impact overall health and survival. Nebulization with LAMA-LABA (Option A) provides the same medications the patient is already taking in a different delivery form. Switching to nebulized form of the same medications is unlikely to provide significant additional benefit when the patient is already on optimal inhaler

therapy. Positive Pressure Ventilation (Option C) is typically reserved for acute respiratory failure or severe COPD exacerbations requiring intensive care management. It is not an appropriate choice for chronic outpatient management of stable COPD with persistent symptoms. Pneumococcal Vaccine (Option D) is an important preventive measure for COPD patients to prevent infectious exacerbations. However, it would not address the immediate concern of persistent breathlessness and frequent exacerbations in a patient already on optimal bronchodilator therapy.

References:

Davidson's Principles and Practice of Medicine, 24th Edition, Page 576, 577, 578

↑ *Back to this question in Part A*

@Neet_pg_bot

Q53: A 60-year-old man with chronic cough and weight loss presents with increasing breathlessness. Chest X-ray shown below. Which of the following is the most likely cause ? (Q860464)

A. Right-sided pneumothorax

B. Right lung consolidation

C. Right lung collapse

D. Massive pleural effusion due to pulmonary malignancy

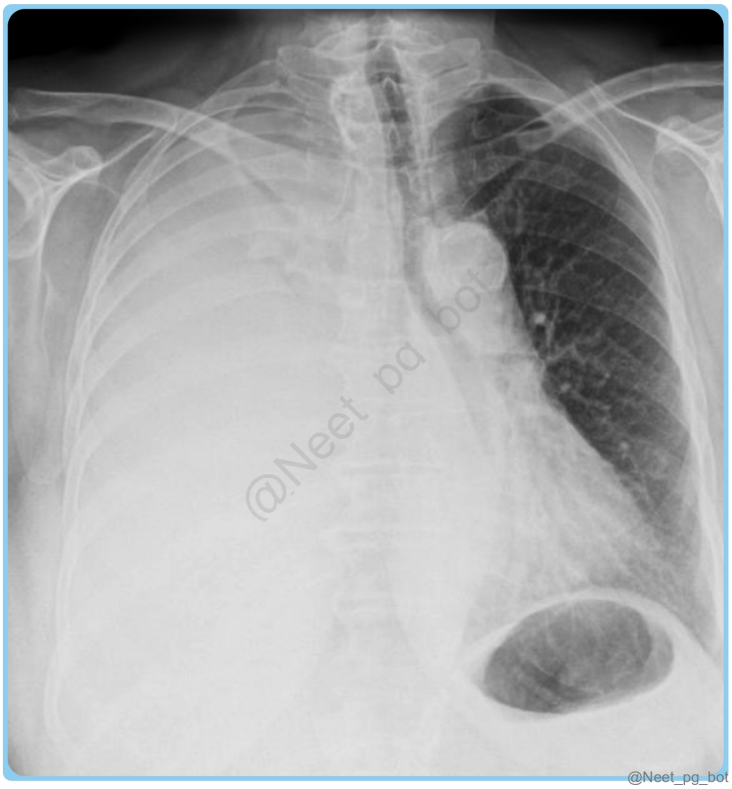

Correct Answer: D. Massive pleural effusion due to pulmonary malignancy

Explanation: The chest X-ray shows a massive right-sided pleural effusion , evident by complete white-out of the right lung field and tracheal deviation to the left due to pressure from the accumulating fluid. Such a large effusion is commonly caused by pulmonary malignancy , which produces exudative pleural fluid and leads to significant mediastinal shift. Right-sided pneumothorax (Option A) Appears hyperlucent (dark) with no lung markings, not white-out. Also causes increased radiolucency, not opacity. Right lung consolidation (Option B) Causes a dense white area but does not shift the trachea , because lung volume remains normal. Right lung collapse (Option C) Produces opacity, but due to volume loss , the trachea is pulled toward the affected side—not pushed away.

References:

Harrison’s Principles of Internal Medicine 21st edition Page 2198, 2199.

https://pmc.ncbi.nlm.nih.gov/articles/PMC4170449/

↑ *Back to this question in Part A*

@Neet_pg_bot

Q54: Which of the following conditions will have an FEV■/FVC ratio < 0.7 and FEV■ < 80% of the predicted value along with wheezing in the morning hours and shortness of breath? (Q860397)

A. Asthma

B. Interstitial Lung Disease

C. Idiopathic Pulmonary Fibrosis

D. Silicosis

Correct Answer: A. Asthma

Explanation: Asthma is characterized by specific spirometric findings including an FEV■/FVC ratio < 0.7 and FEV■ < 80% of predicted value, indicating airflow obstruction. These values, combined with morning wheezing and dyspnea, are diagnostic of mild bronchial asthma. Diagnostic Tests for Bronchial Asthma: Spirometry/PFTs Best initial test Investigation of choice Obstructive pattern Reversible with short-acting β2-agonists (SABAs) Findings: FEV1/FVC < 70% ↓ FEV1 Normal or ↓ FVC (Forced vital capacity) ↑ Residual Volume (RV) ↑ Total Lung Capacity (TLC) Normal or ↑ Diffusing Capacity of Lung for Carbon Monoxide (DLCO) Reversibility: Increase in FEV1 ≥ 12% and >200 mL with SABA (albuterol) PFTs between exacerbations: Often normal Methacholine Challenge Tests for bronchial hyperresponsiveness Positive if ≥20% decrease in FEV1 Sensitive but not specific Arterial blood gas Early Respiratory alkalosis (↓ PaCO2, ↑ pH) due to hyperventilation Late Respiratory acidosis due to muscle fatigue (normalizing PaCO2, normalizing pH, ↓ PaO2) Chest X-ray Normal appearance to hyperinflation with flattening of the diaphragm Classification of Asthma Severity: Spirometry Assessment : Post-bronchodilator FEV1 : Air exhaled in one second after bronchodilator use. FEV1/FVC Ratio : Indicates obstruction if <0.7. Severity Categories: Mild : FEV1 ≥ 80% of predicted Moderate : FEV1 50-79% of predicted Severe : FEV1 30-49% of predicted Very Severe : FEV1 < 30% of predicted ILD (Option B) : Interstitial lung disease typically shows a restrictive pattern with reduced FEV■ but a normal or increased FEV■/FVC ratio, not the reduced ratio seen in this case (Option B ruled out). ILD characteristically presents with a reduced total lung capacity and diffusion capacity. IPF (Option C) : In idiopathic pulmonary fibrosis, the FEV■/FVC ratio is typically normal or increased as both values are reduced proportionally due to the restrictive pattern. The condition does not present with the obstructive pattern described in the question. Silicosis (Option D) : While silicosis can cause progressive decrease in FEV■, it primarily presents as a restrictive lung disease with reduced lung volumes but preserved FEV■/FVC ratio. Also, morning wheezing is not a typical feature of silicosis.

References:

Davidson’s Principles and Practice of Medicine, 24th Edition, Page 570- 576.

↑ *Back to this question in Part A*

@Neet_pg_bot

Q55: Criterion that differentiates exudative from transudative pleural effusion? (Q860390)

A. Low protein in pleural fluid

B. High protein in pleural fluid

C. Low sugar in pleural fluid

D. High sugar in pleural fluid

Correct Answer: B. High protein in pleural fluid

Explanation: The key factor that differentiates exudative from transudative pleural effusions is the protein content of the pleural fluid. Exudative effusion → High protein Transudative effusion → Low protein Pleural fluid Analysis Light's Criteria Differentiates transudative from exudative pleural effusions based on LDH and protein levels in pleural fluid. An exudative pleural effusion meets at least one of the following: Pleural fluid protein/serum protein > 0.5 Pleural fluid LDH/serum LDH > 0.6 Pleural fluid LDH exceeds two-thirds of the normal upper limit for serum. ~25% of transudates may be misidentified as exudates. If exudative criteria are met but a transudative condition is suspected, measure protein difference; if >31 g/L (3.1 g/dL), likely transudative. Low protein in pleural fluid (Option A) : Low protein content is actually characteristic of transudative pleural effusions, not exudative effusions. Transudates occur due to systemic conditions like heart failure or cirrhosis where there is an imbalance in hydrostatic pressures. Low sugar in pleural fluid (Option C) : While pleural fluid glucose levels may be measured in certain conditions, sugar content is not a criterion used to differentiate between exudative and transudative effusions. Glucose levels may be low in specific conditions like empyema or rheumatoid effusions, but this is not a distinguishing feature between transudates and exudates. High sugar in pleural fluid (Option D) : Sugar levels in pleural fluid are not part of Light's Criteria and are not used to distinguish between exudative and transudative effusions. Pleural fluid glucose measurement may be helpful in specific clinical scenarios but is not a determining factor in the basic classification of effusions.

References:

Harrison’s Principles of Internal Medicine 21st edition Page 2198, 2199.

://pmc.ncbi.nlm.nih.gov/articles/PMC4753987/#sec4

↑ *Back to this question in Part A*

@Neet_pg_bot

Q56: Most common cause of death in idiopathic pulmonary fibrosis? (Q844287)

A. Respiratory failure

B. Pulmonary edema

C. Cancer

D. PAH

Correct Answer: A. Respiratory failure

Explanation: Correct Option A - Respiratory failure: Idiopathic Pulmonary Fibrosis (IPF) is a chronic, progressive lung disease characterized by the gradual scarring of lung tissue, which leads to the deterioration of lung function.

The most common cause of death in patients with IPF is respiratory failure. As the disease progresses, the lung tissue becomes increasingly fibrotic, reducing its ability to transfer oxygen into the bloodstream and remove carbon dioxide from it, leading to severe respiratory insufficiency. Incorrect Options: Option B - Pulmonary edema: Pulmonary edema refers to fluid accumulation in the alveoli and interstitial spaces of the lungs, often due to heart failure or other conditions. While it can occur in various pulmonary conditions, it is not the most common cause of death in IPF. Option C - Cancer: While patients with IPF may have an increased risk of developing lung cancer, cancer is not the most common cause of death in IPF. The primary cause of mortality remains respiratory failure due to progressive lung fibrosis. Option D - PAH (Pulmonary Arterial Hypertension): Pulmonary Arterial Hypertension (PAH) can occur as a complication of IPF, but it is not the most common cause of death. PAH can contribute to respiratory failure but is not the primary cause of mortality in IPF.

↑ *Back to this question in Part A*

@Neet_pg_bot

Q57: A patient presents with acute epigastric pain and an increase in serum lipase levels. Three days after stabilization, a chest X-ray is obtained. What is the most common pathology behind the chest X-ray findings? (Q844274)

A. Increased PCWP

B. Pulmonary thromboembolism

C. Non cardiogenic pulmonary edema

D. Aspiration pneumonitis

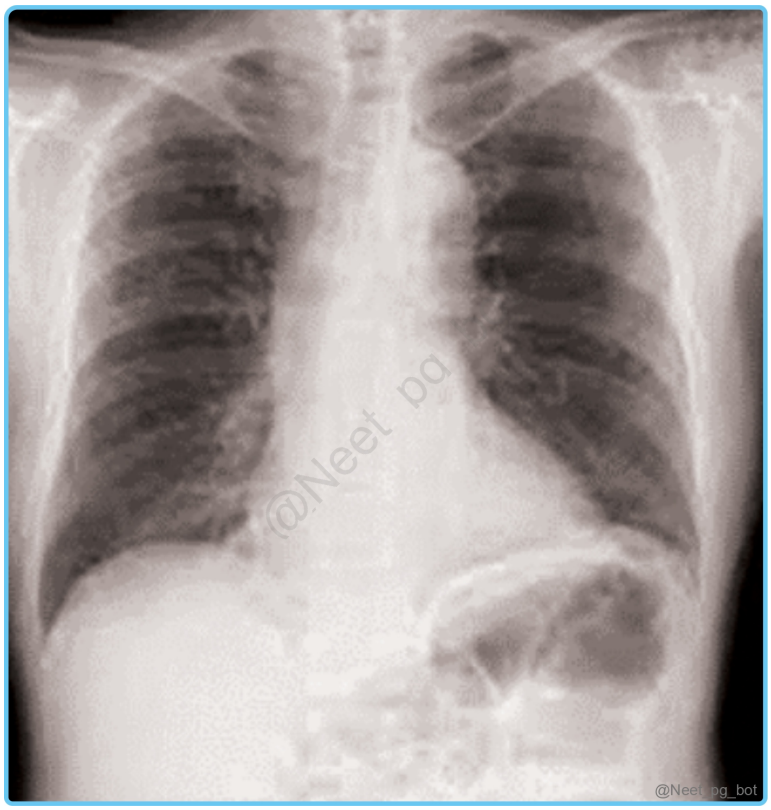

Correct Answer: C. Non cardiogenic pulmonary edema

Explanation: Correct Option C - Non-cardiogenic pulmonary edema: In the context of acute pancreatitis, which is indicated by the elevated serum lipase levels and acute epigastric pain, the most common chest X-ray finding could be related to non-cardiogenic pulmonary edema. This is often a complication of acute pancreatitis due to the release of inflammatory mediators that can lead to increased capillary permeability in the lungs, causing pulmonary edema. The colonic cut-off sign mentioned is a radiographic finding associated with acute pancreatitis, where there is a gas-filled segment of the colon that abruptly ends at the level of the pancreatic inflammation, usually at the splenic flexure. While this sign itself is more directly related to the abdominal pathology, the systemic inflammatory response in severe pancreatitis can lead to complications such as non-cardiogenic pulmonary edema, reflected in the chest X-ray. Incorrect Options: Option A - Increased PCWP (Pulmonary Capillary Wedge Pressure): This finding is typically associated with cardiogenic pulmonary edema, often due to heart failure. In pancreatitis, the pulmonary edema is usually non-cardiogenic, with normal or low PCWP. Option B - Pulmonary thromboembolism: While pulmonary embolism can present with acute chest pain and respiratory symptoms, it is not typically associated with acute pancreatitis. There would also be other clinical signs, like sudden onset of dyspnea, that are not mentioned in this case. Option D - Aspiration pneumonitis: This condition occurs due to the inhalation of gastric contents, leading to lung inflammation. It usually presents with respiratory symptoms like coughing and wheezing shortly after the event. There’s no indication in the case of an aspiration event, and it is less likely related to pancreatitis.

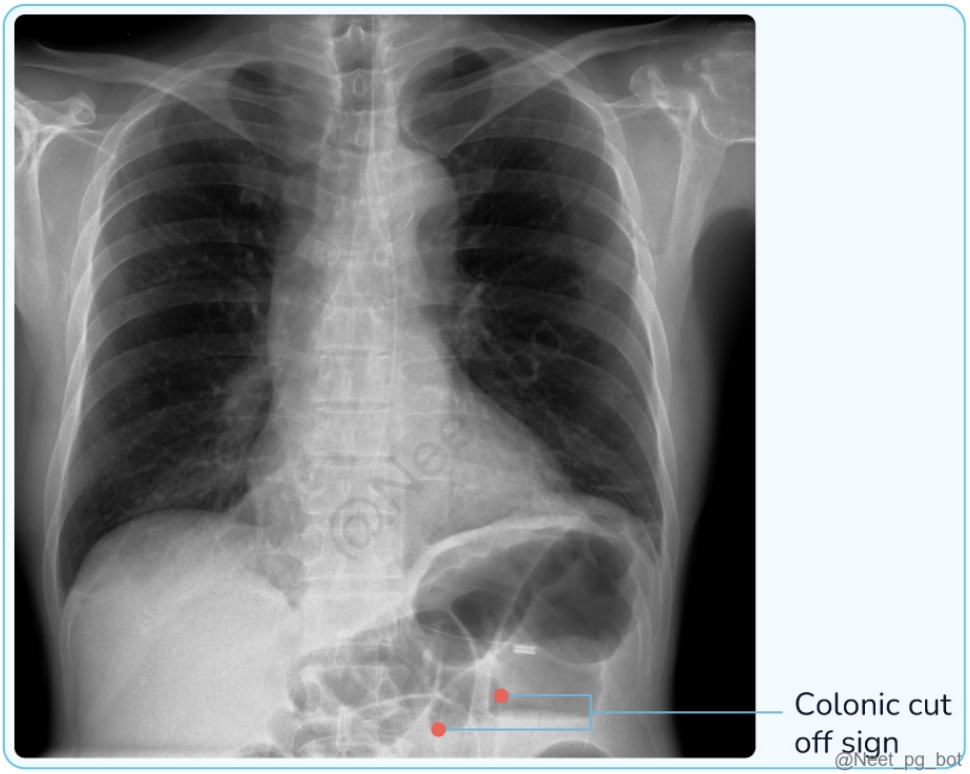

References:

.

↑ *Back to this question in Part A*

@Neet_pg_bot

Q58: What is the expected finding in a patient with the following CXR? (Q844270)

A. Kussmaul breathing

B. Paradoxical breathing

C. Apneustic breathing

D. Bronchial breathing

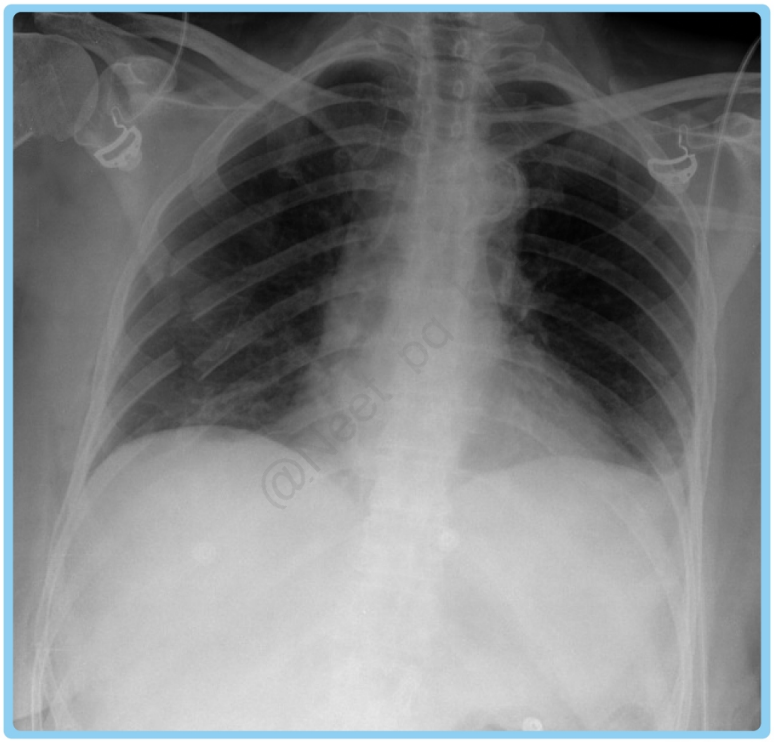

Correct Answer: B. Paradoxical breathing

Explanation: The X-ray shows multiple adjacent rib fractures in at least two places, producing a flail chest segment . A flail segment moves inward during inspiration and outward during expiration , opposite to the normal chest wall movement. This abnormal movement pattern is called paradoxical breathing , which is the expected clinical finding. Kussmaul breathing (Option A): Occurs in metabolic acidosis (e.g., DKA); not related to chest trauma or flail chest. Apneustic breathing (Option C): Due to pontine lesions , causing prolonged inspiratory pauses; unrelated to rib fractures. Bronchial breathing (Option D): Heard over lung consolidation such as pneumonia; this X-ray shows rib fractures, not consolidation.

References:

.

↑ *Back to this question in Part A*

@Neet_pg_bot

Q59: A 60-year-old bedridden patient develops sudden onset breathlessness and chest pain . CTPA was done. Which of the following non-invasive investigations will be useful to confirm the etiology of this presentation? (Q820451)

A. D dimer

B. MRI

C. Coagulogram

D. Doppler

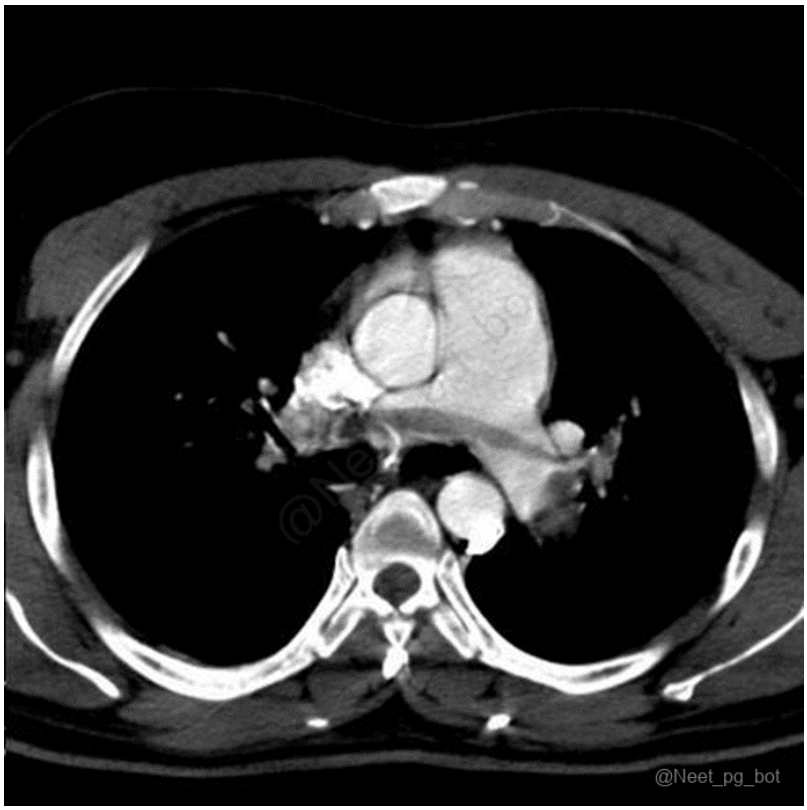

Correct Answer: D. Doppler

Explanation: Correct Option D - Doppler: The sudden onset of breathlessness and chest pain in a bedridden patient, along with the performance of a CTPA, raises suspicion for a pulmonary embolism. Doppler scan will identify deep vein thrombosis and is the best non-invasive investigation test to confirm the etiology of Pulmonary embolism Incorrect Options: Option A - D dimer is a marker of fibrin degradation and is elevated in conditions associated with clot formation and breakdown, such as deep vein thrombosis (DVT) and pulmonary embolism (PE). In this case, the patient's sudden onset of breathlessness and chest pain raises suspicion for a possible pulmonary embolism. A CTPA (computed tomography pulmonary angiography) was performed, a standard imaging technique to diagnose PE. If the CTPA shows evidence of a clot in the pulmonary arteries, a high D dimer level could support the diagnosis, as it indicates ongoing clot formation and breakdown. However it is not the best non invasive investigation . Option B - MRI: Magnetic Resonance Imaging (MRI) is a valuable imaging tool for various medical conditions, but it might not be the most suitable choice in this scenario. CTPA is the preferred imaging modality for assessing pulmonary embolism due to its ability to provide detailed images of the pulmonary vasculature. While MRI could be useful in certain cases, such as evaluating cardiac function or soft tissue structures, it's not the primary investigation for confirming PE. Option C - Coagulogram: A coagulogram is a comprehensive test that evaluates various aspects of blood clotting and can help diagnose bleeding disorders or abnormalities in the clotting cascade. While it might provide some insight into the patient's coagulation status, it wouldn't be the most direct investigation to confirm the cause of sudden onset breathlessness and chest pain, which

is suggestive of a possible pulmonary embolism.

References:

.

↑ *Back to this question in Part A*

@Neet_pg_bot

Q60: A patient presents with wheezing that improves with as-needed use of albuterol. Spirometry shows FEV1 ranging from 70% to 83%, and the patient experiences nighttime chest tightening twice a week. What is the most appropriate treatment? (Q844179)

A. Continue with albuterol

B. Replace with salmeterol twice daily

C. Start Tab prednisolone

D. Add an inhaled corticosteroid

Correct Answer: D. Add an inhaled corticosteroid

Explanation: The patient has moderate persistent asthma : symptoms with nighttime awakenings twice per week and FEV■ between 70–80% . Asthma that requires frequent albuterol use and has nighttime symptoms is not controlled with SABA alone. The next-step therapy per GINA guidelines is to add a daily low-dose inhaled corticosteroid (ICS) . Continue with albuterol (Option A): Inadequate — the patient has persistent symptoms and nighttime awakenings. Replace with salmeterol twice daily (Option B): LABA cannot be used alone; must be combined with an ICS due to increased mortality risk. Start Tab prednisolone (Option C): Oral steroids are for acute exacerbations , not for long-term control of moderate persistent asthma.

References:

.

↑ *Back to this question in Part A*

@Neet_pg_bot

Q61: A 62-year-old woman with a history of chronic obstructive pulmonary disease (COPD) presents with increased breathlessness, cough, and sputum production over the last two days. She appears distressed and has a respiratory rate of 28 breaths per

minute. Her oxygen saturation is 88% on room air. Which of the following management strategies is most appropriate for her immediate treatment? (Q852751)

A. Initiate high-flow oxygen therapy to maintain oxygen saturation above 95%

B. Start nebulised bronchodilator therapy with salbutamol and ipratropium

C. Begin intravenous glucocorticoids immediately

D. Order a chest X-ray before any treatment is provided

Correct Answer: B. Start nebulised bronchodilator therapy with salbutamol and ipratropium

Explanation: Nebulised bronchodilator therapy with salbutamol and ipratropium is the most appropriate immediate treatment for this patient experiencing an acute exacerbation of COPD. This therapy helps relieve bronchospasm and improve airflow, which is critical given her increased breathlessness and distress. Treatment of Acute Exacerbation of COPD: Initial Management and Assessment: Symptoms: Increased breathlessness, cough, sputum production; deterioration in lung function and health status. Triggers: Usually bacterial or viral infections, or changes in air quality. Home management: Increased bronchodilator therapy, short course of oral glucocorticoids, and possibly antibiotics. Hospital referral indicators: Cyanosis Peripheral oedema Altered consciousness Comprehensive assessment upon admission: Level of consciousness (response to commands, ability to cough) Signs of CO_2 retention (warm peripheries, bounding pulse, flapping tremor) Airway obstruction assessment (wheeze, prolonged expiration) Signs of cor pulmonale (peripheral oedema, raised JVP) Background functional status and quality of life Precipitating causes (e.g., infection, environmental factors) Investigations: Investigation Purpose/Findings Arterial blood gases Assess severity of hypoxaemia, hypercapnia, acidaemia; guide oxygen therapy and ventilation. Chest X-ray Identify complications such as pneumonia, pneumothorax, or pleural effusion. (Option D ruled out) Management Strategies: Management Details Oxygen Therapy Administer controlled oxygen at 24% or 28% to maintain $PaO_2 > 8$ kPa (60 mmHg) or $SaO_2 > 90\%$. (Option A ruled out) Regular arterial blood gas monitoring to adjust therapy. Bronchodilators Use nebulised short-acting β2-agonists (e.g., salbutamol, terbutaline) with anticholinergics (e.g., ipratropium). If oxygen sensitivity is a concern, use compressed air for nebulisation. Glucocorticoids Administer oral prednisolone (30 mg for 10 days) to reduce symptoms and improve lung function.Reduces frequency and severity of exacerbations. Consider osteoporosis prophylaxis for repeated courses. Antibiotic Therapy Indicated for increased sputum purulence, volume, or breathlessness. Use simple regimens (aminopenicillin, tetracycline, macrolide); co-amoxiclav in areas with β-lactamase organisms. Non-Invasive Ventilation (NIV) Safe for mild to moderate respiratory acidosis; helps reduce intubation need and mortality. Not suitable for patients unable to protect their airway. Mechanical Ventilation Consider if there is a reversible cause, no prior respiratory failure, or if NIV has failed/contraindicated. Decisions should involve the patient, family, and GP. Additional Therapy Diuretics for peripheral oedema. Limited evidence for intravenous aminophylline; consider arrhythmia risk. Doxapram may be used short-term for low respiratory rates. Discharge and Follow-Up: Discharge criteria: Clinically stable on maintenance medication. Off nebulised therapy for at least 24 hours. PEF reaches 75% of predicted or personal best. Post-exacerbation follow-up: Identify and avoid trigger factors. Provide asthma education and a written self-management plan. Begin intravenous glucocorticoids immediately (Option C) is not the first-line treatment in the acute setting; while glucocorticoids are important in managing exacerbations, nebulised bronchodilators are prioritised for immediate relief of symptoms.

References:

Davidson’s Principles and Practice of Medicine, 24th Edition, Page 577, 578

↑ *Back to this question in Part A*

@Neet_pg_bot

Q62: A patient with a history of pneumonia develops pleural effusion. What is the expected finding in the pleural analysis for parapneumonic effusion? (Q852740)

A. Pleural protein/plasma protein ratio less than 0.5

B. Pleural LDH less than 2/3rd of plasma LDH

C. Pleural pH less than 7.2

D. Pleural LDH less than 0.6 of plasma LDH

Correct Answer: C. Pleural pH less than 7.2

Explanation: Correct Option C - Pleural pH less than 7.2: Parapneumonic effusion is an exudative pleural effusion secondary to pneumonia. As the infection progresses, bacterial metabolism and neutrophil activity increase lactic acid, leading to a low pleural fluid pH (<7.2). A pH below 7.2 indicates a complicated parapneumonic effusion and is an indication for intercostal drainage. Incorrect Options: Option A - Pleural protein/plasma protein ratio less than 0.5: A ratio <0.5 suggests a transudative effusion. Parapneumonic effusions are exudative, with a protein ratio >0.5. Option B - Pleural LDH less than 2/3rd of plasma LDH: Exudative effusions have LDH >2/3rd of the upper limit of normal plasma LDH, not less. Option D - Pleural LDH less than 0.6 of plasma LDH: A pleural fluid LDH/plasma LDH ratio <0.6 again indicates a transudate, which is not seen in parapneumonic effusion.

References:

Harrison's Principles of Internal Medicine, 21st Edition, Page 2198,2199.

Davidson's Principles and Practice of Medicine, 24th Edition, Page 563.

Pleural effusion

↑ *Back to this question in Part A*

@Neet_pg_bot

Q63: A 46-year-old diabetic patient presented with fever, malaise, and a productive cough. His chest X-ray is given below. Which of the following statements is incorrect? {{caption_text}} (Q853358)

A. Patchy infiltrates as seen in pyogenic pneumonia

B. Interstitial infiltrates as seen in Mycoplasma pneumonia

C. Hilar lymphadenopathy with infiltrates as seen in malignancy

D. Aspiration pneumonia is more common in the upper segment of the lower lobe and posterior segment of the upper lobe

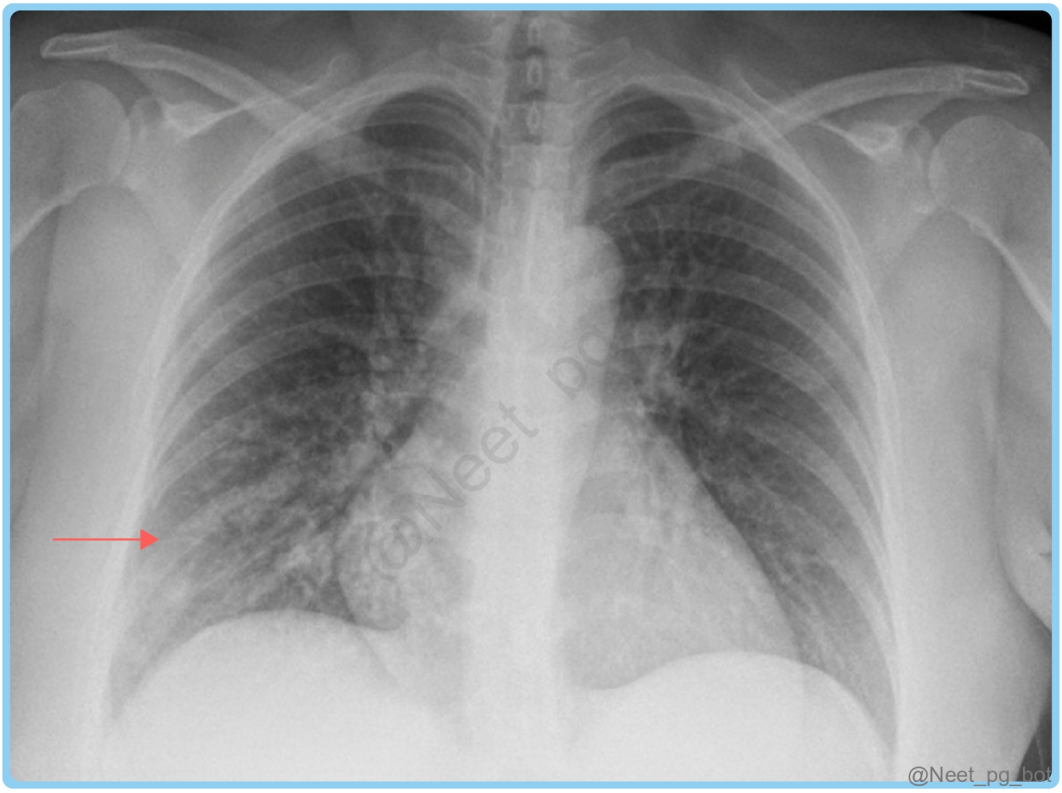

Correct Answer: A. Patchy infiltrates as seen in pyogenic pneumonia

Explanation: Patchy infiltrates are more characteristic of atypical pneumonia, such as Mycoplasma pneumonia or viral infections. Pyogenic (community-acquired) pneumonia more commonly presents with lobar consolidation rather than patchy infiltrates. Interstitial infiltrates in Mycoplasma pneumonia (Option B): Mycoplasma pneumonia typically presents with diffuse interstitial infiltrates rather than lobar consolidation. Hilar lymphadenopathy with infiltrates in malignancy (Option C): Hilar lymphadenopathy can be seen in malignancies such as lung cancer, though it is not relevant to the acute presentation in this case. Aspiration pneumonia distribution (Option D): Aspiration pneumonia commonly affects the upper segment of the lower lobe and posterior segment of the upper lobe due to gravitational factors when the patient is supine.

References:

Harrison's Principles of Internal Medicine, 21st Edition, Pages 1010-1019.

↑ *Back to this question in Part A*

@Neet_pg_bot

Q64: Old man underwent joint replacement surgery 3 days ago. Today he develops SOB with chest pain. O/E : pulse 100/min, BP 100/70 mm Hg, RR28/min and sp02: 85% room air. D-dimer is elevated. Which is the next best test (Q866499)

A. V/Q scan

B. ECG

C. CXR

D. CTPA

Correct Answer: D. CTPA

Explanation: This patient has acute-onset dyspnea, chest pain, hypoxia, and elevated D-dimer 3 days post–orthopedic surgery , which is highly suggestive of pulmonary embolism (PE) . In a hemodynamically stable patient with high pretest probability (post-surgery, classic symptoms), the next best test is CT Pulmonary Angiography (CTPA) , the gold standard for diagnosis as it directly visualizes thrombi in pulmonary arteries. Pulmonary Embolism - Clinical Features and Vitals Examination Clinical Features Vital Signs Unexplained dyspnea Pleuritic chest pain Hemoptysis Syncope Apprehension. Crushing central chest pain Calf cramps Severe Pulmonary Embolism: Sudden collapse of the patient. Severe hypotension Cyanosis Heart Rate: ↑ Respiratory Rate: ↑ Blood Pressure: ↓ Oxygen Saturation: ↓ (hypoxemia) Temperature: ↑ (low-grade fever) Pulmonary embolism (PE) Causes Pathophysiology Most PE originates from deep vein thrombosis (DVT) in the lower limbs. Other rare causes include: Septic emboli (from endocarditis affecting the tricuspid or pulmonary valves). Fat emboli (after fractures of long bones, e.g., femur). Tumour emboli (e.g., choriocarcinoma). Air emboli (In ENT and neurosurgeries commonly) Amniotic fluid emboli (after delivery). PE occurs when a blood clot (thrombus) travels to the lungs, blocking blood flow in the pulmonary artery. Impaired Gas Exchange: Increased anatomic and physiologic dead space due to decreased gas exchange. Hypoxemia and increased alveolar-arterial oxygen gradient result from poor ventilation-perfusion matching. Increased Pulmonary Vascular Resistance: Vascular obstruction by the clot and release of vasoconstricting agents like serotonin. Causes ventilation-perfusion mismatch even in areas away from the embolus. Pulmonary Hypertension : Blockage of the pulmonary artery increases pressure, leading to strain on the right heart. Right Ventricular (RV) Dysfunction : RV dilatation and failure due to increased afterload. RV microinfarction can occur with large PE, leading to elevated serum troponin and brain natriuretic peptide. V/Q scan (Option A): Used if CTPA is contraindicated (e.g., contrast allergy, severe renal failure), but here CTPA is preferred. ECG (Option B): May show nonspecific changes (e.g., sinus tachycardia, S1Q3T3), but not diagnostic for PE. CXR (Option C): Usually normal or nonspecific (e.g., atelectasis, pleural effusion) and cannot confirm PE.

↑ *Back to this question in Part A*

@Neet_pg_bot

Q65: A patient with COVID-19 pneumonia is admitted with severe respiratory distress and their PaO■/FiO■ is < 100. What is the most appropriate ventilatory strategy in this case? (Q866498)

A. Low PEEP, high tidal volume

B. High PEEP, low tidal volume

C. Low tidal volume, low PEEP

D. High tidal volume, high PEEP

Correct Answer: B. High PEEP, low tidal volume

Explanation: The clinical presentation points towards ARDS (PaO■/FiO■ < 100 mmHg with PEEP ≥ 5 cm H■O). ARDS management in COVID-19 follows lung-protective ventilation: Low tidal volume: Prevent volutrauma. Higher PEEP: Improves alveolar recruitment and oxygenation in severe hypoxemia. Low PEEP, high tidal volume (Option A): Causes alveolar overdistension and barotrauma; worsens mortality. Low tidal volume, low PEEP (Option C): Tidal volume is correct, but low PEEP is inadequate for severe ARDS and leads to derecruitment. High tidal volume, high PEEP (Option D): High PEEP helps oxygenation, but high tidal volumes increase risk of ventilator-induced lung injury.

↑ *Back to this question in Part A*

@Neet_pg_bot

Q66: A 45-year-old chronic smoker presents with complaints of dyspnea. Pulmonary function tests reveal an FEV1/FVC ratio of 65% and an RV/TLC ratio of 141%. Which of the following best describes the underlying pathophysiology? (Q865365)

A. Air trapping with hyperinflation of lungs

B. Decreased lung compliance

C. Restrictive lung disease

D. Increased lung compliance

Correct Answer: A. Air trapping with hyperinflation of lungs

Explanation: Given the history of chronic smoking, symptoms of dyspnea and Obstructive pattern on PFTs, this presentation is most consistent with chronic obstructive pulmonary disease (COPD) , especially emphysema , which is characterized by destruction of alveolar walls, air trapping, and lung hyperinflation. Smoking leads to inflammation and destruction of elastic fibers in the lungs, resulting in reduced airway recoil, premature airway closure, and gas trapping, which are hallmarks of emphysema. Pathogenesis of COPD Risk Factors Cigarette

Smoking : Primary risk, correlates with amount and duration. Environmental Factors : Indoor air pollution (e.g., biomass fuel use in confined spaces). Occupational exposures (e.g., coal dust, silica, cadmium). Developmental Factors : Low birth weight and impaired lung growth from infections or maternal smoking. Infections : Recurrent infections accelerate lung decline. Persistent adenovirus may alter inflammatory responses, leading to damage. Genetic Factors : Alpha-1 antitrypsin deficiency . (Option B ruled out) Airway hyper-reactivity . Components of COPD Pulmonary Components Description Mucus hypersecretion Enlargement of mucus glands and goblet cells → chronic bronchitis (cough + sputum for ≥3 months/year). Emphysema Alveolar destruction by proteases and oxidants → permanent enlargement of distal airspaces. Airflow Limitation Loss of elastic tissue + inflammation → premature airway closure, gas trapping, and hyperinflation. This is the primary mechanism for the airflow limitation. Pulmonary vascular remodeling Structural changes in pulmonary vessels.eventually causing PAH. Systemic Components Description Weight Loss Altered fat metabolism. Skeletal Muscle Dysfunction Muscle impairment reduces physical capacity. Peripheral Edema Impaired kidney function → salt and water retention. Osteoporosis Decreased bone density. Increased Inflammatory Markers Elevated systemic inflammation contributes to complications. Incorrect Options: Decreased lung compliance (Option B): Seen in restrictive lung diseases (e.g., pulmonary fibrosis). COPD/emphysema features increased, not decreased, compliance due to alveolar wall destruction. Restrictive lung disease (Option C): Would show normal or increased FEV1/FVC ratio and decreased lung volumes, not increased RV/TLC. Increased lung compliance (Option D): True for emphysema, but A (air trapping with hyperinflation) better encapsulates the specific pathophysiologic hallmark presented in this question.

References:

Davidson’s Principles and Practice of Medicine, 24th Edition, Page 574. 575, 576

↑ *Back to this question in Part A*

@Neet_pg_bot

Q67: A patient presents with progressive shortness of breath for the last 6 months, accompanied by dry cough. Auscultation reveals bilateral basal end-inspiratory crepitations. There is no history of fever, joint pain, or occupational exposure. What is the diagnosis? (Q866819)

A. Cor-pulmonale

B. Sarcoidosis

C. IPF

D. Hypersensitivity pneumonitis

Correct Answer: C. IPF

Explanation: Idiopathic Pulmonary Fibrosis (IPF) is a chronic, progressive fibrosing interstitial lung disease of unknown cause, typically seen in older adults. The classic presentation includes gradually worsening exertional dyspnoea and nonproductive cough over months. On auscultation, bilateral basal end-inspiratory “Velcro” crackles

are characteristic. Absence of fever, joint symptoms, or occupational dust/fume exposure supports an idiopathic diagnosis rather than secondary interstitial lung disease. Incorrect Options: Cor-pulmonale (Option A): Refers to right ventricular hypertrophy and failure secondary to chronic lung disease or pulmonary hypertension; it is a consequence, not the primary cause, of the lung findings here. Sarcoidosis (Option B): Usually presents with systemic features, bilateral hilar lymphadenopathy, and may involve skin or eyes; less likely here due to absence of extrapulmonary signs and chronicity pattern. Hypersensitivity pneumonitis (Option D): Generally linked to a clear history of antigen exposure (birds, mold, farming) and has a more acute/subacute onset; no such history is present in this case.

↑ *Back to this question in Part A*

@Neet_pg_bot

Q68: A patient presents with SOB and fatigue. CXR was done. What is the diagnosis? (Q866818)

A. TB

B. Asbestosis

C. Silicosis

D. Byssinosis



Correct Answer: B. Asbestosis

Explanation: Asbestosis is an interstitial lung disease caused by inhalation of asbestos fibers, often in occupations such as shipbuilding, construction, or insulation work. The hallmark radiologic finding is calcified pleural plaques , especially along the parietal pleura and diaphragm (“peripheral pleural calcification”), along with lower lobe interstitial fibrosis. Patients present with progressive dyspnea and restrictive lung disease on PFTs. Incorrect Options: TB (Option A): More commonly involves apical regions, with cavitation and infiltrates; pleural calcifications are uncommon. Silicosis (Option C): Typically shows upper lobe nodules and “eggshell” hilar node calcification. Byssinosis (Option D): Cotton dust–related disease, usually without pleural calcification.

References:

.

↑ *Back to this question in Part A*

@Neet_pg_bot

Q69: A patient is in ICU and there is a failed attempt of subclavian catheterization. Shortly after, BP drops and the pulse rises. What is the diagnosis? (Q866813)

A. Pneumothorax

B. Displacement of endotracheal tube (ET)

C. Air embolism

D. Dislodgement of ET

Correct Answer: A. Pneumothorax

Explanation: Subclavian vein catheterization carries a significant risk of pleural injury , which can cause pneumothorax . Air entry into the pleural space leads to reduced venous return , causing hypotension and reflex tachycardia. In the ICU setting, this can rapidly progress to tension pneumothorax , which is life-threatening and requires urgent decompression. Typical signs: sudden drop in BP, tachycardia, respiratory distress, unilateral decreased breath sounds, hyperresonance on percussion. Incorrect Options: Displacement of ET (Option B): Would cause hypoxia and respiratory distress, but is not directly related to subclavian line attempt. Air embolism (Option C): Can occur during line placement, but presents with sudden cardiovascular collapse and possibly a "mill wheel" murmur; pneumothorax is more common post failed subclavian attempt. Dislodgement of ET (Option D): Would cause airway compromise but unrelated to catheterization unless ET manipulation occurred.

↑ *Back to this question in Part A*

@Neet_pg_bot

Q70: A 45-year-old patient with a history of smoking a pack of cigarettes for the past 15 years presents with hemoptysis. Chest X-ray shows a 3cm upper lobe mass near the apex of the lung. What is the next best step for managing this patient? (Q858025)

A. Bronchoscopy

B. CT-guided biopsy

C. Sputum cytology

D. Sputum for AFB

Correct Answer: B. CT-guided biopsy

Explanation: xtension to upper abdomen (adrenal level) Sensitivity: 55%, Specificity: 81% Identifies tumor location, extent, and lymph node involvement Lymph node ≥1cm in short axis considered suspicious PET/PET-CT Higher accuracy than CT (Sensitivity: 80%, Specificity: 88%) Identifies metabolic activity and potential metastases Reduces futile thoracotomies Helpful in identifying recurrence post-therapy Invasive Staging & Biopsy Methods CT-Guided Transthoracic Biopsy Preferred for peripheral lesions (Option A) High diagnostic accuracy Minimally Invasive Risk of pneumothorax (especially in emphysematous patients) Contraindicated if high bleeding risk or severe emphysema EBUS-TBNA CP-EBUS: Real-time sampling of mediastinal/hilar nodes RP-EBUS: For smaller/peripheral lesions Navigation bronchoscopy for mapped approach Endoscopic-TBNA Samples through esophageal wall Accesses stations 2, 4, 7, 8, 9 Sensitivity: 89%, Specificity: 100% Mediastinoscopy Used after negative needle technique Samples para-tracheal nodes Sensitivity: 78%, Specificity: 100% Mortality risk: 0.08% VATS/RATS For mediastinal lymph node sampling Full dissection during lung resection Minimally invasive approach Cancer Type Location Primary Investigations Additional Investigations Non-Small Cell Lung Cancer (NSCLC) - Adenocarcinoma Peripheral/Outer regions of lung CT-guided needle biopsy PET-CT scan Blood tests for tumor markers (CEA) Molecular testing (EGFR, ALK, ROS1) MRI brain (for staging) Pulmonary function tests NSCLC - Squamous Cell Central/Main bronchi Bronchoscopy with biopsy Chest CT with contrast Sputum cytology Mediastinoscopy Bone scan (if symptoms) PD-L1 testing Small Cell Lung Cancer (SCLC) Central regions, rapid spread CT chest/abdomen/pelvis Bronchoscopy Blood tests (ProGRP, NSE) MRI brain (mandatory) Bone marrow biopsy Nuclear medicine scans Large Cell Carcinoma Any location PET-CT scan Core needle biopsy Immunohistochemistry Molecular profiling EBUS-TBNA Liquid biopsy Carcinoid Tumors Usually central airways Octreotide scan Bronchoscopy with biopsy 24-hour urine 5-HIAA Chromogranin A levels MIBG scan Endoscopic ultrasound Bronchoscopy (Option A): While bronchoscopy can be useful in evaluating central lesions or endobronchial tumors, it may not be effective for evaluating peripheral lung masses, especially those located near the apex. Sputum cytology (Option C): Sputum cytology is inexpensive and noninvasive but has a lesser sensitivity than biopsy, especially when there is a clear indication of a suspected lung mass on radiography. The yield for sputum cytology is highest for larger and centrally located tumors such as squamous cell carcinoma and small-cell carcinoma. Sputum for AFB (Option D): While TB can cause hemoptysis, the appearance of a 3cm upper lobe mass near the apex on chest X-ray is inconsistent with the typical presentation of TB and indicates a suspected malignancy for which a tissue diagnosis is more urgently needed.

References:

Harrison's Principles of Internal Medicine, 21st Edition, Page 595-601

↑ *Back to this question in Part A*

@Neet_pg_bot

Q71: Which of the following does not cause central cyanosis? (Q855700)

A. Methemoglobinemia

B. Pulmonary arteriovenous fistula

C. High altitude

D. Hypothermia

Correct Answer: D. Hypothermia

Explanation: Hypothermia refers to a decrease in core body temperature below the normal range. It occurs when the body temperature drops below 95 degrees Fahrenheit (35 degrees Celsius). Hypothermia causes peripheral cyanosis. Central cyanosis is seen due to decreased oxygen saturation or oxygen-carrying capacity of the blood. Methemoglobin (Option A) is oxidized hemoglobin due to nitrate exposure. This leads to a reduced oxygen-carrying capacity of the blood and can result in central cyanosis. A pulmonary arteriovenous fistula (Option B) is an abnormal connection between an artery and a vein in the lung. This can result in the bypassing of oxygenated blood from the lungs to the systemic circulation, leading to a decrease in arterial oxygen saturation and central cyanosis. At high altitudes (Option C), the partial pressure of oxygen in the atmosphere is lower, resulting in hypobaric hypoxia. This can cause central cyanosis due to reduced oxygen availability.

References:

Harrison's Principles of Internal Medicine, 21st Edition, Page 274

↑ *Back to this question in Part A*

@Neet_pg_bot

Q72: A chronic cigarette smoker has now joined a construction company. His pulmonary function test results are given below. What is the most likely diagnosis for this patient? Initial lung volumes were: FEV1-0.9L FVC-1.9L FEV1/FVC-0.4 After bronchodilation: FEV1-1.9L FVC-3.9L FEV1/FVC-0.4 (Q855598)

A. Vascular disease with bronchodilator reversibility

B. Restrictive lung disease with bronchodilator reversibility

C. Restrictive lung disease without bronchodilator reversibility

D. Obstructive disease with bronchodilator reversibility

Correct Answer: D. Obstructive disease with bronchodilator reversibility

Explanation: In people with asthma or chronic obstructive pulmonary disease (COPD), bronchodilator reversibility test is commonly used. The purpose of the test is to determine whether the subject's airflow has improved as a result of taking the bronchodilator medication. The given pulmonary function test results indicate a diagnosis of obstructive lung disease with bronchodilator reversibility as the FEV1/FVC is less than 0.7, so it is an obstructive disease, and after bronchodilation there is an increase of >12% in FEV1; hence it is reversible. Improved lung volumes after bronchodilation indicate a response to the bronchodilator, which is a feature of COPD. Vascular disease does not typically present with bronchodilator reversibility . (Option A) Restrictive lung diseases are characterized by reduced lung volumes (Option B), but the given lung volumes do not suggest restriction. Additionally, improved lung volumes after bronchodilation indicate a response to the bronchodilator, which is not typically seen in restrictive lung diseases. The lung volumes provided do not indicate restriction (Option C) . Additionally, the lack of improvement in lung volumes after bronchodilation contradicts this option.

References:

https://www.ncbi.nlm.nih.gov/books/NBK482217/

Harrison's Principles of Internal Medicine, 21st Edition, Pages 2134 to 2138.

↑ *Back to this question in Part A*

@Neet_pg_bot

Q73: A 65-year-old female patient weighing 60 kg is on mechanical ventilation for ARDS secondary to urosepsis. The respiratory parameters are as follows: tidal volume – 360 mL; frequency – 30 breaths/min; PEEP - 5 cm of H2O; and FiO2-90%. The arterial blood gas findings are as follows; paO2-50 mmHg; paCO2-38 mmHg; and pH-7.38. What is the next step? (Q855351)

A. Reduce FiO2

B. Increase tidal volume

C. Increase respiratory rate

D. Increase PEEP

Correct Answer: D. Increase PEEP

Explanation: In the given scenario, the patient is experiencing ARDS (Acute Respiratory Distress Syndrome) secondary to urosepsis and is on mechanical ventilation. The arterial blood gas (ABG) results show a low paO 2 level of 50 mmHg, indicating hypoxemia. To improve oxygenation in ARDS, the next step would be to increase the positive end-expiratory pressure (PEEP). PEEP helps to recruit collapsed alveoli, improve lung compliance,

and maintain alveolar patency. Increasing PEEP helps open up more lung units, improve oxygenation, and increase functional residual capacity (FRC). The FiO2 is already set at 90% to provide a high concentration of oxygen to the patient. Further reducing FiO2 (Option A) may compromise oxygenation and worsen hypoxemia. Increasing tidal volume (Option B) can lead to an increased risk of ventilator-induced lung injury (VILI) and barotrauma. It is generally recommended to use lower tidal volumes (around 6 mL/kg of ideal body weight) in ARDS to minimize complications. Increasing respiratory rate (Option C) may improve minute ventilation but does not directly address the issue of hypoxemia. It is not the ideal intervention to improve oxygenation in ARDS.

References:

Harrison's Principles of Internal Medicine, 21st Edition, Page 2228, 2230, 2233

↑ *Back to this question in Part A*

@Neet_pg_bot

Q74: A 72-year-old man presented with weight loss, decreased appetite, and iron deficiency anemia. Chest x-ray was done and given below. What is the diagnosis? (Q856976)

A. Lung metastasis

B. Bronchogenic carcinoma

C. Miliary tuberculosis

D. Mesothelioma



Correct Answer: A. Lung metastasis

Explanation: The radiological imaging reveals canon ball metastasis of the lung likely secondary to malignancies such as Renal Cell Carcinoma . Cannonball metastases: Cannonball metastases are radiographic findings characterized by multiple large, rounded, well-circumscribed opacities within the lungs. Etiology and Common Primary Tumors : Cannonball metastases are associated with cancers prone to hematogenous spread. The most common primary malignancies known to cause cannonball metastases in the lungs include: Mnemonic: CRESP C: Choriocarcinoma/colorectal carcinoma R: Renal cell carcinoma E: Endometrial carcinoma S: Synovial sarcoma P: Prostate carcinoma Clinical Presentation : Symptoms can be varied and include chronic cough, hemoptysis, dyspnea, weight loss, and fatigue. In some cases, cannonball metastases are incidentally discovered on imaging during evaluation for other symptoms or known malignancies. Pathophysiology : The development of cannonball metastases results from the hematogenous spread of tumor cells, allowing them to bypass lymphatic pathways and form nodular deposits directly in the lung parenchyma. This pattern reflects the aggressive nature of certain tumors and their tendency for vascular invasion. Imaging : X-ray : Multiple large, round, sharply defined opacities scattered throughout the lung fields. CT Scan : Better delineates the size, shape, and distribution of these nodules, allowing for assessment of the primary and any additional thoracic involvement.

References:

https://radiopaedia.org/articles/cannonball-metastasis-mnemonic-1

https://radiopaedia.org/articles/cannonball-metastases-lungs

↑ *Back to this question in Part A*

@Neet_pg_bot

Q75: A 55 year old shipbuilding worker presents with dyspnea. He has been working in this industry for the past 25 years. Which is the most specific malignancy that we can expect in this patient? (Q856984)

A. Bronchogenic carcinoma

B. Malignant mesothelioma

C. Small cell carcinoma of lung

D. Squamous cell carcinoma of lung

Correct Answer: B. Malignant mesothelioma

Explanation: Malignant mesothelioma is a tumor of mesothelial cells. It is the most specific malignancy seen in asbestosis Workers in the shipbuilding and construction trades, including pipe fitters and boilermakers, are occupationally exposed to asbestos. Asbestosis is a diffuse interstitial fibrosing disease of the lung. Past exposure to asbestos is specifically indicated by pleural plaques on chest radiographs, which are characterized by either thickening or calcification along the parietal pleura, particularly along the lower lung fields. Pulmonary function testing in asbestosis reveals a restrictive pattern with a decrease in both lung volumes and diffusing capacity. Complications include mesothelioma and carcinoma of the lung . Mesothelioma A rare cancer arising from mesothelial cells that most commonly affects the pleura. It can also affect the peritoneum, pericardium and tunica vaginalis. Aetiology Asbestos: Mesothelioma is the most specific asbestos-associated cancer . It is not associated with smoking. Pathology Advanced pleural mesothelioma can cause extensive pleural fibrosis and thickening, making the affected side rigid and immobile. Later stages fix the mediastinum in place due to pleural thickening and fibrosis. The mediastinal shift is not a characteristic feature of mesothelioma. M/C cytogenetic abnormality in mesothelioma: Homozygous deletion of chromosome 9p , leading to loss of tumour suppressor gene- CDKN2A. Clinical features Progressive dyspnea, chest pain, weight loss, chronic cough, hemoptysis. Decreased breath sounds and dullness to percussion (due to pleural effusion or thickening). Diagnosis CT scan: Pleural thickening, effusion, or frozen hemithorax (not causing a mediastinal shift in the presence of effusion) Confirmed by biopsy: Epithelioid mesothelioma shows tubules, nests, or papillary structures with uniform round to oval nuclei and eosinophilic cytoplasm. Sarcomatoid mesothelioma consists of spindle-shaped cells resembling fibrosarcoma. Biphasic mesothelioma displays a mixture of both patterns. Specific markers for mesothelioma: Calretinin. Epithelial membrane antigen. Cytokeratin. Mesothelin. {{caption_text}} Mesothelioma- Gross {{caption_text}} Mesothelioma- H & E stain {{caption_text}} Mesothelioma- Calretinin stain {{caption_text}} Coarse, partially calcified right pleural plaques, accompanied by massive right pleural effusion, causing total right lung collapse and mass effect. {{caption_text}} Lobulated pleural soft tissue mass encasing the right lung. Associated erosion of the right 3rd rib anteriorly. Calcified pleural plaques were noted bilaterally, indicating previous asbestos exposure. Bronchogenic carcinoma (Option A) is the most common lung malignancy, it is not the most specific malignancy associated with asbestos exposure (shipbuilding → asbestos exposure)


@Neet_pg_bot

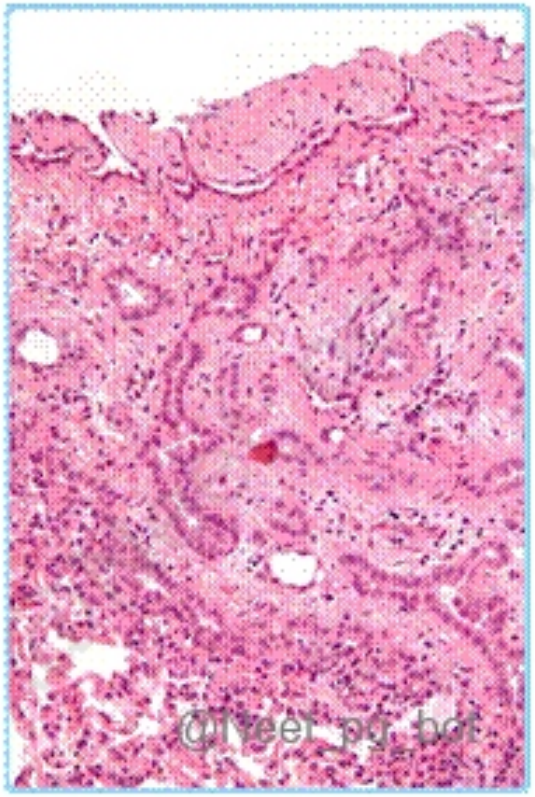
@Neet_pg_bot


@Neet_pg_bot

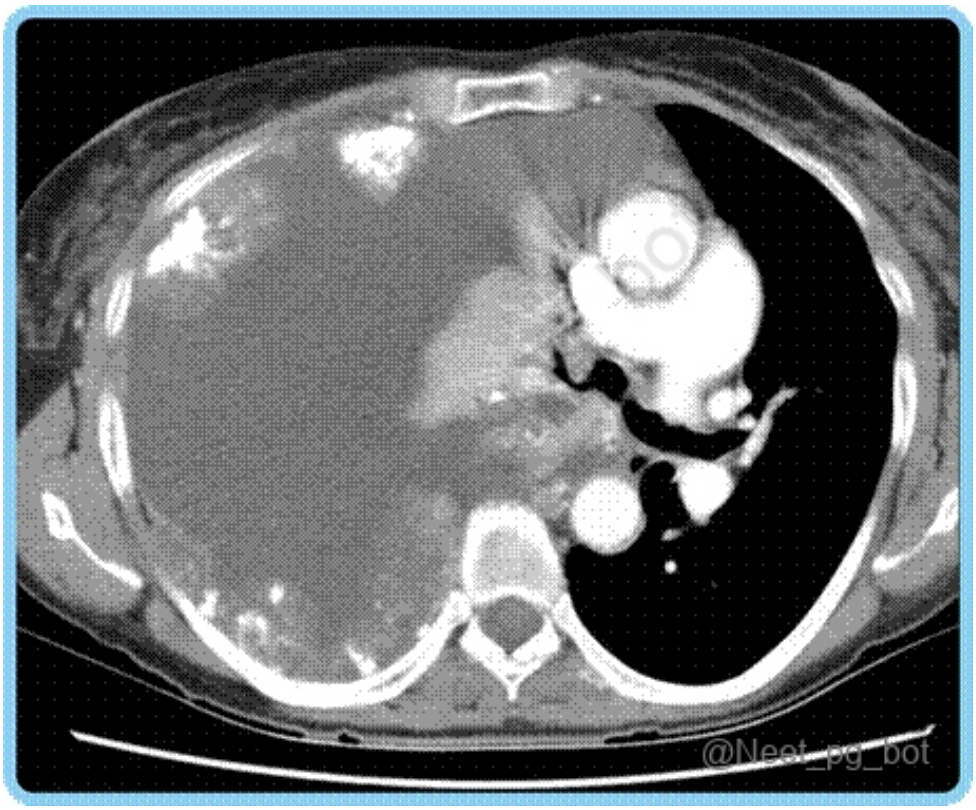
@Neet_pg_bot

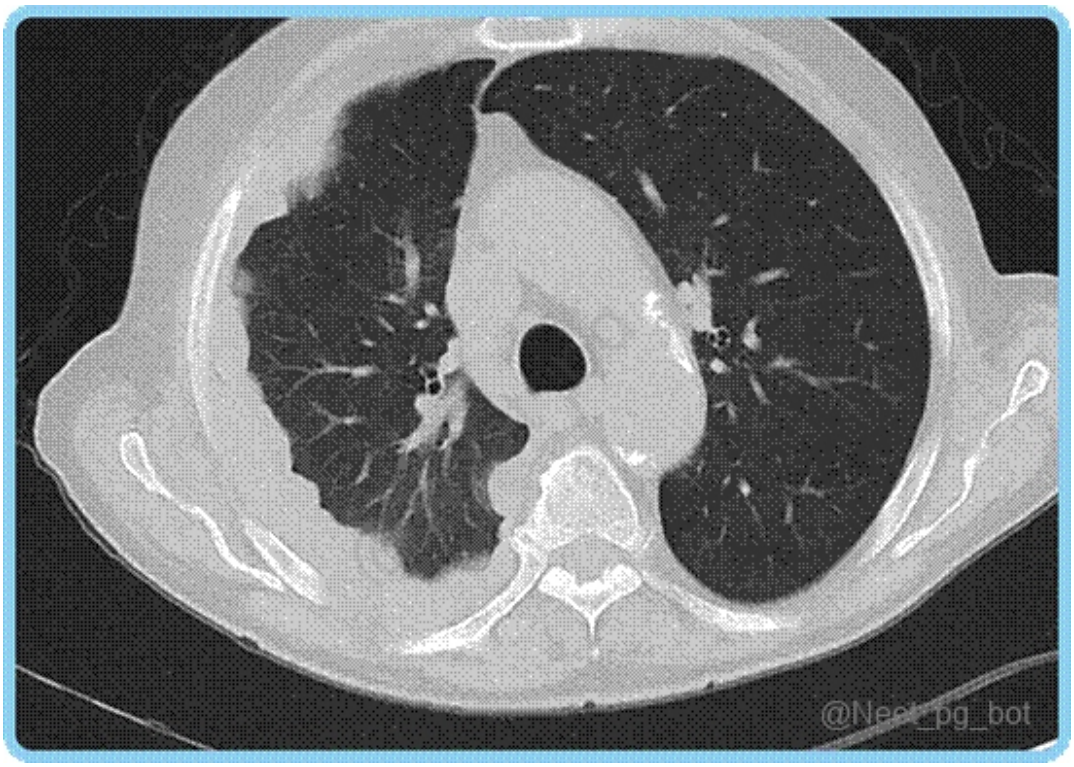

References:

Harrison’s Principles of Internal Medicine, 21st edition, Page 2168, 2198

Davidson’s Principles and Practice of Medicine, 24th edition, Page 615

Robbins and Cotran, Pathologic Basis of Disease, 10th edition, Page 726, 727, 697

↑ *Back to this question in Part A*

@Neet_pg_bot

Q76: A 60-year-old male patient comes to your clinic with an 8-month history of shortness of breath and non-productive cough. He has smoked half a pack of cigarettes for the past 30 years. On physical examination, clubbing is seen and fine crackles are heard on both sides during inspiration. You perform pulmonary function tests and it shows an FEV1/FVC ratio of 92%. The CT scan of the chest is shown below. What is the most probable diagnosis? (Q856989)

A. Bronchial asthma

B. Pulmonary fibrosis

C. Pulmonary tuberculosis

D. Chronic obstructive pulmonary disease

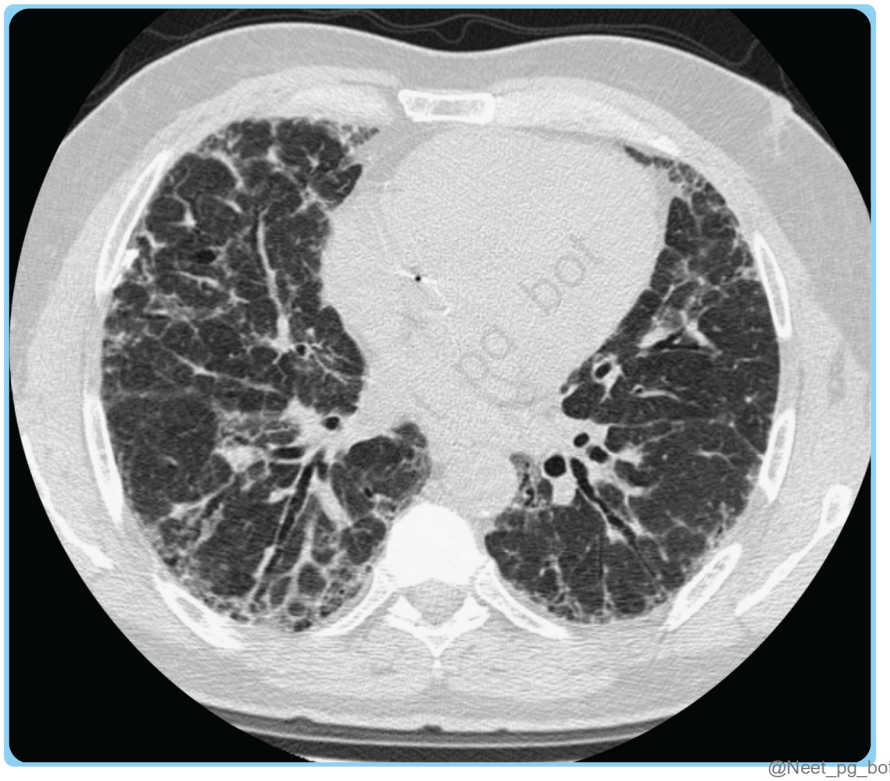

Correct Answer: B. Pulmonary fibrosis

Explanation: Pulmonary fibrosis is the most likely diagnosis in this patient given his symptoms such as shortness of breath, persistent nonproductive cough, clubbing, bilateral inspiratory crackles, pulmonary function tests, and imaging findings. The CT image shows the presence of honeycombing (black arrows), traction bronchiectasis (white arrow), and a reticular pattern (black dotted arrows). The lesions are typically located along subpleural regions. Idiopathic pulmonary fibrosis (IPF) is the most common cause of interstitial lung disease (ILD) of unknown cause. Usual interstitial pneumonia (UIP) is the typical pathological finding in patients with suspected idiopathic pulmonary fibrosis (IPF). Patients with UIP typically present in their sixth and seventh decades. Men are affected more commonly than women. PFTs in patients with pulmonary fibrosis show a restrictive pattern. High-resolution computed tomography (HRCT) demonstrates a characteristic pattern of peripheral (subpleural), bibasilar reticular opacities associated with architectural distortion,including honeycomb changes and traction bronchiectasis.

References:

Harrison's Textbook for Internal Medicine 21st edition, Page 2190, 2191, 2192

https://www.ncbi.nlm.nih.gov/books/NBK448162/

↑ *Back to this question in Part A*

@Neet_pg_bot

Q77: On examination, a person has distended neck veins, absent breath sounds, hyperresonance, and a shift of the trachea. What is the management? (Q866805)

A. Bedside CXR in casualty followed by chest tube insertion

B. Wide bore needle in 2 nd ICS

C. Pericardiocentesis

D. Pleurodesis with doxycycline

Correct Answer: B. Wide bore needle in 2 nd ICS

Explanation: This is tension pneumothorax – caused by air trapping in the pleural space under pressure. Key signs: Respiratory distress Hyperresonance (air in pleural space) Absent breath sounds (no lung expansion) Distended neck veins (↑ intrathoracic pressure → ↓ venous return) Tracheal shift away from the affected side (mass effect) In tension pneumothorax, waiting for imaging can be fatal. Immediate needle decompression is done in the 2nd intercostal space, midclavicular line using a wide-bore cannula , followed by chest tube insertion. Tension Pneumothorax: Pathophysiology: Air enters the pleural space during inspiration but cannot exit (one-way valve mechanism). This increases intrapleural pressure → lung collapse → mediastinal shift → compression of heart and opposite lung → obstructive shock. Causes: trauma, mechanical ventilation, rib fractures, ruptured bleb. Emergency Management: Needle decompression (life-saving) – 2nd ICS MCL or 4th/5th ICS anterior axillary line. Chest tube thoracostomy in the 4th/5th ICS mid-axillary line after decompression. Incorrect Options: Bedside CXR in casualty followed by chest tube insertion (Option A) – Wrong because waiting for imaging delays life-saving decompression. Pericardiocentesis (Option C) – For cardiac tamponade, not pneumothorax. Pleurodesis with doxycycline (Option D) – For recurrent pneumothorax, not for acute life-threatening tension pneumothorax.

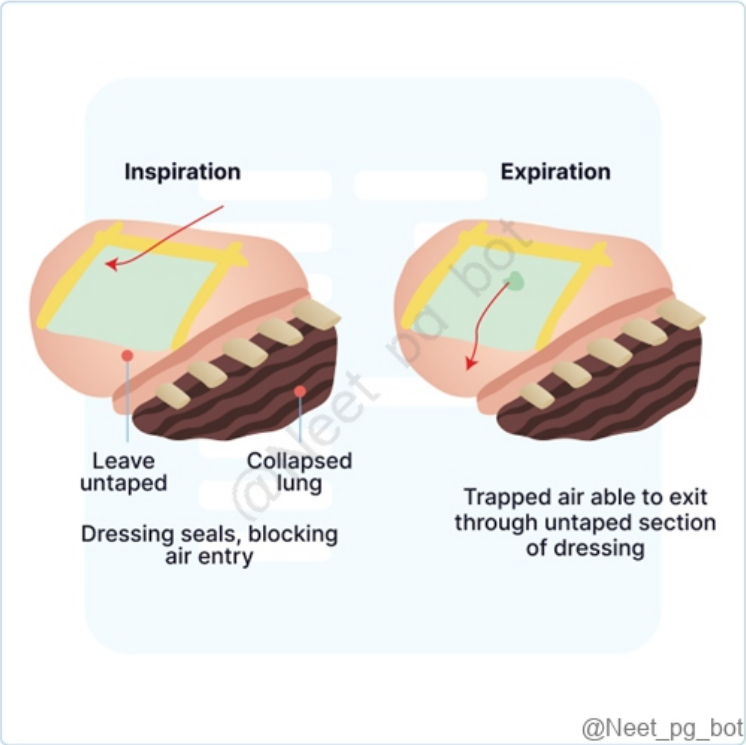

↑ *Back to this question in Part A*

@Neet_pg_bot

Q78: A 5-year-old child presented with recurrent respiratory infections with thickened sputum. Chest X-ray showed bronchial wall thickening. He has been suffering from steatorrhea since birth. Which of the following is the first differential diagnosis? (Q858033)

A. Hyaline membrane disease

B. Cystic fibrosis

C. Alpha 1 anti-trypsin deficiency

D. Malabsorption syndrome

Correct Answer: B. Cystic fibrosis

Explanation: typically presents with steatorrhea, diarrhea, weight loss & various nutrient deficiencies but does not account for the specific respiratory manifestations present in this case. The combination of respiratory and gastrointestinal symptoms points more specifically to cystic fibrosis.

References:

Harrison’s Principles of Internal Medicine, 21st Edition, Volume I, Page. 2176, 2177

↑ *Back to this question in Part A*

@Neet_pg_bot

Q79: Which of the following is a cause of exudative pleural effusion? (Q858016)

A. Heart failure

B. Rheumatic arthritis

C. Dressler syndrome

D. Nephrotic syndrome

Correct Answer: C. Dressler syndrome

Explanation: ressler syndrome is a post–myocardial infarction autoimmune pericarditis that can be associated with exudative pleural effusion. The effusion results from inflammation of the pleura, leading to increased capillary permeability and high protein content. Exudative effusions typically satisfy Light’s criteria. Incorrect Options: Option A - Heart failure: Pleural effusion in heart failure is usually transudative, caused by increased hydrostatic pressure. It typically has low protein and LDH levels. Option B - Rheumatic arthritis: Rheumatoid arthritis can cause pleural effusion, but it is relatively uncommon and usually seen in long-standing disease. It is not the best answer in this context compared to Dressler syndrome. Option D - Nephrotic syndrome: Nephrotic syndrome causes transudative pleural effusion due to hypoalbuminemia and reduced plasma oncotic pressure.

References:

Harrison’s Principles of internal medicine 21st edition Page 2199

Pleural effusion

↑ *Back to this question in Part A*

@Neet_pg_bot

Q80: In which medical condition is a ground-glass appearance observed on high-resolution computed tomography (HRCT)? (Q858009)

A. Asbestosis

B. Silicosis

C. Anthracosis

D. Bagassosis

Correct Answer: B. Silicosis

Explanation: s the disease progresses, nodular opacities called silicotic nodules develop, typically with an upper lung zone predominance, and may calcify over time, resulting in eggshell calcifications. Silicosis: The leading cause of Interstitial lung disease (ILD) in India , frequently resulting from occupational exposure in the glassware, mining, quarrying, and construction industries. Manifests after 10-20 years of continuous exposure. Radiological features: The chest radiograph may show profuse military infiltration or consolidation, and there is a characteristic HRCT pattern of ground glass opacities known as “crazy paving”- A feature of acute silicosis Multiple well-circumscribed 3–5 mm nodular opacities predominantly in the mid-and upper zones. Enlargement of the hilar glands with an “egg-shell” pattern of calcification (seen in 20% of cases). As the disease progresses, progressive massive fibrosis (PMF) may develop. Asbestosis (Option A): Asbestosis is a chronic lung disease caused by the inhalation of asbestos fibers. The characteristic findings on HRCT include linear opacities that typically have a subpleural and lower lung zone predominance, with fine reticular lines, thick bands, or honeycombing. Ground-glass appearance is not a typical feature of asbestosis. Anthracosis (Option C): Anthracosis, or coal workers' pneumoconiosis, is caused by the inhalation and deposition of coal dust particles. The primary HRCT finding is the presence of small, rounded opacities, often referred to as coal macules or coal nodules found in the upper lung zones. Ground-glass opacities are not a characteristic feature. Bagassosis (Option D): Bagassosis is an acute hypersensitivity pneumonitis caused by the inhalation of moldy bagasse. While HRCT findings in bagassosis can vary, they typically include centrilobular nodules and air-trapping. While ground-glass opacities may be seen, they are not the predominant or characteristic feature.

References:

Harrison’s Principles of Internal Medicine, 21st Edition, Page 2169, 2191

Davidson’s Principles and Practice of Medicine, 24th Edition, Page 615

↑ *Back to this question in Part A*

@Neet_pg_bot

Q81: A 65-year-old chronic smoker came to the medicine outpatient department with complaints of upper chest discomfort and drooping of an eyelid. He also complained of pain radiating to the upper arm and a tingling sensation in the 4th and 5th digits of his right hand. The chest X-ray is given below. Which of the following is the most likely diagnosis? (Q855501)

A. Pancoast tumor

B. Superior vena cava obstruction

C. Upper lobe pneumonia

D. Aspergilloma



Correct Answer: A. Pancoast tumor

Explanation: Pancoast tumor This patient's clinical presentation, combined with the findings from the chest X-ray, points towards the Pancoast tumor, a form of lung cancer that occurs in the apex (upper part) of the lung. Pancoast Tumor: A Pancoast tumor, also known as a superior sulcus tumor, is a type of lung cancer that arises in the apex of the lung, often extending to involve nearby structures, including the chest wall, nerves, and blood vessels. These tumors are typically non-small cell lung cancers (NSCLC), most commonly squamous cell carcinoma or adenocarcinoma, strongly associated with smoking, which is a major risk factor. Clinical Presentation The symptoms of a Pancoast tumor are primarily due to the tumor's location rather than systemic effects of lung cancer. Pain: Severe shoulder, arm, or chest wall pain is common due to invasion of the brachial plexus (C8-T2 nerve roots). Horner's Syndrome: Results from sympathetic chain involvement, characterized by: Ptosis (drooping eyelid) Miosis (pupil constriction) Anhidrosis (loss of sweating on the affected side) Weakness and Atrophy: Weakness of the hand muscles and atrophy, due to compression of the lower brachial plexus. Other Symptoms: Cough, hemoptysis, and weight loss may be present if the disease is more advanced. Diagnosis Imaging: Chest X-ray: May show an apical mass. {{caption_text}} MRI (IOC): Provides detailed information about local invasion into nearby structures. Biopsy: Confirms histological diagnosis. PET Scan: Assesses metastasis. Management Radiotherapy : Preoperatively to shrink the tumor. Surgery: For resectable tumors, such as lobectomy or chest wall resection. Chemotherapy: For advanced or unresectable tumors. Superior vena cava obstruction (Option B): This condition can occur due to a tumor compressing the superior vena cava, causing swelling of the face, neck, and upper limbs, but it would not explain the combination of ptosis and pain radiating to the arm. It is usually associated with anterior mediastinal tumors, not typically with Pancoast tumors. Upper lobe pneumonia (Option C): Pneumonia could cause chest discomfort and radiographic findings, but it would not explain the drooping

eyelid (ptosis) or neurological symptoms in the arm. Pneumonia would also show consolidation on a chest X-ray, not a mass. {{caption_text}} Aspergilloma (Option D): Aspergilloma is a fungal infection that typically occurs in pre-existing lung cavities (e.g., after tuberculosis). It could cause chest pain and cough, but it would not explain the ptosis or brachial plexus symptoms. The chest X-ray would typically show a fungal ball within a pre-existing cavity. {{caption_text}}



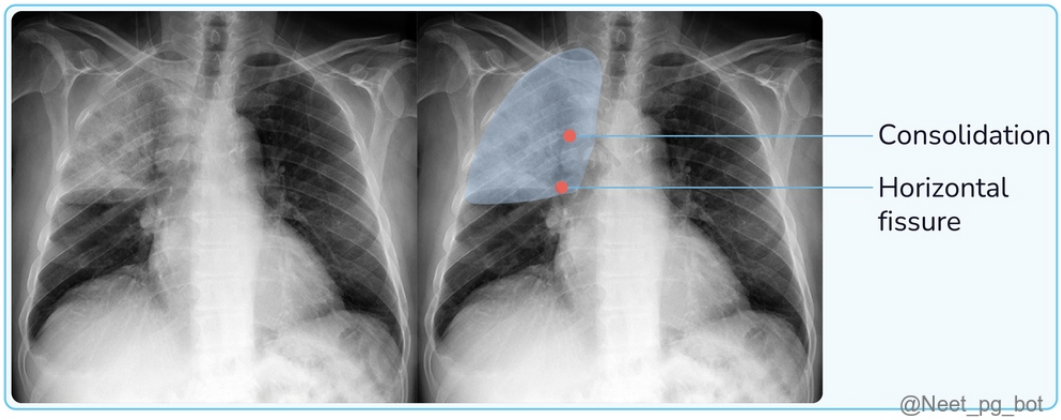

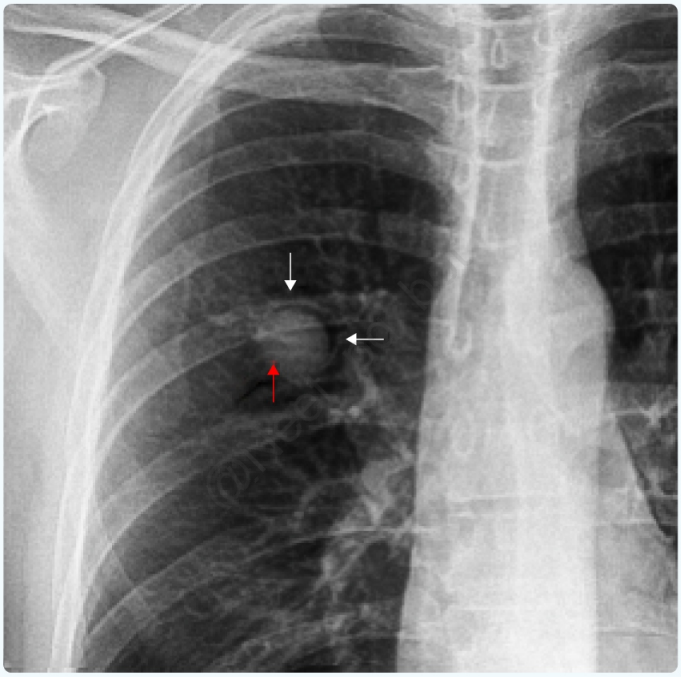

Thin-walled upper lobe cavity (white arrows) with a fungus ball in the dependent portion (red arrow)

@Neet_pg_bot

References:

Harrison's Principles of Internal Medicine, 21st Edition, Page: 565, 566, 598, 1011, 1679. Schwartz's Principles of Surgery - 11th Edition, Page: 680, 699.

↑ *Back to this question in Part A*

@Neet_pg_bot

Q82: Comment on the lung disease? (Q854721)

A. Hypersensitivity pneumonitis

B. Sarcoidosis

C. Acute respiratory distress syndrome

D. Bronchiectasis

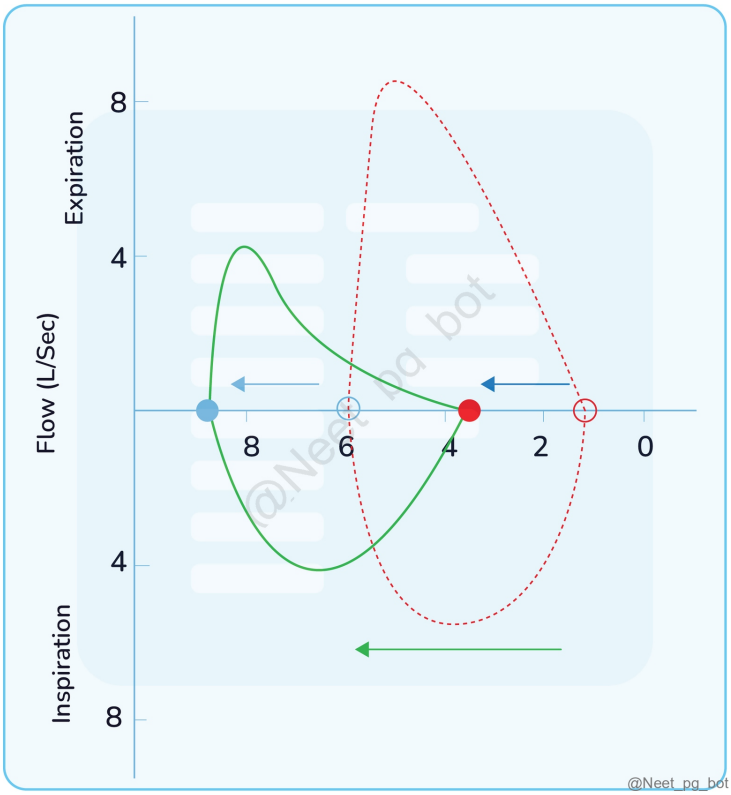

Correct Answer: D. Bronchiectasis

Explanation: The scooped-out pattern on expiration is a classic finding in obstructive diseases like bronchiectasis, which often presents in smokers with chronic symptoms like the patient. The types of flow-volume loops: Flow volume curve loop types and examples: Loop Type Expiratory Curve Inspiratory Curve Example Conditions Normal Symmetrical, peaked Symmetrical, rounded Healthy lungs Obstructive Scooped (concave) Normal COPD, asthma, bronchiectasis Restrictive Narrow, peaked Narrow, peaked Pulmonary fibrosis, pleural effusion, ARDS Fixed Upper Airway Obstruction Flattened (box-like) Flattened (box-like) Tracheal stenosis, a large goiter Variable Extrathoracic Obstruction Normal Flattened Vocal cord dysfunction, laryngeal tumour Variable Intrathoracic Obstruction Flattened Normal Tracheomalacia, bronchogenic tumor Incorrect Options: Options A, B, and C are restrictive lung diseases, and the flow volume shifts to the right in restrictive lung diseases. In restrictive lung diseases, the lungs have decreased compliance, which limits their ability to expand fully during inhalation. As a result, lung volumes (decreased vital capacity) are smaller during each respiratory cycle.

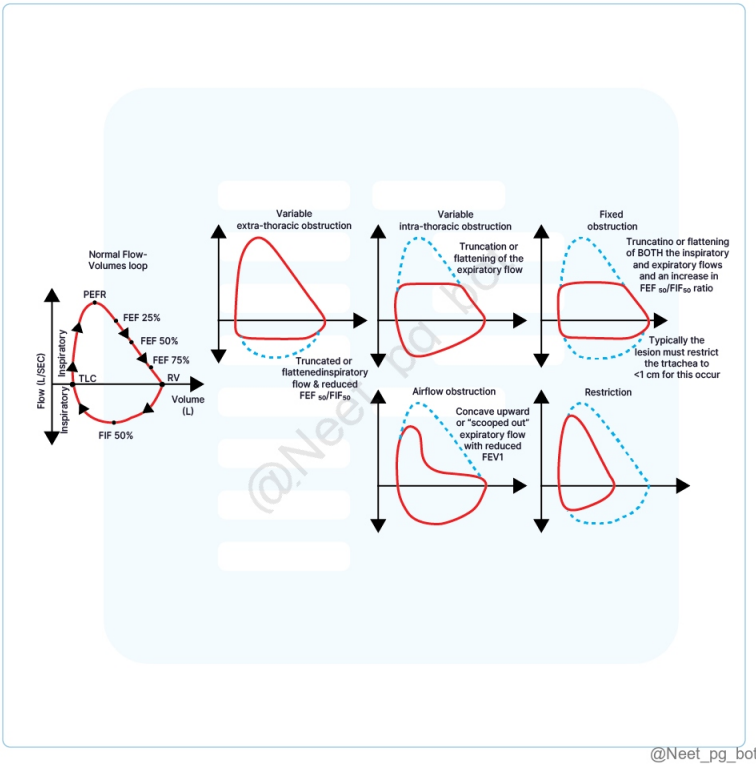

@Neet_pg_bot

References:

Harrison's Principles of Internal Medicine, 21st Edition, Pages: 2134 - 2138.

↑ *Back to this question in Part A*

@Neet_pg_bot

Q83: A male patient who is a known case of COPD presents to the emergency department with dyspnea. The arterial blood gas report is as follows: pH: 7.28 pCO 2 : 60 mmHg HCO 3 : 28 meq/L Which of the following is the most likely diagnosis? (Q854712)

A. Inadequately compensated respiratory acidosis

B. Fully compensated respiratory acidosis

C. Fully compensated respiratory alkalosis

D. Inadequately compensated metabolic alkalosis

Correct Answer: A. Inadequately compensated respiratory acidosis

Explanation: pH 7.28 is decreased, suggestive of acidosis, the pCO 2 = 60mmHg which is elevated, hence the acidosis is likely respiratory. The bicarbonate is 28 meq/L implying that compensation is partial (partial compensation/inadequate compensation) This is a case of inadequately compensated respiratory acidosis because: In acute respiratory acidosis, HCO 3 - will ↑ by 1 mEq/L for every 10 mmHg ↑ in pCO 2 In chronic respiratory acidosis, HCO 3 - will ↑ by 4 mEq/L for every 10 mmHg ↑ in pCO 2 In this patient, ABG shows: pH: 7.28 PaCO 2 : 60 mmHg HCO 3 -: 28 mEq/L Normal PaCO 2 : 38-42 mm Hg Thus, the difference in PaCO 2 = 60 - 42 = 18 mm Hg As this patient has COPD which is the most likely cause of respiratory acidosis in this patient, it is chronic respiratory acidosis We know for every 10 mmHg ↑ in PCO 2 , HCO 3 - should ↑ by 4 mEq/L For 1 mmHg ↑ in PCO 2 , HCO 3 - should ↑ by 4 / 10 mEq/L Thus for 18 mm Hg ↑ in PCO 2 , HCO 3 - should ↑ by 7.2 mEq/L In this patient HCO 3 - should be approx 33 mEq/L, but it is only 28 mEq/L, hence it is only partially compensated respiratory acidosis Incorrect Options: Fully compensated respiratory acidosis (Option B): If this was the condition, the HCO 3 - should have been approximately 33. Fully compensated respiratory alkalosis (Option C) is incorrect since the ABG in the given scenario is respiratory acidosis. Inadequately compensated metabolic alkalosis (Option D) is incorrect since the ABG in the given scenario is respiratory acidosis.

References:

Harrison’s Principles Of Internal Medicine, 21st Edition, Volume I, Page: 359, 360, 361, 367.

Respiratory Acidosis - StatPearls - NCBI Bookshelf

↑ *Back to this question in Part A*

@Neet_pg_bot

Q84: A 70-year-old diabetic man presents after a fall. He is having a high fever, cough and breathing difficulty and appears confused. CXR shows lobar consolidation. Labs show elevated BUN and creatinine. Which is the most appropriate management? (Q854678)

A. Inpatient management with levofloxacin

B. Inpatient management with ceftriaxone

C. Discharge home on Amoxicillin with Clavulanic acid

D. Discharge home on Azithromycin

Correct Answer: A. Inpatient management with levofloxacin

Explanation: The scenario here is of a patient with severe pneumonia with a CURB-65 score of 3 and a comorbidity (diabetes). Hence the modality of treatment would be inpatient management with levofloxacin (respiratory fluoroquinolones). Status Regimen No comorbidities or risk factors for antibiotic resistance Combination therapy with Amoxicillin + either Macrolide or Doxycycline OR Monotherapy with Doxycycline OR Monotherapy with a Macrolide With comorbidities ± Risk factors for antibiotic resistance Combination therapy with: Amoxicillin /clavulanate or a Cephalosporin + Macrolide or Doxycycline OR Monotherapy with respiratory

fluoroquinolone (levofloxacin) Inpatient management with Ceftriaxone (Option B) alone is not enough and will need a combination of Macrolide or Doxycycline with it. Discharge home with Amoxicillin and Clavulanic acid (Option C) is not a choice for severe pneumonia as given in this scenario. Discharge home on Azithromycin (Option D) alone is not enough and needs a combination of Amoxicillin /Clavulanate (or Cephalosporins) with it. This is not suitable for severe cases.

References:

Harrison's Principles of Internal Medicine, 21st Edition, Page: 1014.

↑ *Back to this question in Part A*

@Neet_pg_bot

Q85: A 30-year-old man came with complaints of fever and cough for 3 days. On examination, creatinine is 1.5 and BUN is 45. Chest-x ray shows infiltrates in the right lung and patchy infiltrates in the left lung. A nasopharyngeal swab shows only Rhinovirus. The patient is shifted to the ICU. Which antibiotics are suitable for this patient? (Q854657)

A. Amoxicillin + Clavulanic acid

B. Azithromycin

C. Ceftriaxone + Azithromycin

D. Piptaz + Ciprofloxacin

Correct Answer: C. Ceftriaxone + Azithromycin

Explanation: The scenario here is severe pneumonia signified by admission to the ICU; hence, the best treatment modality is beta-lactam + macrolide, i.e., Ceftriaxone + Azithromycin . Treatment for Lobar Pneumonia Treatment depends on severity ; assess if inpatient or outpatient management is needed. CURB-65 Score: Used to stratify patients with the following factors: CURB-65 Symptom Score (C) Confusion 1 (U) Urea: BUN >19mg/dL (>7 mmol/L) 1 (R) Respiratory rate ≥30/min 1 (B) Blood Pressure - Systolic BP ≤90 mmHg or diastolic BP ≤60 mmHg 1 (65) Age ≥65 years 1 Hospitalisation Criteria: CURB-65 score 0: Outpatient treatment Score 1 or 2: Indicates hospitalization Score ≥3: Indicates ICU admission and more intensive therapy. Empiric Therapy: Outpatient: No comorbidities: Monotherapy with macrolides (Azithromycin, Clarithromycin). With comorbidities (chronic lung/heart disease, diabetes, smoking, HIV): Newer fluoroquinolones (Levofloxacin, Moxifloxacin, Gemifloxacin) or a combination of beta-lactam (e.g., amoxicillin) and a macrolide. Inpatient Non-ICU: Newer fluoroquinolones (Levofloxacin, Moxifloxacin) alone or a combination of beta-lactam (e.g., Ampicillin, Ceftriaxone) and a macrolide. Inpatient ICU: Combination of macrolide (Azithromycin) with beta-lactam (e.g., Ampicillin-sulbactam, Ertapenem, Cephalosporins) or a newer fluoroquinolone (Levofloxacin). If risk of aspiration, consider Ampicillin-sulbactam or Ertapenem; for Pseudomonas infection, use anti-pseudomonal beta-lactam (e.g., Piperacillin-Tazobactam) with anti-pseudomonal fluoroquinolone (e.g., Ciprofloxacin). For

MRSA, add Vancomycin or Linezolid. Duration of Therapy: Typically 5 to 7 days, extended if clinical response is delayed. Influenza Treatment: All hospitalized patients testing positive for influenza should receive Oseltamivir, regardless of illness onset. Incorrect Options: Amoxicillin with clavulinic acid (Option A) : Inadequate for this patient due to the severity of his illness and the risk of resistant organisms. Monotherapy with amoxicillin does not provide sufficient coverage for his condition, especially considering the possibility of Pseudomonas and MRSA. Azithromycin (Option B) : Not appropriate for this patient due to the severity of his condition, indicating he requires more intensive treatment. Azithromycin is preferred for outpatient therapy, suitable for lower-risk patients without significant comorbidities. Piptaz + Ciprofloxacin (Option D) : Piptaz (Piperacillin/Tazobactam) is a combination which is a beta lactam antibiotic. Ciprofloxacin is a fluoroquinolone antibiotic. However, as mentioned above this is not suitable for the condition of the patient here as a macrolide is necessary along with a Fluoroquinolone or a beta-lactam to treat severe pneumonia.

References:

Harrison’s Principles of Internal Medicine, 21st Edition, Page: 1012.

Typical Bacterial Pneumonia - StatPearls - NCBI Bookshelf

↑ *Back to this question in Part A*

@Neet_pg_bot

Q86: In patients affected by COVID-19, which of the following patterns is frequently observed in chest CT scans? (Q856993)

A. Interlobular septal thickening

B. Air bronchograms

C. Ground glass opacity

D. Crazy paving pattern

Correct Answer: C. Ground glass opacity

Explanation: Ground Glass Opacities (GGO) towards the periphery are the earliest manifestation in COVID 19. Crazy pavement pattern and reverse halo sign is also noticed. GGOs are hazy areas with slightly increased density without obscuration of underlying bronchial and vascular margins. CT Findings in Covid 19: {{caption_text}} Common Findings: Ground-glass opacities (GGO) , consolidation, and reticulations. Characteristic Patterns : Bilateral peripheral and lower lobe predominance; features may resemble organizing pneumonia. A reversed halo sign, halo sign , reticulations, and nodules are uncommon and usually appear later. Other atypical findings can include cavitation, isolated lobar or segmental consolidation, lymphadenopathy, pneumothorax, pneumomediastinum, and pleural effusions. Chest X-ray (CXR) Findings: {{caption_text}} Bilateral peripheral and basal multifocal airspace opacities (ground-glass opacities (GGO) and consolidation) Imaging and Assessment: CO-RADS assesses the level of suspicion for pulmonary involvement of COVID-19 based on unenhanced chest CT findings. The level of suspicion increases from very low (CO-RADS category 1) to very

high (CO-RADS category 5) CO-RADS Suspicion Level CT findings CO-RADS 0 Technically inadequate CO-RADS 1 No Normal or non-infectious abnormalities CO-RADS 2 Low Abnormalities consistent with infections other than Covid-19 CO-RADS 3 Indeterminate Unclear whether covid-19 is present CO-RADS 4 High Abnormalities suspicious for covid-19 CO-RADS 5 Very high Typical covid-19 CO-RADS 6 PCR+ Diagnosis : Confirmed through positive reverse transcription-polymerase chain reaction (RT-PCR) Interlobular septal thickening (Option A) and Crazy paving pattern (Option D) is seen in pulmonary alveolar proteinosis

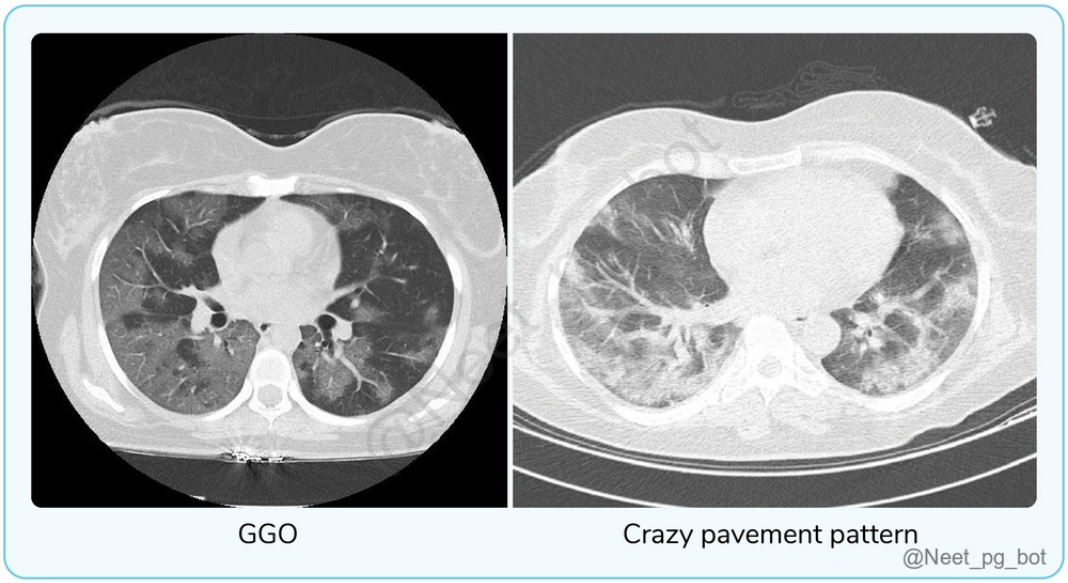

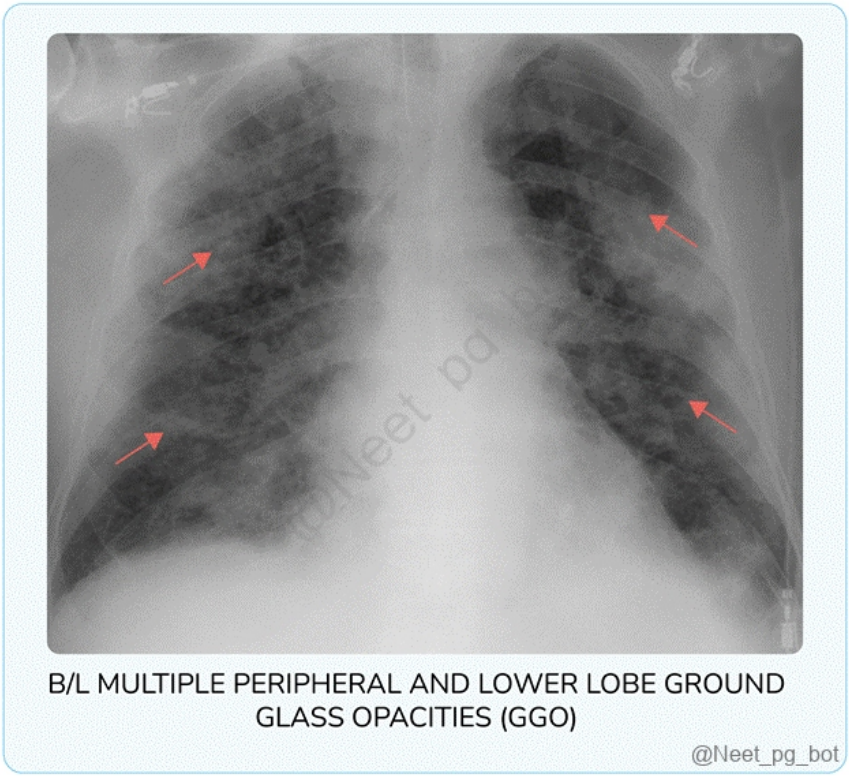

References:

Harrison’s Principles of Internal Medicine, 21st edition, Page 2169

Davidson’s Principles and Practice of Medicine, 24th edition, Page 613

David Sutton Textbook of Radiology & Imaging, 8th edition, Volume 1, Page 994, 996

https://pubs.rsna.org/doi/full/10.1148/radiol.2020201473

↑ *Back to this question in Part A*

@Neet_pg_bot

Q87: A male patient with a history of chronic smoking presents with the complaint of dysphagia . Out of the following, which type of lung cancer is most likely to be found in this patient? (Q793827)

A. Squamous cell carcinoma

B. Adenocarcinoma

C. Large cell carcinoma

D. Bronchogenic carcinoma

Correct Answer: A. Squamous cell carcinoma

Explanation: Correct Option A - Squamous cell carcinoma: Dysphagia can be caused by various conditions, including cancer of the esophagus or lung. However, lung cancer is more commonly associated with dysphagia when it involves the upper part of the lung or the lymph nodes around the trachea, which can press on the esophagus and interfere with swallowing. Given that the patient in question has a history of chronic smoking, squamous cell carcinoma is the most likely type of lung cancer to be found. This is because squamous cell carcinoma is strongly associated with smoking and tends to develop in the central part of the lung, near the bronchus. Incorrect Options: Options B, C and D are incorrect.

References:

Prepladder Notes

↑ *Back to this question in Part A*

@Neet_pg_bot

Q88: What is the diagnosis based on the image given below ? (Q793956)

A. Pulmonary tuberculosis

B. Chronic obstructive pulmonary disease

C. Bronchial asthma

D. Bronchiectasis



Correct Answer: D. Bronchiectasis

Explanation: Correct Option D - Bronchiectasis: Bronchiectasis is a condition characterized by permanent and abnormal dilatation of the bronchi and bronchioles, which results in impaired airway clearance and chronic infections. Imaging studies can confirm the diagnosis of bronchiectasis. The above CT shows Dilated bronchi with thick walls, Clustered cystic spaces, and Lack of normal bronchial tapering The CT findings in bronchiectasis may include: Bronchial dilatation: The most important finding in bronchiectasis is bronchial dilatation, which may be cylindrical or varicose in shape. The dilatation may be segmental or involve entire lobes or lung segments. Thickening of bronchial walls. Mucus plugging: Mucus accumulation in the bronchi can lead to obstruction and recurrent infections. CT may show the presence of bronchial secretions or mucus plugging. Atelectasis: Due to chronic inflammation and obstruction, there may be areas of atelectasis or collapse of lung tissue. Ground-glass opacities: These are areas of hazy increased attenuation on CT, often due to inflammation or edema. Air trapping: Bronchiectasis can lead to impaired airway clearance and air trapping, which may be seen as hyperinflation of the lungs. Bronchial wall irregularity: In severe cases of bronchiectasis, the bronchial walls may appear irregular and nodular, with loss of normal architecture. Incorrect Options: Options A, B and C are incorrect.

References:

Prepladder Notes

↑ *Back to this question in Part A*

@Neet_pg_bot

Q89: A young man presents with a sudden onset of severe headache, dizziness, breathlessness, and blurring of vision while trekking on a mountain at an altitude of 5000 meters . He is unable to climb any further. Which of the following develops at high-altitude? (Q793881)

A. Metabolic alkalosis

B. Respiratory alkalosis

C. Respiratory acidosis

D. Metabolic acidosis

Correct Answer: B. Respiratory alkalosis

Explanation: Correct Option B - Respiratory alkalosis: In respiratory alkalosis, there is carbon dioxide washout, which causes hyperventilation and decreases hydrogen ions. To compensate for this, bicarbonate loss occurs from the kidney. Causes of respiratory alkalosis CNS- Pain, anxiety, hysteria, fever, CVA CHF, pulmonary edema High altitude pulmonary edema Pulmonary embolism Flail chest Sepsis, heat exposure Incorrect Options: Option A - Metabolic alkalosis- Metabolic alkalosis is caused by vomitting, diarrhea, drugs like diuretics. Option C - Respiratory acidosis - Respiratory acidosis is caused by CVA, Asthama, ARDS, COPD exacerbation, Barotrauma. Option D - Metabolic acidosis- Metabolic acidosis is caused by Ketoacidosis, Uremia, Lactic acidosis, toxins

References:

Prepladder Notes

↑ *Back to this question in Part A*

@Neet_pg_bot

Q90: A patient presents with chronic complaints of a productive cough in the morning . The expectoration is yellow, foul smelling and increases on turning from left to right side. Which of the following lung diseases is likely to be present ? (Q793834)

A. Lung cancer

B. Bronchiectasis

C. Bronchial asthma

D. Pulmonary embolism

Correct Answer: B. Bronchiectasis

Explanation: Correct Option B - Bronchiectasis: Bronchiectasis is a chronic respiratory condition characterized by permanent dilation and thickening of the bronchial walls, leading to impaired airway mucus clearance. This can result in persistent coughing, often accompanied by sputum production, which can worsen on changing body position. Here, the cough increases on turning from left to right side, known as the "dependent lung" phenomenon. This occurs because when the patient turns onto the affected side, the mucus collects in the dependent part of the lung and triggers a cough. Incorrect Options: Options A, C and D are incorrect.

References:

Prepladder Notes

↑ *Back to this question in Part A*

@Neet_pg_bot

Q91: Kartagener syndrome is associated with defects in which of the following structures? (Q820676)

A. Microvilli

B. Microtubules

C. Cilia

D. Microfilaments

Correct Answer: C. Cilia

Explanation: .

References:

Prepladder Notes

↑ *Back to this question in Part A*

@Neet_pg_bot

• [11_Infections] 085 Puo Dengue Nipah Zika And Pneumocystis Jirovecii

« Back to Folder Directory

[11_Infections] 085 Puo Dengue Nipah Zika And Pneumocystis Jirovecii — Quick Jump

Q1 (p. 3134)	*Q2 (p. 3134)*	*Q3 (p. 3135)*	*Q4 (p. 3136)*	*Q5 (p. 3137)*	*Q6 (p. 3138)*
Q7 (p. 3138)	*Q8 (p. 3139)*	*Q9 (p. 3140)*	*Q10 (p. 3141)*	*Q11 (p. 3141)*	*Q12 (p. 3142)*
Q13 (p. 3143)	*Q14 (p. 3143)*	*Q15 (p. 3144)*			

Q1: Relative bradycardia is seen in which of the following infections? (Q850949)

A. Brucellosis

B. Influenza

C. Streptococcal Pharyngitis

D. Tuberculosis

Correct Answer: A. Brucellosis

■ *Listen (English)*

■ *Listen (Hindi)*

Explanation: Relative bradycardia is where a person's pulse rate is lower than expected for their body temperature. Causes include Exotoxin mediated vagal stimulation Cytokines liberated like in COVID 19 that may reset the hypothalamic thermoregulatory center and affect autonomic balance, leading to blunted tachycardic response Subclinical myocarditis Causes of Relative Bradycardia in Infectious Diseases : mnemonic: BE CAREFUL -These Little Cold Epidemics Brucellosis Infection with Brucella melitensis leads to relative bradycardia due to inflammatory cytokines and increased vagal tone, despite high fever. COVID-19 Patients may exhibit relative bradycardia associated with myocardial injury and systemic inflammation, showing insufficient heart rate increase despite high fever and hypoxemia. Typhoid Fever Legionnaire's Diseasse Chlamydial Pneumonia Ebola Hemorrhagic Fever

References:

https://pmc.ncbi.nlm.nih.gov/articles/PMC9767972/

↑ *Back to this question in Part A*

@Neet_pg_bot

Q2: A 28-year-old male presents with a history of fever, malaise, and abdominal discomfort for last one week. Physical examination reveals coated tongue, relative bradycardia and a hepatomegaly. NS-1 antigen is negative. What is the most likely fever pattern seen in this case? (Q850950)

A. Intermittent fever

B. Remittent fever

C. Saddle back fever

D. Sustained fever

Correct Answer: D. Sustained fever

■ *Listen (English)*

■ *Listen (Hindi)*

Explanation: Sustained fever is characterized by a continuous elevated temperature that does not fluctuate significantly. It is commonly seen in typhoid fever, where the fever progressively rises in a stepwise manner in intial phase and then shows sustained fever Features of Sustained or continuous fever 1. Temperature remains above normal throughout the day 2. Fluctuations do not exceed 1°C (or 1.5°F) 3. No return to baseline at any point during the day Intermittent fever (Option A) is seen in malaria where it returns to normal between the spikes. Remittent fever (Option B) is where it fluctuates > 1 C but never comes back to normal like in infective endocarditis. Saddle back (Option C) fever is seen in Dengue fever.

References:

https://www.ncbi.nlm.nih.gov/books/NBK324/

↑ *Back to this question in Part A*

@Neet_pg_bot

Q3: Quotidian fever is seen with which of the following species of Plasmodium? (Q850951)

A. Falciparum

B. Malariae

C. Ovale

D. Vivax

Correct Answer: A. Falciparum

■ *Listen (English)*

■ *Listen (Hindi)*

Explanation: Quotidian fever refers to a fever pattern that occurs daily (i.e., every 24 hours), returning to baseline each day. It is typically associated with infections such as Plasmodium knowlesi malaria, early P. falciparum infection, and systemic juvenile idiopathic arthritis (Still's disease). Malaria fever patterns Type of Fever Characteristics Examples Quotidian Fever Fever occurs once every day, and it will touch the baseline. P. falciparum, P. knowlesi Tertian Fever Fever is occurring every 48 hours. P. vivax, P. ovale Quartan Fever Fever will occur after every 72 hours. P. malariae

References:

www.ncbi.nlm.nih.gov/books/NBK8584/

↑ *Back to this question in Part A*

@Neet_pg_bot

Q4: A 55-year-old male presents with a fever of 38.5°C (101.3°F) that has persisted for three weeks. He reports significant weight loss, night sweats, and fatigue. His medical history is unremarkable. On physical examination, he has splenomegaly and cervical lymphadenopathy. Which investigation would be the most appropriate next step in this patient's management? (Q850952)

A. Chest X-ray

B. Blood culture

C. CT scan of the abdomen and pelvis

D. HIV test

Correct Answer: C. CT scan of the abdomen and pelvis

■ *Listen (English)*

■ *Listen (Hindi)*

Explanation: Given the patient's symptoms of prolonged fever, significant weight loss, night sweats, splenomegaly, and lymphadenopathy, a CT scan can help identify potential underlying causes such as infections, malignancies (e.g., lymphomas), or abscesses. It provides a comprehensive view of the abdominal organs and lymphatic structures. Chest X-ray (Option A): Limited to evaluating respiratory causes and may miss abdominal pathologies. Blood cultures (Option B) are important for detecting infections but may not identify structural causes of the patient's symptoms. HIV test (Option D): Relevant for considering infectious etiologies but does not provide immediate insights into potential underlying structural abnormalities.

References:

Harrison’s Principles of Internal Medicine, 22nd Edition, Page 152.

↑ *Back to this question in Part A*

@Neet_pg_bot

Q5: Which of the following is not considered an autoinflammatory syndrome? (Q850953)

A. Familial Mediterranean fever

B. Adult-onset Still's disease

C. Rheumatoid arthritis

D. Cryopyrin-associated periodic syndromes

Correct Answer: C. Rheumatoid arthritis

■ *Listen (English)*

■ *Listen (Hindi)*

Explanation: Autoinflammatory disorders means dysregulation of innate immunity (no autoantibodies) Autoimmune disorders implies dysregulation of adaptive immunity (presence of T-cells, B-cells, autoantibodies) Rheumatoid arthritis is classified as an autoimmune disease and RA factor and anti -CCP antibody that causes erosive arthritis. Familial Mediterranean fever , Adult-onset Still’s disease , and Cryopyrin-associated periodic syndromes , are recognized as autoinflammatory syndromes. (Option A, B, and D) Non-infectious Inflammatory Disorder Category Examples Systemic Rheumatic and Autoimmune Diseases Ankylosing spondylitis Behçet's disease Mixed connective-tissue disease Rheumatoid arthritis Sjögren's syndrome SLE Vogt-Koyanagi-Harada syndrome(VKH Syndrome) Vasculitis Allergic vasculitis Eosinophilic granulomatosis with polyangiitis Giant cell vasculitis/polymyalgia rheumatica Granulomatosis with polyangiitis Kawasaki disease Polyarteritis nodosa Takayasu arteritis Granulomatous Diseases Idiopathic granulomatous hepatitis, sarcoidosis Autoinflammatory Syndromes (Option A, B, and D ruled out) Adult-onset Still's disease CAPS (cryopyrin-associated periodic syndromes) Familial Mediterranean fever Hyper-IgD syndrome (HIDS, also known as mevalonate kinase deficiency) PAPA syndrome (pyogenic sterile arthritis, pyoderma gangrenosum, and acne) PFAPA syndrome (periodic fever, aphthous stomatitis, pharyngitis, adenitis) SAPHO (synovitis, acne, pustulosis, hyperostosis, osteomyelitis) TRAPS (tumor necrosis factor receptor-associated periodic syndrome)

References:

Harrison’s Principles of Internal Medicine, 22nd Edition, Page 2755.

https://pmc.ncbi.nlm.nih.gov/articles/PMC7610735/

↑ *Back to this question in Part A*

@Neet_pg_bot

Q6: A 30-year-old female presents with a fever of 39°C that has persisted for the past five days. She reports severe muscle pain, nausea, and retroorbital pain. On examination, she has mild dehydration and a negative tourniquet test. Which of the following investigations would be most appropriate to confirm the diagnosis? (Q850954)

A. Hematocrit

B. NS-1 Antigen test

C. MAC ELISA for Dengue virus antibody

D. Platelet count

Correct Answer: C. MAC ELISA for Dengue virus antibody

■ *Listen (English)*

■ *Listen (Hindi)*

Explanation: In febrile phase of dengue (day 1-3) NS1 has high sensitivity. (Option B) In critical phase Day 4 - 6, NS-1 antigen begins to decline and IgM starts rising. After day 7 (recovery phase) IgM and IgG antibody is detected. Our case is for day 5 where Antibody detection would be best suited for confirmation of diagnosis. Hematocrit (Option A) is done to evaluate for Dengue shock syndrome and is best prognostic test for dengue. Platelet count (Option D) will deplete in DHF.

References:

Harrison's Principles of internal medicine, 22nd Edition, Page 1668.
https://www.ncbi.nlm.nih.gov/books/NBK430732/

↑ *Back to this question in Part A*

@Neet_pg_bot

Q7: What is the most common neurological complication during the course of dengue fever illness? (Q850955)

A. Encephalopathy

B. Guillain-Barré Syndrome

C. Stroke

D. Encephalitis

Correct Answer: A. Encephalopathy

■ *Listen (English)*

■ *Listen (Hindi)*

Explanation: Encephalopathy is the most common neurological complication during course of dengue fever. It can be due to brain underperfusion due to shock or bleeeding or multi organ dysfunction. Dengue complications Neurological Dengue encephalopathy is most commonly encountered neurological complication of dengue virus linked primarily to dengue hemorrhagic fever and dengue shock syndrome EEG may show abnormalities such as burst suppression and seizures CSF profiles typically remain normal. Neuroimaging can be normal or reveal diffuse cerebral edema. Cardiomyopathy Dengue virus-induced dilated cardiomyopathy should always be considered if a dengue fever patient has refractory shock and signs and symptoms of congestive heart failure. Hepatic injury Liver involvement in dengue is a crucial feature The effect ranges from an asymptomatic rise in liver enzymes to the development of ALF The most common atypical manifestation reported was hepatitis Pneumonia Staphylococcus pneumonia is an important accompanying problem seen in dengue patient co-infection between dengue and influenza can result in exacerbation of pneumonia Orchitis Orchitis usually occurs together with epididymitis Commonly seen in men between 14 and 35 years of age.

References:

Harrison's Principles of internal medicine, 22nd Edition, Page 1665.
https://pmc.ncbi.nlm.nih.gov/articles/PMC8813012/

↑ *Back to this question in Part A*

@Neet_pg_bot

Q8: A 30-year-old farmer presents with high-grade fever, retro-orbital pain, and severe calf muscle tenderness for the past 3 days. What is the most likely diagnosis? (Q850956)

A. Dengue fever

B. Leptospirosis

C. Zika virus

D. Typhoid / Enteric fever

Correct Answer: B. Leptospirosis

■ *Listen (English)*

■ *Listen (Hindi)*

Explanation: Leptospirosis is classically associated with fever + retro-orbital pain + intense myalgia , especially in the calves and lower back . Often occurs after exposure to contaminated water or animals (e.g., farmers, sewage workers). Dengue (Option A) also presents with retro-orbital pain and fever, but calf pain is not as prominent. Myalgia is generalized and accompanied by rash, thrombocytopenia, and hemoconcentration. Zika virus (Option C) presents with mild fever, rash, conjunctivitis, and joint pain — retro-orbital pain is rare, and severe calf pain is not a feature. Typhoid fever (Option D) causes step-ladder fever, abdominal symptoms, and relative bradycardia, but no retro-orbital pain or focal calf tenderness.

References:

Harrison's Principles of internal medicine, 22nd Edition, Page 1442.

↑ *Back to this question in Part A*

@Neet_pg_bot

Q9: Following a sudden outbreak of mystery fever in a South Indian village, several individuals from the same locality developed fever, headache, altered sensorium, and seizures. Which of the following is not true regarding this likely condition? (Q850957)

A. The disease has been linked to Pteropus species as natural reservoirs

B. The condition often presents as rapidly progressive viral encephalitis

C. Case fatality rate below 10%

D. Human-to-human transmission has been documented in prior outbreaks

Correct Answer: C. Case fatality rate below 10%

■ *Listen (English)*

■ *Listen (Hindi)*

Explanation: Clinical features point to Nipah virus which is a zoonotic paramyxovirus with outbreak potential and high public health concern. It is transmitted from Pteropus bats to humans, often via contaminated fruits or intermediate hosts. (Option A) It causes acute encephalitis (Option B) with high neurovirulence and rapid clinical decline and CFR touching 40 to 75%. It is present in body fluids like saliva and can be transmitted from person to person. (Option D)

References:

https://www.ncbi.nlm.nih.gov/books/NBK570576/

↑ *Back to this question in Part A*

@Neet_pg_bot

Q10: A 28-year-old woman presents with fever, conjunctivitis, and a maculopapular rash after returning from a trip to Central America. Local health authorities comfirm antibodies to Zika virus infection. Which of the following is correct about this infection? (Q850958)

A. Transmitted only through infected bodily fluids.

B. Incubation period is 4 weeks

C. Complications include microcephaly and Guillain–Barré syndrome.

D. Reliable diagnosis via serology in the first week.

Correct Answer: C. Complications include microcephaly and Guillain–Barré syndrome.

■ *Listen (English)*

■ *Listen (Hindi)*

Explanation: Zika virus (ZIKV) infection can lead to serious complications such as congenital microcephaly in newborns and Guillain–Barré syndrome in adults. Transmission: (Option A ruled out) Spread by Aedes aegypti and Aedes albopictus mosquitoes (daytime feeders). Sexual transmission is possible. Incubation period: 3–12 days (Option B ruled out) Serology: Retrospective diagnosis; cross-reactivity with other flaviviruses (Option D ruled out)

References:

Harrison's Principles of internal medicine, 22nd Edition, Page 1668.

↑ *Back to this question in Part A*

@Neet_pg_bot

Q11: A 32-year-old male presents with progressive bilateral lower limb weakness over the past 10 days after recovery from zika virus infection. On examination, he has flaccid paralysis and absent deep tendon reflexes in the affected limbs. CSF analysis shows cytoalbuminological dissociation. NCV test confirms a demyelinating pattern. Which diagnostic criteria are used to diagnose this presentation? (Q850959)

A. Brighton

B. Macdonald

C. Hakim's

D. Adam and Victor

Correct Answer: A. Brighton

■ *Listen (English)*

■ *Listen (Hindi)*

Explanation: Post zika virus infection patient has developed bilateral flaccid weakness and absent deep tendon reflexes. CSF findings are albuminocytological dissociation (elevated protein with normal white cell count) and NCV has demyeliantion. All the highlighted text constitute Brighton criteria for diagnosis of gullian barre syndrome. Macdonald criteria (Option B) is for Multiple sclerosis Hakim's and Adam and Victor criterias (Option C and D) are for Normal pressure hydrocephalus.

References:

Harrison's Principles of internal medicine, 22nd Edition, Page 3621.

↑ *Back to this question in Part A*

@Neet_pg_bot

Q12: A 40-year-old HIV-positive patient presents with fever, dry cough, and progressive shortness of breath. His CD4+ count is 150 cells/mm³. Chest X-ray shows bilateral interstitial infiltrates. Which of the following is the most likely mechanism of infection in this patient? (Q850960)

A. Primary infection acquired from a contaminated water source

B. Airborne transmission from an infected individual

C. Ingestion of fungal spores from environmental reservoirs

D. Reactivation of a previously dormant infection acquired during childhood

Correct Answer: B. Airborne transmission from an infected individual

■ *Listen (English)*

■ *Listen (Hindi)*

Explanation: This patient with HIV and a low CD4+ count (150 cells/mm³), fever, dry cough, and bilateral interstitial infiltrates on chest X-ray likely has Pneumocystis jirovecii pneumonia . PJP is a common opportunistic infection in immunocompromised individuals and iit s primarily transmitted via airborne spread from person to person. The organism is inhaled, leading to infection in the lungs, especially when immune defenses are weakened. Primary infection acquired from a contaminated water source (Option A): Pneumocystis jirovecii is not transmitted through water sources. Ingestion of fungal spores from environmental reservoirs (Option C) : There is no evidence suggesting transmission through ingestion of spores. Reactivation of a previously dormant infection

acquired during childhood (Option D) : Partially correct but not the best answer. Although reactivation can occur, the question hints at new infection rather than reactivation.

References:

Harrison's Principles of internal medicine, 22nd Edition, Page 1731.

↑ *Back to this question in Part A*

@Neet_pg_bot

Q13: A 45-year-old male with HIV presents with low-grade fever, nonproductive cough, and progressive shortness of breath over the past month. His HRCT shows bilateral ground-glass opacities. Which of the following is not correct about the suspected oppurtunisitic infection? (Q850961)

A. Increased Alveolar arteriolar gradient

B. Use of steroids during treatment of this oppurtunistic infection

C. Crushed ping pong ball appearance on Gomori methamine stain

D. Cultured on Sabaroud dextrose agar

Correct Answer: D. Cultured on Sabaroud dextrose agar

■ *Listen (English)*

■ *Listen (Hindi)*

Explanation: Pneumocystis jirovecii cannot be cultured using conventional laboratory culture methods. Hence Beta 1,3 D glucan, BAL staining with Gomori-methamine stain where the cyst wall is stained black. Due to intersttial pneumonia, Alveolar gradient is increased. During treatment cotrimoaxazole is used. But during treatment the release of inflammatory cytokines can lead to ARDS. Hence steroids are co-administered if PaO■ < 70 mmHg or A–a gradient > 35 mmHg.

References:

Harrison's Principles of Internal Medicine, 22nd Edition, Page 1731, 1732.

↑ *Back to this question in Part A*

@Neet_pg_bot

Q14: Which of the following diagnostic methods provides the highest sensitivity for confirming the presence of Pneumocystis jirovecii ? (Q850962)

A. Induced sputum and staining with gomori methamine stain

B. Sputum immunofluuroscence

C. Polymerase Chain Reaction

D. β-D-glucan assay

Correct Answer: C. Polymerase Chain Reaction

■ *Listen (English)*

■ *Listen (Hindi)*

Explanation: PCR of BAL fluid is the most sensitive test for diagnosing Pneumocystis jirovecii , especially when direct microscopy is negative. It has sensitivity rates up to 96%. IF study is highly specific but less sensitive Sequence is PCR> IF > Gomori methamine staining

Criteria	PCR	Immunofluorescence (IF)
Sensitivity	Very High	Moderate to High
Specificity	High (can pick colonization)	Very High (detects active infection)
Turnaround time	Short (hours)	Short
Usefulness in low fungal load (non-HIV)	Excellent	Limited

@Neet_pg_bot

References:

Harrison's Principles of Internal Medicine, 22nd Edition, Page 1732.

↑ *Back to this question in Part A*

@Neet_pg_bot

Q15: A 35 year old truck driver with AIDS is having CD4 count of 150 cells/ cu.mm. He has sulfa drug allergy. Which of the following drugs can be used in this patient by nebulization route for prevention of this opportunisticinfection? (Q850963)

A. Pentamidine

B. Trimethoprim and Sulfamethoxazole

C. Atovaquone

D. Clindamycin with Primaquine

Correct Answer: A. Pentamidine

■ *Listen (English)*

■ *Listen (Hindi)*

Explanation: Nebulized (aerosolized) Pentamidine is used for PCP prophylaxis in patients who: have sulfa allergy , or cannot tolerate Trimethoprim/Sulfamethoxazole (TMP-SMX). Treatment of Pneumocystis Jiroveci Treatment Administration Indication Pentamidine IV: 4 mg/kg/day For patients intolerant to TMP/SMX Atovaquone Oral: 750 mg twice daily Effective for mild to moderate PCP, fewer side effects Clindamycin + Primaquine Combination therapy For patients failing TMP/SMX or pentamidine Dapsone Alone or with TMP For prophylaxis and treatment in select cases Caspofungin Combination with low-dose TMP/SMX For severe cases Adjunctive Therapy like Corticosteroids: Recommended for moderate to severe PCP, especially with low oxygen levels (PaO2 < 70 mm Hg or oxygen saturation < 92%) .

References:

Harrison's Principles of Internal Medicine, 22nd Edition, Page 1734.

↑ *Back to this question in Part A*

@Neet_pg_bot

• [11_Infections] 086 Aspergillosis Aids And Covid-19

« Back to Folder Directory

[11_Infections] 086 Aspergillosis Aids And Covid-19 — Quick Jump

Q1 (p. 3146)	*Q2 (p. 3147)*	*Q3 (p. 3148)*	*Q4 (p. 3148)*	*Q5 (p. 3149)*	*Q6 (p. 3150)*
Q7 (p. 3151)	*Q8 (p. 3152)*	*Q9 (p. 3153)*	*Q10 (p. 3153)*	*Q11 (p. 3154)*	*Q12 (p. 3155)*
Q13 (p. 3156)	*Q14 (p. 3157)*	*Q15 (p. 3158)*	*Q16 (p. 3159)*	*Q17 (p. 3159)*	*Q18 (p. 3160)*
Q19 (p. 3161)	*Q20 (p. 3162)*	*Q21 (p. 3163)*			

Q1: A 42-year-old HIV-positive male with a history of disseminated Mycobacterium avium complex (MAC) infection presents for a routine check-up. He is compliant with antiretroviral therapy (ART) and has a CD4+ count of 46 cells/μL. Which prophylactic therapy is recommended in this patient to prevent Mycobacterium avium complex? (Q850974)

A. Monotherapy with azithromycin

B. Trimethoprim-sulfamethoxazole

C. Clarithromycin + ethambutol

D. Isoniazid + pyridoxine

Correct Answer: C. Clarithromycin + ethambutol

■ *Listen (English)*

■ *Listen (Hindi)*

Explanation: This patient has a history of disseminated MAC, so he requires secondary prophylaxis (maintenance therapy). Standard regimen = macrolide (clarithromycin/azithromycin) + ethambutol. Prevents relapse of MAC and is continued until CD4 >100 for ≥3 months on ART. Azithromycin monotherapy (Option A): Used for primary prophylaxis when CD4 <50 without prior MAC. Not adequate after previous infection → risk of relapse Trimethoprim-sulfamethoxazole (Option B): Used for PCP and toxoplasmosis prophylaxis, not MAC Isoniazid + pyridoxine (Option D): Used for latent tuberculosis prophylaxis , no role in MAC prevention.

References:

Harrison’s Principles of Internal Medicine, 22nd Edition, Page 1597.

↑ *Back to this question in Part A*

@Neet_pg_bot

Q2: An HIV positive patient presented with a whitish plaque in the mouth and esophagus as shown in the image below. Most likely diagnosis is: (Q882169)

A. Oral leukoplokia

B. Hairy cell leukemia

C. Oral candidiasis

D. Oral cancer



Correct Answer: C. Oral candidiasis

Explanation: Correct Option C - Oral candidiasis: Oral Candidiasis is the likely diagnosis in these patients. In patients with HIV, there is decrease in the number of T cells making them more susceptible to infections with such agents. Incorrect Options: Options A, B and D are incorrect.

References:

Prep Ladder notes

↑ *Back to this question in Part A*

@Neet_pg_bot

Q3: A 55-year-old man with triple vessel disease presents with a persistent cough, fever, and shortness of breath. On admission he has respiratory rate 26 /minute and an sp02 92% on room air. His RT-PCR for SARS-COV2 is positive. What is the preferred oxygen delivery device for this patient? (Q850983)

A. Non invasive ventilation with tight fitting face mask

B. Nasal cannula and flow rate of 6L/min

C. CPAP mask

D. Non-rebreathing face mask

Correct Answer: D. Non-rebreathing face mask

■ *Listen (English)*

■ *Listen (Hindi)*

Explanation: The patient has significant hypoxia with SpO■ 92% and underlying cardiac disease (triple vessel disease) . A non-rebreathing mask can deliver high-concentration oxygen (up to ~90% FiO■) and is preferred in this setting to rapidly correct hypoxemia. Nasal cannula and flow rate of 6L/min (Option B) provides low-flow oxygen, which may be insufficient for this patient. Non-invasive ventilation with tight-fitting face mask (Option A) is indicated for respiratory failure rather than moderate hypoxia. CPAP mask (Option C) is primarily used for acute hypoxemic or hypercapnic respiratory failure, not initial oxygen supplementation in moderate hypoxia.

References:

Harrison's Principles of Internal Medicine, 22nd Edition, Page 1542.

https://pmc.ncbi.nlm.nih.gov/articles/PMC7809683/

↑ *Back to this question in Part A*

@Neet_pg_bot

Q4: A 60-year-old woman with obesity and hypertension presents with a cough, fever and shortness of breath for the past four days. Her SpO2 is 90% on room air and her respiratory rate is 34/min. Her RT-PCR for SARS COV2 is positive. Which of the following is correct about laboratory findings seen in this case? (Q850982)

A. Reduced D-dimer

B. Reduced IL-6

C. Elevated platelet count

D. Elevated NLR

Correct Answer: D. Elevated NLR

■ *Listen (English)*

■ *Listen (Hindi)*

Explanation: The clinical presentation and positive RT-PCR result confirm the diagnosis of COVID-19, characterised by an elevated neutrophil-to-lymphocyte ratio (NLR). Laboratory findings of COVID-19: Elevated Parameters Inflammatory markers (interleukin 6, tumour necrosis factor α, ferritin, C-reactive protein) (Option B) NLR (neutrophil-to-lymphocyte ratio) >6 (Option D) Prothrombin time D-dimer assay (Option A) Pro-BNP and troponin I Liver enzymes and lactate dehydrogenase Creatine phosphokinase Reduced parameters Platelet count (thrombocytopenia) (Option C) TLC or Total lymphocyte count (lymphopenia) Erythrocyte count (anemia) Pulmonary function test

References:

Harrison's Principles of Internal Medicine, 22nd Edition, Page 1540, 1541.

https://pmc.ncbi.nlm.nih.gov/articles/PMC7809683/

↑ *Back to this question in Part A*

@Neet_pg_bot

Q5: A 55-year-old man with a history of asthma presents with a persistent cough, fever, and shortness of breath that started three days ago after attending a family gathering. His examination shows a SpO 2 of 92% on room air and a respiratory rate of 26 breaths per minute, with the accompanying X-ray. What is the investigation of choice for this condition? (Q850981)

A. HRCT chest

B. C-reactive protein

C. RT-PCR

D. Rapid antigen test

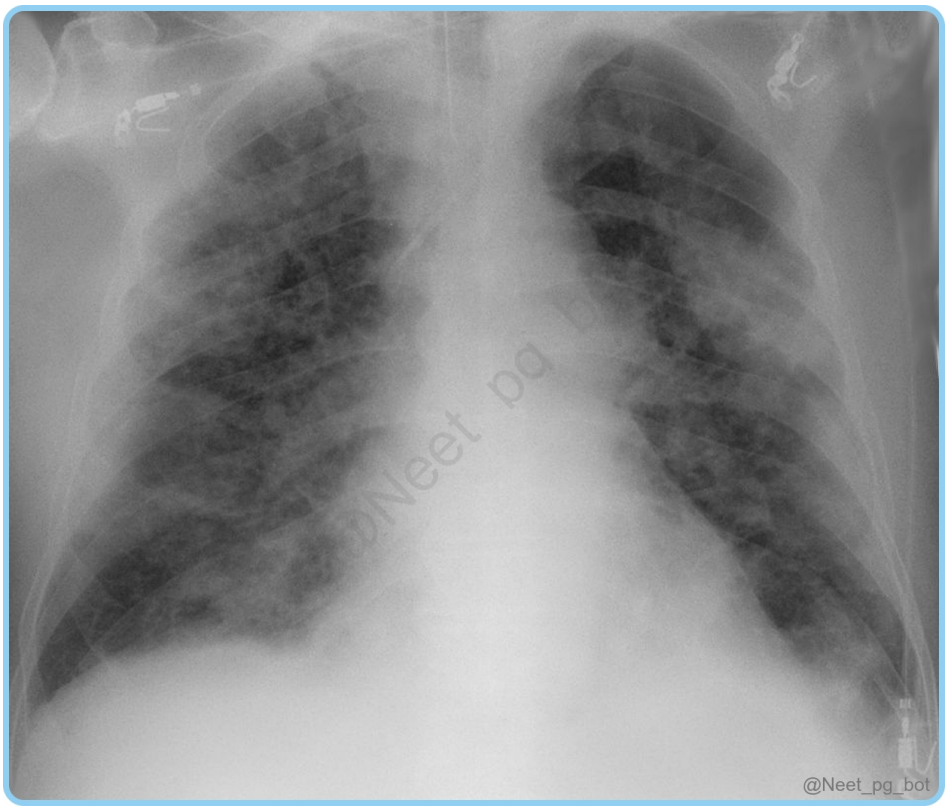

Correct Answer: C. RT-PCR

■ *Listen (English)*

■ *Listen (Hindi)*

Explanation: The patient's symptoms of persistent cough, fever, shortness of breath, and recent exposure to a family gathering raise suspicion of a viral respiratory infection, particularly COVID-19. The above x-ray shows bilateral, peripheral, non-lobar ground glass opacities (hazy, grey areas) RT-PCR (Reverse Transcription Polymerase Chain Reaction) is the standard method for confirming the diagnosis of COVID-19 due to its high sensitivity and specificity. HRCT chest (Option A) can show lung involvement but is not diagnostic. C-reactive protein (Option B) is a non-specific inflammatory marker and cannot confirm infection. Rapid antigen test (Option D) is less sensitive than RT-PCR, especially in early or mild disease.

References:

Harrison’s Principles of Internal Medicine, 22nd Edition, Page 1540, 1541.

↑ *Back to this question in Part A*

@Neet_pg_bot

Q6: A 35-year-old HIV-positive man with a CD4 count of 80 cells/mm³ presents with chronic watery diarrhea and significant weight loss. Stool examination reveals oval-shaped oocysts measuring 20–30 microns, which appear pink to red on modified

Kinyoun stain, showing a characteristic sporoblast. Which of the following is the best treatment? (Q850980)

A. Metronidazole

B. Nitazoxanide

C. TMP-SMX

D. Albendazole

Correct Answer: C. TMP-SMX

■ *Listen (English)*

■ *Listen (Hindi)*

Explanation: Cystoisospora belli is a coccidian parasite that causes prolonged, watery diarrhea in immunocompromised individuals, especially AIDS patients with CD4 < 100. Oocysts are large (20–30 microns), oval , and demonstrate acid-fast positivity (pink to red) on modified Kinyoun stain . TMP-SMX is the first-line treatment and also used for secondary prophylaxis. Metronidazole (Option A) is not effective against coccidia. Nitazoxanide (Option B) is used in Cryptosporidiosis, not preferred here. Albendazole (Option D) has no role against Cystoisospora.

References:

Harrison’s Principles of Internal Medicine, 22nd Edition, Page 1806.

↑ *Back to this question in Part A*

@Neet_pg_bot

Q7: A 36-year-old man with AIDS with CD4 count of 74 cells/μL presents with acute onset of odynophagia and retrosternal chest pain. Upper GI endoscopy reveals well-circumscribed, "volcano-like" ulcers in the mid-esophagus. Which of the following is the most likely diagnosis? (Q850979)

A. Cytomegalovirus esophagitis

B. Herpes simplex virus esophagitis

C. Candida esophagitis

D. ART induced esophagitis

Correct Answer: B. Herpes simplex virus esophagitis

■ *Listen (English)*

■ *Listen (Hindi)*

Explanation: Herpes simplex virus (HSV) esophagitis in immunocompromised patients presents with acute odynophagia, retrosternal pain, and well-circumscribed “volcano-like” ulcers , typically in the mid-to-distal esophagus . Cytomegalovirus esophagitis (Option A) usually causes linear or longitudinal ulcers, not discrete “volcano-like” lesions. Candida esophagitis (Option C) presents with white plaques and pseudomembranes, not well-circumscribed ulcers. ART-induced esophagitis (Option D) is rare and usually manifests as mild irritation or inflammation, not characteristic ulcers.

References:

Harrison’s Principles of Internal Medicine, 22nd Edition, Page 1500.

↑ *Back to this question in Part A*

@Neet_pg_bot

Q8: A medical intern sustains a needle-stick injury from a known HIV-positive patient. What is the ideal time frame to initiate post-exposure prophylaxis for maximum efficacy? (Q850978)

A. Within 2 hours

B. Within 24 hours

C. Within 48 hours

D. After 72 hours

Correct Answer: A. Within 2 hours

■ *Listen (English)*

■ *Listen (Hindi)*

Explanation: Post-exposure prophylaxis for HIV should be started as early as possible preferably within 2 hours. It is not effective after 72 hours. Drugs used are tenofovir, lamivudine and dolutregavir for 4 weeks. Waiting for test results or seroconversion is incorrect and delays treatment. Within 24 hours (Option B): Acceptable if <72 hrs, but not ideal; efficacy decreases as time passes. Within 48 hours (Option C): Still allowed, but significantly less effective than initiation within 2 hrs. After 72 hours (Option D): Not recommended; PEP is ineffective beyond this window.

References:

Harrison’s Principles of Internal Medicine, 22nd Edition, Page 1625.
https://naco.gov.in/sites/default/files/National_Technical_Guidelines_(Web).pdf

↑ *Back to this question in Part A*

@Neet_pg_bot

Q9: You have started fluconazole for secondary prevention of cryptococcus neoformans meningitis. Which of the following is correct statement about it? (Q850977)

A. Continue till CD4 count > 100 cells for one year and HIV RNA suppressed for >3 months

B. Continue till CD4 count > 200 cells for one year and HIV RNA suppressed for > 3 months

C. Continue till CD4 count < 200 cells for one year and HIV RNA suppressed for < 3 months

D. Continue till CD4 count > 200 cells and HIV RNA < 5000 copies/ ml

Correct Answer: A. Continue till CD4 count > 100 cells for one year and HIV RNA suppressed for >3 months

■ *Listen (English)*

■ *Listen (Hindi)*

Explanation: Fluconazole maintenance (secondary prophylaxis) in cryptococcal meningitis is continued until immune reconstitution with ART occurs. It can be safely stopped when CD4 count rises >100 cells/µL and remains so for ≥1 year , along with sustained viral suppression for ≥3 months . This indicates that the patient's immunity is strong enough to prevent relapse. Higher CD4 thresholds (like 200) are not required for cryptococcal infection.

References:

Harrison's Principles of Internal Medicine, 22nd Edition, Page 1706, 1607.

↑ *Back to this question in Part A*

@Neet_pg_bot

Q10: Which of the following drugs is effective against both HIV and hepatitis B? (Q850976)

A. Efavirenz

B. Tenofovir

C. Abacavir

D. Ritonavir

Correct Answer: B. Tenofovir

■ *Listen (English)*

■ *Listen (Hindi)*

Explanation: Tenofovir (in both its formulations, tenofovir disoproxil fumarate [TDF] or tenofovir alafenamide [TAF]) is effective against both HIV and HBV. HIV uses reverse transcriptase to convert its RNA into proviral DNA. Tenofovir inhibits this enzyme ➜ prevents integration into host genome ➜ stops replication. Efavirenz (Option A), Abacavir (Option C) , Ritonavir (Option D) is active against HIV only.

References:

Harrison's Principles of Internal Medicine, 22nd Edition, Page 1616.

↑ *Back to this question in Part A*

@Neet_pg_bot

Q11: A 38 -year-old man is newly diagnosed with HIV. He is asymptomatic with a CD4 count of 650 cells/mm³. Based on WHO recommendations, which of the following combinations would be best suited for treatment of this case? (Q850975)

A. Zidovudine + Lamivudine + Raltegravir

B. Abacavir + Lamivudine + Lopinavir

C. Tenofovir + Lamivudine + Efavirenz

D. Tenofovir + Lamivudine + Dolutegravir

Correct Answer: D. Tenofovir + Lamivudine + Dolutegravir

■ *Listen (English)*

■ *Listen (Hindi)*

Explanation: Tenofovir + Lamivudine + Dolutegravir is a recommended first-line regimen for the treatment of HIV. Drug classes: Tenofovir & Lamivudine → NRTIs Dolutegravir → INSTI Advantages: Fixed-dose combination simplifies therapy, reduces cost, and improves adherence Effective and well-tolerated in adults, adolescents, and HIV/TB co-infected patients Zidovudine + Lamivudine + Raltegravir (Option A) is the first line regimen for HIV-positive neonates as this combination has shown effectiveness in rapidly suppressing viral load in infants and neonates. Abacavir + Lamivudine + Lopinavir (Option B) is generally not used as the first-line therapy for HIV infection. Moreover, Abacavir requires HLA-B*5701 testing due to the risk of hypersensitivity reactions, which can be severe and potentially life-threatening. Tenofovir + Lamivudine + Efavirenz (Option C) was previously recommended as the first-line therapy for HIV. However, according to the 2018 recommendations, efavirenz was replaced by Dolutegravir.

References:

Harrison’s Principles of Internal Medicine, 22nd Edition, Page 1616.

↑ *Back to this question in Part A*

@Neet_pg_bot

Q12: A 55-year-old immunocompromised patient presents with fever, cough, and respiratory distress. CT chest is perfomed. Which of the following investigations would be most specific to confirm the diagnosis? (Q850930)

A. Lung histology shows fungal septate hyphae with branching at 45 degrees

B. BACTEC MGIT 960

C. Galactomannan antigen on sputum

D. Beta 1,3 D- glucan test



Correct Answer: C. Galactomannan antigen on sputum

■ *Listen (English)*

■ *Listen (Hindi)*

Explanation: HRCT chest in an immunocompromised patient shows an air crescent sign (right lung) and Halo sign (posterior segment of the left lower lobe, abutting the vertebral body) seen in Invasive pulmonary aspergillosis. Galactomannan antigen test on BAL is a sensitive and specific biomarker for diagnosing invasive aspergillosis. It detects a polysaccharide component of the Aspergillus cell wall that is released during active infection. Histopathology (Option A): Shows septate hyphae branching at 45°, but biopsy yield is low (10–30%) and often difficult in unstable patients. {{caption_text}} BACTEC MGIT 960 (Option B): ■■■■Designed for mycobacterial culture , not fungal infections. Beta-1,3-D-glucan (Option D): Positive in many fungal infections (Candida, Pneumocystis, Fusarium), so it lacks specificity for Aspergillus .

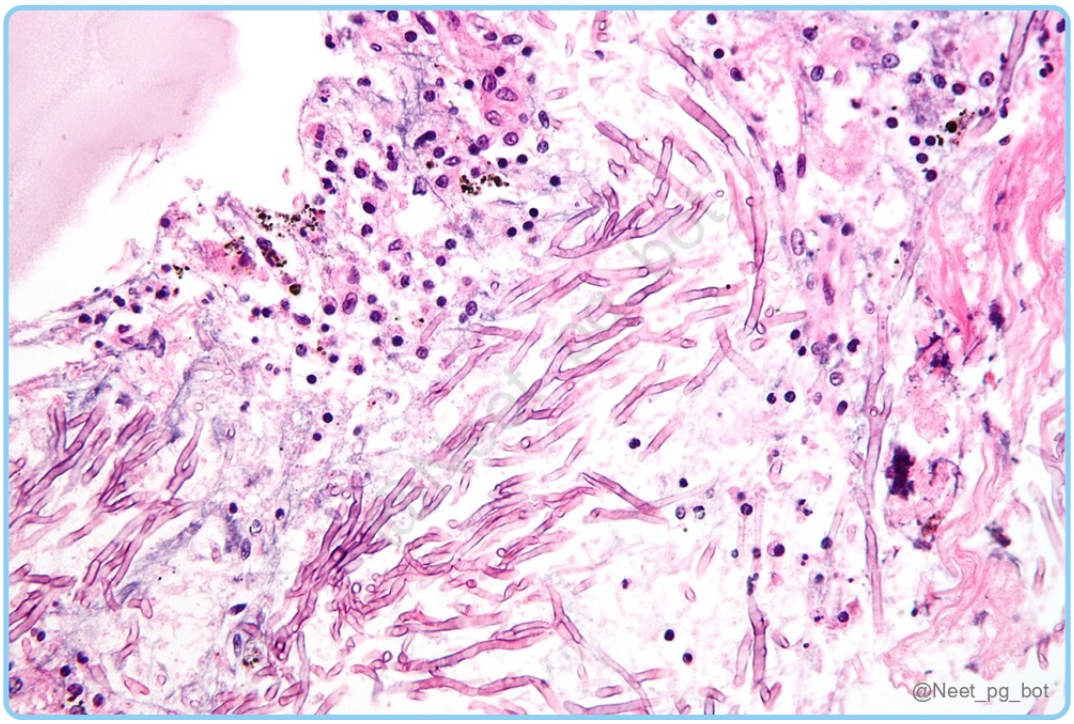

References:

Harrison’s Principles of Internal Medicine, 22nd Edition, Page 1716.

↑ *Back to this question in Part A*

@Neet_pg_bot

Q13: AIDS Patient is having a CD4 count of 200 cells/cu.mm. He has had fever, cough and shortness of breath for the past week. Auscultation reveals scattered bronchial breathing in the left infra-axillary and infrascapular areas. CXR reveals air bronchograms in the left lower lobe. Which opportunistic infection is present in this patient? (Q850973)

A. Pneumococcus

B. Mycobacterium avium intracellulare

C. Mycobacterium tuberculosis

D. Pneumocystis jirovecii

Correct Answer: A. Pneumococcus

■ *Listen (English)*

■ *Listen (Hindi)*

Explanation: In AIDS patients with CD4 counts >200 cells/mm³, community-acquired bacterial pneumonia—most commonly caused by Streptococcus pneumoniae —is the typical opportunistic infection, presenting with fever, productive cough, and lobar consolidation with air bronchograms on CXR. Mycobacterium avium intracellulare (Option B) usually occurs at CD4 <50 cells/mm³ and presents with disseminated disease rather than lobar pneumonia. Mycobacterium tuberculosis (Option C) can occur at any CD4 count but typically shows upper-lobe infiltrates and cavitation. Pneumocystis jirovecii (Option D) generally occurs at CD4 <200 cells/mm³ and presents with diffuse bilateral interstitial infiltrates, not lobar consolidation.

References:

Harrison’s Principles of Internal Medicine, 22nd Edition, Page 1995, 1996.

↑ *Back to this question in Part A*

@Neet_pg_bot

Q14: A truck driver with AIDS is brought in with fever and altered mental status. His family reports a week-long history of worsening headache, fever, projectile vomiting, and confusion. Neuroimaging shows a soapy bubble appearance, and CSF shows 50 lymphocytes/cu.mm with low sugar and a mild increase in protein. Which of the following is the most accurate test for confirmation of the diagnosis of this condition? (Q850972)

A. CSF Lateral flow assay

B. CSF gram staining

C. CSF India ink preparation

D. CSF staining with mucicarmine

Correct Answer: A. CSF Lateral flow assay

■ *Listen (English)*

■ *Listen (Hindi)*

Explanation: Cryptococcal meningitis in AIDS patients can be rapidly confirmed with the CSF lateral flow assay, which detects cryptococcal antigen with high sensitivity and specificity. Sensitivity and Specificity: It has a sensitivity and specificity approaching 100% , even in cases with a low fungal load. Early Detection: It can detect the capsular polysaccharide antigen much earlier and more reliably than microscopy. Speed: It provides results in about 10 minutes. Gram staining (Option B): Gram staining is generally poor for diagnosing fungal infections. While Cryptococcus is a "Gram-positive" budding yeast, it is often missed or misinterpreted on a standard Gram stain. It is much better suited for bacterial meningitis (e.g., Streptococcus pneumoniae). India ink preparation (Option C): This is the classic for identifying the thick polysaccharide capsule. However: Sensitivity is low: It only identifies the fungus in about 60–80% of HIV-positive patients and is even less sensitive in HIV-negative patients. User-dependent: It requires a skilled microscopist to distinguish the yeast from white blood cells or artifacts. Staining with mucicarmine (Option D): Mucicarmine stain is used to highlight the thick polysaccharide capsule of Cryptococcus in bright red. However, this is primarily a histopathology stain used on tissue biopsies (like the "soap bubble" brain lesions or lung tissue). It is not the standard or most accurate way to confirm a diagnosis from a CSF sample compared to antigen testing.

References:

Harrison’s Principles of Internal Medicine, 22nd Edition, Page 1606, 1705.

↑ *Back to this question in Part A*

@Neet_pg_bot

Q15: A 3-week-old infant born to an HIV-positive mother is brought to OPD. The baby was delivered vaginally and was not breastfed. The mother has been on antiretroviral therapy throughout pregnancy. Which of the following is the most appropriate test to diagnose HIV infection in this neonate? (Q850971)

A. PCR HIV RNA

B. PCR HIV DNA

C. Serum ELISA for HIV

D. p24 antigen

Correct Answer: B. PCR HIV DNA

■ *Listen (English)*

■ *Listen (Hindi)*

Explanation: PCR HIV DNA is the most appropriate test for diagnosing HIV in infants <18 months because it detects proviral DNA directly in infected cells. It is reliable even in the neonatal period and unaffected by maternal antibodies. This makes it the preferred early infant diagnostic tool. PCR HIV RNA (Option A) can detect viral RNA but is less commonly used as the first-line test in neonates. Serum ELISA for HIV (Option C) is unreliable in infants <18 months due to maternal antibody interference. p24 antigen (Option D) may be detectable, but

sensitivity is lower compared to HIV DNA PCR in neonates.

References:

Harrison's Principles of Internal Medicine, 22nd Edition, Page 1589.

↑ *Back to this question in Part A*

@Neet_pg_bot

Q16: A 28-year-old lab technician presents 10 days after sustaining a needle-stick injury while drawing blood from an HIV-positive patient. He did not receive post-exposure prophylaxis He is currently asymptomatic and anxious about possible seroconversion. Which of the following test will help in early detection of possible transmission of infection? (Q850970)

A. HIV PCR RNA

B. Western Blot

C. HIV PCR DNA

D. ELISA for HIV-1 and HIV-2

Correct Answer: A. HIV PCR RNA

■ *Listen (English)*

■ *Listen (Hindi)*

Explanation: HIV RNA PCR can detect viral RNA within 10–12 days post-exposure, allowing early detection of acute HIV infection. Western Blot (Option B) is used to confirm HIV infection after antibodies have developed, usually 4–6 weeks post-exposure. HIV PCR DNA (Option C) detects proviral DNA integrated into host cells and is less useful for very early detection. ELISA for HIV-1 and HIV-2 (Option D) detects antibodies, which may not be present during the early "window period" after exposure.

References:

Harrison's Principles of Internal Medicine, 22nd Edition, Page 1589, 1590.

↑ *Back to this question in Part A*

@Neet_pg_bot

Q17: Which is correct about definiton of AIDS? (Q850969)

A. ELISA positive for HIV plus any WHO clinical stage 4 condition that includes AIDS-defining illnesses

B. ELISA positive for HIV plus CD4 count less than 350 cells /cu.mm

C. ELISA positive for HIV plus CD4 count less than 500 cells /cu.mm

D. ELISA positive for HIV plus persistent generalized lymphadenopathy involving > 2 groups

Correct Answer: A. ELISA positive for HIV plus any WHO clinical stage 4 condition that includes AIDS-defining illnesses

■ *Listen (English)*

■ *Listen (Hindi)*

Explanation: According to the World Health Organization (WHO): AIDS is diagnosed in an HIV-positive individual when they have either: A CD4+ T-cell count <200 cells/µL , OR Any WHO clinical stage 4 condition , which includes AIDS-defining illnesses (e.g., Pneumocystis pneumonia, cryptococcal meningitis, Kaposi sarcoma, esophageal candidiasis, etc.)

References:

Harrison's Principles of Internal Medicine, 22nd Edition, Page 1557.

↑ *Back to this question in Part A*

@Neet_pg_bot

Q18: A 53-year-old man visits the clinic with recurring respiratory infections and oral candidiasis. Lab tests show a CD4 count of 150 cells/mm³, raising suspicion for HIV. Which structure allows the HIV virus to attach to CD4 cells initially? (Q850934)

A. CCR5

B. gp41

C. p17

D. gp120

Correct Answer: D. gp120

■ *Listen (English)*

■ *Listen (Hindi)*

Explanation: HIV attaches to CD4■ T-cells using its gp120 envelope glycoprotein , which binds to the CD4 receptor . After gp120 binds CD4, it undergoes a conformational change that allows interaction with a co-receptor

(CCR5 or CXCR4) and then triggers membrane fusion mediated by gp41 . This patient's CD4 count of 150 , recurrent infections, and candidiasis strongly suggest advanced HIV infection. CCR5 (Option A) acts as a co-receptor that allows fusion and viral entry after gp120 binds to CD4. gp41 (Option B) mediates fusion of the viral envelope with the host cell membrane after gp120-CD4 interaction. p17 (Option C) is a matrix protein that helps maintain the structure of the virion but is not involved in attachment. {{caption_text}}

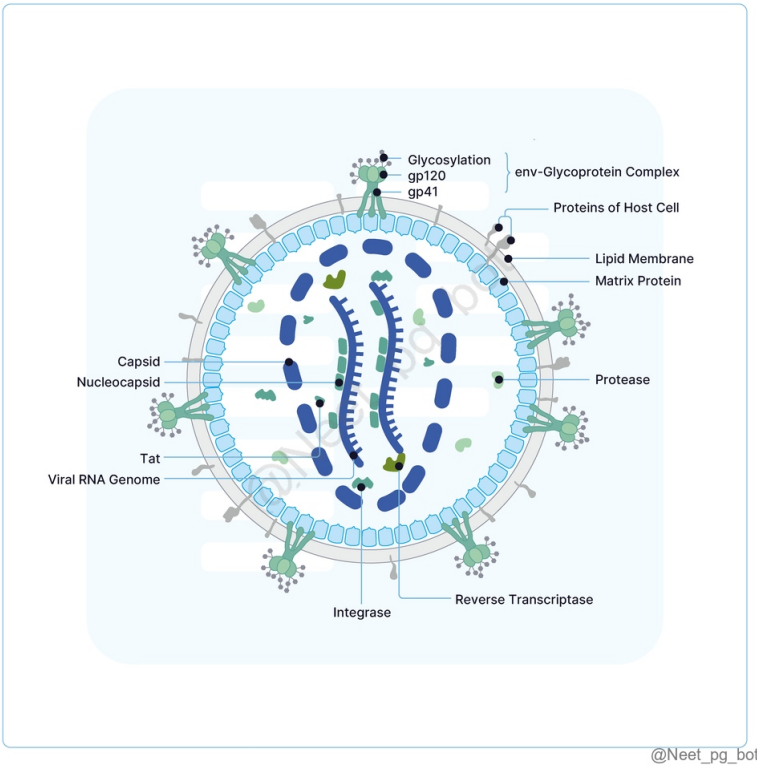

References:

Harrison's Principles of Internal Medicine, 22nd Edition, Page 1557, 1560.

↑ *Back to this question in Part A*

@Neet_pg_bot

Q19: A 31-year-old woman diagnosed with HIV is in her third trimester of pregnancy. Which of the following statements is not true regarding vertical transmission of HIV? (Q850933)

A. ART greatly lowers the risk of vertical transmission.

B. Transmission can occur through breast milk.

C. Prolonged membrane rupture increases transmission risk.

D. Viral transmission does not occur in the first trimester.

Correct Answer: D. Viral transmission does not occur in the first trimester.

■ *Listen (English)*

■ *Listen (Hindi)*

Explanation: Vertical transmission of HIV can occur during any stage of pregnancy, including the first trimester, at delivery, or through breastfeeding. ART has greatly reduced the risk of transmission (Option A) in recent times, combined with cesarean delivery, which has made mother-to-child transmission of HIV extremely low. Transmission can occur through breast milk (Option B): HIV transmission can happen from the affected mother to the child from the first trimester of pregnancy, during delivery and breastfeeding. Prolonged membrane rupture increases transmission risk (Option C): A mniotic sac is no longer intact, and the baby is directly exposed to maternal vaginal and cervical secretions , which may contain high levels of HIV.

References:

Harrison's Principles of Internal Medicine, 22nd Edition, Page 1565.

↑ *Back to this question in Part A*

@Neet_pg_bot

Q20: A 30-year-old asthmatic patient presents with worsening respiratory symptoms and is diagnosed with Allergic Bronchopulmonary Aspergillosis . Which of the following is the most appropriate initial treatment strategy? (Q850932)

A. Voriconazole

B. Itraconazole with low-dose corticosteroids

C. Fluconazole with corticosteroids

D. Posaconazole

Correct Answer: B. Itraconazole with low-dose corticosteroids

■ *Listen (English)*

■ *Listen (Hindi)*

Explanation: The most appropriate initial treatment strategy for an asthmatic patient diagnosed with ABPA is Itraconazole combined with low-dose corticosteroids. Steroids are given as this disease is a hypersensitivity reaction to colonization of the airways with Aspergillus fumigatus. In contrast, invasive pulmonary aspergilloma is treated with voriconazole. Invasive Pulmonary Aspergilloma occurs in immunocompromised hosts (e.g. neutropenic, transplant, prolonged steroids). It is a tissue-invasive infection and not a hypersensitivity. Voriconazole (Option A): Voriconazole is the gold standard for Invasive Aspergillosis . However, for ABPA

(which is an allergic/hypersensitivity condition, not an invasive one), it is generally reserved as a second-line or salvage therapy if the patient cannot tolerate Itraconazole or if the disease is refractory. It is not the "initial" strategy. Fluconazole with corticosteroids (Option C) is ineffective against Aspergillus species as it primarily targets yeasts like Candida by inhibiting ergosterol synthesis. Posaconazole (Option D: Posaconazole is a potent, broad-spectrum antifungal. Similar to Voriconazole, it is typically used for prophylaxis in severely immunocompromised patients or as a later-line treatment for ABPA when first-line therapies fail.

References:

Harrison’s Principles of Internal Medicine, 22nd Edition, Page 1717.

↑ *Back to this question in Part A*

@Neet_pg_bot

Q21: Which of the following findings is not seen with allergic bronchopulmonary aspergillosis? (Q850931)

A. Elevated total serum IgE

B. Central bronchiectasis on HRCT

C. Presence of hyper-attenuated mucus on imaging

D. Halo sign on HRCT chest

Correct Answer: D. Halo sign on HRCT chest

■ *Listen (English)*

■ *Listen (Hindi)*

Explanation: The halo sign is seen with invasive pulmonary aspergilloma and not in ABPA. Both are different diseases, with ABPA being hypersensitivity to Aspergillus fumigatus and characterized by central bronchiectasis. Imaging findings of Allergic Bronchopulmonary Aspergillosis (ABPA) Presence of hyper-attenuated mucus in airways is highly specific (Option C) Proximal /Central Bronchiectasis Tram track appearance in CT d/t bronchiectasis X-ray: Cylindrical & proximal bronchiectasis with thickening of the bronchial wall (Tree in bud appearance) Mucous impaction in dilated bronchi (Finger-in-glove appearance) HRCT: Central bronchiectasis (Option B) and bronchial wall thickening with atelectatic areas. Elevated specific and total serum IgE levels (>1000 IU/mL) (Option A) is seen in ABPA

References:

Harrison’s Principles of Internal Medicine, 22nd Edition, Page 1715, 1716.

↑ *Back to this question in Part A*

@Neet_pg_bot

• [11_Infections] 087 Previous Year Questions

« Back to Folder Directory

[11_Infections] 087 Previous Year Questions — Quick Jump

Q1 (p. 3164)	*Q2 (p. 3166)*	*Q3 (p. 3166)*	*Q4 (p. 3167)*	*Q5 (p. 3168)*	*Q6 (p. 3169)*
Q7 (p. 3170)	*Q8 (p. 3171)*	*Q9 (p. 3172)*	*Q10 (p. 3173)*	*Q11 (p. 3174)*	*Q12 (p. 3175)*
Q13 (p. 3177)	*Q14 (p. 3178)*	*Q15 (p. 3179)*	*Q16 (p. 3183)*	*Q17 (p. 3184)*	*Q18 (p. 3185)*
Q19 (p. 3185)	*Q20 (p. 3186)*	*Q21 (p. 3189)*	*Q22 (p. 3189)*	*Q23 (p. 3190)*	*Q24 (p. 3191)*
Q25 (p. 3192)	*Q26 (p. 3193)*	*Q27 (p. 3194)*	*Q28 (p. 3194)*	*Q29 (p. 3195)*	*Q30 (p. 3196)*
Q31 (p. 3197)	*Q32 (p. 3199)*	*Q33 (p. 3200)*	*Q34 (p. 3201)*	*Q35 (p. 3202)*	*Q36 (p. 3203)*

Q1: The blood investigation of a patient is given below. What is the probable diagnosis? HBsAg- Nonreactive HBeAg- Nonreactive IgG anti-HbcAg – Reactive IgM anti-HbcAg – Nonreactive (Q855717)

A. Acute hepatitis B

B. Chronic hepatitis B

C. Remote infection of hepatitis B

D. Core window period

Correct Answer: C. Remote infection of hepatitis B

Explanation: The patient's reactive IgG anti-HbcAg and nonreactive HBsAg and IgM anti-HbcAg indicate a remote hepatitis B infection. Phase/Condition HBsAg Anti-HBs HBeAg Anti-HBe Anti-HBc Acute HBV (Option A) + Nil + Nil IgM Window Phase Nil Nil Nil + IgM Chronic HBV/ Infective carrier (High infectivity) + Nil + Nil IgG Chronic HBV/Healthy carrier (Low infectivity) (Option A) + Nil Nil + IgG Remote infection Nil Nil Nil Nil IgG Recovery Nil + Nil + IgG Immunized Nil + Nil Nil Nil {{caption_text}} Acute HBV infection with recovery {{caption_text}} Chronic HBV infection Core window period (Option D) refers to the phase of hepatitis B infection when HBsAg is negative, and only IgM anti-HBcAg is positive, signifying the transition between the acute and window phases. However, in this case, the IgM anti-HBcAg is nonreactive, ruling out the core window period as a diagnosis.

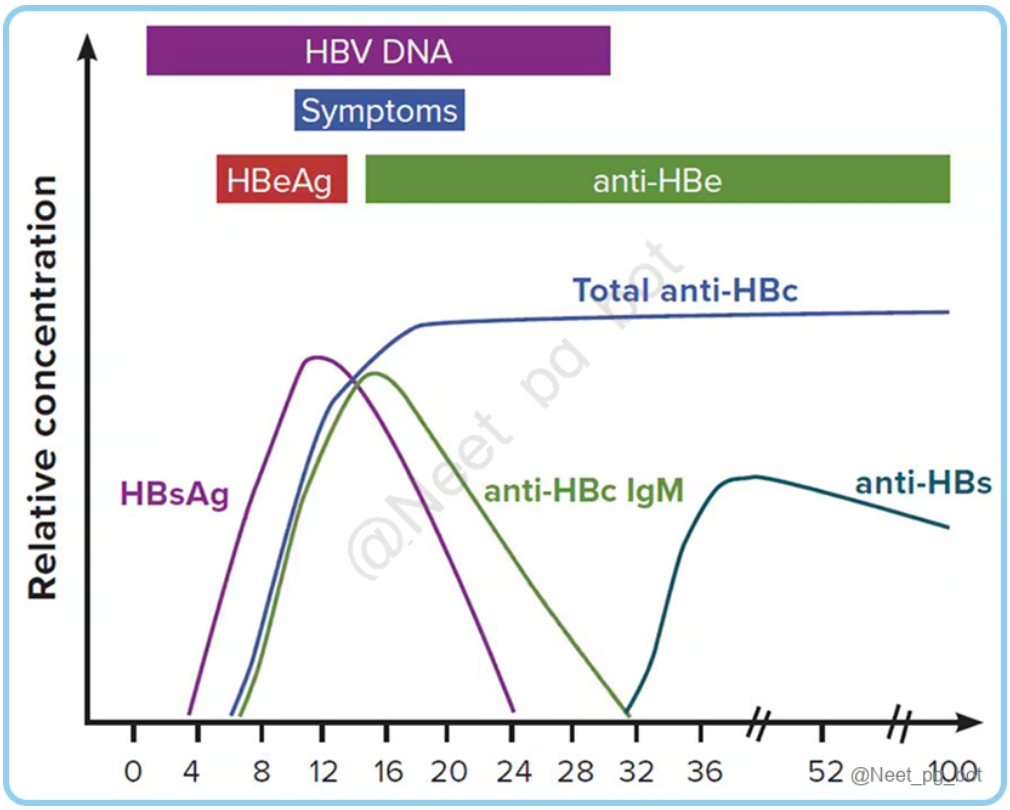

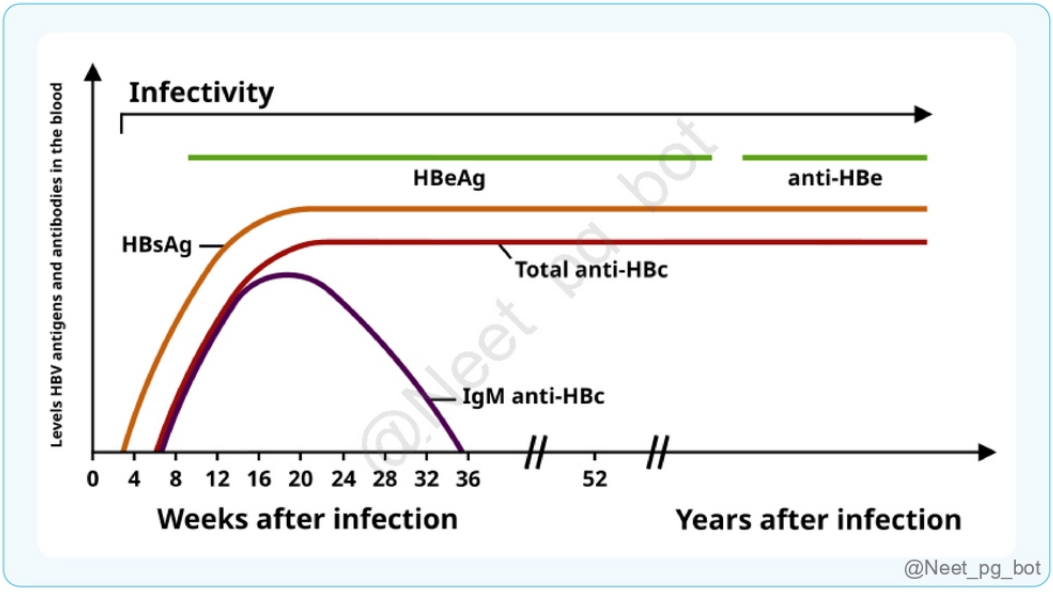

References:

https://www.researchgate.net/publication/354997816_Hepatitis_B_Vaccines

↑ *Back to this question in Part A*

@Neet_pg_bot

Q2: A patient arrives at the hospital with symptoms of fever and chills. A fever profile test is conducted, which rules out malaria and dengue as the cause. However, the rK39 test comes back positive. What is the preferred treatment for this condition? (Q855608)

A. Amphotericin B

B. Griseofulvin

C. Dapsone

D. Hydroxychloroquine

Correct Answer: A. Amphotericin B

Explanation: The patient presents with fever and chills, with malaria and dengue ruled out, but rK39 test positive, which strongly indicates visceral leishmaniasis (Kala-azar), which presents with fever, weight loss, hepatosplenomegaly, and pancytopenia. The rK39 antigen test detects antibodies against Leishmania donovani, the causative agent of visceral leishmaniasis. The treatment of choice for Kala-azar is Amphotericin B, particularly liposomal Amphotericin B, due to its high efficacy and safety profile. Griseofulvin (Option B) is an antifungal medication that works by inhibiting microtubule function , thereby interfering with fungal mitosis. It is primarily used for treating superficial fungal infections like tinea capitis and onychomycosis . Dapsone (Option C) is an antimicrobial drug that inhibits dihydropteroate synthase , disrupting folic acid metabolism. It is mainly used in leprosy (Hansen's disease) as part of multi-drug therapy (MDT) and for Pneumocystis jirovecii pneumonia (PCP) prophylaxis in immunocompromised patients. Hydroxychloroquine (Option D) is an immunomodulatory drug that interferes with antigen presentation by lysosomes. It is widely used in autoimmune diseases like SLE and rheumatoid arthritis , as well as in malaria treatment and prophylaxis .

References:

Paniker's textbook of medical parasitology, 8th edition, Page 60,61, 62

↑ *Back to this question in Part A*

@Neet_pg_bot

Q3: A patient, who is a known case of HIV with a CD4 count of 200 cells/cu.mm, presents with 5 days of cough and high-grade fever without chills and rigors. There is no history of diarrhoea, vomiting, or nuchal rigidity. The chest x-ray is normal. What treatment will you give? (Q855704)

A. Amoxicillin-clavulanic acid + Azithromycin

B. Amphotericin B

C. Co-trimoxazole only

D. Antitubercular treatment

Correct Answer: C. Co-trimoxazole only

Explanation: Co-trimoxazole treatment is recommended for patients with HIV who present with symptoms of a respiratory tract infection and a CD4 count of less than 200 cells/cu.mm. Co-trimoxazole, a combination of sulfamethoxazole and trimethoprim, is commonly used in AIDS patients with cough due to its effectiveness against Pneumocystis jirovecii pneumonia (PJP). PJP is an opportunistic infection that affects individuals with weakened immune systems, such as those with advanced HIV/AIDS. Amoxicillin-clavulanic acid + Azithromycin (Option A) : This combination is typically used for community-acquired pneumonia (CAP) , which often shows lobar infiltrates on chest X-ray . However, the normal chest X-ray and the high CD4 threshold for bacterial pneumonia make this less likely. Also, CAP typically presents with chills and rigors , which are absent here. Amphotericin B (Option B) : This is the drug of choice for disseminated fungal infections such as cryptococcal meningitis or visceral leishmaniasis . However, there is no evidence of cryptococcal infection (e.g., no headache, altered sensorium, or nuchal rigidity), and the patient's symptoms are respiratory, not systemic. Antitubercular treatment (ATT) (Option D) : Tuberculosis (TB) is common in HIV patients, but it usually presents with chronic symptoms like prolonged cough, weight loss, night sweats, and upper lobe infiltrates on chest X-ray . The acute nature of the illness (5 days of symptoms) and normal chest X-ray make TB less likely. Reference:

References:

Harrison's Principles of Internal Medicine, 21st Edition, Page 1563 -1567

↑ *Back to this question in Part A*

@Neet_pg_bot

Q4: Which of the following is NOT a potential complication in a 40-year-old man who presents with a 15-day history of fever and a 1-day history of altered sensorium and is diagnosed with Plasmodium falciparum through a rapid diagnostic test? (Q855326)

A. Blood glucose <40 mg/dL

B. Arterial pH >7.2

C. Serum creatinine -5.2

D. Unarousable coma

Correct Answer: B. Arterial pH >7.2

Explanation: Arterial pH >7.2 (alkalosis) is not a complication associated with Plasmodium falciparum infection. Severe malaria caused by P. falciparum can trigger metabolic acidosis in which the arterial pH is less than 7.2.

Hypoglycemia (blood glucose <40 mg/dL) (Option A) can be a complication of severe malaria, particularly in cases of P. falciparum infection. The parasite's impact on the liver and the increased metabolic demands of the infection can lead to low blood sugar levels. The presence of serum creatinine levels of -5.2 (Option C), indicating a significant decrease in renal clearance, suggests acute kidney injury (AKI). Malaria-associated AKI can result from various factors, such as decreased blood flow to the kidneys, direct parasite-mediated damage, or immune-mediated injury. Cerebral malaria, characterized by impaired consciousness and unarousable coma (Option D) is a severe complication that can occur in P. falciparum infection. Complications of Malaria: Cerebral malaria , Convulsions Black water fever Jaundice Septicemic malaria: The presence of malaria parasites in the bloodstream, leading to systemic inflammation, septic shock, and multiple organ dysfunction. Algid malaria: causes peripheral circulatory failure Noncardiogenic Pulmonary Edema and ARDS Renal failure/Acute kidney injury (AKI) Hypoglycemia Severe anemia Hyperpyrexia Metabolic acidosis and shock Bleeding disturbances Hyperreactive malarial Splenomegaly Quartan malarial nephropathy EBV infection , Burkitt's lymphoma

References:

Harrison’s Principles of Internal Medicine, 21st edition, Page 979, 1724, 1725

Apurba S Sastry’s Essentials of Medical Microbiology, 3rd edition, Page 344, 349, 350

Paniker’s Textbook of Medical Parasitology, 8th edition, Page 78, 79, 80.

↑ *Back to this question in Part A*

@Neet_pg_bot

Q5: A 25-year-old immunocompromised man presents with fever, headache, and altered sensorium. Examination shows neck rigidity and positive Kernig’s sign. CSF reveals lymphocytic predominance, high protein, low glucose, and encapsulated yeast cells on India ink staining. What is the most appropriate treatment regimen for this patient? (Q855355)

A. Piperacillin + Tazobactam

B. Vancomycin + Ceftriaxone

C. Amphotericin B + Flucytosine

D. Ceftriaxone + Ampicillin

Correct Answer: C. Amphotericin B + Flucytosine

Explanation: The patient's presentation is consistent with cryptococcal meningitis , as indicated by the encapsulated yeast cells on India ink staining , most commonly caused by Cryptococcus neoformans . The recommended initial treatment is a combination of amphotericin B and flucytosine for induction therapy, followed by fluconazole for consolidation. {{caption_text}} Fungal meningitis: Causes Cryptococcus neoformans (most common) Candida Histoplasma Blastomyces Coccidioides Sporothrix Risk factors Immunocompromised patients

Clinical features Headache Altered mental status, lethargy Fever Neck stiffness Nausea and vomiting. Investigations Lumbar Puncture: Low glucose and high protein levels. White cell count can be normal or higher than 20 microL and have a lymphocyte predominance. India ink stain shows encapsulated yeast cells. CSF ELISA for CRAG (Cryptococcal Antigen). Treatment (Options A, B & D ruled out) LAMB (Liposomal Amphotericin-B) and 5-Fluorocytosine (Flucytosine) for 2 weeks Fluconazole is given subsequently for 8-10 weeks.

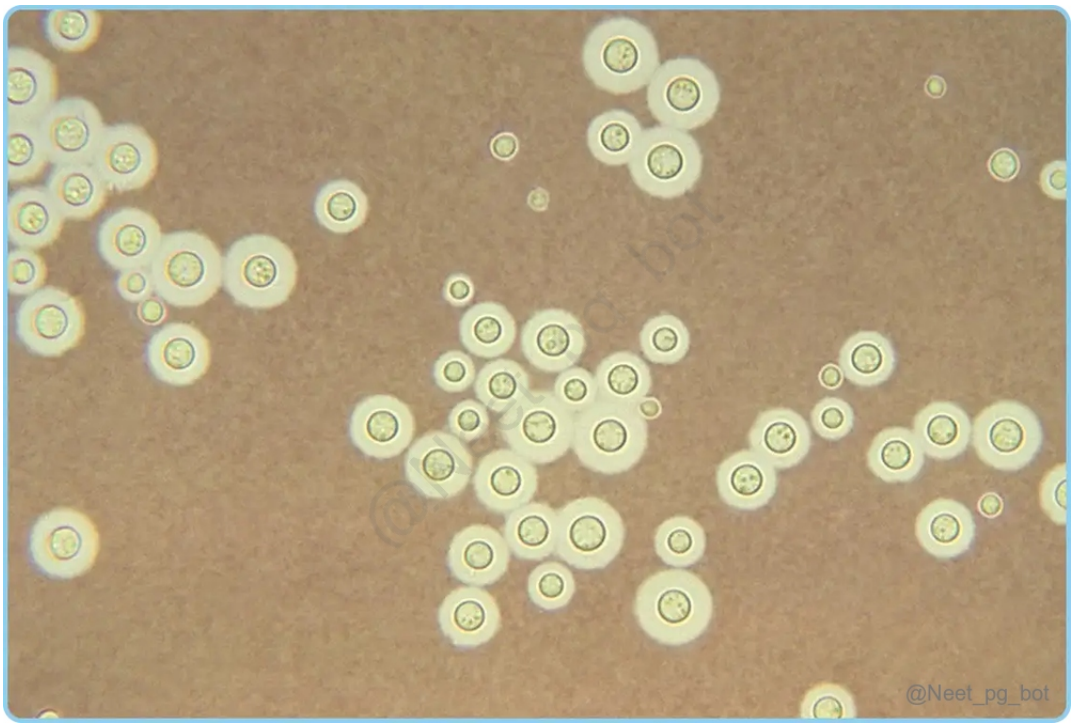

References:

Harrison's Principles of Internal Medicine, Twenty-First Edition Page 946, 1109

Davidson’s Principles and Practice of Medicine, 24th Edition, Page 1118

Cryptococcal meningitis

↑ *Back to this question in Part A*

@Neet_pg_bot

Q6: A patient presents with cough, cold, fever and malaise associated with weight loss and ascites. A radiograph of the chest is shown below. Ascitic fluid analysis showed elevated adenosine deaminase. Which of the following is the next step in management? (Q855357)

A. Biopsy

B. Start ATT after laparotomy stricture removal

C. Start anti-tubercular therapy

D. Symptomatic management

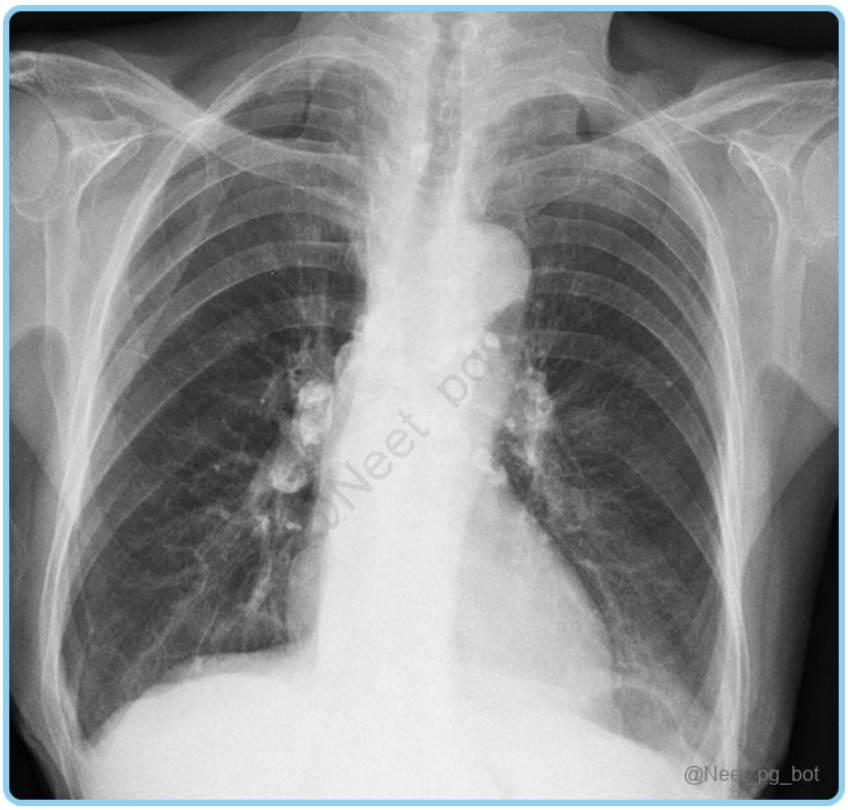

Correct Answer: C. Start anti-tubercular therapy

Explanation: Chest x-ray and clinical symptoms are suggestive of tuberculous peritonitis secondary to pulmonary tuberculosis. High levels of adenosine deaminase, lysozyme, and IFN-gamma may suggest a tuberculous etiology. It is typically managed with a combination of anti-tubercular drugs, including isoniazid, rifampicin, pyrazinamide, and ethambutol. Biopsy (Option A) may be considered if the diagnosis is uncertain or to establish the definitive diagnosis. Start ATT after laparotomy stricture removal (Option B) is not indicated in the management of tuberculous peritonitis. Symptomatic management (Option D) is inadequate, and initiation of anti-tubercular therapy is a more appropriate option.

References:

Harrison’s Principles of Internal Medicine, 21st Edition, Page 1365, 1366

↑ *Back to this question in Part A*

@Neet_pg_bot

Q7: What is the association of Rhino-cerebral Mucor mycosis? (Q857049)

A. Diabetic ketoacidosis

B. Pregnancy

C. Antibiotics

D. Inhaled steroids

Correct Answer: A. Diabetic ketoacidosis

Explanation: Rhino-cerebral mucormycosis is strongly associated with uncontrolled diabetes, particularly diabetic ketoacidosis. Rhino-cerebral mucormycosis, also known as zygomycosis, is a serious fungal infection caused by various species of fungi belonging to the class Mucorales. It primarily affects the nose, sinuses, and brain. Intravenous amphotericin B is the first-line antifungal treatment that targets the causative organisms, significantly improving the patient's chances of survival. Infections in Diabetes Mellitus Diabetes mellitus (DM) increases susceptibility to opportunistic infections. Focused infections: Rhino-cerebral mucormycosis (RCM) Acute emphysematous cholecystitis Pyelonephritis Rhino-Cerebral Mucormycosis (RCM) Aspect Details Overview Severe fungal infection affecting nasal passages, sinuses, and brain. Causative Agent Primarily caused by Rhizopus oryzae , associated with uncontrolled DM and diabetic ketoacidosis (DKA). Pathophysiology Begins in nasal turbinates; progresses rapidly due to angioinvasive nature, causing tissue necrosis and vascular thrombosis. Clinical Manifestations Fever, facial pain, swelling, nasal discharge, necrotic eschar. Diagnosis Imaging studies and histopathological examination. Treatment Immediate antifungal therapy (e.g., amphotericin B) and aggressive surgical debridement.

References:

https://insightsimaging.springeropen.com/articles/10.1186/s13244-021-01109-z

https://www.ncbi.nlm.nih.gov/books/NBK557429/

↑ *Back to this question in Part A*

@Neet_pg_bot

Q8: A 7-year-old boy presents with fever, painful swelling in front of both ears, and difficulty chewing or talking. On examination, he also complains of mild testicular pain. What is the most likely diagnosis? (Q857613)

A. Cervical tuberculosis

B. Diphtheria

C. Mumps

D. Lymphoma

Correct Answer: C. Mumps

Explanation: Mumps is a viral infection caused by the mumps virus, most common in children aged 5–9 years. Classic signs include fever, malaise, and painful swelling of the parotid glands (preauricular or mandibular). Swelling can cause difficulty chewing, swallowing, or talking. Post-pubertal males may develop orchitis, but mild testicular tenderness can occasionally occur in younger boys. Transmission is via respiratory droplets, common in schools or daycare. Diagnosis is primarily clinical, supported by serology if needed. Complications include orchitis, pancreatitis, meningitis, and rarely deafness. The combination of parotid swelling + fever + testicular pain strongly suggests mumps. {{caption_text}} Incorrect Options: Option A) Cervical tuberculosis : Usually presents with painless, firm lymphadenopathy, not parotid swelling or testicular pain. Option B) Diphtheria : Causes pharyngeal pseudomembrane and sore throat, without parotid or testicular involvement. Option D) Lymphoma : Lymph node swelling is usually painless and generalized, not associated with fever or parotid swelling.

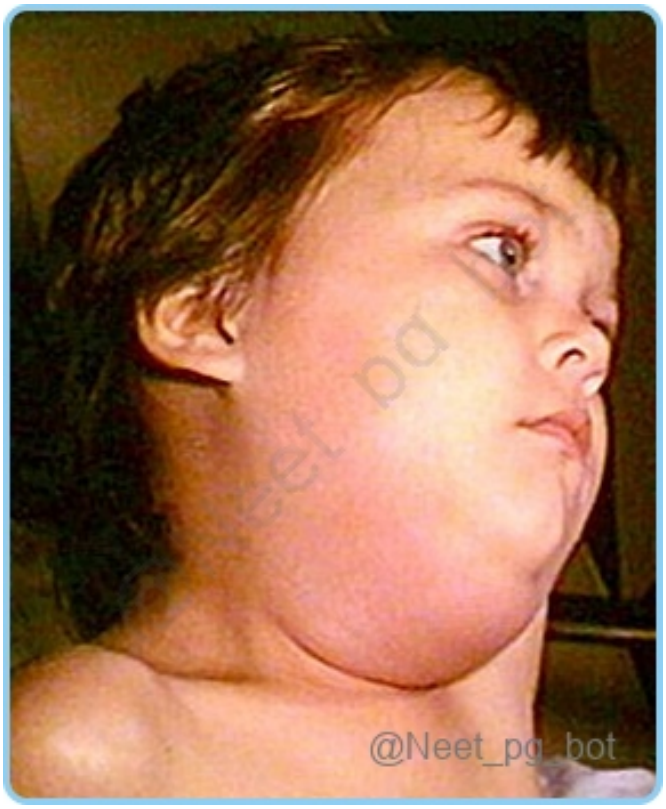

References:

Harrison’s Principles of Internal Medicine, 21st edition, Page 1615

Davidson’s Principles and Practice of Medicine, 24th edition, Page 240

Nelson Textbook of Pediatrics, 21st edition, Page 1680,1682

↑ *Back to this question in Part A*

@Neet_pg_bot

Q9: A newly diagnosed HIV patient presented with fever, cough and haemoptysis. His sputum sample showed acid-fast bacilli. What is the appropriate management for this patient? (Q855702)

A. Start ART if CD4<200

B. Start ART and then ATT after 2 weeks

C. Start ATT and then ART after 2 weeks

D. Start ATT and ART simultaneously

Correct Answer: C. Start ATT and then ART after 2 weeks

Explanation: The appropriate management in an HIV patient with tuberculosis (TB) is to start antitubercular therapy (ATT) first and then initiate antiretroviral therapy (ART) after 2-8 weeks of ATT to avoid the risk of immune reconstitution inflammatory syndrome (IRIS). HIV and TB Co-infection: Increased Risk: People with HIV are 18-26 times more likely to develop active TB than those without HIV. HIV weakens the immune system, reducing CD4 T-cell counts, which are essential for controlling TB infection. This allows TB to progress from latent to active disease. The underlying mechanism of IRIS is due to an imbalance between anti-inflammatory cytokines and pro-inflammatory cytokines that occurs rapidly after the recovery of immune function in HIV patients initiated on HAART. Screening and Diagnosis: Testing for Both Conditions: Patients with TB should be tested for HIV, and vice versa, given the high co-infection rate. Diagnostic Challenges: TB symptoms can overlap with other opportunistic infections in HIV patients. Tests like sputum culture, X-rays, and newer rapid molecular tests (GeneXpert) help in diagnosing TB in HIV-positive patients. Treatment of Co-Infection: Anti-TB Therapy : This involves the standard TB drug regimen, usually with a 6-month course. Treatment may extend for cases of drug-resistant TB. Instead of Rifampicin, Rifabutin is preferred in patients receiving protease inhibitors due to its property of being a less potent inducer of CYP3A4. Antiretroviral Therapy (ART) : Initiating ART is crucial for improving immune function. ART is typically started 2-8 weeks after beginning TB treatment to prevent immune reconstitution inflammatory syndrome (IRIS) , depending on CD4 count and clinical status. Drug Interactions: TB drugs, like rifampicin, can interact with ART drugs, requiring careful selection of the ART regimen to minimize side effects and maintain effectiveness.

References:

https://www.ncbi.nlm.nih.gov/books/NBK567803/# https://www.ncbi.nlm.nih.gov/pmc/articles/PMC3280977/ https://pmc.ncbi.nlm.nih.gov/articles/PMC3290133/#

↑ *Back to this question in Part A*

@Neet_pg_bot

Q10: A patient presents with fever and altered sensorium. Peripheral smear shows multiple ring stages. Best treatment is? (Q866815)

A. Primaquine

B. Quinine

C. Chloroquine

D. Artesunate

Correct Answer: D. Artesunate

Explanation: Fever with altered sensorium in malaria indicates cerebral malaria — a severe form most often due to Plasmodium falciparum . Multiple ring forms on smear strongly suggest falciparum malaria. Artesunate is preferred over quinine for severe malaria as per WHO guidelines, given its better safety profile, faster parasite clearance, and lower mortality. It is administered intravenously in the acute setting. Incorrect Options: Primaquine (Option A): Used for radical cure of P. vivax and P. ovale to target hypnozoites in the liver, not for acute severe falciparum malaria. Quinine (Option B): Historically the drug of choice for severe falciparum malaria, but now replaced by IV artesunate due to superior efficacy and safety. Chloroquine (Option C) : Effective for chloroquine-sensitive malaria, but most P. falciparum strains are resistant, making it inappropriate in this case.

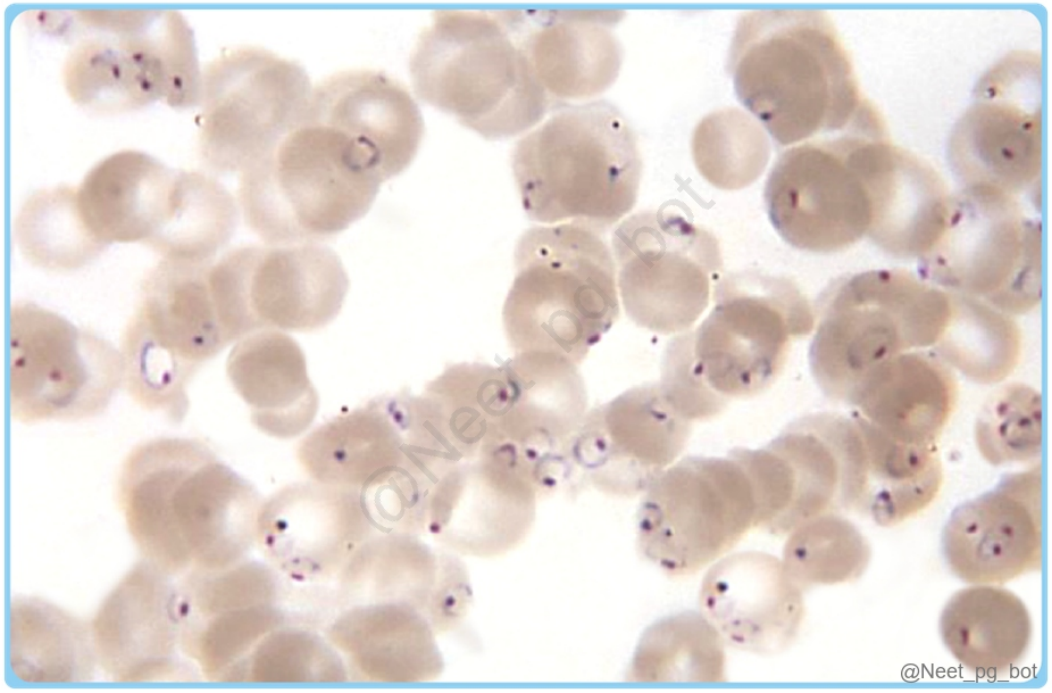

↑ *Back to this question in Part A*

@Neet_pg_bot

Q11: Identify the correct ‘organism-drug to which it is intrinsically resistant’ pair: (Q856588)

A. Aspergillus niger - Voriconazole

B. Aspergillus fumigatus - Micafungin

C. Candida albicans - Amphotericin B

D. Candida Krusei - Fluconazole

Correct Answer: D. Candida Krusei - Fluconazole

Explanation: rug Class Examples of Clinically Used Drugs Mechanism of Action Mechanism of Acquired Resistance Species with Intrinsic or High Rates of Resistance Azoles Fluconazole, Voriconazole, Posaconazole Inhibition of ergosterol biosynthesis Increased efflux pump activity, ERG11 mutations, CYP51 promoter mutations Candida glabrata, Candida krusei , Candida auris, Aspergillus fumigatus (Option B) Echinocandins Caspofungin, Micafungin, Anidulafungin Inhibition of β-1,3-glucan synthase Mutations in hot-spot regions of FKS genes Cryptococcus spp., Fusarium spp. Polyenes Amphotericin B Ergosterol sequestration Decreased membrane ergosterol, ERG mutations Candida auris, Aspergillus terreus Aspergillus niger - Voriconazole (Option A): Aspergillus niger is typically susceptible to voriconazole and does not show intrinsic resistance to this drug. Candida albicans - Amphotericin B (Option C): Candida albicans is usually susceptible to amphotericin B. Resistance to this drug, if present, is acquired rather than intrinsic.

References:

https://pmc.ncbi.nlm.nih.gov/articles/PMC7231573/

https://pmc.ncbi.nlm.nih.gov/articles/PMC7764418/

https://pmc.ncbi.nlm.nih.gov/articles/PMC8519031/

↑ *Back to this question in Part A*

@Neet_pg_bot

Q12: A 23-year-old medical student with fever had developed epistaxis which had resolved on its own and on evaluation his platelet counts are 14,000/µL and BP is 110/70 mmHg and there is a 28% rise in haematocrit. Then he has been afebrile for the last 24 hours now, what should be the next steps of management of this patient? Give 4 units of platelets Give plenty of oral fluids Give IV fluids Keep under observation Discharge the patient (Q856966)

A. 1 and 2

B. 1,2 and 4

C. 2,3 and 4

D. 2 and 5

Correct Answer: C. 2,3 and 4

Explanation: The likely diagnosis in this patient considering the above given scenario, could be dengue. And the appropriate management of dengue patients at this stage would be plenty of oral fluids and IV fluids to ensure adequate hydration. In this patient, since his epistaxis resolved spontaneously and the hematocrit is improving, he needs to be kept as inpatient for observation . Treatment of dengue: Group A (Outpatient) No warning signs: Abdominal pain or tenderness Persistent vomiting Clinical fluid accumulation Mucosal bleed Lethargy or restlessness Liver enlargement > 2 cm Hematocrit count Rise >20% admission value Rapid decrease in platelet count And who are able to: Tolerate adequate volumes of oral fluids To pass urine at least once every 6 hours Treatment Plenty of fluids- ORS, coconut water (avoid excess plain water) Paracetamol(500-650 mg per dose) for high fever Dosing should not be less than six hours Tepid sponge if the patient still has high fever Don't take: aspirin, ibuprofen, diclofenac or mefenamic acid Report to hospital immediately if Bleeding Vomiting Severe abdomen pain Drowsiness Breathing difficulty Not passing urine > 6 hours Group B (Inpatient) Warning signs present or Coexisting: Pregnancy, infancy, old age Obesity, diabetes mellitus, renal failure Chronic hemolytic diseases or Social: Living alone or living far from a health facility without reliable means of transport Note: Group C (ICU) For Hemodynamically unstable Dengue

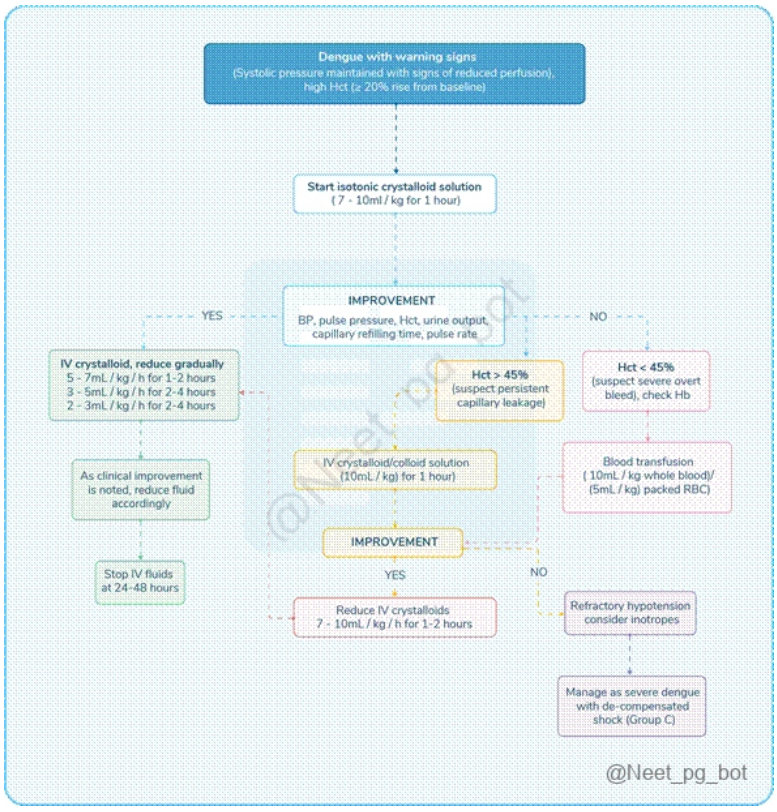

References:

Davidson’s Principles and Practice of Medicine, 24th edition, Page 244

↑ *Back to this question in Part A*

@Neet_pg_bot

Q13: Following is a graphic representation of a patient admitted in the medicine ward with a fever. What could be the possible diagnosis? (Q856270)

A. Cerebral malaria

B. Brucellosis

C. Leptospirosis

D. Typhoid

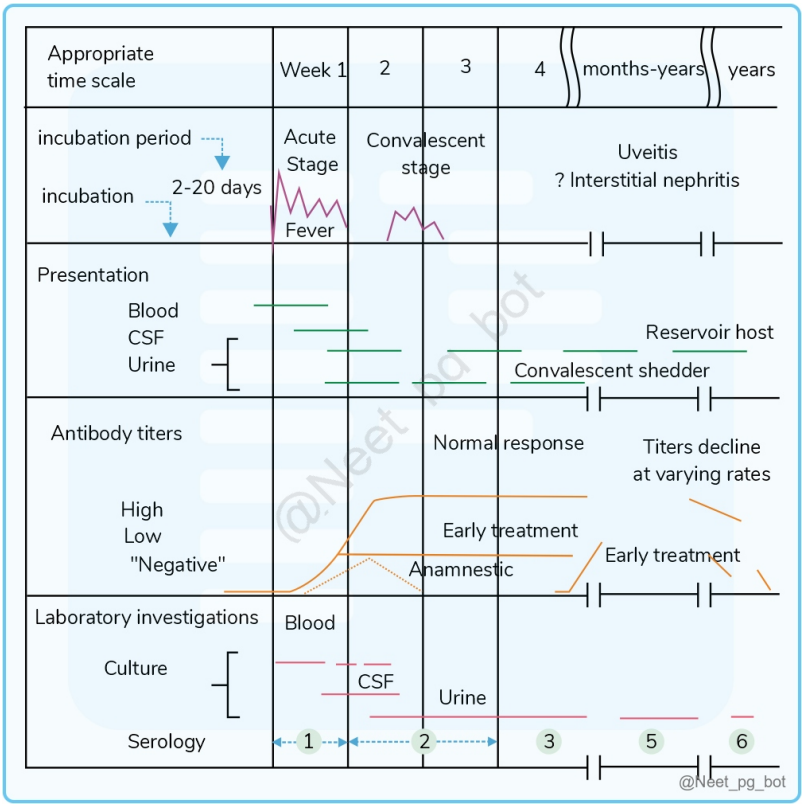

Correct Answer: C. Leptospirosis

Explanation: Graphical representation shows that over time, the disease leads to complications such as uveitis and interstitial nephritis. And CSF is a reservoir for the causative organism and it is shedding through urine. These findings point towards a diagnosis of leptospirosis. Leptospirosis is a bacterial infection caused by the bacteria of the genus Leptospira. It is commonly transmitted to humans through contact with water, soil, or food contaminated with the urine of infected animals. Leptospirosis can present with symptoms such as fever, headache, muscle aches, and can progress to more severe manifestations, including liver and kidney involvement. Leptospirosis Agent Leptospira interrogans (zoonotic bacteria) Reservoir Rodents (Ratus norvegicus, Mus musculus) and domestic animals Source Direct contact or contamination with excreta, urine of infected animals. Exposure to flooded rice paddies. At risk individuals Males 20-45 years (most common) Urine-contaminated mud(Soil) or

water Sports: rafting, fishing and swimming Rice field workers, sewer workers, animal handlers Mode of transmission Direct contact: Urine through skin abrasion Indirect contact: Contact of broken skin with soil, water, vegetation Droplet infection: Inhalation while milking cows. Incubation 4-20 days Diagnosis Clinical features: High fever, severe headache, muscle pain, conjunctival suffusion, and jaundice Dark Field examination: Thin and motile spirochete . IgM ELISA : High sensitivity Labs: Elevated liver enzymes, increased bilirubin , thrombocytopenia Treatment DOC: Penicillin 6 million units daily. Alternate drugs: Doxycycline Amoxicillin Ampicillin Ceftriaxone Prevention Avoid contaminated water and use protective clothing Livestock vaccination, proper waste disposal Rodent control measures: Zinc phosphide Life cycle of Leptospirosis: {{caption_text}}

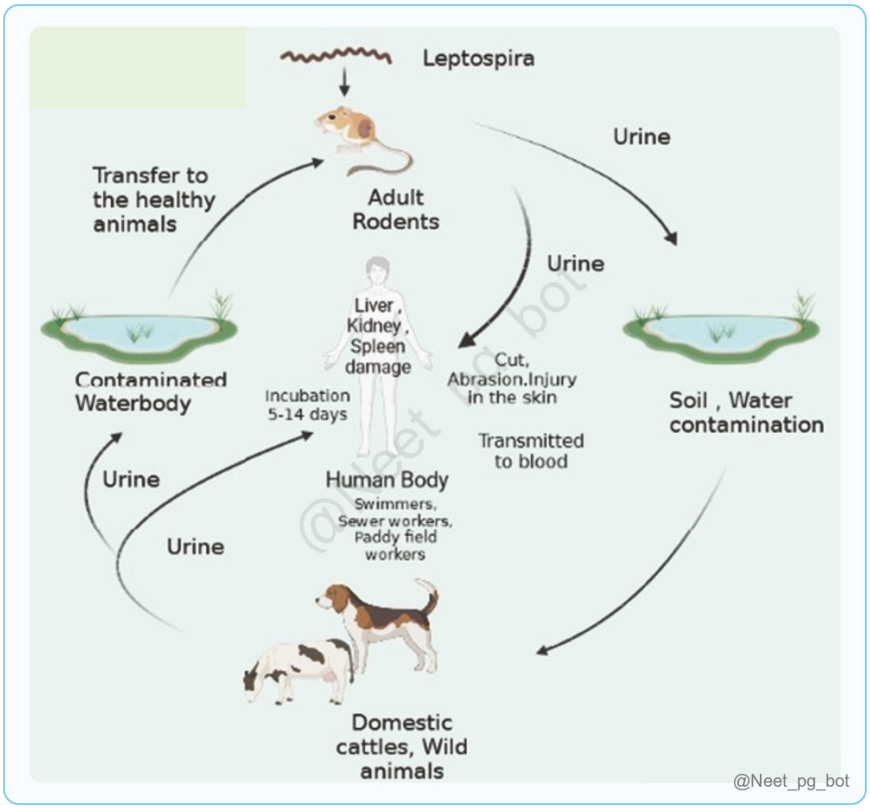

References:

Harrison’s Principles of Internal Medicine, 21st edition, Page 1417

Park’s Textbook of Preventive and Social Medicine 27th edition, Page 338, 339

↑ *Back to this question in Part A*

@Neet_pg_bot

Q14: Which of the following is false about Mycoplasma pneumoniae? (Q856293)

A. Responds well to Amoxiclav

B. Antibodies are useful in diagnosis

C. Chest X-ray shows bilateral infiltrates

D. Can be cultured in a cell-free medium

Correct Answer: A. Responds well to Amoxiclav

Explanation: Amoxiclav, which is a combination of amoxicillin and clavulanic acid, is not considered a first-line treatment for Mycoplasma pneumonia. The drug of choice for Mycoplasma pneumoniae is Azithromycin. Atypical Pneumonia (Walking Pneumonia) Definition Atypical pneumonia is a milder form of pneumonia, often caused by Mycoplasma pneumoniae, certain viruses, or moulds. Symptoms Cough, fever, chest pain, headache, and chills, resembling a bad cold. As it is generally mild, not requiring bed rest or hospitalization, allowing people to continue daily activities called "walking pneumonia." Etiologic Agents Atypical pneumonia is caused by organisms that don't grow on standard cultures or appear on Gram stain , such as: Mycoplasma pneumonia (associated with closed living conditions like at school and military barracks) Chlamydia pneumoniae Legionella species (from stagnant water sources or from air conditioners) Respiratory viruses: Influenza, adenoviruses, respiratory syncytial virus (RSV), human metapneumoviruses, and coronaviruses (e.g., SARS-CoV-2) Prevalence Cases of atypical pneumonia are increasing, particularly among young adults. Diagnosis These pathogens cannot be cultured in the usual ways, making diagnosis more complex. Mycoplasma pneumoniae is a unique bacterium that lacks a cell wall and requires a specialized cell-free medium for culture (Option D) as it cannot be grown on conventional culture media. Detection of specific antibodies (Option B) (IgM and IgG) against Mycoplasma pneumoniae, can be helpful in confirming the diagnosis. PCR and other molecular methods are often necessary for confirmation. Radiology Chest X-ray findings in Mycoplasma pneumonia can vary, but bilateral infiltrates (Option C) are commonly seen. Infiltrates may appear as patchy or diffuse opacities in both lungs. However, chest X-ray findings alone cannot definitively diagnose Mycoplasma pneumonia and should be correlated with clinical symptoms and other diagnostic tests. Treatment The absence of a cell wall makes these organisms resistant to certain antibiotics that target cell wall synthesis, such as penicillins and cephalosporins and require treatment with macrolides like azithromycin, and fluoroquinolones, or tetracyclines like doxycycline.

References:

Harrison’s Principles of Internal Medicine, 21st edition, Page 1010, 1011, 1253, 1441, 1452

Walking pneumonia

https://www.ncbi.nlm.nih.gov/books/NBK532239/

https://www.ncbi.nlm.nih.gov/books/NBK534295/

↑ *Back to this question in Part A*

@Neet_pg_bot

Q15: An HIV-positive patient presents with the following finding. What is the diagnosis & WHO clinical stage of HIV? (Q859754)

A. Oral candidiasis & WHO stage 2

B. Oral hairy leukoplakia & WHO Stage 3

C. Oral candidiasis & WHO stage 3

D. Oral hairy leukoplakia & WHO stage 2



Correct Answer: C. Oral candidiasis & WHO stage 3

Explanation: The lesion shown in the picture is that of oral candidiasis and according to WHO, HIV with oral candidiasis or thrush is categorized as clinical stage 3. Complications of HIV/AIDS Gastrointestinal tract Candidiasis {{caption_text}} Oral, Esophageal and Tracheal candidiasis Presents with odynophagia Treatment: IV fluconazole Black hairy tongue {{caption_text}} Due to the Ebstein-Barr virus. Chronic diarrhoea Due to Cryptosporidium or Isospora Belli Investigation: Microscopy reveals Cyst < 10 µm - Cryptosporidium Larger cyst - Isospora belli Treatment Cryptosporidium: Nitazoxanide Isospora: Cotrimoxazole Neoplastic diseases Kaposi sarcoma {{caption_text}} Due to HHV-8 Vascular tumours on the skin, mucus membrane or organs Non-Hodgkin's lymphoma Immunoblastic lymphoma Burkitt’s lymphoma Primary CNS lymphoma Respiratory system Pneumocystis pneumonia Due to pneumocystis jirovecii Presents with non-productive cough, fever and weight loss Investigation CXR: Bilateral perihilar opacities Beta-1,3-glucan test positive Broncho-alveolar Lavage (BAL): Giemsa staining or methenamine staining shows oval-shaped fungi. Treatment: Trimethoprim-sulfamethoxazole Others Renal HIV associated Nephropathy CVS Myocardial infarction, cardiomyopathy WHO clinical staging of HIV Stage 1 Asymptomatic Persistent generalized lymphadenopathy Stage 2 Unexplained moderate weight loss (< 10% of body weight) Recurrent upper respiratory tract infections Herpes zoster Angular cheilitis Recurrent oral ulceration Papular pruritic eruptions Seborrhoeic dermatitis Fungal nail infections Stage 3 Unexplained severe weight loss (> 10% of body weight) Unexplained chronic diarrhoea for > 1 month Unexplained persistent fever (> 37.5°C for > 1 month) Persistent oral candidiasis Oral hairy leucoplakia Pulmonary tuberculosis Severe bacterial infections Acute necrotising ulcerative stomatitis, gingivitis or

periodontitis Unexplained anaemia (< 80 g/L (8 g/dL)), neutropenia (< 0.5 × 109 /L) and/or chronic thrombocytopenia (< 50 × 109 /L) Stage 4 Candidiasis of oesophagus, trachea, bronchi or lungs Cervical carcinoma – invasive Cryptococcosis – extrapulmonary Cryptosporidiosis, chronic (> 1 month) Cytomegalovirus disease (outside liver, spleen and nodes) Herpes simplex chronic (> 1 month) ulcers or visceral HIV encephalopathy HIV wasting syndrome Cystoisosporiasis (formerly known as isosporiasis), chronic (> 1 month) Kaposi's sarcoma Lymphoma (cerebral or B-cell non-Hodgkin) Mycobacterial infection, non-tuberculous, extrapulmonary or disseminated Mycosis – disseminated endemic (e.g. coccidioidomycosis, talaromycosis (formerly penicilliosis), histoplasmosis) Pneumocystis pneumonia Pneumonia, recurrent bacterial Progressive multifocal leukoencephalopathy Toxoplasmosis – cerebral Tuberculosis – extrapulmonary (CDC includes pulmonary) Sepsis, recurrent (including non-typhoidal Salmonella) (CDC only includes Salmonella) Symptomatic HIV-associated nephropathy Symptomatic HIV-associated cardiomyopathy Leishmaniasis, atypical disseminated Options A, B, and D are incorrect.

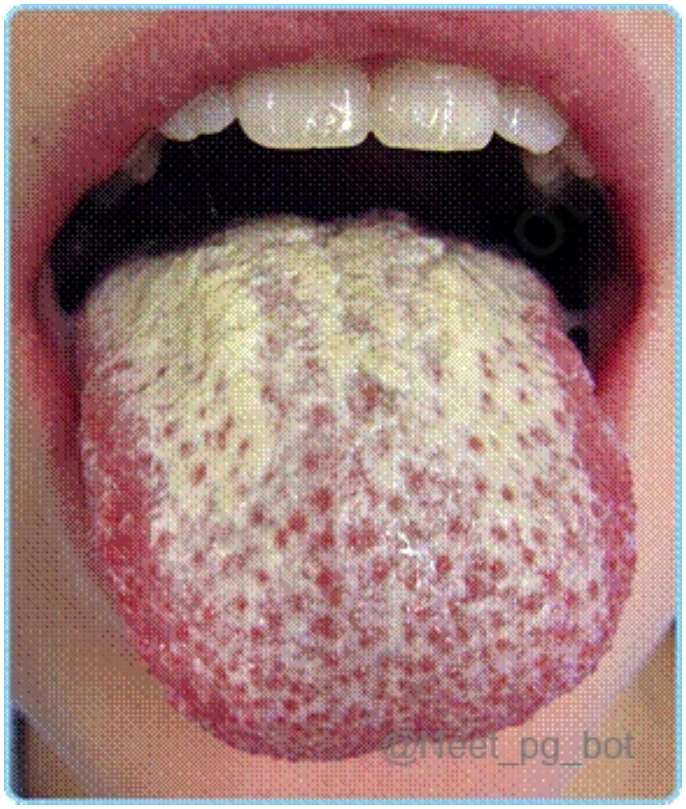





References:

Davidson’s Principles and Practice of Medicine, 24th Edition, Page: 307.

Harrison’s Principles of Internal Medicine, 21st Edition, Page: 1568-1584.

↑ *Back to this question in Part A*

@Neet_pg_bot

Q16: As seen below, a 49-year-old man presents with flu-like symptoms and a palmoplantar rash. On examination, he has epitrochlear lymphadenopathy. Which of the following is the likely diagnosis? (Q859759)

A. Primary syphilis

B. Secondary syphilis

C. Pyoderma gangrenosum

D. Steven Johnson syndrome



Correct Answer: B. Secondary syphilis

Explanation: The classical rash and other symptoms point to the diagnosis of secondary syphilis . Classic Manifestations of secondary syphilis: Mucocutaneous or cutaneous lesions and generalized non-tender lymphadenopathy. The primary chancre may still be present in ~15% of cases, more common in HIV-infected individuals. Skin Rash: Macular, papular, papulosquamous, and occasionally pustular syphilides. Lesions may be subtle, and 25% of patients with a visible rash may not recognize it. Lesions initially present as pale red or pink,

non-pruritic macules on the trunk/extremities. Progress to papular lesions, often affecting palms and soles. Severe necrotic lesions (lues maligna) may occur in HIV patients. Hair and Mucosal Involvement: Patchy alopecia of the scalp, eyebrows, or beard in 5% of cases. Condylomata lata (moist, infectious lesions) may form in intertriginous areas (e.g., perianal, vulva, scrotum) in 10% of cases. Mucous patches (painless silver-grey erosions) occur in 10-15% of patients, commonly in the oral or genital mucosa. Constitutional Symptoms: Sore throat (15–30%), fever (5–8%), weight loss (2–20%), malaise (25%), anorexia (2–10%), headache (10%), and meningismus (5%). Acute meningitis occurs in 1-2% of cases, with up to 40% of early syphilis cases showing CSF abnormalities. Ocular and Otic Involvement: Ocular symptoms: pupillary abnormalities, optic neuritis, iritis, or uveitis; may lead to permanent blindness if untreated. Otic symptoms: sensorineural hearing loss, vertigo, or tinnitus. Prompt diagnosis and treatment are crucial for preventing long-term damage. Less Common Complications: Hepatitis, nephropathy, gastrointestinal issues (e.g., hypertrophic gastritis, proctitis), arthritis, and periostitis. Hepatic involvement is common but typically asymptomatic. Renal involvement results from immune complex deposition, leading to proteinuria and nephrotic syndrome. Resolution: Most secondary syphilis manifestations resolve spontaneously within 1–6 months. Options A, C and D are incorrect.

References:

Harrison’s Principles of Internal Medicine, 21st Edition, Page: 1408, 1409.

↑ *Back to this question in Part A*

@Neet_pg_bot

Q17: A patient diagnosed to be retro-positive was started on highly active antiretroviral therapy (HAART). Which of the following can be used to monitor treatment efficacy? (Q855853)

A. CD4+ T cell count

B. Viral load

C. p24 antigen

D. Viral serotype

Correct Answer: B. Viral load

Explanation: Viral load (HIV RNA levels) is the most reliable parameter for monitoring the efficacy of Highly Active Antiretroviral Therapy (HAART). It reflects the amount of active virus in the bloodstream and is the primary marker for assessing viral suppression. A tenfold reduction in viral load is typically expected within 1-2 months of HAART initiation, and the goal is to achieve viral load levels of <50 copies/mL within 6 months. CD4+ T Cell Count (Option A): Although an increase in CD4+ count reflects immune recovery, it is less sensitive than the viral load for assessing early response to HAART. CD4+ count is better for staging disease progression or assessing immune status, rather than directly evaluating HAART efficacy. p24 Antigen (Option C): The p24 antigen is a core protein of the HIV capsid, used primarily in early diagnosis before seroconversion. It is not a marker for ongoing treatment efficacy. Viral Serotype (Option D): The viral serotype is irrelevant for treatment

monitoring, as most cases of HIV are caused by HIV-1.

References:

Harrison's Principles of Internal Medicine, 21st Edition, Page: 1527, 1529, 1586, 1591, 1592, 1594.

NCBI Article

↑ *Back to this question in Part A*

@Neet_pg_bot

Q18: A patient presents with a fever for 4 days. There are no bleeding manifestations, and vitals are stable. Workup shows Hb = 9 g/dl, platelet count - 20,000/mm³. What is the next appropriate step in management in 1st hour PCM Antibiotic Platelets transfusion Steroids (Q879177)

A. 1,2,3,4

B. 1,2,3

C. 1,2

D. 1

Correct Answer: D. 1

Explanation: A patient with fever for 4 days, stable vitals, and thrombocytopenia (platelet count = 20,000/mm³) without any bleeding manifestations most likely has viral fever (e.g., dengue) or another self-limiting viral illness causing transient bone marrow suppression. Paracetamol is given for symptomatic relief of fever in the first hour of management. NSAIDs (like ibuprofen or aspirin) are avoided, as they can worsen bleeding risk in thrombocytopenia. Platelet transfusion is not indicated unless there is active bleeding or a platelet count <10,000/mm³ (prophylactically). Antibiotics are not indicated empirically unless there is evidence of bacterial infection (e.g., toxic appearance, hypotension, or localising signs). There is no role of steroids in uncomplicated viral fever or thrombocytopenia.

References:

Harrison’s Principles of Internal Medicine, 21st Edition, Page 784.

↑ *Back to this question in Part A*

@Neet_pg_bot

Q19: What immunological abnormality is observed due to the absence of CD40 in B cells? (Q857281)

A. Total lack of NK cells

B. Lack of CD8-mediated cytotoxicity

C. Decreased IgG and increase in IgM

D. Inability of neutrophils to act against infections

Correct Answer: C. Decreased IgG and increase in IgM

Explanation: auses: Results from various X-linked or autosomal mutations. Clinical Manifestations: Pulmonary complications (e.g., infections) Gastrointestinal issues Autoimmune diseases Hematologic abnormalities Lymphoproliferation Increased risk of malignancies Diagnosis: Based on immunoglobulin levels and genetic testing. Management: Treatment varies depending on the genetic mutation and clinical presentation. Options may include immunoglobulin replacement therapy, antibiotics, and management of associated complications. Prognosis: Depends on the severity of symptoms and timely treatment, but early diagnosis and management can improve outcomes. A total lack of NK cells (Option A) or natural killer deficiency is a rare genetic disorder that has a genetic mechanism causing it. This is not associated with hyper IgM syndrome. Lack of CD8-mediated cytotoxicity (Option B) can be as a result of many chronic autoimmune diseases (like multiple sclerosis, rheumatoid arthritis, SLE, etc). It can also be seen in healthy blood relatives of people with autoimmune disorders. However, it is not associated with increased IgM production. The inability of neutrophils to act against infections (Option D) is not associated with the absence of CD40 ligand of B cells.

References:

https://pubmed.ncbi.nlm.nih.gov/30439505/

↑ *Back to this question in Part A*

@Neet_pg_bot

Q20: A HIV-positive patient presents with chronic diarrhoea for 4 weeks. Stool microscopy shows oval/ elliptical cysts measuring 16 X 20 µm. Diagnosis is? (Q866800)

A. Cryptosporidium

B. Cryptococcus

C. Cyclospora

D. Cystoisospora

Correct Answer: D. Cystoisospora

Explanation: Cystoisospora (formerly Isospora belli) causes chronic diarrhea in immunocompromised patients like those with HIV. Its oocysts are oval/elliptical, acid-fast, and measure around 20–30 µm (commonly ~16 × 20 µm). Cystoisospora belli infection leads to malabsorptive diarrhea, often chronic in HIV patients. Diagnosis is made via stool microscopy or modified acid-fast staining, showing large oval oocysts. The organism is transmitted via ingestion of sporulated oocysts in contaminated food or water. Treatment typically involves trimethoprim-sulfamethoxazole (TMP-SMX). Opportunistic Protozoal GI infections in HIV: Feature Cryptosporidium Cyclospora Cystoisospora Size 4-6 µ 8-12 µ 24-36 µ Shape Round Round Oval Acid fast (Coccidian cold ZN stain/Kinyoung) + Variable +/- + Autofluorescence - + + Treatment Nitazoxanide Cotrimoxazole Cotrimoxazole Incorrect Options: Cryptosporidium (Option A): Much smaller oocysts (4–6 µm); typically causes acute watery diarrhea. Cryptococcus (Option B): A fungus, not a protozoan; causes meningitis, not diarrhea. Cyclospora (Option C): Smaller oocysts (8–10 µm) and more spherical.

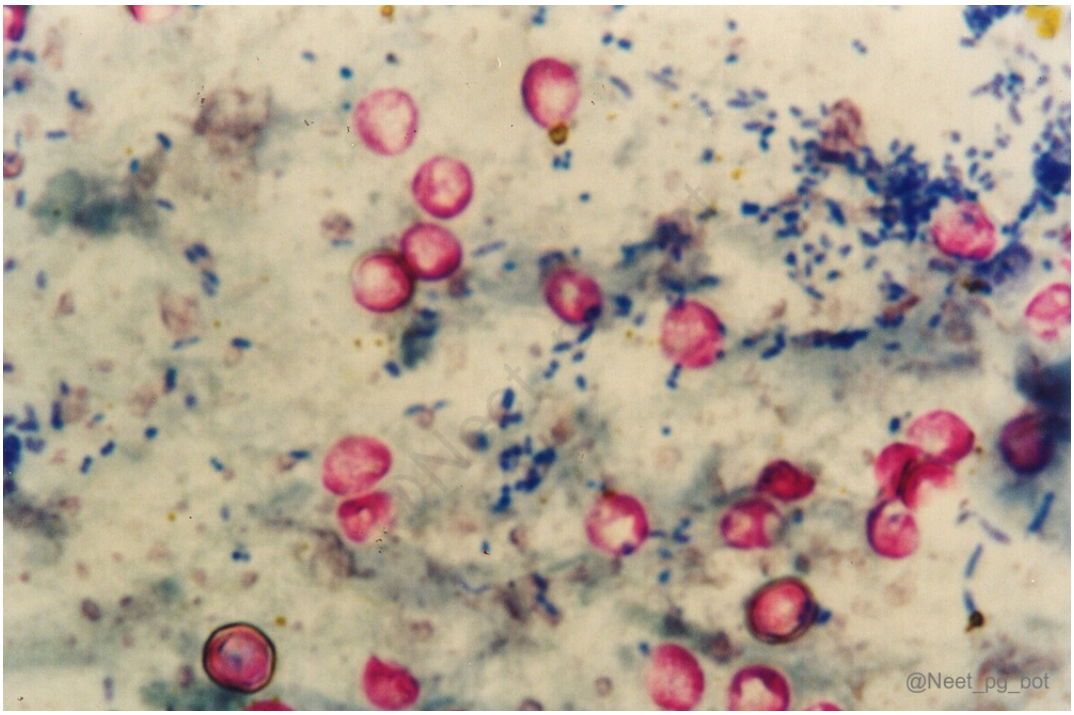

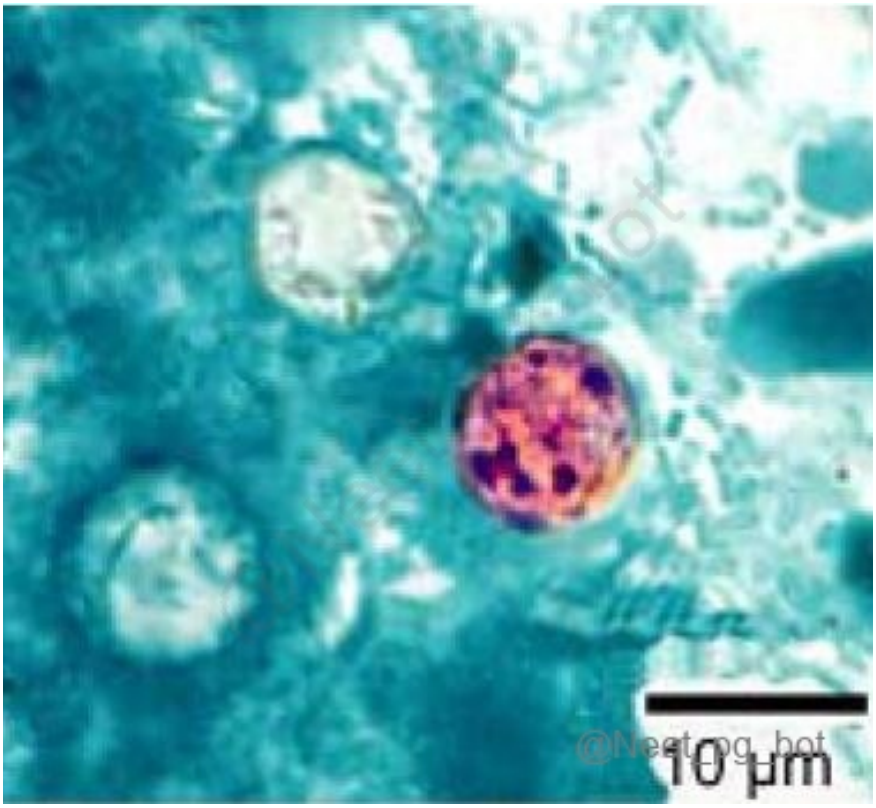



↑ *Back to this question in Part A*

@Neet_pg_bot

Q21: A 35-year-old farmer presents with intermittent fever, profuse sweating, fatigue, and arthralgia for 3 weeks. He reports handling livestock and consuming unpasteurized dairy products. Mild hepatosplenomegaly is noted. Blood cultures reveal Brucella species. Which of the following is the most appropriate antimicrobial therapy? (Q866824)

A. Doxycycline alone

B. Doxycycline plus rifampicin

C. Doxycycline with azithromycin

D. Doxycycline plus ceftriaxone

Correct Answer: B. Doxycycline plus rifampicin

Explanation: Brucellosis (undulant fever) is caused by Brucella species, often from livestock exposure or unpasteurized dairy. Doxycycline inhibits bacterial protein synthesis, while Rifampicin blocks RNA synthesis, acting synergistically. Combination therapy reduces relapse rates compared to monotherapy. Treatment is given for 6 weeks to eradicate both intracellular and extracellular bacteria. It prevents chronic complications like spondylitis and endocarditis. This regimen is the WHO-recommended first-line therapy for uncomplicated adult brucellosis. Incorrect answers: Option A) Doxycycline alone: Higher relapse rate due to monotherapy; insufficient for intracellular bacteria. Option C) Doxycycline + Azithromycin: Not first-line; limited evidence for efficacy in brucellosis. Option D) Doxycycline + Ceftriaxone: Reserved for complicated cases like neurobrucellosis; unnecessary in uncomplicated cases.

↑ *Back to this question in Part A*

@Neet_pg_bot

Q22: 30 year old man presents with severe headache, fever for one day with altered sensorium. Nuchal rigidity is absent. Guarded LP was done and CSF shows 50 cells with 20% neutrophils and 80% lymphocytes with CSF sugar of 70 mg and RBS 100 mg/dl with protein= 90 mg/dl. Diagnosis is? (Q866829)

A. Viral encephalitis

B. Acute bacterial meningitis

C. Tubercular Meningitis

D. Viral meningitis

Correct Answer: A. Viral encephalitis

Explanation: - Viral encephalitis: Viral encephalitis typically presents with acute fever, severe headache, and altered sensorium, with minimal or absent meningeal signs. CSF shows mild lymphocytic pleocytosis, normal glucose, and mildly elevated protein, as seen here (50 cells, 80% lymphocytes, normal CSF sugar). Absence of nuchal rigidity further supports parenchymal brain involvement rather than meningitis. Incorrect Options: Option B - Acute bacterial meningitis: Typically presents with neutrophilic pleocytosis, markedly elevated protein, and low CSF glucose. Altered sensorium may occur, but CSF findings here are not suggestive. Option C - Tubercular meningitis: Characterized by a subacute onset, lymphocytic CSF with very high protein and low CSF glucose. The acute presentation and normal glucose make TB meningitis unlikely. Option D - Viral meningitis: Viral meningitis presents with prominent meningeal signs (neck stiffness) and usually preserved sensorium. Altered mental status points more toward encephalitis.

References:

.

↑ *Back to this question in Part A*

@Neet_pg_bot

Q23: A patient underwent cardiac surgery and was admitted to the ICU. He later developed ventilator-associated pneumonia (VAP) and was started on empirical antibiotics. A few hours later, the patient developed acute kidney injury (AKI). Serum procalcitonin was sent. Which of the following statements regarding procalcitonin is correct? (Q865372)

A. It helps in determining the duration of antibiotic therapy

B. It helps in identifying which empirical antibiotics to be given

C. It can be used to confirm source of infection

D. It is used to differentiate bacterial from fungal cause

Correct Answer: A. It helps in determining the duration of antibiotic therapy

Explanation: Procalcitonin (PCT) is widely used to guide the duration of antibiotic therapy , especially in ICU settings and conditions like ventilator-associated pneumonia (VAP). Serial PCT measurements help determine when to discontinue antibiotics , usually when PCT falls below 0.25–0.5 ng/mL or decreases by 80–90% from the peak value. Role of Procalcitonin: Helps detect bacterial infections early and differentiate from non-bacterial causes. Guides when to start or stop antibiotics based on specific cut-off values. Decreases by ~50% every 24 hours after infection control, helping monitor treatment. Differentiates between infectious and non-infectious conditions in various diseases. Reduces unnecessary antibiotic use in respiratory, postoperative, and other

conditions. Correlates with severity in sepsis, offering prognostic information. Used in ED and ICU algorithms to manage antibiotic timing and duration. Levels <0.1 ng/mL have high negative predictive value to rule out bacterial infections. Incorrect Options: It helps in identifying which empirical antibiotics to be given (Option B): PCT does not identify specific pathogens or recommend particular antibiotics. It only indicates the likelihood of a bacterial infection, not which organisms are involved or their sensitivity patterns. Empirical antibiotic selection is based on clinical judgment, local antibiograms, and patient risk factors. It can be used to confirm source of infection (Option C): PCT is a non-specific marker of systemic bacterial infection and cannot pinpoint the source (e.g., lungs, urinary tract, blood). Imaging and cultures are needed to confirm the anatomical site of infection. It is used to differentiate bacterial from fungal cause (Option D): While PCT can help distinguish bacterial from viral infections, it is not reliable in differentiating bacterial from fungal infections. Invasive fungal infections may not always cause elevated PCT levels, limiting its utility in such cases.

References:

Procalcitonin - StatPearls - NCBI Bookshelf

↑ *Back to this question in Part A*

@Neet_pg_bot

Q24: A 38-year-old male presents with a one-week history of fever, headache, retro-orbital pain, and myalgia. Skin examination reveals multiple purpura and petechiae on the left shoulder, trunk, and legs. Similar cases have been reported linked to increased incidence of mosquito breeding. What is the most common neurological complication associated with this condition? (Q852755)

A. Encephalopathy

B. Guillain-Barré Syndrome

C. Stroke

D. Encephalitis

Correct Answer: A. Encephalopathy

Explanation: The clinical presentation including fever, headache, retro-orbital pain, myalgia, and the presence of purpura and petechiae, suggests a viral infection consistent with dengue fever. The association with increased mosquito breeding further supports this diagnosis. Encephalopathy is the most common neurological complication associated with this condition. Dengue complications Neurological Dengue encephalopathy is most commonly encountered neurological complication of dengue virus linked primarily to dengue hemorrhagic fever and dengue shock syndrome EEG may show abnormalities such as burst suppression and seizures CSF profiles typically remain normal. Neuroimaging can be normal or reveal diffuse cerebral edema. Encephalitis GBS Stroke Cardiomyopathy Dengue virus-induced dilated cardiomyopathy should always be considered if a dengue fever patient has refractory shock and signs and symptoms of congestive heart failure. Hepatic injury Liver involvement

in dengue is a crucial feature The effect ranges from an asymptomatic rise in liver enzymes to the development of ALF The most common atypical manifestation reported was hepatitis Pneumonia Staphylococcus pneumonia is an important accompanying problem seen in dengue patient co-infection between dengue and influenza can result in exacerbation of pneumonia Orchitis Orchitis usually occurs together with epididymitis Commonly seen in men between 14 and 35 years of age. Dengue Hemorrhagic Fever All of the following: Acute onset of fever 2-7 days duration Hemorrhagic manifestations Positive tourniquet test/Petechiae Ecchymosis Purpura/Bleeding from mucosa, GIT, Injection sites, etc Platelet count ≤ 100,000 cells/cu.mm. Plasma leakage Rising hematocrit Hemoconcentration >20% Pleural effusion, ascites/Hypoproteinemia) Dengue Shock Syndrome DHF criteria plus Signs of Shock Tachycardia/Cool extremities/Weak pulse/Lethargy/Restlessness Pulse pressure <20 mm Hg with increased Diastolic pressure (e.g. 100/80) Hypotension (Systolic <80 mm Hg for age <5 years/80-90 mm Hg for older child and adults)

References:

Davidson's Principles and Practice of Medicine, 24th Edition, Page 243

https://link.springer.com/article/10.1007/s11910-022-01213-7

https://journals.lww.com/annals-of-medicine-and-surgery/fulltext/2023/02000/acute_liver_failure_in_a_young_patient_with_dengue.46.aspx#:~:text=Hepatic%20encephalopathy%20is%20usually%20corrected,prevent%20hepatotoxic%20injury23%2C24.

https://symbiosisonlinepublishing.com/pulmonology-infectious-diseases/pulmonology-infectious-diseases10.php

https://pmc.ncbi.nlm.nih.gov/articles/PMC4352732/#:~:text=Dengue%20fever%20can%20have%20varied,antivirals%2C%20immunosuppressants%2C%20and%20steroids.

https://journals.lww.com/kleu/fulltext/2016/09030/dengue_fever_presenting_as_epididymo_orchitis.15.aspx

↑ *Back to this question in Part A*

@Neet_pg_bot

Q25: A patient has pleural fluid with an LDH level greater than 0.6 times the serum LDH and protein greater than 0.5 times the serum protein. What is the most likely diagnosis? (Q844266)

A. Tuberculosis (TB)

B. Heart failure

C. Hepatic failure

D. Renal failure

Correct Answer: A. Tuberculosis (TB)

Explanation: Correct Option A - Tuberculosis (TB): The pleural fluid analysis shows an LDH level greater than 0.6 times the serum LDH and protein greater than 0.5 times the serum protein, which are criteria for an exudative pleural effusion according to Light's criteria. Tuberculosis is a common cause of exudative pleural effusion, especially in areas where TB is prevalent. Exudative effusions occur due to increased capillary permeability or lymphatic obstruction, and they are often associated with infections, malignancies, and inflammatory conditions like TB. Incorrect Options: Option B - Heart failure: Heart failure typically causes a transudative pleural effusion, which is characterized by lower protein and LDH levels in the pleural fluid relative to serum levels. This option is incorrect because the fluid described meets the criteria for an exudative effusion, not a transudative one. Option C - Hepatic failure: Hepatic failure (such as in cirrhosis) usually causes a transudative pleural effusion due to low oncotic pressure from hypoalbuminemia, not an exudative effusion. Therefore, it is not the most likely diagnosis in this scenario. Option D - Renal failure: Renal failure can cause pleural effusions, but they are typically transudative unless complicated by infections or other factors. The described pleural fluid characteristics are more consistent with an exudative process.

↑ *Back to this question in Part A*

@Neet_pg_bot

Q26: What is the investigation of choice for detecting enteric fever in the first week? (Q860128)

A. Blood culture

B. Urine culture

C. Stool culture

D. Antibody detection

Correct Answer: A. Blood culture

Explanation: Blood culture is the most sensitive diagnostic modality for early detection of enteric fever , as Salmonella typhi or Salmonella paratyphi are present in the bloodstream during the initial phase of infection. Duration of Disease Specimen Examination % Positivity 1st week Blood culture 90% 2nd week Blood culture Faeces culture Widal test 75% 50% Low Titre 3rd week Widal test Blood culture Faeces culture 80-100% 60% 80% 4th week Urine Culture 25-40% Urine culture (Option B): This test becomes relevant only in the fourth week of illness when bacteria begin to be excreted in the urine. By this time, the disease has already progressed significantly, making it unsuitable for early diagnosis. Stool culture (Option C): This investigation typically becomes positive in the third week of illness when bacteria are shed in the feces. It is not useful for early diagnosis as bacterial shedding in stool occurs later in the disease course. Antibody detection (Option D): The Widal test for antibody detection is generally performed in the second week of illness, as antibodies take time to develop. The test has low sensitivity and specificity in the first week.

References:

Harrison's Principles of Internal Medicine, 21th Edition, Pages 1292-1295

↑ *Back to this question in Part A*

@Neet_pg_bot

Q27: Which of the microorganisms listed below will exhibit intrinsic resistance to meropenem and aminoglycosides, but have sensitivity to cotrimoxazole? (Q857273)

A. Burkholderia cepacia

B. Acinetobacter

C. Pseudomonas

D. Stenotrophomonas

Correct Answer: D. Stenotrophomonas

Explanation: hronic respiratory diseases (e.g., cystic fibrosis) Hematologic malignancies, chemotherapy-induced neutropenia Organ transplants, HIV infection, hemodialysis, neonates Hospital settings, ICU stays, mechanical ventilation, tracheostomies Central venous catheters, severe burns, trauma, mucosal damage, and prolonged antibiotic use increase the risk. Management: First-line treatment: Trimethoprim-sulfamethoxazole (TMP-SMX) (co-trimoxazole) at high doses (15 mg/kg of trimethoprim component). Alternative treatments: Fluoroquinolones (e.g., levofloxacin, moxifloxacin) have good efficacy, particularly in lung infections. Minocycline and tigecycline show high effectiveness (80-100% susceptibility). Ticarcillin-clavulanic acid, ceftazidime, colistin, and chloramphenicol can be considered. Emerging treatments: New agents like Cefiderocol, Eravacycline, Omadacycline, and Delafloxacin show promising in-vitro activity. Combination therapies (e.g., TMP-SMX/ciprofloxacin, ticarcillin-clavulanate/aztreonam) have demonstrated synergistic effects. Challenges: Resistance to many common antibiotics like meropenem, and aminoglycosides is rising, necessitating new treatments. Studies on aerosolized antibiotics, bacteriophage therapy, and other innovative approaches are ongoing. Duration of treatment: Pneumonia: Typically 7 days, extended to 10-14 days in immunocompromised patients. Bacteremia: Generally treated for 14 days. Source control: Surgical removal of infected devices (e.g., central venous catheters) and drainage of infected collections is critical for successful treatment. Option A, B, and C: These organisms are susceptible to meropenem and aminoglycosides.

References:

https://www.ncbi.nlm.nih.gov/books/NBK572123/

↑ *Back to this question in Part A*

@Neet_pg_bot

Q28: In a patient with HIV, the incorrect statement regarding prophylaxis for various organisms is: (PCP-Pneumocystis pneumonia, MAC-Mycobacterium avium complex)

(Q854659)

A. Prophylaxis for PCP is indicated when CD4 count is <200 cells/µL

B. Stop prophylaxis for Coccidioides if CD4 count is >250 cells/µL for 6 months

C. Prophylaxis for MAC is indicated when CD4 count is <50 cells /µL

D. Prophylaxis for cryptococcus is indicated when the CD4 count is >150 cells/µL

Correct Answer: D. Prophylaxis for cryptococcus is indicated when the CD4 count is >150 cells/µL

Explanation: Prophylaxis for cryptococcus is indicated when the CD4+ count is < 250/µL. Pathogen Indication Treatment Pneumocystis jirovecii CD4 + < 200/µL (Option A) May stop if CD4+ >200/µL for >/=3 months DOC : TMP-SMX Trimethoprim-sulfamethoxazole Alternative : Dapsone + Pyrimethamine + Leucovorin Mycobacterium Avium Complex CD4+ < 50/µL and no prior h/o MAC (Option C) DOC : Azithromycin or Clarithromycin (Monotherapy) Alternative: Rifabutin CD4+ < 50/µL and Prior h/o MAC DOC : Clarithromycin + Ethambutol Alternative : Azithromycin + Ethambutol Toxoplasma gondii TOXO IgG +ve CD4 + < 100/µL DOC : TMP-SMX Trimethoprim-sulfamethoxazole Alternative :Dapsone + Pyrimethamine + Leucovorin H/O Toxoplasmic encephalitis CD4 + < 200/µL DOC : Sulfadiazine + Pyrimethamine + Leucovorin Alternative : Clindamycin + Pyrimethamine + Leucovorin Mycobacterium tuberculosis PPD>5 mm IGRA +ve Contact with active TB DOC : Isoniazid + Pyridoxine - x 9 months Alternative : Rifabutin or Rifampin CMV CD4+ < 100/µL Prior infection DOC : Valacyclovir Alternative : Foscarnet Cryptococcus Coccidioides Positive serology CD4+ < 150/µL (vs Option D) Endemic zone May stop if CD4+ ≥250/µL for >6 months (Option B) Fluconazole Histoplasmosis CD4+ < 150/µL Endemic zone May stop if CD4+ >150/µL and cART for ≥6 months Itraconazole Salmonella Recurrent infections Ciprofloxacin Bartonella CD4+ < 200/µL Prior infection Doxycycline or Azithromycin

References:

Harrison’s Principles of Internal Medicine, 21st Edition, Page: 1563, 1564.

↑ *Back to this question in Part A*

@Neet_pg_bot

Q29: A 30-year-old HIV-positive man presents with neck rigidity and papilledema. His CSF sample showed a capsulated organism positive for India ink staining. Which of the following statements is true? (Q854680)

A. Intracranial pressure remains normal

B. Delay antiretroviral therapy by 4-6 weeks after the initiation of antifungal treatment

C. Initiate treatment with oral fluconazole

D. Brain imaging shows changes in > 80 % of patients

Correct Answer: B. Delay antiretroviral therapy by 4-6 weeks after the initiation of antifungal treatment

Explanation: The patient has signs and symptoms of meningitis, which, along with the positive India ink stain leads to the diagnosis of Cryptococcal meningitis, which is a CNS complication of HIV occurring due to opportunistic infection by Cryptococcus neoformans. Fungal Meningitis in AIDS The leading cause of meningitis in AIDS patients is primarily Cryptococcus neoformans (C. neoformans), with C. gattii accounting for up to 12% of cases. Cryptococcal meningitis is common in patients with CD4+ T-cell counts <100/µL, especially in untreated AIDS patients. Symptoms: Subacute meningoencephalitis with fever, nausea, vomiting, altered mental status, headache, and meningeal signs Seizures and focal neurologic deficits are rare Elevated intracranial pressure (Option A) CSF Findings: Mild increase in WBCs and protein Low glucose Elevated opening pressure Diagnosis: CSF: Positive India ink examination Cryptococcal antigen detection in CSF Blood cultures may also be positive A biopsy may be needed for CNS cryptococcoma or distinguishing from immune reconstitution syndrome MRI: Soap bubble appearance is seen in less than 30% of cases (Option D) Treatment: Initial: IV Amphotericin B with Flucytosine for at least 2 weeks. (Option C) Continued with Amphotericin until CSF culture is negative, followed by Fluconazole (400 mg/d) for 8 weeks and then 200 mg/d until CD4+ T-cell count >200/µL for 6 months. Repeated lumbar punctures may be needed to manage elevated intracranial pressure. Immune Reconstitution Syndrome : Occurs after initiating effective ART, leading to worsening of pre-existing opportunistic infections or autoimmune conditions. Types of IRIS: Paradoxical IRIS: Exacerbation of known pre-existing infections or neoplasms. Unmasking IRIS: Emergence of previously undiagnosed conditions. Immune Reconstitution Disease (IRD) : Refers to IRIS related to opportunistic infections or autoimmune diseases. Symptoms : Lymphadenitis Prolonged fever Pulmonary infiltrates Hepatitis Increased intracranial pressure Uveitis Sarcoidosis Graves' disease Mechanism : Related to type IV hypersensitivity reactions due to immune recovery as HIV RNA levels drop and immune suppression is reversed. Management : Severe cases may require immunosuppressive drugs (e.g., glucocorticoids) alongside specific antimicrobial therapy. Due to the risk of IRIS (immune reconstitution inflammatory syndrome), ART should be deferred by 4-6 weeks after the initiation of antifungal treatment. Other Causes: Other fungi like C. immitis and H. capsulatum , as well as amoebas like Acanthamoeba and Naegleria , can cause meningitis in HIV-infected individuals.

References:

Harrison's Principles of Internal Medicine, 21st Edition, Page: 1574, 1576, 1577.

↑ *Back to this question in Part A*

@Neet_pg_bot

Q30: A 30-year-old farmer from Tamil Nadu presented with fever, myalgia, headache and cough. On physical examination, a lesion is seen on the chest. Lung auscultation shows extensive bilateral rales. Blood investigation showed positive IgM for scrub typhus. What would be the appropriate treatment? (Q854699)

A. Doxycycline

B. Doxycycline with Ceftriaxone

C. Ceftriaxone with Azithromycin

D. Doxycycline with Azithromycin



Correct Answer: D. Doxycycline with Azithromycin

Explanation: The patient is from a scrub typhus–endemic region (Tamil Nadu) and presents with fever, myalgia, cough, bilateral rales , and a characteristic eschar , along with positive IgM —confirming scrub typhus caused by Orientia tsutsugamushi. Recent evidence shows that combination therapy provides: Faster fever clearance Better response in severe/complicated scrub typhus Benefit in areas with emerging doxycycline resistance Therefore, IV doxycycline + azithromycin is preferred over monotherapy in moderate–severe disease. Option B and C are incorrect.

References:

https://pubmed.ncbi.nlm.nih.gov/36856615/

https://www.ncbi.nlm.nih.gov/books/NBK558901/

↑ *Back to this question in Part A*

@Neet_pg_bot

Q31: A 50-year-old HIV patient presented with a painful lesion, as shown in the image. What is the most likely diagnosis? (Q855448)

A. Basal cell carcinoma

B. Kaposi sarcoma

C. Malignant melanoma

D. Squamous cell carcinoma

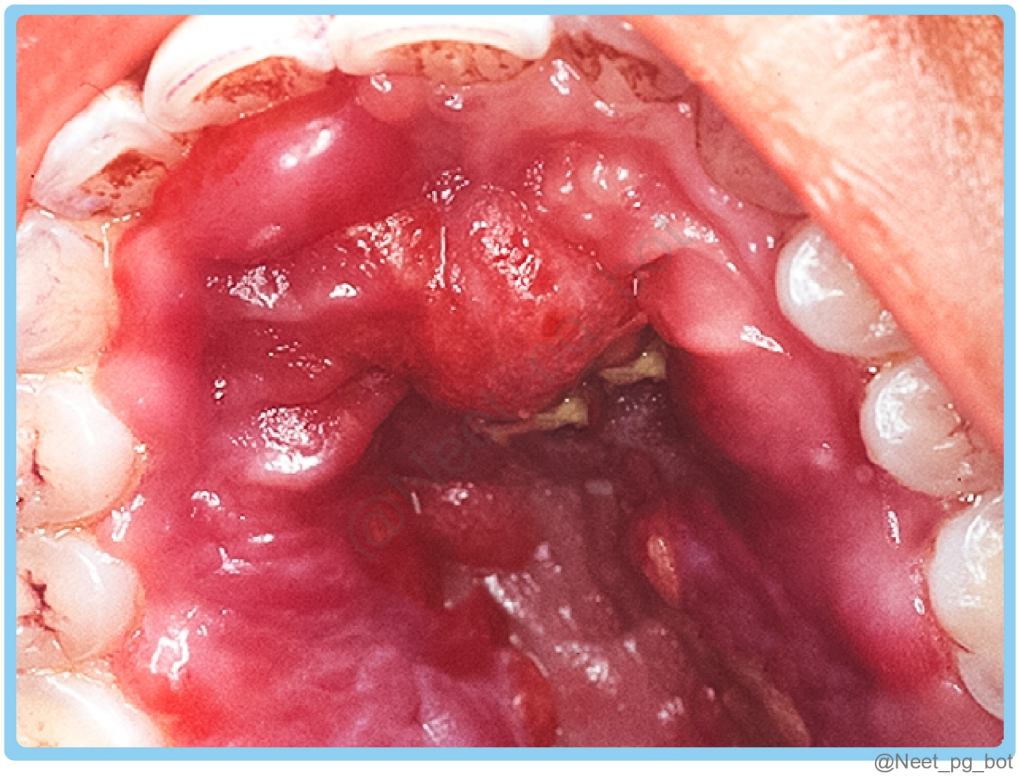

Correct Answer: B. Kaposi sarcoma

Explanation: linical Stages: Patch Stage: Flat, pink or red lesions. Plaque Stage: Raised, purple or brown lesions. Nodular Stage: Firm, raised nodules, may ulcerate. Variants: Classic KS: Affects elderly men of Mediterranean or Eastern European descent. Endemic KS: Common in sub-Saharan Africa, affecting younger individuals. Transplant-associated KS: Seen in organ transplant recipients on immunosuppressive therapy. AIDS-associated KS: Seen in HIV-positive individuals, especially those with low CD4 counts. Pathophysiology: Caused by HHV-8, which infects endothelial cells, leading to angiogenesis and tumor growth. Diagnosis: Confirmed by biopsy showing spindle-shaped cells, angiogenesis, and extravasated red blood cells. PCR or serology for HHV-8 can be used for detection. Management: ART: Restores immune function in HIV/AIDS, reducing KS lesions. Chemotherapy: Liposome-encapsulated doxorubicin or paclitaxel for advanced KS. Radiotherapy: Effective for localized lesions. Surgical Treatment: Cryotherapy or excision for small lesions. Basal cell carcinoma (Option A): This skin cancer typically presents as a pearly, nodular lesion, usually on sun-exposed areas, and does not have the violaceous coloration seen in Kaposi sarcoma. Malignant melanoma (Option C): Malignant melanoma often presents as dark, irregularly pigmented lesions with asymmetry, and is not characteristic of the violaceous macules seen in this case. Squamous cell carcinoma (Option D): Squamous cell carcinoma can occur in the oral cavity but usually appears as an ulcerative lesion or growth with a hard, raised edge, not as violaceous macules or plaques.

References:

Robbins and Cotran Pathologic Basis of Disease, 10th Edition, Page: 520-522. PubMed - 23679875

↑ *Back to this question in Part A*

@Neet_pg_bot

Q32: A 45-year-old HIV-positive male came with complaints of persistent cough and weight loss. He has skin lesions that appear as umbilicated papules and nodules predominantly on the face, trunk, and upper extremities. Chest x-ray showed multiple bilateral nodular infiltrates. His sputum CBNAAT for tuberculosis was negative and he has a low CD4 count. What is the probable diagnosis? (Q855461)

A. HIV with disseminated histoplasmosis

B. HIV with disseminated cryptococcosis

C. HIV with molluscum contagiosum

D. HIV with tuberculosis

Correct Answer: A. HIV with disseminated histoplasmosis

Explanation: The clinical presentation of a HIV-positive patient with persistent cough, weight loss, skin lesions (umbilicated papules and nodules), and bilateral nodular infiltrates on chest x-ray, along with a low CD4 count, suggests a diagnosis of disseminated histoplasmosis. Histoplasmosis A systemic fungal infection caused by Histoplasma capsulatum, a dimorphic fungus endemic in regions like the Ohio and Mississippi River valleys, Central/South America, and Africa. Pathophysiology: Acquired by inhaling fungal microconidia from contaminated soil (bird/bat droppings). Yeast forms multiply in macrophages, spreading through lymphatics and bloodstream. Immunocompromised hosts (e.g., HIV/AIDS, CD4+ <200/μL) are at higher risk of dissemination. Clinical Features: Asymptomatic: Common in immunocompetent individuals. Acute Pulmonary: Fever, cough, chest pain, flu-like symptoms. Chronic Pulmonary: Associated with COPD, presenting with cough, weight loss, and cavitary lung lesions. Progressive Disseminated Histoplasmosis (PDH): Systemic: Fever, weight loss, hepatosplenomegaly, thrombocytopenia. Lungs: Diffuse interstitial or reticulonodular infiltrates. Skin: Papules, plaques, or ulcers (~10% cases). HIV with disseminated cryptococcosis (Option B): Cryptococcosis is commonly associated with meningeal involvement in immunocompromised patients. This patient's symptoms (including the skin lesions and lung involvement) do not suggest cryptococcosis, especially as there are no signs of meningitis. HIV with molluscum contagiosum (Option C): Molluscum contagiosum is a skin infection caused by a poxvirus, typically characterized by umbilicated papules on the skin. While this patient does have skin lesions, the lung involvement and the bilateral nodular infiltrates on the chest x-ray point to a systemic fungal infection rather than a localized skin condition. HIV with tuberculosis (Option D): Tuberculosis would typically present with symptoms like cough, hemoptysis, and weight loss. However, the patient's negative sputum CBNAAT for tuberculosis and absence of granulomas on imaging make tuberculosis less likely.

References:

Harrison's Principles of Internal Medicine, 21st Edition, Page: 1658-1660.
https://www.ncbi.nlm.nih.gov/pmc/articles/PMC3687172/
https://www.ncbi.nlm.nih.gov/pmc/articles/PMC3969680/

↑ *Back to this question in Part A*

@Neet_pg_bot

Q33: An HIV-positive man presents with a high-grade fever. Examination reveals a positive Kernig's sign. CSF shows reduced glucose, increased protein, and increased leukocytes. A diagnosis of cryptococcal meningitis is made. What is the appropriate management for this patient? (Q858018)

A. Vancomycin

B. High dose fluconazole with flucytosine

C. Voriconazole

D. Liposomal amphotericin B

Correct Answer: D. Liposomal amphotericin B

Explanation: : Vancomycin is primarily used to treat bacterial infections, particularly those caused by methicillin-resistant Staphylococcus aureus (MRSA). It has no activity against Cryptococcus neoformans, and would be ineffective in treating cryptococcal meningitis. High dose fluconazole with flucytosine (Option B): While these antifungal medications are used in cryptococcal meningitis treatment, they are not the optimal initial therapy for severe cases. High-dose fluconazole with flucytosine lacks the rapid fungicidal activity of liposomal amphotericin B and is reserved for maintenance therapy or cases where amphotericin B is contraindicated. Voriconazole (Option C): Voriconazole is primarily used to treat invasive aspergillosis and other filamentous fungal infections. It is not the drug of choice for cryptococcal meningitis as it has limited evidence for efficacy against Cryptococcus neoformans compared to the standard regimen.

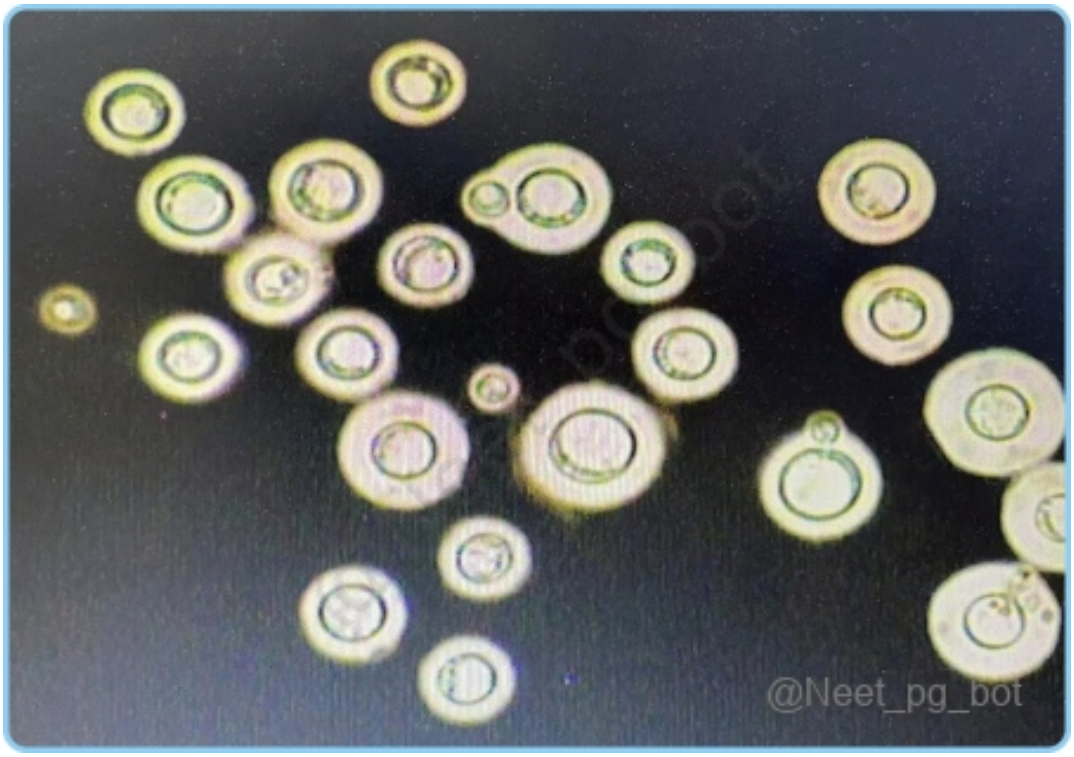

References:

Harrison’s Principles of Internal Medicine, 21st Edition, Page 1109

Davidson’s Principles and Practice of Medicine, 24th Edition, Page 1118

Cryptococcal meningitis

↑ *Back to this question in Part A*

@Neet_pg_bot

Q34: A 70-year-old patient with a smoking history presents with high-grade fever, cough, confusion, and diarrhea. Chest X-ray shows bilateral infiltrates in bilateral lower lung fields. On sputum gram stain, no organisms were detected. Laboratory results reveal Na: 126mEq/L, AST:62, ALT:56, RBS:112 mg/dl, serum bilirubin of 0.8mg%, and a positive HIV test. Which of the following organisms is responsible? (Q858022)

A. Streptococcus

B. Legionella

C. Pneumocystis jiroveci

D. Klebsiella

Correct Answer: B. Legionella

Explanation: isease General Features Incubation period: 2-10 days Non-specific flu-like symptoms initially Often more severe than typical pneumonia Clinical Features Respiratory Dry cough Shortness of breath Chest pain Systemic High fever (102-105°F) Headache Myalgias Fatigue Gastrointestinal Diarrhea Nausea/vomiting Abdominal pain Diagnosis Laboratory Tests Blood Analysis- Hyponatremia, Elevated Liver Enzymes Urinary Antigen- Most common test, rapid results, detects L. pneumophila serogroup-1 Culture- Gold standard, requires special media, takes 3-5 days PCR Imaging Findings Chest X-ray: Focal infiltrates/consolidation, predominantly lower lobes CT: Ground-glass opacities, consolidation, pleural effusions possible Can be multilobar in immunocompromised patients Treatment Mild-Moderate Disease: Azithromycin 500mg PO daily Levofloxacin 750mg PO daily Clarithromycin 500mg PO BID Severe Disease: Levofloxacin 750mg IV daily Azithromycin 500mg IV daily Consider combination therapy for severe cases Streptococcus (Option A): Streptococcus pneumoniae is a common cause of community-acquired pneumonia, but it typically presents with a productive cough with rust-colored sputum. In this case, the sputum gram stain did not detect any organisms, making Streptococcus less likely. Additionally, the extrapulmonary symptoms are not typical for pneumococcal pneumonia. Pneumocystis jiroveci (Option C): While the patient is HIV positive, the symptoms described and chest X-ray findings of bilateral infiltrates are not specific to Pneumocystis jiroveci pneumonia. PJP typically presents with a more gradual onset of dry cough and progressive dyspnea without the characteristic hyponatremia and liver enzyme elevation seen here. Also, chest X-ray shows pneumatoceles or thin-walled cysts and reticular opacities with septal thickening. Klebsiella (Option D): Klebsiella causes pneumonia in individuals with a history of alcoholism or COPD. While the patient has a smoking history, the clinical presentation (including confusion and diarrhea) is inconsistent with Klebsiella pneumonia infection. Additionally, Klebsiella would typically be visible on gram stain.

References:

Harrison's Principles of Internal Medicine, 21st Edition, Page 1254-1257

↑ *Back to this question in Part A*

@Neet_pg_bot

Q35: A 65-year-old male presented with unexplained fever and prolonged respiratory distress despite appropriate treatment. A diagnosis of cryptic tuberculosis was made. Which of the following is the correct statement related to this condition? (Q858030)

A. Positive skin tuberculin test and negative chest X-ray

B. Positive skin tuberculin test and positive chest X-ray

C. Negative skin tuberculin test and negative chest X-ray

D. Negative skin tuberculin test and positive chest X-ray

Correct Answer: C. Negative skin tuberculin test and negative chest X-ray

Explanation: , it does not represent cryptic tuberculosis where both tests are characteristically negative.

References:

Genotyping Mycobacterium tuberculosis isolates with few copies of IS6110: Value of additional genetic markers - ScienceDirect

IS6110-based restriction fragment length polymorphism (RFLP) analysis of Mycobacterium tuberculosis H37Rv and H37Ra - PubMed

TB lab investigations

Harrison's Principles of Internal Medicine, 21st Edition, Page 1367

↑ *Back to this question in Part A*

@Neet_pg_bot

Q36: What is the drug of choice for Legionnaire’s disease? (Q793967)

A. Vancomycin

B. Azithromycin

C. Streptomycin

D. Erythromycin

Correct Answer: B. Azithromycin

Explanation: Correct Option B - Azithromycin: Legionnaire's disease is a severe form of pneumonia caused by the bacterium Legionella pneumophila. Treatment typically involves antibiotics, and the drug of choice for Legionnaire's disease is Azithromycin. Azithromycin is a macrolide antibiotic that has activity against Legionella pneumophila. Incorrect Options: Options A, C and D are incorrect.

References:

Prepladder Notes

↑ *Back to this question in Part A*

@Neet_pg_bot

• [12_Oncology] 088 Previous Year Questions

« Back to Folder Directory

[12_Oncology] 088 Previous Year Questions — Quick Jump

Q1 (p. 3204) *Q2 (p. 3204)* *Q3 (p. 3205)* *Q4 (p. 3206)* *Q5 (p. 3207)* *Q6 (p. 3208)*

Q1: Which of the following is not used in management of tumor lysis syndrome? (Q793977)

A. Urine acidification

B. IV fluids

C. Dialysis

D. Rasburicase

Correct Answer: A. Urine acidification

Explanation: - Urine acidification: Tumor lysis syndrome (TLS) results in hyperuricemia, hyperkalemia, hyperphosphatemia, and hypocalcemia due to rapid tumor cell breakdown. Management includes aggressive IV hydration, rasburicase to rapidly degrade uric acid, and dialysis in severe or refractory cases. Urine acidification is not recommended because it increases the risk of uric acid and calcium phosphate crystal precipitation in renal tubules, worsening acute kidney injury. Incorrect Options: Option B - IV fluids: Aggressive IV hydration is the cornerstone of TLS management, helping maintain urine output and prevent crystal-induced renal failure. Option C – Dialysis: Dialysis is indicated in TLS with severe metabolic derangements or renal failure not responsive to medical therapy. Option D – Rasburicase: Rasburicase converts uric acid to allantoin, which is more soluble and easily excreted, making it highly effective in preventing and treating hyperuricemia in TLS.

References:

.

↑ *Back to this question in Part A*

@Neet_pg_bot

Q2: Most common cause of hypercalcemia in a hospitalized patient is: (Q857290)

A. Malignancy

B. Parathyroid Adenoma

C. Parathyroid hyperplasia

D. Follicular thyroid CA

Correct Answer: A. Malignancy

Explanation: etiology: Hypercalcemia of malignancy Paraneoplastic syndromes in Squamous cell carcinoma of lungs Breast carcinoma Parathyroid adenoma Sarcoidosis Vitamin D toxicity Milk alkali syndrome Jansen disease: Autosomal dominant defect in PTHR-1 leading to receptor gain mutation (hyperactive receptor) Lithium toxicity: Causes diabetes insipidus and activation of parathyroid glands. Familial hypocalciuric hypercalcemia: Autosomal dominant defect in CaSR receptor in parathyroid and kidneys, which leads to excess PTH secretion Investigations: Serum electrolytes: ↑ calcium and ↓ phosphate. ↑ Serum alkaline phosphatase. ↑↑↑ Serum PTH in cases of parathyroid adenoma Treatment: Aggressive hydration with normal saline: First-line management to correct dehydration and promote renal calcium excretion. Forced diuresis with loop diuretics: Can be used after adequate hydration to enhance calcium excretion in the urine. Intravenous Zoledronate: Drug of choice for lowering calcium. It begins to act within 1-2 days and lasts up to 3 weeks. Calcitonin: Promotes calcium deposition in bones but may develop tachyphylaxis (reduced response over time). Denosumab: Inhibits osteoclast differentiation by binding to RANK ligand, reducing bone resorption. Peritoneal dialysis: Indicated in renal failure, it can rapidly reverse life-threatening hypercalcemia. Parathyroid Adenoma (Option B): Primary hyperparathyroidism, most commonly due to a parathyroid adenoma, is the leading cause of hypercalcemia in the outpatient setting rather than hospitalized patients. It leads to increased secretion of parathyroid hormone (PTH), causing increased calcium resorption from bones and reduced renal calcium excretion. Parathyroid Hyperplasia (Option C): Parathyroid hyperplasia causes primary hyperparathyroidism, but it is less common than parathyroid adenoma. It is associated with multiple endocrine neoplasia (MEN) syndromes, particularly MEN 1 and MEN 2A. Like adenomas, it is more commonly seen in outpatient settings rather than as a cause of acute hypercalcemia in hospitalized patients. Follicular Thyroid Carcinoma (Option D): While follicular thyroid carcinoma can sometimes lead to bone metastases, resulting in hypercalcemia, it is not a common cause. Hypercalcemia from malignancy is more often seen in cancers that secrete PTHrP (e.g., squamous cell lung cancer) or cause direct bone destruction (e.g., multiple myeloma).

References:

Harrison’s principle of internal medicine, 21st edition, Page: 3182, 3183.

↑ *Back to this question in Part A*

@Neet_pg_bot

Q3: What is the most frequently observed delayed symptom of radiation therapy for the head and neck? (Q859545)

A. Dysphagia

B. Xerostomia

C. Myelopathy

D. Dysgeusia

Correct Answer: B. Xerostomia

Explanation: The most common late symptom of radiation therapy for head and neck cancers is xerostomia (dry mouth) . Late symptoms of radiation therapy for head and neck tumours Side effects Symptoms Management Permanent dry mouth (xerostomia) Dry mouth, difficulty in eating, swallowing, and speaking Maintain adequate oral hygiene, salivary substitutes' saliva stimulation, low-level laser treatment of the salivary gland, chlorhexidine, antifungal therapy, adequate hydration, acupuncture Burning mouth syndrome Burning or scalded of mouth; dryness, increased thirst; loss of taste Oral rinses, lidocaine, saliva substitutes, capsaicin, clonazepam or Klonopin, antidepressants, pain medications, low-level laser therapy, cognitive behavioural therapy Dental caries Dental caries Oral hygiene, management of xerostomia, topical fluorides and/or remineralizing agents Osteoradionecrosis Pain, bad breath, dysgeusia, numbness, trismus, mastication and speech difficulties Debridement, antibiotic treatment and prophylaxis, hyperbaric oxygen Fibrosis Woody texture and limited neck enhance lymphedema Physiotherapy, myofascial release, external laser Physiotherapy, myofascial release, external laser Mastication muscles fibrosis Oral appliances, diet modification, pharyngeal strengthening, swallow retraining The dropped head syndrome Severe kyphotic deformity of the cervicothoracic spine Supportive care, external orthotic devices Pharyngoesophageal stenosis Dysphagia (Option A) Dilation, surgery and stents Skin changes and skin cancer Acute inflammatory reaction in an area previously exposed to radiation after a chemotherapeutic agent or other medication Removal of skin cancer, maintaining proper skin hygiene, hydrophilic or lipophilic barrier creams with or without hydrogel or hydrocolloid dressings Lymphedema Neck and facial swelling, heaviness, achiness Manual lymph drainage, compression bandages and garments, lymphatic pump Hypothyroidism Slowing of metabolic processes symptoms Thyroxine replacement Hyperparathyroidism Excessive urination, abdominal pain, tiring weakness, depression. bone and joint pain, nausea, vomiting and loss of appetite Calcimimetics, hormone replacement therapy, bisphosphonates Surgical removal of the parathyroid adenoma(s) is curative in most patients Brachial plexopathy Paresthesia, dysesthesia, decreased sensitivity, movement loss, muscular atrophy, shoulder joint dislocation Physical and occupational therapies Eye damage Cataract, retinopathy Monoclonal antibody, triamcinolone, laser, photodynamic therapy, hyperbaric oxygen, pentoxifylline Myelopathy (Option C) refers to a condition affecting the spinal cord and is not a common delayed symptom of head and neck radiation therapy. Dysgeusia (Option D) refers to a distorted or altered sense of taste. While taste changes can occur after head and neck radiation therapy, xerostomia is more commonly observed as a delayed symptom.

References:

https://pmc.ncbi.nlm.nih.gov/articles/PMC7533405/

↑ *Back to this question in Part A*

@Neet_pg_bot

Q4: For which of the following cancers is prophylactic cranial irradiation (PCI) routinely recommended as part of standard management (Q859648)

A. Lung cancer

B. Liver cancer

C. Prostate cancer

D. Breast cancer

Correct Answer: A. Lung cancer

Explanation: Prophylactic cranial irradiation (PCI) is given to cancers with a high risk of brain metastases. It is standard in small cell lung cancer (SCLC) to prevent occult brain metastases and improve survival. It is not routinely used in breast, prostate, or liver cancers.

References:

https://pmc.ncbi.nlm.nih.gov/articles/PMC9020164/

https://pmc.ncbi.nlm.nih.gov/articles/PMC4477380/

↑ *Back to this question in Part A*

@Neet_pg_bot

Q5: A lung cancer patient has hyperpigmentation of palmar and sole creases. Which of the following is responsible for this presentation? (Q860465)

A. Melanocyte Stimulating Hormone (MSH)

B. C-peptide

C. Neuropeptide Y

D. Melanin

Correct Answer: A. Melanocyte Stimulating Hormone (MSH)

Explanation: The clinical manifestations indicate Ectopic Cushing's syndrome , a paraneoplastic syndrome commonly associated with lung cancer. Proopiomelanocortin (POMC) produced by the tumor is cleaved to form Melanocyte Stimulating Hormone (MSH) and ACTH , leading to hyperpigmentation. This process represents one of the most common hormonally-induced paraneoplastic syndromes in small cell lung cancer (SCLC). Ectopic Cushing's Syndrome Definition ACTH production from non-pituitary sources leading to Cushing's syndrome Epidemiology Accounts for 10-20% of cases of Cushing's syndrome Common Sources Small cell lung cancer (most common) Bronchial and thymic carcinoids Islet tumors Pheochromocytomas Medullary thyroid carcinomas Pathophysiology Increased expression of POMC gene from non-pituitary sources Production of MSH , β-lipotropin, and other POMC-derived peptides Production of ACTH fragments Clinical Features Hyperglycemia Marked fluid retention Hyperpigmentation manifestations due to MSH Less marked weight gain compared to pituitary Cushing's Centripetal fat redistribution Hypertension Hypokalemia Metabolic alkalosis Glucose intolerance Diagnosis Very high ACTH levels (typically >2-3 times normal) No response to high-dose

dexamethasone suppression Treatment Treatment of underlying malignancy Glucocorticoid receptor blockers Steroidogenesis inhibitors Management of complications (diabetes, hypokalemia) Key Distinctions from Pituitary Cushing's Higher ACTH levels No response to dexamethasone suppression More rapid onset More severe metabolic complications C-peptide (Option B) is a byproduct formed during the conversion of proinsulin to insulin. It has no role in the hyperpigmentation seen in paraneoplastic syndromes associated with lung cancer. Neuropeptide Y (Option C) is involved in appetite regulation through hypothalamic signaling. This peptide does not contribute to the hyperpigmentation observed in paraneoplastic syndromes. Melanin (Option D) is the end product of melanogenesis responsible for skin pigmentation. While it is the final pigment, the question asks about the hormone responsible for triggering the hyperpigmentation, which is MSH.

References:

Harrison’s Principles of Internal Medicine 21st edition Page 724

Davidson's Principles and Practice of Medicine, 24th Edition, Page: 600-603.

↑ *Back to this question in Part A*

@Neet_pg_bot

Q6: Which of the following mutations is associated with the Philadelphia chromosome? (Q860473)

A. Inversion

B. Insertion

C. Reciprocal translocation

D. Deletion

Correct Answer: C. Reciprocal translocation

Explanation: The Philadelphia chromosome is a balanced translocation between the long arm of chromosomes 9 and 22 [t(9;22)(q34.1;q11.2)] . It is present in the majority of patients with chronic myeloid leukaemia (CML). Formation of Philadelphia chromosome: A balanced translocation is a type of chromosomal rearrangement in which segments of two different chromosomes break and exchange places without any loss of genetic material. In the case of CML, a segment of chromosome 9 containing the ABL gene (Abelson Leukemia) , located at the q34 region, moves to chromosome 22. Similarly, the segment of chromosome 22 containing the BCR gene (breakpoint cluster region) , located at the q11 region, moves to chromosome 9. This exchange results in the formation of two derivative chromosomes: one with the truncated chromosome 9 segment and the BCR-ABL fusion gene and the other with the truncated chromosome 22 segment. The chromosome containing the BCR-ABL fusion gene is known as the Philadelphia chromosome. {{caption_text}} The BCR-ABL fusion forms a novel oncoprotein called p210 bcr-abl-1 (210 = molecular weight in kiloDalton—210 kDa). Inversion (Option A) occurs when a segment of DNA breaks away from the chromosome, flips around, and reattaches in the reverse orientation. This is not the mechanism involved in Philadelphia chromosome formation. Insertion (Option B) involves the addition of extra

nucleotides into a DNA sequence. This type of mutation can cause frameshift mutations but is not responsible for the Philadelphia chromosome. Deletion (Option D) results in the loss of a segment of DNA from a chromosome. While deletions are important mutations, they do not cause the formation of the Philadelphia chromosome, which involves an exchange of genetic material between chromosomes.

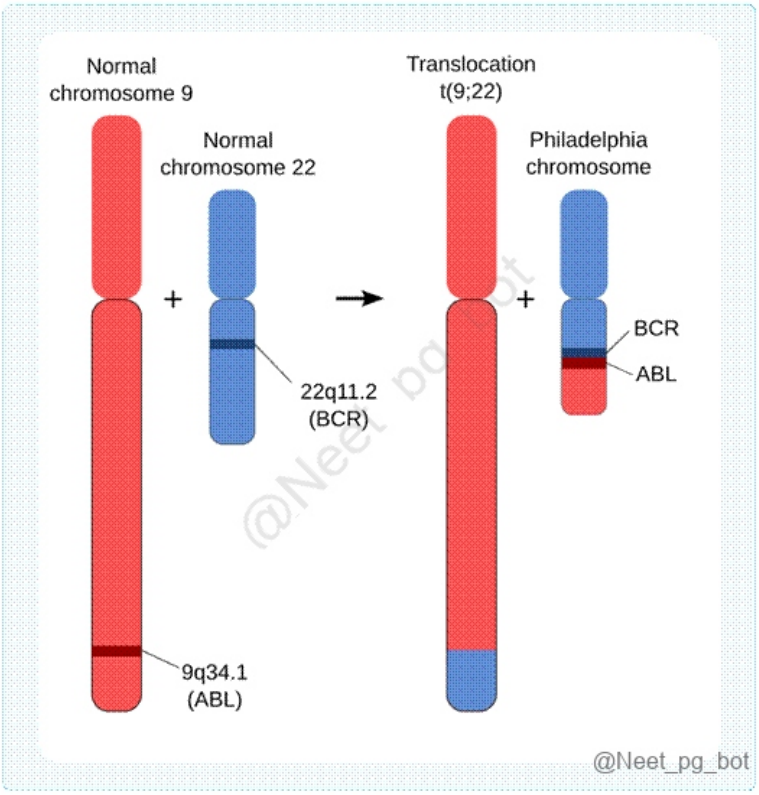

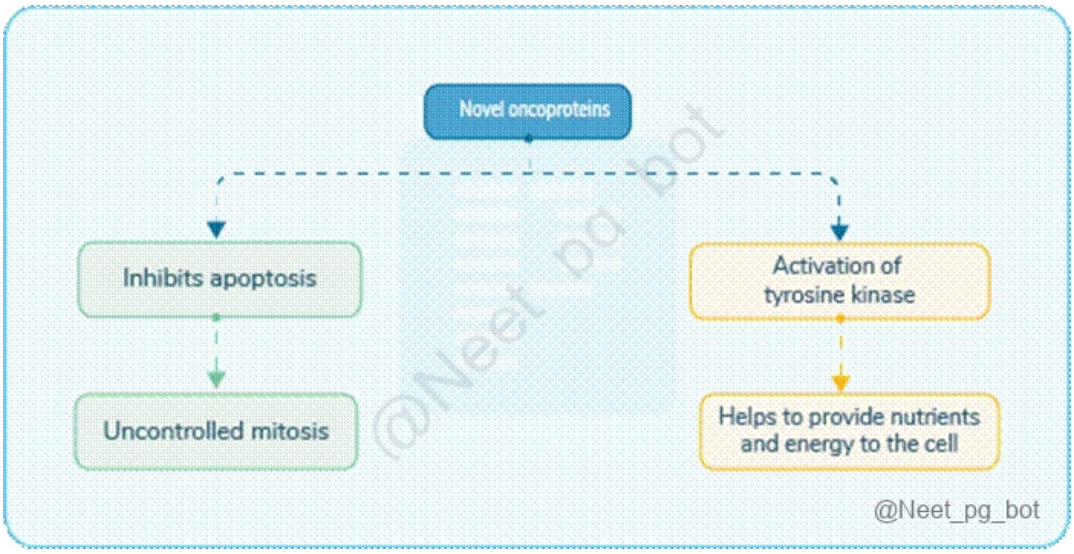

References:

Harrison’s Principles of Internal Medicine, 21st edition, Page 820

Robbins and Cotran, Pathologic Basis of Disease, 10th edition, Page 595,622

↑ *Back to this question in Part A*

@Neet_pg_bot

• [13_Miscellaneous Topics] 089 Previous Year Questions

« Back to Folder Directory

[13_Miscellaneous Topics] 089 Previous Year Questions — Quick Jump

Q1 (p. 3211) *Q2 (p. 3211)* *Q3 (p. 3212)* *Q4 (p. 3213)* *Q5 (p. 3214)* *Q6 (p. 3214)* *Q7 (p. 3215)*

Q1: What vitamin deficiency is responsible for the following symptoms in a patient: tingling sensation in the hands and feet, generalized weakness, easy fatigability, pallor, and ataxia? (Q793810)

A. Vitamin B1

B. Vitamin B12

C. Vitamin B2

D. Vitamin B3

Correct Answer: B. Vitamin B12

Explanation: The symptoms described in the question, including tingling sensation in hands and feet, generalized weakness, easy fatiguability, pallor, and ataxia, are suggestive of a neurological condition known as peripheral neuropathy. Several vitamin deficiencies can cause peripheral neuropathy, but the most common ones are deficiencies in vitamin B12. Vitamin B12, also known as cobalamin, is important to produce red blood cells and the proper functioning of the nervous system. Deficiency in vitamin B12 can cause pernicious anemia, which can manifest as peripheral neuropathy, as well as weakness, fatigue, and pallor. Therefore, vitamin B12 deficiency is a likely cause of the symptoms described in the question. Incorrect choices: Option a: Vitamin B1, also known as thiamine, is essential for the proper functioning of the nervous system, muscles, and cardiovascular system. A deficiency in vitamin B1 can cause a condition called beriberi, which can manifest as peripheral neuropathy, muscle wasting, and heart failure. However, the symptoms described in the question, such as ataxia and pallor, are not typical of beriberi. Option c: Vitamin B2, also known as riboflavin, is important to produce energy and the metabolism of fats, carbohydrates, and proteins. Deficiency in vitamin B2 can cause a condition called ariboflavinosis, which can manifest as glossitis, cheilosis, and skin rash, but not peripheral neuropathy. Option d: Vitamin B3, also known as niacin, is important for the proper functioning of the nervous system and the metabolism of fats, carbohydrates, and proteins. Deficiency in vitamin B3 can cause a condition called pellagra, which can manifest as the "3 Ds" - dermatitis, diarrhea, and dementia, but not peripheral neuropathy.

↑ *Back to this question in Part A*

@Neet_pg_bot

Q2: Cat scratch disease is caused by? (Q793845)

A. Bartonella henselae

B. Bartonella quintana

C. Bartonella bacilliformis

D. Borrelia burgdorferi

Correct Answer: A. Bartonella henselae

Explanation: Cat scratch disease (CSD) is a bacterial infection caused by the bacterium Bartonella henselae. The disease is most commonly transmitted to humans through the bite or scratch of an infected cat, although it can also be transmitted through fleas that have fed on an infected cat. Bartonella henselae is a gram-negative, rod-shaped bacterium that can survive and replicate within cells, including human cells. Once the bacteria enter the body through a cat scratch or bite, they typically spread to nearby lymph nodes, where they can cause inflammation and swelling. Incorrect Choices: b. Bartonella quintana, another species of the Bartonella genus, is the causative agent of trench fever, a common bacterial infection among soldiers during World War I. c. Bartonella bacilliformis is the causative agent of Carrion's disease, a bacterial infection transmitted by sandflies and found in parts of South America. d. Borrelia burgdorferi, conversely, is the causative agent of Lyme disease, a bacterial infection transmitted to humans through the bite of infected ticks.

References:

.

↑ *Back to this question in Part A*

@Neet_pg_bot

Q3: A man brings his father who became unconscious while working in a field in the host sun at 42 degrees Celsius in May. One examination, there were no physical signs of dehydration. His serum electrolyte values were normal. The physician found that the body temperature was 106 F. Which of the following symptoms is least likely to be seen in this patient? (Q793895)

A. Nausea

B. Hypotension

C. Sweating

D. Headache

Correct Answer: C. Sweating

Explanation: Sweating is least likely to be seen in this patient. This is because the patient is suffering from heat stroke, which is a severe form of heat illness that occurs when the body's temperature regulation system fails. In heat stroke, the body's core temperature can rise to 104 F (40 C) or higher, which can lead to serious complications, including organ damage and death. Sweating is the body's natural mechanism to cool down in hot environments. However, in cases of severe heat stroke, the body's thermoregulatory system becomes impaired, and sweating may stop. This happens when the body's sweat glands fail to produce sweat or when the sweat evaporates too quickly due to the dry and hot environment. Incorrect choices: Option a: Nausea is a common symptom of heat stroke, as the body tries to cope with the high temperature by increasing blood flow to the skin and reducing blood flow to the digestive system. This can lead to nausea, vomiting, and diarrhea. Option b: Hypotension (low blood pressure) is also a common symptom of heat stroke, as the body tries to conserve fluid by constricting blood vessels. This can cause blood pressure to drop, which can lead to dizziness, fainting, and shock. Option d: Headache is another common symptom of heat stroke, as the brain tries to cope with the high temperature by increasing blood flow to the head. This can lead to headaches, confusion, and seizures.

↑ *Back to this question in Part A*

@Neet_pg_bot

Q4: What is the most likely diagnosis for a tall male with a lack of pubic and axillary hair, underdeveloped genitalia, elevated levels of LH and FSH, and a karyotype of XXY? (Q793914)

A. Vanishing testis syndrome

B. Klinefelter’s syndrome

C. Noonan syndrome

D. Adrenal hyperplasia

Correct Answer: B. Klinefelter’s syndrome

Explanation: The most probable diagnosis for a tall male with absent pubic and axillary hair, infantile genitalia, high LH and FSH levels, and an XXY karyotype is Klinefelter's syndrome. Klinefelter's syndrome is a genetic disorder that occurs in males who have an extra X chromosome, resulting in a karyotype of 47, XXY instead of the normal 46, XY. This condition can lead to a variety of physical, cognitive, and behavioral symptoms, including tall stature, decreased body hair, underdeveloped genitalia, infertility, and cognitive and language delays. The elevated levels of luteinizing hormone (LH) and follicle-stimulating hormone (FSH) are a result of testicular failure and impaired testosterone production. Incorrect choices: Option a: Vanishing testis syndrome is a condition in which one or both testes fail to descend into the scrotum and subsequently atrophy, resulting in reduced testosterone production. This condition can cause infertility and hormonal imbalances, but it typically presents with normal male external genitalia and normal LH and FSH levels. Option c: Noonan syndrome is a genetic disorder that affects multiple body systems and can cause a variety of symptoms, including short stature, heart defects, developmental delays, and abnormal facial features. While Noonan syndrome can affect sex hormone levels, it is

not typically associated with the absence of pubic and axillary hair or infantile genitalia. Option d: Adrenal hyperplasia is a group of genetic disorders that affect the adrenal glands and can cause hormonal imbalances. Depending on the specific type of adrenal hyperplasia, symptoms can include abnormal genital development, early puberty, and elevated levels of sex hormones. However, the absence of pubic and axillary hair and infantile genitalia are not typical features of adrenal hyperplasia.

References:

.

↑ *Back to this question in Part A*

@Neet_pg_bot

Q5: How much sodium deficit needs to be corrected in a 40 kg female with a serum sodium level of 120 mEq/L to achieve a desired sodium concentration of 140 mEq/L? (Q830815)

A. 400 mEq

B. 300 mEq

C. 200 mEq

D. 100 mEq

Correct Answer: A. 400 mEq

Explanation: Correct Option A - 400 mEq: Sodium Deficit=(Desired Na–Current Na)×Total Body Water (TBW) where, TBW = 0.5 x body weight in Kg, for females Hence, Sodium deficit= 0.5 x 40 x (140-120) = 0.5 x 40 x 20 = 400 mEq

↑ *Back to this question in Part A*

@Neet_pg_bot

Q6: During the medication review of an elderly male patient with a history of COPD, hypertension, and diabetes, what criteria should the physician consider? (Q830826)

A. Duke’s criteria

B. Light criteria

C. Beer’s criteria

D. Jones criteria

Correct Answer: C. Beer’s criteria

Explanation: Correct Option C - Beer’s criteria: Beer's criteria are guidelines related to the use of medications in older adults, focusing on potentially inappropriate medications and drug-disease interactions in the elderly. It provides recommendations to avoid certain medications or adjust doses based on the potential risks and side effects in the geriatric population. Incorrect Options: Option A - Duke’s criteria: Duke's criteria are primarily used for the diagnosis of infective endocarditis. Option B - Light criteria: Light's criteria are employed in the assessment of pleural effusions to differentiate transudative from exudative effusions. Option D - Jones criteria: Jones criteria are used in the diagnosis of rheumatic fever.

↑ *Back to this question in Part A*

@Neet_pg_bot

Q7: Match the following? a. Trisomy 13 1. Huntington's disease b. Trisomy 18 2. Patau syndrome c. Trinucleotide repeat sequence 3. Sickle disease d. Hb point mutation of glutamate to valine 4. Edward syndrome (Q857256)

A. a-2, b-4, c-1, d-3

B. b-1, a-3, d-2, c-4

C. a-2, b-1, c-4, d-3

D. a-4, b-1, c-3, d-2

Correct Answer: A. a-2, b-4, c-1, d-3

Explanation: hromosomal anomaly Disease Clinical features Trisomy 13 Patau syndrome Short life expectancy Cleft lip and palate Polydactyly Small head Frequent congenital heart disease Trisomy 18 Edward syndrome Early demise Characteristic skull and facies Frequent heart, kidney, and other organ anomalies Trinucleotide repeat sequence Huntington's disease Motor disturbances Behavioural and psychiatric symptoms Cognitive decline Hb point mutation of glutamate to valine Sickle disease Anemia Jaundice Dactylitis Sickle cell crisis Fatigue Fever Chest pain Shortness of breath

References:

Davidson’s Principles and Practice of Medicine, 24th Edition, Page: 44.

https://www.ncbi.nlm.nih.gov/books/NBK559166/

https://www.nhlbi.nih.gov/health/sickle-cell-disease/symptoms

↑ *Back to this question in Part A*

• [14_Miscellaneous] 090 Previous Year Questions

« Back to Folder Directory

[14_Miscellaneous] 090 Previous Year Questions — Quick Jump

Q1 (p. 3217) *Q2 (p. 3218)* *Q3 (p. 3219)* *Q4 (p. 3220)* *Q5 (p. 3220)* *Q6 (p. 3221)*
Q7 (p. 3222) *Q8 (p. 3223)* *Q9 (p. 3225)*

Q1: A patient has a long arm span, hypermobile joints and hypermobile lens. What is the defective protein? (Q866820)

A. Fibrillin-1

B. Collagen

C. Elastin

D. Keratin

Correct Answer: A. Fibrillin-1

Explanation: The presentation describes Marfan syndrome , a connective tissue disorder caused by mutations in the FBN1 gene , leading to defective fibrillin-1 , an essential component of microfibrils that provide structural integrity to connective tissue and regulate TGF-β signaling. Clinical features include tall stature, disproportionately long limbs (increased arm span-to-height ratio), joint hypermobility, lens subluxation (typically upward), and cardiovascular involvement (aortic root dilatation, aneurysm). Incorrect Options: Collagen (Option B): Defects cause disorders such as Ehlers–Danlos syndrome and osteogenesis imperfecta, which may have joint hypermobility but not the full Marfan phenotype with lens dislocation and long arm span. Elastin (Option C): Deficiency is associated with conditions like supravalvular aortic stenosis and Williams syndrome, but not the Marfan skeletal and ocular features. Keratin (Option D): Structural protein in epithelial cells; mutations lead to skin and hair disorders, not connective tissue or cardiovascular manifestations.

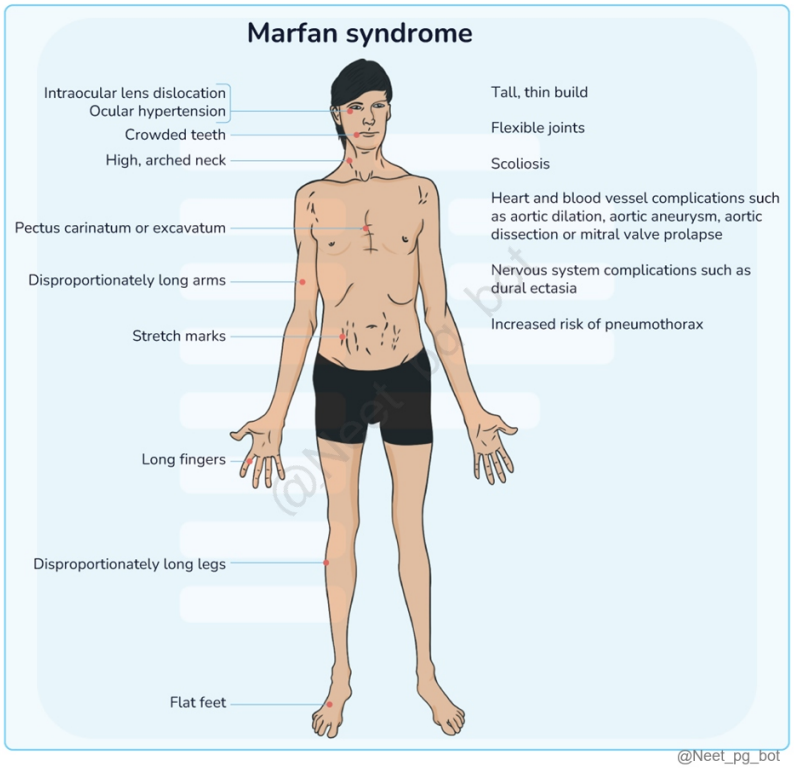

↑ *Back to this question in Part A*

@Neet_pg_bot

Q2: A skin graft was performed on a immunocompromised patient, using tissue from a immunocompetent donor. After a few weeks, the recipient developed skin contractures along with systemic symptoms such as fever, rash, and diarrhea. What is the most likely diagnosis? (Q866831)

A. Graft-versus-host disease

B. Graft failure

C. Rejection due to recipient T8 cells

D. Delayed wound healing

Correct Answer: A. Graft-versus-host disease

Explanation: Graft-versus-host disease (GVHD) occurs when donor immunocompetent T cells attack the recipient's tissues , which happens most often in immunocompromised recipients who cannot eliminate donor lymphocytes. GVHD causes systemic symptoms such as fever, rash, liver involvement, diarrhea, and can also lead

to skin changes and contractures over time. This delayed, systemic pattern is classic for GVHD. Graft failure (Option B): Results from the inability of the graft to establish blood supply, leading to necrosis — it occurs early, not weeks later, and does not cause systemic immune symptoms. Rejection due to recipient T8 cells (Option C): This is host-versus-graft rejection, not GVHD, and requires an immunocompetent recipient — which is not the case here. Delayed wound healing (Option D): Common in immunocompromised states but does not explain systemic features or the contractures caused by immune-mediated damage.

References:

.

↑ *Back to this question in Part A*

@Neet_pg_bot

Q3: What is the enzyme deficiency in Pompe’s disease? (Q857265)

A. Lysosomal acid alpha-glucosidase

B. Glucose 6 phosphatase

C. Muscle phosphorylase

D. Phosphofructokinase

Correct Answer: A. Lysosomal acid alpha-glucosidase

Explanation: : Hypotonia, muscle weakness, feeding difficulties, hepatomegaly, hypertrophic cardiomyopathy LOPD: Proximal limb-girdle muscle weakness, respiratory muscle involvement, cardiac rhythm disturbances Laboratory Findings Elevated serum CK, AST, ALT, LDH Cardiomegaly on chest X-ray (infantile form) ECG changes- shortened P-R interval, tall QRS complexes Treatment Enzyme replacement therapy with alglucosidase alfa High-protein diet (for LOPD) Histopathology findings: muscle biopsy/ cardiac biopsy has vacuoles within muscle fibres which stain with PAS strongly (glycogen is pas positive, diastase sensitive) Glucose 6 phosphatase (Option B) is an enzyme involved in gluconeogenesis and glycogenolysis. Deficiency of this enzyme is seen in Von Gierke's disease (glycogen storage disease type I), not in Pompe's disease. Muscle phosphorylase (Option C) , also known as myophosphorylase, is an enzyme involved in glycogenolysis (the breakdown of glycogen into glucose) in muscle tissue. A deficiency of muscle phosphorylase leads to McArdle disease (glycogen storage disease type V), characterized by exercise intolerance and muscle cramps. Phosphofructokinase (Option D) is an enzyme involved in glycolysis, the breakdown of glucose to produce energy. Deficiency of phosphofructokinase leads to Tarui disease (glycogen storage disease type VII), characterized by exercise intolerance and muscle weakness.

References:

Davidson’s Principles and Practice of Medicine, 24th Edition, Page: 370.

↑ *Back to this question in Part A*

@Neet_pg_bot

Q4: All of the following tests are done for screening in patients with Turner's syndrome, except? (Q857282)

A. ANA

B. Audiometry

C. Echocardiography

D. Fasting blood glucose

Correct Answer: A. ANA

Explanation: , glycated haemoglobin, serum creatinine, and urinalysis at 10 years and above to screen for diabetes mellitus and kidney disease.

References:

https://www.ncbi.nlm.nih.gov/books/NBK554621/

↑ *Back to this question in Part A*

@Neet_pg_bot

Q5: Which is the best confirmatory method to ensure the central line is in the jugular vein? (Q859533)

A. Chest X-ray

B. Blood pH

C. Blood color

D. ETCO 2

Correct Answer: A. Chest X-ray

Explanation: Correct Option A - Chest X-ray: Chest X-ray is the gold standard to confirm the position of a central venous catheter, ensuring it is in the internal jugular vein or superior vena cava, and to rule out complications such as pneumothorax. It provides anatomical confirmation rather than relying on indirect signs. Incorrect Options: Option B - Blood pH: Blood pH does not reliably differentiate between arterial vs venous placement, as venous blood pH may vary only slightly. Option C - Blood Color is unreliable, especially in hypoxemic patients; dark red

blood may still be arterial, and bright red may be venous. Option D - ETCO■ is used to confirm endotracheal tube placement, not central venous catheter position.

References:

https://www.ncbi.nlm.nih.gov/books/NBK470286/

↑ *Back to this question in Part A*

@Neet_pg_bot

Q6: What is the most likely diagnosis for an adult patient with a pulsatile swelling in the neck below the jaw angle that causes an outward expansile impulse, based on the findings of an MRI angiography? (Q859536)

A. Grave’s disease

B. Branchial cyst

C. Thymic cyst

D. Carotid body tumour



Correct Answer: D. Carotid body tumour

Explanation: In the above scenario, there is a pulsatile swelling, and on MRI angiography, it shows Lyre's sign which is the splaying of internal and external arteries , which is diagnostic of carotid body tumour. Carotid Body Tumor (CBT) CBT, also known as paraganglioma or chemodectoma , is a rare benign neck tumour originating from the neural crest at the adventitia of the common carotid artery bifurcation. CBTs grow slowly, have a low cancer rate, and are not significantly associated with age or gender, though some suggest a slightly higher incidence in women. The pathogenesis is unclear but is linked to chronic hypoxia and mutations in mitochondrial oxygen-sensitive genes. Diagnosis: B-mode Ultrasonography: It shows solid, hypoechoic tumours near blood vessels. Digital Subtraction Angiography (DSA): DSA visualized tumour blood supply and the displacement of arteries, with a diagnostic coincidence rate of 100%. Magnetic Resonance Imaging (MRI): MRI showed tumours at the bifurcation of the carotid artery with compression and displacement of arteries. Tumours appeared as round or round-like masses, showing heterogeneous or high signals on T2-WI. The Lyre sign refers to the splaying of the internal and external carotid by a carotid body tumour. It is classically described in angiography it is also visible in CT angiography. Treatment: Surgical Resection: The most effective treatment for CBTs. Other Modalities: Radiotherapy, embolization, and combination therapy can also be considered. Incorrect Options: Grave’s disease (Option A) is a hyperthyroid condition with bulging eyes, and the neck swelling is not pulsatile. Branchial cysts (Option B) are small fluid-filled sacs that look like lumps under the skin on the side of the neck and are more common in children than adults. A thymic cyst (Option C) is a benign mediastinal disease and presents with dyspnea, chest pain, cough, hoarseness and dysphagia.

References:

https://pmc.ncbi.nlm.nih.gov/articles/PMC8748146/

https://radiopaedia.org/articles/lyre-sign-carotid-artery

↑ *Back to this question in Part A*

@Neet_pg_bot

Q7: A 32-year-old Mount Everest tour guide presents with blisters on her hand, severe pain, and erythema after prolonged exposure to extreme cold. Which of the following is the most appropriate initial management for this patient? (Q859647)

A. Administer oxygen

B. Rapidly rewarm in warm water and protect

C. Pentoxyphylline

D. NSAID’s



Correct Answer: B. Rapidly rewarm in warm water and protect

Explanation: The image depicts frostbite , a cold injury from prolonged exposure, presenting with blisters, erythema, severe pain, and tenderness , commonly on hands, feet, nose, and ears. Early signs include numbness and color changes , with later blistering or tissue necrosis. Initial management is rapid rewarming in 40–42°C water until skin is soft and pliable , followed by loose protection to prevent refreezing , which improves tissue survival. Avoid direct heat, rubbing, or casting during initial treatment. Administer oxygen (Option A): Oxygen is not the first-line treatment for frostbite; rewarming and tissue protection are prioritized. Pentoxifylline (Option C) may be used later as an adjunct to improve microcirculation, but it is not part of initial management . NSAIDs (Option D) can help with pain and inflammation but do not treat the underlying frostbite injury .

References:

https://www.ncbi.nlm.nih.gov/books/NBK534837/

↑ *Back to this question in Part A*

@Neet_pg_bot

Q8: A 30-year-old man presented the findings shown in the given image. What is this physical finding called? (Q859760)

A. Spoon-shaped nails

B. Raynaud's phenomenon

C. Pallor

D. Clubbing



Correct Answer: D. Clubbing

Explanation: The image shows typical findings of clubbing of fingers, seen in various cardiopulmonary conditions. Clubbing is not always irreversible and can be reversible in certain conditions. Clubbing of fingers Definition Enlargement of distal segments of fingers and toes Proliferation of connective tissue Particularly on the dorsal surface Changes at the base of clubbed nail Pathophysiology Connective tissue proliferation Exact mechanism unknown Platelet-derived growth factors implicated Clinical Signs Bulbous Enlargement of the Distal Phalanges Loss of the Normal Angle Between the Nail and the Nailbed (Lovibond's Angle) Increased Sponginess of the Soft Tissue at the Base of the Nail Nail Changes: Nail flattening / nail curvature Hippocratic fingers : The tips of the fingers become enlarged, and the nails curve downward Clinical tests Schamroth's Sign: Normal : A small diamond-shaped window should be visible between the nails when the fingers are positioned in this way. Positive Schamroth's Sign : The window disappears, and there is no gap between the nails, indicating the loss of the normal angle at the nail bed. Associated Conditions Cyanotic congenital heart disease Infective endocarditis Bronchiectasis Cystic Fibrosis Lung cancer Tuberculosis Inflammatory bowel disease Key Features Can be hereditary or acquired May be reversible in certain circumstances Associated with hypertrophic osteoarthropathy Can cause pain and arthritis-like changes Spoon-shaped nails (koilonychia) (Option A): The nail abnormality is characterized by thin, fragile nails with a concave appearance, either horizontally or vertically oriented. The nail plate appears to be depressed in the centre and bent outward at the edges. Raynaud's phenomenon (Option B) presents as repeated constriction of blood vessels in the fingers and toes, typically triggered by cold temperatures or stress. Pallor (Option C) refers to a noticeable decrease in the normal colour and tone of the skin or mucous membranes, which may occur due to changes in blood flow, anaemia, or other unclear factors.

References:

Harrison’s Principles of Internal Medicine, 21st Edition, Volume I, Page: 275.

↑ *Back to this question in Part A*

@Neet_pg_bot

Q9: Which of the following animals is most likely responsible for biting a 10-year-old child who presented with symptoms of tachycardia, hypertension, tongue fasciculation, hypersalivation, dilated pupils, and mild erythema at the site of the wound? The child recalls that the animal had a curved tail pointing upwards. (Q859779)

A. Sea urchin

B. Caterpillar

C. Scorpion

D. Shellfish

Correct Answer: C. Scorpion

Explanation: The clinical features and the characteristics of the animal with a curved tail pointing upwards point to the possibility of the animal being a scorpion . Less dangerous scorpions: Local pain, swelling, and burning sensation Symptoms resolve in a few hours Possible allergic reactions to venom Bark scorpions (e.g., Centruroides species): Intense pain, paresthesia, and hyperesthesia (worsened by tapping) Restlessness, blurred vision, abnormal eye movements Excessive salivation, sweating , and difficulty handling secretions Nausea, vomiting, slurred speech Muscle twitching , jerking, and shaking (may resemble seizures) Tachycardia, arrhythmias, hypertension, hyperthermia, rhabdomyolysis Respiratory arrest, especially in children and the elderly Venomous scorpions (e.g., Tityus serrulatus, Leiurus quinquestriatus): Hypertensive crises, arrhythmias, myocardial damage Pulmonary oedema, central nervous toxicity Other species (e.g., Hemiscorpius lepturus): Pain, hemolysis, tissue necrosis (delayed onset) Systemic complications: hemoglobinuria, acute kidney injury General symptoms of envenomations: Immediate sharp local pain Edema, ecchymosis, and burning sensation Symptoms generally resolve within hours for most species Treatment of scorpion sting: Identification of the scorpion species is essential for determining treatment, as stings from non-lethal species typically only require basic care. Non-lethal stings : Most stings cause local discomfort and can be managed at home with ice packs, analgesics, or antihistamines. Patients should return to the emergency department if cranial-nerve or neuromuscular symptoms develop. Severe envenomations : Aggressive supportive care and careful use of antivenom can prevent deaths from more dangerous stings. Initial measures : Keeping the patient calm, applying pressure dressings, and using cold packs can reduce venom absorption. Treatment for symptoms : Continuous IV infusion of midazolam can control agitation and muscle movements, but close monitoring is needed due to the risk of respiratory arrest, especially when sedatives or narcotics are used. Management of complications : Hypertension and pulmonary oedema : Managed with nifedipine, nitroprusside, hydralazine, or prazosin . Bradycardia : Managed with atropine. Antivenin : FDA-approved antivenin (C. sculpturatus IgG F(ab')2 in horse serum) is available in some countries and can rapidly reverse cranial-nerve dysfunction and muscular symptoms when administered intravenously.

Options A, B, and D are incorrect.

References:

Harrison’s Principles of Internal Medicine, 21st Edition, Page: 3613.

↑ *Back to this question in Part A*

@Neet_pg_bot