Yourwish

1. CELL INJURY

Injury
↓
Adaptation
↓ (Fails)
Reversible Cell Injury
↓ (Injury continues)
Irreversible Cell Injury
↓
Cell Death

- Most common cause of cell injury: Hypoxia
- Most common cause of hypoxia: Ischemia
- Cell most sensitive to hypoxia (3-5 min): Neurons / CNS
- Cell most resistant to hypoxia: Fibroblast

REVERSIBLE CELL INJURY

00:02:02

FMGE 2023, 2019, 2025
AIIMS 2019, 2024

- Hypoxia → Mitochondrial dysfunction → ↓ ATP
- Decrease in ATP will cause:
  - Failure of Na^+K^+ ATPase pump
  - Anaerobic glycolysis
  - Decrease in protein synthesis

Failure of Na^+K^+ ATPase pump	Anaerobic glycolysis	↓ protein synthesis

• In normal cell: 3 Na^+ goes out and 2 K^+ comes in
• In failure of Na^+K^+ ATPase pump: 3 Na^+ comes in and 2 K^+ goes out
  ○ This leads to cellular swelling/ hydropic change
  ○ Swelling of the endoplasmic reticulum
  ○ Loss of microvilli
  ○ Cytoplasmic blebs
  ○ Myelin figures
	• Lactic acid → ↓pH
	• Causes nuclear chromatin clumping
		• Due to the detachment of ribosomes

- Myelin figures:
  - Made of: Phospholipid > Ca^{2+}
  - Seen in:
    → Reversible Cell Injury: Myelin figures start to appear
    → Irreversible Cell Injury: Myelin figures increase in numbers
  - Appearance in electron microscopy: Concentric lamellations

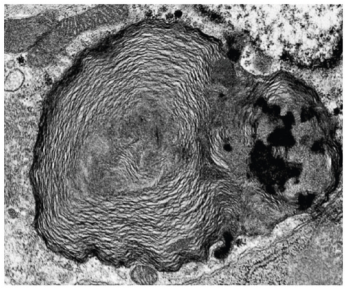

Yourwish

Important Information

- First change in cell injury: Mitochondrial dysfunction
- First morphological change in cell injury: Cell swelling / hydropic change

IRREVERSIBLE CELL INJURY

00:08:58

FMGE 2023, 2025
AIIMS 2024

- Severe membrane damage & Severe mitochondrial damage → Ca^{2+} influx
- Amorphous flocculent densities:
  - Made of Ca^{2+}
  - Present in mitochondria
  - Seen in irreversible injury
- Ca^{2+} → activation of enzymes
  - Phospholipase
  - Protease
  - Nuclease

Nuclear Changes In Cell Injury

Normal		
Pyknosis	Nucleus condensed	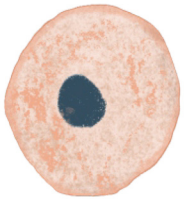
Karyorrhexis	Nuclear fragmentation	
Karyolysis	Nuclear dissolution	

CELL DEATHS

00:12:40

FMGE 2019
AIIMS 2018, 2019, 2023

Necrosis

- Pathological cell death associated with inflammation

Coagulative Necrosis

- MC type of necrosis
- MOA: Denaturation of protein
- Occurs in solid organs:
  - Kidney
  - Liver
  - Heart (MI)- MC organ
- Tissue architecture is preserved
- Microscopic examination:
  - Ghost cells → Tombstone appearance
- Subtype: Zenker's degeneration
  - Seen in typhoid
  - Site: Skeletal muscle
    → Rectus abdominis
    → Diaphragmatic muscle

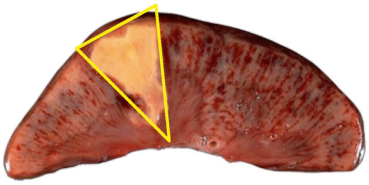

Wedge shaped infarct

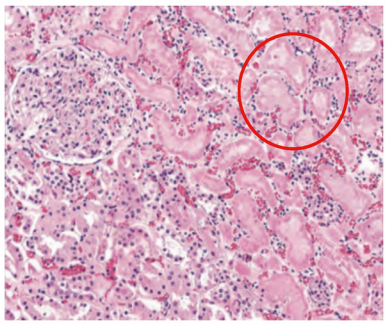

Tubules with Ghost Cells

Important Information

- Ghost cells → Pilomatrixoma
- Tombstone appearance → Pemphigus vulgaris

Liquefactive Necrosis

FMGE 2025

- AKA: Colliquative necrosis
- Organs commonly affected: Brain, Pancreas
  - Rich in hydrolytic enzymes
- Tissue architecture is not preserved

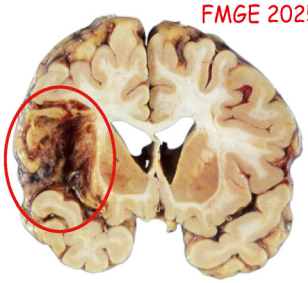

Loss of Tissue Architecture

Caseous Necrosis

- Combination of: Coagulative necrosis > Liquefactive necrosis
- Gross appearance: Cheese-like
- Reason: High lipid content in the cell wall
- Examples:
  - Tuberculosis
  - Fungal infections (Histoplasmosis, Coccidioidomycosis)

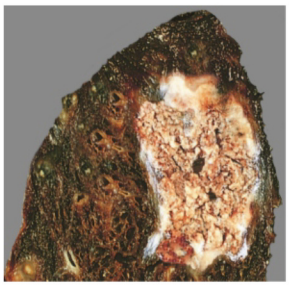

Fat Necrosis

FMGE 2023

- Examples:
  - Breast: Trauma → Fat Breakdown
  - Omentum: Acute Pancreatitis → Lipase ↑→ Fat Breakdown
- Fatty Acid + attract Ca^{2+} → Chalky white areas
- Acute Pancreatitis:
  - Within Pancreas → Liquefactive Necrosis
  - Peripancreatic Fat → Fat Necrosis (MC)

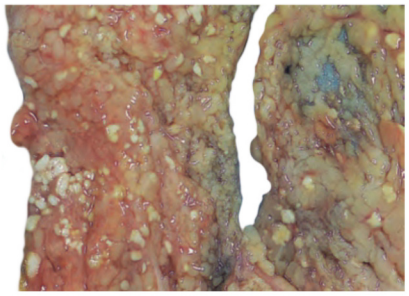

Fibrinoid Necrosis

- MOA: Antigen-Antibody reaction

Yourwish

- Examples:
  - Polyarteritis Nodosa
  - Rheumatic Heart Disease → Aschoff bodies
  - Systemic Lupus Erythematosus
  - Malignant Hypertension

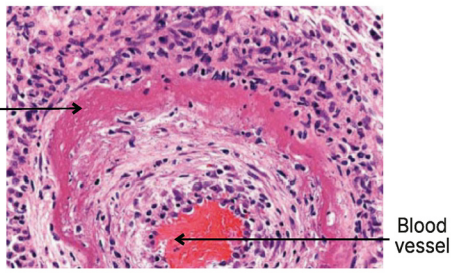

Blood vessel showing fibrinoid necrosis - in PAN

Gangrene

- Not a pathological term; it is a clinical term
- Black, foul-smelling
- Types:
  - Dry Gangrene: Primarily Coagulative necrosis
    → Shows a line of demarcation
  - Wet Gangrene: Primarily Liquefactive necrosis
  - Gas Gangrene: Caused by C. perfringens

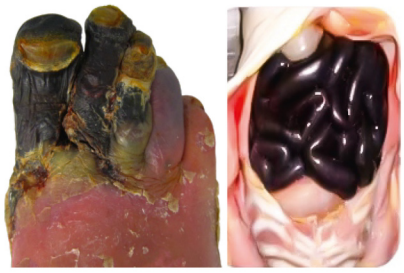
Dry Gangrene Wet Gangrene

Apoptosis

00:25:44
FMGE 2024, 2025
AIIMS 2023
NEET PG 2019, 2025

- Definition: Caspase-dependent programmed cell death
- Inflammation: Not present
  - Necrosis involves inflammation and is always pathological
- Physiological apoptosis
  - Examples: Embryogenesis / Organogenesis
    → If defective → Syndactyly
- Pathological apoptosis
  - Councilman Bodies: Viral hepatitis (HBV, HCV)
  - Civatte / Colloid / Cytoid Bodies: Lichen planus

Mechanism Of Apoptosis

FMGE 2024
AIIMS 2024
AIIMS 2025

- Caspase:
  - Enzyme
  - Cleaves after aspartic acid
  - Made up of cysteine residues

Initiation	Execution

• Extrinsic pathway
  ○ Caspase 8
  ○ Caspase 10
• Intrinsic pathway
  ○ Caspase 9
	• Caspase 3 (most important)
	• Caspase 6
	• Caspase 7

Initiation-Extrinsic Pathway

- AKA: Death receptor pathway
- Ligand Binding:
  - Fas Ligand (CD95L), located on the surface of a T-cell, binds to the Fas Receptor (CD95) on the target "Apoptotic" cell.
- Trimerization:

Yourwish

- Once the ligand binds, it causes three Fas receptors to cluster together
- This clustering recruits an adapter protein called FADD (Fas-Associated Death Domain)
- FADD converts Procaspase 8 or 10 into Caspase 8 and 10

- FLIP:
  - Anti-apoptotic because it inhibits the activation of procaspases
  - Stops the extrinsic pathway

Initiation-Intrinsic Pathway

FMGE 2025

- Stress → Trigger stress sensors (BIM, BID, BAD, NOXA, PUMA)

Increase Pro-apoptotic factors	Decrease anti-apoptotic factors
• p53 • Bak • Bax • Bcl XS	• Bcl 2 • Mcl 1 • Bcl XL

- Signal is sent to mitochondria and releases:
  - SMAC/DIABLO
  - Cytochrome C
    → Binds with Apaf 1 to form Apoptosome
    → Apoptosome converts Procaspase 9 into Caspase 9

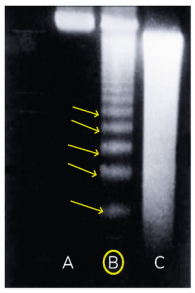

NEET PG 2025

Execution

- Caspases (8, 9, 10) activate the caspases (3, 6, 7)
- Activate enzymes:
  - Phospholipase
  - Protease
  - Endonuclease → Internucleosomal Cleavage
    → Break DNA into fragments of 180–200 base pairs
    → "Step-ladder" pattern on gel electrophoresis.

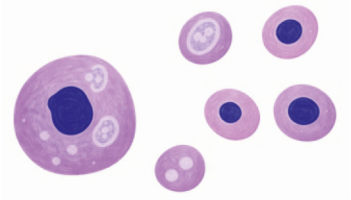

- The cell breaks into membrane-bound fragments called Apoptotic Bodies
  - Contains cell membrane, organelles, and nuclear fragment
- Flipping of Phosphatidyl Serine → acts as a signal to macrophages to engulf the fragments
  - "Eat Me" Signal/ Efferocytosis

Identification Of Apoptosis

Markers

- Annexin V:
  - Marker of "flipping" of Phosphatidyl Serine
    → Annexin A1 → Marker for Hairy Cell Leukemia
- Molecular Marker: CD95/Fas.

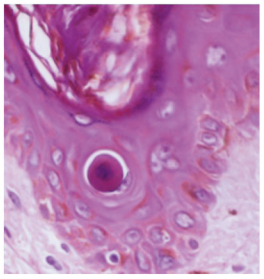

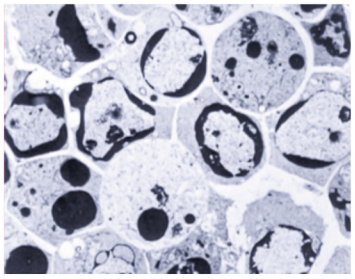

Microscopic Examination

- Cell Shrinkage
- Cytoplasm becomes more pink
- Nuclear Chromatin Condensation → Hallmark of apoptosis.

Yourwish

Diagnostic Staining And Testing

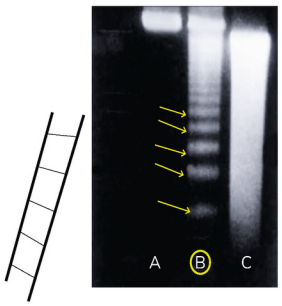

- TUNEL Stain: Positive for apoptosis and negative for necrosis.
- Gel Electrophoresis: Stepladder pattern
  - A: Normal DNA
  - B: Stepladder Pattern (Apoptosis > Necrosis)
    → Stepladder fever is seen in typhoid
  - C: Smearing Pattern (Necrosis > Apoptosis)

Necroptosis

00:48:00

- Necrosis + apoptosis
- Definition: Caspase-Independent programmed cell death
- High inflammation +
- Occurrence:
  - Physiological: Involved in growth plate formation
  - Pathological: Seen in Pancreatitis and Steatohepatitis
- Mechanism:
  - Triggered by TNF binding to the TNF Receptor
  - Recruitment of RIPK1, RIPK3 and Procaspase 8
    → Procaspase 8 is not activated to Caspase 8 in this pathway
  - The process leads to MLKL Phosphorylation → Cell death

Pyroptosis

- Definition: Programmed cell death associated with fever
- Mechanism:
  - Triggered by bacteria like Salmonella and Shigella → NOD receptors
  - Activation of Inflammasome
  - Activation of Caspases 1, 4, 5, and 11 → cell death
    → Caspases 1 → Activation of IL-1 → fever

Caspases

Function	Caspases
Apoptosis Initiation	8, 9, 10
Apoptosis Execution	3, 6, 7
Necroptosis	Procaspase 8
Pyroptosis	1, 4, 5, 11

CELLULAR ADAPTATION

00:53:25

Type	Definition	Mechanism
Normal	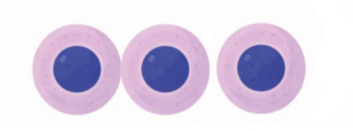	-

Hypertrophy	↑ in cell Size 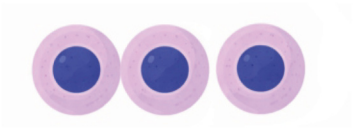	↑ Transcription Factors: GATA, NFAT, MEF2
Hyperplasia	↑ in Cell number 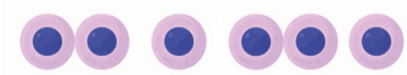	Division
Atrophy	↓ Cell size & number 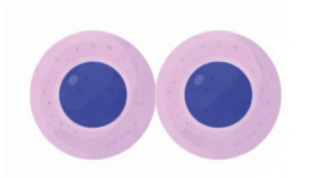	Ubiquitin Proteasome Pathway
Metaplasia	Change 	Reprogramming of Stem Cells
Dysplasia	Precancer 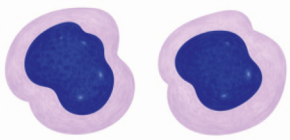	—

Hypertrophy vs. Hyperplasia

FMGE 2023, 2019
AIIMS 2019

Mixed Adaptations

- Some organs undergo both hypertrophy and hyperplasia simultaneously:
  - Gravid Uterus: Predominantly Hypertrophy
  - Breast (Puberty & Pregnancy): Predominantly Hyperplasia

Pure Hypertrophy

- Body Builders: Occurs in Skeletal Muscle
- Proximal to Obstruction:
  - Left Ventricular Hypertrophy due to Aortic Stenosis
  - Hypertrophy of the urinary bladder proximal to obstruction (calculi)

Pure Hyperplasia

- Endometrial hyperplasia: Due to increased Estrogen
  - Leads to risk of Endometrial Cancer Type I
- Prostate hyperplasia (BPH):
  - Driven by Dihydrotestosterone (DHT), which is converted from Testosterone via the enzyme 5 alpha-reductase
  - Treatment: Finasteride (inhibits 5 alpha-reductase)
  - Prostate hyperplasia does not lead to cancer

Yourwish

Atrophy Examples

- Disuse Atrophy: e.g., muscle atrophy after wearing a cast for 6 weeks
- Malnutrition
- Ischemic Atrophy: e.g., observed in Alzheimer's Disease
- Denervation Atrophy
- Endometrial Atrophy:
  - Occurs Post-Menopausal due to decreased Estrogen
  - Carries a risk of Endometrial Carcinoma Type II

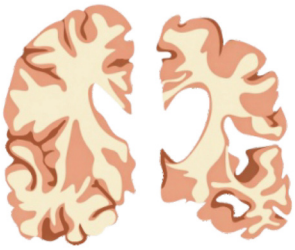

Important Information

- Hyperplasia → Endometrial Carcinoma Type I
- Atrophy → Endometrial Carcinoma Type II (worst prognosis)

Metaplasia

- Definition: Change of one tissue type to another
- It is always reversible

Types Of Metaplasia

- Epithelial Metaplasia:
  - Squamous Metaplasia (Lung):
    - → Transition: Ciliated columnar epithelium → Squamous epithelium
    - → Causes: Smoking or Vitamin A deficiency/excess
    - → Risk: Increased risk of Squamous cell carcinoma of the Lung
  - Columnar Metaplasia (Barrett's Esophagus):
    - → Transition: Squamous epithelium → Intestinal columnar epithelium
    - → Cause: Chronic GERD
    - → Presence of Goblet Cells, which contain acidic mucin
    - → Diagnostic Stain: Alcian Blue positive (+)
    - → Risk: Increased risk of Adenocarcinoma of the Esophagus
- Mesenchymal Metaplasia:
  - Myositis Ossificans: Bone formation within muscle following trauma and subsequent calcification

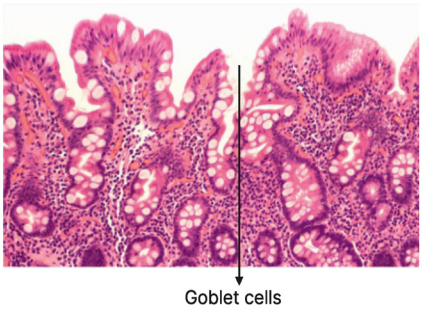

INTRACELLULAR ACCUMULATIONS

01:05:00

Pigments

FMGE 2020, 2022 AIIMS 2021, 2022

Melanin	• Hair, eyes, skin (Stratum basale), brain (substantia nigra)
	• Stain:
	  ○ Masson fontana
	  → Masson Trichrome: Muscle appears red, and collagen appears blue
	  ○ Schmorl's stain
	• Enzyme for staining: Dopa oxidase
	• IHC: HMB 45, S100

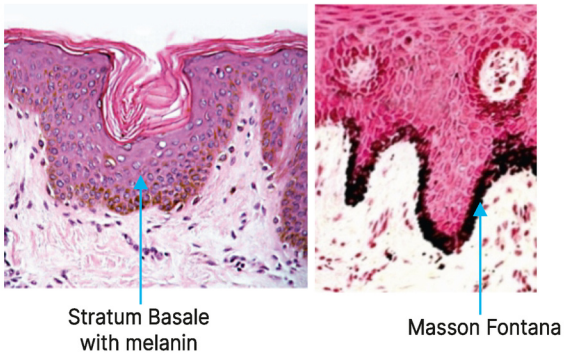

Yourwish

Yourwish

Hemosiderin	• H/o hemorrhage or bleeding → ↑Fe
	• Iron overload → Hemochromatosis
	  ○ HFE gene on chromosome 6
	• Stain:
	  ○ Perl's/ Prussian blue

Copper	• Copper overload → Wilson disease
	  ○ ATP 7B gene on chromosome 13
	  → ATP 7A gene → Menke's disease
	• Stain:
	  ○ Rhodanine
	  → Rhodamine: For Mycobacterium TB
	  ○ Rubeanic acid

Lipofuschin	• AKA: Old age pigment
	  ○ Senile atrophy
	  ○ Wear & tear pigment
	  ○ Telltale sign of free radical injury
	• Free radical injury → Lipid peroxidation → Lipofuscin
	• Location: Perinuclear
	• Stain:
	  ○ Oil red O
	  ○ Acid-fast/ ZN+

Anthracotic pigment	• Carbon → Black pigment

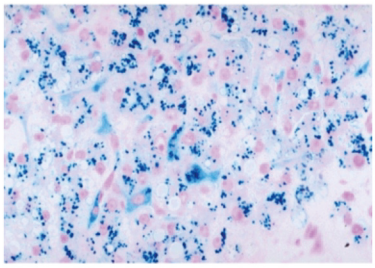

Iron-related → Perl's stain.

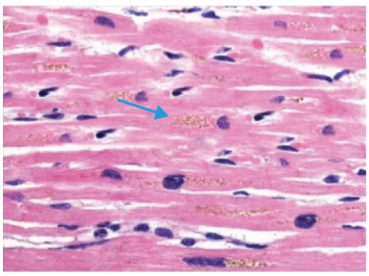

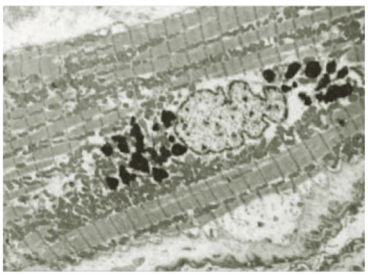

Glycogen

- Glycogen storage disease, DM
- Glycogen in Proximal Convoluted Tubule → Armani Ebstein lesion
- Stains:
  - PAS+ → Pink
  - Diastase sensitive

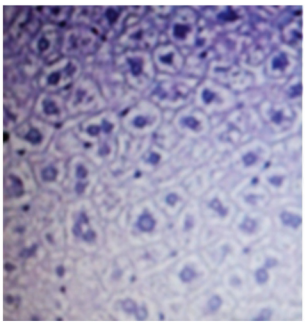

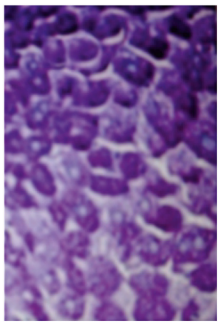

Lipid

- Site:
  - Liver → Fatty liver (MC)
  - Heart → Tigered/ Tabby cat appearance
    → Diphtherial myocarditis

Yourwish

- Gall bladder
  → Cholesterolosis → Strawberry GB
- Stain:
  - Oil red O
  - Sudan Black B
  - Sudan IV
- Technique to visualise fat :
  - Frozen section/Cryostat

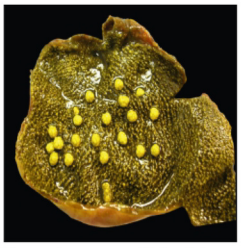

Strawberry gallbladder

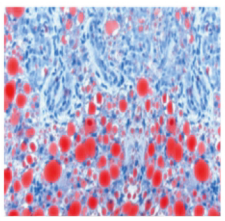

OIL RED O

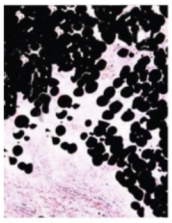

Sudan Black B

Calcium

- Stains:
  - Von Kossa stain → Black
  - Alizarin Red S → Red
    → Stain for a minute amount of calcium
  - Calcein
  - Azan stain
    → Calcification stages for mature and immature bone

Calcification

NEETPG 2020
FMGE 2023
AIIMS 2019

- Calcification first begins in mitochondria
  - Except in the kidney → In the basement membrane

Types

Feature	Dystrophic Calcification	Metastatic Calcification
Tissue Type	Dead / Degenerating tissue	Normal tissue
Serum Calcium	Normal	Elevated (MC in lungs)
Examples	Dead Parasite TB Atheroma Monckeberg Sclerosis Psammoma Bodies	Hyperparathyroidism Vit D ↑ → ↑ Ca^{2+} Milk alkali syndrome Sarcoidosis → Vit D ↑ Multiple myeloma (Bone lytic → ↑Ca^{2+})

- Psammoma Bodies **(Mnemonic: (PSMM)^2):**
  - **P:** Papillary Carcinoma
  - **P:** Prolactinoma
  - **S:** Somatostatinoma
  - **S:** Serous Ovarian Tumor (CA 125 ↑)
  - **M:** Meningioma
  - **M:** Mesothelioma

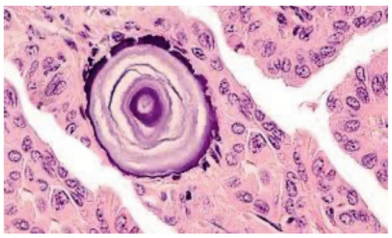

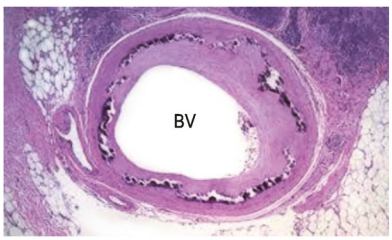

- Monckeberg Sclerosis:
  - Also called Calcific Medial Degeneration
  - Involves dystrophic calcification of the tunica media in blood vessels
  - Typically associated with old age

AUTOPHAGY (SELF EATING)

01:21:50
FMGE 2024



- AKA: Cell Cannibalism
- Nobel Prize: Yoshinori Ohsumi (2016)
- Associated Diseases:
  - Cancers
  - Malnutrition
  - Neurodegenerative diseases (e.g., Alzheimer's, Parkinson's)
- Marker: Lc3
- Most Important Gene: ATG1 gene
- Diseases associated with ATG genes:
  - ATG5 mutation → ↑ risk of TB
  - ATG16L mutation → Inflammatory Bowel Disease

CELLULAR AGEING

01:24:17
FMGE 2020, 2023

- Causes:
  - Free radical injury (MC)
  - Telomere shortening
  - Insulin resistance
- Telomere: Terminal sequence "TTAGGG" that shortens with each cell division
- Hayflick Limit: Average number of cell divisions (50–60)
- Telomerase: RNA-dependent DNA polymerase
  - Prevents telomere shortening
  - AKA: "immortality gene"
  - Found maximally in germ cells
  - Reactivated by cancer cells

Sirtuins

- Histone Deacetylases
- Genes: SIRT 1-7
- Benefits:
  - Anti-ageing
  - Treatment of Cancer
  - Treatment of DM (by ↑ insulin sensitivity)
- Increase Sirtuins:
  - ↑ Red Wine and ↓ Calories

Premature Ageing

01:30:33
NEETPG 2020
INICET 2022

- Progeroid syndrome
  - Werner syndrome
    → Adult onset
    → DNA helicase defect
  - Hutchinson-Gilford syndrome
    → Childhood onset
    → Lamin A defect (LMNA deficiency) → Laminopathy

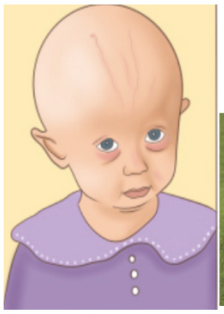



Yourwish

Important Information

- Wermer syndrome → MEN I syndrome

Free Radical Injury

FMGE 2025 INICET 2024

- Free radicals are Reactive O_2 species
  - Cause Lipofuschin++
- Oxygen is converted to Superoxide
  - Triggers: Toxins, Poison, Chemicals
- Superoxide Dismutase converts Superoxide into Hydrogen Peroxide
- Fenton's Reaction:
  - Hydrogen Peroxide reacts with metals (Fe, Cu) to form the Hydroxyl Radical (most potent)
  - During this process, Fe^{2+} is converted to Fe^{3+}

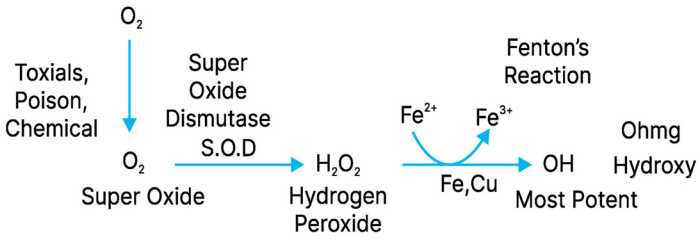

- Ferroptosis:
  - Fe induced cell death
  - Resembles necrosis
  - Master Regulator → Glutathione Peroxidase 4

Protection

- Diet: Vit A, C, E
- Transport proteins:
  - Fe - Transferrin
  - Cu - Ceruloplasmin
- Enzymes:
  - Catalase: Breaks down Hydrogen Peroxide
  - Glutathione Peroxidase: Breaks down Hydrogen Peroxide and Hydroxyl Radical
  - Superoxide Dismutase → Protection in the Brain
    → SOD1 Gene Mutation: Amyotrophic Lateral Sclerosis
    - UMN + LMN
    - Microscopic Examination: Bunina Bodies

PYQs

01:37:57

Q. Which of the following types of cell death involves activation of caspase enzymes?

a. Necrosis and Apoptosis
b. Apoptosis and Pyroptosis
c. Apoptosis and necroptosis
d. Apoptosis only

Yourwish

Yourwish

Answer: **b. Apoptosis and Pyroptosis**

- Pyroptosis involves caspases 1, 4, 5, 11
- Apoptosis:
  - Initiator Caspases 8, 9, 10
  - Executioner Caspases: 3, 6, 7

Q. Which nuclear change of cell injury is being shown in the image?



a. Pyknosis
b. Karyorrhexis
c. Karyolysis
d. Normal nucleus

Answer: **b. Karyorrhexis**

Q. Which of the following is an anti-apoptotic gene?
a. BAK
b. MCL1
c. PUMA
d. BAD

Answer: **b. MCL1**

Q. Caspase-1 is primarily involved in which type of programmed cell death?
a. Apoptosis
b. Pyroptosis
c. Necroptosis
d. Necrosis

Answer: **b. Pyroptosis**

Q. Which of the following is pro-apoptotic?
a. Bcl-2
b. Bcl-xL
c. Mcl-1
d. Bax

Answer: **d. Bax**

Q. Histopathological difference between Barrett's epithelium and gastric mucosa? FMGE 2025 INICET 2024
a. Barrett's mucosa is acidic and stains alcian blue positive
b. Barrett's is alkaline and stains prussian blue positive
c. Barrett's alcian blue is negative because it's neutral
d. Gastric mucosa is alkaline and stains alcian blue positive

Answer: **a. Barrett's mucosa is acidic and stains alcian blue positive**

Yourwish

Q. A diabetic male presented with seizures. Radiological examination shows a lesion. Histopathological examination shows liquefactive necrosis. What is the most important mechanism responsible for this?

a. Enzymatic degradation
b. Mechanical
c. Ischemic
d. Pressure

Answer: a. Enzymatic degradation

Q. Which of the following are the changes seen in irreversible cell injury?

a. Bleb formation
b. Amorphous density of mitochondria
c. Clumping of chromatin
d. Cellular Swelling

Answer: b. Amorphous density of mitochondria

Q. Apoptotic bodies comprise of?

a. Include cytoplasm + intranuclear material + organelle
b. Cytoplasm + organelle
c. Organelle + intranuclear material
d. Only organelle

Answer: a. Include cytoplasm + intranuclear material + organelle

Q. Which among the following is less related to irreversible cell injury?

a. Blebs formation
b. Karyolysis
c. Amorphous densities
d. Pyknotic nucleus

Answer: a. Blebs formation

Q. Stepladder pattern on gel DNA electrophoresis is seen with?

a. Necrosis
b. Apoptosis
c. Both A and B
d. None of the above

Answer: c. Both A and B

- Stepladder pattern on gel DNA electrophoresis is most likely seen with Apoptosis

2. INFLAMMATION

CLASSIFICATION OF INFLAMMATION

00:00:20

Based On Fluid Type

Type	Appearance	Example
Serous	Watery	E.g., Serofibrinous pericarditis AKA Bread & butter pericarditis
Fibrinous	Thready/Stringy	
Purulent	Pus	E.g. Abscess
Catarrhal (M/c)	Mucus + water	E.g. Common cold

Based On Duration

Type	Duration	Lab investigations	Exception
Acute	• Early onset • Short lived	• All acute inflammations show neutrophils	• Typhoid- Shows relative lymphocytosis
Chronic	• Delayed onset • Long lived	• All chronic inflammations show **L**ymphocytes, **M**acrophages, and **P**lasma cells	• Chronic pseudomonas- Show an increase in neutrophils

ACUTE INFLAMMATION- EVENTS

00:03:42

Vascular Events

AIIMS 2019, FMGE 2021

- **Vasocontriction:** First event; transient; reflex
- **Vasodilation:** Increased blood flow due to histamine, serotonin
- **Increased vascular permeability:**
  - Cells, plasma, protein move out of blood vessels → Exudate/edema
- **Stasis:** Increased RBC viscosity → Sluggish blood flow

Increased Vascular Permeability

00:06:45

- Hallmark event of acute inflammation

Mechanisms	Actions
Endothelial cell contraction/ retraction	• Endothelial cells are CD34+ • Gaps are created by serotonin & histamine between 2 Endothelial cells • Immediate & transient response • M/c mechanism

Yourwish

Direct endothelial injuries	• Either something from inside/outside damages the endothelial cells
	  ○ Delayed sunburn- Delayed, prolonged response
	  ○ Sepsis- Immediate, sustained

Transcytosis	• Gaps are not formed between 2 cells, but a secret tunnel called the Vesiculo-vacuolar organelle through the cell is formed • Due to VEGF, histamine
Angiogenesis	• New/immature blood vessels- Leaky channels • Due to VEGF, histamine

Cellular Events

00:11:50

Mnemonic- M RAT COP

AIIMS 2021, NEET PG 2018

— Margination

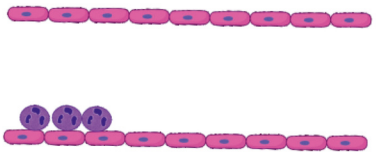

- Normal physiology
  - Normal laminar flow- Cells at the centre & plasma at the periphery
  - Centremost cells- RBCs
- Pathology
  - As the plasma leaks out through the cells, the RBCs come to the periphery

R- Rolling & Weak Adhesion

- Cells that come from the periphery start rolling with weak adhesion (roll and stop, and then roll)
- Rolling is done by Selectins/CD26+
- Types of selectin
  - P selectin- Present on the Platelets, Endothelial cells
  - E selectin- Present on the Endothelial cells
  - L selectin- Present on the Leucocytes
- P & E selectins bind to Sialyl Lewis X
- L selectin binds to Glycam/Madcam/CD34

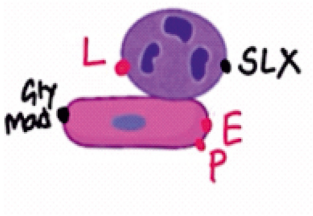

A- Adehsion

- After the cells roll, they stop rolling by adhesion through integrins present in WBCs
  - β_1, AKA VLA- Bind to VCAM
  - β_2, AKA CD11/18, LFA/Mac- Binds to ICAM



Important Information

ICAM

- Binds to β_2 integrin
- Rhinovirus attachment
- Plasmodium falciparum attachment (cerebral)

T- Transmigration/Diapedesis

- Migration of the cell out of the vessel
- Mediated by PECAM-1/CD31

Yourwish

Yourwish

- Requires breakdown of the basement membrane by MMP (Matrix Metalloproteinase)
- Zinc is required for the functioning of MMP



C-Chemotaxis

- Unidirectional targeted movement of WBC to bacteria
- Facilitated by chemotactic agents
  - Exogenous- Bacterial products
  - Endogenous- **L**T-B_4; **I**L-8; C_{5a}/C_{3a}

O-Opsonization

- Coating of bacteria with Opsonin
- Most important Opsonin- IgG
- Most important complement Opsonin- C_{3b}

P-Phagocytosis

- Phagolysosome formation
- Intracellular killing
- O_2-dependent killing (more potent)
  - Activation of NADPH oxidase (most important); PHOX gene
  - H_2O_2-MPO-HALIDE system
- O_2 independent killing
  - E.g., MBP (Major Basic Protein) release by eosinophils killing parasitic infection

Nets

00:25:50

NEET PG 2022, AIIMS 2018

- Neutrophil Extracellular Traps
- Nuclear chromatin is sent extracellularly with the help of Arginine (amino acid) → Trap the microorganism → Kill it
- Beneficial suicide- At the end of the process, the neutrophil dies
- Side effect: ANA- SLE
- Extracellular killing

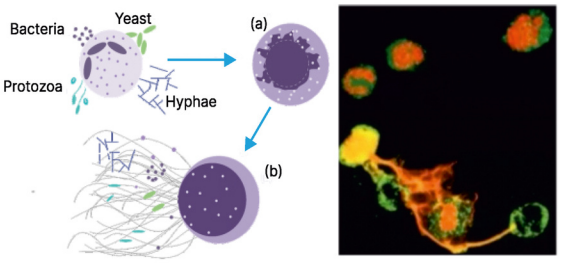

Emperiopolesis

00:29:00

AIIMS 2022

- Cell in cell appearance
- No killing
- No clinical significance
- Diseases showing Emperiopolesis
  - **M**yelodysplastic syndrome/Myeloproliferative neoplasm
  - **A**utoimmune hepatitis
  - **R**osai Dorfmann disease
  - **C**hronic lymphocytic leukemia

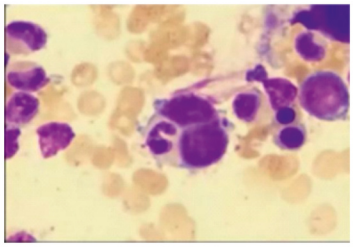

Yourwish

Associated Diseases

00:30:25

Disease	Defect	Clinical features
LAD-1 (Leucocyte Adhesion Disease)	• β_2 integrin (CD11/18)	• Autosomal recessive • Delayed umbilical cord stump shedding
LAD-2	• Sialyl Lewis x	• Autosomal recessive • Bombay blood group (Oh)- A, B, H antigens are absent, and A, B, H antibodies are present
LAD-3	• FRMT 3 gene	• Autosomal recessive • Bleeding
Bruton's hypogammaglobulinemia	• BTK gene	• M/c in boys • B-cell defect (decreased plasma cells) • Decreased opsonisation (Decreased IgG)
Chediak Higashi Syndrome	• LYST gene	• C- CNS/Neurological problem • HE- Hemorrhage • DI- Decreased immunity • A- Albinism; Silvery gray hair • K- Coarse granules 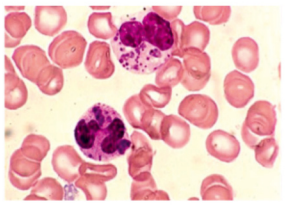
Chronic granulomatous disease	• Deficiency of NADPH oxidase (PHOX gene) → No phagocytosis	• Infections: Catalse +ve; S.aureus • Screening- NBT (Nitroblue Tetrazolium) • Confirmatory/Diagnostic- DHR (Dihydrorhodamine)

MEDIATORS OF INFLAMMATION- CLASSIFICATION

00:37:30

Cell-Derived Mediators

FMGE 2021, 2024, AIIMS 2018, NEET PG 2018, 2019

Preformed Mediators

Preformed mediators	Functions
Histamine	• Source: Mast cells (richest source), Basophils • Vasodilation, increased vascular permeability, and bronchoconstriction
Serotinin	• Source: Enterochromaffin cells (richest source), Platelets
Lysosomal enzymes	
Primary granules/ Azurophilic granules	• Release Acid hydrolase, Bacteria killer myeloperoxidase, Collagenase, Cathepsin, Defensin, Elastase, Lysozyme
Secondary granules/Specific granules	• Release Specific collagenase (type IV), lactoferrin, Lysozyme
Tertiary granules/C particles	• Release Gelatinase

Important Information

- Toluidine blue stain is used to dye mast cells and basophils

Newly Formed Mediators

Newly synthesized mediators	Functions
Nitric oxide	• Antiplatelet aggregator, Vasodilation L-Arginine $\xrightarrow{\text{iNOS}}$ NO + L-Citrulline
Platelet-activating factor	• Platelet aggregation, vasoconstriction • More potent than histamine
Chemokines	• Attract WBCs • C- Cysteine • X- any other AA
CXC3	• E.g., Fractalkine
CXC (α)	• E.g., IL-8 (attracts neutrophils)
CC (β)	• E.g., Eotaxin (Attract eosinophils), Rantest (Attract T-cells), MCP (Attract monocytes, macrophages)
C ( )	• E.g,. Lymphotactin (attracts lymphocytes)

Newly Synthesized Cytokines

AIIMS 2022 FMGE 2024

Newly synthesized cytokines	Function
Fever	• IL-1, IL-6, TNF-α
Decrease appetite	• TNF-alpha
Regulates acute-phase reactants	• IL-6 • Positive APR: CRP, Hepciden, Ferritin, Fibrinogen, SAA • Negative APR: Transferrin, Transcortin, Transthyretin, Albumin • IL-6 is mediatory for Multiple Myeloma and Anemia of chronic disease
Pro and anit-inflammatory	• IL-4, IL-6
Anit-inflammatory	• IL-10
Most fibrogenic	• TGF-β
T cell maturation	• IL-7

Yourwish

Eosinophil activation	• IL-5
Neutrophil recruitment	• IL-8

Important Information

- TNF-α- Decreases appetite
- TGF-α- Mentrier disease (increased)
- TGF-β- Most fibrogenic

Newly Synthesized Interferons

	Sources	Functions
INF-α	Leucocytes	Antiviral properties
INF-β	Fibroblasts	T/t of Multiple Sclerosis
INF-γ	TH_1 cells	Granuloma formation T/t of Chronic granulomatous disease

NEWLY SYNTHESIZED MEDIATORS- ARACHIDONIC ACID METABOLITES

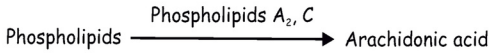

- Arachidonic acid has 20 carbon compounds
- Causes inflammation, neutrophils, pain, etc.
- T/t- Steroids (inhibit Phospholipase A_2, C)

Mechanisms by which Arachidonic acid causes inflammation

Cyclo-oxygenase pathway	• Produces Prostaglandins, Thromboxane 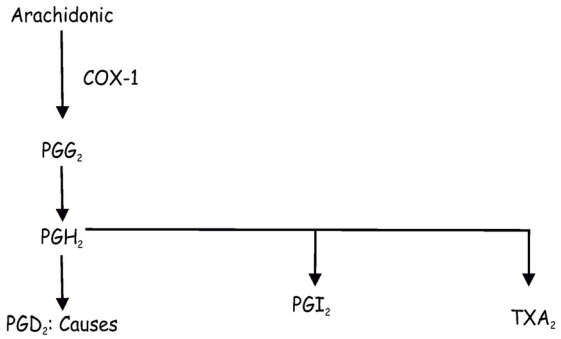 **Peptic ulcer disease** • COX-1 is gastroprotective • Using NSAIDs/Aspirin inhibits COX-1, leading to PUD • To prevent PUD, while treating inflammation, Selective COX-2 inhibitors are used (e.g., Celecoxib)

Yourwish

Yourwish

Lipo-oxygenase pathway	• Produces Leukotrienes, Lipoxins 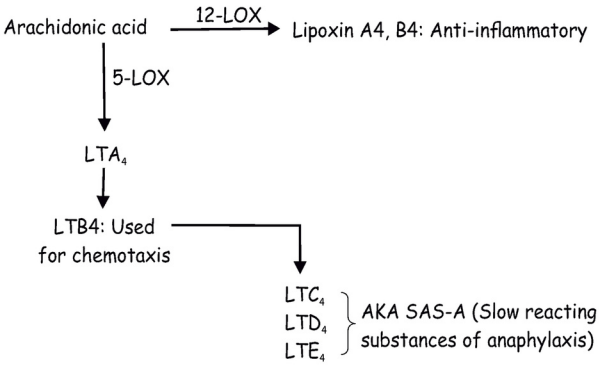 • **Treatment of asthma** ○ Zileuton inhibits 5-LOX ○ LTR_c antagonist (E.g. Montelukast) targets LTC_4, LTD_4, LTE_4

Plasma Derived- Complement System

01:00:20

	Classical pathway	Lectin pathway	Alternative pathway
Triggered by	IgM, IgG	Organisms	IgA
Starts from	C_1	C_2, C_4	C_3
Resulting in	**Membrane attack complex (MAC)** • Causes bacterial lysis • Composition of MAC- C_{5b} to C_9		

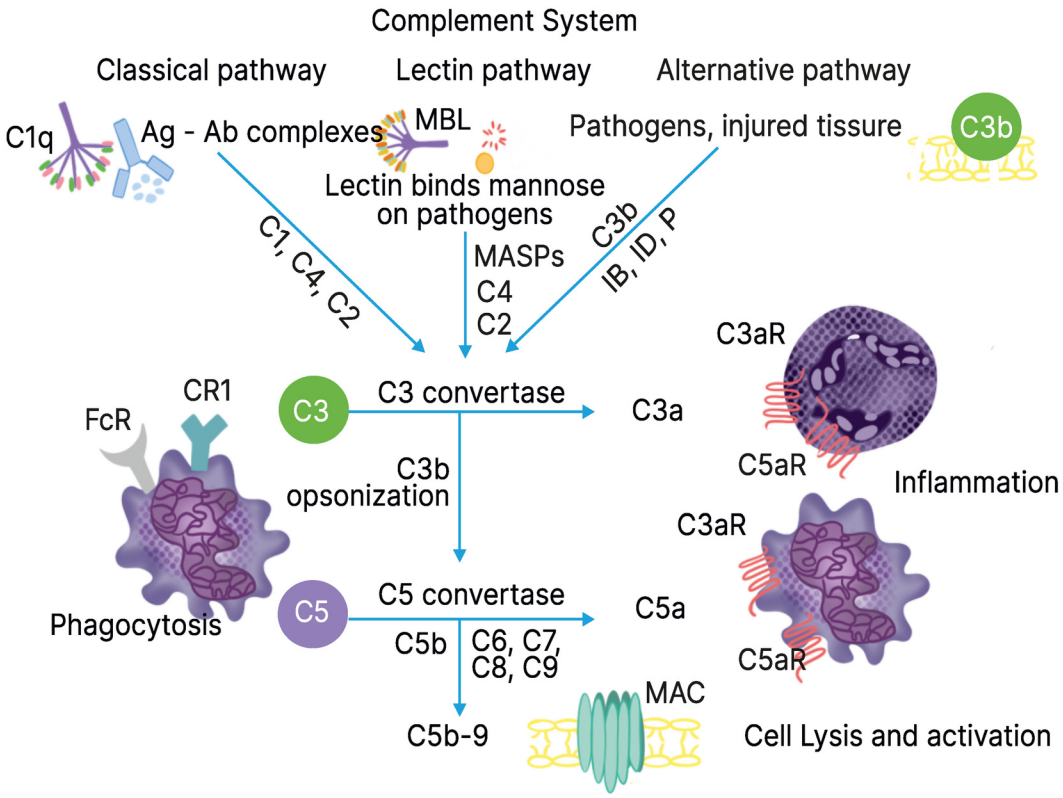

Yourwish

Deficiencies Associated With The Complement System

01:02:58

Deficiency	Disease
M/c complement deficiency	• C_2
C_1, C_2, C_4 deficiency	• Associated with SLE
MAC deficiency (C_{5b} to C_9)	• Meningococcal infections

C_1 inhibitor deficiency	• C_1 is inhibited by C_1INH
	• C_1INH deficiency results in Hereditary angioedema; Autosomal dominant
	  ○ Lips, eyes, laryngeal edema
	  ○ Emergency- Respiratory difficulty 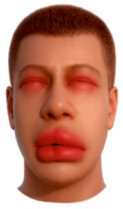

CHRONIC INFLAMMATION

01:05:25

Macrophages

INICET 2022, FMGE 2020, 2023

- AKA Histiocytes

Organ	Macrophages
Brain	Microglia
Lungs	Dust cells/Alvolar macrophages
Liver	Kupffer cells
Kidney	Mesangial cells
Spleen	Littoral cells
Placenta	Hoffbauer cells
Bone	Osteoclasts
Synovium	Type A synoviocytes

Important Information

- Zika virus localizes in Hofbauer cells of the placenta during mother-to-child (vertical) transmission

Granulomatous Inflammation

01:07:20

- Subtype of chronic inflammation
- Components of Granuloma

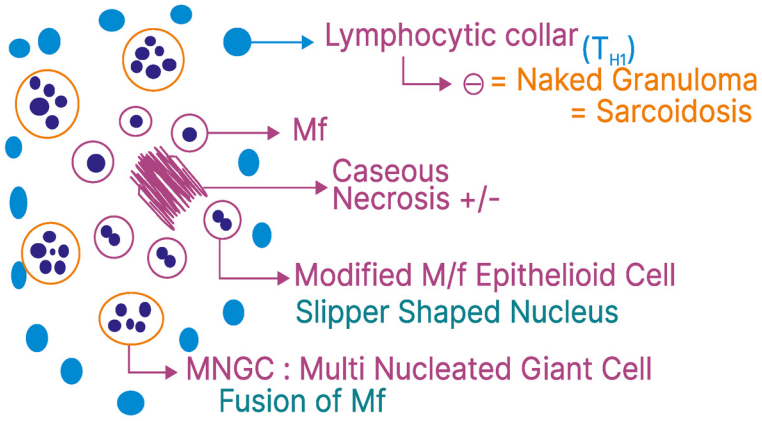

Multinucleated Giant Cells

01:10:35

Type	Nuclei	Disease
Langhans GC 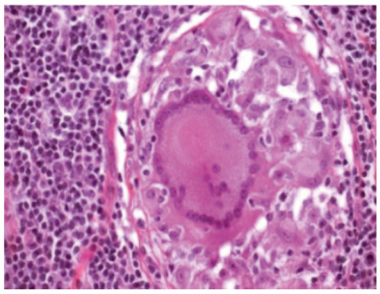	Horseshoe-shaped nuclei	TB
Touton GC 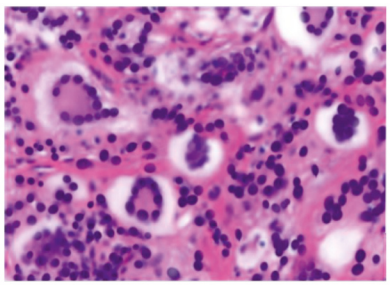	Wreath nuclei (round-shaped)	Xanthoma
Foreign body GC 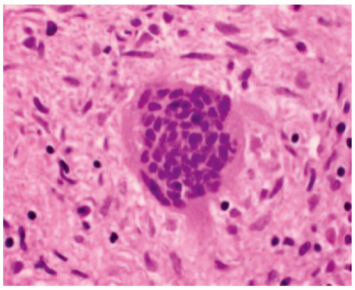	Haphazard nuclei	Foreign body

Yourwish

Warthin Finkeldey GC 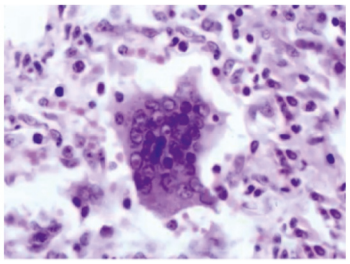	Intranuclear & intracytoplasmic inclusion	Measles (fever + 3C- Cough, Coryza, Conjunctivitis)
Reed Sternberg GC 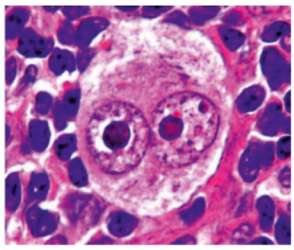	Owl eye appearance (redish pink) 	Hodgkin's lymphoma
CMV GC 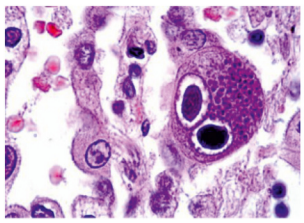	Owl eye appearance (green)	CMV
Herpes Giant cell 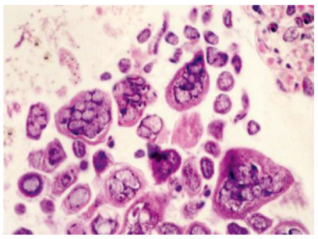	Multinucleation, Molding, Margination	HSV

Important Information

- Langerhans cells are antigen-presenting cells of the skin

Special Types Of Granulomas

01:14:30

Type	Disease
Stellate granuloma 	• Cat scratch disease (Bartonella henselae) • Lymphogranuloma venereum (Chlamydia)

Yourwish

Doughnut granuloma 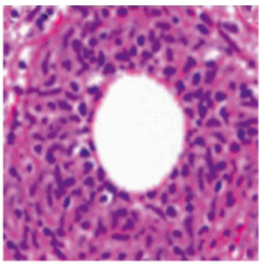	• Q fever (Coxiella) • Allopurinol overdose
Durck granuloa 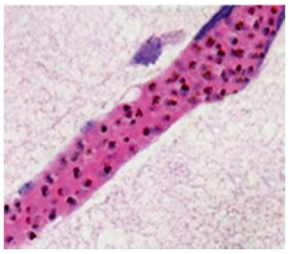 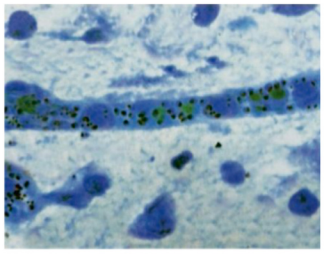	• Plasmodium falciparum- Cerebral malaria ○ Stained using the Field stain

WOUND HEALING

01:16:25

INICET 2024 FMGE 2024

- Types:
  - Primary intention- Clear regular wound (surgical incision)
  - Secondary intention- Dirty irregular wound (wounds incurred in RTA)

Day 0	• Blood clot: Platelet + Fibrin
Day 1	• Blood clot, Neutrophils
Day 2	• Blood clot, Neutrophils • Thin epithelial layer
Day 3	• Macrophages • Granulation tissue starts (Hallmark of repair)- Rich in blood vessels • Collagen starts along the margins
Day 5	• Granulation tissue maximum • Collagen bridging
Day 21 (week 3)	• Collagen maximum (scar)

Commonly Asked Questions (Surgery + Pathology)

Questions	
Factors needed for wound healing	• Vitamin C • Zinc

Yourwish

M/c cause of delayed wound healing	• Infections
100% wound strength	• Never
Collagen start	• Collagen type 3
Collagen end	• Collagen type 1 • Ratio of Type 1 to Type 3 at the end of wound healing- 4:1
Wound contraction	• Caused by Myofibroblast ○ Contraction + collagen production

Excessive Wound Healing

01:23:00

Excessive granulation tissue	Excessive scar- Keloid	Excessive scar- Hypertrophic scar
• AKA proud flesh • T/t- Cauterization 	• Crosses wound margins • M/c site- Sternum • T/t- Intralesional Injection of Triamcinolone (steroid)  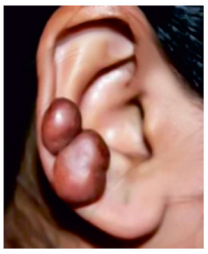	• Within wound margins 

Masson Trichrome Staining

- Done to differentiate between muscle and collagen
  - Muscle- Red
  - Collagen- Bule

Keloid	Hypertrophic scar
• Haphazard thick collagen 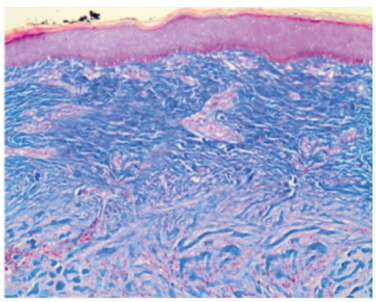	• Orderly arranged thin collagen 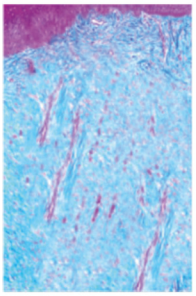

MCQs

01:25:47

Q. Which of the following molecules helps in the firm adhesion of the leukocyte to the endothelium during inflammation?

a. P-selectin
b. Platelet-activating factor
c. VCAM-1
d. Complements

Ans: c

Q. A 12-year-old child presented with 15 days of cough. On examination, cervical lymphadenopathy was noted, and the lymph node biopsy showed caseating granulomas. What is the most probable diagnosis?

a. Tuberculosis
b. Leprosy
c. Sarcoidosis
d. Syphilis

Ans: a

Q. Which of the following parameters decreases in acute inflammation?

a. CRP
b. Hepcidin
c. Fibrinogen
d. Albumin

Ans: d

Q. Cyclooxygenase plays a role in which of the following pathways?

a. Kreb's cycle
b. Prostaglandin
c. Leukotriene
d. Vitamin K

Ans: b

Q. During acute inflammation, leukocytes exit the bloodstream and migrate toward the site of tissue injury through several coordinated steps. Arrange the following events in the correct chronological order:

1. Chemotaxis	**5. Phagocytosis**
2. Adhesion	**6. Margination**
3. Opsonization	**7. Cytokine-mediated integrin activation**
4. Rolling	**8. Transmigration**

a. 1, 2, 3, 4, 5, 6, 7, 8
b. 6, 4, 7, 2, 8, 1, 3, 5

Yourwish

c. 4,6,2,1,3,7,8,5
d. 2,1,4,3,5,6,7,8

Ans: c

Q. Basement membrane degradation is caused by:
a. Matrix metalloproteinases
b. Oxidases
c. Elastases
d. Hydroxylase

Ans: a

Q. The main feature of chemotaxis is:
a. Random movement of neutrophils
b. Adhesiveness to blood vessels
c. Phagocytosis
d. Unidirectional locomotion of neutrophils

Ans: d

Q. A 19-month-old male child presents with recurrent infections. Peripheral blood smear shows neutrophilic leukocytosis. Advanced studies show a defect in the neutrophilic adhesion. Further, the mother gives a history of delayed umbilical cord stump shedding. The child's defect is mostly commonly attributed to?
a. LAD 1
b. LAD 2
c. Bruton's agammaglobulinemia
d. SCID

Ans: a

Q. A 10-year-old child presents with repeated bleeding episodes, delayed milestones, and hypopigmentation. Peripheral smear shows the following findings. What is your likely diagnosis?
a. Defect in selectins
b. Defect in phagocytosis
c. Defect in opsonization
d. Defect in integrins

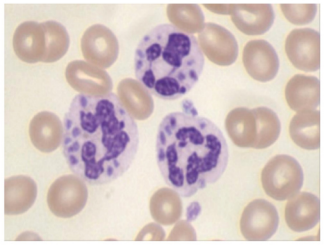

Ans: b

Q. Find the incorrect match?
a. Osteoclast – Physiological giant cell
b. Touton giant cells – Xanthogranulomatous disease
c. Warthin-Finkeldey giant cell – Measles
d. Langerhans cell – TB

Ans: d

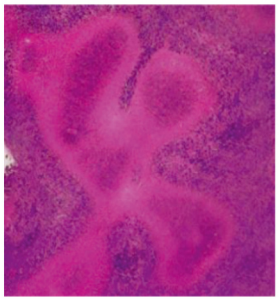

Q. The granuloma shown below is associated with which of the following diseases?

a. Cat scratch disease
b. LGV
c. Both a and b
d. None

Ans: c

Yourwish

5. GENETICS

Term	Meaning
Genotype	Genetic makeup of an individual
Phenotype	Final expression of the genes

- Example (Eye colour):
  - Mother: Brown eyes
  - Father: Black eyes
  - Genes from both → Genotype
  - Final expressed eye colour → Phenotype

OVERVIEW OF GENETIC DISORDERS

- Mendelian disorders
  - Autosomal dominant
  - Autosomal recessive
  - X-linked recessive
  - X-linked dominant
  - Y-linked
- Non-Mendelian disorders
  - Mitochondrial inheritance
  - Trinucleotide repeat disorders
  - Genomic imprinting
  - Gonadal mosaicism
- Chromosomal disorders
- Multifactorial disorders

MENDELIAN DISORDERS

00.47.00

Autosomal Dominant (Ad)

- MC inheritance overall
- Autosomal → No gender bias (males = females)
- Dominant → All generationS affected

Mnemonic	Disorders

HE (Hereditary disorders)	• Hereditary spherocytosis
	• Hereditary hemorrhagic telangiectasia
	• Hereditary non polyposis colon cancer HNPCC (Lynch syndrome)
	  ○ CEO has gone for lunch
	  → Colon cancer

	→ Endometrial cancer → Ovarian cancer
Has	• Huntington disease • Hypertrophic cardiomyopathy (banana-shaped heart)
A	• ADPKD
Very	• Von Willebrand disease • Von Hippel-Lindau (Deletion 3p)
D	• Muscle dystonia
O	• Osteogenesis imperfecta
M	• Marfan syndrome
I	• Intermittent porphyria
N	• NF1, NF2
A	• Achondroplasia
N	• Noonan syndrome
T	• Tuberous sclerosis
Powerful	• Pseudohypoparathyroidism
Father (FA)	• Familial adenomatous polyposis • Li-Fraumeni syndrome (p53 mutation) • Familial hypercholesterolemia

- Structural protein defects → Autosomal dominant

Marfan Syndrome

00.04.26

- Genetics
  - Autosomal dominant Inheritance
  - The chromosome 15 is involved
  - Gene → FBN1 (Fibrillin-1)
- Dominant Negative Concept
  - Defective protein → Fibrillin
  - Negatively affected protein → Elastin
  - Here, the mutated FBN1 Gene not only makes the fibrillin protein defective but also negatively affects the function of the elastin protein.
- Revised Ghent Criteria for the diagnosis of Marfan syndrome
  - Presence of a family history of Marfan syndrome in AD inheritance
  - Presence of Fibrillin mutation
  - Clinical features of Marfan syndrome

Yourwish

- **CLINICAL FEATURES**
  - M – Mitral valve prolapse: MC cardiac abnormality
  - A – Aortic dissection: MCC of death
  - R – Retinal detachment
  - F – Freely movable joints, the MC involved is the thumb
    → Hypermobile joints
- they can move their joints(thumb) in any direction)
  → Arachnodactyly (spider fingers- Very long fingers)
- Steinberg sign (thumb sign)
  → When the patient makes a fist, their thumb will be projecting out
- Walker sign (wrist sign)
  → They can hold their wrist between the thumb and the little finger
  → High arched palate
  - A – Arachnodactyly (SPIDER fingers), High Arched palate
  - N – Nine feet tall
  - S - Syndrome/ Sternum issue – Pigeon chest
  - Disease, Dislocation of lens / ectopic lentils

Condition	Lens Dislocation Direction	Mnemonic
Marfan syndrome	Superotemporal (up & out)	Fan on ceiling → up & out
Homocystinuria	Inferonasal (down & in)	HomocystINuria → IN (down & in)

- Most Common Abnormality
  - Overall → Skeletal
  - Cardiac → Mitral valve prolapse

Autosomal Recessive (Ar)

- AR is the MC inheritance for inborn errors of metabolism
- Autosomal - No gender bias is present
- Recessive means hiding → every generation will not show the disease (Generations skipped)
- Mnemonic Pasta and Fried Chaval

Mnemonic	Disorders
PASTA	• P - Phenylketonuria (musty/mousy odor of urine) • A - Alkaptonuria (Black urine when standing; black cartilage; such as the tips of the ears, nails, due to the buildup of homogentisic acid) • S - Sickle cell anemia • TA - Thalassemia

FRIED CHAWAL	• Fried - Friedreich ataxia
	• C - Cystic fibrosis
	• H (All HC)
	  ○ Hemophilia C
	  ○ Homocystinuria
	  ○ Hemochromatosis. – iron overload
	• A – Alpha-1 antitrypsin deficiency

Yourwish

Yourwish

FRIED CHAWAL	• W - Wilson disease
	• A -
	  ○ Albinism
	  ○ Congenital adrenal hyperplasia.
	• L - All lysosomal storage disorders
	  ○ Exception (XLR)
	  →Fabry disease
	  →Hunter disease

Big FAX	• Big - Bloom syndrome • F - Fanconi anemia • A- Ataxia telangiectasia • X- Xeroderma pigmentosum

Lysosomal Diseases

00:13:14

FMGE 2025, INICET 2019, 2020, 2025

Feature	Tay-SAchs [Six]	Niemann-Pick [A man has gone to pick the zebra]	Gaucher [Ouchers]
Enzyme Deficiency	Alpha Hexosaminidase	Sphingomyelinase	β-Glucocerebrosidase
Key Features	Neurodegeneration	Lipid accumulation	Bone pain[ouch], cytopenias
Organomegaly	No	Splenomegaly	Splenomegaly
Classic Cells/Findings	Balloon neurons(water balloons); Onion-skin in lysosomes	Zebra bodies (in lysosomes)	"Crumpled tissue paper" appearance in macrophages
Eye Finding	Cherry-red spot (in macula)	Cherry-red spot (can be present)	
	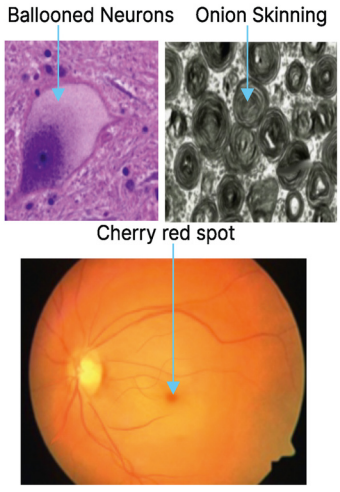	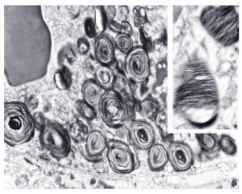 Zebra Bodies	NEET PG 2024, INICET 2024 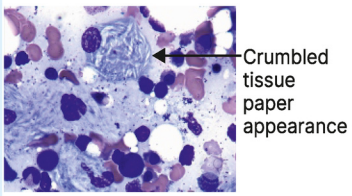

X-Linked Recessive (XLR)

- Males are affected, since they carry only 1 X chromosome
- Females are carriers - She carries a defective chromosome

Yourwish

NEET PG 2024
FMGE 2025
INICET 2025

Mnemonic: Wise Abcdefgh

- WISe - Wiskott-Aldrich
- A - Hemophilia A, B
- B - Bruton's agammaglobulinemia
- C - Chronic granulomatous disease, red-green color blindness, ocular albinism
- D - Duchenne Muscular Dystrophy, Becker Muscular Dystrophy
- E - Lesch-Nyhan (HGPRT deficiency)
- F - Fabry,Fragile X (more common XLR > XLD)
- G - G6PD deficiency
- H - Hunters disease



Important Information

- Hemophilia C= AR
- Hemophilia AB=XLR
- Albinism = AR
- Ocular albinism = XLR

X-Linked Dominant (XLD)

00:19:22

- DAD To All Daughters (DDD)
- Mnemonic: RAVI
  - R - Rett syndrome - Neurological problems
  - A - Alport syndrome (most common inheritance XLD), but can be AD, AR, XLR
  - V - Vitamin D-resistant rickets
  - I - Incontinentia pigmenti

Y-Linked (Holandric Inheritance)

- Father → All sons
- Example:Hairy ears/ Hypertrichosis

NON-MENDELIAN DISORDERS

00:21:55

Mitochondrial Inheritance

- mtDNA is only inherited from the mother
  - Mother → All the children get the disease
  - Father → None of the children gets the disease
- Most common Mitochondrial inheritance → MELAS
  - M— Mitochondrial
  - E - Encephalopathy
  - L - Lactic
  - A - Acidosis
  - S - Stroke-like episodes
- Most common Mitochondrial inheritance affecting Muscle involvement → CPEO
  - Chronic Progressive External Ophthalmoplegia
- Other:
  - LHON - Leber hereditary optic neuropathy
  - NARP - Neurogenic Ataxia Retinitis Pigmentosa

- Leigh syndrome
- Pearson syndrome
- Kearns-Sayre syndrome
- MERRF - Myoclonus Epilepsy with Red Ragged Fibers

INICET 2018, 2019

- MERRF - Myoclonus Epilepsy with Red Ragged Fibers
  - Myoclonus epilepsy
  - Muscle biopsy with Modified Gomori trichrome stain shows Red ragged fibers are in mitochondria
    → Phonographic record of mitochondrial appearance
    → Parking lot appearance

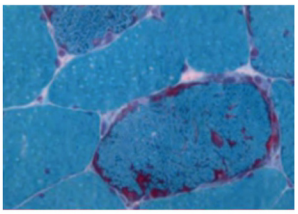
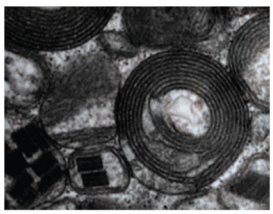

Trinucleotide Repeat Disorders

00:26:00

NEET PG 2021, FMGE 2019
INICET 2018

- These are a set of disorders in which the tri-nucleotide sequence will repeat many times.
- Intron (Non-coding - Introverts)
  - Fragile X → CGG
  - Myotonic dystrophy → CTG (Chr 19)
    → If they hold on to something cannot terminate grip
    → Christmas tree cataract
    → Hatchet face - prominent Jawline
  - Friedreich ataxia → GAA
- Exon (Coding - Extroverts)
  - Huntington → CAG (Chr 4)
  - Kennedy → CAG
  - [Kennedy Hunting in a CAGE]

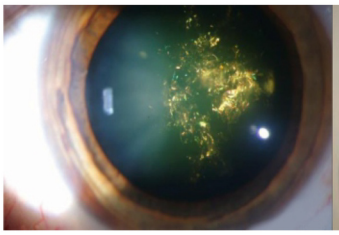
Christmas tree Cataract

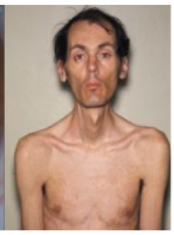
Hatchet Facies

Fragile X Syndrome

- Chromosome → Xq
- Gene → FMR1 9 (Familial mental retardation gene)
- Trinucleotide Repeats → CGG repeats

Repeats	Effect	Clinical condition
<55	• Normal	
55-200	• Premutation (Gain of function)	• Fragile X Tremors and Ataxia
>200	• Mutation (Loss of function)	• Fragile X syndrome

- Sherman's Paradox/ Anticipation
  - Number of repeats increase with every generation, which also worsens the clinical features

NEET PG 2018, 2019
INICET 2021

- Clinical Features
  - IQ will be 20-60
  - Facial features: Long face, Large ear, Large mandible
  - Most characteristic finding comes after puberty → Macroorchidism
  - Females are usually carriers, but they have Premature ovarian failure[POF]
- Diagnosis
  - IOC: PCR
  - If PCR fails: Southern blot (DNA)



Yourwish

Blotting Summary

Test	Detects
Southern(DOSA)	DNA
Northern(ROTI)	RNA
Western(PiZZA)	Protein
Eastern	Post-translational modification

Genomic Imprinting

00:35:00

- Genomic - Gene, Imprinting - Silencing
- Mechanism: Gene silencing via methylation(mute)
  - Gene Activation happens through Acetylation
- Chromosome 15 is affected in Prader-Willi and Angelman syndromes

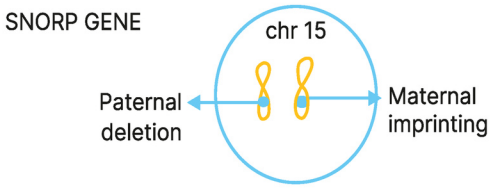

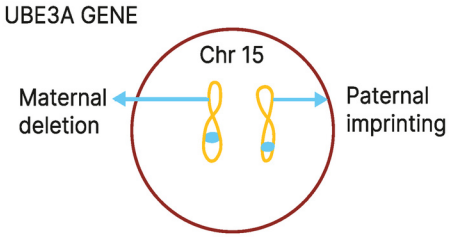

Feature	Prader-Willi (Chota Mota)	Angelman
Gene	SNORP	UBE3A
Deletion	Paternal deletion (Papa region deleted)	Maternal deletion (Mama region deleted)
Imprinting	Maternal imprinting(Silencing)	Paternal imprinting(Silencing)
Build	Short, obese	
Hormone	↑ Ghrelin is responsible for obesity.	
Clinical features	Intellectual disability	S -Seizures, A - ataxia R - Mental Retardation I- Inappropriate laughter They are called "Happy puppet."

- If Uniparental Disomy in these syndromes
  - Both chromosomes from one parent
  - If Maternal Disomy - So Paternal deletion → Prader-Willi
  - If Paternal Disomy - So Maternal deletion → Angelman

Gonadal Mosaicism

00:41:30

- Pop up / surprise case which happens in completely normal Parents (Father + Mother)
- There will be no family history.
- It is because of a mutation at the level after zygote formation, called a post-zygotic mutation

Yourwish

Yourwish

- Example: Osteogenesis Imperfecta, Tuberous Sclerosis
  - If Father has Osteogenesis imperfecta, then the inheritance is AD
  - If there is no family history of OI, then it is Gonadal Mosaicism

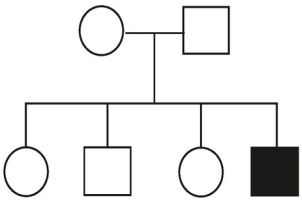

CHROMOSOMAL DISORDERS

00:43:20

NEET PG 2021
FMGE 2019, 2025
INICET 2018

Trisomy 21 (Down Syndrome)

- MC trisomy → Trisomy 16, which results in intrauterine death, mostly
- MC Trisomy compatible with life → Trisomy 21
- Trisomy is due to meiotic nondisjunction in the maternal ova in Chromosome 21
  - Resulting in an extra 21 st chromosome in the baby
  - Associated with advanced maternal age
- Clinical feature
  - Macroglossia: the tongue is very big
  - Micrognathia- Chin is small
  - Mongoloid faces
    → Eyes are inward and oblique, and the nose is flat
    → The nasal bone will be hypoplastic
  - Iris has Brushfield spots
  - Hands will show
    → Single palmar crease - **Simian crease**
    → Single crease in the 5th digit
  - Feet will have
- Sandal gap is the increased space between the great toe and the 2nd toe




Mongoloid Facies

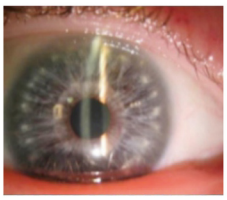
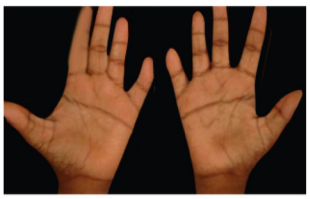


Sandal toe

- Complications

System	Finding
Leukemia	• MC leukemia overall ALL • MC leukemia in <3 years then is AML M7 • MC hematological abnormality is TAM(Transient Abnormal Myelopoiesis) ○ There will be 4 -5 months of abnormal WBC production, which will normalize after that
CNS	Presenile Alzheimer's usually starts at the age of 30
CVS	MC is Endocardial cushion defect > VSD
GIT	• Hirschsprung Disease • Duodenal atresia • Annular pancreas

Yourwish

Stage	Test	Findings in Down Syndrome
I. Screening	Ultrasound (USG)	• Nasal bone hypoplasia • ↑ Nuchal translucency
	Triple Test	• ↓ AFP ↓ Estriol ↑ β-hCG
	Quadruple Test	• ↓ AFP ↓ Estriol ↑ β-hCG ↑ Inhibin A
II. Confirmation	Karyotyping	Trisomy 21 (47, +21)

Trisomy 13 And 18

00:51:15

Feature	Trisomy 13 (Patau)	Trisomy 18 (Edward)
Cause	Maternal Origin	
CVS	VSD, PDA	
Feet	Rocker Bottom feet(convex feet)	
MR	Present	
Key Defects	Polydactyly	Strawberry skull - It is characterized by a very broad occipital region and a very small chin.
	Cleft lip, palate	Horseshoe kidney- The lower poles of both kidneys are fused.
	Coloboma- Keyhole defect in the eye	

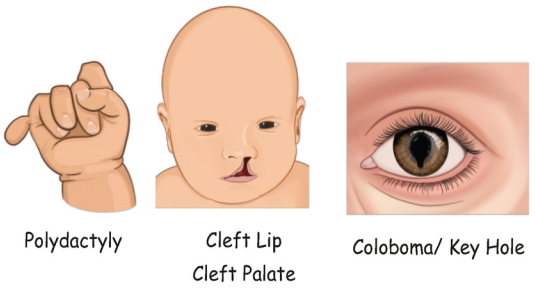

Polydactyly

Cleft Lip
Cleft Palate

Coloboma/ Key Hole

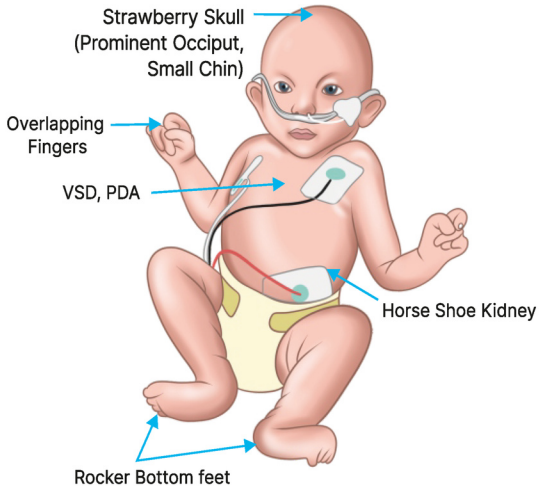

Important Information

- Multiple colobomas, which look like CAT eyes - Trisomy 22
- CAT cry/Cridu chat = partial deletion of chromosome 5p

Klinefelter (47XXY)

00:54:22

NEET PG 2024
FMGE 2024, INICET 2024

- Genetics: Presence of an extra X chromosome in a male patient
  - Genotypes 47XXY,48XXXY

- Cause : Maternal > Paternal nondisjunction (A/w advanced age of father)
- Clinical features
  - Mental retardation
    → The intensity of MR is more on increase in the number of X chromosomes
  - Hypogonadism ,tall stature
  - Secondary sexual characteristics are decreased
  - It is associated with Gynecomastia
- Complication
  - MC cancer:
    → Extragonadal germ cell tumors - Seminoma, teratoma occur outside the gonads, e.g., chest,mediastinum
    → They have an increased risk of male breast cancer(associated with BRCA2 mutation and Klinefelter's syndrome)
  - CVS : Mitral valve prolapse
- Hormone profile: ↓ Testosterone; ↑ LH, FSH

Turner (45xo)

00:57:23

NEET PG 2020, FMGE 2023
INICET 2020

- Genetics: 1 X chromosome will be deleted, 45XO, thus the person will be female
- Clinical features.
  - IQ will be normal (turners turns the table hence IQ normal)
  - Short stature
  - Webbed neck, it looks like the head and shoulder are bridged
  - Low posterior hairline- the hairline will come to the lower part of the neck
  - Streak ovaries/ Rudimentary ovaries- They present with primary amenorrhea
  - Congenitally, they can be born with a cystic hygroma(Lymphangioma)
  - Cardiac abnormalities
    → Bicuspid aortic valve
    → Coarctation of the aorta

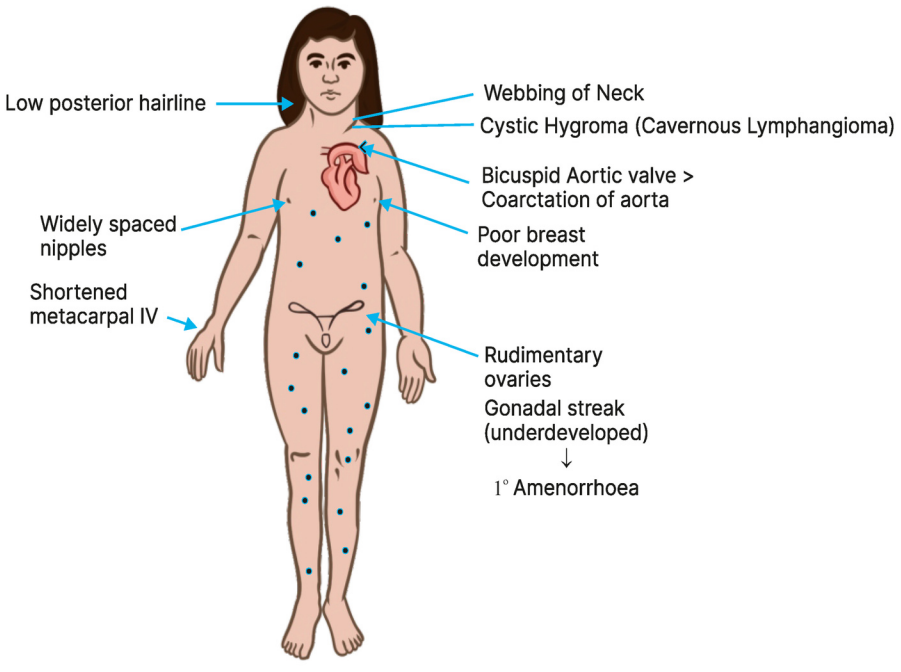

Yourwish

MULTIFACTORIAL

00:59:50

- Multifactorial inheritance is caused by the interplay of both genes and environmental factors.
  - Diabetes mellitus
  - Hypertension
  - Cleft lip/palate
  - Congenital heart disease

DIAGNOSIS OF GENETIC DISEASES

Pedigree Analysis

01:03:35

Symbol	Meaning	Symbol	Meaning
	Male		Index Case
	Female	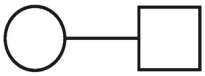	Marriage
	Unknown gender	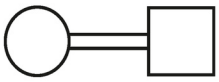	Consanguinous Marriage
	Stillbirth	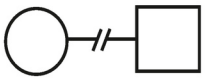	Divorced
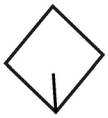	Miscarriage	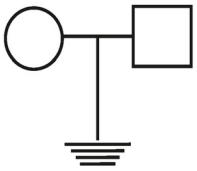	No Kids
	Pregnancy		Adopted
	Diseased	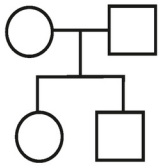	Offsprings
	Carrier		
	X Linked Carrier	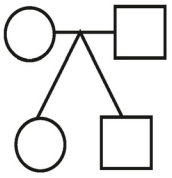	Dizygotic Twins
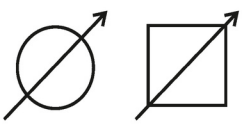	Death	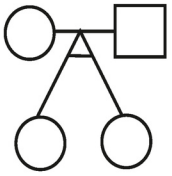	Monozygotic Twins

Yourwish

Yourwish

- 2G rule : Gender and generation
  - First look, is there any gender bias?
    → If gender bias is there, then X-linked
  - Then look at the generation
    → If generation is skipped, then Recessive

Category	Type	Key Features (2G Rule: Gender & Generation)
Mendelian Disorders	**Autosomal Dominant (AD)**	No gender bias; all generations affected
	Autosomal Recessive (AR)	No gender bias; generations skipped; common in inborn errors of metabolism
	X-Linked Recessive (XLR)	Usually, males are affected; females are carriers
	X-Linked Dominant (XLD)	Affected father → all daughters; affected mother → 50% of children
	Y-Linked (Holandric)	Father → all sons only
Non-Mendelian Disorders	**Mitochondrial Inheritance**	Mother → all children; father → none
	Gonadal Mosaicism	Appears suddenly ("Pop up") in offspring

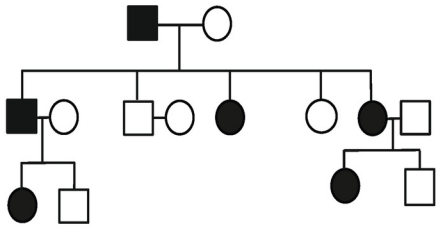	• No gender bias since both males and females are affected - Autosomal • All generations are affected- Dominant	• Autosomal Dominant
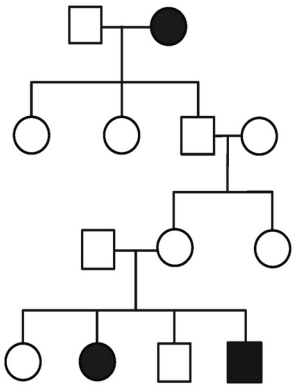	• No gender bias because both males and females are affected = Autosomal • Some generations are skipped = Recessive	• Autosomal recessive
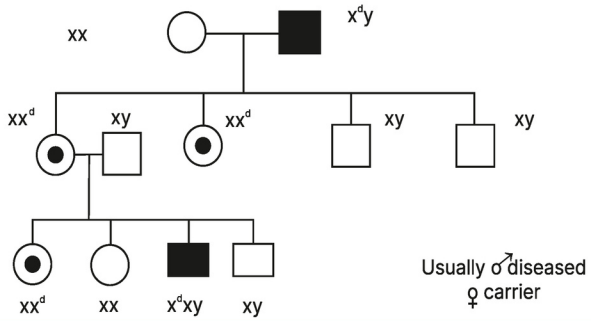	• Gender bias present: Only some boys have the disease and girls are not affected; they are just carriers • Some generations are skipped	• XLR

Yourwish

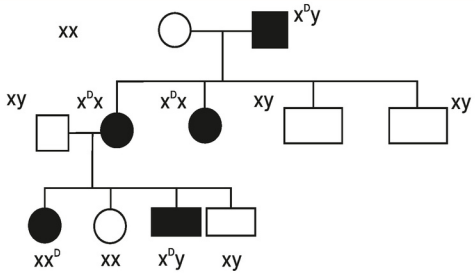	• Gender bias present: Both men and women are affected • No generations are skipped • Dad has given the disease to all daughters	• XLD
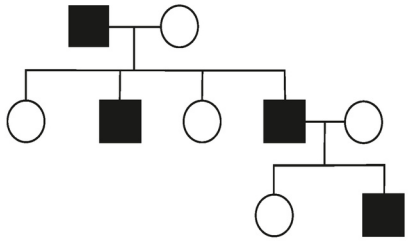	• Gender Bias: All of the men are affected • Generation: All generations are involved, with only boys	• Y-linked
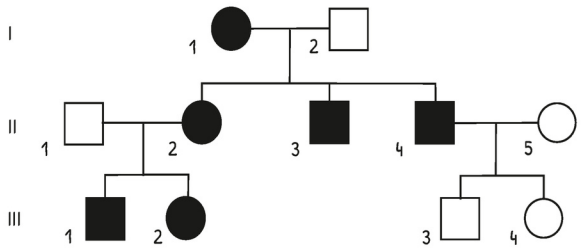	• Mother is giving a disease to all of her kids • Father to none	• Mitochondrial NICET 2018, 2025
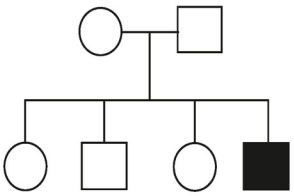	• It's a disease with surprise • None of the generations affected	• Gonadal Mosaicism

Karyotyping

01:08:15

- Sample
  - Pregnant women: Chorionic villi sampling (from 10th week) >Amniotic fluid
  - Normal individual: Blood lymphocytes(lymphocyte), Skin (Fibroblast)
- Arrest at metaphase with the help of Colchicine
- Fixative → Carnoy (Made from Methanol: Glacial Acetic acid = 3:1)
- Staining
  - G banding (Giemsa)
  - Q Banding → Quinacrine stain (Fluorescent Stain)
- The chromosomes are arranged in descending order of length
- Shortest chromosome - 21

INICET 2018, 2021, 2025

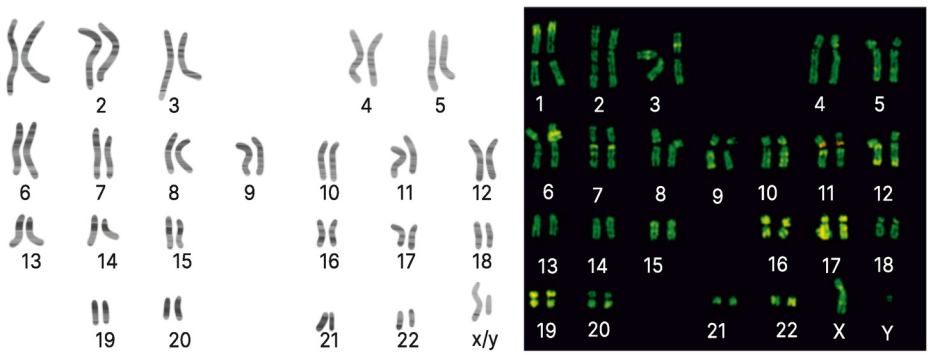

Fish

01:11:35

NEET PG 2024
FMGE 2024, 2025

- Fluorescent In Situ Hybridization
- Arrest at interphase
- Fluorescent probes are used
- Example
  - In the image red is 21 and green is 13
  - Then there are 3 - 21 chromosomes
- Fish can help detect chromosomal disorders
  - Amplification
  - Deletion
  - Translocation
  - Not a point mutation, we need PCR for that.

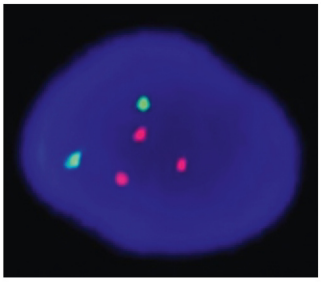

PCR

FMGE 2023
INICET 2018, 2020, 2021

01.12.25

- Steps: DAE
  - Denaturation (95°C)- separating the DNA into single strands
  - Annealing (55°C) - It is the making of new DNA by attaching primers
  - Extension (72°C) - Making of new DNA by extension
- Types

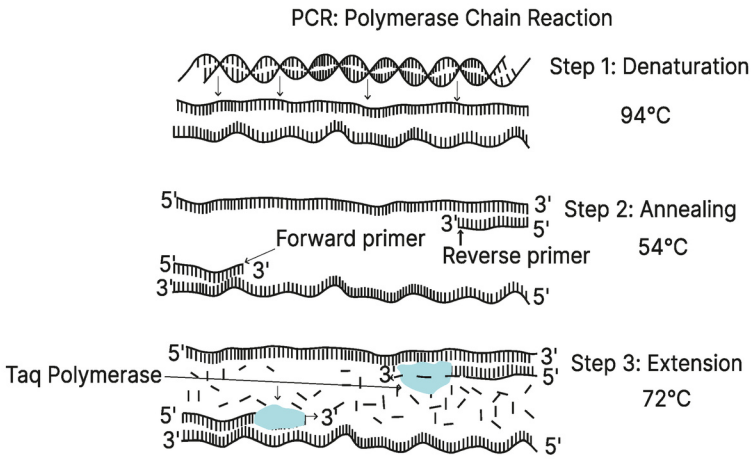

Technique	Description / Use
Sanger Sequencing	• Gold standard PCR

SBPE (Single Base Primer Extension)	• Performed when a specific mutation is known.
	• Example:
	  ○ Hairy cell leukemia - BRAF 600E codon;
	  ○ Polycythemia - JAK2 mutation in 617F codon .

Pyrosequencing	• Used when tumor yield is low or the sample is contaminated. • Eg : Biopsy samples or patients undergoing chemotherapy\ with less tumour cells ALL.
GWAS (Genome Wide Association Study)	• Used for research at the population level.
Amplicon Length Analysis (Fragile X)	• Used for lengthy DNA regions, mainly trinucleotide repeats.
RFLP (Restriction Fragment Length Polymorphism)	• Used for inheritance studies to determine the inheritance pattern.
Real-time PCR (Quantitative qPCR)	• Used in the prognosis of disease. • Eg: Bcr-AbL copies in CML

Yourwish

RT-PCR	• Used for RNA viruses. • Example: COVID (rRT-PCR).
Nested PCR	• Uses two primers on each strand during the annealing stage. • It is more specific.
Droplet PCR 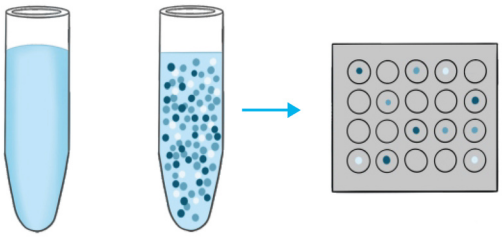	• Absolute quantification test. • One sample is divided into multiple droplets/parts, and multiple PCR reactions are performed on those samples.
Multiplex PCR 	• Uses many primers; • Random primers are used,so it does not give a specific outcome. • Time-saving but non-specific.

CGH (Comparative Genomic Hybridisation)

01:20:15

- Initial color
  - Normal gene green
  - Patient gene Red
- Following the mix

Color	Meaning	
Yellow	Normal	Normal
More of Red	Gain of mutation	Patient has something more
OnlyGreen	Loss of mutation	The patient gene is not working



Codominance

- When both of the genes are working together
- Egs: AB blood group,HLA

Lyon Hypothesis

- One of the X chromosomes becomes inactive
- It is decided randomly between the maternal and paternal X gene
- It happens as early as Day 5.5 of the embryo
- The XIST gene is responsible for the inactivation

- The sleeping or inactivated X chromosome
  - In buccal mucosa : Barr body
  - Drumstick appearance in neutrophils : Davidson body
- Formula for
  - Number of Bar bodies = (Number of X chromosomes) – 1
    → Males have (46XY) 0 bar bodies
    → Klinefelter's syndrome 48XXXY - Bar bodies are 2
    → Female (46 XX) 1 Bar body

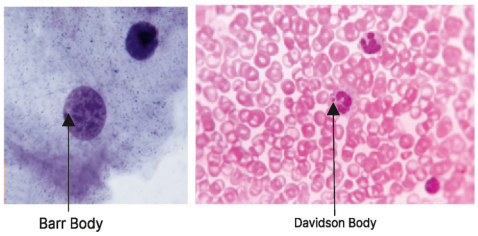

NEET PG August 2024

PYQ Practice

01:25:00

Q. A 23-year-old female with a height of 4 feet has a karyotype, as shown in the image below. Which of the following conditions is the most likely etiology?



A. Turner syndrome
B. Klinefelter syndrome
C. Mayer-Rokitansky-Küster-Hauser syndrome (MRKHS)
D. Edwards syndrome

Ans: A

Q. Identify the syndrome associated with the following chromosomal pattern on chromosome number 15?
A. Angelman syndrome
B. Prader-Willi syndrome
C. Rett syndrome
D. Cri-du-chat syndrome

Ans: B

Q. An adult tall male presents with subluxation of the lens, long arm span, pectus excavatum, and cardiac abnormalities. What is the most likely protein found to be defective?

NEET PG August 2024



A. Elastin
B. Collagen
C. Fibrillin
D. Laminin

Ans: C

Q. Which of the following diseases follows the mode of inheritance shown in the image provided?

NEET PG August 2024 (Evening Batch)

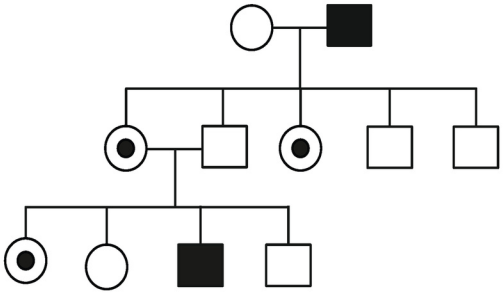

A. Wiskott-Aldrich syndrome
B. Wilson's disease
C. Prader-Willi syndrome
D. Achondroplasia

Ans: A

Yourwish

Q. What does the given pedigree chart indicate?

FMGE Jan 2024

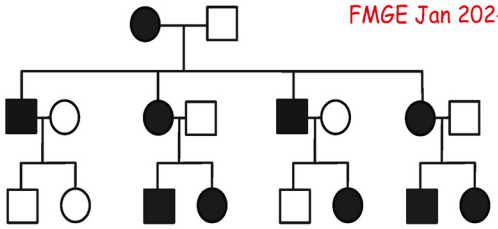

A. Autosomal Dominant (AD)
B. Autosomal Recessive (AR)
C. Mitochondrial Disorder
D. X-linked Recessive (XLR)

Ans: C

Q. Identify the disease associated with the image provided:

NEET PG August 2024 (Evening Batch)

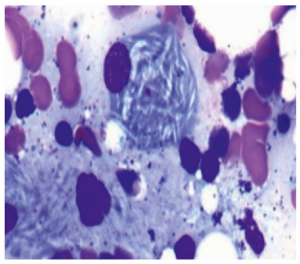

A. Gaucher's disease
B. Tay-Sachs disease
C. Sandhoff's disease
D. Fabry's disease

Ans: A

Q. A child with a strawberry skull, mental retardation, and the given karyotype suggests which diagnosis?

FMGE Jan 2024

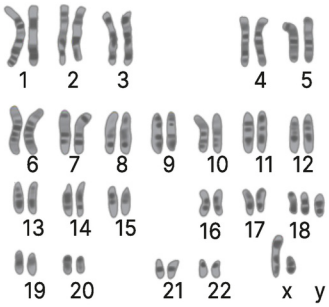

A. Patau syndrome
B. Edward syndrome
C. Prader-Willi syndrome
D. Angelman syndrome

Ans: B

Q. A karyotyping image is given below. What are the clinical features most likely to be expected in such patients?

INI CET July 2021



A. Gynecomastia and long limbs
B. Flat occiput
C. Webbing of neck and lymphedema
D. Cleft lip and polydactyly

Ans: A

Q. Father has XLD disorder. How many percent of daughters will be affected by the disease further?

A. 0%
B. 50%
C. 75%
D. 100%

Ans: A

Q. Find the incorrect match with regard to disease and trinucleotide repeats?

A. Fragile x syndrome – cgg
B. Myotonic dystrophy – ctg

C. Huntington disease - gag
D. Friedreich's ataxia - GAA

Ans: C

- It's CAG for Huntington

Q. Incorrect for Fragile X syndrome?
A. Shows CGG premutation
B. Associated with loss of function of the FMR gene
C. Repeats can be detected by PCR
D. Females can show POF

Ans: A

Q. Which of the following is incorrect about Prader-Willi syndrome?
A. Associated with paternal imprinting
B. Associated with maternal deletion
C. Associated with maternal imprinting
D. Can be due to maternal disomy

Ans: A

Q. A 54-year-old female has a breast lump measuring 9×7 cm in the upper outer quadrant. The lump is firm to hard in consistency and seems to be fixed to the underlying muscle. A Tru-cut biopsy is done, which reveals infiltrating ductal carcinoma. Further, the tumor cells constitute only 8 percent of the biopsy. The rest is composed of stromal fat and ducts. Which of the following techniques is best suited?
A. Sanger sequencing
B. Sbpe
C. Pyrosequencing
D. Amplicon Length Analysis

Ans: C

Next-gen sequencing > pyrosequencing

Yourwish

9. NEOPLASIA

CLASSIFICATION OF NEOPLASM

FMGE 2018, 2022, 2024
NEET PG 2018
INICET 2022

- Benign tumors: OMA
  - E.g., Lipoma, Fibroma, Osteoma, Adenoma
  - Exceptions: Lymphoma, Melanoma, Seminoma, Teratoma, Chloroma (AML in soft tissues—orbit—proptosis)
- Malignant tumors
  - Carcinoma: Epithelial origin (Squamous cell carcinoma)
  - Sarcoma: Mesenchymal origin (Leiomyosarcoma- Smooth muscle, Rhabdomyosarcoma- Skeletal muscle)
- Teratoma
  - >2 germ layers involved
  - Mature: Benign
    → A cyst plus is called a dermoid cyst
  - Immature: Malignant ±
  - Rokitansky protruberans: Thickening



- Mixed tumors
  - Pleomorphic adenoma (MC salivary gland tumor)- A combination of epithelial & mesenchymal tissues

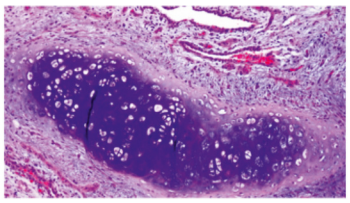

- Hamartoma: Haphazard proliferation of native tissue
  - Eg: Pulmonary hamartoma = Chondroma (lots of cartilage proliferation)
  - Coin lesion on CXR
  - Popcorn calcification: Also seen in fibroadenoma

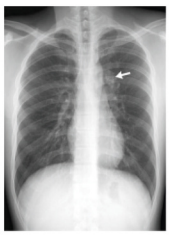

- Choristoma
  - Ectopic tissue
  - Eg: Pancreatic tissue in the stomach

FEATURES OF NEOPLASIA

00:07:26
FMGE 2021

- Anaplasia:
  - Loss of differentiation (hallmark)
  - Differentiation: Structural & functional similarity of tumors of the parent origin

Dysplasia	Anaplasia
• Precancer	• Cancer
• Basement membrane intact	• Basement membrane breached
• Partially reversible	• Irreversible

Yourwish

Yourwish

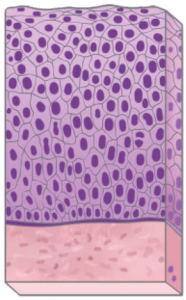

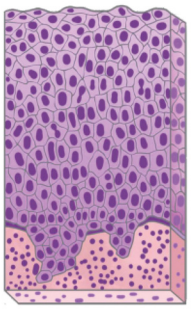

- Rate of growth: More for malignant tumors
- Local invasion: Local spread of the tumor; 2nd most reliable sign
- Metastasis:
  - Most reliable sign of malignancy
  - Distant spread of the tumor
  - All cancers show metastasis except
    → BCC/Rodent's ulcer
    → Glioma (brain tumors)

Pathways Of Spread Of Cancer

Pathway		
Lymphatic	All carcinomas	Except for RCC, HCC, and FCT (scalp mets), which spread hematogenously
Hematogenous (veins > artery)	All sarcomas	Except for Rhabdomyosarcoma, Synovial sarcoma, which spread lymphatically
Direct seeding of the body cavity	Pseudomyxoma peritonei (appendix/ovarian Ca) Blummer's shelf (stomach Ca to the pouch of Douglas) Drop mets (Medulloblastoma to CSF)	
Transcoelomic spread	Krukenberg tumor: cancer travelling to the ovary (from the stomach (MC), breast, colon, pancreas)	

Tumor showing bone metastasis:

INICET 2024

- Cancers such as
  - Prostate: L-S vertebrae (back pain), Osteoblastic
  - Breast: Osteoblastic/Osteolytic
  - Lung: Osteoblastic/Osteolytic
  - Intestine: Osteolytic
  - Kidney: Osteolytic
  - Thyroid: Osteolytic

Yourwish

- After reaching the respective bones,
  - Osteolytic: Breaking the bone
  - Osteoblastic: Making the bone
  - Osteoblastic/osteolytic: Both

FUNDAMENTALS OF NEOPLASIA:

00:20:56

Self-Sufficiency Of Growth Signals

NEET PG 2022

By mutating the growth signal genes, making them available

- PDGF beta: Brain tumor (Astrocytoma) INICET 2021
- PDGFR beta: Brain tumor (Astrocytoma)
- HST gene: Osteosarcoma
- HGF (AKA Scatter factor): HCC
- EGFR1: ERBB1; Adenocarcinoma of the lung (Erlotinib)
- EGFR2: ERBB2/Her2neu; Breast cancer (Trastuzumab)
- RET: Gain-of-function mutation which is present on Ch10, causing medullary carcinoma of the thyroid and causing MEN 2a, B
  - Loss-of-function in this gene causes Hirschsprung's disease
- cKit/CD 117:
  - GIST
  - AML
  - Mastocytosis
  - Melanomma
  - Seminoma
- ALK: Adenocarcinoma of the lung, Anaplastic lymphoma, Inflammatory myofibroblastic tumor (IMFT)
- RAS
  - KRAS: Colon, Pancreatic, Lung cancers
  - HRAS: RCC, Urinary bladder cancer, Pituitary cancer
  - NRAS: Melanoma, AML
- Myc genes
  - C-myc: Burkitt's lymphoma
  - L-myc: SCL cancer
  - N-myc: Neuroblastoma
- ABL: BCR-ABL fusion causing CML
- GNAQ: Uveal melanoma
- BRAF: Occurs at codon 600, BRAF $V_{600}E$ is seen in
  - Hairy cell leukemia
  - Langerhans cell histiocytosis
  - Papillary carcinoma of the thyroid
  - Pilocytic astrocytoma
  - Colon cancer
  - Melanoma
- Cyclin-D
  - Mantle cell lymphoma

Cell Cycle

INICET 2024

- Cell cycle phases:
  - G0: Inactive stage; Variable time
  - G1: Variable time
  - S: 6 hours
  - G2: 4 hours
  - M: 2 hours
- Cell cycle checkpoints
  - G1 and S: p53 and RB
  - G1 and M: p53
- Cell cycle progression

Cyclins	Cyclin-dependent kinase (CDK)
Cyclin D	CDK 4, 6
Cyclin E	CDK 2
Cyclin A	CDK 2
Cyclin B	CDK 1

- Point of no return: S phase
- Most radioresistant: S phase
- Most radiosensitive: G2M phase
- Most radiosensitive tumor: Ewing's sarcoma
- Most radiosensitive testicular tumor: Seminoma
- Most radiosensitive organ: Bone marrow > Gonads
- Most radiosensitive blood cell: Lymphocytes
- Least radiosensitive blood cell: Platelets

Inactivation Of Tumor Suppressor Genes

INICET 2023, 2024, 2025

Gene	
p53	Chromosome 17p13 AKA policeman/gatekeeper/guardian of the genome Mutation: AD Li Fraumeni tumors (breast, brain, bone, blood) Criteria: Chompret criteria Big brother of p53: p73
RB	Chromosome 13q14 AKA governor Sporadic retinoblastoma (MC): U/L RB Familial retinoblastoma: B/L RB + OS Trilateral retinoblastoma: Pinealblastoma (sporadic and familial) M/E: Flexner-wintersteiner true rosette + Homer wright pseudorosette Normal RB (RB-E2F) to hypophosphorylated RB and E2F induces cell cycles, causing cancer

Yourwish

NF1	Chr 17, neurofibromatosis
NF2	Chr 22, neurofibromatosis
BRCA1	Chr 17, breast cancer
BRCA2	Chr 13
WT1	Chr 11p
WT2	Chr 11p
APC	Chr 5q21, causing FAP
PTEN	Chr 10 Cowden syndrome: Endometrial cancer, Thyroid cancer, Trichilemmoma, Breast cancer, Polyp
CDH1 (e-cadherin)	Loss of e-cadherin Diffuse gastric cancer Invasive lobular carcinoma

Limitless Replicative Potential

- Increased telomerase

Evasion Of Apoptosis

- Increase anti-apoptotic factors. E.g., BCL2

Angiogenesis

- Promotor: VEGF
- Inhibitor: Thrombospondin

Invasion and metastasis

Dna repair defects

INICET 2021

Mechanism	Disease
Nucleotide excision repair gene • Under UV light, thymidine dimers are formed and are corrected by NER genes	Xeroderma pigmentosum- Skin cancers
Mismatch repair gene • Corrected by MMR genes, AKA spell checker/ proofreader	HNPCC/hereditary non-polyposis colon cancer (Lynch syndrome)- Colon, endometrial, ovarian
Homologous recombination gene • Corrected by HR genes	Bloom syndrome Fanconi anemia Ataxia-telangiectasia

Yourwish

Yourwish

Warburg Effect

- Aerobic glycolysis and glucose hunger: Cancer cells use their intermediate products of the pathway for growth
- Radiology: 18 FDG-PET scan to look for mets

ETIOLOGY OF NEOPLASIA

00:56:56

- Radiation
- Chemicals
- Microorganism

FMGE 2023
NEET PG 2021
AIIMS 2022

Radiation Carcinogenesis

UV	UV-B: skin cancers
Most common cancer associated with IR	AML
Most common thyroid cancer associated with IR	Papillary carcinoma of the thyroid
Cancer is never associated with radiation	CLL

FMGE 2025
INICET 2024

Chemical Carcinogenesis

Alcohol	HCC
Tobacco	Oral and lung cancer RCC
Asbestos • Shipyard • Cement	MC: Adenocarcinoma of the lung Most specific: Mesothelioma
DES	DES daughters had Clear cell tumors of the genital tracts
Estrogen	Endometrial cancer
OCP	Cervical cancer
VAT: Vinyl chloride, Arsenic, Thorotrast	Angiosarcoma of the liver
Benzene	AML
Benzidine	Bladder cancer

- AMES test: To know the mutagenicity of a chemical

Microbial Carcinogenesis

H. pylori • Has cagA and vacA	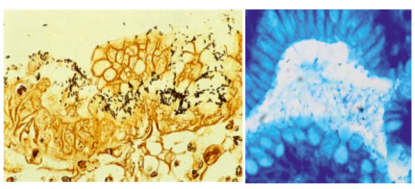	Adenocarcinoma, MALToma

Yourwish

Aflatoxin • Peanut/groundnut contamination • Aspergillus flavus	HCC, by mutation of p53 at codon 249
Schistosoma haematobium	SqCC UB > TCC UB
Clonorchis sinensis	Cholangiocarcinoma
HPV: Proteins are • L1: Vaccine • E2: Controller • E6 and E7: Deactivate p53 and RB, respectively • E4 and E5: Koilocyte	Causes cancer where squamous epithelium is present: Cervical cancer Penile Anal canal 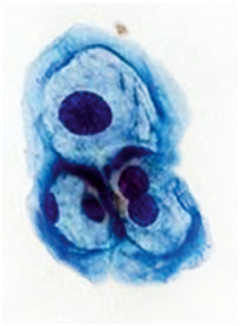 Pap smear 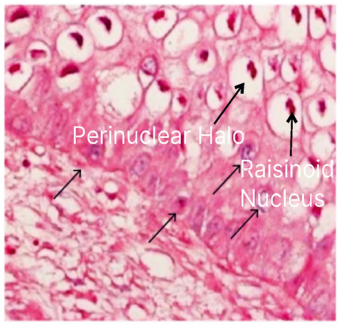 Cervical biopsy
EBV • Releases LMP1, EBNA2, VIL10 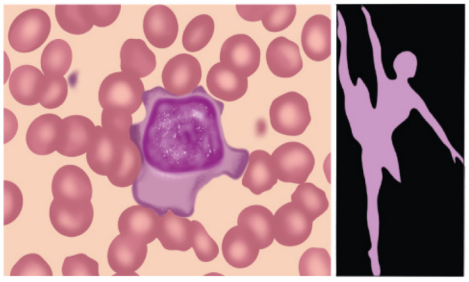	Causes IM (kissing's disease); Downey cells are seen, which are atypical lymphocytes (CD8 T cells) with a ballerina skirt appearance Carcinoma: Gastric and nasopharyngeal Lymphoma: Hodgkins and non-Hodgkins (DLBCL, BL) Sarcoma: LMS
HHV 8	Kaposi sarcoma Primary effusion lymphoma Castleman disease • Lollipop follicles • Onion peel appearance 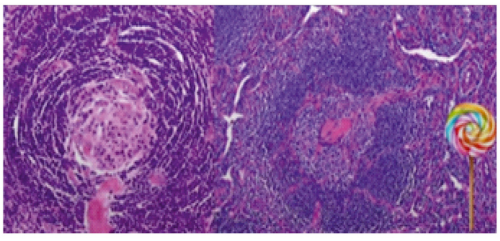
HTLV	Adult T-cell leukemia/lymphoma (ATLL) by the TAX gene

DIAGNOSIS OF TUMORS

01:11:58
FMGE 2024
INICET 2023, 2024, 2025

- Tumor markers

Tumor markers	Tumors
Beta HCG	Choriocarcinoma
Calcitonin	Medullary Ca. Thyroid
Catecholamines	Pheochromocytoma
5HIAA	Carcinoid Tumor/Sht → Shiaa
AFP	Yst, Hcc, Hepatoblastoma
CEA	Colon Cancer
PSA, PAP	Prostate Cancer
Ig	Multiple Myeldma
NSE NEURON SP. ENOL	Neurden Docrine Tx, Neuro Bl.
Ca125	Surface Epithelial Tx, Ovaly
Ca19-9→P	Pancreatic Tx
CA15-3/3	BREAST Cancer
NMP22	Recurrent Bladder Ca.

- FNAC
  - Fine needle aspiration cytology
  - Franzen handle
  - USG-guided thyroid FNAC
  - Pitfall: Cannot diagnose Follicular Ca thyroid

FMGE 2025
INICET 2022



Ultrasound-guided FNAC.



- Biopsy
  - Gold standard
  - Light microscopy: 10% neutral buffered formalin
  - E/M: In 2-2.5% glutaraldehyde

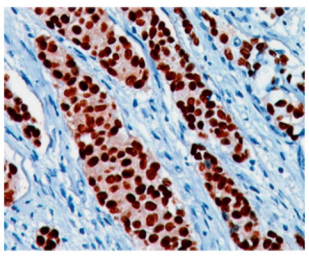

Marker	Tumor
Cytokeratin	Carcinoma

Yourwish

Vimentin	Sarcoma
LCA/CD 45	Lymphoma
HMB 45	Melanoma
CD1a	LCH
CD 99	Granulosa cell tumor
CD 99/MIC 2	Ewing's sarcoma

- IHC
  - Brown due to DAB (di-amino-benzidine)
  - Eg: leiomyosarcoma: SMA+, vimentin+; Rhabdomyosarcoma: desmin, myoD1, vimentin

CK 7	CK 20	Disease
+	+	• Urinary bladder • Ovarian mucinous
+	-	• Endometrial • Cervical • Ovarian • Thyroid • Salivary gland • Breast • Pancreatic • Cholangiocarcinoma
-	+	• Colon cancer • Merkel cell carcinoma
-	-	• RCC • HCC • SqCC lung • SmCC lung

PARANEOPLASTIC SYNDROMES

01:20:25

- Signs & symptoms associated with tumors but not due to tumor spread

Hypercalcemia (MC)	Lung SqCC: PTHrP, increasing calcium
Cushing syndrome	Lung SmCC, RCC
SIADH	Lung SmCC
Acanthosis nigricans	Gastric cancer
Labert-Eaton syndrome	Lung SmCC
Migratory thrombophlebitis: Trosseau phenomenon	Lung adenocarcinoma

Yourwish

Myasthenia gravis	Thymoma
Pure red cell aplasia	Thymoma
Hypoglycemia	Fibrosarcoma
Hyperglycemia	Bone tumours
Osteomalacia	Phosphaturic mesenchymal tumor

PYQs

01:23:24

Q. CA19-9 is a tumor marker of what?

a. Stomach cancer
b. Pancreatic cancer
c. Colon cancer
d. Lung cancer

Ans: b. Pancreatic cancer

Q. A 65-year-old man with complaints of muscle weakness and a dry cough for 4 months. He has smoked 2 packs of cigarettes daily for 45 years. A chest X-ray shows a 4-cm central, left lung mass. Laboratory studies reveal hyperglycemia and hypertension. A transbronchial biopsy is diagnosed as small cell carcinoma. Metastases to the liver are detected by a CT scan. Which of the following might account for the development of hyperglycemia and hypertension in this patient:

a. Diabetes mellitus
b. Paraneoplastic syndrome
c. Pituitary adenoma
d. Pituitary metastases

Ans: b. Paraneoplastic syndrome

Q. Which of the following describes the correct order of cyclins in cell cycle progression?

a. ADEB
b. DEAB
c. BEAD
d. DEBA

Ans: b. DEAB

Q. A 62-year-old woman presents with a breast lump that she discovered 6 days ago. A breast biopsy shows lobular carcinoma in situ. Compared to normal epithelial cells of the breast lobule, these malignant cells would most likely show decreased expression of which of the following proteins?

a. Desmin
b. E-cadherin
c. P-selectin
d. Telomerase

Ans: b. E-cadherin

Yourwish

Q. In what situation is popcorn calcification observed?
a. Hodgkins lymphoma
b. Pulmonary hamartoma
c. Metastasis
d. Fungal ball

Ans: b. Pulmonary hamartoma

Q. Which of the following is true about anaplasia?
a. Loss of cohesion between cells
b. Loss of differentiation
c. Change of epithelium type
d. Benign and fully reversible

Ans: b. Loss of differentiation

Q. Why do neoplastic cells utilize Warburg metabolism? NEET PG 2022
a. It decreases glucose utilization by neoplastic cells
b. It forms metabolic intermediates, which are needed for cell growth and multiplication
c. It provides more energy in the form of increased ATP production
d. It prevents apoptosis and makes the cancer immortal

Ans: b. It forms metabolic intermediates, which are needed for cell growth and multiplication

Q. Which of the following is true? INI CET July 2021
1. BRCA1 is an oncogene
2. HER2neu is amplified only in a fraction of breast cancer cases
3. EGFR+ is seen in non-small cell lung cancer
4. N-MYC is a tumor suppressor gene

a. 1, 2
b. 1, 3
c. 2, 3
d. All of these

Ans: c. 2, 3

Q. Match the malignancies in Column A with the genes in Column B: INICET May 2022

Column A	Column B
1. Pleomorphic adenoma	a. Rb
2. Burkitt lymphoma	b. N-MYC
3. Neuroblastoma	c. C-MYC
4. Retinoblastoma	d. PLAG 1

1-c, 2-b, 3-d, 4-a
1-b, 2-c, 3-d, 4-a
1-d, 2-c, 3-b, 4-a
1-b, 2-d, 3-c, 4-a

Ans: c. 1-d, 2-c, 3-b, 4-a

Q. Which of the following statements is true about proto-oncogenes? INICET May 2022

1. KIT has decreased expression via the tyrosine kinase signalling pathway in GIST
2. KRAS mutation is more commonly associated with small-cell lung cancer
3. ERBB2 is overexpressed in association with breast carcinomas
4. PDGFR-B has suppressed expression in colorectal cancer

a. 2 only
b. 3 only
c. 1 and 4
d. 2 and 3

Ans: b. 3 only

Q. Match the given mutations with the respective cancers:

A. K-RAS	1. Myeloproliferative neoplasm
B. KIT	2. Adenocarcinoma
C. JAK 2	3. Pancreatic cancer
D. ALK	4. GIST

a. A-3, B-4, C-1, D-2
b. A-2, B-3, C-4, D-1
c. A-1, B-3, C-2, D-4
d. A-2, B-4, C-3, D-1

Ans: a. A-3, B-4, C-1, D-2

Q. The human papillomavirus inactivates the Rb gene by which of the following proteins?

a. E6
b. E7
c. L1
d. L2

Ans: b. E7

Q. A 55-year-old male patient presents with fever, night sweats, and pleural effusion. On further investigation, he is diagnosed with primary effusion lymphoma. What is the most likely causative agent responsible for this condition?

Yourwish

a. HHV-8
b. EBV
c. HPV
d. HIV

Ans: a. HHV-8

Q. What is the tumor marker for a carcinoid tumor?
a. beta-HCG
b. Calcitonin
c. 5-HIAA
d. Alpha-fetoprotein

Ans: c. 5-HIAA

Q. Match the following:

A. Medullary thyroid cancer	I. Catecholamine
B. Hepatoblastoma	II. AFP
C. Choriocarcinoma	III. Calcitonin
D. Pheochromocytoma	IV. Beta HCG

a. A-I, B-II, C-III, D-IV
b. A-III, B-II, C-IV, D-I
c. A-IV, B-III, C-II, D-I
d. A-II, B-I, C-III, D-IV

Ans: b. A-III, B-II, C-IV, D-I

Yourwish

7. CENTRAL NERVOUS SYSTEM PATHOLOGY

CELLS AND VARIATIONS

00.00.18

Cells	Function	Stain
Astrocyte	• Forms the Blood-Brain Barrier • Helps repair following injury	• IHC →GFAP (Glial Fibrillary acidic protein) 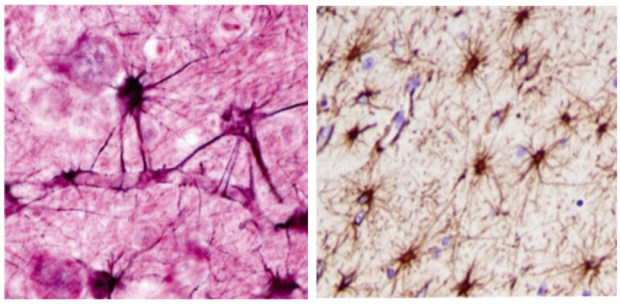
Oligodendrocyte	• Forms myelin in CNS ○ Formation of myelin in the PNS is by Schwann cells	• Luxol Fast blue
Ependymal cells	• Present in the ventricles • Helps in CSF production	
Microglia	• Act as macrophage	

Variation of macrophage

Cells	Seen in	Description
Rod cells	Neurosyphilis → 3° syphilis	• Macrophage becomes elongated 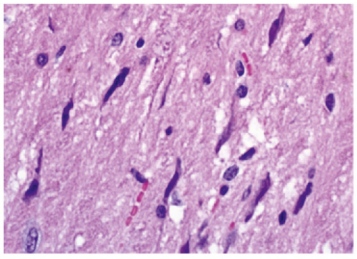
Neuronophagia	Rabies, Polio	• Dead and degenerated neurons are phagocytosed by macrophages 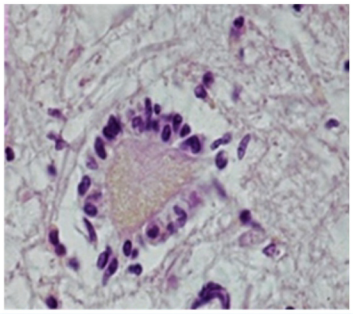

Yourwish

Microglial nodule	HIV	• Arrangement of macrophage in group 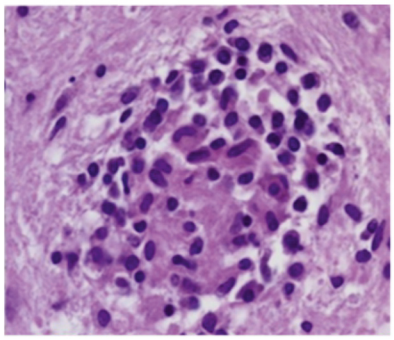
Globoid cells	Krabbe's disease	• Macrophage becomes round 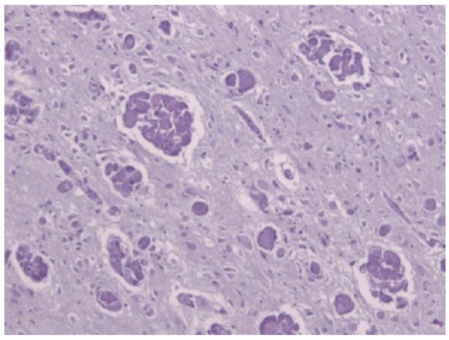

DEGENERATIVE DISORDER

00.03.10

Alzheimer Disease

- Manifest around 70 - 75 years
- Presents with dementia

Genetics

- APP (Amyloid precursor protein) → Chromosome 21
  - Trisomy 21 (Down's syndrome) causes premature alzheimer disease
- PS1 → Chromosome 14
- PS2 → Chromosome 1

Increased γ secretase activity in Meyenert nucleus

↓

Leads to decreased levels of acetylcholine

↓

Cause dementia

- $APOE_4$ → Early onset

Microscopy

- Beilshowsky stain → Silver
  - Neuritic plaque →composed of Amyloid β 40, 42 surrounded by neurons
  - Neurofibrillary tangles →Hyperphosphorylated Tau protein

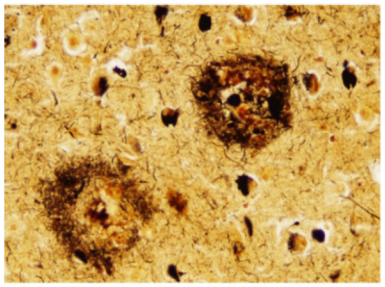

Neuritic Plaques

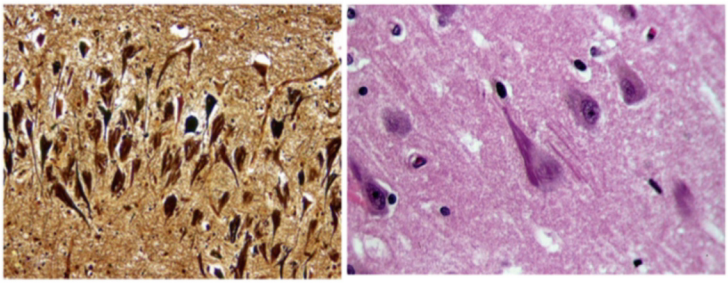

Neurofibrillary Tangles

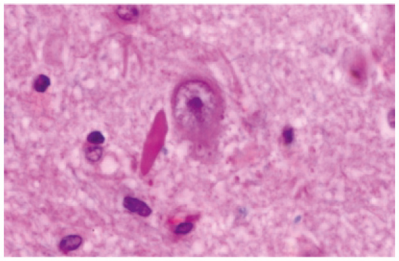

Hirano Bodies

- HPE
  - Flame cells
  - Hirano bodies →composed of actin

Features

- Cerebral amyloid angiopathy → Aβ 40 damages blood vessels
- Granulovacuolar degeneration

Parkinson Disease

- Manifests with tremors

Genetics

Decreased dopaminergic neurons

↓

Decreased DOPA

↓

Decreased melanin

↓

Pale substantia nigra

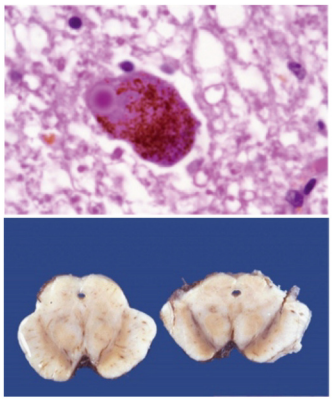

Microscopy

- Lewy Bodies → composed of α-synuclein

Pick's Disease

- Knife-life sulci and gyri



Huntington Disease

- Presents with chorea

Genetics

- CAG repeats in the exon
- Present in Chromosome 4
- Affect the caudate nucleus

Microscopy

- Increased Huntingtin
- Increased Ubiquitin

Yourwish

Amyotrophic Lateral Sclerosis (als)

- UMN + LMN

Genetics

- SOD 1 (superoxide dismutase) gene mutation

Microscopy

- Bunina bodies

Important Information

- Negri bodies seen in Rabies

BRAIN TUMORS

00.11.40

- MC malignancy is Metastasis
- St Ann Mayo Grading

Basis of classification	
A → Atypia M → Mitosis E → Endothelial proliferation N → Necrosis	
Classification	
Grade 1	• No 4 features present • Good prognosis
Grade 2	• Atypia present
Grade 3	• Atypia and Mitosis present
Grade 4	• 3 or 4 features present • Poor prognosis

Juvenile Pilocytic Astrocytoma

- Genetic
  - Mutation → BRAF $V_{600}E$ or BRAF - KIAA fusion
- Common in children
- Clinical features
  - Site → Cerebellum
  - Presents as cystic cavity with mural nodule
- Grade I tumor with good prognosis
- Imaging
  - Rosenthal fibres (hair-like)

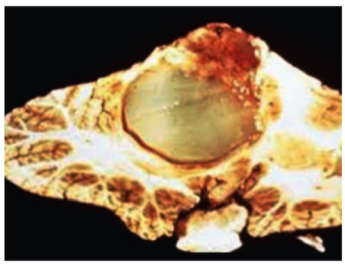

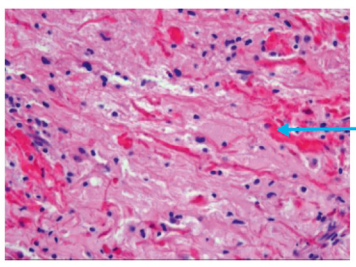

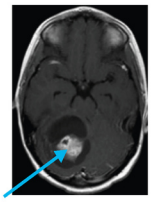

Rosenthal fibres

Yourwish

Yourwish

Glioblastoma

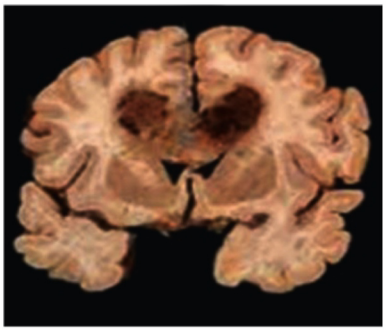

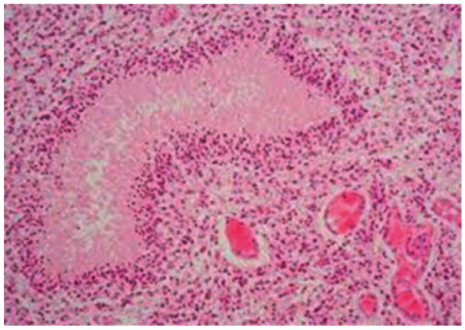

- Genetic
  - 90 % IDH wild type → normal
  - 10 % IDH mutant
- Common in adults
- Grade IV tumor with poor prognosis
- Imaging
  - Butterfly glioma
  - Serpentine necrosis with pseudopalisading of tumor cells
  - Glomeruloid body →Proliferation of blood vessels

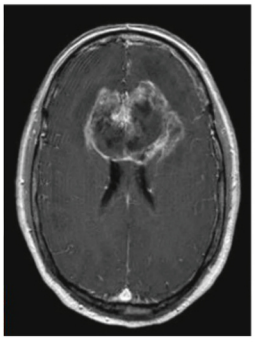

Important Information

- Glomeruloid body:
  - AKA: Schiller-Duval body → seen in Yolk sac tumor

Oligodendroglioma

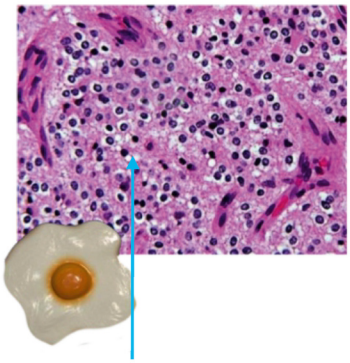

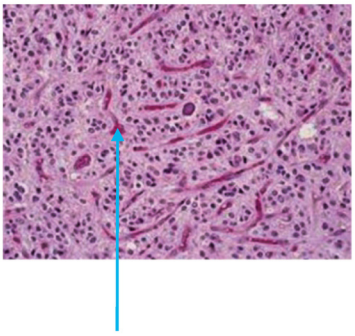

- Genetic IDH mutation
  - Codeletion of Chromosome 1p / 19q
- Prognosis → Good response to chemotherapy
- Imaging
  - Fired egg appearance
  - Chicken wire blood vessels
  - Calcification

- IDH Mutation is also seen in
  - Enchondroma
  - Glioblastoma (10%)
  - Oligodendroglioma
- Calcification is also seen in:
  - Craniopharyngioma
  - Oligodendroglioma
  - Meningioma

Fried egg appearances	Chicken wire appearance

• Brain →Oligodendroglioma
• BMB → Hairy cell Leukemia
• Testes/Ovary → Seminoma / Dysgerminoma
• Microbiological colonies
  ○ Mycoplasma
  ○ Malassezia furfur
	• Calcification → Chondroblastoma
	• Blood vessels
	  ○ Brain - Oligodendroglioma
	  ○ Breast FNAC - Mucinous / colloid ca.
	• Fibrosis = Alcoholic liver disease

Ependymoma

- Genetics
  - Gene involved is NF2 → Located on chr 22
  - Associated with neurofibromatosis
- Site → Fourth ventricle (Infratentorium)
- Rela fusion Ependymoma
  - Rela gene
  - Chromosome 11
  - Site → Above Supratentorium
- Imaging
  - Perivascular pseudo-rosette → Tumor cells surrounding the blood vessels

Medulloblastoma

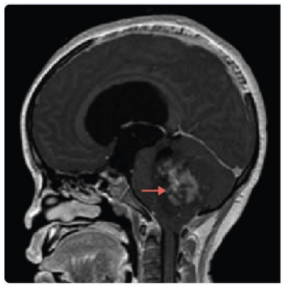

- Seen in children
- Site → Cerebellum
- Grade IV tumor with poor prognosis
- Imaging
  - Home Wright pseudorosette

Rosette		
Perivascular pseudorosette	**Homer Wright pseudorosette**	**Flexner wintersteiner true rosette**
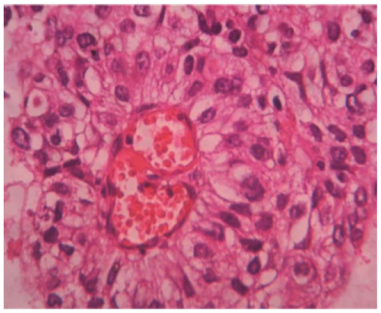	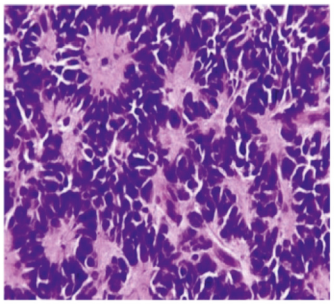	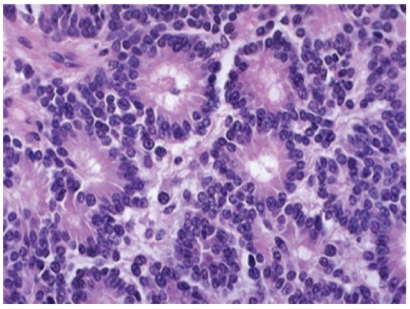
• Tumor cells surrounding the blood vessels	• Tumor cell surrounding the pink material	• Tumor cells with clear centre
• Ependymoma	• Medulloblastoma • Ewing's sarcoma • Neuroblastoma • Retinoblastoma	• Retinoblastoma

Meningioma

- Genetics
  - Gene involved is NF2 gene → Chromosome 22
  - Associated with Neurofibromatosis
- Arise from the meninges
- More common in females → PR +

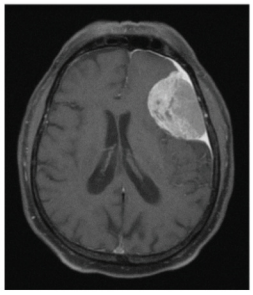

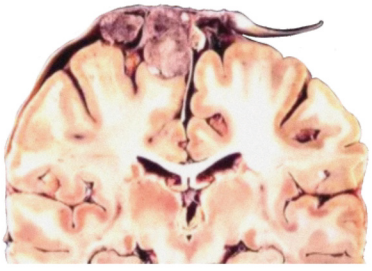

- Imaging
  - Whorling of tumor cells
  - Psammoma bodies present
- Radiologically → Dural tail sign

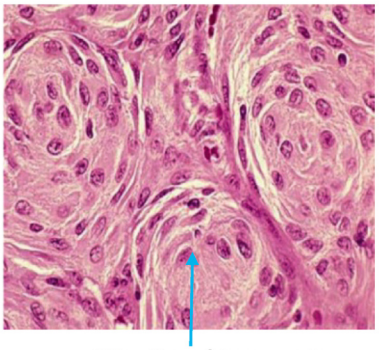

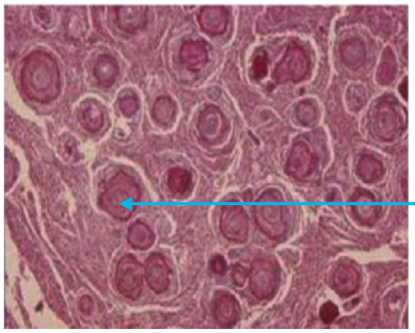

Atypical Teratoid/rhabdoid

- Gene mutated → SNF / INI

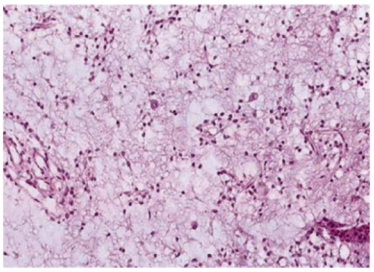

DNET

- Imaging shows floating neurons in pools of mucin

Lymphoma

- MC type of lymphoma → Diffuse large B cell lymphoma (DLBCL)
- Occur among immunocompromised patients with HIV
- Imaging
  - Angiocentric pattern
  - Hooping →Reticulin fibres

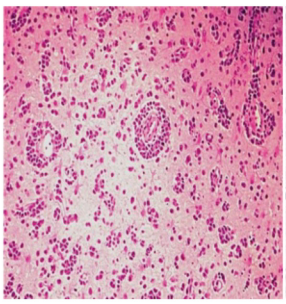

Angiocentric Pattern

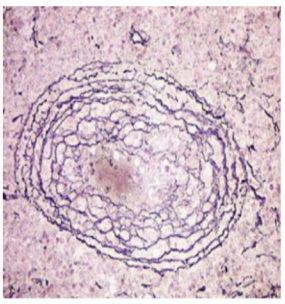

Hooping- Reticulin Fibres

Diffuse Midline Glioma

- Mutation of gene H_3 K27 M → a part of Histone
- a/w poor prognosis

Schwannoma

- a/k/a B/L Acoustic Schwannoma
- Involvement of the 8th cranial nerve
- Can involve the Cerebellopontine angle
- Gene involved is NF2 gene → Chromosome 22
- Associated with Neurofibromatosis
- Imaging: Icecream cone appearance

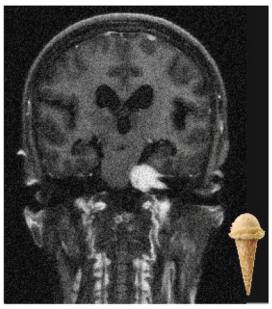

- Histology:
  - Antony A → Hypercellular
  - Antony B → Hypocellular
  - Verocay bodies → Two rows of palisading nuclei with cytoplasm in center

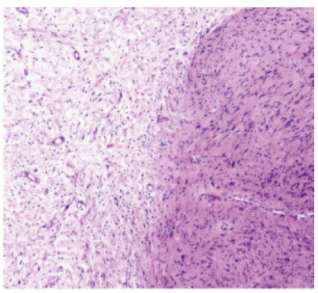

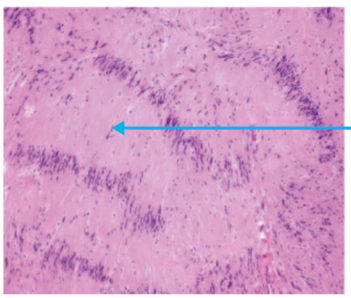

Important Information

- NF2 → Chromosome 22
  - Mi - Multiple
  - S - Schwannoma
  - M - Meningioma
  - - Ependymoma

Yourwish

Craniopharyngioma

- Site → Suprasellar region / Sella turcica
- Defect in Rathke's pouch
- Age of presentation: Children
- Clinical presentation : Visual disturbance , headache
- Histology:
  - Peripheral palisading
  - Stellate reticulum
  - Wet keratin → Machine oil fluid

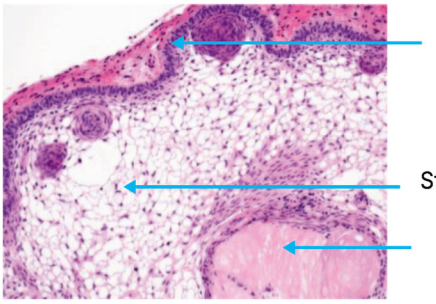

PRION DISEASES

- a/k/a Transmissible spongiform encephalopathy
- Causes
  - Iatrogenic
  - Defect in prion protein gene codon 129
- Pathology:
  - PrP^{c} → misfolded to → PrP^{sc}
- Spongiform pattern seen in
  - Creutzfeldt-Jakob disease
  - Kuru disease →has kuru plaque
  - Congo red +
  - PAS +
  - Scrapie disease
  - Bovine spongiform encephalopathy
- Fatal familial insomnia does not show spongiform pattern
- Clinical features
  - Myoclonus
  - Behavioral changes
- Investigations
  - 14-3-3 in CSF
  - Periodic sharp wave EEG

00.36.08

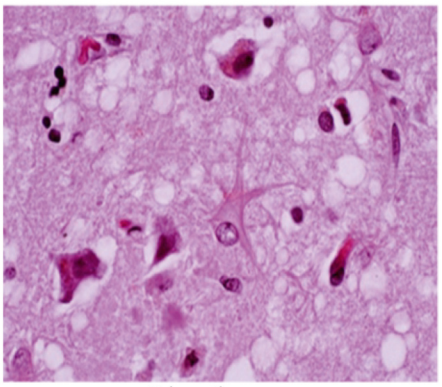

Prion diseases

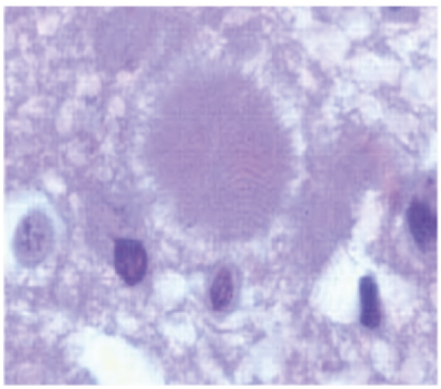

Kuru plaque

PYQ

00.38.18

Q.Which of the following is a marker of Alzheimer's disease?

NEET PG August 2024

a.Synuclein
b.Aβ 40 and 42
c.Polyglutamine
d.FUS

Ans.: b.Aβ 40 and 42

Q.A 78-year-old woman presents with a progressive decline in daily activity. She gives a history of convulsions and visual hallucinations. She does not talk to anyone and keeps looking at the sky. Pathological examination shows the presence of Lewy bodies within the neurons. What is the most probable diagnosis?

NEET PG 2023

Yourwish

a.Parkinson's disease
b.Prion disease
c.Huntington's chorea
d.Alzheimer's disease

Ans: a.Parkinson's disease

Q.A child presents with visual disturbances and delayed growth. Imaging reveals a suprasellar mass, and histopathology shows the presence of "wet keratin" (compact, eosinophilic anucleate keratin). What is the most likely diagnosis?

NEET PG 2025

a.Craniopharyngioma
b.Medulloblastoma
c.Glioma
d.Pituitary adenoma

Ans: a.Craniopharyngioma

Q.A 45-year-old female presents with a 2-year history of progressive unilateral hearing loss, tinnitus, and unsteadiness. An MRI scan reveals a well-defined tumor located in the cerebellopontine angle (CPA). A surgical resection is performed, and subsequent histopathological examination of the tumor tissue is given below. Based on these histopathological findings, what is the most likely diagnosis?

NEET PG 2025

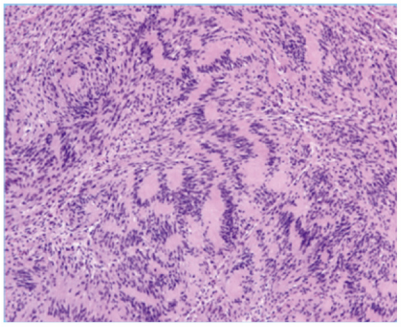

a.Schwannoma
b.Ependymoma
c.Meningioma
d.Neurofibroma

Ans: a.Schwannoma

Q.A 70-year-old patient presents with progressive memory loss, cognitive decline, and behavioral changes. Imaging reveals characteristic amyloid plaques and neurofibrillary tangles in the brain. On further investigation, the accumulation of a specific protein is found to be a hallmark of this disease. What is the protein responsible for the amyloidosis seen in Alzheimer's disease?

FMGE July 2023

a.Amyloid beta protein
b.ATTR
c.Amyloid beta 2 protein
d.Acal

Answer: a.Amyloid beta protein

- Amyloid β 2 Microglobulin is seen in patients with hemodialysis

Q.A male presents with a history of vestibular schwannoma and psammoma bodies in the brain. Which of the following is the most likely diagnosis?

FMGE Jan 2025 Part 2

a.Meningioma
b.GBM (Glioblastoma Multiforme)
c.Pilocytic astrocytoma
d.Oligodendroglioma

Ans: a.Meningioma

4. CARDIAC PATHOLOGY

MYOCARDIALINFARCTION

00:00:12
NEET PG 2019, 2020
FMGE 2019, 2020, 2023, 2024

Clinical Manifestations of Myocardial Infarction

- Left-sided chest pain
- Pain may radiate to the right side, leftarm,jaw,and shoulder
- Epigastric pain
  - Especially in women
- Nausea Vomiting
- Diaphoresis Excessive sweating

Cardiac markers in MI

- Sequence of rise of cardiac markers Mnemonic: MY TIME TO CALL

Marker	Rise	Peak	Fall
Myoglobin	2 hours	-	24 hours
Troponin I > T	2-4 hours	48 hours	7-10 days
CK-MB	2-4 hours	24 hours	48-72 days
AST /SGOT	<12 hours	48 hours	4-5 days
LDH1	24 hours	4-5 days	>10 days

- Myoglobin:
  - Earliest rise and early fall
  - Nonspecific.
  - Present in skeletal muscle also
- Flipping of LDH:
  - Normally:
    In blood LDH 2 >1
    In heart LDH 1> 2
  - **MI:**
    In blood LDH 1> 2
    During MI, the heart muscle breaks LDHl leaks into the blood
- Markers rising earlier than myoglobin
  - Ischemia-modified albumin
  - HFABP (Heart fatty acid binding protein)
- Marker of reinfarction: Troponin serial monitoring
  - If troponin increases >20% Indicates reinfarction

Yourwish

Pathology of MI

Duration of ischemia	Type of injury
<20-40 minutes	Reversible
>40 minutes	Irreversible

Autopsy Findings

Electron Microscopy	< 30 minutes	Hydropic change • Mitochondrial swelling • Relaxation of cardiac fibers
Light Microscopy	30 minutes - 4 hours	• Waviness and vacuolization of cardiac fibers
Gross (Naked Eye)	> 4 hours	• Visible pallor → Mottling • Solid organs → Coagulative necrosis

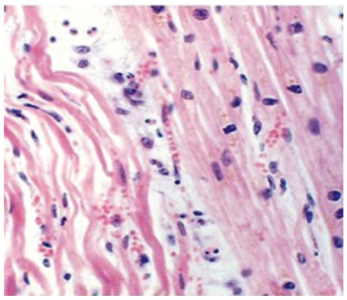



Repair after MI

- Hallmark of repair → Granulation tissue

Day	Change
Day 7	Granulation tissue formation (blood vessels ++)
Day 10	Scar formation

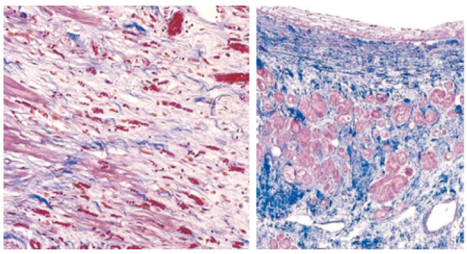

- Stain used for scar: Masson trichrome
  - Muscle → Red
  - Collagen (scar) → Blue
- Special gross stain:
  - TTC stain (Triphenyl tetrazolium chloride) → stains LDH1
  - Detect MI if death occurs <4 hours

Tissue	LDH1	Appearance after TTC stain
Normal myocardium	Present	Brick red
Infarcted myocardium	Absent	Pale

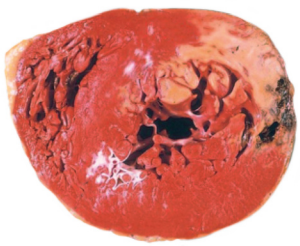

Yourwish

Yourwish

Reperfusion Injury

00:11:00

- MI → Ischemia → Accumulation of calcium and free radicals → Treatment for MI in hospital (Thrombolytic therapy, Stent placement) → Reperfusion → Sudden influx of free radicals and calcium → Sudden contraction of cardiac muscle → Contraction band necrosis

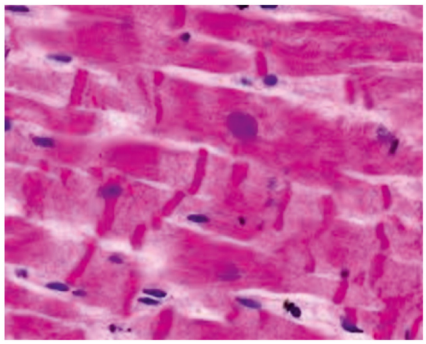

CARDITIS

00:12:41
AIIMS 2021
NEET PG 2019, 2021

Pericarditis

- Bread and butter pericarditis
  - Serofibrinous fluid between the parietal and visceral pericardium
- Seen in rheumatic heart disease

Myocarditis

- MC viral cause: Coxsackie virus
  - Other virus: Herpes virus
- MC parasitic cause: Trichinella spiralis

Endocarditis

Disease	Cause
Rheumatic heart disease	Group A β-hemolytic streptococcus
Infective endocarditis	Staph aureus, Staph epidermidis, Streptococcus viridans
Non-bacterial thrombotic endocarditis (Marantic endocarditis)	Leukemia → AML M3 Cancer → Lung, pancreatic cancer
Libman-Sack's endocarditis	SLE

Verruca/ Vegetation Characteristics

Disease	Vegetation appearance	Embolization
Rheumatic heart disease 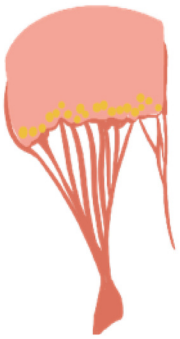	Small, warty, along the line of closure	No emboli Sterile

Infective endocarditis 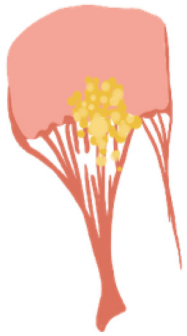	Large bulky vegetations Can cause damage to the chordae tendineae	Emboli +/- Non-sterile
NBTE (Marantic) 	Weak, friable vegetations Cancer releases mucin Mucin → promotes thrombosis	Emboli +++ Sterile
Libman-Sacks 	Vegetations on both sides of the valve (Lower > Upper)	No emboli Sterile

Rheumatic Heart Disease (RHD)

00:18:50

- Causative Organism: Group A β-hemolytic Streptococcus (Streptococcus pyogenes)

Pathogenesis of RHD



- Mechanism: Molecular mimicry
  - Bacterial component: M-protein is identical to the glycoproteins of the heart, skin, and joints
- Type of hypersensitivity: Type II
- Most common valve affected: Mitral valve
- Least common valve affected: Pulmonary valve

Acute RHD

- Vegetations appear in the mitral valve → Mitral Regurgitation → Damage to left atrium
  - Area of damage caused by regurgitant jet → MacCallum patch
    → Seen in the left atrium (posterior wall)

Chronic RHD

- After 10-15 years, mitral regurgitation progresses to Mitral stenosis
  - Valve becomes fish mouth valve/ buttonhole valve

Important Information

- Fish mouth vertebra is seen in:
  - Osteoporosis
  - Sickle cell anemia

Microscopic findings in RHD

- Most characteristic feature: Aschoff bodies
  - Fibrinoid necrosis
  - Surrounding cells: Anitschkow cells
    - → Caterpillar appearance
    - → Owl-eye appearance
  - Seen in:
    - → Pericardium
    - → Myocardium (maximum)
    - → Endocardium

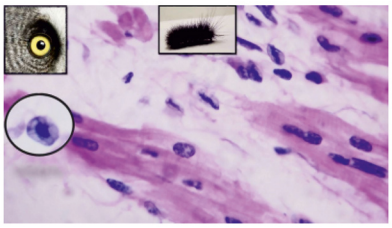

Revised Jones Criteria

Major Criteria	• **J**oints -Migratory polyarthritis → Earliest • **S**ubcutaneous **N**odules - Painless • **E**rythema marginatum • **S**ydenham chorea → Late feature • Carditis (Pancarditis)
Minor Criteria	• Clinical: Fever, Arthralgia • Laboratory: Increased ESR, Prolonged PR interval
Supporting Evidence	• Antigen testing • Antibody Test: Anti-streptolysin O titers • Culture: Throat swab

Infective Endocarditis

00:26:13

- MC valve: Mitral valve
- MC valve in IV Drug abuse: Tricuspid valve
- Criteria: Modified Duke's Criteria
  - Janeway Lesions: Rashes on the palm
    - → Osler's Nodes: Painful subcutaneous nodules on fingers
    - → Roth Spots: Retinal hemorrhage/embolization
      - Seen on fundus examination

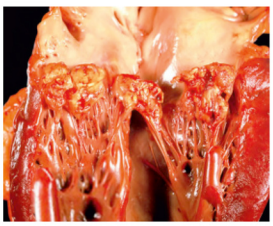





Yourwish

CARDIOMYOPATHY

AIIMS 2021, NEET PG 2019, 2024 00:27:58

Dilated cardiomyopathy (DCM)	• Dilation of all 4 chambers → Globoid balloon-like heart
	• Cause:
	  ○ Most common: Idiopathic
	  ○ Alcohol
	  ○ Titin gene mutation (largest protein)
	• Pathology:
	  ○ Ninja star nucleus
	  ○ Dilation + hypertrophy
	 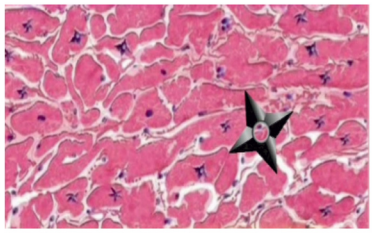

Takotsubo cardiomyopathy	• AKA: Broken heart syndrome
	  ○ Only LV dilation → Takotsubo pot (octopus pot) shape
	• Cause: Severe emotional stress
	  ○ Property dispute, monetary loss, death of loved one
	  ○ Severe emotional stress → ↑ Catecholamines → LV damage
	 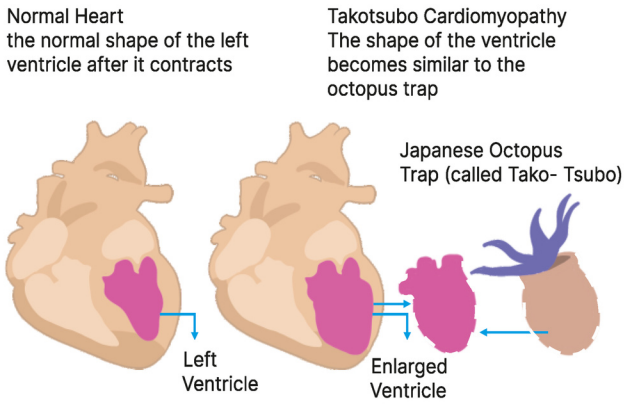

Hypertrophic cardiomyopathy (HCM)	• Inheritance: AD • Mutation: MYH/ β-MHC (Myosin heavy chain) • Asymmetric hypertrophy of the interventricular septum → Banana-shaped, narrow LV • Microscopy Helter-skelter appearance of cardiac fibers • Sudden collapse in a young athlete → Death ○ Cause of death: VF 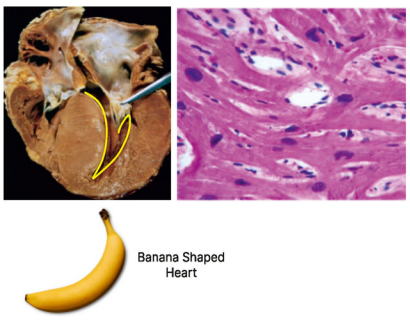
Arrhythmogenic right ventricular cardiomyopathy (ARVCM)	• Inheritance: AD • Mutation: Desmosome protein mutation • Fatty infiltration of the RV • Microscopy: Clear fat spaces in RV
Naxos Syndrome	• ARVC + Woolly hair + Keratoderma (Thick palm/sole) • Inheritance: AR • Mutation: Plakoglobin mutation

Yourwish

Yourwish

	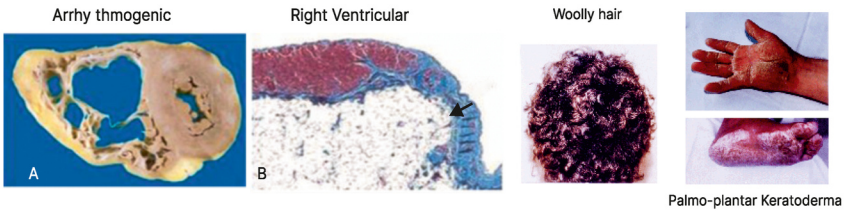
Restrictive cardiomyopathy (RCM)	• Impaired diastolic relaxation • M/c cause: Amyloidosis • Cardiac biopsy → Amyloid ○ Pink, extracellular, eosinophilic

- Hemochromatosis: DCM > RCM

CARDIAC TUMORS

00:37:02

- MC cardiac malignancy: Metastasis
- MC primary cardiac tumor in adults:
  - Benign: Myxoma
  - Malignant: Angiosarcoma
- MC primary cardiac tumor in children:
  - Benign: Rhabdomyoma
  - Malignant: Rhabdomyosarcoma
- MC primary cardiac valve tumor: Papillary fibroelastoma (sea anemone-like)

Feature	Myxoma	Rhabdomyoma
Age Group	Adults	Children
Location	Left atrium	Left ventricle
Gross	Gelatinous/jelly-like mass	-
Microscopy	Lepidic cells in gelatinous myxoid matrix	Spider cells (spider web appearance) • Glycogen in empty spaces → PAS positive
Syndrome Associations	Carney complex GNAS mutation NAME syndrome N → Nevi A → Atrial myxoma M → Myxoid neurofibroma E → Ephelides LAMB syndrome L → Lentigines A → Atrial myxoma M → Myxoid neurofibroma B → Blue nevi	Tuberous sclerosis

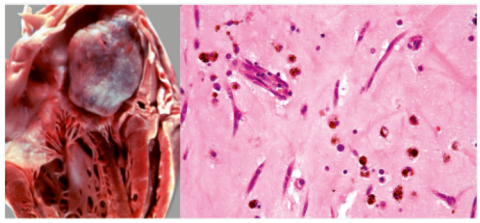

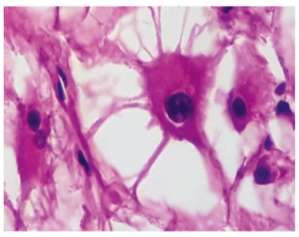

HEART FAILURE

00:41:00

Feature	Right-Sided Heart Failure	Left-Sided Heart Failure
Basic Mechanism	Right heart failure → blood flows backward → Chronic venous congestion (CVC)	Left heart failure → blood backs up into lungs → Pulmonary congestion
Main Organs Affected	Liver: Nutmeg liver • Dark areas: Hemorrhagic necrosis • Light areas: Fatty change  Spleen: Gamna-Gandy bodies	Lungs: Heart failure cells • Hemosiderin-laden macrophages • Left HF → Pulmonary congestion →Blood in alveoli → Hb breakdown → Hemosiderin → Macrophages ingest → Heart failure cells 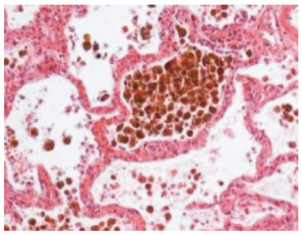 **Special Stain:** Prussian blue (Perl's stain) for iron/hemosiderin

PYQs

00:43:38

Q. A 30-year-old football player is brought to the emergency department after he collapsed due to sudden cardiac arrest. Based on the biopsy findings of his cardiac tissue, what is the most likely cause of his death?

NEET PG Aug 2024

A. Hypertrophic obstructive cardiomyopathy

B. Dilated cardiomyopathy

C. Restrictive cardiomyopathy

D. Arrhythmogenic cardiomyopathy

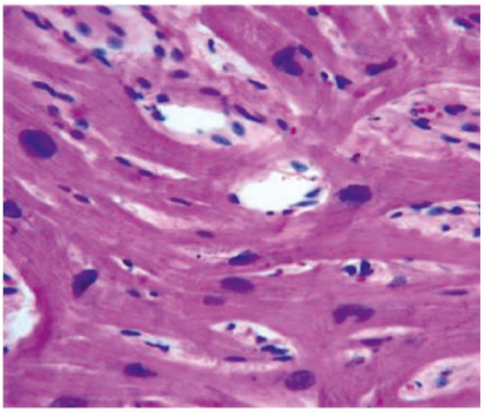

Ans: A

Q. A 61-year-old female patient presents with left-sided chest pain, radiating to the left arm and jaw. Patient explains that the pain has increased severely over the past 40 minutes. She is immediately rushed to the hospital. Cardiac enzymes are elevated. The patient is admitted and started on thrombolytic therapy. However, on the 5th day of observation, she suddenly collapses and dies. Which of the following necrosis are you most likely to find in the heart of this patient?

A. Liquefactive necrosis
B. Coagulative necrosis
C. Fat necrosis
D. Fibrinoid necrosis

Ans: B

Q. A 68-year-old man presents with progressive exertional dyspnea, bilateral pedal edema, and episodes of syncope. He has a history of carpal tunnel syndrome and recently noticed numbness in his feet. On examination, he has elevated JVP and hepatomegaly. Echocardiography revealed concentric left ventricular hypertrophy with preserved ejection fraction. An endomyocardial biopsy is performed. Histopathology reveals amorphous, acellular, eosinophilic extracellular deposits between myocardial fibres. Which of the following is the most likely diagnosis?

A. Hypertrophic cardiomyopathy.
B. Cardiac sarcoidosis
C. Cardiac amyloidosis
D. ARVCM

Ans: C

Q. A 19-year-old college basketball player suddenly collapses on the court. A cardiac monitor shows ventricular tachycardia and then ventricular fibrillation. He is successfully resuscitated and hospitalized. The patient's history indicates that his father died suddenly at 38 years of age. The boy's echocardiogram reveals a thickened left ventricular wall, with a small slit-like chamber. The interventricular septum is also markedly thickened. Five years later, the patient expires suddenly. Histologic examination of the heart muscle at autopsy is shown in the image. Which of the following is the most likely diagnosis?

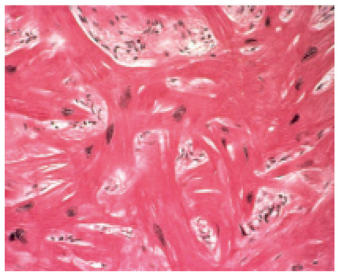

A. Amyloidosis
B. Cardiac myxoma
C. Dilated cardiomyopathy
D. Hypertrophic cardiomyopathy

Ans: D

Q. Autopsy diagnosis of myocardial infarction can be done by immersion of tissue slices in a solution of?

A. Triphenyl tetrazolium chloride
B. 100% alcohol
C. Orcein stain
D. Crystal violet

Ans: A

Yourwish

- Orcein stain → HBsAg stain
- Crystal violet → Heinz bodies in G6PD deficiency

Yourwish

3. VASCULAR PATHOLOGY

NORMAL BLOOD VESSEL

00:00:11

- Tunica adventitia → outermost layer
- Tunica media → middle muscular layer
- Tunica intima → innermost layer
- Lumen lined by endothelial cells
  - Endothelial cells → CD34 positive

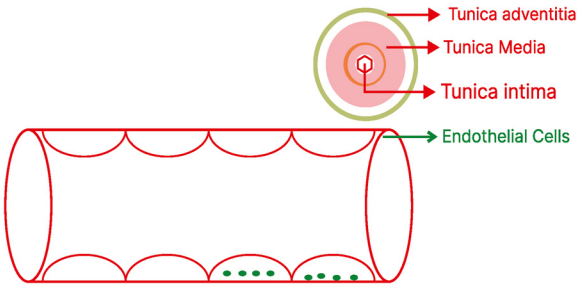

Weibel-palade Bodies

- Present inside endothelial cells
- Contain:
  - von Willebrand factor
  - P-selectin
- Remember → WPWP (Weibel-Palade → vWF + P-selectin)

VASCULITIS

AIIMS 2019,
NEET PG 2019, 2020, 2021, 2024
INICET 2024
FMGE 2024

- "-itis" → inflammation of a blood vessel
- Classification → Chapel Hill classification
- Classified according to the size of vessels

Large Vessel Vasculitis

00:01:04

Temporal Arteritis / Giant Cell Arteritis

Vessel Involved

- Most common → Superficial temporal artery
- Nodular swelling over the artery

Clinical Features

- Most common symptom → localized throbbing headache
- Most specific symptom → jaw claudication (jaw pain)
- Most dangerous → ocular involvement → blindness

Important Management

- Do NOT wait for the pathology report
- Start steroids immediately (stat)

Histopathology

- Giant cells present
- Granuloma present
- Fragmentation of the internal elastic lamina

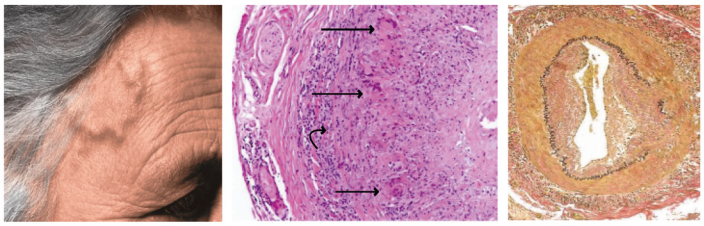

Yourwish

Special Stain

- **Verhoeff-Van Gieson (VVG) stain**
  - Demonstrates internal elastic lamina (zig-zag black line)
  - Shows breaks/fragmentation

Age Of Presentation

- Most common vasculitides in adults
- Age → >50 years (elderly)

Takayasu Arteritis

- Seen in <50 years
- Also called aortitis
- The arch of the aorta branches affected

Vessels

- Most commonly affected → subclavian artery
- Least common → coronary artery

Pathogenesis

- Intimal thickening → lumen narrowing → ↓ blood flow
- ↓ subclavian flow → ↓ upper limb perfusion
- Weak/absent radial pulse → Pulseless disease

Treatment

- Steroids

Comparison

- Temporal arteritis → >50 yrs
- Takayasu arteritis → <50 yrs
- Both → large vessel vasculitis
- Treatment → steroids

Medium Vessel Vasculitis

Mnemonic: Paan Khata Bachcha

- Polyarteritis nodosa
- Kawasaki disease
- Buerger disease

Polyarteritis Nodosa (pan)

00:06:10

- Multiple arteries affected

Association

- 20-30% cases → HBsAg positive (Australia antigen)
- Typical case → ~30-year-old female

Vessels
- Most common → renal vessels

Renal Effect
- Does NOT cause:
  - Nephritic syndrome
  - Nephrotic syndrome
- Causes → flea-bitten kidney (red hemorrhagic spots)

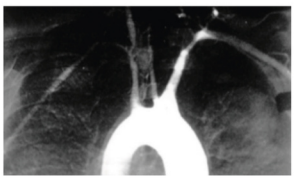

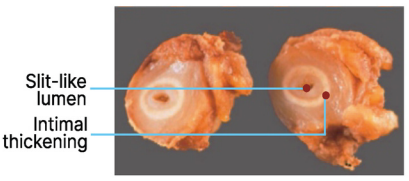

Vessel Never Involved
- Pulmonary vessels
- Therefore → no hemoptysis

Microscopy
- Fibrinoid necrosis of the vessel wall

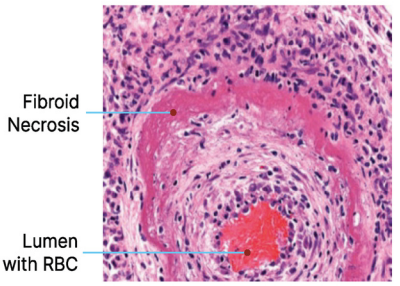

00:07:54

Kawasaki Disease
- K → kids (<5 years)

Criterion
- **Mandatory**- Fever >5 days
- **>4 / 5 of the following criteria**
  - Bilateral non-purulent **C**onjunctivitis
  - **R**ash
  - **E**dema/swelling
  - Unilateral cervical lymph**a**denopathy
  - **M**ucosal involvement → strawberry tongue


Strawberry Tongue

Important Information
- Strawberry tongue is also seen in scarlet fever
- In child + vasculitis → Kawasaki disease

Cause
- Anti-endothelial cell antibodies

Blood Finding
- Thrombocytosis (↑ platelets)

Complications
- Coronary artery involvement
- Can lead to myocardial infarction (MI) in a child
  - Even a 4-5-year-old child can develop a heart attack

Management
- Same protocol as MI prevention
  - Aspirin
- Two treatments:

Yourwish

- IV immunoglobulin (IVIg)
- Aspirin
  → Initially → high dose
  → Later → low dose (to prevent coronary complications)

Buerger's Disease (thromboangiitis Obliterans)

00:11:00

- Note: Buerger's (vasculitis) ≠ Berger's (IgA nephropathy kidney disease)
- AKA Thromboangiitis obliterans

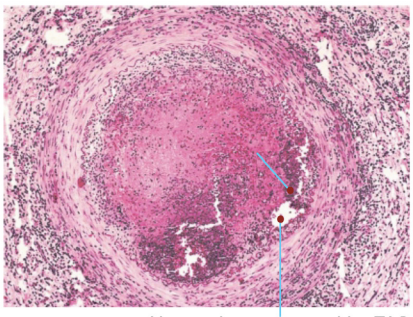

Narrow lumen caused by TAO

Association

- Chronic smoking (always a smoker in question)

Pathogenesis

- Thrombus formation
- Lumen obliteration + inflammation (angiitis)

Vessels Involved

- Arteries → involved
- Veins → involved
- Nerves → involved
- Lymphatics → NOT involved

Clinical Features

- Lower limb vessels affected → ↓ blood flow
- Pain on exertion → intermittent claudication
- Later → pain even at rest (nerve involvement)

Treatment

- Cessation of smoking

Small Vessel Vasculitis

00:11:30

Henoch-schönlein-purpura (hsp)



Skin

- Palpable purpura
- Located below the buttocks / lower limb
- Platelet count → normal (not thrombocytopenia)

Features ("paarpura")

- Purpuric rash
- Arthralgia
- Abdominal pain (GI involvement)
- Renal involvement → hematuria
  - Most common organ involved → kidney

Pathogenesis

- ↑ IgA deposition in vessel wall → vasculitis → palpable purpura

Yourwish

Yourwish

Rules Of Purpura

- Normal platelets → palpable purpura
- Low platelets (ITP, dengue) → non-palpable purpura
- Pinch purpura → amyloidosis (periorbital changes: Racoon eyes)

Treatment

- Steroids (prednisolone) if severe GI or renal involvement

Important Information

- HSP → most common vasculitis in children
- Kawasaki → vasculitis in children causing death due to coronary involvement

Anca-associated Vasculitis

- Wegener's granulomatosis (GPA)
- Microscopic polyangiitis
- Churg-Strauss

WEGENER'S GRANULOMATOSIS	• **AKA Ganulomatosis with polyangiitis**
	• **Granulomas present in**
	  ○ Blood vessels
	  ○ Kidney- RPGN type 3
	  ○ Lung- cavitary lesions
	• **ENT triad**
	  ○ Ear → otitis media
	  ○ Nose → nasal septal perforation
	  ○ Throat/gums → strawberry gums (Strawberry tongue → Kawasaki/scarlet fever)
	• **Treatment**
	  ○ Rituximab + cyclophosphamide
	  ○ Active/induction phase → rituximab followed by cyclophosphamide
	 
	Strawberry Gums

MICROSCOPIC POLYANGIITIS	**Polyarteritis Nodosa**
	• Polyarteritis nodosa → associated with Hepatitis B
	• Microscopic polyangiitis → glomerulonephritis present
	• PAN → no glomerulonephritis
	• PAN → no pulmonary vessel involvement
	• Microscopic polyangiitis → pulmonary vessels involved
	Microscopic Polyangiitis
	• Most vasculitis → some necrosis/giant cells/granuloma
	• Exception → Microscopic polyangiitis
	  ○ No granuloma formation
	  ○ Also called leucocytoclastic vasculitis
	  → Leuco → WBC
	  → Clastic → fragmented
	  ○ Shows fragmented white blood cells

CHURG-STRAUSS SYNDROME (EGPA)	• Similar to Wegener's granulomatosis, but with many eosinophils • New name → EGPA (Eosinophilic Granulomatosis with Polyangiitis) • Eosinophils attack → heart • Causes → cardiac complications

Yourwish

Anca (anti-neutrophil Cytoplasmic Antibody)

00:21:45

- Antibody against the cytoplasm of a neutrophil

Types And Immunofluorescence

- Entire cytoplasm green → C-ANCA
- Outline around nucleus → P-ANCA

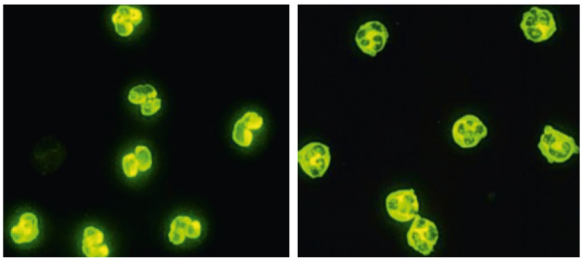

Perinuclear staining (P-ANCA/MPO-ANCA)

Cytoplasmic staining (C-ANCA/PR3-ANCA)

Antigens

- C-ANCA → PR3-ANCA
- P-ANCA → MPO-ANCA
- Mnemonic → CPR (C-ANCA = Pr3)

Associations

- Wegener's granulomatosis → both, more commonly C-ANCA
- Microscopic polyangiitis → P-ANCA
- Churg-Strauss → P-ANCA

Other Associations

- GI → Ulcerative colitis, Crohn disease → P-ANCA
- Liver → Primary sclerosing cholangitis → P-ANCA

Behcet's Disease

00:25:25

- Usually, small vessel vasculitis
- Can involve large vessels (CNS vessels)
- Associated with HLA-B51
- **Triad- Triple "U"**
  - Oral **U**lcers (recurrent aphthous)
  - **U**veitis
  - Genital **U**lcers
- **Diagnosis**
  - Pathergy test
- **CNS manifestation**
  - Dural sinus thrombosis

SCLEROSIS (ARTERIOLOSCLEROSIS)

00:26:55

FMGE 2020

- Sclerosis → stiffness of vessels

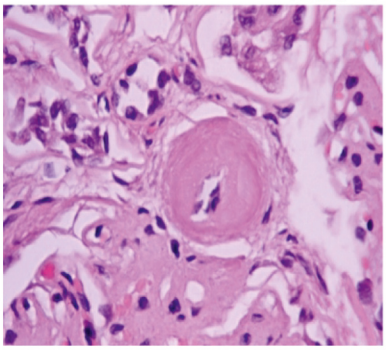

Hyaline Arteriolosclerosis

- Pink glassy material in arterioles
- Seen in:
  - Benign hypertension
  - Diabetes mellitus

Hyperplastic Arteriolosclerosis

- ↑ smooth muscle & fibroblasts
- Onion-skin appearance
- Seen in malignant hypertension

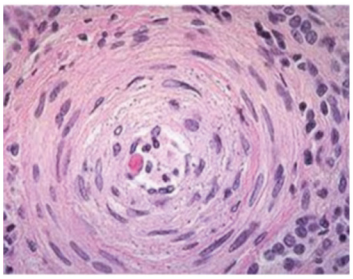

Monckeberg Sclerosis (calcific Medial Degeneration)

- Calcium deposition in the tunica media
- Old age degeneration
- No clinical significance
- Calcification type → dystrophic calcification

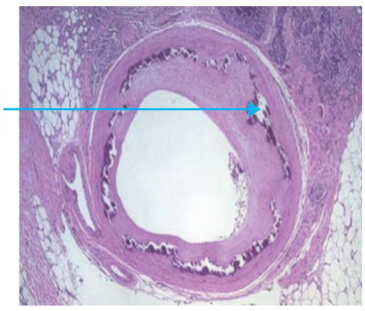

Atherosclerosis

00:29:14

Definition

- Cholesterol deposition in blood vessels

Risk Factors

- Sedentary lifestyle
- Obesity
- Hypertension
- Smoking

Infectious Associations

- Chlamydia
- Cytomegalovirus
- Herpes virus

Pathogenesis

- Endothelial injury hypothesis
- First injury → intima

Lesions

- First lesion → fatty streaks
  - Yellow
  - Few millimeters
- Progression → atheromatous plaque (subintimal)

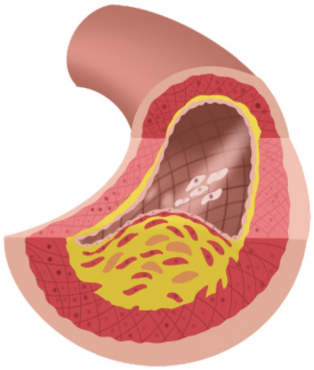

Microscopy

- Foam cells → lipid-laden macrophages
- Fat stain → Oil Red O

Yourwish

Acute Complications

- Aneurysm
- Calcification
- Ulceration
- Thrombosis
- Embolism → Leads to angina, MI

Vessels Affected

Mnemonic: ACP of Delhi traffic Is Cute

- **A** → Abdominal aorta (most common vessel)
- **C** → Coronary artery
- **P** → Popliteal artery
- **Delhi traffic** → Descending thoracic aorta
- **Is** → Internal carotid artery
- **Cute** → Circle of Willis (base of brain)

VASCULAR TUMORS-CLASSIFICATION

00:34:11

FMGE 2020

Benign Vascular Tumors

Hemangioma

CAPILLARY HEMANGIOMA	CAVERNOUS HEMANGIOMA
• Occurs in superficial sites (Skin, mucosa) • Microscopy- small, closely packed vessels	• Deep-seated (Deep tissue, organs) • Microscopy- dilated vascular channels • Associated with von Hippel lindau syndrome

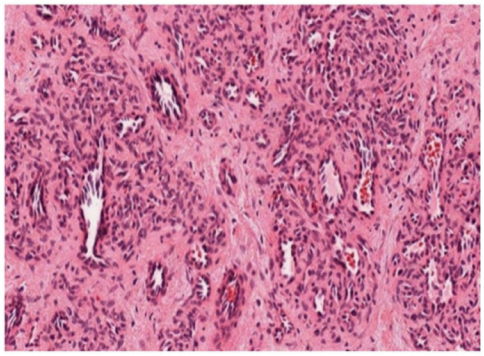

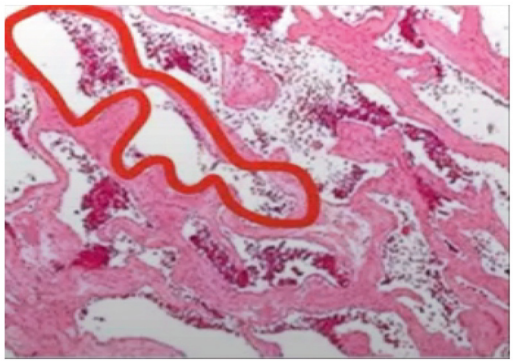

Strawberry Hemangioma

- Seen in children
- Increases in size initially
- Later decreases → disappears by ~7 years
- Type → capillary hemangioma
- Association → von Hippel-Lindau (VHL), chromosome 3 deletion

Pyogenic Granuloma

- Name incorrect (not pus, not granuloma)
- Also called → granuloma gravidarum
- Pregnancy tumor

Yourwish

Yourwish

Clinical

- Pregnant female
- Reddish lesion
- Site → finger or oral cavity
- Regresses after delivery



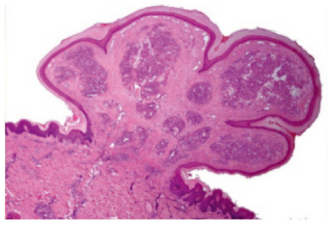

Microscopy

- Capillary hemangioma
- Lobular capillary hemangioma (PYQ)

Lymphangioma

- Association → Turner syndrome (45XO)
- Neck swelling → cystic hygroma
- Type → cavernous lymphangioma



Glomus Tumor

- Location → subungual (nail bed)
- Very small but extremely painful
- Origin → glomus body (arteriovenous anastomosis for thermoregulation)

Bacillary Angiomatosis

- Caused by → Bartonella henselae
- Special stain → Warthin-Starry silver stain (organism appears black)
  - Also used for → H. pylori

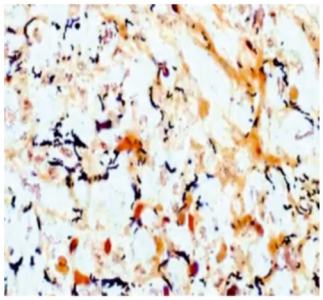

00:41:14

Intermediate Tumor

Kaposi Sarcoma

- Cause → HHV-8
- Seen in → immunocompromised (HIV/AIDS)

Sites

- Skin (most common → lower limb)
- Lymph nodes- 2nd MC

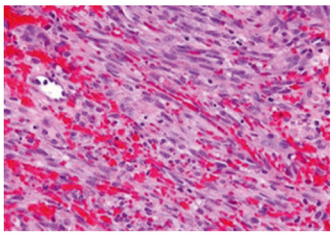

Lesions

- Purple-red vascular lesions

Microscopy

- Spindle cells
- Slit-like blood vessels

Special Stain

- LANA positivity (latency-associated nuclear antigen)

Yourwish

Malignant Vascular Tumors

00:43:04

Angiosarcoma

- Common site → liver

Associated Chemicals

- Vinyl chloride (PVC/plastics)
- Arsenic (pesticides)
- Thorotrast (old thorium contrast dye)

Hemangiopericytoma

- Malignant tumor
- Characteristic → staghorn / fish-hook blood vessels
- Compared with → fibroadenoma breast (staghorn clusters on FNAC)

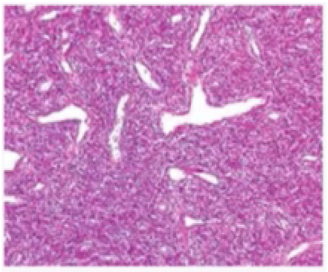

PYQs

00:44:40

Q. Which of the following is not a part of the criteria for diagnosis of Kawasaki disease?

INICET May 2024

a. Strawberry tongue
b. Polymorphic rash
c. Purulent conjunctivitis
d. Cervical lymphadenopathy

Ans: c. Purulent conjunctivitis

Q. A 7-year-old boy has non-blanching rashes on the legs and buttocks. He also complains of joint pains, abdominal pain, vomiting, and blood in the stool. Lab investigations revealed a normal platelet count, and urine analysis shows haematuria +++ and proteinuria +. What is the diagnosis?

FMGE June 2021

a. Systemic lupus erythematosus (SLE)
b. Henoch Schoenlein purpura (HSP)
c. Immune thrombocytopenic purpura (ITP)
d. Polyarteritis nodosa (PAN)

Ans: b. Henoch-Schönlein-Purpura (HSP)

Q. A 50-year-old HIV patient presented with a painful lesion, as shown in the image. What is the most likely diagnosis?

a. Basal cell carcinoma
b. Kaposi sarcoma
c. Malignant melanoma
d. Squamous cell carcinoma



Ans: b. Kaposi sarcoma

Q. A 45-year-old man presents with pain in the legs upon exercise and the destruction of finger tipsHe has an 80-pack-year history of smoking. Laboratory values include hemoglobin of 16 g/dL, WBC count of 8500, serum cholesterol of 220 mg/dL, fasting blood sugar of 90 mg/dL, and negative tests for antinuclear antibodies. A biopsy of the affected area (shown in the image) reveals intraluminal thrombi in medium-sized arteries and inflammation extending from arteries to neighboring veins and nerves. What is the appropriate diagnosis?

a. Buerger disease
b. Churg-Strauss disease
c. Kawasaki disease
d. Polyarteritis nodosa

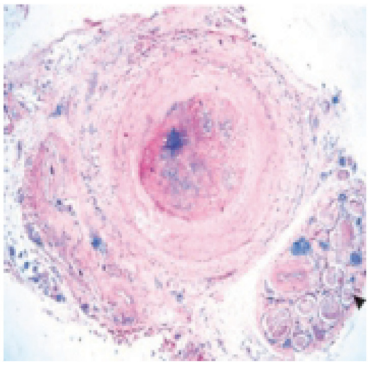

Ans: a. Buerger disease (Thromboangiitis obliterans)

Yourwish

Q. A 70-year-old woman complains of a throbbing U/L headache and vision problems. She reports weight loss and mandibular pain while eating. The patient also has a history of recurrent bouts of fever accompanied by malaise and muscle aches. Physical examination reveals nodular enlargement of the temporal artery with pain on palpation. A biopsy (shown in the image). What is the appropriate diagnosis?

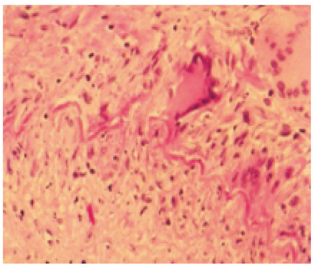

a. Giant cell arteritis
b. Kawasaki disease
c. Polyarteritis nodosa
d. Wegener granulomatosis

Ans: a. Giant cell arteritis

Q. A 35-year-old woman presents with complaints of slowly progressive difficulty hearing in the right ear. She also has pulsatile tinnitus. On examination, a reddish mass was seen behind the tympanic membrane, and an audible bruit was heard over the mastoid when auscultation with a stethoscope was performed. Her Rinne test was negative. Which of the following is the most likely diagnosis?

FMGE Dec 2021

a. CSOM
b. ASOM
c. Mastoiditis
d. Glomus tumor

Ans: d. Glomus tumor

Yourwish

6. LUNG PATHOLOGY

OBSTRUCTIVE LUNG DISEASE

00:00:15

- Problem with expiration (breathing air out) due to airway obstruction
- Categories (CAB):
  - **C**: COPD (Includes Emphysema and Chronic Bronchitis)
  - **A**: Asthma
  - **B**: Bronchiectasis

Copd

NEET PG 2019
FMGE 2022

Emphysema

- Permanent, irreversible damage distal to the terminal bronchiole
- The terminal bronchiole remains normal
- Damage occurs in the Acinus (RDS):
  - **R**: Respiratory Bronchiole
  - **D**: Alveolar Duct
  - **S**: Alveolar Sac

Mechanism

- Loss of elastic recoil (similar to a worn-out rubber band)
  - Oxygen inhalation is normal
  - Carbon dioxide (CO_2) cannot be easily pushed out

Clinical Pathology

- Pink Puffers: Patients maintain normal oxygen saturation levels

Radiology Findings

- Lung enlargement/expansion
- Flattening of the diaphragm (originally dome-shaped, now pushed down)

Types Of Emphysema

Centriacinar

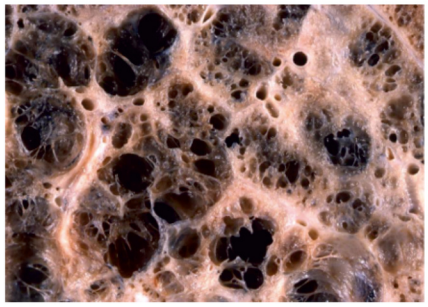

- Central portion damaged (Respiratory bronchiole)
- Alveolar duct and sac remain normal
- Associated with smoking (hot air rises → affects upper lobes)
- Most common clinical type

Yourwish

Panacinar 	• Entire acinus affected (RB, duct, and sac) • Associated with Alpha-1 Antitrypsin deficiency • Affects the lower lobes • Associated with multi-organ involvement (e.g., Liver cirrhosis)
Distal acinar 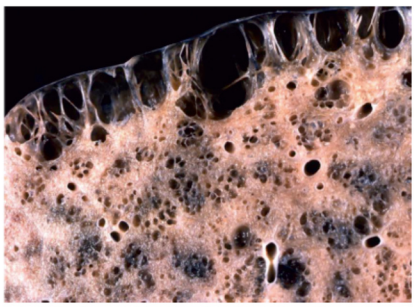	• The alveolar duct and sac are affected; RB is normal • Fibers are thin and prone to bursting • Associated with spontaneous pneumothorax
Irregular	• Patchy damage to various areas • Most common type found histologically (under the microscope)

Microscopy

- "Floating Septa": Broken alveolar walls appearing as fragmented tissue floating within enlarged air spaces

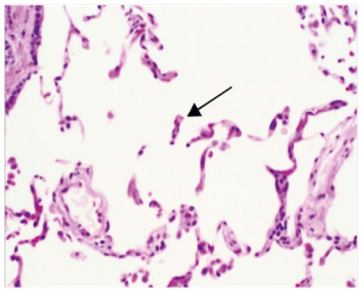

Chronic Bronchitis

00:05:46

NEET PG 2024

- Productive cough for 3 months in 2 consecutive years
- All other causes ruled out→ TB, Cancer, Bronchiectasis, Asthma

Pathophysiology

- Smoking/irritants → Hypertrophy of submucosal glands → ↑ Mucus production by submucosal glands
- Mucus promotes bacterial growth.
  - 1st Most common: Influenza
  - 2nd Most common: Moraxella catarrhalis



Reid's Index

- Reid's index= $\frac{\text{Submucosal gland thickness}}{\text{Overall thickness}}$

- Normal: 0.4
- Chronic Bronchitis: ↑ Reid's index (>0.4) due to gland hypertrophy

Complications

- Mucus obstruction → Hypoxia (↓ Oxygen)
- Cor pulmonale

Hypoxia
↓
Vasodilation & Pulmonary vasoconstriction (unique to the pulmonary system)
↓
Pulmonary Hypertension
↓
Back pressure on the right heart
↓
Right-sided heart failure

- Can be seen in later cases of emphysema

Clinical Presentation

- Blue Bloaters: Due to hypoxia and systemic congestion

Asthma

00:10:38

- Type 1 Hypersensitivity (Allergic reaction)

Sputum microscopy (the 3 cs):

NEET PG 2022, 2024

Charcot-Leyden Crystals	Creola Bodies	Curschmann Spirals
• Needle-shaped; composed of Galectin-10 • Derived from eosinophils	• Clusters/groups of shed airway epithelial cells	• Spiraled/twisted mucus plugs
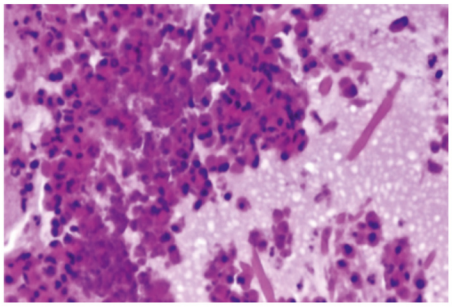	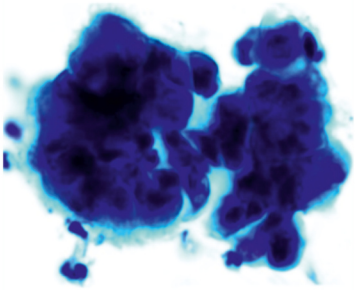	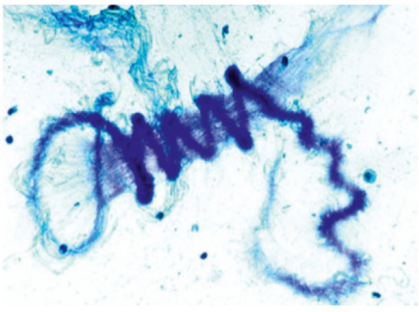

Airway Remodelling

FMGE 2023

- Chronic asthma changes in all layers of the airway
  - Mucosa
  - Basement membrane
  - Muscle layer (hypertrophy)
  - Submucosal glands

Yourwish

Reids Index

- Normal (0.4) in BA as both the numerator (glands) and denominator (overall wall thickness) increase proportionally

INICET 2022

Bronchiectasis

00:13:18

- Permanent dilation of bronchi and bronchioles
- Common Site: Left lower lobe



Causes

- Severe infections (Sepsis)
- Obstruction (e.g., aspiration of a peanut, coin, or toy)
- Kartagener Syndrome (Genetic):
  - Defect in Dynein protein of cilia
  - Associated with infertility due to ciliary dysfunction
  - Triad (BSS)
    - → Bronchiectasis
    - → Sinusitis
    - → Situs inversus (earlier known as Dextrocardia)

Investigations

- **IOC**: HRCT (High-Resolution CT)
- Radiological Findings
  - Tram-track appearance: Dilated bronchi visible as parallel lines
  - Signet ring appearance: Dilated bronchus adjacent to its pulmonary artery



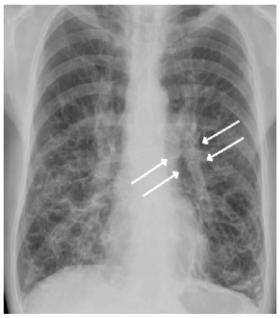

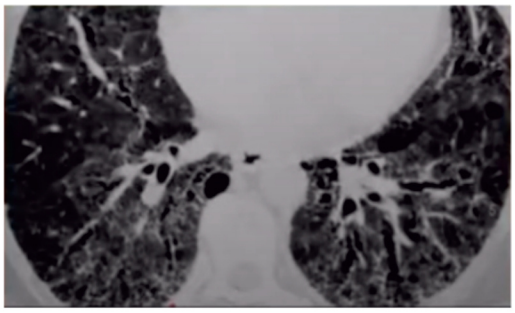

Important Information

- Tram track appearance on microscopy is seen in MPGN type 1

RESTRICTIVE LUNG DISEASES

00:16:34

- Difficulty with inhalation/expansion due to fibrosis
- Consists of
  - Sarcoidosis
  - Pneumoconiosis

Sarcoidosis

FMGE 2021, 2023

- Cause: Unknown (Immune dysregulation)
- Multi-organ involvement:

Yourwish

Yourwish

- Lung (MC organ affected): Fibrosis (RLD)
- Lymph Nodes (2nd MC organ affected): Potato lymph nodes (hilar lymphadenopathy)
- Liver: Non-viral hepatitis
- Skin: Erythema Nodosum
- Eyes: Uveitis
- Glands: Lacrimal and Salivary (Mikulicz syndrome)

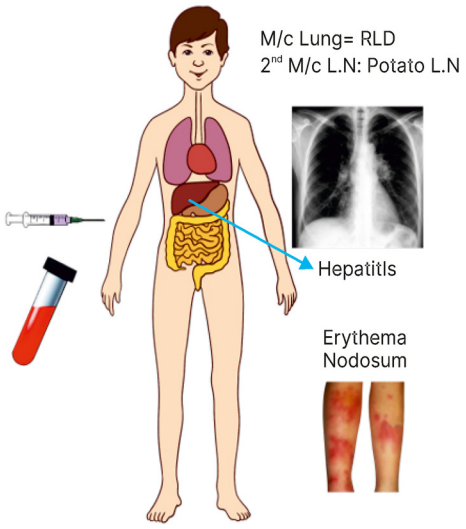

Diagnosis

- ↑ CD4/CD8 ratio (>3.5; normal is 2:1)
- ↑ ACE (Angiotensin Converting Enzyme) levels
- ↑ Calcium levels
- Kveim Test: Historical skin test

Biopsy

- Non-caseating granulomas (vs. caseating in TB)
- Naked Granulomas
  - Lacks a peripheral lymphocytic collar
- Asteroid Bodies
  - Star-shaped intracellular bodies (found within giant cells)
- Schaumann Bodies: Laminated calcium and protein deposits (resemble Psammoma bodies)

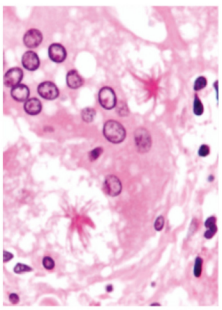
Asteroid Bodies

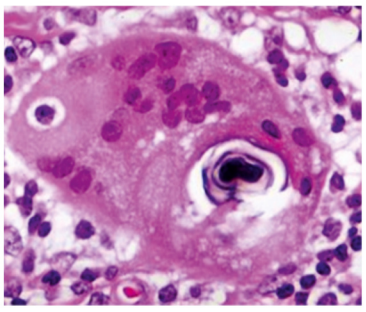
Schaumann Bodies
Sarc Ca^{2+}

Important Information

- Asteroid bodies in Sporothrix schenckii (Rose Gardener's disease) are extracellular; in Sarcoidosis, they are intracellular

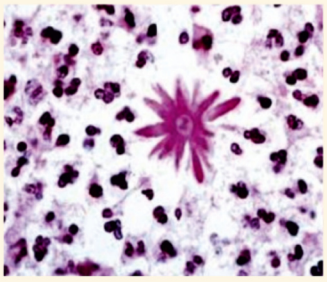

Lofgren Syndrome

- A clinical subtype presenting with:
  - Erythema Nodosum
  - Granulomas
  - Lymphadenopathy
  - Fever
  - Arthralgia (Joint pain)

Pneumoconiosis

00:21:46

Silicosis	• MC pneumoconiosis • Industry: Glass, grinding, or mining • Agent: Quartz (Silica) • Causes nodular fibrosis and eggshell calcification of lymph nodes • Increased risk of: TB and lung cancer

Yourwish

Coal workers pneumoconiosis	• **Anthracosis-** Carbon pigment (black lungs); asymptomatic • **Simple CWP-** Centriacinar emphysema. • **Complicated CWP-** Progressive Massive Fibrosis **Associated Syndromes** • Caplan Syndrome: Pneumoconiosis + Rheumatoid Arthritis. • Erasmus Syndrome: Pneumoconiosis + Systemic Sclerosis (Scleroderma)
Byssinosis	• D/t Cotton dust (Organic dust)
Bagassosis	• D/t Sugarcane dust
Berylliosis	• D/t Beryllium • Presents with non-caseating granulomas (distinguish from Sarcoid via history and normal ACE/Ca)
Baritosis	• D/t Barium
Stannosis	• D/t Tin or Lead
Siderosis	• D/t Iron

Asbestosis	• Industry: Shipyard or Cement
	
	Fibers
	• Amphibole/Crocidolite: Rigid and straight
	• Chrysotile/Serpentine: Wavy (like a snake)
	
	Progression
	• Pleural Plaque → Pleural Nodule → Cancer
	
	Microscopy
	• Asbestos/Ferruginous Bodies seen
	  ○ Dumbbell-shaped
	  ○ Center is an asbestos fiber coated in Iron
	• Stain: Perls Prussian Blue
	
	Associated Cancer
	• Most common: Adenocarcinoma of the lung
	• Most specific: Mesothelioma
	
	 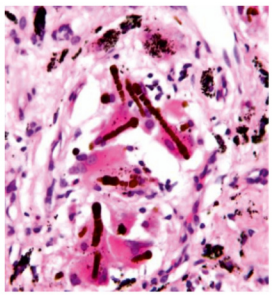
	 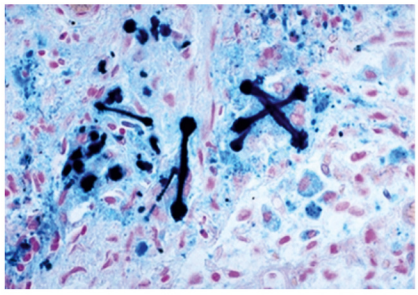
	Fe: Perl's/ Prussian Blue

Important Information

- All pneumoconiosis commonly involves the upper lobes, except Asbestosis, which involves the lower lobes

Different Dumble Shaped Structures In Medicine

Lungs • Asbestos body	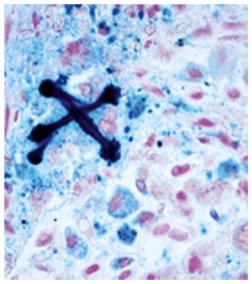
Urine crystal • Calcium oxalate	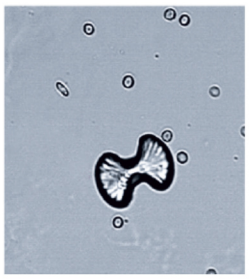
Radiology • Schwannoma spine	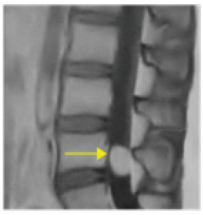 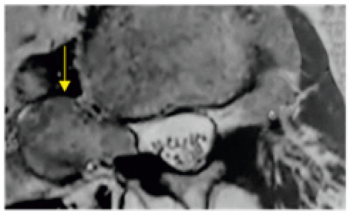
Microbiology • Pox virus dna	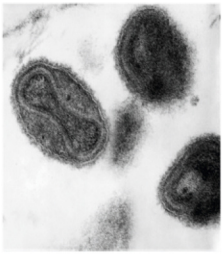

LUNG TUMORS

00:30:47

Benign lung tumor

Pulmonary hamartoma/chondroma

- Most common benign lung tumor
- Indigenous or native tissue that increases in volume
- Native lung tissue (cartilage) increases → Chondroma (benign tumor)

Radiology

- Shows a round, coin-like lesion
- Displays "popcorn calcification"

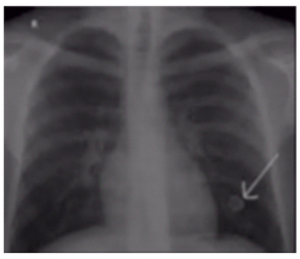
Coin Lesion


Popcorn Calc

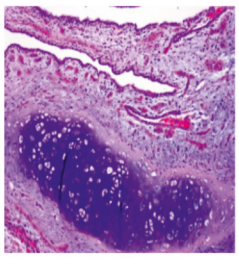
Cartilage

Yourwish

NEET PG 2024
INICET 2024
FMGE 2024

Malignant Lung Tumors

- Most common malignancy found in the lungs- Metastasis
- Cannonball metastasis- Shows multiple nodules throughout the lung
- 4 types
  - Squamous cell carcinoma
  - Adenocarcinoma
  - Small cell carcinoma (previously called "Oat cell" cancer)
  - Large cell carcinoma

Features	Squamous cell cancer	Adeno- carcinoma	Small cell carcinoma	Large cell carcinoma
Common		M/C	Most aggressive	
Smoking	Yes	Usually not	Yes	Usually not
Location	Central	Peripheral	Central	Peripheral
Genetics	p53 gene	EGFR 1 ALK gene KRAS	Loss of Ch3P (almost all) L-myc amplification	
Precancer	+	+	+	+
Hpe 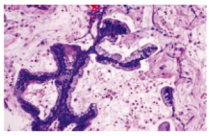	Characterized by pink keratin pearls 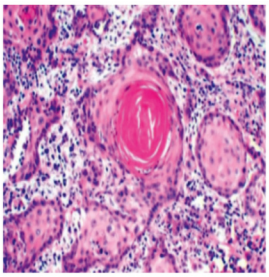	Characterized by gland formation	Azzopardi Effect: Smeared tumor cells/DNA depositing on blood vessels, making them appear blue Smeared tumor cells/DNA depositing on blood vessels, making them appear blue 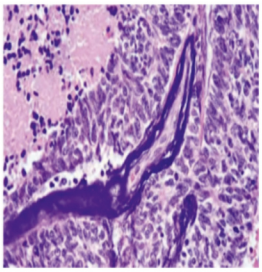 Feulgen stain is specific for DNA Salt and Pepper Nuclei: Nuclei show alternating black dots and white areas	

Yourwish

			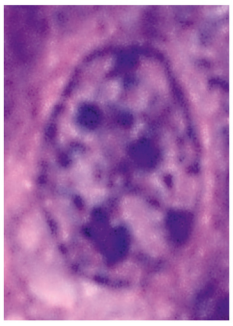 Electron microscopy shows neurosecretory granules 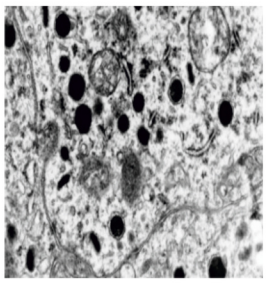	
IHC markers	P40 and P63 positive P40 is the best/ superior marker	Napsin A TTF1 Mucin 1 (Muc1) positive	Synaptophysin Chromogranin Bombesin CD56 and CD57 NSE (Neuron-specific enolase) INSM: The only intranuclear marker	
Para-neoplastic syndrome	Hypercalcemia	Migratory thrombophlebitis (Trousseau phenomenon) Characterized by inflammation of veins (phlebitis) and blood clots (thrombo) moving between veins	MC type to show PNS SIADH- MC Cushing Syndrome Lambert-Eaton Syndrome	Gyneco-mastia

Adenocarcinoma In Situ

- Precancerous stage of Adenocarcinoma
- Formerly known as Bronchoalveolar Carcinoma (BAC)
- Cancer cells are sitting on the alveolar walls without invading or breaking through them
  - Known as
    → Butterflies on a fence appearance
    → Picket fence appearance
    → Lepidic pattern

Mesothelioma

00:43:35

- Tumor of the Pleura
- Most specific cancer associated with Asbestos exposure
- Linked to the shipyard and cement industries
- Associated with the BAP1 gene mutation
- Associated with SV40 virus (DNA virus)

Radiology

- Radiology: Shows a peripheral "cage-like" tumor around the lung.
- Patients often present with pleural effusion
- Differential Diagnosis: Mesothelioma vs. Adenocarcinoma
  - Both are peripheral and asbestos-linked.
  - Electron Microscopy (Microvilli):
    → Adenocarcinoma → Short microvilli with no branching
    → Mesothelioma → Long, branching microvilli (like tree branches)



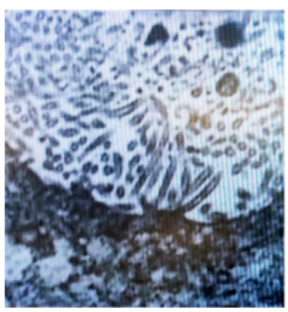

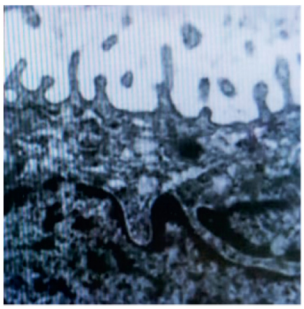

Ihc Markers

- Calretinin is the marker for mesothelioma

PYQs

00:45:50

Q. Which of these is used as a marker in mesothelioma?
a. Calretinin
b. TTF-I
c. CK-8/9
d. Glypican

Ans: a. Calretinin

Q. Marker of small cell cancer of the lung is?
a. Chromogranin
b. Cytokeratin
c. Desmin
d. Vimentin

Ans: a. Chromogranin

Q. A 30-year-old patient arrives at the emergency room with complaints of respiratory discomfort. The patient has been experiencing shortness of breath, coughing, and chest pain for the past few weeks. The patient's

medical history is unremarkable, and there is no significant smoking history. Upon further Investigation, a lung biopsy is performed, and microscopic examination reveals the presence of asteroid bodies. What is the most likely diagnosis for this patient?

a. Sarcoidosis
b. RA
c. Sjogren syndrome
d. SLE

Ans: a. Sarcoidosis

Q. A patient presents with respiratory distress and is diagnosed with pan-acinar emphysema. Which deficiency is responsible for his condition?

NEET PG Aug 2024

a. Type 1 surfactant
b. Type 2 surfactant
c. Alpha-1 antitrypsin deficiency
d. Albumin

Ans: c. Alpha-1 antitrypsin deficiency

Q. A 63-year-old woman with chronic bronchitis presents with shortness of breath. A chest X-ray reveals a 2-cm "coin lesion in the upper lobe of the left lung. A CT-guided lung biopsy is obtained. Which of the following describes the histologic features of this lesion if the diagnosis is hamartoma?

a. Benign neoplasm of epithelial origin
b. Disorganized normal tissue
c. Ectopic islands of normal tissue
d. Granulation tissue

Ans: b. Disorganized normal tissue

Yourwish

8. GASTROINTESTINAL PATHOLOGY

LAYERS OF GI TRACT

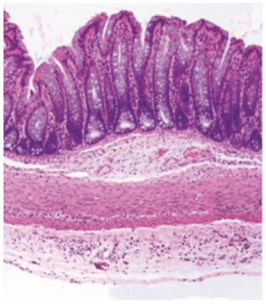

00:00:17

- Layers:
  - Mucosa
  - Submucosa
  - Muscularis propria
  - Serosa
- Pacemaker cells → cells of Cajal
- Submucosa is absent in the gallbladder
- Serosa is absent in the esophagus

ESOPHAGUS

00:00:54

- Physiology:
  - Contraction → Acetylcholine
  - Relaxation → Nitric oxide (NO), VIP

Achalasia Cardia

NEET PG 2020
FMGE 2023
INICET 2020



- No relaxation due to loss of inhibitory neurons: NO + VIP
- Causes
  - Idiopathic
  - Trypanosoma cruzi (Chagas disease) → Romana sign
- Clinical feature
  - Dysphagia → liquids > solids
- Diagnosis:
  - Barium → Bird beak appearance
  - IOC → Manometry (↑ pressure)
- Treatment:
  - Inj. Botox (↓ acetylcholine)
  - Heller's myotomy



ROMANA SIGN

Alcohol-induced Lacerations

NEET PG 2020
FMGE 2019, 2020, 2022

Mallory-weiss

- Superficial tear
- Involving Mucosa + submucosa
- Longitudinal tear
- Below the GE junction

Boerhaave Syndrome

- Full-thickness tear → More severe
- Above GE junction (~2.5 cm)

Yourwish

Yourwish

- Mackler's triad:
  - Vomiting
  - Painful hematemesis
    → Painless hematemesis → Esophageal varices
  - Chest pain
- Hamman's crunch heard→ Subcutaneous emphysema

Barrett's Esophagus

00:05:47

FMGE 2023
INICET 2020, 2022

- Metaplasia: Squamous → Intestinal columnar
- Features: Goblet cells
  - Contains acidic mucin
  - Alcian blue positive
- Endoscopy: Red velvety mucosa
- Risk of adenocarcinoma

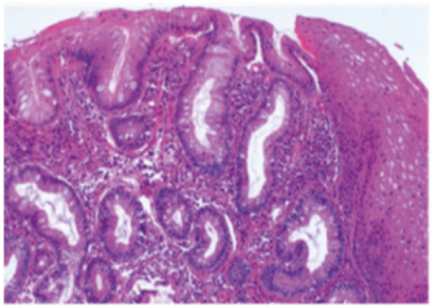
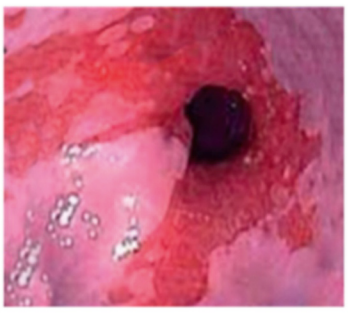
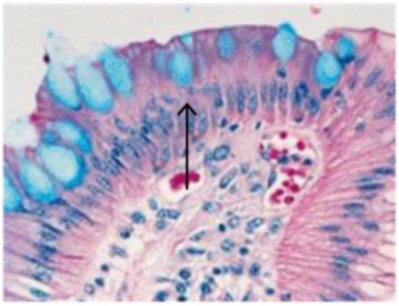

Esophageal Cancer

Adenocarcinoma

- Risk → Barrett's esophagus
- Location → Lower ⅓ GEJ

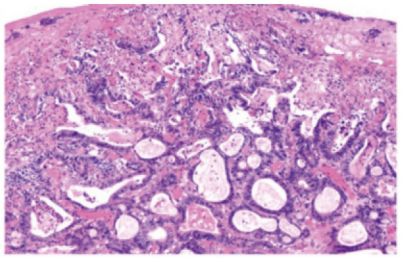

Squamous Cell Carcinoma

- Risk factors
  - Alcohol, smoking, and hot beverages
  - Celiac disease
  - Drugs, radiation
  - Epidermolysis bullosa
  - Tylosis palmaris et plantaris
    → Hyperkeratosis of palms/soles
  - HPV
  - Plummer-vinson syndrome
- Location → Upper and middle ⅓ GEJ
- Overall MC

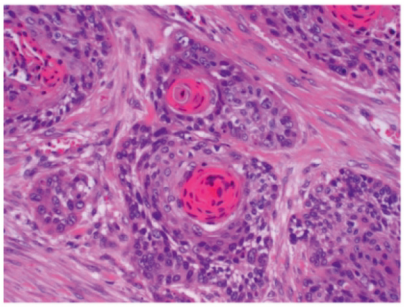

Plummer-vinson Syndrome

- AKA: Sideropenic Dysphagia/Patterson Brown Kelly Syndrome
- Triad
  - Iron deficiency

- Esophageal webs
- Atrophic glossitis

- Seen in → Middle-aged women
- Risk → SCC esophagus
- Gold standard diagnosis → biopsy → keratin pearls

STOMACH

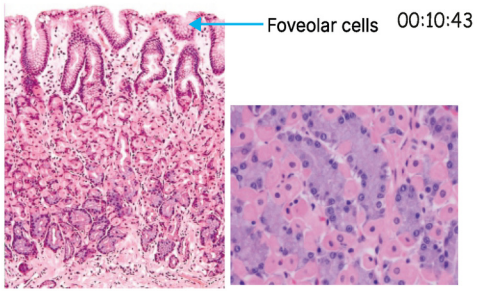

- Normal histology
  - Foveolar cells → Mucin
  - Parietal cells → Pink
  - Chief cells → Blue

Pernicious Anemia

- Autoimmune destruction of parietal cells → ↓ intrinsic factor → ↓ vitamin B12 absorption

Menetrier's Disease



- More common → men
- Cause → ↑ TGF-α
- Clinical features
  - Protein-losing enteropathy
  - Edema
- Gross: Giant cerebriform rugae
- Microscopy: Foveolar cell hyperplasia

Important Information

- TNF-α → anorexia/cachexia
- TGF-β → fibrosis

Stress Ulcers

Cushing ulcer	Curling ulcer
Cause → ↑ intracranial pressure	Cause → Burns
Site → Cardia of stomach	Site → Duodenum
Deep/pushing ulcer	Superficial ulcer

Helicobacter Pylori

FMGE 2019, 2021

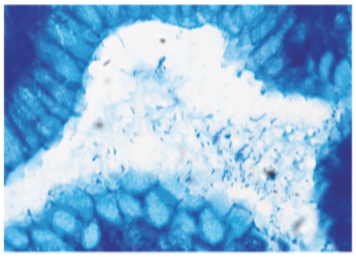

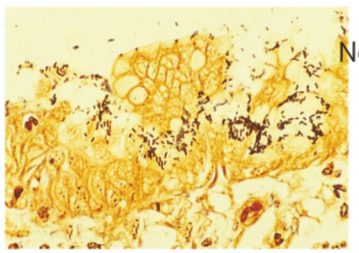



- Survives in acidic pH
- Urease positive
- Virulence:
  - cagA
  - vacA
- Diseases:
  - Gastritis
  - Peptic ulcer
  - Gastric adenocarcinoma
  - MALT lymphoma
- Stains:
  - Warthin-Starry silver stain → Black
  - Modified Giemsa (best)

Gastric Adenocarcinoma

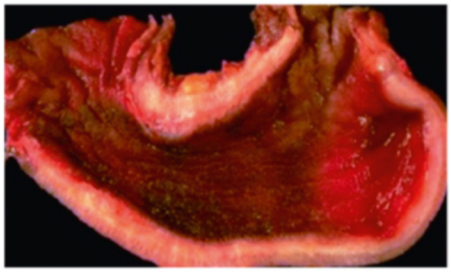

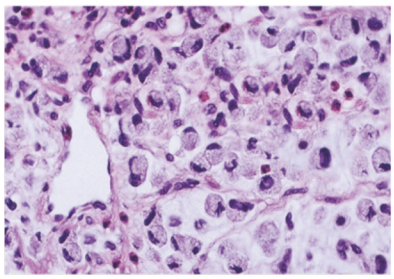

- Most common cancer in the stomach
- Risk factors
  - Alcohol, smoking
  - Smoked/salted food
  - H. pylori
  - Adenomatous polyps
  - Blood group A
- Location
  - Most common → antrum
  - Exception: Pernicious anemia → fundus
- Spread of gastric cancer
  - Ovary → Krukenberg tumor
  - Pouch of Douglas → Blummer shelf
  - Periumbilical → Sister Mary Joseph nodule
  - Left supraclavicular LN → Virchow's node
  - Axillary LN → Irish node
- Diagnosis
  - Gold standard → Biopsy

Lauren Classification

- Intestinal type: Gland formation
- Diffuse type:
  - Loss of E-cadherin → Cells loosely arranged

Yourwish

Important Information

- Loss of E-cadherin→
  - Diffuse gastric carcinoma (DGC)
  - Invasive lobular carcinoma (ILC) of the breast
- Signet ring cells are seen in
  - Diffuse gastric carcinoma (DGC)
  - Invasive lobular carcinoma (ILC) of the breast
  - Krukenberg tumor

Diffuse Gastric Cancer

- Tumor in the wall → Linitis plastica (leather bottle stomach)
- Microscope: Signet ring cells
  - Mucin-filled cell → nucleus pushed to periphery

Gastric Maltoma (Malt Lymphoma)

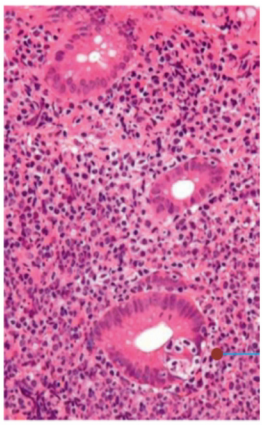

- Type → Marginal Zone Lymphoma
- Causes
  - H. Pylori
  - Translocation t(11;18)
- Microscopy
  - Lymphoepithelial Lesion (LEL)
- Components
  - Lymphoid Component → Malignant → invades epithelium
  - Epithelial Component → Non-malignant

GIST (Gastrointestinal Stromal Tumor)

- Origin → Cells Of Cajal
- Type → Mesenchymal (Stromal Tumor)
- Location
  - Most Common → Stomach > Intestine
- Mutations
  - CD117 (C-Kit) → Most Common
  - PDGFR A
  - SDH (Succinate dehydrogenase) → Pediatric GIST
- Pathogenesis: ↑ Tyrosine Kinase Activity
- Treatment
  - Imatinib (Tyrosine Kinase Inhibitor)
    → Also given in CML
- Markers
  - Most Sensitive → CD117
  - Others → CD34
  - Most Specific → DOG1

Yourwish

Yourwish

INTESTINE

00:25:01

Malabsorption Syndromes

- Hallmark → Steatorrhea
- Stool Features:
  - Bulky
  - Frothy
  - Foul Smelling

Celiac Disease

- AKA:
  - Celiac Sprue / Gluten-Sensitive Enteropathy
- Gluten Sources (BROW)
  - Barley
  - Rye
  - Oat
  - Wheat
- Pathogenic Component: Alpha-Gliadin
- Genetics: HLA-DQ2, HLA-DQ8 polymorphism
- Immunology
  - CD4 + CD8 T cell Activation
  - Antibodies: IgA
    → Anti-Endomysial
    → Anti-Gliadin
    → Anti-TTG
- Site - Duodenum
- Clinical symptoms
  - Diarrhea → Steatorrhea
  - Iron Deficiency Anemia
  - Skin: Dermatitis Herpetiformis
    → Treatment → Dapsone
- Diagnosis: Marsh criteria
  - Villous Atrophy
  - Crypt Hyperplasia
  - ↑ Intraepithelial Lymphocytes (CD8)
- Treatment
  - Avoid → BROW
  - Allowed → Rice, Maize
  - Steroids
- Cancer: Risk of Enteropathy Associated T-Cell Lymphoma

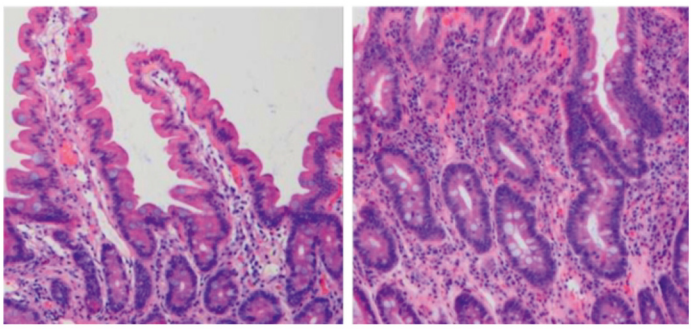

Environmental Enteropathy (tropical Sprue)

- Cause → E. Coli
- Involves → Entire Intestine
- Deficiencies
  - Iron

- B12
- Folic Acid

- Result: Megaloblastic Anemia
- No risk of cancer
- Treatment → Antibiotics

Whipple's Disease

FMGE 2019
NEETPG 2024


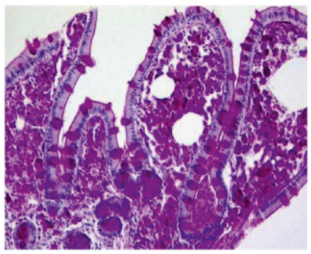

- Organism → Tropheryma Whipplei (Gram +)
- Features:
  - Multiorgan Involvement (GI, CVS, CNS)
- Histology: Foam Cells (Macrophages)
- Diagnosis:
  - PAS Positive Macrophages In Lamina Propria
- Treatment → Antibiotics

Cryptosporidium

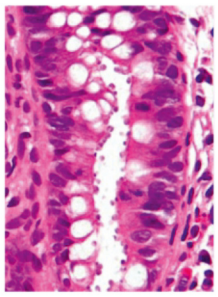
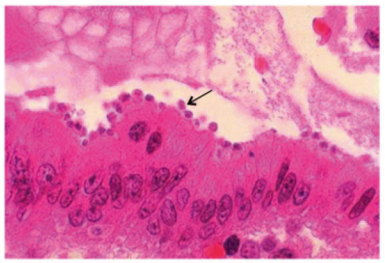

- Type → Parasite
- Location: Brush Border of the intestine
- Clinical features
  - Malabsorption
  - Seen In Immunocompromised

Giardia Lamblia

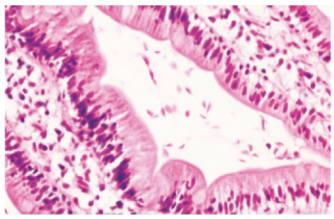
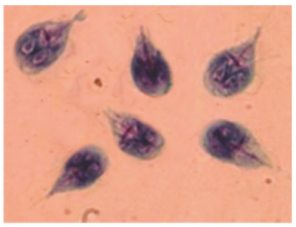

- Feature → Falling Leaf Motility
- Location: Duodenum (Lumen)
- Morphology
  - Stool → Pear-Shaped
  - Duodenum → Sickle-Shaped

FMGE 2021, 2024, INICET 2025

Intestinal Ulcers


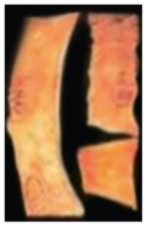
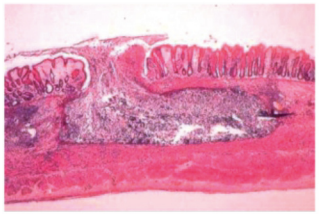

- TB → Transverse Ulcer
- Typhoid → Longitudinal Ulcer
- Entamoeba Histolytica → Flask-Shaped Ulcer

00:35:35

Inflammatory Bowel Disease (IBD)

- Types
  - Intestinal
  - Extraintestinal → UC + PSC
- Mutations:
  - NOD 2
  - ATG 16 L
- Antibodies
  - Crohn's disease
    → ASCA
    → p-ANCA

- Ulcerative colitis
  → p-ANCA (more common)
- Treatment
  - Crohn's disease
    → Steroids
    → Anti-TNF alpha
  - Ulcerative colitis
    → 5-ASA + 6 MP

Crohn's disease

- S → Skip lesion + Skin nodules
- I → most common site → Ileum
- S → Strictures, String sign, ASCA (anti-saccharomyces cerevisiae antibody)
- T → Transmural involvement → fissures, fistulas
- E → Entire wall involved
- R → Rectum spared
- M → Microscopy → Non-caseating granuloma
- A → Aphthous ulcer (first lesion) → serpentine ulcers
- C → Creeping fat outside, cobblestone appearance inside
- Cytokine → ↑ TNF-ALPHA



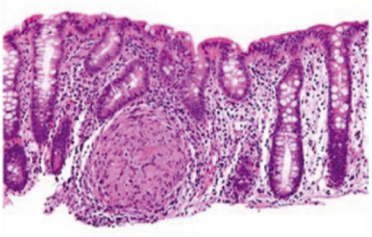
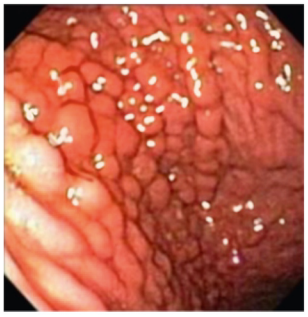

Ulcerative Colitis

NEET PG 2021
INICET 2025
FMGE 2019, 2022, 2025

- Ulcerative → superficial ulcers + pseudopolyps (regenerating mucosa)
- C → Continuous involvement
  - Retrograde involvement
  - Backwash ileitis
- O → Often rectum involved
- L → Lead pipe appearance (radiology)
  - Loss of haustra
- I → Immunity → p-ANCA +++
- T → Toxic megacolon
- I → Increased risk of cancer (UC > CD)
- S → Smoking




Yourwish

Intestinal Polyps

- Hyperplastic
- Hamartomatous
- Adenomatous → Causes Colon Cancer

Hyperplastic Polyp

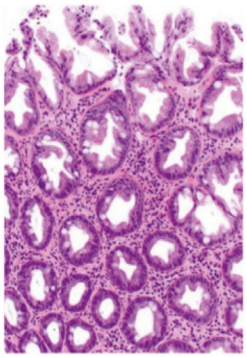

- Mechanism → Hyperplasia (↑ Cells)
- Features: ↑ Crypts
  - Lower Crypts → Round, Regular
  - Upper Crypts → Serrated, Zigzag
- Cancer Risk → No

Hamartomatous Polyps

- Cancer Risk → No

Juvenile Rectal Polyposis

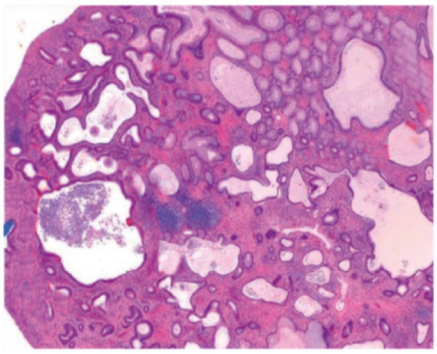

- Age → < 5 Years
- Site → Rectum
- Presentation → Bleeding Per Rectum
- Genes
  - SMAD 2,4
  - BMPR 1a
- Histology: Cystically Dilated Glands

PEUTZ-JEGHERS POLYP

INICET 2019
FMGE 2020





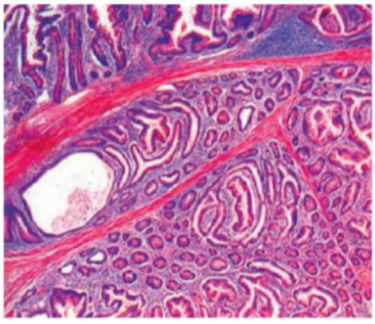

- Gene → STK11 (LKB1)
- Age → > 11 Years
- Features
  - Mucocutaneous Pigmentation
  - Polyps → Jejunum
- Morphology
  - Christmas Tree / Arborizing Polyps
    → Branches → Smooth Muscle

COWDEN SYNDROME

- Gene → PTEN (Chromosome 10)
- Features
  - Endometrial Cancer
  - Thyroid Cancer
  - Trichilemmoma
  - Breast Cancer
  - Hamartomatous Polyps

Banayan Ruvalcaba Riley Syndrome

- Gene → PTEN (Chromosome 10)
- Feature → Mental Retardation

Yourwish

Yourwish

Tuberous Sclerosis

- Genes
  - TSC1 (Chromosome 9)
  - TSC2 (Chromosome 16)
- Association: Cardiac Rhabdomyoma

Cronkhite-canada Syndrome

- Not hereditary
- Age → > 50 Years
- Features
  - Skin Pigmentation
  - Hair Loss
  - Nail Atrophy
  - Hamartomatous Polyps

Adenomatous Polyps

Types

- Tubular Adenoma
- Villous Adenoma → Maximum risk of intestinal/ colon cancer
- Tubulovillous Adenoma
- Sessile Serrated Adenoma
- Familial Adenomatous Polyposis

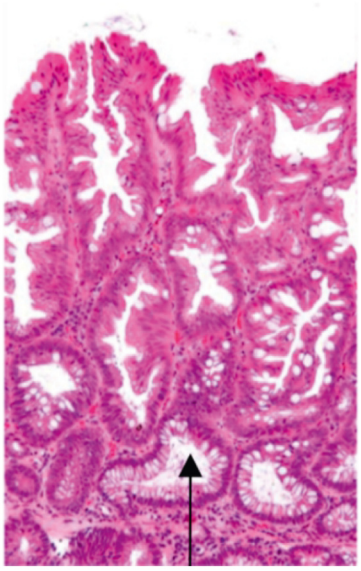

Sessile Serrated Adenoma

- Serrations: Upper + Middle + Lower Crypts
- Shape: Boot-Shaped Crypts

Important Information

- Hyperplastic → Only Upper Serration (No Cancer)
- Sessile Serrated → Full-Length Serration (Cancer Risk)

- **FAMILIAL ADENOMATOUS POLYPOSIS (FAP)**
- Inheritance → Autosomal Dominant
- Polyps → ≥ 100
- Cancer Risk → 100%
- Gene: APC (Chromosome 5q21)

TYPES OF FAP

Classical FAP	Turcot syndrome	Gardner syndrome

• Colon → 100 Polyps
• Congenital Hypertrophy Of Retinal Pigment Epithelium
	• Colon → 100 Polyps
	• Brain Tumors:
	  ○ Medulloblastoma
	  ○ Glioblastoma
		• Colon → 100 Polyps
		• Skin → Sebaceous Cyst
		• Fibrous Tissue → Fibroma
		• Bone → Osteoma
		• Teeth → Supernumerary Teeth

Intestinal Cancer

- Conditions:
  - Crohn's Disease
  - Ulcerative Colitis
  - FAP
  - Lynch Syndrome (HNPCC)
  - Diet:
    → Low Fiber
    → High Fat

INICET 2022
FMGE 2021

Adenoma → Carcinoma Sequence

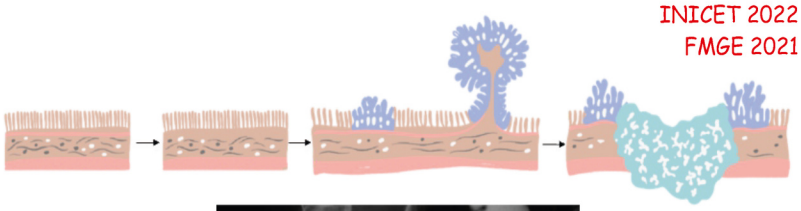

- Genetic: AK 53
  - APC → KRAS → p 53, SMAD 2,4

- Diagnosis
  - Imaging: Apple Core Lesion (Barium Enema)
  - Tumor Marker for colon carcinoma: CEA
  - Occult Blood Test: Guaiac Test (Stool)

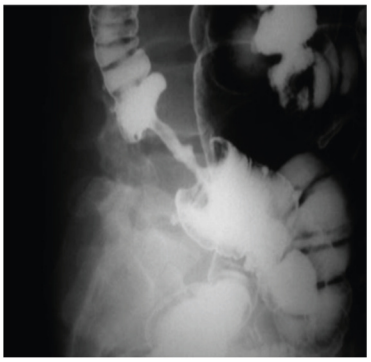

Important Information

- Marker for intestinal inflammation:
  - CRP
  - Fecal Calprotectin
  - Fecal Lactoferrin
- Marker for sepsis: Procalcitonin

PYQs

00:58:53

Q. A 28-year-old female presents to the clinic with complaints of frequent diarrhea, abdominal cramps, bloating, and weight loss over the past two weeks. She mentions that she recently traveled to a rural area for a camping trip and drank untreated stream water during her stay. On physical examination, no fever is noted, but mild tenderness is present in the right upper quadrant of the abdomen. Stool examination reveals the presence of trophozoites and cysts with characteristic "falling leaf" motility under microscopy. Which organism is most likely responsible for this patient's symptoms?

FMGE July 2023

a. Salmonella typhi
b. Entamoeba histolytica
c. Giardia lamblia
d. Cryptosporidium parvum

Ans: c. Giardia lamblia

Q. Which of the following intestinal pathologies is associated with dermatitis herpetiformis?

FMGE Jan 2024

a. Ulcerative colitis
b. Whipple's disease
c. Celiac disease
d. Crohn's disease

Ans: c. Celiac disease

Q. A 70-year-old male patient presents with progressive dysphagia to solids and liquids, and the manometry findings include uncoordinated or absent peristalsis with increased LES resting pressure. What is the most likely diagnosis for this patient?

FMGE July 2023

a. Stomach cancer
b. Cancer esophagus
c. GERD
d. Achalasia cardia

Ans: d. Achalasia cardia

Yourwish

13. HEPATOBILIARY PATHOLOGY

HEPATO-BILIARY SYSTEM: NORMAL ANATOMY

00:00:10

- Liver Lobule Architecture
  - Hexagonal lobule structure.
  - The center consists of the central vein.
  - Periphery consists of the portal triad.
- Hepatocytes and Blood Supply
  - Hepatocytes are arranged in cords.
  - Blood supply is provided by sinusoids.
  - Kupffer cells (liver macrophages) are present within the sinusoids.
- Space of Disse
  - Located between hepatocytes and sinusoids
  - Site for amyloid deposition in the liver
  - Contains Ito cells (also known as Stellate cells)
- Ito / Stellate Cell Function
  - Function depends on the circumstance.
  - Storage: Ito cells store Vitamin A
  - When Ito cells become activated, they become stellate cells
  - Stellate cells deposit Collagen Type 1 and Type 3 → fibrosis → cirrhosis of the liver.
- Liver Pigments and Regeneration
  - Bilirubin is the primary liver pigment.
  - Special stain for bilirubin: Hall stain
  - Liver has high regenerative ability due to stem cells.
  - Stem cells: Known as Oval cells, located in the Canals of Hering

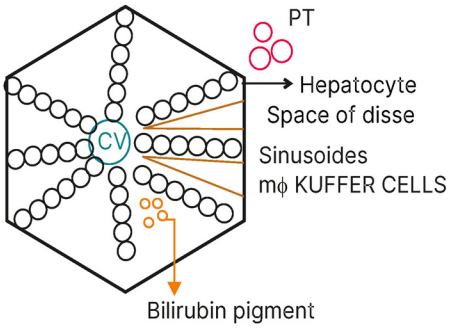

Histopathology of Normal Liver

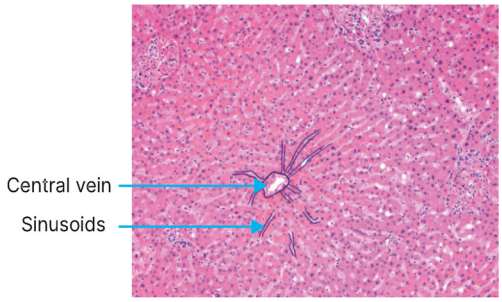

- Central vein in the middle, pink-colored hepatocyte cords, and white spaces representing sinusoids

HYPERBILIRUBINEMIA

NEET PG 2023, FMGE Jan 2024

UNCONJUGATED	CONJUGATED

• Hemolytic anemias (excessive heme production)
  ○ RBC breakdown → Heme release → Heme converted to bilirubin
	• Cause: Any obstruction in the bile duct
	  ○ Stones in the bile duct
	  ○ Strictures

Yourwish

Yourwish

- Syndromes:
  - Crigler-Najjar Syndrome
  - Gilbert Syndrome
  - Cholangiocarcinoma
  - Clonorchis (Parasitic infection)
- Syndromes:
  - Dubin-Johnson Syndrome
  - Rotor Syndrome
- Biliary diseases:
  - Primary biliary cholangitis (PBC)
  - Primary sclerosing cholangitis (PSC)

UNCONJUGATED HYPERBILIRUBINEMIA SYNDROMES

- UDP-glucuronyltransferase (UGT) deficiency

Crigler-Najjar Type 1	Crigler-Najjar Type 2	Gilbert Syndrome:
• Complete deficiency of UGT • 100% fatal disease	• Partial UGT deficiency. • Treatment: Phenobarbital	• Very mild deficiency • Mostly asymptomatic • Manifests under stress, fever, or pregnancy

CONJUGATED HYPERBILIRUBINEMIA SYNDROMES

Dubin-johnson Syndrome	Rotor Syndrome
• Defect: MRP2 gene. • Key finding: Dark pigmented liver. ○ Pigment d/t Epinephrine	• ATP family Defect • Key finding: No liver pigment

- Inheritance Patterns
  - Most are Autosomal Recessive
  - Crigler-Najjar Type 2: Autosomal Dominant
  - Gilbert Syndrome: Some cases may be Autosomal Dominant

BILIARY DISEASES

- Types:
  - Primary biliary cholangitis (PBC)
  - Primary sclerosing cholangitis (PSC)

INI CET 2021, 2025, FMGE Jan 2025

Primary Biliary Cholangitis (PBC)	Primary Sclerosing Cholangitis (PSC)
• Intrahepatic bile duct affected • Antibody: Anti-mitochondrial antibody (AMA) • Associated with: Sjögren's syndrome • Demographics: More common in women • Age: Older population (50–55 years).	• Intra + extrahepatic bile duct affected 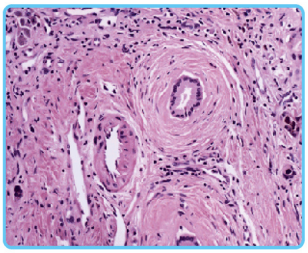

Yourwish

- Onion skinning fibrosis
- Radiology:

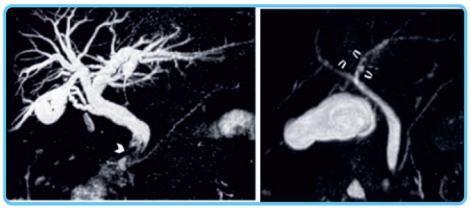

  - Pruning of small bile duct, stricture and beading appearance of large bile duct
- Antibody: P-ANCA
- Associated with: Ulcerative Colitis
- Demographics: More common in men
- Age: Younger population (30s)

CIRRHOSIS

00:10:32

- Definition
  - Liver is replaced by nodules of varying sizes
  - Nodules are separated by fibrosis (Collagen 1 and 3 by Stellate cells)
- Nodule Classification



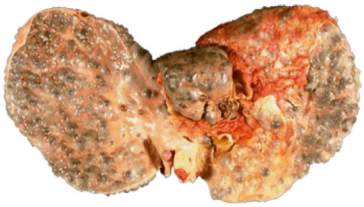

  - Micronodular: Nodules < 3mm (looks like sand grains)
  - Macronodular: Nodules > 3mm
- Causes by Nodule Size
  - Micronodular: Hemochromatosis, PBC, Indian Childhood Cirrhosis
  - Macronodular: Viral hepatitis, Wilson's disease (Copper)
  - Alcoholic Liver Disease: Shows both; starts micro, progresses to macro
- Special Stain for Cirrhosis: Masson Trichrome Stain (Differentiates tissue types)
  - Muscle stains Red
  - Collagen/Fibrosis stains Blue



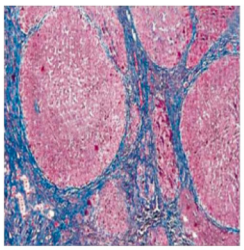

- Causes:
  - ALD/ AIH
  - Biliary diseases
  - Cryptogenic cirrhosis
  - Drug induced
  - Enzyme deficiency
  - Hepatitis
  - Hemochromatosis
  - Wilson disease

ALCOHOLIC LIVER DISEASE (ALD)

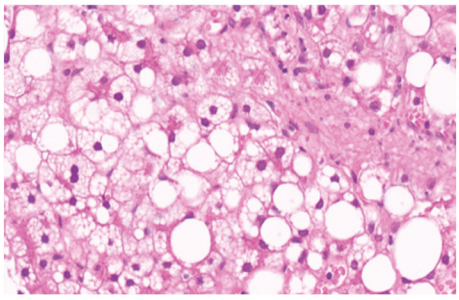

- Stage 1: Steatosis (Fatty Liver)
  - First stage of alcohol consumption
  - Microvesicular: Small fat droplets
  - Macrovesicular: Large fat droplets
  - ALD can show both types
- Stage 2: Steatohepatitis
  - Fat remains + inflammation (itis)

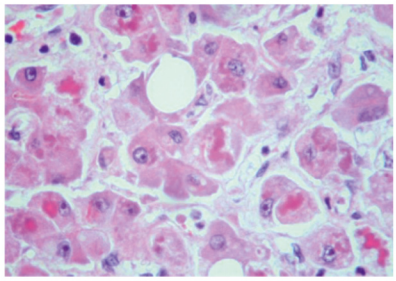

  - Microscopic findings: Mallory-Hyaline bodies/ Denk bodies (pink colour)

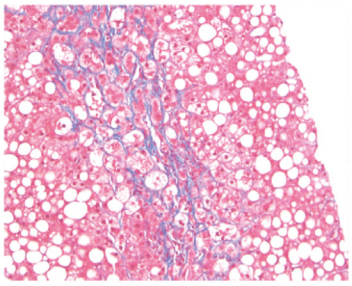

  - Fibrosis: "Chicken wire" fibrosis (pericellular fibrosis)
- Stage 3: Laennec Cirrhosis
  - End-stage scarring where the entire liver is fibrous tissue

MICROVASCULAR VS MACROVASCULAR STEATOSIS

MICROVESICULAR STEATOSIS	MACROVESICULAR STEATOSIS

• Reye Syndrome (Aspirin use in children).
• Fatty Liver of Pregnancy
• HELLP Syndrome (in pregnancy)
 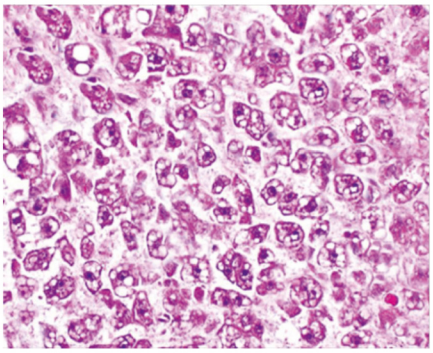
	• Metabolic:
	  ○ Obesity
	  ○ Diabetes Mellitus
	  ○ Total Parenteral Nutrition (TPN)
	  ○ Starvation.
	• Hepatitis: Hep C and Hep D
	  ○ Note: Hep B rarely/least likely causes fatty liver
	 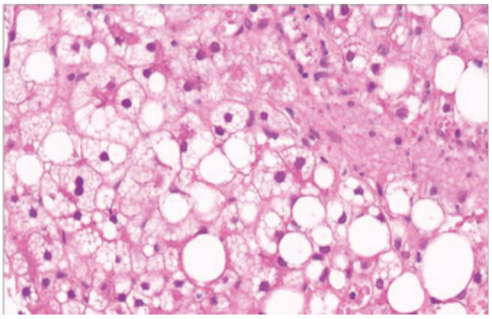

Yourwish

MALLORY HYALINE BODIES

- Composition: Cytokeratin 8 and 18 (CK 8/18)
  - These are intermediate filaments.
- Conditions where present (**Mnemonic:** NEW INDIAN WATCH)
  - **New:** Non-Alcoholic & Alcoholic Liver Disease
  - **Indian:** Indian Childhood Cirrhosis
  - **W:** Wilson's Disease (Copper)
  - **A:** Alpha-1 Antitrypsin Deficiency
  - **T:** Tumors (Hepatocellular Carcinoma)
  - **C:** Cholestasis / Bile stasis
  - **H:** Primary biliary / hepatic diseases
- Conditions where ABSENT
  - Hemochromatosis (Iron overload)
  - Secondary biliary diseases

Cryptogenic Cirrhosis (NALD)

- Causes: Metabolic disturbances
  - Diabetes, high triglycerides, high cholesterol, obesity
- Progression
  - Follows same stages as ALD: Steatosis → Steatohepatitis → Cirrhosis
- Most common cause of death: Cardiac complications

Autoimmune Hepatitis

00:19:44

- Drug-induced AIH: Anti-LKM2 antibody
- Features:

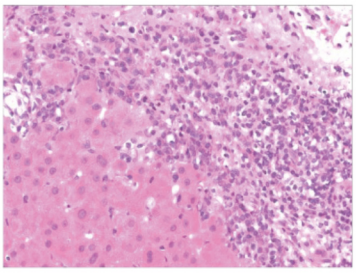

Interface Hepatitis:

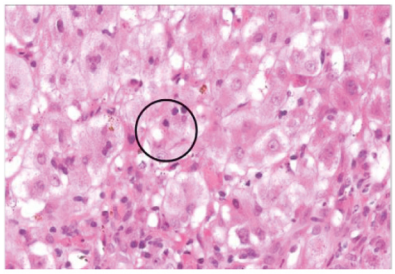

Emperipolesis

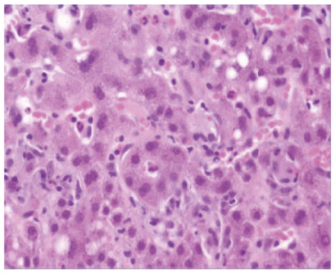

Hepatocyte Rosettes

  - Interface Hepatitis: Inflammation (lymphocytes/plasma cells) at the junction of hepatocytes and portal triads
  - Emperipolesis: Cell-in-cell phenomenon (liver cell engulfing inflammatory cells)
  - Hepatocyte Rosettes: Hepatocytes arranged in round, rose-petal clusters

ENZYME DEFICIENCY - ALPHA-1 ANTITRYPSIN DEFICIENCY

- Genetics
  - Gene: SERPINA1 on Chromosome 14
  - Inheritance: Autosomal Recessive.
- Genotypes
  - PiMM: Normal levels
  - PiZZ: Disease state

Yourwish

Yourwish

- PiMZ: Carrier state

NEET PG Aug 2024

- Clinical Presentation
  - Organs affected: Lungs (Panacinar Emphysema) and Liver (Cirrhosis).
  - Pediatric presentation: Young child ("Lal") with liver and lung involvement
- Diagnosis
  - PAS stain: PAS-positive
  - Diastase Resistant

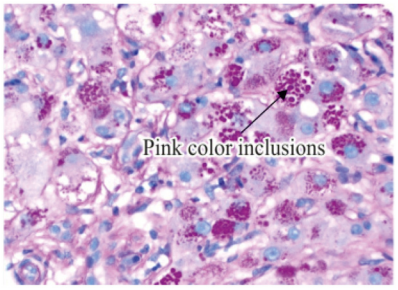

VIRAL HEPATITIS

- Chronic hepatitis B (HBV) and C (HCV) lead to cirrhosis.
- Biopsy rationale: Performed only for chronic hepatitis (B and C) to determine grade and stage
- General Viral Findings
  - Councilman bodies: Apoptotic bodies seen in viral hepatitis.
- Hepatitis B Specifics
  - Morphology: Ground-glass hepatocytes.
  - Appearance: Hazy, faint, pink cytoplasm due to accumulation of Surface Antigen (HBsAg/Australia Antigen)
  - Special stain: Orcein-Shikata stain
- Hepatitis C Specifics
  - Morphology: Fatty change (steatosis) and lymphoid aggregates

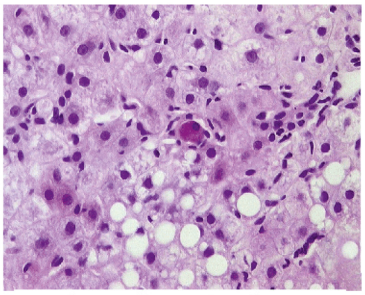

Councilman bodies

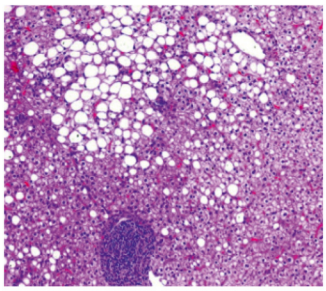

Fatty change
lymphoid aggregates

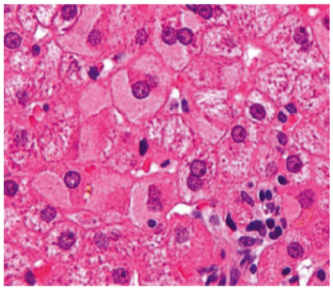

Ground-glass
hepatocytes

HEMOCHROMATOSIS (IRON OVERLOAD)

FMGE 2021, 2022, 2025

- Genetic Etiology
  - HFE gene mutation on Chromosome 6
  - Juvenile Hemochromatosis: HJV (Hemojuvelin) gene mutation
- Acquired Etiology
  - Repeated blood transfusions (e.g., Thalassemia patients).
- Clinical Presentation: "Bronze Diabetes"
  - Pancreatic involvement: Iron deposition → ↓ insulin production → Diabetes
  - Skin involvement: Hyperpigmentation (bronzing) → primarily due to increased Melanin, with a secondary contribution from Hemosiderin
- Diagnosis
  - Special stain: Perls or Prussian Blue stain
- Treatment
  - Treatment of choice: Phlebotomy

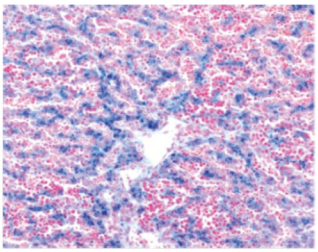

Perls/Prussian Blue

Yourwish

- Pharmacotherapy: DOC is Iron chelators (e.g., Desferrioxamine)

COPPER OVERLOAD (WILSON DISEASE)

INICET Nov 2022, FMGE June 2021
NEET PG Aug 2024

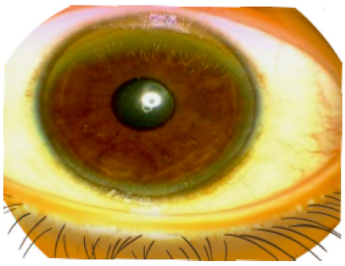

- Genetics
  - Mutation: ATP7B gene on Chromosome 13
- Clinical Findings
  - Ocular: Kayser-Fleischer (KF) rings (Copper deposition in the Desmet membrane of the cornea)
  - Neurological: Deposition in the brain (putamen, basal ganglia) → psychosis or Parkinson-like features
  - Liver cirrhosis
- Treatment
  - Copper chelators: Trientine

TUMOR HCC

00:29:10

- M/c Liver malignancy: Metastasis (M/c colorectal)

Feature	Classical HCC	Fibrolamellar HCC
Age	• ~40 years	• Young (~19 years)
Sex	• Male predominance	• Equal
Associations	• Hepatitis B • Hepatitis C • Cirrhosis	• Not related to HBV/HCV • D/t deletion of ch-19
Tumor marker	• Alpha-fetoprotein	• Neurotensin
Spread	• Hematogenous	• Lymphatic
Prognosis	• Poor	• Good

- Gross:
  - Central stellate scar
  - Also seen in FNH

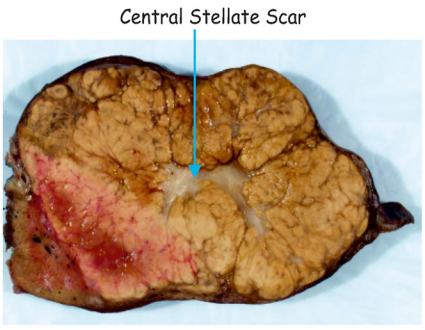

NEW TUMOR MARKERS HCC

- IHC Markers
  - HEP-PAR 1
  - ARGINASE 3
  - GLYPICAN 3

NUTMEG LIVER

- Cause: Right heart failure
- Pathology:
  - Dark areas : hemorrhagic necrosis
  - Light areas : fatty change



PYQ

00:33:09

Q What condition is associated with a 36-year-old male presenting with right upper quadrant abdominal pain, jaundice, palpably enlarged liver, elevated liver enzymes, a single large liver mass on CT, and markedly elevated serum alpha-fetoprotein?

a. Aflatoxin B1
b. C. sinensis
c. Tetracyclines
d. Polyvinyl chloride

Answer: **a**

Q Which of the following is associated with conjugated hyperbilirubinemia?

FMGE Jan 2024

a. Crigler Najjar -1 syndrome
b. Crigler Najjar -2 syndrome
c. Gilbert syndrome
d. Dubin-Johnson syndrome

Answer: **d**

Q A 35-year-old man with a history of ulcerative colitis presents with fatigue and pruritus. Laboratory investigations show a cholestatic liver function test pattern. MRCP reveals multifocal strictures and beading of intrahepatic and extrahepatic bile ducts. Liver biopsy demonstrates concentric "onion-skin" fibrosis around bile ducts. What is the most likely diagnosis?

a. Primary biliary cholangitis
b. Primary sclerosing cholangitis
c. Autoimmune hepatitis
d. Secondary biliary cirrhosis

Answer: **b**

Q A patient presents with respiratory distress and is diagnosed with pan-acinar emphysema. Which deficiency is responsible for his condition?

a. Type 1 surfactant
b. Type 2 surfactant
c. Alpha-1 antitrypsin deficiency
d. Albumin

Answer: **c**

Q What is the composition of the characteristic finding observed in the liver biopsy of a 45-year-old man with chronic alcohol abuse, presenting with abdominal pain, jaundice, malaise, elevated liver enzymes, centrilobular necrosis, and neutrophilic infiltration?

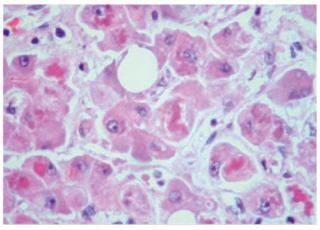

a. CK 4
b. CK 5/6
c. CK 7
d. CK 8/18

Answer: **d**

Yourwish

15. RENAL PATHOLOGY

NORMAL KIDNEY & GLOMERULUS

00:00:29

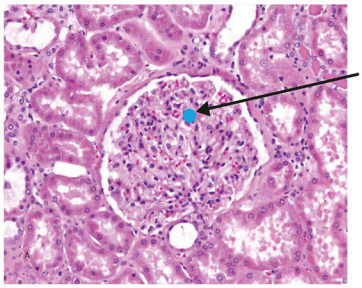

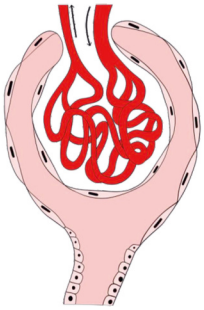

Filtration membrane

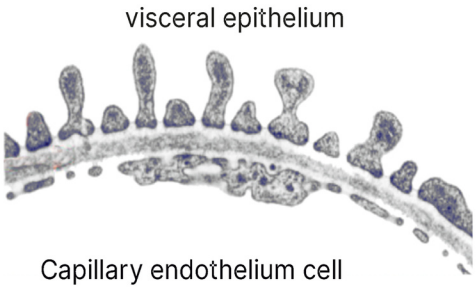

- Glomerulus consists of capillaries lined by endothelial cells.
- Electron Microscopic view of the glomerulus.
  - Inside → capillary endothelial cells,
  - Outside → visceral epithelium of Bowman's capsule (foot processes/podocytes)
  - Connecting them is the glomerular basement membrane (GBM).
    → GBM contains collagen type 4.
- Filtration occurs through a trilaminar membrane.
- Mesangium is located in the middle of the kidney.
  - Contains mesangial cells → Macrophages of the kidney.
  - Serves as the first site for amyloid deposition in the kidney.

RENAL SPOTTERS MACROSCOPIC PATHOLOGY

00:02:29

PUTTY KIDNEY

- Seen in Tuberculosis
- Shows caseous necrosis → Cheesy appearance.
- Radiograph/gross image showing a calcified mass on top of necrosis.
- Clinical history → Sterile pyuria
  - Pus cells present
  - The urine culture is negative

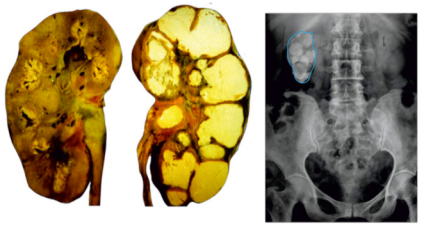

Caseous Necrosis

Waxy Kidney

- Surface looks like candle wax
- Seen in amyloidosis.
- Clinically present as nephrotic syndrome



Leather Grain Kidney

- Surface looks very granular, like sand particles
- Seen in benign hypertension



Yourwish

Yourwish

Flea Bitten Kidney



- Surface shows dark spots resembling insect bites.
  - Represents pinpoint hemorrhages.
- Seen in: (Mnemonic: We Hate PSM)
  - W → Wegener's granulomatosis.
  - H → Henoch-Schonlein purpura, Hemolytic uremic syndrome.
  - P → Polyarteritis nodosa, PSGN (shows cola-colored urine).
  - S → SLE, Subacute bacterial endocarditis.
  - M → Malignant hypertension.

Chronic Pyelonephritis (Cpn)

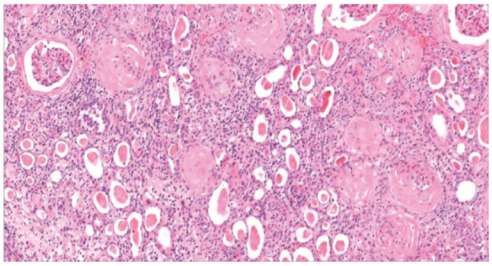

- Chronic inflammation of the tubules.
- Arises from M/c urinary tract infection → E. coli.
- Microscopic view
  - Tubules filled with pink material.
  - Appearance resembles thyroid colloid → Thyroidization of tubules
- Only glomerular finding → Periglomerular fibrosis.

Malacoplakia

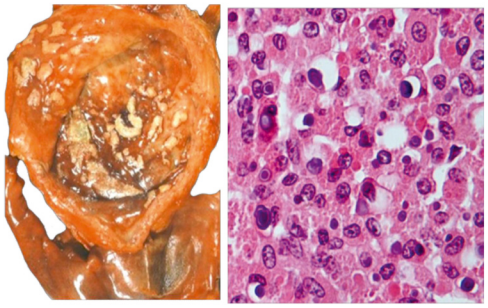

- Caused by a defect in phagocytosis
- Cystoscopy showing yellow mucosal plaques in the urinary bladder
  - Mimics malignancy → Requires biopsy to confirm.
- Body deposits calcium around bacteria → Michaelis-Guttmann bodies
- Entire macrophage containing these bodies → Von Hansmann cell

POLYCYSTIC KIDNEY DISEASE (PKD)

FMGE June 2021
NEET PG 2022

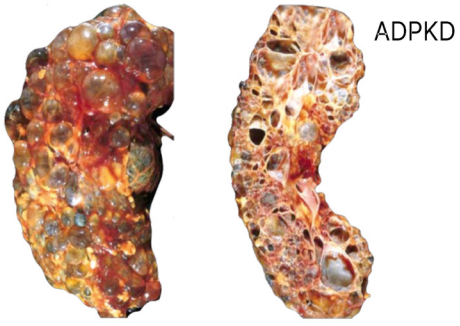

ADPKD

ARPKD



AUTOSOMAL DOMINANT PKD (ADPKD)	AUTOSOMAL RECESSIVE PKD (ARPKD)
• Involves chromosomes 16 and 4 • Defect in PKD gene → Polycystin protein. • Clinical presentation M/c in boys → Hypertension and hematuria • Cysts present in kidney, pancreas, liver, and intestine (colonic diverticula)	• Involves chromosome 6. • Defect in PKHD gene → Fibrocystin protein. • Associated with congenital hepatic fibrosis.

Yourwish

- Fatal complications → Heart (aortic aneurysms, dissections) and brain.
- Gross specimen of the kidney:
  - Shows cysts on both the outer and inner surfaces.

- Gross specimen of the kidney:
  - Outer surface is normal/flat → Cysts are present only on the inner surface.

URINARY CAST AND CRYSTALS

00:10:18

Urinary Crystals

NEET PG Aug 2024
FMGE Dec 2021

Cystine



Hexagonal

Tyrosine

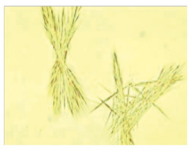

Thin Needles

Bilirubin

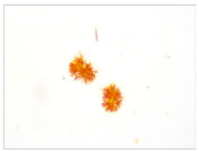

PIGM
Thin Needle

Ammonium Biurate
Apple Thorn

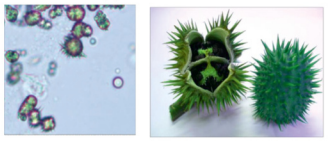

H/O Laxative abuse

Leucine



Lamellated

Cholesterol



Broken chips



Triple PD4/ Struvite
Coffin Lid

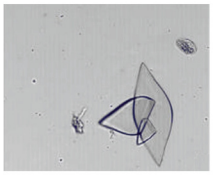

Uric Acid
Rhomboid

Calcium Oxalate
hydrate

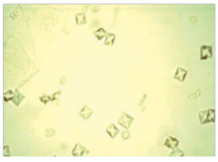

Envelope
shape

Calcium
Oxalate hydrate

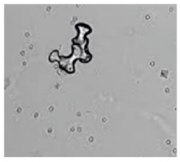

Dumbbell
shape

Calcium
Carbonate

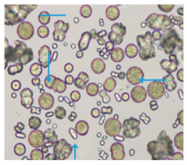

Round

CRYSTAL TYPE	APPEARANCE / FEATURES
Cystine Crystals	• 6-sided (hexagonal) shape
Tyrosine Crystals	• Thin needle-like
Bilirubin Crystals	• Thin pigmented needles
Ammonium Biurate Crystals	• Apple thorn appearance (spiky); • Associated with laxative abuse
Leucine Crystals	• Laminated appearance (resembles tree bark or parasitoid egg)
Cholesterol Crystals	• Broken chip appearance
Triple Phosphate Crystals (Struvite)	• Coffin-lid appearance; • Forms in alkaline pH due to Proteus → may lead to staghorn calculus
Uric acid crystals	• Variable shapes (triangle, diamond, rhomboid); • Seen in gout
Calcium carbonate crystals	• Round shape (resembles car wheels)
Calcium oxalate crystals	• Monohydrate: Dumbbell shaped ("mona is dumb") • Dihydrate: Envelope-shaped

Urine Casts

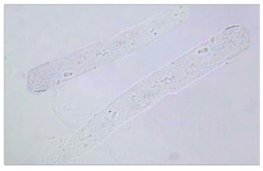

Hyaline Cast

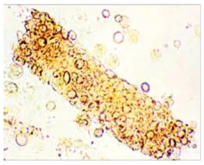

RBC cast

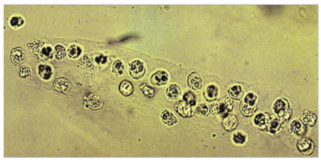

WBC cast

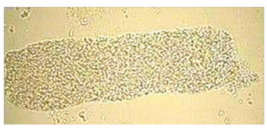

Granular cast

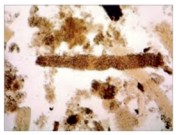

Muddy Brown Cast

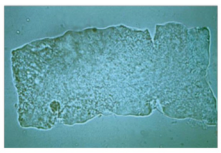

Broad waxy Cast

Cast Type	Composition / Description	Clinical Significance
Hyaline Cast	Transparent cylindrical structures made of Tamm-Horsfall protein (Loop of Henle)	Normal finding; seen in dehydration
RBC Cast	Red blood cells embedded in hyaline cast	Indicates Glomerulonephritis
WBC Cast	White blood cells in hyaline cast	Indicates Pyelonephritis
Eosinophil Cast	Eosinophils in hyaline cast	Indicates Interstitial Nephritis
Granular Cast	Degenerated cellular debris on hyaline cast	Non-specific kidney pathology (needs fresh sample)
Muddy Brown Cast	Brown cast due to necrotic tubular cells	• Indicates Acute Tubular Necrosis (ATN); • Seen in ethylene glycol poisoning (Antifreeze)
Broad Waxy Cast	Very broad, waxy, rigid cast	Indicates Chronic Renal Failure

NEPHROTIC VS NEPHRITIC SYNDROME

00:16:56

NEPHROTIC SYNDROME	NEPHRITIC SYNDROME

• Massive loss of protein and fat in urine.
  ○ Urine appearance → Frothy/bubbly urine.
  ○ Massive proteinuria → >3.5 grams/24 hrs urine→ Hypoalbuminemia.
• M/c cause of edema → Salt and water retention > Hypoalbuminemia.
• Loss of Antithrombin III → Causes thrombotic events
	• Mild loss of protein in urine.
	  ○ Mild proteinuria → < 1 gram/24 hrs urine
	• Urine appearance → Cola-colored urine.
	• Hypertension
	• Oliguria → < 400 ml/day.
	• Hematuria → > 3 RBCs per high power field.
	• Azotemia → ↑ Blood urea nitrogen

	

Yourwish

Nephritic Syndromes

Post-streptococcal Glomerulonephritis (PSGN)

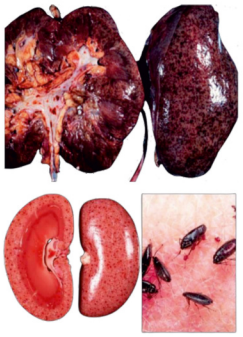
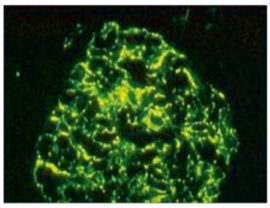
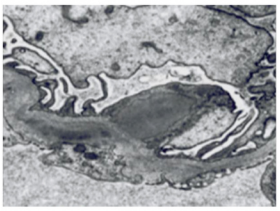

- M/c nephritic syndrome in the pediatric age group.
- Caused by Group A beta-hemolytic streptococcus (Streptococcus pyogenes).
  - Also known as Acute Proliferative Glomerulonephritis (APGN).
- Type 3 hypersensitivity reaction.
- Clinical presentation → Sore throat followed by cola-colored urine after 10 to 14 days.
- Blood findings → Transient hypocomplementemia (↓ C3 levels for a few weeks).
- Light microscopy → Hypercellular glomerulus.
- Electron microscope → Subepithelial humps
  - Immune complex deposits below podocytes
- Immunofluorescence → Starry sky appearance.
- Gross appearance: Fleabitten kidney
- Treatment → Supportive management (resolves within 6 weeks).

IgA NEPHROPATHY (BERGER'S DISEASE)

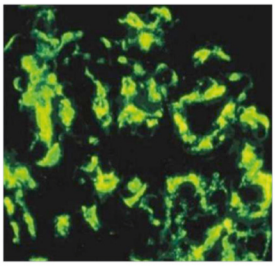

- M/c nephritic syndrome in adults and M/c worldwide.
- Clinical presentation → Sore throat followed by cola-colored urine within 2 to 3 days.
- Immunofluorescence: IgA1 deposits in the mesangium (capillary loops are black/normal)

RAPIDLY PROGRESSIVE GLOMERULONEPHRITIS (RPGN)

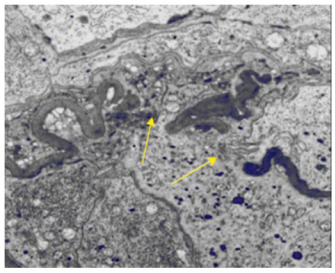
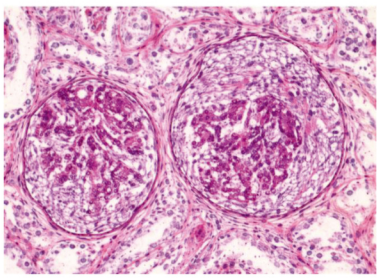

- Aka Crescentic Glomerulonephritis.
- Crescent acts as a flap made of → Fibrin, leukocytes, parietal and visceral bowman's capsule (Parietal > visceral)
- Prognosis: ↑ Crescents indicate a worse patient prognosis.
- Electron microscope: Rupture and wrinkling of the basement membrane

RPGN TYPE 1 (GOODPASTURE SYNDROME)

INICET May 2023

- Type 2 hypersensitivity reaction (anti-GBM antibodies).
- Antibodies target alpha-3 chain of Type 4 collagen.

Yourwish

Yourwish

- Affects lungs → Hemoptysis.
- Affects kidney → Hematuria.
- Immunofluorescence image: Straight linear pattern

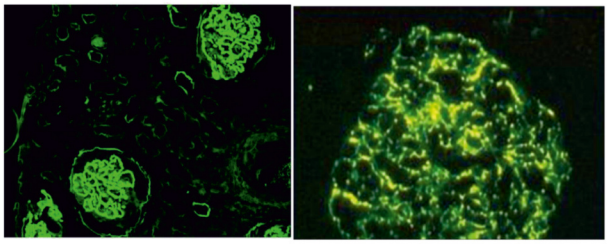

RPGN TYPE 2

- Caused by pre-existing antigen-antibody complexes (e.g., IgA, PSGN, SLE, HSP).
- Immunofluorescence: Lumpy, bumpy, granular, starry sky pattern

RPGN TYPE 3 (PAUCI-IMMUNE)

- Lacks immune complexes.
- Negative on immunofluorescence.
- Associated with ANCA vasculitis → Wegener's granulomatosis and Microscopic polyangiitis

Basement Membrane Chain Disorders

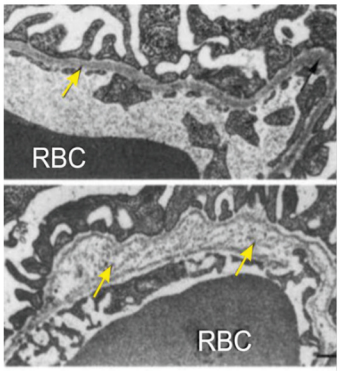

- Alpha-3 chain defect → Goodpasture syndrome.
- Alpha-4 chain defect → Thin basement membrane disease (Benign familial hematuria).
- Alpha-5 chain defect → Alport syndrome.
  - M/c inheritance of Alport syndrome → X-linked dominant (XLD).
  - Electron microscope: Basket weave appearance of the basement membrane
  - Extra-renal features → Sensorineural hearing loss (2nd M/c affected organ) and anterior lenticonus.

Nephrotic Syndromes

Minimal Change Disease (MCD)

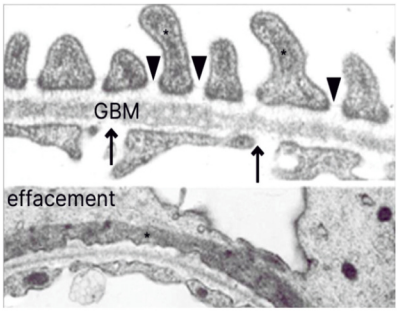

- M/c nephrotic syndrome in children.
- Associated with Hodgkin's lymphoma and atopy (due to cytokine release).
- Shows selective proteinuria → Loss of albumin only.
- Treatment → Excellent response to steroids.
- Light microscopy → Normal glomerulus.
- Tubules show lipid accumulation → Lipoid nephrosis.
- Immunofluorescence → Nil deposit disease.
- Electron microscope → Effacement (loss) of foot processes (Gold standard)

FOCAL SEGMENTAL GLOMERULOSCLEROSIS (FSGS)

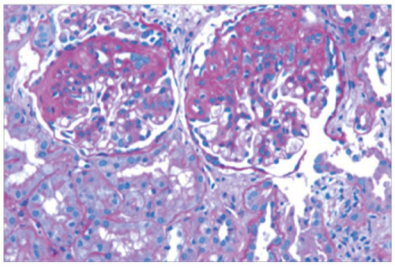

- M/c nephrotic syndrome in adults.
  - Focal → Few glomeruli affected.
  - Segmental → Only a part of the glomerulus shows pink sclerosis.
- Causes → (Mnemonic: HHHRRS)
  - HIV, Hepatitis B, Hypertension, Heroin abuse, Reflux nephropathy, Renal tissue loss, Sickle cell anemia.
- HIV associated nephropathy → HIVAN.

Yourwish

- Colombian classification:
  → M/c type → Not otherwise specified.
  → Best prognosis → Glomerular tip type.
  → Worst prognosis → Collapsing type (seen in HIVAN/HIV).

Membranous Glomerulonephropathy (MGN)

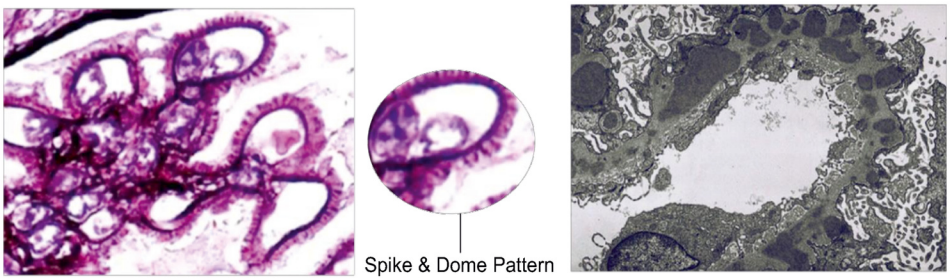

- M/c nephrotic syndrome in the elderly and in cancer patients.
- Primary MGN:
  - M/c caused by antibodies against Phospholipase A2 Receptors
  - Emerging antibodies → Thrombospondin and CD10.
- Electron microscope image → Shows spike and dome appearance.
  - Immune complex forms the dome (subepithelial deposit).
  - Basement membrane fights back and forms the spike.
- Causes of Secondary MGN:
  - Drugs→ NSAIDs, gold, penicillamine.
  - Cancers → Lung, melanoma, colon.
  - Infections → Hepatitis B, Hepatitis C, Schistosoma, Syphilis.

MEMBRANOPROLIFERATIVE GLOMERULONEPHRITIS (MPGN)

MPGN TYPE 1

- Associated with Hepatitis B and C.
- Electron microscope → Tram track appearance (splitting of basement membrane).
  - Shows subendothelial deposits.
- Displays persistent hypocomplementemia.

MPGN TYPE 2 (DENSE DEPOSIT DISEASE)

- Caused by C3 nephritic factor (C3NeF) in the blood.
- Electron microscope → Intramembranous basement membrane deposits as a dense black line.
  - Shows intramembranous deposits.

LUPUS NEPHRITIS (SLE)

00:43:54

- Comprises 6 classes.
- Light microscopy → Wire loop lesions.
  - Represents subendothelial deposits.
- Seen in classes 3, 4, and 5 (maximum in class 4).
- Immunofluorescence → Full house effect (all antibodies/complements deposited).
- Electron microscope → Thumbprint appearance.

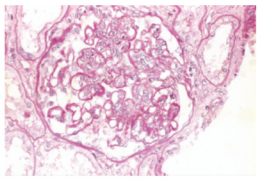

Wire loop lesions
(Subendothelial)

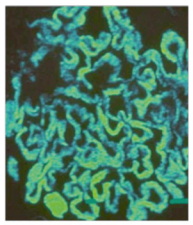

Full house

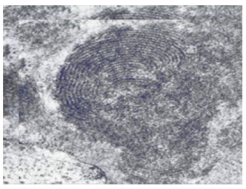

Thumb print

Summary of Deposits

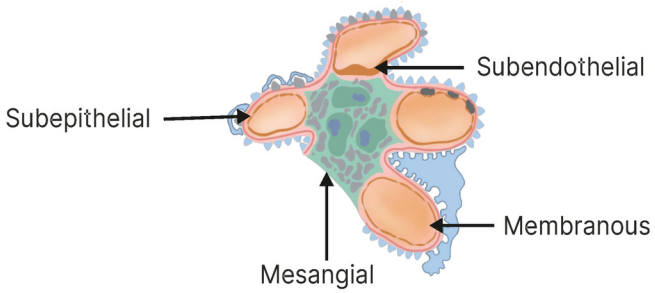

Location of Deposit	Associated Disease(s)	Characteristic Feature
Mesangium	Berger's disease (IgA nephropathy)	IgA1 deposition in mesangium
Subepithelial	Post-streptococcal glomerulonephritis (PSGN)	"Hump"-like deposits
	Membranous glomerulonephritis (MGN)	"Dome" appearance
Intramembranous	MPGN Type 2 (Dense deposit disease)	Dense deposits within GBM
Subendothelial	MPGN Type 1	"Tram-track" appearance
	Systemic lupus erythematosus (SLE)	"Wire loop" lesions

DIABETIC NEPHROPATHY

00:46:30

- Clinical history → Uncontrolled HbA1c
- Blood vessels → Hyaline arteriolosclerosis.
- Tubules (PCT) → Glycogen deposition known as Armani-Ebstein lesion
- Glomerulus
  - M/c finding → Diffuse glomerulosclerosis (entire glomerulus turns pink).
  - Most characteristic finding → Nodular glomerulosclerosis (Kimmelstiel-Wilson / KW lesion).
- Special stain for glycogen and KW lesions → PAS positive (diastase sensitive)

Nodular Glomerulosclerosis
Most characteristic lesion

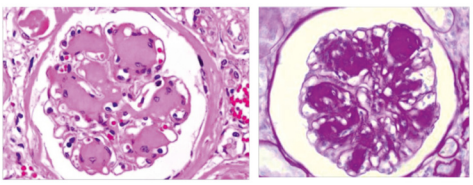

KW Lesion / Kimmelstiel Wilson

RENAL TUMORS

- Benign → Oncocytoma
- Malignant → Wilms (Children), RCC (Adults)
  - Wilms: Abdominal mass + hematuria + Fever



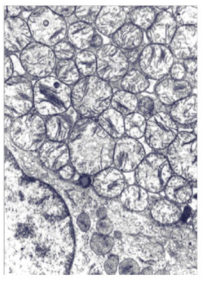

Yourwish

- RCC: Abdominal mass + hematuria + Abdominal pain.

Oncocytoma

- Benign tumor.
- Gross: Mahogany brown color with a central stellate scar
- Microscopic: Oncocytic cells with abundant mitochondria

Important Information

- Differential diagnosis of Central stellate scar:
  - Oncocytoma
  - Chromophobe RCC,
  - Focal nodular hyperplasia (liver),
  - Fibrolamellar carcinoma (liver),
  - Serous cystadenocarcinoma (pancreas),
  - Radial scar (breast)

RENAL CELL CARCINOMA

CLEAR CELL RCC

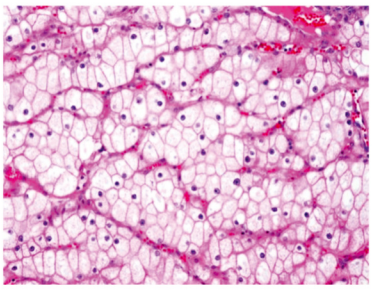

- M/c RCC.
- Cells look clear due to lipid and glycogen accumulation.
- Associated with VHL syndrome
  - Chromosome 3 / 3p deletion

PAPILLARY RCC

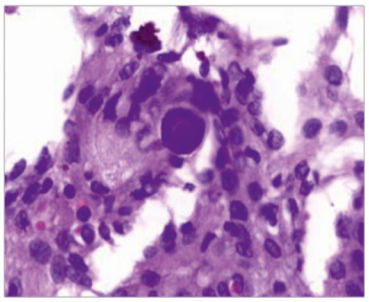

- Shows Psammoma bodies
- Associated with dialysis.
- Caused by:
  - Loss of Y chromosome
  - Trisomy 7 (MET gene)
  - Trisomy 17.
- HLRCC syndrome (Hereditary leiomyomatosis) - Due to Fumarate Hydratase (FH) gene mutation

MEDULLARY RCC

- Associated with sickle cell trait

BELLINI DUCT RCC

- Collecting duct RCC
- Worst prognosis among all RCC types
- Microscopic finding → Hobnail cells

CHROMOPHOBE RCC

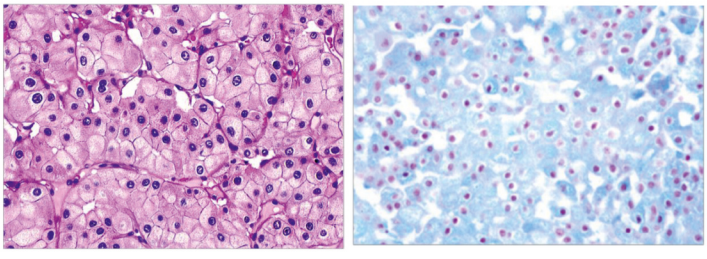

- Best prognosis among malignant tumors.
- Shows multiple chromosomal losses.
- Associated with Birt-Hogg-Dube syndrome.

Yourwish

Yourwish

- Microscopic → Plant cells
  - Raisanoid nucleus with perinuclear halo
- Stain → Hale's colloidal iron positive.

PEDIATRIC RCC

- Due to TFE3 gene mutation on chromosome Xp11

Wilms Tumor (Nephroblastoma)

INICET May 2024

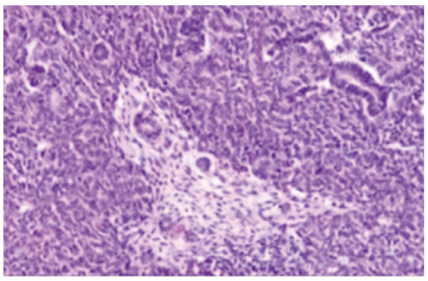

- M/c in children.
- Caused by WT1 and WT2 gene mutations.
- Microscopic finding → Triphasic tumor.
  - Epithelial (tubules)
  - Mesenchymal (stroma)
  - Blastemal (blue cells)
- Cancerous changes/anaplasia → Indicates p53 gene mutation→ Results in poor response to chemotherapy.

MCQs

00:55:40

Q. A young patient presents to the outpatient department (OPD) with recurrent colicky abdominal pain. Urine examination reveals the presence of red blood cells (RBCs). What is the most likely diagnosis?

NEET PG August 2024

a. Glomerulonephritis
b. Oxalate stone
c. Polycystic kidney disease
d. Cystine stone

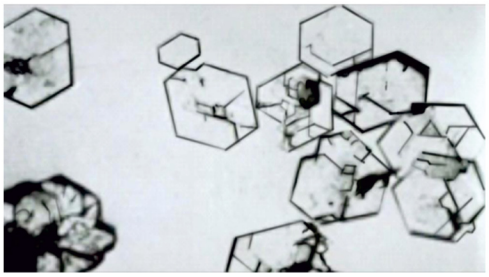

Answer: **d**

Q. A 47-year-old male with 400 ml urine output per 24 hrs. On histology, he had RPGN with pauci-immune glomerulonephritis with crescents. What is the main etiology?

INICET May 2023

a. Anti-GBM
b. ANCA
c. Anti-PLA2R
d. ANA

Answer: **b**

Q. A 10-year-old presents with edema and anasarca. A diagnosis of minimal change disease is made. Which of the following is true about this condition?

NEET PG 2022

a. Light microscopy shows effacement of podocytes
b. Good response to steroids
c. Most common in adults
d. Non-selective proteinuria

Answer: **b**

Yourwish

12. FEMALE AND MALE GENITAL SYSTEMS

FEMALE GENITAL SYSTEM

00:00:03

Cervix

FMGE Jan 2024
INI CET 2021

PAP Smear



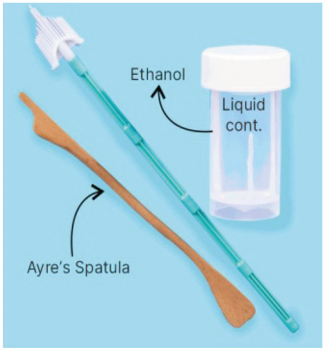

- Pap smear was invented by George Papanicocolau
- 2 types
  - Conventional PAP
  - Liquid based cytology
- Conventional PAP smear

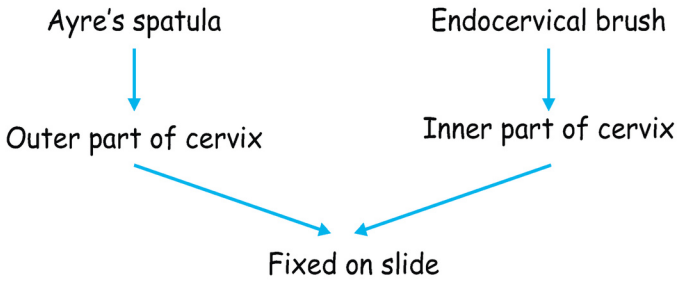





- Liquid based cytology
  - Sample taken from cervix transferred to liquid media
  - Automation done with the help of machine
  - Two types LBC machine

Sure path	Thin prep
• Smaller circle of 13 mm 	• Larger circle of 20 mm 
Mucus and hemorrhage is been removed in LBC	

- Fixative → 95% ethanol
- Stain → PAP stain
  - Hematoxylin
  - Orange green 6
  - EA 50 (Eosin Azure) → Eosin , light green , Bismarck brown

- Adequacy criteria → Bethesda system reporting
  - Conventional PAP
    → Ectocervical cells → 8000-12000 / 10hpf
    → Endocervical cells → ≥10cells
  - LBC
    → Ectocervical cells → ≥5000 / 10hpf
    → Endocervical cells → ≥10cells
- Appearance of ectocervical cells
  - Superficial cells → Pink pyknotic
  - Intermediate cells → Blue
  - Parabasal cells → Round cluster

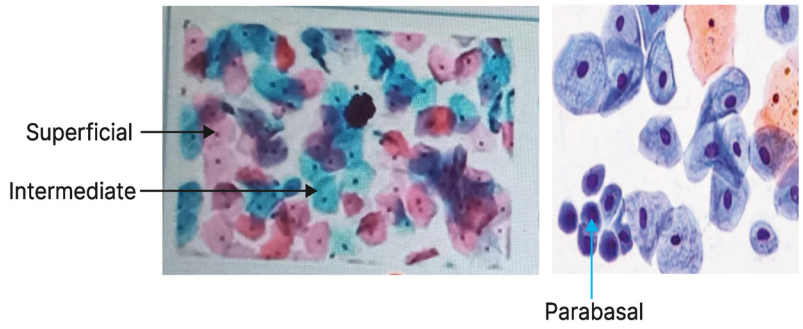

- Appearance of endocervical cells
  - Long elongated cells
  - Honey comb appearance / Butterfly on fence appearance



- Maturation index
  - Proportion of Parabasal , Intermediate and superficial cells
  - Presence of superficial cells → indicate estrogen predominance
  - Presence of intermediate cells → indicate progesterone predominance
  - Presence of parabasal cells → seen in Post menopausal female
- Interpretation of Maturation index
  - P/I/S - 0/10/90 → indicate estrogen predominance
  - P/I/S - 0/90/10 → indicate progesterone predominance
  - P/I/S - 90/10/0 → seen in Post menopausal female

- Appearance of Endometrial cell
  - Sample taken during Day 1 to Day 5 → appears as 3D ball clusters
  - Sample taken during Day 6 to Day 10 → Shedding of endometrium appears as Exodus

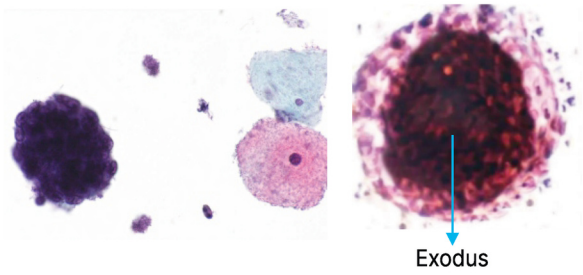

Infections

Infections	Features

Trichomonas vaginalis	• Greenish discharge
	• Gross appearance → strawberry cervix
	• Trichomonas grows along with Leptothrix
	• Microscopy → Spaghetti & meatball appearance
	  ○ Spaghetti → Leptothrix (appears as long thread)
	  ○ Meatball → Tichomonas (appears as pear shaped organism)

Yourwish


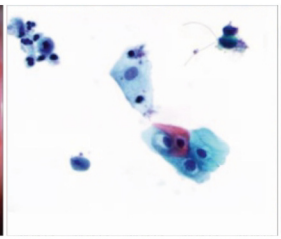
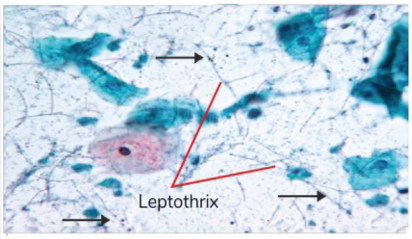

Candida albicans

- Curdy white discharge
- Microscopy → Sheesh kebab appearance

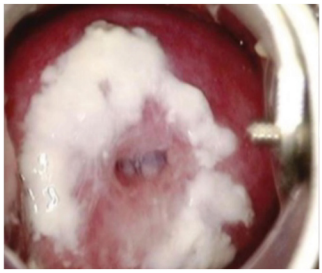
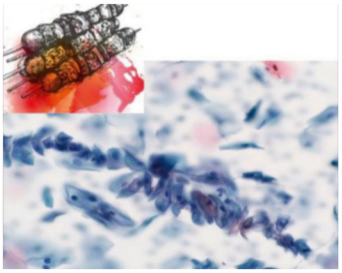

Bacterial vaginosis

- Caused by Gardenerella vaginalis
- Organisms grows on both background and cells
- Amsel's criteria
  - Filmy background
  - Clue cells → Cocco-bacilli on cell
- Nugent's criteria

FMGE June 2021
INI CET Nov 2023

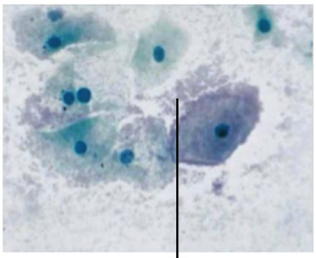
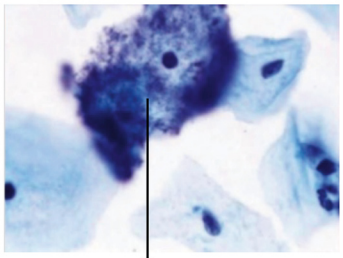

Actinomyces

- H/O IUCD insertion
- Microscopy
  - Sunray
  - Cotton ball / wooly ball
  - Dust bunnies
  - Gupta bodies

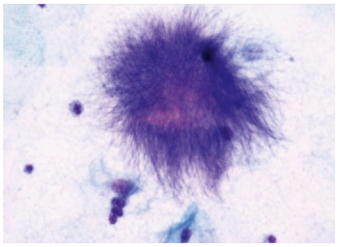

Human papilloma virus

- Microscopy
  - Koilocye → Raisanoid nucleus and Perinuclear halo

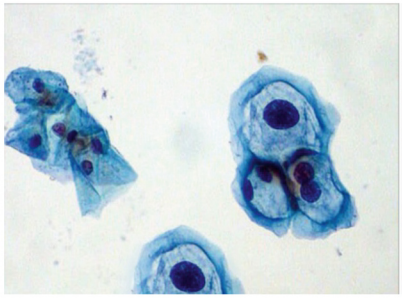
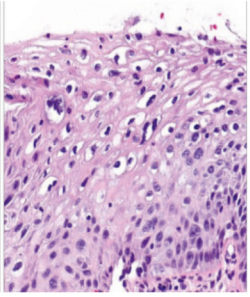

Yourwish

Yourwish

Herpes simplex virus	• Microscopy ○ Multinucleation , Moulding, Margination

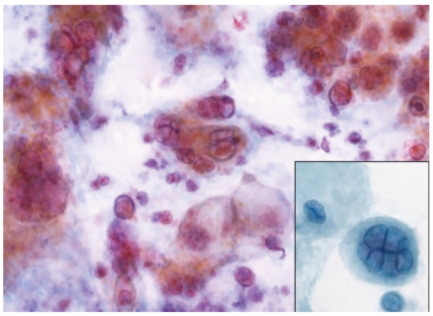

Important Information

- Spaghetti & meatball appearance → Malassezia furfur
- Plant cell → Raisanoid nucleus and Perinuclear halo - seen in Chromophobe variety of RCC

Carcinoma

- Squamous cell carcinoma
  - Cells appears like Tadpole

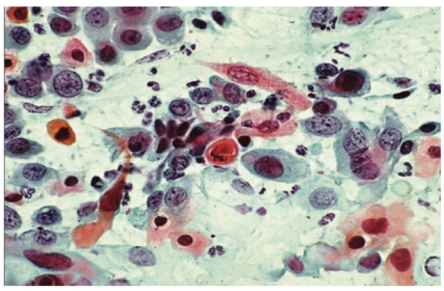

Uterus

Endometriosis

- Endometrial glands & stroma are present outside the uterus

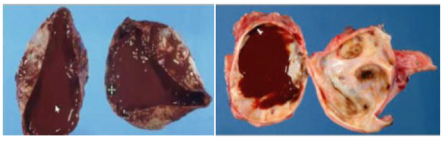

- Location
  - Ovary - MC site
  - Broad ligament
  - Colon
  - Lungs
- Gross
  - Chocolate cyst → Shedding of endometrial glands and stroma
- Microscopy
  - Presence of endometrial glands & stroma
  - Hemosiderin deposition

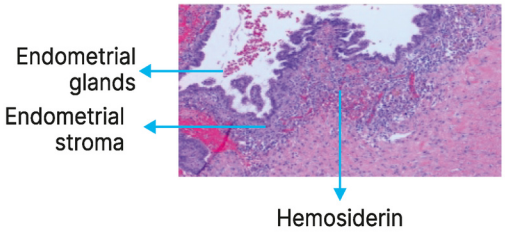

Adenomyosis

- Endometrial glands & stroma in myometrium, >2.5 mm away from endomyometrial junction

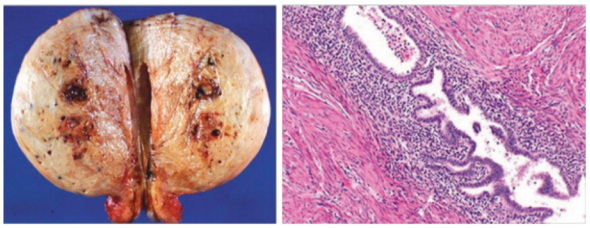

FMGE Jan 2025

Leiomyoma

- A/k/a Fibroid
- Benign tumor of smooth muscle
- Occurs due to MED 12 mutation
- Conditions associated with MED 12 mutation

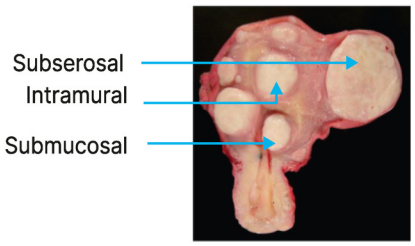

Yourwish

- Fibroids
- Fibroadenoma
- Phyllodes

- Types
  - Submucosal→ Inside the uterine cavity, max risk of bleeding
  - Intramural→ Inside the muscle
  - Subserosal→ Below serosa
- Microscopy
  - Whorling pattern
  - Cigar nuclei

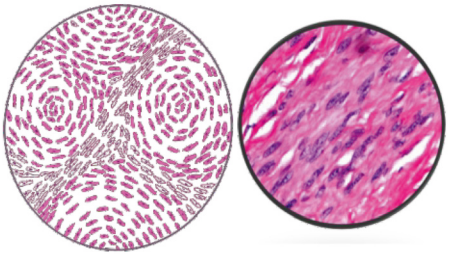

- Degeneration
  - Red degeneration
    - → Beefy red
    - → Pain, increased ESR and TLC
    - → A/w pregnancy
  - Hyaline degeneration
  - Calcific degeneration

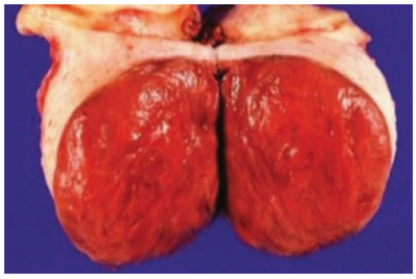

Leiomyosarcoma

- Malignant transformation of Leiomyoma
- Presence of mitosis is the most important criteria → ≥10 /10hpf
  - ≥10 /10hpf seen in condition like Leiomyosarcoma & Malignant phyllodes
- Cigar nuclei
  - Cigar nuclei seen in condition like normal smooth muscle, Leiomyoma, Leiomyosarcoma

Ovary

Ovarian Tumors

- Surface epithelial tumor
  - Arise from epithelial cells
- Germ cell tumor
  - Arise from germ cells
- Sex cord stromal tumor
  - Arise from sex cord stromal cells

INICET 2021, 2025

Surface epithelial tumor			
Tumors	**Gross**	**Microscopy**	**Tumor marker**
Serous ovarian tumor	• Uniloculated cyst • Watery fluid 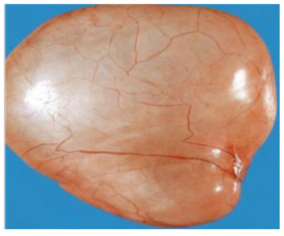	• Ciliated epithelium • Psammoma bodies 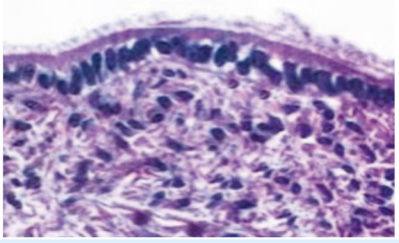	CA 125

Mucinous ovarian tumor	• Multiloculated cyst • Mucinous fluid 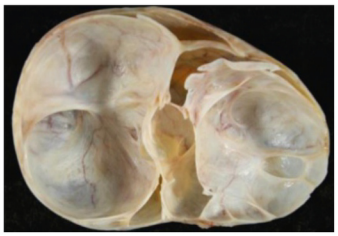	• Mucinous epithelium 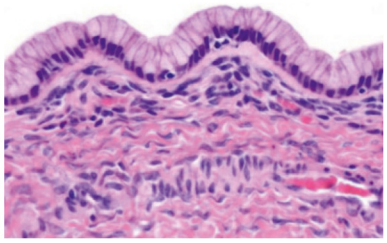	
Brenner tumor		• Bladder / transitional epithelium • Coffee bean nuclei	
Clear cell tumor	a/w Diethylstillbesterol		
Endometrioid tumor	a/w endometriosis		
Germ cell tumor			
Tumors	**Gross**	**Microscopy**	**Tumor markers**
Dysgerminoma	• Cut potato	• Fried egg with Lympho-plasmacytic infiltrate 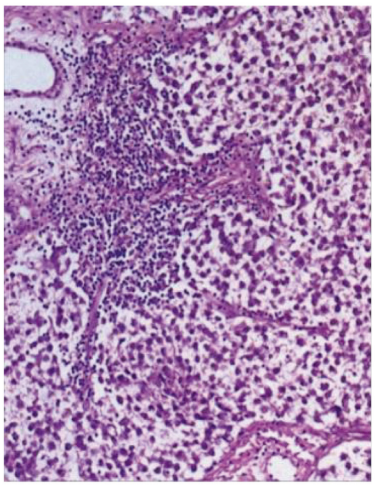	LDH, PLAP, CD117, D240, OCT 3/4, SALL 4, NANO G, HCG (30%)
Yolk sac / Endodermal sinus tumor		• Schiller duval bodies / Glomeruloid bodies ○ Blood vessels surrounded by 2 layers of tumor cells 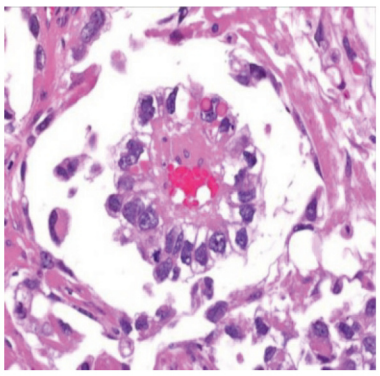	AFP, Alpha 1 anti-trypsin

Yourwish

Choriocarcinoma	• Hemorrhage & necrosis 	• Cytotrophoblast, syncytiotrophoblast, no villi 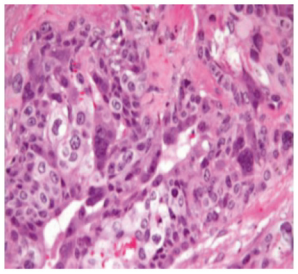	HCG

Teratoma ≥2 germ cell layer	• Hair, teeth, bone
	 
		• Mature cystic teratoma → Benign tumor
		• Immature cystic teratoma → Malignant tumor
		  ○ Site - Rokitansky protuberance
		• Monodermal teratoma/ Struma ovarri
		  ○ Presence of thyroid gland tissue
		  ○ Functional tumor leads to hyperthyroidism
		 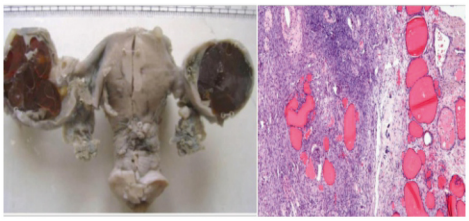	

Sex cord stromal tumors			
Tumors	**Feature**	**Microscopy**	**Tumor markers**
Sertoli cell / Leydig cell / Sertoli-Leydig cell	• Masculinisation	• Leydig cells → Reinke's crystalloids 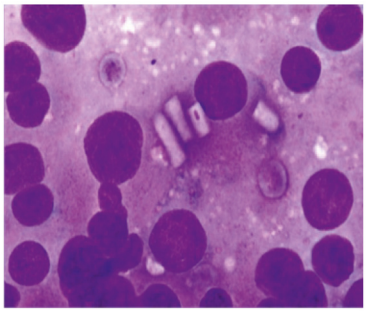	Inhibin
Fibroma	• Meig's syndrome→Right hydrothorax, Ascites, Fibroma • Gorlin syndrome→ Desmoplastic medulloblastoma, BCC, Bilateral fibroma	Vimentin	

Yourwish

Yourwish

Thecoma		Oil red O	
Granulosa cell tumor	• FOXL2 gene mutation • Seen in postmenopausal women • A/w hyperestrogenism and bleeding P/V	• Call exner bodies • Coffee bean nuclei 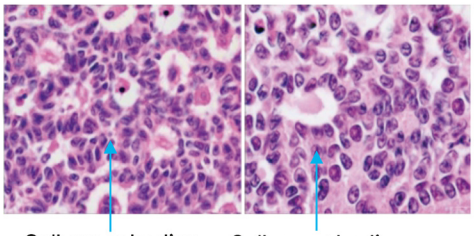 Call exner bodies Call exner bodies	Inhibin CD 99

Important Information

- Ewing's sarcoma: CD 99/ Mic 2 Positive
- Metastatic-Krukenberg Tumor
  - Metastatic tumor to the ovary
  - Metastasis occurs from stomach (MC site) , breast , colon
  - Microscopy
    → Deposition of mucin and nucleus pushed to periphery → Signet ring cells

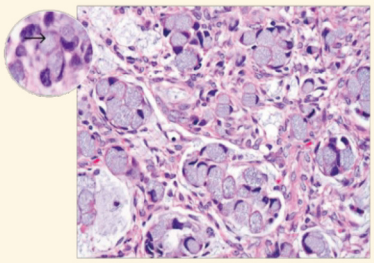

Gestational Trophoblastic Disease

Hydatidiform Mole

- Partial mole
  - Fetal parts are present
  - IHC = p57 positive
- Complete mole
  - Fetal parts are absent
  - IHC = p57 negative
- Gross → Grape like vesicles
- Microscopy → Hydropic villi

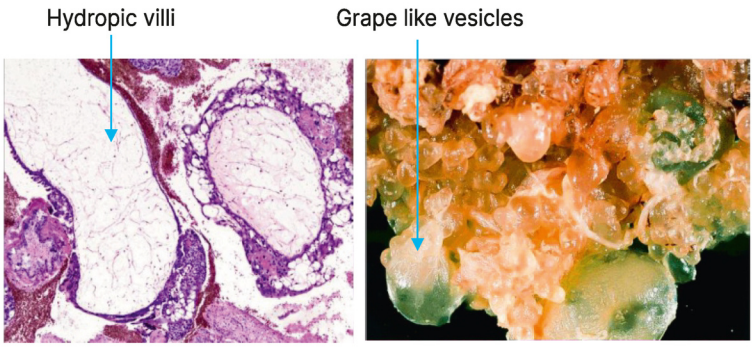

PYQ

00:35:53

INI CET Nov 2021

Q. What fixative is used for a pap smear?

a. Formalin
b. Air dried
c. Normal saline
d. 95% ethanol

Ans: **d. 95% ethanol**

Q. A pap smear taken from a patient revealed hyperchromatic nuclei, irregular nuclear borders, and a low maturation index involving the whole thickness but did not breach the basement membrane. What is the diagnosis?

a. Dysplasia
b. Carcinoma
c. Metaplasia
d. Hyperplasia

Ans: **a. Dysplasia**

Q. What are clue cells? INI CET Nov 2023

a. Vaginal epithelial cells lined by bacteria
b. Cervical epithelial cells lined by bacteria
c. Uterine endothelial cells lined by bacteria
d. Abdominal cells lined by bacteria

Ans: b. Cervical epithelial cells lined by bacteria

MALE GENITAL SYSTEM

00:37:10

Cryptorchidism

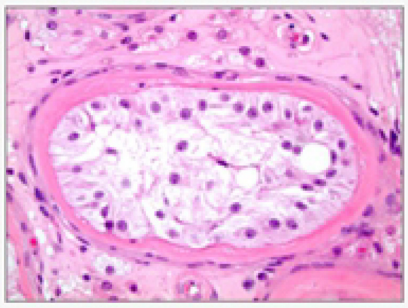

- Failure of the testis to descent
- MC site of arrest → Inguinal canal
- Risk of cancer is increased
- Rx
  - Orchiopexy (Risk of cancer decreases)b
- Microscopy
  - Absent spermatogenesis, Sertoli cells are present
  - Thickened basement membrane
  - Leydig cells: Appear hyperplastic (due to prominence), but true hyperplasia is not present

Testicular Tumor

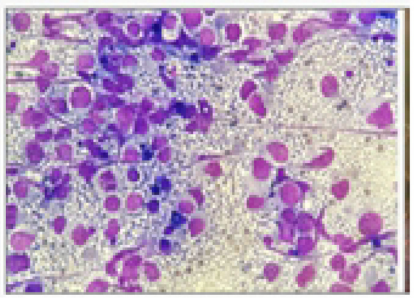

- Associate with i12P, Klinefelter syndrome
- Precursor for testicular tumor → Germ cell neoplasia in situ
  - Except Teratoma and Spermatocytic seminoma
- FNAC and Truecut biopsy from testes is C/I
- FNAC from lymph nodes is done
  - Tigroid appearance

Classification of Testicular Tumor

- Germ cell tumors
  - Seminomatous tumor
  - Non-seminomatous tumors
    - → Yolk sac tumor
    - → Choriocarcinoma
    - → Teratoma
    - → Embryonal carcinoma → CD30+
- Non germ cell tumors
  - Sex cord stromal tumors
- Lymphoma
  - Above 60 years
  - B/L testis involvement
  - Bad prognosis
  - M/c -DLBCL

Spermatocytic Seminoma

- Above 65 years
- Gain of chromosome 9
- Excellent prognosis
- Microscopically
  - Small cells
  - Medium cells
  - Large multinucleate cells

Q. A surgeon suspecting testicular carcinoma in a patient asks the intern to send the sample for histopathology. What is the fluid in which the intern should send the sample to the pathologist?

a. Bovine solution
b. 10% formalin
c. 95% ethanol
d. Alcohol

Ans: b. 10% formalin

- 10% neutral buffer formalin is used for testicular tumors
- Bouin solution containing picric acid is used for assessment of sperms in case of infertility

Gleason Score

- Used for assessment of prostate carcinoma
- 3 component
  - Pattern
  - Score
  - Grade

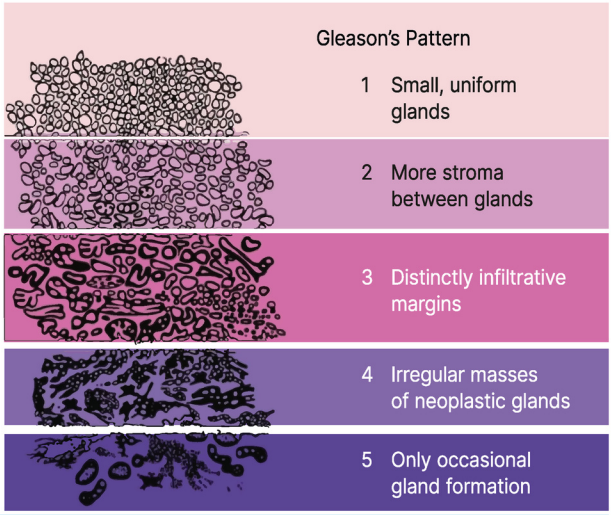

Pattern	
1	Prostate glands are stuck to each other
2	Little amount of space is present between gland
3	More amount of space is present between gland
4	Cribriform, Hypernephroid 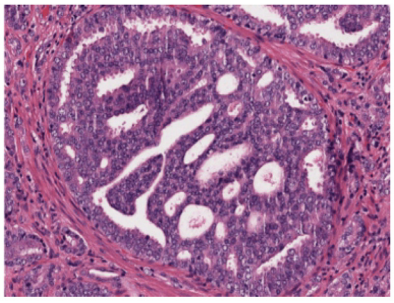

Yourwish

5	Single cell and Comedonecrosis 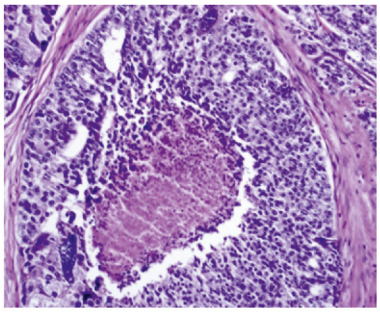
Score	
	If only one pattern are present then it should be doubled
	If two pattern are present then it is added
	If three pattern are present then, primary pattern is added with another highest pattern
Grading	
Gleason score ≤6	Grade group I
Gleason score 3+4 = 7	Grade group II
Gleason score 4+3 = 7	Grade group III
Gleason score 8	Grade group IV
Gleason score 9 to 10	Grade group V

PYQ

00:50:01

Q. A 69-year-old male is found on rectal examination to have a hard, irregular nodule within his prostate. PSA levels are 100 ng/ml. TRUS-guided biopsy shows the presence of tumor cells without any glandular formation. 10% of the tumor shows a cribriform pattern. What is the Gleason grade?

a. Grade 2
b. Grade 3
c. Grade 4
d. Grade 5

Ans: d. Grade 5

Q. Prostate biopsy shows the presence of adenocarcinoma predominantly in a cribriform pattern followed by a crowded pattern but separate glands and a minor component (5%) of single cell infiltration. What is the Gleason grade?

a. Grade 2
b. Grade 3
c. Grade 4
d. Grade 5

Ans: d. Grade 5

Yourwish

Q. Post-orchidectomy, the specimen shows Reinke's Crystals. What is the diagnosis?

a. Seminoma
b. Leydig Cell tumor
c. Metastasis
d. Yolk sac tumour

Ans: b. Leydig Cell Tumor

Q. A 30-year-old man presents with a painless testicular mass. An ultrasound shows a well-circumscribed, homogeneous, non-hemorrhagic testicular tumour. Which of the following is the most likely diagnosis?

a. Yolk sac tumour
b. Choriocarcinoma
c. Teratoma
d. Seminoma

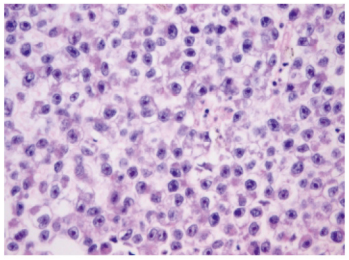

Ans: d. Seminoma

Yourwish

11. BREAST/ BONE/ SKIN/ SOFT TISSUE PATHOLOGY

BREAST PATHOLOGY

00:00:11

Fibrocystic Disease

- Characterized by fibrosis and blue dome cysts.
- Fibrosis appears as whitish areas.
- Cysts contain secretions derived from cells → Apocrine snouts.

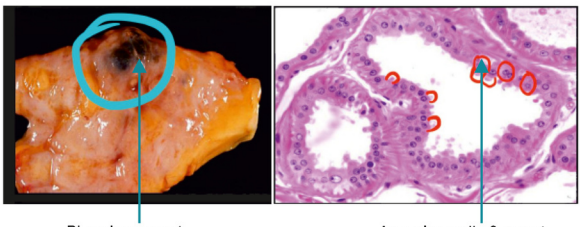

Blue dome cyst | Apocrine cells & snout

Radial Scar

- Gross appearance: Star-shaped or starry scar (central stellate scar).
- Microscopic appearance: Pinkish scar sending projections in all directions
- Clinical significance: Considered a precancerous/ premalignant condition.

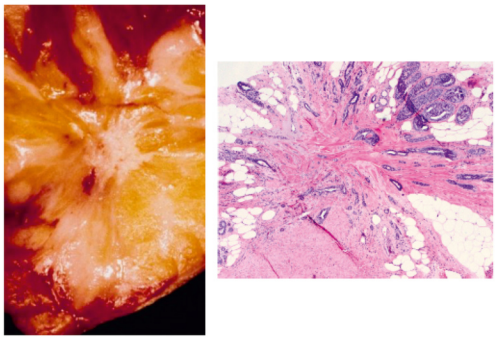

Benign Breast Tumors

FIBROADENOMA

- Known as the "Breast Mouse" due to high mobility
- Radiology finding: Popcorn calcification (also seen in pulmonary hamartoma)
- Fine Needle Aspiration Cytology (FNAC):
  - Staghorn clusters: Cells arranged like deer horns
  - Bare nuclei: Blue-colored cells in the background
- Biopsy Findings:
  - Intracanalicular pattern: Compressed ducts resembling the alphabet "I."
  - Pericanalicular pattern: Open ducts resembling the alphabet "P."
  - Prognosis is identical for both patterns

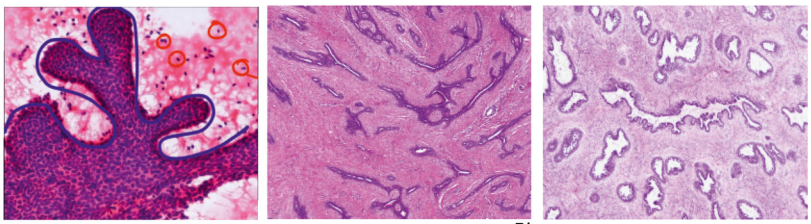

FNAC
Staghorn clusters , Bare nuclei | Intra canalicular | Biopsy | Peri canalicular

PHYLLODES TUMOR

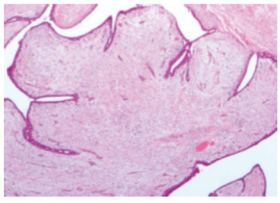

Leaf like

- Characterized by leaf-like stromal growth.
- Categories: Benign, Borderline, and Malignant.
- Grading by Mitotic Count:

Criteria	Benign	Borderline	Malignant
Mitoses / 10 HPF	< 5	5-9	≥ 10

Ductal Carcinoma In Situ (Dcis)

- Characterized by an intact basement membrane.
- Types:
  - Cribriform: Resembles a sieve with holes.
  - Comedo Necrosis: Central necrotic material resembles acne material

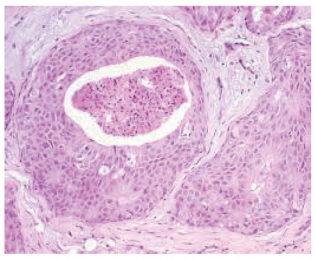

Comedonecrosis DCIS

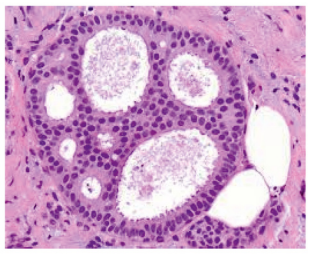

Cribriform DCIS



Mucinous (Colloid) Carcinoma

- Characterized by pools of mucin
- FNAC finding: Chicken wire blood vessels
- Biopsy: Tumor cells floating in mucin pools

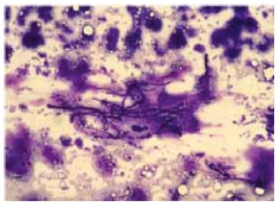

Chicken wire blood vessels

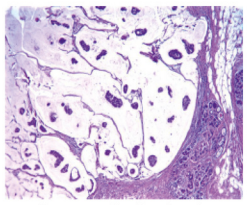

Tumor cells floating in pools of mucin

Inflammatory Breast Carcinoma

- Skin appearance: Peau d'orange (orange-peel appearance)
- Spread: Cancer spreads to sub-dermal lymphatics.





Invasive Lobular Carcinoma

- Indian File Pattern: Tumor cells arranged in a single-file line.
- May show signet ring appearance
- Genetics: Loss of E-cadherin
  - Note: Loss of E-cadherin also occurs in diffuse gastric cancer

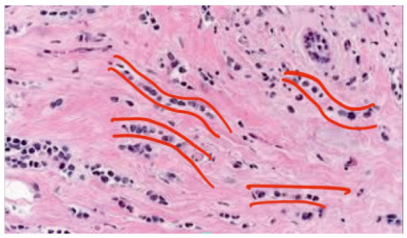

Molecular Classification of Breast Cancer

00:06:08

- Estrogen (ER) and Progesterone (PR) Receptors
  - Positive finding: Brown color in the nucleus (Nuclear positivity).
  - Allred Scoring: At least 1% of cells must be positive.
- Her2neu Receptor
  - Positive finding: Membranous positivity (not nuclear)
  - Scoring System:
    → 0 / 1+ → Negative
    → 3+ → Positive (entirely brown); Treat with Trastuzumab (Herceptin).
    → 2+ → Equivocal/Doubtful; requires confirmation by FISH
  - Fluorescence In Situ Hybridization (FISH)
    → Interpretation:(Her2/Chromosome 17) ratio > 2.2 → Positive for Her2 amplification → Treat with Trastuzumab

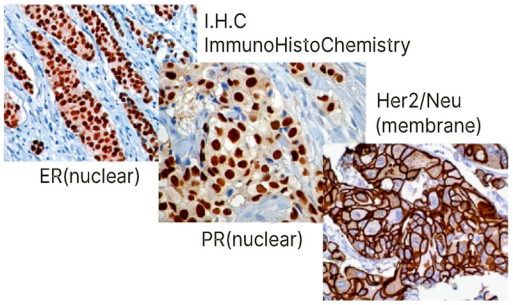

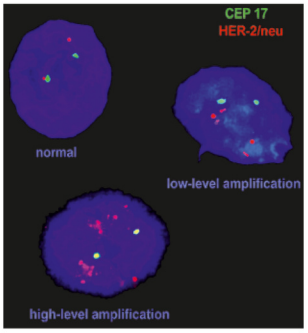

Yourwish

Type	ER	PR	HER2
Luminal A	Positive	Positive	Negative, Ki67 < 14% (low proliferation)
Luminal B	Positive	Positive	Negative, Ki67 > 14% (high proliferation)
HER2 rich	Negative	Negative	Positive
Triple negative	Negative	Negative	Negative

- Burkitt's Lymphoma: Ki67 ~ 100%
- Some Luminal B cases are Triple Positive (ER, PR, and Her2 all positive)
- Triple Negative: Medullary, Metaplastic, Claudin-low

Luminal A	Luminal B	HER2 rich	Triple negative
• Tubular carcinoma • Mucinous carcinoma • Papillary carcinoma • Low-grade ILC	• High-grade ILC	• Apocrine carcinoma	• Medullary carcinoma • Metaplastic carcinoma

Paget Disease

00:11:41

- Affects both breast and vulva
- Presentation: Crusting of the nipple-areola skin
- Mechanism: Underlying DCIS tumor cells migrate to the skin
- Microscopic finding: Paget cells (clear cells) in the skin.



Crusting

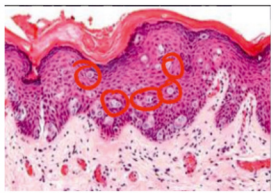

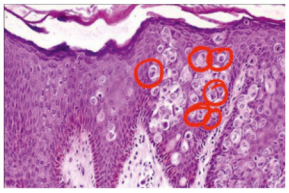

Paget's cells.

BONE PATHOLOGY

00:12:55

Osteosarcoma

- Radiology:
  - Codman Triangle: Formed by shaft and lifted periosteum.
  - Sunburst appearance: Result of new bone formation.
- Pathology:
  - Hallmark: Osteoid formation.
  - Osteoid appearance: Thin, pink, lacy, and glassy unmineralized bone.

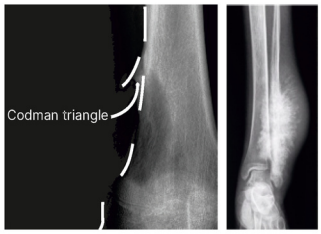

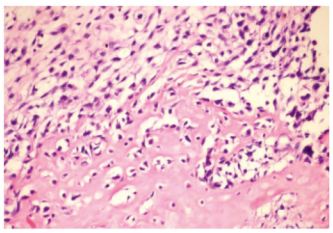

Cartilage Tumors

Tumors		Extra
Enchondroma	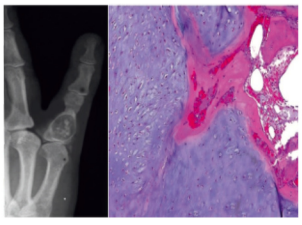	IDH1,2

Yourwish

Osteochondroma / Exostosis	 	EXT1,2
Chondroblastoma / Codman Tumor	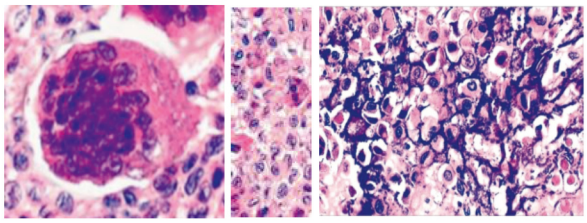	—
Chondrosarcoma	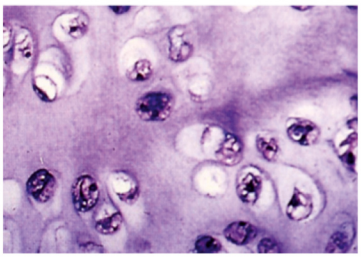	PERMEATION

- Enchondroma
  - Benign tumor, usually in small bones (e.g., fingers).
  - Radiology: Well-circumscribed with speckled calcification
  - Genetics: IDH (Isocitrate Dehydrogenase) mutation.
  - Note: IDH mutations are also seen in Glioblastoma and Oligodendroglioma
- Chondrosarcoma
  - Malignant tumor, usually in axial skeleton (e.g., pelvis).
  - Radiology: Shows permeation and invasion.
  - Microscopic: Large, bizarre malignant cartilage cells.
- Osteochondroma (Exostosis)
  - Genetics: Mutation in EXT1 and EXT2 genes
  - Appearance: Mushroom-like outgrowth.
  - Both the cortex and marrow bulge out into the tumor.
- Chondroblastoma (Codman Tumor)

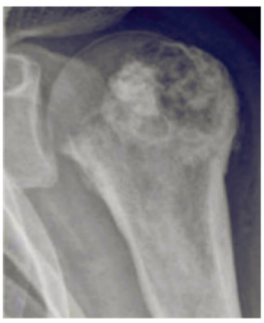
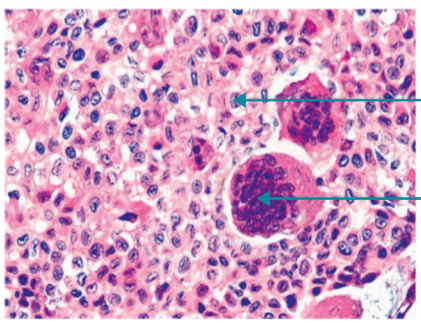

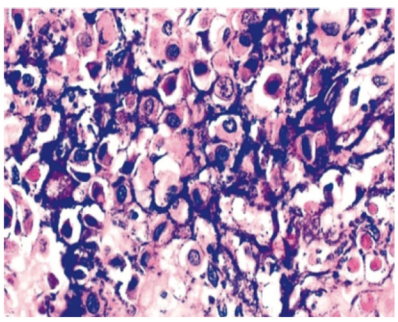

  - Located in the epiphysis.
  - Microscopic Findings:
    → Giant cells and mononucleated cells

Yourwish

→ Coffee bean nuclei: Cells with a central line.
→ Chicken wire calcification: Calcification around every cell

Important Information

- Chicken Wire Blood vessels (FNAC) → mucinous carcinoma
- Chicken Wire Blood vessels (biopsy) → oligodendroglioma
- Chicken Wire Calcification → chondroblastoma
- Chicken Wire Fibrosis → alcoholic liver disease

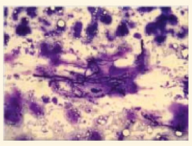

Chicken Wire BV

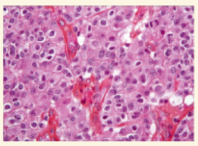



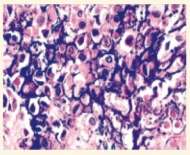

Chicken Wire

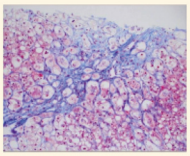

Miscellaneous Tumors

INICET Nov 2022

EWING SARCOMA

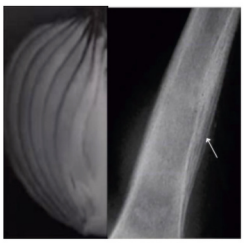

ONION PEEL

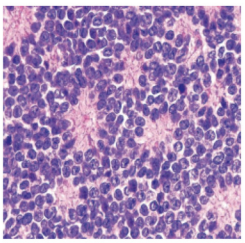

HOMER WRIGHT PSEUDOROSETTES

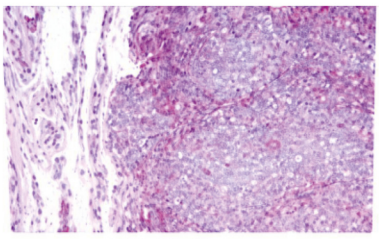

PAS+DS Glycogen

- Radiology:
  - Onion peel appearance due to periosteal reaction
- Microscopic Findings:
  - Homer-Wright Pseudo-rosettes.
    → Medulloblastoma, Ewing's, Neuroblastoma, Retinoblastoma
- Staining:
  - PAS positive and Diastase sensitive (indicates glycogen content).
- Markers:
  - CD99 positive.
  - MIC2 positive.
- Clinical Presentation:
  - Adolescents (~17 years).
  - Pain, swelling, and fever (mimics osteomyelitis).
- Genetics:
  - Translocation t(11;22).
  - EWS and FLI1 fusion

GIANT CELL TUMOR

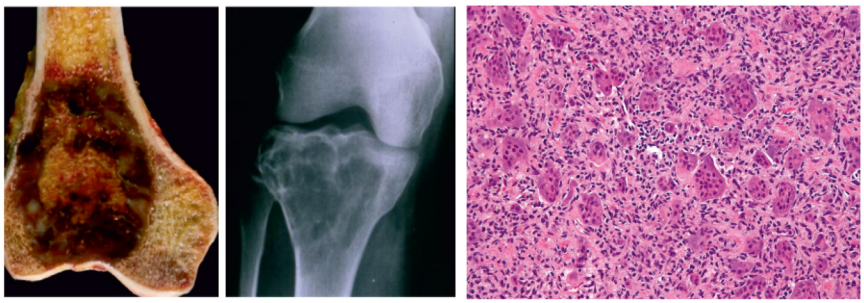

GIANT CELL TUMOR	• Morphology
	  ○ Contains both giant cells and mononuclear cells.
	  ○ Note: The mononuclear cells are the actual neoplastic/tumor part
	• Radiology
	  ○ "Soap bubble" appearance (d/t excessive bone breakdown)
	• Treatment
	  ○ Denosumab → inhibits the RANK-RANKL pathway to stop bone destruction.

Chordoma

00:21:44

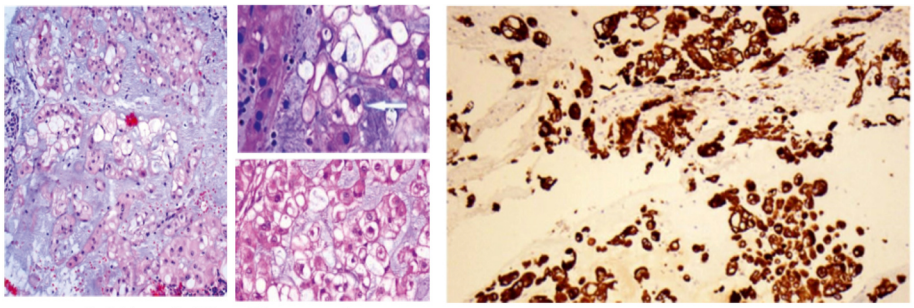

Bubbly cells/Physaliferous cells

- Origin and Location
  - Arises from remnants of the embryological notochord
  - Found along the body midline: Clivus or Sacrococcygeal region
- Microscopic Features
  - Physaliphorous cells: Characterized by a bubbly appearance.
- Gene mutation/IHC marker: Brachyury (shows brown color on IHC).

Fibrous Dysplasia

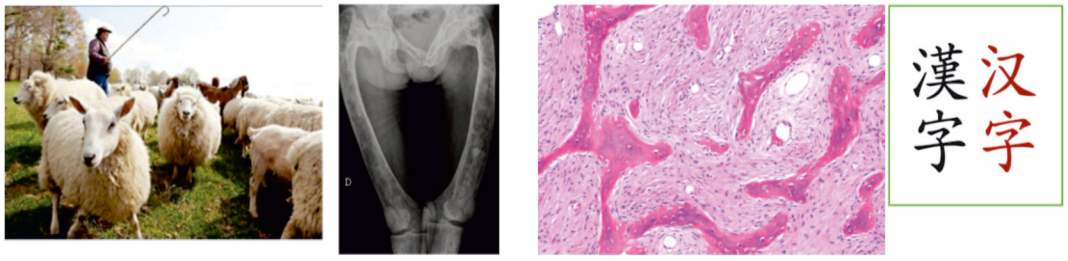

- Radiology:
  - Shepherd's Crook deformity (bending of the femur)
  - Ground glass appearance
- Pathology:
  - Chinese letter pattern of bony trabeculae.
  - Absence of osteoblastic rimming

Non-Ossifying Fibroma

- Differentiated from FD by the presence of osteoblastic rimming

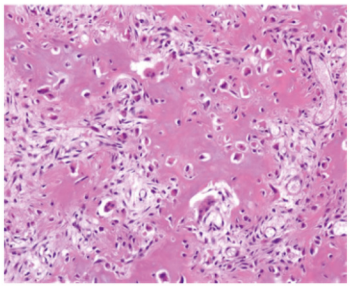

Yourwish

Aneurysmal Bone Cyst

- Giant cells around blood-filled spaces
- Genetics
  - Associated with USP6 gene mutation.


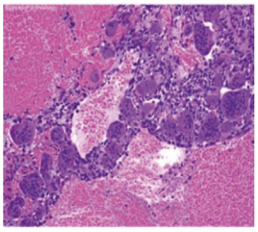

Epiphyseal	Metaphyseal	Diaphyseal
Mnemonic ECG • Chondroblastoma • Clear cell tumor • Chondrosarcoma • Giant cell tumor	**Mnemonic: SOFA Chair** • Simple bone cyst • Osteosarcoma • Fibrous dysplasia • ABC • **Chair:** Osteochondroma	**Mnemonic: MALE Officer** • Multiple myeloma • Adamantinoma • Leukemia • Ewing sarcoma • **Officer:** Osteoid osteoma

SKIN PATHOLOGY

00:26:58

Psoriasis

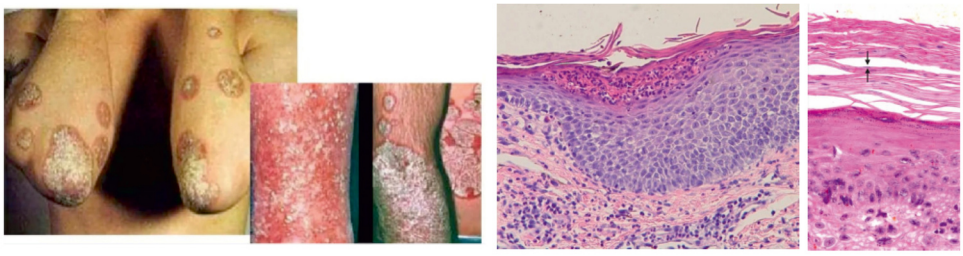

- Clinical Presentation
  - Silvery or fish-like scales.
  - Scaling removal → underlying reddish skin.
- Histological Findings
  - Hyperkeratosis: Thickened stratum corneum.
  - Parakeratosis: Retention of nuclei in the stratum corneum.
  - Munro's microabscess: Accumulation of inflammatory cells in the stratum corneum.
- Differential Interpretation
  - Munro's microabscess → Psoriasis (Rule: M asks for P)
  - Pautrier's microabscess → Mycosis Fungoides/T-NHL (Rule: P asks for M)

Lichen Planus

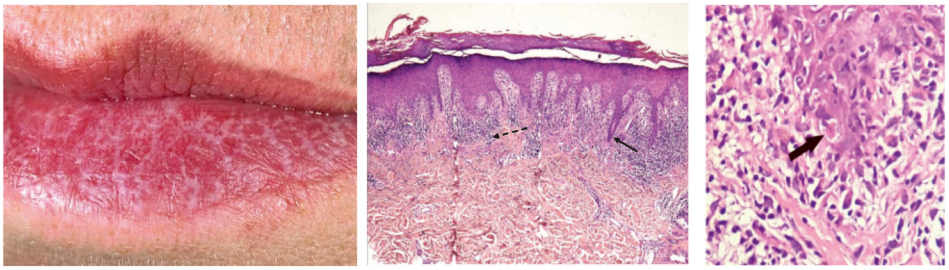

Wickham's Striae

- Clinical and Pathological Features
  - Wickham striae: White color lines on the skin.
  - Saw-toothing of rete ridges.

Yourwish

Yourwish

- Band-like lymphocytic infiltrate.
- Civatte/Colloid/Cytoid bodies: Apoptotic cell remnants
- Max-Joseph space: Empty space formed after cell death

Molluscum Contagiosum

INICET Nov 2022

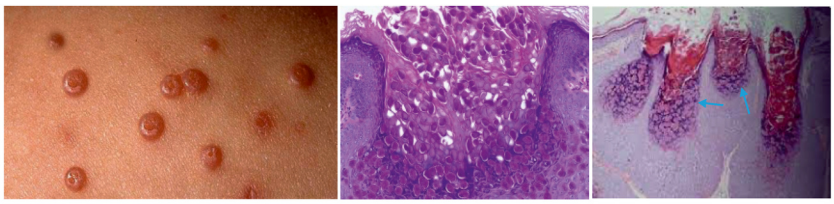

- Etiology
  - Caused by Molluscum Contagiosum virus (DNA virus, Poxvirus family).
- Clinical Presentation
  - Skin/tan-colored umbilicated lesions (central hole).
- Microscopic Findings
  - Cup-shaped lesion.
  - Henderson-Patterson (HP) bodies: Viral inclusions.
    → Special stain: Phloxine Tartrate.
- Comparison
  - HP bodies (Henderson-Patterson) → Molluscum Contagiosum.
  - HP bodies (Halberstaedter-Prowazek) → Trachoma (Ophthalmology)

Bullous disorders

Pemphigus

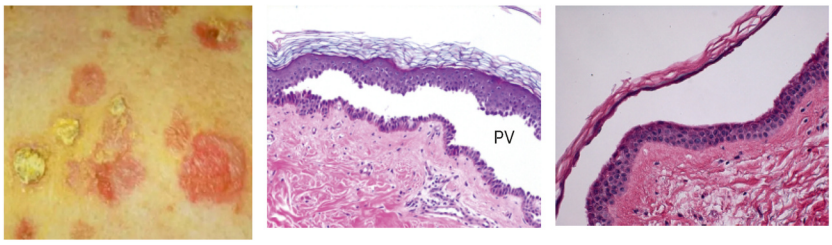
Pemphigus Vulgaris
Pemphigus Foliaceous

- Characterized by flaccid bullae and crusting.
- Pemphigus Vulgaris:
  - Antibodies against Desmoglein 3 and 1.
  - Suprabasal split → "row of tombstones" appearance of basal cells
- Pemphigus Foliaceus:
- Antibody against Desmoglein 1
  - Subcorneal split (outermost layer)
- Immunofluorescence:
  - Fish-net or reticular pattern
  - Seen in both Foliaceous and Vulgaris

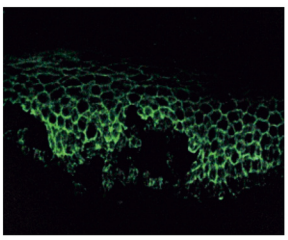

Bullous Pemphigoid (BP)

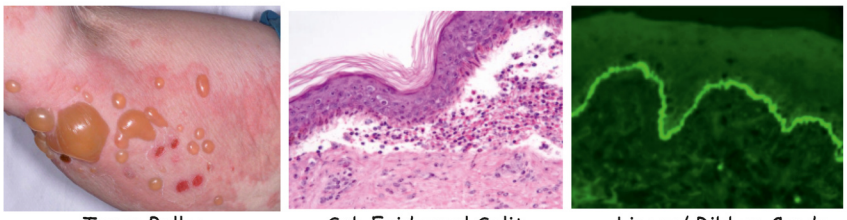
Tense Bullae
Sub Epidermal Split
Linear/ Ribbon Candy

- Antibodies against Hemidesmosomes (BP antigen).
- Tense bullae (not flaccid).
- Subepidermal split with numerous eosinophils
- Immunofluorescence:
- Linear or "ribbon candy" appearance on the roof of the bulla.

Yourwish

Epidermolysis Bullosa Acquisita (EBA)

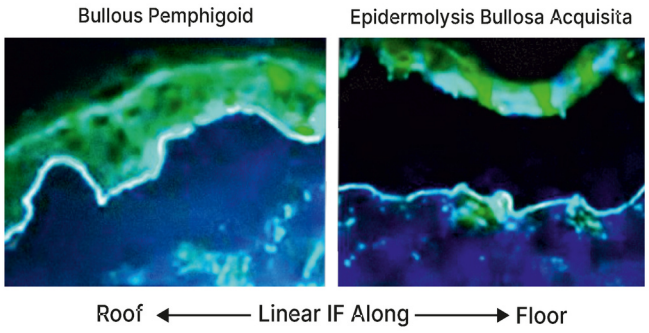

- Defect: Collagen 7.
- Immunofluorescence: Linear appearance on the floor of the bulla.
- Differentiation:
  - In bullous pemphigoid green coloured line is on the Roof
  - In acquisita, green coloured line is on the Floor

Dermatitis Herpetiformis

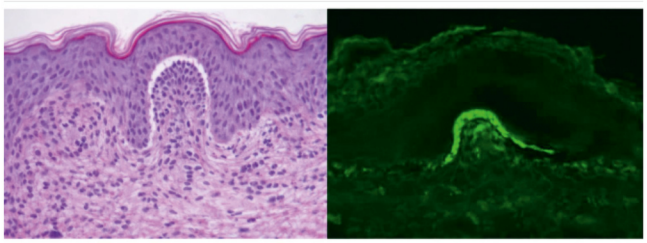

- Subepidermal split with neutrophils at the dermal papillae
- Immunofluorescence: Granular IgA deposition at the tips
- Association: Celiac disease (gluten sensitivity to wheat, barley, rye, oats)

Basal Cell Carcinoma

FMGE June 2024, Jan 2025
INICET Nov 2022

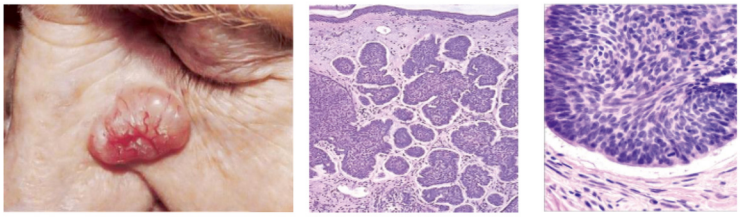

- Known as "Rodent Ulcer"
- Pearly nodule, rolled margins, and telangiectatic blood vessels.
- Microscopic Findings
  - Peripheral palisading: Cells arranged in a straight parallel line
  - Retraction artifacts: Gaps between cancer cells and normal tissue.
- Genetics
  - Syndrome: Gorlin syndrome.
  - Pathway: Sonic Hedgehog pathway (PTCH gene).

SOFT TISSUE PATTERNS

00:36:30

Fibrosarcoma

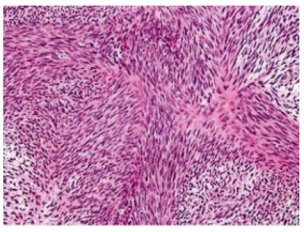

- Diagnostic pattern: Herring-bone pattern (radiating fish-spine bone pattern).

Leiomyosarcoma

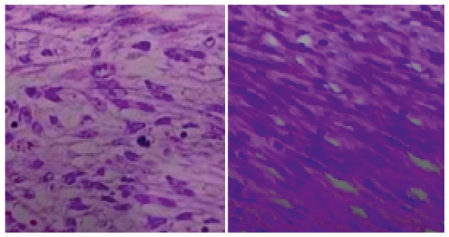

- Arises from smooth muscle.
- Cigar-shaped nuclei.
- IHC: Vimentin and SMA (Smooth Muscle Actin) positive.

Rhabdomyosarcoma

- Arises from skeletal muscle; common in children
- Embryonal type: Sarcoma botryoides (resembles a bunch of grapes)

- Histology:
  - Cambium layer: High-density cancer cell layer
  - Cells: Strap cells or tennis racket cells
- IHC: Desmin and MyoD1 positive
- Special stain: PTAH (Phosphotungstic Acid Hematoxylin)

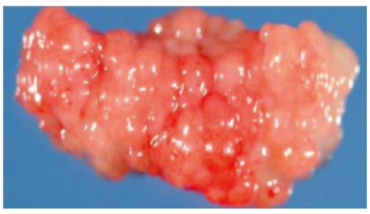
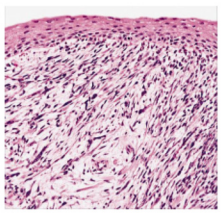
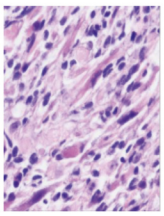

Important Information

- TENNIS RACKET APPEARANCE

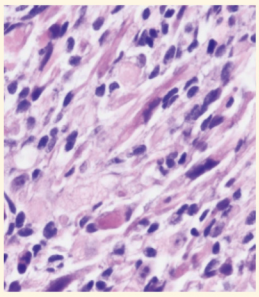
RMS


LCH


Giardia Lamblia

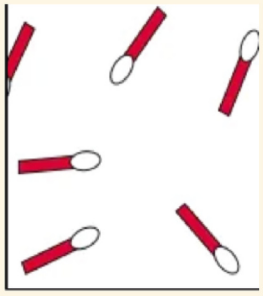
Clostridium Tertium

  - Rhabdomyosarcoma cells.
  - Birbeck granules on EM (Langerhans Cell Histiocytosis)
    → CD marker for LCH: CD1a, CD207, HLADR, S100
  - Giardia lamblia
  - Clostridium tertium

Gout Vs Pseudogout

Feature	Gout	Pseudogout
		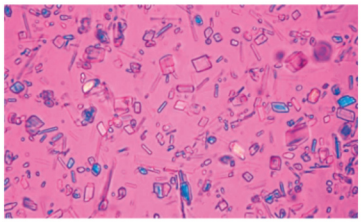
Crystal	Uric acid	CPPD
Shape	Needle-shaped	Rhomboid
Birefringence	Negative	Weakly positive

MCQ

00:40:49

Q. A 15-year-old boy presents with swelling in the upper diaphyseal part of the tibia. X-ray shows periosteal reaction. Histopathology image of biopsy is given below. IHC was positive for synaptophysin and MIC2. What is the likely diagnosis?

INICET Nov 2022

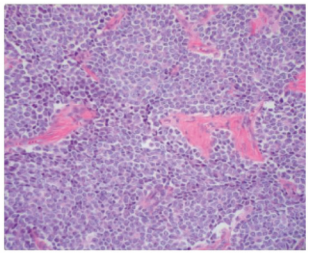

a. Osteosarcoma
b. Ewing sarcoma
c. Metastatic neuroblastoma
d. Osteoclastoma

Answer: **b. Ewing sarcoma**

Yourwish

Q. A woman presents with nodular lesions (4–6 mm) on inner thighs and perianal region. Lesions appear pale, and histopathology shows multiple intracytoplasmic inclusion bodies consistent with Henderson–Patterson bodies. What is the most likely diagnosis?

a. Trichodysplasia spinulosa
b. Condyloma acuminata
c. Molluscum contagiosum
d. Donovanosis

Answer: c. **Molluscum contagiosum**

Q. Identify the histopathological image:

FMGE June 2024

a. Basal cell carcinoma
b. Squamous cell carcinoma
c. Adenocarcinoma
d. Malignant melanoma

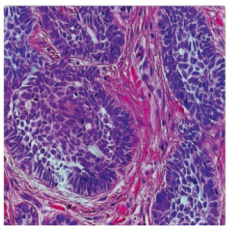

Answer: a. **Basal cell carcinoma**

Q. An elderly man presents with an ulcerative lesion at the inner canthus of the eye with pearly margins. On microscopic examination, it shows palisading arrangement of cells. Identify the lesion:

a. Squamous cell carcinoma
b. Basal cell carcinoma
c. Keratoacanthoma
d. Melanocytic melanoma

Answer: b. **Basal cell carcinoma**

Yourwish

Yourwish

10. ENDOCRINE PATHOLOGY

THYROID GLAND

00.00.10

Thyroid Gland- Histology

- Follicular cells → secrete colloid
  - Colloids appears as pinkish material
- Parafollicular C-cells → secrete calcitonin
  - Maintains calcium homeostasis

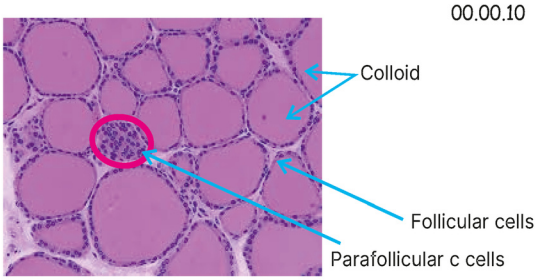

Thyroid Gland- Fnac

- Adequacy of FNAC given by Bethesda system
- Adequate if
  - ≥6 follicles with ≥10 cells / follicles
  - Exception: Cancers, Colloid cyst, Inflammation (e.g Hashimoto thyroiditis)

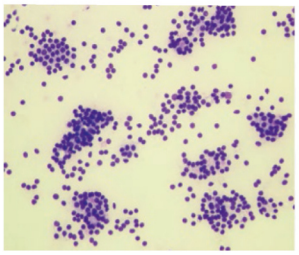

Hypothyroidism

HASHIMOTO'S THYROIDITIS

- A/k/a Lymphocytic thyroiditis
- Genetic

  HLA DR3,5 gene polymorphism

  ↓

  Formation of anti TPO and anti TG antibodies
- Clinical features

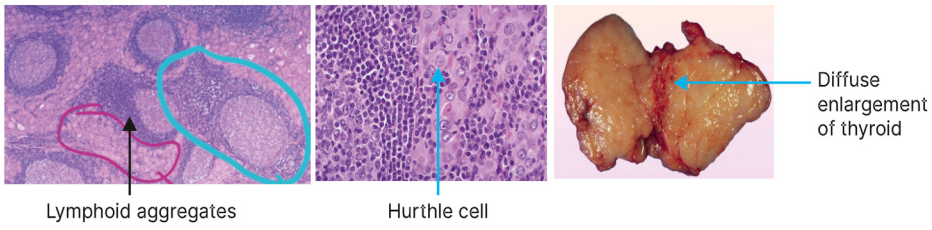

  - Diffuse enlargement of thyroid gland
  - Increased risk of papillary carcinoma of thyroid and MALToma
- Histology
  - Lymphoid aggregates with germinal centres
  - Hallmark : Hurthle / Askanazy cells → rich in mitochondria

DE QUERVAIN'S THYROIDITIS

- A/k/a giant cell thyroiditis
- Etiology
  - Occurs following post viral infection → Mumps, adenovirus
- Clinical features
  - Painful thyroiditis
- Histology: Giant cells

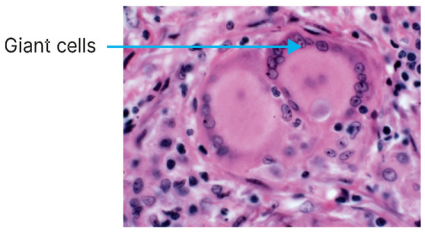

SUBACUTE LYMPHOCYTIC THYROIDITIS	• Postpartum thyroiditis • Painless
REIDELS THYROIDITIS	• IgG4 related disease ○ Leads to fibrosis of gland • Stony hard in consistency, mimic carcinoma

Hyperthyroidism

Grave's disease

NEET PG Aug 2024

- A/k/a Basedow disease
- Autoimmune disease where Thyroid stimulating Immunoglobulin (TSI) are produced leading to hyperthyroidism
- Clinical features
  - Exophthalmos
  - Pre-tibial myxedema
  - Acropachy → swelling of digits
- Gross appearance → Beefy red

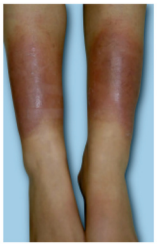
Pre-tibial myxedema


Exophthalmos

Acropachy

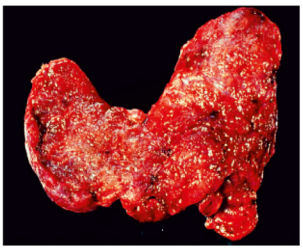

- Microscopy

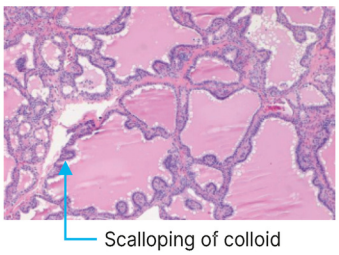

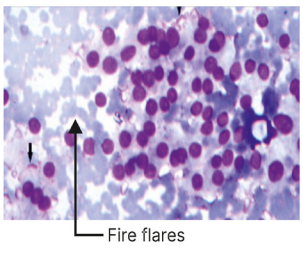

  - FNAC → Fire Flares due to increased hormone production
  - Biopsy → scalloping of colloid
- Radioactive iodine
  - Increased uptake of radioactive iodine



Thyroid cancer

Papillary thyroid carcinoma

NEET PG 2025
INICET 2022, 2025

- Risk factor
  - Radiation
  - Hashimoto thyroiditis
- Genetic
  - M/c: BRAF V600 E mutation
  - RET-PTC fusion

Microscopy

• True papillae → blood vessel core	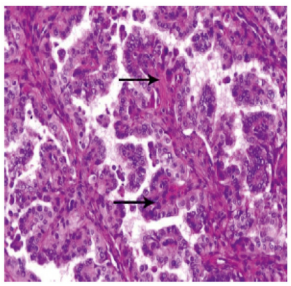
• Orphan annie eye nuclei → optically clear • Formalin artefact (not seen on FNAC)	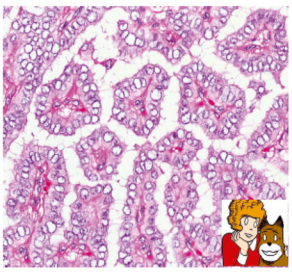
• Intranuclear inclusions and Intranuclear grooves	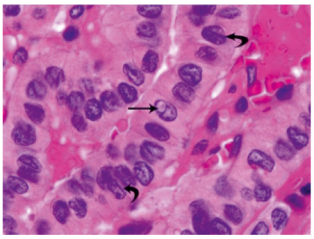
• Psammoma bodies	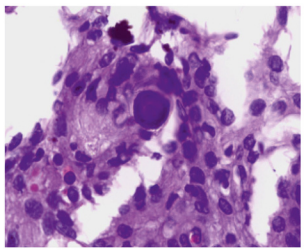
• Chewing gum colloid on FNAC	

Variants Of Papillary Thyroid Cancer

- Micro PCT → <1cm
- Follicular variant of PCT → presence of follicles instead of a papillae
- Lindsay tumor → solid encapsulated follicular variant of PCT

Prognosis

- Excellent prognosis
- Tumor with bad prognosis
  - Diffuse sclerosing PCT
  - Tall cell variant → length >3 times the width and >30% of tumor cells are tall

Yourwish

Follicular Thyroid Cancer

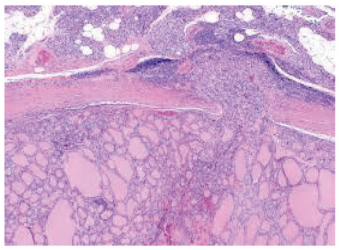
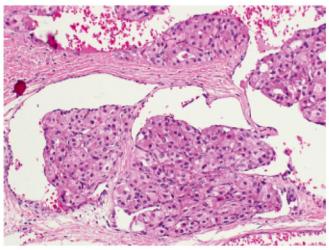

- Genetic / pathology
  - RAS mutation
  - Hematogenous spread → MC site of metastasis is scalp
- Diagnosis
  - Cannot be diagnosed on FNAC
  - Biopsy → Capsular & Vascular invasion

Medullary Carcinoma Of Thyroid

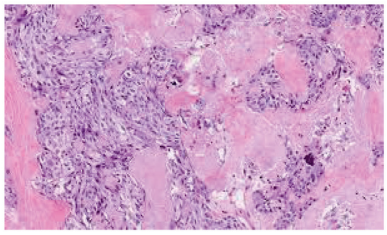
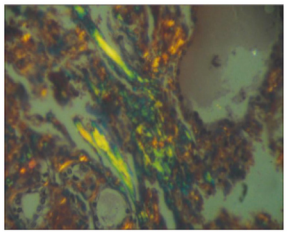

- Genetics / pathology
  - RET mutation on chr 10
  - Arise from parafollicular c cells
  - A/w MEN IIA, B
- Tumor marker
  - Calcitonin
  - Acal → stains with congo red, appears apple green birefringence on polarized microscopy
  - CEA

Anaplastic Carcinoma

- Worst prognosis

ADRENAL GLAND TUMORS

00.13.55

Neuroblastoma

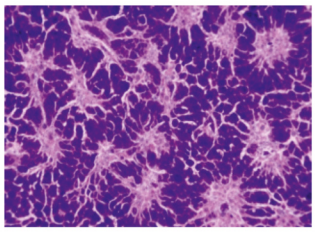

- Amplification of n-myc gene
- Microscopy
  - Homer wright pseudorosette

Important Information

Homer wright pseudorosette

- Meduloblastoma
- Ewing's sarcoma
- Neuroblastoma
- Retinoblastoma

Pheochromocytoma

FMGE Jan 2023
INICET Nov 2024

- Clinical features
  - Headache, sweating, palpitation
  - MC Symptom - Headache
  - MC sign - Hypertension
- Tumor markers
  - Metanephrines / VMA
- Biopsy / FNAC is C/I

Yourwish

Yourwish

- Rule of 10
  - 10 percent bilateral
  - 10 percent children
  - 10 percent extra-adrenal → Paraganglioma, seen in organ of zuckerkandl
  - 10 percent malignant
  - 10 percent do not cause hypertension
- 25% are familial
- Microscopy → Zellballen / nesting appearance
  - Chief cells → neuroendocrine component
  - Supporting / sustentacular cells

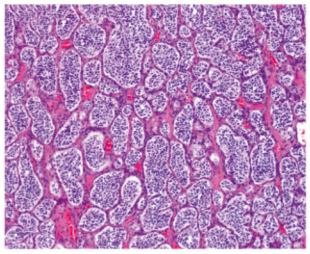

- IHC
  - Neuroendocrine markers → Chromogranin , synaptophysin
  - Sustentacular cells → S100 +

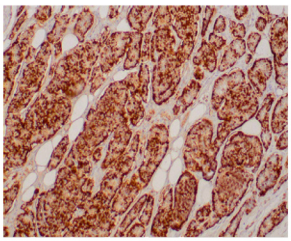

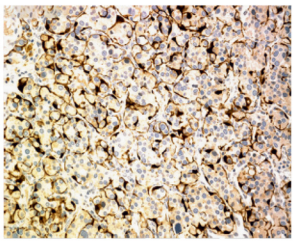

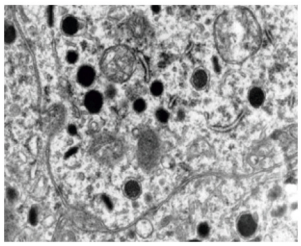

- Electron microscopy → Neuro secretory granules
- Treatment
  - α Blocker → β Blocker → Surgery

Men Syndrome

FMGE June 2024

MEN I / Wermer syndrome	MEN IIa / Sipple syndrome	MEN IIb / III	MEN IV
MENIN gene mutation	RET gene mutation	RET gene mutation	CDKN1B gene mutation
• Pituitary adenoma (Prolactinoma) • Parathyroid hyperplasia • Pancreatic tumor (Gastrinoma)	• Parathyroid hyperplasia • Medullary carcinoma of thyroid • Pheochromocytoma	• Mucosal neuroma • Marfanoid habitus • Medullary carcinoma of thyroid • Pheochromocytoma	• MEN I + Renal tumors + Reproductive tumors

Important Information

- Werner syndrome / Progeria → Premature ageing

PYQ

0.22.11

Q. A young woman presents with weight loss, tachycardia, heat intolerance, and tremors. On examination, she has exophthalmos. What is the most likely diagnosis?

NEET PG Aug 2024

A. Parkinson's disease
B. Grave's disease
C. Addison's disease
D. Alzheimer's disease

Answer: B

Yourwish

Q. A patient presents with a mass in the front of the neck, along with odynophagia and dyspnea. Histopathology reveals tumour cells positive for TTF-1, synaptophysin, and chromogranin, and there is evidence of amyloid deposition. What is the most likely diagnosis?

NEET PG 2025

A.Papillary thyroid carcinoma
B.Follicular thyroid carcinoma
C.Medullary thyroid carcinoma
D.Anaplastic thyroid carcinoma

Answer: C

Q. A 50-year-old woman presents with a slowly enlarging, painless thyroid nodule. She has no history of radiation exposure. On examination, the nodule is firm and mobile. Thyroid function tests are within normal limits. Ultrasound shows a solitary, solid lesion in the right lobe of the thyroid. Fine-needle aspiration cytology (FNAC) is performed, but is inconclusive. Hemithyroidectomy is done, and histopathology reveals capsular and vascular invasion. What is the most likely diagnosis?

INICET May 2025

A. Papillary thyroid carcinoma
B. Follicular adenoma
C. Follicular thyroid carcinoma
D. Medullary thyroid carcinoma

Answer: C

Q. A patient presents with complaints of sudden onset headache, palpitation, and profuse sweating. The patient has had multiple similar episodes in the past. During these episodes, the patient's blood pressure is elevated. A 24-hour urine metanephrine is elevated. What is the most likely diagnosis?

FMGE Jan 2023

A.Addison's disease
B.Renal artery stenosis
C.Pheochromocytoma
D.Hyperthyroidism

Answer: C

15. RED BLOOD CELLS

BONE MARROW STUDY

00:00:16

INICET May 2022

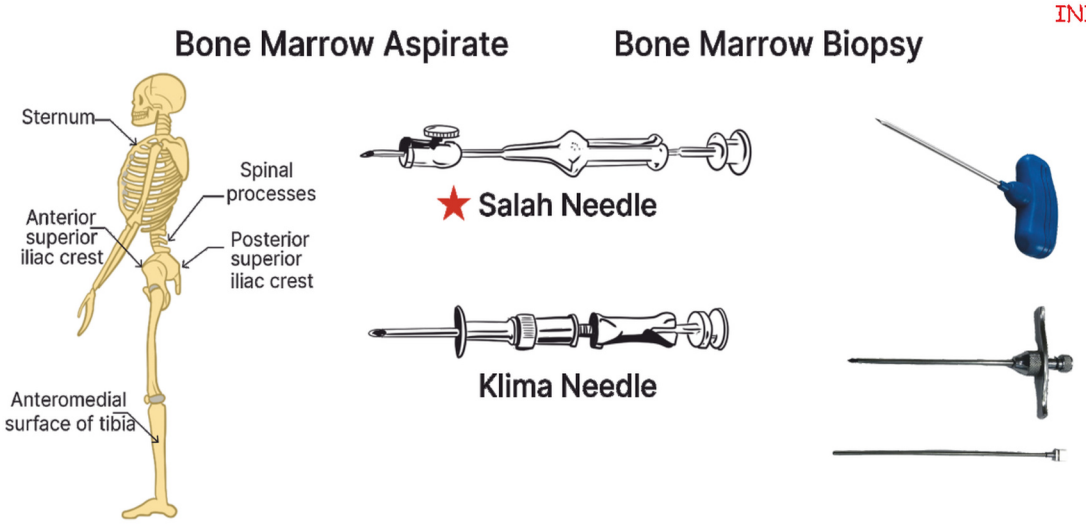

Bone Marrow Aspirate

- Needles:
  - Salah needle (identified by side screw)
  - Klima needle (identified by longitudinal screw)

Bone Marrow Study

- Needle used:
  - Jamshidi BMB needle (T-shaped)
- Normal bone marrow:
  - Consists of bony trabeculae, cells & fat
  - Normal cell to fat ratio in an adult - 1:1
  - To measure cellularity: (100 - age) % cells

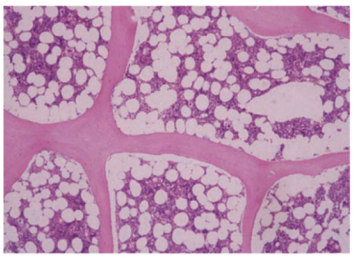

Sites For Bone Marrow Studies

- MC Site: PSIS (Posterior superior iliac spine)
- In obese patients: ASIS (Anterior superior iliac spine)
- In children: Anterior medial surface of upper end of tibia

Peripheral Smear

- Romanowsky family of stains:
  - Giemsa stain
  - Leishman stain
- Wright Stain
- Jenner Stain
- Field Stain (Stain for Plasmodium falciparum)

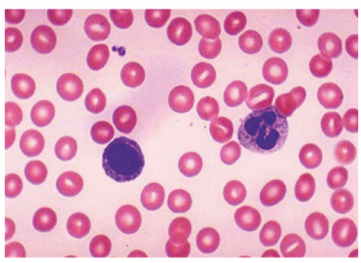

Yourwish

RBC FORMATION

00:03:54

- Inside bone marrow, cells with nucleus:

Pronormoblast
(First cell to contain Hemoglobin, seen on electron microscope)
↓
Early normblast/Basophilic normblast (B)
↓
Intermediate normblast/Polychromatophic normblast (P)
(Hemoglobin can be seen on light microscope)
↓
Late normblast/Orthochromic normblast (O)

- Inside peripheral blood, cells lack nucleus:

Reticulocyte
(First cell in peripheral smear)
(First cell without nucleus)
↓
Erythrocyte/RBC

Reticulocytes

00:06:35

FMGE Jan 2024, June, Dec, 2021

- Cell that contains a reticulum of RNA
- To stain a Reticulocyte: Supravital stain (In-living stain; no methanol, ethanol fixation)
  - Examples:
    - → New methylene blue
    - → Brilliant cresyl blue
- Normal value: 0.5 to 2%
- Corrected Reticulocyte count = Reticulocyte count × ($Hb_{Patient}$/$Hb_{NormalPerson}$)
- Reticulocyte Production Index = Corrected Reticulocyte count/Maturation factor

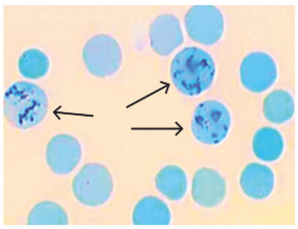

Hematocrit (Hct)	Maturation factor
≥40%	1.0
30 - 39.9 %	1.5
20 - 29.9 %	2.0
<20%	2.5

NORMAL RBC INDICES

00:10:04

- Mean Corpuscular Volume (MCV)
  - Size of RBC
  - Normal MCV: 80 - 100 FL (Normocytic)
    - → <80 FL: Microcytic
    - → >100 FL: Macrocytic
- Mean Corpuscular Hemoglobin (MCH)
  - Normal value: 27 - 32 pg
- Mean Corpuscular Hemoglobin Concentration (MCHC)

Yourwish

Yourwish

- Normal value: 33 - 37 g/dl
- Only anemia where Hb concentration (MCHC) will increase: Hereditary Spherocytosis

- Red Cell Distribution Width (RDW)
  - Variation of size in RBC: Measure of Anisocytosis
  - Normal value: 11.5% - 14.5%
- Packed Cell Volume (PCV)
  - Also called Hematocrit (Hct)
  - Normal value: ≈ 45%

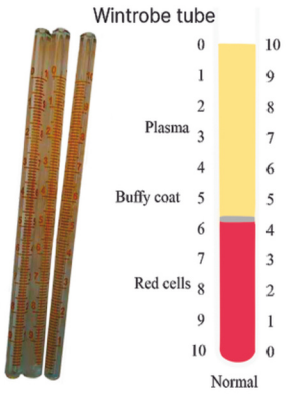



Wintrobe tube	Westergren pipette
• Identification: Open at one end and closed at another • It is used to measure PCV and ESR (erythrocyte sedimentation rate)	• Identification: Open from both ends • It is used only to measure ESR (not PCV)

MICROCYTIC HYPOCHROMIC ANEMIA

00:14:53

Features

- S = Sideroblastic Anemia
- I = IDA (Iron Deficiency Anemia)
- T = Thalassemia
- A = AOCD (Anemia of Chronic Disease)
- L = Lead Poisoning (type of Sideroblastic Anemia)

Iron Metabolism

- Iron from Food: Fe^{3+}
- Iron absorbed from the duodenum can't be in Fe^{3+} form
- Cytochrome b reductase converts Fe^{3+} to Fe^{2+}
- Fe^{2+} enters the duodenum via Divalent Metal Transporter -1 (DMT-1)
- Fe^{2+} gets into the blood via Ferroportin
- Fe^{2+} is converted back to Fe^{3+} by Hephaestin & Ceruloplasmin
- Transportation of iron occurs via Transferrin
- Transferrin Saturation: 33%
- Storage form of iron: Ferritin
- Master regulator of iron: Hepcidin

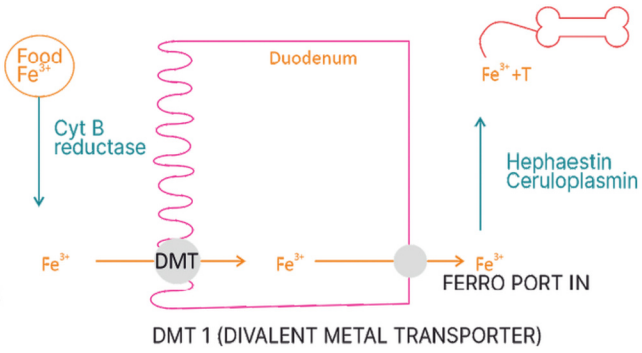

Iron Deficiency Anemia

00:19:33

Causes

NEET PG Aug 2024

- Diet (lack of iron in diet)
- Blood loss:
  - Trauma
  - PUD
  - Colon cancer
  - Menorrhagia
- Hookworm infection



Yourwish

- Spoon-shaped nails (Koilonychia)
- History of Pica

Blood Findings

- Low Hemoglobin
- Low MCV (microcytic anemia)
- Low MCH, MCHC (hypochromic anemia)
- High RDW (Anisocytosis)
- Low Serum Iron
- Low Transferrin Saturation
- Low Ferritin
- High TIBC (total iron binding capacity)
- Most Specific Test: Bone Marrow Studies
  - Stain: Prussian Blue Stain
- Peripheral Smear:
  - Microcytic hypochromic anemia with anisocytosis (variation in size) & poikilocytosis (variation in shape: pencil-shaped cell)

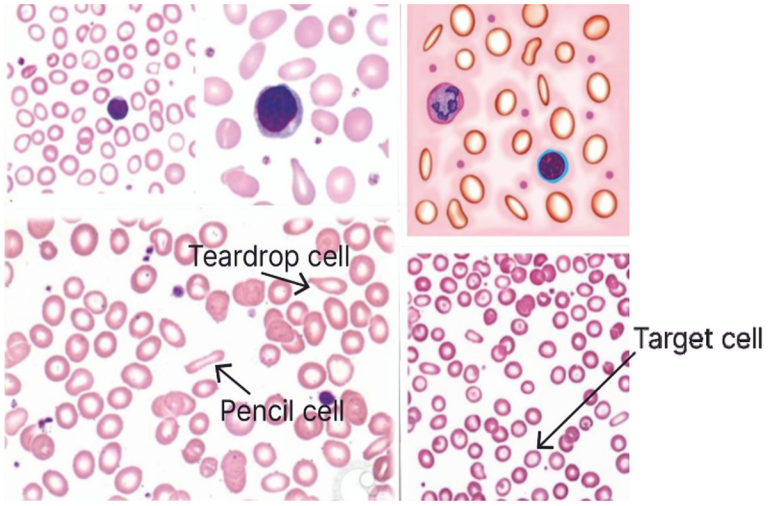

Anemia Of Chronic Disease

00:24:25

FMGE Jan 2024

Pathophysiology

Chronic diseases like Rheumatoid Arthritis (RA)

↓

Release of Interleukin (IL6)

↓

Act on the liver and release Hepcidin

↓

Inhibits Absorption of Iron (Inhibits ferroportin) &
Inhibits the release of iron from ferritin

↓

Serum Iron & Transferrin saturation will decrease

↓

TIBC (total iron binding capacity) will decrease, Ferritin will increase

Investigations & Management

- Peripheral Smear: Normocytic Normochromic Anemia >> Microcytic hypochromic anemia
- Management: Treat the underlying chronic disease

Features	Iron Deficiency Anemia (IDA)	Anemia of Chronic Disease (AOCD)	Sideroblastic Anemia
Serum Iron	Decreased	Decreased	Increased
Transferrin Saturation	Decreased	Decreased	Increased
Ferritin	Decreased	Increased	Increased
TIBC	Increased	Decreased	Decreased

Sideroblastic Anemia

00:29:35

FMGE June 2022
INICET Nov 2021

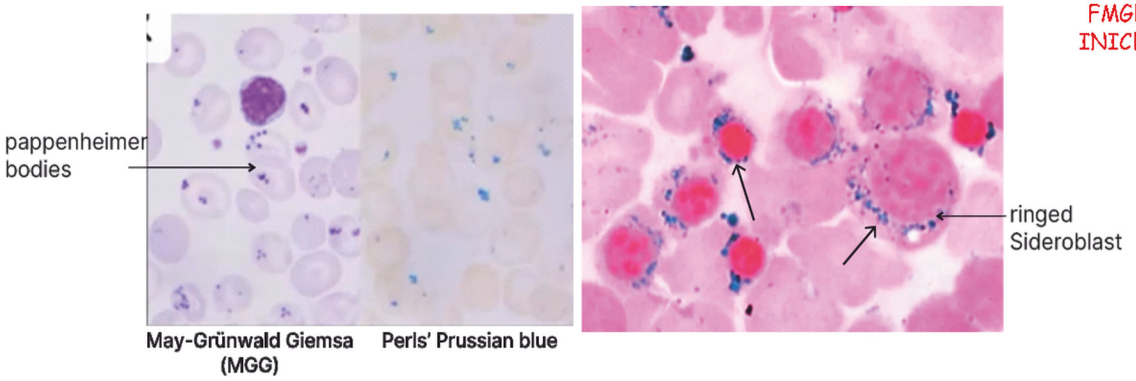

Pathophysiology

Succinyl Coenzyme-A

↓ (ALA synthase)

ALA

↓ (ALA dehydratase)

Protoporphyrin + Fe

↓ (Ferrochelatase)

Heme

Causes

- Enzyme deficiency
- Vitamin B_6 (co-factor) deficiency
- Isoniazid consumption
- Lead (Pb) poisoning
  - Inhibits ferrochelatase
- Alcohol poisoning
  - Inhibits ferrochelatase

Nvestigations

- Peripheral Smear
  - Pappenheimer Bodies (iron)
- Bone Marrow Studies
  - Ringed Sideroblasts on Perl's/Prussian blue stain
    → >= 5 iron granules make a ring around the nucleus, covering more than 1/3rd of the circumference of the nucleus

MACROCYTIC ANEMIA

00:34:19

Causes

- Lady: Liver Disease
- Harding: Hypothyroidism
- Medical: Megaloblastic Anemia
  - Pernicious Anemia
- College: Chemotherapy

Yourwish

Megaloblastic Anemia

- Occurs because of deficiency of Vitamin B_{12} and Folic acid (FA)
- B_{12} is absorbed from the terminal ileum with Intrinsic factor (IF)/Castle factor (parietal cells of the stomach)
- FA absorbed from the jejunum

Pernicious Anemia

- Antibodies form against the parietal cells of the stomach
- Inhibits the formation of intrinsic factors (IF)
- Prevents absorption of Vitamin B_{12}

Important Information

- Parasite infection that causes B_{12} deficiency: Diphyllobothrium Latum
- Hookworm infection causes iron deficiency anemia

Clinical Features

- Pure vegetarian or vegan patient
  - B_{12} is majorly in eggs, meat, milk in a normal diet
- Hyperpigmentation of phalanges & knuckles
- Neurological problems:
  - S - Sub
  - A - Acute
  - C - Combined (sensory and motor)
  - D - Degeneration



Biochemical Findings

- Increased Serum Bilirubin and LDH (due to hemolysis)
- Decreased Vitamin B_{12}
- Decreased Folic Acid
- Increased Homocysteine
- Increased Methylmalonyl CoA
- Anti-IF antibody (Pernicious Anemia)
- FIGLU test (measures folic acid levels in urine)

FMGE June 2021

Peripheral Smear Findings

- Macrocytic Macro-ovalocyte
- Howell Jolly Bodies:
  - Single
  - Composed of DNA remnant
  - Seen in:
    - → Megaloblastic Anemia
    - → Post-splenectomy
- Cabot ring:
  - Made up of arginine rich mitotic spindle
- Fine Basophilic Stippling
  - Seen in:

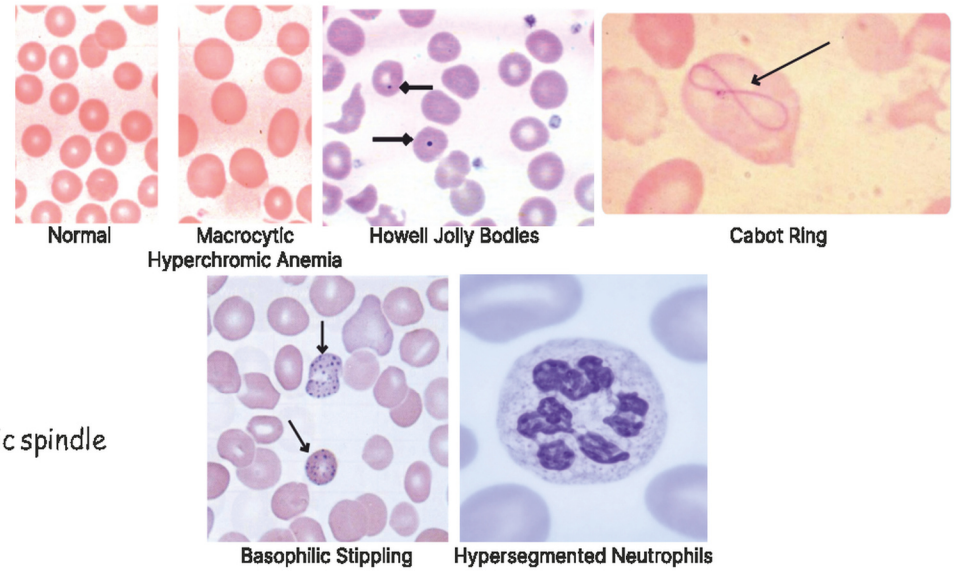

Yourwish

Yourwish

→ B_{12} deficiency
→ Thalassemia

- Coarse Basophilic Stippling is seen in lead (Pb) poisoning
- Hyper-segmented Neutrophil:
  - 1 Neutrophil with 6 or more lobes or 5% Neutrophil with 5 lobes Hemolytic Anemias (normal - 3 to 5 lobes)

HEMOLYTIC ANEMIA

00:43:54

FMGE Jan 2023

- Intravascular Hemolysis (inside blood vessel)
  - High LDH
  - Hemoglobinuria
  - Decreased Haptoglobin levels
  - Decreased Hemopexin levels
- Extravascular Hemolysis (in spleen, liver):
  - Splenomegaly
  - Gall stones

Rbc Membrane

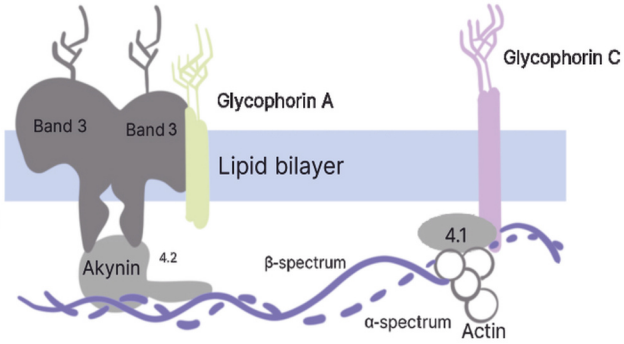

- Protein responsible for the biconcave shape of RBC: Spectrin
- Most abundant protein: Glycophorin
- Band-3 defect: Pincer cells (mushroom)

Hereditary Spherocytosis

00:46:51

- Most common defect: Ankyrin gene defect (AD)
- Most severe defect: Spectrin gene mutation (AR)
- Defect never seen: Glycophorin

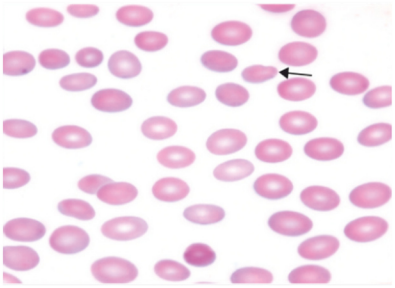

Pathophysiology

Normal shape of RBC: Biconcave
↓
Ankyrin gene defect
↓
Spherical RBC due to water loss
↓
Increased MCHC
↓
Lifespan decreases to 10-20 days
↓
RBCs lysed by the spleen
(Extravascular Hemolysis)

Yourwish

Clinical Features

- Jaundice
- Splenomegaly
- Gall stones

Diagnosis & Management

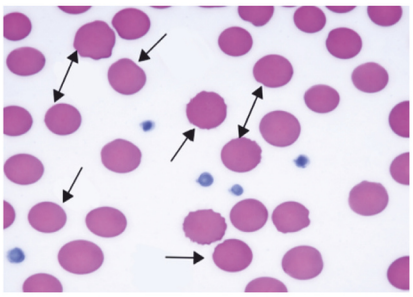

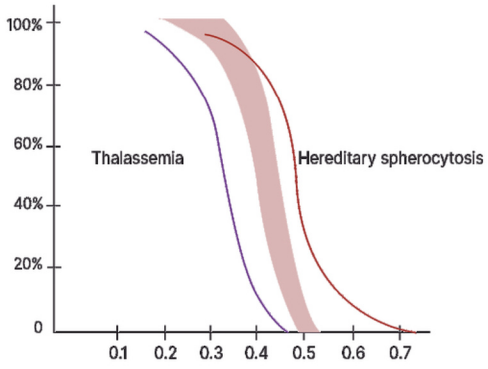

- Peripheral smear
  - Spherocytes
    - → MCC: Auto-immune hemolytic anemia
    - → 2nd MCC: Hereditary Spherocytosis
    - → 3rd MCC: G6PD deficiency anemia
  - Increased Reticulocyte count
  - Decreased MCV
  - Increased MCHC
  - Increased RDW
- Aplastic Crisis in Parvovirus B19 Infection
- Screening test: Osmotic Fragility Test
  - Normal RBC: Lysis starts at 0.5% NaCl and is completed by 0.3%
  - In HS: Lysis starts before 0.7% NaCl (right shift) due to increased fragility
- Confirmatory test: Eosin-5-Maleimide Test
  - Flow cytometry using Eosin-5-Maleimide dye
- Treatment
  - Splenectomy
    - → Give prophylactic vaccination for capsulated organisms like Neisseria meningitidis, Hemophilus influenzae, and Pneumococcus before splenectomy

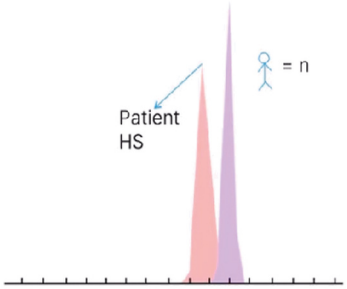

Other Shapes

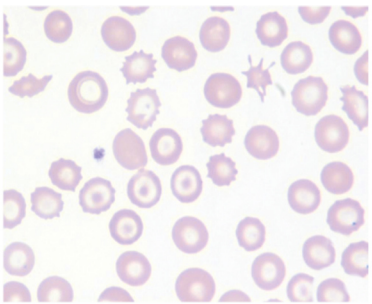

	Acanthocytes	Spurr Cell	Echinocytes
Also known as:	Target cells or Codocytes	Acanthocyte/spike cell	Burr cells
Seen in:	Thalassemia	Abetalipoproteinemia	Burns and Uremia

G6pd Deficiency

00:56:02

INICET May 2024

Causes

- X-linked recessive (XLR) disorder
- Seen more commonly in males
- Intermittent disorder
- Triggers:
  - Infections (MC)
  - Anti-malarial drugs
  - Fava beans consumption
- No splenomegaly
- No gallstones

Diagnosis

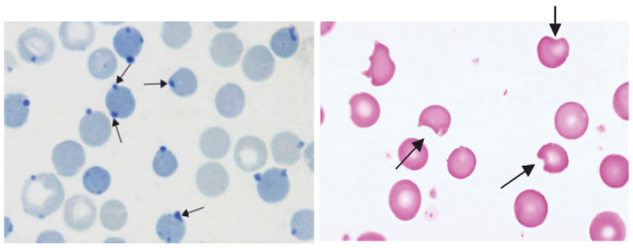

- Blood Findings:
  - Heinz Bodies (Denatured hemoglobin)
    → Crystal Violet stain
  - Bite cells/Degmacytes on Romanowsky stain
- Screening test:
  - Fluorescent spot test
  - Methemoglobin reduction test
- Confirmatory test: ELISA (G6PD levels)
- Romanowsky stain
  - Howell-Jolly Bodies (single dot) - Vitamin B12 Deficiency
  - Pappenheimer Bodies (multiple dots) - Sideroblastic Anemia

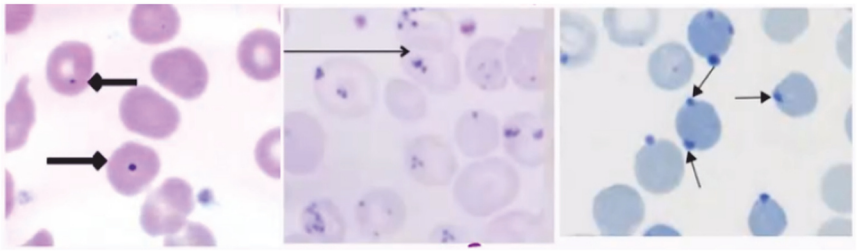

- Crystal Violet stain:
  - Heinz-bodies - G6PD Deficiency

Paroxysmal Nocturnal Hemoglobinuria

INICET Nov 2021
FMGE Jan 2026

01:01:01

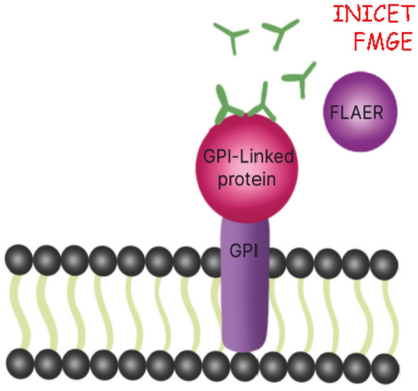

Causes

- Only acquired defect causing hemolytic anemia due to Intravascular hemolysis
- PIGA gene defect:
  - GPI anchors not formed, leading to the absence of:
    → CD55 (DAF)
    → CD59 (MIRL)
  - Decreased Leukocyte alkaline phosphate (LAP) enzyme

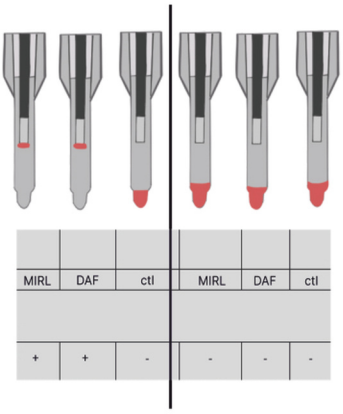

Diagnosis

- Screening test:
  - Ham's acidified serum test
  - Sucrose lysis test
  - Gel card test

Yourwish

- Confirmatory test:
  - Flow Cytometry: Dual Population of CD markers
    → CD 55 Negative, CD 59 Negative
    → CD 55 Positive, CD 59 Positive
  - FLAER: Measures GPI anchors

Complications

- Thrombosis
  - Cerebral vein thrombosis
  - Hepatic vein thrombosis (Budd-Chiari syndrome)
- Aplastic Anemia
- Acute Leukemia

Treatment

- Eculizumab: Acts like CD 55 & CD 59
- Curative treatment: Hematopoietic Stem Cell Transplant

HEMOGLOBINOPATHIES

01:07:02

Sickle Cell Anemia

INICET Nov 2024

Causes

- Autosomal Recessive condition
- Previously, it was thought to be due to the replacement of Glutamate by Valine at the Beta-6 position
- Latest advance: Replacement of Glutamate by Valine at Beta 7 position
- Types:
  - Sickle cell Trait (some Hb is sickled)
  - Sickle cell Anemia (all Hb is sickled)

Clinical Features

- Vaso-occlusion
- Skull: Crew-cut appearance/ hair on end
- Fish mouth vertebrae
- Auto-splenectomy

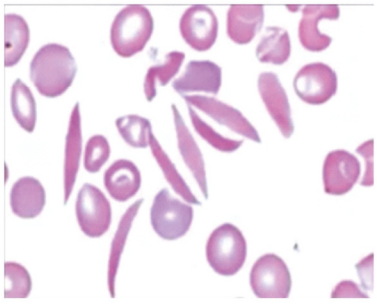

Diagnosis

- Peripheral Smear:
  - Sickle cells or Drepanocytes
    → Seen in sickle cell anemia
    → Not seen in sickle cell trait patients
- Sickling Test:
  - Blood reacts with 2% sodium metabisulfite → Induces hypoxia → Sickling occurs
- Hemoglobin Electrophoresis

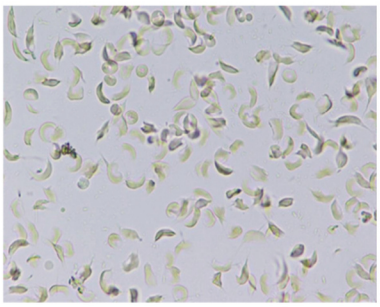

Yourwish

Yourwish

- H: Hemoglobin
- A: Adult Hb
- F: Fetal Hb
- S: Sickled Hb
- A: A_2 Hb

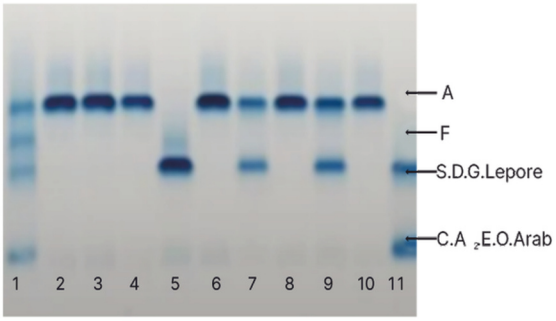

- HPLC (Gold standard investigation)

Treatment

- Hydroxyurea
  - Increases fetal hemoglobin (Increased oxygen affinity)

Hbc Disease

01:13:10

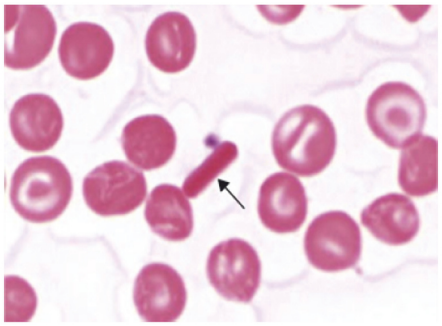

- At the beta-6 position, Glutamate is replaced by Lysine
- HbC crystals are seen

Thalassemia

01:14:02

- Normal adult hemoglobin: $\alpha_2\beta_2$
  - 2 alpha chains from 4 alpha genes on chromosome 16
  - 2 beta chains from 2 beta genes on chromosome 11
- Alpha gene deletion: α-Thalassemia
- Beta gene mutation: β-Thalassemia

Alpha Thalassemia

01:15:35

Alpha (α) Gene	Condition
αα/αα	Normal
αα/α-	Asymptomatic
αα/--	Alpha Thalassemia Trait (asymptomatic)
α-/-- with β-4 tetramers	HbH Disease Golf ball inclusions 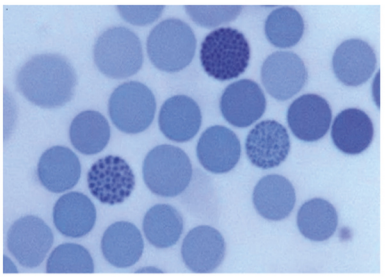
--/-- with γ-4 tetramers	Hb Bart's Disease • Results in intra-uterine death or Hydrops fetalis

Yourwish

Beta Thalassemia

01:18:08

NEET PG 2025
FMGE Jan 2023

- Splicing Mutations (MC)
  - MCC in India
  - In Introns (IVS), at codon 1-5, there is a change of G to C
- Frameshift Mutations
  - Codon 8/9
  - Codon 41/42
- Only Deletion
  - 619 base pair deletion

Types

Features	B -thalassemia major/cooley's anemia	B-thalassemia intermedia	B-thalassemia minor/trait
Clinical Features	• Require lifetime blood transfusion • Pallor • Jaundice • Splenomegaly • Chipmunk facies • Crew-cut/Hair-on-end appearance • Target cells/Codocytes on PBS	• Pallor • Jaundice • Splenomegaly	Asymptomatic
Hemoglobin Levels	3-5	5-8	>8
Iron Profile	Increased	Normal	Normal
Hb Electrophoresis & HPLC (Gold Standard)	HbF >90% ($\alpha_2\gamma_2$)	-	HbA_2 >3.5%



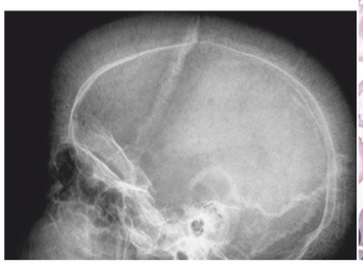

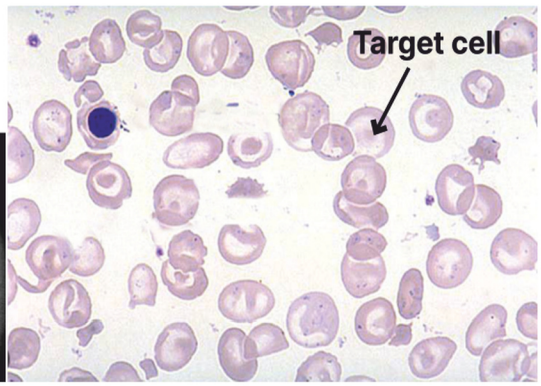

Iron deficiency anemia	Features	Beta-thalassemia minor
>13	**Mentzer Index (MCV/RBC)**	<13
Increases	**RDW**	Normal
<3.5%	**HbA_2 confirmation**	>3.5%

Nestrof Test

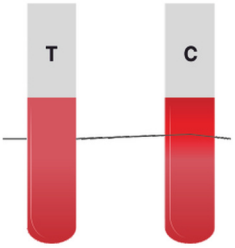

- Naked Eye Single Tube Red Cell Osmotic Fragility (NESTROF) Test
- Normal saline is added to red blood cells
  - Normal RBCs break down - Line visible
  - Thalassemia RBCs do not break down - Line not visible

AUTO-IMMUNE HEMOLYTIC ANEMIA

01:25:56

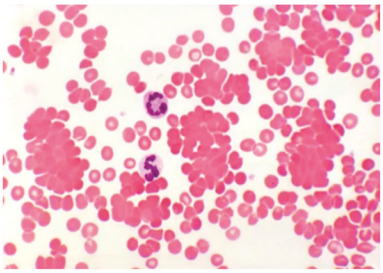

- Type II hypersensitivity disorder
- Two types of antibodies:
  - Warm antibodies (37°C): IgG
    → CLL
  - Cold antibodies (4°C): IgM
    → Mycoplasma infection
- Cold Hemolysin disease/Paroxysmal Cold Hemoglobinuria:
  - Occurs at 4°C
  - Due to IgG: Donath Landsteiner antibodies

SCHISTOCYTIC/ANGIOPATHIC HEMOLYTIC ANEMIA

01:29:50

- Schistocyte/ fragmented RBCs

Causes

Prosthetic heart valves ↓ RBC lysis ↓ Macro-angiopathic hemolytic anemia	Hemolytic Uremic Syndrome, TTP & DIC ↓ Micro-angiopathic hemolytic anemia

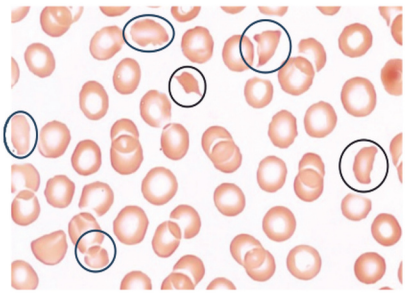

HEMOLYTIC ANEMIAS

01:31:22

Intravascular Hemolysis	High LDH Hemoglobinuria Decreased Haptoglobin Decreased Hemopexin PNH PCH G6PD Deficiency

Yourwish

Extra-vascular Hemolysis (Spleen, Liver)	Hereditary Spherocytosis Sickle Cell Anemia Thalassemia G6PD Deficiency
Intra-corpuscular Defect	Hereditary Spherocytosis G6PD Deficiency Hemoglobinopathies
Extra-Corpuscular Defect	AIHA MIHA

Dog-Ear Projections

01:32:44

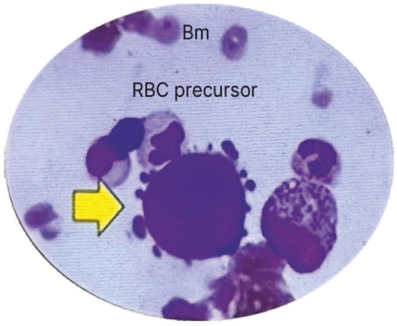

- RBC precursors in bone marrow show dog-ear projections are seen in:
- Parvovirus B19 infection

MCQS

01:33:09

Q. Which of the following needles is commonly used for bone marrow biopsy? INICET May 2022

a. Klima Needle
b. Salah Needle
c. Jamshidi Needle
d. Islam Needle

Answer: **c) Jamshidi Needle**

Q. What is the most likely diagnosis for an 18-year-old male with gum bleeding, fever for 2 months, pallor, low hemoglobin (3gm/dl), low TLC (1500/microL), low platelet count (15000/microL), macrocytes of peripheral smear, 0.5% reticulocyte count and bone marrow examination showing fatty streaks and lack of megakaryocytes but no immature cells? FMGE Dec 2021

a. Idiopathic acquired aplastic anemia
b. Paroxysmal nocturnal hemoglobinuria
c. Myelodysplastic syndrome
d. Tuberculosis

Answer: **a) Idiopathic acquired aplastic anemia**

Yourwish

Yourwish

Q. A female patient presents with fatigue and history of piles. Routine complete blood count analysis showed Hb 8.5gm/dL, MCV 65fL, RBC count 3.2 million, and increased RDW., A peripheral smear is given below. What is the next best investigation for this patient? FMGE Jan 2024

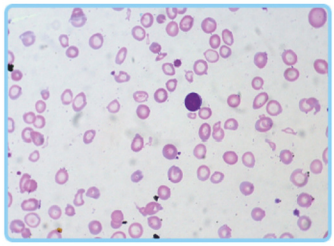

a. HbA2 levels
b. Serum ferritin levels
c. Serum folate levels
d. Serum homocysteine levels

Answer: **b) Serum ferritin levels**

Q. How is transferrin saturation affected in iron deficiency anemia? NEET PG Aug 2024

a. Increased
b. Decreased
c. Normal
d. Dynamic

Answer: **b) Decreased**

Q. A patient reports to the OPD with complaints of fatigue. Investigation results indicate HB 5.9 gm/Dl, increased RDW and TIBC, and low ferritin. What is the most likely diagnosis? FMGE Jan 2024

a. Sideroblastic Anemia
b. Iron Deficiency Anemia
c. Anemia of Chronic Disease
d. Hemolytic Anemia

Answer: **b) Iron Deficiency Anemia**

Q. In which of the following conditions is macrocytic anemia seen? FMGE June 2022

a. Thalassemia
b. Anemia of chronic disease
c. Sideroblastic anemia
d. Liver diseases

Answer: **D) Liver diseases**

Q. Which of the following is used in the treatment of sideroblastic anemia? INICET Nov 2021

a. Vitamin B12
b. Vitamin B6
c. Vitamin B1
d. Iron

Answer: **b) Vitamin B6**

Q. Which of the following is a feature of hemolytic anemia? FMGE Jan 2023

a. Increased Haptoglobin

Yourwish

b. Neutropenia
c. Reticulocytopenia
d. Decreased Haptoglobin

Answer: **d) Decreased Haptoglobin**

Q. Which of the following is not a feature of G6PD deficiency? INICET May 2024
a. Males & females are equally affected
b. Oxidative stress
c. Absence of NADPH
d. Presence of Heinz bodies

Answer: **a) Males & females are equally affected**

Q. Which mutation is seen in sickle cell anemia? INICET Nov 2024
a. Glu to Val (7)
b. Lys to Arg
c. Glu to Lysine
d. Glu to Val (6)

Answer: **a) Glu to Val (7)**

Q. A 16-year-old boy presents with jaundice and splenomegaly. His family had a similar illness during adolescence. His MCHC was high. What is the most likely diagnosis? NEET PG 2025
a. IDA
b. Hereditary Spherocytosis
c. Thalassemia major
d. AIHA

Answer: **b) Hereditary Spherocytosis**

Q. A 30-year-old pregnant woman with thalassemia trait visits the clinic for genetic counselling. Her husband is also confirmed to have thalassemia trait. Considering their genetic background, what is the likelihood of their next offspring having thalassemia? FMGE Jan 2023
a. 100%
b. 75%
c. 50%
d. 25%

Answer: **d) 25%**

1. WHITE BLOOD CELLS

WBC

00:00:04

- TLC 4000 - 11000 cells/cu.mm
- Decreasing order of DLC count
  - Neutrophils > Lymphocyte > Monocyte > Eosinophil > Basophil
  - Mnemonic: Never Let Monkeys Eat Bananas

Morphology Of Wbc

- Neutrophil
  - 3 -5 lobes
  - Hypersegmented neutrophil (> 5 lobes) → Vitamin B12 deficiency
  - Increased in Acute inflammation
- Lymphocyte
  - Increased in Chronic inflammation and TB
- Monocyte
  - Kidney-shaped nucleus
  - Increased in Malaria
- Eosinophil
  - Orange granules
  - Spectacle-shaped nucleus
  - Increased in allergic conditions and parasitic infections
- Basophil
  - Blue-black granules
  - Increased in CML

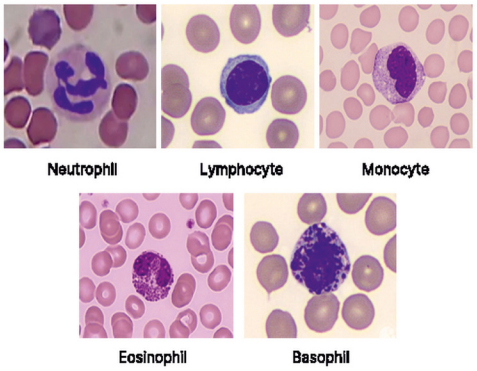

Important Information

- Dohle bodies → Dilated endoplasmic reticulum
  - Seen in sepsis
- Special stain used for visualization of basophils and mast cell → Toluidine blue

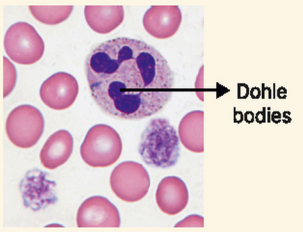

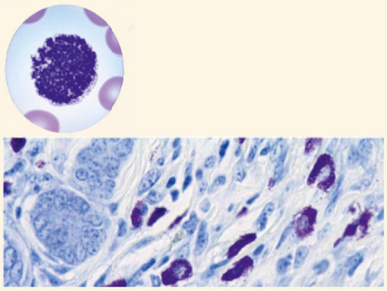

Development Of Wbc

- Myeloblast
- Lymphoblast
- Monoblast

Yourwish

Myeloblast lineage

Stages	Feature
Myeloblast ↓ Pro-myelocyte ↓ Myelocyte ↓ Meta-myelocyte ↓ Band / Stab form ↓ Granulocyte • Neutrophils • Eosinophils • Basophils	• Myeloblast ○ Auer rod → Lysosomal granules 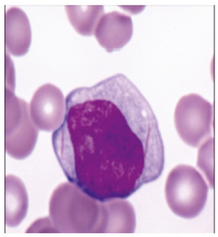 Myeloblast Auer Rods
	• Pro myelocyte ○ Largest cell 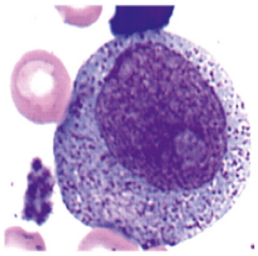 Promyelocyte
	• Myelocyte ○ D-shaped nucleus 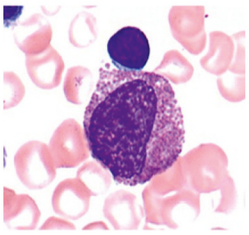 Myelocyte
	• Metamyelocyte ○ Indentation of the nucleus 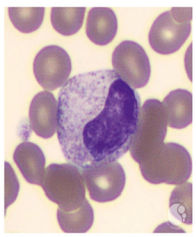 Metamyelocyte
	• Band/stab form ○ Deeper indentation of the nucleus 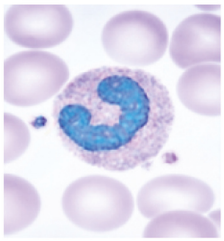 Band/Stab Form

Lymphoblast lineage

Lymphoblast

↓

Lymphocyte

Yourwish

Yourwish

Monoblast lineage

Monoblast

↓

Monocyte

Stains

INICET May 2022

- Myeloblast
  - MPO
  - Sudan black B
  - CAE (Cholroacetate esterase)
- Lymphoblast
  - Dot - Block positivity of PAS
  - Acid phosphatase → specific for T - lymphoblast
- Monoblast
  - NSE (Non-specific esterase)

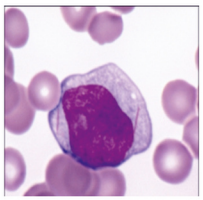

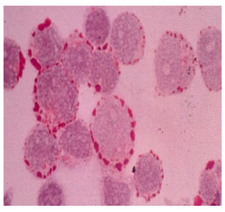

LEUKEMIA

00:06:25

- Acute leukemia: Blast > 20%
- Chronic leukemia: Blast < 20%
- MC in children → ALL
- MC in Down syndrome overall → ALL
- MC in Down syndrome < 3 years old → AML M7
- MC in elderly → CLL
- MC in west → CLL
- MC leukemia a/w radiation → AML
- Leukemia not a/w radiation → CLL

Acute Lymphoblast Leukemia (All)

INICET Nov 2024

- > 20% blast
- Stain
  - Dot and Block positivity of PAS
  - Acid phosphatase → specific for T - lymphoblast

Classification

Fab Classification	
L1	• Most common • Good prognosis
L2	
L3	• Least common • Worst prognosis • Vacuolated blast contains fat → Positive for Oil red O

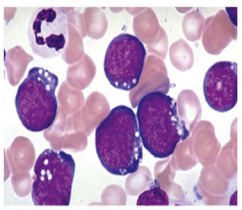

Yourwish

Who Classification	
B ALL	
T ALL	• Common in the teenage group • a/w NOTCH gene mutation • T ALL has infiltration into tissue → like CNS, Mediastinum, Testes • T ALL has a poor prognosis • Males have a poor prognosis

Genetics

- Good prognosis:
  - Hyperdiploidy (>2n)
  - Trisomy 4, 7, 10
  - t (12: 21)
- Poor prognosis:
  - Hypodiploidy

FMGE June 2022
NEET PG 2023

Acute Monoblastic Leukemia (Aml)

- >20% blast
- If a/w genetics, then classified as AML irrespective of blast count

Genetics

- t(8:21), t(15:17), inv 16

Fab Classification

- M0 - AML undifferentiated
  - MPO negative
- M1 - AML without maturation
- M2 - AML with maturation → MC type
  - a/w t(8:21)
  - Good prognosis
- M3 - Acute promyelocytic leukemia
  - a/w t(15:17) → fusion of PML - RARA gene
  - Faggot cells → maximum auer rods with criss-cross arrangement
  - a/w DIC
  - Treatment → ATRA (All trans retinoic acid) + Arsenic trioxide
  - Good prognosis
- M4 - Acute myelomonocytic leukemia
  - Presence of both myeloblast and monoblast
  - a/w inv 16
  - Tissue infiltration leads to → Gum hypertrophy and Leukemia cutis
  - Good prognosis
- M5 - Acute monoblastic leukemia
  - Tissue infiltration leads to → Gum hypertrophy and Leukemia cutis
- M6 - Pure erythroid leukemia

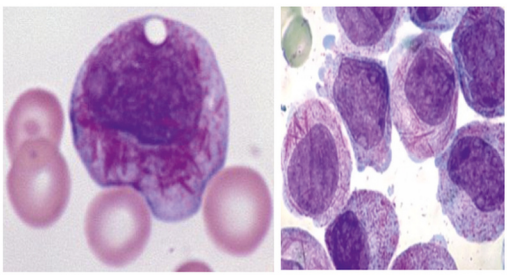

Faggot cells AML M3

- M7 - Acute megakaryoblastic leukemia
  - Least common
  - a/w BM fibrosis and Down's syndrome in less than 3 years of age

Stains

- AML M0 → MPO negative
- AML M4 → Dual esterase +
- AML M3, M6 and AML M7 → PAS +

Chronic Lymphocytic Leukemia (Cll)

- MC in the elderly
- MC in the west
- Del 13q → deletion of microRNA 15,16
- Not a/w exposure to radiation
- Criteria
  - Absolute lymphocyte count > 5000cells/mm^3
  - Flow cytometry → CD5+ , CD23+ , Cd200+
  - BM biopsy → Lymphocyte >30%
- Peripheral smear
  - Presence of only lymphocytes → Convent school girl appearance
  - Smudge / Basket / Parachute cell is an artefact → present due to loss of vimentin
- Staging of CLL → Rai & Binet
- Evan's syndrome
  - Warm AIHA + CLL + ITP
- Richter syndrome
  - CLL in the lymph node is called SLL (Small lymphocytic lymphoma)
  - CLL / SLL changed to DLBCL (Diffuse large B cell lymphoma)

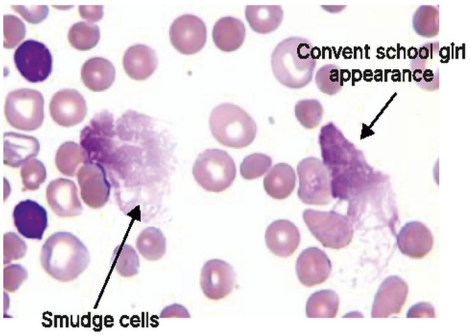

Chronic Myeloid Leukemia (Cml)

INICET Nov 2022
FMGE Dec 2021

Pathology

Reciprocal translocation
↓
t(9:22) → Philadelphia chromosome
↓
Fusion of the BCR-ABL gene
↓
Increased tyrosine kinase

Weight of the protein	Disease
190KD	Acute Lymphoblastic Leukemia
210KD	Chronic myeloid leukemia
230KD	Chronic neutrophilic leukemia

Yourwish

Clinical Features

- Massive splenomegaly leading to a dragging sensation of the abdomen
- Phases of CML
  - Chronic → Blast < 10%
  - Accelerated → Blast 10-19%
    → Basophils >20%
    → Increased TLC
    → Platelets may be increased or decreased
    → Massive splenomegaly
    → Unresponsive to treatment
  - Blast crisis → Blast >20%
    → CML changed to AML > ALL

FMGE June 2024

Investigations

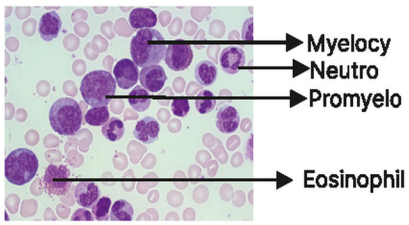

- Peripheral smear
  - Leucocytosis with shift to the left → Immature cells
  - College girl/garden party appearance
- FISH - Fluorescent in situ hybridization → IOC
  - ABL gene - Red, BCR gene - green
  - Fusion of ABL BCR gene → change in color is seen
- Screening test
  - LAP / NAP → Leucocyte alkaline phosphatase / Neutrophil alkaline phosphatase
  - Normal is 40 - 100

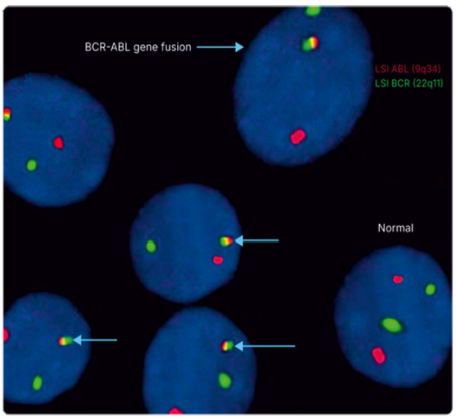

Decreased NAP / LAP	Increased NAP / LAP

• CML
• PNH
	• Leukamoid reaction
	  ○ Increase in TLC count
	  ○ Seen in sepsis
	• Pregnancy
	• OCP
	• Neutrophilia
	• Down's syndrome

Treatment

- Imatinib
  - Tyrosine kinase inhibitors
  - Used in CML and GIST

Yourwish

Yourwish

LYMPHOMA

00:30:52

Development Of B Cell

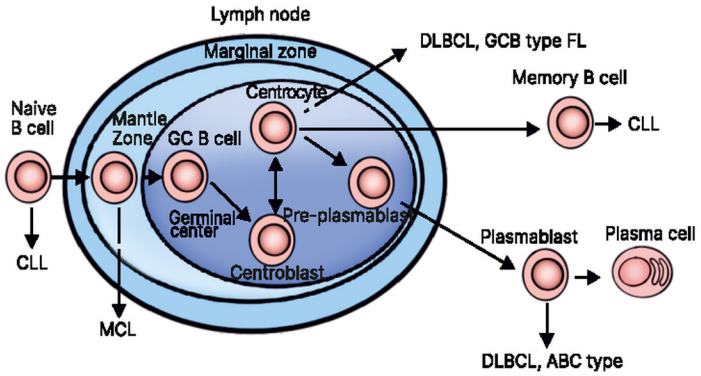

Naive B cell
↓
GC B cell
↓
Centroblast
↓
Centrocyte
↙ ↘
Memory B cell Plasma cell

Origin Of Lymphoma

Lymphoma	Origin
CLL / SLL	Naive B cell
Mantle cell lymphoma	Mantle zone / unchallenged zone
Marginal zone lymphoma	Marginal zone
Follicular lymphoma	Germinal centre
Burkitt lymphoma	
DLBCL	
Hodgkin's lymphoma	Post germinal centre
Multiple myeloma	Plasma cell
Hairy cell leukemia	Memory B cell

Classification

- Hodgkin's lymphoma
  - Classical Hodgkin's lymphoma
  - Non-classical Hodgkin's lymphoma
- Non-Hodgkin's lymphoma
  - B-NHL
  - T-NHL

Yourwish

Hodgkin's Lymphoma

INICET 2021, 2024

- Classical Hodgkin's lymphoma → a/w EBV
- Non-classical Hodgkin's lymphoma →Not a/w EBV

Classical Hodgkin's lymphoma		
	RS cell Positive for CD 15,30, PAX5 Sensitive marker - CD 30 Specific marker - PAX 5	**Other features**
Nodular sclerosis	Lacunar RS cell → RS cell surrounded by empty space 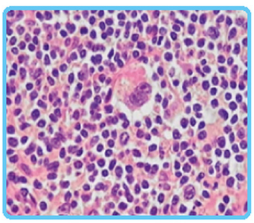 Lacunar RS	• MC in the world • Mediastinal involvement • Best prognosis in classical HL
Mixed cellularity	Classical RS cell → owl eye appearance 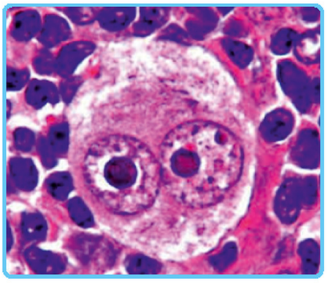 Owl Eye Classical RS	• MC in India • MC a/w EBV and HIV
Lymphocyte rich	Mononuclear RS cell	
Lymphocyte depleted	Mummified RS cell	• a/w Immunodeficiency • Worst prognosis
Non classical hodgkin lymphoma		
	RS cell Positive for CD20 , CD45 , EMA , Bcl6	**Other features**
Nodular lymphocyte predominant Hodgkin's lymphoma	Popcorn / L&H RS cell 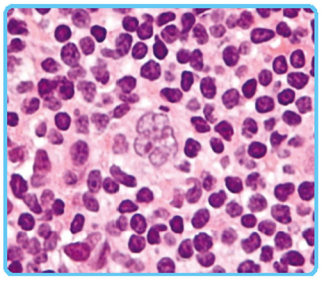 Popcorn RS	• Best prognosis overall

Non-Hodgkin's Lymphoma

NEET PG 2021, 2023

- B-NHL
  - Follicular lymphoma
  - DLBCL
  - Burkitt's lymphoma
  - CLL/SLL
  - Mantle cell lymphoma
  - Marginal zone lymphoma / MALToma
  - Hairy cell leukemia
- T-NHL
  - Anaplastic large cell lymphoma
  - Mycosis fungoides

	Genetics	Markers	Features
B cell NHL			
Follicular lymphoma	t(14:18)	Bcl2 ↑	• Best prognosis
DLBCL			• Most common • Worst prognosis • Richter's syndrome ○ CLL/SLL → DLBCL

Burkitt's lymphoma	t(8:14) , t(8:22) , t(2:8)	cmyc , ki67 - 100%	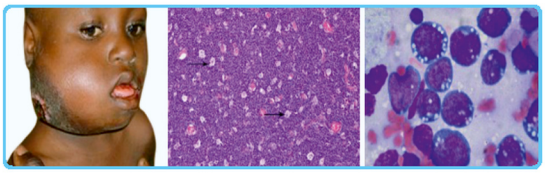
			• Endemic in Africa
			• Child with jaw swelling
			• a/w EBV
			• P/S → vacuolations containing fat
			  ○ Oil red O +
			• Biopsy → Starry sky appearance
			  ○ Star - macrophage
			  ○ Sky - tumor cell
			• Highly proliferative

CLL/SLL		CD5+ ,CD23+ , CD200+	
Mantle cell lymphoma	t(11:14)	CD5+ ,CD23- , CD200- , cyclin D1+ , SOX 11+	
Marginal zone lymphoma / MALToma	t(11:18)	CD5- ,CD23- , CD200-	

Yourwish

Hairy cell leukemia 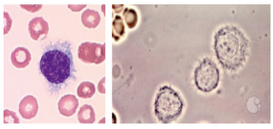	BRAF V600E mutation	Annexin A1 , TRAP+ , CD11+,CD25+ ,CD103+ New marker: DBA44 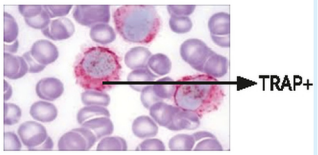	• MC in boys • Massive splenomegaly ○ Enlargement of red pulp of the spleen • Infections with MAC • P/S → pancytopenia • BM aspirate → Dry tap • BM biopsy (IOC)→ Fried egg appearance 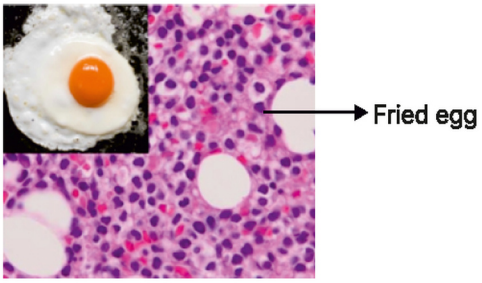
T cell NHL			
Anaplastic large cell lymphoma	t(2:5) ALK gene	CD30+	• P/S → Doughnut cell, indentation of the nucleus 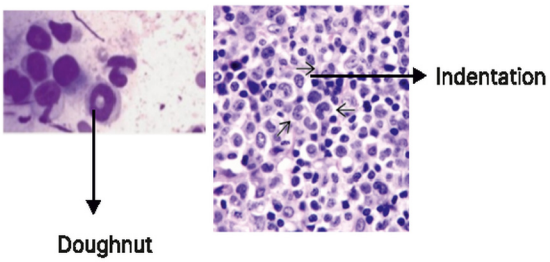

Mycosis fungoides			• Cutaneous TNHL
			 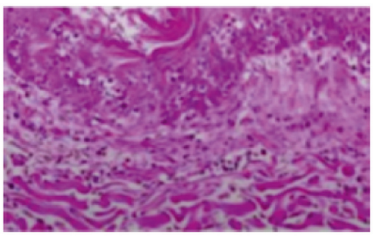
			  ○ Skin biopsy → Pautrier's microabscess
			• Tumor cell in blood → Sezary syndrome
			 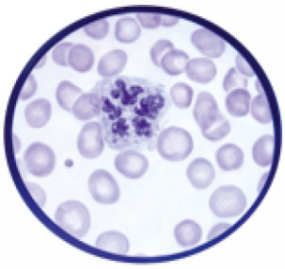
			  ○ Cerebriform / sezary cell

Yourwish

Yourwish

Important Information

- Munro's microabscess → Psoriasis
- Pautrier's microabscess → Mycosis fungoides

PLASMA CELL

00:50:21

- Eccentric nucleus
- Cartwheel chromatin
- Perinuclear halo → increased Golgi apparatus with increased immunoglobulin

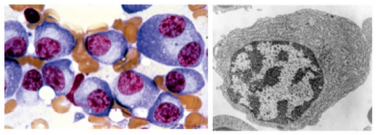

Multiple Myeloma

NEET PG Aug 2024

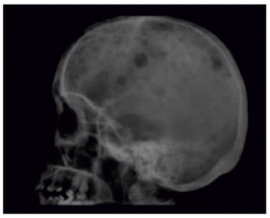

- BM plasma cell > 10%
- Immunoglobulin > 3gm → MC Ig is IgG
- Myeloma-defining events
  - C - Hypercalcemia
  - R - Renal insufficiency → elevated serum creatinine
  - A - Anemia
  - B - Bony lytic lesion
  - S - >60% of plasma cells
  - Li - Light chain is excreted in urine → Bence-Jones proteinuria
  - M - MRI >5mm
- P/S → Roulex formation (stack of coins appearance)

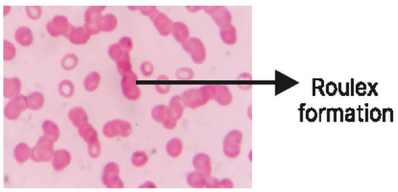

- Bone marrow

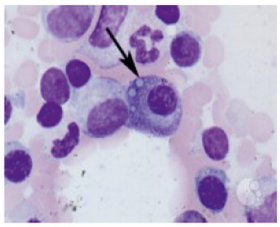

Russell body

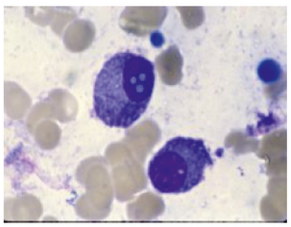

Dutcher body

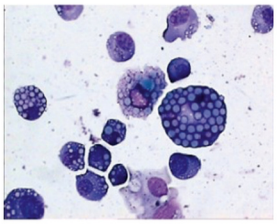

Mulberry/Mott cell

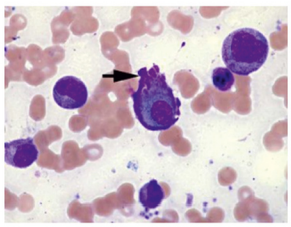

Flame cell

  - Russel bodies: Intracytoplasmic inclusions → composed of IgG immunoglobulin
  - Dutcher bodies: Intranuclear inclusions → composed of IgG immunoglobulin
  - Mulberry / Mott cell → composed of IgG immunoglobulin
  - Flame cell → composed of IgA immunoglobulin
- Serum protein electrophoresis → M spike is seen

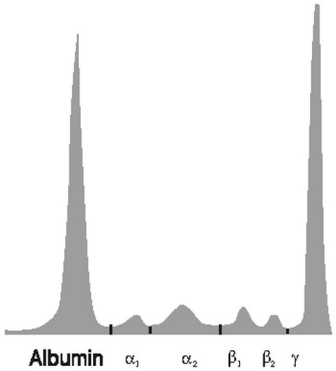

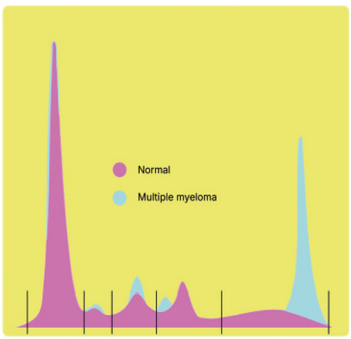

Yourwish

- Immunofixation → Detect the type of antibodies

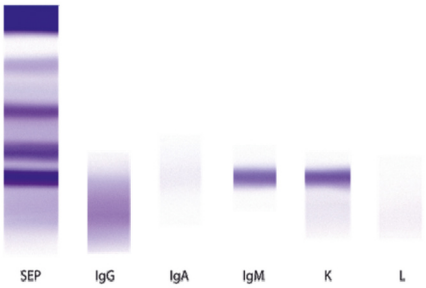

- Flow cytometry
  - Normal plasma cells → CD45+ , CD19+ , CD38+ , Cd138+
  - Malignant plasma cells → CD45- , CD19- , CD38+ , Cd138+

Plasma Cell Leukemia

- >5% of plasma cells in the peripheral blood

Waldenstrom Macroglobulinemia

- a/k/a Lymphoplasmacytic lymphoma
- IgM is elevated
- Lymphocyte, Plasma cells, Mast cells are present
- Mutation of MYD88
- Clinical features
  - Hyperviscosity due to the elevation of IgM
    → Hypertension
    → Visual disturbance

FLOW CYTOMETRY

00:58:57

- a/k/a Immunophenotyping

Principle

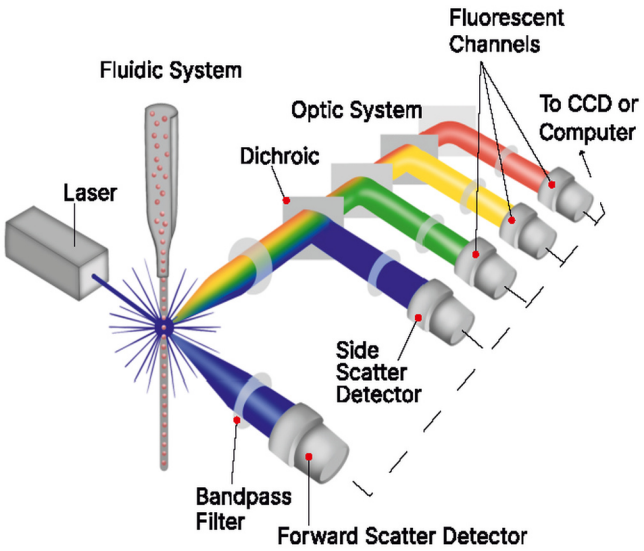

- Hydrodynamic focussing
- Blue light of wavelength 488 nm strikes the particles, which are passed one after another

- Forward scatter is observed
  - Depends on the size of the particles
  - Increase in size leads to an increase in forward scatter
- Side scatter is observed
  - Depends on complexity/granularity
  - Increase in complexity leads to an increase in side scatter
- The fluorescent dye present is FITC (Fluoro-iso-thio-cyanate)

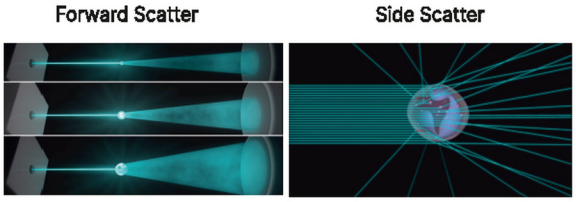

Interpretation

- Dot plot
  - Double positive → M1+ , M2+
  - Double negative → M1- , M2-
  - M1+
  - M2+
- Histogram

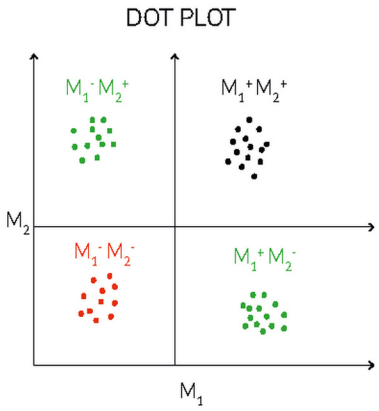

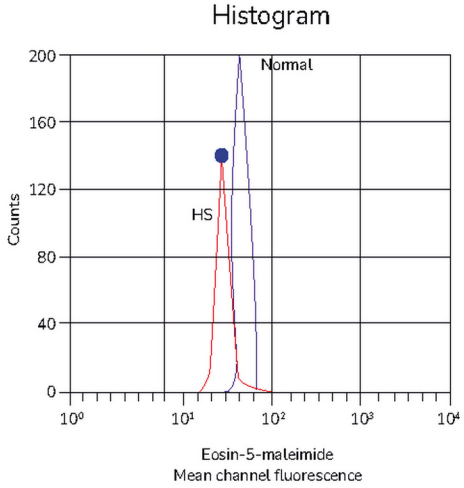

SUMMARY

01:02:17

Lineage	Markers
Blasts	TDT , HLA DR , CD34
LCA	CD45
T cells	CD1-8 , CD28 (Pan T → CD3)
B cells	CD10(CALLA) , CD19-23 , CD40 , CD79a , CD79b (Pan B → CD19)
NK cells	CD16 , CD56 , CD94
Myeloid cells	MPO , CD13 , CD33
Monocytic lineage	CD11 , CD14 , CD64
Megakaryocytic lineage	CD41 , CD42 , CD61
CLL/SLL	CD5+ , CD23+ , CD200+

Yourwish

Mantle cell lymphoma	CD5+ , CD23- , CD200-
Marginal zone lymphoma/ MALToma	CD5- , CD23- , CD200-
PNH	CD55- , CD59-
Plasma cells	CD45+ , CD19+ , CD38+ , CD138+
Multiple myeloma	CD45- , CD19- , CD38+ , CD138+
T-ALL	TdT , CD3
B-ALL	TdT , CD19
AML	HLA DR , MPO
Biphenotypic leukemia	HLA DR , CD3 , MPO

Q. Dot plot analysis?

a. MZL
b. MCL
c. CLL
d. AML

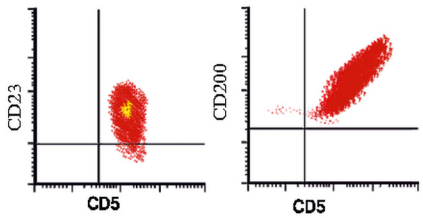

Answer: c. **CLL**

PYQ

01:06:40

INICET Nov 2024

Q. A young child presents with bleeding gums and bruising for the past two weeks. Bone marrow biopsy and flow cytometry have been performed. What is the diagnosis?

a. Acute myeloid leukemia
b. CLL
c. ALL: B Phenotype
d. ALL: T Phenotype

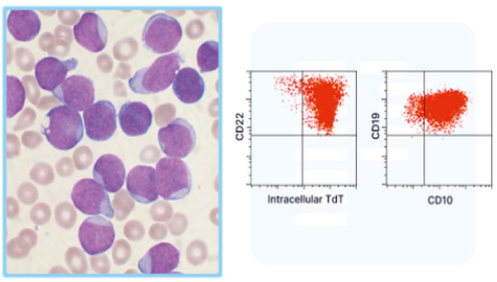

Answer: c. **ALL: B Phenotype**

Q. A 38-year-old man presented with bleeding gums for 20 days. He has gingival hyperplasia and hepatosplenomegaly. On investigation, Hb-11 g/dL, platelet count-95,000 platelets/mm3, and WBC count-45000 cells/mm3. A bone marrow biopsy shows 100% cellularity, with many blast cells that are peroxidase-negative and non-specific esterase-positive. The most likely diagnosis is:

FMGE June 2022

a. Acute myeloid leukemia M2 (AML M2)
b. Acute myeloid leukemia M0 (AML M0)
c. Acute myeloid leukemia M5 (AML M5)
d. Acute myeloid leukemia M7 (AML M7)

Answer: c. **Acute myeloid leukemia M5 (AML M5)**

Yourwish

Yourwish

Q. A 25-year-old male presented with low haemoglobin, a platelet count of 25,000/mL, gum bleeding, and raised PT and aPTT. The image of his peripheral smear is shown below. What is the likely diagnosis? NEET PG 2023

a. AML with t(8;21)
b. AML with inv(16)
c. AML with t(15;17)
d. AML with t(11;22)

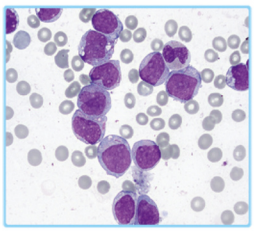

Answer: c. AML with t(15;17)

Q. Investigations of a patient being evaluated for leukaemia revealed a WBC count of 450,000/µL, with eosinophilia and basophilia. What is the likely diagnosis in this case? INI CET Nov 2022

a. Acute Lymphoblastic Leukemia (ALL)
b. Chronic Myelogenous Leukemia (CML)
c. Chronic Lymphocytic Leukemia (CLL)
d. Acute Myelogenous Leukemia (AML)

Answer: b. Chronic Myelogenous Leukemia (CML)

Q. A 30-year-old male presents with fatigue for the past year. Examination reveals massive splenomegaly. His blood workup shows the following findings: FMGE Dec 2021

- Anemia
- Total leukocyte count (TLC): 150,000/microliter
- Peripheral smear : 60% neutrophils, 6% basophils, 4% eosinophils, myeloblasts, myelocytes, and metamyelocytes
- Myeloid to erythroid ratio: 18:1

Q. What is the most likely diagnosis?

a. Acute Lymphoblastic Leukemia (ALL)
b. Acute Myeloid Leukemia (AML)
c. Chronic Myelogenous Leukemia (CML)
d. Chronic Lymphocytic Leukemia (CLL)

Answer: c. Chronic Myelogenous Leukemia (CML)

Q. Which mutation is linked to the Philadelphia chromosome?

a. Inversion
b. Deletion
c. Reciprocal translocation
d. Insertion

Answer: c. Reciprocal translocation

Q. Mark the incorrect statement regarding Hodgkin Lymphoma: INICET May 2024

a. Reed-Sternberg cells are of B-cell origin
b. Waldeyer's ring is involved
c. Nodular sclerosing is the most common subtype and involves the mediastinum

Yourwish

d. CD 15, 30 Positivity in Reed Sternberg cells

Answer: b. Waldeyer's ring is involved

Q. A 6-year-old boy came with bilateral cervical lymphadenopathy. What is the probable diagnosis, cell, and virus associated with the image given below?

INICET July 2021

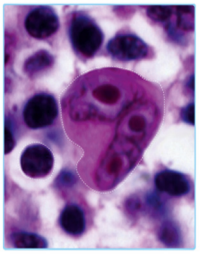

a. Non-Hodgkin's lymphoma, RS cell, EBV
b. Kaposi sarcoma, Giant cell, HIV
c. Hodgkin's lymphoma, RS cell, EBV
d. Infectious mononucleosis, RS cell, CMV

Answer: c. Hodgkin's lymphoma, RS cell, EBV

Q. A 54-year-old patient presents to the outpatient department with fatigue, tiredness, and cervical lymphadenopathy. The TLC and DLC were normal, with no immature cells. A lymph node biopsy showed diffuse effacement of the lymph node architecture and cells with an indented nucleus and prominent nucleolus that are atypical. CD10 and BCL2 are positive. What is the likely diagnosis?

INICET July 2021

a. Follicular lymphoma
b. Burkitt lymphoma
c. Mycosis fungoides
d. Chronic myeloid leukaemia

Answer: a. Follicular lymphoma

- Follicular lymphoma a/w t(14:18)

Q. An African child is found to have a mass in the jaw. A biopsy of the mass was done, and it appears as shown in the image below. The child also has a translocation, t(8;14). What is the probable diagnosis?

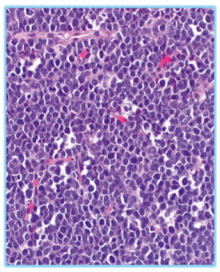

a. Acute myeloid leukemia
b. Follicular lymphoma
c. Multiple myeloma
d. Burkitt lymphoma

Answer: d. Burkitt lymphoma

Q. An elderly patient presents with elevated calcium levels, increased serum creatinine levels, and decreased hemoglobin. Electrophoresis reveals a monoclonal spike. Her immunofixation test findings are given below. Which of the following best describes her condition?

NEET PG Aug 2024

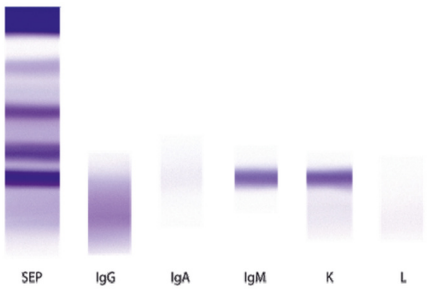

a. Multiple myeloma with increased IgG
b. Multiple myeloma with increased IgM
c. Multiple myeloma with increased IgA
d. Monoclonal gammopathy of unknown significance

Answer: b. Multiple myeloma with increased IgM

14. PLATELETS

HEMATOLOGY – PLATELET AND COAGULATION PATHWAY

00:00:13

- Normal platelet count → 1.5-4.5 lakhs/mm3
- Precursor of platelet in BM → Megakaryocyte

Types of Megakaryocytes

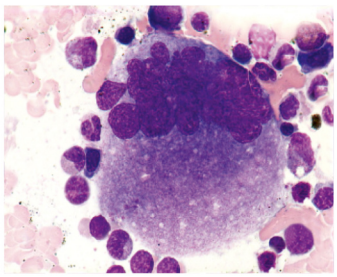

Normal Megakaryocyte



Staghorn Megakaryocyte

- Seen in Essential Thrombocythemia

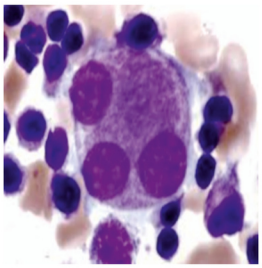

Pawn Ball Megakaryocyte

- Seen in Myelodysplastic Syndrome

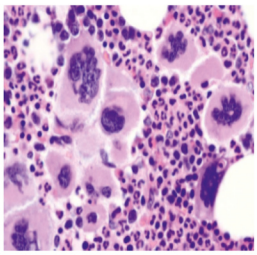

Cloud-like Megakaryocyte

- Seen in Primary Myelofibrosis

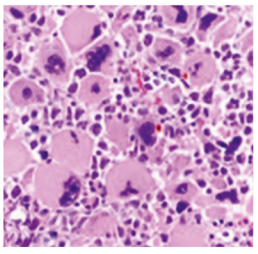

Dwarf like Megakaryocyte

- Seen in CML

Clot Formation - Platelet

00:01:25

1. Platelet Adhesion:

- GpIb/IX → Present on the surface of platelets
- VWF → Present in the endothelial cells → Released after injury to the cells
- Binding of GpIb/IX to VWF → Platelet adhesion

2. Platelet Secretion:

- Release of granules by the platelets

Yourwish

Granules	δ/Dense Granules
• P-Selectin • PF4 • PDGF • Factor - 5,8,1(fibrinogen)	• ADP, ATP • Serotonin • Epinephrine • Calcium

3. Platelet Aggregation:

- Formation of the primary plug with the help of GpIIB/IIIA
- GpIIB/IIIA → Binds to Fibrinogen → Formation of the Primary plug.
  - Two GpIIB/IIIA molecules won't get attached to each other

4. Activation of the Clotting Pathway:

- For the activation of clotting, → Platelets need a -ve charge on the surface

Flipping of Phosphatidyl Serine
↓
-ve Charge
↓
Activates Intrinsic Pathway

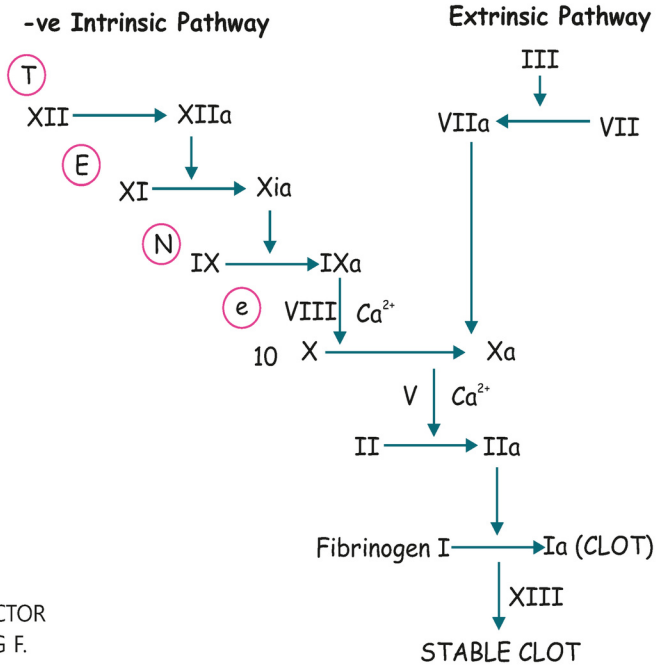

UMB.CORD BLEED
T ⊖
F13: LAKI LORAND FACTOR
or FIBRIN STABALISING F.

The Stable clot formed is called the secondary plug

- Factor 13 → Laki Lorand Factor/Fibrin Stabilising Factor
  - Deficiency → Umbilical cord bleeding
- Factor 6 → Does not exist
- Factor 4 → Calcium
- Vitamin K-dependent factors → 2,7,9,10

Tests for Clotting

00:07:40

- **BT → Bleeding Time**

Yourwish

Yourwish

  - Normal → 2-9 minutes
  - Measures platelets (Example: Dengue →↓ plt count)
    → If Platelet count ↓→ BT ↑
- **CT → Clotting Time**
  - Normal → 8-15 minutes
- **PT → Prothrombin Time**
  - Normal → 11-16 seconds
  - Measures the Extrinsic pathway
- **APTT → Activated Partial Thromboplastin Time**
  - Normal → 25-35 seconds
  - Measures the intrinsic pathway
- **TT → Thrombin Time**
  - Measures F1 (fibrinogen)
- **Urea clot solubility test**
  - Measures F13



To measure PT & APTT
→ Sample collected in
Light Blue vacutainer

Platelet Defects

Functional

- Platelet count → Normal

Defect	Disease
GpIb/IX	Bernard Soulier Sx
GpIIb/IIIa	Glanzmann Thrombasthenia
Alpha granule defect	Grey Platelet Sx
Delta granule defect	Hermanski Pudlak Sx (Oculo-cutaneous Albinism)

- Bernard Soulier Sx & Glanzmann Thrombasthenia → Big/Giant platelets
- Small platelets → Wiskott Aldrich Sx

Platelet Defects - ITP

- IgG Ab directed against Gp Ib/IX and Gp IIb/IIIa receptors on the surface of platelets.

Feature	Acute ITP	Chronic ITP
Age	Child	Adult
H/o Viral Infection	+	-
Platelet Count	< 50,000	Very low ↓↓
Resolution	< 6 months (Typically self-limiting)	> 6 months (Chronic course)
Treatment	Supportive	Steroids

- BM of ITP shows: Megakaryocytic Hyperplasia

Yourwish

Hemophilia

INICET May 2023, Nov 2023, May 2024
FMGE Dec 2021

- H/o Knee joint swelling (Bleed +)

Hemophilia A	Hemophilia B / Christmas Disease
Deficiency: F8	Deficiency: F9
PT → Normal APTT: ↑	PT → Normal APTT: ↑
Treatment: Cryoprecipitate Inj. Humate	Treatment: Fresh Frozen Plasma

- Hemophilia A and B → XLR disorder
- Hemophilia C → AR → Factor 11 deficiency
- Parahemophilia → Factor V deficiency

Von Willebrand Disease

00:14:40
INICET May 2025

- Autosomal Dominant
- vWF Function:
  - Platelet Adhesion
  - Carrier of F8 (Protects Factor VIII from degradation)
- Lab findings:
  - BT ↑ (Adhesion defect)
  - APTT ↑ (Secondary deficiency of Factor VIII)
  - PT → Normal
- Treatment → Cryoprecipitate (F1,F13,F8,vWF)

Lab findings in Platelet Disorders

Disease	Platelet Count	BT	PT	APTT
Bernard Soulier Syndrome	(N)	↑		
Glanzmann Thrombasthenia	(N)	↑		
ITP	↓	↑		
Hemophilia A (F8 -)				↑
Hemophilia B (F9 -)				↑
vWD		↑	(N)	↑

PYQs

00:16:55
INICET May 2024

Q. Which of the following is used in the treatment of Hemophilia B?

a. Factor 9
b. Cryoprecipitate
c. Factor 8
d. Tranexamic acid

Ans: a. Factor 9

Q. A 26-year-old female presents with menorrhagia and excessive bleeding after a minor surgery. She gave the history of her father and sister having the same bleeding issues and the pattern of inheritance was determined to be autosomal dominant. What is the most likely disorder? INI CET Nov 2023

a. Von Willebrand disease
b. Hemophilia A
c. Christmas disease
d. Factor 10 deficiency

Ans: a. Von Willebrand disease

Q. A 26-year-old female with a bleeding disorder following autosomal dominant inheritance. She gave the history of her father and sister having the same bleeding disorders. What is the most likely disorder? INICET May 2023

a. Von Willebrand disease
b. Hemophilia A
c. Christmas disease
d. Factor X deficiency

Ans: a. Von Willebrand disease

Q. What is the pattern of inheritance for Hemophilia A? FMGE Dec 2021

a. X-linked recessive
b. X-linked Dominant
c. Autosomal dominant
d. Autosomal recessive

Ans: a. X-linked recessive

Yourwish

16. BLOOD BANKING AND TRANSFUSION MEDICINE

BLOOD GROUP GENETICS

00:00:10

- The blood groups → given by Landsteiner
- A, B, AB, and O Blood Groups: Determined by Chromosome 9.
- H Gene
  - Essential precursor for ABO expression.
  - Determined by Chromosome 19.
- Rh (D) Antigen
  - Determines positive/negative status.
  - Located on Chromosome 1
- H Ag is present in all blood groups

INICET May 2024

	Group A	Group B	Group AB	Group O
Red blood cell type				
Antibodies in plasma	Anti-B 	Anti-A 	None	Anti-A and Anti-B 
Antigens in red blood cells	A antigen 	B antigen 	A and B antigen 	None

- Bombay Blood Group
  - Condition: Absence of A, B, and H antigens.
  - Antibodies: Anti-A, Anti-B, and Anti-H present
  - Transfusion: Can only receive blood from another Bombay blood group donor
  - Association: Leukocyte Adhesion Deficiency (LAD) Type 2
- H/o Trauma (Goal: Rapid transfusion without prior grouping)
  - Whole Blood/RBCs: O negative (lacks A and B antigens).
  - Fresh Frozen Plasma (FFP): AB group (lacks Anti-A and Anti-B antibodies) → safest for emergency needs

BLOOD GROUPS & BLOOD TYPING

00:03:00

- Antisera Color Coding (Mnemonic: BIG)
  - Anti-A: Blue
  - Anti-B: Yellow
  - Anti-D (Rh): Grey/Clear
  - Anti-Human Globulin (AHG): Green (used for Coombs test)
- Procedure & Interpretation



Yourwish

- Control:
  → Blood sample + normal saline
  → Should not clot
- Interpretation:
  → If clotting occurs → test invalid
  → Control must remain clear (non-clotted) for reliable results
- Interpretation based on agglutination (clotting):
  → Anti-A + Anti-D positive → A+
  → Anti-A only positive → A-
  → Anti-B + Anti-D positive → B+
  → Anti-B only positive → B-
  → Anti-A + Anti-B + Anti-D positive → AB+
  → Anti-A + Anti-B only positive → AB-
  → Anti-D only positive → O+
  → No agglutination in any → O-
  → When everything with control comes positive, it becomes invalid.

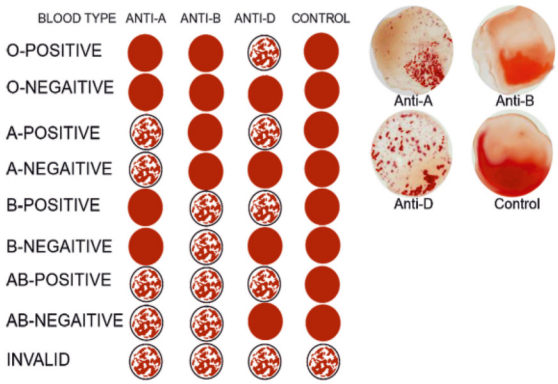

Elisa Method

- Structure: 8 rows × 12 columns = 96 wells
- Used to test multiple samples simultaneously (~20–30 patients)



Gel Card

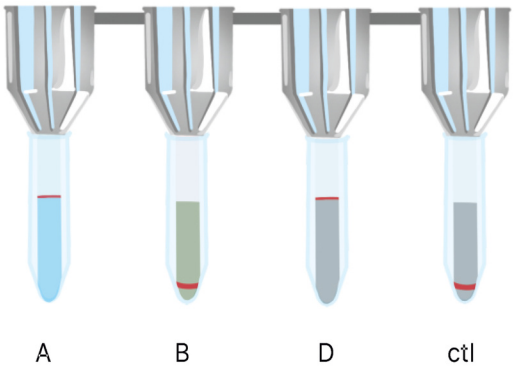

- Band at top → Positive (agglutination present)
- Band at bottom → Negative (no agglutination)
- Example: Agglutination with Anti-A + Anti-D → A+

Automated Machine

- When all these are done with big machines, it becomes automated

FMGE June 2022

00:07:40

BLOOD DONATION CRITERIA

- Age: > 18 and <65 Years
- Hemoglobin: >12.5gm
- Weight: >45 kg
  - 45-55 kg → 350ml blood
  - >55 kg → 450 ml blood





- Machine: Biomixer
  - Measures weight of collected blood
  - Ensures proper mixing with anticoagulant
- Collection Process
  - Needle: usually 18G
  - Blood first enters mother bag → contains whole blood
  - Then separated into components (component bags):
    → Packed RBCs
    → Platelet-rich plasma
    → Fresh frozen plasma



- Penta Bag
  - Purpose: Pediatric blood transfusion.
  - Design: Mother bag divided into four smaller 100ml pouches
  - Prevents wastage when small volumes are needed for infants



- Pre-donation bag:



  - First 10–30 mL collected separately
  - Removes contaminated blood (skin flora, antiseptic, tissue debris)
- Leukocyte Reduction Filter
  - Purpose: Removes White Blood Cells (WBCs).
  - Takeaway: Prevents Cytomegalovirus (CMV) transmission and Febrile Non-Hemolytic Transfusion Reactions (FNHTR) caused by Interleukin-1 release

TTI (TRANSFUSION TRANSMITTED INFECTIONS) SCREENING

- Mandatory tests:
  1. HIV 1 & 2
  2. Hepatitis B
  3. Hepatitis C
  4. Malaria
  5. Syphilis

PRESERVATIVES

00:14:25

- ACD (Acid Citrate Dextrose): 21 days (3 weeks)
- CPD (Citrate Phosphate Dextrose): 21 days (3 weeks).
- CPD & A (Citrate Phosphate Dextrose Adenine): 35 days (5 weeks)

- CP-SAGM (Saline Adenine Glucose Mannitol): 42 days (6 weeks)
  - Best
- Note: Citrate acts as a calcium chelator to prevent clotting.

STORAGE

Component	Temperature	Shelf life
Whole blood/ PRBC	Refrigerator: 2-6 Degree celsius	3weeks/5weeks/ 6weeks
PRP	20-24 Degree celsius 	5 days with continuous agitation
Random Donor Platelet (collected from multiple donors)	20-24 Degree celsius	5 days
Single Donor Platelet (collected from a single person)	20-24 Degree celsius	5 days
FFP	< -18degree celsius	1 year

• Cryoprecipitate
  ○ Factor 8
  ○ VWF
  ○ Factor 1
  ○ Factor 13		

- If platelet agitator not working, shelf life drop down to 1 day
- If the freezer is not working, FFP → thawed(melting), shelf life drops down to 1 day

APHERESIS MACHINE

00:19:50

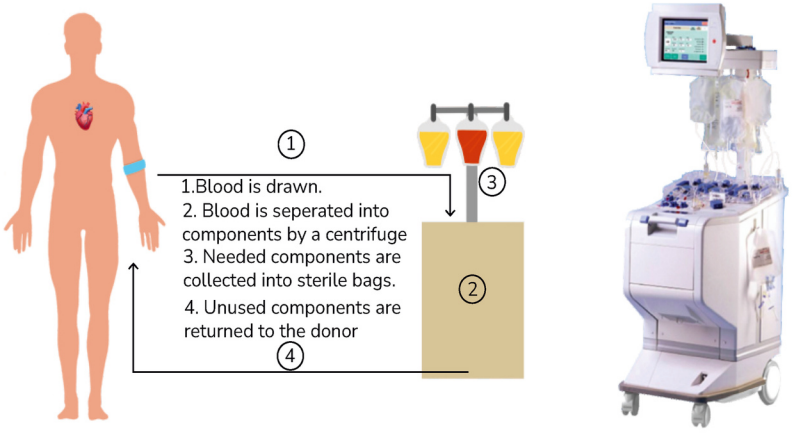

Yourwish

- Principle:
  - Blood is drawn from donor → enters apheresis machine
  - Machine separates components (RBCs, Platelets, Plasma) in real time
- Process:
  - Required component is collected
  - Remaining components are returned to donor (continuous process)
- Based on component collected, it can be:
  - Plateletpheresis → platelets collected
  - Plasmapheresis → plasma collected (e.g., antibodies)

MISCELLANEOUS IMAGES

00:21:10

EDTA Vacutainers

INICET Nov 2021

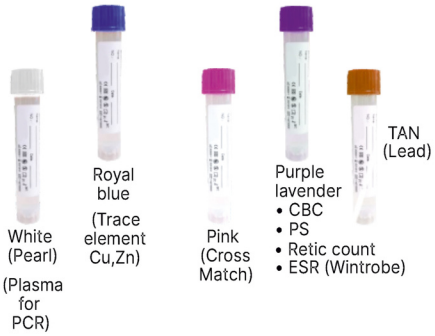

- Anticoagulant: K2 EDTA
- Types
  - Purple/Lavender
    → Primary uses: CBC, Peripheral Smear, Reticulocyte count, ESR (Wintrobe), HbA1c.
  - Pearl White: PCR/Molecular testing
  - Royal Blue: Trace elements (Copper, Zinc)
  - Pink: Blood bank cross-matching/grouping
  - Tan: Lead poisoning testing

Gray Vacutainer



- Anticoagulant: Potassium Oxalate
- Additives: Sodium Fluoride (inhibits Enolase to prevent glycolysis)
- Uses: Random/Fasting/Post-prandial blood sugar, GCT, GTT
  - Exception: HbA1c

Heparin Vacutainer

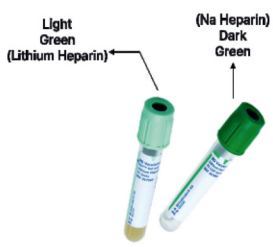

- These are green containers
  - Light green-Contains Lithium heparin
  - Dark green-Contains Sodium heparin
- Use:
  - OFT
  - ABG
  - Serum electrolytes

Yourwish

Yourwish

Blue Vacutainer	• Anticoagulant: 3.2% Trisodium Citrate
	• Anticoagulant: Blood ratio
	  ○ 1:9-coagulation studies (PT, APTT)
	  ○ 1:4 ESR (Westergren)
		

Black Cap Vacutainer	• Anticoagulant: trisodium citrate • Used for: automated ESR test	

Important Information

- Wintrobe: EDTA (Purple)
- Westergen: Tri sodium citrate (Light blue)
- Automated: Black

Coagulating Vacutainers

- Used to separate serum (Serum separator tubes)
- Preferred for
  - Hormone profile (Serum T3, T4, TSH, HCG, Prolactin, LH, FSH, Testosterone)
  - Enzymes
  - Antibodies
  - KFT, LFT
  - Serum electrolyte

Red vacutainer	Golden yellow vacutainer	Orange vacutainer
• Clotting time is 60 mins. • Clot activator is added • Gel is not added 	• Clotting time is 30 mins • Clot activator is added • Gel is added that makes clot faster 	• Contains Thrombin based activator gel • Clotting time is 5 mins only 

- Number of times mixed
  - Purple (EDTA), Gray, Green → 8 times
  - Light blue- 3-4 times
  - Serum separator tubes- 5-6 times

ORDER OF BLOOD DRAW

00:28:44

- **Mnemonic: Stop Light is Red, Yellow, Green Light Go**
  - Stop - Sterile- for cultures (Light Yellow)

Yourwish

- Light - Light blue-for coagulation studies.
- Red - Red-for serum profiles
- Yellow - Serum separating tubes (Yellow) -for serum profiles
- Green - Green- for ABG
- Light - Lavender- Routine tests (CBC)
- Go - Gray- for Glucose



NEUBAUER CHAMBER

00:30:01

Chamber



- Grids are divided into:
  - WBC, 4 big squares (peripheral)
  - RBC, in the central grid
    → 4 small squares in the periphery
    → 1 central square
  - Platelets, entire central grid
    → Except for the green line

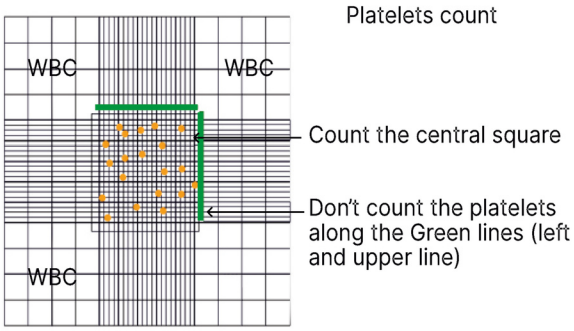

Fluids and Pippete

	RBC Pipette	WBC Pippete
Bead, Mouthpiece Color	Red	White
Markings	0.5,1,101	0.5,1,11
Cells Counted	Lakhs	Thousands
Dilution Range	0.5 to 101 times	0.5 to 11 times

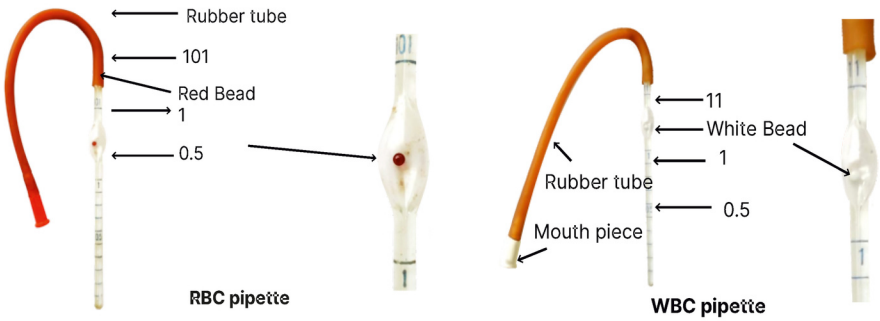

- RBC diluting fluid: Hayem & Dacie fluid
- WBC diluting fluid: Turk fluid
- Platelet diluting fluid: Rees & Ecker fluid

Sahil's Hemoglobinometer

00:32:34

- Used for hemoglobin estimation
- Contains
  - Hemoglobin pipette is used to collect the tube
    → Does not have bead
  - Sahli's graduated hemoglobin tube
    → Blood and N/10 HCL is added to this
    → Makes Acid hematin (brown color)
    → Dilution is continued till the color of the blood is the same as the comparator.
  - The blood is mixed with a stirrer (glass rod)
  - Comparator with a brown glass-standard.

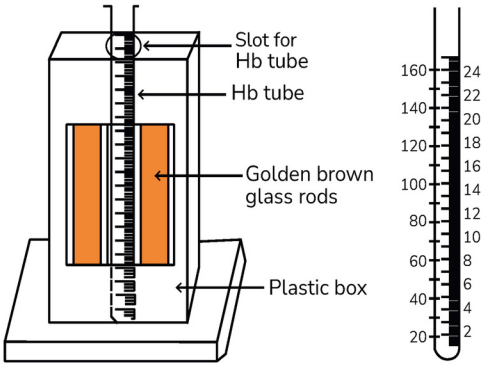



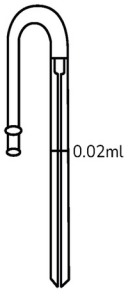

Hemoglobin pipette


Stirrer
Thin glass rod.

PYQ

00:33:49

Q. In a trauma patient with an unknown blood group who is unstable and requires urgent blood transfusions, which type of blood should be transfused?

INICET May 2024

a. A positive
b. AB positive
c. O positive
d. O negative

Ans: d. O negative

Q. Which of the following tests is not conducted before a blood transfusion for a person with RTA, when a family member is volunteering for blood donation?

FMGE June 2022

a. Hepatitis A
b. Hepatitis B
c. Hepatitis C
d. HIV 1 and 2

Ans: a. Hepatitis A

Yourwish