



# 1. BASICS OF RADIOLOGY

## TYPES OF RADIATION

00:00:46

- 2 types
  - Electromagnetic radiations
  - Particulate radiations

Electromagnetic radiations	Particulate radiations
<ul style="list-style-type: none"> <li>• Travels as photons</li> <li>• E.g → Light, X-rays, Gamma rays               <ul style="list-style-type: none"> <li>○ Light has no energy. As a result, penetration does not occur, and an image is not formed.</li> </ul> </li> </ul>	<ul style="list-style-type: none"> <li>• It has subatomic particle</li> <li>• E.g → α rays, β rays, neutrons               <ul style="list-style-type: none"> <li>○ α rays: nucleus of helium → positively charged</li> <li>○ α rays: electrons → negatively charged</li> </ul> </li> </ul>

## Damage And Penetration

- Damage is inversely proportional to Penetration.

$$\text{Damage} \propto \frac{1}{\text{Penetration}}$$

- Decreasing order of Penetration of various radiations
  - Gamma rays > X rays > β rays > α rays
- Decreasing order of Damage of various radiations
  - α rays > β rays > X ray > Gamma rays

## Important Information

- USG and MRI have no radiation effect
  - USG uses sound waves
  - MRI uses radio waves
- X-ray, CT, Fluoroscopy has radiation effect
- Gamma rays used in nuclear medicine has radiation effect

## IMAGING MODALITIES

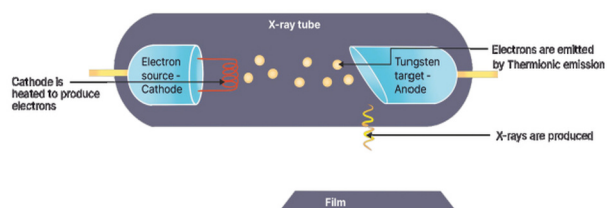
00:03:29

### X Ray / Radiography

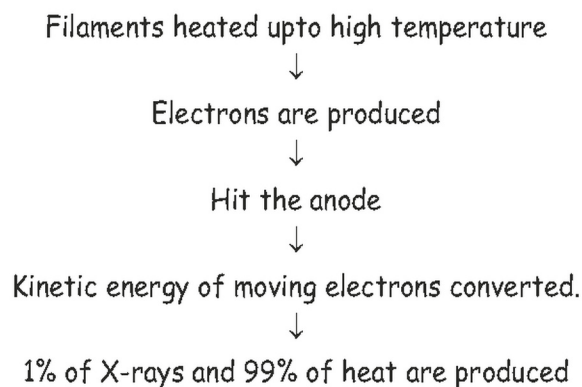
00:03:50

FMGE July 2023

- An X-ray tube produces X-rays
- Components of X ray tube
  - Cathode → It acts as a filament and produces electrons
  - Anode
- Composition
  - Cathode → Tungsten (W) + Thorium
  - Anode → Tungsten (W) + Rhenium



## Yourwish

**Thermionic Emission****Mechanism**

- Based on **Bremsstrahlung radiation / Braking radiation**
  - Electrons having energy move towards nucleus of anode, which is positively charged
  - ↓
  - Electrons hit and deflected from the anode.
  - ↓
  - Energy produced
  - ↓
  - X-rays are formed

**Fate Of X-Ray**

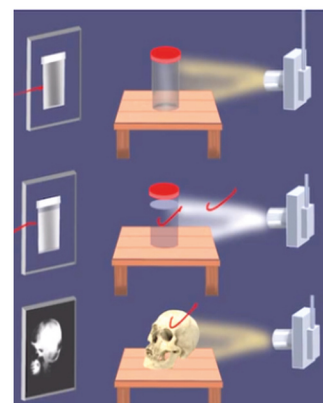
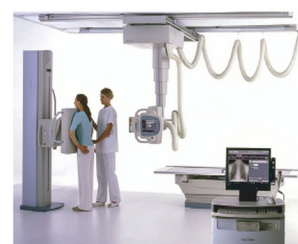- X-ray comes out from X-ray tube, passes through the patient, and has the following fate:
  - X-ray with high energy → penetrates and forms images
  - X-ray with low energy → stays in the body and causes more damage
  - X-ray deviates like a scatter radiation → **Compton effect**

**Important Information**

- Photoelectric effect → Effect produced due to contrast

**Digital Radiography**

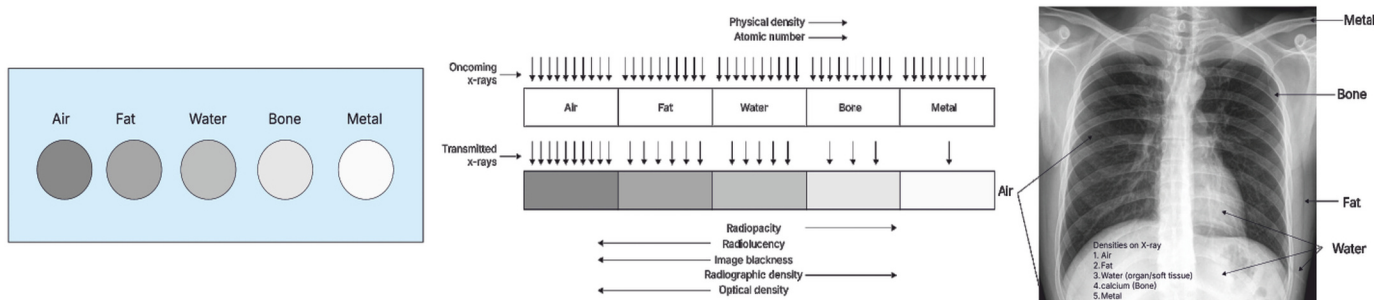
- X-ray film holder → holds the X-ray
- Component of X-ray film holder
  - Silver halide
  - Silver bromide
- Advantages
  - Duration is fast
  - Communication is possible
  - Picture archiving and communication system (PACS)

**Principles In X-Rays**

- Black and white principle:
  - Air → Image is black (maximum penetration)
  - Water → Image is grey
  - Bone → Image is white (maximum attenuation)

- Density is inversely proportional to Transmission.

$$\text{Density} \propto \frac{1}{\text{Transmission}}$$



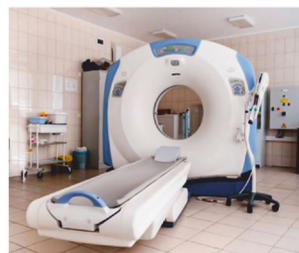- Decreasing order of Density
  - Metal > Bone > Water > Fat > Air
- Decreasing order of Transmission of X-ray
  - Air > Fat > Water > Bone > Metal

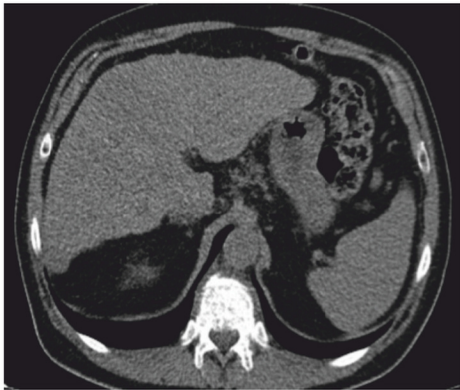
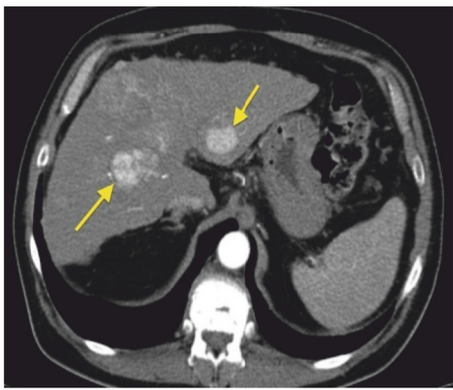
### Ct (Computed Tomography)

- 3D X-ray
- Parts
  - X-ray tube → Rotating
  - Detector
- CT was invented by **Godfrey Hounsfield**
- IOC in emergency conditions
- C/I in pregnancy
- It includes Non-contrast CT and Contrast-enhanced CT

00:12:08

INICET May 2025



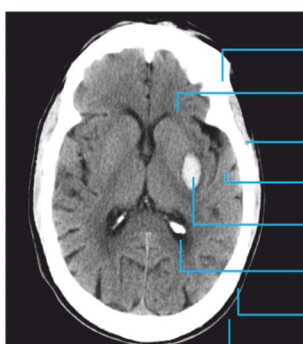
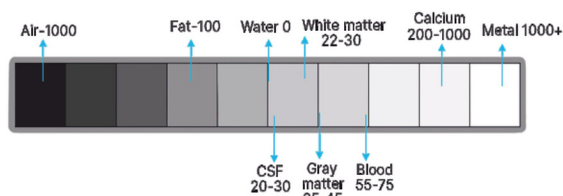
	NCCT	CECT
<b>Identification</b>	<ul style="list-style-type: none"> <li>• Blood appears grey</li> </ul> 	<ul style="list-style-type: none"> <li>• Blood appears white because Iodinated contrast given is radiodense and appears white.</li> </ul> 

<p><b>Uses</b></p>	<ul style="list-style-type: none"> <li>• Conditions where calcification is seen                     <ul style="list-style-type: none"> <li>○ Renal and ureteric stones</li> </ul> </li> <li>• Acute hemorrhage → RBC appears hyperdense                     <ul style="list-style-type: none"> <li>○ Head trauma</li> </ul> </li> </ul>	<ul style="list-style-type: none"> <li>• Any space-occupying lesions</li> <li>• Infective and Inflammatory Pathology</li> <li>• Contrast used → Iodinated (Iohexol)                     <ul style="list-style-type: none"> <li>○ Low osmolar</li> <li>○ Non-ionic</li> </ul> </li> <li>• Administered through the IV route</li> <li>• RFT is done before giving contrast                     <ul style="list-style-type: none"> <li>○ Serum urea</li> <li>○ Serum creatinine</li> </ul> </li> </ul>
--------------------	---	---

**Hu Value**

INICET May 2024


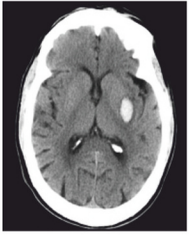

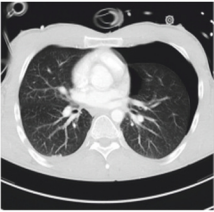
- Units in CT → HU units (Hounsfield units)
- Depends on the electron density / Attenuation coefficient
- Increased density → Increased HU value → appears white on CT
- Positive HU value
  - Bone → +1000
- **Zero HU value → Water**
- Negative HU value
  - Air → -1000
  - Fat → -50 to -100



CT number ranges in Hounsfield units (HU)	
Bone	+1000
White matter	+20 to 30
Muscle	+20 to 40
Gray matter	+30 to 40
Hemorrhage	+65 to 95
CSF (water)	0
Fat	-30 to -70
Air	-1000

Structure	HU value	Appearance
Bone	+1000	White
Hemorrhage	+65 to +90	Not white as bone
White matter → Myelin	+20 to +30	
Muscle	+20 to +40	
Gray matter → cell body	+30 to +40	
CSF (Water)	0	Dark
Fat	-30 to -70	Dirty black
Air	-1000	Jet black

## Ct Findings

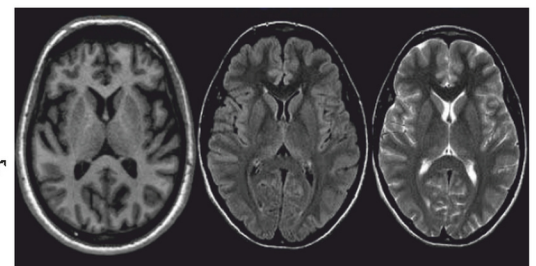
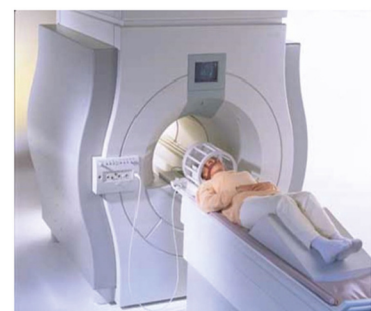Image	Findings
	<ul style="list-style-type: none"> <li>• Metallic foreign bodies               <ul style="list-style-type: none"> <li>○ Appears white</li> <li>○ MRI is C/I</li> </ul> </li> </ul>
	<ul style="list-style-type: none"> <li>• Acute hemorrhage               <ul style="list-style-type: none"> <li>○ Appears white</li> </ul> </li> </ul>
	<ul style="list-style-type: none"> <li>• Angiomyolipoma               <ul style="list-style-type: none"> <li>○ Fat deposition in kidney</li> <li>○ Appears black</li> </ul> </li> </ul>
	<ul style="list-style-type: none"> <li>• Pneumothorax               <ul style="list-style-type: none"> <li>○ Air appears black</li> </ul> </li> </ul>

## Magnetic Resonance Imaging (Mri)

- Appears like a Tunnel
- Strength of the magnet measured in Tesla
- Principle → Gyromagnetic properties of protons in the body
- C/I of MRI
  - Pacemaker
  - Aneurysm clip
  - Cochlear implant
  - Metallic foreign bodies
- Bone cortex and fibrous tissue appear black in the MRI T2 sequence
- Fat appears white in MRI
- Sequence in MRI
  - T1 → White matter white, Gray matter black, Fluid black
  - T2 → Fluid appears white
  - FLAIR (Fluid attenuation inversion recovery) → White matter black, Gray matter black, Fluid black
  - In condition to find out edema, Flair sequence is used.

00:23:44

FMGE June 2021  
INICET July 2021

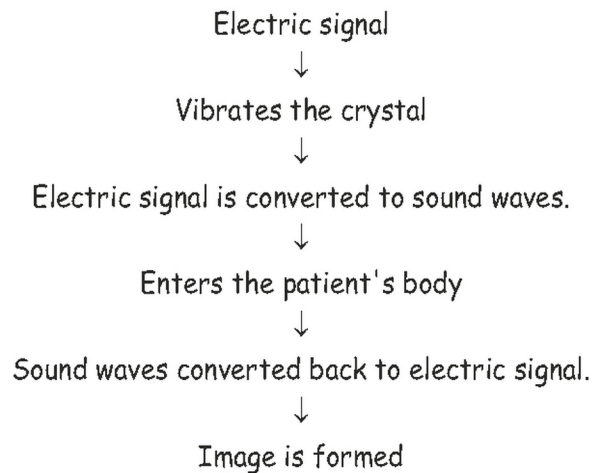


# Yourwish

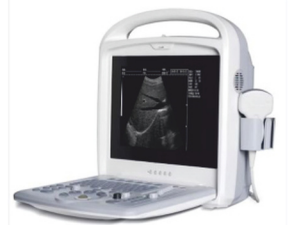## Usg

00:27:37

- Principle → Piezoelectric effect
- Crystal material present is Lead zirconium titanate

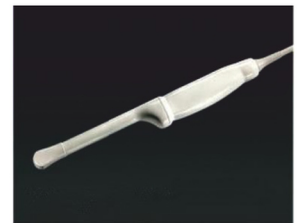

- No risk of radiations
- Sound is not audible because the frequency of sound is high and is outside the audible range of the human ear.



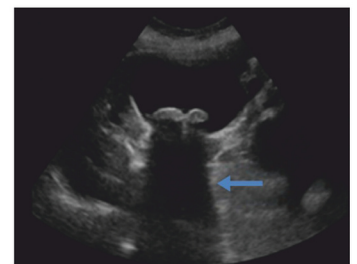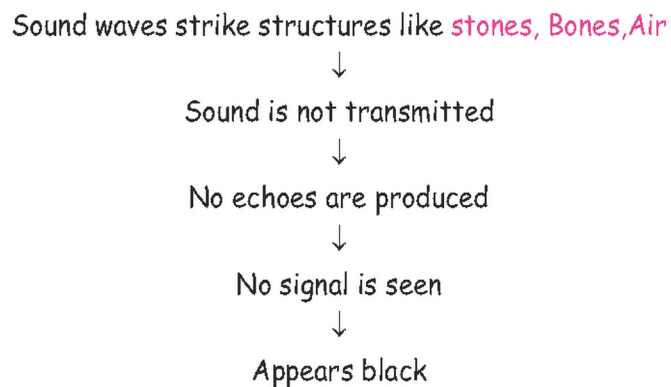
## Types Of Probes

- Different-sized probes are present, which indicate different penetration into tissues.
- Convex probe
  - Low frequency, High penetration
  - Used in the abdomen
- Linear probe
  - High frequency, Low penetration
  - Used in organs like the breast and thyroid
- Probe used in cavities
  - TVS
  - TRUS



## Post Acoustic Shadow

- It appears black
- Pathogenesis

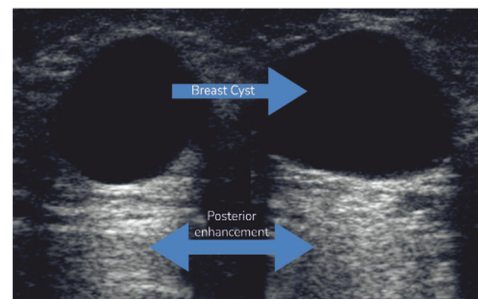
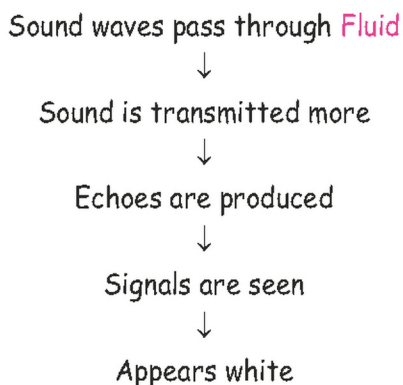


- IOC for Gallstones → USG

- IOC for Renal stones → NCCT

**Post Acoustic Enhancement**

- It appears white
- Pathogenesis



- Posterior acoustic enhancement seen in cystic lesions

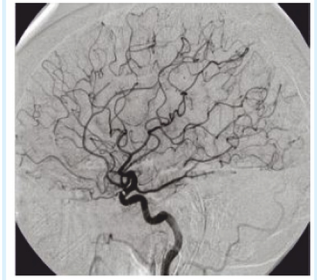
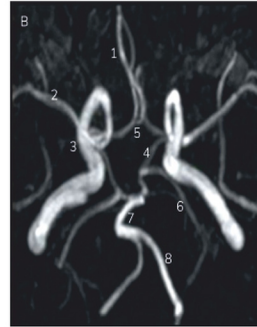
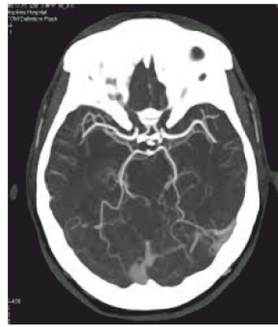
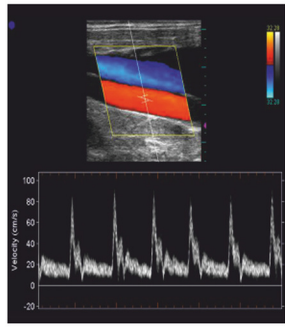
**Modifications Of Usg**

USG M-mode	USG DOPPLER
<ul style="list-style-type: none"> <li>• Assess the motion of structure</li> <li>• Used for moving structures like Diaphragm and Fetal cardiac activity</li> </ul>	<ul style="list-style-type: none"> <li>• Sound passes through the moving blood → cause shift in the frequency of sound</li> <li>• Color in the doppler produced indicates direction of blood</li> <li>• 1st investigation in vascular pathology</li> </ul>

**Investigations For Vascular Pathologies**

	Vascular doppler	CT Angiography	MR Angiography	DSA
<b>Radiation</b>	No	Yes	No	Yes due to presence of Fluoroscopy
<b>Contrast</b>	No	Iodinated contrast injected Intravenously	No (vascular structure identified through Time of flight sequence )	Iodinated contrast injected Intrarterially
<b>Therapeutic advantages</b>	No	No	No	Yes , to remove embolus

**Images**



**SUMMARY OF INVESTIGATIONS**

00:38:07

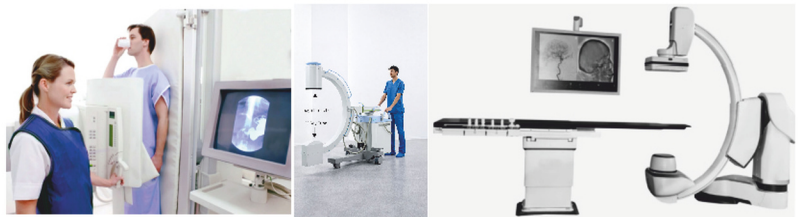	Black	White
<b>X ray</b>	Radiolucent	Radio opaque
<b>CT</b>	Hypodense	Hyperdense
<b>USG</b>	Hypoechoic	Hyperechoic
<b>MRI</b>	Hypointense	Hyperintense
<b>MRI sequence</b>	Fat • White in both T1 and T2 sequences Fluid • White in T2 • Dark in T1	

**EQUIPMENT IDENTIFICATION**

00:39:30

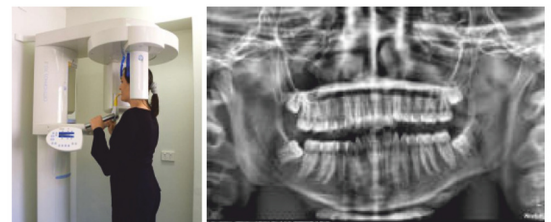
**Fluoroscopy**

- Video X-ray
- Includes
  - Barium studies- More radiation than X-ray
  - C arm used in Orthopaedics OT
  - DSA



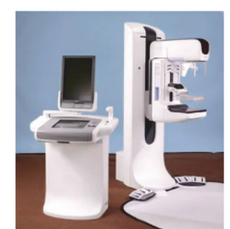**Orthopantomography**

- Evaluates the temporomandibular joints
- TMJ is best evaluated by MRI
- Panoramic radiography: Broad-view X-ray of the entire mouth, including both upper and lower jaws, teeth, and surrounding bone

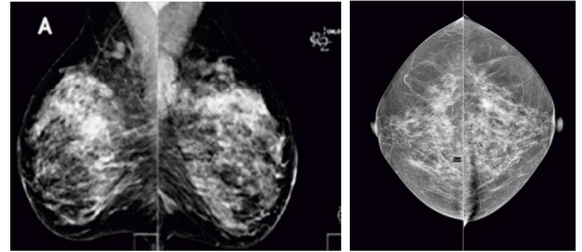


**Mammography**

- X-ray Breast with compression
- Used in females over 40 years with mass in the breast
- Carcinoma has a feature of microcalcifications, which appear white



- 3 views
  - Cranio caudal
  - Mediolateral
  - Mediolateral oblique → helps in visualization of the axilla



**Anatomy Of Breast**

- Young females → presence of gland in breast and appears white
  - Difficult to differentiate glandular breast from microcalcifications
- Elder female → presence of fat and appears black

**Investigations In Various Breast Pathologies**

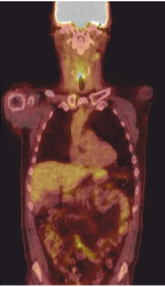

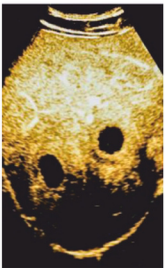
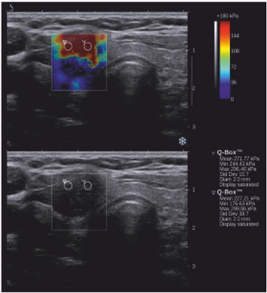
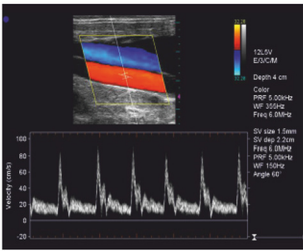
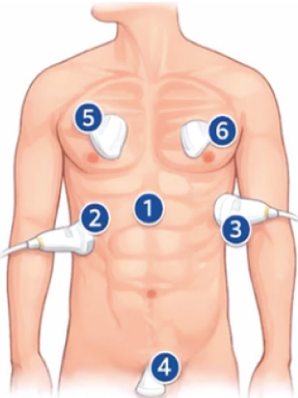
- Painless lump
  - Young female
    - 1st investigations in young female USG
    - IOC → MRI
  - Elder female
    - Mammography
- Breast abscess → USG
- Acute mastitis
- Breast implant → MRI
- DCIS → MRI

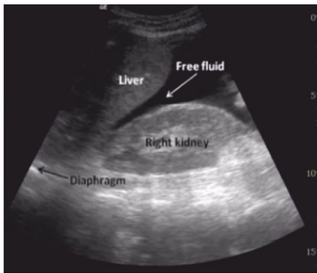**IDENTIFYING INVESTIGATIONS**

00:44:32

Investigations	Description
<b>CT</b>	<ul style="list-style-type: none"> <li>• Bone is white</li> <li>• Bone marrow → contains fat appears black</li> <li>• Bone cortex → White</li> </ul> <div style="text-align: center;"> </div>
<b>MRI</b>	<ul style="list-style-type: none"> <li>• Bone is black</li> <li>• Bone marrow → contains fat appears white</li> <li>• Bone cortex → black</li> </ul> <div style="text-align: center;"> </div>

Yourwish

<p><b>PET CT</b></p>	<ul style="list-style-type: none"> <li>• Orange CT</li> <li>• Example of Hybrid / Fusion Imaging</li> <li>• PET → Nuclear medicine             <ul style="list-style-type: none"> <li>○ Radiation from body</li> </ul> </li> <li>• CT → Radiodiagnosis             <ul style="list-style-type: none"> <li>○ Radiation from the machine</li> </ul> </li> </ul>	
<p><b>B - USG</b></p>		
<p><b>Contrast-enhanced USG</b></p>		
<p><b>Elastography</b></p>	<ul style="list-style-type: none"> <li>• Measures of strains</li> <li>• Unit is kPa</li> <li>• Tells about the fibrosis in the lesion</li> <li>• Used in thyroid nodules, Liver cirrhosis, and breast lumps</li> </ul>	
<p><b>Doppler</b></p>	<ul style="list-style-type: none"> <li>• Units is cm/s</li> </ul>	
<p><b>FAST scan</b></p>	<ul style="list-style-type: none"> <li>• Focused assessment sonography in trauma</li> <li>• Sites             <ul style="list-style-type: none"> <li>○ Xiphisternum → Pericardium</li> <li>○ Right hypochondrium</li> <li>○ Left hypochondrium</li> <li>○ Pelvic area</li> </ul> </li> <li>• Detects free fluid in the dependent area</li> <li>• Free fluid → FAST positive             <ul style="list-style-type: none"> <li>○ Patient stable → CECT</li> <li>○ Patient unstable → Exploratory laparotomy</li> </ul> </li> </ul>	



<b>eFAST scan</b>	<ul style="list-style-type: none"> <li>• Extended Focussed assessed sonography in trauma</li> <li>• Sites <ul style="list-style-type: none"> <li>○ Pericardium</li> <li>○ Right upper quadrant</li> <li>○ Left upper quadrant</li> <li>○ Suprapubic area</li> <li>○ Right anterior thoracic</li> <li>○ Left anterior thoracic</li> </ul> </li> <li>• Detects pneumothorax and Hemothorax</li> <li>• Pneumothorax → Barcode sign is seen</li> </ul>
-------------------	--

- Whole body CT → Limbs are not included

## INVESTIGATIONS OF CHOICE

00:49:46

### General Principles

Structure	Investigations
Air	<ul style="list-style-type: none"> <li>• CT → appears black</li> </ul>
Fluid	<ul style="list-style-type: none"> <li>• USG → appears as Black</li> </ul>
Calcification	<ul style="list-style-type: none"> <li>• CT → appears white</li> </ul>
Soft tissue (nerves, muscles, ligaments, IVD, and cartilage)	<ul style="list-style-type: none"> <li>• MRI</li> </ul>
Bone cortex	<ul style="list-style-type: none"> <li>• CT</li> </ul>
Bone marrow	<ul style="list-style-type: none"> <li>• MRI (STIR)</li> </ul>
Medical device position (eg, Pacemaker)	<ul style="list-style-type: none"> <li>• X ray</li> </ul>
Vascular pathologies	<ul style="list-style-type: none"> <li>• 1st Investigations is Doppler</li> <li>• Other investigations: CT/MRA and DSA</li> </ul>
Metallic foreign bodies	<ul style="list-style-type: none"> <li>• CT</li> </ul>
Gallstones	<ul style="list-style-type: none"> <li>• USG</li> </ul>
Renal stones	<ul style="list-style-type: none"> <li>• NCCT</li> </ul>

### Regional Wise



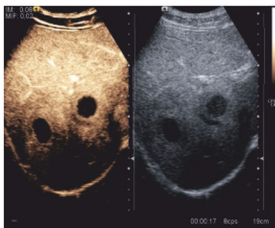
FMGE Jan 2024

Structure	Investigations
Brain	<ul style="list-style-type: none"> <li>• MRI</li> <li>• Head injury → NCCT <ul style="list-style-type: none"> <li>○ Except DAI, where SWI MRI is done</li> </ul> </li> </ul>

Chest	<ul style="list-style-type: none"> <li>• CT</li> <li>• Anterior mediastinal mass → CECT</li> <li>• Posterior mediastinal mass → MRI</li> </ul>
Upper abdomen	<ul style="list-style-type: none"> <li>• Gallbladder → USG</li> <li>• Pancreas → CT</li> <li>• Liver → Triple phase CT</li> </ul>
Pelvis	<ul style="list-style-type: none"> <li>• USG → TVS</li> <li>• MRI</li> </ul>
Perineum	<ul style="list-style-type: none"> <li>• Perianal fistula → MRI</li> </ul>

## CONTRAST MEDIA

00:52:33  
INICET May 2024

Contrast	Features
Iodinated contrast → Iohexol 	<ul style="list-style-type: none"> <li>• Used in all X-ray-based modalities               <ul style="list-style-type: none"> <li>○ CECT</li> <li>○ HSG</li> <li>○ IVP</li> <li>○ ERCP</li> </ul> </li> <li>• Side effect               <ul style="list-style-type: none"> <li>○ M/C is Anaphylactoid reaction → non-IgE mediated</li> <li>○ Contrast-induced nephropathy, as a result, kidney function is checked before giving contrast</li> </ul> </li> </ul>
Omniscan 	<ul style="list-style-type: none"> <li>• Component → Gadolinium</li> <li>• It has a paramagnetic compound</li> </ul>
Contrast-induced ultrasound 	<ul style="list-style-type: none"> <li>• Component → Microbubble sulfur hexafluoride (SF6) gas</li> <li>• It is excreted via the lungs</li> <li>• It is safe to use in renal failure</li> </ul>

## Microbar



- Component → Barium sulphate
- Used to visualize GIT
- C/I in perforated because it is insoluble and can cause peritonitis
- To detect perforation, iodinated dye can be used
  - Iohexol > Gastrografin
  - Iohexol has low osmolar properties

## RADIATION UNITS

00:55:10

Dose	Conventional units	SI units
Exposure Dose → unit of charge	Roentgen	Coulomb/ KG
Radiation Absorbed Dose	RAD	Gray 1Gy = 100Rad
Equivalent Dose	REM	Sievert 1Sievert = 100REM
Effective Dose	-	Sievert

## RADIATION IN VARIOUS INVESTIGATIONS

00:56:54

Examination	Effective dose (mSv)	Number of chest X-rays	Length of background exposure
<b>X- Ray</b>			
Limbs and joints (except hip)	<0.01	<0.5	<1.5 days
Chest (single PA)	0.02	1	3 days
Skull	0.07	3.5	11 days
Lumbar spine	1.3	65	7 months
Hip	0.3	15	7 weeks
Pelvis	0.7	35	4 months
Abdomen	1.0	50	6 months
<b>IVU</b>			
IVU	2.5	125	14 months
<b>Barium studies</b>			

## Yourwish

Barium meal	3	150	16 months
<b>CT studies</b>			
CT head	2.3	115	1 years
CT chest	8	400	3.6 years
CT abdomen or pelvis	10	500	4.5 years
<b>Radionuclide studies</b>			
Kidney ( $^{99m}\text{Tc}$ )	1	50	6
Thyroid ( $^{99m}\text{Tc}$ )	1	50	6
Bone ( $^{99m}\text{Tc}$ )	4	200	1.8 years
PET head (F-18 FDG)	5	250	2.3 years

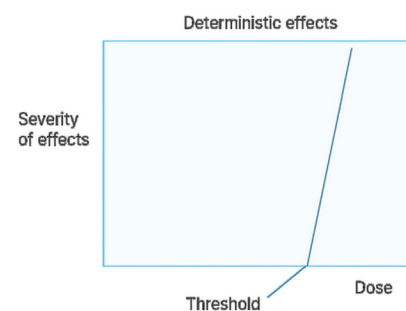
**RADIATION EFFECTS**

00:57:36

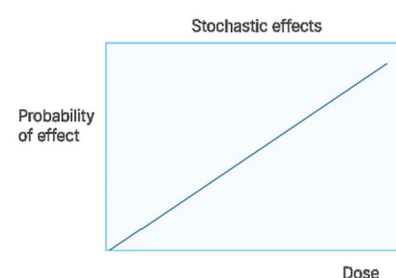
- Radiation produces 2 effect
  - Deterministic effect
  - Stochastic effect

**Deterministic Effect**

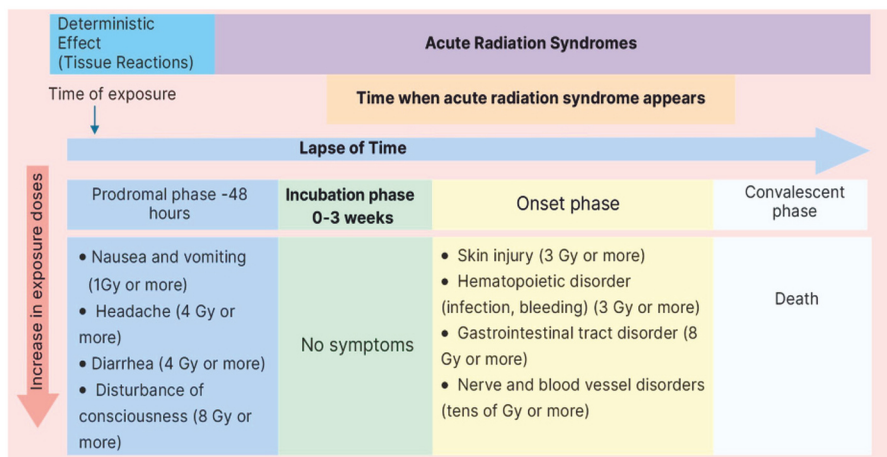
- Occurs due to the killing of cell
- Have a dose threshold
  - Occurs at severe Gy.
- Specific to particular tissues
- Severity of harm is dose-dependent.

**Stochastic Effect**

- Occurs due to cell changes (DNA) and proliferation towards a malignant disease
- No dose threshold
  - Occurs at very small doses
- The probability of effect increases with dose
- Severity is independent of the dose

**Acute Radiation Syndrome**

- Sudden exposure to a high dose of radiation > 1 to 2 Gy
- It includes
  - Prodromal phase
  - Incubation phase
  - Onset phase
  - Convalescent phase



Phase	Clinical features
<b>Prodomal phase - 48 hrs</b>	<ul style="list-style-type: none"> <li>Nausea and vomiting: 1 Gy or more</li> <li>Headache: 4 Gy or more</li> <li>Diarrhoea: 4 Gy or more</li> <li>Disturbance of consciousness: 8 Gy or more</li> </ul>
<b>Incubation phase - 0 to 3 weeks</b>	<ul style="list-style-type: none"> <li>No symptoms</li> </ul>
<b>Onset phase</b>	<ul style="list-style-type: none"> <li>Hematopoietic disorder → Infection and bleeding <ul style="list-style-type: none"> <li>First to be affected</li> <li>3 Gy or more</li> </ul> </li> <li>Skin injury <ul style="list-style-type: none"> <li>3 Gy or more</li> </ul> </li> <li>Gastrointestinal tract disorder <ul style="list-style-type: none"> <li>8 Gy or more</li> </ul> </li> <li>Nerve and blood vessel disorder <ul style="list-style-type: none"> <li>Last to affect</li> </ul> </li> </ul>
<b>Convalescent phase</b>	<ul style="list-style-type: none"> <li>Death</li> </ul>

## RADIATION SAFETY AND PROTECTION

01:00:11

- ALARA principle
  - Radiation exposure must be as low as reasonably achievable
- 10-day rule
  - Investigations involving radiation exposure should be done during the first 10 days of the menstrual cycle in women
- TDS principle
  - Time of radiation exposure should be minimal
  - Distance of radiation exposure should be more
  - Shields
- Inverse square law
  - As distance increases, radiation intensity decreases by the square

### Aerb Guidelines

- AERB has laid down recommendations for personal protection of radiation workers.
- The protective barrier between the operator and X-ray tube should have a minimum lead equivalence of 1.5mm.
- Protective aprons and gloves should have a minimum lead equivalence
  - 0.25mm → Ideal
  - 0.5mm → MC
- Gonadal shields should have a minimum lead equivalence of 0.5 mm
- Any additional radiation protection devices that would be necessary for specialized radiological investigations should have a minimum of 0.5 mm lead equivalence

### Dose Limitations

01:02:31

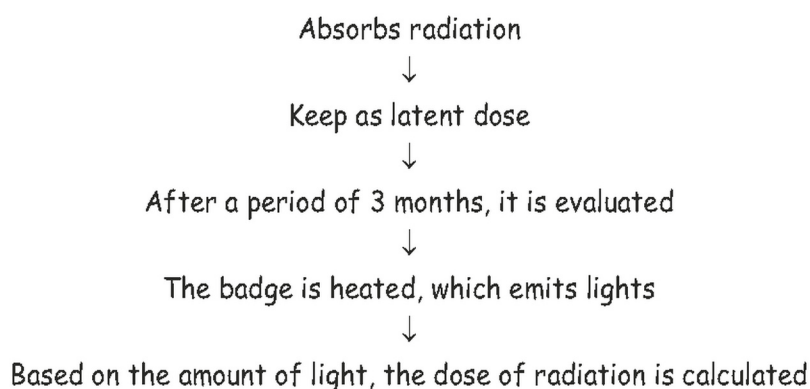
INICET May 2024

- For pregnant radiation workers, radiation should not exceed
  - 2 mSv on female
  - 1 mSv on the embryo/fetus

Part of the body	Occupational Exposure	Public Exposure
Whole body (Effective dose)	<ul style="list-style-type: none"> <li>• 20 mSv/year average over 5 consecutive years</li> <li>• 30 mSv in any single year</li> </ul>	• 1m Sv/y
Lens of eyes (Equivalent dose)	<ul style="list-style-type: none"> <li>• 150 mSv in a year</li> </ul>	• 15 mSv/y
Skin (Equivalent dose)	<ul style="list-style-type: none"> <li>• 500 mSv in a year</li> </ul>	• 50 mSv/y
Extremities (Hands and Feet) Equivalent dose	<ul style="list-style-type: none"> <li>• 500 mSv in a year</li> </ul>	

### Tld Badge

- Thermoluminescent dosimeter
- Measure the radiation dose the occupational worker gets
- Component
  - India → Calcium sulphate and Dysprosium
  - Others → Lithium fluoride
- It is changed every 3 months
- It is worn below the lead apron
- Principle



01:04:47

## PYQs

Q. The principle of Linear accelerators is utilized in the production of?

FMGE July 2023

- Protons
- X-rays
- Gamma rays
- Neutrons

**Ans: b**

Q. Which of the following is the best investigation for detecting ureteric calculi?

INICET May 2025

- NCCT
- Ureteroscopy
- X-ray
- CT scan

**Ans: a**

Q. Which of the following is true regarding CT scan?

INICET May 2024

- CT score of water is 0
- CT consists of unfiltered X-ray beams
- It is the investigation of choice for Gallstones
- The typical effective dose for an NCCT head scan is 20mSv

**Ans: a**

- CT is a filtered X-ray beam, which is a low-energy ray, and causes more damage
- USG is IOC in Gallstones
- The typical effective dose for an NCCT head scan is 2mSv

Q. The magnetic field in MRI machines is measured in which of the following units?

FMGE June 2021

- Tesla
- HU
- Khz
- Hg

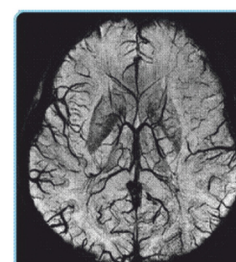
**Ans: a**

Q. What type of MRI image is given below?

INICET July 2021

- Proton density image
- Susceptibility weighted image
- Gradient echo image
- Inversion recovery image

**Ans: b**

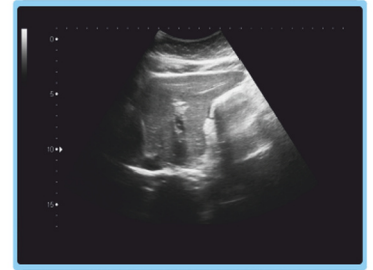


## Yourwish

Q. Identify the imaging modality given below?

- a. USG
- b. Fluoroscopy
- c. X-Ray
- d. MRI

INICET Nov 2021

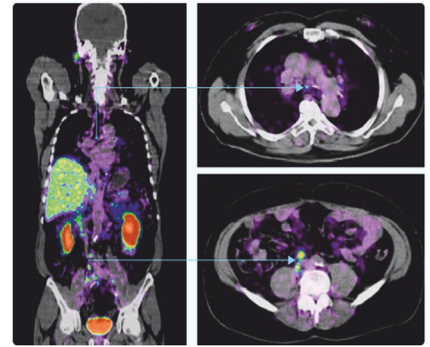


**Ans: a**

Q. During the procedure shown below, which one of the following substances is uptaken by the cancer cells?

- a. Alanine
- b. Glucose
- c. Sodium
- d. Calcium

FMGE Jan 2024



**Ans: b**

Q. Whole-body CT scan protocol for a trauma patient includes all, except?

- a. CT Head
- b. CT Cervical spine
- c. CT Limbs
- d. CT Abdomen

FMGE Jan 2023

**Ans: c**

Q. Which of the following contrast agents is safe to use in renal failure patients?

- a. Gadolinium
- b. Iodinated ionic contrast
- c. Iodinated non-ionic contrast
- d. USG contrast

**Ans: d**

Q. Ideal thickness of lead aprons to be worn by workers working in the radiology department?

- a. 0.5mm
- b. 1mm
- c. 0.75mm
- d. 2mm

**Ans: a**

Types Of Radiation	00:00:46
Damage And Penetration	
X Ray / Radiography	00:03:50

Principles In X-Rays	
Ct (Computed Tomography)	00:12:08
Hu Value	
Ct Findings	
Usg	00:27:37
Investigations For Vascular Pathologies	
Summary Of Investigations	00:38:07
Equipment Identification	00:39:30
Identifying Investigations	00:44:32
Investigations Of Choice	00:49:46
Contrast Media	00:52:33
Radiation Units	00:55:10
Radiation In Various Investigations	00:56:54
Radiation Effects	00:57:36
Radiation Safety And Protection	01:00:11
Dose Limitations	01:02:31
Tld Badge	
Pyqs	01:04:47



## 2. RESPIRATORY RADIOLOGY

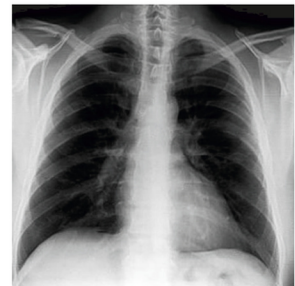
### CHEST X-RAY VIEW

00:00:20

- Routine View → PA (Posterior-Anterior)
  - Erect position
  - Full inspiration for optimal lung visualization
  - PA view importance → Heart is seen in true size
  - AP (Antero-Posterior) view → Results in false cardiomegaly (enlarged heart appearance)
- Pneumothorax → **Expiratory view**
- Pleural Effusion → **Ipsilateral decubitus view** (horizontal beam of x ray)
- Right Middle Lobe Collapse → **Lordotic view (Apical view)**

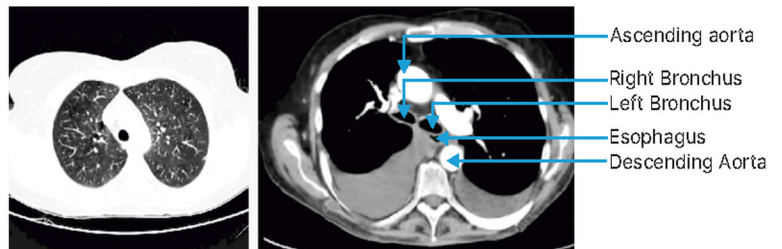
### NORMAL ANATOMY

- Trachea: black central shadow
- Spinous processes: white shadows overlapping trachea
- Hilum mainly formed by pulmonary artery
- Inferior pulmonary vein does not contribute to hilar shadow
- Costophrenic angle : between diaphragm and ribs
- Cardiophrenic angle : between heart and diaphragm

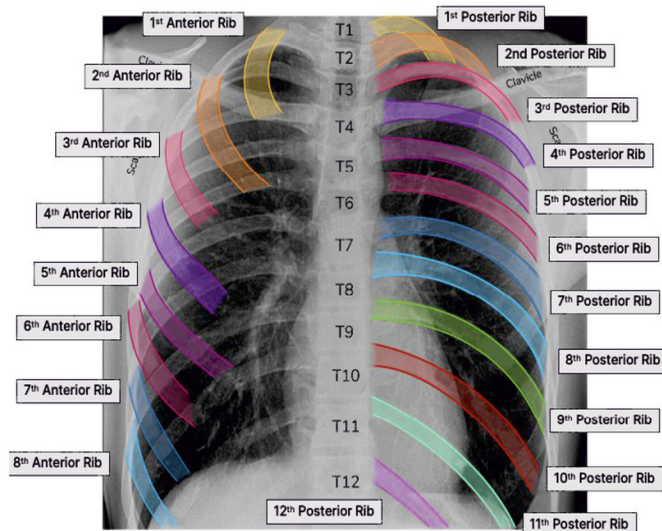
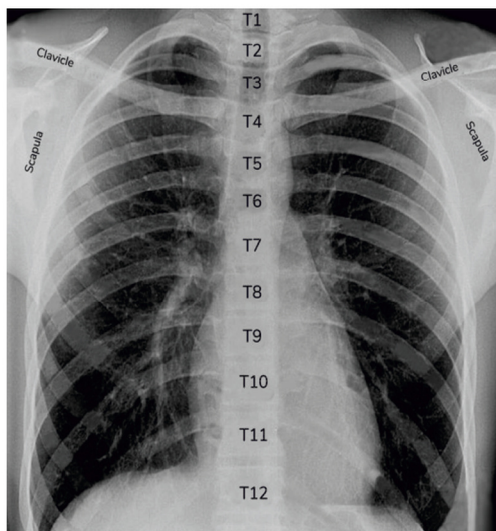


### CT Thorax Anatomy

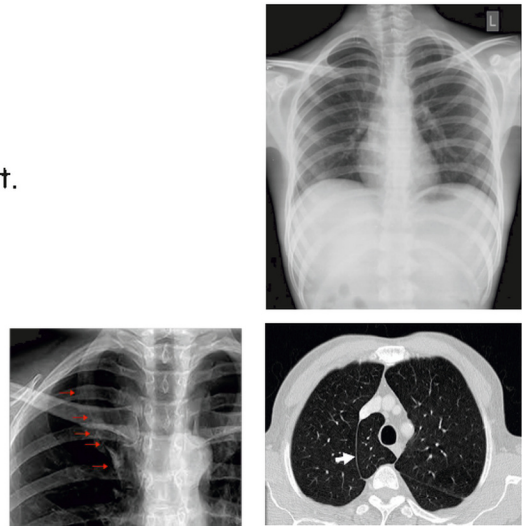
- Trachea: black air-filled structure in centre
- Bronchi : black air-filled structures
- Vascular markings → White structures within the lung



### RIB COUNTING



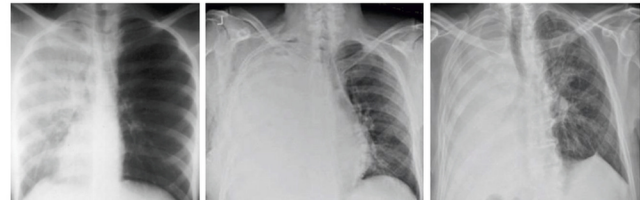
- Rib Orientation:
  - Posterior end → Attached to vertebrae; horizontal
  - Anterior end → Oblique; contains costal cartilage
- Visualization:
  - Cartilage → Not seen on X-ray unless calcified.
  - Midline → Posterior ribs reach the midline; anterior ribs do not.
- Counting Sequence:
  - Start from the anterior end of the 1st rib
  - Note → Posterior ends of 1st and 2nd ribs often overlap
- Cervical rib
  - Vertically oriented rib above the 1st rib
  - Association → Thoracic Outlet Obstruction Syndrome
- Azygous fissure seen in: right upper lobe
  - Azygous fissure forms: azygous lobe



FMGE Jan 2024

## WHITEOUT HEMITHORAX

- Causes :
  - Consolidation (no tracheal shift)
  - Pleural effusion (trachea shifted to opposite side)
  - Collapse (trachea shifted to same side)



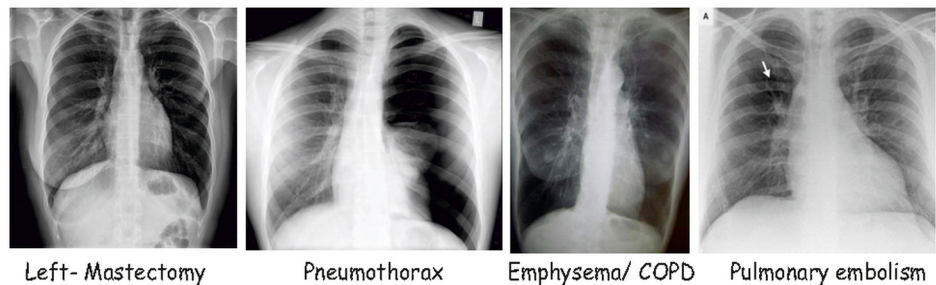
Consolidation

Pleural effusion

Collapse

## BLACKOUT HEMITHORAX

- Causes
  - Pneumothorax
  - Emphysema
  - Pulmonary embolism
  - Mastectomy
- Pneumothorax:
  - Hyperlucent hemithorax
  - No vascular markings
  - Collapsed lung visible
- Emphysema:
  - Flat diaphragm
  - Hyperexpanded lungs
  - Tubular heart
- Pulmonary embolism: decreased vascular markings
- Pneumonectomy: **whiteout hemithorax with same side shift**



Left- Mastectomy

Pneumothorax

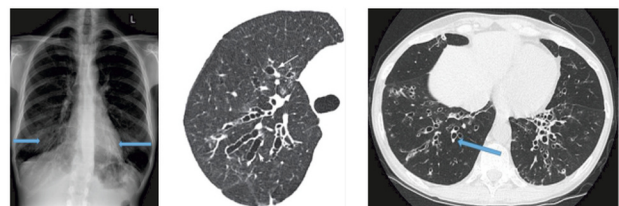
Emphysema/ COPD

Pulmonary embolism

## PATHOLOGIES

### Bronchiectasis

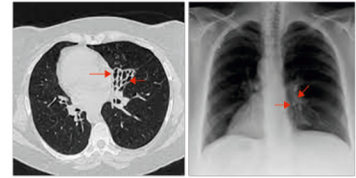- Bronchiectasis: dilated bronchi
- Commonly affects: lower lobes
- H/o elderly patients presenting with cough
- CT signs:
  - Tram track sign



00:10:16

# Yourwish

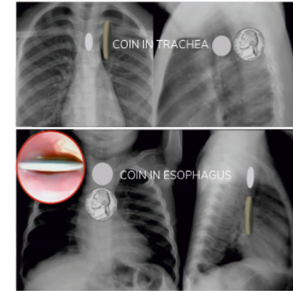
- Signet ring sign (dilated bronchus with adjacent artery)
- IOC: HRCT chest
- Kartagener syndrome:
  - Bronchiectasis
  - Situs inversus
  - Infertility



## Coin In Trachea Vs Esophagus

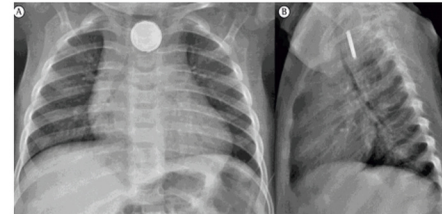
INI CET May 2023

- AP view:
  - Coin appears circular in esophagus
  - Coin appears slit-like in trachea
- Lateral view:
  - Esophageal coin becomes slit-like
  - Tracheal coin becomes circular

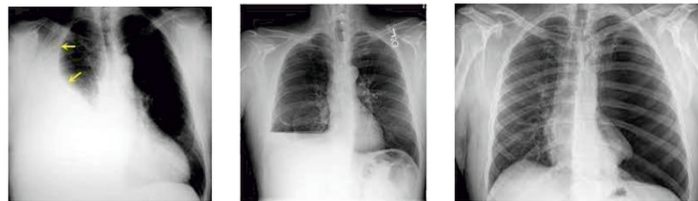

## Button Battery

- Button battery shows **double ring sign**
- Lateral view: sloping edge
- Button battery must be removed even if asymptomatic



## Pleural Pathologies



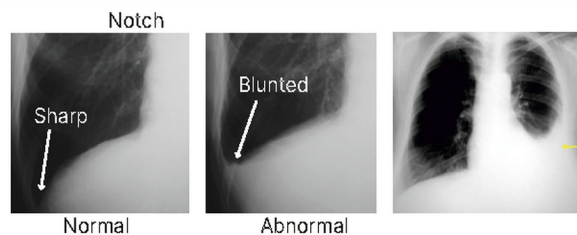
Pleural effusion      Hydropneumothorax      Pneumothorax

### HYDROPNEUMOTHORAX

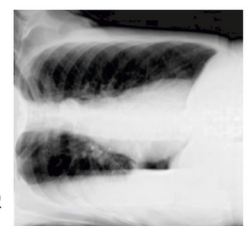
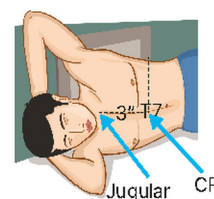
- Air-fluid level is horizontal
  - Horizontal level seen in : hydropneumothorax

### PLEURAL EFFUSION

FMGE June 2022

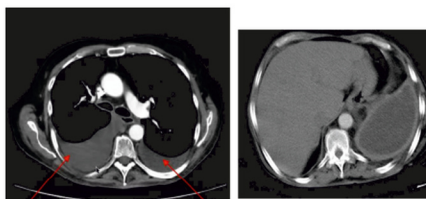


- Earliest sign: blunting of costophrenic angle
- Pleural effusion gives: meniscus sign or Ellis curve
- Trachea shifts to opposite side
- Percussion note: dull
- Most sensitive chest X-ray view:



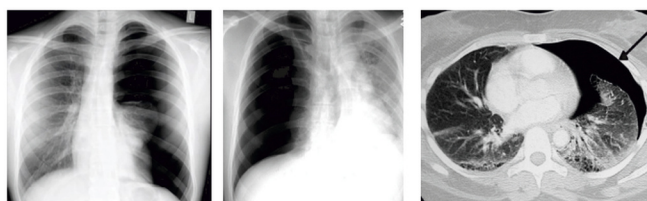
## PLEURAL EFFUSION

- Ipsilateral decubitus view with Horizontal beam
- Most sensitive investigation: **ultrasound**
- Pleural effusion Vs Empyema

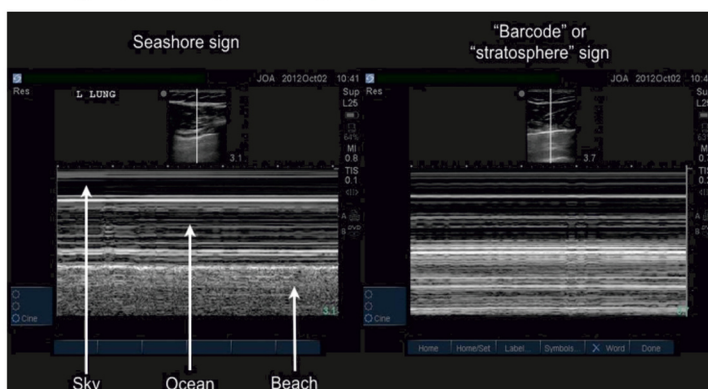
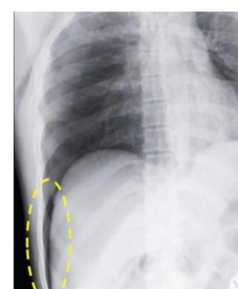


- Empyema: pleural effusion containing pus
- Empyema shows: pleural thickening
- Characteristic CT sign: **split pleura sign**
- Pleural effusion on CT:
  - Gray posterior collection
  - No pleural thickening

## PNEUMOTHORAX

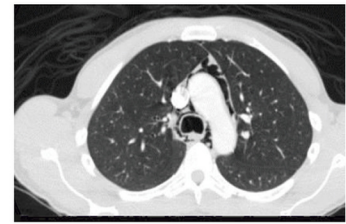

- Pneumothorax: air in pleural cavity without vascular markings
  - Air appears: jet black
  - Collapsed lung seen as white opacity
- Tension pneumothorax :
  - Opposite side mediastinal shift
  - Needle decompression first
  - Then ICD insertion
- Percussion note: hyperresonant
- CT finding:
  - Jet black air without vascular markings
  - Air collects anteriorly in supine CT
- Supine X-ray
  - Deep sulcus sign seen
- Seashore and Barcode sign (M-mode USG → eFAST)
  - Seashore sign: normal lung
  - Barcode sign (stratosphere sign): **pneumothorax**

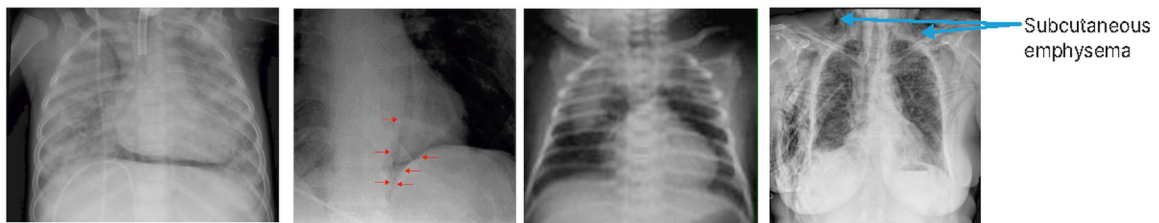


## Pneumomediastinum

00:21:15



- Pneumomediastinum: air surrounding mediastinal structures
- Clinical sign: **Hamman's crunch**



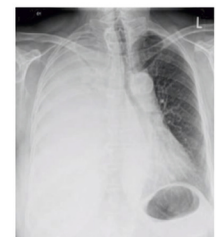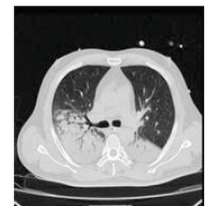
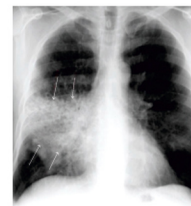- Naclerio V sign: air between aorta and diaphragm
- Spinnaker sail sign: thymus elevated by air
  - Angel wings sign : bilateral thymic elevation
- Ginkgo leaf sign : air in pectoralis major muscle fibers
- Most sensitive investigation for air pathology: **CT scan**

## LOCALISATION OF PATHOLOGIES

00:23:36

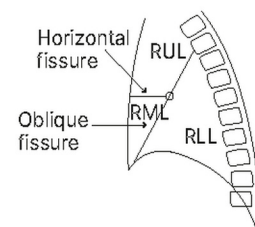
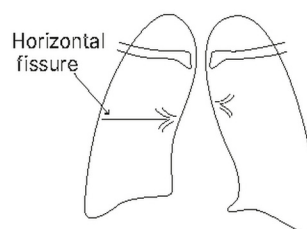
### Parenchymal Vs Extraparenchymal - Air Bronchogram Sign

- Black bronchi visible in white lung
- Indicates intraparenchymal pathology
- Seen in Consolidation:
  - Pneumonia
  - Pulmonary edema
  - Pulmonary hemorrhage
  - Hyaline membrane disease
- Not seen in extraparenchymal pathologies like
  - Pleural effusion
  - Mediastinal mass



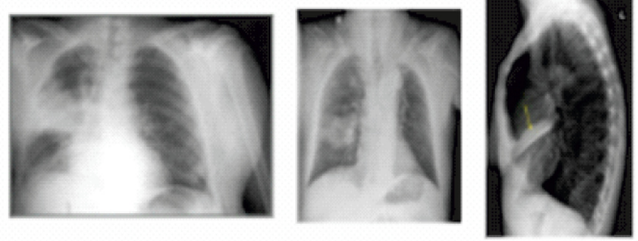
### Lobar Localisation & Lung Fissures

- Right lung: three lobes, two fissures
- Left lung: two lobes, one fissure
- Horizontal fissure present only in right lung
- Oblique fissure present in both lungs
- Right middle lobe lies between horizontal and oblique fissures adjacent to right heart border
- Lingula lies adjacent to left heart border
- Lower lobes lies posteriorly



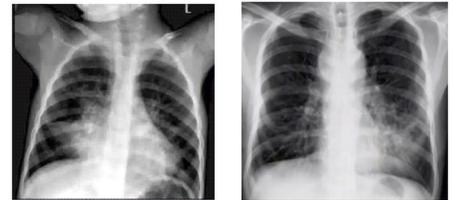
## Localization of Pathology

- Image 1 → Pathology above horizontal fissure: right upper lobe pathology
- Image 2 → Pathology below horizontal fissure: right middle lobe pathology
- Image 3 → Pathology overlying heart on lateral view: right middle lobe pathology



## Silhouette Sign

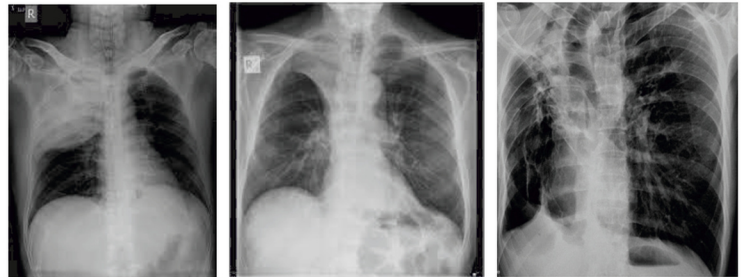
- Right heart border obliteration: right middle lobe pathology
- Left heart border obliteration: lingular pathology



## Consolidation Vs Collapse

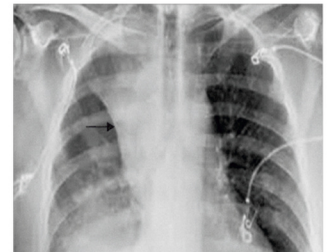
00:29:10

- Consolidation:
  - No mediastinal shift
  - Fissure remains in normal position
- Collapse:
  - Same side mediastinal shift
  - Fissure shifts toward collapse
- Image 1 → R-Upper lobe consolidation
- Image 2 → R-Upper lobe Collapse



## Golden S Sign

- Golden S sign seen in right upper lobe collapse
- Cause: d/t mass (bronchogenic carcinoma) obstructing right upper lobe bronchus
- Horizontal fissure shows reverse S shape



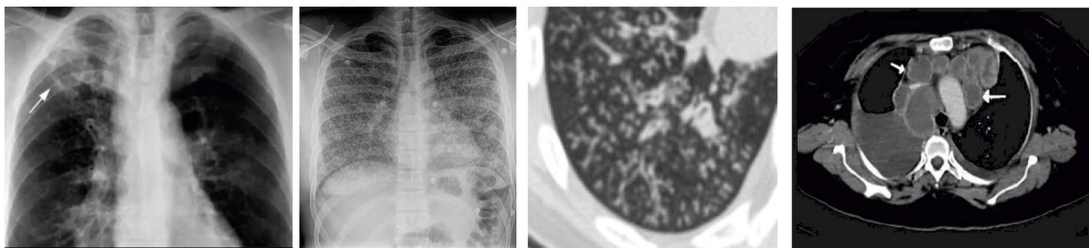
## INFECTIONS

00:31:34

### Tuberculosis

INICET Nov 2025  
FMGE Jan 2024

- Common site: right upper lobe and apical region
- Common findings:
  - Fibrotic strands, Cavitation, Hilar lymphadenopathy, Mediastinal lymphadenopathy



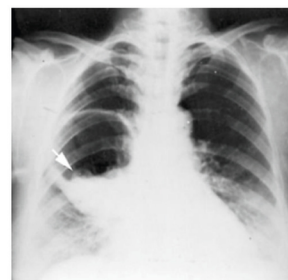- Image 1 → Fibrocavitary TB : fibrosis with cavity formation
- Image 2 → Miliary TB
- Image 3 → Tree in bud sign

# Yourwish

- Seen in TB with active endobronchial spread
- Image 4 → Pleural effusion common in TB
  - Necrotic mediastinal lymph nodes with pleural effusion suggest TB

## Hydatid Cyst

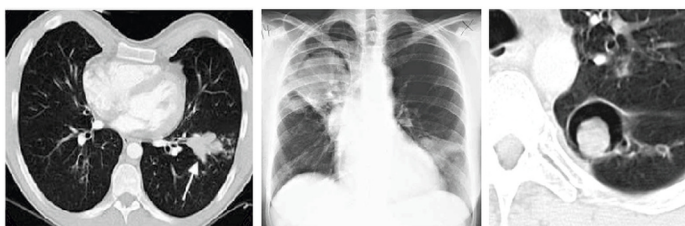
- Hydatid cyst may occur in lung
- Water lily sign seen
  - Detached membrane floating on fluid



FMGE Jan 2024

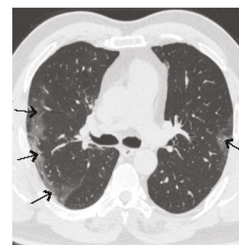
## Aspergillosis

- Image 1 → Allergic Bronchopulmonary Aspergillosis (ABPA)
  - Patient history → Asthma, raised IgE
  - Features → Central bronchiectasis
  - White-white appearance in bronchi due to mucus and fungal elements instead of air
  - "Glove-in-finger" or "Finger-in-glove" sign
- Image 2 and 3 → Aspergilloma (Fungal Ball)
  - Fungal ball sitting inside a Pre-existing cavity (e.g., from old Tuberculosis).
  - "Air crescent sign" or "Monod sign."
  - Confirmation → Perform prone CT → Fungal ball is mobile and moves



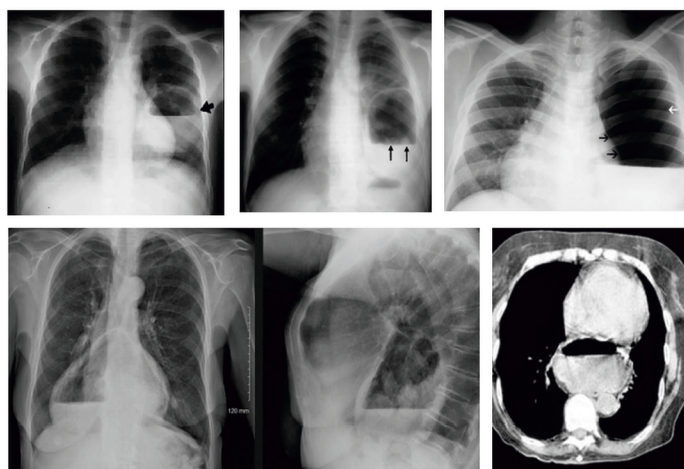
## Covid-19

- CORADS 5 (Highly suspicious) → Bilateral, peripheral, subpleural ground glass opacities.



## Air Fluid Levels D/D

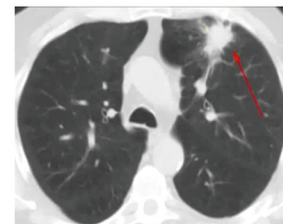
- Image 1 → Lung Abscess
  - Clinical history → High-grade fever
  - Image → Lung lesion with air-fluid level; nothing floating on the fluid
- Image 2 → Hydatid Cyst
  - Sign → "Water lily sign."
  - Features → Air-fluid level with floating structures.
- Image 3 → Hydropneumothorax
  - Features → Air-fluid level involving the entire hemithorax (not just a lesion).
  - Associated findings → Pneumothorax (no vascular markings)
- Hiatus Hernia



- Image 6 → CT showing Air-fluid level located retrocardiac
- Image 4 and 5 → X-ray confirms air-fluid level posterior to the heart.
- Cause → Stomach herniating through the diaphragm.

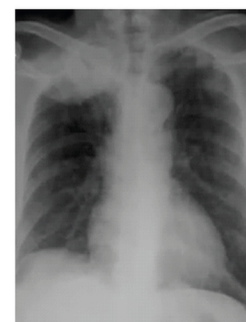
### Lung Cancer

- Evaluation → CECT (Contrast Enhanced Computed Tomography).
  - Features → Speculated margins (infiltrative lesion).
- **Gold Standard for Diagnosis** → CT-guided biopsy
- Staging → PET CT
- Clinical history → Weight loss, hemoptysis, and smoker status

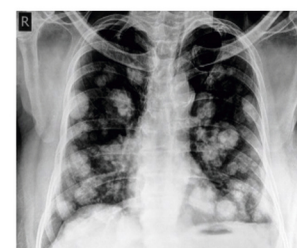

### Specific Lung Tumors

- Pancoast Tumor
  - Location → Apex (superior sulcus tumor).
  - Clinical presentation → Upper limb pain (brachial plexus invasion) + Horner syndrome (sympathetic trunk invasion).
  - IOC → MRI (better for evaluating nerve/soft tissue invasion).



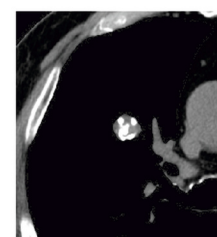
- Metastasis
  - Presentation → Multiple lung lesions.
  - Sign → "Cannon ball metastasis."
  - Common primary sources → Choriocarcinoma, Renal cell carcinoma.



### Popcorn Calcification

- Popcorn calcification in lung → Pulmonary Hamartoma
- Popcorn calcification in other locations:
  - Breast → Fibroadenoma
  - Brain → Cavernoma
  - Pelvis/Uterus → Involuting fibroid

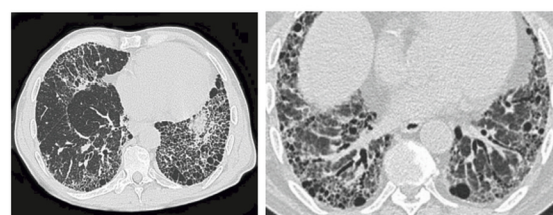
FMGE Dec 2021



00:40:34

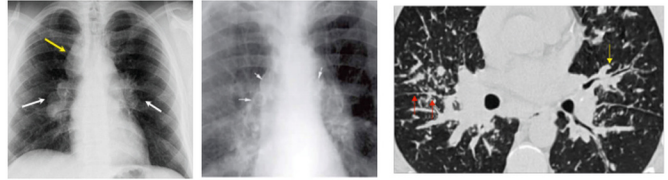
### Honey Combing In Interstitial Lung Disease

- Clinical profile → Progressive dyspnea, dry cough.
- Idiopathic Pulmonary Fibrosis (IPF) / Usual Interstitial Pneumonia (UIP)
  - Sign → "Honeycombing appearance."
  - CT findings → Air-filled cysts stacked together + Traction bronchiectasis (fibrosis pulling bronchi open)
  - Distribution → Peripheral and basal parts of the lung

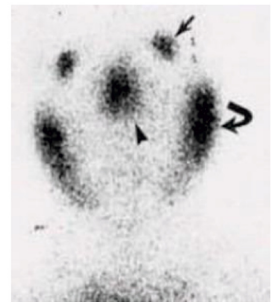
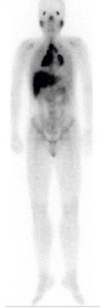
## Sarcoidosis

- Key Sign → Bilateral hilar lymphadenopathy
- Lymph node groups → "1-2-3 sign" (Bilateral hilar + right paratracheal nodes).
- Nuclear Scan (Gallium Scan) Signs:



- "Lambda sign" → Based on lymph node uptake
- "Panda sign" → Uptake in enlarged salivary and lacrimal glands.
- Eggshell calcification of lymph nodes.
- Image 3 → HRCT Features:
  - Fissural nodularity (nodules along the lung fissures).
  - "Galaxy sign" → Large nodule surrounded by smaller satellite nodules.

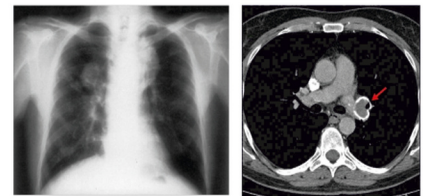


## Silicosis

- History → Sand mine workers.
- Features → Eggshell calcification + "Crazy pavement appearance" (on CT)
- Location → Predominantly upper lobes (mimics TB).

00:43:12

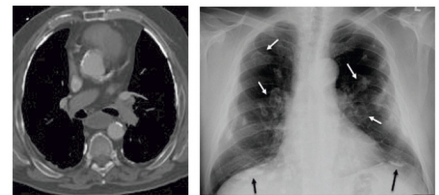
FMGE Jan 2023



## Asbestosis

- History → Shipyard workers
- Location → Predominantly base of the lung (lower lobes)
- Signs → Calcified pleural plaques (Pathognomonic) or "Holly leaf sign" on X-ray
- Malignancy association → Mesothelioma (pleural tumor)

FMGE June 2021

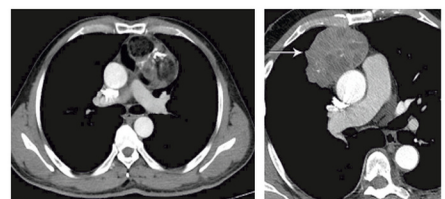


## Mediastinal masses

### Thymoma vs teratoma

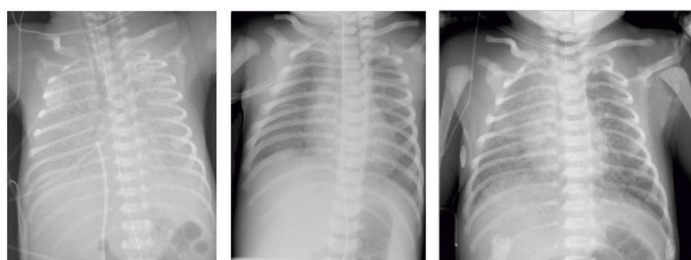
- Image 2 → Thymoma
  - Association → **Myasthenia Gravis** (History of ptosis/fatigue).
  - Location → Anterior mediastinal mass (anterior to aorta/vessels).
- Image 1 → Teratoma
  - Identification → Contains both fat and calcification.
  - CT markers → Hounsfield Unit (HU) value of -65 (indicates fat presence)

NEET PG August 2024



## Respiratory Distress In Newborn

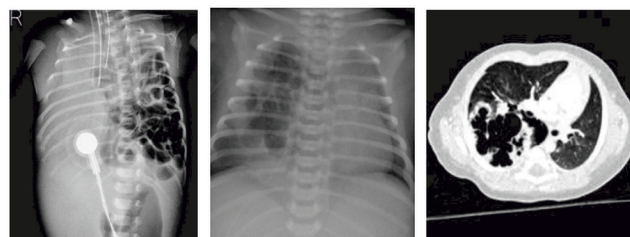
- Image 1 → Hyaline Membrane Disease (HMD)
  - History → Pre-term newborn
  - Features → Bilateral white-out lungs with air bronchogram sign; ↓ lung volume.
- Image 2 → Transient Tachypnea of Newborn (TTN)
  - History → Delivery by LSCS (fluid not squeezed out).
  - Features → Fluid in fissures, "Sun ray appearance," or laminated pleural effusion
  - Progress → Improves within 24-48 hours.
- Image 3 → Meconium Aspiration Syndrome
  - History → Post-term newborn
  - Features → Patchy opacities throughout lungs



## Congenital Diaphragmatic Hernia Vs Cbam

- Image 1 → Congenital Diaphragmatic Hernia (CDH)
  - Features → Round lucencies in the thorax (bowel loops) + mediastinal shift.
  - Sign → Absent diaphragm shadow
- Image 2 & 3 → Congenital Pulmonary Airway Malformation (CPAM/CCAM)
  - Features → Air-filled cystic spaces in the lung
  - Differentiating from CDH → History: 3-year-old with recurrent infections (CPAM) vs. Day 1 respiratory distress and scaphoid abdomen (CDH)

FMGE Dec 2021, FMGE Jan 2024  
NEET PG 2025, NEET PG August 2024



## IOC KEY POINTS

- CXR view for pneumothorax → Expiratory view
- Most sensitive Ix for pleural effusion → Ultrasound
- Most sensitive CXR view for pleural effusion → Ipsilateral decubitus view
- IOC for SPN/ lung lesion → CECT
- Gold std for lung cancer → CT-guided biopsy
- For staging of lung cancer → PET CT
- For bronchiectasis → HRCT
- For interstitial lung disease → HRCT

## ERRORS TO AVOID

- Rib counting (overlap of the 1st and 2nd ribs)
- Consolidation vs collapse:
  - Tracheal shift is absent in consolidation, present in collapse.
- lung abscess vs hydropneumothorax:
  - Abscess is a localized lesion; hydropneumothorax affects the whole hemithorax.
- Consolidation vs pleural effusion:
  - Consolidation has air bronchograms; effusion shows blunting of costophrenic angles.
- Pleural effusion vs hydropneumothorax:

## Yourwish

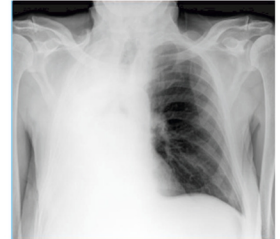
- Effusion has a curved upper border (Ellis S-curve); hydropneumothorax has a straight horizontal air-fluid level.
- CDH vs CPAM:
  - CDH presents immediately at birth; CPAM presents later with recurrent infections.

## PYQ

00:51:06

Q. Which of the following conditions is not a potential cause for the radiological finding shown below?

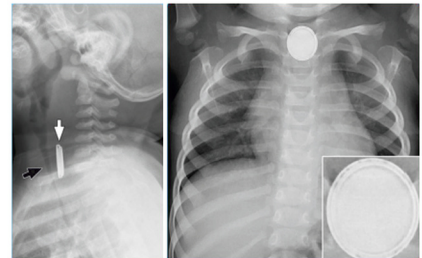
- a. Consolidation
- b. Collapse
- c. Pleural effusion
- d. Foreignbody



**Answer :** a) Consolidation

Q. A child presents with breathlessness .On chest xray , the following object is seen.Identify the object

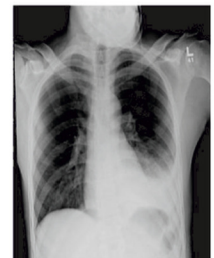- a. Button battery
- b. Coin
- c. Ball
- d. bottle cap



**Answer :** a. Button battery

Q. What is the subject matter of the X-ray image below?

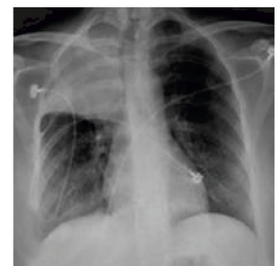- a. Emphysema
- b. Tension pneumothorax
- c. Pleural effusion
- d. Bronchiectasis



**Answer :** c) Pleural effusion

Q. What is the most probable diagnosis based on the image provided?

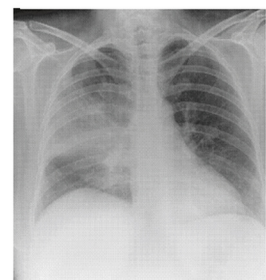
- a. RUL collapse
- b. RUL consolidation
- c. Bronchogenic carcinoma
- d. Lung abscess



**Answer :** a. RUL collapse

Q. The patient has a history of fever and cough for the last 5 days. The examination findings show crepitations, and a chest X-ray is shown below. Based on these details, what is the likely diagnosis for this patient?

- a. Apical segment of right lower lobe consolidation
- b. Right middle lobe consolidation

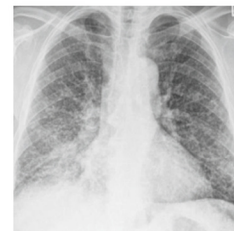


- c. Posterior segment of right lower lobe consolidation
- d. Loculated pleural effusion

**Answer : b. Right middle lobe consolidation**

**Q.** A 25-year-old male presents with a history of low-grade fever and cough. Based on the provided Chest X-ray image, what is the most likely diagnosis?

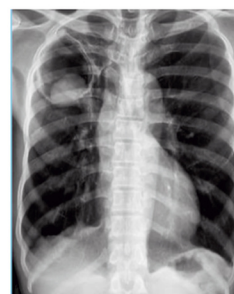- a. Lung cancer
- b. Miliary TB
- c. ARDS
- d. Aspergilloma



**Answer : b. Miliary TB**

**Q.** A patient who has been treated for TB in the past now presented with hemoptysis. Make a diagnosis based on the given X-ray.

- a. Bronchogenic carcinoma
- b. Aspergilloma
- c. Hydatid cyst
- d. Lung abscess



**Answer : b. Aspergilloma**

**Q.** In what situation is popcorn calcification observed?

- a) Hodgkin's lymphoma
- b) Pulmonary hamartoma
- c) Metastasis
- d) Fungal ball

**Answer : b) Pulmonary hamartoma**

**Q.** A 45-year-old patient who has been working in a factory for the past 20 years presents with breathlessness. HRCT of the chest shows pleural thickening and fibrosis. What is the person suffering from?

- a. Asbestosis
- b. Coal worker pneumoconiosis
- c. Silicosis
- d. Berylliosis

**Answer : a. Asbestosis**

**Q.** In which medical condition is a ground-glass appearance observed on high-resolution computed tomography (HRCT)?

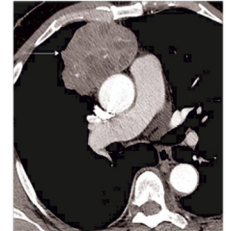- a. Asbestosis
- b. Silicosis
- c. Anthracosis

d. Bagassosis

**Answer : b. Silicosis**

Q. A 45-year-old patient presents with ptosis and muscle weakness that improves with rest. She also complains of dysphagia and has engorged veins in her thorax. Based on the CT scan image provided, what is the most likely diagnosis?

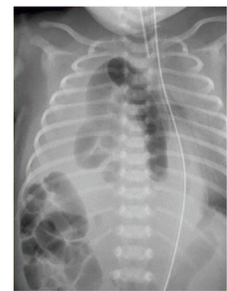- a. Thymoma
- b. Pancoast tumor
- c. Adenocarcinoma
- d. Small cell lung cancer



**Answer : a. Thymoma**

Q. Identify the condition as shown below in the X-ray radiograph of a neonate.

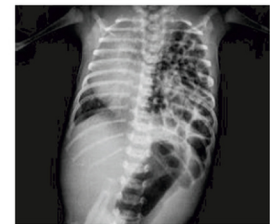- a. Pneumomediastinum
- b. Cystic fibrosis
- c. Congenital diaphragmatic hernia
- d. Bronchiolitis



**Answer : c. Congenital diaphragmatic hernia**

Q. A 24-hour-old baby with severe respiratory distress was admitted to the ICU. A chest X-ray of the neonate is given. What is the most probable diagnosis?

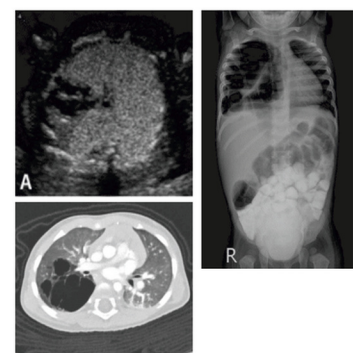
- a. Congenital Pulmonary Airway Malformation (CPAM)
- b. Congenital Diaphragmatic Hernia (CDH)
- c. Congenital lobar emphysema
- d. Neonatal pneumonia



**Answer : b. Congenital Diaphragmatic Hernia (CDH)**

Q. A 3-year-old child presents with respiratory distress and a history of recurrent respiratory infections. Based on the radiographs provided, what is the most likely diagnosis?

- a. Lung abscess
- b. Congenital pulmonary airway malformation
- c. Pyopneumothorax



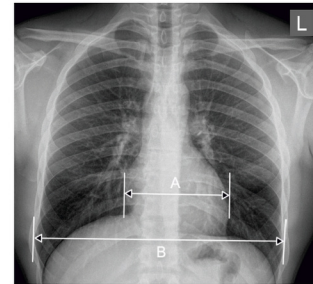
**Answer : b. Congenital pulmonary airway malformation**



# 1. CVS RADIOLOGY

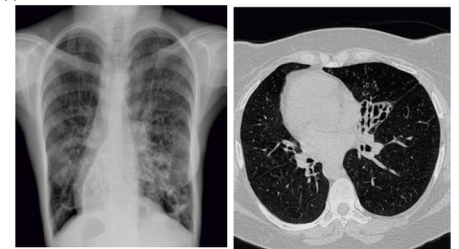
## ANATOMY

- Cardiothoracic ratio
  - Comparing the cardiac size to that of the thoracic size
  - Uses → assess cardiomegaly
  - Normal CTR: **0.5**
- Apex of the heart
  - Normal → towards the left
  - Dextrocardia → apex of the heart towards right and stomach bubble towards left
  - Situs inversus → both apex of the heart and stomach bubble towards right
- Kartagener syndrome
  - Situs inversus
  - Bronchiectasis
  - Infertility



00:00:20

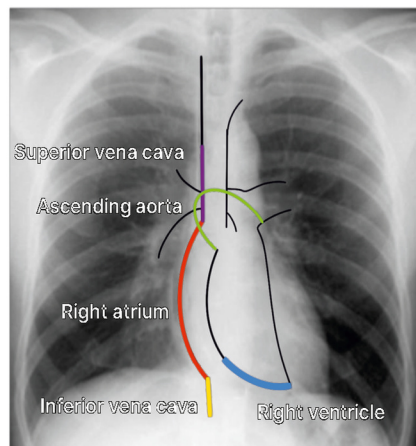
NEET PG August 2024



FMGE 2020, 2021

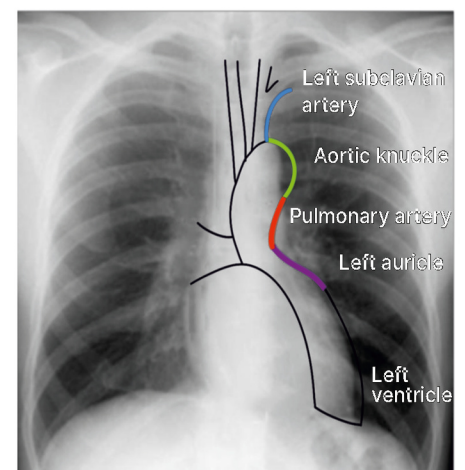
## Identification Of Heart Borders

- Right heart border



- SVC, RA, IVC
- Sometime ascending aorta contributes to right heart border
- Right ventricles do not contribute to the right heart border
- Left heart borders

- Left ventricle, left auricle (left atrial appendage), pulmonary artery, aortic knuckle, left subclavian artery

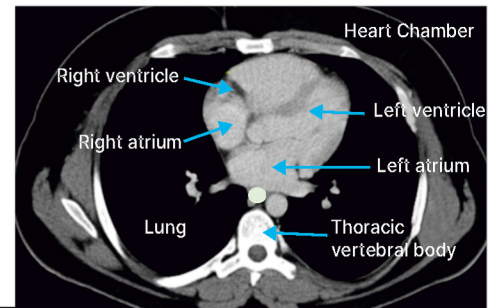


## Yourwish

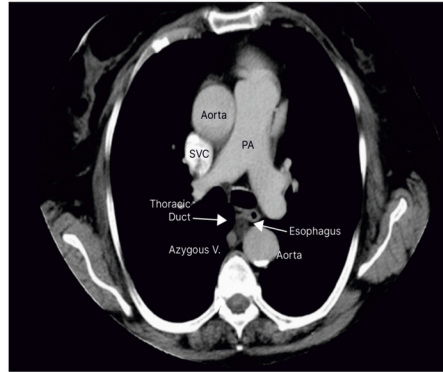
## Identification Of Heart Chambers

NEET PG 2022

- Anterior → Right ventricle
- Posterior → Left atrium
- Esophagus is in close proximity to aorta and LA
  - TEE is done to identify LA thrombus and aortic dissection



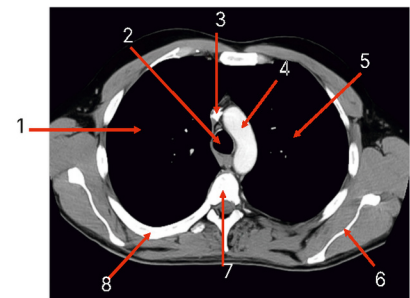
## Identification Of Blood Vessel



- From right to left
  - SVC
  - Aorta
  - Pulmonary artery - divides into right and left and enters lungs

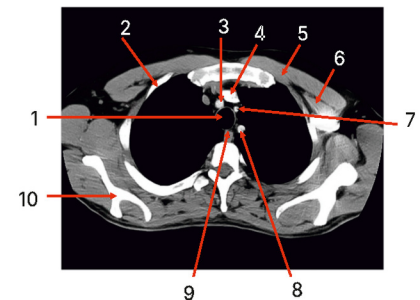
- Cut section at the level of aortic arch

- Arch of aorta
- SVC



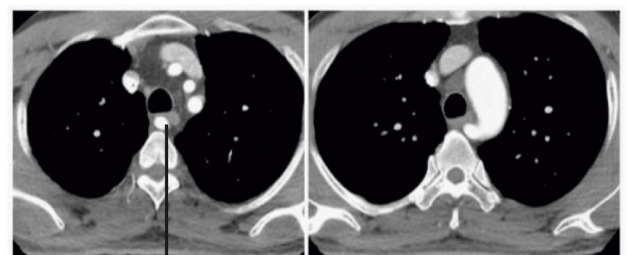
- Cut section above the level of aortic arch

- Branches of aorta → Brachiocephalic trunk, left common carotid, and left subclavian.
- Left and right brachiocephalic veins join to form SVC



- Aberrant right subclavian artery

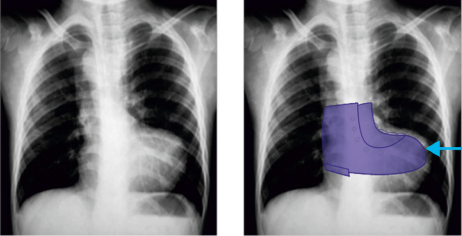
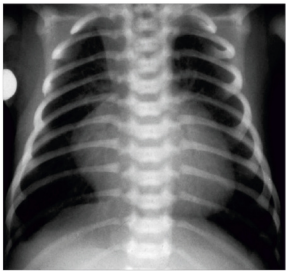
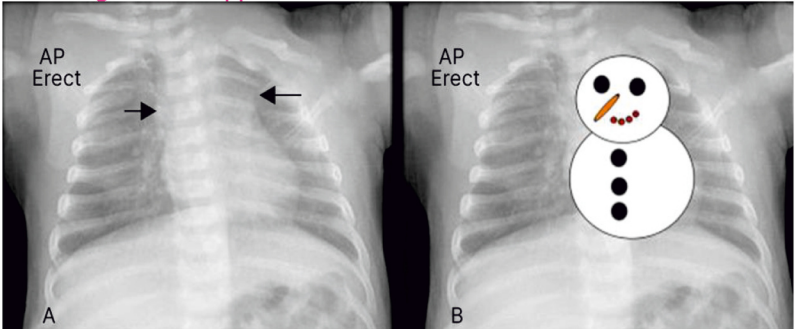
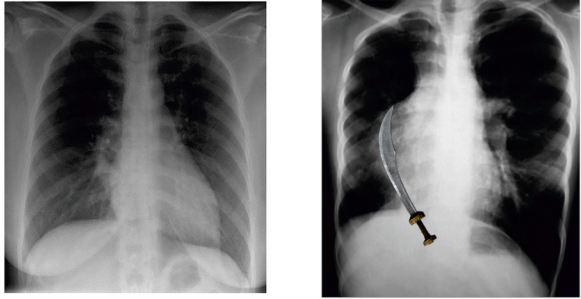
- ARSA arises from arch of aorta and courses from left to right behind the esophagus

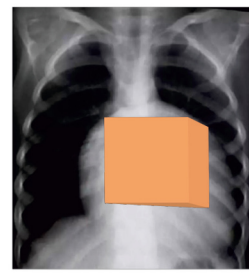
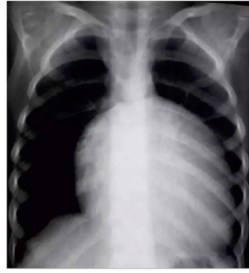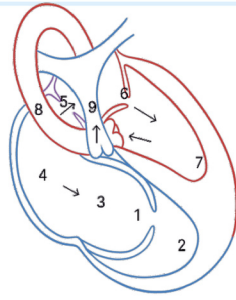


Aberrant

## CONGENITAL HEART DISEASE

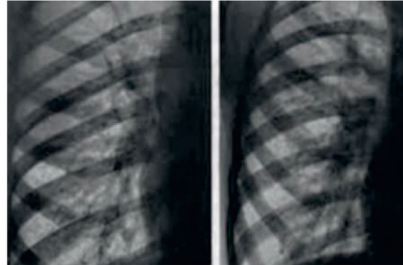
INICET May 2022 00:07:08

Congenital heart disease	Description
<p><b>Tof</b></p>	<ul style="list-style-type: none"> <li>• Boot-shaped heart</li> <li>• Right ventricular hypertrophy → apex turned upwards</li> <li>• Pulmonary stenosis → decreased pulmonary blood flow → Pulmonary oligemia</li> </ul>  <p style="text-align: right;">Boot shaped heart</p>
<p><b>Tga</b></p>	<ul style="list-style-type: none"> <li>• A/w maternal diabetes mellitus</li> <li>• Cyanosis is seen in neonates around day 1 / day 2</li> <li>• Egg on string/side appearance</li> </ul> 
<p><b>Tapvc</b></p>	<ul style="list-style-type: none"> <li>• The pulmonary vein does not drain into the LA</li> <li>• Supracardiac type <ul style="list-style-type: none"> <li>◦ Snowman/figure of 8 appearance</li> </ul> </li> </ul> <p style="text-align: right;">NEET PG 2021</p> 
<p><b>Papvc</b></p>	<ul style="list-style-type: none"> <li>• The right-sided pulmonary vein drains inferiorly</li> <li>• Scimitor appearance</li> </ul> 
<p><b>Ebstein anomaly</b></p>	<ul style="list-style-type: none"> <li>• Occurs due to teratogenic effect of lithium</li> <li>• Downward displacement of tricuspid valve</li> <li>• Enlarged RA → moves beyond sternum → Box-shaped heart</li> </ul>



**Asd**

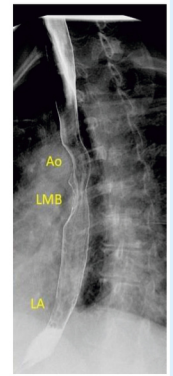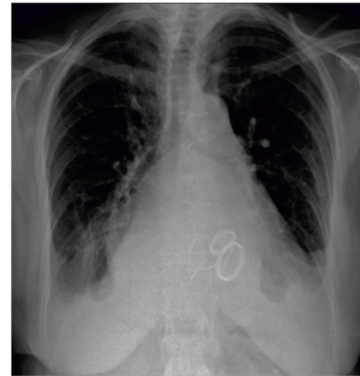- Hilar dance → prominent pulsation of pulmonary artery



**Mitral stenosis**

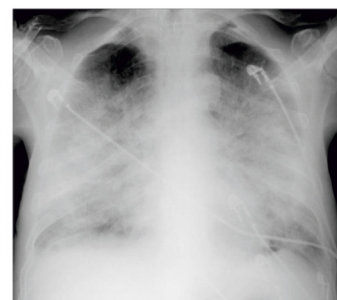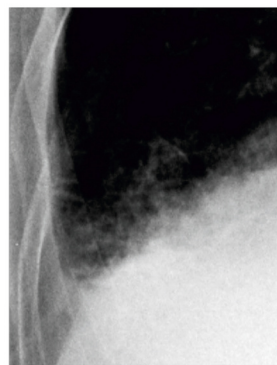
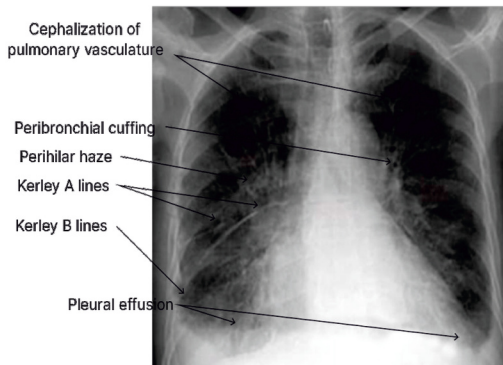
- MS leads to left atrial enlargement
- LAE → LA pushed towards left, up, and then right
- LA towards left
  - Straightening of left heart border
- LA towards up
  - Left main bronchus elevation → Increased carina
- LA towards right
  - Double-density sign
- LA enlargement causes compression of the esophagus

NEET PG 2021, INICET July 2021



**CONGESTIVE HEART FAILURE**

00:12:35



- Pulmonary vein congestion → pulmonary venous hypertension
  - Cephalisation ( upper lobe vessels becomes prominent )
- Interstitial edema
  - Kerley B lines
- Pulmonary alveolar hypertension
  - Opacities in both lungs → **Bat wing appearance**
  - Cardiomegaly
- Pleural effusion

## Non Cardiogenic Pulmonary Edema

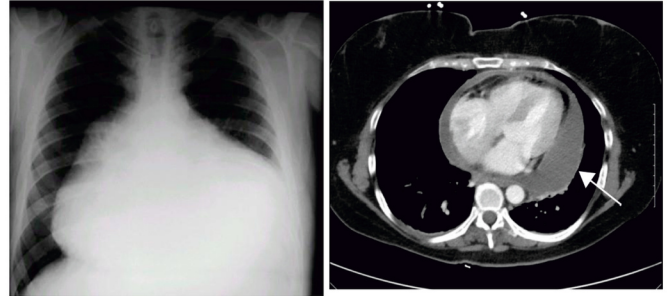
- a/k/a ARDS
- No cardiomegaly
- Develops following pancreatitis

## PERICARDIAL PATHOLOGIES

00:14:52

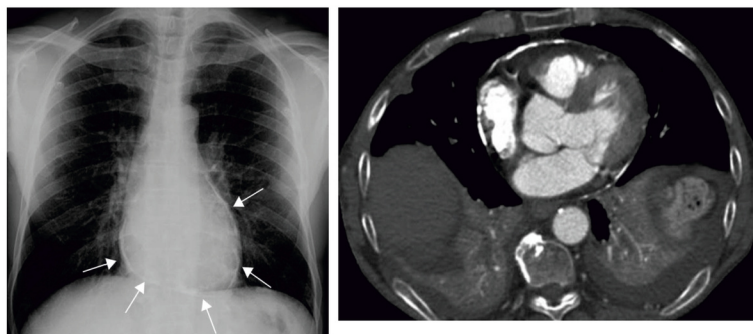
### Pericardial Effusion

- Fluid surrounding the pericardium
- Water bottle/money bag appearance
- IOC - Echocardiogram



### Calcific Chronic Pericarditis

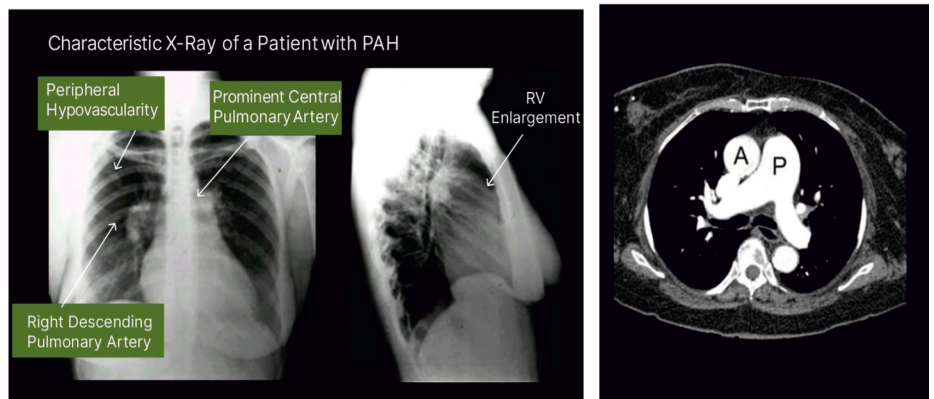
- Calcific deposition
- In India → a/w TB



## PULMONARY PATHOLOGIES

00:16:24

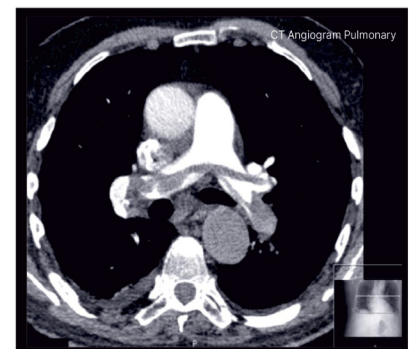
### Pulmonary Artery Hypertension



- Enlarged PA → RV hypertrophy
  - Enlargement of RV → RV pushed anteriorly → loss of retrosternal space
- Peripheral pulmonary vessels are constricted → **Pruned tree appearance**
- Diameter of Pulmonary artery > Aorta → PAH

### Pulmonary Embolism

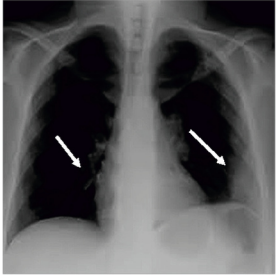
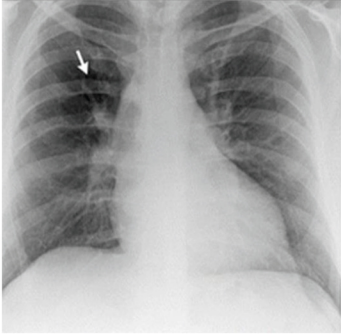
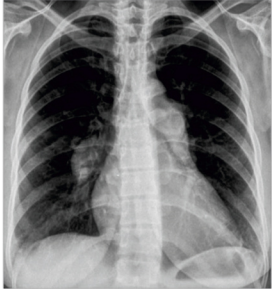
- Cause → DVT
- Clinical features
  - Tachypnea
  - Respiratory distress
- Investigations
  - Screening → elevation of D-dimer
  - IOC → CTPA / CECT



## Yourwish

→ Contrast filling defect in the pulmonary artery → **saddle embolism**

○ X ray

Signs seen on X-ray in pulmonary embolism	
Palla sign	<ul style="list-style-type: none"> <li>Prominent right descending pulmonary artery</li> </ul> 
Hampton's hump	<ul style="list-style-type: none"> <li>Infarct</li> </ul>
Westermarck sign	<ul style="list-style-type: none"> <li>Decreased vascular markings → focal oligemia</li> </ul> 
Fleischner sign	<ul style="list-style-type: none"> <li>PA is prominent than aortic knuckle</li> </ul> 

## AORTIC PATHOLOGIES

### Coarctation Of Aorta

- Focal narrowing in the aorta
- Figure of 3 appearance
- Pathology

Narrowing of aorta occurs distal to subclavian artery

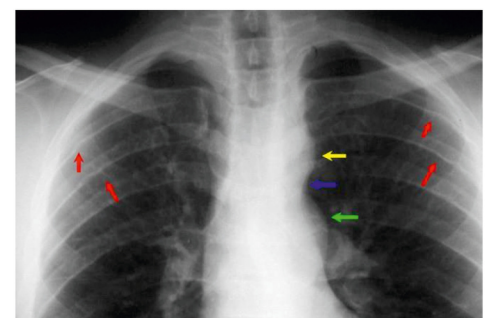


Compensation occurs



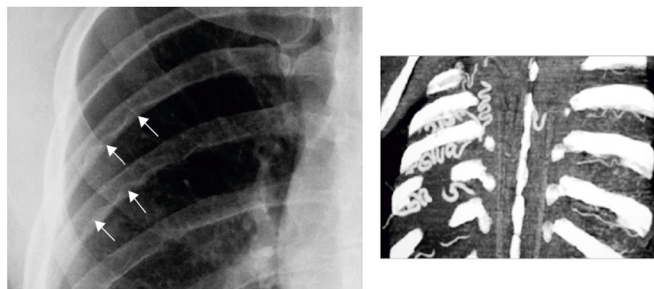
Collaterals are formed by Intercostals arteries

- Radiofemoral delay → Lower limb BP is less than upper limb BP
- Inferior rib notching → Prominent intercostal arteries



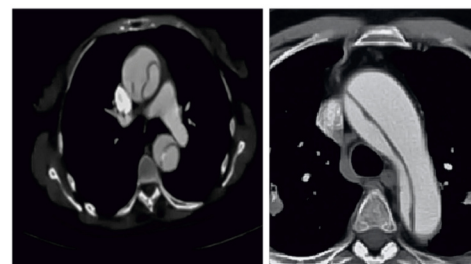
00:21:03

NEET PG 2021

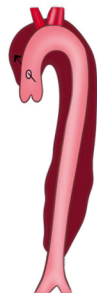
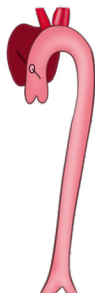



### Aortic Dissection

- Aortic lumen is divided into two due to intimal tear
- Risk factor → Hypertension
- 2 lumen
  - True lumen
  - False lumen
- Clinical features
  - Chest pain radiating to back
  - Upper limb BP is unequal
- Classification
  - Stanford A → ascending aorta involved with/without descending aorta
  - Stanford B → ascending aorta not involved



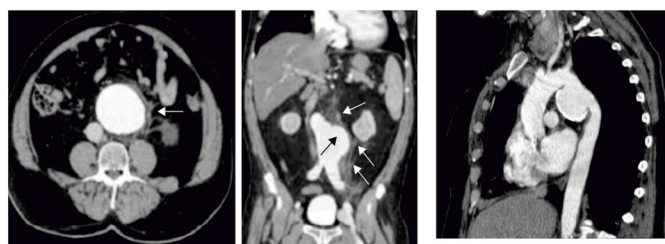
FMGE June 2021, NEET PG 2023

Classification			
Percentage	60%	10-15%	25-30%
Type	DeBakey I Stanford A (Proximal)	DeBakey II Stanford A (Proximal)	DeBakey III Stanford B (Distal)
			

- IOC
  - Stable patient → CECT
  - Unstable patient → TEE

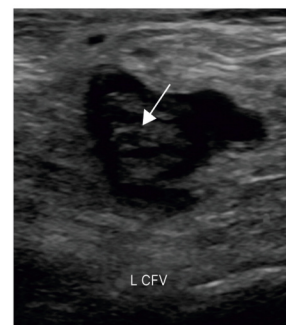
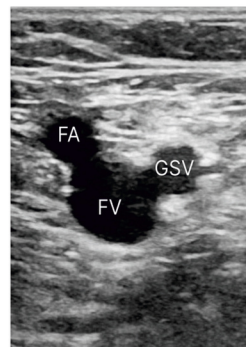
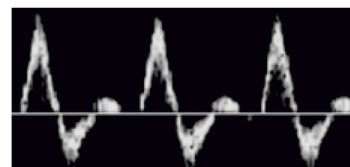
### Aortic Aneurysm

- Dilatation of the aorta
- Cause → Atherosclerosis
- Abdominal aorta > 3cm
- It can be saccular or fusiform
- True size of aneurysm is identified by CT angiogram
- Investigations used for interventions → CT angiogram
- Investigations used for surveillance → USG



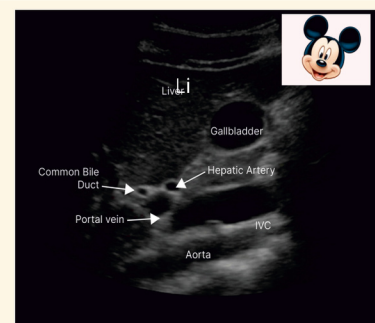
## PERIPHERAL VESSELS

- A patient with intermittent claudication → 1st Investigations done is doppler
- Normal peripheral arterial doppler
  - Triphasic waveform
- DVT → USG with Doppler
  - Non - compressible vein
  - Absent flow in Doppler
  - Echogenicity suggests thrombus
- Mickey Mouse sign
  - Seen at **Sphenofemoral junction**
  - Great saphenous vein draining into common femoral vein

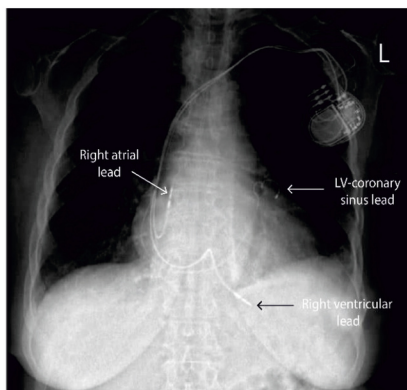


### Important Information

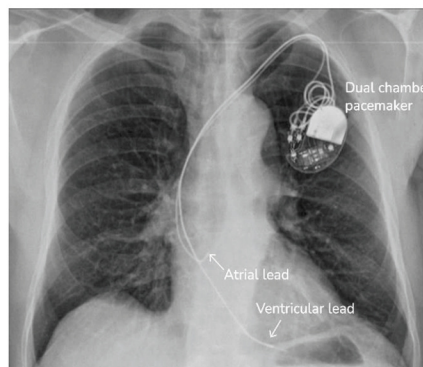
- Mickey Mouse sign present at other site → **Portal triad**
  - Portal vein
  - Hepatic artery
  - Common bile duct



## PACEMAKER



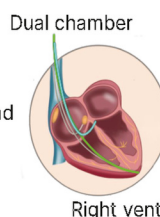
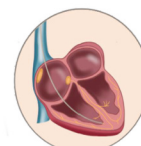
Biventricular pacemaker



Dual lead pacemaker

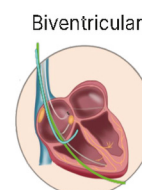
Single chamber - Lead goes into right ventricle

- Position of pacemaker leads are identified with the chest X-ray
- Single chamber
  - Lead goes into the right ventricle
- Dual chamber
  - Lead goes into the right atrium and ventricle
- Biventricular
  - Leads goes into the right atrium and ventricle
  - Via coronary sinus leads are placed in left ventricle also
- Implantable cardioverter defibrillator



Right atrial lead

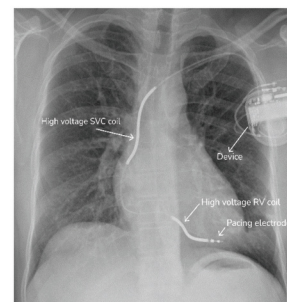
Right ventricular lead



Left ventricular lead via coronary sinus

Right ventricular and atrial leads

- Presence of thick isolating coils
- Gives defibrillation in case of arrhythmias



ICD

## INVESTIGATION OF CHOICE

00:30:49

- X-ray
  - Cardiothoracic ratio to detect cardiomegaly
- CT
  - Calcium score → Agatston score
  - Detects the calcification load in atherosclerosis
- USG / Echo
  - For pericardial effusion
  - TEE for LA pathology and aortic dissection
- MRI - LGE (Late gadolinium enhancement)
  - S/O scar seen in MI
- Nuclear scans
  - For ejection fraction → MUGA
  - For myocardial ischemia → Thallium scan
- Pulmonary embolism IOC → CTPA / CECT

## ERROR FILES

00:32:15

- Pulmonary edema
  - Cardiogenic
    - Cardiomegaly
    - Heart failure
  - Non cardiogenic
    - No cardiomegaly
    - Pancreatitis → ARDS
- Dextrocardia → apex of the heart towards right and stomach bubble towards left
- Situs inversus → both apex of the heart and stomach bubble towards right
- Coarctation of the aorta → Inferior rib notching

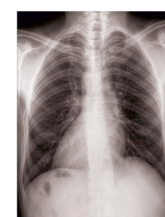## PYQ

00:32:59

NEET PG August 2024

Q. Patient presents with recurrent lung infections, and CXR is given below. What is the most likely diagnosis?

- Kartagener syndrome
- Cystic fibrosis
- Digeorge syndrome
- Down syndrome

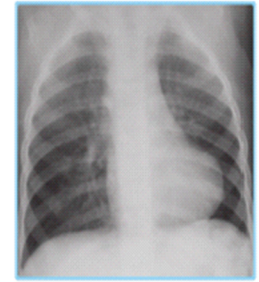


## Yourwish

**Ans: a. Kartagener syndrome**

Q. A child presents with cyanosis. His chest radiograph is shown below. What is the diagnosis?

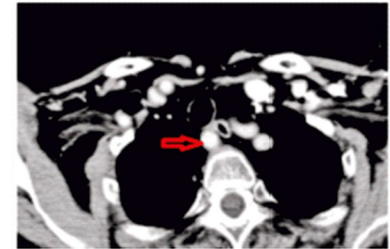
- Tetralogy of Fallot (TOF)
- Ebstein's anomaly
- Transposition of great arteries (TGA)
- Total anomalous pulmonary venous return (TAPVC)



**Ans: a. Tetralogy of Fallot (TOF)**

Q. Identify the vascular structure marked in the given radiology image?

- Aberrant right subclavian artery
- Aberrant left subclavian artery
- Ascending aorta
- Main pulmonary artery



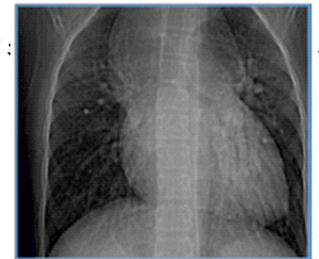
INI CET May 2024

**Ans: a. Aberrant right subclavian artery**

- Compression of esophagus by aberrant right subclavian artery leads to dysphagia lusoria

Q. A 12-week-old infant presented with fever, cyanosis, and fatigue. His chest X-ray is : most likely diagnosis?

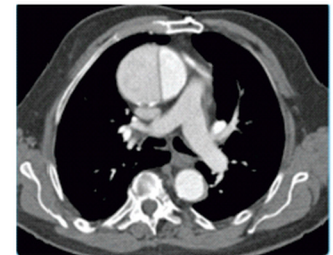- Total anomalous pulmonary venous circulation
- Tetralogy of Fallot
- Transposition of great arteries
- Pericardial effusion



**Ans: a. Total anomalous pulmonary venous circulation**

Q. Comment on the diagnosis of CT chest shown below.

- Aortic dissection
- Pulmonary embolism
- Cardiac myxoma
- Aortic aneurysm



**Ans: a. Aortic dissection**

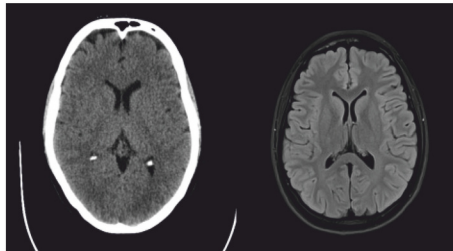
- Involvement of ascending aorta → Stanford type A
- Requires immediate intervention



## 2. NEURORADIOLOGY

### CT vs MRI

00:00:22

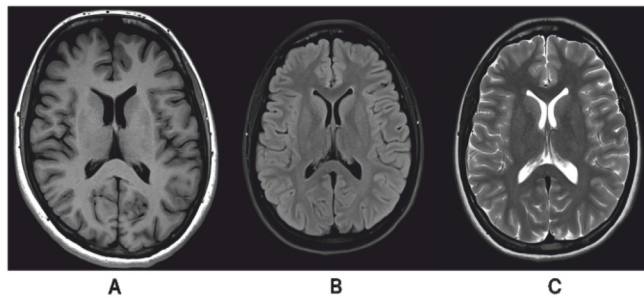


- On a CT scan, bone appears white
- On MRI, bone appears black

### MRI Sequences

00:01:03

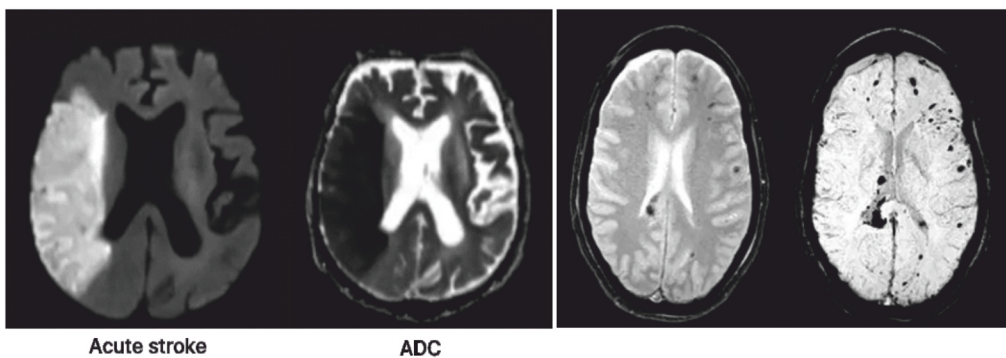
FMGE June 2021



	T1	FLARE	T2
CSF	Black	Black	White
White Matter	White	Black	Black

### Dwi Vs Swi

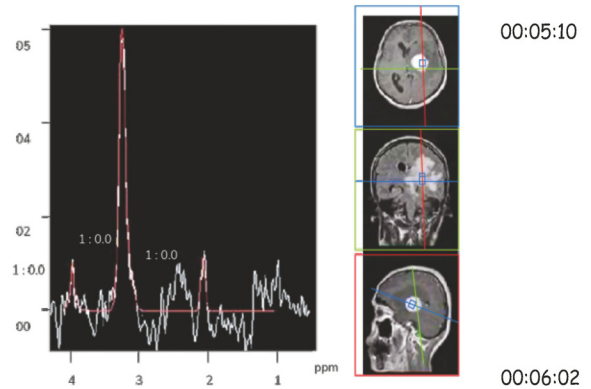
00:03:14



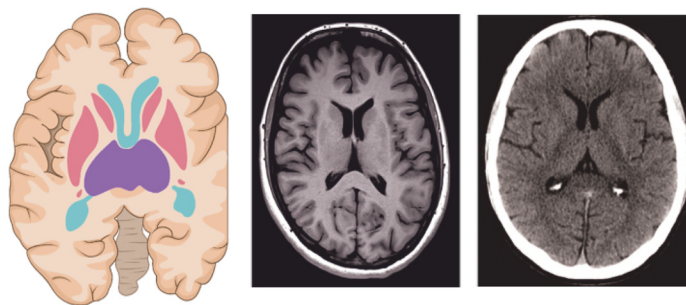
Diffusion weighted Imaging (DWI)	Susceptibility Weighted Imaging (SWI)
<ul style="list-style-type: none"> <li>• Most sensitive investigation for diagnosing acute infarct                             <ul style="list-style-type: none"> <li>○ Restricted diffusion</li> </ul> </li> </ul>	<ul style="list-style-type: none"> <li>• Helps to differentiate hemorrhage from calcification</li> <li>• Appears like "areas of blooming" (black areas)</li> </ul>

**Mr Spectrography**

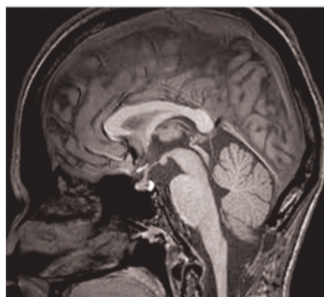
- Graph of chemical metabolites in the brain
- Normal brain: NAA peak
- Tumors: Choline peak
- TB: Lipid Peak



**NORMAL ANATOMY**

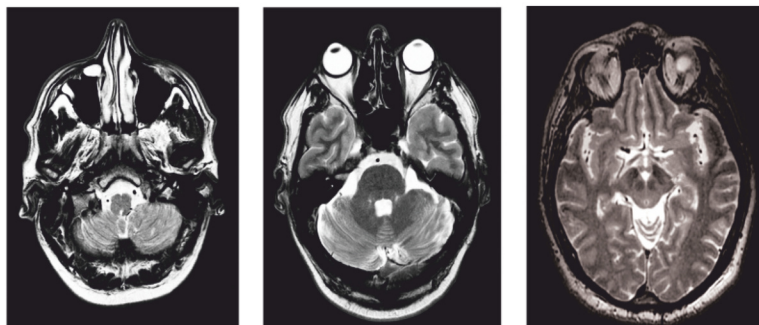


- T1-weighted MRI
- CT scan
- Sagittal Anatomy:



**Identification Of Medulla, Pons & Midbrain**

00:09:10



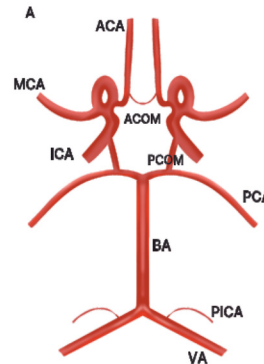
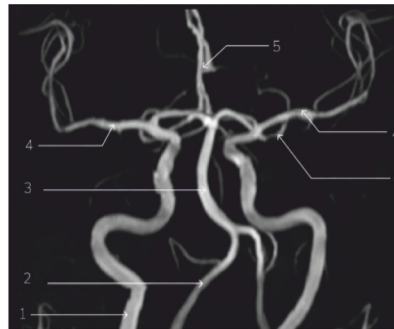- Midbrain: Mickey Mouse or heart-shaped
- Red nucleus inside the midbrain
- Basilar artery lies anterior to the pons

- The 4th Ventricle and cerebellum lie posterior to the pons
- The vertebral arteries lie adjacent to the medulla oblongata

**Angiogram**

00:10:23

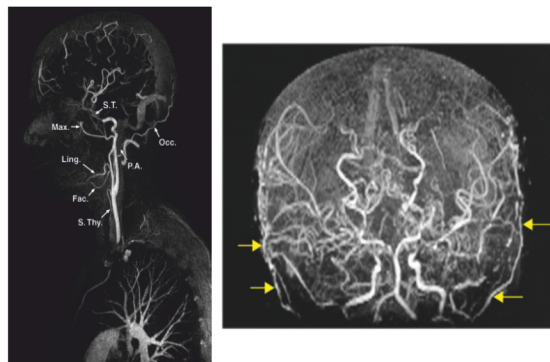
INICET Nov 2024



- 2 vertebral arteries join to form the basilar artery
- Terminal branch of basilar artery: Posterior Cerebral Artery (PCA)
- Branch of vertebral artery: Posterior-Inferior Cerebellar Artery (PICA)
- The internal carotid artery gives 2 terminal branches:
  - Anterior Cerebral Artery (anterior)
  - Middle Cerebral Artery (horizontal & lateral)
- Posterior Communicating Artery (PCOM) joins ICA & PCA

**Superficial Temporal Artery**

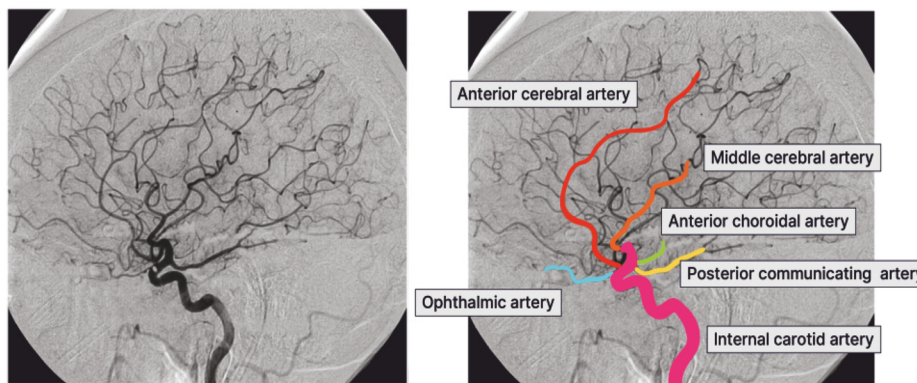
INICET Nov 2024



- Terminal branch of the External Carotid Artery (ICA)

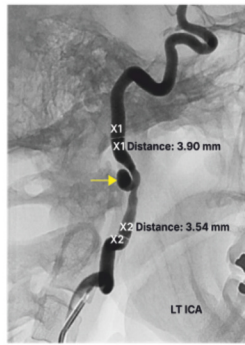
**Digital Subtraction Angiography**

00:12:08



- Vessels appear black

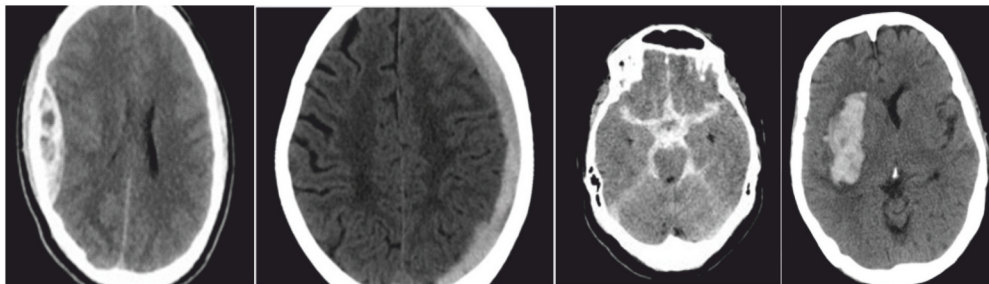
Ica Pseudoaneurysm



CNS HEMORRHAGE

00:13:16

FMGE Jan, June 2024, NEET PG August 2024, NEET PG 2023



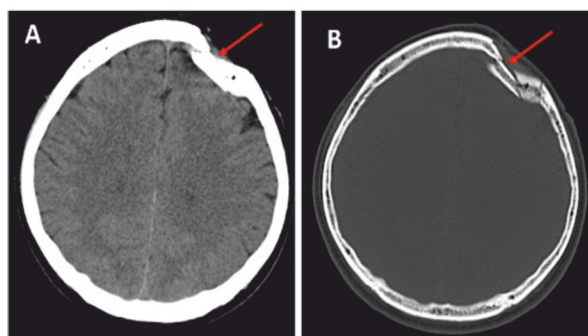
EDH	SDH	SAH	ICH
<ul style="list-style-type: none"> <li>• Extra-dural Hemorrhage</li> <li>• Biconvex or lentiform shaped</li> <li>• Occurs due to rupture of the middle meningeal artery (MMA)</li> <li>• Does not cross the sutures</li> </ul>	<ul style="list-style-type: none"> <li>• Subdural Hemorrhage</li> <li>• Sickle shape</li> <li>• Occurs due to rupture of bridging veins</li> <li>• Crosses midline</li> </ul>	<ul style="list-style-type: none"> <li>• Sub-arachnoid Hemorrhage</li> <li>• Sub-arachnoid space is replaced by blood</li> <li>• Occurs due to rupture of berry aneurysm</li> <li>• "Star of death" appearance</li> <li>• Thunderclap headache</li> <li>• IOC: NCCT Head followed by CT Angiography</li> </ul>	<ul style="list-style-type: none"> <li>• Intracranial/ Intraparenchymal Hemorrhage</li> <li>• IOC: NCCT</li> <li>• MCC: Hypertension</li> <li>• MC Site: Putamen (Basal Ganglia)</li> </ul>

CNS TRAUMA

Depressed Skull Fracture

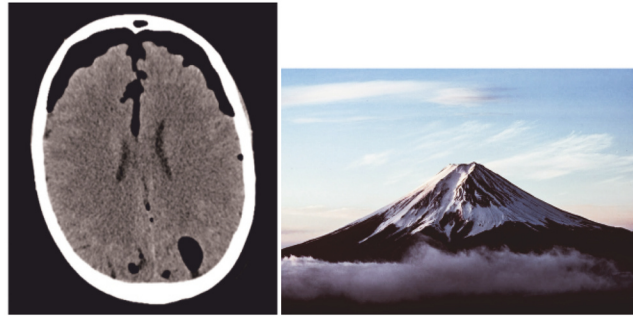
00:15:40

FMGE July 2023



**Pneumocephalus**

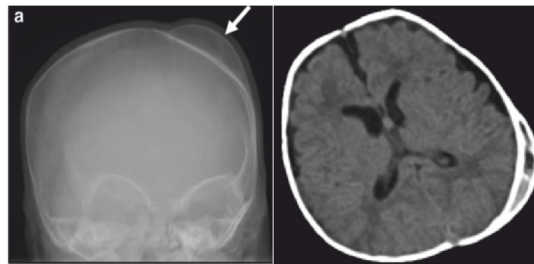INICET May 2024



- Mount Fuji sign

**Cephalohematoma**

FMGE June 2024

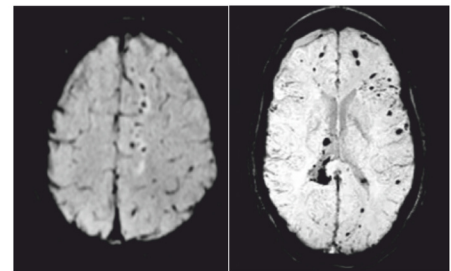


- Unilateral
- Calcified margin
- Does not cross midline

**Diffuse Axonal Injury**

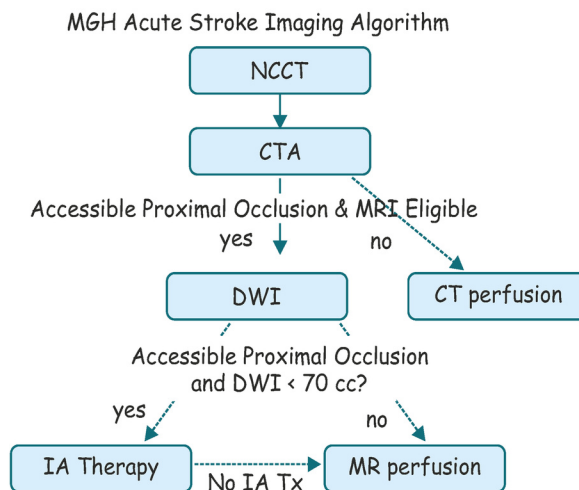
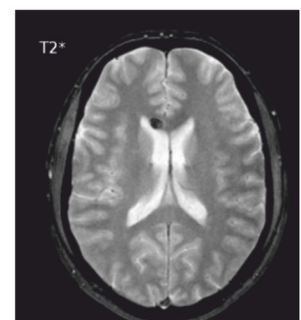
INICET July 2021

- MC in road traffic accident patient with GCS worsening
- CT scan is normal or shows small punctate hemorrhages
- IOC: SWI MRI
  - Punctate Hemorrhages
  - Areas of blooming involving the corpus callosum
- Adam's grading is used

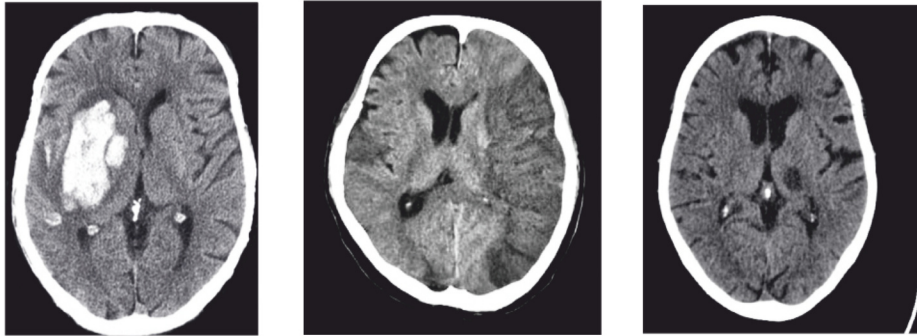


**STROKE IMAGING**

- Focal neurological deficit
- First investigation: NCCT
  - To differentiate the cause of stroke: infarct or hemorrhage

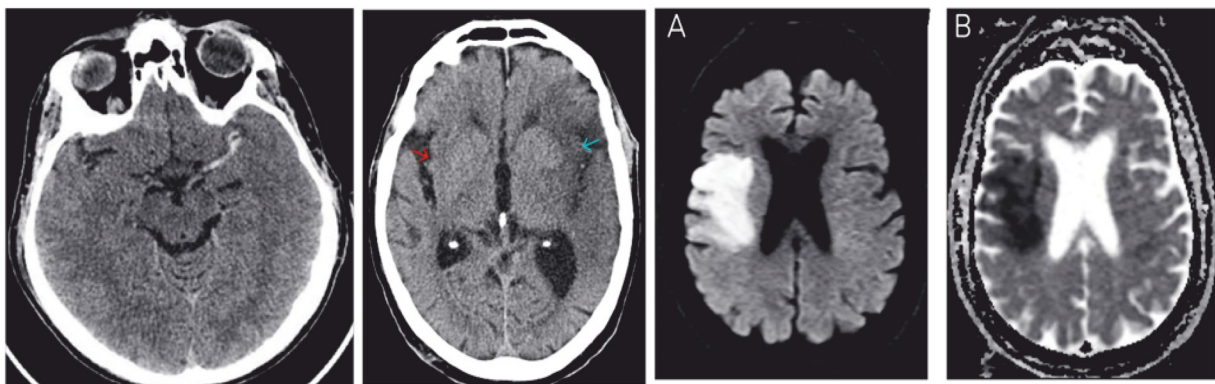


## Infarct Vs Hemorrhage



- NNCT-
  - Hemorrhage - Hyperdense (white)
  - Hypodense - Infarct (black/grey)

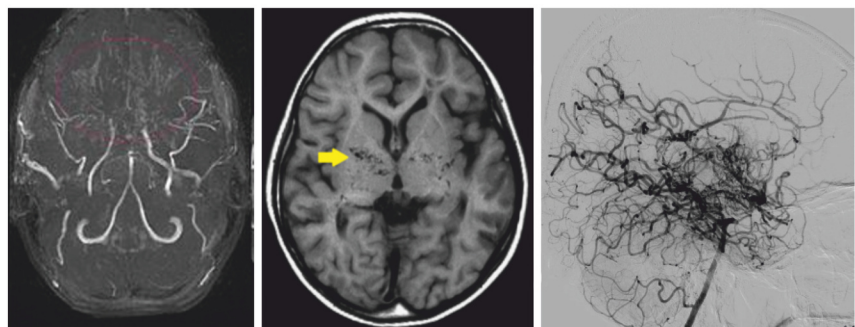
## Acute Infarct Signs



- Hyperdense vessel sign (Hyperdense MCA sign)
- Hypodense insula area - **Loss of insular ribbon sign**
- Restricted diffusion in DWI MRI

## Moya Moya Disease

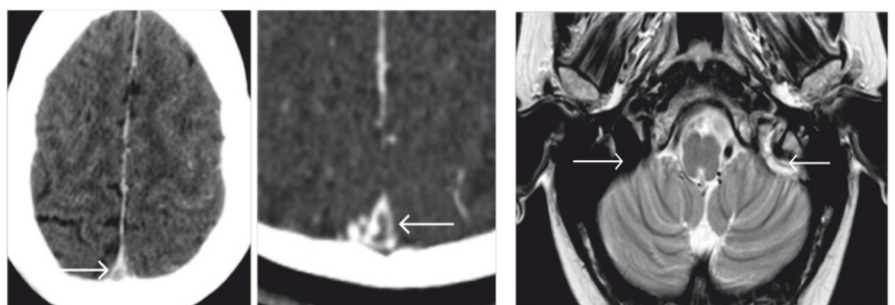
- Commonly seen in children with history of transient ischemic attack (TIA)
- ICA stenosis
- The brain develops collaterals
- Puff of Smoke' appearance on DSA



00:22:56

## Dural Venous Thrombosis

- Venous occlusion leads to the formation of hemorrhagic infarcts
- Superior sagittal thrombosis: **Empty Delta sign** on CECT
- Absent flow void on MRI
- IOC: MR Venogram

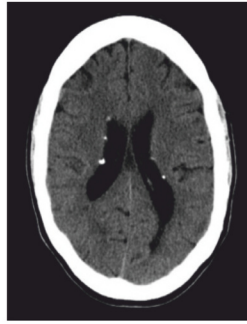


00:24:06

## NEURO CUTANEOUS SYNDROMES

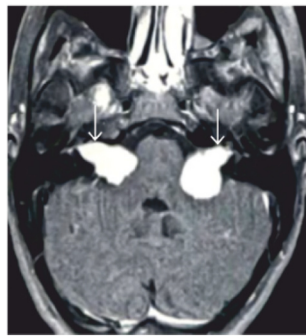00:25:33

### Tuberous Sclerosis



- Calcified sub-ependymal nodules
- Can enlarge and form SEGA (Subependymal Giant Cell Astrocytoma)
  - MC site: Foramen of Monro

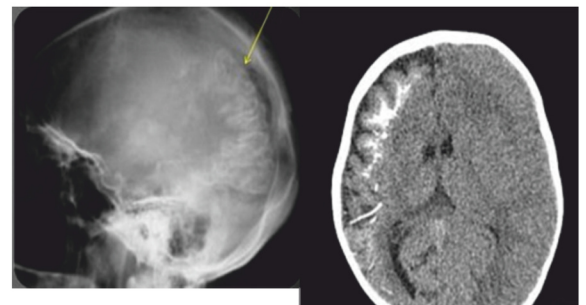
### Neurofibromatosis



- Tumor at the cerebellopontine angle
- **Ice-cream cone appearance** - Vestibular Schwannoma
- B/L Vestibular Schwannoma: NF-2

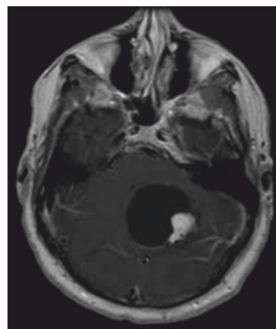
### Sturge-Weber Syndrome

- Port-wine stain
- History of seizures
- Gyri-form Tram-tract calcifications
- Cortical atrophy



### Von-Hippel Lindau Disease

NEET PG August 2024



- Cerebellar hemangioblastoma
- Appears as a cystic lesion with an enhancing mural nodule
- DD: Pilocytic Astrocytoma

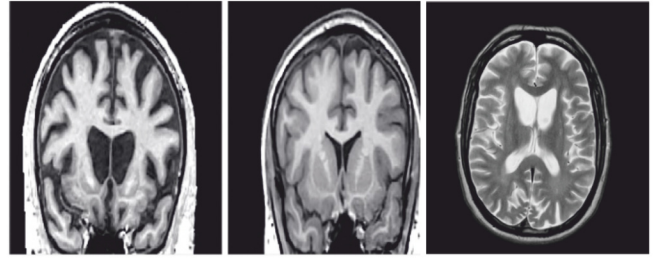
## NEURODEGENERATIVE DISEASES

00:28:51

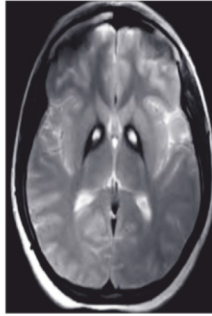
INICET Nov 2025

### Huntington's Disease

- 3 M's:
  - Movement abnormality
  - Mood - Irritable
  - Memory impairment (dementia)
- Cause: Caudate atrophy
- Box car ventricle

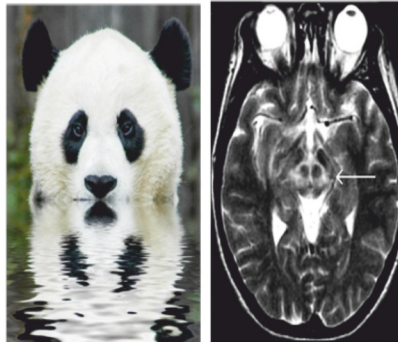
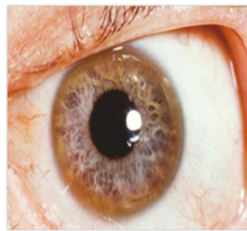
### Pantothenate Kinase-Associated Neurodegeneration (Pkan)/ Hallervorden-Spatz Syndrome



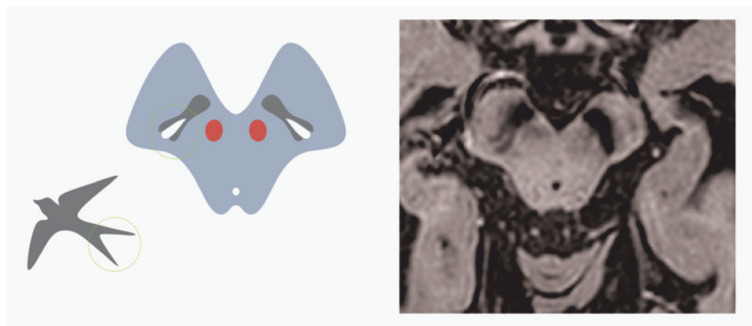
- Eye of the Tiger' sign in Globus Pallidus

### Wilson's Disease



- KF rings
- Face of Giant Panda' sign

### Parkinson's Disease



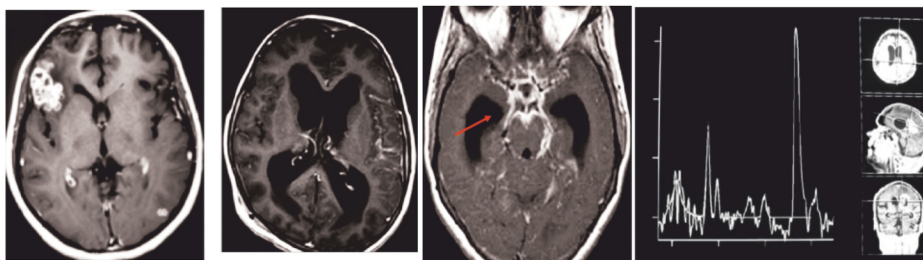
- Absence of swallow tail sign or split tail sign

## INFECTIONS

00:31:58

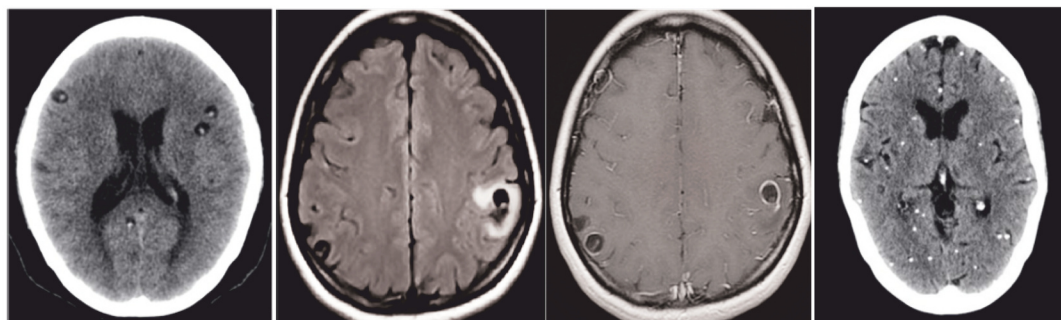
### Tuberculosis

- Causes CNS tuberculomas
- Ring-enhancing lesions
- Conglomerate lesions
- Tubercular meningitis
- Hydrocephalus
- IOC: MRI with contrast
- Basal exudates
- MR spectroscopy:  
Lipid peak (mycolipid in TB bacteria)



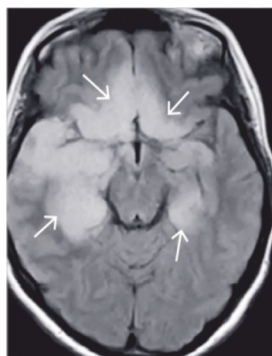
### Neurocysticercosis

INICET May 2025



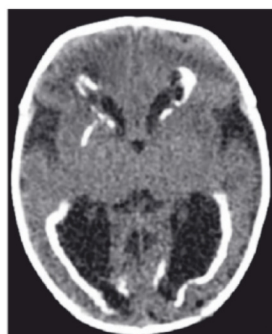- Cyst with scolex (Cyst with dot appearance)
- Edema
- Ring-enhancing lesion with a dot inside
- Starry sky appearance

### Hsv Encephalitis



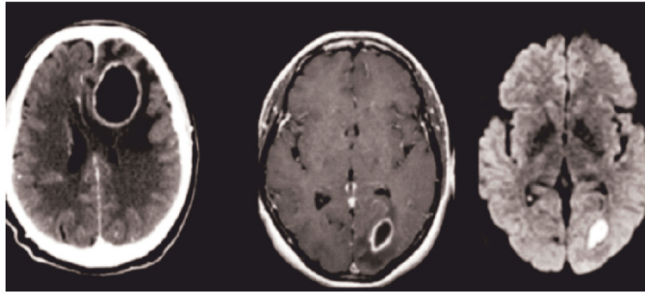
- The temporal lobe is usually affected
- Generally hemorrhagic in nature

### Congenital Cmv



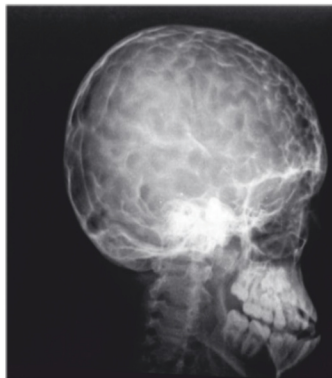
- Calcifications around ventricles: **Periventricular calcifications**

## Brain Abscess



- Pus in center (non-enhancing)
- Ring-enhancing lesion
- Central restricted diffusion on DWI

## Raised Icd

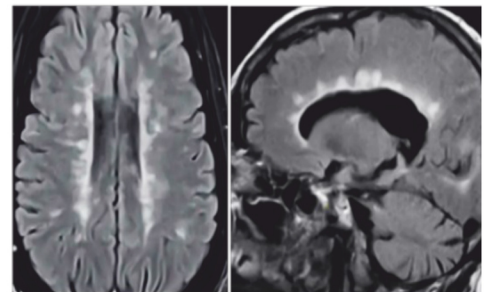


- Copper/Silver beaten skull appearance
- First sign in child: Sutural diastasis

## DEMYELINATING LESIONS

### Multiple Sclerosis

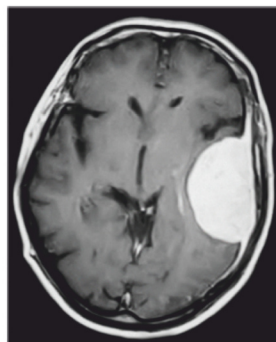
- History of a young-adult female with:
  - Optic neuritis
  - Myelitis
- Demyelinating plaques in periventricular regions → Dawson's Fingers
- Axial MRI: Dawson's Fingers
- IOC: MRI with contrast
  - Enhancing: Active lesion (Relapse)



00:36:43

## BRAIN TUMORS

### Meningioma



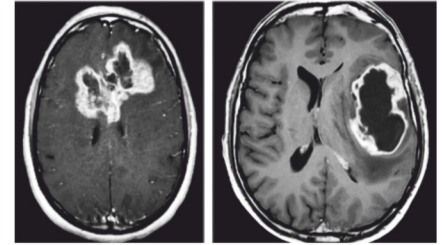
- Extra-axial brain tumor
- Enhances homogeneity
- Dural tail sign

00:37:55

NEET PG 2025

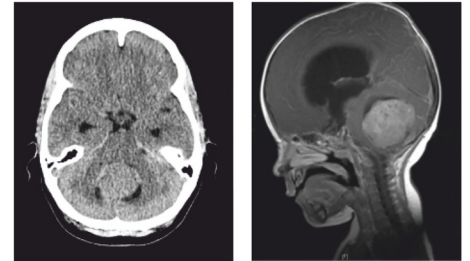
**Glioblastoma Multiforme**

- Highly aggressive tumor
- Central necrotic non-enhancing areas
- Peripheral irregular enhancement
- Can cross midline and involve the corpus callosum: **Butterfly Glioma**

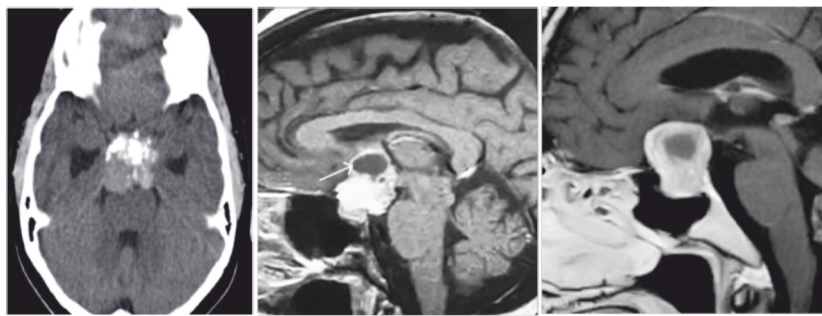


**Medulloblastoma**

- History of a child with a posterior fossa lesion & hydrocephalus
- Hyperdense on CT scan (due to high vascularity)
- Upstream hydrocephalus
- Related to the roof of the 4<sup>th</sup> ventricle



**Craniopharyngioma Vs Pituitary Adenoma**



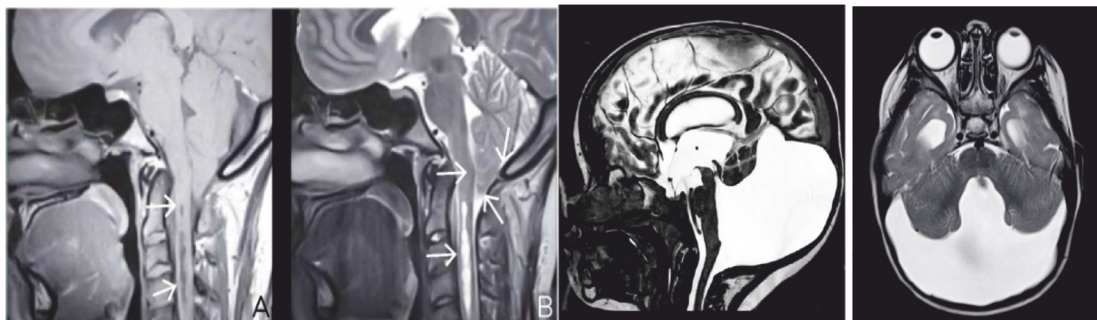
Craniopharyngioma	Pituitary Adenoma
<ul style="list-style-type: none"> <li>• Suprasellar lesion</li> <li>• Seen in:                             <ul style="list-style-type: none"> <li>○ Child</li> <li>○ Centre</li> <li>○ Calcification</li> <li>○ Cystic Lesion</li> <li>○ Cholesterol-like fluid</li> </ul> </li> <li>• Bitemporal Hemianopia</li> </ul>	<ul style="list-style-type: none"> <li>• Sellar Lesion</li> <li>• Widening of Sella</li> <li>• Figure-of-8 appearance</li> </ul>

**CONGENITAL MALFORMATIONS**

**Arnold Chiari Vs Dandy Walker Malformation**

00:41:30

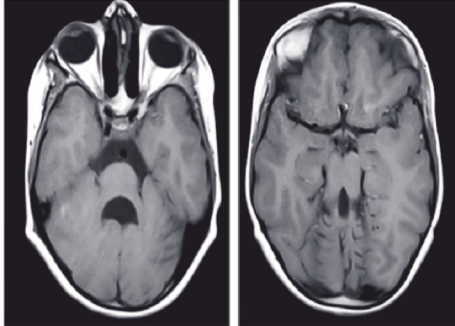
NEET PG August 2024



## Yourwish

Arnold-Chiari Malformation	Dandy-Walker Malformation
<ul style="list-style-type: none"> <li>• Small posterior fossa</li> <li>• Cerebellar tonsil gets herniated</li> <li>• Peg-like tonsils in AC type I</li> <li>• Central dilated syrinx</li> </ul>	<ul style="list-style-type: none"> <li>• Large cystic lesion in posterior fossa</li> <li>• Communicates with 4<sup>th</sup> ventricle</li> <li>• Keyhole appearance</li> <li>• Vermis is absent</li> </ul>

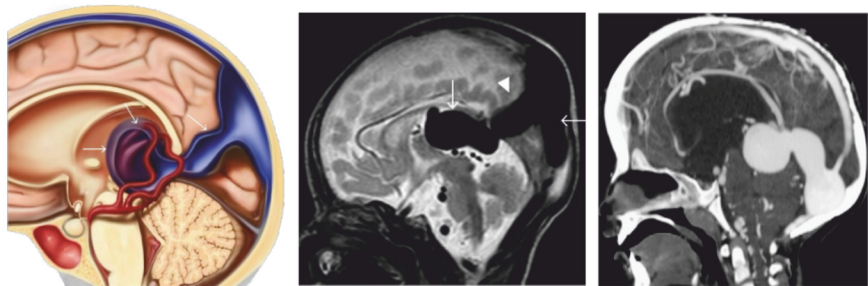
## Jobert Syndrome



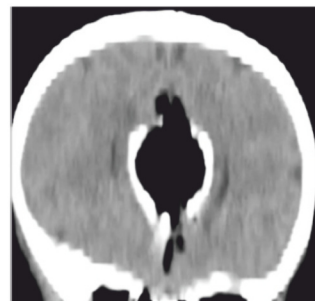
- Elongated superior cerebellar peduncles
- Molar-tooth sign

## Vein Of Gallen Malformation

- AV fistula in brain
- Hydrocephalus
- Heart failure



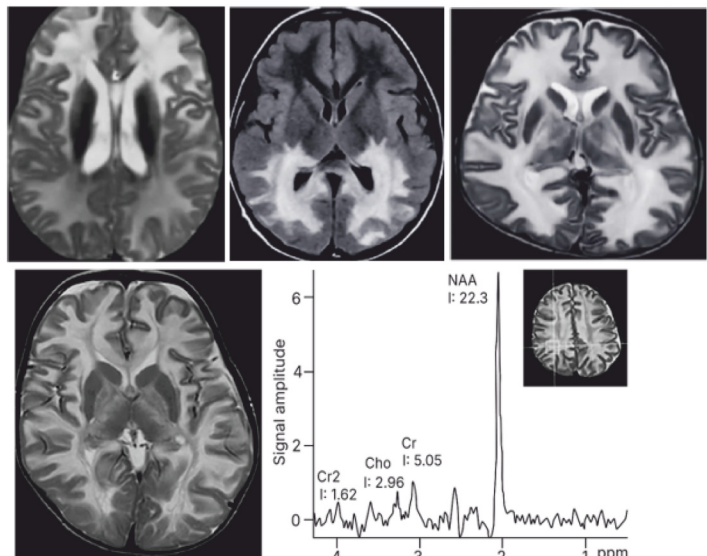
## Corpus Callosal Lipoma



- Bracket Calcification

## Leukodystrophy

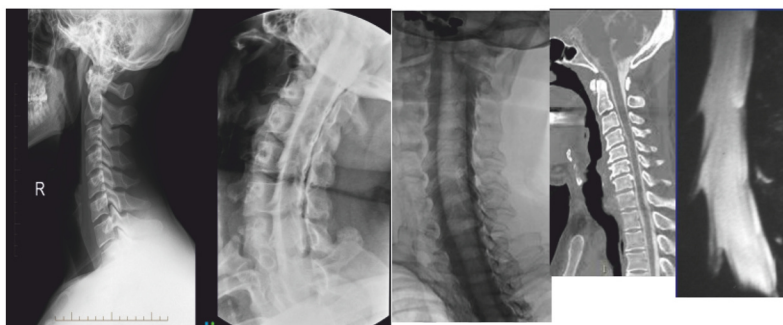
- Alexander Leukodystrophy
  - Affects the frontal white matter predominantly
- X-linked adrenoleukodystrophy
  - Affects the peritrigonal posterior white matter predominantly
- Canavan's Leukodystrophy
  - Continuous white matter is involved
  - NAA peak on MR Spectroscopy



## SPINE IMAGING

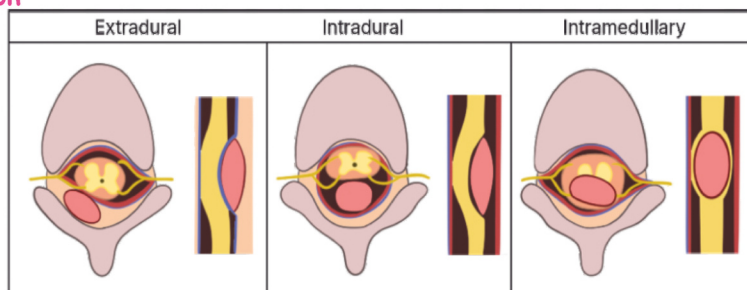
- Imaging modality of choice: MRI

### Mr & Ct Myelogram



- Contrast surrounding spinal cord in MRI or CT scan
- Head-low position

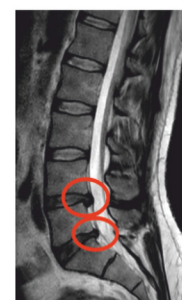
### Localization Of The Lesion



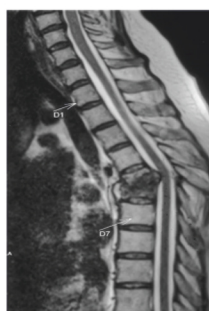Extra-Dural	Intra-Dural	Intra-Medullary
<ul style="list-style-type: none"> <li>Compression of sub-arachnoid space</li> </ul>	<ul style="list-style-type: none"> <li>Expansion of sub-arachnoid space</li> </ul>	<ul style="list-style-type: none"> <li>Dilated cord lesions</li> <li>Trouser leg appearance</li> </ul>

### Disc Herniation

- IOC: MRI Spine
- T2 bright disc - Normal
- T2 dark disc - Herniated disc
- In L4-L5 disc herniation: L5 nerve root is compressed
- In L5-S1 disc herniation: S1 nerve root is compressed



### Pott's Spine

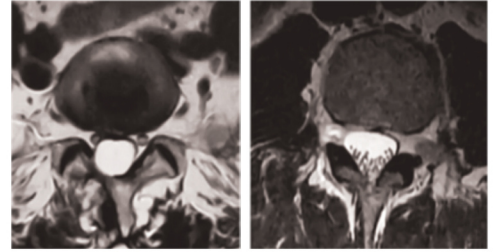


- TB spine involves intravertebral disc and adjacent vertebrae
- Can form epidural abscess

FMGE June 2022

### Empty Theca Sign

- Seen in Arachnoiditis
- Thecal sac appears white without any nerve roots



### INVESTIGATION OF CHOICE

00:50:45

- IOC for head injury: NCCT
- IOC for DAI: SWI MRI
- IOC for traumatic paraplegia: MRI
- First investigation in stroke: NCCT Head
- Most sensitive investigation for acute infarct: DWI-MRI
- Role of CT perfusion in stroke: To look at penumbra region
- IOC for acute hemorrhage: NCCT
- IOC for chronic hemorrhage: SWI-MRI
- MRI sequence for differentiating hemorrhage from calcification: SWI-MRI
- IOC for posterior fossa brain: MRI
- IOC for brain tumor/Vestibular schwannoma: MRI with contrast
- IOC for degenerative spine: MRI spine

### Errors To Avoid

00:52:03

- Infarct vs Chronic hemorrhage
  - Infarct: Well-defined lesion
  - Hemorrhage: Not well-defined
- SAH vs Meningitis
  - SAH: Neck stiffness and Headache
  - Meningitis: Neck stiffness and Fever

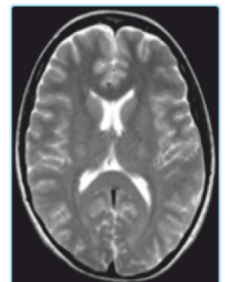
### PYQs

00:53:02

Q. Which of the following MRI imaging techniques is shown in the image below?

FMGE June 2021

- T1-MRI
- T2-MRI
- STIR
- FLAIR

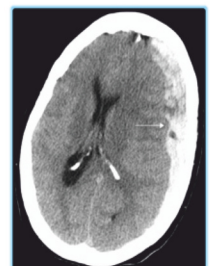


Ans: d

Q. Which type of intracranial haemorrhage is most likely depicted in the image given below?

FMGE Jan 2024

- Extradural Hemorrhage
- Sub-arachnoid Hemorrhage
- Subdural Hematoma
- Intraparenchymal Hemorrhage

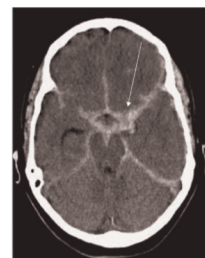


Ans: c

Q. A 40-year-old female patient with complaints of persistent headache. A CT-scan of the head was performed, as shown below. What is the most accurate diagnosis?

NEET PG August 2024

- Sub-arachnoid Hemorrhage
- Epidural Hemorrhage
- Subdural Hemorrhage
- Intraparenchymal Hemorrhage

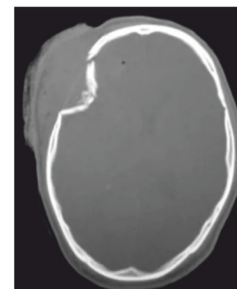


Ans: a

Q. A patient presented with a head injury after a hammer fell on the skull. His CT scan is given below. What is the likely diagnosis?

FMGE July 2023

- Concussion
- Epidural Hematoma
- Depressed skull fracture
- Sub-arachnoid Hemorrhage



Ans: c

Q. Mount Fuji sign on CT scan is seen in which of the following conditions?

- Pneumocephalus
- Pneumoperitoneum
- Pneumomediastinum
- Pneumothorax

Ans: a

Q. A 22-year-old male was brought to the emergency room after being involved in a car accident. During the examination, his GCS was E2M2V3. There was no fracture, hydrocephalus, or increased ICP within the skull. An NCCT was conducted and revealed no abnormalities. What is the suspected diagnosis?

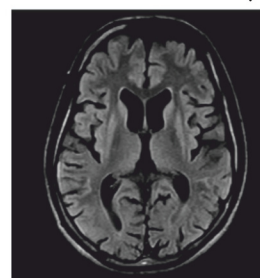
- Diffuse axonal injury
- Post-concussion syndrome
- Extradural Hemorrhage
- Herniation of the brain

Ans: a

Q. A 28-year-old man presents with involuntary, jerky movements of the face and limbs that have gradually worsened over the past year. His family reports personality changes, irritability, and progressive forgetfulness. O/E, he has choreiform movements involving both upper limbs and lower limbs and an unsteady gait. What is the most likely diagnosis?

INICET Nov 2025

- Tardive dyskinesia
- Huntington's disease
- Sydenham's chorea
- Tourette syndrome



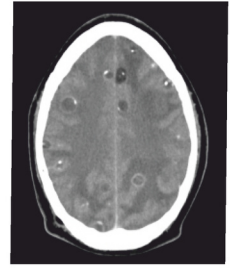
## Yourwish

Ans: b

Q. Based on the CT image, what is the diagnosis?

- Tuberculoma
- Brain abscess
- Neurocysticercosis
- Brain Metastasis

INICET May 2025

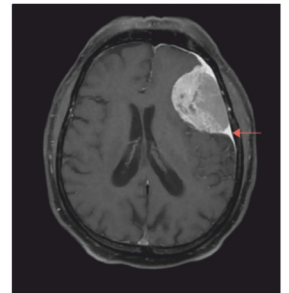


Ans: c

Q. A 30-year-old male presents with complaints of recurrent headache and nausea. His MRI brain is given below. What is the diagnosis?

- Meningioma
- Glioma
- Ependymoma
- Pilocytic Astrocytoma

NEET PG 2025

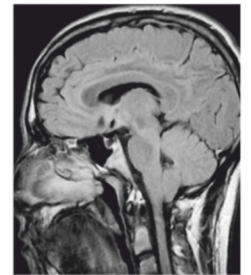


Ans: a

Q. Using the provided MRI, which diagnosis is most likely?

- Chiari type-1 malformation
- Dandy-walker malformation
- Vein of Galen malformation
- Corpus callosum agenesis

NEET PG August 2024

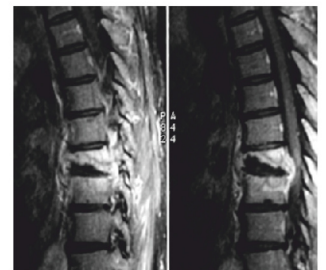

Ans: a

Q. Based on the provided image, what is the possible diagnosis?

- Multiple myeloma
- Ankylosing spondylitis
- Pyogenic spondylitis
- Pott's spine

FMGE June 2022



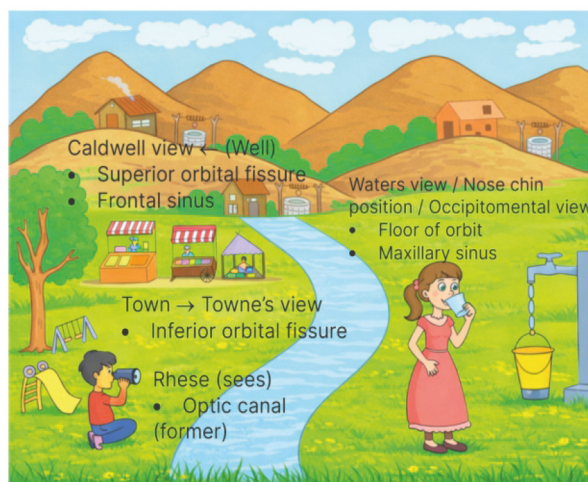Ans: d



## 2. HEAD AND NECK IMAGING: PNS, TEMPORAL BONE, ORBIT & NECK

### X-RAY VIEWS

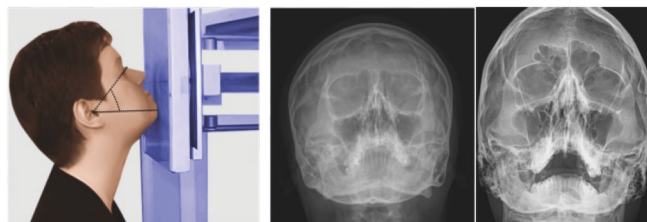
- Caldwell View
  - Superior orbital fissure
  - Frontal sinus
- Water's View (Occipitomeatal View/Head-Chin View)
  - Floor of orbit
  - Maxillary sinus
- Towne's View
  - Inferior orbital fissure
- Rhese's View
  - Optic canal



00:00:32

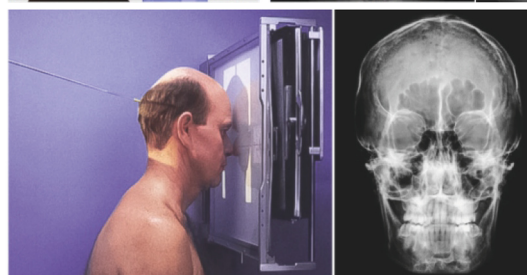
### Water's View

- Maxillary sinus appears black (normally, as it contains air)
- Modified Water's view with open mouth: Pierre's View
  - Sphenoid Sinus



### Caldwell View

- Occipito-frontal view
- Nose-forehead position
- Frontal sinus
- Maxillary sinus is not visible due to bone overlapping it

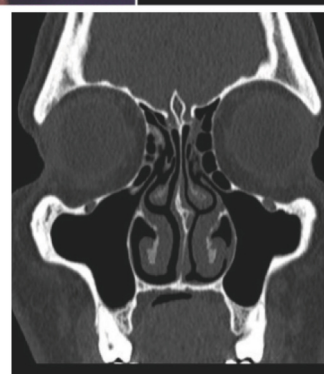

00:02:44

### CT PNS

#### Normal Anatomy & Variants

- Best investigation for PNS
- Gold standard investigation before FESS
- Osteo-meatal Unit
  - Maxillary sinus ostium drains into infundibulum then into hiatus semilunaris and middle meatus
- Uncinate process will be absent in a patient who has undergone FESS (Uncinectomy is done in FESS)



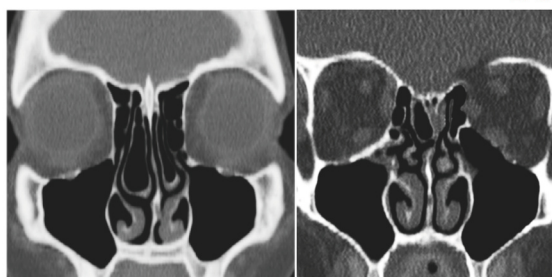
00:03:18

### Concha Bullosa

- Middle turbinate inflated by air
- Pneumatization of the middle turbinate (Image 1)
- Pneumatization of the superior turbinate (Image 2)

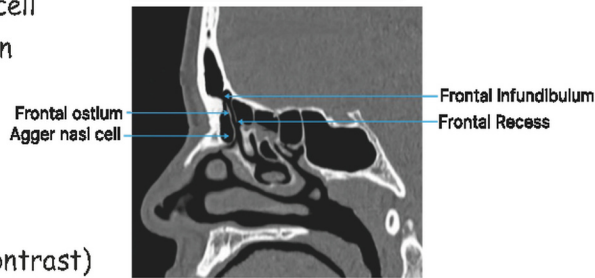
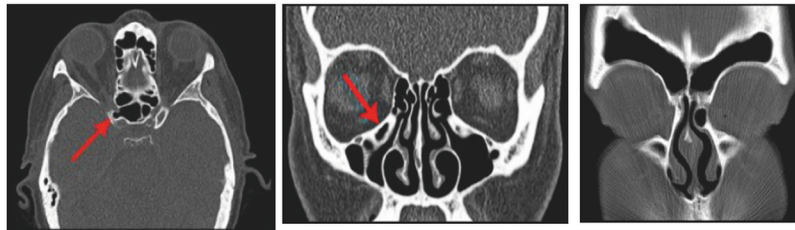
### Onodi, Haller & Agger Nasi Cell

- Onodi Cell:



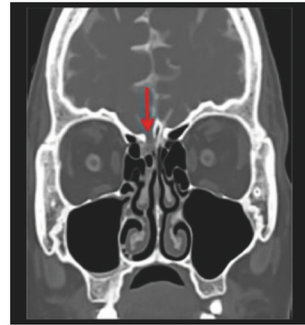INI CET Nov 2021

- Posterior ethmoidal cell
- Related to the optic nerve (ON)
- Haller Cell
  - Infraorbital air cell
- Agger Nasi Cell
  - Anterior most ethmoidal cell
  - On sagittal reconstruction



**Ct Cisternogram**

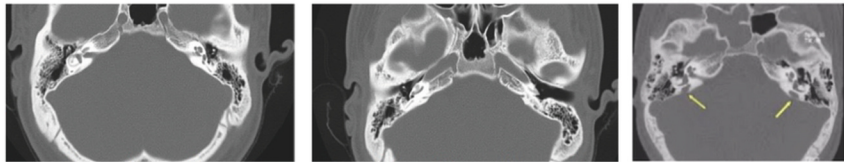
- CSF appears white (due to contrast)
- Indications:
  - CSF leak
  - CSF rhinorrhea
  - CSF otorrhea
- Helps localize the site of CSF leak



00:07:00

**Temporal Bone Anatomy**

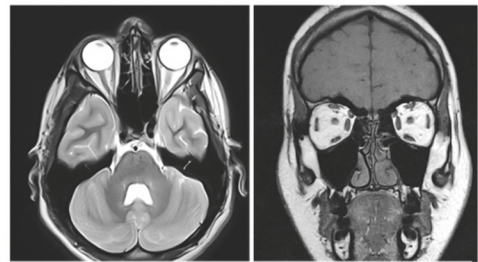
- Mastoid air cells
- Posterior to interior auditory canal lies the vestibular aqueduct
- Carotid canal contains the internal carotid artery



00:08:03

**Orbit Anatomy**

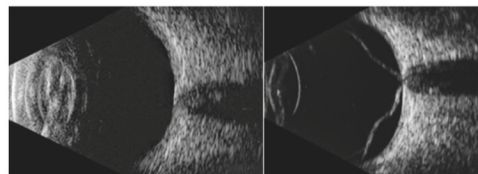
- Optic nerve is surrounded by:
  - Medially: Medial Rectus
  - Laterally: Lateral Rectus



00:09:32

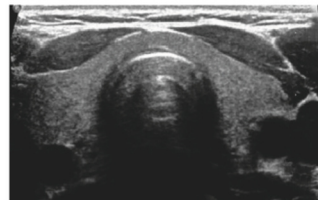
**B-scan Of Orbit**

- Helps to visualize and evaluate the posterior segment of the eye (vitreous humor & retina)
- Vitreous appears black
- Retinal detachment:
  - The retina is detached except from the optic nerve head
  - History of "curtain falling" vision loss



**USG NECK**

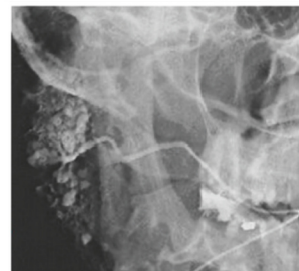
- Trachea surrounded by the thyroid gland
- Parathyroid glands lie posterior to the thyroid gland



00:11:44

**SIALOGRAPHY**

- X-ray with contrast of the salivary glands
- Invasive procedure
- Not used now
- Indications: Salivary gland stones



00:12:13

**PATHOLOGIES**

**Allergic Fungal Sinusitis**

- Double density:
  - Fungal elements appear white
  - Mucus appears grey
- Serpiginous appearance

**Antrochoanal Polyp**

- Polyp filling up the maxillary sinus and coming out of the ostium and going posteriorly into the choana
- Retention cyst present

**Mucocele**

- Dilated & expanded sinus with thinned-out wall
- Appears grey on CT scan (due to mucus)
- T2 Hyperintense appearance
- Can compress the orbit & cause proptosis

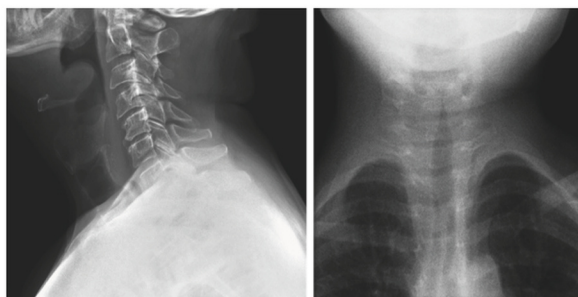
**Juvenile Nasopharyngeal Angiofibroma (jnaf)**

- Clinical Presentation: Adolescent male with recurrent epistaxis
- IOC: CECT/CT Angiography
  - **Hollman Miller sign**
    - Anterior bowing of the posterior wall of the maxillary sinus due to compression from JNAF

**Carotid Body Tumor/chemodactoma**

- **Lyre's sign**
  - Widening of the space between the internal & external carotid artery

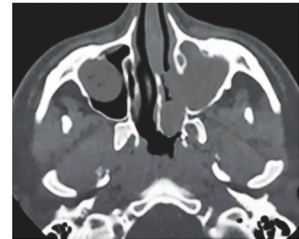
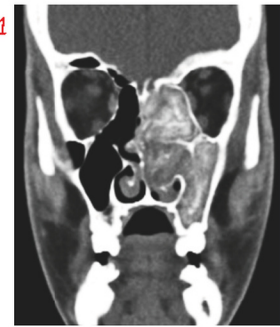**Epiglottitis Vs Croup**



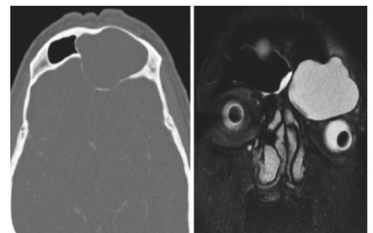Epiglottitis	Croup
<ul style="list-style-type: none"> <li>• Clinical Presentation:                             <ul style="list-style-type: none"> <li>◦ Sick patient</li> <li>◦ Drooling of saliva</li> <li>◦ Difficulty swallowing</li> </ul> </li> <li>• Epiglottitis appears like a thumb: <b>Thumb sign</b> (on lateral view X-ray Neck)</li> </ul>	<ul style="list-style-type: none"> <li>• Laryngotracheobronchitis</li> <li>• Clinical Presentation:                             <ul style="list-style-type: none"> <li>◦ Barking cough</li> </ul> </li> <li>• Pointed appearance: <b>Steeple Sign</b> (on AP view X-ray Neck)</li> </ul>

INI CET July 2021

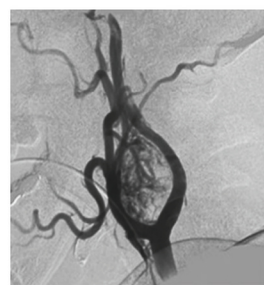
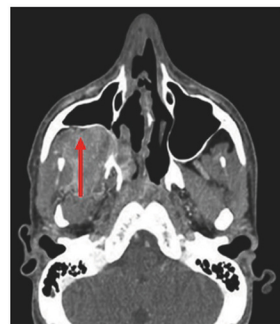
00:12:50



NEET PG 2023



FMGE Jan 2025

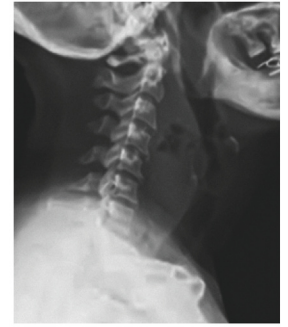

FMGE Jan 2025

# Yourwish

## Retropharyngeal Abscess

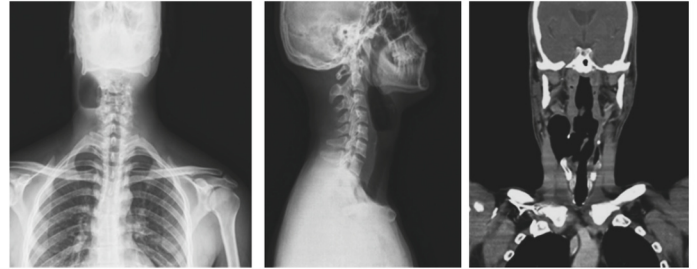
- Increased pre-vertebral soft tissue thickness
- Black foci



## Laryngocele

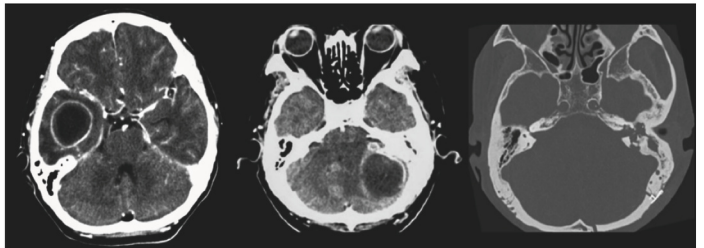
- History of trumpet blower with neck swelling
- The larynx will form a diverticulum (laryngocele)
- Appears black on X-ray & CT scan

FMGE Dec 2021



## Csom & Its Complications

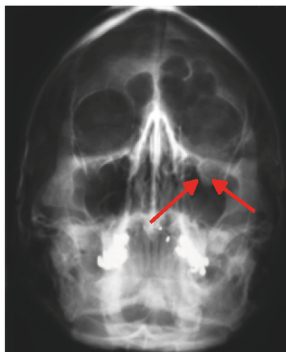- Mastoiditis
- Temporal lobe abscess: Ring-enhancing lesion with restricted diffusion
- Cerebellar abscess



## Blow-out Fracture

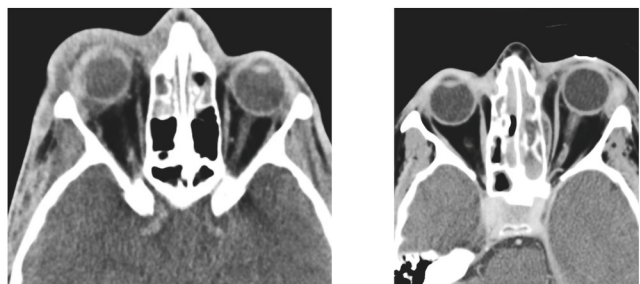
- Fracture of the floor of the orbit
- Tear-drop sign

FMGE June 2022



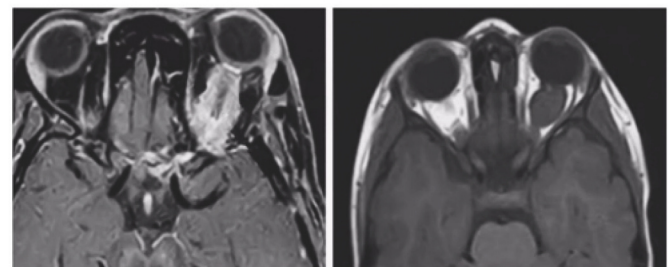
## Orbital Cellulitis

- Pre-septal cellulitis
- Subperiosteal abscess



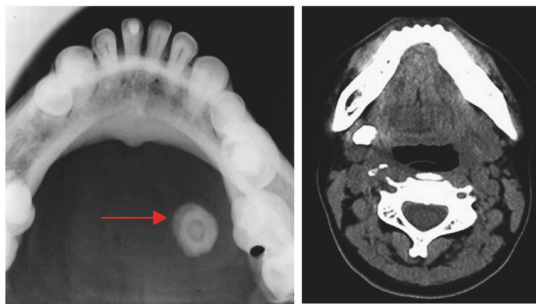
## Optic Meningioma Vs Optic Glioma

Optic Meningioma	Optic Glioma
<ul style="list-style-type: none"> <li>• Tumor surrounding the optic nerve</li> <li>• Tram-tract appearance</li> </ul>	<ul style="list-style-type: none"> <li>• Fusiform enlargement of the optic nerve</li> </ul>



**Sialolithiasis**

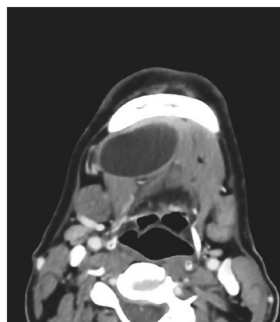
- Salivary gland calculus appears white



NEET PG 2022

**Ranula**

- Appears like a grey lesion near the mandible



INICET Nov 2023

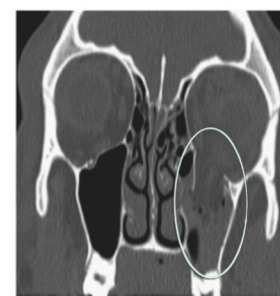
**PYQs**

00:25:11

Q. What would be your diagnosis for a patient who has a prior history of trauma and is currently experiencing symptoms such as double vision, nosebleeds, and limited eye movements, based on the provided CT image?

FMGE June 2022

- A. Le-Forte Fracture
- B. Fracture maxilla
- C. Fracture zygomatic bone
- D. Blow-out fracture

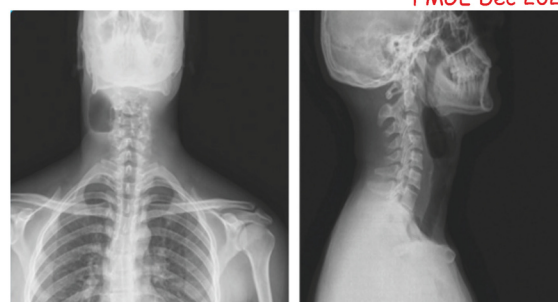


Answer: D. Blow-out fracture

Q. A young male who is a professional trumpet blower presented with a swelling on the left side of the neck. On examination, there is a gurgling sound on compressing the swelling. His X-ray neck is given below. What is the most likely diagnosis?

FMGE Dec 2021

- A. Pharyngeal pouch
- B. Laryngocele
- C. Tracheo-esophageal fistula
- D. Tonsillar cyst

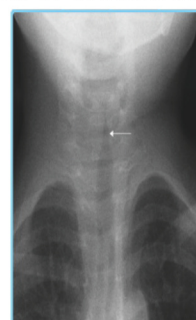

Answer: B. Laryngocele

Q. A patient presented to the OPD with sudden onset of shortness of breath. Identify the condition with the radiological image given below.

FMGE Jan 2025

- A. Epiglottitis
- B. Laryngotracheobronchitis
- C. Bronchitis
- D. Laryngomalacia



Answer: B. Laryngotracheobronchitis

Q. Hollman Miller's sign is seen in:

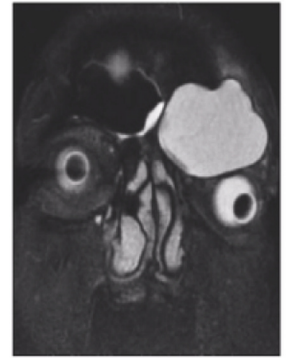- A. Juvenile Nasopharyngeal Angiofibroma
- B. Maxillary sinusitis
- C. Nasal polyp
- D. Rhinosporidiosis

**Answer: A.** Juvenile Nasopharyngeal Angiofibroma

Q. What is the probable diagnosis for a 30-year-old male who has non-axial proptosis in his left eye and a history of road traffic accident 15 years ago, as suggested by provided MRI image?

- A. Frontal Mucocele
- B. Frontal Meningioma
- C. Juvenile Nasopharyngeal Angiofibroma
- D. Pseudotumor of orbit

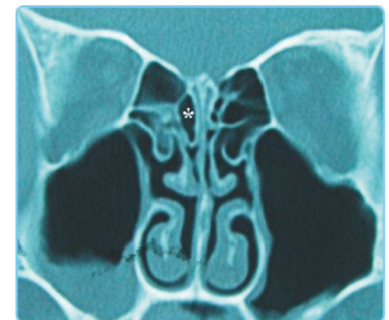
**Answer: A.** Frontal Mucocele



Q. Choose the best description for the structure marked in the CT given below:

- A. Agger Nasi Cell
- B. Pneumatized superior turbinate
- C. Onodi cell
- D. Haller cell

INICET Nov 2021



**Answer: B.** Pneumatized superior turbinate



## 2. GASTROENTEROLOGY RADIOLOGY

### BARIUM STUDIES

00:00:16

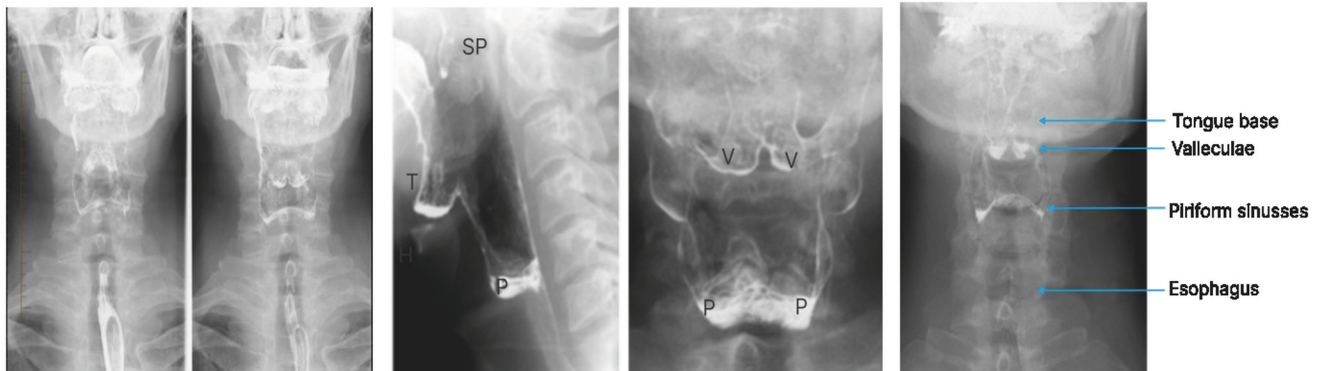
- Barium sulphate is used as a contrast
- C/I in perforation
  - Water insoluble → Leak → Peritonitis
- Water-soluble iodinated contrast, like iohexol, is used in perforation

<ul style="list-style-type: none"> <li>• Esophagus has white barium → Barium swallow</li> </ul>	<ul style="list-style-type: none"> <li>• Barium in stomach- Barium meal</li> </ul>	<ul style="list-style-type: none"> <li>• Barium meal follow-through for the small intestine</li> <li>• Bowel loops (jejunal loops) have a feathery appearance</li> </ul>	<ul style="list-style-type: none"> <li>• Large bowel seen in barium enema (given rectally)</li> <li>• Haustrations seen</li> <li>• Black areas seen, which is air → Double contrast barium enema</li> <li>• Only barium seen → Single contrast barium enema</li> </ul>

### Contrast X-ray/barium Swallow

NEET PG 2025

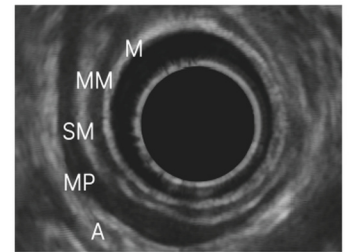
- Vallecula and pyriform sinus are seen
  - Vallecula is more superior and more rounded
  - Pyriform sinus is inferiorly located and more pointed
- Done under fluoroscopy → Video x-ray



# Yourwish

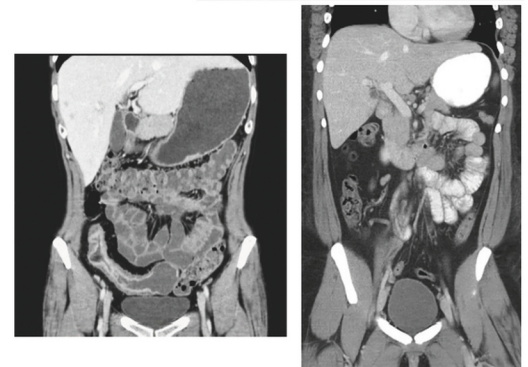## Endoscopic Ultrasound

- Circular concentric rings appearance → Shows layers of the GIT part clearly
- Helps in evaluating the depth of the tumour
- Best investigation for T staging of CA esophagus



## Ct Enterography Vs Ct Abdomen

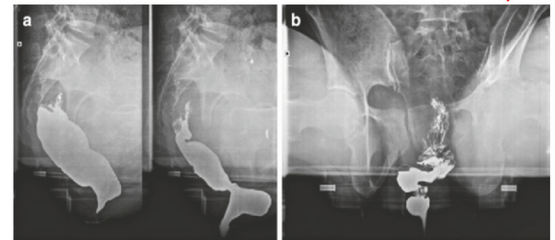
- CT means the bones are white
- Patient drinks iodinated contrast mixed with water → CT abdomen → Appears white because of contrast
- CT enterography, the patient drinks mannitol to distend the bowel loops with water
  - Layers are separated on either side
  - White mucosal lesions are seen well on a black background
- Tells how severe Crohn's disease is



INICET May 2025

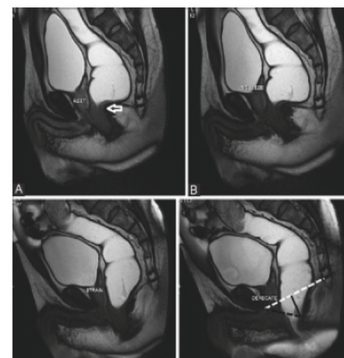
## Defecography X-ray

- Dynamic scan
- Patient strains, and we check for rectal prolapse
- Type of contrast X-ray
- Barium in the rectum present



## Mri Defecography

- Prolapse can be seen when the patient defecates

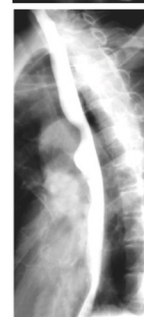

00:07:58



## ANATOMICAL STUDIES

### Normal/esophageal Indentations On Barium Swallow

- 3 normal indentations
  - Aortic arch
  - Bronchus (left bronchus)
  - Cardiac left atrium

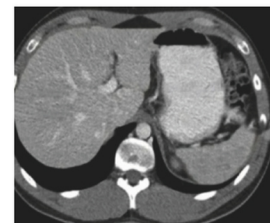

### Large Bowel Vs Small Bowel In X-ray

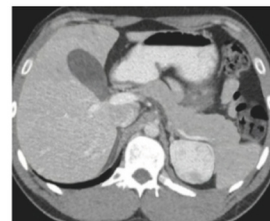LARGE BOWEL	SMALL BOWEL
<ul style="list-style-type: none"> <li>• Periphery</li> <li>• Haustrations                             <ul style="list-style-type: none"> <li>○ Incomplete projections</li> </ul> </li> </ul> 	<ul style="list-style-type: none"> <li>• Centre</li> <li>• Volvulae connimentes                             <ul style="list-style-type: none"> <li>○ Complete ring structures</li> </ul> </li> </ul> 

### Structures In Ct Abdomen

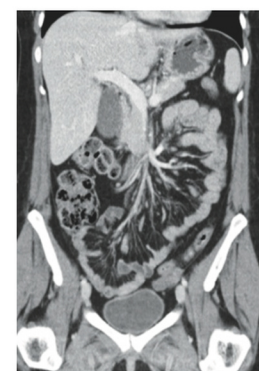- Bone is white
- Aorta white → Contrast CT
- Liver on the right side
- Spleen on the left side
- Left of the liver → Stomach shows black air, and the white in the stomach is the oral contrast given



- Liver, spleen seen
- Adjacent to the liver, the grey colour of the water density is the gall bladder
- Anterior to the pancreas, the stomach is present

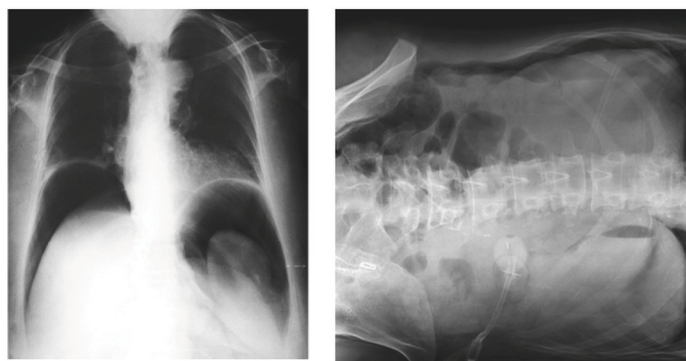


- Coronal CT image
- Liver, gallbladder, and stomach seen
- Bowel loops seen
- Grey colour in the pelvis is the bladder

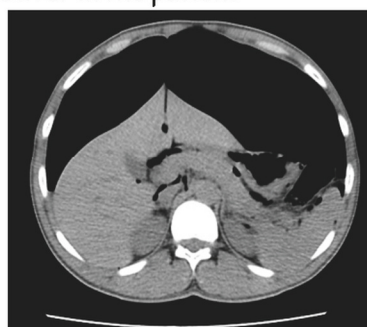


### PNEUMOPERITONEUM

- H/o peptic ulcer disease
- Air from the gut comes out because of a perforation, leading to air in the peritoneum
- Severe acute pain in the abdomen
- Air is black on X-ray and CT
- Chest X-ray erect is best for pneumoperitoneum as air rises above the diaphragm



- Supine position, air rises anterior to the liver in the patient
- No bowel markings seen



00:11:32

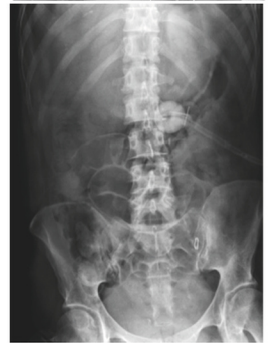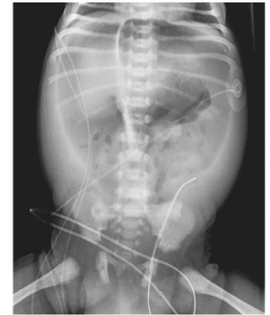FMGE Jan 2024

- In case erect chest X-ray is not possible, left lateral decubitus position is preferred
- Air moves to the right side, and the liver provides a good contrast
- Air moves out from the epiploic foramen as well
- Most sensitive investigation for pneumoperitoneum- CT

### X-ray Signs In Pneumoperitoneum

#### Football Sign

- Luscency seen in abdomen (air in abdomen) → Football sign
- The falciform ligament sign is seen- Visible because air surrounds the ligament

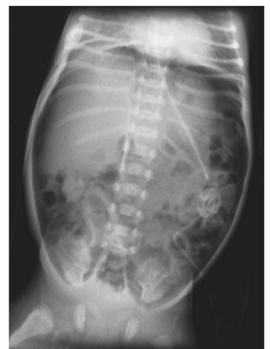

#### Wriggler Sign

- The bowel wall is distinctly seen
- The bowel wall is surrounded by air on either side

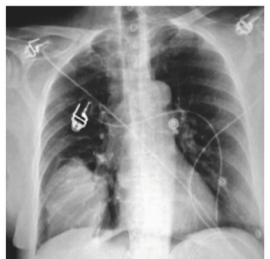
#### Inverted V Sign

- White lines in the pelvis- Air surrounding the umbilical ligament



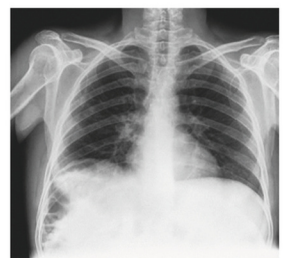#### Cupola Sign

- Lucency beneath the central part of the diaphragm



### PSEUDOPNEUMOPERITONEUM /CHILAITDI'S SYNDROME

- Lucency in the diaphragm
- Hausterations bowel marking is seen- Not true air
- Seen in Chilaidti's syndrome, where there is interposition of the colonic loop

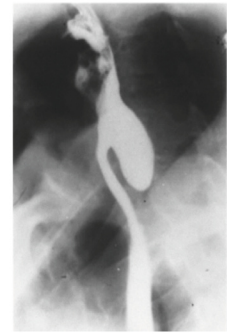


00:17:20

### ZENKERS DIVERTICULUM

- Seen in the upper esophagus- Killian's dehiscence
- Seen in elderly pt's d/t weak wall

- False diverticulum
- Directed posteriorly
- Best investigation- Barium swallow to seen the diverticulum in real time

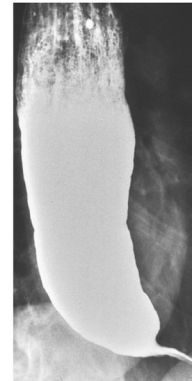


**Triad**

- Dysphagia
- Regurgitation
- Halitosis

**ACHALASIA CARDIA**

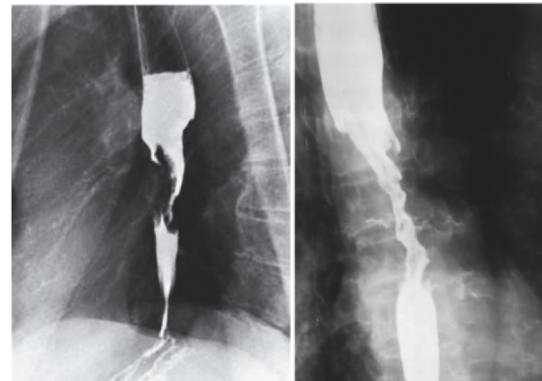
- Shows contracted LES bird beak appearance/Rat tail appearance in the distal esophagus is seen
- Esophagus massively dilated
- Dysphagia more to liquids > solids
- Gold standard investigation- Manometry



00:18:55

**CARCINOMA ESOPHAGUS**

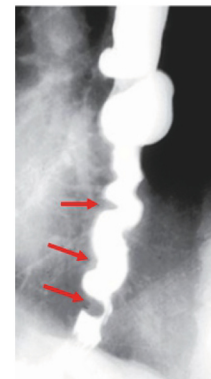
- H/o progressive dysphagia, Weightloss
- CA present in the mid esophagus
- Irregular narrowing
- Shouldering appearance- Apple core sign
- Endoscopic USG- Best for T-staging



00:20:09

**DIFFUSE ESOPHAGEAL SPASM**

- Contractions seen in the esophagus
- Cork-screw appearance



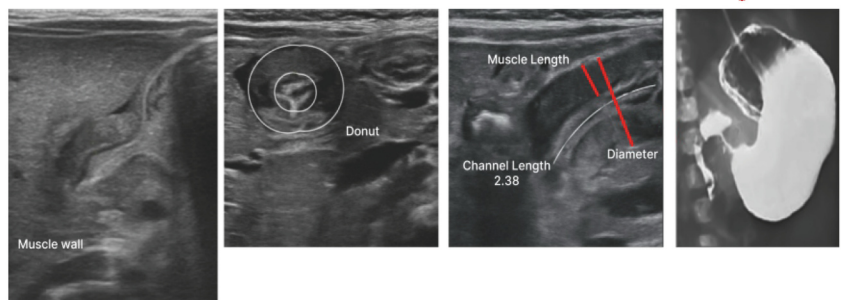
00:21:14

00:21:38

**PYLORIC STENOSIS**

- Idiopathic hypertrophic pyloric stenosis
- Muscular layer hypertrophied- Circular muscle
- Vomiting in a child
  - Age of presentation- 3-4 weeks
  - Non-bilious projectile vomiting
- Can be palpated in the abdomen like an olive-like lump
- IOC- USG
  - No radiation (better for children)
  - Can tell the thickness of the muscle layer >4 mm
  - Length of pylorus is seen >16 mm

NEETPG Aug 2024



## Yourwish

- Narrow lumen seen on axial image
  - The inner circle and the outer circle are seen separately- Donut sign or Target sign
- Barrowm meal shows
  - String sign (narrowing of the pylorus stenosis)
  - Looks like a mushroom, also called the mushroom sign

### Management

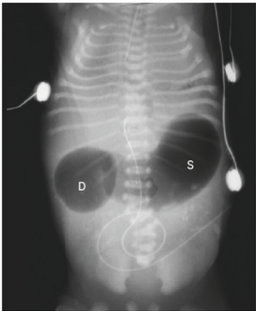

- 1<sup>st</sup> correct metabolic alkalosis

### BUBBLE SIGN

00:25:14

FMGE 2023, 2024

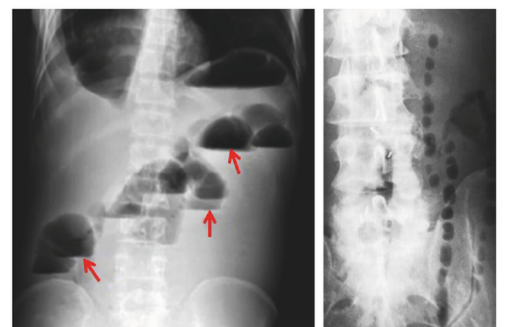
- More down u go, the number of bubbles increases
- Stomach obstructed- 1 bubble
- Duodenum obstructed- 2 bubble
- Jejunum obstructed- 3 bubbles
- Ileum obstructed- multiple bubbles

DOUBLE BUBBLE SIGN	TRIPLE BUBBLE SIGN
<ul style="list-style-type: none"> <li>• Duodenal atresia</li> <li>• Biliary vomiting immediately after birth</li> </ul> 	<ul style="list-style-type: none"> <li>• Jejunal atresia</li> </ul> 

### BOWEL OBSTRUCTION

00:26:01

- Patient presents as
  - Abdominal distension
  - Abdominal vomiting
  - Patient unable to pass stools
- A bowel obstruction will have air-fluid levels- Stepladder pattern
  - >3 air-fluids levels should be present to diagnose bowel obstruction
- Order of distension- Small bowel 3 cm > large bowel 6 cm > caecum 9 cm
- X-ray sign
  - Fluid accumulating in the bowel pushes air locules in the wall of the bowel of periphery → String of pearls appearance on X-ray abdomen



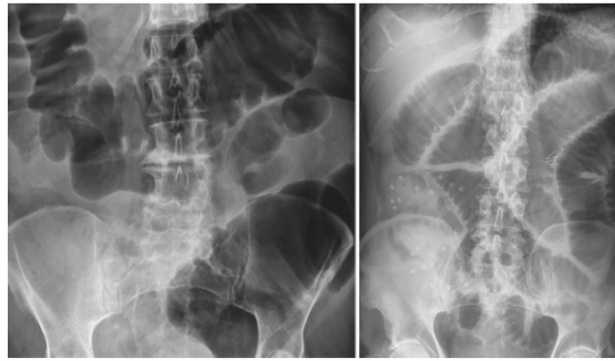
#### Important Information

- String of pearls on angiography- Fibromuscular dysplasia
- String of pearls om USG pelvis- PCOS

## LARGE BOWEL OBSTRUCTION VS SMALL BOWEL OBSTRUCTION

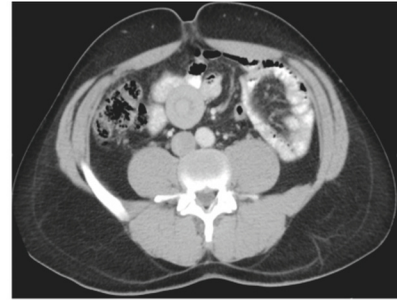
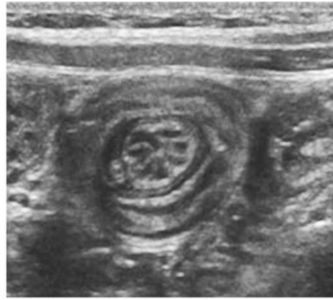00:28:08

FMGE June 2021  
INI CET Nov 2022



### INTUSSUSCEPTION

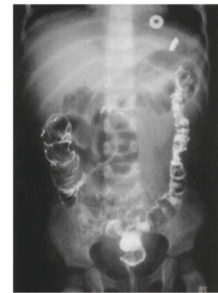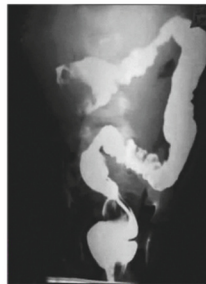- H/o red current jelly stools
- One bowel telescopes inside the other
  - Inner bowel and outer bowel are seen
  - Target sign



00:28:23

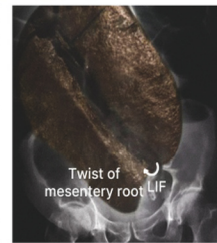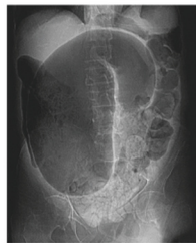### Barium Enema

- Claw sign is seen
- Barium just outlines the inner bowel → Coiled spring sign



### SIGMOID VOLVULUS

- Classically shows coffee bean sign
- Sigmoid volvulus no haustrations

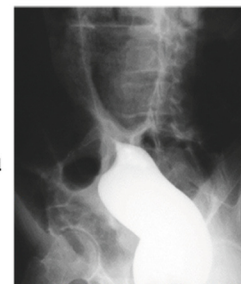


00:30:10

FMGE Jan 2025

### Barium Enema

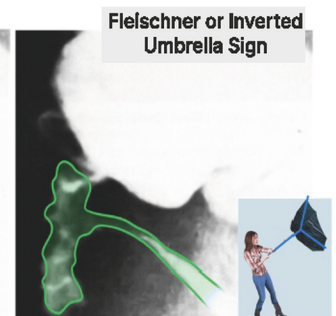
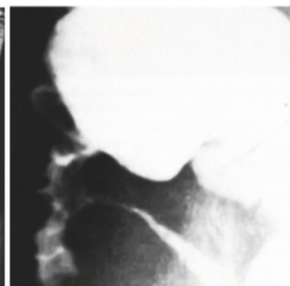
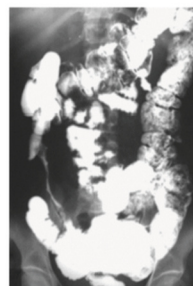
- Beak-like appearance → Bird of prey sign



### ILEOCAECAEAL TB

- Terminal ileum is a very common site
  - TB everywhere causes fibrosis and strictures
  - String sign seen
- The caecum has fibrosis → Contracture seen
- Inverted umbrella sign- Narrow ileum and thickened ileocaecal valve area

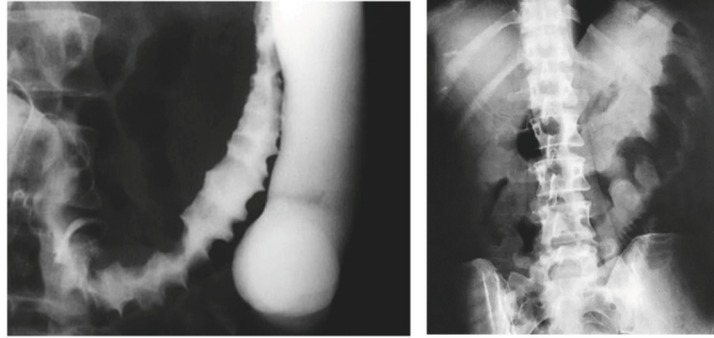
FMGE June 2021 00:31:20



## ISCHEMIC COLITIS - THUMBPRINT SIGN

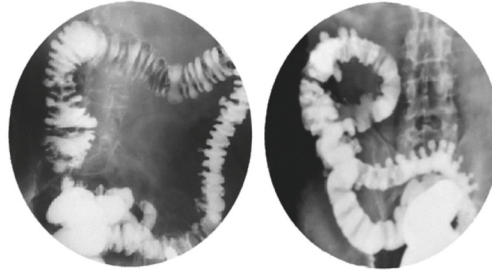
00:32:43

- Ischemic colitis- Haustrations of the colon become edematous and thick



## DIVERTICULOSIS

- Diverticula project out gives a saw-toothed sign
- Pain in the left iliac fossa (MC site is sigmoid colon) is present in diverticulitis
- CECT is done to see in detail
- Barium study- Outpouchings seen



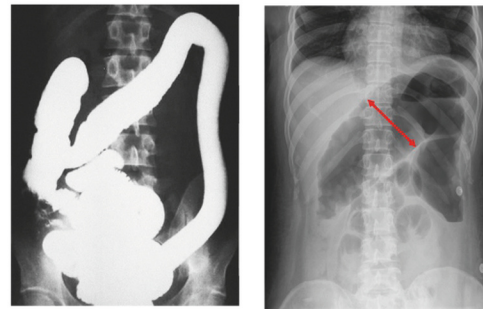
00:33:46

FMGE June 2021



## ULCERATIVE COLITIS

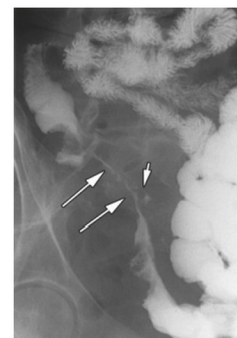
- Involves colon
  - Starts at the rectum → Retrograde travel
  - No skip lesions
  - Haustrations absent → Lead pipe colon
- Colon can get dilated >6 cm- Toxic megacolon
  - X-ray enough for diagnosis



00:35:05

## CROHNS DISEASE

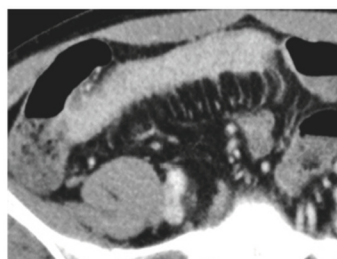- Complete gut can be involved
- Shows skip lesions
- Not continuously
- Presents similar to TB
  - Strictures
  - Fistula seen
  - String sign of cantour



00:36:00

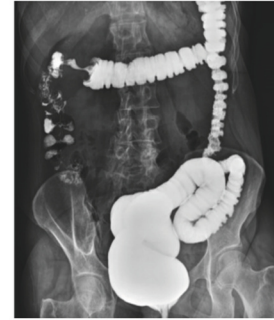## Ct Scan

- Vasa recta appears prominent
- Comb sign → Active inflammation is present



## CARCINOMA COLON

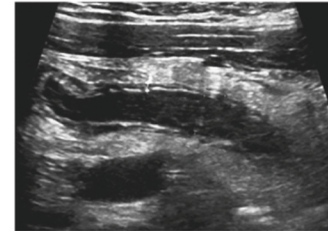
- Barium enema is single contrast- No air present
- Apple core appearance seen
  - Shouldering-like appearance at either end



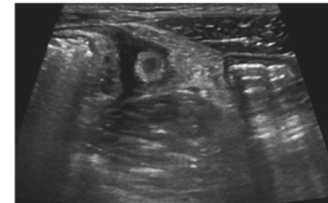00:37:25

## APPENDICITIS

- Patient present
  - Pain in the right iliac fossa
  - Tenderness at mcburney point
- IOC- USG
  - Graded compressed USG
  - The normal appendix compresses
  - I/c/o appendicitis not compressible
- Black colour surrounds the fluid due to inflammation



00:37:56



## Retrocaecal Appendix

- CECT is the best investigation to localise the appendix

## IOC KEY POINTS

- IOC for T staging of CA esophagus- Endoscopic USG
- IOC for CHPS- USG
- X-ray for pneumoperitoneum- Chest X-ray erect to look for air under the diaphragm
  - If not erect- Left lateral decubitus with horizontal beam
- IOC Zenker diverticulum- Barium swallow
- IOC Diverticulosis- Barium enema
- IOC for Diverticulitis- CECT
- IOC for Acute appendicitis- USG
- Best investigation for Acute appendicitis- CECT
- IOC for Toxic megacolon- X-ray
- Contrast used in perforation- Iodinated water-soluble contrast like iohexol

00:39:49

## ERRORS TO AVOID

- Barium is CI in perforation
- Investigation identification- Barium studies
- CA esophagus vs achalasia
- Double bubble vs triple bubble sign
- Small vs large bowel on X-ray
- Claw sign is seen on USG in intussusception- False
- Colitis thumbprint vs Diverticulosis sawtooth on barium enema

00:40:39

## PYQs

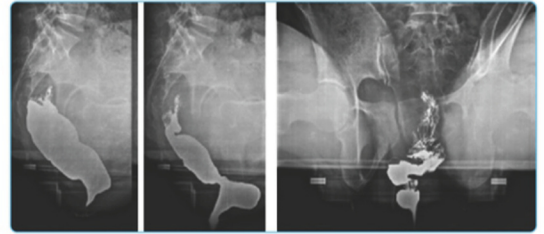
- Q. Which imaging modality is being used in the image shown below?

00:41:46

INICET May 2025

## Yourwish

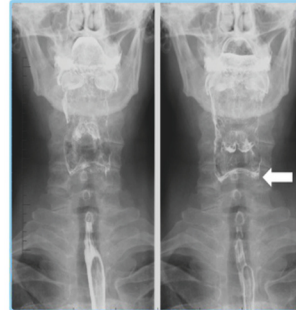- a. MRI Defecography
- b. X-ray Defecography
- c. CT abdomen
- d. Barium enema



**Ans: b.** X-ray Defecography

**Q.** Identify the structure on AP barium swallow.

- a. Pyriform sinus
- b. Epiglottis
- c. Vallecula
- d. Thyroid cartilage

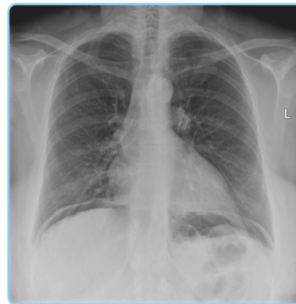

NEET PG 2025

**Ans: a.** Pyriform sinus

**Q.** A 45-year-old male presented with severe abdominal pain following alcohol intake. Make a diagnosis based on the given X-ray.

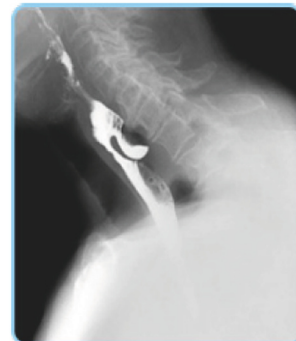- a. Pneumoperitoneum
- b. SBO
- c. Esophageal perforation
- d. Pneumomediastinum



**Ans: a.** Pneumoperitoneum

**Q.** An elderly male presents with foul-smelling breath and dysphagia. A barium swallow X-ray is provided. What is the most likely diagnosis?

- a. Tracheoesophageal fistula
- b. Achalasia cardia
- c. Carcinoma esophagus
- d. Zenker's diverticulum

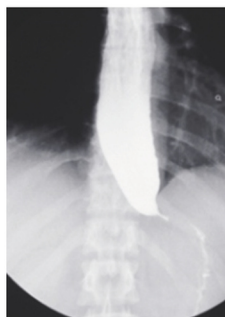

INICET Nov 2024

**Ans: d.** Zenker's diverticulum

**Q.** The provided barium swallow indicates:

- a. Achalasia cardia
- b. Diffuse esophageal spasm
- c. Nutcracker esophagus
- d. Hypertensive lower esophageal sphincter



INICET May 2024

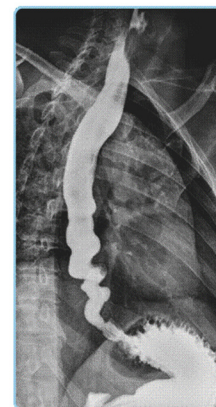
**Ans: a.** Achalasia cardia

**Q.** The characteristic appearance of the esophagus on barium swallow, as shown in the image below, is seen in which of the following conditions?

- a. Diffuse esophageal spasm

- b. Esophageal carcinoma
- c. Esophageal ulcer
- d. Achalasia cardia

**Ans: a.** Diffuse esophageal spasm

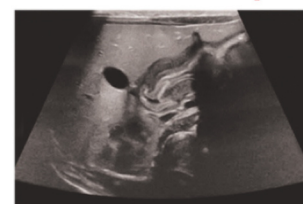

**Q.** A 6-week-old child is brought to the emergency department with recurrent projectile, non-bilious vomiting. Based on the radiograph provided, what is the most likely diagnosis?

NEETPG Aug 2024

- a. Annular pancreas
- b. Congenital hypertrophic pyloric stenosis
- c. Duodenal atresia
- d. Meckel's diverticulum

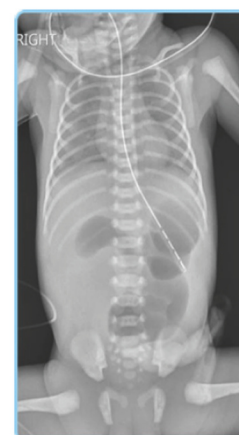
**Ans: b.** Congenital hypertrophic pyloric stenosis



**Q.** Identify the condition in the image shown below:

- a. Duodenal atresia
- b. Jejunal atresia
- c. Small bowel obstruction
- d. Ileal atresia

**Ans: b.** Jejunal atresia

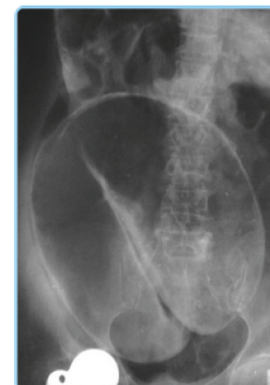


**Q.** What could be the most probable diagnosis for an elderly woman who is experiencing abdominal pain and swelling, considering her past medical history of scoliosis? Please refer to the provided X-ray image of the image of the woman's upright abdomen for further information.

FMGE Jan 2024

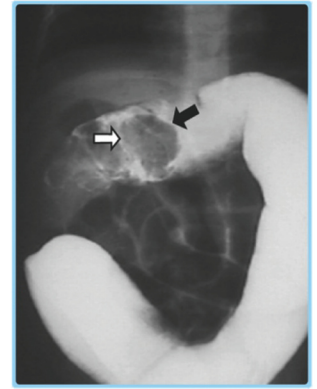
- a. Large bowel obstruction due to sigmoid volvulus
- b. Large bowel obstruction due to fecolith
- c. Cecal volvulus
- d. Small bowel obstruction due to bowel perforation

**Ans: a.** Large bowel obstruction due to sigmoid volvulus



**Q.** A baby presented with abdominal pain. On examination, a mass is palpated in the left lumbar region. A barium enema is done, and the image is given below. What is the likely diagnosis?

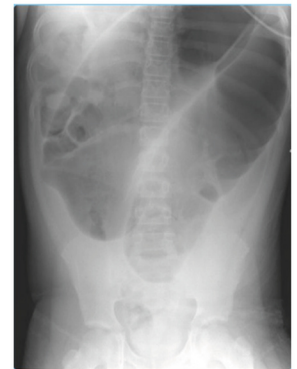- Intussusception
- Volvulus
- Duodenal atresia
- Intestinal obstruction



**Ans:** a. Intussusception

**Q.** A 33-year-old male presents with sudden onset acute abdominal pain, constipation for 1 day, persistent hiccups, and occasional vomiting. An abdominal X-ray was performed. Identify the pathology. FMGE Jan 2025

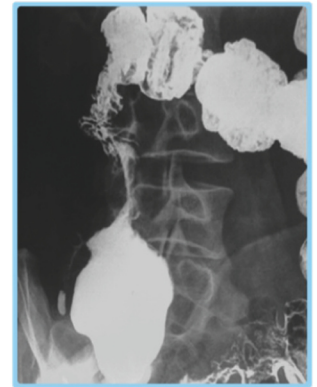- Sigmoid volvulus
- Caecal volvulus
- Intussusception
- Dynamic obstruction



**Ans:** a. Sigmoid volvulus

**Q.** A 30-year-old female presented with a low-grade fever of 1-week duration associated with loss of appetite and weight loss. Barium meal follow-through image of the patient is given below. What is the probable diagnosis?

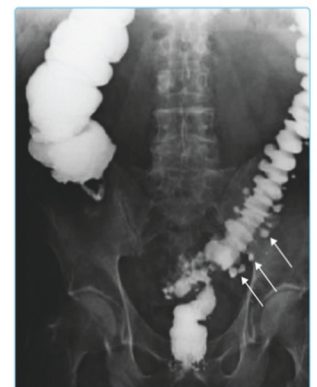- Ileocecal TB
- Ulcerative colitis
- Crohn's disease
- Carcinoma caecum



**Ans:** a. Ileocecal TB

**Q.** Which of the following conditions has a barium enema as shown in the picture below? FMGE June 2021

- Multiple colonic polyps
- Ulcerative colitis
- Diverticulosis
- Irritable bowel syndrome



**Ans:** c. Diverticulosis





## 7. MUSCULOSKELETAL RADIOLOGY

### INVESTIGATIONS

00:00:23

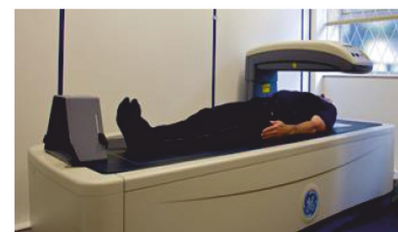#### CT vs MRI

CT SCAN	MRI
<ul style="list-style-type: none"> <li>• Bone cortex appears white</li> <li>• In CT scan, fatty marrow appears black</li> </ul>	<ul style="list-style-type: none"> <li>• Bone cortex appears black</li> <li>• In MRI, fatty marrow appears white</li> </ul>
	

#### DEXA SCAN

00:01:43



- Dual-Energy X-ray Absorptiometry
- Evaluates bone mineral density
- Used in the diagnosis of osteoporosis
  - According to WHO, Osteoporosis → **T-score < -2.5 SD.**
  - Other investigation: Quantitative CT scan



#### NORMAL ANATOMY

00:02:39

#### Identifying Carpal Bones & Tarsal Bones

CARPAL BONES	TARSAL BONES
	

## Yourwish

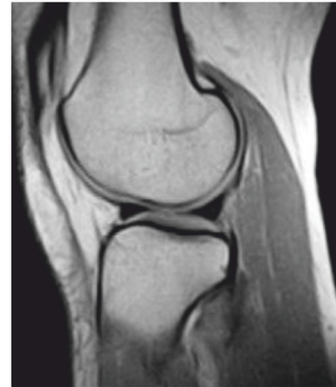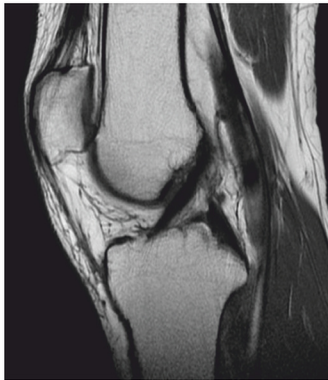- From radius to ulna
- Proximal row:
  - **She:** Scaphoid
  - **Looks:** Lunate
  - **Too:** Triquetrum
  - **Pretty:** Pisiform
- Distal row:
  - **Try:** Trapezium
  - **To:** Trapezoid
  - **Catch:** Capitate
  - **Her:** Hamate
- Calcaneum (forms the heel)
- Talus (forms the ankle joint with tibia)
- Navicular (boat-shaped bone in front of talus)
- Cuboid (on the lateral side)
- 3 Cuneiforms

**Important Information**

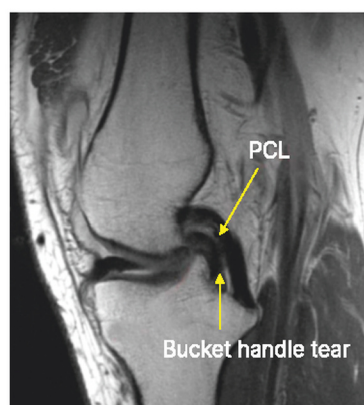
- Scaphoid fracture causes tenderness in the anatomical snuff box and has a high risk of avascular necrosis
- Pisiform → Last carpal bone to ossify

**Acl Vs Pcl On Mri**

00:05:48



- Identify patella (present on the anterior side)
- Ligament attached to the anterior surface of the tibia: Anterior Cruciate Ligament/ACL
- Ligament attached on the posterior surface of the tibia: Posterior Cruciate Ligament/PCL
- Triangular structures: Meniscus

**Double Pcl Sign**

- Seen in **Bucket handle tear** of the medial meniscus

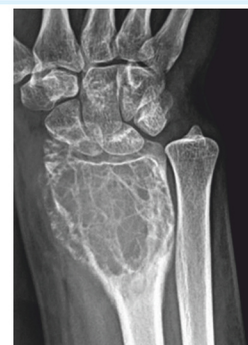## BONE TUMORS

00:07:12

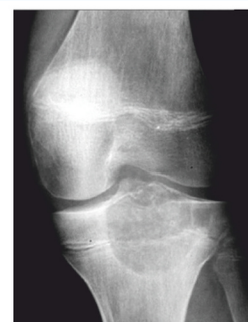NEET PG 2023, INI CET May 2022

**Giant Cell Tumor**

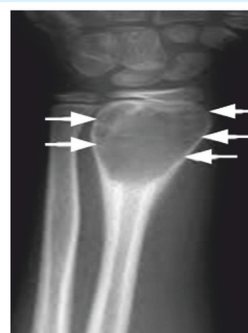
- Adult 30-40s
- Involves epiphysis
- Expansile
- Extends up to the articular surface
- Soap bubble appearance
- Treatment: Extended curettage followed by bone grafting (ECBG)

**Chondroblastoma**

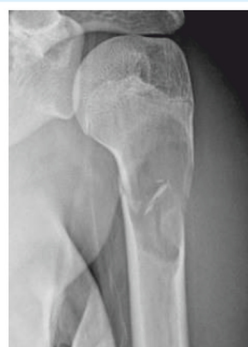- Epiphysis
- Younger patient
- Bone is unfused

**Aneurysmal Bone Cyst**

- Metaphysis
- Unfused
- Soap bubble appearance
  - Multiple septations
  - Gives a trabeculated appearance

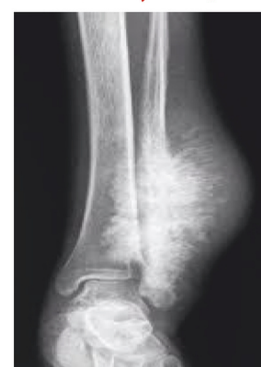**Simple Bone Cyst**

- AKA: Unicameral bone cyst
- **Fallen leaf / Trap door sign**
- MC site: Proximal humerus
- Young age
- Bone is unfused

**Osteosarcoma**

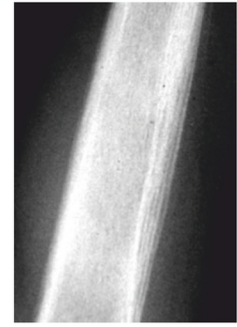
- Common in 15-16-year-olds
- MC site: Around the knee
- Sunburst or sunray type of periosteal reaction
- Involves metaphysis
- Aggressive lesion
- **Codman triangle**: V-shaped periosteal elevation

INICET May 2025, FMGE Jan 2025



### Ewing's Sarcoma

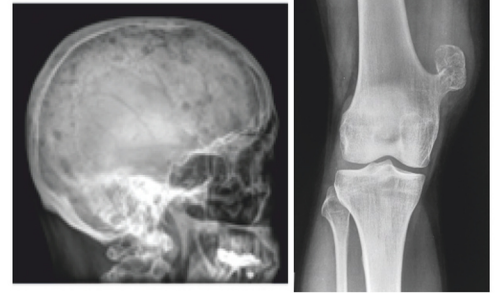
- Child: Usually 5-10 years
- Diaphysis → Shaft
- Fever + swelling present
- Mimics osteomyelitis
- Periosteal reaction: **Onion peel appearance (multi-laminated)**



### Osteochondroma

- Cartilage cap present- Not visible on X-ray, visible on MRI
  - X-size < Clinical size
- Sessile or Pedunculated
- Grows away from the joint
- IOC- MRI
  - >2cm cap thickness → malignant.

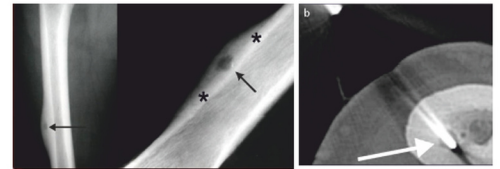
FMGE Jan 2023



### Osteoid Osteoma

- Young patient
- Diaphysis
- Pain worsens at night
- Relieved by aspirin/ Prostaglandin inhibitors
- **Central nidus** present
- Cortical bone thickening
- IOC: CT scan
- TOC: Radiofrequency ablation

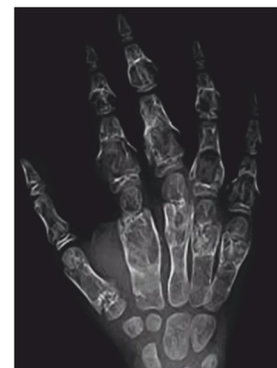FMGE Jan 2024



### Enchondroma

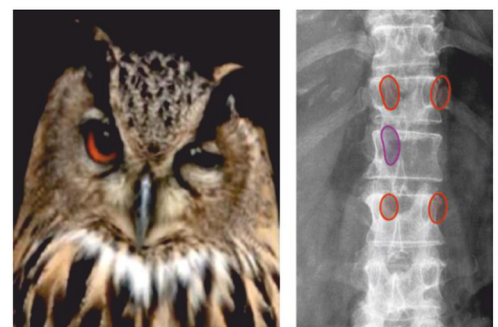
- Cartilagenous tumor
- Involves fingers
- Speckled calcifications +
- **Ollier's disease** → Multiple enchondromas
- **Maffucci syndrome** → enchondromas + hemangioma

NEET PG 2022, FMGE Jan 2023



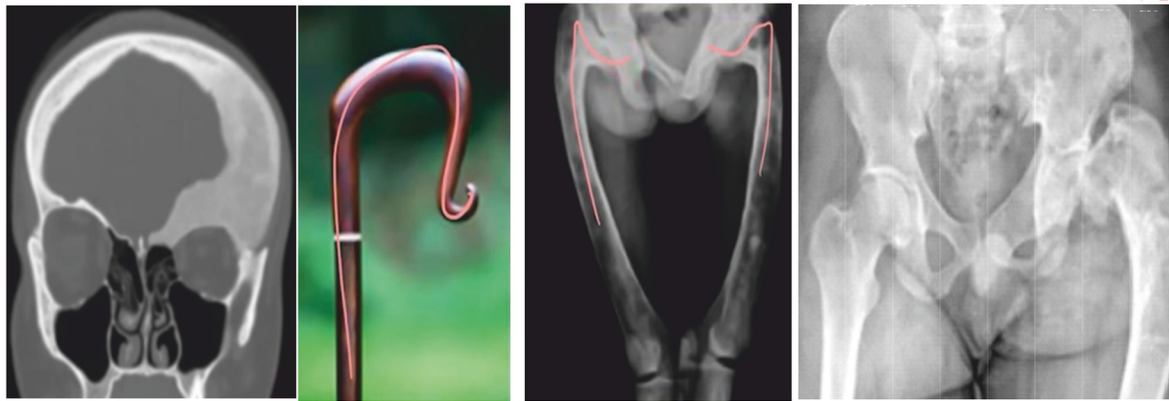### Vertebral Metastasis

- Involves pedicles
- **Winking Owl sign**



## Fibrous Dysplasia

00:16:50  
NEET PG 2023

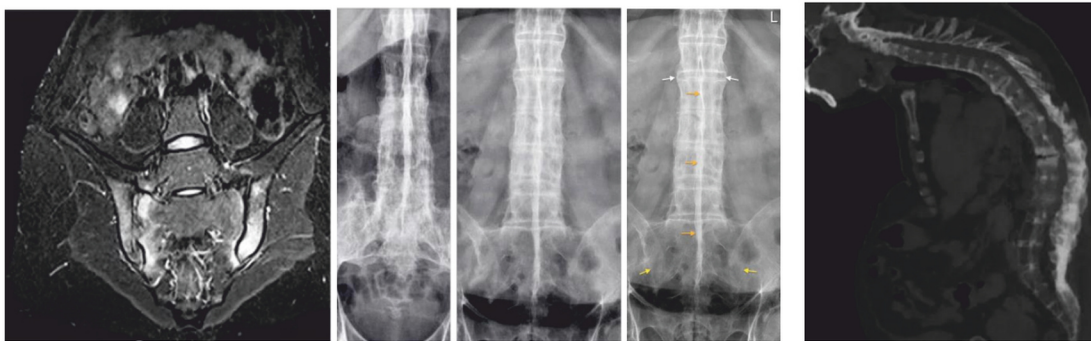


- Bone has fibrous tissue → Less density → White bone becomes grey
  - Ground glass matrix
- **Shepherd's crook deformity** of the femur

## ARTHRITIS

00:17:56

### Ankylosing Spondylitis

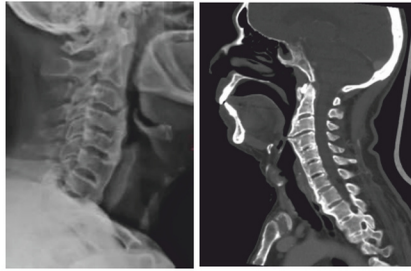


- Inflammatory arthritis
  - Ankylosing → Fusing (Anterior and posterior spine)
  - Spondylitis → Inflammation of the spine
- H/o morning stiffness
- Starts in sacro-iliac joints → Low back ache
- Occurs in young age group (30-40 yrs)
- Earliest and most sensitive investigation: MRI
  - Inflammation → Bone marrow edema → STIR sequence
- Fusion of vertebra → **Bamboo spine appearance**
- Ossification in the interspinous ligament → White line → **Dagger sign**

### Dish

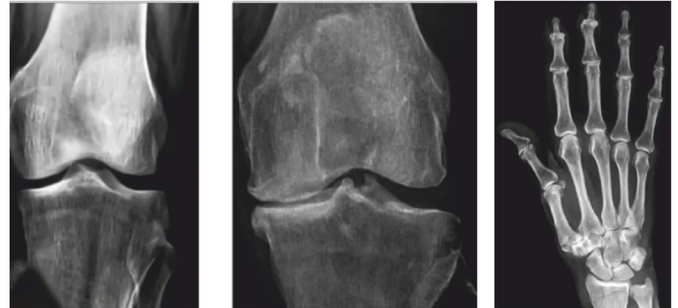
- Diffuse Idiopathic Skeletal Hyperostosis
- AKA: Forestier disease
- Idiopathic
- Occurs in the elderly (>50 years)
- Non-inflammatory
- Fusion of anterior spine → Flowing wax ossification

## Yourwish



## Osteoarthritis

- Degenerative arthritis
- Pain increases with activity
- Asymmetrical involvement of joints
  - Knee joint → Medial compartment > Lateral compartment
- Osteophyte formation
- Reduction of joint space
- Subchondral sclerosis
- First joint involved in hand → 1st carpo-metacarpal joint
- Can involve the Distal Interphalangeal (DIP) joint also
  - Never involved in rheumatoid arthritis



## Important Information

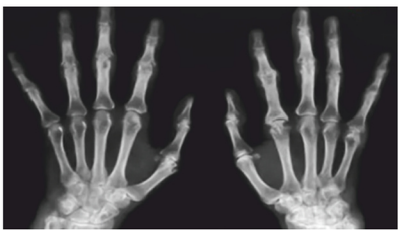- Degenerative arthritis → Asymmetrical involvement of joints
- Inflammatory arthritis → Symmetrical involvement of joints (Erosions +)

## Rheumatoid Arthritis

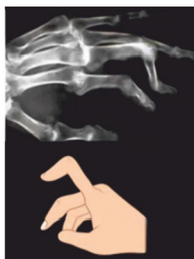
00:23:45

- Inflammatory arthritis
- B/L symmetrical
- MCP joints are involved early
- DIP is never involved

INICET Nov 2025

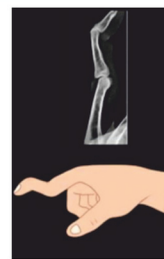


- Periarticular osteopenia +



## Swan Neck Deformity

- PIP → hyperextension
- DIP → flexion

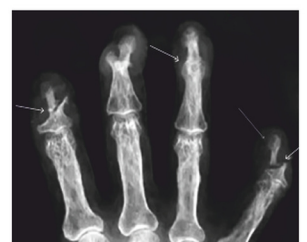

## Boutonnière Deformity

- PIP → flexion
- DIP → hyperextension

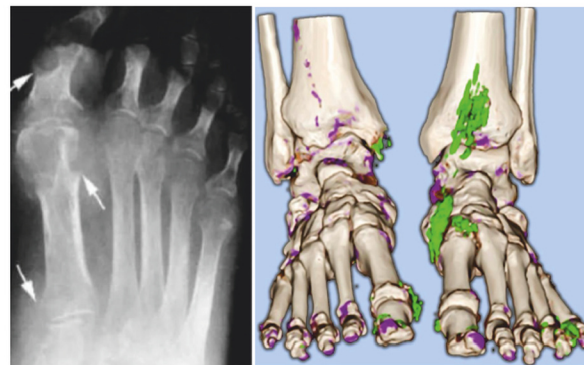
## Psoriatic Arthritis

- Pencil in cup appearance
- Can involve all joints
- AKA: Arthritis mutilans
- H/o of psoriatic skin lesions



## Gout

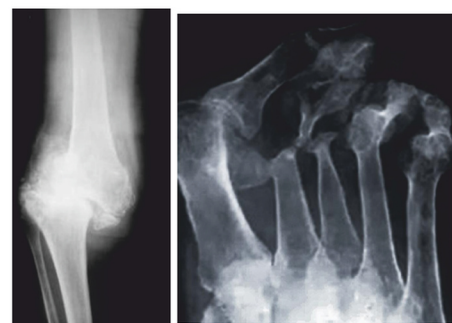- MC site: 1st MTP (Great toe)
- Inflammatory arthritis:
  - Erosions with overhanging edges → Punched out erosions
  - **Rat bite erosions/ Martel sign**
- Deposition of monosodium urate (MSU) crystals
- Uric acid is radiolucent
- IOC: DECT (Dual-Energy Computed Tomography)
  - Detects Tophi deposition



## Charcot's Arthropathy - Neuropathic Joint

- Signs > Symptoms
- Seen in DM, leprosy
- Features:
  - Dense debris
  - Dislocation of joints
  - Destruction of joints
  - Dense appearance of bones
- Non-osteoporosis
- **Licked candy appearance** is seen in leprosy

00:27:11  
FMGE June 2021



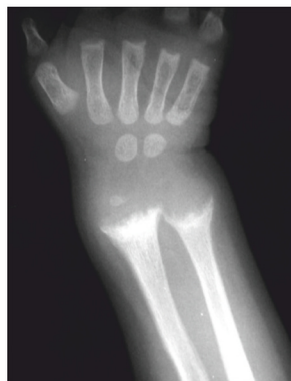## METABOLIC & ENDOCRINE DISORDERS

### Scurvy Vs Rickets

00:28:30

FMGE Jan 2025, NEET PG 2021

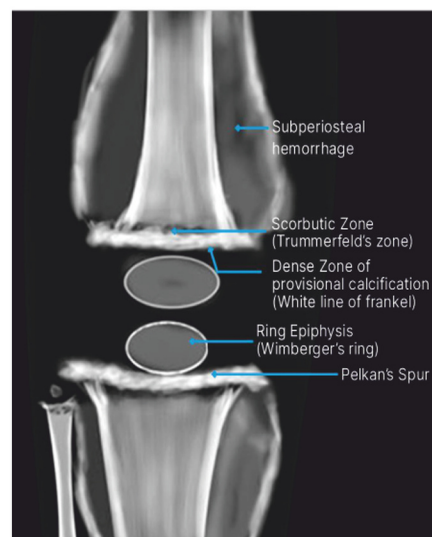
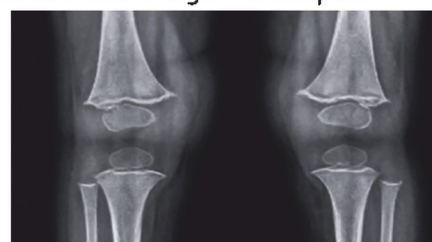
#### Rickets → Vitamin D deficiency



- Widened provisional zone of calcification
- No calcium → **White line of Frankel is absent**
  - White line of Frankel is present during healing
- Changes:
  - Cupping
  - Fraying → irregular margins
  - Splaying → widening of metaphysis, especially in weight-bearing bones
- Bowing of legs

#### Scurvy → Vitamin C deficiency

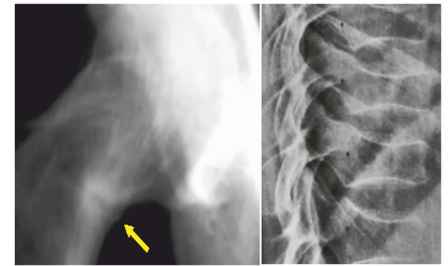
- Pencil-thin cortex
- Subperiosteal hemorrhage → Bone pain



## Osteomalacia

00:31:05

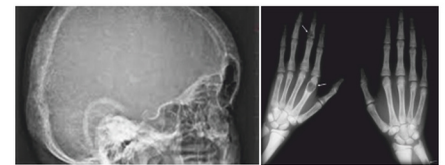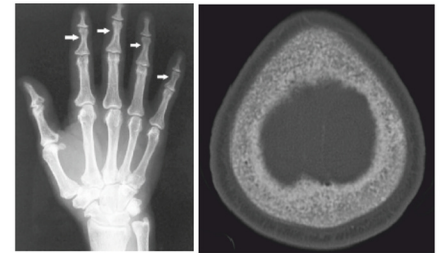
- Vitamin D deficiency in adults
- Pseudofractures → Looser's zone
- Surrounded by sclerosis
- Biconcave-shaped vertebra
  - Codfish/ fish mouth appearance
  - Also seen in osteoporosis (Normal calcium)



## Hyperparathyroidism

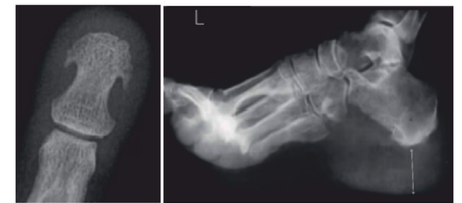00:32:19

- Clinical features:
  - Bones → bone pain
  - Stones → renal stones (due to hypercalcemia)
  - Moans → abdominal pain
  - Groans → muscle weakness, fatigue
- Subperiosteal resorption
  - Starts in the middle phalanx → Concave
  - Skull → Salt & pepper/ pepper-pot skull
- Lytic lesions in bone → Brown tumor



## Acromegaly

- ↑ GH
- Overgrowth of distal phalanx → Spade phalanx
- ↑ heel thickness

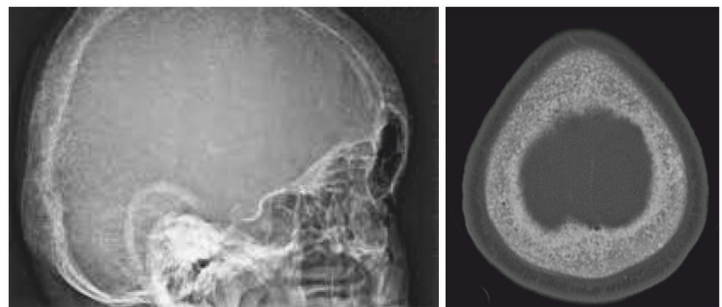


## SKULL APPEARANCES

00:34:36

### Salt & pepper appearance:

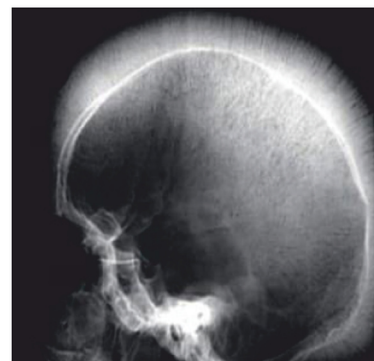- Seen in hyperparathyroidism



### Hair-on-end/ crew-cut appearance

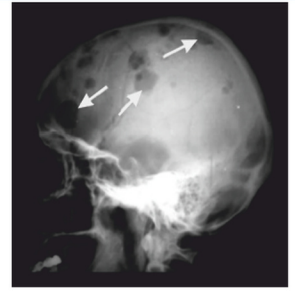
- Seen in hemolytic anemia
- ↑ hematopoiesis

FMGE Jan 2024, June 2022

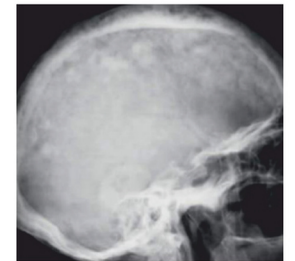

**Punched out/ raindrop lesions**

- Involves outer and inner tables equally
- Seen in multiple myeloma
  - Normal Alkaline phosphatase
  - No new bone formation
  - Cold spot in bone scan

**Cotton wool appearance**

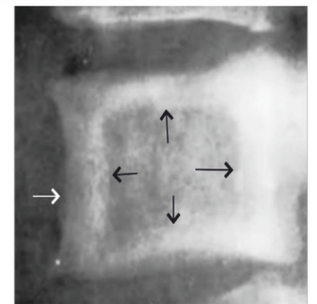
- Seen in Paget's disease

**VERTEBRAL APPEARANCES**

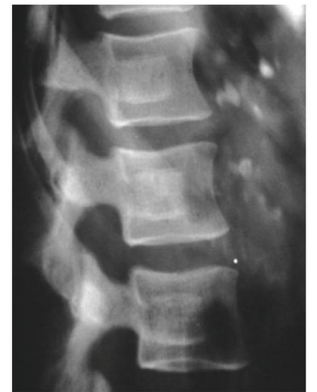00:36:36

**Picture-frame vertebra**

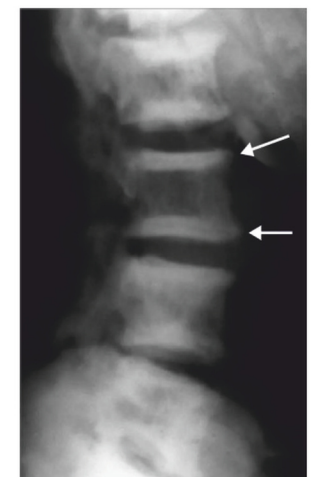
- Thickened cortex
- Seen in Paget's disease

**Bone within bone appearance**

- Seen in Osteopetrosis
  - Marble bone disease

**Rugger Jersey Spine**

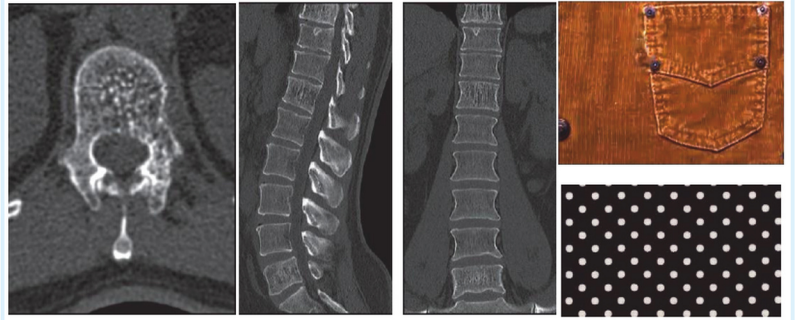- White-black-white appearance
- Seen in renal osteodystrophy
  - Secondary hyperparathyroidism



## Yourwish

**Corduroy / Jail-bar appearance**

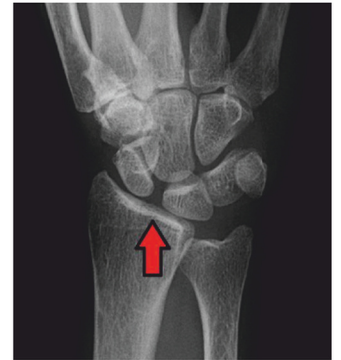- Trabeculated appearance (vertical striations)
- Polka-dot appearance on CT
  - Seen as multiple round hyperdense dots (thickened vertical trabeculae in cross-section)
- Seen in Vertebral Hemangioma

**TRAUMA**

00:39:20

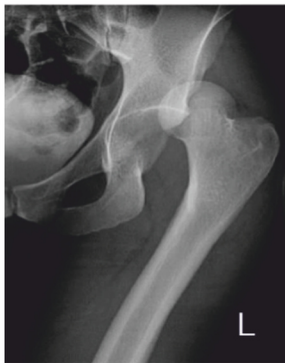**Scapho - Lunate Dissociation**

- Increased gap between scaphoid and lunate
  - Terry Thomas sign

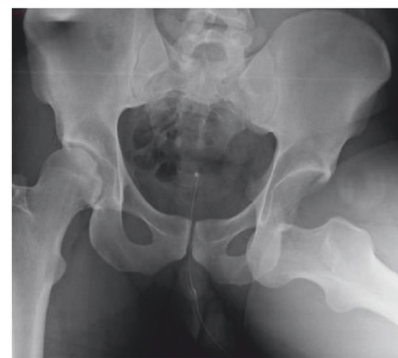**Hip Dislocation**

- Posterior dislocation > Anterior dislocation

FMGE Jan 2025

**Posterior dislocation (Dashboard injury) → FADIR**

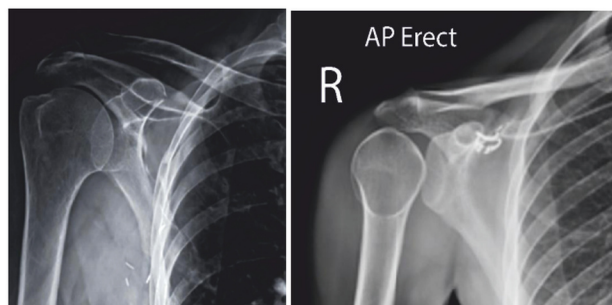
- Flexion, ADduction, IR (Internal Rotation)
- The femoral head is outside the acetabulum
- Femur → Superior

**Anterior dislocation → FABER**

- Flexion, ABduction, ER (External Rotation)
- External rotation → Lesser trochanter prominent
- The femoral head is outside the acetabulum
- Femur → Inferior

**Shoulder Dislocation**

00:42:06



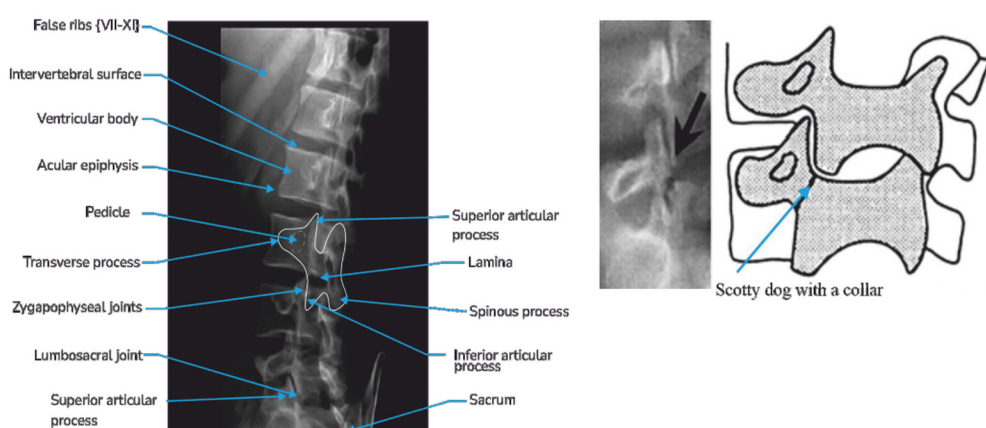

Normal

Posterior dislocation

- Posterior dislocation of shoulder
  - Light bulb sign
  - Associated with seizures and electric shock
  - No overlapping of the humerus head and the glenoid

### Spondylolysis Vs Spondylolisthesis

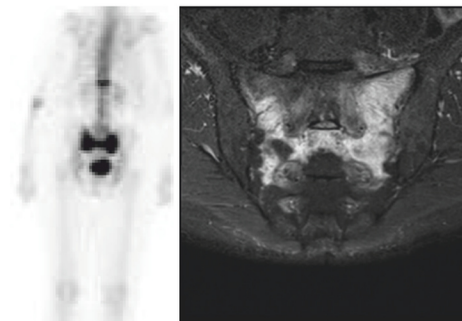
FMGE Dec 2021

SPONDYLOLYSIS	SPONDYLOLISTHESIS
<ul style="list-style-type: none"> <li>• Fracture in the pars interarticularis of the vertebra</li> <li>• In a normal oblique view X-ray → Scotty dog appearance                             <ul style="list-style-type: none"> <li>○ In Spondylolysis → Scotty dog with collar</li> </ul> </li> </ul> 	<ul style="list-style-type: none"> <li>• Slipped vertebra → Malalignment of vertebra</li> </ul> 

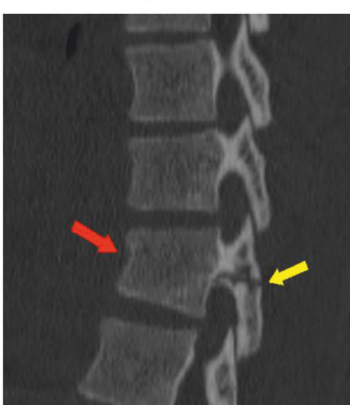

### Sacral Insufficiency Fracture

INICET May 2025

- Honda sign on bone scan
- Fracture surrounded by edema



### Chance Fracture Vs Burst Fracture

<ul style="list-style-type: none"> <li>• Horizontal fracture</li> <li>• Due to seat belt injury</li> <li>• Involves all columns of spine</li> </ul> 	<ul style="list-style-type: none"> <li>• Vertical loading</li> <li>• Due to fall from height</li> <li>• Retropulsion of fragment +</li> </ul> 
---	--

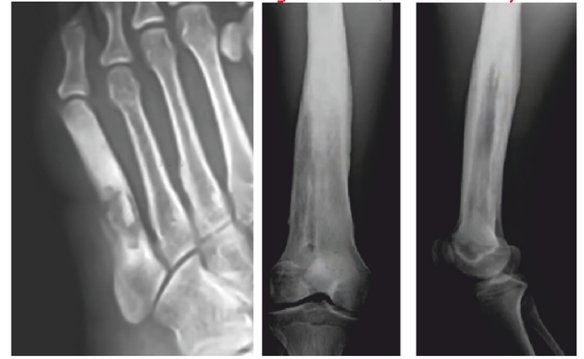## INFECTIONS

00:46:33

### Osteomyelitis

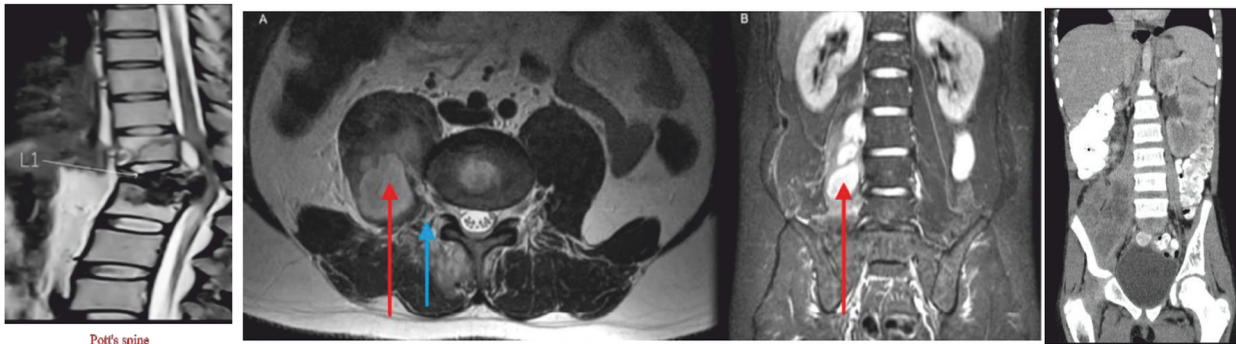
NEET PG August 2024, INICET May 2024

- Earliest finding: Bone marrow edema
- Sensitive investigation: MRI
- Discharging sinus → Seen in chronic osteomyelitis
  - Sequestrum: Dead bone fragment inside the lesion  
→ Appears dense/white
  - Cloaca: Opening in the involucrum
  - Involucrum: Sclerosis surrounding the sequestrum



### Pott's Spine & Psoas Abscess

FMGE June 2022

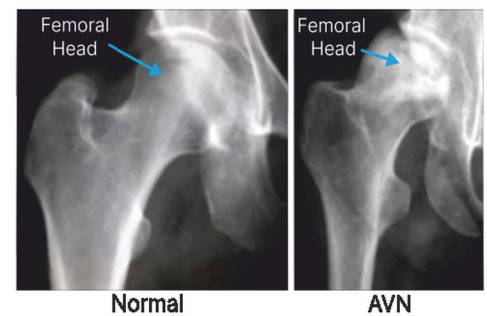


- Potts spine/ TB spine:
  - IOC for Pott's spine: MRI
  - Paradiscal involvement (MC)
  - The intervertebral disc and adjacent vertebral bodies are affected
- TB spine affecting the paraspinal muscle → Psoas abscess

### Avascular Necrosis

INICET Nov 2022

- H/o steroids intake
- Hip pain+
- Most sensitive investigation: MRI
- X-ray in late stages:
  - Collapse of the femoral head
  - More dense (dead bone)
  - Subchondral fracture → **Crescent sign**



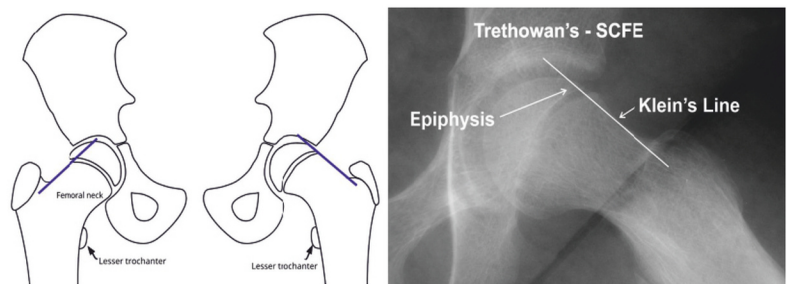
## PEDIATRIC MUSCULOSKELETAL IMAGING

00:51:22

### Perthes

- Similar to AVN

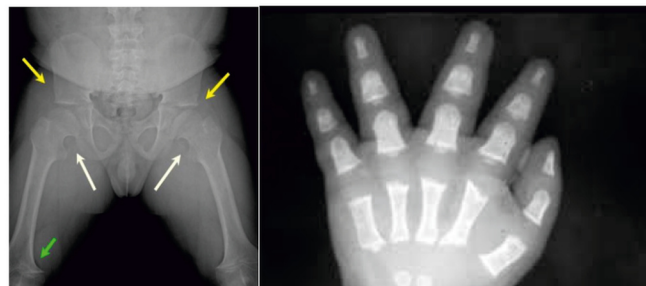
### Scfe



- Slipped Capital Femoral Epiphysis (SCFE)
  - Slipping of the femoral head epiphysis posteriorly and medially
- MC in the puberty age group and an obese child with endocrine abnormalities
- Klein's line: To diagnose SCFE
  - A line along the lateral aspect of the femoral neck should intersect the femoral head epiphysis
  - Failure suggests SCFE → **Trethowan Sign**

### Achondroplasia

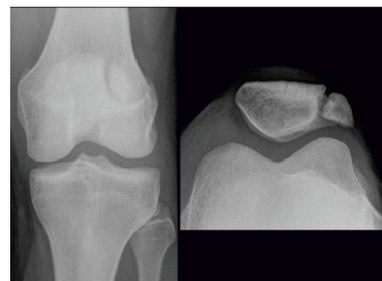
- Short stature
- **Trident Hand**
  - AKA: Starfish hand
  - Increased gap between the middle and ring fingers
- Champagne glass pelvis
- Tombstone appearance of iliac blades



### Bipartite Patella

- No history of trauma
- Failure in fusion of patella
- MC - Lateral
- Smooth cortex

NEET PG 2023



### INVESTIGATION OF CHOICE

00:55:04

- Most sensitive for ankylosing spondylitis - MRI
- IOC for avascular necrosis - MRI
- IOC for stress fractures - MRI
- MRI sequence for bone edema - STIR sequence
- CT is IOC for which bone tumor - Cortical bone tumor → Osteoid osteoma
- IOC for skip metastasis in bone tumor - MRI
- Bone scan radionuclide - Technetium 99m-methyl diphosphonate (99mTc MDP)
- For osteoporosis - DEXA for bone mineral density
- For screening of DDH - USG
- Early changes in osteomyelitis - MRI

### PYQs

00:57:00

Q. A 17-year-old boy presents with a progressively increasing swelling over the tibia along with fever. Radiological examination reveals a Codman triangle and sunburst appearance. What is the most likely diagnosis?

- Osteosarcoma
- Ewing sarcoma
- Giant cell tumor
- Chondrosarcoma

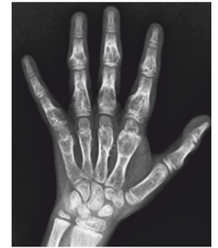**Answer: a. Osteosarcoma**

## Yourwish

Q. A woman during her routine examination presents with the following X-ray finding. What is her most likely diagnosis?

- Multiple brown tumor
- Fibrous dysplasia
- Multiple Enchondromas
- Multiple exostoses

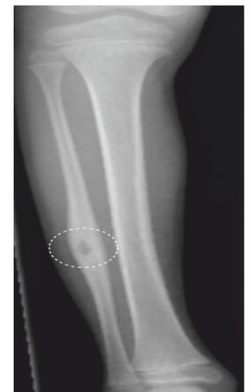NEET PG 2022



**Answer: c.** Multiple Enchondromas

Q. A 30-year-old male presents to the OPD with complaints of pain in the left knee region. He reports that the pain is often worse at night and mentions that he has been taking Aspirin to relieve the pain. An X-ray of the knee is shown below. What is the diagnosis?

- Chondroblastoma
- Osteoid osteoma
- Skeletal TB
- Osteosarcoma

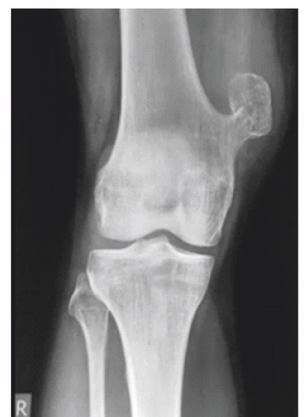

**Answer: b.** Osteoid osteoma

Q. What is the most probable diagnosis for a 17-year-old male patient who visits the clinic with a painless lump on the outer side of his left knee, as depicted in the radiograph provided?

- Enchondroma
- Chondroblastoma
- Osteochondroma
- Giant cell tumor

FMGE Jan 2023

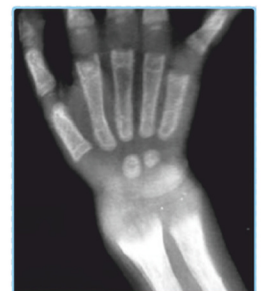

**Answer: c.** Osteochondroma

Q. A 7-year-old child was brought with bow legs, and on x-ray of the wrist, the following were the findings. What is the diagnosis?

- Rickets
- Scurvy
- Hypophosphatemia
- None

FMGE Jan 2025



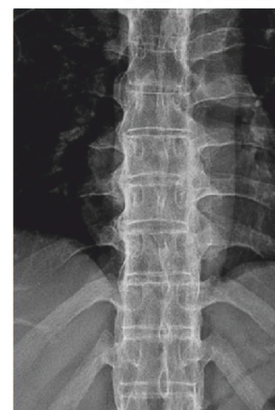**Answer: a.** Rickets

Q. A young man came to the medical OPD with complaints of early morning backache and stiffness, which improve on exercise, and persistent red eyes. On examination, lung expansion was less than 3 cm. X-ray is shown in the image given below. What is the most probable diagnosis?

- Ankylosing Spondylitis
- Paget's Disease
- Healed Tuberculosis
- Osteopetrosis

**Answer: a.** Ankylosing Spondylitis

NEET PG 2023

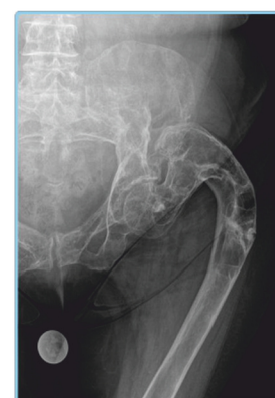

Q. What is the probable diagnosis for a child brought to the orthopedics OPD with a lower limb deformity and hyperpigmented skin lesions, based on the presented X-ray of her thigh?

- Non-ossifying fibroma
- Fibrous dysplasia
- Paget's disease
- Osteogenesis imperfecta

**Answer: b.** Fibrous dysplasia

NEET PG 2023

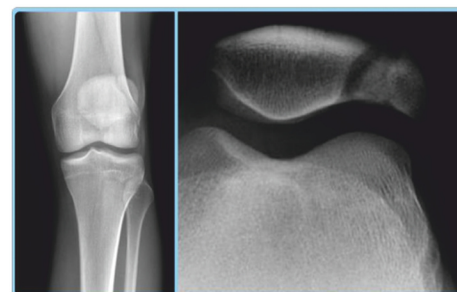

Q. The radiograph below depicts a patient who is experiencing persistent knee pain without any previous injury. Identify the specific condition displayed in the image?

- Patellar avulsion fracture, TBW
- Bipartite patella, X-ray of the opposite knee
- Fracture of the upper pole of the patella, cylindrical cast
- Avulsion fracture, interfragmentary screw fixation

**Answer: b.** Bipartite patella, X-ray of the opposite knee

NEET PG 2023

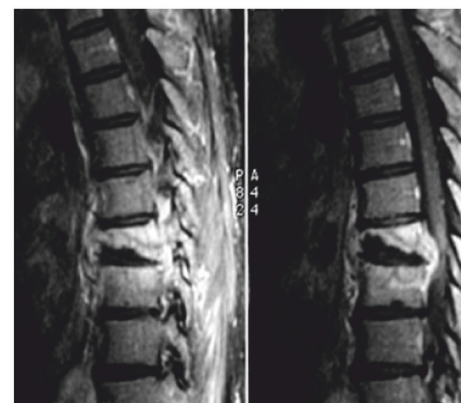

Q. Based on the provided image, what possible diagnosis can be determined?

- Multiple myeloma
- Ankylosing spondylitis
- Pyogenic spondylitis
- Pott's spine

**Answer: d.** Pott's spine

FMGE June 2022

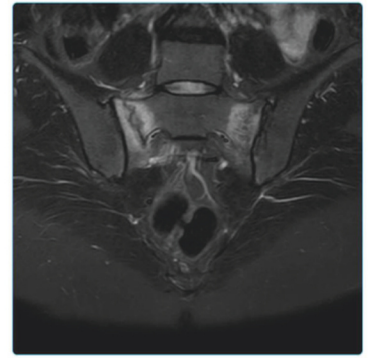


Q. Identify the condition associated with the image shown below:

- Sacral metastasis
- Sacral insufficiency fracture
- Transient edema of the sacroiliac joint
- Infective sacroiliitis

**Answer: b.** Sacral insufficiency fracture

INICET May 2025

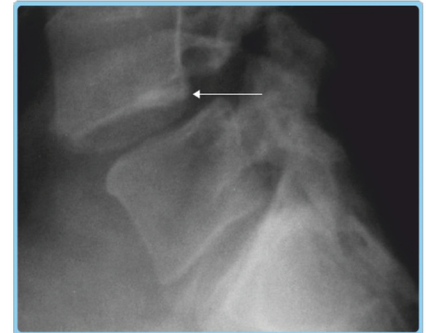


Q. A 74-year-old man, who was previously a weightlifter, presented with lower back pain that was radiating to his legs. On examination, a palpable step was felt in the lumbosacral region of the spine. The X-ray of the spine is given below. What is the likely diagnosis?

- Spondylolysis
- Spondylolisthesis
- Disc prolapse
- Spondylosis

**Answer: b.** Spondylolisthesis

FMGE Dec 2021

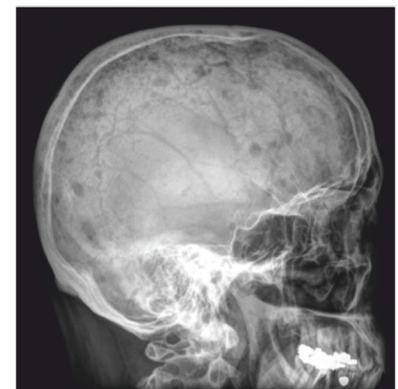


Q. An elderly woman presented with symptoms of confusion, thirst, and abdominal pain. On examination, she had pallor and thoracic spine tenderness. Her lab investigations showed the following findings. An X-ray of her skull is shown below. What is the most likely diagnosis?

- Hb-6.9g/dl
  - WBC 4000/cm<sup>3</sup> with normal differential count
  - Serum calcium 13mg/dl
  - Creatinine 2.3mg/dl
  - Albumin 2.4g/dl
  - Urinalysis: positive for Bence-Jones proteins
- Metastatic breast cancer
  - Multiple myeloma
  - Primary hyperparathyroidism
  - Milk alkali syndrome

**Answer: b.** Multiple myeloma

FMGE June 2022



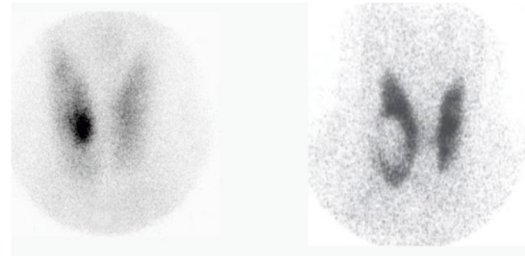


## 2. NUCLEAR MEDICINE

### BASIC PRINCIPLE OF NUCLEAR MEDICINE

00:00:54

- Radioisotope is used, and it is bound to a ligand
- Ligand takes the radioisotope to the organ site of interest
- The radioisotope will emit radiation from there
- Gamma camera detects radiation that comes out
- Based on this, we can know whether that region/organ is **hypo-functioning (Cold Spot - white)** or **hyper-functioning (Hot Spot - black)**



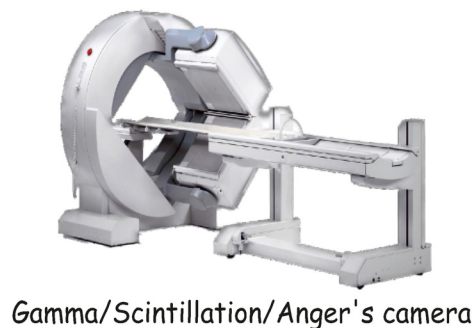### MODALITIES IN NUCLEAR MEDICINE

00:02:30

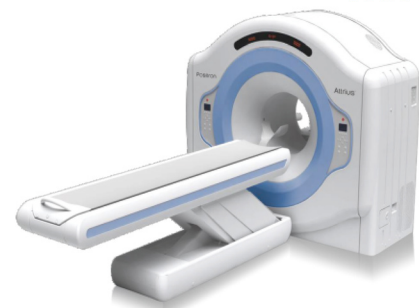
- Nuclear Scan/Scintigraphy
  - 2-Dimensional
- Single Photon Emission Computed Tomography
  - 3-Dimensional
  - Better resolution
- Positron Emission Tomography (PET)

### Mc Radioisotopes Used

- Scintigraphy - Tc99m
  - Half-life: 6 hours
  - Emit gamma rays
- PET scan - F18
  - Half-life: 110 minutes
  - Emits Positrons



Gamma/Scintillation/Anger's camera



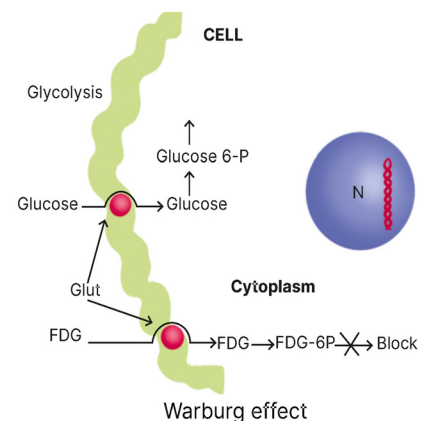
PET Scan

FMGE Dec 2021

### Principle of Pet Scan

00:05:13

- Most commonly used for:
  - Staging of cancer
  - Response of cancer to treatment
  - Detect recurrence of cancer
- F18 & deoxy-glucose (FDG)
- Cancer cells show the Warburg effect
  - Normal glucose undergoes complete glycolysis
  - FDG gets trapped in cancer cells and will show increased uptake



# Yourwish

## Annihilation Coincidence Circuit

F18 emits Positrons



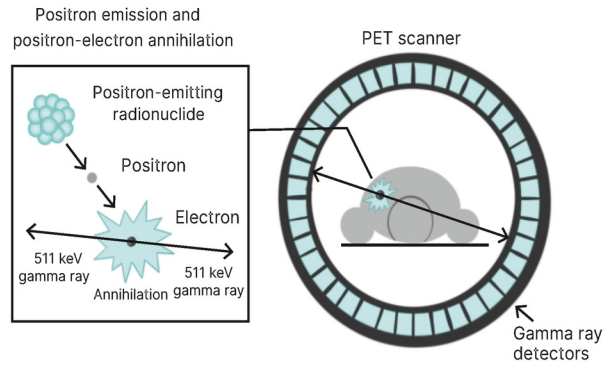
Positron-Electron Annihilation



Energy is converted to two photons, with the energy of each photon being 511 keV gamma key (Dual Photon Peak)



Detected by the ring detector in PET

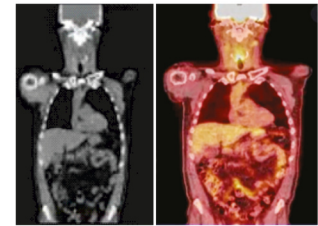


FMGE June 2024

00:07:41

## PET-CT SCAN

- More commonly used
- Hybrid functional imaging
- Orange color reflects areas of uptake



## Nuclear Scan For Parathyroid




00:08:23

- Sestamibi scan (most preferred)
- SPECT is preferred over scintigraphy
- Patient presents with a history of:
  - Stones - Renal Stones (hypercalcemia)
  - Bones - Bone Resorption & Pain
  - Moans - Psychiatric features
  - Groans - Abdominal Pain

## Thyroid Scan

00:09:00

	<p>Cold nodule (white)</p>
	<p>Hot nodule</p>

	Toxic Multinodular Goiter- multiple hot nodules
	Diffuse decreased uptake Seen in Thyroiditis
	Diffuse increased uptake Seen in Grave's disease

- Cold nodules have a higher chance of being malignant than hot nodules
- Ideal radioisotope: I-123
- MC radioisotope used in India: I-131

### Iodine Isotopes

FMGE June 2021

Isotope	Half life	Uses
$^{123}\text{I}$ (Iodine 123)	13.2 hours	Diagnostic purposes
$^{125}\text{I}$ (Iodine 125)	60.14 days	Brachytherapy
$^{131}\text{I}$ (Iodine 131)	8.04 days	Radioablation of thyroid

### Cardiac Scans

00:10:58

Condition	Preferred Scan
Myocardial Ischemia	Thallium scan (picks up ischemic areas that are reversible as cold spots)
Myocardial Infarct	Pyrophosphate scan (appears as a hot spot)

Ejection fraction or LV function	MUGA (Multigated Acquisition) scan - uses radiolabeled RBCs
Myocardial Viability	PET (metabolic & perfusion) scan
Viability	Cardiac MRI with Late Gadolinium Enhancement (LGE) - Gold standard investigation

### Renal Scans

00:12:36

- DMSA
  - Morphology of the kidney
  - Scarring of the kidney (VUR)
    - Gold standard investigation for VUR: MCU
- DTPA
  - Renal physiology - Glomerular Filtration Rate (GFR)
- MAG3
  - Overall function of the kidney (including tubular function)

### Bone Scan

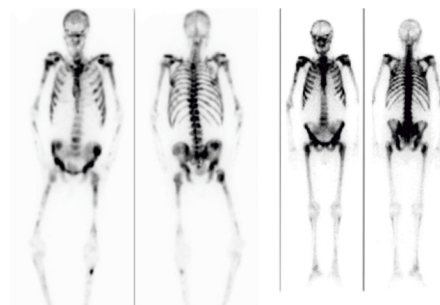
00:13:41

- Methylene Diphosphonate (MDP) scan
  - New bone formation shows hot spots
    - Callus formation in fracture
    - Osteomyelitis
    - Bone tumors
  - Not specific for bone metastasis
  - Multiple Myeloma shows hot spots despite no new bone formation

### Super Scan


00:14:38

- Type of bone scan
- Shows multiple bones with a lot of uptake in the scan
- No uptake is seen in the kidney
- Seen in:
  - Hyperparathyroidism
  - Renal failure



### Sacral Insufficiency Fracture

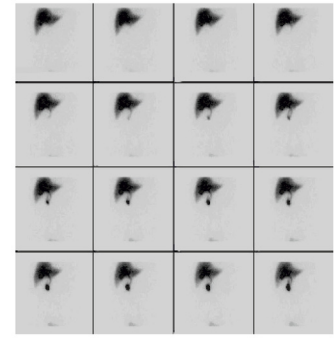
INICET May 2025



**Hida Scan**

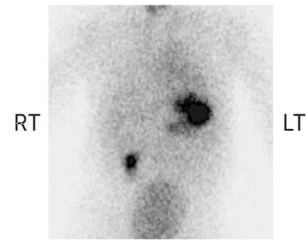
00:15:37

- To check the patency of the biliary tract
- Used to rule out:
  - Biliary atresia
  - Bile leak



**Pertechnetate Scan**

- Used for Meckel's Diverticulum
- Ectopic gastric tissue will take up Pertechnetate in the right iliac fossa
- Warthin tumor shows hot spot



**Mibg Scan**

- Used for Pheochromocytoma (including extra adrenal)
  - IOC for Pheochromocytoma: MRI
    - Light bulb sign
    - Not useful in extra-adrenal pheochromocytoma → MIBG
  - DOPA-PET
    - Dihydroxyphenylalanine Positron Emission Tomography scan

DOTA-TOC/DOTA-NOC Scan	Used for Neuroendocrine tumors
Prostate-specific membrane antigen (PMSA) Scan	Used for prostate cancer
NaF PET	Used for bone metastasis
C11 Methionine PET	Used for grading brain tumors
HMPAO SPECT	Used for cerebral perfusion

**PET SCAN**

FMGE Jan 2024

False Positive Results	False Negative Results
<ul style="list-style-type: none"> <li>• Infections</li> <li>• Inflammation</li> </ul>	<ul style="list-style-type: none"> <li>• Low-grade tumors</li> <li>• Broncho-alveolar carcinoma</li> <li>• Carcinoid tumor</li> </ul>

- Physiological Uptake: B/L supraclavicular uptake

**PYQs**

00:20:39

Q. Ga-68 PSMA PET scan is used to diagnose which of the following conditions?

FMGE Jan 2024

- Lung cancer
- Prostate cancer
- Colon cancer

## Yourwish

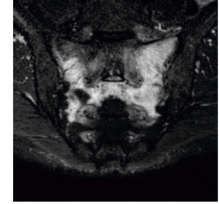
d. Liver cancer

**Answer: b. Prostate cancer**

**Q.** A patient presents with low back pain. Bone scan reveals the characteristic "Honda H" sign. What is the most likely diagnosis?

FMGE June 2021

- a. Acute osteomyelitis
- b. Marrow edema
- c. Bilateral sacral insufficiency fracture
- d. Metastatic sacral lesion



**Answer: c. Bilateral sacral insufficiency fracture**

**Q.** For the treatment of thyroid cancer, which radioactive iodine isotope among the options listed below is used?

INICET May 2025

- a. Iodine -125
- b. Iodine-131
- c. Iodine-127
- d. Iodine-123

**Answer: b. Iodine -131**

**Q.** Radioisotope used in PET-CT scan?

FMGE June 2024

- a. 18F-FDG
- b. Iodine
- c. Radium
- d. Cesium-131

**Answer: a. 18F-FDG**

**Q.** Most common radioisotope in PET scan:

FMGE Dec 2021

- a. 13C
- b. 14C
- c. 18F
- d. All of the above

**Answer: c. 18F**



# 1. HEPATOBILIARY AND PANCREAS


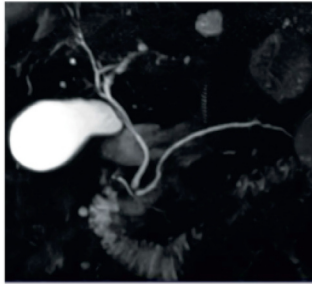
## IDENTIFYING THE INVESTIGATIONS

00:00:17

### Cholangiopancreatogram

- Visualizing bile duct and pancreatic duct
- 2 types
  - ERCP → Endoscopic Retrograde cholangiopancreatogram
  - MRCP → Magnetic resonance cholangiopancreatogram

NEET PG 2024  
FMGE 2024  
INICET 2025

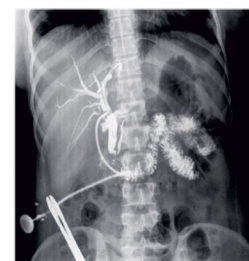
Ercp	Mrcp
	
<ul style="list-style-type: none"> <li>• Endoscope</li> </ul>	<ul style="list-style-type: none"> <li>• MRI</li> </ul>
<ul style="list-style-type: none"> <li>• Invasive</li> <li>• Gold standard</li> </ul>	<ul style="list-style-type: none"> <li>• Non-Invasive</li> <li>• IOC</li> </ul>
<ul style="list-style-type: none"> <li>• Contrast X-ray performed under fluoroscopy</li> <li>• Risk of radiation exposure</li> </ul>	<ul style="list-style-type: none"> <li>• No radiation exposure</li> </ul>
<ul style="list-style-type: none"> <li>• Contrast used → Iodinated contrast</li> </ul>	<ul style="list-style-type: none"> <li>• Contrast is not been used</li> <li>• T2-weighted images               <ul style="list-style-type: none"> <li>○ Water appears white</li> </ul> </li> </ul>
<ul style="list-style-type: none"> <li>• Advantage               <ul style="list-style-type: none"> <li>○ Luminal pathology</li> </ul> </li> <li>• It is used for diagnosis and treatment</li> </ul>	<ul style="list-style-type: none"> <li>• Advantage               <ul style="list-style-type: none"> <li>○ Evaluates surrounding abdominal structure</li> </ul> </li> <li>• It is used only for diagnosis</li> </ul>

### T Tube Cholangiogram

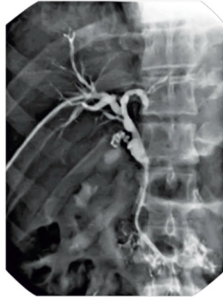
- Done post cholecystectomy
- Uses
  - Diversion and Draining of the Bile

### Percutaneous Transhepatic Cholangiogram

- The catheter is moved into the intrahepatic biliary radicle
- Uses



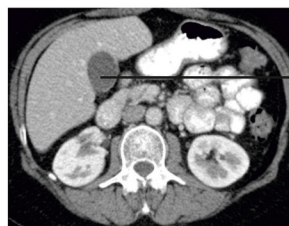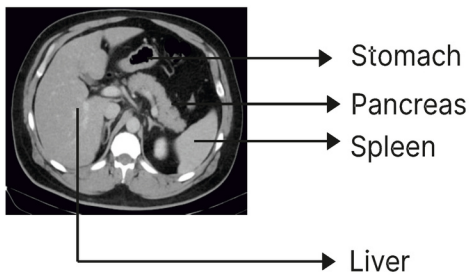
- The main bile duct cannot be excised due to significant narrowing.
- As a result, the bile radicle is excised through the periphery



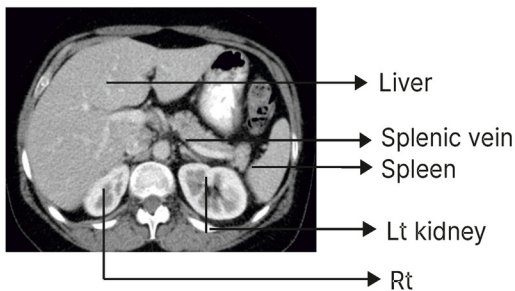
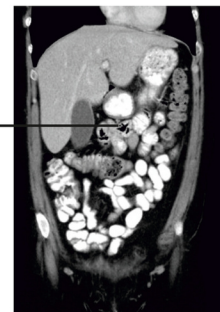
**ANATOMY**

00:03:06

**Identification Of Organs**



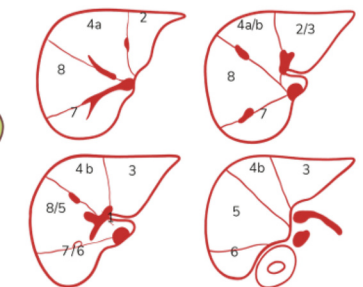
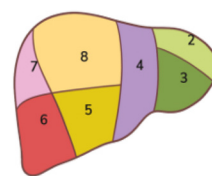
Gallbladder



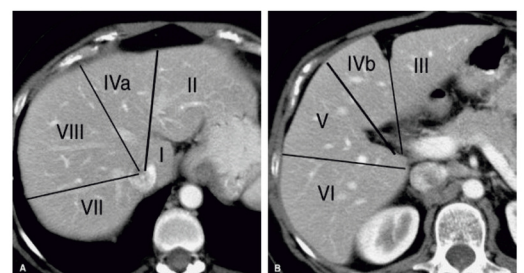
**Identification Of Liver Segments**

FMGE 2023

- Cantlie line
  - Divides the liver into right and left lobe
  - Cantlie line contains middle hepatic vein
  - Right lobe - segments 5, 6, 7, 8
  - Left lobe - segments 2, 3, 4
- Portal vein
  - Divides the liver into upper and lower half
  - Upper half - segment 2, 4A, 8, 7
  - Lower half - segment 3, 4B, 5, 6
- Segment 1 → Caudate lobe, which is the independent segment
- Identification of the segment through CT scan
  - Kidneys are seen → lower half, which includes segment 3, 4B, 5, 6
  - Kidney not seen → upper half which includes segment 2, 4A, 8, 7
- Posterior segment → segment 6, 7
- Anterior segment → segment 5, 8
- Left medial segment → segment 4
- Left lateral segment → segment 2, 3

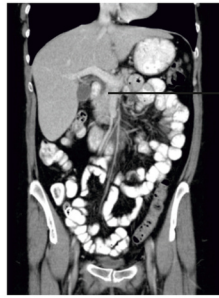


Liver segments

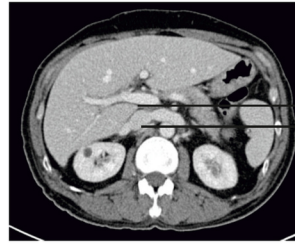


## Identification of blood vessels

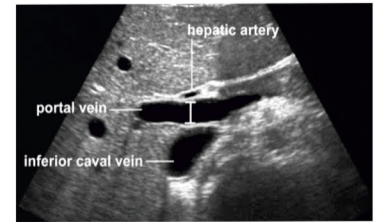
### Ct scan



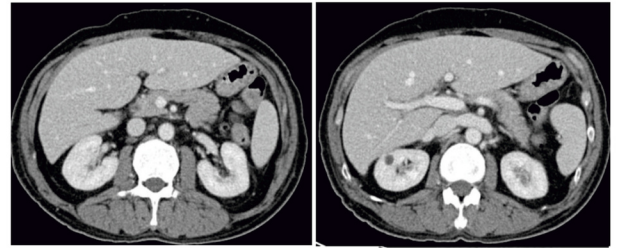
Portal vein



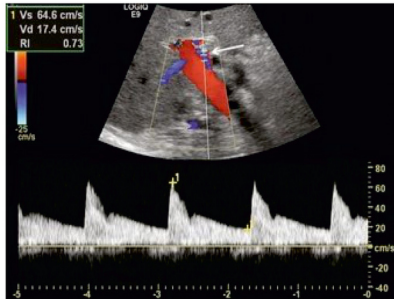
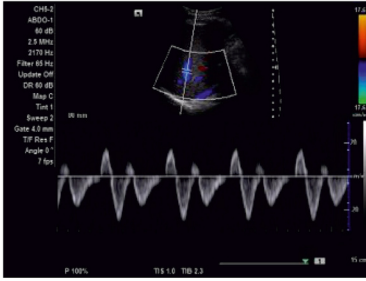
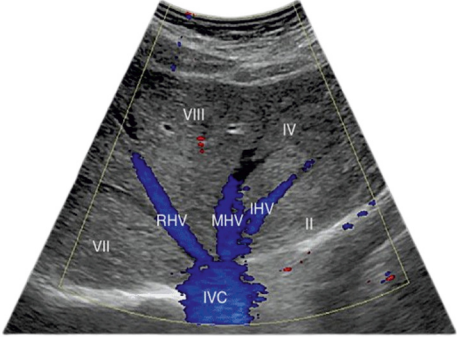
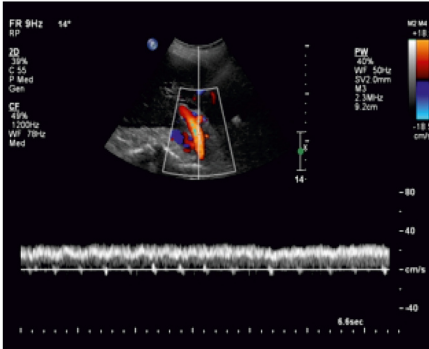
Portal vein  
IVC



- Left renal vein present between Aorta and SMA
- Left renal vein drains into IVC
- Nutcracker syndrome
  - Left renal vein is compressed between aorta and SMA



### Doppler

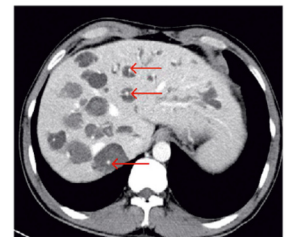
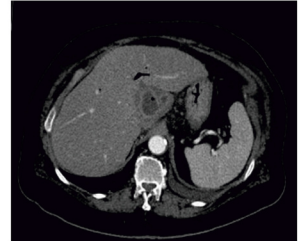
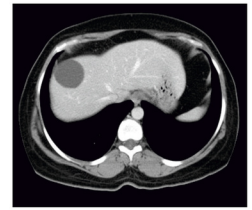
<p><b>Hepatic artery</b></p>	<ul style="list-style-type: none"> <li>• Arterial waveform → upstroke and downstroke</li> </ul> 
<p><b>Hepatic vein</b></p>	<ul style="list-style-type: none"> <li>• 3 hepatic vein drains into IVC and heart</li> <li>• Pulsatile waveform</li> </ul>  
<p><b>Portal vein</b></p>	<ul style="list-style-type: none"> <li>• Unidirectional flow</li> </ul> 

## LIVER PATHOLOGIES

### Cystic Lesion

- Cyst → Thin wall
- Abscess
  - Thick enhancing wall
  - Double target sign
    - Abscess fluid
    - Enhancing wall
    - Liver edema
  - Amoebic liver abscess
    - H/O dysentery
    - Solitary lesions
  - Pyogenic liver abscess
    - Multiple lesions
- Caroli's disease
  - It is a type V choledochal cyst
  - Central dot sign → Central dot represents the portal vein radicle

00:08:14  
INICET 2022



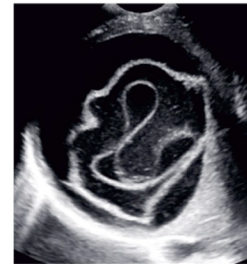### Hydatid Cyst

- Causative organism → Echinococcus
- Signs in hydatid cyst
  - Water lily sign
  - Honeycomb sign
  - Calcified hydatid cyst

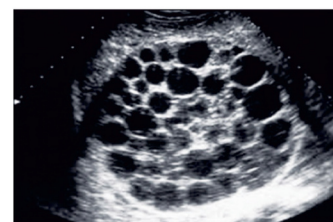INI CET 2023

#### Signs in Hydatid cyst

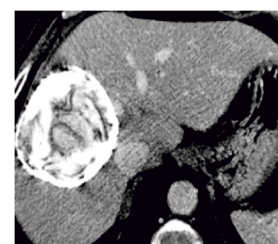
- Water lily sign → Membranes of Echinococcus can detach
  - Gharbi 2
  - WHO 3A



- Honeycomb sign



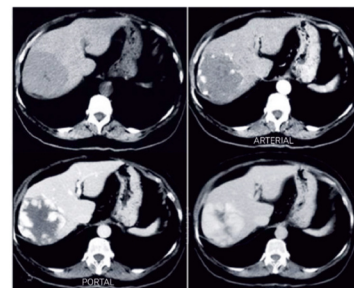
- Calcified hydatid cyst → Final stage of hydatid cyst



## Benign Lesions

### Hemangioma

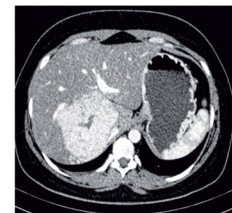
- Detected incidentally
- On USG → Hyperechoic
- On Triple phase CT
  - Hypodense → non-contrast scan
  - Peripheral nodular enhancement → arterial phase
  - Centripetal filling → portal phase



NEET PG 2025

### Focal Nodular Hyperplasia (Fnh )

- On CT → Central stellate scar
- On T2 weighted MRI → it appears hyperintense



### Important Information

- Fibrolamellar HCC
  - On CT → Central stellate scar
  - On T2 weighted MRI → it appears hypointense

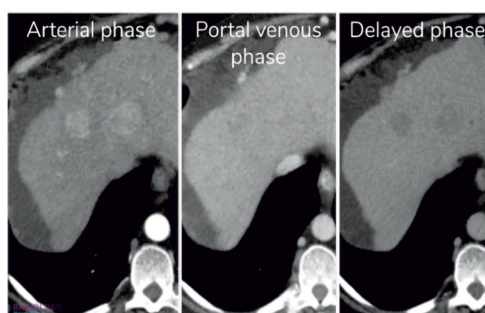
### Hepatic Adenoma

- a/w intake of OC pills
- Increased risk of bleeding, which can lead to hemoperitoneum
- Presence of early arterial enhancement but not early washout

## Malignant Lesions

### Hepatocellular Carcinoma

- Supplied by the hepatic artery

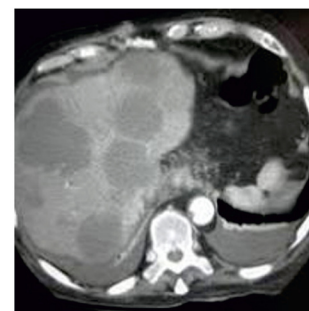


INI CET 2021

- Presence of early arterial enhancement and early washout
- LIRADS → Liver imaging reporting and data system
  - Characterises Benign and malignant lesions

### Hepatic Metastasis

- Multiple hypodense lesions

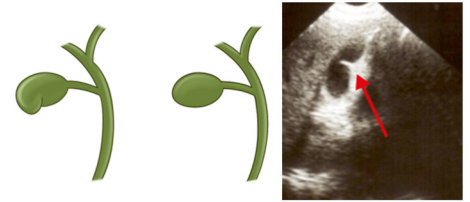

## GALL BLADDER PATHOLOGIES

INI CET May 2023 00:14:07

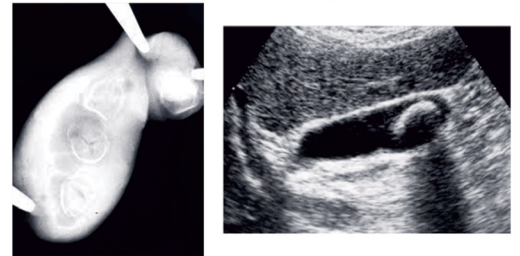
### Phrygian Cap

- Normal variant
- Gall bladder wall is folded in the region of fundus



### Gall Stone

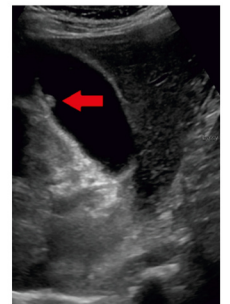
- Echogenic
- Posterior acoustic shadow is present
- Gall stone is mobile
- IOC → USG
- X-ray → Mercedes-Benz sign
  - Air in the gallstone is in triradiate pattern



### Gall Bladder Polyp

- Echogenic
- Posterior acoustic shadow is absent
- Gall bladder polyp is not mobile

INI CET NOV 2022



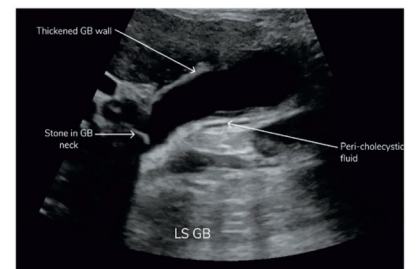
### Cholecystitis

- Inflammation of the gall bladder
- Pain over the Rt hypochondrium
- Murphy sign +

INI CET NOV 2022  
FMGE June 2021

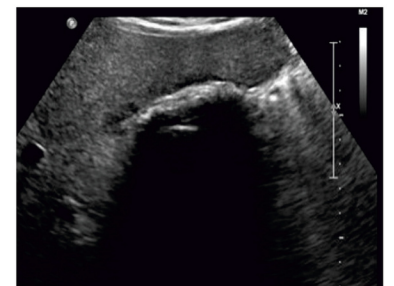
### Acute Cholecystitis

- Distended with thick wall > 3mm due to edema
- Surrounding fluid +
- Cause → Gallstone at GB neck, Acalculous cholecystitis
- Investigations
  - USG - IOC
  - HIDA - gold standard → non-visualization of gall bladder



### Chronic Cholecystitis

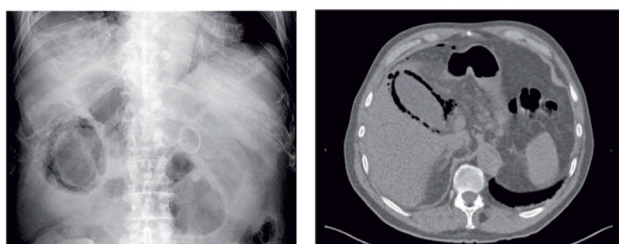
- Gall bladder is contracted and shrunken
- WES sign +
  - Wall
  - Echogenic
  - Post-acoustic shadow



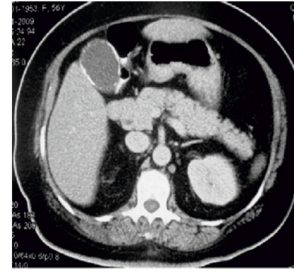
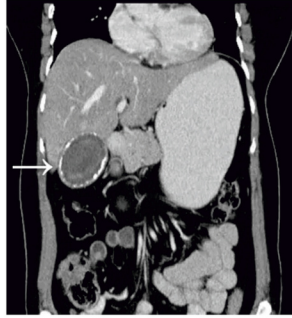
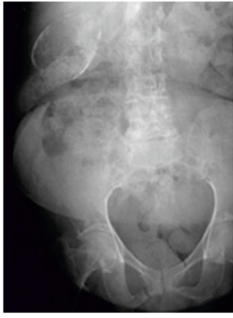### Emphysematous Cholecystitis

- Air in the gallbladder wall

FMGE 2023



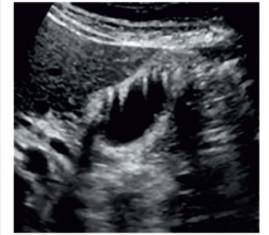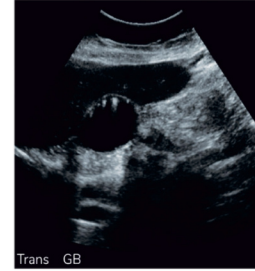## Porcelain Gall Bladder



- Calcification of the gall bladder wall
- Premalignant and needs to be removed

## Adenomyomatosis

- a/k/a **cholesterolosis**
- Deposition of cholesterol in the gall bladder wall
- Gross appearance → Strawberry gall bladder
- Comet tail sign

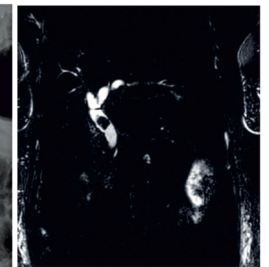
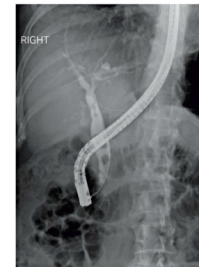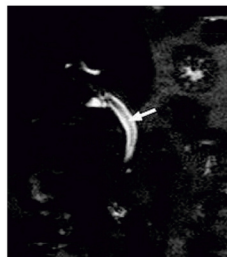


## BILE DUCT PATHOLOGIES

- IOC - MRCP

### Bile Duct Filling Defect

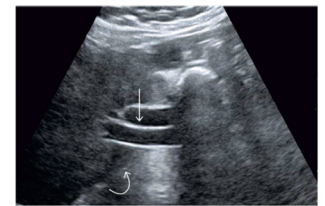- Round → Stone
  - Choledocholithiasis → stone in the bile duct
- Tubular → Ascariasis



00:18:28

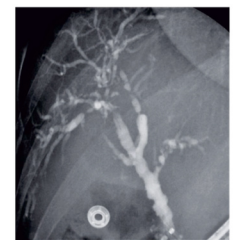### Cbd Obstruction

- Double-barreled sign → Visualization of portal vein and CBD



### Primary Sclerosing Cholangitis

- Fibrosis of the biliary tree
- a/w Ulcerative colitis
- Beaded appearance
  - Biliary tree is beaded due to stricture formation as a result of fibrosis
- Pruned tree appearance
  - Peripheral biliary branches are not seen



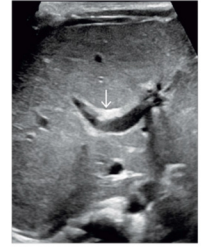### Biliary Atresia

- Seen in neonates

FMGE June 2024,  
NEET PG 2023

# Yourwish

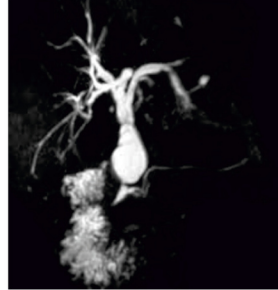
- Presents with obstructive jaundice
- **Triangular cord sign**
- HIDA scan helps in ruling out biliary atresia



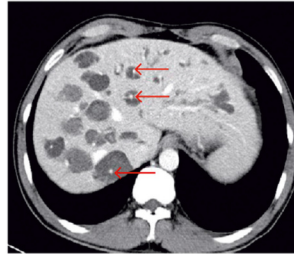
NEET PG August 2024

## Choledochal Cyst

- Todani's classification
  - Type I - Fusiform dilatation of CBD



- Type V - Caroli's disease

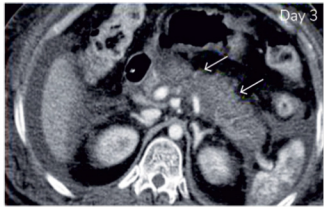

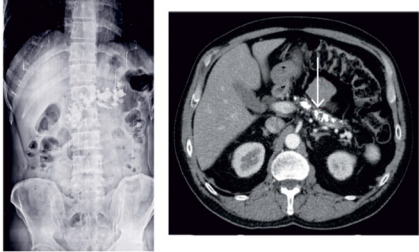


## PANCREATIC PATHOLOGIES

00:21:07

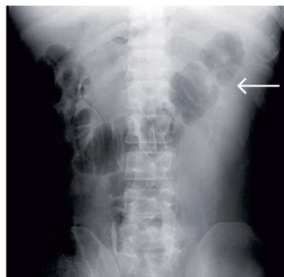### Pancreatitis

NEET PG 2024

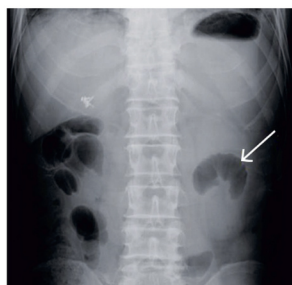
	Acute pancreatitis	Chronic pancreatitis
<b>Pancreas size</b>	Edematous/bulky	Atrophic
<b>Pancreatic duct</b>	Narrow	Dilated (Can be seen on MRCP)
<b>Fluid</b>	Present	
<b>Signs</b>	<ul style="list-style-type: none"> <li>• Bulky</li> </ul>  <ul style="list-style-type: none"> <li>• Pseudocyst → fluid surrounding the wall after 4 weeks in non-necrotizing pancreatitis</li> </ul> 	<ul style="list-style-type: none"> <li>• Calcific</li> <li>• Chain of lakes</li> <li>• Beaded appearance</li> </ul> 

**X-Ray Sign In Acute Pancreatitis**

- Colon cut off sign



- Sentinel loop sign

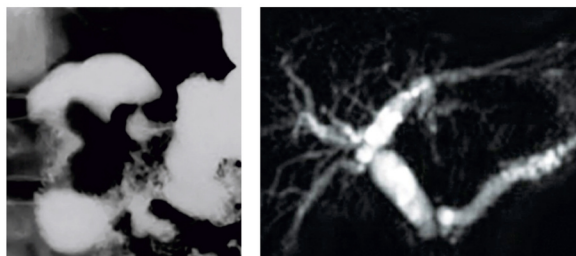


- Gaseless abdomen

**Periampullary Carcinoma**

INICET NOV 2022

- Ampulla of Vater → both CBD and pancreatic duct drain
- It includes carcinoma of the head of pancreas



- Double duct sign → Periampullary cancer causes dilatation of CBD and pancreatic duct
- Reverse figure of 3 sign → Duodenal wall is pulled inside.

**INVESTIGATION OF CHOICE**

00:25:26

- Triple phase CT is done for → Liver lesions
- Gallstone IOC → USG
- Acute cholecystitis IOC → USG
- Acute cholecystitis gold standard → HIDA
- Bile duct IOC → MRCP
- Nuclear scan for biliary tree → HIDA scan
- Pancreatic complications/prognosis IOC → CECT
- Pancreatic duct IOC → MRCP

**ERROR FILES**

00:25:56

- Water lily sign → Membranes of Echinococcus can detach

- Gharbi 2
- WHO 3A
- FNH
  - On CT - central scar
  - T2 weighted - hyperdense
- Fibrolamellar variant of HCC
  - On CT - central scar
  - T2 weighted - hypodense
- Hepatic adenoma
  - Arterial-enhancing liver lesion with no early washout
- HCC
  - Arterial-enhancing liver lesion with early washout
- Double-barreled sign
  - CBD obstruction with obstructive jaundice
- Double duct sign
  - Periapillary carcinoma

**PYQ**

00:26:38

Q.A 50-year-old alcoholic patient presents with a history of waxing and waning jaundice for the past 2 months. His CT examination reveals dilatation of the common bile duct and pancreatic duct. What is the most probable diagnosis in the patient?

INI CET Nov 2022

- a. Cholangiocarcinoma
- b. Periapillary carcinoma
- c. Common bile duct stone
- d. Head of the pancreas carcinoma

**Ans: b. Periapillary carcinoma**

Q.A 35-year-old man with a history of ulcerative colitis presents with fatigue and pruritus. Laboratory investigations show a cholestatic liver function test pattern. MRCP reveals multifocal strictures and beading of intrahepatic and extrahepatic bile ducts. Liver biopsy demonstrates concentric "onion-skin" fibrosis around bile ducts. What is the most likely diagnosis?

- a. Primary biliary cholangitis
- b. Primary sclerosing cholangitis
- c. Autoimmune hepatitis
- d. Secondary biliary cirrhosis

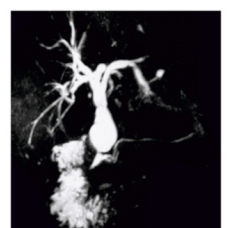
**Ans: b. Primary sclerosing cholangitis**

Q.What condition is indicated by the MRCP image below?

NEET PG August 2024

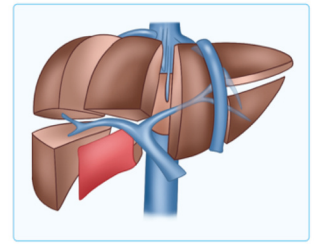
- a. Choledochal cyst
- b. Cholangiocarcinoma
- c. Cholelithiasis
- d. Choledocholithiasis

**Ans: a. Choledochal cyst**



Q. Please determine the segment of the liver that is highlighted in red in the provided image.

- a. V
- b. IVa
- c. VII
- d. III

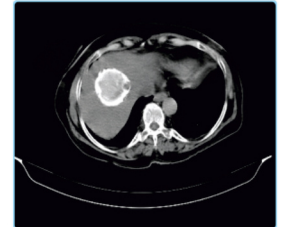


**Ans: a.V**

Q. Identify the condition based on the non-contrast CT scan of a patient given below:

- a. Hepatocellular carcinoma
- b. Fibronodular hyperplasia
- c. Liver abscess
- d. Hydatid cyst

INICET May 2022

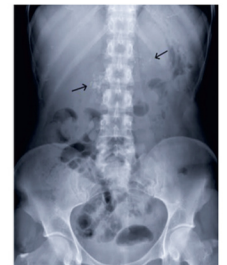

**Ans: d. Hydatid cyst**

NEET PG August 2024

Q. Identify the condition depicted in the radiograph below.

- a. Pancreatic calcification
- b. Mesenteric calcification
- c. Horseshoe kidney
- d. Jejunal fecolith

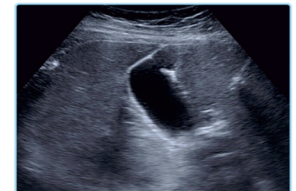

**Ans: a. Pancreatic calcification**

INI CET May 2023

Q. What is the sign of the gallbladder seen in this USG?

- a. Phrygian cap sign
- b. Murphy sign
- c. Claw sign
- d. Omega sign



**Ans: a. Phrygian cap sign**



## 2. URINARY TRACT IMAGING

### INVESTIGATIONS

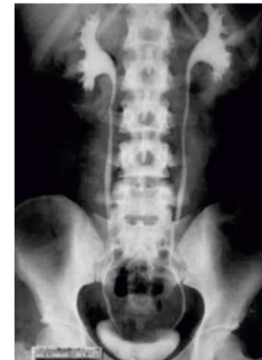00:00:19

#### IVP, RGP, MCU, RGU

- Contrast x-ray studies

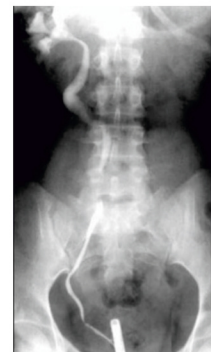#### IVP: (Contrast KUB)

- Iodinated contrast given through IV
- Images taken while the kidneys excrete
- Urethra → Not visible
- Both kidneys are visible → Normal
- One kidney is not visible
  - Agenesis/Non-functioning kidney



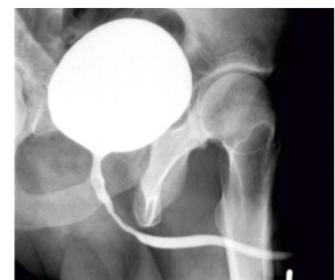#### RGP: Retrograde pyelogram

- Catheterise the ureteric orifice
- Cannula visible at the pelvis



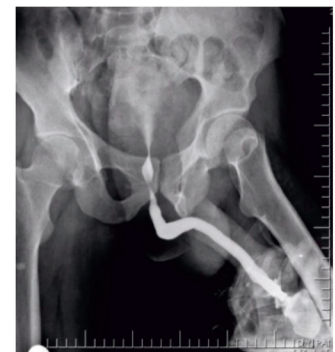#### MCU: Micturating cystourethrogram

- Aka Voiding cystourethrogram (VCUG)
- Contrast is injected into the bladder, and images are taken while micturating
- Bladder + urethra seen



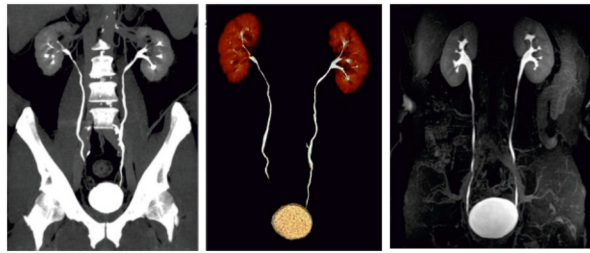#### RGU: Retrograde urethrogram

- Aka Ascending urethrogram (ASU)
- Cannulate the external urethral orifice
- Contrast is injected with a syringe
- Contrast moves in retrograde fashion



Ct Mr Urography

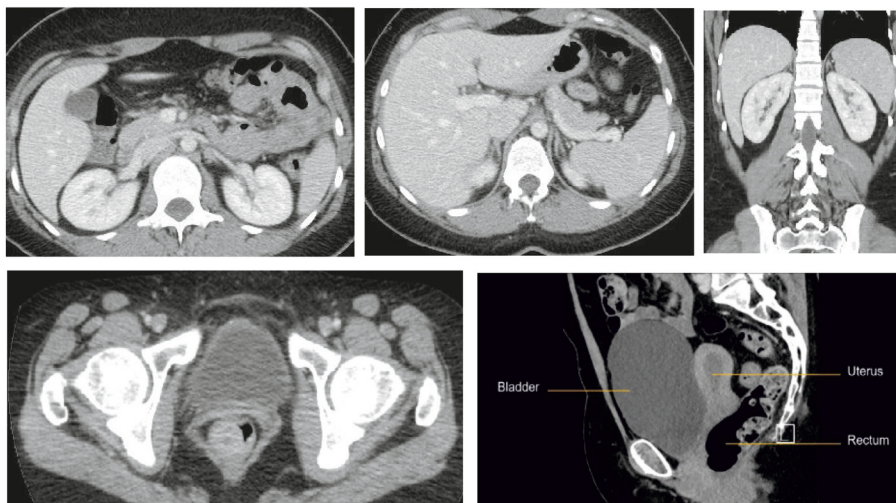
00:03:40



- Bones visible → CT Urography
- Bones not visible → MR Urography
- MR Urography → Can be visualised without contrast (T2 weighted image)
  - Can be used in pts with renal failure

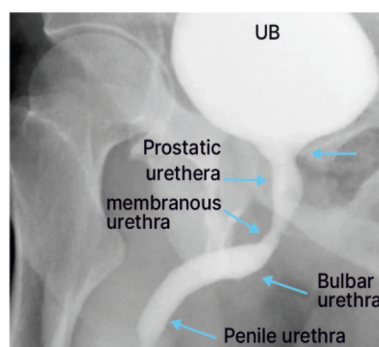
ANATOMY

00:04:48



Various Parts Of The Urethra

FMGE Jan 2024



- Narrowest part → Membranous urethra
  - Affected in cases of pelvic fracture

PATHOLOGIES

00:06:47

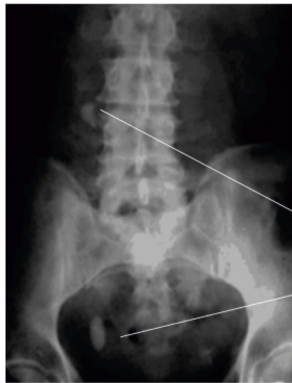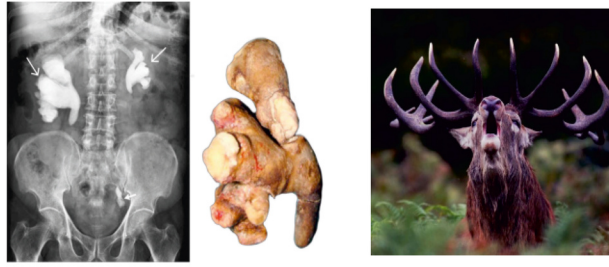Urolithiasis

- IOC → NCCT (Calcified stones)

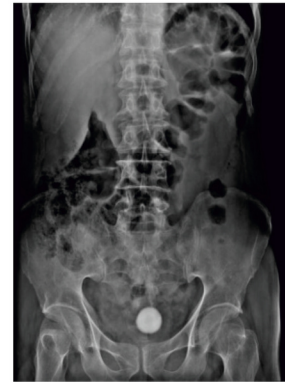**Staghorn calculus**

NEET PG 2021, 2022, 2023

- Commonly seen with Proteus infection



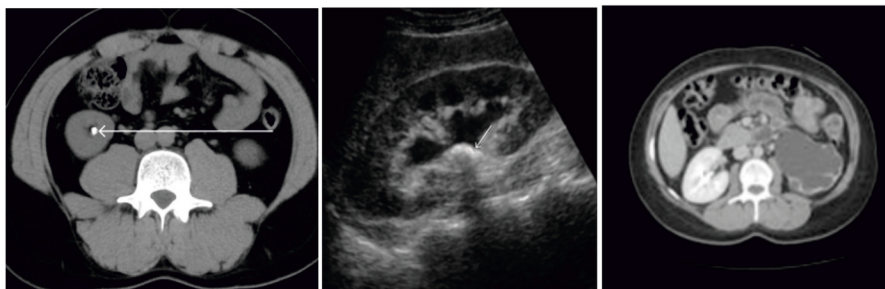
Ureteric stones



Urinary bladder stone

**Renal calculus- hydronephrosis:**

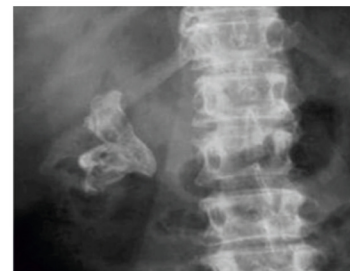FMGE Jan 2023



- **Image 1** → Left renal calculi (CT can pick small calculi)
- **Image 2** → Posterior acoustic shadowing in USG → Renal calculi → resulting in hydronephrosis
- **Image 3** → **Rim sign** → Narrowing of renal parenchyma d/t hydronephrosis

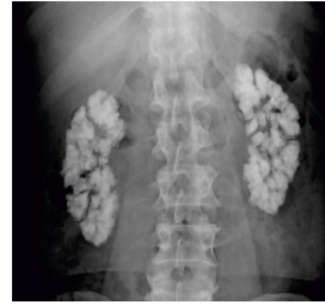**Renal Calcification Differentiation**

**Staghorn Calculus**



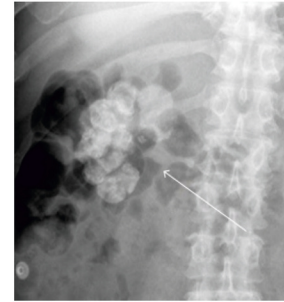
**B/L Medullary Nephrocalcinosis:**

- Seen in hyperparathyroidism

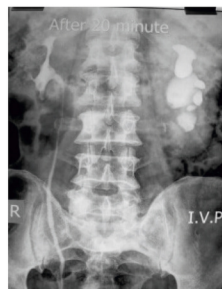

**Putty Kidney**

- Lobulated calcifications
- Seen in Tuberculosis
  - H/o sterile pyuria



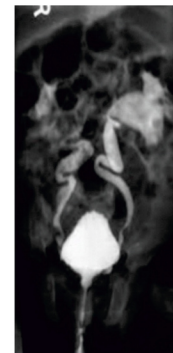
**Puj Obstruction**



- Delayed IVP image
- Done in

**Vesicoureteric Reflux**

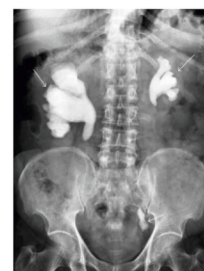- H/o child with recurrent UTI
  - IOC → MCU
- **Image** → Urethra visible & bladder distended → MCU
- Contrast in the ureter and the kidney → VUR
  - Normally ureter is not visible in the MCU
  - Here ureter is visible → Reflux + → VUR
- IOC for scar secondary to VUR → DMSA



NEET PG 2022

**Staghorn Vs Puj Obstruction Vs Vur**

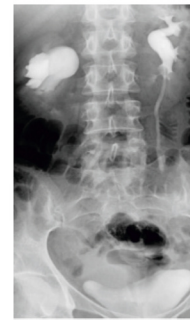**Staghorn calculus**



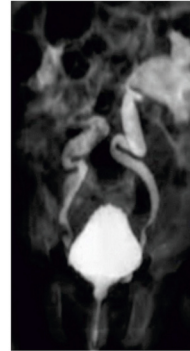
# Yourwish

## PUJ Obstruction on the right side

- Hydronephrosis seen on IVP



## VUR



## Pyelonephritis

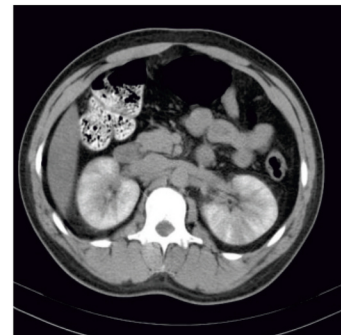
00:14:24

### Acute Pyelonephritis

- Acute inflammation → Enlarged kidney

### Striated appearance on CT

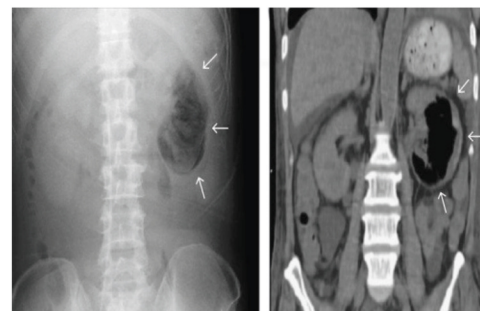
- Enlarged parenchyma compresses the vessels → opacification affected



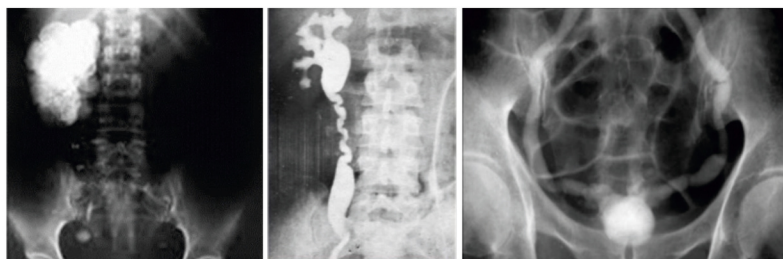### Emphysematous Pyelonephritis

#### Jet black → Air

- Air present inside the kidney



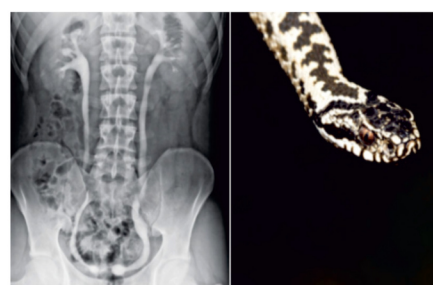Tb - Urinary Tract



- **Image 1** → Putty kidney
- **Image 2** → Beaded appearance / cork screw appearance of the ureter
- **Image 3** → Thimble bladder (Small contracted bladder)
  - Golf hole ureteric orifice seen on cystoscopy
  - H/o Sterile pyuria seen

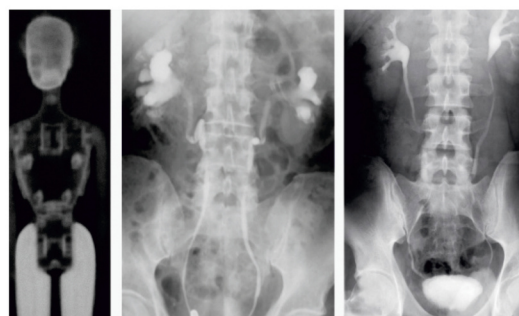
**Cobra Head Appearance** → Ureterocele

- Dilation of the ureter at the insertion
- Aka Adder Head Appearance



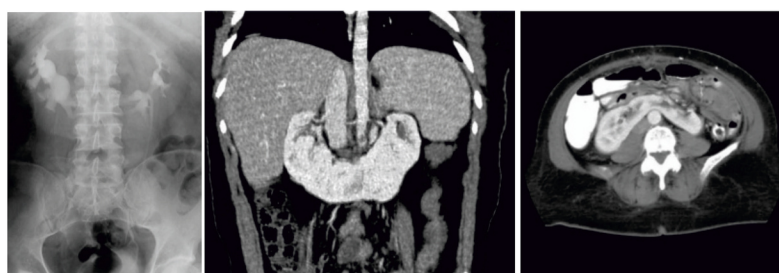
**Maiden Waist Ureter**

- Medial deviation of the ureter
  - D/t fibrosis
- Seen in Retroperitoneal fibrosis
  - Ormond's disease
- Normally, → Ureter runs paravertebrally
  - Overlapping of the ureter over the vertebra → Medial deviation



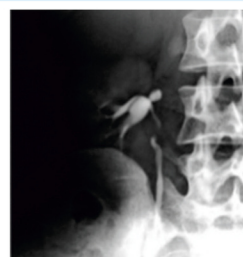**Horseshoe kidney**

- Fusion of the kidneys at one pole
- Flower vase appearance
  - Aka Joining hands appearance



**Duplex moiety**

- Drooping lily appearance
- Drooping of the lower moiety by the pressure from the enlarged, obstructed, non-functioning upper moiety.

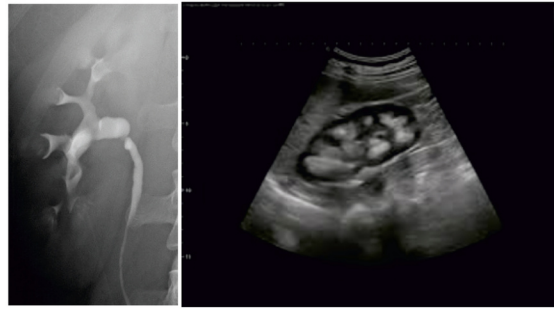

**Medullary Sponge Kidney**

**Image 1** → Paintbrush appearance on IVP

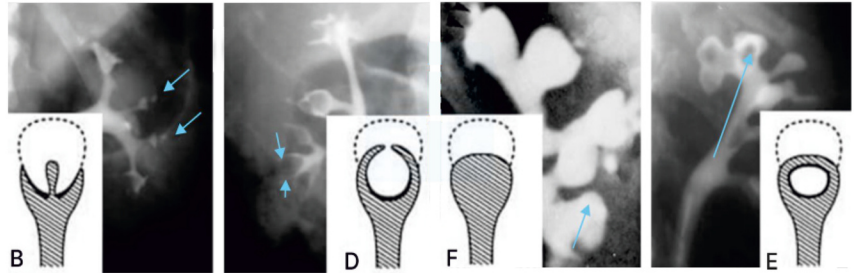
- D/t dilation of CD

**Image 2** → Echogenic pyramids on USG



**Renal Papillary Necrosis**

- **Image 1** → Ball on tee sign
- **Image 2** → Lobster claw sign
- **Image 3** → Clubbing of calyces
- **Image 4** → Signet ring appearance



**Renal Lesions**

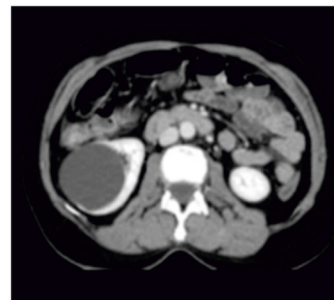00:22:13

**Renal Cyst Vs Aml Vs Rcc**

FMGE Jan 2023

**Renal cyst:**

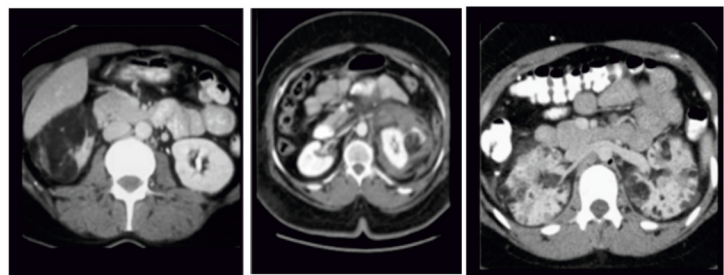
- Cyst → Water-containing
  - Grey non-enhancing
- **Bosniak classification**
  - Based on CECT



**Angiomyolipoma:**

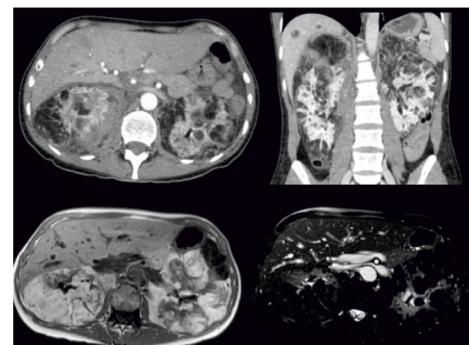
- Fat → Black areas
- Vessels +
- Associated with **Tuberous Sclerosis**

FMGE Jan 2023



**MRI**

- **T1WI** → Fat appear white
- **STIR** → Fat suppressed sequence → Fat appear dark

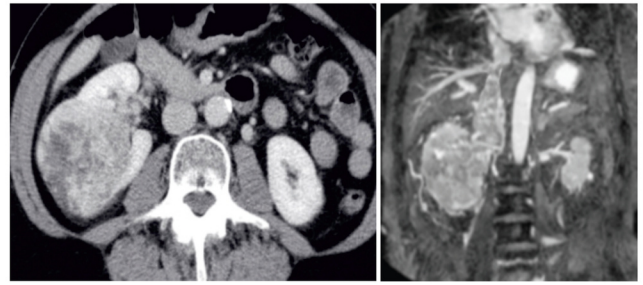


**RCC:**

**Image 1** → Enhancing d/t vascularity

**Image 2** → Tumour thrombus invading IVC

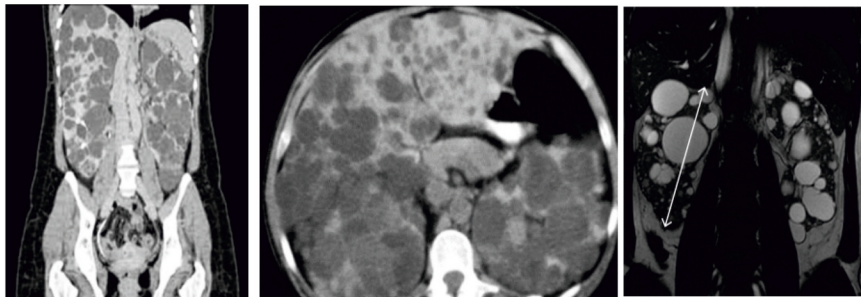
- Tumour thrombus → MRI



**ADPKD**

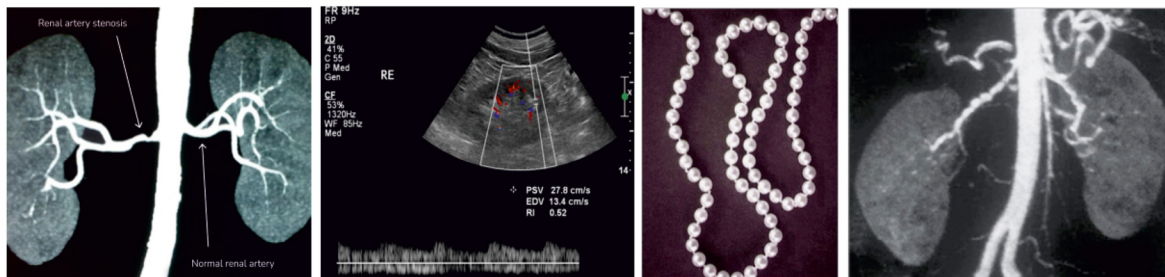
NEET PG August 2024

- M/c in Adults
- Positive Family history & renal failure present
- Multiple cyst → Grey
- Enlarged kidneys with multiple cyst → Grey lesions (Water → Grey)



- **Image 3** → T2WI MRI → Water → White

**Renal Artery Stenosis & Fibromuscular Dysplasia**



- Renal artery narrowing → Secondary HTN
  - RAS → **1st Investigation** → Renal artery doppler
  - Better Investigation → **MR Angiography**

**Image 1** → MR Angiogram → Renal Artery stenosis on the right side

**Image 2** → Renal artery doppler → Parvus tardus waveform

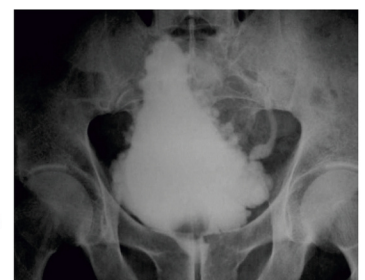- Slow rising waveform with decreased PSV

**Image 3** → Beaded appearance of renal artery (string of pearls appearance)

- Seen in Fibromuscular Dysplasia

**Neurogenic Bladder**

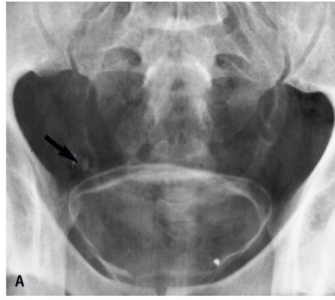
- The tone of the bladder is affected
- Elongated bladder with multiple diverticuli → **Christmas/Fir/Pine tree appearance**



## Yourwish

**Schistosoma**

- Caused by *Schistosoma hematobium*

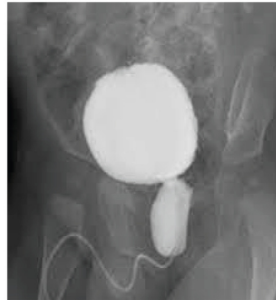

- Peripheral calcification of the urinary bladder → **Fetal skull calcification** appearance

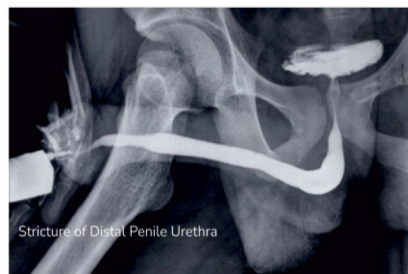**Posterior Urethral Valve**

FMGE Jan 2025

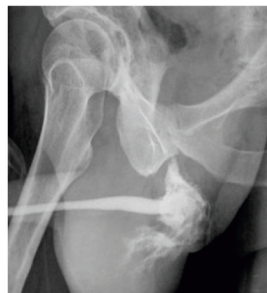- H/o male child with urinary tract obstruction



- **IOC** → MCU (Valve opens towards the bladder & hence RGU is not preferred)
- Bladder with dilated posterior urethra → **Keyhole appearance**

**Urethral Stricture**

- Stricture of the distal penile urethra
- **IOC** → **RGU**

**Urethral Rupture**

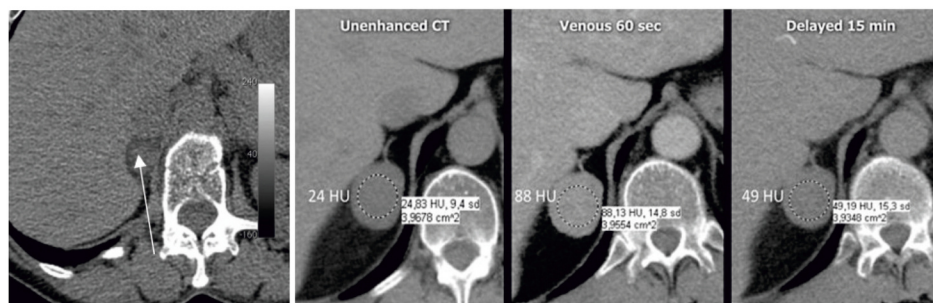
- **IOC** → **RGU**
  - Contrast leaking out of the urethra → Urethral rupture

- MCU → Not done → Rupture may aggravate while inserting foley's catheter
- Pelvic fracture → Membranous urethra rupture

## Adrenal Lesions

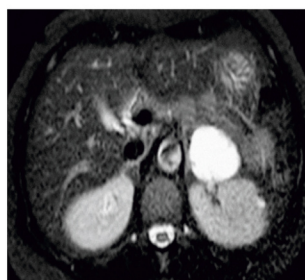### Adrenal Adenoma

- M/c incidentaloma
- Lipid-rich → HU < 10



- Early wash-in & early washout of contrast
- Absolute wash out =  $\frac{\text{Enhanced CT (HU)} - \text{Delayed CT (HU)}}{\text{Enhanced CT (HU)} - \text{Unenhanced CT (HU)}} \times 100\% = \frac{88 - 49}{88 - 25} = 62\%$
- Relative washout =  $\frac{\text{Enhanced CT (HU)} - \text{Delayed CT (HU)}}{\text{Enhanced CT (HU)}} \times 100\% = \frac{88 - 49}{88} = 44\%$

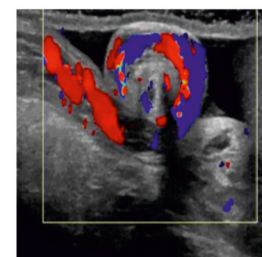
### Pheochromocytoma



- IOC → MRI
  - T2WI → Light bulb appearance
- Nuclear scan → MIBG scan

### Testicular Torsion

- Patient presents with sudden testicular pain
- IOC → Doppler
- The vascular supply of the testes is compromised (d/t twisted vascular pedicle)
  - Whirlpool sign



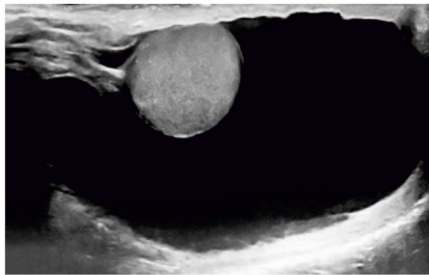
00:34:16

### Epididymo-Orchitis

- Presents with sudden acute pain
- Doppler → Increased Vascularity

### Hydrocele

- Image → USG Testis
  - Fluid surrounding the testis → Hydrocele



- IOC → USG

## IOC - KEY POINTS

00:35:02

- Urinary tract stone / ureteric colic → NCCT
- PUJ obstruction → Delayed IVP
- VUR → MCU
- PUV → MCU
- TB urinary tract → CT Urography
- Urethral stricture → RGU
- Urethral rupture → RGU

## ERRORS TO AVOID

- IVP is an invasive investigation → False
- IVP is performed percutaneously → False
- IOC for PUV → MCU
- MCU done in urethral injury → False
- Lung cancer patient with an adrenal mass with HU = 5, diagnosis? → Adrenal adenoma
- Cobra head appearance is seen in uterocele → False

## PYQ

00:36:52

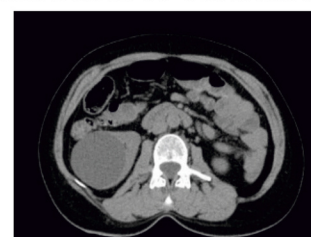Q. A newborn male presents with urinary retention, lethargy and a distended bladder. Antenatal ultrasound showed a "keyhole sign" with a thickened bladder wall. Which of the following is the most likely diagnosis?

- Hypospadias
- Vesicoureteral reflux
- Posterior urethral valves
- Neurogenic bladder

Ans: c

Q. A 62-year-old female undergoes a contrast-enhanced abdominal CT scan for unrelated mild abdominal discomfort. The scan reveals a solitary, 4 cm, round, dark, fluid-filled lesion in the right kidney, as shown in the image. The lesion does not change in appearance or become brighter after the administration of intravenous contrast.

- Renal cyst
- Renal tumor
- ADPKD
- Hydatid cyst

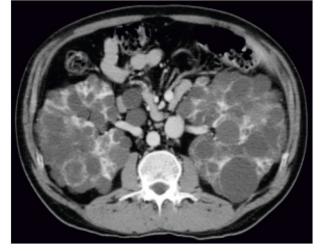


**Ans: a**

**Q.** Based on the CT scan shown below, what is the most likely diagnosis?

- Renal cyst
- Renal cell carcinoma
- Polycystic kidney disease (AD)
- Renal angiomyolipoma

NEET PG August 2024



**Ans: c**

**Q.** A 55-year-old male patient presents with hematuria and a neovascular mass in the left kidney on a CT scan, as shown below. What is the diagnosis?

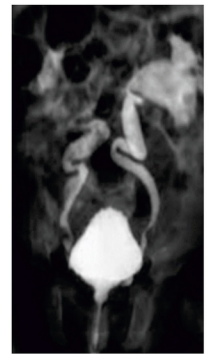- Renal cell carcinoma
- Renal oncocytoma
- Renal angiomyolipoma
- Renal cyst

FMGE Jan 2023

**Ans: c**

**Q.** A 6-year-old boy came with a history of recurrent urinary tract infections. Imaging was done and is shown below. What is the diagnosis?

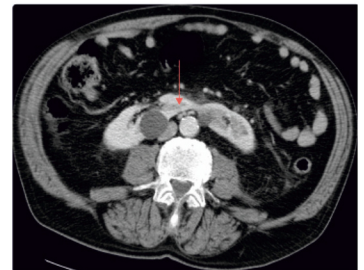- Vesicoureteric reflux
- Urinary bladder diverticulum
- Urinary bladder hernia
- Vesicocolic fistula



**Ans: a**

**Q.** A male patient presented with complaints of hematuria and recurrent urinary tract infection. You notice the following finding in his CT. What is the likely condition indicated by the arrow in the image?

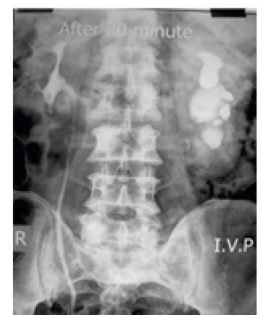- Polycystic kidney disease
- Horseshoe kidney
- Hydronephrosis
- Pancake kidney



**Ans: b**

**Q.** A delayed intravenous urogram of a patient is given below. What is the likely diagnosis?

- Pelviureteric junction obstruction
- Putty kidney
- Staghorn calculus
- Cystic kidney

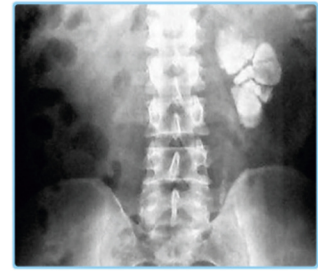

**Ans: a**

## Yourwish

Q. In a patient with abdominal pain and sterile pyuria, what is the finding shown in the image given?

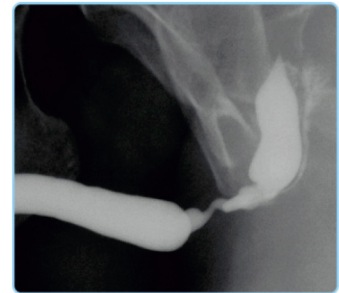
- a. Putty kidney
- b. Nephrocalcinosis
- c. Staghorn calculus
- d. Psoas calcification



Ans: a

Q. Identify the condition in the image:

- a. Urethral stricture
- b. Urethral injury
- c. Urethral tear
- d. Prostate hyperplasia



Ans: a



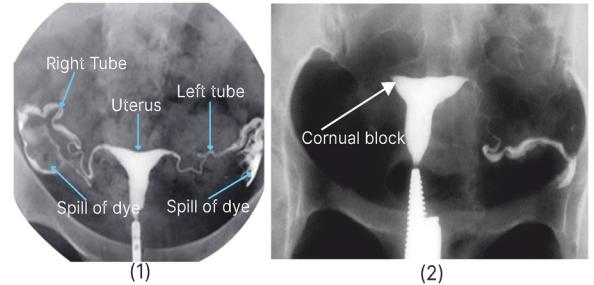
## 2. OBGY AND BREAST IMAGING

### INVESTIGATIONS

00:00:20

#### Hsg: Hysterosalpingogram

- Evaluates tubal patency
- Contrast X-ray with radiation
- Safest time for HSG: First 10 days of cycle
- Best time: Day 7 to Day 9
- Patent tube → Dye spill into peritoneum
- Blocked tube → No spill
  - Cornual block: Tube blocked at the level of cornu

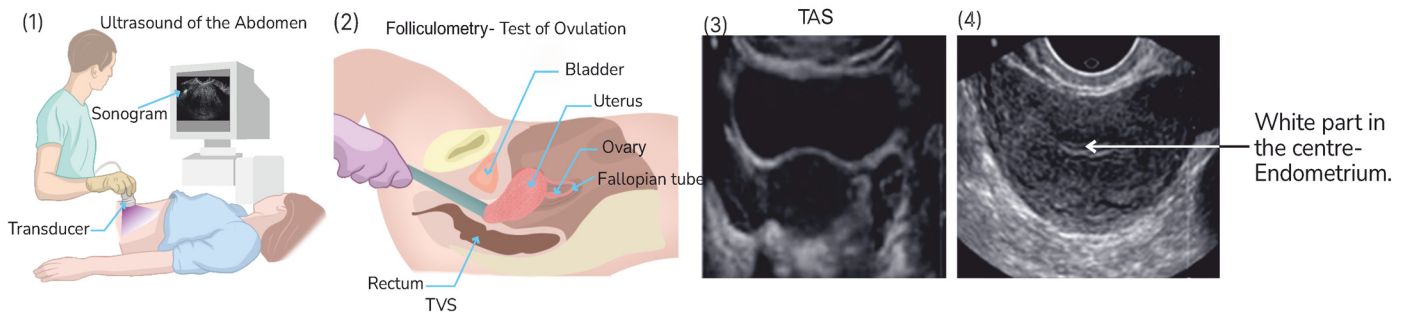


#### Important Information

- Main imaging modalities in OBGY :
  - Ultrasound
  - MRI
- CT: contraindicated in pregnancy

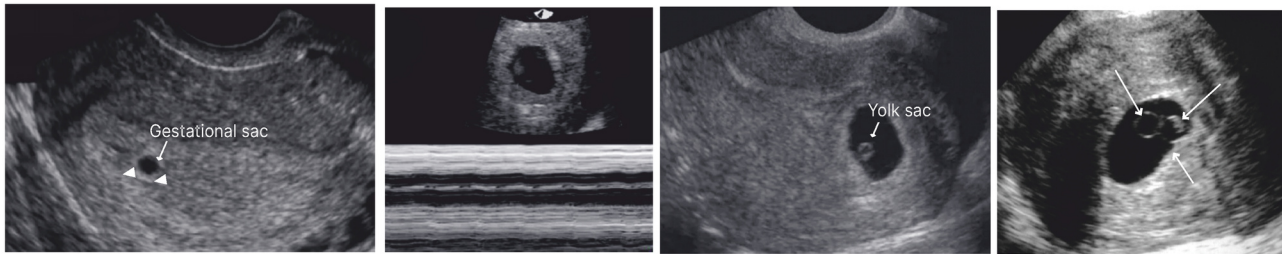
### Ultrasound

- Types of ultrasound :
  - TAS: Full urinary bladder require
  - TVS: empty urinary bladder required
- Early pregnancy ultrasound: TVS is more sensitive



### Early Pregnancy Ultrasound

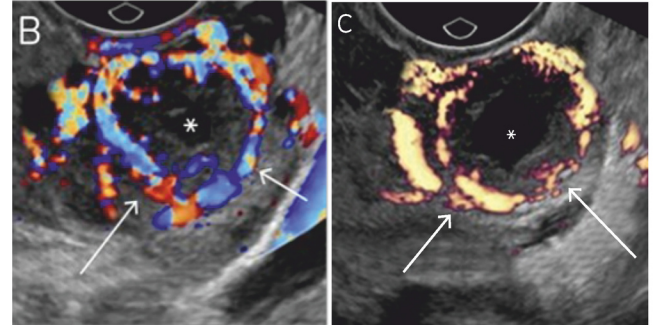
- First sign of intrauterine pregnancy: Gestational sac
- First definitive sign of intrauterine pregnancy: Yolk sac
- Double bleb sign :
  - Yolk sac
  - Amnion
- Fetal cardiac activity :
  - Seen on M-mode ultrasound



INI CET Nov 2021

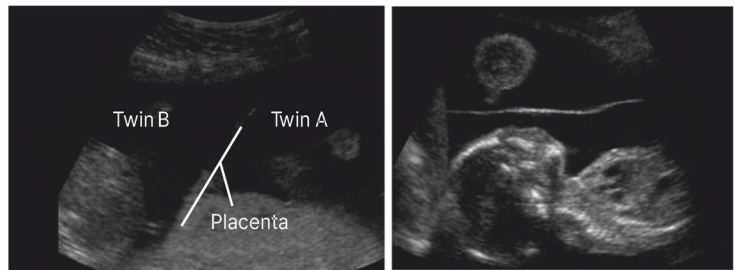
### Ectopic Pregnancy

- Best investigation: TVS
- Findings :
  - Empty uterus or pseudogestational sac in the adnexa
  - Peripheral vascularity
- Peripheral vascularity on Doppler: **Ring of fire sign**



### Twin Pregnancy

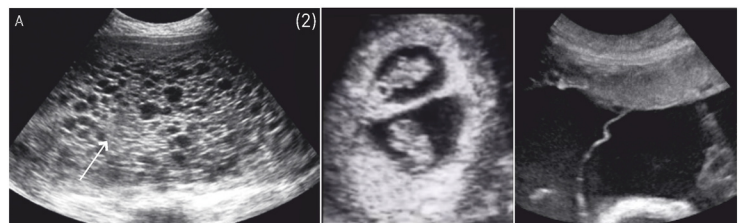
- Dichorionic pregnancy :
  - Thick separating membrane
  - Lambda sign/ Twin peak sign
- Monochorionic pregnancy :
  - Thin separating membrane
  - T sign
- Lambda sign: Dichorionic diamniotic pregnancy
- T sign: Monochorionic diamniotic pregnancy



INICET July 2021, FMGE June 2021

### Molar Pregnancy

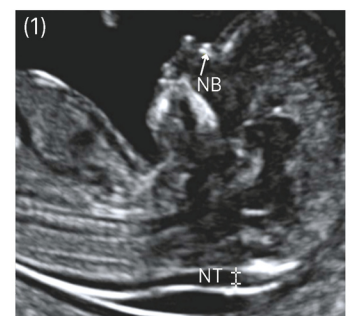
- Complete mole :
  - No fetal parts
  - **Snowstorm appearance**



### Nt Scan

00:08:06

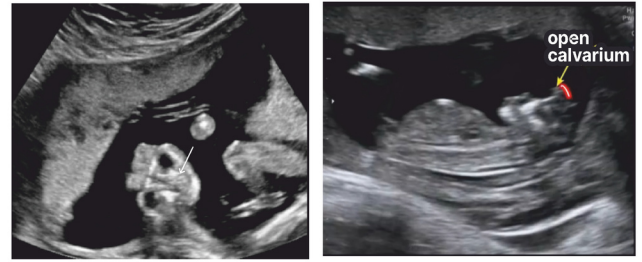
- Nuchal Translucency scan: First-trimester screening for Down syndrome
- Done at 11 to 14 weeks
- CRL: 45 to 84 mm
- Normal NT: 3 mm
- Increased NT → Increased risk of Down syndrome
- Increased NT may also be seen in :
  - Normal pregnancy
  - Cardiac anomalies
  - Other genetic conditions
- Increased NT requires karyotyping to confirm
- Another marker of Down syndrome: Absent nasal bone



### Anomaly Scan

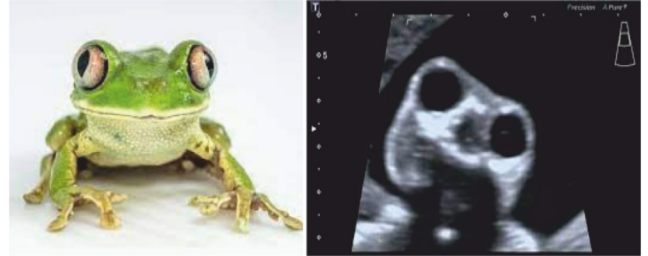- Done at: 18 to 20 weeks
- Also called: TIFA (Targeted imaging for fetal anomalies)

INICET July 2021, NEET PG August 2024



### Anencephaly

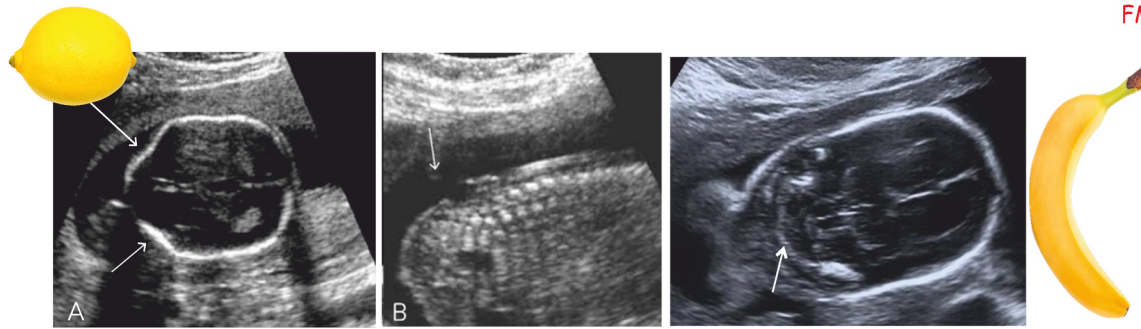
- Earliest anomaly seen on ultrasound
- Seen at: 10 to 11 weeks
- Feature: Absent calvarium
- Sign: Frog eye sign
- Management: MTP
- Folic acid: Prevents but does not treat anencephaly



### Neural Tube Defects

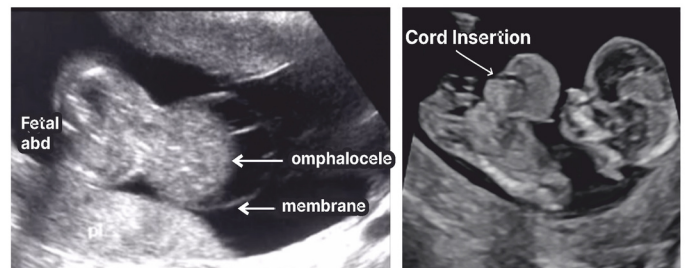
- Lemon sign: Concavity of the frontal bone
- Banana sign: Curved cerebellum → seen in spina bifida

INICET Nov 2023, FMGE Jan 2024




### Omphalocele Vs Gastroschisis

- Omphalocele :
  - Umbilical cord attached to defect
  - Membrane present
- Gastroschisis :
  - Defect adjacent to the umbilical cord
  - No membrane



### UMBILICAL ARTERY DOPPLER

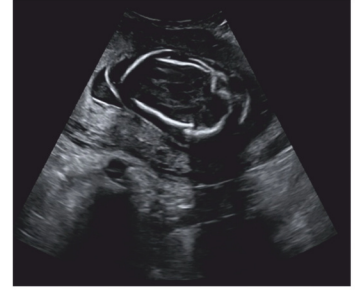00:13:06



- Used to diagnose IUGR
- Normal umbilical artery :
  - Low resistance flow
  - Good diastolic flow

# Yourwish

- IUGR :
  - Increased resistance
  - Decreased diastolic flow
  - Increased S/D ratio
- Severe IUGR :
  - Absent diastolic flow
  - Reversed diastolic flow
    - Impending IUD
    - Emergency LSCS required



## Iud / Iufd

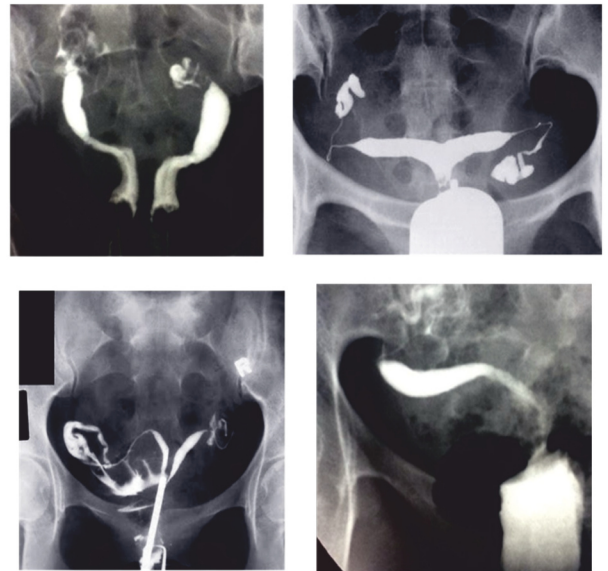
- Spalding sign: Overlapping skull bones
- Robert's sign: Intracardiac gas shadow - Earliest sign of IUD

## GYNECOLOGICAL IMAGING

00:15:08

### Müllerian Anomalies

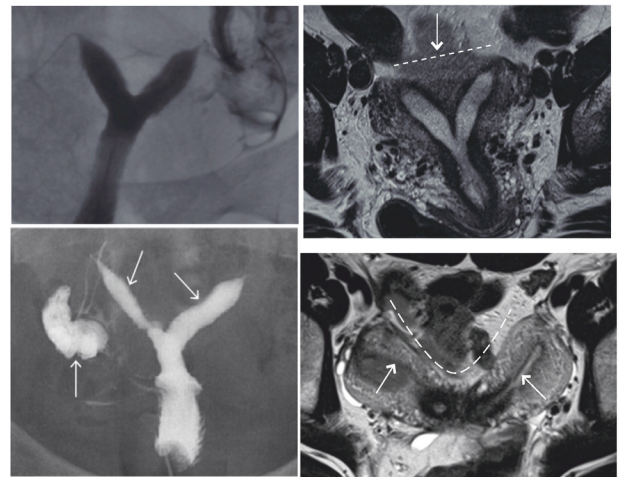
- Female reproductive tract develops from Müllerian ducts
- Failure of fusion or septal resorption leads to uterine anomalies
- Uterus didelphys :
  - No fusion of Müllerian ducts
  - Two separate uterus
  - Two separate cervixes
- Unicornuate uterus :
  - Only one Müllerian duct develops
  - Banana uterus
- Bicornuate uterus :
  - Fusion defect
  - Widely separated cornua
  - Wide separating angle
- Septate uterus :
  - Fusion occurs, but septum persists
  - Small separating angle



### Septate Vs Bicornuate Uterus

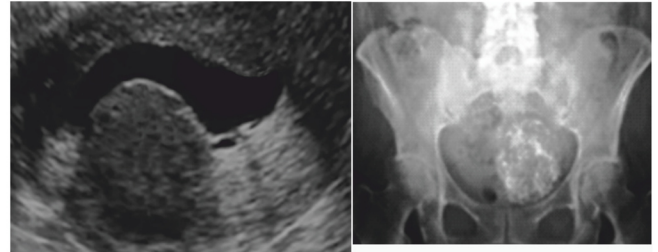
- HSG may not reliably differentiate a bicornuate from a septate uterus → MRI > 3D ultrasound > HSG
- MRI findings :
  - Septate uterus: Smooth outer contour
  - Bicornuate uterus: Bifid outer contour
- Best investigation for uterine anomalies: MRI
- Gold standard: Laparoscopy + hysteroscopy

NEET PG 2022



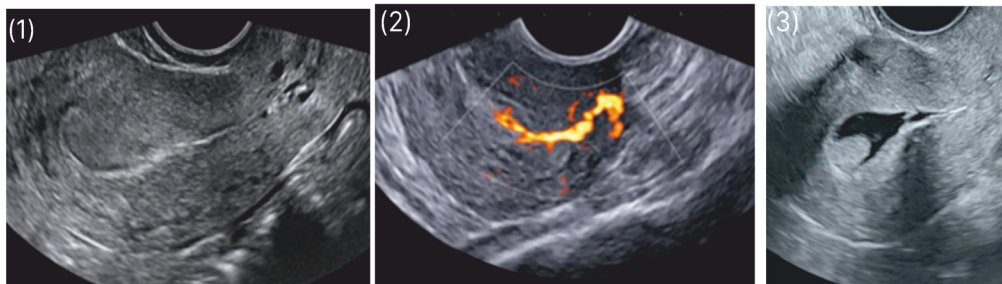
**Fibroid**

- Uterine Leiomyoma
- Fibroid on ultrasound: Hypoechoic mass
- Elderly female with pelvic popcorn calcification



**Endometrial Polyp**

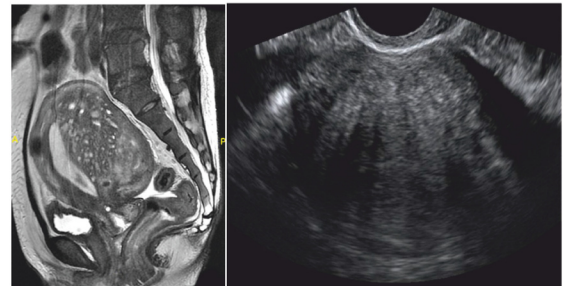
- Endometrial polyp appears: Hyperechoic
- Feeding vessel sign on Doppler → Endometrial polyp
- Saline infusion sonography helps differentiate a polyp from fibroid
  - Polyp lies within the endometrial cavity
  - Fibroid lies outside the endometrial cavity



**Adenomyosis**

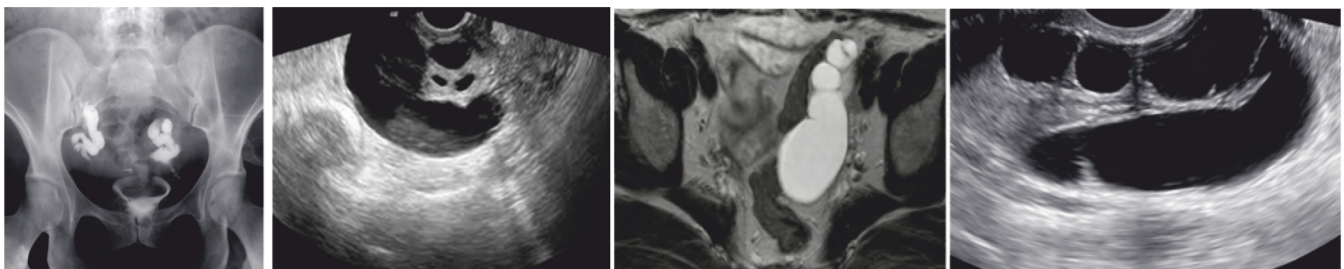
NEET PG 2025

- Adenomyosis: Endometrial glands infiltrating the myometrium
- MRI finding: Thickening of the junctional zone
- Myometrium shows salt and pepper appearance
- Ultrasound finding: Venetian blind sign



**Hydrosalpinx**

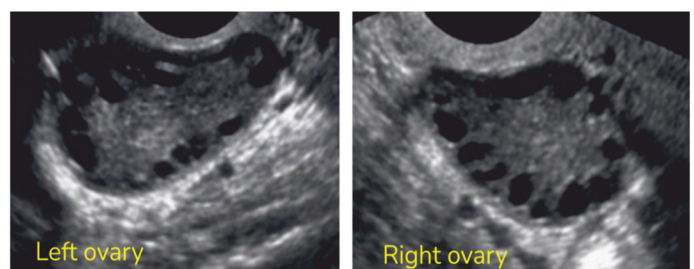
- Hydrosalpinx: Dilated fallopian tube with fluid
- Ultrasound: Dilated tubular structure with incomplete septations
- Characteristic sign: Cogwheel appearance
- Fluid appears black on ultrasound



**PCOS**

FMGE Jan 2025

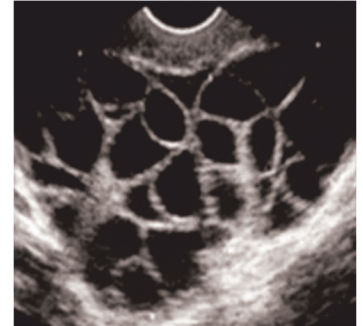- PCOS features :
  - Irregular cycles
  - Obesity
  - Hirsutism
  - Infertility
- Ovary in PCOS :



- Bulky ovary
- Increased stromal tissue
- Small peripheral follicles
- No dominant follicle
- Characteristic sign: String of pearls sign/ Necklace sign
- Follicles in PCOS: < 10 mm

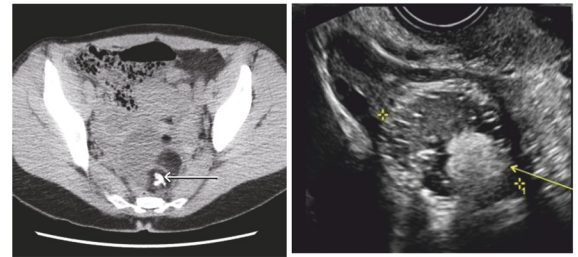
**OHSS**

- OHSS seen in infertility treatment or IVF
- Ovary in OHSS:
  - Large follicles
  - No stromal increase
- Similar appearance is seen in theca lutein cyst



**Ovarian Dermoid**

- Dermoid contains Fat and Calcification
- Fat on CT: negative HU value → dirty black
- Calcification appears white
- Ovarian dermoid findings:
  - Fat + calcification
  - Rokitansky protuberance
  - Dot and dash appearance due to hair

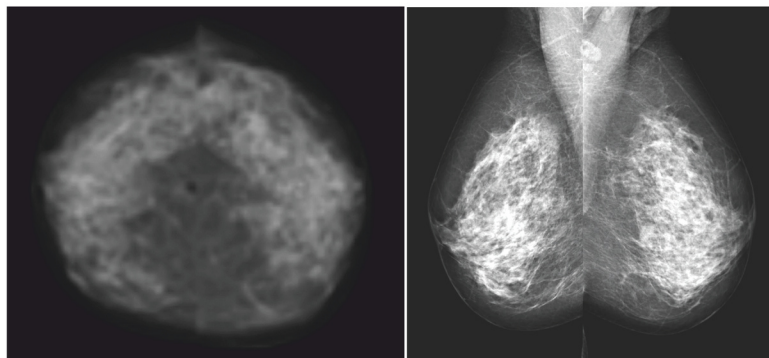
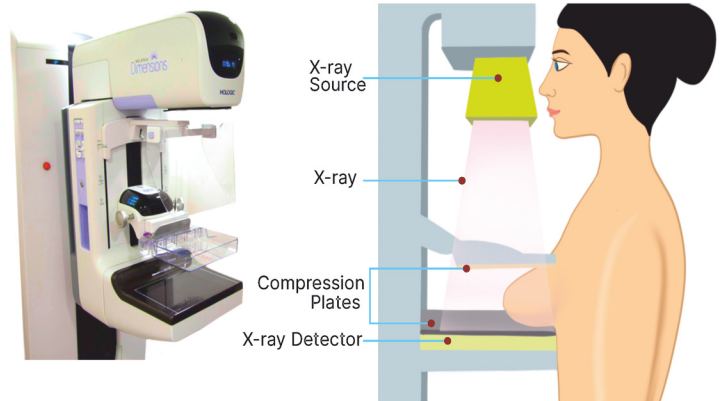


**BREAST IMAGING**

00:25:26

**Mammography**

- X-ray of the breast with compression
- Mammography has radiation
- Used for early detection of breast cancer
- Recommended after 40 years
- In a young female with breast lump: Ultrasound preferred → Dense breast makes mammography difficult
- Basic mammography views:
  - Craniocaudal view
  - Mediolateral oblique view



**Birads**

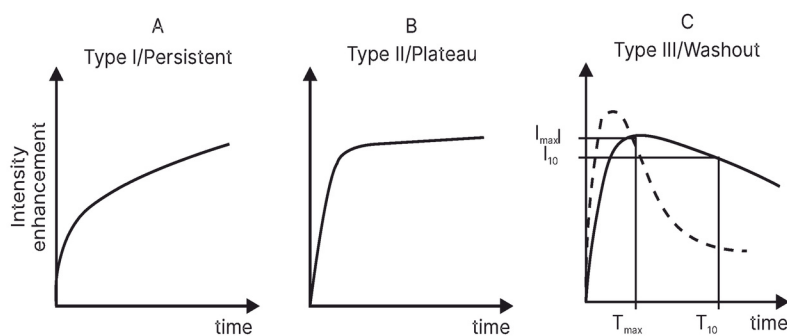
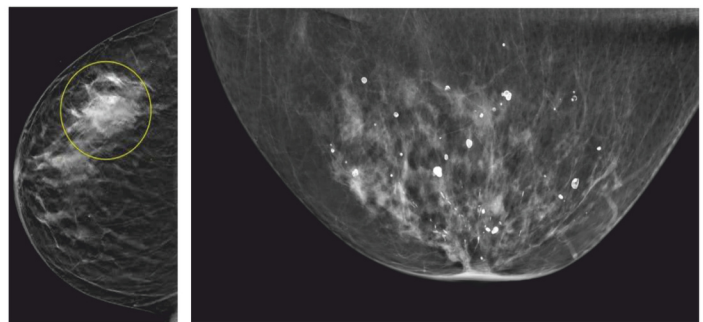
INICET May 2022

- Breast Imaging-Reporting and Data System

Category	Category 1	Management	Likelihood of Cancer
0- Assessment	Incomplete Assessment	Additional imaging required	Not applicable yet
1	Negative	Routine annual screening	No cancer detected
2	Benign	Routine annual screening	0%
3	Probably Benign	Follow-up scan after 6 months or earlier, as advised by your doctor	0% to 2%
4	Probably Malign	Breast tissue biopsy recommended by the doctor	4A - 2% to 10% 4B - 10% to 50% 4C - 50% to 95%
5	Malignant	Biopsy to be done essentially	>95%
6	Biopsy-Proven Malignancy	Further treatment evaluations will be done by the oncologist	Cancer already present

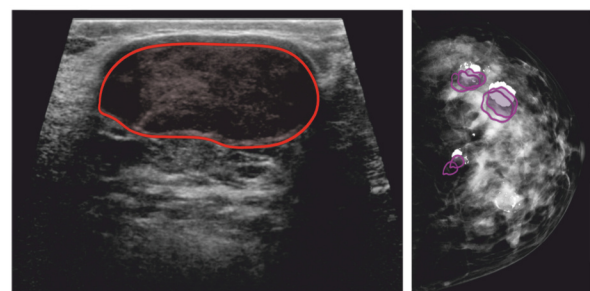
**Breast Cancer Imaging Features**

- Mammography findings suggestive of malignancy :
  - Spiculated mass
  - Dense mass
  - Microcalcification
- Ultrasound finding suggestive of malignancy:
  - Taller than wide lesion
- MRI finding suggestive of malignancy: Type 3 curve
  - Early wash in
  - Early wash out



**Fibroadenoma**

- Seen in young females
- Ultrasound appearance :
  - Hypoechoic lesion
  - Wider than tall
- Mammography finding: Popcorn calcification



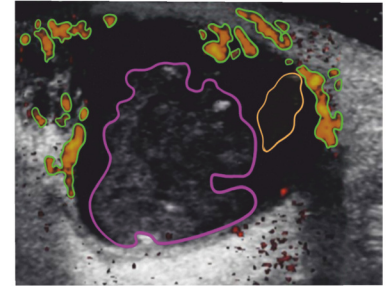
# Yourwish

## Important Information

- Popcorn calcification in lung: Pulmonary hamartoma
- Popcorn calcification in breast: Fibroadenoma

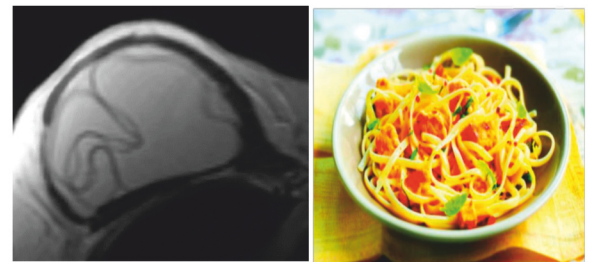
## Breast Abscess

- Classical history: Lactating female with breast pain and fever → Point tenderness present
- Investigation of choice: Ultrasound
- Mammography is not preferred
- Ultrasound findings :
  - Abscess cavity
  - Internal echoes due to pus
  - Peripheral vascularity



## Breast Implants

- Investigation of choice: MRI
- Mammography is not preferred
- Intracapsular rupture :
  - Rupture within capsule
  - Membranes seen within capsule → **Linguini sign**



## INVESTIGATION OF CHOICE

- Early pregnancy: TVS
- Contraindicated in pregnancy: CT
- Gold standard for uterine anomalies: Laparoscopy plus hysteroscopy
- Best non-invasive test for uterine anomalies: MRI
- Young female with breast lump: Ultrasound
- DCIS breast most sensitive investigation: MRI
- High-risk female breast screening: MRI
- Average-risk female breast screening: Mammography
- IOC for Breast implant: MRI

## Errors To Avoid

- HSG has radiation
- Mammography malignant calcification: Microcalcification
- Normal mammography: BIRADS 1
- BIRADS 4 and 5: biopsy required
- Posterior acoustic enhancement: Cystic lesion
- Septate uterus :
  - Smooth outer surface
  - Small angle of separation

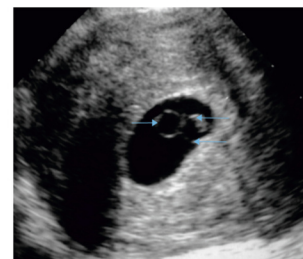
**PYQ**

00:33:01

Q. What is the cause of the double bleb sign observed during early pregnancy?

INI CET Nov 2021

- a. Twin pregnancy
- b. Amnion and chorion
- c. Yolk sac and amniotic sac
- d. Heterotopic pregnancy

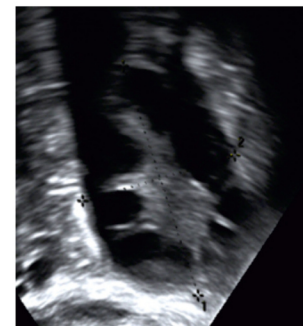

**Answer:** c. Yolk sac and amniotic sac

FMGE Jan 2025

Q. A female presents with hirsutism, delayed periods, and obesity. USG findings are given below. What is the likely diagnosis?

- a. PCOS
- b. POI
- c. OHSS
- d. Thecal luteal cyst

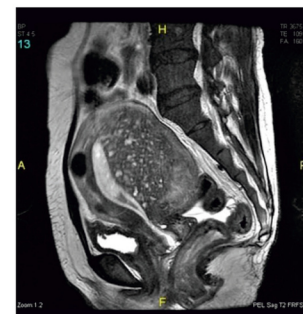


**Answer:** a. PCOS

Q. A 42-year-old woman presents with chronic lower abdominal pain and dysmenorrhea. MRI is as shown. What is the most likely diagnosis?

NEET PG 2022

- a. Uterine fibroid
- b. Adenomyosis
- c. Endometriosis
- d. Endometrial carcinoma

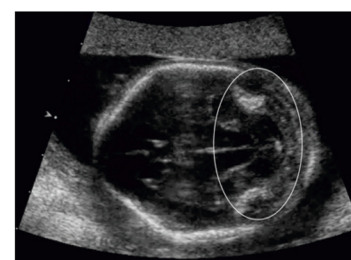


**Answer:** b. Adenomyosis

Q. Banana sign on USG is seen in which of the following conditions?

- a. Omphalocele
- b. Spinal bifida
- c. Anencephaly
- d. Encephalocele

INI CET Nov 2023

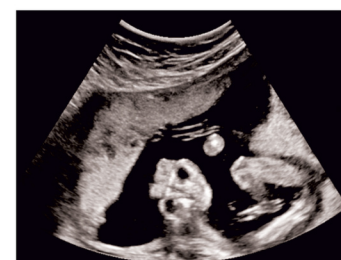

**Answer:** b. Spinal bifida

Q. What is the diagnosis?

NEET PG 2024

- a. Anencephaly
- b. Hydranencephaly
- c. Spina bifida
- d. Lissencephaly



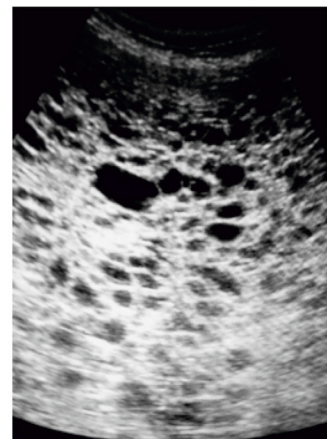
**Answer:** a. Anencephaly

Q. A primigravida in her 10th week of gestation presents with spotting. On examination, the uterus corresponds to 12 weeks. A transvaginal ultrasound scan is given below. What is your diagnosis?

INI CET July 2021

- a. Blighted ovum
- b. Missed abortion
- c. Ectopic pregnancy
- d. Hydatidiform mole

**Answer:** d. Hydatidiform mole





## 2. RADIOTHERAPY

### MECHANISM OF ACTION

- Radiotherapy uses radiation to treat conditions like cancer.
- Mechanism of action → DNA damage.
  - Acts directly or indirectly by producing free radicals

00:00:20

FMGE July 2023

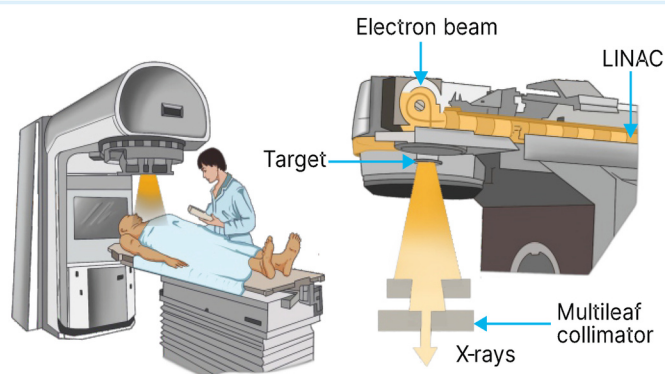
### TELETHERAPY VS BRACHYTHERAPY

FMGE June 2022

FMGE June 2024

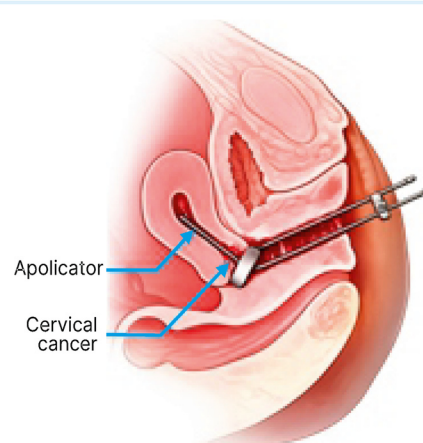
Feature	Teletherapy (External Beam RT)	Brachytherapy (Internal RT)
<b>Definition</b>	Radiation source outside the body	Radiation source placed inside/near the tumor
<b>Distance from tumor</b>	Far (external beam)	Very close / within tumor
<b>Radiation source</b>	LINAC (X-rays)- MC Cobalt-60 (Gamma rays)	Seeds/ implants: Ir-192, Cs-137, I-125, Pd-103
<b>Dose distribution</b>	Uniform, passes through normal tissue	High dose to tumor, rapid fall-off → spares normal tissue
<b>Precision</b>	Less precise compared to brachytherapy	Highly localized and precise
<b>Treatment area</b>	Large fields (regional treatment)	Localized small area
<b>Radiation exposure to staff</b>	None	Possible exposure (needs precautions)
<b>Common uses</b>	Brain, lung, breast, head & neck	Cervix, endometrium, prostate, oral cavity

- Brachy therapy follows the Inverse Square Law → Radiation ↓ by the inverse square of the distance.
  - Double the distance → Radiation becomes 1/4th.
  - Triple the distance → Radiation becomes 1/9th



#### LINAC Machine

- LINAC (Linear Accelerator) → Produces X-rays and electrons
- Used for teletherapy

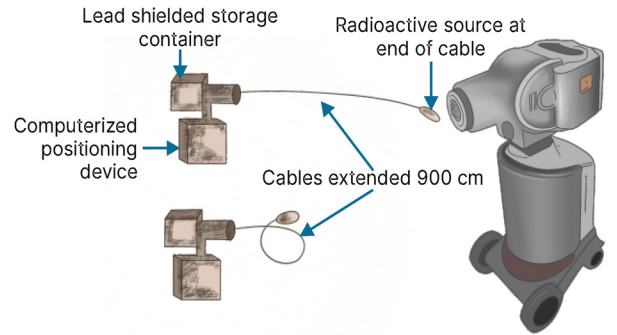


#### Brachytherapy

## Yourwish

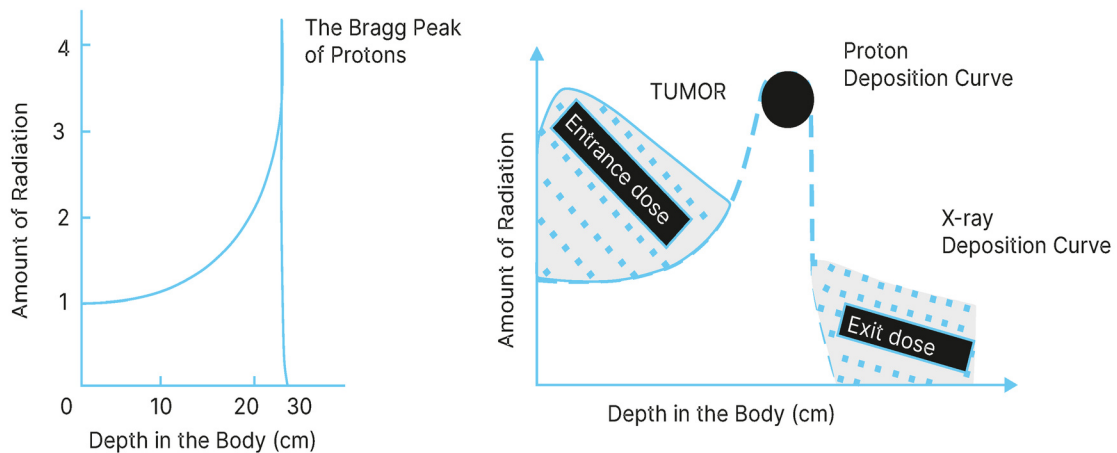
**After loading**

- Afterloading is used in brachytherapy. It is a robotic system that places seeds/implants into the patient to ↓ manual handling and ↓ staff exposure

**AGENTS**

00:04:50

- MC used overall: X-rays (LINAC)
- Gamma rays → Used in Cobalt-60
- Electrons.
- Proton beam
  - Advantage → Delivers highly targeted, pencil-beam-like therapy

**Bragg Peak**

- This sharp peak at the tumor site is called the Bragg Peak
- Seen with **protons**

**RADIO-ISOTOPES HALF LIFE**

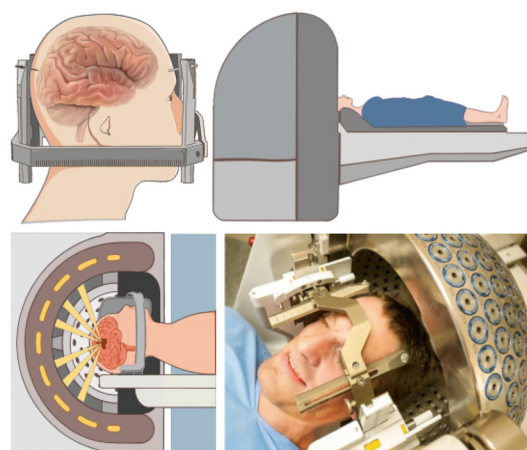
00:06:15

Isotope	Half life
Radium - 226	1600 years
Cesium - 137	30 years
Cobalt - 60	5.26 years
Iridium - 192	74.2 days
Iodine - 125	60.2 days

## GAMMA KNIFE

00:07:28

- Comes under Stereotactic Radiosurgery
- Invented by neurosurgeon Lars Leksell.
- Uses Gamma rays (Cobalt-60).
- Limited to brain pathologies only
- Uses multiple sources of focused gamma rays
- Treats → Pituitary macroadenoma, trigeminal neuralgia, AV malformations, vestibular schwannoma
  - Not used for Tuberculosis (requires anti-TB drugs)



### Gamma Knife Vs Cyber Knife

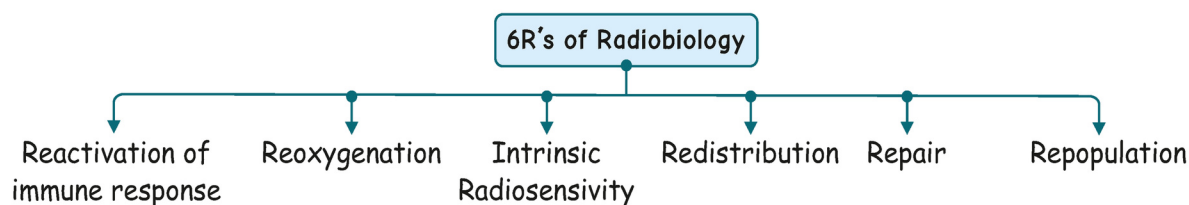
Feature	Gamma Knife	Cyber Knife
Radiation source	Cobalt-60 ( $\gamma$ -rays)	Linear accelerator (X-rays)
Machine design	Fixed helmet with multiple sources	Robotic arm (LINAC-based)
Immobilization	Rigid stereotactic frame (invasive)	Frameless (mask-based, non-invasive)
Target area	Brain only	Whole body (brain + spine + lung + prostate, etc.)
Typical use	Brain tumors, AVMs, and trigeminal neuralgia	Brain + extracranial tumors

FMGE Jan 2023

00:10:03

## RADIOBIOLOGY & FRACTIONATED RADIOTHERAPY

- "Radiobiology = interaction of radiation with biological systems and its effects."



R	Term	Key Concept (Exam-Oriented)
1	Repair	Repair of <b>sublethal DNA damage</b> (normal tissues > tumor)
2	Reoxygenation	Hypoxic tumor cells become oxygenated → ↑ radiosensitivity
3	Redistribution (Reassortment)	Cells move into <b>radiosensitive phases (G2/M)</b> of the cell cycle
4	Repopulation	Tumor cells proliferate during treatment → <b>treatment failure risk</b>
5	Radiosensitivity	Intrinsic sensitivity of cells (e.g., lymphocytes > neurons)
6	Reactivation of immune response	Radiation enhances <b>anti-tumor immunity</b>

## Fractionation Radiotherapy Comparison

Feature	Conventional Fractionation	Hypofractionation	Hyperfractionation	Accelerated Fractionation
Dose per fraction	1.8-2 Gy	High (>2 Gy)	Low ( $\approx$ 1-1.2 Gy)	$\sim$ 1.8-2 Gy (same as conventional)
No. of fractions/day	1	1 (sometimes $\leq$ 1)	2 or more/day	$\geq$ 2/day
Overall treatment time	Standard (5-7 weeks)	Reduced	Same or slightly prolonged	Reduced (shortened)
Total dose	Standard	Reduced or similar	Increased total dose possible	Same or slightly reduced

## RADIOSENSITIVE & RESISTANT

00:14:29

- Highly Radio-Sensitive Tumours (Mnemonic  $\rightarrow$  WELMS)
  - Wilms Tumor
  - Ewing Sarcoma
  - Lymphoma
  - Multiple Myeloma
  - Seminoma (and Dysgerminoma in females)
- Highly Radioresistant Tumors (Mnemonic  $\rightarrow$  MORPH)
  - Melanoma
  - Osteosarcoma
  - Renal Cell Carcinoma
  - Pancreatic Cancer
  - Hepatocellular Carcinoma
- Law of Bergonié: Tissues with actively dividing cells are more radiosensitive.
- Most radiosensitive tissue  $\rightarrow$  Bone marrow (due to continuous hematopoiesis).
- Most radioresistant tissue  $\rightarrow$  Nervous system / Neurons (do not regenerate or divide).
- Most radiosensitive organ overall  $\rightarrow$  Gonads (Testis and Ovary)
- Most radiosensitive blood cell  $\rightarrow$  Lymphocytes
- Most radioresistant blood cell  $\rightarrow$  Platelets

FMGE June 2021, 2024

## ERRORS TO AVOID

- LINAC produces - X-ray
- Iodine isotopes
  - Iodine-125  $\rightarrow$  Used as a brachytherapy implant/seed for prostate cancer
  - Iodine-131  $\rightarrow$  Radioisotopes in systemic therapy
- Bragg peak - seen with protons
- Most radiosensitive tissue and organs
  - Tissue  $\rightarrow$  Bone marrow
  - Organ overall  $\rightarrow$  Gonads (Testis and Ovary)

## PYQs

Q. What is the most radiosensitive tissue in our body?

FMGE June 2021

- a. Skin
- b. Muscles
- c. Bone marrow
- d. Nervous tissue

**Ans: c. Bone marrow**

Q. Which among the following is most radiosensitive?

FMGE June 2024

- a. Testis
- b. Bone
- c. Nerve
- d. Muscle

**Ans: a. Testis**

Q. What is the name of the radiotherapy treatment given to a cancer patient that involves administering a dose of 1.8 to 2 Gy once daily for 5 days per week over a period of 6 to 8 weeks?

FMGE Jan 2023

- a. Regular Fractionated radiotherapy
- b. Hyperfractionated radiotherapy
- c. Accelerated fractionation radiotherapy
- d. Brachytherapy

**Ans: a. Regular Fractionated radiotherapy**

Q. Which among the following radioactive isotopes is not employed in brachytherapy?

FMGE June 2022

- a. Iodine-125
- b. Iodine-131
- c. Cobalt-60
- d. Iridium-192

**Ans: b. Iodine-131**

- Iodine-125: Used in prostate cancer
- PSMA-positive prostate cancer
  - Uses Pluvicto
  - Contains Lutetium

Q. Radioactive isotope used for teletherapy?

FMGE June 2024

- a. Iridium-192
- b. Iodine-125
- c. Cobalt-60
- d. Iodine-131

**Ans: c. Cobalt-60**

## Yourwish

**Q.** What statement accurately describes radiotherapy?

FMGE July 2023

- a. Intensity is inversely proportional to the square of the distance
- b. Vomiting is a late adverse reaction
- c. Rapidly proliferating cells are most radioresistant
- d. All the adverse effects are reversible

**Ans:** a. Intensity is inversely proportional to the square of the distance