PREP XI RR

STUDY NOTES

ORTHOPAEDICS

14
VIDEOS

165
PAGES

PREMIUM STUDY MATERIAL

PREP XI RR

Table of Contents follows on next page

TABLE OF CONTENTS

Orthopaedics

#	Topic / Video Name	Pages
	RR Reignite	
1	Introduction to Orthopedics/ Typical & Atypical Fractures	3 – 6
2	Special X-Ray Views in Ortho	7 – 13
3	Tuberculosis of Bone	14 – 23
4	Osteomyelitis/ Osteochondritis/ Avascular Necrosis	24 – 36
5	Upper Limb Trauma	37 – 62
6	Lower Limb Trauma	63 – 81
7	Malunion & Open Fractures	82 – 85
8	ARDS & Volkmanns Ischemia	86 – 89
9	Bone Tumor	90 – 101
10	Peripheral Nerve Injury	102 – 106
11	Other Nerve Injuries	107 – 117
12	Miscellaneous Topics Part 1	118 – 132
13	Miscellaneous Topics Part 2	133 – 156
14	Miscellaneous Topics Part 3	157 – 167

1. INTRODUCTION TO ORTHOPEDICS TYPICAL & ATYPICAL FRACTURES

BIG QUESTION 1: What is orthopedics? What are the classifications of fractures, and what are the stages of fracture healing?

Broad Answer: Orthopedics is the branch of medicine concerned with the prevention, diagnosis, and treatment of musculoskeletal disorders. Fractures are classified by type, site, and etiology, and they heal through inflammatory, reparative, and remodeling stages.

DETAILED QUESTIONS

Q1.1: Who coined the term 'orthopedics'?

Answer:

- Orthopedics comes from the Greek words "ortho" (making straight) and "paedics" (child).
- It means "making bent bones of a child."
- The term was coined by **Sir Nicholas Andry**, who is known as the **Father of Orthopedics**.

Q1.2: What is a fracture?

Answer: A fracture is a **breach in the continuity of a bone, periosteum, or both.**

Q1.3: What are the key differences between typical and atypical fractures?

Answer:

Typical Fractures	Atypical fractures
• Pain and tenderness • Abnormal mobility • Loss of transmitted movements • Deformity • Types: o Transverse fracture o Oblique fracture o Spiral (twisted) o Segmental fracture o Comminuted fracture 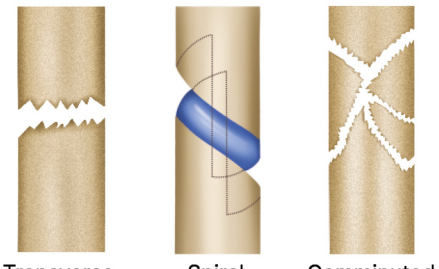 Transverse Spiral Comminuted	• The fracture does not exhibit typical features and can be diagnosed only with the help of radiological imaging. • Types: o Greenstick fracture- only seen in children before epiphysial closure. Most commonly seen in forearm bone- fall on outstretched hand. Treatment- break and open the cortex at the same level then apply cast for 4-6 weeks. Excellent prognosis o Hairline/march/ stress/ fatigue fracture- most commonly on the neck of the second metatarsal. Treatment: bed rest for 3 weeks. No cast is needed. o Torus/ buckling fracture- most commonly in weight-bearing bone. Treatment- cast(conservative) o Avulsion Fracture- the most common site is tibial tuberosity. Treatment- screw fixation. o Wedge compression fracture: The most common site is the thoracic vertebra. (T 12 fracture). Pathological fracture (osteoporosis>malignancies)


Oblique


Segmental

- Impacted fracture- most common site is neck of femur. Can also be seen in Pilon fracture. Treatment- disimpaction done surgically.

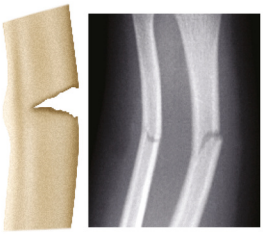
Greenstick Fracture


Hairline Fracture

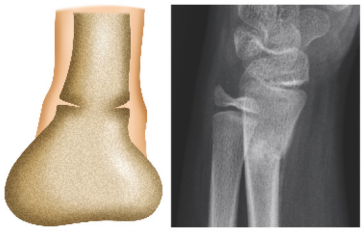
Torus/Buckling Fracture

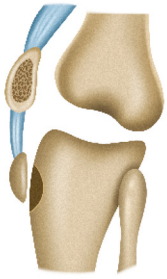
Avulsion Fracture

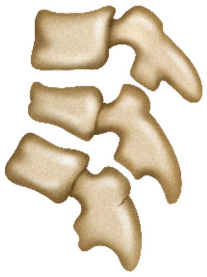
Wedge compression Fracture


Impacted Fracture

Q1.4: What are the stages of fracture union/healing?

Answer:

- The stages are:
  - Stage of impaction
  - Stage of induction
  - Stage of hematoma formation
  - Stage of callus formation
  - Stage of consolidation
  - Remodeling

Q1.5: How does the prognosis of a fracture vary with the type of fracture?

Answer:

- The prognosis is best for fractures with the highest raw surface area for healing, which are **oblique**.
- **The prognosis decreases in the following order:** oblique (best) > transverse > spiral > comminuted > segmental (worst).

BIG QUESTION 2: What are the complications of fractures? Describe their clinical features, diagnosis, and management.

Broad Answer:

- Complications of fractures may be early (shock, infection, fat embolism) or late (malunion, nonunion, joint stiffness, myositis ossificans, osteoarthritis).
- **Myositis ossificans** is a late complication where heterotopic bone forms within muscle, leading to pain and restricted joint movement.

DETAILED QUESTIONS

YOURWISH

Q2.1: What is Myositis ossificans, and what is its most common cause?

Answer:

- AKA heterotropic ossification
- Myositis ossificans is **ectopic ossification**, or bone formation in an abnormal site such as muscle, tendon, fascia, or periosteum.
- Ossification is typically membranous or endochondral.
- The most common cause is an **ill-advised massage of a joint**.

Q2.2: What are the common structures and sites involved in myositis ossificans?

Answer:

- Four Structures Involved
  - Muscle
  - Tendon
  - Fascia
  - Periosteum
- Common Sites
  - Elbow joint: Brachialis muscle
  - Hip joint
  - Shoulder joint
  - Knee joint: Rare

Q2.3: What are the clinical features of myositis ossificans?

Answer:

- Pain
- Warmth due to excessive vascularity.
- Glossy skin
- A bony, hard mass was felt on palpation.
- Restriction of joint movement.

Q2.4: What are the differential diagnoses of myositis ossificans?

Answer:

Differential Diagnosis: Osteogenic sarcoma

- It is difficult to differentiate myositis ossificans and osteogenic sarcoma clinically and radiologically.
- The presence of a bony, hard mass indicates possible myositis ossificans or osteogenic sarcoma.
- Medical history assists in differentiating the two.
- If a patient had a violent massage from a traditional bone setter and developed the related clinical features, a diagnosis of myositis ossificans is made.

Q2.5: What are the radiological findings for myositis ossificans?

Answer:

- On X-ray, both myositis ossificans and osteogenic sarcoma show a **periosteal reaction**, where the periosteum appears lifted.
  - Codman's triangle is observed in osteogenic sarcoma.



Q2.6: What are the histological findings of myositis ossificans?

Answer:

- The definitive diagnosis is by **biopsy**, which shows **Ackermann's Zone phenomenon.**
  - o A biopsy of a mass positive for myositis ossificans shows a three-layered structure under the microscope.
  - o Cell and tissue types appear segregated into 3 zones.
  - o **3 zones :**
    - → Innermost cellular zone
    - → Middle fibroblastic tissue
    - → Outermost mature, well-oriented bone

Q2.7: What are the treatment options for myositis ossificans?

Answer:

- The **first-line treatment** is **rest and immobilization for at least 6 weeks.**
- The drug of choice is **Indomethacin.**
- **Excision** is performed if the mass restricts joint movement, but only after it has matured (about 1.5 years).
- **Radiotherapy** may be performed after excision to remove any remaining mass and prevent recurrence.

Q2.8: What are the two main categories of myositis ossificans?

Answer: The two categories are **myositis ossificans traumatica** (acquired) and **myositis ossificans progressiva** (congenital).

Q2.9: What is Myositis Ossificans Progressiva, and what are its key features?

Answer:

- AKA Fibrodysplasia Ossificans Progressiva
- It is a **congenital condition** that presents around the age of **5-15 years.**
- It usually starts in the **trapezius and latissimus dorsi** muscles and then progresses to other joints.



Q2.10: What are the common associations of Myositis Ossificans Progressiva?

Answer:

- **Macrodactyly** (short fingers)
- **Klippel-Feil syndrome** (congenitally fused cervical vertebrae).
  - o Also associated with Sprengel's shoulder.

Q2.11: What is the prognosis for a patient with Myositis Ossificans Progressiva?

Answer:

- There is **no cure.**
- The patient eventually dies from an **intercurrent infection** or **respiratory failure** because the disease affects the joints of the rib cage.
- The disease causes morbidity and is not traumatic.
- Bisphosphonates may retard the regeneration of bony bars after excision.

2. SPECIAL X-RAY VIEWS IN ORTHO

BIG QUESTION 1: What are the special X-ray views used to evaluate shoulder injuries, and what is the clinical significance of each?

Broad Answer

- The 45° Lordotic View is used to visualize the clavicle with a cephalic tilt, helping detect clavicle fractures.
- The Serendipity (Rockwood) View assesses the sternoclavicular joint for dislocations using a supine position with a 45-60° beam angle.
- Zanca's View highlights the acromioclavicular joint, useful for detecting AC joint dislocations and arthritis.
- The WestPoint View, with the patient prone and arm abducted, visualizes the anterior glenoid rim to detect Bankart lesions in shoulder instability.
- The Axial View evaluates shoulder dislocations and proximal humerus pathology by showing the glenohumeral joint articulation clearly.

DETAILED QUESTIONS

Q1.1 Describe 45° Lordotic View (Cephalic Tilt View)

Answer:

- Specific view for visualizing the clavicle
- The patient is in a standing position with a 45° tilt.

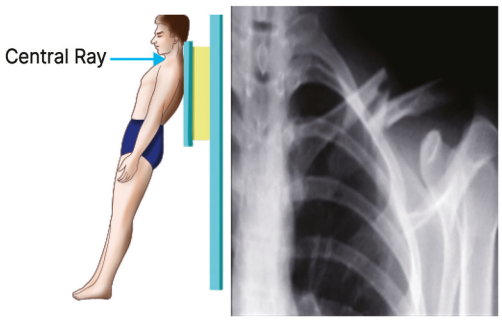

Q1.2 Explain Serendipity View

Answer:

- Also called Rockwood View
- Specific view for visualizing the sternoclavicular joint
- The patient lies in a supine position
  - Ray is passed at 45-60°

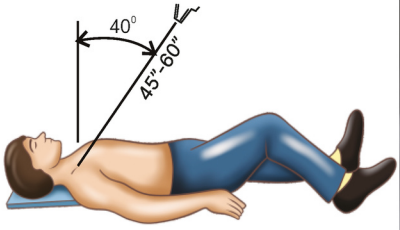



Q1.3 What is Zanca's View in shoulder radiography?

Answer:

- Zanca's View
- It is a standing radiograph of the Acromioclavicular joint
- The X-ray beam is directed 10 to 15° Cephalad
- Demonstrates the AC joint and distal clavicle
  - AC joint dislocation
  - AC joint arthritis
  - Distal clavicular osteolysis
  - Measuring the coracoclavicular distance

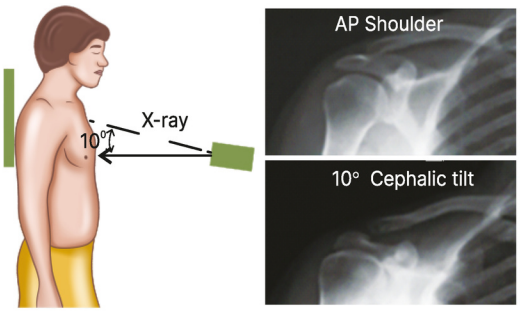

YOURWISH

Q1.4 Outline the positioning and clinical utility of the WestPoint View in detecting Bankart's lesions.

Answer: Specific view for demonstrating the Anterior aspect of the Glenoid Rim for detecting Bankart's lesion

The patient is prone on an X-ray table

↓

Abduct the affected arm away from the body by 90°

↓

The elbow flexed to allow the forearm to hang freely over the side of the table

↓

Rotate the head away from the affected side

↓

Place the cassette against the superior surface of the affected shoulder

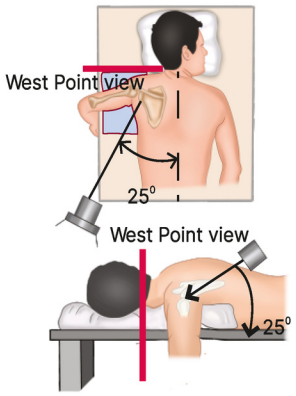

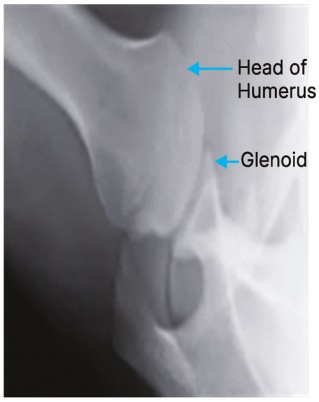



Q1.5 What is the Axial View in shoulder radiography, and what clinical conditions does it help assess?

Answer:

- It is an appropriate projection to assess
  - o Suspected Shoulder Dislocations
  - o Proximal Humerus Pathology
  - o GlenoHumeral Articular Surface Abnormalities

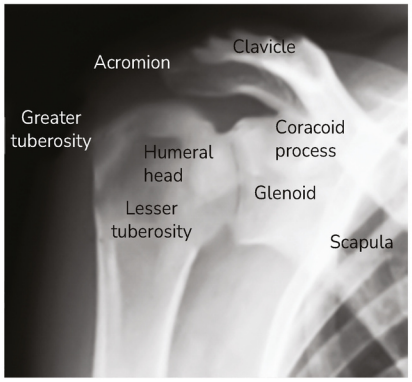

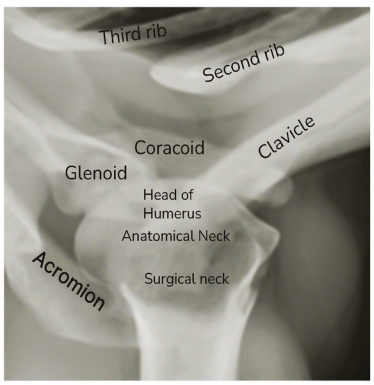

Q1.6 What is the Velpeau View in shoulder radiography, and when is it used?

Answer:

- In Velpeau View, the beam is directed from superior to inferior through the shoulder with the patient's arm in a sling & the patient leaning back.
- It is important to rule out glenohumeral dislocation.

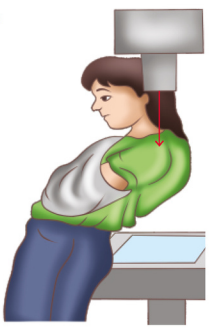

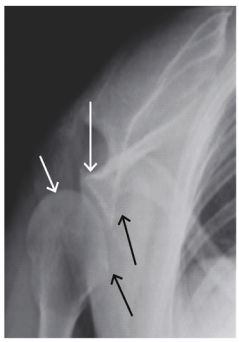

YOURWISH

Q1.7 What is another name for the Shoulder AP Glenoid view?

Answer: Grashey's view or True AP view.

Q1.8 What is Grashey's View used to assess?

Answer:

- The integrity of the glenohumeral joint
- The articular surface of the humerus
- Joint space for subtle fractures, such as a Bankart's lesion
- Post Dislocation-Relocation,
- Proximal migration of the humerus

Q1.9 How is the patient positioned to obtain Grashey's view?

Answer:

- Grashey's view (AP oblique) is obtained with the patient rotated 35-45°, so the x-ray beam is parallel to the articular surface of the glenoid.

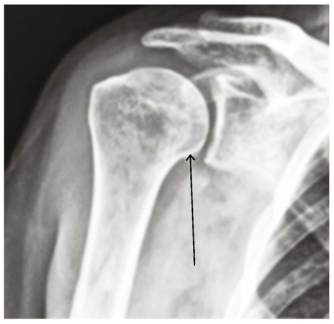

Q1.10 Describe the Scapular Y view and its significance in shoulder imaging.

Answer:

- The Scapular Y view is shot at an angle that separates the scapula and humerus from the ribs.
- It is essentially a true lateral view of the scapula.
- The scapula looks like a Y when viewed laterally.
- Laterally, the body of the scapula, acromion, and coracoid process converge at the glenoid.

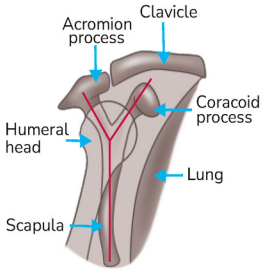



Q1.11 What is the purpose of the Stryker's Notch view in shoulder imaging?

Answer: The Stryker notch view is a specialized projection of the shoulder aimed at assessing the posterior humerus.





Q1.12 What pathologies does Stryker's Notch view in shoulder imaging help to detect?

Answer:

- This is particularly useful in demonstrating
  - Hill-Sachs deformities
  - Gleno-Humeral dislocation

BIG QUESTION 2: What are the indications and technique for Coyle's view of the elbow, and how is the scaphoid view performed?

Broad Answer:

- The Coyle's view, also known as the trauma oblique view of the elbow, is performed with the patient seated, elbow flexed at 90°, palm facing down, and the X-ray tube angled 45° lateromedially.
- It is primarily used to detect radial head fractures, elbow dislocations, and to visualize the capitellum of the distal humerus.
- he scaphoid view involves positioning the wrist in ulnar deviation to eliminate bony overlap and enable clear visualization of the scaphoid bone. This is usually performed as a PA projection, but can also be considered an AP view.
- Both views enhance the detection of subtle fractures and joint abnormalities in the wrist and elbow.

DETAILED QUESTIONS

Q2.1 What is Coyle's view of the elbow, and what are its clinical indications?

Answer:





- Also called the Trauma Oblique View of the Elbow
- In the Coyle method, the sitting axial lateromedial projection, where the patient is seated, the elbow is flexed at 90°, palmar side downwards, with the X-ray tube at a 45° angle projection lateromedially.
- The Coyle's view is performed for
  - Suspected Radial Head Fracture
  - Elbow Dislocation
  - Visualise Capitellum of the Distal Humerus

Q2.2 Explain the positioning and purpose of the Scaphoid View in wrist radiography.

Answer:

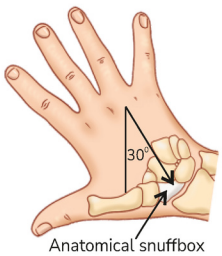



- The view is performed with the wrist in ulnar deviation to free the scaphoid from bony superimposition.
- Although typically performed as a PA projection, the view may also be described as an AP view.

Q2.3 Explain Carpal Tunnel View

Answer:

- It is used to obtain an axial view of the carpal canal, with particular attention to the hook of the hamate, pisiform bone, and trapezium fractures.
- The hand is maximally dorsiflexed using the opposite hand or a strap

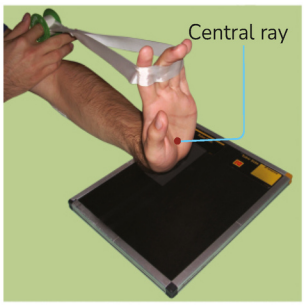

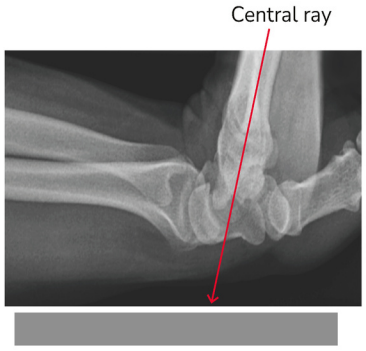

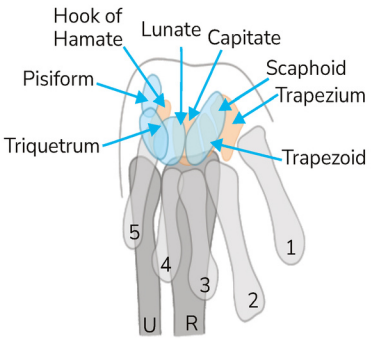



Q2.4 What is Brewerton's View and what is its clinical significance?

Answer:

- The metacarpophalangeal joint is flexed to 65°, with the dorsum of the proximal phalanx flat against the radiograph cassette.
- The beam is angled 15° from ulnar to radial to profile the collateral recesses.
- It is helpful to visualize a collateral ligament Avulsion Fracture.



Q2.5 What is Robert's View in radiology, and what conditions is it used to evaluate?

Answer:

- A true AP view of the thumb taken with the wrist in maximal pronation, with the dorsum of the thumb parallel to the table. The beam is centered on the trapeziometacarpal joint.
- Used to assess the base of the 1st Metacarpal fracture & Trapeziometacarpal arthritis
- If, instead of maximum pronation, the wrist is pronated to 30°, it is called Bett's view.

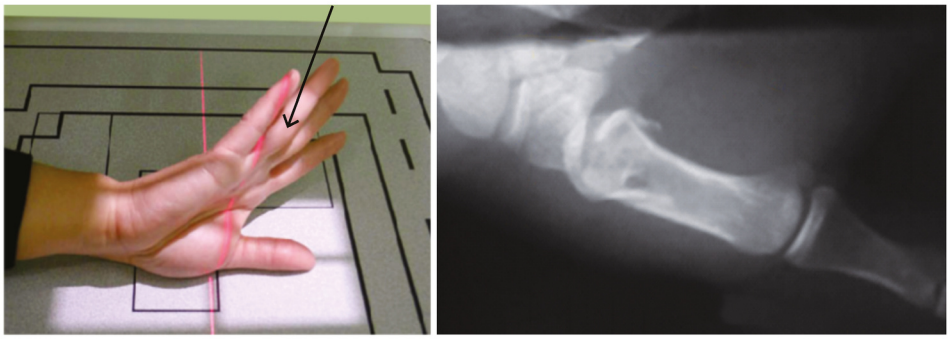

Q2.6 What is Dunn's View?

Answer: It is a radiographic projection of the hip that demonstrates and examines the Hip joint, Femoral head, and Acetabulum, particularly the relationship between the Femoral Head and Acetabulum.

Q2.7 What are the indications for Dunn's View?

Answer:



Q2.8 What is the Positioning for Dunn's View?

Answer:

- Patient is supine, hips flexed to 90°, and abducted to 20°
- Beam-focused midpoint between the pubic symphysis & ASIS

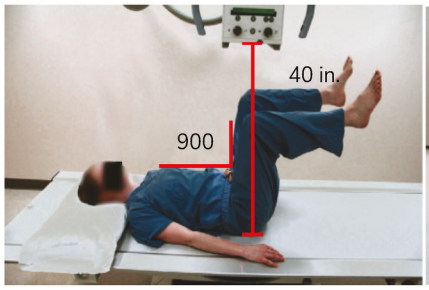

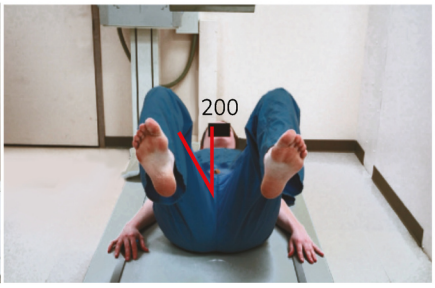

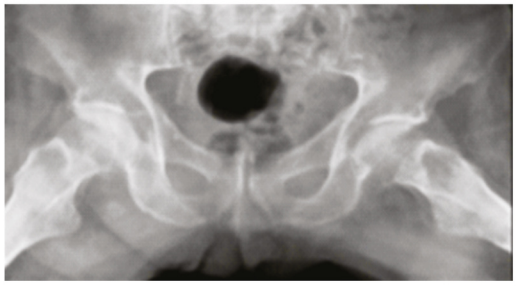

Q2.9 Describe Frog Leg Lateral View

Answer:

- In the Frog-leg view, the knee joint is flexed 30°-40° in a supine position, while the hip is externally rotated by 45° so that the image is taken toward the middle of the line connecting the upper symphysis pubis and the anterior-superior iliac spine.
- Used to demonstrate developmental dysplasia of the hip.


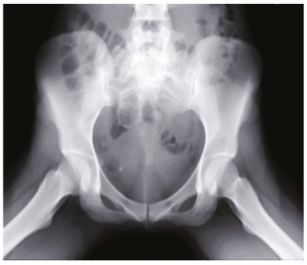

Q2.10 Describe Danelius-Miller's View

Answer:

- An axiolateral projection of the acetabulum and the proximal femur to include the head, neck, and trochanters.
- This view is specifically done to visualize the Neck.





Q2.11 What is the Clements-Nakayama View, and when is it used in hip imaging?

Answer:

- Modified Axiolateral View of the Hip
- The Clements-Nakayama view of the Proximal Femur is a highly specialized lateral projection utilized on patients with Bilateral Femoral Fractures or patients unable to mobilize due to postoperative requirements.

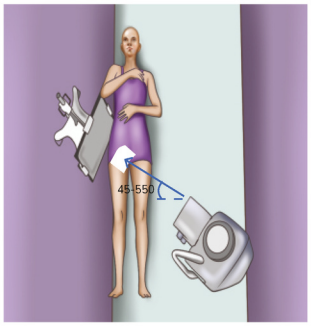


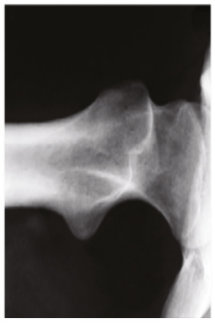

Q2.12 Explain Skyline Laurin or Axial View, or Merchant View

Answer:

YOURWISH

- The knee Skyline Laurin view is an inferior-superior projection of the patella.
  - o Knee is flexed to 45°

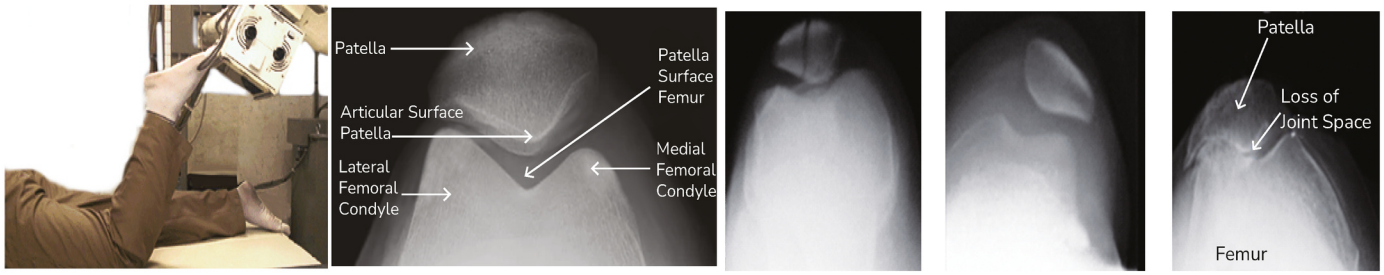

Q2.13 What are the indications for Skyline Laurin or Axial View, or Merchant View?

Answer:

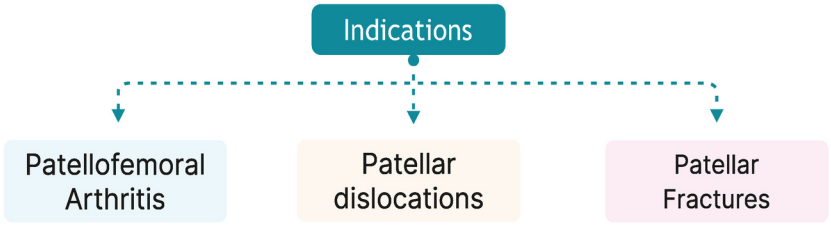

Q2.14 Describe the Sunrise View in knee radiography and its clinical significance.

Answer:

- Here, the Patella appears to be rising over the horizon
- The radiograph is taken with the X-ray beam tangential to the patella, parallel to the long axis of the lower extremity

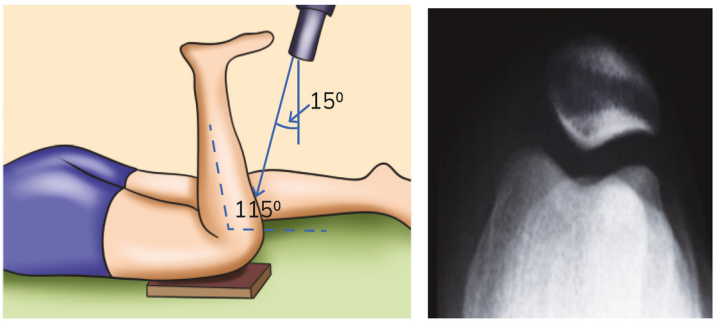

Q2.15 Compare and contrast the Sunrise View with the Merchant View for knee imaging.

Answer: In the Merchant view, the Knees are bent at 45 degrees, and the muscles are relaxed, allowing the Patella to settle into the Trochlear groove, but in the sunrise view, the Knees are at maximum flexion (115°)

3. TUBERCULOSIS OF BONE

BIG QUESTION 1: What are the causes, presentation, diagnosis, and key features of skeletal tuberculosis?

Broad Answer:

- Skeletal tuberculosis, most common in young adults, is usually caused by the human-type tubercle bacilli in India and spreads hematogenously, often from pulmonary TB (seen in 99% of cases).
- It first involves the epiphyseal cartilage and presents in two forms: caseating type in children and proliferative dry type in adults.
- Characteristic symptoms include 'night cries' due to pain from synovial stretching.
- Radiographic findings include soft tissue swelling, periarticular osteoporosis, joint space narrowing, and Phemister's triad.
- Diagnosis is confirmed by synovial biopsy, and healing occurs by fibrosis leading to fibrous ankylosis.

DETAILED QUESTIONS

Q1.1 What is another name for tuberculosis of bone?
Answer: Skeletal tuberculosis.

Q1.2 In which age group does skeletal TB have the highest incidence?
Answer: Young adults.

Q1.3 Is skeletal TB common or uncommon in old age?
Answer: Uncommon

Q1.4 What is the main causative organism of skeletal TB in India?
Answer: Human-type tubercle bacilli.

Q1.5 Which type of tubercle bacilli spreads via raw milk?
Answer: Bovine type.

Q1.6 What is the most common mode of spread of skeletal TB?
Answer: Hematogenous spread.

Q1.7 What percentage of skeletal TB patients have pulmonary TB?
Answer: Approximately 99%

Q1.8 Which cartilage is first affected in skeletal TB?
Answer: Epiphyseal cartilage

Q1.9 Name the two pathological types of skeletal TB and their common age groups.
Answer:

- Caseating type - Children
- Proliferating type (caries sicca, dry type) - Adults

Q1.10 What is the only confirmatory diagnostic method for skeletal TB?

Answer: Synovial biopsy.

Q1.11 Is epiphyseal cartilage a barrier to infection in skeletal TB?

Answer: No, the epiphyseal cartilage is not a barrier to infection in skeletal TB.

Q1.12 Name two sites where infection can persist as tubercular chronic osteomyelitis.

Answer:

- Vertebrae
- Greater trochanter of the femur

Q1.13 How does healing of skeletal TB usually occur?

Answer: By fibrosis and incomplete ankylosis (fibrous ankylosis).

Q1.14. What symptom is characteristic of skeletal TB during nighttime?

Answer: Night cries.

Q1.15. Name another bone condition where night cries are seen.

Answer: Osteoid osteoma.

Q1.16. Why do night cries occur in skeletal TB?

Answer: Because muscle relaxation at night stretches the synovium (rich in nerve endings), causing pain.

Q1.17. What are the two differential diagnoses for night cries given in the text?

Answer:

- Skeletal tuberculosis
- Osteoid osteoma

Q1.18 What are the X-Ray Findings of Skeletal TB?

Answer:

- First and characteristic radiological signs: soft tissue swelling and periarticular osteoporosis.
- Washed-out appearance: Hazy nature of articular margins and bony cortex.
- Narrowing of the articular space.
- Enlargement of epiphysis.
- Phemister's triad
  - Periarticular osteoporosis
  - Peripherally located bony lesions/ erosions
  - Joint space narrowing
- Epiphysis enlarged.
- Sub-articular bone erosion on both sides of the joint

Q1.19 Describe the first-line therapy for skeletal TB.

Answer:

YOURWISH

1st line therapy (HRZES)	
Drugs	**Description**
Isoniazid (INH) (H)	• Bacteriostatic • **Dose:** 5 mg/kg/day • It inhibits cell wall synthesis. • **Idiosyncratic complications:** Hepatotoxicity and Peripheral neuropathy
Rifampicin (R)	• Bactericidal • **Dose:** 10 mg/kg/day • **Complications:** Hepatitis • Red color urine (not a medical concern)
Pyrazinamide (Z)	• Bactericidal • **Dose:** 25 mg/kg/day • **Complications:** GI upset
Ethambutol (E)	• Bacteriostatic • Dose,15 mg/kg/day • **Complications:** Subacute myelo-optic neuropathy (SMON)
Streptomycin (S)	• Bactericidal • 15 mg/kg/day • **Complications:** Ototoxicity, Nephrotoxicity, Neuromuscular blockade

Q1.20 Describe the 2nd line therapy for skeletal TB

Answer:

2nd line therapy	
Drugs	**Description**
Thioacetazone	• Bacteriostatic • 2.5 mg/kg/day
Para amino salicylic acid (PAS)	• Bacteriostatic • 10 gm/day
Ethionamide	• Bacteriostatic • 15 mg/kg/day
Cycloserine	• Bacteriostatic • 1 gm/day • **Complication:** Psychosis

Q1.21 What is the WHO treatment recommendation for skeletal TB?

Answer: For skeletal TB, the WHO recommends Category 1 treatment: 2 months of HRZE, followed by 4 months of HR.

BIG QUESTION 2: Describe the core features, spread, and common sites of involvement in spinal tuberculosis (Pott's spine).

Broad Answer:

- Pott's spine, described by Sir Percival Pott, is the most common form of skeletal tuberculosis, with thoraco-lumbar vertebrae (D12, L1) most frequently affected.

YOURWISH

YOURWISH

- It usually occurs in the first three decades and results from hematogenous spread from a primary pulmonary focus via the arterial arcade of subchondral bone or Batson's valveless venous plexus.
- The infection typically starts in the anteroinferior vertebral body, spreading to the disc and adjacent vertebrae, producing para-discal, anterior, or central lesions.
- Clinically, it presents with progressive bone destruction, vertebral collapse, kyphosis, cold abscess, or Pott's paraplegia. Posterior element involvement is rare.

DETAILED QUESTIONS

Q2.1 Who described Pott's spine?
Answer: Sir Percival Pott.

Q2.2. What is the most common site of skeletal tuberculosis?
Answer: Spine.

Q2.3. Which part of the spine is most commonly affected in spinal TB?
Answer: Thoraco-lumbar region (D12 followed by L1).

Q2.4. In which age group is spinal TB most common?
Answer: First three decades of life.

Q2.5. List three major manifestations of spinal TB.
Answer:

- Progressive bone destruction with vertebral collapse
- Kyphosis
- Cold abscess (no signs of inflammation)

PYQ: INICET 2022

Q2.6. Spinal TB is usually secondary to which primary site?
Answer: Pulmonary TB.

Q2.7. How does spinal TB spread to the spine from the lungs?
Answer: Hematogenous spread (arterial or venous).

Q2.8. Which arterial structure facilitates the spread of infection to the para-discal region?
Answer: Arterial arcade of subchondral regions.

Q2.9. What is Batson's paravertebral venous plexus?
Answer: A valveless plexus that allows spread of infection to the central vertebral body.

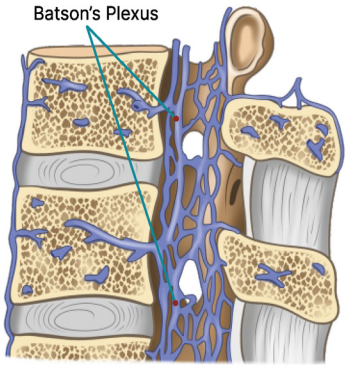

Q2.10. Where does spinal TB usually start in the vertebra?

Answer: Anteroinferior aspect of the vertebral body (via Batson's venous plexus).

Q2.11. How does infection spread to the disc in spinal TB?

Answer: From the anteroinferior vertebral body to the central part of the disc.

Q2.12. What are the commonly involved lesion types in spinal TB?

Answer: Para-discal, anterior, and central lesions.

Q2.13. What is the rarest site of involvement in spinal TB?

Answer: Posterior elements (pedicles, transverse processes).

Q2.14 What are the clinical manifestations of Pott's spine?

Answer:

- Painful stiff back
- Systemic symptoms may not be present.
- Classical night cries are seen.
- Primary deformity: loss of normal cervical and lumbar lordosis due to paraspinal muscle spasm.
- Secondary deformity could be GIBBUS.
  - Upon palpation of the spine bony protrusion can be seen
  - Due to damage to the vertebral body, crowding of more than one spinous process occurs, which leads to the protrusion known as gibbus.
  - GIBBUS is seen in the thoracic spine predominantly.
- Spastic type of Paraplegia
  - It is mostly seen in the intervertebral disc space of the thoracic spine.

Q2.15 What is the earliest X-ray sign of spinal TB?

Answer: Radiolucencies with loss of definition of plate margins (washed-out appearance).

Q2.16 What is the most common lesion site in spinal TB?

Answer: Paradiscal region.

Q2.17 Name the four common lesion sites in spinal TB.

Answer:

1. Paradiscal (most common)
2. Central body of a vertebra
3. Anterior portion of vertebra
4. Posterior elements (rare – pedicles, transverse process, spinous process)

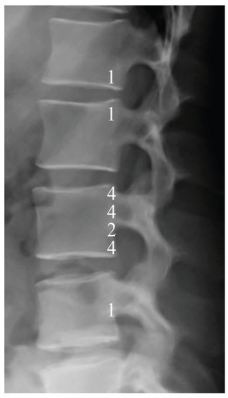

Sites of in the vertebral column

Q2.18 Which spinal TB lesion site is rare?

Answer: Posterior elements (pedicles, transverse process, spinous process).

Q2.19 What is the "bird nest appearance" in spinal TB?

Answer: Fusiform-shaped cold abscess of the thoracic region.

Q2.20 What is the most preferred imaging modality to assess vertebral body degeneration and sequestrum formation in spinal TB?

Answer: CT scan

Q2.21 Describe the role of MRI in the diagnosis of Spinal TB

Answer:

- For early and accurate diagnosis
- Best radiological option
- Beneficial to assess.
  - Spinal nerve root compression due to Pott's paraplegia
  - Discitis
  - Para-spinal soft tissue lesion
  - Investigational choice among non-invasive techniques.

Q2.22 Describe the role of biopsy in the diagnosis of Spinal TB

Answer:

- Less preferred
- Percutaneous CT-guided biopsy is done.

Q2.23 What is the minimum duration of chemotherapy for spinal TB?

Answer: At least 9 months.

Q2.24 Describe SM Tuli's middle path regime

Answer:

- Employed to prevent unwanted surgeries.
- It includes.
  - Rest the patient on a Hard or POP bed
  - Antitubercular therapy (ATT)
  - Follow up every 3 months for X-ray and ESR for prognosis.
  - Gradual mobilization in patients with no neurological compromise using spinal braces.
  - Surgical indication is reserved when the patient is not recovering or worsening of neurological symptoms.

Q2.25 What are the indications for surgery in TB spine?

Answer:

Patients having a neurological deficit	Patients with no neurological deficit
• No recovery even after 3-4 weeks of ATT • Worsening of paraplegia • Spastic paraplegia with severe and uncontrollable spasms of the legs	• Extensive paravertebral abscess and not responding to ATT. • Mechanical instability • Ex: When bilateral facet joints are affected

Q2.26 Name three surgical procedures used in the management of spinal TB

Answer:

- Surgeries in practice

YOURWISH

- o Costo-transversectomy
- o Anterolateral decompression: Hong Kong procedure, Antero Compression, and spinal fusion
- o Posterolateral or Transpedicular approach
  - → This is predominantly used.

BIG QUESTION 3: Describe the common sites, clinical features, and stages of hip joint tuberculosis.

Broad Answer

- Hip joint TB is the second most common skeletal TB, often seen in the first 30 years, especially in children.
- The most commonly affected site is the acetabular roof, followed by the epiphysis of the femoral head, the metaphysis of the femoral neck (Babcock's triangle), the greater trochanter, and lastly the synovial membrane.
- Clinically, patients present with night cries, antalgic gait, and restricted movements. Stage I (synovitis) shows FABER position with apparent lengthening and ~25% terminal restriction of movement.
- Stage II (early arthritis) shows FADIR position with apparent shortening, ~50% restriction of movements, muscle wasting, and X-ray findings of osteopenia with joint space narrowing.
- Early diagnosis and ATT can prevent progression to late destructive stages.

DETAILED QUESTIONS

Q3.1 What is the second most common type of skeletal tuberculosis?

Answer: Tuberculosis of the hip joint.

Q3.2. In children with hip joint TB, which site is most commonly affected?

Answer: Acetabular roof.

Q3.3 List the sequence of sites affected in hip joint TB.

PYQ: AIIMS 2019 PYQ: FMGE 2020-21

Answer:

1. Acetabular roof
2. Epiphysis of the femoral head
3. Metaphysis of the femoral neck (Babcock's triangle)
4. Greater trochanter
5. Synovial membrane (last affected)

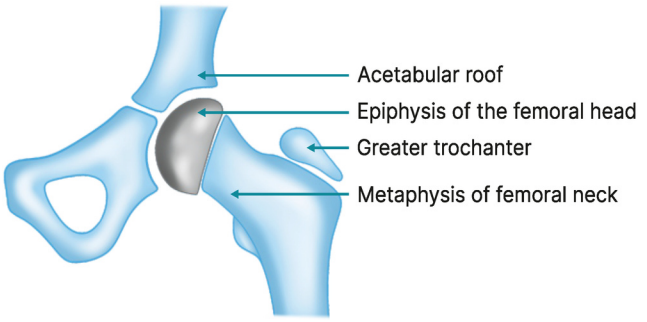

Q3.4. Which age group is most commonly affected by hip joint TB?

Answer: First 30 years of life.

Q3.5. Name three key clinical features of hip joint TB.

Answer:

- Night cries
- Antalgic gait
- Restriction of movements

YOURWISH

YOURWISH

Q3.6 Describe the Stage I stage of Babulkar and Pandey Clinico-Radiological Classification of synovitis

Answer:

Stages	Description
Stage I- Stage of Synovitis	• Irritable hip • **Increased FABER** (mnemonic) of the hip joint o Flexion o Abduction o External rotation • Apparent lengthening due to FABER • Terminal **movements** will be **restricted by 25%**

Q3.7 Describe the Stage II stage of Babulkar and Pandey Clinico-Radiological Classification of synovitis

Answer:

Stage II- Stage of Early Arthritis	• Articular cartilage damage • **Increased FADIR** of the hip joint o Flexion o Adduction o Internal rotation • Apparent limb shortening due to FADIR. • **Gluteal, Quadriceps muscle wasting** • All ranges of movements (ROM) are **restricted by 50%** • X-ray shows osteopenia and narrowing of joint space

Q3.8 Describe the Stage III stage of Babulkar and Pandey Clinico-Radiological Classification of synovitis

Answer:

Stage III- Stage of Late Arthritis	• Significant articular surface destruction • Marked FADIR • True limb shortening • Gross restriction of movements usually **more than 50%** • X-ray shows marked **subchondral destruction**

Q3.9 Describe Stage IV- Stage of Pathological Dislocation

Answer:

Stage IV- Stage of Pathological Dislocation	• Gross destruction of the femoral head or pathological dislocation of the superior acetabular margin • **Wandering or Travelling Acetabulum-** Upward displacement of the head of the femur and may be out of the ilium. • Marked shortening. • Gross restriction in all range of movements • **Protrusio Acetabuli-** Medial protrusion of the head of the femur through destroyed acetabulum.

Q3.10 Describe the treatment for different stages of T.B. of the Hip Joint

PYQ: FMGE 2019

Answer:

Stages	Description
Stage of Synovitis	• Rest and mobilization exercises • Traction • ATT
Stage of Arthritis	• Non-weight-bearing ROM exercises. • ATT • If unresponsive, then o Synovectomy (Removal of synovium). o Joint debridement

BIG QUESTION 4: Describe the common features, deformities, and management of tuberculosis of the knee joint.

Broad Answer:

- TB of the knee is the third most common site of skeletal TB, with the initial lesion starting in the synovium (unlike the hip joint, where synovium is last affected).
- A characteristic finding is the triple deformity—posterior subluxation, flexion of the knee, and external rotation—caused by spasms of the biceps, hamstrings, and iliotibial band, also seen in poliomyelitis.
- Management includes ATT (2HRZE + 4/7HR), traction, synovectomy, and joint debridement; total knee replacement may be needed in advanced cases.
- Related TB manifestations include TB dactylitis (spindle-shaped swelling of fingers—*Spina Ventosa*), BCG osteomyelitis (rare), and Poncet's arthritis (a reactive arthritis resembling RA)

DETAILED QUESTIONS

Q4.1 What is the most common initial site of TB lesion in the knee joint?

Answer: Synovium.

Q4.2 Explain the triple deformity of the knee in TB and its mechanism.

Answer:

- Triple deformity
  - o Posterior subluxation
  - o Flexion of the knee
  - o External rotation
- This is due to spasms of the biceps, hamstrings, and iliotibial band.
- It is seen in TB of the knee and poliomyelitis.

Q4.3 Describe the treatment for TB of the knee joint.

Answer:

Treatment

- ATT (2HRZE+4/7HR)
- Traction
- Synovectomy and joint debridement
- Total knee replacement

Q4.4 What is the common radiological appearance of TB dactylitis?

Answer: Fusiform (spindle-shaped) expansion of the bone-Spina Ventosa.

Q4.5 What is the main treatment for TB dactylitis?

Answer: Anti-tubercular therapy (ATT).

Q4.6 Which rare bone infection can occur after BCG vaccination?

Answer: BCG osteomyelitis.

4. OSTEOMYELITIS/ OSTEOCHONDRITIS/ AVASCULAR NECROSIS

BIG QUESTION 1: Describe the pathogenesis, common sites, causative organisms, and key clinical features of acute osteomyelitis.

PYQ: FMGE 2020 PYQ: NEET PG 2022

Broad Answer:

- Acute osteomyelitis is an infection and inflammation involving all layers of bone and bone marrow,
- The metaphysis is the most commonly affected site due to poor phagocytic activity (Hobo's theory) and sluggish blood flow at hairpin bends (Trueata's theory).
- In children, common sites include the proximal tibia, distal femur, and proximal femur, with *Staphylococcus aureus* as the leading pathogen; in children <4 years, *H. influenzae* is common.
- Early pathology includes acute inflammation and pus formation within 2-3 days; bone death by 1 week; and periosteal new bone formation by 2 weeks.
- Clinically, it presents with fever, localized pain, swelling, and pseudoparalysis in children.
- Diagnosis is confirmed by MRI or pus aspiration, and management includes immobilization, antibiotics, and surgical drainage if no improvement within 36 hours.

DETAILED QUESTIONS

Q1.1 Define osteomyelitis.

Answer: Infection and inflammation of all layers of the bone and bone marrow.

Q1.2 Who coined the term osteomyelitis and popularised the term osteomyelitis?

Answer:

- Reynolds coined the term osteomyelitis
- Nelaton popularized the term osteomyelitis.

Q1.3 What are the subtypes of osteomyelitis?

Answer:

- Subtypes of osteomyelitis: Waldvogel classification
  - Acute < 2 weeks.
  - Subacute - 2 to 4 weeks.
  - Chronic > 4 weeks.

Q1.4 Which is the Commonest mode of spread of acute osteomyelitis?

Answer: Hematogenous spread

Q1.5 In which age group is acute osteomyelitis most common?

Answer: Most common in - younger than 5 years

Q1.6 Which is the most common site for osteomyelitis in children?

Answer:

- Proximal tibia.
- Distal femur.
- Proximal femur

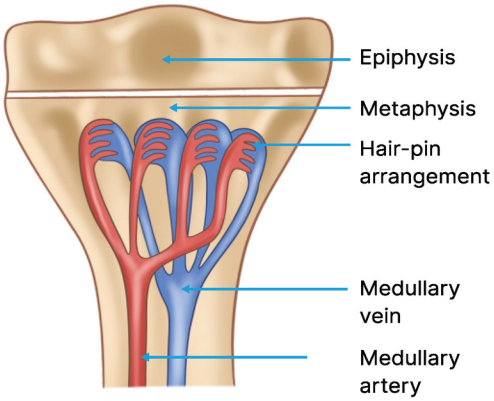

Q1.7 Which is the most common causative organism in pyogenic osteomyelitis?

Answer: Staphylococcus aureus.

Q1.8 Which is the most common causative organism in a child under 4 years?

Answer: Haemophilus influenzae.

Q1.9 Which is the most common site of pyogenic osteomyelitis in adults?

Answer: Thoraco-lumbar vertebrae > long bones.

Q1.10 Which is the earliest pathological change in pyogenic osteomyelitis?

Answer: Acute inflammatory reaction.

Q1.11 When does pus formation occur in pyogenic osteomyelitis?

Answer: On the 2nd-3rd day.

Q1.12 When is evidence of bone death seen?

Answer: Around 1 week.

Q1.13 When does new bone formation from deep layers of stripped periosteum occur?

Answer: By the end of the 2nd week.

Q1.14 Which is the most common part of the bone affected in both children and adults?

Answer: Metaphysis.

Q1.15 Explain Hobo's theory for the localization of pyogenic osteomyelitis in the metaphysis.

Answer:

- Hobo's theory
  - Phagocytic theory
  - The metaphysis is normally deficient in phagocytes.
  - Therefore, if any bacteria invade, no phagocytosis leads to infection.

Q1.16 Explain Trueata's theory for the localization of pyogenic osteomyelitis in the metaphysis.

Answer:

- Hairpin bends theory
  - The medullary artery and medullary vein are straight in the diaphysis.

- Forms hairpin-like bends in the metaphysis.
- If an organism is present in the blood, it travels fast through the straight vessels.
- But at the hairpin-like vessels in the metaphysis, it moves more slowly, sluggish movement.
- Therefore, it can escape from vessels and form an abscess on the metaphysis.

Q1.17 In which age group can infection cross the epiphyseal plate, and what does it cause?
Answer: Infants and children under 1 year; can cause septic arthritis.

Q1.18 What is pseudoparalysis in infantile osteomyelitis?
Answer: Apparent paralysis due to pain and refusal to move the affected limb, but without neurological damage.

Q1.19 What is the differential diagnosis of Acute Osteomyelitis?
Answer:

- Acute osteomyelitis
- Scurvy
- Congenital syphilis

Q1.20 Why is MRI preferred over X-ray in early osteomyelitis diagnosis?
Answer: MRI can detect **bone marrow edema** and **soft tissue changes** much earlier than X-ray, making it extremely sensitive for early diagnosis.

Q1.21 When is X-ray usually normal in acute osteomyelitis?
Answer: First 10 days.

Q1.22. What is the earliest X-ray sign of acute pyogenic osteomyelitis?
Answer: Periosteal new bone formation (end of 2nd week).

Q1.23 What are the late X-ray signs of osteomyelitis?
Answer:

- Regional osteoporosis (living bone)
- Segment of high density (dead bone → chronic osteomyelitis)

Q1.24 Which imaging modality is most sensitive in early osteomyelitis?
Answer : MRI.

Q1.25 Which nuclear scan is highly sensitive but less specific for osteomyelitis?
Answer: Radioscintigraphy with **Gallium citrate**.

Q1.26 What is the most certain confirmatory diagnostic method for osteomyelitis?
Answer: Aspiration of pus (invasive).

Q1.27 What is the first step in osteomyelitis treatment?
Answer: Supportive therapy for pain and dehydration.

Q1.28 Describe the treatment approach for acute pyogenic osteomyelitis in children and adults.

Answer:

- Splinting of the affected part: Immobilization of the affected part.
- Antibiotic therapy
- Surgical drainage: Last option
- Older children and adults with Staphylococcus osteomyelitis are best treated with flucloxacillin + fusidic acid - IV.
- Fusidic acid
  - It is preferable over B penicillin.
  - Due to resistance to penicillin, fusidic acid gets concentrated.
- Children below 4 years: 2nd-generation cephalosporins.
- Salmonella osteomyelitis: cotrimoxazole.
- Streptococcal osteomyelitis: benzoyl penicillin.
- If constitutional symptoms and local pain fail to improve within 36 hours, surgical drainage is done.
- Full weight bearing is allowed only after 4 weeks.
  - If not, it leads to pathological fractures.

Q1.29 What are the Complications of acute osteomyelitis?

Answer:

- Septicemia, septic shock
- Septic arthritis: Tom Smith Arthritis (Child <1 year: Hip joint)
- Growth disturbances - as the epiphysis is involved.
- Chronic osteomyelitis - acute if not treated properly leads to chronic osteomyelitis.

BIG QUESTION 2: Describe the pathology, radiological features, and management of Brodie's abscess, and differentiate it from Garre's osteomyelitis.

Broad Answer:

- Brodie's abscess, first described by Sir Benjamin Brodie in 1832, is a localized abscess in cancellous bone caused by low-virulence organisms in a host with good resistance, leading to a walled-off infection and cavity formation.
- On X-ray, it appears as an osteolytic lesion with a sclerotic rim; differentials include osteoid osteoma, Langerhans histiocytosis, eosinophilic granuloma, and tuberculous osteomyelitis.
- Management is by surgical drainage. Garre's osteomyelitis, in contrast, is a dry osteomyelitis with no abscess cavity, showing diffuse sclerosis of the metaphysis and diaphysis.
- It is analogous to TB sicca, where “dry pus” is seen due to a lack of liquefaction.

DETAILED QUESTIONS

Q2.1 Describe the features of Sub-Acute Osteomyelitis

Answer:

- A well-defined cavity in the cancellous bone is seen.
- Causative organism - Staphylococcus aureus.
- Temperature and WBC count - normal.
- ESR: Increased
- 3 main types
  - Brodie's abscess.
  - Garre's osteomyelitis.
  - Salmonella osteomyelitis.

YOURWISH

Q2.2 Who first described Brodie's abscess and when?

Answer: Sir Benjamin Brodie, in 1832.

Q2.3 What type of bone is affected in Brodie's abscess?

PYQ: NEET PG 2022

Answer: Cancellous bone

Q2.4 What is the most common site, age, and organism for Brodie's Abscess?

Answer:

Features	Description
Most common site	• Upper tibia • Lower femur
Most common organism	• Staphylococcus aureus
Most common age	• 2nd decade

Q2.5 Describe the pathogenesis of Brodie's Abscess

Answer:

- Low virulence of the organism and good host resistance
- Leads to confining the infection.
- A cavity is formed.

Q2.6 What are the X-ray findings of Brodie's Abscess?

Answer:

- Seen as an osteolytic lesion with a sclerotic rim

Q2.7 What is the differential diagnosis of an osteolytic lesion with a sclerotic rim on X-ray?

Answer:

- Brodie's abscess
- Osteoid Osteoma
- Langerhans histiocytosis
- Eosinophilic granuloma
- TB osteomyelitis

Q2.8 What is the treatment for Brodie's Abscess?

Answer: Treatment: surgical drainage

Q2.9 Explain Garre's osteomyelitis

Answer:

- No abscess cavity.
- It is dry osteomyelitis.
- Diffuse sclerosis in the metaphysis and diaphysis is seen.
- This can be correlated with TB sicca, as both have 'dry pus.
- Most common sites
  - Upper tibia - more common.
  - Jaw (mandible) - 2nd common site.

YOURWISH

Q2.10 What is another name for Typhoid osteomyelitis?
Answer: Salmonella osteomyelitis

Q2.11 What are the common sites of Typhoid osteomyelitis?
Answer:

- 1st - ulna
- 2nd - ribs
- 3rd - vertebra

Q2.12 What is the mode of spread of Typhoid Osteomyelitis?
Answer: Hematogenous.

Q2.13 Which systemic condition is most commonly associated with Salmonella osteomyelitis?
Answer: Sickle cell anemia.

Q2.14 What is the treatment for Typhoid Osteomyelitis?
Answer:

- Treatment: Surgical
- Drug: Cotrimoxazole

BIG QUESTION 3: Explain the core concept, causes, and classical features of chronic osteomyelitis according to Waldvogel's classification.

Broad Answer:

- Chronic osteomyelitis, as per Waldvogel's classification, is a bone infection persisting for >4 weeks and most commonly caused by Staphylococcus aureus (S. epidermidis in implant-related cases).
- It usually affects the upper tibia or lower femur, often in young adults (2nd decade).
- The hallmark is a discharging sinus showing a waxing and waning pattern, sometimes expelling bone chips (pathognomonic).
- The pathogenesis involves septic thrombosis → bone infarction → periosteal lifting → sequestrum formation (dead bone within living bone).
- Classical radiology after 4-6 weeks shows thickened, irregular cortex, regional osteoporosis, and dense sequestrum.
- The most certain diagnosis is confirmed by pus aspiration.

DETAILED QUESTIONS

Q3.1 According to Waldvogel's classification, how long must osteomyelitis persist to be termed chronic?
Answer: More than 4 weeks.

Q3.2. What is the most common cause of chronic osteomyelitis?
Answer: Staphylococcus aureus.

Q3.3. Is the causative organism for chronic osteomyelitis the same as for acute and subacute forms?
Answer: Yes, Staphylococcus aureus is common in all three.

Q3.4. Which organism most commonly causes osteomyelitis in foreign body implant cases?

Answer: Staphylococcus epidermidis (Staphylococcus albus).

Q3.5 Describe the Clinical Features of Chronic Osteomyelitis.

Answer:

- A classical Walenkamp phenomenon
- Walenkamp Phenomenon - Cycle

The swelling increases, but the skin is intact.
↓
Pain intensity increases.
↓
Toxic symptoms severity increases.
↓
Suddenly, the skin breaks and pus discharges out - Sinus.
↓
Once the pus comes out, the severity of the symptoms will decrease.
↓
Patients undergo temporary healing.

- Discharging sinus with classical Waxing and Waning Pattern
- Discharge of bone chips: Most pathognomic (Direct evidence of osteomyelitis)
- Scars, Swelling
- Deformity

Q3.6 Differentiate between sinus and fistula.

Answer:

- Sinus: Blind tract lined by epithelium.
- Fistula: It is the tract that connects two hollow viscera (e.g., perianal fistula).

Q3.7 Difference between Tuberculous Sinus from Pyogenic Sinus

Answer:

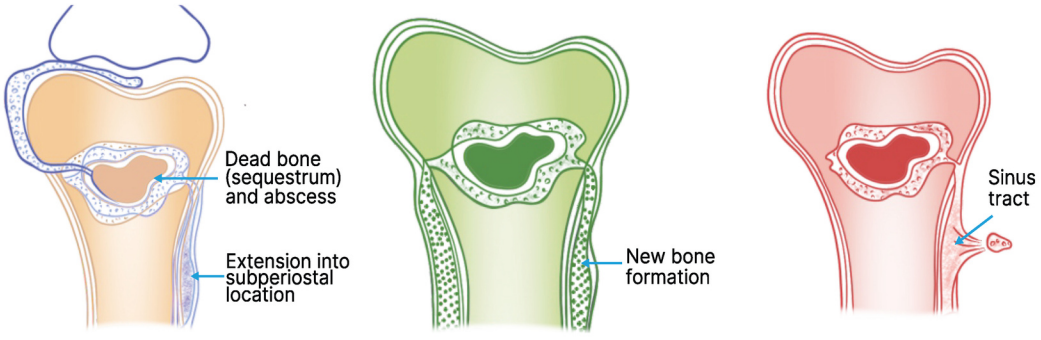

Tuberculous Sinus	Pyogenic Sinus
• Shows bluish discoloration. • Undermined edges. • Shows either hypoesthesia or anesthesia	• Sinus edges are black in color • Shows normal reaction to touch.

Q3.8 What is a sequestrum?

PYQ: FMGE 2020 PYQ: AIIMS 2020

Answer: Dead bone within a living bone, like a nidus



Sequestrum

Two Surfaces of the Sequestrum

- **Outer surface**- Smooth.
  - **Inner surface** - Rough.
- **Reason:** It is constantly in touch with pus.
  - **Reason:** It is in contact with the granulation tissue.

Q3.9 Describe the pathogenesis of Sequestrum

Answer: Non-sterile(septic) thrombus clogs the vessels in the bone, local area undergoes infarction with sepsis. Then pus comes out and lifts the periosteum, which causes the death of the underlying bone.

Q3.10 What are the types of sequestrum according to shape?

Answer:

- According to Shape
  - o Pencil-like: Infants.
  - o Ring: Pin tract infection.
    - → Mostly due to external fixators.
  - o Conical: Amputation stump.
  - o Coralliform: Perthes disease.

Q3.11 Describe the types of sequestrum according to Consistency

Answer:

- Coke like: TB.
  - o Coke: Oily substance acquired in the process of heating coal.
- Feathery: Syphilis.
- Sandy: TB.

Q3.12 What are the types of sequestrum according to colour?

Answer:

- Black: Fungal, amputation stump.
- Green: Pseudomonas aeruginosa infection.

Q3.13 Describe the 1st line investigation for chronic osteomyelitis.

Answer:

- The cortex of the infected bone becomes thicker and irregular with a disorganized trabecular pattern.
- Classical X-ray pictures show a patchy loss of density.
  - o Regional osteoporosis (Discussed in acute osteomyelitis).
- Clear evidence of sequestrum in radiology appears only after 4 - 6 weeks.
- Sequestrum appears compared to the surrounding bone. denser
- There will be a loss of cortico-medullary differentiation (Loss of medullary canal)
- Cloaca can be easily observed in an X-ray.

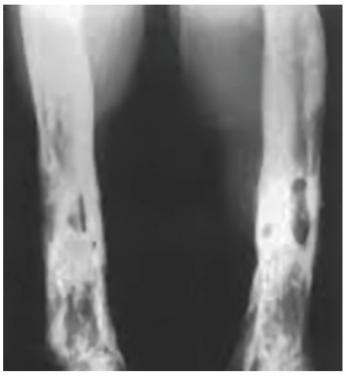

X-ray

Q3.14 What are the sinogram findings in chronic osteomyelitis?

Answer:

- Major role: To remove the sinus.
- When there are multiple sinuses, a sinogram may be done.
- Radio-opaque dye is injected and read with X-ray or CT.

Q3.15 What is the CT scan finding of chronic osteomyelitis?

Answer: The major role of a CT scan in chronic osteomyelitis is the detection of sequestrum.

Q3.16 What is the MRI finding of chronic osteomyelitis?

Answer:

- Provides an accurate determination of the extent of pathology in bone and soft tissue.
- Also shows a sinus tract.
- Choice among noninvasive investigations

Q3.17 What is the treatment for chronic osteomyelitis?

Answer:

- The 4 important steps are.
  - Radical debridement
  - Dead space management
  - Soft tissue coverage
  - Antibiotic therapy.

Q3.18 Describe radical debridement as treatment for chronic osteomyelitis?

Answer:

- This is achieved by Sequestrectomy and Saucerization.
- Removal of infected non-viable bone: Sequestrectomy.
- Conversion of a hollow cavity into a shallow cavity: Saucerization.
- Suppose any implants, such as plates and screw, are there, they should be removed because of the source of biofilm (Source of infection)
- Antibiotics can't penetrate the biofilm.

Q3.19 Describe Dead Space Management as a treatment of chronic osteomyelitis.

Answer:

- After radical debridement, defects in bone and soft tissues are formed - Dead space.
- If the dead space is not treated properly, it will lead to early recurrence of infection.
- To prevent such, various methods of dead space management are implied.
  - Papineau: Friedlander's technique
  - VAC therapy.
    - → VAC: Vacuum Assisted Closure.
  - Antibiotic PMMA beads.
    - → PMMA: Poly Methoxy Methyl Acrylate.
  - Masquelet technique
  - Ilizarov technique

YOURWISH

Q3.20 Why is soft tissue coverage often required in chronic osteomyelitis?

Answer: Due to extensive scarring of muscles, fascia, and skin.

Q3.21 How is soft tissue coverage achieved in chronic osteomyelitis?

Answer: By muscle flaps and skin grafting.

Q3.22 Explain antibiotic therapy in chronic osteomyelitis?

Answer:

- Staphylococcus aureus -IV Nafcillin or Cefazolin.
- MRSA (Methicillin-resistant Staphylococcus aureus) - Vancomycin.
- Vancomycin resistance: Linezolid.
- Antibiotics are given for 4 to 6 weeks.

Q3.23 Why is antibiotic treatment given for 4-6 weeks in chronic osteomyelitis?

Answer: It takes 4 weeks for revascularization of the bone by which antibiotic agents are able to infiltrate the site of infection.

Q3.24 Describe the special types of osteomyelitis.

Answer:

Brucellar Osteomyelitis	• M.C. site - Spine. Next - Knee • Treatment - Tetracycline
Syphilitic Osteomyelitis	• Congenital syphilis causes Epiphysitis • M.C. site - Distal end of femur, proximal of tibia • Congenital syphilis causes pseudoparalysis • It also causes dactylitis • Secondary and Tertiary Stages affect the bone • Secondary stages cause periostitis • Tertiary stage causes Gumma - skull, Sternum & Hard Palate
Tom Smith's Arthritis	• Usually, in an infant below 1 year • Focus commonly from septic Umbilicus • M.C. joint involved - Hip joint • Clinically, this condition mimics CDH • X-ray shows a complete absence of the head & neck of the femur • The end result is a hypermobile joint instead of Bony Ankylosis: Very characteristic • If there is gas in the joint - Suspect E. coli

Q3.25 What are the Complications of Chronic Osteomyelitis?

Answer:

- Acute exacerbation
- Growth disturbances: If the epiphysis is involved
- Pathological fracture.
  - o A very common complication.
  - o Osteomyelitis causes sequestrum; in severe trauma, the bone may break.
  - o Epithelioma/ Squamous Cell carcinoma
  - o Sinus scar tissue is lined by the squamous epithelium.
  - o Secondary amyloidosis - Leads to Nephrotic syndrome.

Q3.26 Describe the causes and pathogenesis of osteonecrosis.

Answer:

Causes & Pathogenesis	
• Fracture • Dislocation • Infection	Interruption of arterial supply
• Sickle cell disease • Vasculitis • Caison's disease	Arteriolar occlusion
• Gaucher's Disease • Fatty infiltration due to steroids / Alcohol	Capillary composition

Q3.27 What are the common sites of Osteonecrosis?

Answer:

- Femoral head
- Femoral condyle
- Head of humerus
- Capitulum
- Scaphoid
- Lunate
- Talus
- Calcaneum

Q3.28 What is the time taken for bone cells to die after anoxia?

Answer: 12-48 hours (72 hours in pathology textbooks).

Q3.29 What is the first histological change in AVN?

Answer: Loss of outline of fat cells in bone marrow.

Q3.30 What is the First clinical symptom of AVN?

Answer: Pain.

Q3.31 Which is the Earliest reliable investigation for AVN?

Answer: MRI.

Q3.32 What is the Earliest X-ray sign of AVN?

Answer: Increased bone density.

Q3.33 What is the crescent sign?

Answer: Thin, tangential fracture line below the articular surface on X-ray; indicates subchondral fracture in AVN.

Q3.34 What is the Normal intramedullary pressure?

Answer: 10-20 mmHg.

Q3.35 Which radionuclide is used in AVN diagnosis?

Answer: Tc-sulphur colloid.

Q3.36 Specify the FICAT and Arlet Staging

Answer:

Stage I	No Radiographic abnormality, MRI may show changes, High Intramedullary pressure may be there. Diagnosis confirmed only by biopsy
Stage II	Painful. Early Radiographic Change present, Bone outline normal
Stage III	Clear-cut radiographic features. Abnormal bone outline. In this stage, intramedullary pressure is normal
Stage IV	Collapse of the articular surface & secondary change of degenerative arthritis

Q3.37 Describe the treatment for osteonecrosis.

Answer:

Stage 1 and 2 (early-conservative)	Medullary decompression Bone grafting
Stage 3 and 4 (late)	Arthroplasty (joint replacement)

BIG QUESTION 4: Explain the core concepts, causes, and key sites of involvement in avascular necrosis (AVN) and related osteochondritis conditions.

Broad Answer:

- Avascular necrosis (AVN) occurs due to loss of blood supply to bone, leading to death of bone cells and marrow, and healing occurs by *creeping substitution*.
- In *Caisson's disease*, the ends of long bones are most commonly affected, while drug-induced AVN often involves the head of the femur or humerus.
- In *Gaucher's disease*, the femoral head is commonly involved with marrow infiltration by Gaucher cells, producing anemia, cytopenias, and the *Erlenmeyer flask deformity* of the distal femur.
- *Radiation necrosis* affects the shoulder, ribs, and jaw, and shows an absence of repair or remodeling.
- Osteochondritis lesions affect specific sites such as the patella (Johansson-Larsen), tibial tuberosity (Osgood-Schlatter), lunate (Kienbock's), scaphoid (Preiser), and others, each with characteristic location-based pathology.

DETAILED QUESTIONS

Q4.1 What is the healing pattern in AVN?

Answer: Creeping substitution.

Q4.2. Which is the most common site of AVN in Caisson's disease?

Answer: Ends of long bones.

Q4.3. Which is the most common site of drug-induced AVN?

Answer: Head of femur or humerus.

Q4.4 Which is the most common site of AVN in Gaucher's disease?

Answer: Femoral head.

Q4.5. What is the classic bone X-ray finding in Gaucher's disease?
Answer: Erlenmeyer flask deformity.

Q4.6. What are the common sites of radiation necrosis?
Answer: Shoulder, ribs, jaw.

Q4.7. Which is the striking histological feature of radiation necrosis?
Answer: Absence of repair and remodeling.

Q4.8. Johansson-Larsen syndrome involves which bone part?
Answer: Patella.

Q4.9. Osgood-Schlatter disease involves which part of the bone?
Answer: Tibial tuberosity.

Q4.10. Sever's disease involves which site?
Answer: Calcaneal tuberosity.

Q4.11. Hawkins disease involves which site?
Answer: Talus.

Q4.12. Freiberg's disease involves which site?
Answer: Second metatarsal head.

Q4.13. Iselin's disease involves which site?
Answer: Base of the 5th metatarsal.

Q4.14. Hasse's disease involves which site?
Answer: Head of humerus.

Q4.15. Panner's disease involves which site?
Answer: Capitulum of humerus.

Q4.16. Preiser's disease involves which site?
Answer: Scaphoid.

Q4.17. Kienbock's disease involves which site?
Answer: Lunate.

Q4.18. Friedrich's disease involves which site?
Answer: Clavicle.

Q4.19. Scheuermann's disease involves which site?
Answer: Spine (thoracic kyphosis).

Q4.20 Calve`s diseases involve which site?
Answer: Spine (rim)

YOURWISH

5. UPPER LIMB TRAUMA

BIG QUESTION 1: What are the peculiarities, fracture patterns, and management principles of the clavicle?

Broad Answer: The clavicle, meaning "key" (from *clavis*), is unique in its ossification, growth pattern, and structural features. It is the first bone to ossify (5th week IUL) and the last to complete ossification (25 years). Its fractures are common, especially at the junction of the medial two-thirds and lateral one-third, and are mostly managed conservatively with methods like cuff-and-collar slings or figure-of-8 bandages. Complications include malunion, neurovascular injury, and thoracic outlet syndrome.

DETAILED QUESTIONS

Q1.1: What are the peculiarities of the clavicle?

Answer:



- Clavis means key
- 1st bone to ossify (5th week of intrauterine life)
- Last physis in the body to close (25 years)
- Growing end: Medial/sternal end
- Ossifies from two primary centers
- Only long bone to ossify from the membrane
- Only a long bone without a medullary canal
- The most common bone fractured in newborns

Q1.2: What are the deforming forces in a clavicle fracture and their effect?

Answer: Leads to malunion - the most common complication. Due to:

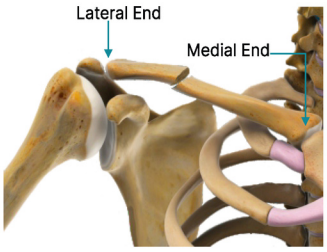

- The lateral 1/3rd is pulled down by the weight of the upper limb
- The medial 2/3rd is pulled up by the sternocleidomastoid muscle

Q1.3: What are the mechanisms of clavicle injury and the most common site of fracture?

Answer:

- Fall onto affected shoulder (87%) - most common
- Direct impact (10%)
- Fall onto outstretched hand (2%)
- Most common site: Junction of medial 2/3rd and lateral 1/3rd

Q1.4: What imaging views are used for clavicle fracture evaluation?

Answer:

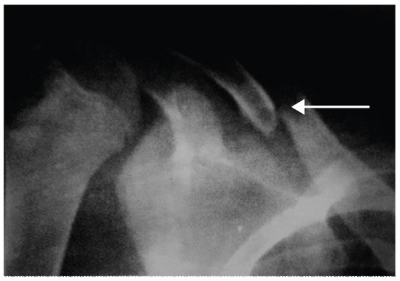

- X-ray:
  - 45° lordotic/cephaloid view - choice for clavicle fracture
  - Zanca view (15° cephaloid) - ideal for acromioclavicular joint dislocation
- CT scan:
  - Detect intraarticular extension
  - Investigation of the choice for the lateral end (acromial end) fracture

Q1.5: What is the Allman/Craig classification and its treatment relevance?

Answer: It is the classification system for clavicular fractures.

Group I	Middle 3rd (80%): Conservative treatment
Group II	Lateral 3rd (15%): Surgical treatment
Group III	Medial 3rd (5%)

Q1.6: What are the conservative treatment methods for a clavicle fracture?

PYQ: FMGE 2020

Answer:

- 90% clavicle fractures are treated conservatively, and 10% require surgical intervention
- Gold standard: Cuff-and-collar sling
- Strapping
- Sabre method - rigid dressing over fracture
- Billington Yoke method - POP over padded figure-of-8 dressing
- Figure-of-8 bandage (gold standard)
- Age-based:
  - 0-2 years: Strapping (avoid figure-of-8)
  - >2 years: Cuff-and-collar with figure-of-8 bandage

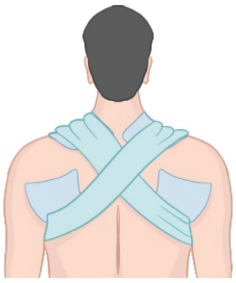

Figure-of-8 bandage

Q1.7: What are the major complications of a clavicle fracture?

Answer:

- Malunion - most common
- Subclavian vessel injury - the most common vessel injury
- Medial cord of the brachial plexus - the most common nerve injury
  - Medial root of the median nerve, medial cutaneous nerve of the arm, medial cutaneous nerve of the forearm, ulnar nerve, medial pectoral nerve
  - Ulnar nerve - most commonly injured
- Most common associated fractures: Rib and scapula fractures
- Thoracic outlet syndrome
- Non-union (rare)

Q1.8: What is the mechanism of action of conservative devices in clavicle fracture?

Answer:

- Cuff-and-collar sling: Pulling down the action of the lateral one-third by neutralizing the upper limb
- Figure-of-8 bandage: Pulling up of the medial two-thirds by neutralizing the sternocleidomastoid

Q1.9: What are the indications of surgery for a clavicle fracture?

Answer:

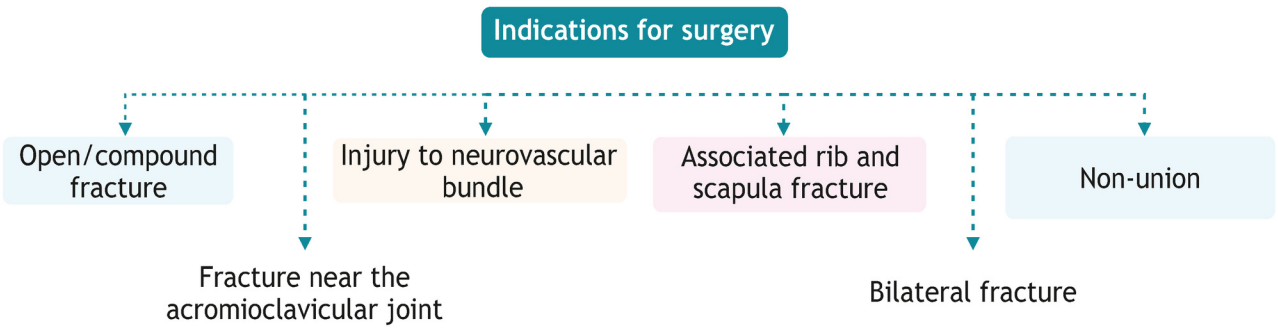

BIG QUESTION 2: What are the types, clinical features, imaging findings, management, and complications of shoulder dislocation?

Broad Answer: Shoulder dislocation is the most common joint dislocation in the human body, with anterior dislocation being the most frequent. Clinical signs include loss of deltoid contour, positive Duga's, Hamilton's, Callaway's, Bryant's, and Regiment badge tests. Imaging may reveal Bankart's and Hill-Sachs lesions on MRI, while X-ray signs are more relevant for posterior dislocations. Acute dislocations are reduced using techniques like Kocher's method, while recurrent dislocations may require surgical interventions. Complications include axillary nerve injury, axillary artery damage, and recurrent instability, classified as TUBS or AMBRI.

DETAILED QUESTIONS

PYQ: AIIMS 2019 PYQ: INICET 2023

Q2.1: What are the types of shoulder dislocation?

Answer:

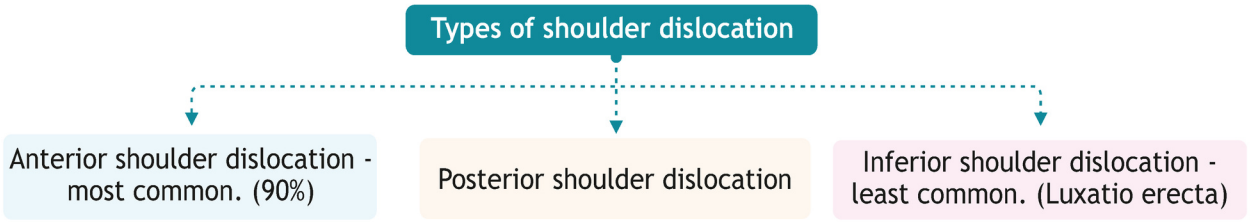

Q2.2: What are the key clinical features of anterior shoulder dislocation?

Answer:

- Loss of deltoid contour (first sign)
- Shoulder held in extension, abduction, and external rotation

Q2.3: What are the clinical tests used for the diagnosis of shoulder dislocation, and what is the significance of the Regiment Badge test?

PYQ: INICET 2022

Answer:

- Duga's test: Inability to touch opposite shoulder (only fresh dislocations)
- Hamilton's ruler test: Loss of gap between ruler and arm
- Callaway's test: Increased axillary girth on the affected side. Measured using an inch tape.
- Bryant's test: Anterior axillary fold lowered on the affected side
- Regiment badge test: Loss of sensation over the deltoid due to axillary nerve injury



Anterior Shoulder Dislocation- Hamilton's ruler test

Q2.4: What are the X-ray features of shoulder dislocation that help in diagnosis?

Answer:

- X-ray:
  - Posterior dislocation: Vacant glenoid sign, Daylight/Light bulb sign
  - Anterior dislocation: No specific X-ray sign

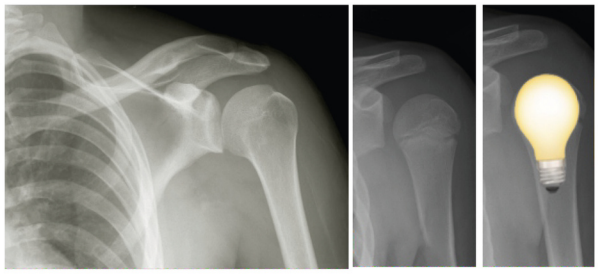

Q2.5: What are the MRI findings noticed in shoulder dislocation?

Answer:

- MRI: Commonly needed, and shoulder dislocation occurs with soft tissue injury.
  - Bankart's lesion - Damage of the anterior structures, such as the capsule and labrum (tear in the anteroinferior aspect of the capsule and the labrum)
  - Hill-Sachs lesion - posterolateral humeral head defect (hatchet deformity)
  - Mnemonics: **BAI** = Bankart's lesion anteroinferior; **HPL** = Hill-Sachs lesion posterolateral

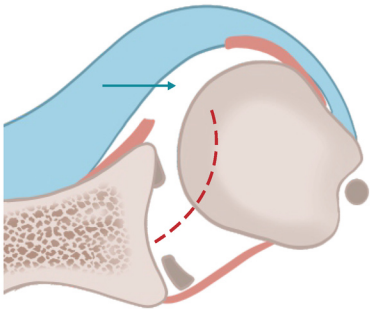





Q2.6: What is the terrible triad of the shoulder and its significance?

Answer:

- Associated with recurrent shoulder dislocation
- Components:

Bankart's lesion

Hill-Sachs lesion

Erosion of anterior glenoid rim

Q2.7: What are the treatment methods for acute shoulder dislocation?

Answer: Kocher's method (method of choice): **TEAM** — Traction, **E**xternal rotation, **A**dduction, **M**edial rotation

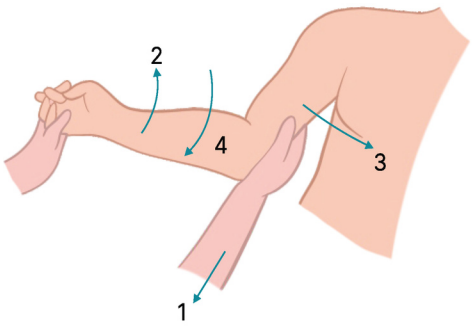

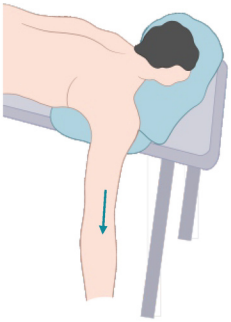

- Stimson's gravity method
- Hippocrates' method (outdated): Keeping the foot in the axilla, traction is applied, and the arm is adducted with the foot acting as a fulcrum.

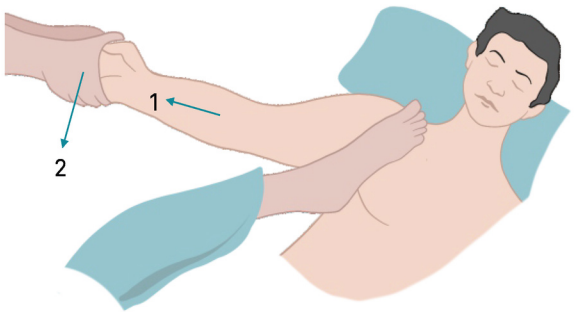

YOURWISH

Q2.8: What are the surgical options for recurrent shoulder dislocation?

Answer:

- Bankart operation
- Putti-Platt's operation
- Bristow's operation
- McLaughlin's operation
- Weber's operation
- Nicolandi operation

Q2.9: What are the major complications of shoulder dislocation?

Answer:

- Axillary nerve injury - the most common nerve injury.
- Axillary artery injury - the most common arterial injury.
- Recurrent dislocation (the shoulder is the most common joint for recurrent dislocation).

Q2.10: How is the recurrent shoulder dislocation defined and classified?

Answer:

- Defined as ≥3 dislocations in 12 months.
- Classified as:
  - **TUBS**: **T**raumatic, **U**nidirectional, **B**ankart's lesion → **S**urgery.
  - **AMBRI**: **A**traumatic, **M**ultidirectional, **B**ilateral → **R**ehabilitation (Inferior capsular shift).

BIG QUESTION 3: What are the mechanisms, classifications, treatments, and complications of humerus fractures?

Broad Answer: Humerus fractures may involve the proximal humerus or the shaft, with distinct mechanisms, neurovascular injuries, and treatment approaches. Proximal humerus fractures are common in postmenopausal women due to osteoporosis and are classified by Neer's system into four types based on the number of displaced parts. Treatment ranges from conservative slings to arthroplasty, depending on severity. Shaft fractures are usually due to direct trauma and are often associated with radial nerve injury. Specific fracture patterns like Holstein-Lewis carry a high risk of nerve palsy and may require surgical decompression.

DETAILED QUESTIONS

Q3.1: What are the common sites of humerus fractures?

Answer:

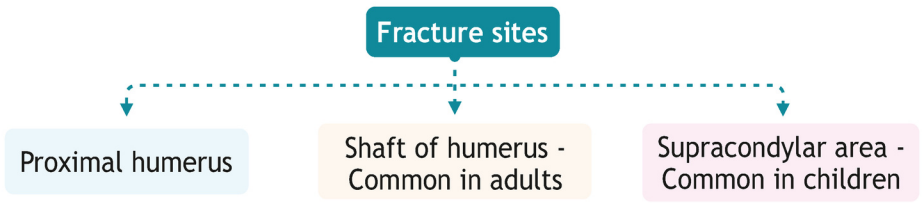

Q3.2: What are the common mechanisms of humerus fracture and associated vascular injuries?

Answer:

- Proximal humerus fracture: Fall on outstretched hand
  - Most common artery injured: Axillary artery
- Shaft of humerus fracture: Direct trauma
  - Most common artery injured: Brachial artery

Q3.3: What are the common nerve injuries in humerus fractures?

Answer:

- Proximal humerus fracture: Axillary nerve (most common)
- Shaft of humerus fracture: Radial nerve (most common)

Q3.4: What are the parts of the proximal humerus and the definitions of necks?

Answer:

- Four parts: Greater tuberosity, Lesser tuberosity, Head of humerus, Shaft
- Anatomical neck: Between the head and the greater tuberosity
- Surgical neck: Between the shaft and the lesser tuberosity

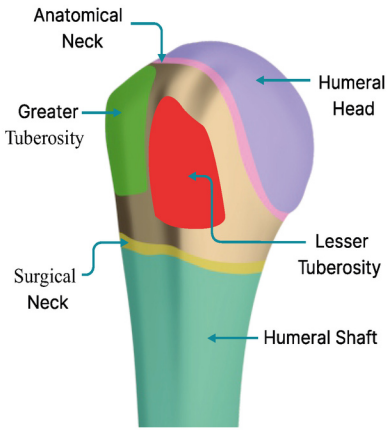

Q3.5: When is a fracture considered displaced?

Answer: A part is displaced if:

- >1 cm displacement
- >45° angulation

Q3.6: What is Neer's classification and its significance?

Answer:

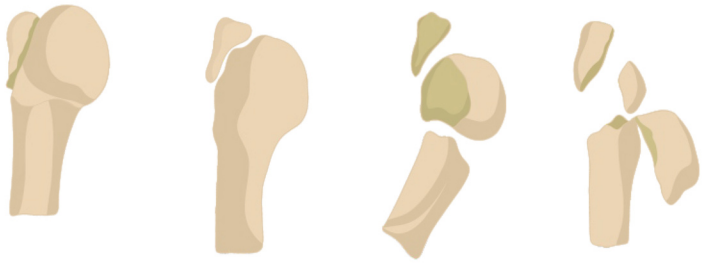

Type I	One-part fracture: Fracture line involves 1 of the 4 parts and no part is displaced.
Type II	Two-part fracture: Fracture line involves 2 of the 4 parts and 1 part is displaced.
Type III	Three-part fracture: Fracture line involves 3 of the 4 parts and 2 parts are displaced.
Type IV	Four-part fracture: Fracture line involves all the 4 parts, and 3 parts are displaced.

Q3.7: What is the significance of a four-part fracture of the proximal humerus?

Answer:

- The complication of a proximal humerus fracture is avascular necrosis.
- Overall maximum chance of avascular necrosis occurs in a four-part fracture.

Q3.8: Which type of proximal humerus fracture carries the maximum risk of avascular necrosis?

Answer: If a Two-part fracture involves the anatomical neck, it has the maximum chance of avascular necrosis.

Q3.9: How is Neer's type 1 humerus fracture managed?

Answer:

- Most fractures are undisplaced and impacted.
- Conservative treatment
- Treated with:
  - Triangular arm sling
  - Velpeau bandage

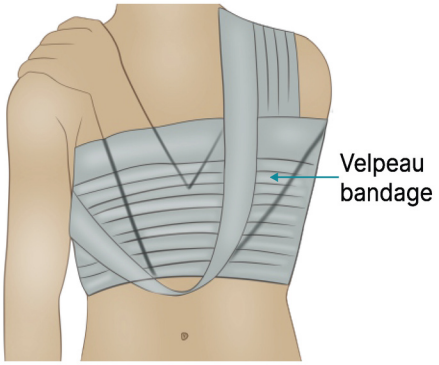

Q3.10: What are the treatment options available for Neer's type 2 humerus fracture?

Answer:

- If the surgical neck is displaced, closed reduction and arm sling or K-wire fixation are used.
- In the Greater tuberosity, displacement is mostly associated with shoulder dislocation.
- Reduction of the shoulder with open reduction and internal fixation (ORIF).
- The greater tuberosity is attached to 3 tendons: the Supraspinatus, the Infraspinatus, and the Teres minor

Q3.11: How is Neer's type 3 humerus fracture managed?

Answer:

- Open reduction and internal fixation (ORIF) with the PHILOS plate.
- PHILOS: Proximal humerus interlocking system.

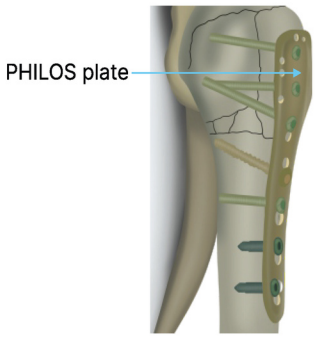

Q3.12: How is Neer's type 4 humerus fracture managed?

Answer:

- High chance of AVN.
- Arthroplasty: Shoulder joint replacement.

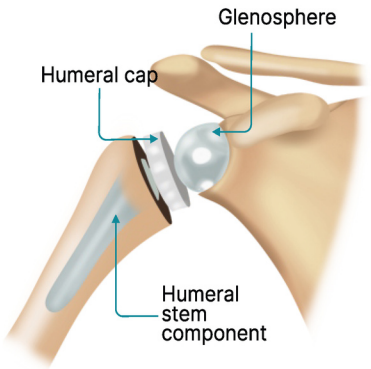

Q3.13: What are the complications of a proximal humerus fracture?

Answer:

- Joint stiffness - most common
- Avascular necrosis
- Axillary nerve injury - the most common nerve injury
- Suprascapular nerve injury - the second most common
- Non-union of the surgical neck
- Fracture-dislocation of the shoulder
- Myositis ossificans
- Malunion

Q3.14: What are the key features of the shaft of humerus fracture and its management?

Answer:

- Most common mechanism: Direct injury
- Most common nerve injury: Radial nerve neuropraxia

Q3.15: How is the shaft of the humerus fracture managed?

Answer:

- Conservative: Hanging arm cast
- Surgical: Plate fixation, interlocking nails
  - Open reduction and internal fixation with plate and screw
  - Plate osteosynthesis
  - Post-op wrist drop due to radial nerve neuropraxia

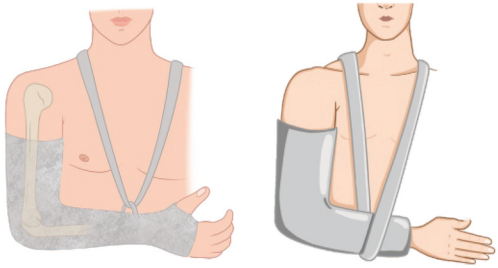

Hanging arm cast

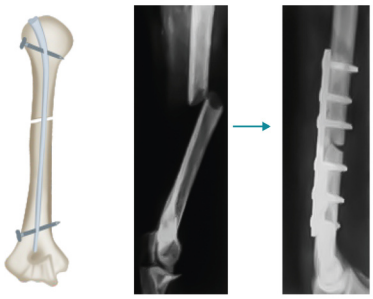

RT nailing technique Plate osteosynthesis

Q3.16: What is a Holstein-Lewis fracture, and why is it important?

Answer:

- Fracture of the distal 1/3rd of the humeral shaft - usually an oblique or spiral fracture with the distal end deviating radially → high chance of radial nerve palsy
- Cannot be treated conservatively- requires decompression if nerve compressed + fixation with plate and screw



Holstein-Lewis's fracture

Q3.17: What surgical technique can reduce radial nerve injury risk?

Answer: Russell-Taylor's (RT) nailing technique.

BIG QUESTION 4: What is the epidemiology, mechanisms, displacement patterns, and classification of supracondylar fracture of the humerus?

PYQ: NEET PG 2022 PYQ: FMGE 2019

Broad Answer: Supracondylar fracture is the most common fracture in children (5-6 years), especially boys, usually affecting the left side due to FOOSH injury. The extension type is most common, with displacement patterns remembered by DIM (Dorsal, Impaction, Medial tilt/shift). Gartland classification divides fractures into Types I-III based on displacement, guiding treatment. The most common nerve injured is the anterior interosseous nerve (AIN), and the most common vessel injured is the brachial artery.

DETAILED QUESTIONS

Q4.1: What is the epidemiology of supracondylar fracture?

Answer:

- The most common fracture in children.
- The most common fracture requiring surgery in children.
- Peak age: 5-6 years.
- More common in boys than in girls
- More common on the left side
  - Because most people are right-handed, whenever we fall, our left hand unconsciously comes forward first for defense(as it is less used).
  - Fall on outstretched hand(FOOSH).

Q4.2: Why are children <10 years old more prone to supracondylar fractures?

Answer:

- Active bone remodeling → weaker bone.
- Less cylindrical: Flat appearance, easy to break.
  - Adults have a cylindrical appearance.

YOURWISH

- Metaphysis is just distal to 2 fossae: Coronoid fossa & Radial fossa
- The cortex is thin.
- Ligamentous laxity allows hyperextension → Linear forces convert to bending force.

Q4.3: What is the common mechanism of injury?

Answer:

- Most common: FOOSH with the elbow in full extension.
- With forced elbow hyperextension, the olecranon forcefully pushes into the olecranon fossa. It acts as a fulcrum, while the anterior capsule simultaneously provides a tensile force on the distal humerus at its insertion.

Q4.4: What are the types and displacement patterns in supracondylar fractures?

Answer:

- Displacement of distal fragments: Mnemonic- **DIM**
  - o **D**orsal displacement (extension)
  - o **I**mpaction (proximal shift)
    - → Impaction of the distal fragment to the proximal fragment.
  - o **M**edial tilt/shift (pronation)
- Extension type:
  - o Most common: 98%
  - o Also called the posterior type.
  - o Divided into 2 subtypes: Posterior-lateral & Posterior-medial
- Flexion type: Less common (2%)

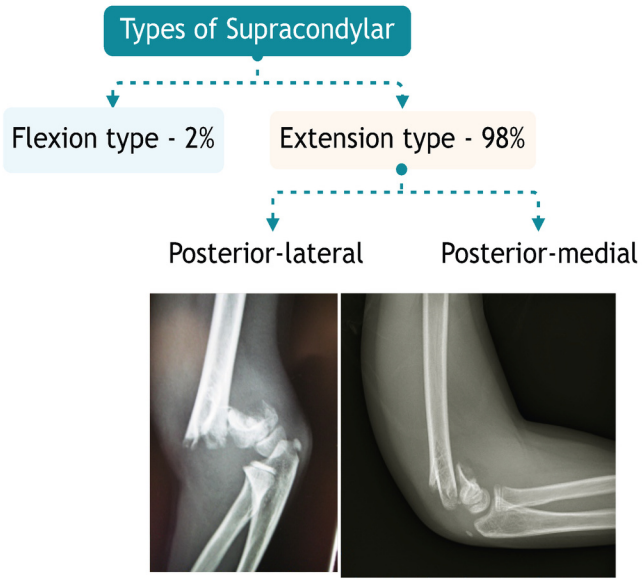

Q4.5: What is the difference between the postero-medial and postero-lateral extension type supracondylar fracture?

Answer:

Posteromedial	Posterolateral
• Most common: 80% • The dorsal fragment was displaced posteriorly and shifted medially. • Fragment injures the Radial nerve.	• Less common: 20%. • Injures anterior interosseous nerve (AIN). o Branch of the median nerve.

Q4.6: In supracondylar fractures of the humerus, which type is associated with more nerve injuries, and what is most commonly nerve injured?

Answer:

- The posterolateral type is associated with more nerve injury than the posteromedial type.
- Hence, the most common nerve injury in the supracondylar fracture is the Anterior Interosseous nerve (AIN).

Q4.7: What is the Gartland classification?

Answer:

Type 1	• Hairline fracture. • **No displacement** of the posterior and anterior cortex. • Undisplaced fracture.

Type 2	• The fracture line runs between the anterior and **posterior cortex.** • Anterior cortex displaced. • The posterior cortex is intact. • **Partial displacement.**
Type 3	• Completely displaced anterior and posterior cortex. • **Dangerous fracture.**

Gartland Classification

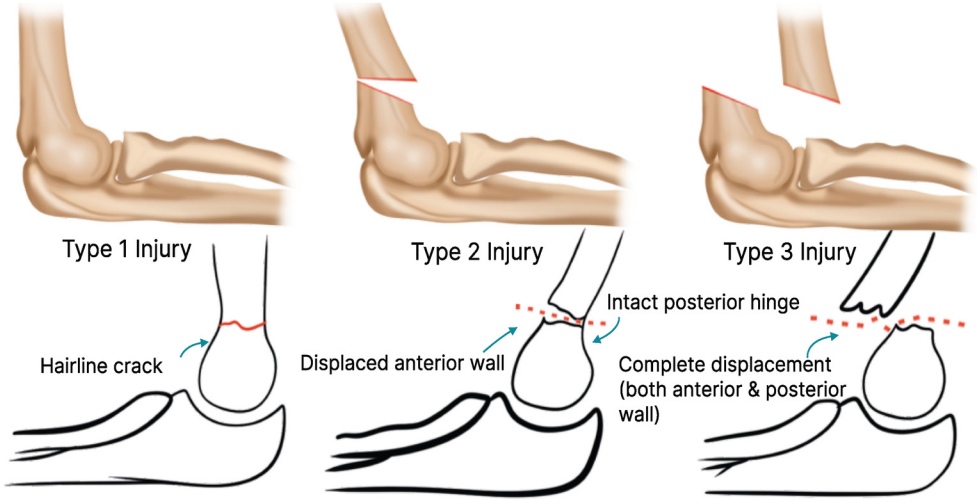

BIG QUESTION 5: What are the clinical features, radiological signs, treatment options, and complications of supracondylar fracture?

Broad Answer: Clinically, displaced fractures show S-shaped deformity, the dimple sign, and preservation of the bony triangle. Lateral view X-ray signs include fat pad sign, disturbed teardrop sign, altered anterior humeral line, and fishtail sign. Management depends on displacement: Type I - casting; Type II - closed reduction + K-wire; Type III - ORIF with K-wire. Complications include AIN injury, brachial artery injury, malunion (cubitus varus), Volkmann's ischemia, myositis ossificans, and Metev's sign in late stages.

DETAILED QUESTIONS

PYQ: FMGE 2019

Q5.1: What are the clinical features of a supracondylar fracture?

Answer:

- S-shaped deformity - seen in Type III
- Dimple sign - skin puckering near the fracture site, seen in Type III
- Bony triangle (radial epicondyle, lateral epicondyle, olecranon) preserved in fracture, altered in elbow dislocation



Q5.2: What are the key X-ray signs on the lateral view?

PYQ: INICET 2020

Answer:

5 Classical signs

- **Fat pad sign**

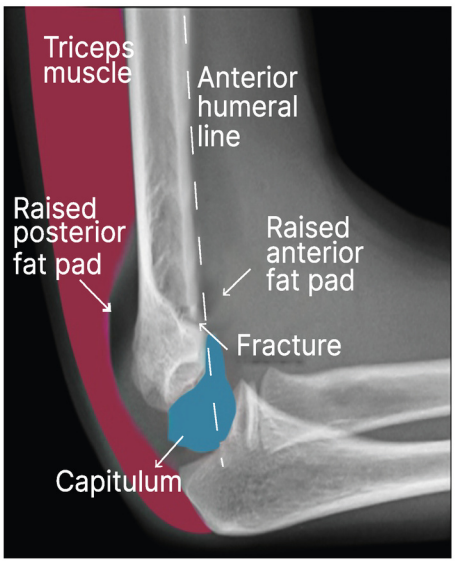

- **Soft tissue signs are** shown in an x-ray.
- A translucent **shadow-like** appearance is seen in the diagram.
  → It is a posterior fat pad.
  → An anterior fat pad is also seen.

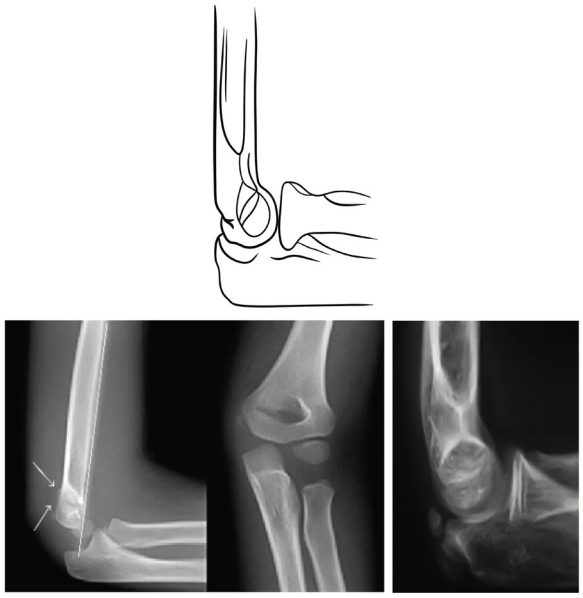

- **The teardrop sign is** normally present in every individual.
  - Disturbed in **supracondylar fracture.**

- **Anteriorhumeralline**



- StraightlinefromAHLcrossesthecapitelluminnormal individuals.
- Insupracondylarfracture,Ahldoesnotcutthe capitulum

- **Marion's Crescent sign**

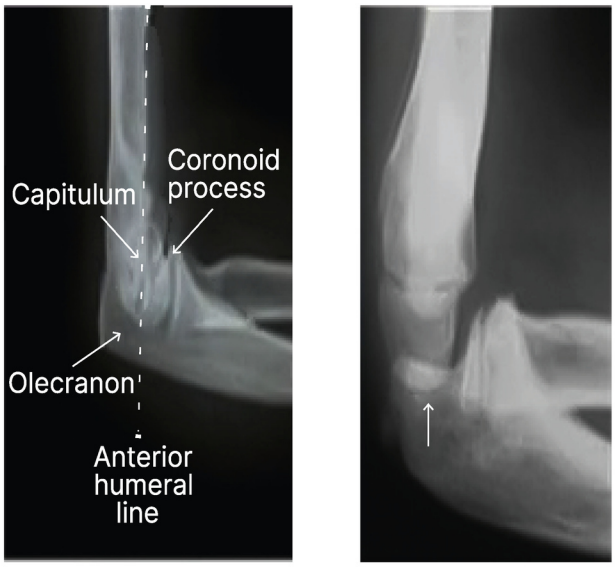

- The normal radiolucent gap of the elbow joint is missing, and it is a crescent-shaped shadow due to the overlap of the olecranon over the capitulum
- Indicates either varus or valgus tilt of the distal fragment.

YOURWISH

- **Fishtail sign**

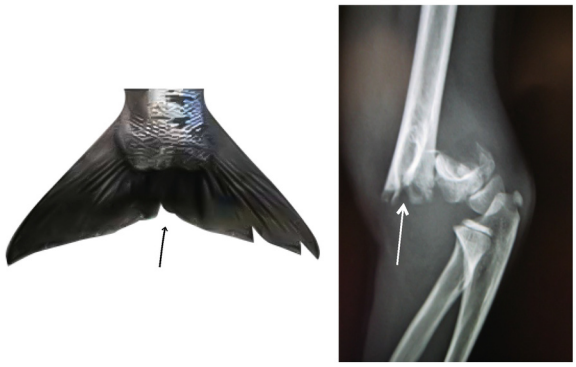

  - The ends of the proximal fragment are a little widened and serrated.
  - Resembles a **fishtail.**
- All the X-ray signs are **lateral view signs.**

Q5.3: What is the management based on the type of supracondylar fracture?

Answer:

Type 1	• **Undisplaced fracture.** • Immobilization in a long arm cast at **60 to 110 degrees** flexion. • It is indicated for 2 to 3 weeks. • The triceps acts like **a splint** and prevents the disturbance of the fracture. • Medial and lateral tilt are corrected first, and the posterior displacement is next. The AE slab is given with the elbow in hyperflexion and the forearm in a pronated position.
Type 2	**Closed reduction** with percutaneous K-wire fixation.
Type 3	Open reduction internal fixation with *K-wire*.

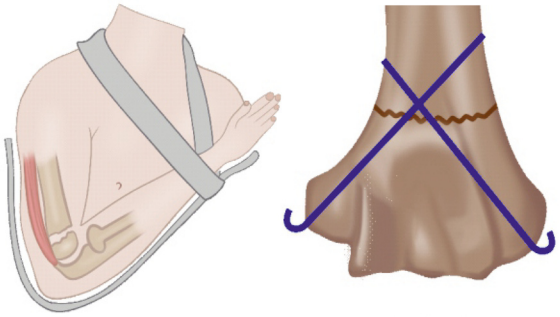

Long arm cast K-wire fixation

Q5.4: What are the major complications?

Answer:

- Most common nerve injury: Anterior interosseous nerve (branch of the median nerve)
- Most common artery injury: Brachial artery
- Most common late complication: Malunion → cubitus varus (gunstock deformity)
- Volkmann's ischemia, compartment syndrome
- Myositis ossificans

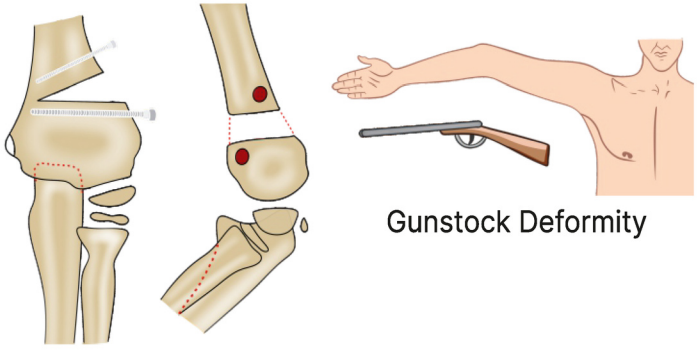

Gunstock Deformity

YOURWISH

Q5.5: What is Metev's sign?

Answer:

- Seen in myositis ossificans after a supracondylar fracture
- Median nerve entrapped in ossified tissue - X-ray shows an opaque mass with a hole-like appearance in the middle where the median nerve pierces
- This non-opaque structure is called Metev's sign
- Indicates late-stage myositis ossificans

BIG QUESTION 6: What are the key features and classification of lateral condyle fractures of the humerus in children?

Broad Answer: Lateral condyle fracture is the second most common childhood fracture, also called Jupiter fracture or fracture of necessity (always requiring surgery). It usually occurs between 5-15 years, often from a varus injury with an extended elbow. Classified by Milch, it is diagnosed by clinical signs and X-ray, though the latter may underestimate the fragment size. Management is open reduction and internal fixation with a K-wire.

DETAILED QUESTIONS

Q6.1: What are the distal fragment fractures?

Answer:

- Supracondylar fracture
- Lateral condyle fracture

Q6.2: What is the epidemiology, mechanism, and synonyms of a lateral condyle fracture?

Answer:

- Epidemiology: 2nd most common fracture in children; most common age group is 5-15 years
- Mechanism: Fall on an outstretched hand with the elbow extended and forced into varus → varus injury
- Synonyms: Jupiter fracture, Fracture of necessity (100% require surgery; another example is Galeazzi fracture)

Q6.3: What are the developmental features of the lateral condylar epiphysis?

Answer:

- Also called capitular epiphysis
- Begins ossifying during the 1st year of life
- Fuses with the shaft between 12-16 years

Q6.4: What is the Milch classification of lateral condyle fractures?

Answer:

Type 1	Type 2
• Fracture line lateral to the trochlea into the capitulotrochlear groove. • Salter-Harris type IV. • Elbow stable (no dislocation).	• Fracture line into the apex of the trochlea. • Salter-Harris type II • Elbow unstable • Most common type

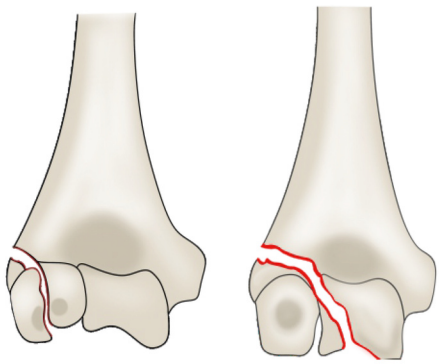

Q6.5: What are the clinical and radiological signs of a lateral condyle fracture?

Answer:

- Clinical: Three bony points not well maintained; increased intercondylar distance; the triangle formed by the three bony points is not isosceles
- Radiology: X-ray often shows a smaller fragment due to the cartilaginous part being invisible



Posterior dislocation

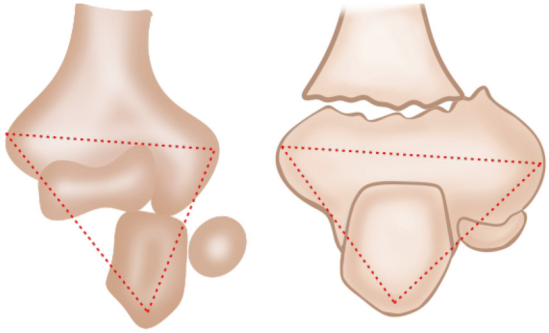

Q6.6: What is the treatment of a lateral condyle fracture?

Answer: Always open reduction and internal fixation with K-wire (because it is a fracture of necessity).

Q6.7: What are the common complications of a lateral condyle fracture?

Answer:

- Most common: Lateral condylar spur (overgrowth in the lateral condyle)
- Non-union (very common)
- Cubitus valgus (progressive type of valgus; due to growth plate injury; treated by Milch osteotomy)
- Tardy ulnar palsy (due to cubitus valgus, causing ulnar nerve stretching)
- Posterolateral instability of the elbow
- Cubitus varus (rare)
- Myositis ossificans

BIG QUESTION 7: What are the types, clinical features, treatment, and complications of elbow dislocation and pulled elbow?

Broad Answer: Elbow dislocation is the most common joint dislocation in children, most often the posterior type, with the posterolateral variant being more common. Clinical signs include a shorter forearm, altered three bony points, and the bowstring sign. Management involves reduction under general anesthesia with immobilization. Complications may include brachial artery and median nerve injury. Pulled elbow (nursemaid's elbow) occurs in young children when the radial head subluxates from the annular ligament, often after sudden traction on an extended, pronated forearm. It is associated with characteristic ages of appearance of the elbow epiphyseal centers.

DETAILED QUESTIONS

Q7.1: What are the types of elbow dislocation?

Answer:

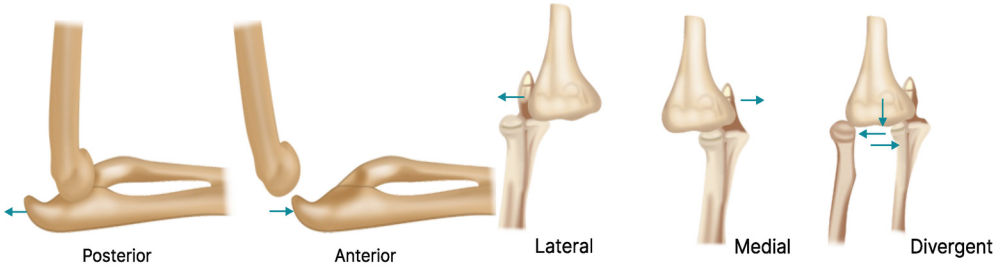

- Posterior Elbow Dislocation - Most common type; olecranon is posterior to the humerus.
  - o Subtypes:
    - → Posterolateral (more common)
    - → Posteromedial
    - → Divergent
- Anterior Elbow Dislocation - Olecranon is anterior to the humerus.

Q7.2: What are the key clinical features of elbow dislocation?

Answer:

- Shorter forearm compared to the unaffected side
- Alteration of the three bony points around the elbow
- Olecranon pushed backward in a posterior dislocation
- Bowstring sign (classical sign): Triceps tendon appears prominent, resembling a bowstring



Posterior dislocation

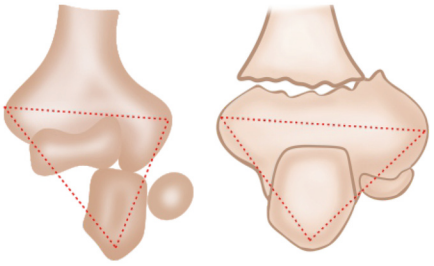

Q7.3: What is the "Terrible Triad" of the elbow and its alternate name?

Answer:

- Known as the **Hotchkiss Triad**
- Includes:

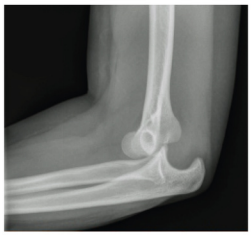

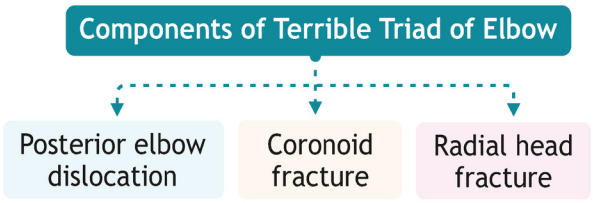

Q7.4: What is the standard treatment for elbow dislocation?

Answer:

- Reduction under General Anesthesia (GA)
- Immobilization with above-elbow POP cast for 3 weeks

Q7.5: What are the common complications of elbow dislocation?

Answer:

- Most common vessel injured: Brachial artery
- Most common nerve injured: Median nerve (followed by ulnar and radial nerves)

Q7.6: What is a pulled elbow, and in which age group is it most common?

PYQ: NEET PG 2020

Answer:

- Also called Nursemaid's elbow
- Occurs when a sudden pull on an extended and pronated forearm causes the radial head to subluxate from the annular ligament, often with an audible snap
- Most common in: Children aged 1 to 4 years
- Rare after 5 years

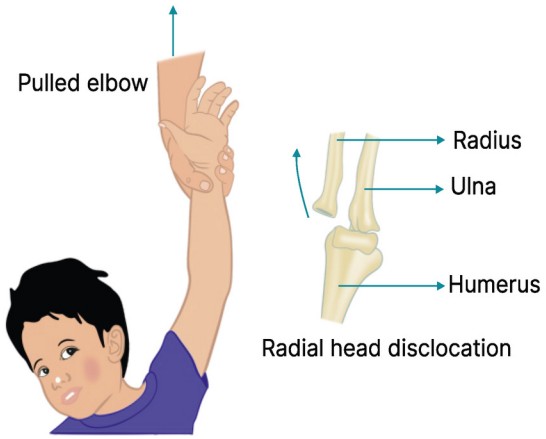

YOURWISH

Q7.7: What are the ages of appearance of epiphysial centers around the elbow joint?

Answer:

Mnemonic: **CRETOL**

- **C** - Capitulum: 2 years
- **R** - Radial head: 4 years
- **E** - Medial Epicondyle: 6 years
- **T** - Trochlea: 8 years
- **O** - Olecranon: 10 years
- **L** - Lateral epicondyle: 12 years

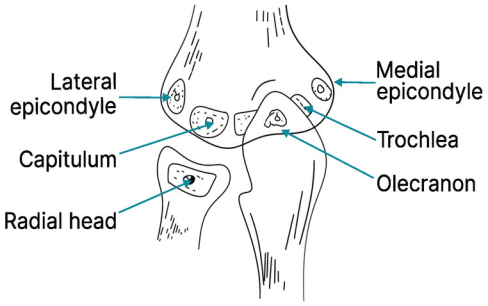

BIG QUESTION 8: What are the features, classification, treatment, and complications of a Monteggia fracture?

Broad Answer: A Monteggia fracture is a fracture of the upper third of the ulna with radial head subluxation, most often due to FOOSH (fall on outstretched hand) with hyperpronation injury. It is more common in children. Bado's classification describes four types based on the direction of radial head dislocation and fracture angulation. Diagnosis requires careful X-ray evaluation to avoid missing the radial head injury. Treatment differs between children and adults, and complications can involve nerve injury, malunion, and joint deformities.

DETAILED QUESTIONS

Q8.1: What is the definition and common cause of a Monteggia fracture?

Answer:

- Fracture of the upper third of the ulna with radial head subluxation
- Commonly caused by FOOSH, especially with hyperpronation injury
- Occurs more often in children



Q8.2: What is Bado's classification of the Monteggia fracture?

Answer:

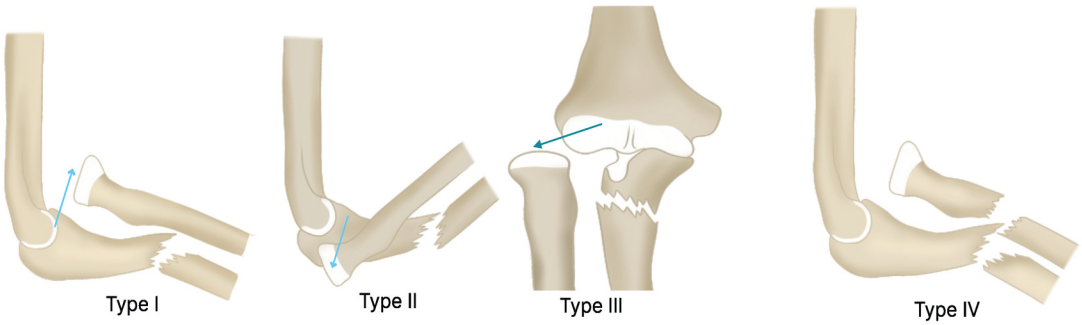

- **Type 1 (Extension type):** 60% of cases; most common in children; anterior dislocation of the radial head with anterior angulation of the ulnar fracture.
- **Type 2 (Flexion type):** 5%; most common in adults; posterior dislocation of the radial head with posterior angulation of the ulnar fracture.
- **Type 3:** 20%; lateral dislocation of the radial head; seen exclusively in children.
- **Type 4:** Anterior dislocation of the radial head with fractures of both radius and ulna at the same proximal level; exclusively in adults.

Q8.3: Which nerve injuries are associated with a Monteggia fracture, and which type is most commonly affected?

Answer:

- Posterior interosseous nerve and radial nerve injuries are most common
- Overall, nerve injury is most common in Type 2 fractures

Q8.4: Why is the Monteggia fracture called a "Treacherous fracture," and what precautions should be taken in X-ray evaluation?

Answer:

- Called "Treacherous fracture" because the ulnar fracture is easily seen, but the radial head injury can be missed
- Recommended to take an X-ray of one bone above and one bone below the forearm fracture site
- McLaughlin's line is used to confirm radial head alignment on X-ray

Q8.5: What is Mclaughlin's line?

Answer:

Draw a straight line along the center of the shaft of the radius

↓

Extend the line so that it cuts the capitulum, irrespective of the position of the elbow

↓

If the line doesn't cut the capitulum - it indicates radial head dislocation.

↓

Presence of Monteggia Fracture

Q8.6: What is the treatment of choice for a Monteggia fracture in children and adults?

Answer:

- Children: Closed reduction with above-elbow POP cast
- Adults: ORIF (Open Reduction and Internal Fixation) with plate and screw

Q8.7: What are the possible complications of a Monteggia fracture?

Answer:

- Unreduced dislocation of the radial head
- Posterior interosseous nerve palsy
- Malunion or non-union of the ulna
- Cubitus valgus
- Radioulnar synostosis
- Myositis ossificans

BIG QUESTION 9: What are the clinical features, treatment, complications, and related concepts of Galeazzi fracture?

Broad Answer: Galeazzi fracture is a fracture of the lower third of the radius with distal radioulnar joint (DRUJ) subluxation. It is also called Piedmont fracture, Fracture of necessity (requiring 100% surgical intervention), or Reverse Monteggia fracture. It presents with ulnar prominence and tenderness, is more common in adults, and is three times more common than a Monteggia fracture. ORIF with a long plate and screw is the treatment of choice. Complications include ulnar nerve injury (Apley), anterior interosseous nerve injury (Watson-Jones), and rare entrapment of the extensor carpi ulnaris tendon. Galeazzi's sign, a separate entity, is used for detecting DDH or CDH by comparing knee levels in a flexed hip/knee position.



DETAILED QUESTIONS

Q9.1: What is the definition and alternative names for the Galeazzi fracture?

PYQ: AIIMS 2019 PYQ: FMGE 2020

Answer:

- Definition: Fracture of the lower third of the radius with distal radioulnar joint (DRUJ) subluxation
- Other names:
  - Piedmont fracture
  - Fracture of necessity (100% surgery is necessary)
  - Reverse Monteggia fracture

Q9.2: What are the two fractures of necessity in orthopedics?

Answer:

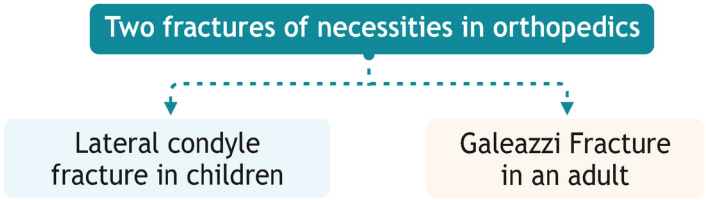

Q9.3: What are the key clinical features of a Galeazzi fracture?



Answer:

- Main feature: Prominence and tenderness of the lower end of the ulna
- Classical sign: Piano key sign
- More common in adults
- Three times more common than a Monteggia fracture

Q9.4: What is the treatment approach for a Galeazzi fracture?

Answer:

- Conservative treatment: Not recommended (100% surgery is necessary)
- Treatment of choice: ORIF with long plate and screw (Asian Dynamic Compression Plate)

Q9.5: What are the common complications of a Galeazzi fracture?

Answer:

- Most common (according to Apley): Ulnar nerve injury
- Most common (according to Watson Jones): Anterior interosseous nerve injury
- Rare: Entrapment of the extensor carpi ulnaris tendon

Q9.6: What is Galeazzi's sign, and how is it performed?

Answer:

- Definition: A clinical sign seen in congenital dislocation of the hip (CDH) and Developmental dysplasia of the hip (DDH)
- Also called the Allis test
- Procedure:
  1. Make the baby lie supine.
  2. Flex both hip joints to 90°.
  3. Flex both knee joints to 90°.
  4. Observe the knee joint levels. If both are leveled, it is normal
- Interpretation: If the knee level is lower on the affected side → suggests DDH

BIG QUESTION 10: What are the different types of forearm and wrist fractures, including Essex-Lopresti fracture, Radial Styloid fracture, and Barton fracture, along with their features, diagnosis, and treatment?

Broad Answer: Forearm and wrist fractures include the Essex-Lopresti fracture, Radial Styloid fracture (Chauffeur's fracture), and Barton fracture (volar and dorsal types). Each has distinct anatomical features, mechanisms, diagnostic findings, and treatment protocols, ranging from closed reduction and casting to open reduction and internal fixation (ORIF) with specialized plates or prostheses.

DETAILED QUESTIONS

Q10.1: What are the key features and diagnosis of the Essex-Lopresti fracture?

Answer:

- Definition: A combination of Monteggia fracture and Galeazzi fracture.
- Anatomy: Comminuted fracture of the radial head with distal radioulnar subluxation.
- Clinical feature: Wrist pain is the most sensitive sign.
- Diagnosis: Best diagnosed by a lateral X-ray of the wrist.

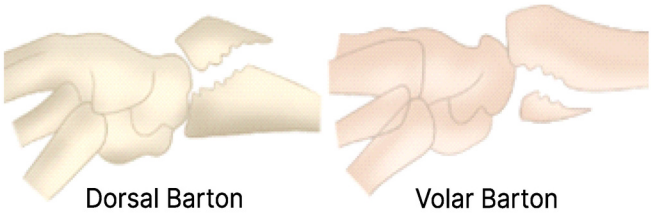

Dorsal Barton Volar Barton

Q10.2: How is the Essex-Lopresti fracture managed?

Answer:

- Treatment:
  - If the distal radioulnar joint is disrupted → excision of the radial head.
  - Excision can cause proximal migration of the radius due to radioulnar joint disruption.
  - After excision, replace with a silastic prosthesis to prevent migration.
- Note: Essex-Lopresti classification is different—used for classifying calcaneum fractures.

Q10.3: What is the Radial Styloid fracture, and how is it treated?

Answer:

- Synonyms: Chauffeur's fracture, Hutchinson's fracture(demonstrated by Hutchinson), or backfire fracture
- Treatment:
  - Stable fracture: Closed reduction + below elbow POP cast.
  - Unstable fracture: Percutaneous K-wire fixation, followed by elbow POP cast.



Q10.4: What is the Barton fracture? The types, features, and treatment of Barton fracture?

Answer: A Barton fracture is a vertical, marginal intra-articular fracture of the lower end of the radius

Q10.5: What are the types of the Barton fracture?

Answer:

Volar Barton	• True Barton - volar chunk. • Classical Barton - most common type.
Dorsal Barton	• Dorsal chunk. • Very rare.

Q10.6: What are the treatment options available for Barton's fracture?

Answer:

- Volar Barton: ORIF with anterior T buttress plating (Ellis plate) - treatment of choice.
- Dorsal Barton: Closed reduction + above elbow POP (conservative treatment)- treatment of choice.

Q10.7: What is the key difference between a Barton fracture and Colle's fracture?

Answer:

- Barton fracture → intra-articular (joint involvement).
- Colle's fracture → extra-articular (no joint involvement).

BIG QUESTION 11: What are the key features, diagnosis, treatment, and complications of Colle's fracture, and how does it differ from the Smith fracture?

Broad Answer: A Colle's fracture, named after Sir Abraham Colle's (also called Poutteau's fracture), is an extra-articular fracture-dislocation of the distal radioulnar joint occurring ~2.5 cm above the carpal extremity of the radius. It commonly affects older people following FOOSH with a pronated dorsiflexed hand, presenting with a "dinner fork" deformity. Diagnosis relies on the styloid process test, and treatment involves closed reduction with immobilization in the Cotton loader's position. Common complications include stiffness, malunion, median nerve injury, and EPL tendon rupture. Smith fracture (reverse Colle's) differs in mechanism, displacement direction, and deformity pattern.

DETAILED QUESTIONS

Q11.1: What is the definition, anatomical location, and epidemiology of a Colle's fracture?

Answer:

PYQ: INICET 2020, 21 PYQ: FMGE 2019, 23

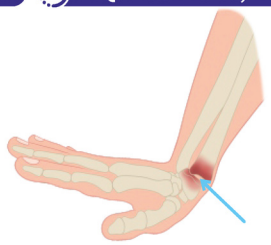

- Named after Sir Abraham Colles, also called Poutteau's fracture
- Defined as an extra-articular fracture-dislocation of the distal radioulnar joint
- Occurs about 2.5 cm above the carpal extremity of the radius at the cortico-cancellous junction
- One of the most common fractures in older people

Q11.2: What is the mechanism of injury and the "DILS" mnemonic for Colle's fracture?

Answer:

- Mechanism: FOOSH (fall on outstretched hand) with the hand in pronation and dorsiflexion
- Component:

YOURWISH

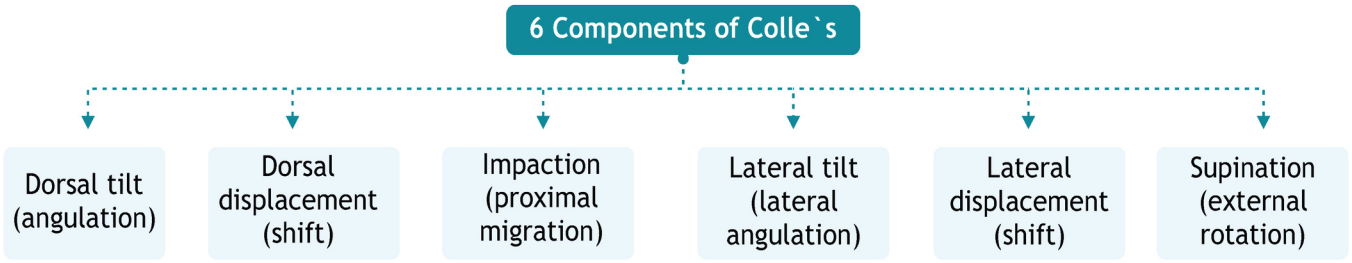

Q11.3: What is the styloid process test, and why is it important in diagnosing Colle's fracture?

Answer:

- The best test to identify Colle's fracture: The styloid process test.
- Normally, the radial styloid process is 1.3 mm lower than the ulnar styloid process
- In Colle's fracture, both styloid processes lie at the same level
- This is the most reliable clinical sign for Colle's fracture

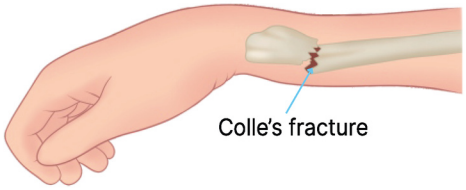

Q11.4: What is the classical deformity seen in Colle's fracture, and how is it treated?

Answer: Classical deformity: "Dinner fork" deformity

Q11.5: How is Colle's fracture treated?

Answer:

- Closed reduction followed by below-elbow POP cast for 6 weeks in full pronation with palmar flexion and ulnar deviation at the wrist (Cotton loader's position)
- Steps:

2 people are needed to perform the method
↓
Traction and countertraction are applied on the forearm - Impaction is neutralized
↓
Pronation is done - Supination is neutralized
↓
Palmar flexion is done - Dorsal displacement is neutralized
↓
Ulnar deviation at the wrist is done - Lateral tilt and displacement are neutralized.



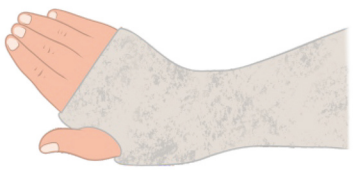

Q11.6: What are the common complications of Colle's fracture?

Answer:

- Most common: Stiffness of fingers.
- 2nd most common: Malunion (persistent dinner fork deformity).
- Most common nerve injured: Median nerve — very common cause of carpal tunnel syndrome.
- Tendon injury: Extensor pollicis longus — most commonly injured tendon.

Q11.7: How does a Smith fracture differ from a Colle's fracture in mechanism, deformity, and treatment?

Answer:

- Also called "Reverse Colle's fracture"
- Displacement direction: Ventral tilt/displacement (Colle's is dorsal)
- Mechanism: FOOSH with the hand pronated and palmar-flexed
- Classical deformity: "Garden spade" deformity
- Treatment: Closed reduction + above-elbow POP in extension for 6 weeks; if not reducible, open reduction with Ellis plate fixation

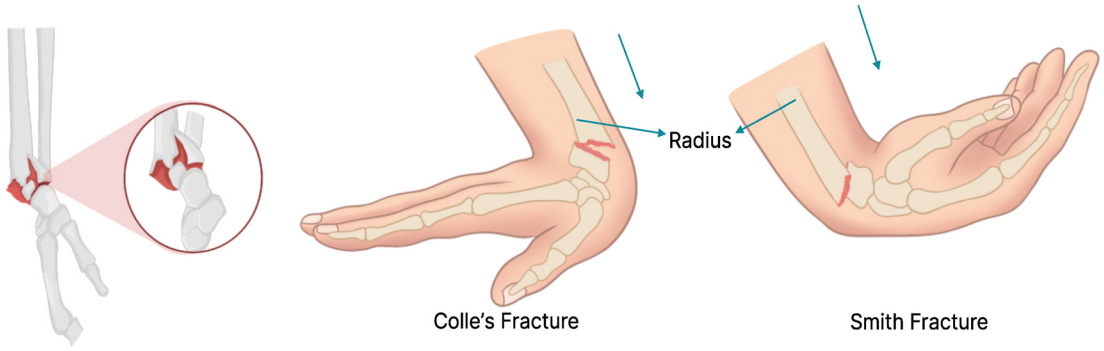

Q11.8: What are the 4 important distal fragment fractures of the distal radius?

Answer:

- Radial styloid fracture
- Barton fracture
- Colle's fracture
- Smith fracture

BIG QUESTION 12: What is the anatomy, clinical features, investigations, and management of scaphoid fracture?

Broad Answer: The scaphoid is the most commonly fractured carpal bone, followed by the triquetrum, trapezium, and lunate. It articulates with five bones and uniquely lies across both the proximal and distal carpal rows. Blood supply from the radial artery flows distal-to-proximal, predisposing the proximal pole to avascular necrosis. Most fractures occur at the waist (>70%), commonly in young adults due to FOOSH injury. Clinical signs include anatomical snuffbox tenderness and humpback deformity. Diagnosis is made via scaphoid view X-ray or MRI. Treatment depends on displacement, with scaphoid casting for undisplaced fractures and ORIF with a Herbert screw for displaced fractures. Complications include non-union and Preiser's disease (AVN).

DETAILED QUESTIONS

Q12.1: What are the carpal bones most commonly fractured and their order of frequency?

Answer:

- Most common: Scaphoid
- 2nd most common: Triquetrum
- 3rd most common: Trapezium
- 4th most common: Lunate

Q12.2: What is the anatomy and articulation of the scaphoid bone?

Answer:

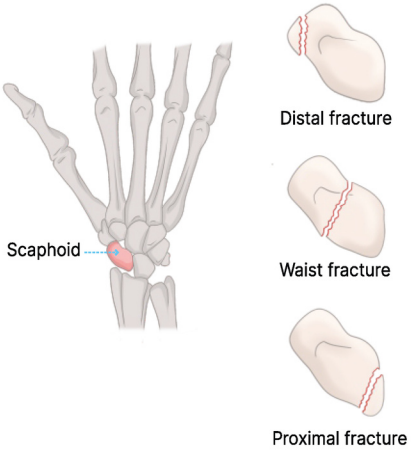

- Articulates with 5 bones: Radius, Lunate, Triquetral, Trapezium, Capitate
- Unique feature: Only bone lying on both proximal and distal rows
  - Proximal pole: Rests on the proximal row
  - Distal pole: Rests on the distal row
  - Waist: Unsupported segment

Q12.3: What is the blood supply of the scaphoid bone?

Answer:

- Blood supply: From scaphoid branches of the radial artery (distal → proximal)
  - Supplies mainly the distal pole
  - Proximal pole at higher risk for AVN

Q12.4: What is the epidemiology, common fracture sites, and mechanism of injury of scaphoid fracture?

Answer:

- Common in: Young adults
- Rare in: Children and older adults
- Most common site: Waist of scaphoid (>70%)
- Other sites: Distal area (20%), Proximal area (10%, rare)
- Mechanism of injury: FOOSH (Fall On Outstretched Hand) or kickback injury

Q12.5: What are the clinical features and deformities associated with scaphoid fracture?

Answer:

- Main clinical sign: Pain and tenderness in the anatomical snuffbox
- Deformity: Humpback deformity (displaced scaphoid fracture)
- Clinical tests:
  - Scaphoid lift test: Volar shifting causes dorsal pain
  - Watson test: Pain when the wrist moves from ulnar to radial deviation

Q12.6: What are the classical deformities associated with Colles fracture, Smith fracture, and Scaphoid fracture?

Answer:

- Fracture deformities comparison:
  - Colle's fracture → Dinner fork deformity
  - Smith fracture → Garden spade deformity
  - Scaphoid fracture → Humpback deformity

Q12.7: What are the imaging modalities used for diagnosis and follow-up in scaphoid fractures?

Answer:

- X-ray view of choice: Oblique (scaphoid view)
- If no fracture is seen, but suspicion is high:
  - Apply a scaphoid cast immediately
  - Repeat X-ray in 2-3 weeks

- If no fracture line → Remove cast after 2-3 weeks
- If healing line seen → Continue cast for a total of 8-10 weeks

- MRI: Detects fractures earlier than X-ray

Q12.8: How is a scaphoid fracture managed depending on displacement?

Answer:


Bohler-Gauntlet scaphoid cast

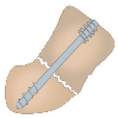
Herbert's screw

- Undisplaced fracture:
  - Scaphoid cast for 6-10 weeks
  - Bohler-Gauntlet scaphoid cast (below elbow, glass-holding position)
- Displaced fracture:
  - ORIF with Herbert's screw (headless, can be buried inside bone)

Q12.9: What are the main complications of scaphoid fracture?

Answer:

- Non-union and Avascular necrosis:
  - Proximal pole: 40%
  - Distal pole: 1%

Q12.10: What is avascular necrosis of the scaphoid bone called?

Answer: Preiser's disease

BIG QUESTION 13: What are the types, mechanisms, and treatments of Bennett's fracture, Rolando's fracture, and mallet finger?

Broad Answer: Bennett's fracture is an oblique intra-articular fracture-dislocation at the base of the 1st metacarpal, often from an axial blow during fist fighting, with the distal fragment attached to the abductor pollicis longus tendon. Rolando's fracture is a comminuted intra-articular fracture of the base of the 1st metacarpal, often T- or Y-shaped. Mallet finger results from extensor tendon injury of the terminal phalanx due to forced flexion during active extension. Management differs: Bennett's is treated with K-wire fixation, Rolando's with mini screw fixation, and acute mallet finger with splinting for 8 weeks.

DETAILED QUESTIONS

Q13.1: What is the Bennett's fracture?

Answer: **Bennett's fracture** is an oblique intra-articular fracture-dislocation at the base of the 1st metacarpal involving the metacarpophalangeal joint

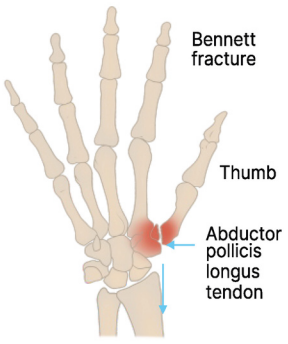

Q13.2: What is the mechanism of injury, and the key anatomical feature of Bennett's fracture?

Answer:

- Mechanism: Axial blow to partially flexed metacarpals, commonly during fist fighting (hence called “fist fighter's fracture”)
- Key anatomical feature: The Distal fragment remains attached to the abductor pollicis longus tendon

YOURWISH

Q13.3: What are the complications and treatment of Bennett's fracture?

Answer:

- Complication if untreated: Non-union.
- Treatment of choice: Open reduction with K-wire fixation.

Q13.4: What is Rolando's fracture, and how is it managed?

Answer:

- Definition: Intra-articular comminuted fracture of the base of the 1st metacarpal
- Pattern: Comminution may be T-shaped or Y-shaped
- Treatment of choice: Open reduction with mini screw fixation

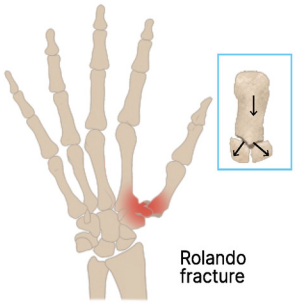

Q13.5: What is mallet finger, its mechanism, and examples of causes?

Answer:

- Other names: Baseball finger or drop finger
- Definition: Injury to the extensor tendon of the terminal phalanx
- Mechanism: Forced flexion of the distal phalanx while the extensor actively attempts to extend the finger
- Examples: Tucking a blanket under a mattress, catching a ball

Q13.6: What is the best management for acute mallet finger, and which treatments are outdated or not advised?

Answer:

PYQ: NEET PG 2019

- Best management for acute mallet finger: Splinting with a Mallet Finger splint for 8 weeks
- Outdated: Smilies cast
- Not advised: Surgery, even with fracture-dislocation

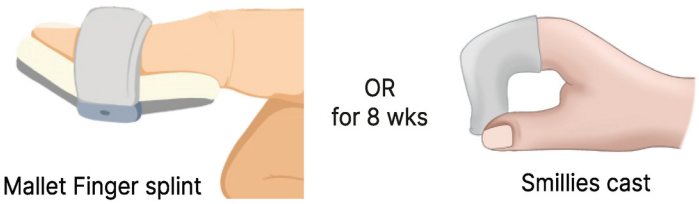

BIG QUESTION 14: What are the major vessels and nerves injured in upper limb fractures, and what are the key named fractures with their defining features?

Broad Answer: Upper limb fractures can be associated with specific vessel and nerve injuries depending on the fracture site. Common vessel injuries include subclavian, axillary, brachial, and anterior interosseous arteries. Nerve injuries vary from axillary, radial, and median to ulnar and interosseous nerves. Named fractures in the upper limb have distinctive anatomical patterns, mechanisms, and clinical associations that guide diagnosis and management.

Q14.1: What are the major vessels injured in specific upper limb fractures?

Answer:

Fractures	Vessel
Clavicle fracture	Subclavian
Proximal humeral fracture	Axillary
SOH (Shaft of the humerus) fracture	Brachial
Supracondylar fracture	Brachial
Posterior dislocation of the elbow	Brachial
Fracture both bones of the forearm.	Anterior Interosseous vessel

Q14.2: What are the major nerves injured in specific upper limb fractures?

Answer:

Fracture	Nerves Injured
Clavicle fracture	Medical cord- Ulnar nerve
Proximal humerus fracture	Axillary nerve
SOH (Shaft of the humerus) fracture	Radial nerve
Supracondylar fracture	Anterior Interosseous nerve
Posterior dislocation of the elbow	Median nerve
Monteggia Fracture	Posterior Interosseous nerve
Hook of hamate	Deep Branch of ulnar nerve
Wrist injury	Median nerve

Q14.3: What are the defining features of fractures of the upper limb?

Answer:

Holstein Lewis fracture	• Distal 3rd humerus fracture. • Oblique in nature. • Causes radial nerve palsy.
Monteggia fracture	• Fracture of upper 3rd ulna. • Proximal radial head dislocation
Galeazzi Fracture	• Fracture of lower 3rd radius. • Distal radioulnar subluxation
Piedmont fracture	• Another name for Galeazzi fracture
Treacherous fracture	• Another name for Monteggia fracture.
Fracture of necessity	• Lateral condyle fracture of humerus in children. • Galeazzi Fracture.
Essex Lopresti Fracture	• Is a combination of Monteggia and Galeazzi fracture. • Comminuted fracture of the radial head with distal radioulnar subluxation.
Nightstick fracture	• Isolated crack fracture of the ulna. • 99% caused by assault. • Above elbow POP slab - treatment of choice.
Poutteau's fracture	• Colle`s fracture
Smith fracture	• Reverse colle`s fracture.
Barton Fracture	• It is a vertical, marginal intra-articular fracture of the lower end of the radius.
Hutchinson's fracture	• Radial styloid fracture or Chauffeur's fracture.
Bennett fracture	• Oblique intra-articular fracture dislocation of the base of the 1st Metacarpal
Rolando fracture	• Intra-articular comminuted fracture of the base of the first metacarpal.
Boxer's fracture	• Crack fracture of shaft of the 5th metacarpal.
Malgagnian fracture	• Supracondylar fracture.
Baby Car fracture	• **Uncommon in India.** • Sideswipe injury of the elbow of a baby in the car. • Shattering the elbow of the baby. • **Poor prognosis**

6. LOWER LIMB TRAUMA

BIG QUESTION 1: Explain the key clinical features, blood supply concerns, classification, and management principles of fracture neck of femur, highlighting why it is called the "unsolved fracture of femur" and the implications for prognosis and treatment.

Broad Answer: Fracture neck of the femur occurs mainly in elderly osteoporotic women after a minor fall, causing limb shortening and external rotation. It's "unsolved" due to high risk of avascular necrosis from poor blood supply.
Classified by fracture site and displacement, prognosis worsens with displacement. Early surgery within 24 hours is essential; treatment ranges from fixation to joint replacement, depending on fracture type and age.

DETAILED QUESTIONS

Q1.1: What is the other name for the fracture neck of the femur?
Answer: Unsolved fracture of the femur

Q1.2: Which population is most commonly affected by the fracture neck of the femur and why?
Answer: Elderly females (Post menopause) due to osteoporosis.

Q1.3: What is the most common mechanism causing a fracture neck of the femur?
Answer:

- Trivial fall because of a direct blow over the greater trochanter
- Mostly, it will be a pathological condition

Q1.4: What are the three main mechanisms responsible for causing a fracture neck of the femur?
Answer:

- Trivial fall
- **2nd most common** mechanism - lateral rotation
- The most recent mechanism suggested is **cyclical loading**

Q1.5: What are the characteristic clinical features of the affected limb in a fracture neck of the femur?
Answer:

- Apparent shortening limb
- Externally rotated limb

Q1.6: What are the main sources of blood supply to the femoral head?
Answer: PYQ: INICET 2022 PYQ: FMGE 2019, 23 PYQ: AIIMS 2019

- **Retinacular vessels:** Major supply
  - The deeper femoral artery gives the Medial circumflex femoral and Lateral circumflex femoral arteries; from these, the retinacular vessels arise
- Intraosseous cervical and blood vessels: 2nd most important
- Artery of ligamentum teres: 3rd most important
  - Also called a Foveolar Vessel.

YOURWISH

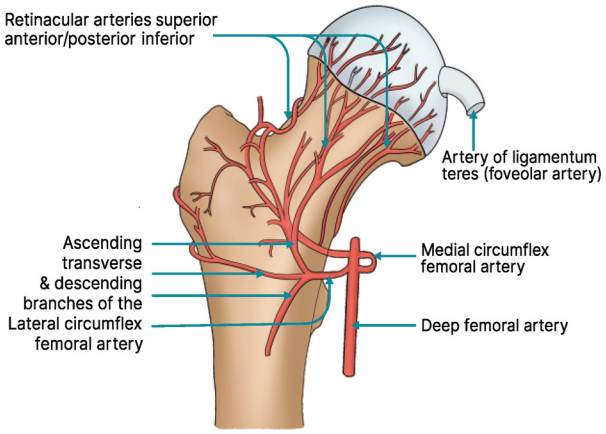

Q1.7: Why does fractured neck of the femur often lead to avascular necrosis and non-union?

Answer:

- In a fractured neck of femur, the blood supply to the neck of the femur stops as the vessels are damaged, leading to Avascular necrosis
- 90% of cases don't heal, causing non-union due to lack of blood supply

Q1.8: What are the reasons for delayed union or non-union in intracapsular fracture neck of femur?

Answer:

- Synovial fluid contains an enzyme called lysin, which lyses blood clots at the fracture site
- No cambium layer in the intracapsular area, so very poor callus formation
  - Normally not present in the neck of the femur.
  - Layer of periosteum
  - Helps in callus formation
  - Deficiency of the cambium layer, so remodelling is very low naturally
- Less vascular

Q1.9: What is the broad classification of the fracture neck of the femur?

Answer:

- Intracapsular: Inside the joint, 90%
- Extracapsular: Outside the joint, 10%

Q1.10: What is the anatomical (intracapsular) classification of the neck of the femur?

Answer:

- **Sub capital**
  - Fracture just below the head of the femur
  - Most common
  - Worst prognosis
  - Higher chances of avascular necrosis and nonunion
- **Transcervical**
  - The middle part of the neck of the femur
- **Basicervical**
  - Base of the neck of the femur
  - Below this, it becomes extracapsular

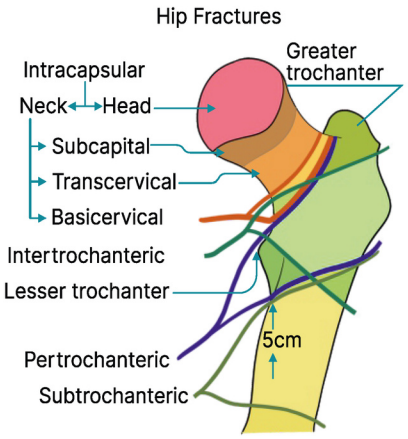

YOURWISH

YOURWISH

Q1.11: What is Pauwel's classification of the fracture neck of the femur?

Answer:

- **Pauwels angle**
  - On the fractured neck of the femur a horizontal line is drawn - Pauwels's line
  - The angle between the Pauwels' line and the fracture neck of the femur - Pauwels angle
- Type 1: Angle < 30^0
- Type 2: Angle between 30^0 to 50^0
- Type 3: Angle > 70^0
- **As the angle increases, the prognosis becomes worse**

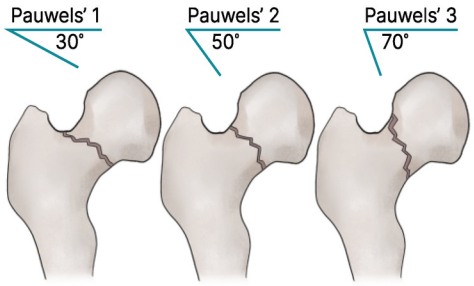

Q1.12: What is Garden's classification of fracture neck of femur, and how does it relate to fracture displacement and prognosis?

Answer:

- Based on
  - Completeness or incompleteness of the fracture line
  - Displacement of fracture
  - Trabecular pattern in X-ray of the Head of the femur, Neck of the femur, and the Acetabulum
- **Grade 1**
  - Incomplete fracture line (valgus impacted)
  - Normal alignment of trabeculae between the acetabulum, head, and neck
  - Best prognosis
- **Grade 2**
  - Complete fracture
  - No displacement (undisplaced)
  - Trabecular pattern is maintained
- **Grade 3**
  - Complete fracture
  - Partial displacement
  - Trabecular pattern of femoral head - not aligned with the acetabulum and neck
- **Grade 4**
  - Complete fracture
  - Total displacement
  - Distal fragments get externally rotated. The head comes in a normal position
  - The trabecular pattern of the head is parallel to the acetabulum and neck
  - Worst prognosis.

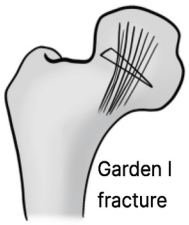

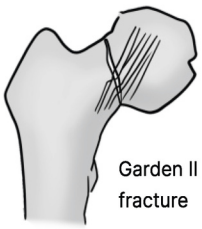

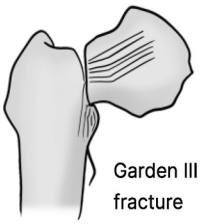

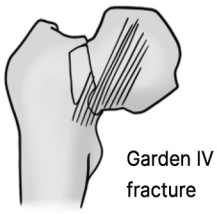

Q1.13: What is the classification of a fracture neck of the femur that is intracapsular?

Answer:

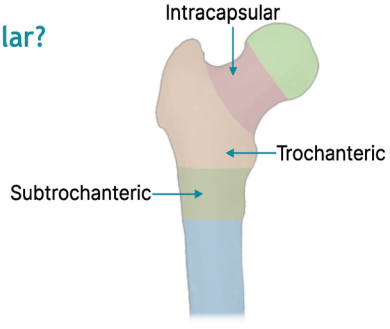

Q1.14: Which classification system is used for pediatric fracture neck of femur, and how common is this condition in children?

Answer: Pediatric fracture neck of femur is very rare, and it is classified using Delbet's classification

Q1.15: What are the key clinical manifestations of a fracture neck of the femur?

Answer:

- Tenderness over the anterior joint line - below and lateral to from mid inguinal point. 2.5 cm
- Shortening of the limb
- Externally rotated limb
- The vascular sign of Narath is positive

Q1.16: Which X-ray view is recommended for diagnosing a fracture neck of the femur, and what is the characteristic radiological sign?

Answer:

- X-ray pelvis with both hips - AP is the recommended X-ray
- Characteristic sign - breakage of Shenton's line

Q1.17: What is Shenton's line and how is it used to diagnose the fracture neck of the femur?

Answer:

- Line drawn from the superior margin of the obturator foramen to the margin of the neck
- Gives a smooth curve
- Breakage of Shenton's line - the smooth curve is disrupted
  - Happens in the fracture neck of the femur

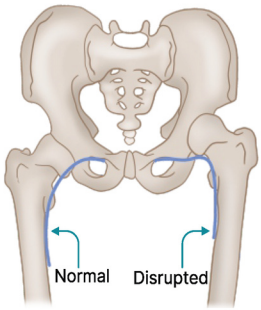



Q1.18: What is the differential diagnosis of a broken Shenton's line?

Answer:

- Fracture neck of femur
- Posterior dislocation of the hip in adults
- Congenital dislocation of the hip
- Tom-Smith`s Arthritis
- Tuberculosis of the Hip
- Girdlestone Excision Arthroplasty

Q1.19: Why is fractured neck of the femur considered an orthopedic emergency, and what factors influence its treatment?

Answer:

- Should be fixed as soon as possible, within 24 hours, due to the risk of avascular necrosis
- Treatment depends upon two factors:
  - Garden's classification
  - Age of the individual

Q1.20: How is fracture neck of femur managed according to Garden's classification?

Answer:

- **Garden's type 1:** Managed by
  - Hip spica
  - In children
    - → Austin Moore's pin (Austin Moore's pin)
    - → Knowles screw
- **Garden's type 2**
  - Fixing with a dynamic hip screw (DHS) / Three-point fixation
  - The screw is placed at the fracture region
  - Protects the head of the femur
- **Garden's type 3 and 4**
  - Prosthesis - Joint replacement
  - As there is a risk of avascular necrosis

Q1.21: How does the treatment of the fracture neck of the femur vary according to the age of the patient?

Answer:

Group	Un-displaced fracture	Displaced fracture
70 years	DHS	THR
Young adults	DHS	DHS • After 2 to 3 months if the head survives then DHS is enough. • If the head undergoes avascular necrosis, then prosthetic replacement should be done.
Children	• Hip spica • Moore's pinning • Knowles screw	• The patient is left to attain skeletal maturity. • After skeletal maturity osteotomy can be performed.

Q1.22: When is the hemiarthroplasty procedure performed, and what part of the hip joint is replaced?

Answer:

- Performed if there is no damage to the acetabulum
- Patient over 60 years old
- Replacement of only the head and neck

Q1.23: Difference between Austimoore's Prosthesis & Thompson's Prosthesis?

Answer:

Austimoore's Prosthesis	Thompson's prosthesis
• Calcar (neck) is inadequate • Fenestration present • Used when there is an adequate neck of the femur i.e., not completely damaged  Austimoore's Prosthesis	• Calcar is adequate • Fenestration is absent • Used when the neck of the femur is completely damaged  Thompson's prosthesis

YOURWISH

BIG QUESTION 2: Describe the types of hip dislocations, their mechanisms of injury, clinical features, diagnostic differentiation, and general treatment principles, particularly focusing on posterior dislocation of the hip (PDH).

Broad Answer: Hip dislocations are posterior, anterior, or central. Posterior is most common, caused by force on a flexed, adducted, internally rotated hip, showing limb shortening and FADIR position. Urgent closed reduction and immobilization are key; fractures need surgery. Common complications are nerve injury and avascular necrosis. Anterior dislocations cause limb lengthening, and central dislocations involve pelvic displacement of the femoral head.

DETAILED QUESTIONS

Q2.1: Enumerate types of hip dislocation.

Answer:

Posterior dislocation of hip (PDH)	Anterior dislocation of hip (ADH)	Central dislocation of hip (CDH)
• Head is dislocated to the posterior or behind of the acetabulum • Most common type	• Head is dislocated to the front of the acetabulum • 2nd most common type	• If the acetabulum is totally fractured and the head is entering into the pelvic cavity • Least common.

Q2.2: What is the most common type of hip dislocation?

PYQ: INICET 2021 PYQ: FMGE 2019, 21

Answer: Posterior dislocation of the hip (PDH)

Q2.3: What is the typical mechanism of injury in posterior dislocation of the hip, often seen in car accidents?

Answer: Axial force applied to a flexed, adducted, and internally rotated hip (e.g., dashboard injury)

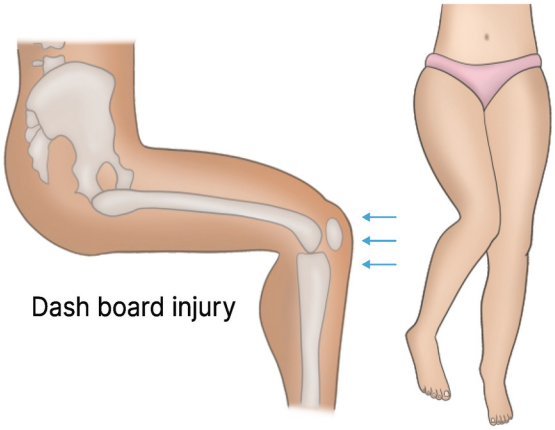

Q2.4: What is the common limb position in posterior hip dislocation?

Answer:

- Flexion, Adduction, and Internal Rotation
- Marked of the limb with gross restriction of all hip movements

Q2.5: Which clinical sign is positive in posterior dislocation of the hip?

Answer: Vascular sign of Narath

Q2.6: What percentage of PDH cases are associated with a posterior chip fracture of the acetabulum?

Answer: 50%

YOURWISH

Q2.7: What is the investigation of choice in hip dislocations with associated fractures?

Answer:

- 50% of PDH are associated with a posterior chip fracture of the acetabulum
- **CT scan - investigation of choice in dislocation with fractures.**

Q2.8: How is the femoral head size typically different on X-ray in posterior versus anterior dislocation of the hip?

Answer: In PDH, the femoral head appears smaller; in ADH, it appears larger

Q2.9: What is the typical limb position in anterior dislocation of the hip?

Answer: Flexion, Abduction, and External Rotation

Q2.10: How does the limb appear in a central hip dislocation?

Answer: It appears near normal

Q2.11: Which conditions can present with a positive Vascular Sign of Narath?

Answer:

- Fracture neck of the femur
- Posterior hip dislocation
- Congenital dislocation hip (developmental dysplasia of the hip)
- Tom Smith arthritis
- Girdlestone excision arthroplasty
- Tuberculosis of the Hip

Q2.12: What is the Thompson and Epstein Classification of PDH?

Answer:

Type 1	Dislocation without fracture
Type 2	Dislocation with a single large fracture of posterior acetabular rim
Type 3	Dislocation with a communited fracture of posterior actabular rim
Type 4	Dislocation with fracture acetabular floor
Type 5	Dislocation with femoral head fracture



Type I Type II Type III Type IV Type V

Type V (Femoral head fracture), is further classified, named **Pipkin's classification.**

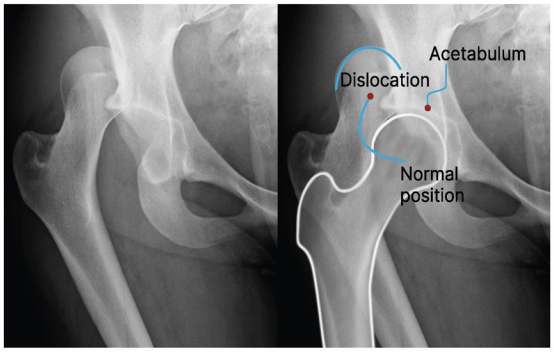

Q2.13: What is the recommended treatment for a pure posterior dislocation of the hip, and what are some common reduction techniques used?

Answer:

- For Pure or Isolated PDH
  - o Usually, closed reduction is tried under anesthesia
  - o Should be treated within 6-12 hours
  - o Treatment techniques
    - → Stimson's Gravity method
    - → Allis Traction
    - → Bigelow's method
    - → Classical Watson-Jones method
    - → East Baltimore technique
  - o After reduction, the hip is immobilized in a Thomas splint for 3 weeks
  - o Full weight bearing is allowed after 6 weeks only (as re-dislocation is common)
- For dislocation with associated fracture: Open reduction

Q2.14: Describe Stimson's Gravity method used in the reduction of posterior hip dislocation.

Answer:

- Patient lies on the examination couch in a prone position
- One person supports the pelvis
- The other gives gravity to the knee joint
- The results are not that good

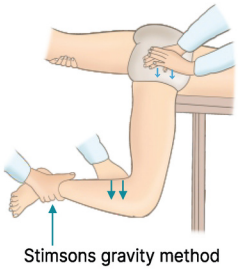

Q2.15: What are the steps involved in the Allis Traction method for reducing posterior hip dislocation?

Answer:

- The patient is put in a supine position
- One person supports the pelvis
- The other one gives:
  - o Step 1: A forward pull is given
  - o Step 2: Hip is made to a 90-degree angle and pulled upward
  - o Step 3: Hip is rotated internally and externally
  - o Step 4: The Leg is placed back to the original position
- Has good results

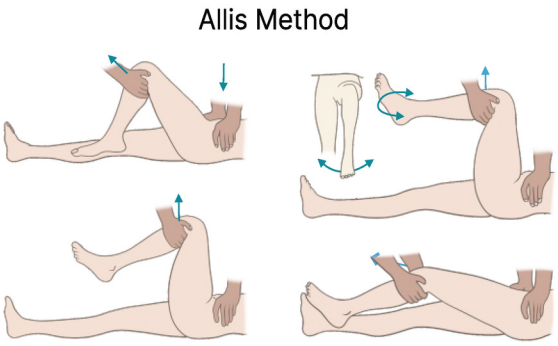

Q2.16: How is the Classical Watson-Jones method performed for the reduction of posterior hip dislocation?

Answer:

- The pelvis is pushed down by the 2nd person
- And the 1st person stands and places the knee and hip at 90-degree flexion and pulls the leg

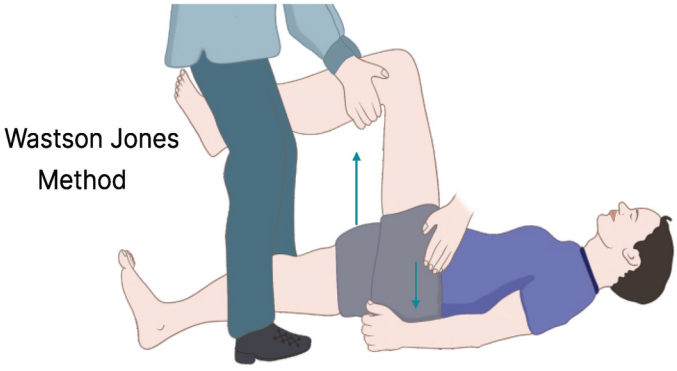

Q2.17: What are the common nerve and artery injuries associated with posterior dislocation of the hip, and what other complications can occur?

Answer:

- Most common nerve: Sciatic nerve injury - Peroneal division
- Most common artery: Superior Gluteal artery
- Myositis ossificans
- Traumatic osteoarthritis due to avascular necrosis
- Rarely: Recurrent dislocation

Q2.18: How common is anterior dislocation of the hip?

PYQ: AIIMS 2020 PYQ: FMGE 2020

Answer: It is very rare.

Q2.19: What is the typical mechanism of injury for anterior hip dislocation?

Answer:

- Forced abduction and lateral (external) rotation of the hip
- Needs more forced trauma than a dashboard injury
- Example: Violent RTA, Air crash

Q2.20: What is the characteristic limb position in anterior hip dislocation?

Answer: The limb shows marked lengthening.

Q2.21: Which nerve is most commonly injured in an anterior dislocation of the hip?

Answer: Femoral nerve.

Q2.22: Is the Vascular Sign of Narath positive or negative in anterior hip dislocation?

Answer: Negative.

Q2.23: What are the two types of anterior hip dislocations according to Epstein's classification?

Answer:

- **Type I:** Superior dislocation, Pubic type
- **Type II:** Inferior dislocation, Obturator type

Q2.24: What anatomical structure is fractured in a central dislocation of the hip?

Answer: The floor of the acetabulum is broken.

Q2.25: Where does the femoral head displace in central dislocation of the hip?

Answer: It enters into the pelvic cavity.

Q2.26: How can central dislocation of the hip be detected on physical examination?

Answer: On per rectal examination, the bony femoral head can be felt pressing against the thumb

Q2.27: What forms the proximal part of tibia?

Answer: The proximal-most part of the Tibia is made up of the Articular surfaces (Tibial Plateau) of the Medial and lateral Tibial Condyles

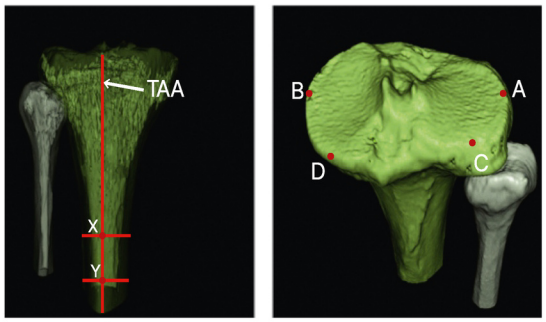

Q2.28: What separates the medial and lateral tibial plateaus?

Answer: The intercondylar eminence

Q2.29: What is the mechanism of injury fracture Tibial Condyle?

Answer:

- Road traffic accidents: Most common cause in Young Adults
- Trivial fall: Most common cause in the Elderly (Osteoporosis)
- In Young Adults, bone is strong, so the most common type of Fracture is a Split fracture, Which is highly associated with Ligament Injuries
- In the Elderly, the Bone is weak, so the most common type of fracture - Depression Fracture or Split-depression Fracture. Low rate of Ligament Injuries

Q2.30: What are the clinical features of a fracture Tibial Condyle?

Answer:

- Patients present with marked Knee swelling due to Hemarthrosis
- Always look for Signs of **Compartment Syndrome**
  - Stretch pain is the earliest sign of compartment syndrome

Q2.31: What imaging modalities are used to diagnose tibial condyle fractures?

Answer:

- X-ray
- CT scan with 3D Reconstruction: **Gold Standard/ Investigation of choice**
- MRI: Rules out ligament injuries

Q2.32: What is the Schatzker-Tile's classification, and how does it categorize tibial condyle fractures?

Answer:

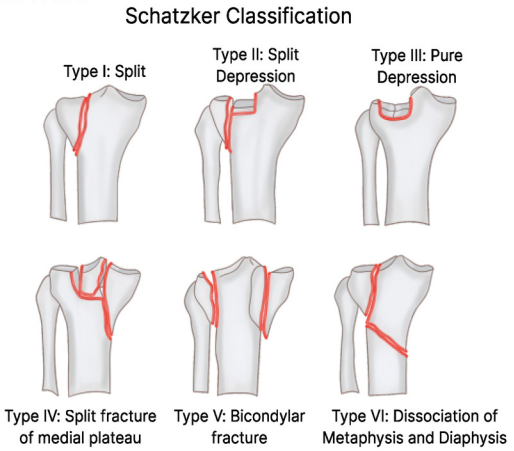

Type I	• Lateral Plateau Split fracture • Seen in young adults
Type II	• Lateral Plateau Split Depression fracture • Seen in young adults
Type III	• Lateral Plateau Pure depression fracture • Seen in elderly
Type IV	• Medial Plateau fracture
Type V	• Bicondylar Plateau fracture
Type VI	• Plateau fracture with separation of Metaphysis from Diaphysis

YOURWISH

Q2.33: What are the treatment options for tibial condyle fractures, and when is surgical intervention indicated?

Answer:

- Non-Surgical
- Undisplaced fractures are managed non-Surgically using an above-knee Cast
  - Complete bed rest for 8-12 weeks
  - Weight-bearing is restricted
- Surgical Displaced fracture & Fracture with Intraarticular Extension- **ORIF** (Hockey stick plate)
  - Treatment of choice



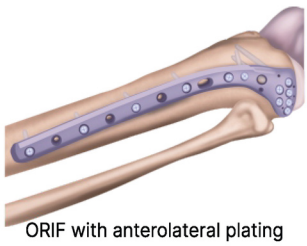

ORIF with anterolateral plating

Q2.34: What are the major complications of tibial condyle fractures?

Answer:

- Compartment syndrome
- Popliteal Artery Injury
- Peroneal Nerve Injury
  - Emergency Management is needed for all the complications

BIG QUESTION 3: Describe the key types of fractures around the ankle and foot, including their mechanisms, involved structures, and standard treatments.

PYQ: NEET PG 2022

Broad Answer: Fractures around the ankle and foot include Pott's (bimalleolar), Cotton (trimalleolar), Maisonneuve's, and Pilon fractures. Pott's and Cotton are due to twisting injuries and usually need ORIF. Maisonneuve's is a proximal fibula fracture with syndesmotic injury, always requiring surgery. Pilon fractures involve the distal tibia from high-impact trauma. Other foot fractures, like talus, calcaneus, patella, and Lisfranc are treated based on severity and displacement.

DETAILED QUESTIONS

Q3.1: What are the three malleoli of the ankle?

Answer:

- Three malleoli
  - Lateral: Lowermost portion of the fibula (Distal to syndesmosis)
  - Medial: Lowermost portion of the tibia
  - Posterior: Distal Posterior aspect of tibia

Q3.2: What is Pott's fracture, and which malleoli are involved?

Answer:

- Pott's fracture is a bimalleolar fracture
- It involves the lateral and Medial malleoli



Q3.3: What are the common mechanisms of injury that cause Pott's fracture?

Answer: Supination, adduction injury, or pronation abduction injury of the foot

Q3.4: What is the treatment of choice for Pott's fracture?

Answer:

- TOC: Surgical Fixation (ORIF)
- Medial malleolus fixation: 4 mm cancellous lag screw
- Lateral malleolus fixation: 1/3rd tubular plate

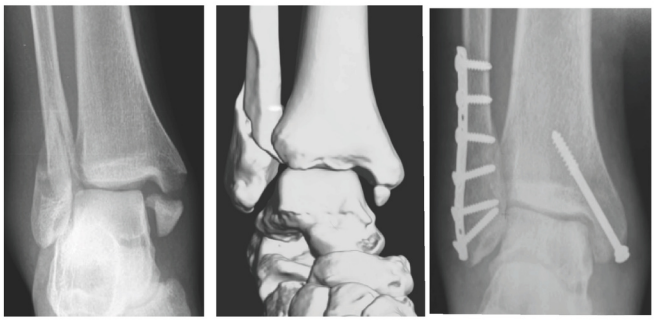

Q3.5: What is a Cotton fracture?

Answer: It is a Trimalleolar fracture, including all three malleoli

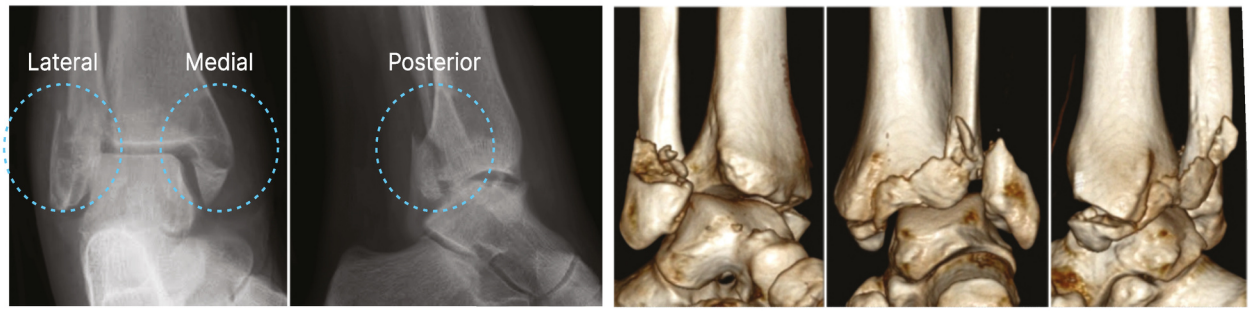

Q3.6: What is the mechanism of injury of a Cotton fracture?

PYQ: AIIMS 2019

Answer: Supination, external rotation injury

Q3.7: What is the management of a cotton fracture?

Answer:

- Conservative
- Posterior malleoli fixed with a screw
- Medial malleoli fixed with a screw (4 mm cancellous lag screw)
- Lateral malleolus fixed witha 1/3rd tubular plate

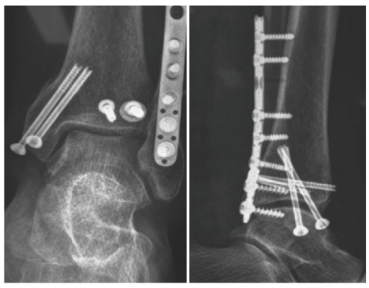

Q3.8: What is a Maisonneuve's fracture?

Answer: Fracture of the proximal 1/3 of the fibula with injury to distal tibiofibular syndesmosis and deltoid ligament, with or without Medial malleolar fracture

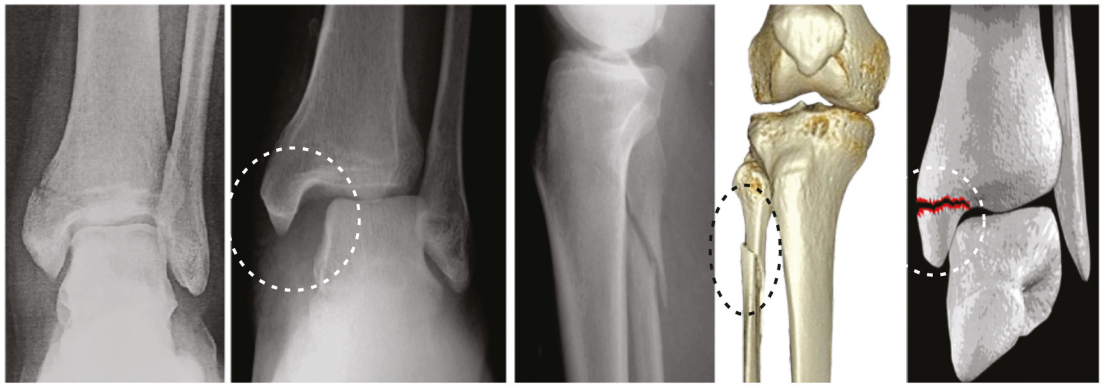

Q3.9: What is the mechanism and treatment of a Maisonneuve's fracture?

Answer:

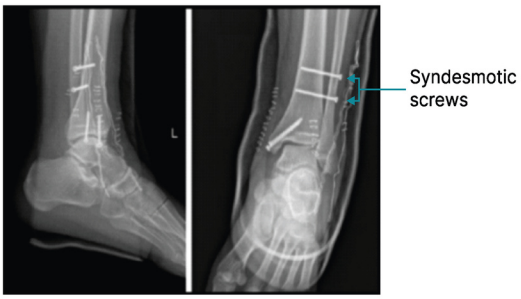

- Mechanism: Pronation, external rotation injury
- It is a **highly unstable fracture**, so it needs 100% surgery
  - Fibula fixed with fibular plate
  - Distal tibiofibular syndesmosis fixed with syndesmotic screws

Q3.10: What is a Tibial plafond fracture, its cause, and treatment?

Answer:

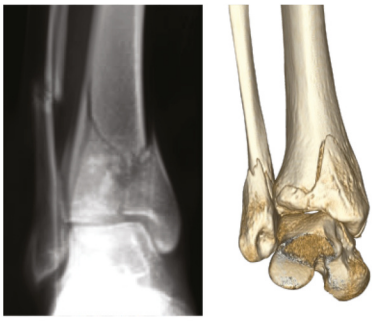

- Involves the distal tibia at its articulation with the talus
- Caused by high-energy axial load
- TOC: Surgery
- Mostly, it is a comminuted fracture

Q3.11: What is the patella?

PYQ: NEET PG 2022

PYQ: INICET 2023

Answer: The patella is the largest sesamoid bone in the body

Q3.12: What are the primary functions of the patella?

Answer:

- Increases the mechanical advantage of the quadriceps tendon
- To aid in the nourishment of articular cartilage
- To protect the femoral condyles from injury
- Acts as a hydraulic brake

Q3.13: What are the common mechanisms of injury for patella fractures?

Answer:

- Direct trauma: Produces comminuted fracture (direct injury) - **Most common**
- Indirect trauma: Produces a transverse fracture (due to violent contractions of the quadriceps)

Q3.14: How are patella fractures classified based on displacement and anatomical pattern?

Answer:

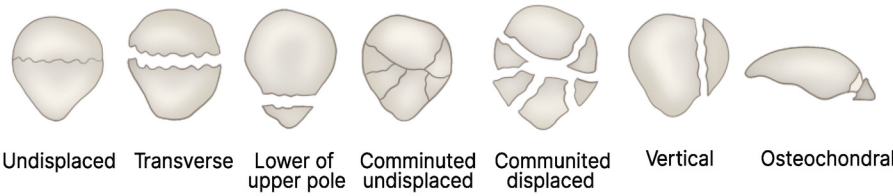

- Undisplaced: Gap is **< 2 mm**
- Displaced: Gap is more than 2 mm
- Depending on the anatomical pattern, 4 types
  - Transverse fracture (**most common**, about 85%)
  - Oblique fracture (rare)
  - Vertical fracture (rare)
  - Comminuted fracture (2nd common)

Q3.15: What is the preferred imaging method for diagnosing patella fractures?

Answer:

- X-ray
  - o Skyline view/Axial view/ Merchant's view is the view of choice
  - o Intercondylar notch view

Q3.16: How is the Skyline view X-ray for the patella performed?

Answer:

Patient lay in prone position

↓

Flex the knee joint to 110 degree

↓

Pass a beam obliquely

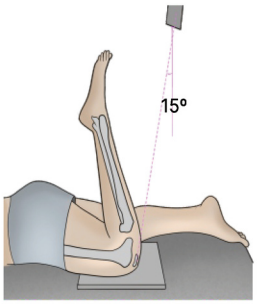

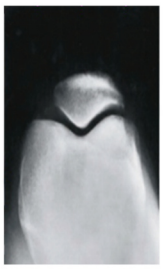

Q3.17: What are the treatment options for undisplaced and displaced patella fractures?

Answer:

- **Undisplaced**
  - o Conservative treatment
    - → **Cylindrical** cast is the treatment of choice
    - → Also called tube cast
- **Displaced (>2 mm)**
  - o Surgery is TOC, cannot go for conservative treatment (as it goes for non-union)
  - o Should be performed within 7 days
  - o Surgery of choice
    - → Transverse fracture: **Tension band wiring** (Martin's circumferential tension band wiring)
    - → Comminuted fracture: Patellectomy (only last 10-degree extension of the knee is not possible - Extensor lag)

Q3.18: What is extensor lag, and which patella fracture treatment complication does it relate to?

Answer:

- The **only complication of Patellectomy**
- Patients can't perform the last 10-degree bend of the knee (terminal extension)

Q3.19: Where does recurrent dislocation of the patella occur, and how does it differ from habitual dislocation?

Answer:

- Usually occurs on the lateral side
- Recurrent dislocation - 2-3 times dislocation
- Habitual dislocation - dislocation occurs in each flexion and extension



Q3.20: What are the predisposing factors for recurrent dislocation of the patella?

Answer:

- Predisposing factors:
  - o Patella alta
    - → Abnormally high-lying patella
  - o Patella Baja

YOURWISH

→ Abnormally low-lying patella

- Tight lateral structures
  - → Most common in India
  - → Example: Poliomyelitis (tightening of the iliotibial band)
- Genu Valgum
  - → Also called knock knee
  - → Q (quadriceps) angle increases
- Genu Recurvatum
  - → Excessive concavity or curvature of the knee

Q3.21: What are the important X-ray lines used to assess patellar position?

Answer:

- **Blumensaat's line:** Represents the bony roof of the intercondylar notch
  - Usually, the lowermost pole of the patella should touch Blumensaat's line
  - If it is above the line - Patella alta
  - If it is below the line - Patella baja
- **Insaal's line / Insaal Salvetti ratio:** Ratio between the length of the patellar tendon and patella
  - Usually it is 1
  - If >1 suggest Patella alta

Q3.22: What are the treatment options for recurrent dislocation of the patella, and which is considered the procedure of choice?

Answer:

- **Modified Campbell's operation**
  - Lateral release
  - Iliotibial bands are made free, so that they won't pull the patella laterally
  - Widely used. Procedure of choice
- **Roux-Goldthwait's procedure**
  - Proximal realignment of the capsule of the knee, quadriceps
  - Not used mostly.
- **West and Soto Hall procedure**
  - Patellectomy
  - Done if both above fail
  - Only complication is the Extensor lag

Q3.23: What is the most common cause and site of a talus fracture?

Answer:

- MC cause: RTA > Fall from height
- MC site: Neck

Q3.24: What is the mechanism of injury in a talus fracture?

Answer: Hyperdorsiflexion of the ankle

Q3.25: Why is a talus fracture also called an aviator's fracture, and what causes it?



Answer:

- It is also called an aviator's fracture
  - Talus Fracture occurring in pilots during a crash landing
  - Due to the impaction of the rudder bar over the plantar aspect of the foot

Q3.26: What is a Hawkins fracture for talus fracture?

Answer:

Type 1	Undisplaced
Type 2	Talus neck fracture + Subtalar dislocation
Type 3	Talus neck fracture + Subtalar dislocation + Ankle dislocation
Type 4	Talus neck fracture + Subtalar dislocation + Ankle dislocation + Talonavicular dislocation

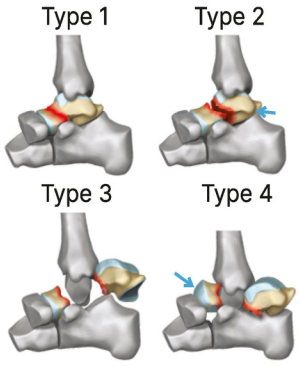

Q3.27: What is the Hawkins angle in talus fractures?

Answer: Fracture angle of the talus

Q3.28: What is Hawkins disease related to talus fractures?

Answer: Avascular necrosis of the talus

Q3.29: How are talus fractures classified?

Answer: Hawkins classification

Q3.30: What is the management of a talus fracture?

Answer:

Undisplaced fracture	Displaced fracture
• Conservative o Below knee case o For 8 to 12 weeks	• ORIF with screw fixation (cancellous screw) • Sometimes, Herbert's screw is used o **Headless screw** o No need for removal after insertion

Q3.31: What are the main complications of talus fractures?

Answer:

- Avascular necrosis
  - In Types 1 and 2: 0 to 50%
  - In Types 3 and 4: 50 to 100%
- Delayed union and non-union
- Malunion
- Subtalar and ankle arthritis

Q3.32: What is Hawkins' sign in talus fractures?

Answer:

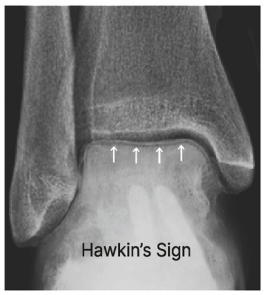

- Radiolucent line in the subchondral region - Viable
- This line is known as Hawkins's sign
- Presence of Hawkins sign - **Less chances** of avascular necrosis in the talus
- Positive sign

Q3.33: What is the most common cause of calcaneal fractures?

Answer: Fall from height

Q3.34: Name three fractures commonly caused by axial load

Answer:

- Tavares fracture
- Calcaneal fracture
- Spine fracture

Q3.35: In the given image of the calcaneus, identify the bony landmarks labeled as 1, 2, and 3.

Answer:



- 3 is the anterior process
- 2 is the Posterior facet
- 1 is the calcaneal tuberosity

Q3.36: What is Bohler's angle, and how is it used in diagnosing calcaneal fractures?

Answer:

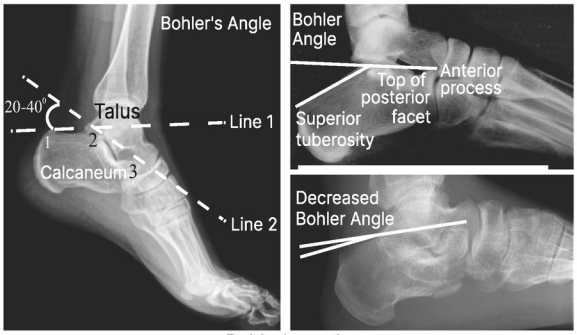

Bohler's angle

- A line is drawn from the superior Posterior facet, crossing the anterior process
- Another line (horizontal) is drawn from the superior aspect of the calcaneal tuberosity
- The angle between 2 lines is Bohler's angle
- Approximately 20 to 40
- Bohler's angle < 20: **Calcaneal fracture**

Q3.37: What is the Gissane angle and its significance in calcaneal fractures?

Answer:

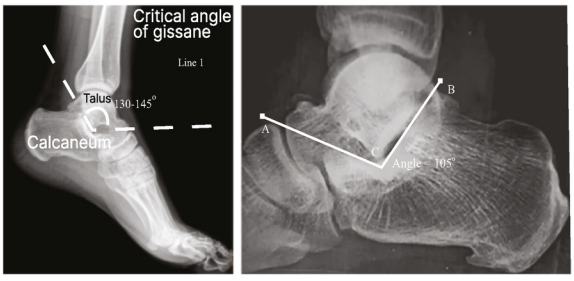

- A line is drawn from the posterior facet to the anterior process
- Another line is drawn from the anterior process
- The angle between both lines is the Gissane angle
- Normal range: 130 to 145
- Gissane angle > 145: **Calcaneal fracture**

YOURWISH

Q3.38: What are the classifications used for calcaneal fractures, and which imaging is essential?

Answer:



- Two types of classification
  - Essex-Lopresti classification: By X-ray
  - Sander's classification: CT scan
- A CT scan with 3D reconstruction is a must in a calcaneal fracture

Q3.39: What is the treatment approach for calcaneal fractures?

Answer:

- Undisplaced fracture: Conservative (below-knee pop cast)
- Displaced fracture: Surgery (screw fixation)

Q3.40: What are the common complications of calcaneal fractures?

Answer:

- Malunion
- Loss of subtalar movement
- Persistent heel pain
- Peroneal tendonitis
- Post-traumatic arthritis
- Complex regional pain syndrome
- Avascular necrosis - Sever's Disease

Q3.41: What is the Lisfranc joint?

Answer: Articulation of the tarsus with the metatarsal base

Q3.42: How do the first three metatarsals articulate in the Lisfranc joint?

Answer:

- The first three metatarsal bases articulate with three cuneiforms, respectively.
  - 1st metatarsal articulates with the Medial cuneiform.
  - The 2nd metatarsal articulates with the Intermediate cuneiform.
  - The 3rd metatarsal articulates with the lateral cuneiform.

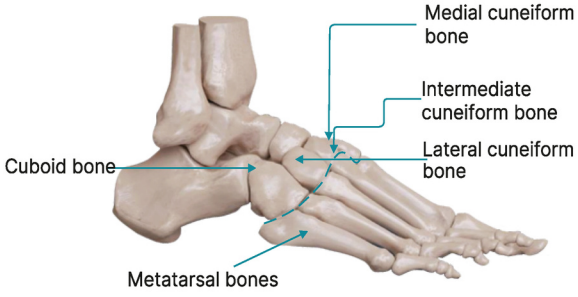

Q3.43: Which tarsal bone do the 4th and 5th metatarsals articulate with?

Answer: 4 and 5 metatarsals articulate with the cuboid

Q3.44: What is the Lisfranc ligament?

Answer: Strong band that attaches the Medial cuneiform to the 2nd metatarsal base of the plantar aspect of the foot

Q3.45: What is a Lisfranc fracture?

Answer: Dislocation of the articulation of the tarsus with the metatarsal base

Q3.46: What is the most common mechanism of Lisfranc fracture?

Answer: Direct or indirect load on the plantar aspect of the foot

YOURWISH

YOURWISH

Q3.47: What is the treatment approach for Lisfranc fractures?

Answer:

- Undisplaced fracture: Conservative (BK POP cast for 12 weeks)
- Displaced fracture: ORIF

Q3.48: What is the main complication of a Lisfranc fracture?

Answer: Dorsalis pedis artery injury

Q3.49: What is a Jones fracture, and how is it different from a pseudo-Jones fracture?

Answer:

- Named after Watson Jones
- Fracture of diaphysis (shaft) of 5th metatarsal bone, 1.5cm above the tip of the tuberosity
  - o If below 1.5 cm - Pseudo Jones or Dancer's fracture (usually developed in Ballet dancers)
- It is an avulsion fracture due to the pull of the peroneus brevis muscle
- Usually fixed with a below-knee slab
- If unstable, K-wire fixation to be done

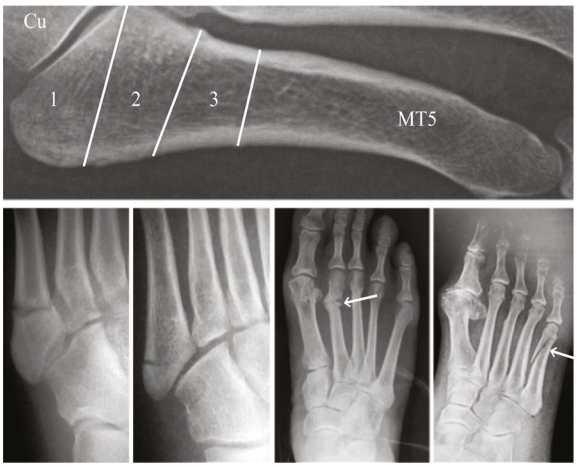

Q3.50: What is a March fracture, and how is it treated?

Answer:

- A stress fracture/ hairline fracture/ march fracture
- Seen in March pasting people (army personnel, police)
- The neck of the 2nd metatarsal is broken
- Treatment: Bed rest, NSAIDs can be given for pain



7. MALUNION & OPEN FRACTURES

BIG QUESTION 1: What is malunion of a fracture, what are its types with examples, and what treatment options are available?

Broad Answer: Malunion is the healing of a fracture in an incorrect anatomical position, leading to deformity or functional impairment. It can be classified by angulation, rotation, or shortening, and treatment includes corrective osteotomy, physiotherapy, or supportive measures.

DETAILED QUESTIONS

Q1.1: What is malunion?

Answer:

- **Definition:** Fracture fragments unite in an abnormal position.
- **Causes:** Improper treatment.
- **Effects:** Shortening, alteration in posture/balance.

Q1.2: What are the types of Malunion?

Answer:

Types of Malunion	Description
Length Malunion	• **Other Name:** Overlap Malunion • Overriding of the proximal and distal fragments • So, the **length is altered**
Rotatory Malunion	• Proximal and distal fragments are united in the wrong fashion. • **Normal length** is maintained. • Alignment of the fragments is altered **(Rotated)** o Worst type o It can not be corrected by remodeling
Angulatory Malunion	• Proximal and distal fragments are not present in the straight line **(Angulation)**

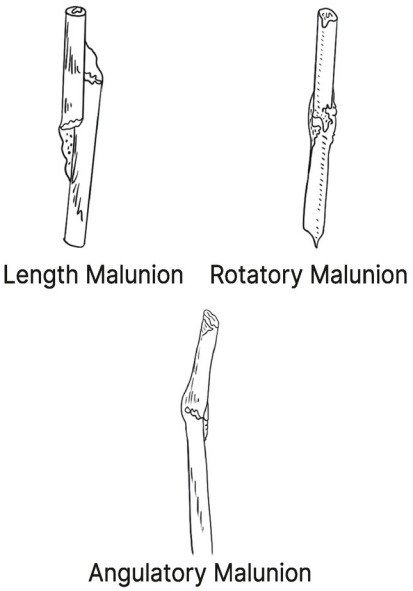

Q1.3: What are the Treatment options for Malunion?

Answer:

- Malunion of 5° - 10° can be corrected by remodeling, so active treatment is not necessary.
- 3 methods of treatment
  - o Osteoclasis
  - o ORIF
  - o Osteotomy
- Treatment of choice: Corrective osteotomy

Methods	Explanation
Osteoclasis	• Voluntary breaking of the bone. • Bone is broken and the angulation is corrected, and is refixed.
ORIF (Open reduction internal fixation)	• Osteoclasis is done **(First).** • The angular bone is straightened. • It is fixed with the plate and screws.
Osteotomy 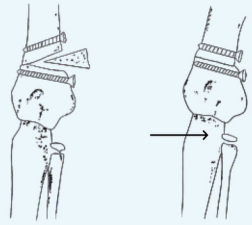	• When Malunion is around the joint. • Cutting the wedge of the bone, correcting the angle and fixing again. • It is known as the corrective osteotomy. • It is the **gold standard treatment.**

BIG QUESTION 2: What is non-union of a fracture, its causes, types, classification systems, and management?

Broad Answer: Non-union is the failure of a fracture to heal within the expected time, resulting in persistent mobility and pain at the fracture site. Causes include infection, poor blood supply, and mechanical instability; types are hypertrophic, atrophic, and oligotrophic, classified by systems like Weber-Cech, with management ranging from immobilization and bone grafting to surgical fixation.

DETAILED QUESTIONS:

Q2.1: What is Non-Union?

PYQ: INICET 2020

Answer:

- A minimum of nine months has elapsed since the injury or fracture shows **no radiological signs of healing for three months.**
- Painless abnormal mobility in both planes is the only reliable sign.

Q2.2: What are the Causes for Non-Union?

Answer:

Mnemonic: 8 I and ABCD

- Inadequate immobilization and reduction: The most common cause
- Ischemia
- Infection
- Interposition of soft tissue
- Intact fellow bone
  - In case of a tibia fracture, the fibula is intact
  - The fibula won't allow contact with the proximal and distal fragments. Hence, it will cause non-union.
- Illness **(systemic)**
- Individual bone susceptibility
- Iatrogenic
- Abnormal biomechanics of the bone
- Bone loss
- Comminuted and Compound fracture
- Distraction
- Smoking

Q2.3: What is the Cech and Weber Classification of Non-Union?

Answer:

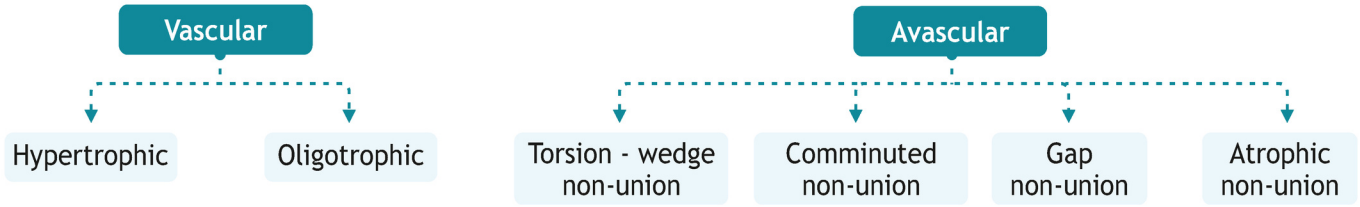

Q2.4: What are the key features of Vascular nonunion?

Answer:

- **Other Name:** Hypertrophic nonunion or Hypervascular
- Excess callus is formed between the proximal and distal fragments.
- Hypertrophic nonunion is further subdivided into two types:
  - **Elephant foot**
  - **Horse-hoof (Within the limits)**
- Oligotrophic (Minimal callus)

Q2.5: What are the key features of an Avascular nonunion?

Answer:

- Other Name: Atrophy
- Lack of vascularity
- It is divided into four types:
  - **Torsion:** Wedge non-union (Union is present on one side)
  - **Comminuted non-union** (Thrown into many pieces)
  - **Gap non-union** (Open fracture)
  - **Atrophic non-union:** Tapering edges are present in the bone

Q2.6: What is the Management of Non-Union?

Answer:

- No role of conservative management
- Managed by open reduction and internal fixation, and bone grafting

Vascular Non-union	Avascular non-union
• Vascularity is maintained. • Open reduction and internal fixation with nibbling of the excess callus • This can be managed without bone grafting.	• Vascularity is lost. • Cancellous bone grafting is recommended.

BIG QUESTION 3: What are open fractures? Discuss their types and classification systems, and explain the principles and methods of their management.

Broad Answer: Open fractures are fractures in which the bone communicates with the external environment through a wound in the skin. They are classified based on severity and soft tissue injury, and management includes prompt wound care, stabilization, antibiotics, and definitive surgical fixation.

YOURWISH

DETAILED QUESTIONS

Q3.1: What are open fractures?

PYQ: INICET 2021

Answer:

- Open fractures, previously known as compound fractures
- Definition: Fracture in communication with the external environment.

Q3.2: What is Gustilo and Anderson's classification of open fractures?

Answer:

Types	Description
Type I 	• Wound <1 cm • There is **no devitalization** of the soft tissue • Through this <1 cm fracture site is exposed to the environment
Type-II 	• Wound >1 cm and <10 cm • There is **no devitalization** of soft tissue
Type-III 	• Wound >10 cm • Soft tissue is **devitalized** • It is further subdivided into three types: o Type III A o Type III B o Type III C
Type III A	• Open fracture with adequate soft tissue coverage • Skin grafting is not required. • Orthopaedic surgeon is sufficient
Type III B	• Open fracture with inadequate soft tissue coverage • Needs skin grafting or flap cover • Plastic surgeon and orthopaedic surgeon are required for repair
Type III C	• Associated with arterial injuries • Orthopedic emergency • A plastic surgeon, orthopaedic surgeon and vascular surgeon are required

Q3.3: What is the Treatment for Open fractures?

Answer:

- Thorough wound wash with saline.
- **Wound debridement** is the mainstay of the treatment.
- **Complication: Gas gangrene**
- **Antibiotics:** Cefazolin + Aminoglycoside (Amikacin)
  - Broad-spectrum antibiotics are recommended.
  - These are preferred before the blood culture.
- **Stabilization** of the skeleton is done by using an **external fixator.**

8. ARDS & VOLKMANNS ISCHEMIA

BIG QUESTION 1: What are the etiopathogenesis, clinical features, diagnostic criteria, radiological investigations, and management of adult respiratory distress syndrome caused by fat embolism?

Broad Answer: Adult respiratory distress syndrome (ARDS) due to fat embolism occurs when fat globules from bone marrow enter the circulation, causing pulmonary inflammation and hypoxia. Clinically, it presents with dyspnea, hypoxemia, and diffuse infiltrates on imaging, and management is mainly supportive with oxygen therapy, ventilation if needed, and stabilization of fractures. PYQ: FMGE 2020

DETAILED QUESTIONS

Q1.1: What are the alternative names for Adult Respiratory Distress Syndrome (ARDS)?

Answer: Fat embolism, traumatic wet lung, shock lung

Q1.2: Within how many hours does ARDS typically manifest after injury or trauma?

Answer: Within 48 hours.

Q1.3: What is the common etiology of ARDS?

Answer:

- **Young adults:** long bone fracture, especially a **fracture of the femur shaft.**
- **Elderly:** Pelvic fracture, procedure of reaming

Q1.4: What are the main sources of fat that contribute to fat embolism leading to ARDS?

Answer:

- Bone marrow- Fat accumulates in the blood and causes **embolism**
- Plasma by agglutination of chylomicrons
- Free fatty acids destroy the pneumocytes

Q1.5: What is the SEVITT's clinical criteria for ARDS?

Answer:

- **Onset 24-48 hours**
- Tachycardia >140 beats/min
- Tachypnoea
- Cyanosis
- Pyrexia >40°
- Lower conjunctival petechiae
  - **Petechial hemorrhage can occur anywhere in the body**
  - **Most important clinical criteria for diagnosis:** The occurrence of **petechiae in the lower conjunctiva** is pathognomonic of fat embolism.



Q1.6: What is GURD's triad?

Answer:

- It is a triad of symptoms
  - Mental Confusion (unrelated to head injury)
  - Dyspnea
  - Petechial hemorrhage (Lower conjunctival)

PYQ: FMGE 2021

Q1.7: What is the typical chest X-ray appearance in ARDS?



Answer: Snowstorm appearance

Q1.8: What are the investigation findings with ARDS?

Answer:

- PaO2: <60mm Hg
- Platelet count <1.5 lakhs
  - Thrombocytopenia may be present

Q1.9: What are the typical ECG findings in fat embolism syndrome?

Answer:

- S-wave is prominent
- P, Q, R, and T waves are normal

Q1.10: What bedside test provides direct evidence of fat embolism?

Answer:

- GURD test (bedside investigation): **Isolation of fat emboli from blood**
  - 100% positive test
  - Direct evidence of fat embolism

Q1.11: What is the procedure for the GURD test?

Answer:

5ml of patients venous blood is taken

↓

Pour the blood in the dark color muslin cloth

↓

Sedimentation of the blood will occur

↓

Minute micro golden yellow fat globules are seen on the muslin cloth

Q1.12: What is the management protocol for Fat Embolism Syndrome (ARDS)?

Answer:

- Oxygen: Ventilatory support.
- Low molecular weight heparin
- Low molecular weight dextran, a plasma expander.
- Antiplatelets
- Severe hypoxia: Ventilatory support
- In case of an accident, Splint the patient on the road without any mobilization.

BIG QUESTION 2: What are the causes, pathogenesis, clinical features, classification systems, and management of Volkmann's ischemia (VIC)?

Broad Answer: Volkmann's ischemia results from compromised blood flow to the forearm muscles, often following fractures or compartment syndrome. The ischemic injury causes muscle necrosis and fibrosis. This process leads to flexion contractures of the wrist and fingers, causing functional disability.

DETAILED QUESTIONS

Q2.1: What is Volkmann's Ischemia, and what causes it?

Answer:

- AKA **Compartment Syndrome.**
- Caused by the elevation of interstitial pressure in a closed osseofascial compartment, which results in microvascular compromise and eventual contracture of muscles
- A compartment means a closed space between bones.
- Interstitial pressure is also called intracompartmental pressure (the most important pressure in orthopedic assessments of compartment syndrome)

Q2.2: What is the normal interstitial (intracompartmental) pressure, and at what pressure is Volkmann's Ischemia diagnosed?

PYQ: FMGE 2020 PYQ:INICET 2021

Answer:

- **Normal interstitial pressure - 10-20 mmHg** (same as the intraocular pressure - ophthalmology)
- **If interstitial pressure > 10-20 mmHg → Volkmann's Ischemia** (Raised intracompartmental pressure)

Q2.3: What are the common sites for Volkmann's ischemia?

Answer: Volar (flexor) compartment of the forearm > Anterior and deep posterior compartments of the legs

Q2.4: What are the rare sites for Volkmann's ischemia?

Answer: Buttocks, shoulder, hand, foot, arm, and lumbar paraspinal muscles

Q2.5: What is the most common cause of Volkmann's Ischemia in children?

Answer: Supracondylar fracture

Q2.6: What is the most common cause of Volkmann's Ischemia in adults?

Answer: Both bone forearm fractures

Q2.7: What is the most common cause of Volkmann's Ischemia overall?

Answer:

- Inappropriate tight bandaging done by quacks
  - To avoid this, apply a slab first (to allow expansion) and then a cast

Q2.8: Which muscle is the first to be affected in Volkmann's Ischemia?

Answer: Flexor digitorum profundus

Q2.9: Besides the flexor digitorum profundus (FDP), which other muscles are commonly involved in Volkmann's Ischemia?

Answer: FLP, FDS, wrist flexors, thumb flexors

YOURWISH

Q2.10: What is TSUGE'S Classification of Volkmann's Ischemia?

Answer:

- Depends on the muscles involved
- 3 types
  - **Type-I:** mild: Involvement of **flexor digitorum profundus (FDP) only**
  - **Type-II:** moderate: Involvement of **FDP** + flexor digitorum superficialis **(FDS)** + flexor pollicis longus **(FPL)**
  - **Type-III:** severe: Involvement of **FDP + FDS + FPL + Wrist and Thumb flexors**

Q2.11: What is Volkmann's sign, and in which type of Volkmann's Ischemia is it positive?

Answer:

- Fingers, thumb, and wrist are all flexed in VIC
- When the wrist is passively flexed, the fingers get extended spontaneously
- **Volkmann's sign is +ve in TSUGE'S Type-III**

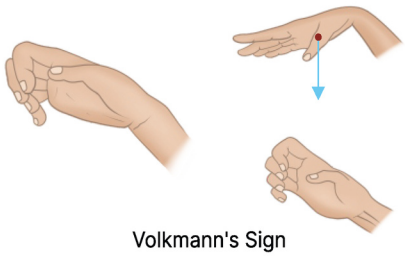

Volkmann's Sign

Q2.12: What are the treatment options for Volkmann's Ischemia?

Answer:

- Early sign: Stretch pain
- Late sign: Pulselessness (Other complications may occur)
- If positive clinical sign: Fasciotomy
- **Doubtful case ICP more than 30 mm/hg: Fasciotomy**
- Doubtful case ICP less than 30mm/hg: Conservative



Emergency Fasciotomy

Q2.13: What are the treatment options for mild Volkmann's Ischemia?

Answer:

- **Mild (Tsuge's Type-I) - Only FDP**
  - Turnbuckle's splint (Volkmann's splinting)

Q2.14: What are the treatment options available for moderate Volkmann's Ischemia?

Answer:

- **Moderate (Tsuge's Type-II) - FDP+FDS+FPL (Attached to medial epicondyle)**
- **Max Page's operation**
  - Soft tissue sliding procedure
  - Cutting a tight muscle
  - Release the muscle tendon
  - And the hand is cosmetically improved
  - Hand functioning can't be improved

Q2.15: What are the treatment options for severe cases of Volkmann's Ischemia?

Answer:

- **Severe (Tsuge's Type-III) - FDP + FDS + FPL + Wrist and Thumb flexors**
  - Soft tissue procedure is not enough
  - A bony procedure named **Seddon's carpectomy** is to be performed
    - → The proximal bone of the carpals is removed (the only treatment available)

9. BONE TUMOR

BIG QUESTION 1: What is the classification of bone tumors, and what are the origin, common sites, clinical features, radiological findings, and treatment of osteochondroma?

Broad Answer: Bone tumors are classified as benign or malignant, based on origin, behavior, and histology. Osteochondroma is a common benign bone tumor arising from the metaphysis of long bones, presenting as a painless bony swelling; diagnosis is by X-ray, and treatment is surgical excision if symptomatic.

DETAILED QUESTIONS

Q1.1: What is the Lichtenstein Classification of bone tumors?

Answer:

Cell type	Benign	Malignant
Bone	Osteoid osteoma	Osteosarcoma PYQ: AIIMS 2020
Cartilage	• Chondroma or Enchondroma • Osteochondroma or exostosis	Chondrosarcoma PYQ: AIIMS 2020
Fibrous tissue	Fibroma	Fibrosarcoma
Bone marrow	Eosinophilic granuloma - comes under histiocytosis-X.	• Ewing's sarcoma (arises from endothelial cells of the bone marrow) • Multiple myeloma (arises from plasma cells of bone marrow)
Vascular	Haemangioma	Angiosarcoma
Uncertain	Giant cell tumor (osteoclastoma)	Malignant giant cell tumor

Q1.2: What are the key features of Osteochondroma?

PYQ: FMGE 2021, 2023

PYQ: INICET 2023

Answer:

- Also called **exostosis.**
- **Most common primary benign bone tumor.**
- It is an offshoot of the spongy bone tissue covered with a **cartilaginous cap.**
  - This is due to the unwanted activity of the cambium layer of the periosteum.
- **Most common age :**
  - Growth period (growth spurt) - teenagers.
  - Male preponderance.

Q1.3: What are the common sites of osteochondroma?

Answer: Most common site -The lower end of the femur.

- 2nd common site - Upper end of the tibia.

- Around the knee joint.
- Most common around the metaphysis of long bones, the crest of the ilium.

Q1.4: What are the Clinical Presentations of Osteochondroma?

Answer:

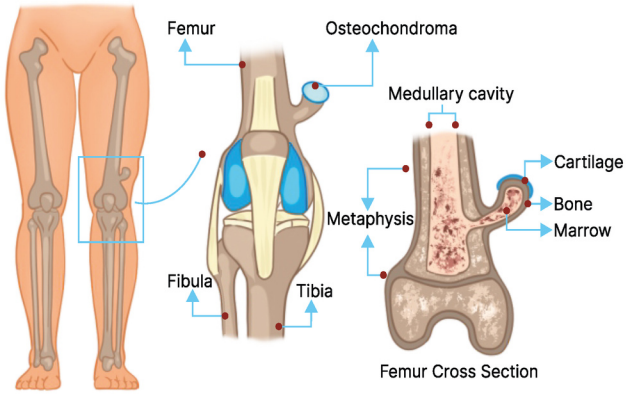

- 99% are asymptomatic
- Pain - Pain should not happen in Osteochondroma.
  If present, the possibilities are:
  - Adventitious bursitis
  - Fracture of exostosis
  - Compression of surrounding nerves - Neuritic pain.
  - Malignant change of Osteochondroma - 1% chance.
- Restriction of joint movements
- A firm, tender swelling fixed to the bone
- Gross appearance of exostosis - **Cauliflower appearance.**

Q1.5: What are the complications of osteochondroma?

Answer:

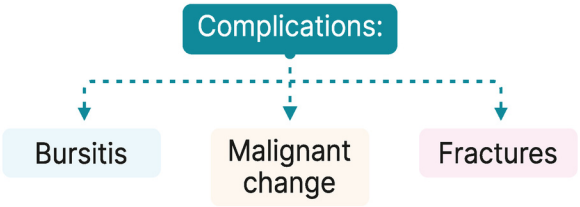

Q1.6: What is the treatment plan for Osteochondroma?

Answer:

- Excision is the treatment of choice.
  - Extraperiosteal excision.
  - Complete excision to prevent recurrence.

Q1.7: What are the key features of Hereditary multiple exostosis?

Answer:

- AKA **Diaphyseal achalasia.**
- Most common and least disfiguring of skeletal dysplasias.
- **Autosomal dominant** (boys = girls).
- X-ray shows -the **distal ulna is carrot-shaped** - a characteristic feature.

BIG QUESTION 2: What are the features, clinical presentation, diagnosis, and management of chondroma?

Broad Answer: Chondroma is a benign cartilaginous tumor, commonly arising in small bones of the hands and feet. It usually presents as a painless swelling; diagnosis is by X-ray showing well-defined, lytic lesions with calcifications, and treatment is surgical excision if symptomatic.

DETAILED QUESTIONS

Q2.1: What are the key features of Chondroma?

Answer:

YOURWISH

- Also called **Enchondroma** - it occurs inside the bone.
- Benign tumor, the potential for undergoing malignancy.
- Arises from hyaline cartilage and destroys the cancellous bone.
- Most common age - 10 to 50 years.

Q2.2: What are the common sites of chondroma?

Answer: Most common site - Phalanges of the hand, especially the little finger.

- The most common tumor seen in the hand and foot is.

Q2.3: What are the radiologic findings of chondroma?

PYQ: NEET PG 2022

PYQ:FMGE 2023



Answer: X-Ray Shows

- **Expanded lytic lesions** with a wisp of calcification.
- Very pathognomic.
- It appears as a ring, also called an **O-ring sign.**

Q2.4: What is the treatment of Chondroma?

Answer: **Treatment**

- Curettage with wall cauterization - Treatment of choice.
  - It can reduce the chance of recurrence (very common).
- Chondroma in the pelvis - Worst prognosis.
  - Difficult to identify as it is deeply situated.
  - The 1st presentation may be Malignancy.

BIG QUESTION 3: What are the features, clinical presentation, diagnosis, and management of chondroblastoma?

Broad Answer: Chondroblastoma is a rare benign bone tumor arising from the epiphysis of long bones, most commonly the proximal humerus, distal femur, and proximal tibia. It presents with joint pain, swelling, and limited motion; diagnosis is by X-ray showing a well-defined epiphyseal lytic lesion with a sclerotic margin, and treatment is curettage with bone grafting.

DETAILED QUESTIONS

Q3.1: What are the key features of Chondroblastoma?

Answer:

- Also known as Codman's tumor
- Benign tumor of the cancellous bone.

Q3.2: What are the common sites of chondroblastoma?

Answer: Epiphyseal end of Long Bones **(before epiphyseal closure)**

Q3.3: What are the clinical presentations of chondroblastoma?

Answer:

- Common age group: 10 to 20 years

- Males >>> Females
- Asymptomatic (sometimes localized pain)

Q3.4: What are the histopathological findings of chondroblastoma?

Answer:

- Sheets of chondroblasts
- The matrix gives a cobblestone/ chicken wire appearance.

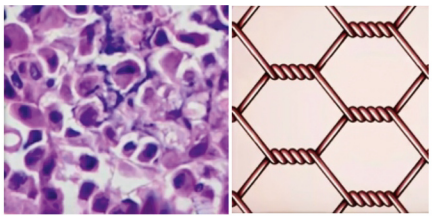

Cobble Stone Appearance

Q3.5: What are the radiological findings seen in chondroblastoma?

Answer:

- Clear osteolytic lesion in the epiphysis
- X-ray: Rarefaction at the epiphysis and mottled calcification are very characteristic.

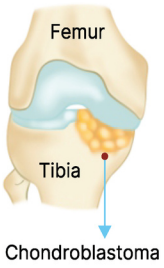

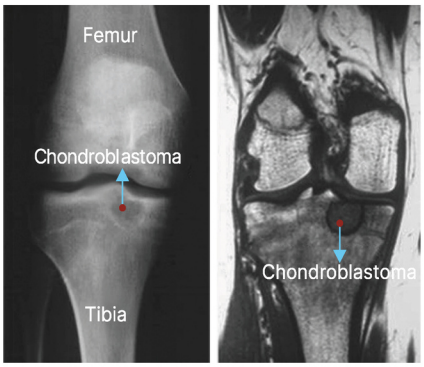

Q3.6: What is the treatment of Chondroblastoma?

Answer: TOC: Wide curettage and bone grafting, and absolutely no malignant potential.

BIG QUESTION 4: What are the features, types, clinical presentation, diagnosis, and management of osteoma?

Broad Answer: Osteoma is a benign bone tumor, most commonly affecting the skull and facial bones.
It can be classified into osteoid osteoma (small, may cause pain) and ivory osteoma (dense, usually asymptomatic); diagnosis is by imaging, and treatment is needed only if symptomatic.

Q4.1: What are the types of osteoma?

Answer:

- Osteomas arise from proper bone cells.
- Two Types:
  - Osteoid osteoma
  - Ivory osteoma/ membranous osteoma/ compact osteoma

Q4.2: What are the key features of Osteoid Osteoma?

Answer:

- It is a benign osteoblastic tumor with a well-demarcated nidus.
- It affects the diaphysis.
- Tumor of young adults.
- Male >>> Female

Q4.3: What are the common sites of osteoid osteoma?

Answer: Most Common site: Upper tibia and femur

Q4.4: What are the clinical presentations of osteoid osteoma?

Answer: The most common presenting feature is pain, especially at night (night cries - also seen in skeletal TB)

- Pain is classically relieved by high-dose Aspirin.

Q4.5: What is a characteristic X-ray finding seen in osteoid osteoma?



Answer:

- Nidus in the diaphysis (<1.5cm radiolucent area)
- It is a seed-like structure.
- It is a Fibro-vascular tissue.
- Rich in nerve endings
- Liberates PGs 99m

Q4.6: What are the other radiological investigations for osteoid osteoma?

Answer:

- Best investigation: 99mTc-HDP Scintigraphy
- A CT scan is better than an X-ray
- **IOC: Tc-HDP Scintigraphy (TC-99) >> CT scan > X-ray**

Q4.7: How are osteoid osteomas managed?

Answer: **Treatment:**

- Medical: **Aspirin** can be given for temporary relief.
- The only effective treatment is complete removal of the nidus.

Q4.8: What are the differential diagnoses of osteoid osteoma?

Answer:

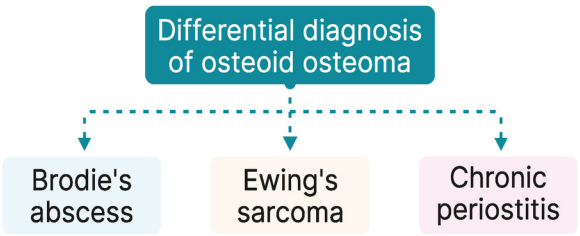

Q4.9: What are the key features of Ivory Osteoma?

Answer:

- AKA Compact Osteoma
- It is seen in membranous bones only.
- It affects either the outer or inner surface of a compact bone.
- **Most Common site**: the outer surface of the Skull (especially in front of the frontal sinus)
- **Absolutely painless**
- It can cause cosmetic problems, but surgery is not advised in such cases.
- It can form a mucocele.
- It can become a space-occupying lesion (if the inner table of the skull is involved) and can predispose to epilepsy.
- **TOC:** Excision

BIG QUESTION 5: What are the features, types, clinical presentation, diagnosis, and management of bone cysts?

Broad Answer: Bone cysts are benign fluid-filled lesions within bone, commonly seen in children and adolescents. They

are classified as unicameral (simple) or aneurysmal; presentation is often painless swelling or pathological fracture, diagnosis is by X-ray or MRI showing lytic lesions, and management includes observation, steroid injection, or surgical curettage with grafting if symptomatic.

DETAILED QUESTIONS

Q5.1: What are the types of Bone Cysts?

Answer:

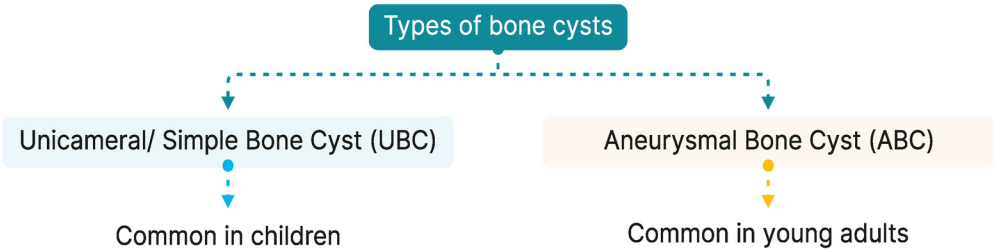

Q5.2: What are the key features of Aneurysmal Bone Cyst?

Answer:

- It affects the metaphyseal ends of long bones.
- Age group: Young adults
- Male >>> Female

Q5.3: What are the radiological findings seen in an aneurysmal bone cyst?

Answer:

- X-ray: Well-defined radiolucent cyst
  - o No malignant transformation



Q5.4: What is the difference between an Aneurysmal Bone Cyst and a Giant Cell Tumor?

Answer: An important differential diagnosis of aneurysmal bone cysts is Giant cell tumor.

Aneurysmal Bone Cyst	Giant Cell Tumor
• Filled with bloody fluid. • FNAC shows hemosiderin. • Multinucleated giant cells are visible	• FNAC shows no hemosiderin. • Multinucleated giant cells are visible

Q5.5: What is the treatment of an aneurysmal bone cyst?

Answer: TOC: Curettage with bone grafting or packing with Methyl Methacrylate cement

Q5.6: What are the key features of Unicameral/ Simple Bone Cyst?

Answer:

- It affects the metaphyseal end of long bones.
- Common site
  - o 1st: Upper end of humerus
  - o 2nd: Proximal femur

YOURWISH

- MC Age group: Children
- Microscopy: Giant cells

Q5.7: What are the radiological findings of a simple bone cyst?

Answer: X-ray

- Lytic lesion in **Juxta juxtaepiphyseal portion of the metaphysis**
- **Fallen fragment is seen (+ve sign)**
  - Fallen fragment is seen in UBC / SBC
  - Called fallen as this is present in the dependent position.
  - Gold standard

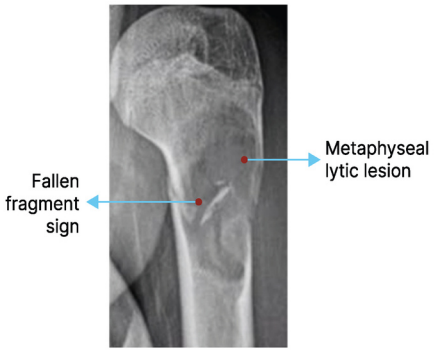

Q5.8: What is the treatment of choice for a unicameral bone cyst?

Answer: TOC: Surgical excision

Q5.9: Why are the bone cysts called bone hamartomas?

Answer: Both ABC and UBC are **not true tumours (faulty formations)**, and are thus called hamartomas.

BIG QUESTION 6: What are the features, clinical presentation, diagnosis, and management of osteogenic sarcoma?

Broad Answer: Osteogenic sarcoma is a malignant bone tumor, most commonly arising in the metaphysis of long bones, especially around the knee. It presents with pain, swelling, and sometimes pathological fractures; diagnosis is by X-ray showing a mixed lytic-sclerotic lesion with periosteal reaction, confirmed by biopsy, and management involves neoadjuvant chemotherapy, surgical resection, and postoperative chemotherapy.

DETAILED QUESTIONS:

Q6.1: What are the key features of Osteogenic Sarcoma?

Answer:

- **The most common primary malignant bone tumor of non-hematopoietic origin is/ solid malignant bone tumor.**
- It arises from common multifactorial mesenchymal tissues.
- Age group: 2nd decade (15 to 25 years)
- **Males >> Female**

Q6.2: What are the common sites of osteosarcoma?

Answer:

- Common sites:
  - 1st - Lower end of femur
  - 2nd - Upper end of tibia
- It arises from the **metaphysis.**

Q6.3: What are the types of osteogenic sarcoma?

Answer:

- It can be of 3 types:
  - Osteosclerotic

YOURWISH

  - Osteolytic
  - Both - Mixed type (most common)
- Grossly, it gives a **leg of mutton appearance**

Q6.4: What are the causes and predisposing factors of Osteogenic Sarcoma?

Answer: **Predisposing factors**

- Polyoma and SV 40 virus
- Radiation given > 2000 rads
- Chemicals: Methylcholanthrene, beryllium

Q6.5: What are the clinical features of osteosarcoma?

Answer:

- Pain is usually the first symptom. (Periosteal stretch causes pain.)
- Swelling is the second symptom.

Q6.6: What are the X-ray findings of Osteogenic Sarcoma?

PYQ: FMGE 2022

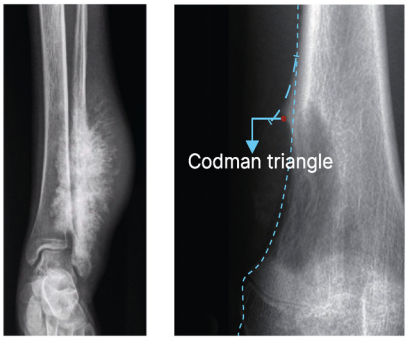

Answer:

- Hazy osteolytic area alternating with dense osteoblastic area.
- Streaks of new bone radiating outwards from the cortex - **Sunburst appearance.**
  - Microcalcification is deposited along the Sharpey fibers, which carry blood vessels. This microcalcification is seen as a Sunburst appearance.
- Reactive new bone formation elevating the periosteum - **Codman's triangle**
- A CT scan is superior to an X-ray, but a Biopsy is confirmatory.

Q6.7: What are the key features of Secondary Osteogenic Sarcoma?

Answer:

- Predisposing factors
  - Paget's disease
  - Diaphyseal achalasia (hereditary)
- **Less malignant than primary osteogenic sarcoma**
- Spread: Haematological spread
- The most common organ affected by its metastasis is the lungs.

Q6.8: What is the treatment of Osteogenic Sarcoma?

Answer:

- Surgical amputation procedure of choice.
- Chemotherapeutic agents that are used are:
  - Methotrexate
  - Citrovorum factor
  - Adriamycin

- **Latest (combined or sandwich therapy)**
  - 1st Chemotherapy
  - 2nd radiotherapy
  - 3rd surgery (limb salvage)
- Pulmonary metastasis best managed by chemotherapy **(DOC is erlotinib HCL)**
- The BCG vaccine can improve immunological status in osteogenic sarcoma.
  - BCG protects from osteogenic sarcoma and bladder cancer.

BIG QUESTION 7: What are the features, clinical presentation, diagnosis, and management of osteoclastoma?

Broad Answer: Osteoclastoma (giant cell tumor) is a benign but locally aggressive bone tumor, usually affecting the epiphysis of long bones, commonly around the knee. It presents with pain, swelling, and limited joint movement; diagnosis is by X-ray showing a lytic, eccentric epiphyseal lesion, and management includes curettage with bone grafting or wide resection in aggressive cases.

DETAILED QUESTIONS

Q7.1: What are the key features of Giant Cell Tumor?

Answer:

- It's both benign and malignant.
- It arises from the epiphysis.
- Most common Age: 15-35

Q7.2: What are the common sites of osteoclastoma?

Answer:

- Most Common site
  - 1st: Lower end of femur
  - 2nd: Upper end of tibia

Q7.3: What are the clinical features of osteoclastoma?

Answer:

- No pain, only swelling.
- **Female** > Male
- On palpation, it gives **an 'Eggshell crackling sensation'**

Q7.4: What is the characteristic histology finding seen in osteoclastoma?

Answer: Histology: Abundant tumor giant cells

Q7.5: What are the X-ray findings in a giant cell tumor?

Answer:

- The cortex is expanded and thinned.
- No periosteal new bone formation
- Thin Septa of bone traverse the interior and produce a **Soap Bubble Appearance.**



Q7.6: What is the TOC of a giant cell tumor?
Answer: Treatment of choice- Surgical excision

BIG QUESTION 8: What are the features, clinical presentation, diagnosis, and management of Ewing's sarcoma?
Broad Answer: Ewing's sarcoma is a malignant bone tumor of children and adolescents, usually in the diaphysis of long bones, presenting with pain and swelling, diagnosed by imaging and biopsy, and treated with chemotherapy, surgery, and/or radiotherapy.

Q8.1: What are the key features of Ewing's Sarcoma?
Answer:

- Commonly arises from the endothelial cells of the bone marrow of the diaphysis.
- Most common Age: 10-20
- **Male** >> Female

Q8.2: What are the common sites of Ewing's sarcoma?
Answer: Common sites are the Upper tibia and the Lower femur.

Q8.3: What are the histological features of Ewing's sarcoma?
Answer:

- Histologically: **Shows pseudo-rosettes (Homer-Wright rosettes- also seen in Neuroblastoma)**
  - Retinoblastoma shows **True /Flexner Wintersteiner rosettes.**

Q8.4: What is an important differential diagnosis for Ewing's sarcoma?
Answer:

- The main differential diagnosis for Ewing's sarcoma is **Reticulum cell sarcoma.**
  - Erythrocyte sarcoma stains for glycogen positivity, and Reticulum cell shows a silver stain.

Q8.5: What are the X-ray findings in Ewing's Sarcoma?
Answer:

- Moth-eaten appearance
- Cracked ice appearance
- **Onion peel appearance** (periosteum is layered into different layers) is also seen.
  - Differential diagnosis for Onion peel appearance :
  - Ewings sarcoma
  - Osteomyelitis
  - Malignant lymphomas



Q8.6: What is the treatment of Ewing's sarcoma?
Answer: Ewing's sarcoma is highly radiosensitive and melts when exposed to radiation, but it has a chance of recurrence.

BIG QUESTION 9: What are the features, clinical presentation, diagnosis, and management of multiple myeloma?
Broad Answer: Multiple myeloma is a malignant plasma cell tumor that commonly affects the axial skeleton, causing bone pain, anemia, hypercalcemia, renal dysfunction, and recurrent infections. Diagnosis is by serum/urine protein

studies, bone marrow biopsy, and imaging, and management includes chemotherapy, targeted therapy, bisphosphonates, and stem cell transplant.

PYQ: FMGE 2021, 2023

PYQ: NEET PG 2022

Q9.1: What are the key features of Multiple Myeloma?

Answer:

- Another name: Plasmacytoma
- Arises from the red marrow **(plasma cells)**
- **The most common primary malignant tumor in adults and the elderly**
- Age: 7th decade and above
- Common site: Vertebrae
- **Microscopy: Spokes of wheel appearance**

Q9.2: What are the X-ray findings of Multiple Myeloma?

Answer:

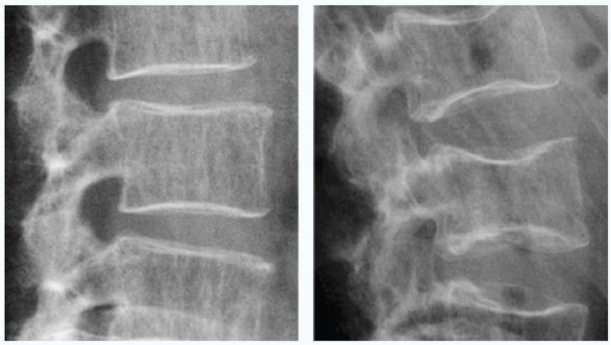

Normal Biconcave or cod fish vertebrae

- **Biconcave or cod fish vertebral bodies**

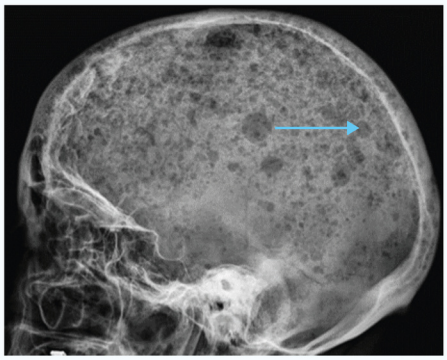

- Multiple punched-out lesions in the skull (Raindrop skull), pelvis, and flat bones.



- **Disappearing/ Vanishing vertebrae**

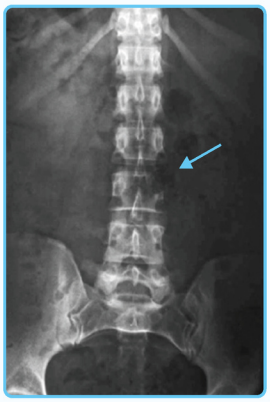

- **Pedicle sign (Winking-Owl sign)**

Q9.3: What is the treatment of Multiple Myeloma?

Answer:

- **TOC: Chemotherapy (Mnemonic: SCUM)**
  - Steroids
  - Cyclophosphamide
  - Urethane
  - Melphalan (Myleron) - DOC

YOURWISH

YOURWISH

Q9.4: What is the most common primary solid bone tumor?

Answer: MC primary solid bone tumor/primary bone tumor of non-hematopoietic origin: **Osteogenic sarcoma**

Q9.5: What is the most common malignant bone tumor?

Answer: Secondaries

Q9.6: What is the most common primary malignant bone tumor?

Answer: Multiple myeloma

Q9.7: What is the common site of osteochondroma (exostosis)?

Answer:

- Osteochondroma commonly arises from the **metaphysis** of long bones.
  - Trevor disease (epiphyseal osteochondroma)
  - Hereditary (diaphysis osteochondromas

Q9.8: What is the common site of chondroblastoma?

Answer: **Epiphysis** of long bones.

Q9.9: What is the common site of chondromyxoid fibroma?

Answer: Chondromyxoid fibroma commonly arises in the **metaphysis**.

Q9.10: What is the common site of osteoid osteoma?

Answer: Osteoid osteoma commonly occurs in the **diaphysis** of long bones.

Q9.11: What is the common site of an aneurysmal bone cyst (ABC)?

Answer: Aneurysmal bone cyst commonly arises in the **metaphysis**.

Q9.12: What is the common site of unicameral (simple) bone cyst (UBC)?

Answer: Unicameral bone cyst commonly occurs in the **metaphysis**.

Q9.13: What is the common site of osteogenic sarcoma?

Answer: Osteogenic sarcoma commonly arises in the **metaphysis** of long bones.

Q9.14: What is the common site of osteoclastoma (giant cell tumor)?

Answer: Osteoclastoma commonly arises in the **epiphysis** of long bones.

Q9.15: What is the common site of Ewing's sarcoma?

Answer: Ewing's sarcoma commonly affects the **diaphysis** of long bones.

10. PERIPHERAL NERVE INJURY

BIG QUESTION 1: What are the general facts, pathogenesis, classifications, investigations, and management principles of peripheral nerve injuries?

Broad Answer: Peripheral nerves include spinal and cranial nerves, each with specific anatomy and distribution. Injury to these nerves can cause degeneration, regeneration, and functional loss, with recovery depending on injury type. Classification systems (Seddon, Sunderland) help determine prognosis and management, which may be conservative or surgical depending on severity and time since injury.

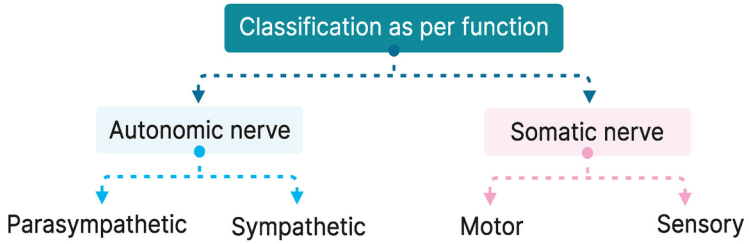

DETAILED QUESTIONS

Q1.1: What are the main types and structures of peripheral nerves?

Answer:

- Types:
  - Spinal nerves - 31 pairs (8 cervical, 12 thoracic, 5 lumbar, 5 sacral, 1 coccyx)
  - Cranial nerves - 12 pairs (total peripheral nerves = 43 pairs)
    → Peripheral nerves that mainly innervate anatomical structures in the head and neck, except for the Vagus.
- Structure:
  - Basic unit: Axon
  - Axons → fascicle → nerve
  - Connective tissue layers: Endoneurium (around axon), Perineurium (around fascicle), Epineurium (around nerve)

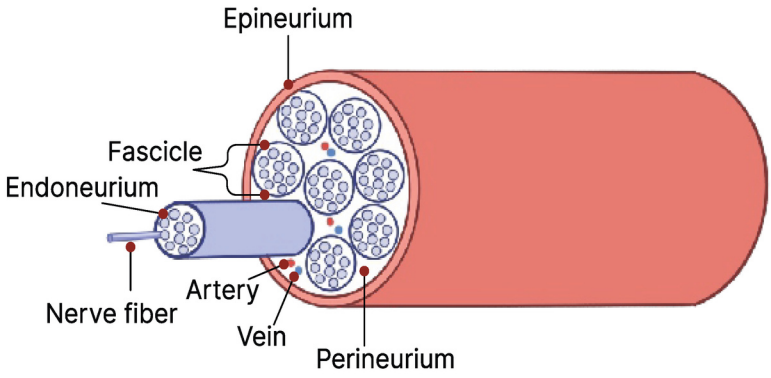

Q1.2: What are the causes of peripheral nerve Injury?

Answer:

PYQ: NEET PG 2023 PYQ: FMGE 2023

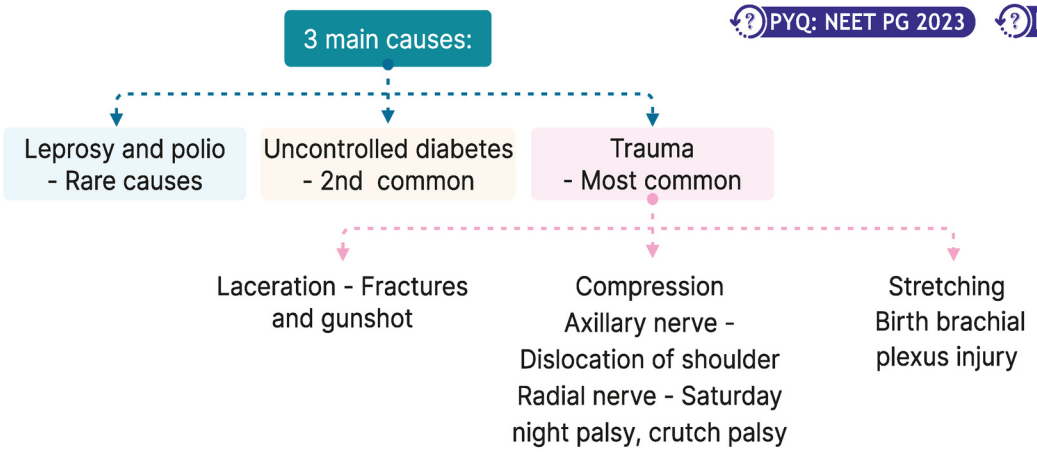

Q1.3: What is the pathogenesis of peripheral nerve injury?

Answer:

Nerve injury

↓

Neurons detached from their nucleus

↓

Common: Degeneration of neuron distal to the point of injury **(Wallerian/ Secondary Degeneration)**

or

Rare: Some degeneration can happen proximal to the point of injury (Retrograde/ Primary Degeneration)

- Time taken for degeneration depends on:
  - Sensory or motor
  - Size of nerve fiber
  - Myelination of a nerve fiber
- Within a few days of injury

Axons in the distal segment are fragmented and shrink

↓

Axonal debris

↓

Removed by macrophages (phagocytosis)

↓

The gaps are filled by Schwann cells

- After Degeneration
  - Nerve regeneration starts.
  - Nerve regeneration rate is 1 mm/day or approximately 1 inch/month

Q1.4: What are the signs of regeneration?

Answer:

- Motor March: Muscles nearest to the site of injury are reinnervated first, followed by other distal muscles
- Tinel's Sign:
  - Also known as **Hoffman's sign**
  - **Law of Projection:**
    - → On percussion, a tingling sensation is felt only distally along the course of the nerve
    - → No tingling sensation on the percussion site

YOURWISH

- With progressive regeneration tinel sign moves distally - a favourable sign
- A positive Tinel sign indicates
  - → **Axonal regeneration**
  - → **Sensory recovery**

Q1.5: What is Seddon's classification?

Answer:

- Most widely used
- Three types:
  - Neuropraxia
  - Axonotmesis
  - Neurotmesis

Q1.6: What are the key features of neuropraxia?

Answer:

- Transient episode of complete motor with a little sensory paralysis
- Temporary physiological disruption of nerve impulse **(No anatomical damage)**

- Complete recovery is possible and has an excellent prognosis
- Thought to be a local reaction to ischemia that results in ion-induced conduction blockage
- **No Wallerian degeneration**
- **Tinel's sign: Negative**
- Recovery
  - Begins within 2 to 3 weeks.
  - Complete recovery can be seen within 8 weeks
- Examples
  - Crutch palsy
  - Saturday night palsy

Q1.7: What are the key features of axonotmesis?

Answer:

- More severe injury, involving loss of continuity of the axon, with maintenance of continuity of the outer sheath
- The motor, sensory, and autonomic paralysis is complete
- Denervated muscle atrophy can be progressive
- Wallerian Degeneration (distal)is seen
- Tinel's sign: Positive progressive
- Motor march is seen
- Recovery is never complete
- Examples - Closed fractures and Dislocations

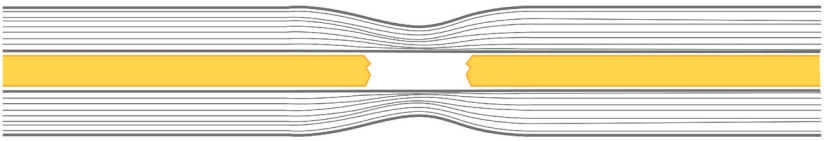

YOURWISH

YOURWISH

Q1.8: What are the key features of neurotmesis?

Answer:

- Complete transection of the nerve
- Common in severe lacerated injuries
- Tinel's sign: Positive and non-progressive
- Spontaneous recovery is not possible
- Requires nerve repair
- If ends are widely separated in Neurotmesis, it can lead to:
  - Proximal - Neuroma
  - Distal - Glioma



Q1.9: What is Sunderland's classification (1951)?

Answer:

- Type I
  - Focal conduction block
  - No Wallerian degeneration
  - Similar to Neuropraxia
- Type II
  - Axonal disruption
  - Similar to Axonotmesis
- Type III
  - Axon + Endoneurium disruption
- Type IV
  - Axon + Endoneurium + Perineurium disruption
- Type V
  - Axon + Endoneurium + Perineurium + Epineurium disruption
  - Similar to Neurotmesis

Q1.10: What are the investigations for peripheral nerve Injuries?

Answer:

- X-ray
  - This is needed to diagnose associated fractures and dislocations
- MRI
  - Very useful in brachial plexus injury to evaluate the avulsion of nerve roots from the spinal cord.
- Nerve Conduction Studies (NCS)
  - Important means of evaluating the functional integrity of peripheral nerves.
  - NCS + Needle EMG (Electromyograph)
    - → Determine whether the nerve injury is complete or incomplete
    - → Best guide to access prognosis
- Electromyograph (EMG)
  - Performed only after 4 weeks of nerve injury

- If performed before 4 weeks, it may give false results
- Evidence of denervation - Indicates the presence of muscle fibrillation.
- Evidence of Reinnervation - Presence of motor unit potential (MUP)

- High-Resolution USG
  - Shows individual nerve fasciculi.
  - The entire anatomical course of the peripheral nerve can be depicted
  - Reveals the discontinuity of the nerve
  - Clearly shows scar tissue and the presence of a neuroma

Q1.11: What is general management of peripheral nerve injuries?

Answer:

Conservative Management

- Closed nerve injury with Neuropraxia -Specific splints are used

Surgery

- Surgical intervention is needed if nerve injury doesn't show signs of recovery by 6 months
- Endoneurolysis
  - When the nerve is stretched or chronically compressed, internal scarring may occur
  - So, the epineurium is opened under a microscope, and the scar within the nerve is removed
  - This will restore the nerve continuity
- Neurorrhaphy
  - Nerve repair
  - Direct approximation of cut ends
  - Should be done without nerve tension
- Nerve Graft
  - A segment of an unrelated nerve is used to replace or bridge an injured portion of the nerve
  - The sural nerve is preferred
- Tendon Transfer
  - The main indication for tendon transfer is a peripheral nerve injury that has no potential to recover.
  - Critical period of nerve recovery:
    - → Upper limb nerves- 6 to 9 months
    - → Lower limb nerves- 9 to 12 months

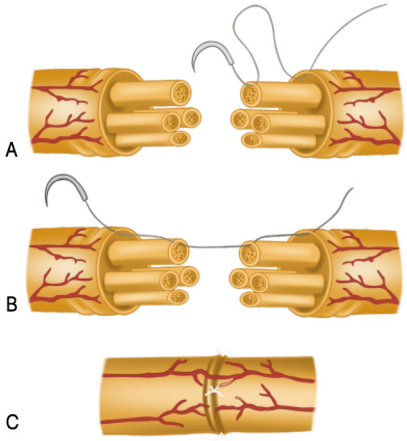

- Tendon transfer is the only alternative to regain some or all functions after the critical period

Q1.12: What are the basic criteria that should be fulfilled before tendon transfer?

Answer:

- The joint should be supple and should not be stiff.
- It should pass through a healthy bed of tissue free from inflammation, edema, and scar
- The donor tendon should have adequate strength (Grade IV muscle power)
- The donor muscle must be expandable
- The donor muscle should be a synergistic muscle
- Transfer should be in the straight line of pull
- One donor muscle is for one single function

11. OTHER NERVE INJURIES

BIG QUESTION 1: What are the causes, clinical features, and management strategies for radial nerve injury at different anatomical levels?

Broad Answer: Radial nerve injury can occur at the axilla, spiral groove, radial tunnel, or wrist due to trauma (fractures of the humerus, dislocations), compressive neuropathies ("Saturday night palsy"), or entrapment syndromes. It produces level-specific deficits such as wrist drop, finger drop, or isolated thumb extension loss, often with sensory loss over the dorsum of the hand. Diagnosis is mainly clinical, supplemented by nerve conduction studies. Management includes splinting, physiotherapy, and surgical exploration or tendon transfer in non-recovering cases.

DETAILED QUESTIONS

Q 1.1:What are the causes of Radial nerve injury?

Answer:

PYQ: FMGE 2021 PYQ: NEET PG 2022

In the arm:

- Holstein - Lewis fracture: Lower third humeral fracture -oblique in nature with an entrapped radial nerve
- Crutch palsy
  - When the patient holds the crutch, the wooden part compresses the radial nerve at the arm level
  - Neuropraxia type of radial nerve palsy



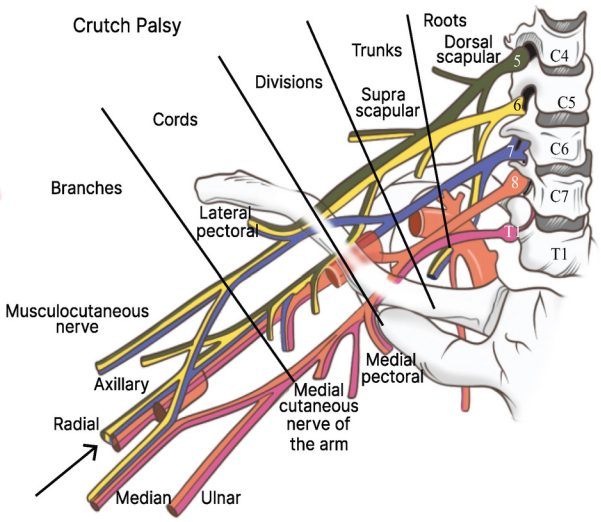

Saturday night palsy

- Neuropraxia type of radial nerve palsy



In the forearm

- Elbow dislocation
- Fractures around the elbow
- Tight POP cast

YOURWISH

- Radial tunnel syndrome
  - In the forearm, the nerve may be compressed at the tendinous origin of the supinator, i.e., the Arcade of Frohse
- Wardenberg syndrome
  - It is the entrapment of the superficial sensory branch of the radial nerve in the distal forearm
  - It is otherwise called watch palsy

Q1.2: How does Radial nerve injury present clinically?

Answer :

At the axilla	At radial groove	At or below the elbow
The following functions are lost : • Elbow extension • Wrist extension • Finger extension • Sensation over the posterior part of the forearm and dorsum of the hand  Wrist drop	The following functions are lost : • Triceps supply is preserved, so the elbow extension is present • Extensor muscles of the wrist • Extensor muscles of the finger • Extensor muscles of the thumb • Sensation over the radial dorsal part of the hand & posterior part of the forearm	• In isolated PIN palsy, sensation is spared, only finger & thumb drop present • In a distal radial sensory lesion at the wrist no motor weakness, only numbness on the dorsum of the hand, sparing the little finger

Q1.3: What are the treatment options for radial nerve injury?

Answer :

1. Cock-up splint
2. Dynamic splint
3. Nerve repair
4. Tendon transfers

Q1.4: What is Jones' triple transfer?

Answer :

- If the nerve doesn't recover within 9 months after the repair - Jones Triple Transfer
  - Pronator teres → Extensor carpi radialis brevis
  - Flexor Carpi Ulnaris → Extensor digitorum communis
  - Palmaris Longus → Extensor Pollicis Longus

Q1.5: What are the disadvantages of Jones' triple transfer?

Answer :

- Disadvantages are:
  - Large incision
  - Multiple scars
  - Bulging of the Pronator teres

YOURWISH

YOURWISH

Q1.6: What is Modified Jones Transfer and its advantages?

Answer :

- Pronator teres → Extensor Pollicis Longus
- Flexor Carpi Radialis → Extensor digitorum communis & Extensor Carpi Radialis Longus
- Advantages:
  - Smaller incision
  - More cosmetic
  - No bulging of PT

BIG QUESTION 2: What are the causes, key diagnostic tests, and treatments for median nerve injury?

Broad Answer: Median nerve injury occurs from trauma at the arm/elbow, entrapment at the pronator teres or carpal tunnel, or lacerations at the wrist. It leads to weakness of forearm pronation, thumb opposition, and loss of precision grip with sensory loss in the radial three-and-a-half fingers. Clinical tests such as the pen test, Ochsner's clasp test, and Phalen's maneuver help in diagnosis. Management includes conservative measures for compressive neuropathies and surgical repair, grafting, or tendon transfer when deficits persist.

DETAILED QUESTIONS

Q 2.1: What are the causes of medial nerve injury?

PYQ: FMGE 2020,2021

PYQ: NEET PG 2020

Answer :

- In the arm
  - Tight Tourniquet's
  - Humerus fracture
- In the elbow
  - Supracondylar fracture

o Posterior dislocation elbow

  - Entrapment at the distal humerus by Ligament of Struthers
- In the wrist
  - Carpal Tunnel Syndrome

Q 2.2: What are the various tests performed to evaluate median nerve injury clinically?

Answer:

- Pointing index (Ochsner's Clap Test)
  - Otherwise called the Benediction sign
- The Ape Thumb Deformity (Abductor Pollicis Brevis Paralysis)
- Test for FDS (Flexor Digitorum Superficialis)
- Test for FDP (Flexor Digitorum Profundus)
- Test for FPL (Flexor Pollicis Longus)
- Test for APB (Pen Test)
- Test for Opponens Pollicis (O sign)

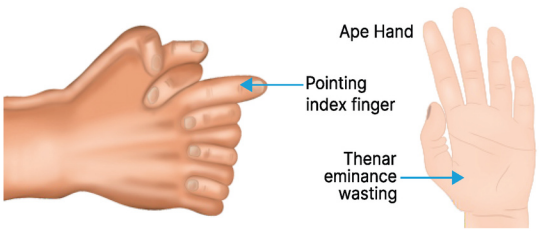

Q 2.3: How do you test for FDS?

Answer :

- The patient is asked to flex the middle finger at the level of the metacarpophalangeal joint.
- The patient will be unable to flex the finger if the FDS is not acting

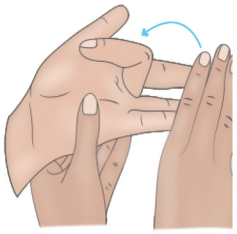

Q 2.4: How do you test for FDP?

Answer :

- The patient is asked to flex the terminal phalanx of the middle finger.
- Inability to do so shows paralysis of the FDP

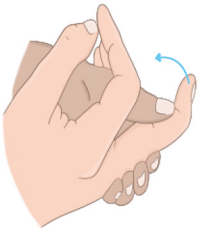

Q 2.5: How do you test for FPL?

Answer :

- The resistance is applied to the thumb of the patient, and asked to flex the thumb.
- Inability to do so shows FPL paralysis.



Q 2.6: How do you test for APB?

Answer:

- Pen Test
  - o A pen is held behind the thumb, and the patient is asked to touch the pen with the thumb.
  - o Inability to do so shows paralysis of the Abductor Pollicis Brevis.



Q2.7: How do you test for Opponens pollicis?

Answer :

- Test for Opponens Pollicis (O sign)
  - o If opponens pollicis is paralyzed, the O sign is not possible to make

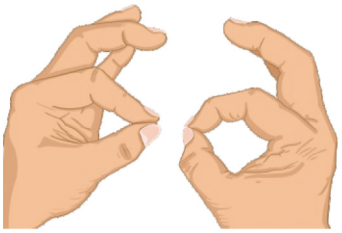

Q 2.8: How do you treat median nerve injury?

Answer :

- If no recovery by 9 months in high lesion and 12 months in low lesion, tendon transfer should be done
- For high median nerve palsy
  - o The transfer of BR (Brachioradialis) or ECRL (Extensor Carpi Radialis Longus) to Flexor pollicis Longus (FPL) restores the lost thumb flexion and side-to-side transfer of FDP of the index finger
- For Low median nerve palsy
  - o To restore the opposition of the thumb, the Flexor digitorum superficialis of the middle finger or the Extensor Carpi radialis is used

BIG QUESTION 3: What are the common causes, characteristic signs, and correction methods for ulnar nerve injury?

Broad Answer: Ulnar nerve injury is commonly due to elbow fractures/dislocations, cubital tunnel entrapment, or Guyon's canal compression at the wrist. It produces sensory loss in the ulnar digits, weakness of intrinsic hand muscles, Froment's sign, and the classic claw hand deformity. Diagnosis relies on clinical examination supported by electrodiagnostic studies. Management includes splinting, nerve decompression or repair, and surgical correction of clawing by static or dynamic tendon transfer.

DETAILED QUESTIONS

Q3.1: What are the causes of ulnar nerve injury?

Answer:

1. Dislocation of the elbow
2. Supracondylar fracture
3. The most common site of Ulnar nerve entrapment is Cubital tunnel syndrome (Epicondylar groove)
4. The second most common site of Nerve entrapment is Guyon's canal

Q3.2: What are the various tests used to evaluate clinically?

Answer:

- Test for FDP (Flexor Digitorum Profundus)
- Test for FCU (Flexor Carpi Ulnaris)
- Test for Abductor digiti minimi
- Test for Palmar interossei (Card test)
- Egawa Test - Test for Dorsal interossei
- Froment's Sign - Book test

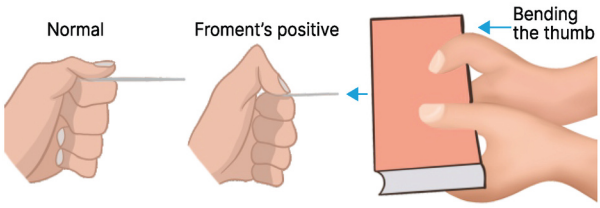

Q3.3: How do you test for FDP?

PYQ: NEET PG 2022

Answer:

- Test for FDP (Flexor Digitorum Profundus)
  - Ask the patient to do flexion of the terminal phalanx



Q3.4: How do you test for FCU?

Answer:

- Test for FCU (Flexor Carpi Ulnaris)
  - Ask the patient to forcefully adduct against resistance
  - Do ulnar deviation against resistance
  - The prominence of the Flexor carpi ulnaris can be seen



Q3.5: How do you test for the Abductor digit minimi?

Answer:

- Test for Abductor digiti minimi
  - Ask the patient to abduct the little finger against resistance



Q3.6: How do you test for palmar interossei?

Answer:

- Test for Palmar interossei (Card test)
  - The palmar interossei cause adduction
  - The patient is asked to hold a card between the index and middle fingers, and the examiner pulls the card.
  - If the patient can't adduct the palmar interossei, the card can be easily pulled.



Q3.7: What is the Egawa test?

Answer:

- Egawa Test - Test for Dorsal interossei
  - With palm flat on the table, the patient is asked to move the middle finger sideways (test for the dorsal interossei of the Middle finger)



Q3.8: What is partial and total claw hand?

PYQ: NEET PG 2023

PYQ: FMGE 2022

Answer:

- Partial claw hand
  - Only the little and ring finger goes for clawing due to pure ulnar nerve injury.



- Total claw hand
  - Clawing of all the fingers of the hand due to the injury to both the ulnar and the median nerves.

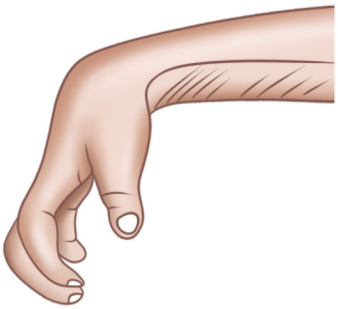

Q3.9: What is the ulnar paradox?

Answer:

- Ulnar paradox
  - When the lesion is high, the deformity is less

Q 3.10: What is Tardy ulnar nerve palsy?

- Tardy ulnar nerve palsy

YOURWISH

- Very slow development of ulnar nerve palsy
- Cubitus valgus is the common cause of ulnar nerve palsy

Q 3.11: What's the treatment for ulnar nerve injury?

Answer:

- The procedure to correct a claw hand is of two types
  - Static procedures
    1. Zancolli capsulodesis
    2. Zancolli Lasso procedure
- Dynamic procedure
- Modified Bunnel Technique
  - The FDS (Flexor Digitorum Superficialis) tendon of the middle finger is divided into a number of slips
- Brand technique
  - Here Extensor Carpi Radialis Brevis as a power

BIG QUESTION 4: What is the mechanism, presentation, classification, and management of Erb's palsy?

Broad Answer: Erb's palsy results from traction injury to the upper brachial plexus (C5-C6 roots), typically during difficult delivery or falls. It causes paralysis of shoulder abductors and elbow flexors, producing the characteristic "waiter's tip" posture with arm adduction, internal rotation, and pronation. Severity is classified into neuropraxia, rupture, or avulsion. Many cases recover spontaneously with physiotherapy; surgical nerve grafting or transfers are indicated if biceps function does not return within 3-6 months

DETAILED QUESTIONS

Q4.1: What's a birth brachial plexus injury?

PYQ: AIIMS 2019 PYQ: FMGE 2019



Willhelm ERB Duchenne de Boulogne

Answer:

- The birth brachial plexus palsy (Obstetric plexus injury) is partial or complete paralysis of upper brachial plexus -C5 & C6 roots
- This was introduced by Wilhelm ERB & Duchenne de Boulogne
- The most commonly involved nerves in the birth brachial plexus are
  - Suprascapular nerve
  - Musculocutaneous nerve
  - Axillary nerve

Q 4.2: What is Erb's palsy?

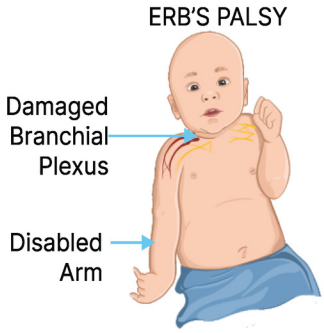

Answer:

- In Erb's palsy, there is paralysis of the deltoid, biceps, & brachialis muscles with loss of sensation in the arm
  - The upper limb assumes a characteristic position with the arm hanging by the side, rotated internally with the elbow in extension & forearm pronated

Q4.3: What is the waiter's tip hand?

Answer:

- Waiter's Tip Hand / Police Man Tip Hand:
  - The arm can't be abducted
  - The elbow can't be flexed
  - The forearm can't be supinated

Q4.4: What's the mechanism that's involved with shoulder dystocia?

Answer:

- It was generally accepted that the injury occurred in cases of shoulder dystocia, and the mechanism was the traction to the neck caused by the pull of hand or instruments like forceps or vacuum
- Now it is believed that the trauma during delivery may not be the cause in every case; it could be caused by intrauterine maladaptation

Q4.5: Describe the classical birth plexus injury.

Answer:

- The classical birth plexus injury is the damage to the C5, C6 roots, but all roots can be involved
- The level & nature of root involvement vary from a neuropraxia to varying levels of axonotomesis to neurotmesis
- In the worst injuries, even a root avulsion is possible

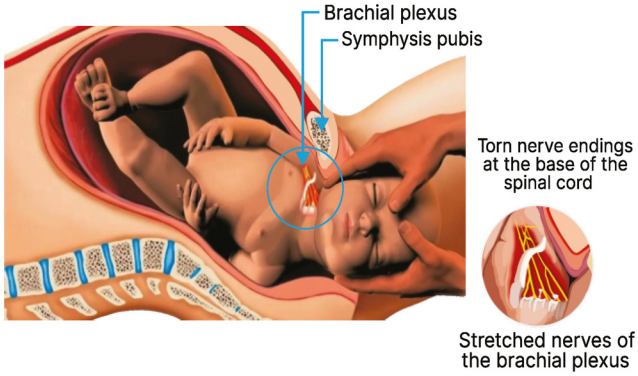

Q4.6: What are the clinical features of Erb's palsy?

PYQ: INICET 2023 PYQ: NEET PG 2023

Answer:

- Apart from the waiter's tip hand or police man tip hand, the patient has redness in the upper arm
- Winging of the scapula
- Horner syndrome - components
  - Ptosis
  - Miosis
  - Anhydrosis
  - Hoarseness of voice

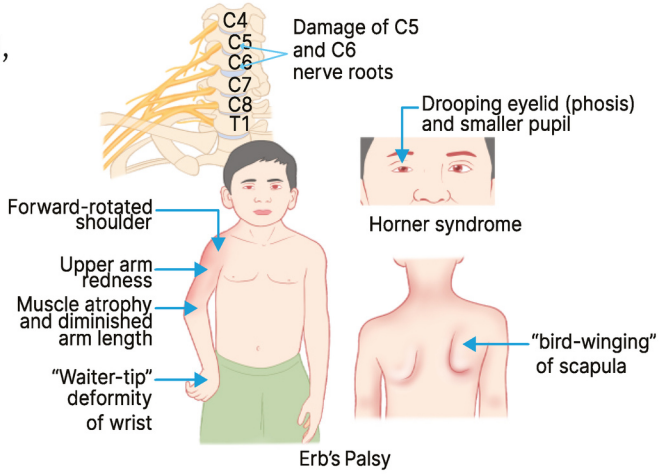

Q4.7: Describe the classification used for Erb's palsy?

Answer:

- Narak's Classification of Erb's Palsy
- Grade 1: C5-C6 roots
  - Paralysis of Deltoid and Biceps
  - Intact wrist finger flexion/extension
- Grade 2: C5-C6 roots
  - Paralysis of the Deltoid, Biceps, Wrist and Finger flexion and extension
  - Intact wrist and finger flexion

- Grade 3: C5 -T1 roots - Total brachial plexus
- Grade 4: C5-T1 roots - Associated with Horner's syndrome.

Q4.8: Explain the treatment protocol of Erb's palsy?

Answer :

- Spontaneous recovery is possible in nearly over 90% of cases & others may need surgery
- An electrophysiology study is recommended at 4 weeks initially and confirm the diagnosis and get a baseline reading
- Surgical treatment

Q4.9: What's the surgical treatment for Erb's palsy?

Answer:

- Indication for surgery: If there is no Biceps function at 3 months.
- Surgery consists of a complete exploration of the supra & infraclavicular plexus & nerve repair using microsurgical techniques
- The source of nerve grafts is both the sural nerves and the ipsilateral medial cutaneous nerve of the forearm
- If the nerve repair fails, secondary surgery has to be done

Q4.10: Describe the secondary surgery.

- Secondary is performed to treat either untreated older children or as a follow-up to primary nerve reconstruction.
- Secondary surgery involves surgery on the shoulder, elbow, as well as hand
  - Shoulder: Release of contracted pectoralis major & subscapularis, or in late cases, derotation osteotomy of the humerus
  - Elbow: The surgery is directed towards the restoration of flexion or extension
    - → For elbow flexion, the triceps is transferred to the biceps; Lattissimus dorsi can also be transferred
    - → For extension, the transfer of choice is Deltoid to Triceps
  - Hand: The tendon transfers are done depending on the nerve injury
- 90 % will recover spontaneously
- 10% will go for surgery
- If nerve transfer is not successful, then do tendon transfer

BIG QUESTION 5: What are the injury mechanisms, presentation, and prognosis in Klumpke's paralysis?

Broad Answer: Klumpke's paralysis is caused by traction on the lower brachial plexus (C8-T1), often from breech delivery, sudden upward pull, or cervical rib. It presents with paralysis of intrinsic hand muscles, resulting in claw hand, sensory loss in the medial forearm and hand, and sometimes Horner's syndrome due to sympathetic involvement. Classification distinguishes pre- and postganglionic lesions. Prognosis is poor in root avulsions, while postganglionic lesions may benefit from nerve repair or tendon transfer.

DETAILED QUESTIONS

Q5.1: What is Klumpke's palsy?

Answer:

- Augusta Dejerine klupke (1885)
- In Klumpke's palsy, the lowest roots, C8-T1, are paralyzed

- Clinically, it presents as "Claw Hand " (Intrinsic Minus Hand) deformity, with numbness in the C8-T1 distribution
- If Horner syndrome is present, there is miosis (Constriction of pupils) in the affected eye



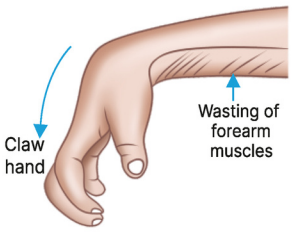



Johann Friedrich Horner



Q 5.2: What's the mechanism of injury in Klumpke's paralysis? PYQ: NEET PG 2019

Answer:

- The risk of injury to the lower brachial plexus results from traction on an abducted arm, as with an infant being pulled from the birth canal by an extended arm above the head
- In Civilian injuries, someone can catch themselves on a branch as they fall from a tree
- It has a poor prognosis if the lesion is a Preganglionic injury.

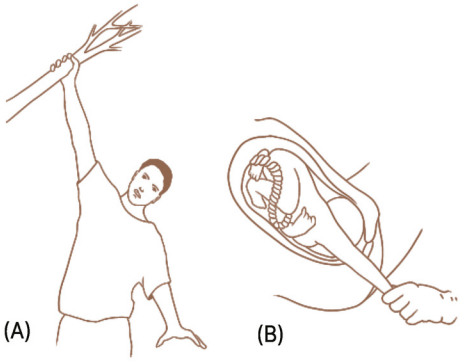

Q5.3: What's the difference between Erb palsy and Klumpke's palsy?

Answer:

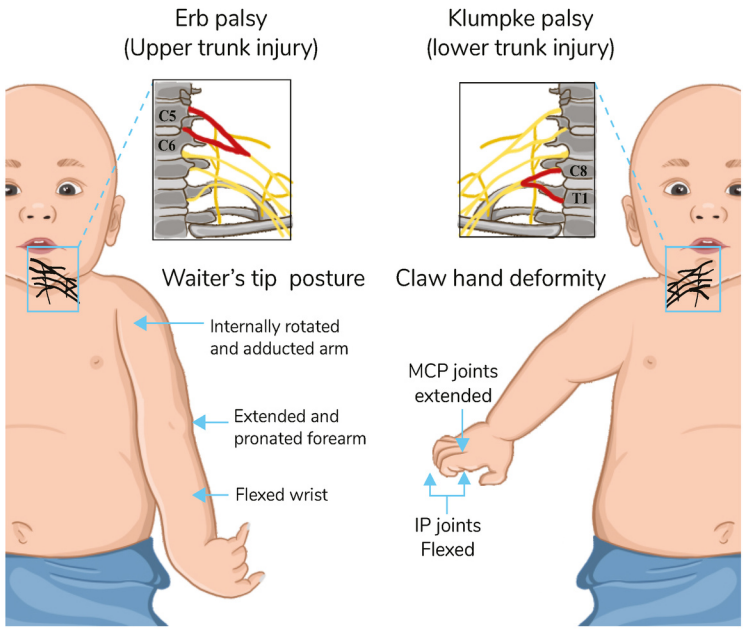

BIG QUESTION 6: What are the causes, clinical presentation, and surgical options for common peroneal nerve injury?

Broad Answer: The common peroneal nerve is vulnerable around the fibular neck, where trauma, tight plaster casts, or habitual leg crossing may injure it. Clinically, it produces foot drop due to loss of dorsiflexors and evertors, along with sensory loss over the lateral leg and dorsum of the foot. Diagnosis is clinical and supported by electrodiagnostic testing. Management involves ankle-foot orthosis, physiotherapy, and if no recovery occurs after 12 months, tendon transfers (tibialis posterior to dorsum of foot) may be performed.

YOURWISH

YOURWISH

DETAILED QUESTIONS

Q6.1: What are the causes of common peroneal nerve injury?

Answer:

1. Neck of fibula fracture - most common cause
2. Hip dislocations
3. Knee dislocations
4. Proximal tibial fracture
5. Tight cast

Q6.2: What are the clinical features of common peroneal nerve injury?

PYQ: FMGE 2020

Answer:

- Foot drop
- High stepping gait
- Unable to evert the ankle
- Decreased sensation in the dorsum of the foot and the outer part of the leg



Foot Drop

Q 6.3 : Describe the treatment options for common peroneal nerve injury?

Answer:

- If no recovery even after 12 months of nerve repair, tendon transfer has to be done
- Tibialis posterior tendon transfer
  - The two commonly followed methods
    - → Through the Interosseous route (Barr Technique)
    - → Circumtibial route (Ober's Technique)
- Double tendon transfer
  - Here Tibialis posterior and Flexor digitorum longus are used as donors.

12. MISCELLANEOUS TOPICS PART -1

BIG QUESTION 1: What are the causes, pathology, clinical features, investigations, and management of intervertebral disc prolapse?

Broad Answer: Intervertebral disc prolapse occurs when the nucleus pulposus protrudes through the annulus fibrosus, most commonly in the lumbar spine (especially L5-S1). Causes include disc degeneration (main), trauma, mechanical loading, nutrient transport deficiency, genetic factors, and lifestyle influences. Pathology includes disc bulge, herniation (protrusion, extrusion, sequestration), and desiccation. Clinical features vary with site and type of herniation, often presenting with sciatica, weakness, and paraesthesia, with root-level-specific signs. MRI is the gold standard investigation. Management ranges from conservative therapy (rest, NSAIDs, physiotherapy) to surgery (discectomy, microdiscectomy) when indicated.

DETAILED QUESTIONS

Q1.1: What are the most common sites and causes of disc herniation?

Answer:

- Intervertebral disc herniation occurs when a part or all of the Nucleus pulposus protrudes through the Annulus fibrosus.
- Most common site: Lumbar spine (especially L5-S1)
  Next most common: Cervical spine
- Common causes:
  - Disc degeneration (most common)
  - Trauma (next most common)
  - Mechanical loading of the nucleus pulposus
  - Poor nutrient transport to the disc (worsens with ageing, smoking)
  - Genetic factors and smoking
  - Lower lumbar segments are more vulnerable to degenerative changes
  - The decreased water content of the disc

Q1.2: What are the pathology and stages of Disc Prolapse?

Answer:

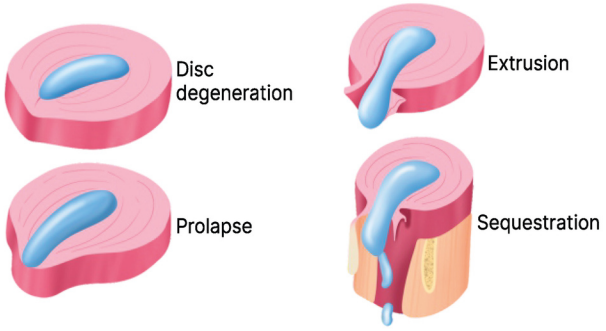

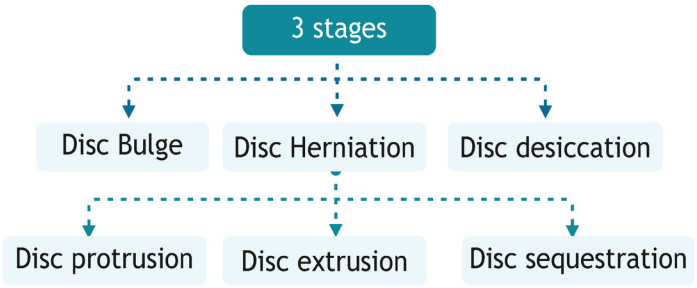

Q1.3: What is a Disc Bulge?

Answer:

- The Nucleus pulposus intrudes into the fissure in the inner layer of the Annulus & pushes it, producing a **bulge in the Annulus.**
- The circumference of the Annulus fibrosus extends beyond the vertebral bodies.
- The disc bulge may be circumferential or localised.

Q1.4: What are the key features of a Disc Herniation?

Answer:

- A fragment of the Nucleus pulposus is pushed out of the Annulus into the spinal canal through a tear in the Annulus fibrosus.
- The herniated disc may compress an adjacent spinal nerve.
- The herniated disc impinges upon the nerve associated with the inferior vertebra.
  - E.g. L4/L5 disc herniation will compress the L5 nerve root.
- The most common site of a Disc herniation is L5-S1.
  - The reason is that the posterior longitudinal ligament is thinnest at its caudal end.
- Disc Herniation can be:
  - Posterolateral disc herniation - most common
  - Central disc herniation - second most common
- The three subtypes are:
  - Disc protrusion
  - Disc extrusion
  - Disc sequestration

Q1.5: What is Disc Desiccation?

Answer:

- This is the end stage
- The Nucleus pulposus shrinks as the gelatinous form is replaced by fibrous tissue.
- The resultant flattened disc may impinge on the spinal nerve, leading to pain & weakness.

Q1.6: What are the Clinical Features of Disc Herniation?

Answer:

- **Sciatica**
  - Pain radiates along the sciatic nerve down the back of the thigh & calf into the foot.
  - Caused by compression of the lower spinal nerve roots L5 & S1

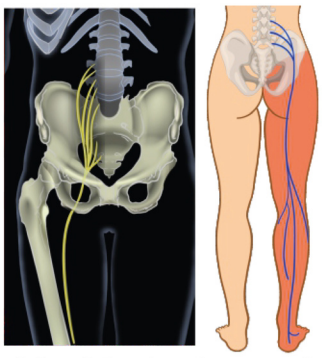

Pain radiating along the course of the sciatic nerve

- Pain from the herniation increases with activity & decreases with rest, especially in **Semi Fowler's position -** Hip and knee joints are flexed → The sciatic nerve is relaxed → Pain reduces
- Other symptoms of Disc Herniation are: Weakness & Paraesthesia.
- Patients with Lumbar disc prolapse often present with a Sciatic List (Sciatic scoliosis)
  - Axillary type of disc prolapse - The trunk is tilted to the same side
  - Shoulder type of disc prolapse - The trunk is tilted to the opposite side

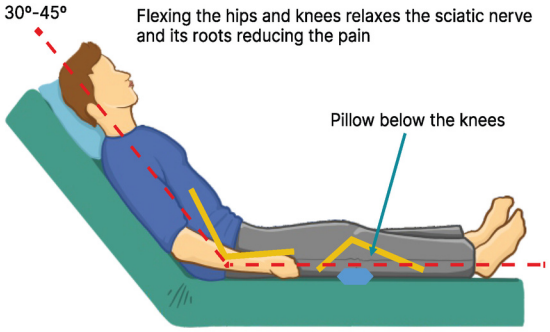

Q1.7: What is the Straight Leg Raising Test?

Answer:

- The patient is in a supine position
- Extend the knee, and slowly raise the leg
  - 0-35°
  - 35-75°
  - Over 75°
- Significant if patients have severe low back pain in the initial 0-35°

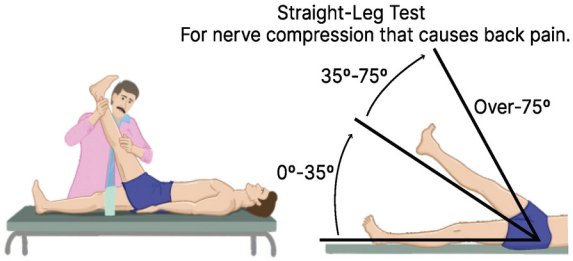

Q1.8: What is the Lasegue test?

Answer:

- Modification of the Straight Leg Raising Test
- The leg is raised and relaxed at a point. o
- Dorsiflex the foot at 10 lower than where the pain is felt in the Straight Leg Raising Test.
  - Causes pain in sciatica.

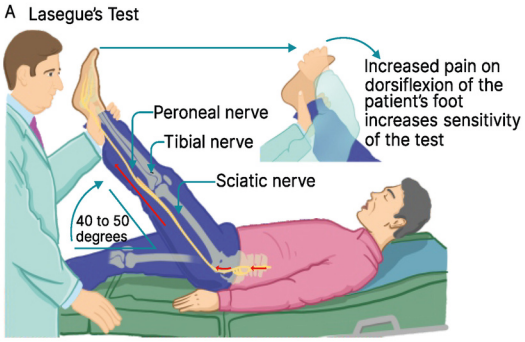

Q1.9: What is the Femoral Stretch Test?

Answer:

- The patient is in a prone position
- Extend the hip and flex the knee
- The patient may experience stretch pain

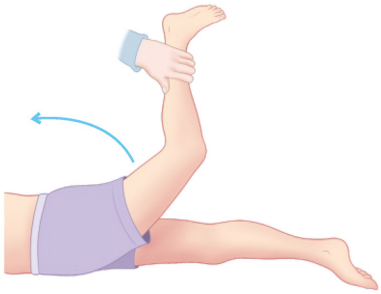

Q1.10: How is the localisation of the Level L4 Root Level done?

Answer:

- Paraesthesia on the medial side of the leg below the knee
- Motor weakness of the knee extensors
- Sensory deficit over the medial side of the leg & great toe
- **Knee jerk: Absent**

YOURWISH

YOURWISH

Q1.11: How is the localisation of the Level L5 Root Level done?

Answer:

- Paraesthesia on the lateral side of the leg & dorsum of the foot.
- Weakness of:
  - Extensor hallucis longus (EHL)
  - Gluteus medius
  - Extensor digitorum longus (EDL)
  - Extensor digitorum brevis muscle (EDB)
- Sensory loss over the lateral aspect of the leg and dorsum of the foot
- Reflexes: Not affected

Q1.12: How is the localisation of the Level S1 Root Level done?

Answer:

- Paraesthesia on the lateral side of the foot & little toe, up to the back of the calf.
- Weakness of:
  - Flexor hallucis longus muscle (FHL)
  - Peroneus longus & Brevis
  - Gastrosoleus
  - Gluteus maximus
- Sensory loss over the lateral aspects of the foot & little toe
- **Ankle jerk: Absent**

Q1.13: What are the radiological findings of Disc prolapse?

Answer: MRI is the Gold standard IOC for disc prolapse.

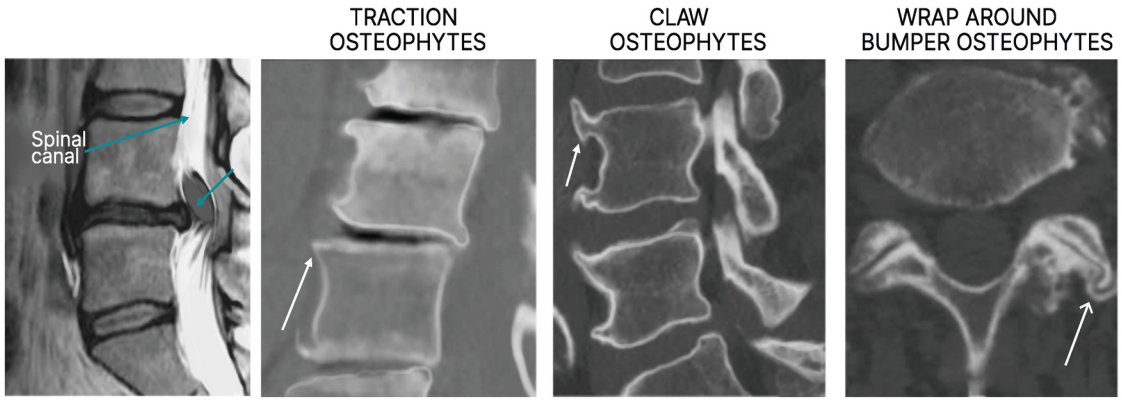

X-ray

- Mainly used to diagnose other abnormalities in vertebrae rather than to diagnose intervertebral disc prolapse.
- Features suggestive of intervertebral disc prolapse are:
  - Reduced intervertebral disc space
  - **Three types of osteophytes**
    - → Traction osteophytes
    - → Claw osteophytes
    - → Wraparound bumper osteophytes

Q1.14: What are the treatment options for Disc prolapse?

Answer:

Non-surgical therapy	• Bed rest: 7 days • Skin traction o Purpose: Intervertebral disc space increases • NSAIDs/Oral steroids : Methylprednisolone • Epidural steroids o When Oral steroids are not effective. • Physiotherapy • **Contraindications** o **Cauda equina syndrome, or** o **Severe motor deficit**
Surgical therapy	• Open Discectomy o Laminectomy & Discectomy o Microdiscectomy • **Micro - Endoscopic Discectomy** o Superior o Less injury to surrounding structures

Q1.15: What is the pathophysiology of Hungry Bone Syndrome?

Answer:

- HBS is typically noted after parathyroidectomy or thyroidectomy.
- Exaggerated hypocalcemia following parathyroidectomy → Decreases Osteoclastic activity without decreasing Osteoblastic activity. → This, in turn, leads to an increased influx of calcium. → Bone eats lots of calcium: Hungry bone. → This worsens Hypocalcemia.

Q1.16: What are the symptoms of Hungry Bone Syndrome?

Answer:

- Seizures
- Arrhythmias, Prolonged QT
- Severe Tetany
- Chvostek's sign: Excessive muscle twitching of the face.
- Trousseau's sign
- Erb's sign: Excessive galvanic twitching of facial muscles

Q1.17: How to manage Hungry Bone Syndrome?

Answer:

Lab Diagnosis

- Low serum calcium
- Low phosphate
- High alkaline phosphatase

Treatment

- Oral/ IV calcium
- Vitamin D for one year
- Pre-OP vitamin D prevents the incidence of HBS → Before parathyroidectomy.

BIG QUESTION 2: What are the causes, clinical features, diagnosis, and management of gout and pseudogout?

Broad Answer: Gout is due to **monosodium urate crystal deposition**, commonly in the great toe, causing acute painful attacks and chronic tophi with arthropathy. Diagnosis: serum uric acid >7 mg/dl and needle-shaped, negatively birefringent crystals. Treatment: NSAIDs, colchicine, steroids for acute attacks; febuxostat, allopurinol, lifestyle changes for chronic cases. Pseudogout (CPPD arthropathy) is due to **calcium pyrophosphate crystals**, usually in the knee, showing rhomboid-shaped, positively birefringent crystals. Managed with NSAIDs, joint aspiration, intra-articular steroids, and rest.

DETAILED QUESTIONS

Q2.1: What is the aetiology of gout?

Answer:

- **Primary gout**: Underexcretion of urate in the kidneys without an obvious cause.
- **Secondary gout**: Due to myeloproliferative disorders, diuretics, renal failure, and preeclampsia.
- **Precipitating factors**: Male sex, menopause in women, age, obesity, alcohol, sugary foods, and heavy meat.

Q2.2: What are the key features of gout?

Answer:

- Metabolic disorder, which produces inflammation of joints due to the precipitation of monosodium urate crystals within joints
- Most commonly affected joint - **Great Toe**
- An acute attack may be followed by remission.
- **If >2 episodes of acute attack happen within 12 months, it is called chronic gout.**

Q2.3: What are the clinical features of acute gout?

Answer:

- Asymptomatic hyperuricemia is 10 times more common than gout.
- Acute gout affects the following joints:
  - First MTP joints (Podagra) - 70% of cases
  - Knee
  - Ankle
  - Midfoot
  - Elbow
  - Wrist
- The acute attacks often begin at night, and within a few hours, the affected joint will become red, hot, swollen, and extremely painful.
- The patient may not be able to walk or bear the touch of a bedsheet.
- **Symptoms normally settle after 5-7 days.**



Podagra

Q2.4: What are the clinical features of Chronic gout?

Answer:

- **More than 2 acute gout attacks within 12 months.**
- Multiple joints are involved.
- The urate deposits are chalky deposits of uric acid, collected in (**Tophi**), subcutaneous planes as masses under the skin of the affected joint.
  - They usually develop after several years of gout.
- In joints, tophi result in an erosive disease called Chronic gouty arthropathy.



Tophaceous deposit

Q2.5: How to diagnose gout?

PYQ: FMGE 2019

Answer:



Gout crystals

- Normal Uric acid level is 6.8 mg/dl:
  - **Over 7 mg/dl is considered hyperuricemia.**
- Hyperuricemia remains an important feature of gout, but may be normal during acute attacks.
- If gout is suspected, repeated estimations of serum uric acid over a few weeks can be of great value.
- Acute gout can be diagnosed by identifying urate crystals in synovial fluid, bursa, or an aspirate of a Tophus.
- Crystals are **Needle-shaped & strongly Negative Birefringent** under polarised light. However, the absence of crystals doesn't rule out gout.

Q2.6: How to manage an acute attack of Gout?

Answer:

- Topical ice and rest of the inflamed joint
- **NSAIDs - DOC**
  - Indomethacin 75 mg BD - India
  - Naproxen 500 mg BD - Western countries
- Oral and IV Colchicines
- Intra-articular and systemic steroids

PYQ: NEET PG 2021

Q2.7: How to manage Chronic Gout?

Answer:

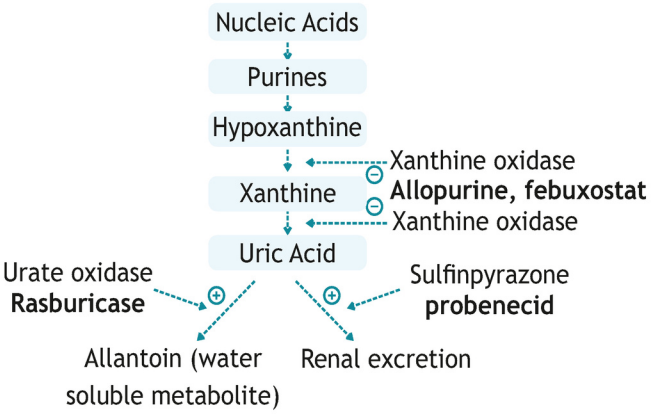

- Appropriate lifestyle modifications
  - Weight loss
  - Reduction of alcohol and fructose consumption
- Urate-lowering drugs:
  - **Uricostatic drugs (Xanthine Oxidase inhibitors)**
    - → Allopurinol
    - → Oxypurinol
    - → **Febuxostat - DOC**
- Uricosuric drugs (indicated in patients who are allergic to allopurinol and have intolerance to uricosuric drugs)
  - Probenecid
  - Benzbromarone
  - Losartan
- Note: These drugs are indicated only in patients with normal renal function and no lithiasis

Q2.8: What is Martel's G sign?

Answer:



- The characteristic sign of Gout.
- Osteolytic lesion in the great toe.
- Rat bite lesion.

YOURWISH

Q2.9: What are the key features of Pseudogout?

Answer:

- **Calcium pyrophosphate crystal-associated arthropathy (CPPD)**
- Consequence of cartilage changes related to:
  - Aging
  - Degeneration
  - Enzymatic degradation
  - Trauma
- Results in the deposition of calcium phosphate (CPP) crystals.
- Direct trauma, medical illness, surgery & blood transfusion are the potential triggers, though many attacks occur for no reason.

PYQ:FMGE 2022

- **The knee joint is most commonly involved.**
- It may also be seen in the shoulder & ankle joints.
- Acute calcium pyrophosphate crystal arthritis is known as pseudogout.
- This is an acute inflammatory reaction within the joint caused by CPP crystals.
- Acute CPP is the most common cause of acute monoarthritis in hospitalised elderly.

Pseudogout crystals:

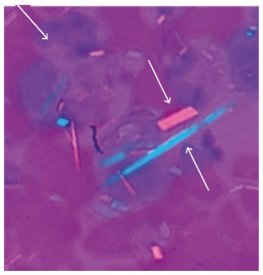

- Calcium pyrophosphate crystals
- Rhomboid shape
- Positive birefringence

Q2.10: What are the clinical features and differential diagnosis of Pseudogout?

Answer:

- Onset is with swelling and pain, which becomes severe over 6-24 hrs.
- **In elderly patients, fever is common.**
  - Differentiation from gout is difficult, especially if the first MTP is involved (**Pseudopodagra**).

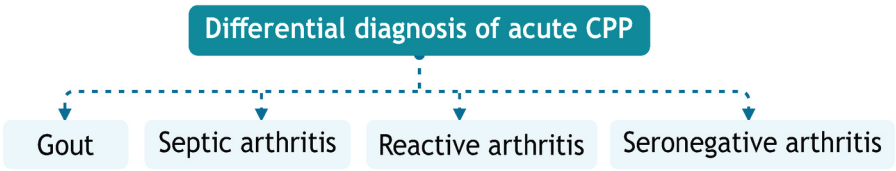

Q2.11: How to manage Pseudogout?

Answer:

Diagnosis

- Identification of positively birefringent rhomboid-shaped crystals in the synovial fluid establishes the diagnosis.

Treatment

- Rest
- Analgesia
- NSAIDs · Aspiration and injection with steroids

BIG QUESTION 3: What are the causes, clinical features, pathology, diagnosis, and management of primary, secondary, and tertiary hyperparathyroidism?

Broad Answer: Hyperparathyroidism is caused by excessive secretion of parathyroid hormone (PTH). **Primary hyperparathyroidism** is most often due to a parathyroid adenoma (85%) and manifests as *stones, bones, abdominal groans, and psychic moans*, with bone changes like osteitis fibrosa cystica, brown tumours, and subperiosteal resorption. **Secondary hyperparathyroidism** occurs due to chronic kidney disease with phosphate retention and hypocalcemia, leading to compensatory PTH rise. **Tertiary hyperparathyroidism** develops after long-standing secondary hyperparathyroidism, when parathyroid glands become autonomously hypersecretory. Treatment depends on type: surgery for primary and tertiary, while secondary is managed medically with phosphate restriction, binders, vitamin D analogues, and calcimimetics.

DETAILED QUESTIONS

Q3.1: What are the main causes of primary hyperparathyroidism?

Answer:

- 85%: Parathyroid adenoma (most common).
- 15%: Carcinoma (rare).

Q3.2: What are the classical symptoms of primary hyperparathyroidism?

Answer:

- "Stones, bones, abdominal groans, and psychic moans."
- Symptoms apart from bone lesions are due to hypercalcemia.

Q3.3: What bone changes are seen in primary hyperparathyroidism?

Answer:

- **Histopathology:**
  - Cortical cutting cones with spearhead osteoclasts.
  - Enlarged Haversian & Volkmann canals.
  - Dissecting osteitis (tram-track appearance).
- **Severe cases:**
  - Osteitis fibrosa cystica.
  - Brown tumours.
  - Subperiosteal resorption (distal phalanges).
  - Tapering distal clavicle.
  - Salt & pepper skull (raindrop skull).
  - Rugger jersey spine.
  - Absence of lamina dura in alveoli.

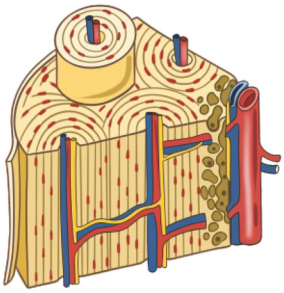

Enlarged Haversian & Volkmann Canals

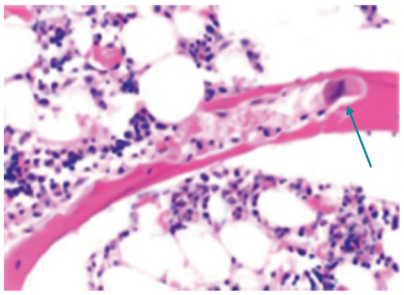

Railroad or Tramtrack Appearance

Q3.4: What are brown tumours and their features?

Answer:

- **Localised benign bone cysts.**
- Rare in primary, common in secondary hyperparathyroidism.
- Sites: **mandible** (most common), clavicle, ribs, femur, pelvis.
- Histology: haemorrhage, **hemosiderin**, fibrous tissue replacing marrow.
- X-ray: well-defined lytic lesion, no new bone formation.
- **Resolved within 6 months after adenoma removal.**

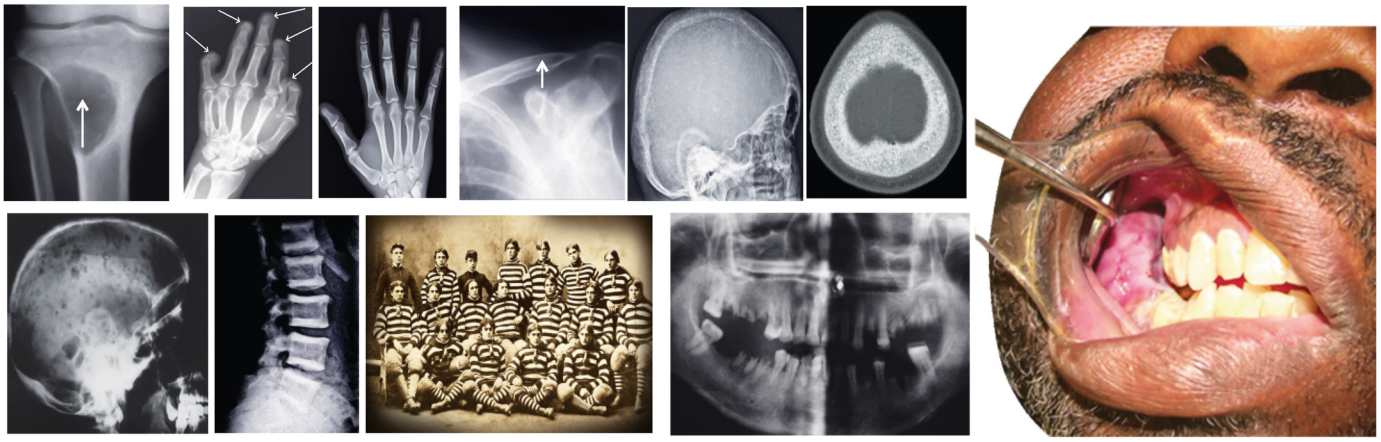

Q3.5: What is the Difference between a Brown tumour and Osteitis fibrosa cystica?

Answer: It is worth noting that the most recent version of Robbins' pathological basis of disease states that "Brown Tumour" is a mass lesion that results from fibrous tissue ingrowth, whereas "Osteitis Fibrosa Cystica" is the combination of Cystic brown tumours, peri-trabecular fibrosis, and increased bone activity

Q3.6: What is the Treatment of Primary Hyperparathyroidism?

Answer:

- Surgery is the treatment of choice
  - Removal of adenoma
  - The cure rate is about 95%

Q3.7: What is the cause and mechanism of secondary hyperparathyroidism?

Answer:

- Cause: Chronic renal failure (↓ GFR → ↓ phosphate clearance → hyperphosphatemia → excessive secretion ofPTH.).
- Mechanisms of PTH stimulation:
  - Direct stimulation by phosphorus.
  - Hypocalcemia (Ca-P precipitation).
  - Inhibition of 1α-hydroxylase →↓ active vitamin D.

Q3.8: What are the clinical features and treatment of secondary hyperparathyroidism?

Answer:

- Clinical features: No hallmark presentation; often detected on lab testing in CKD patients.
- Treatment:
  - Dietary phosphate restriction.
  - Phosphate binders.
  - Vitamin D analogues.
  - Calcimimetics.

Q3.9: What is tertiary hyperparathyroidism?

Answer:

- **Long-standing** secondary hyperparathyroidism → **autonomous hypersecretion of PTH.**
- Causes hypercalcemia due to unregulated parathyroid function.
- Treatment: Surgical removal of the parathyroid gland.

BIG QUESTION 4: What are the causes, clinical features, radiological findings, and management of major metabolic bone disorders (Rickets, Scurvy, Paget's disease, and Spondylolisthesis)?

PYQ: NEET PG 2023

PYQ: INICET 2022

Broad Answer:

Metabolic bone disorders include:

- Rickets - defective mineralisation (Vit D deficiency), skeletal deformities, X-ray: fraying/cupping/splaying.
- Scurvy - Vit C deficiency, haemorrhages, bone pain, X-ray: Frankel's line, Wimberger's ring, Pelken spur.
- Paget's disease - abnormal remodelling (mosaic bone), bone pain, deformities, X-ray: flame-shaped/cotton-wool skull, Tx: calcitonin, bisphosphonates.
- Spondylolisthesis - forward slip of vertebra (L5/S1), back pain, step-off sign, X-ray/MRI diagnosis, conservative or surgical management.

DETAILED QUESTIONS

Q4.1: What are the key features of Rickets?

Answer:

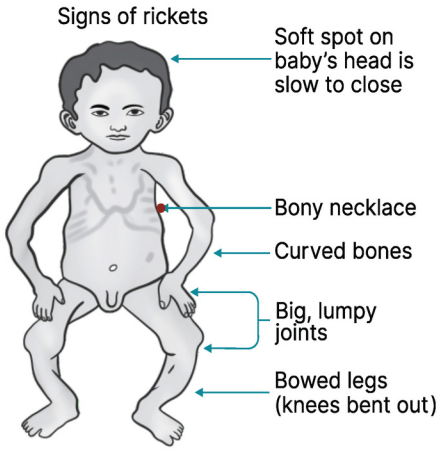

- Defective **mineralisation** of osteoid (osteoid formation normal).
- Common in <4 years; nutritional type is most common in India.
- The earliest bone change occurs in the skull. Skull changes: **Ping pong skull (craniotabes, MacEwan sign), hot cross bun appearance** (Make the baby sit on a stool and have a bird's-eye view from above), **delayed fontanelle closure.**
- Chest changes: Pigeon chest (pectus carinatum), rachitic rosary **(Vertically, on palpation, the costochondral junctions are widened and smooth) Harrison sulcus** (The ribs go inside, and it is seen as a sulcus as the bone has become pliable and flexible).
- Limb deformities: Genu varum/valgum, windswept deformity.
- Labs: ↓Ca, ↓PO_4, ↑ALP (Ca may be normal later).
- X-ray findings:
  - Fraying, splaying, and cupping of the metaphysis.
  - Looser zones (Milkman fractures) - Microfracture due to stress and occurs at the diaphysis of long bones.
  - Codfish vertebrae, triradiate pelvis, rib fractures.

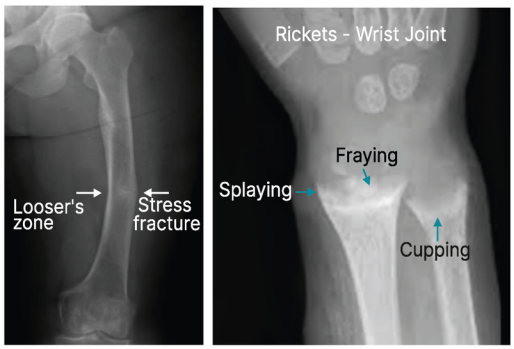

Q4.2: What is familial hypophosphatemic rickets?

Answer:

- The most common form worldwide; X-linked dominant.
- Normal Ca, low phosphate.
- Resistant rickets → requires very high vitamin D doses (50,000 IU).

YOURWISH

YOURWISH

Q4.3: What are the clinical and radiological features of Scurvy?

PYQ: NEET PG 2021

PYQ: FMGE 2021

Answer:

- Cause: Vitamin C deficiency → **defective collagen synthesis and osteoid formation.**
- Age: 6 months-2 years.
- X-ray findings:
  - Subperiosteal haemorrhage.
  - Trummerfeld zone (scorbutic zone, translucency in metaphysis).
  - White line of Frankel (dense calcification).
  - Wimberger's ring sign (epiphyseal ring).
  - Pelken spur (corner metaphyseal fracture).

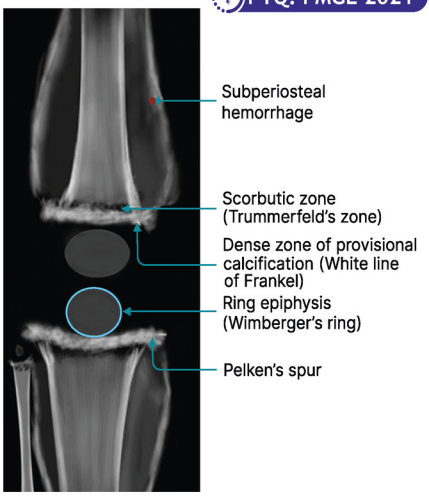

Q4.4: What are the key features and types of Paget's disease?

Answer:

- Slow replacement of compact bone with vascular spongy bone (also known as osteitis deformans).
- Histology: **Mosaic pattern.**
- Types:
  - Monostotic - (single bone involvement): Clavicle, tibia.
  - Polyostotic - (multiple bone involvement)
  - Facial - Jawbone

Q4.5: What are the clinical features of Paget's disease?

Answer:

Clinical Presentation

- The most common symptom is severe bone pain, which is not relieved by NSAIDs
- The skull will be irregularly enlarged, leading to constant change in the hat size.
- Rarely, patients can present with cardiac failure (due to increased pulse pressure). Micro arteriovenous fistula → Hyperdynamic circulation → Cardiac failure
- The pelvis is the most common bone involved.
- The skull base is flattened, known as **Platybasia**.
  - Foramina are narrowed and become flat.
  - This causes cranio-neuropathy (cranial nerve compression).
- **Spinal claudication** is typically seen in Paget's disease.

Q4.6: What are the X-ray findings of Paget's disease?

Answer:

X-Ray Findings

- Honeycomb or spongy appearance of bone: Most common finding.
- Flame-shaped lesions: Most typical
- Osteoporosis circumscripta
- Blade of grass appearance
- Cotton wool appearance
- Picture window frame vertebra.

Q4.7: What are the Biochemical findings of Paget's disease?

PYQ: NEET PG 2021
PYQ: FMGE 2020

Answer:

- Increased plasma **alkaline phosphatase** activity is a sign of osteoblastic activity.
- Increased excretion of **hydroxyproline** in urine is a sign of osteoclastic activity.

Q4.8: What is the treatment plan for Paget's disease?

Answer:

- **Calcitonin** is mostly widely used to relieve pain. (drug of choice)
- Latest drugs: Bisphosphonates, Etidronate, Pamidronate, Clodronate and Zoledronic acid

Q4.9: What is spondylolisthesis, and how is it classified?

Answer:

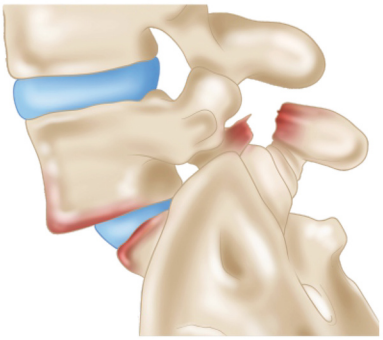

- Forward slip of a vertebra over the one below, most common at L5/S1.
- Five Types:
  - Type I: Congenital or Dysplastic
  - Type II: Isthmic
  - Type III: Degenerative
  - Type IV: Traumatic
  - Type V: Pathologic

Q4.10: What is Type I spondylolisthesis?

Answer:

Congenital or Dysplastic

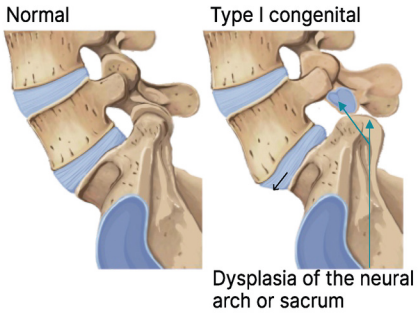

- Congenital malformations of the posterior elements, especially elongation of the Pars Interarticularis or **Spina Bifida Occulta**, can cause spondylolisthesis.
- These malformations reduce the ability of the posterior bony elements to resist anterior translation of the vertebra.
- Even though the anomalies are present at birth, they manifest after the child starts walking.

Q4.11: What is Type II spondylolisthesis?

Answer:

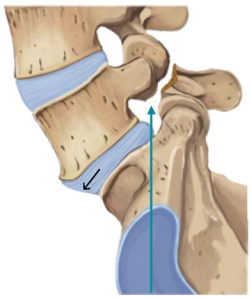

Isthmic

- Fracture of the Pars interarticularis or elongation of the Pars interarticularis results in an isthmic type of spondylolisthesis.
  - Also called **Lytic Type**

Q4.12: What is Type III spondylolisthesis?

Answer:

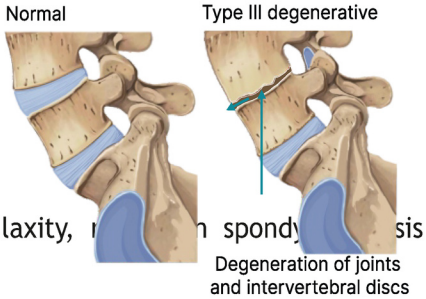

Degenerative

- The most common type in adults.
- Degenerative spondylolisthesis **commonly occurs at the L4-L5 level.**
  - This is due to the degeneration in the intervertebral & facet joints.
- The loss of Disc height, associated with Hypertrophic facet & ligament laxity, [illegible] spondy[illegible]sis

Q4.13: What is Type IV spondylolisthesis?

Answer:

Traumatic

- This is usually following high-energy trauma.
- Unlike the Isthmic Type, the fracture is not through the Pars.
- Rather, it is through any other part of the posterior elements, usually involving the pedicles or facets.

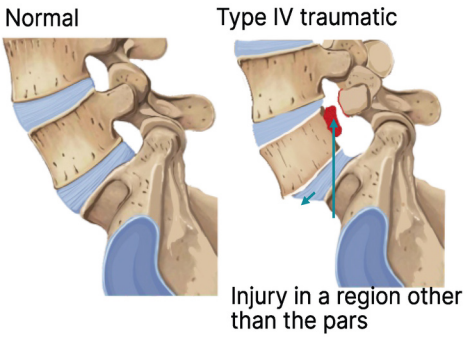

Q4.14: What is Type V spondylolisthesis?

Answer:

Pathological

- Generalised or localised home disease & structural weakness of the bone.
  - o Such as infection or Paget's disease, leading to instability of the affected segment.

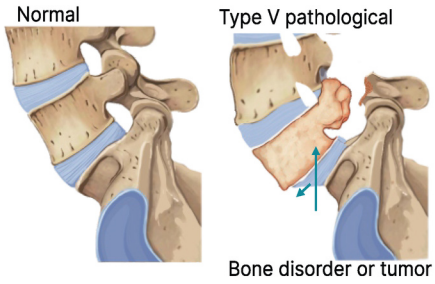

Q4.15: What are the clinical features and signs of spondylolisthesis?

Answer:

- Asymptomatic
- Initial presentation: Low backache, radiating to buttocks & posterior thigh.
- Degenerative spondylolisthesis presents with back pain, radiculopathy, and neurogenic claudication.
- There will be hyperlordosis in the thoracolumbar junction & lumbar vertebra.
- Hamstring tightness
- If L5 is involved, there will be Extensor hallucis longus (EHL) weakness.
- Palpable **STEP OFF sign positive if grading is >50%**

Q4.16: What is Meyerding Grading?

Answer: The percentage of slip in spondylolisthesis is graded by Meyerding Grade.

Grade 1	<25% of vertebral diameter
Grade 2	25%-50%
Grade 3	50%-75%
Grade 4	75%-100%
Spondyloptosis	>100%

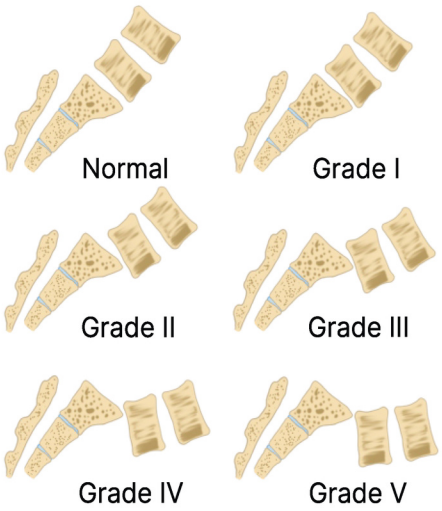

YOURWISH

Q4.17: What are the key imaging findings in spondylolisthesis?

PYQ: FMGE 2021

Answer:

- X-ray:
  - Oblique view (view of choice):
    - → Isthmic defects are best visualised in an oblique view.
    - → The classical "Beheaded Scottish Terrier Sign" is the normal appearance of the lumbar vertebra. In which the posterior elements look like a Scottish Terrier Dog. In Spondylolisthesis, the Pars interarticularis, or the neck of the dog, will have a defect it looks as if the dog has a collar around the neck or decapitated.
  - Flexion-extension lateral: instability.
- CT: Pars defect, facet arthropathy, foraminal stenosis.
- MRI: Root compression (most sensitive).

Q4.18: How is spondylolisthesis treated?

Answer:

Non Surgical

- Indications
  - Young patient
    - → Low-grade slip
    - → Lack of slip progression
    - → In the elderly with degenerative spondylolisthesis, there are minimal neurological signs.
    - → Mechanical back pain alone
  - The modalities available are:
    - → Activity Restriction
    - → NSAIDS
    - → Physical Therapy
- Surgical · Indications
  - Radiculopathy not responding to conservative management.
  - High grade slip > 50%
  - Spondylolisthesis with gross instability
  - Traumatic Spondylolisthesis
- Procedures available are: Decompression, Reduction and Fusion with instrumentation.

YOURWISH

13. MISCELLANEOUS TOPICS PART -2

BIG QUESTION 1: What is a Charcot joint? What are its key causes, clinical forms, and how is it managed?

Broad Answer: A Charcot joint is a neuropathic, degenerative joint disease due to loss of pain and proprioception, commonly seen in diabetics and affecting the foot. It can be atrophic or hypertrophic. Key symptoms include joint deformity and instability. Management includes pressure relief (Total Contact Casting), infection control, and surgery if needed.

DETAILED QUESTIONS

Q 1.1: What is a Charcot joint?

Answer: Charcot joint, also called a neuropathic joint, is a progressive, degenerative & destructive joint disorder due to abnormal pain sensation & proprioception

Q 1.2: Which joints are most commonly affected in Charcot joints?

Answer:

- The most common joints involved are the foot:
  - 60% are the Tarsometatarsal joint
  - 30% are the Metatarsophalangeal joint
  - 10% is the Ankle joint

Q 1.3: What are the common causes of Charcot joint?

Answer:

1. Diabetes is the most common cause - Foot



Diabetic foot

2. Syphilis - Involves Knee joint

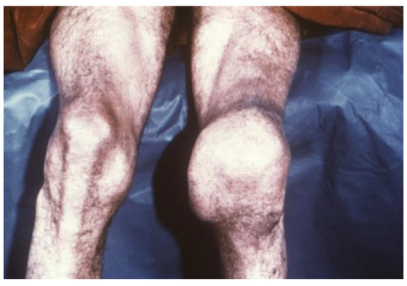

3. Syringomyelia - involves Shoulder joint



4. Leprosy - involves hand and foot



5. Meningomyelocele

Q 1.4: What is the basic pathogenesis of a Charcot joint?

Answer:

Minor injury induces an inflammatory response

↓

Results in destruction of the bones (Osteolysis)

Q 1.5: In what two forms can a Charcot joint manifest?

Answer: Atrophic and Hypertrophic

Q 1.6: What are the key features of the atrophic form of Charcot joint?

Answer:

- Mainly occurs in non-weight-bearing joints of the upper limb & Tarsometatarsal joint.
- It is characterised by the resorption of the ends of affected bone with joint destruction &resorption of fragments.
- Absence of sclerosis & Osteophytes

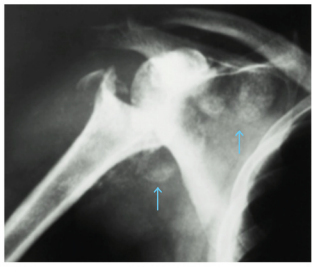

Q 1.7: What are the features of the hypertrophic form of Charcot joint?

Answer:

- It is characterised by joint destruction with Periarticular debris & bone fragmentation.
- Osteosclerosis &Osteophytes are present.



Q 1.8: What are the clinical features of a Charcot joint?

Answer:

- Mild swelling without deformity or significant swelling with deformity
- Instability of the joint
- Loss of joint function
- A loose bag of bones elicited in passive movement



Deformed foot

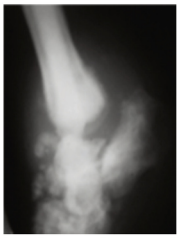

Q 1.9: What are the imaging findings in the Charcot joint?

Answer:

On X ray

Hypertrophic

- It is characterized by periarticular fracture
- Six Ds are seen on X ray
  1. Distended joint
  2. Density decreased
  3. Debris(Loose body)
  4. Dislocation
  5. Disorganization
  6. Destruction

Atrophic

- Osteolysis seen



Q 1.10: What are the key components of Charcot joint treatment?

Answer: Treatment includes vascular management (like muscle grafting), infection control (VAC dressing), pressure relief (main method), use of braces, partial or complete non-weight bearing, and surgical options when necessary.

Q 1.11: How does Total Contact Casting help in managing a Charcot joint?

Answer:

- This is used for pressure relief
- This allows the patient to walk while preventing the progression of deformity
- It involves encasing the whole foot, including toes and lower legs, in a specialised POP cast
- This redistributes the weight and pressure in the foot, which prevents further damage
- The cast is checked weekly for proper fit, & replaced once in two weeks
- Aim - To make the patient walk

Q 1.12: What types of braces are used in Charcot joint management?

Answer:

- Patellar tendon bearing (PTB) brace
- Charcot restraint orthotic walker
  - o Foot hygiene is maintained





Q 1.13: Why is partial non-weight bearing recommended in the treatment of a Charcot joint instead of complete non-weight bearing?

Answer:

- Complete non-weight bearing is ideal, but that is not possible
- Partial non-weight bearing is advised
- It will decrease the amount of stress on the affected extremity

Q 1.14: What are the surgical treatment options for a Charcot joint?

Answer:

- ORIF (Open reduction & Internal fixation)
- Excision of the bony prominences that cause pressure
- Reconstruction of the joint
- Arthrodesis
- Amputation


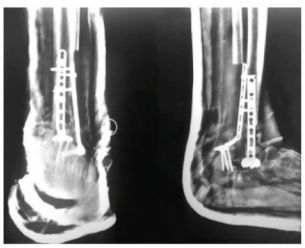

Q 1.15: What causes haemophilic arthritis?

Answer: Haemophilic arthritis is caused by recurrent spontaneous haemarthrosis (bleeding into joints).

Q 1.16: Which factors are deficient in Classic Haemophilia A and B?

Answer: Deficiency of either Classic Haemophilia A (Factor VIII) & Haemophilia B (Factor IX)

Q 1.17: In which population does haemophilic arthritis typically manifest?

Answer: Young males.

Q 1.18: When does haemophilic arthritis usually start manifesting in a child?

Answer: It manifests after the child becomes ambulant (starts walking).

Q 1.19: What is meant by the term "target joint" in haemophilic arthritis?

Answer:

- Once a joint is involved -> repeatedly the same joint is targeted
- The joint that gets involved first is the TARGET JOINT

Q 1.20: Which joints are most commonly affected in haemophilic arthritis?

Answer:

- Most common site - knee joint
- Elbow joint
- Ankle joint
- Shoulder joint

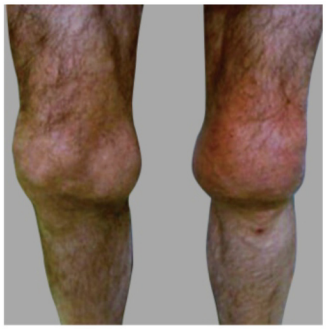

Q 1.21: How is haemophilia classified based on the percentage of clotting factor present in the plasma?

Answer:

- Depending upon the percentage of the factor in the plasma
  - Mild - A 5 to 25% factor is present in plasma
  - Moderate - 1 to 5% factor is present in plasma
  - Severe - < 1% factor is present

Q 1.22: What are the common X-ray findings in Haemophilic Arthritis?

Answer:

- Haemarthrosis
- Articular erosions
- Periarticular Osteopenia
- Enlarged Epiphysis
- Narrowing of the joint space
- Fibrous ankylosis · Fibrous ankylosis - Incomplete ankylosis
- Bony ankylosis is called complete ankylosis
- Widening of the Femoral Interchondylar notches
- Enlargement of the Proximal radius
- Squaring of the distal end of Patel

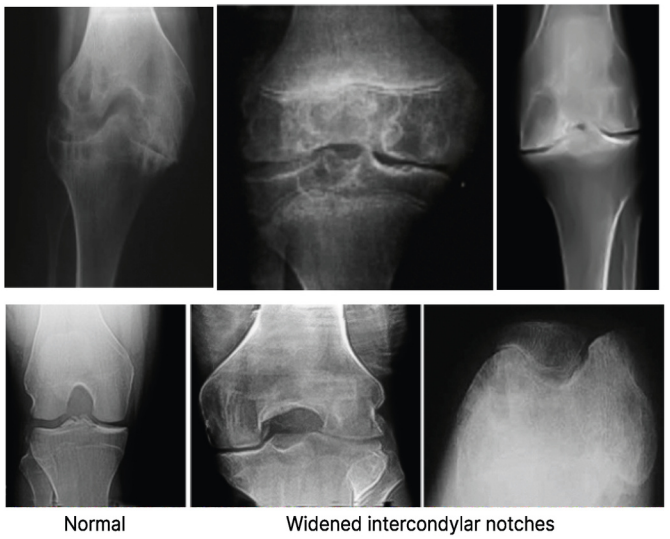

Normal | Widened intercondylar notches

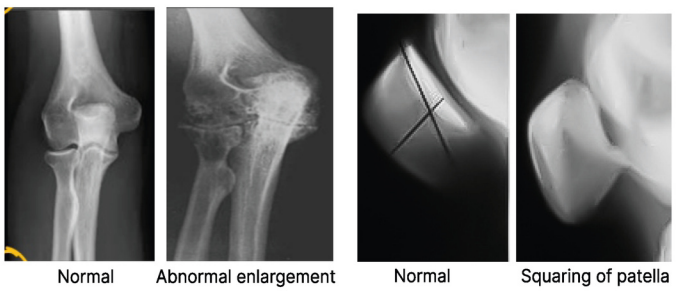

Normal | Abnormal enlargement | Normal | Squaring of patella

Q 1.23: In which conditions is periarticular osteopenia commonly seen?

Answer:

- Rheumatoid arthritis
- TB Arthritis
- Haemophilic arthritis

Q 1.24: Which conditions commonly present with fibrous ankylosis?

Answer:

- TB arthritis
- Rheumatoid arthritis
- Haemophilic arthritis

Q 1.25: Which conditions are associated with bony ankylosis?

Answer:

- Pyogenic arthritis
- Ankylosing Spondylitis

Q 1.26: What is the Arnold & Hilgartner Radiological Classification of Haemophilic Arthritis?

Answer:

- Stage 1 - Soft tissue swelling
- Stage 2 -Slight narrowing of the joint space & Squaring of the bone ends
- Stage 3 - Marked narrowing of the joint space
- Stage 4 - Joint disintegration

Q 1.27: How is acute haemarthrosis in haemophilic arthritis managed?

Answer:

- An undamaged joint should be managed aggressively with
  - Strict bed rest
  - Aspiration
  - Restorative physical therapy
  - Immobilisation of the limb
  - Correction of coagulation defect
    - → By FFP/Factor replacement/Cryoprecipitate
    - → To raise the level of Factor 8 to 25-50% and Factor IX to 15 to 25%
  - Pain relief by COX2 inhibitors - CELECOXIB

Q 1.28: How is chronic haemarthrosis in haemophilic arthritis managed?

Answer:

- The source of recurrent haemarthrosis is bleeding from hypertrophied vascular synovium.
  - Hence, Synovectomy is done
- If surgical synovectomy is not practical
  - Radiosynovectomy with Yttrium 90 silicate or Phosphorous 31 colloid
- Advanced mutilated Arthritis - joint replacement

Q 1.29: What are the indications of Synovectomy?

Answer:

- If the joint bleeds more than three times in six months
- If Synovitis fails to resolve after 3 months of treatment
- Synovectomy can be done if the child is more than 3 years old

Q 1.30: What are the Post & Tefler surgical principles for operating on a haemophilic patient?

Answer:

- Tight wound closure to avoid dead space
- Avoidance of Electrocautery
- Suction for a minimum of 24 hours
- No Aspirin
- As many procedures in one single surgical session
- No IM injection

Q 1.31: What are the common complications of Haemophilic Arthritis?

Answer:

- CNS bleed
- Joint contractures
- Fibrous ankylosis
- Compartment syndrome
- Blood-borne infection
- Haemophilic pseudotumor

BIG QUESTION 2: What are meniscal injuries, how do they present, and how are they diagnosed and managed?

Broad Answer: Meniscal injuries commonly affect the posterior horn of the medial meniscus and occur due to trauma or degeneration. Symptoms include joint line pain, locking, and clicking. Diagnosis is by clinical tests (McMurray, Apley) and MRI. Treatment is conservative for stable tears and arthroscopic surgery for symptomatic or complex tears.

DETAILED QUESTIONS

Q 2.1: In which age group are meniscal injuries most common?

PYQ: INICET 2020

Answer: Adolescents and young adults

Q 2.2: How common are meniscal tears in children?

Answer: Meniscal tears are very rare in children.

Q 2.3: What are the two main types of meniscal tears?

Answer: Traumatic or degenerative.

Q 2.4: What is the most common site of a meniscal tear?

Answer: Posterior horn of the medial meniscus

Q 2.5: Which type of meniscal tear is most frequently seen?

Answer: Longitudinal tear

Q 2.6: In which meniscus is a discoid shape more commonly found?

Answer: Discoid meniscus is more common in the lateral meniscus.

Q 2.7: What is the O'Connor Classification?

Answer:

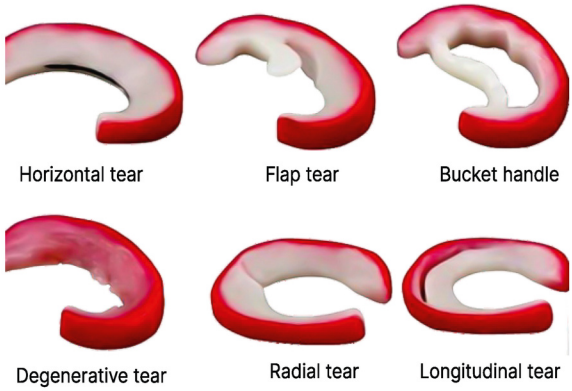

Q 2.8: Which type of meniscal tear is most commonly associated with mechanical symptoms?

Answer: Bucket handle type

Q 2.9: What are the common clinical features of a meniscal injury?

Answer:

- Pain in the joint line, more commonly at the Posteromedial part of the knee
- Mechanical symptoms:
  - Painful clicking
  - Popping
  - Locking - More common with bucket handle
  - Catching pain
  - Feeling of giving away

Q 2.10: What conditions can cause true locking of the knee?

Answer:

- Medial meniscal tear
- Loose bodies
- Intraarticular tumor
  - False locking (pseudo-locking) occurs in Hamstring spasm

Q 2.11: How can you differentiate true locking from false (pseudo) locking?

Answer:

- To differentiate between true and false locking:
  - Once the muscle is relaxed, false locking goes away
  - True locking is seen until Surgical intervention is seen

Q 2.12: What is the procedure of the McMurray test in diagnosing meniscal tears?

Answer:

- Step 1 - Patient is in supine position.
  - Examiner holds the knee and palpates the joint line
  - The other hand holds the sole
- Step 2 - The Knee is kept in full flexion
- Step 3 - Examiner applies valgus test to the knee
  - With the other hand, the foot & leg are externally rotated
- Step 4 - The knee is gradually extended
- Step 5 - Audible click and pain denote a Medial meniscal tear

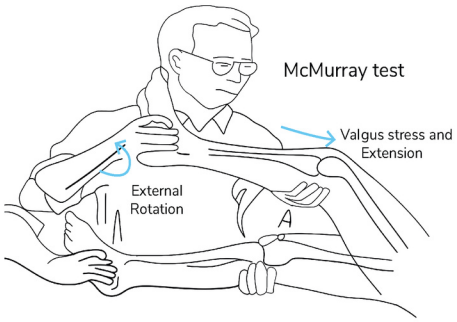

Q 2.13: What is the McMurray test used to diagnose?

Answer: Both the medial and lateral meniscus tears

Q 2.14: What are the steps of Apley's grinding test?

Answer:

- Step 1 - Patient is put in the prone position with the knee flexed to 90 degrees
- Step 2 - The patient's thigh is fixed to the examination table with the examiner's knee
- Step 3- The examiner medially and laterally rotates the Tibia, combined with distraction
  - If there is pain associated with excessive rotation-> it is a ligamentous injury.
- Step 4 - The examiner medially and laterally rotates the tibia, combined with compression
  - If there is pain associated with restriction of rotations -> It is a meniscal injury.

Q 2.15: What are the sensitivity and specificity of Apley's grinding test in diagnosing meniscal injuries?

Answer:

- 87% specificity
- 97% sensitivity

Q 2.16: What is the investigation of choice for diagnosing meniscal injuries?

Answer:

- X-ray - AP lateral view done in standing position
- MRI: Investigation of choice
  - MRI has 98% accuracy for the Medial meniscus tear & 90 % accuracy for the Lateral meniscus
- Diagnostic Arthroscopy

Q 2.17: What are the indications for non-surgical treatment of meniscal injuries?

Answer:

- Incomplete Meniscal tear
- A small stable tear without ACL injury
- A stable vertical tear in the Red Red zone

Q 2.18: What is a contraindication for non-surgical treatment of meniscal injuries?

Answer: Acute meniscal injury with mechanical symptoms

YOURWISH

Q 2.19: What are the conservative management methods used for non-surgical treatment of meniscal injuries?

Answer:

- Groin to ankle cylinder cast or knee immobiliser for 6 weeks
- Crutch walking with touch-down weight bearing
- Progressive isometric exercise for the Quadriceps, Hamstrings and around the knee joint

Q 2.20: What are the surgical options for meniscal injuries and their specific indications?

Answer:

- Arthroscopic Meniscal Repair
  - It is indicated only by a vertical longitudinal tear in the red zone
- Arthroscopic Partial Meniscectomy
  - It is indicated for radial, oblique, flat, horizontal tear & any tear in White white zone.

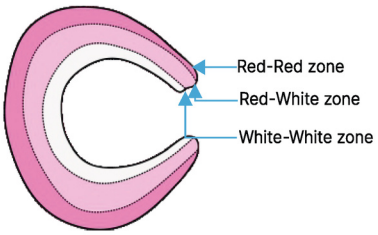

Q 2.21: What are the two types of Osteoarthritis?

PYQ: AIIMS 2019 PYQ: INICET 2022

Answer:

- Primary: Articular degeneration without any underlying cause
- Secondary: Consequence of preexisting abnormalities like RA, TB, and Septic arthritis

Q 2.22: What is the pathogenesis of Osteoarthritis?

Answer:

- Progressive softening and disintegration of articular cartilage
- Associated with the new growth of cartilage and bone at joint margins
- The earliest change is an increase in the water content of the cartilage (microscopic change)
- MC precursor of primary osteoarthritis - Stress
- The earliest sign is pain

Q 2.23: What is the M/C distressing symptom of osteoarthritis?

Answer: Loss of function

Q 2.24: What are Bouchard's and Heberden's nodules?

Answer:

- Nodule in the proximal phalangeal joint - Bouchard's nodule
- Nodule in the Distal phalangeal joint - Heberden's nodule



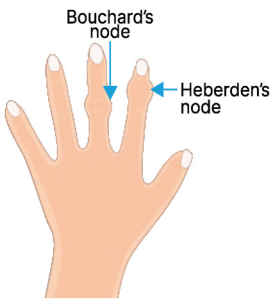

Q 2.25: What is Kashin-Beck Osteoarthritis?

Answer:

- It is caused by ingestion of Mycotoxin (a toxin produced by the fungus) in spoiled wheat
- Mostly seen in cold countries where wheat bread is stored to eat.

Q 2.26: What is Mseleni Osteoarthritis?

Answer:

- It is the primary osteoarthritis of the hip
- Genetically determined

Q 2.27: What is the typical X-ray pattern seen on osteoarthritis?

Answer:

- Asymmetric narrowing of joint space: Only one side is narrow, and the other is normal
  - Symmetrical narrowing is seen in Rheumatoid Arthritis
- Sclerosis of subchondral bone
- Cyst in the joint surface
- Osteophyte at joint margins: A hook-like structure at the margin

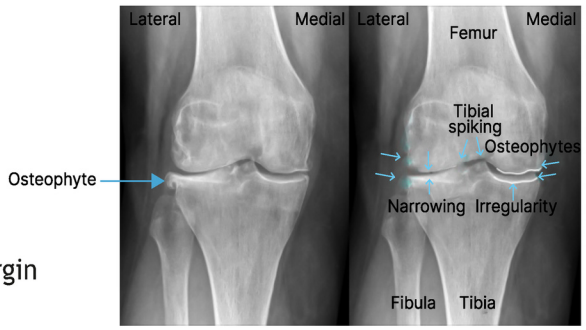

Q 2.28: What are the main goals of non-surgical treatment in osteoarthritis?

Answer:

- Patient education & Physical therapy
  - Quadriceps strengthening exercises
- Weight loss
- Knee bracing
- NSAIDs
- Intra-articular injection

Q 2.29: What are the indications of the surgical treatment of osteoarthritis?

Answer:

- HTO: High Tibial Osteotomy
  - Only in the medial component
- TKA: Total Knee Arthroplasty
  - Done in very severe cases
  - If both the medial and lateral, posterior components are damaged

Q 2.30: What is another name for Osteopetrosis?

Answer: Osteopetrosis is also known as Marble bone disease or Albers-Schönberg disease.

Q 2.31: What is the basic defect in Osteopetrosis?

Answer: Failure of osteoclasts to resorb bone, leading to impaired bone modelling and remodelling.

Q 2.32: What is the result of the osteoclast defect in Osteopetrosis?

Answer:

- The result is increased bone mass, but a fragile bone
- The bones are brittle and break even with a trivial trauma

Q 2.33: What are the two main types of Osteopetrosis?

Answer:

- Autosomal dominant
- Autosomal recessive

Q 2.34: What are the key features of Autosomal Dominant Osteopetrosis?

Answer:

- Mildest form of Osteopetrosis
- Usually undiagnosed in adulthood

Q 2.35: What are the classical clinical features of Autosomal Dominant Osteopetrosis?

Answer:

- Fracture following trivial trauma, especially ribs and long bones
- Recurrent Osteomyelitis of the jawbone is seen
- Cranial hyperostosis is seen
- This can be associated with Hematopoietic insufficiency


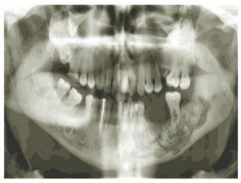

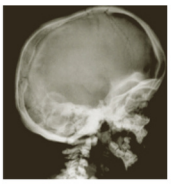

Q 2.36: What is another name for the Autosomal Recessive type of Osteopetrosis?

Answer:

- Infantile Osteopetrosis or Malignant Osteopetrosis.
- It is a dangerous type.

Q 2.37: When is Autosomal Recessive Osteopetrosis typically diagnosed?

Answer: Very early in life.

Q 2.38: What complications are associated with Autosomal Recessive Osteopetrosis?

Answer:

- Cranial neuropathies due to narrowing of the foramina
- Hydrocephalus, deafness, and proptosis were seen



Q 2.39: What haematological problem arises when osseous tissue encroaches on the bone marrow in Autosomal Recessive Osteopetrosis?

Answer: Pancytopenia

Q 2.40: What are common developmental issues seen in Autosomal Recessive Osteopetrosis?

Answer: Failure to thrive and growth retardation

Q 2.41: What are the key characteristic X-ray findings in Osteopetrosis?

Answer:

- Generalized Osteosclerosis
- Skull thickening, especially at the base, with small. The sinus cavity becomes small.

- Classical sandwich vertebra
  - Diffuse end plate sclerosis with a sharp delineation between peripheral bony sclerosis
  - Lucency of the central vertebral body
- Bone within bone appearance

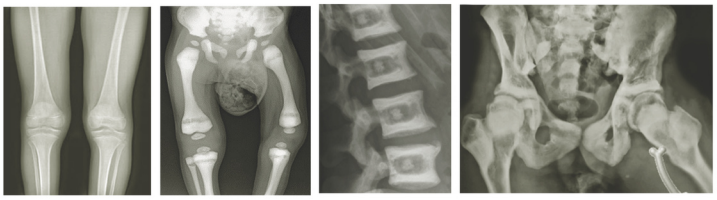

Q 2.42: What is the treatment approach for the Autosomal recessive and Autosomal dominant types of Osteopetrosis?

Answer:

- Hematopoietic Stem Cell Transplantation (HSCT)
  - The only treatment available at present for the Autosomal recessive type
- No treatment available for the Autosomal dominant type

Q 2.43: What percentage of psoriasis patients develop arthritis?

Answer: 15-25% of patients with psoriasis develop arthritis

Q 2.44: What types of joint conditions does psoriasis cause?

Answer: Spondylitis and arthritis

Q 2.45: Under which category is psoriatic arthritis classified?

Answer: It is classified under spondyloarthritis

Q 2.46: What are some other common causes of spondyloarthritis?

Answer:

- Ankylosing spondylitis
- Reactive arthritis
- Crohn's disease
- Ulcerative colitis

Q 2.47: Where can extra-articular manifestations occur in psoriatic arthritis?

Answer:

- Skin
- Eye
- Mouth

Q 2.48: What is the aetiology of psoriatic arthritis?

Answer:

- Unknown
- Associated with HLA B27 - Only in 50%

Q 2.49: How does the association of HLA B27 in ankylosing spondylitis compare to its association in psoriatic arthritis?

Answer:

- Psoriatic Arthritis - Associated with HLA B27 - Only in 50%
- Ankylosing spondylitis - Association of HLA B27 is >50%

YOURWISH

YOURWISH

Q 2.50: What are the differences between asymmetrical oligoarthritis and symmetrical polyarthritis?

Answer:

- Asymmetrical Oligoarthritis
  - One joint may be involved
- Symmetrical Polyarthritis
  - Many joints are involved
  - Ex: Rheumatoid arthritis

Q 2.51: Which joints are most commonly involved in psoriatic arthritis?

Answer:

- Common joints involved
  - Knee
  - Ankle
  - Foot

Q 2.52: Which joint is characteristically involved in psoriatic arthritis?

Answer: Distal Interphalangeal (DIP) joint



Q 2.53: What are arthritis mutilans?

Answer: Severe form of Psoriatic arthritis in which bone resorption happens



Q 2.54: Is sacroiliitis always present in psoriatic spondylitis?

Answer: Spondylitis can occur with or without sacroiliitis

Q 2.55: What are the differential diagnoses for dactylitis (sausage digit)?

Answer:

- Rickets
- Tuberculosis
- Sickle cell disease
- Syphilis
- Sarcoidosis
- Spondyloarthropathy
- Infection





Q 2.56: How is Psoriatic Arthritis diagnosed?

Answer:

- No lab or radiological features specific to Psoriatic arthritis
- Diagnosis is purely clinical

Q 2.57: What are the medical treatment options for Psoriatic Arthritis?

Answer:

- NSAIDs
- Physiotherapy
- Methotrexate, Sulfasalazine, HCQ
- Intra-articular steroid injection

Q 2.58: What are the surgical treatment options for Psoriatic Arthritis?

Answer:

- Arthroscopic Synovectomy
- Arthroplasty

BIG QUESTION 3: Explain the pathogenesis, clinical features, diagnosis, and treatment of Rheumatoid Arthritis, highlighting its epidemiology and key deformities.

Broad Answer: Rheumatoid arthritis is a chronic inflammatory joint disease causing pain, swelling, and deformities, mainly in middle-aged women. It shows symmetrical small joint involvement and is diagnosed by clinical signs, blood tests, and X-rays. Treatment includes steroids, DMARDs like methotrexate, and biologics; surgery is for severe cases

DETAILED QUESTIONS

Q 3.1: What is Rheumatoid Arthritis?

PYQ: AIIMS 2019

Answer:

- Chronic inflammatory disease is characterised by
  - Hyperplasia of the synovial lining cells
  - Angiogenesis
  - Infiltration of the mononuclear cells
- Finally results in Pannus formation (hallmark), cartilage erosion & ultimately ending in joint destruction
- The most common cause of Inflammatory arthritis in the world

Q 3.2: What is the epidemiological profile of Rheumatoid Arthritis?

Answer:

- 1% of the adult population suffers from RA
- 75% are women
- The peak age of incidence is 40 to 50 years

Q 3.3: What is the aetiology of rheumatoid arthritis?

Answer:

- 15 to 20% of monozygotic twins exhibit concordance
- HLA DR4 found to be a major risk factor

- HLA DW16 is a major risk factor in Asian Indians
- 4. Infectious Causes
  - Bacteria: Mycoplasma, Mycobacteria, E. coli
  - Virus: EBV, CMV, Parvo, Rubella
- HLA DRB1 individuals who smoke are at high risk

Q 3.4: Which joints are commonly involved in rheumatoid arthritis?

Answer:

- Symmetrical involvement of the small joints of the hands and feet
- Joints involved (decreasing frequency):
  - MCP (metacarpophalangeal) >> Wrist >> PIP (proximal interphalangeal) >> Knee >> MTP (metatarsophalangeal) >> Shoulder >> Ankle >> CS (cervical spine) >> Hip >> Elbow >> TMJ (temporomandibular joint)
- Only the cervical spine is involved

Q 3.5: What is a key clinical feature of rheumatoid arthritis?

Answer: Back pain is not a feature of RA

Q 3.6: Which joints are typically *not* involved in rheumatoid arthritis?

Answer:

- DIP (Distal Interphalangeal joint)
- SIJ (Sacroiliac joint)

Q 3.7: In what percentage of rheumatoid arthritis cases are rheumatic nodules present?

Answer: It is present only in 25% of cases

Q 3.8: Where are rheumatic nodules commonly seen in rheumatoid arthritis patients?

Answer:

- Olecranon aspect of the Elbow
- Achilles tendon
- Extensor aspect of the hand and foot



Q 3.9: What is a potential side effect of Methotrexate treatment in RA patients?

Answer: Nodulosis (increase in size of nodules)

Q 3.10: In which population are rheumatic nodules more common—Indian or European?

Answer: European population

Q 3.11: What is Caplan's syndrome?

Answer: Rheumatoid Arthritis + Coal workers' pneumoconiosis

Q 3.12: What is Felty's syndrome?

Answer: Rheumatoid Arthritis + Splenomegaly + Neutropenia

Q 3.13: What is Still's disease?

Answer: Juvenile Rheumatoid Arthritis

Q 3.14: How does pregnancy affect RA symptoms?

Answer: RA symptoms improve during pregnancy

Q 3.15: Do all autoimmune disorders show improvement during pregnancy?

Answer: Yes, symptoms of autoimmune disorders typically improve

Q 3.16: What are the typical deformities seen in Rheumatoid Arthritis? PYQ: FMGE 2021

Answer:

- Swan neck deformity
- Boutonniere deformity
- Hitch Hikers deformity
- Z-deformity
- Main -En-Lorgnette deformity (Telescoping fingers)
- Wind-swept deformity
- Torch -light deformity
- Sudden onset of flash foot -Due to Tibialis posterior insufficiency
- Protrusio Acetabuli
- Baker's cyst



Wind-swept deformity

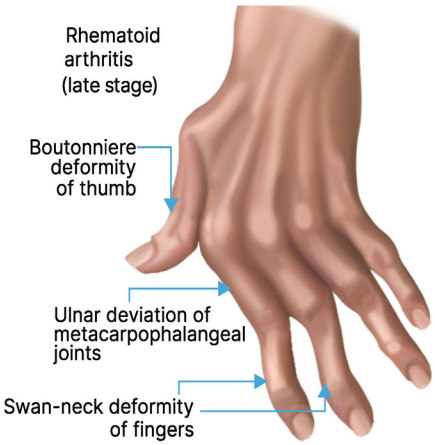

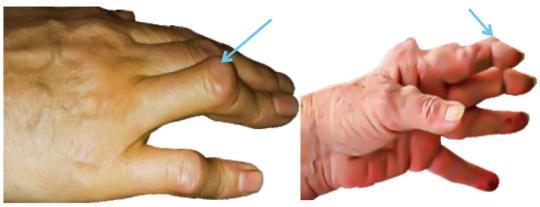

Boutonniere deformity and Swan neck deformity

Q 3.17: What are the 1987 American College of Rheumatology (ACR) Revised Criteria for the diagnosis of Rheumatoid Arthritis (RA)?

Answer:

- The 1987 ACR criteria for RA diagnosis include the following: Any 4 out of 7 present for at least 6 weeks are diagnostic.
  - o Morning stiffness of more than one hour
  - o Arthritis of three or more areas
  - o Arthritis of hand joints
  - o Symmetrical arthritis
  - o Rheumatoid nodules

- Positive rheumatoid factor
- Subcutaneous nodules and positive radiological features

Q 3.18: What are the classical radiological features of Rheumatoid Arthritis (RA)?

Answer:

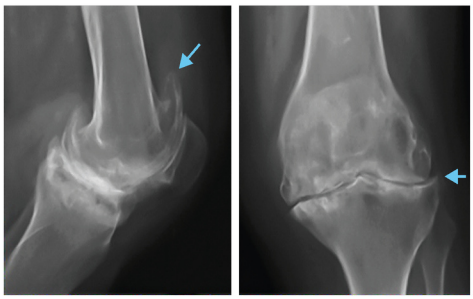

- Symmetrical joint space narrowing
  - Joint space narrowing is uniform on the medial and lateral sides
- Marginal and central articular erosion -Earliest articular change
- Periarticular osteoporosis
- Soft tissue swelling -Earliest sign

Q 3.19: How can radiological features help differentiate Rheumatoid Arthritis from Osteoarthritis?

Answer:

- Asymmetrical joint space narrowing comes under Osteoarthritis
- Periarticular Osteopenia is seen in RA and TB

Q 3.20: What is the significant lab test for diagnosing early Rheumatoid Arthritis?

Answer:

- Anti-CCP
  - Can be positive in the early stages
  - Has prognostic importance
  - Best investigation

Q 3.21: What are the limitations of Rheumatoid Factor (RF) in diagnosing Rheumatoid Arthritis?

Answer:

- Good investigation
- Positive only in 60% of cases
- May give false positives in:
  - Cryoglobulinemia
  - Parvo 19 infection
  - Hepatitis C
  - Sjogren's Syndrome
  - SLE
  - 5% of normal individuals
  - Malaria

Q 3.22: Which additional lab findings support the diagnosis of Rheumatoid Arthritis aside from Rheumatoid Factor?

Answer:

- Positive ANA occurs in 40%
- Elevated ESR and CRP

Q 3.23: What is the initial treatment approach for Rheumatoid Arthritis in the acute stage?

Answer:

- Acute Stage
  - Corticosteroids are used temporarily for 1 to 2 weeks to control inflammation.

Q3.24: What are commonly used DMARDs in the treatment of Rheumatoid Arthritis?

Answer:

- HCQ (200mg BD)
- Sulfasalazine
- Methotrexate (Best)
  - 7.5mg once weekly
  - Antimitotic agent
  - It causes Folic acid deficiency
  - So patients should be supplemented with Folinic acid
- Leflunomide (the latest DMARD drug)

Q3.25: What are some commonly used biological DMARDs in Rheumatoid Arthritis treatment?

Answer:

- Infliximab
- Etanercept
- Adalimumab
- Golimumab
- Anakinra
- Tocilizumab (Currently very effective)

Q3.26: Why is it important to rule out subclinical tuberculosis before starting DMARD therapy in Rheumatoid Arthritis patients?

Answer:

- Before starting DMARD, one should rule out subclinical Tuberculosis
  - Otherwise, Tuberculosis will flare up that endangering the patient's life
  - Surgical correction - Total Knee Replacement

BIG QUESTION 4: Explain the classification, clinical features, investigations, and treatment options for rotator cuff injuries. What are the key differences in the mechanism, clinical features, diagnostic tests, and treatment approaches for Anterior and Posterior Cruciate Ligament (ACL and PCL) injuries?

Broad Answer:

- Rotator cuff tears are partial or complete, causing shoulder pain, weakness, and night pain. Key signs include Arm Drop and Horn Blower's. MRI confirms diagnosis. Treatment is conservative for minor tears and surgery for full-thickness tears.
- ACL injuries occur with twisting or deceleration, causing swelling and instability; diagnosed by the Lachman test and MRI, treated with physio or surgery.
- PCL injuries follow direct tibial trauma, often subtle; diagnosed by Posterior Drawer or Godfrey's sign, managed conservatively or with reconstruction.

DETAILED QUESTIONS

Q 4.1: What are the two main types of rotator cuff injuries?

PYQ: FMGE 2021

Answer:

- Partial
- Complete

Q 4.2: What is Ellman's classification for Partial-Thickness RC Tear?

Answer: This helps in guiding management

Grade 1	25% tear of the Tendon thickness
Grade II	25-50% tear of the Tendon thickness
Grade III	> 50% tear of the Tendon thickness

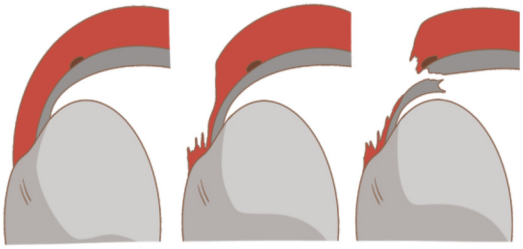

Q 4.3: What is Patte's classification for complete rotator cuff tears?

Answer:

Stage I	Proximal retracted Stump near the Bony insertion
Stage II	Proximal retracted Stump is at the level of the Humeral head.
Stage III	Proximal retracted Stump is at the level of the Glenoid.

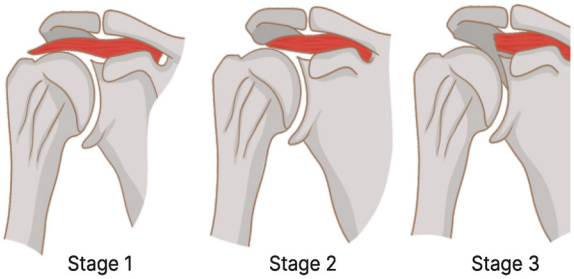

Q 4.4: What are the key clinical features of rotator cuff injuries?

Answer:

- Pain on the lateral aspect of the shoulder radiating to the Deltoid insertion
- Pain & weakness are consistent complaints
- Night pain is very characteristic
- The patient would feel a Pop in the shoulder
- Arm Drop Sign

Q 4.5: What is the Arm Drop Sign in rotator cuff injuries?

PYQ: NEET PG 2019

Answer:

- Examiner abducts the arm to the maximum
- The patient is asked to lower the arm gradually

YOURWISH

- The patient will be able to lower his arm around 100°, after which he suddenly loses control of his arm & his arm drops down.
- This strongly indicates a full-thickness tear.

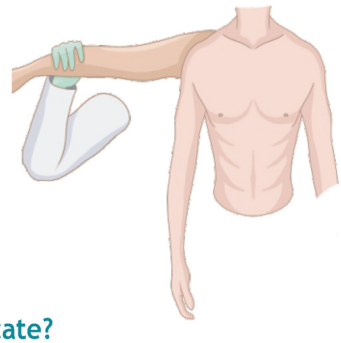

Q 4.6: What is Patte's Sign (Horn Blower's Sign) and what does a positive result indicate?

Answer:

- Done with the patient in sitting or standing
- The patient's arm is supported in 90° abduction in the scapular plane with the elbow flexed to 90°
- The patient is then asked to rotate the forearm externally
  - o If the patient is unable to rotate the shoulder externally at this position
  - o Horn Blower's Sign is positive
- This strongly suggests suggestthe s Teres Minor Tear



Q 4.7: What are the standard X-ray views used to investigate rotator cuff injuries?

Answer:

- AP view in the plane of the scapula
- AP view in the coronal plane
- Axillary view of the shoulder

Q 4.8: What are the specialised X-ray views used in diagnosing rotator cuff injuries?

Answer:

- Supraspinatus outlet view (10 to 15° caudal tilt lateral scapular view) to access the supraspinatus outlet harrowing
- AP coronal view in 30° cephalic-tilt view to evaluate the AC joint for Acromioclavicular Arthritis

Q 4.9: What are the key X-ray findings in rotator cuff injuries?

Answer:

- Acromiohumeral interval <7mm
- Subacromial calcification

Q 4.10: What are the radiological stages of rotator cuff (RC) tear progression?

Answer:

- RC Tear shows certain stages
  - o Stage 1: Greater Tubercle undergoes Sclerosis
  - o Stage 2: GT undergoes Spur formation
  - o Stage 3: GT undergoes roughness (irregularity)
  - o Stage 4: GT becomes smooth
    - → GT dent is missing
    - → The humeral head becomes the femoral head
    - → So this is called Femoralization of the humerus

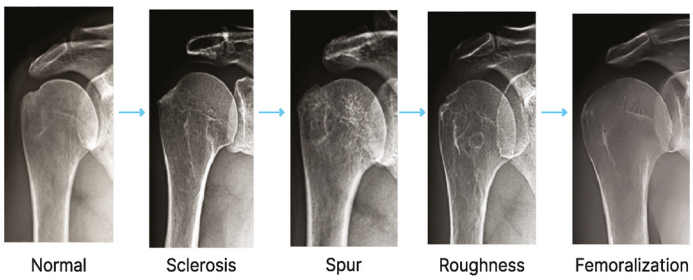

YOURWISH

YOURWISH

Q 4.11: What are the types of acromion, and which type is most associated with rotator cuff tears?

Answer:

1. Type 1
   - Looks flat

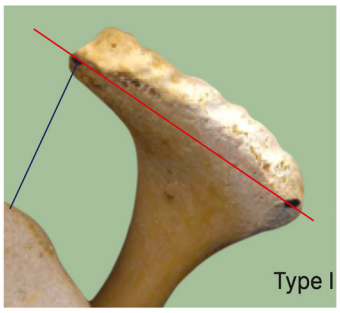

2. Type 2
   - Little concave

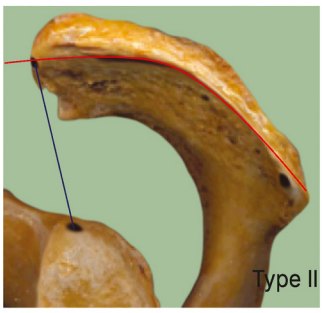

3. Type3
   - Very concave
   - More prone for RC Tear

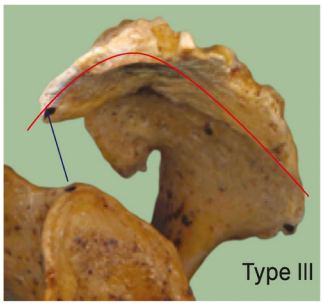

Q 4.12: What are the key imaging modalities used to diagnose a rotator cuff tear?

Answer:

- Most consistent Ultrasound findings of an RC Tear are
  - Non-visualization
  - Focal Thinning
  - Discontinuity of the cuff
- MRI is the Gold Standard Investigation

Q 4.13: What is the treatment approach for partial and full-thickness rotator cuff tears?

Answer:

- Arthroscopic RC Repair combined with Tuberoplasty
  - Gold Standard treatment for Full-Thickness RC Tears
- If it is a partial-thickness RC Tear, Grades 1 & II can be treated conservatively
  - But Grade III needs surgery

Q 4.14: What are the common mechanisms of injury for an isolated anterior cruciate ligament (ACL) tear?

Answer:

- An isolated ACL tear usually results from
  - Quick deceleration
  - Hyperextension
  - Rotation
  - Cutting action

Q 4.15: What is the Terrible Triad (Unhappy Triad) of the knee?

Answer:

- When the knee joint gets hit from the side
  - ACL injury may be associated with medial meniscal and medial collateral ligament injury
- Aka 'o' donoghue Unhappy Triad

Q 4.16: What are the clinical features of an Anterior Cruciate Ligament (ACL) injury?

Answer:

- The patient usually falls to the ground and cannot get up immediately

- Severe swelling of the knee within a few hours - Haemarthrosis
- Most patients have a history of giving away feelings in the knee on climbing downstairs

Q 4.17: What does a history of the knee "giving way" while climbing upstairs typically indicate?

Answer: Posterior cruciate ligament injury

Q 4.18: What is the Anterior Drawer test?

Answer:

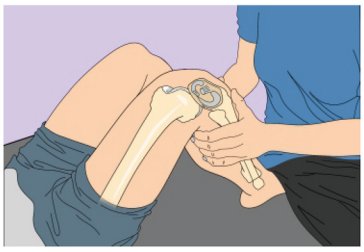

- The patient is in the supine position
- The knee joint is flexed to 90°
- The examiner sits over the dorsum of the foot
- The thumbs of both hands are on the tibial tuberosity.
- This test is considered positive if there is a 'soft end feel' exists
- It is less accurate than the Lachman Test
- Due to Door doorstep phenomena

When the knee joint is flexed to 90 degrees, if ACL injury is associated with a Meniscal injury

↓

The posterior horn of the Medial meniscus will catch

↓

Anterior translation of the tibia cannot be identified easily

- Associated medial meniscus injury

Q 4.19: Describe the Lachman test and its significance in diagnosing ACL injury.

Answer:



- The patient is in the supine position
- The knee is flexed to 30°
- The examiner places one hand behind the Tibia with the thumb on the tibial tuberosity, and the other hand is placed on the patient's thigh.
- More than 2mm of anterior translation associated with a 'soft end feel' - positive.

Q 4.20: Why is the Lachman test preferred over the Anterior Drawer test for diagnosing ACL injuries?

Answer:

- Lachman test is:
  - More reliable
  - More sensitive
  - Superior to Anterior Drawers Test

Q 4.21: What are the advantages of the Lachman test in diagnosing ACL injuries?

Answer:

- Less hurt to the patient. (Flexing only to 30 degrees)
- No doorstep phenomenon gold standard physical test for ACL injury

Q 4.22: What is the Pivot Shift Test, and how does it help in diagnosing ACL injuries?

Answer:

- Diagnose the rotatory instability related to injury of the anterior cruciate ligament ACL of the knee.
- The patient is supine.
- The examiner grasps and immobilises the lateral femoral condyle with one hand and palpates the proximal Tibia or fibula with the thumb.
- On the other hand, the examiner holds the patient's lower leg in internal rotation and abduction (valgus stress)
- From this starting position, the knee is moved from extension into flexion
- In a torn anterior cruciate ligament, the valgus stress will cause the Tibia to subluxate anteriorly while the knee is still in extension

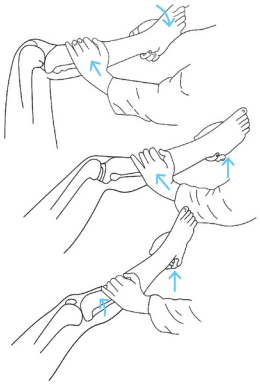

Q 4.23: What findings on X-ray can indicate an ACL injury?

Answer:

- It may show a tibial eminence fracture
- It indicates the avulsion of the tibial attachment of the ACL

Q 4.24: What is a Segond fracture, and what is its clinical significance in knee injuries?

Answer:

- It is the avulsion fracture of the lateral tibial plateau
- It is pathognomonic of an ACL tear

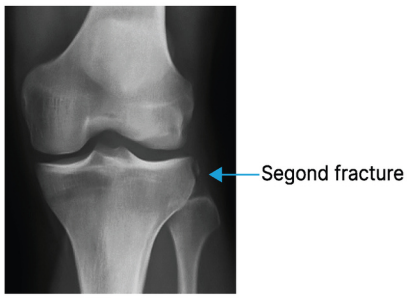

Q 4.25: What are the key MRI findings in an ACL injury?

Answer:

- MRI is the investigation of choice
- MRI with the knee in 15° external rotation will show the entire ACL
- Evidence of bone contusion & oedema in the lateral femoral condyle near the sulcus terminalis & posterolateral aspect of the Tibia
  - o It is called a kissing lesion.

Q 4.26: What are the key non-surgical management strategies for ACL injuries?

Answer:

- Activity modification
- Hamstring strengthening (Closed chain physiotherapy)

Q 4.27: What are the surgical treatment options for ACL injuries?

Answer:

- If a bony avulsion is present, the avulsed fragment is fixed with sutures or a trans-osseous screw.
- Primary repair of ACL
- Reconstruction of ACL - TOC.
  - o Types of grafts are
    - → Bone-Patella Tendon-Bone Graft (BTB)

→ Semitendinosus - Gracilis Muscle Graft (ST-G)

- Typically, surgery is done 4 weeks after trauma

Q 4.28: What is the most common mechanism of injury for Posterior Cruciate Ligament (PCL) injuries?

Answer: A direct blow to the posterior aspect of the Tibia

Q 4.29: What are the key clinical features and signs of isolated Posterior Cruciate Ligament (PCL) injury?

Answer:

- Isolated PCL injury is often asymptomatic because the instability is often subtle.
- Posterior Drawer Test Positive for PCL injury
- Godfrey sign

Q 4.30: What is the Godfrey sign in Posterior Cruciate Ligament (PCL) injury?

Answer:

- Godfrey sign
  - This is otherwise called the Gravity Sign or Sag Sign
  - Patient is lying on an examination couch. The knee joint is flexed to 90 degrees. The hip joint is flexed to 90 degrees
  - When viewed, the knee /tibial tuberosity tangentially
  - The tibial tuberosity sags down when compared to the normal side



Q 4.31: What is the investigation of choice for diagnosing Posterior Cruciate Ligament (PCL) injury?

Answer: MRI

Q 4.32: How is a Posterior Cruciate Ligament (PCL) injury treated surgically?

Answer: PCL reconstruction is done through a tibial /femoral tunnel technique

Q 4.33: What are the common graft options used in the reconstruction of Posterior Cruciate Ligament (PCL) injury?

Answer:

- Patellar tendon-bone graft (PTB)
- Quadriceps Tendon Bone Graft (QTB)
- Semitendinosus/Gracilis Tendon Graft (ST-G)

14. MISCELLANEOUS TOPICS PART -3

BIG QUESTION 1: What are the key features, associations, and treatment principles of Congenital Talipes Equino Varus (CTEV)?

Broad Answer: Congenital Talipes Equino Varus (Clubfoot) is a polygenic congenital deformity of the foot, most common in males, and often bilateral. The condition primarily involves structural abnormalities of the talus and calcaneus, leading to deformities remembered by the mnemonic CAVE. It has various syndromic associations and requires early treatment, starting with manipulation and progressing to surgical procedures depending on age.

DETAILED QUESTIONS

Q1.1: What is Congenital Talipes Equino Varus, and what is its inheritance pattern?

PYQ: INICET 2022

Answer:

- CTEV, also called Clubfoot, has polygenic inheritance.
- It is most common in males and bilateral in 50% of cases.

Q1.2: What are the suggested etiologies of CTEV?

PYQ: AIIMS 2019

PYQ: FMGE 2022

Answer:

- Abnormal intrauterine position of the fetus
- Primary germplasm defect of the talus (most accepted theory) → faulty formation, altered shape/size of talus → congenital talonavicular dislocation.
- Primary soft tissue abnormalities

Q1.3: What are the classical deformities seen in CTEV?

Answer:

- (Mnemonic: CAVE):
  - Cavus → excess medial arch
  - Adduction → forefoot adduction at the tarsometatarsal joint
  - Varus → at the subtalar joint
  - Equinus → at the ankle joint

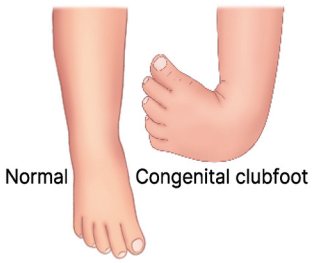

Q1.4: What conditions are associated with CTEV?

Answer:

- Meningomyelocele (most common) → look for a tuft of hair, a dimple
- Spina bifida
- Arthrogryposis multiplex congenita
- Tibial hemimelia (tibia absent on one side, fibula intact)
- Lateral popliteal nerve palsy
- Poliomyelitis
- Cerebral palsy

Q1.5: How does the X-ray finding differ in a normal vs. CTEV foot?

Answer:

- Normal: Axis of talus passes through navicular and 1st metatarsal.
- CTEV: Line deviates to the 3rd or 4th metatarsal.

Q1.6: What are the principles of treatment of CTEV?

Answer:

- Start as early as possible (manipulation by mother)
- Correction order: Forefoot adduction → Inversion → Equinus
- Wrong correction order → Rocker-bottom foot (also seen in congenital vertical talus, Edward syndrome)
- Use of minimal force gives the best outcome
- The squatting test checks the adequacy of correction

Q1.7: What are the treatment options for CTEV at different ages?

Answer:

Duration	Procedure
Birth to 2 months	Manipulation by mother Ponseti technique
2 months to 5 years	Posteromedial soft tissue release is called **Turco's procedure.** Releasing of: • Tendo Achilles • Tibialis posterior tendon
5- 10 years	Bony reshaping is called the **Dillwyn Evans procedure.** • Change the shape of the talus or calcaneus bone.
10 years and above (Neglected CTEV)	**Triple arthrodesis:** Artificial fusion of 3 joints - subtalar, calcaneocuboid, and talonavicular joint to attain a pain-free stable joint.

BIG QUESTION 2: What are the key features, diagnostic tests, and treatment options for Congenital Dislocation of Hip (CDH) / Developmental Dysplasia of Hip (DDH)?

Broad Answer: Congenital Dislocation of Hip (DDH) is a developmental disorder of the hip joint, far more common in Europe than in India. It has a strong female predominance, commonly affects the left hip, and is associated with delayed ossification of the femoral head and shallow acetabulum. Diagnosis is made using specific clinical tests such as Ortolani, Barlow, Galeazzi, and Telescopic tests. Risk factors include firstborn status, female sex, breech presentation, and exposure to maternal relaxin. Treatment depends on age and includes splints, gentle reduction with casting, and osteotomy in neglected cases.

DETAILED QUESTIONS

Q2.1: What is Congenital Dislocation of the Hip, and how common is it in different regions?

Answer:

- Also called Developmental Dysplasia of the Hip (DDH)
- Uncommon in India, very common in Europe
- Indian mothers' way of carrying babies reduces the incidence

Q2.2: What is the epidemiology and laterality of DDH?

Answer:

- Female predominance (Girl:Boy = 7:1).
- Mostly unilateral; the left hip is more commonly affected.

Q2.3: What anatomical abnormalities are seen in DDH?

Answer:

- Delayed ossification of the capital femoral epiphysis
- Small-sized head of the femur
- Shallow acetabulum (more common)

Q2.4: What are the common clinical features of DDH?

Answer:

- Leg shortening on the affected side
- Additional thigh crease (posterior/medial) on affected side (normally only one crease present)

Q2.5: What are the important diagnostic tests for DDH?

Answer:

- Ortolani test (Test of entry): Hip reduced with a click on abduction and internal rotation → femoral head enters acetabulum.
- Barlow's test (Test of exit): Provocative test to dislocate a dislocatable hip (not routinely practised).
- Telescopic test: Positive when the femoral head moves up and down on pressing/pulling the flexed knee (DDx: CDH, PDH, fracture neck femur, Tom Smith arthritis, Girdlestone).
- Galeazzi's sign (Allis test): Supine baby with hips and knees flexed → knee level lower on affected side.

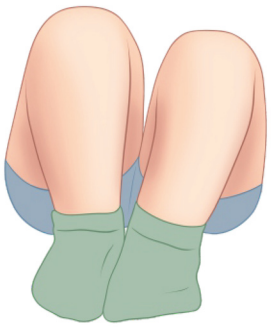

Q2.6: What are the risk factors for DDH?

Answer:

- Firstborn baby
- Female sex
- Full-term baby (maternal relaxin causes ligament laxity in the fetus)
- Breech presentation

Q2.7: What is the best investigation for DDH?

Answer: Real-time ultrasound is superior to X-ray

Q2.8: What are the treatment options for DDH at different ages?

Answer:

Stage	Treatment
Infants below 3 months	Von Rosen's splint

YOURWISH

Between 3-6 months	• Reduced by gentle manipulation under GA and immobilized in a plaster cast with hip in **90° flexion and 45° abduction** - human position for 30 days. • If immobilized by more than 45°, the blood supply to the head/femur is affected, leading to avascular necrosis of the head of the femur.
Neglected CDH	Schantz osteotomy (CHIARI's osteotomy - Apley)

Q2.9: What is a major complication of forceful reduction or excessive abduction in DDH?

Answer: Avascular necrosis of the head of the femur

BIG QUESTION 3: What are the causes, clinical features, diagnostic tests, and treatments of Carpal Tunnel Syndrome and Dupuytren's Contracture?

Broad Answer: Carpal Tunnel Syndrome (CTS) results from compression of the median nerve in the carpal tunnel, most often due to physiological states (pregnancy, menopause) or pathological conditions like hypothyroidism and rheumatoid arthritis. It is diagnosed with clinical tests such as Tinel's, Phalen's, and Durkan's, and treated by correcting underlying causes or surgically releasing the flexor retinaculum.

Dupuytren's Contracture is an autosomal dominant fibrotic condition of the palmar fascia, usually affecting the ring and little fingers. It is commonly associated with uncontrolled diabetes, alcohol use, and certain drugs, and may be linked with systemic fibrotic conditions like Peyronie's disease and Ormond syndrome.

DETAILED QUESTIONS

Q3.1: What is Carpal Tunnel Syndrome, and what are its causes?

Answer:

- CTS is a compression of the median nerve in the carpal tunnel
- Causes include:
  - Pregnancy, menopause (most common cause)
  - Myxoedema (hypothyroidism) - the most common pathological cause
  - Rheumatoid arthritis
  - Compound palmar ganglion (TB = most common cause of ganglion)
  - Lunate dislocation
  - Malunited Colles fracture

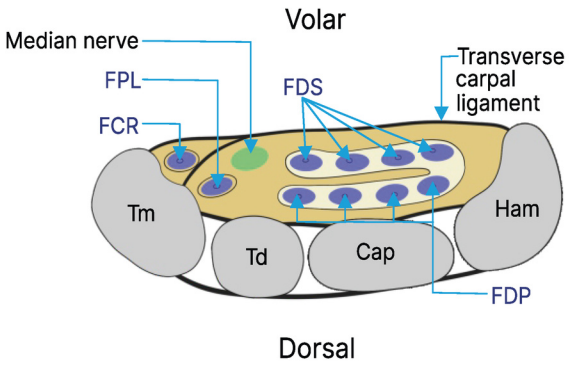

Q3.2: What clinical tests are used to diagnose Carpal Tunnel Syndrome? PYQ: FMGE 2019

Answer:

- Tinel's sign: Tapping over the median nerve → tingling along its course
- Phalen's test: Flexed wrists for 1 min → pain/tingling along the median nerve. (Reverse Phalen's can also be done)
- Durkan's test: Pressure applied over the median nerve for 1 min → numbness and pain


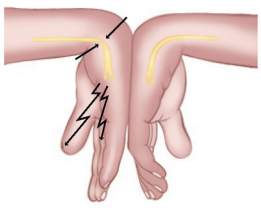

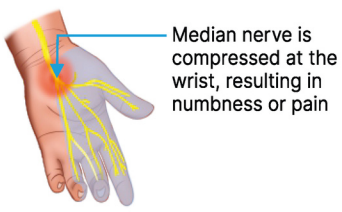

YOURWISH

Q3.3: What are the treatment principles of Carpal Tunnel Syndrome?

Answer:

- Self-limiting if due to physiological causes
- Correct the deformity in pathological causes
- Persistent cases: Surgical release of the flexor retinaculum

Q3.4: What is Dupuytren's Contracture, and where is it most commonly seen?

Answer:

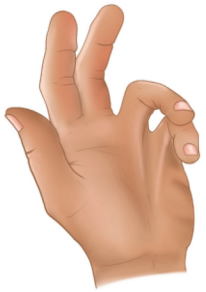

- Contracture of the superficial palmar fascia
- Most common site → palmar aponeurosis opposite to the ring and little finger
- Inherited as an autosomal dominant
- Garrod's pads: hyperkeratosis & hyperpigmentation over knuckles

Q3.5: What are the causes of Dupuytren's Contracture?

Answer:

- Uncontrolled diabetes (the most common cause)
- Drugs like phenytoin
- AIDS
- Alcohol use
- Tuberculosis

Q3.6: What systemic associations are linked with Dupuytren's Contracture?

Answer:

- Peyronie's disease: Fibrosis of the ventral penis
- Ormond Syndrome (Idiopathic retroperitoneal fibrosis): Ureter compression → hydronephrosis; precancerous condition

BIG QUESTION 4: What are the causes, pathology, clinical features, diagnostic tests, and treatment options for Lateral Epicondylitis (Tennis Elbow)?

Broad Answer: Lateral Epicondylitis, also known as Tennis Elbow, is a tendinosis (not tendinitis) involving degenerative changes at the common extensor tendon origin, most commonly the extensor carpi radialis brevis (ECRB). It is idiopathic, self-limiting, and most frequent between 35-55 years, affecting the dominant arm equally in both sexes. Clinical diagnosis relies on provocative tests such as Cozen's, Mill's, Maudsley's, and the Chair test. MRI is the best investigation. Management is mainly conservative with rest, NSAIDs, physiotherapy, and injections; resistant cases may need surgery, like the Modified Nirschl technique.

DETAILED QUESTIONS

Q4.1: What is Lateral Epicondylitis, and which tendons are most commonly affected?

Answer:

- A tendinosis (chronic degeneration), not an inflammatory disorder.
- Involves common extensors of tendon origin:
  - Extensor carpi radialis brevis (ECRB) - most common, superior fibres.

- Extensor digitorum
- Extensor digiti minimi
- Extensor carpi ulnaris

Q4.2: What is the pathogenesis and histological hallmark of Tennis Elbow?

Answer:

- Previously considered tendinitis; now recognised as tendinosis.
- Pathological hallmark: Angio-fibroblastic hyperplasia.
- Nirschl Classification:

Stage I	**Temporary** irritation.
Stage II	• Permanent tendinosis. • Involves < **50%** of the tendon cross-section.
Stage III	• Permanent tendinosis. • Involves > **50%** of the tendon cross-section.
Stage IV	Partial or **total** tendon rupture.

Q4.3: What are the clinical features of Lateral Epicondylitis?

Answer:

- Age: 35-55 years
- Pain & tenderness: Localised over the lateral epicondyle (Stage I), diffuse in later stages.
- Pain aggravated by: Gripping, lifting a jar, handshaking.

Q4.4: What clinical tests are used to diagnose Tennis Elbow?

Answer:

- Cozen's (Thompson's) test: Resisted wrist extension in pronation → pain
- Mill's test: Pronated forearm, wrist flexed, elbow extended → pain
- Maudsley's test (Middle finger test): Resisted 3rd digit extension → pain
- Chair test: Lifting a chair → pain at the lateral epicondyle

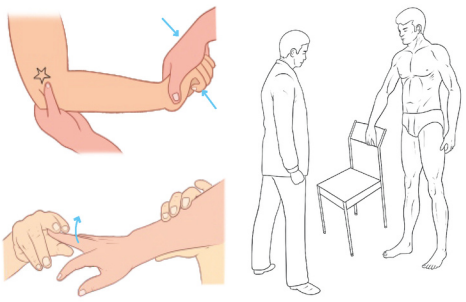

Q4.5: What are the differential diagnoses of Lateral Epicondylitis?

Answer:

- Cervical root compression (C6, C7)
- Posterior Interosseous Nerve (PIN) entrapment at the arcade of Frosch
- Local bursitis

Q4.6: What investigations help in diagnosis?

Answer:

- X-ray: Calcification
- Doppler USG: Neovascularisation, grey-scale changes
- Thermography: Correlates severity
- MRI: Best for degenerative changes & tendon tears

Q4.7: What are the treatment principles for Tennis Elbow?

Answer:

- Aims: Pain control, restore movement, regain grip strength, and prevent recurrence
- Non-operative (first line):
  - Rest (6 weeks - best initial management)
  - NSAIDs
  - Stretching & physiotherapy (ultrasound/infra-red therapy)
  - Counter-force brace
  - Steroid injection
  - Extracorporeal shockwave therapy
  - Platelet-rich plasma / autologous blood injection
- Operative (for persistent cases):
  - Modified Nirschl technique (Extensor slide) - best results
  - Arthroscopic release
  - Hohmann's procedure: Percutaneous epicondylar stripping

BIG QUESTION 5: Discuss the classification, stages, and factors affecting fracture healing.

Broad Answer: Fracture healing is the unique process where bone repairs itself after injury. It is classified into primary healing (direct osteonal healing without callus under rigid fixation), secondary healing (classical callus-based healing in 7 stages as described by John Hunter), and distraction histogenesis (Ilizarov method). The 7 stages are impaction, induction, hematoma (inflammation), granulation, callus, consolidation, and remodelling. Healing is influenced by injury, patient, tissue, and treatment variables such as fracture type, age, nutrition, infection, and fixation methods.

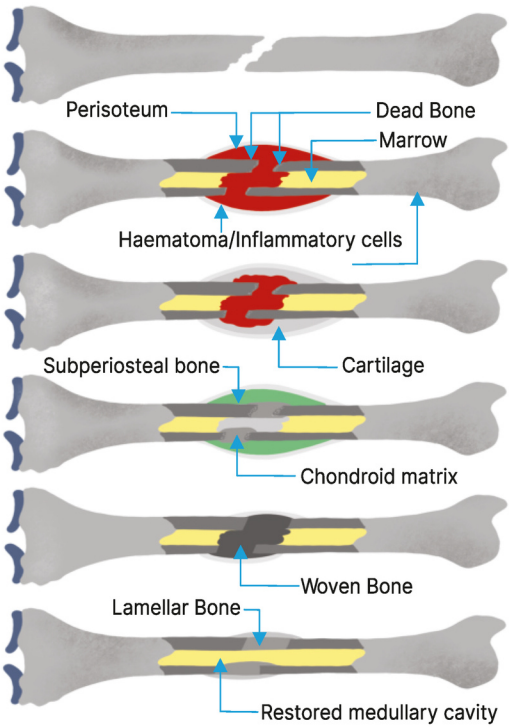

DETAILED QUESTIONS

Q5.1: What are the types of fracture healing?

Answer:

- Primary healing (direct osteonal healing, no callus, requires rigid fixation)
- Secondary healing (callus formation with remodelling in stages)
- Distraction histogenesis / Ilizarov method

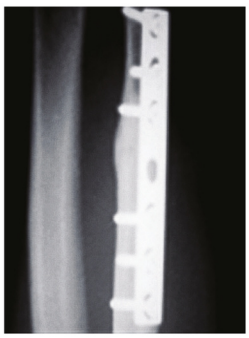

YOURWISH

Q5.2: What is primary fracture healing?

Answer:

- Primary healing occurs when cortical fragments unite without callus, through direct extension of osteons and cutting cone formation.
- It requires anatomical restoration by rigid internal fixation.

Q5.3: What is secondary fracture healing?

Answer:

- It involves classical callus-based healing in 7 stages: impaction, induction, hematoma, granulation, callus, consolidation, and remodelling.

Q5.4: Describe the stage of hematoma in fracture healing.

Answer:

- Also called the stage of inflammation
- Features: pain, swelling, heat
- Blood forms a hematoma, fractured ends undergo necrosis, inflammatory cells invade, and precursor cells from the periosteum are sensitised.
- Duration: ~7 days

When bone is fractured

↓

Blood seeps out

↓

Forms a **hematoma**

↓

Contained by the periosteum or soft tissue envelopes formed by muscles, fascia, and the skin

↓

A few millimeters of fractured ends of the bones undergo ischemic necrosis.

↓

Open ends of the torn vessels are thrombosed.

↓

Release of lysosomal enzymes

↓

Macrophages, leukocytes, and other Inflammatory mediators invade the area.

↓

Some cells from the periosteum are sensitized and form precursor cells.



Inflammation

Q5.5: What happens in the stage of granulation?

Answer:

- Also called cellular proliferation
- Soft granulation tissue forms (blood vessels, fibroblasts, osteoblasts)
- Blood clot resorbed by macrophages
- Provides a weak union between fragments
- Duration: 2-3 weeks

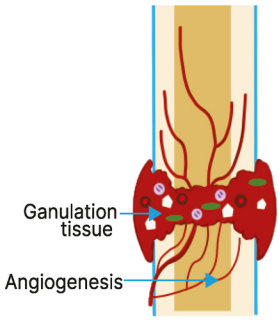

YOURWISH

Q5.6: What is the stage of callus formation?

PYQ: FMGE 2020

Answer:

- Also called the primary woven bone stage
- Osteoblasts lay matrix + calcium salts → immature woven bone
- Provides rigidity
- May be visible radiologically by 3 weeks
- Duration: 4-12 weeks

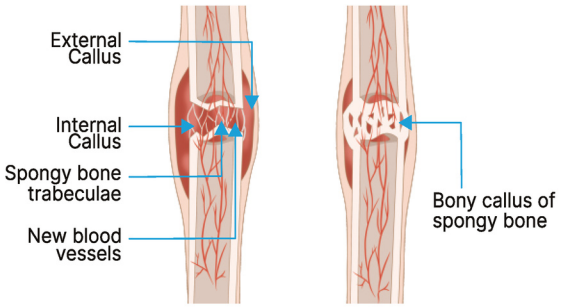

Q5.7: What occurs in the consolidation stage?

Answer:

- Also called the hard callus stage
- Woven bone gradually transforms into lamellar bone
- Duration: 3-6 months

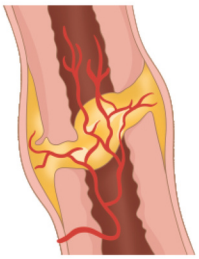

Q5.8: What occurs in the remodelling stage?

Answer:

- After complete healing
- Woven/fibre bone converted to lamellar bone
- Bulbous callus reabsorbed, cortex and canal restored
- Duration: lasts for years

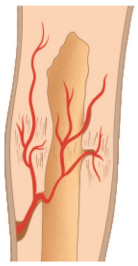

Q5.9: What are the factors affecting fracture healing?

Answer:

- Injury variables: open fracture, severity, intra-articular, soft tissue interposition
- Patient variables: age, nutrition, smoking, medication
- Tissue variables: cancellous vs cortical bone, bone disease, infection
- Treatment variables: anatomical reduction, stable/rigid fixation, micromotion, bone grafting

BIG QUESTION 6: Discuss Slipped Capital Femoral Epiphysis (SCFE) with respect to definition, clinical features, diagnostic signs, and management.

Broad Answer: Slipped Capital Femoral Epiphysis (SCFE), also called Adolescent Coxa Vara or Epiphysiolysis, is the posteroinferior migration of the proximal femoral epiphysis through the physis, though in reality, the metaphysis moves. It occurs mostly in boys aged 10-16 years, often left hip > right hip, and is associated with obesity, tall stature, and hormonal imbalance. Patients present with a limp, externally rotated limb, and limitation of internal rotation (the earliest sign). Classical diagnostic signs include the Axis Deviation (Knee-Axilla) Sign and Trethowan's Sign. Treatment depends on severity: mild - pin fixation, moderate - ORIF with screws, severe - corrective osteotomy.

DETAILED QUESTIONS

Q6.1. What are the other names of SCFE?

PYQ: FMGE 2022

Answer:

- Adolescent Coxa Vara
- Epiphysiolysis

Q6.2. What is the pathology in SCFE?

Answer: Posterior-inferior migration of the femoral epiphysis through the physis, though the metaphysis moves

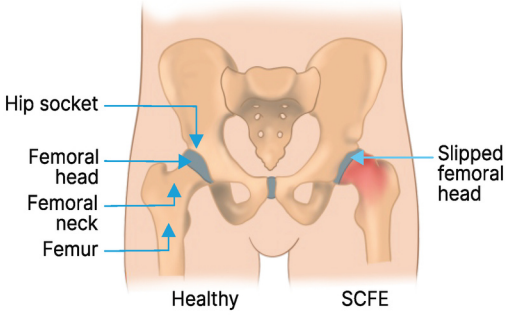

Q6.3. What is the age and sex predilection of SCFE?

Answer:

- Boys, 10-16 years
- More common in the left hip than> right hip

Q6.4. What are the risk factors for SCFE?

Answer:

- Obesity
- Tall stature
- Hormonal imbalances during puberty (weak growth plate)

Q6.5. Which type of slip is more common - acute or chronic?

Answer: Chronic slip is more common

Q6.6. What are the clinical features of SCFE?

Answer:

- Mild painful limp
- The affected limb is externally rotated
- Limitation of internal rotation (the earliest sign)

Q6.7. What is the Axis Deviation (Knee-Axilla) Sign, and how is it elicited?

Answer:

- Child supine, hip and knee flexed to 90°
- On over-flexion, normally the knee moves towards the opposite nipple/axilla
- In SCFE, the knee moves towards the same-side axilla
- It is a classical sign of SCFE

Q6.8. What is Trethowan's Sign?

Answer:

- A line drawn along the upper border of the femoral neck normally cuts the head
- In SCFE, the line does not cut the femoral head

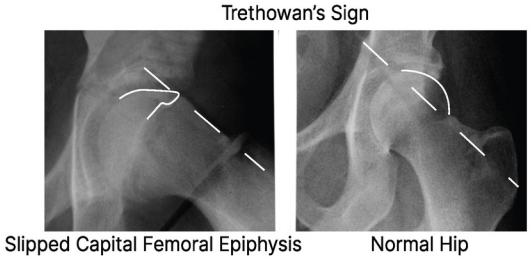

Q6.9. What is the treatment of SCFE?

Answer:

- Mild slip → Reduction + fixation with Austin Moore's pins
- Moderate slip → Open Reduction & Internal Fixation (cancellous screws)
- Severe slip → Corrective osteotomy