

# **ANATOMY**

---

# Cranial Nerve Columns

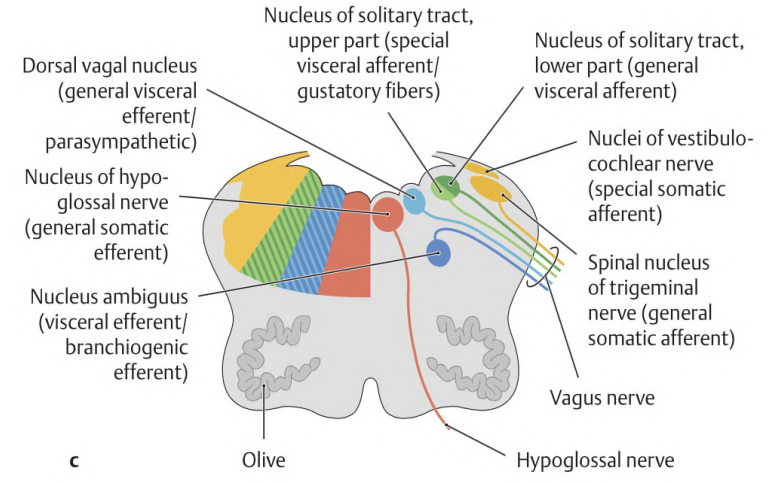
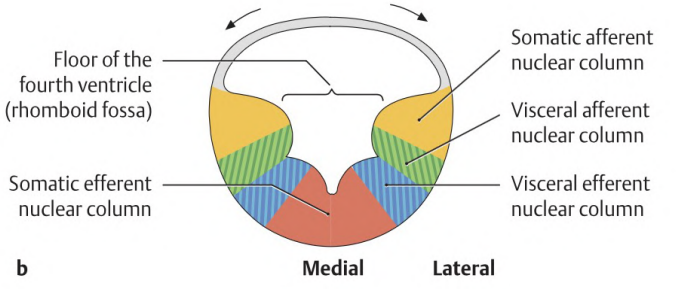
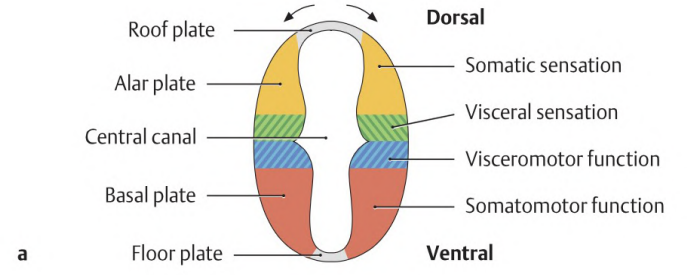
**“SAVE VA SAVE VASE”**

---

--	--	--	--	--	--	--

<b>Cranial nerve nucleus</b>	<b>Pre-ganglionic</b>	<b>Ganglion</b>	<b>Post-ganglionic</b>	<b>Structure</b>
<b>Edinger-Westphal nucleus</b>	<b>CN III</b>	<b>Ciliary ganglion</b>	<b>Nasociliary nerve Short ciliary nerves</b>	<b>Ciliary muscles</b>
<b>Superior salivatory nucleus</b>	<b>CN VII</b>	<b>Pterygopalatine ganglion  Submandibular ganglion</b>	<b>Maxillary nerve (V2) –Zygomatic branch  Lingual nerve</b>	<b>Lacrimal gland  Sublingual/ submandibular glands</b>
<b>Inferior salivatory nucleus</b>	<b>CN IX</b>	<b>Otic ganglion</b>	<b>Auriculotemporal nerve</b>	<b>Parotid gland</b>
<b>Dorsal motor nucleus</b>	<b>CN X</b>	<b>-</b>	<b>Vagal Nerve</b>	<b>Heart, lungs upper GI</b>

**Medial to lateral:**  
**GSE-SVE-GVE**  
**GVA-SVA-GSA-SSA**



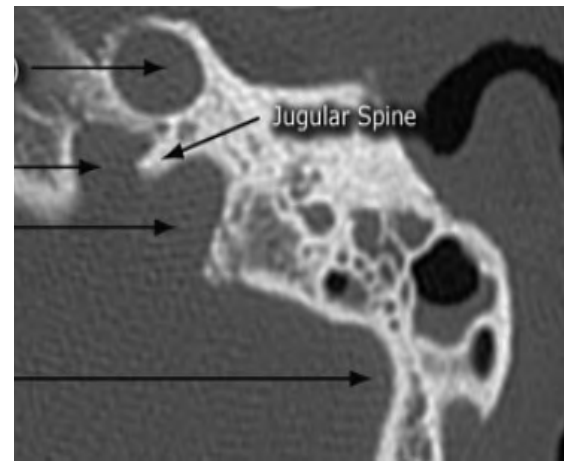
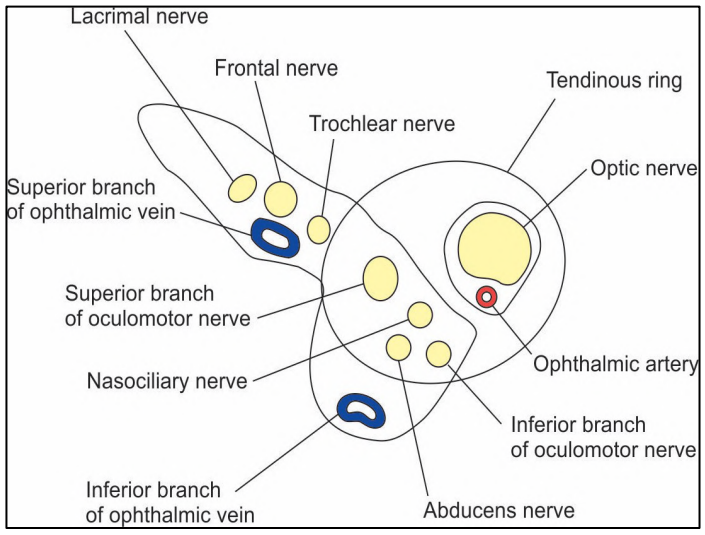
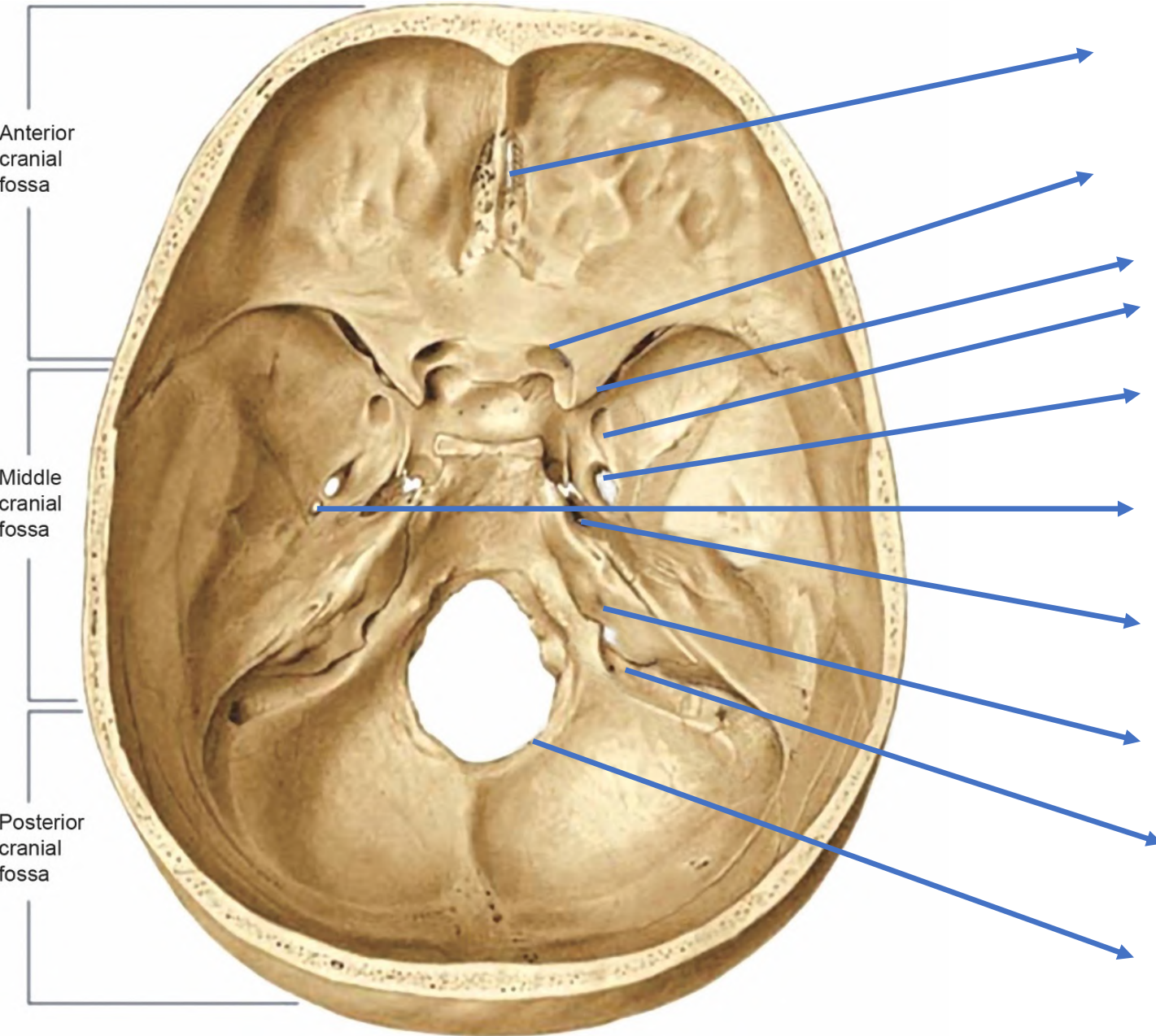
**REFLEXES:**

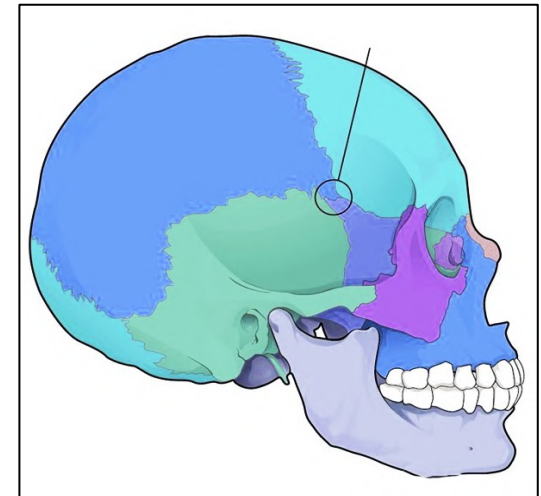
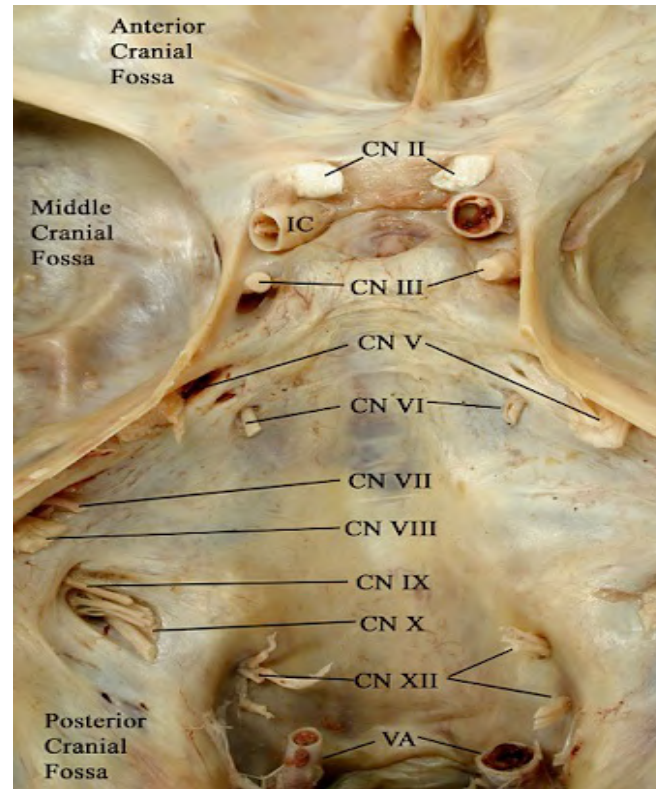
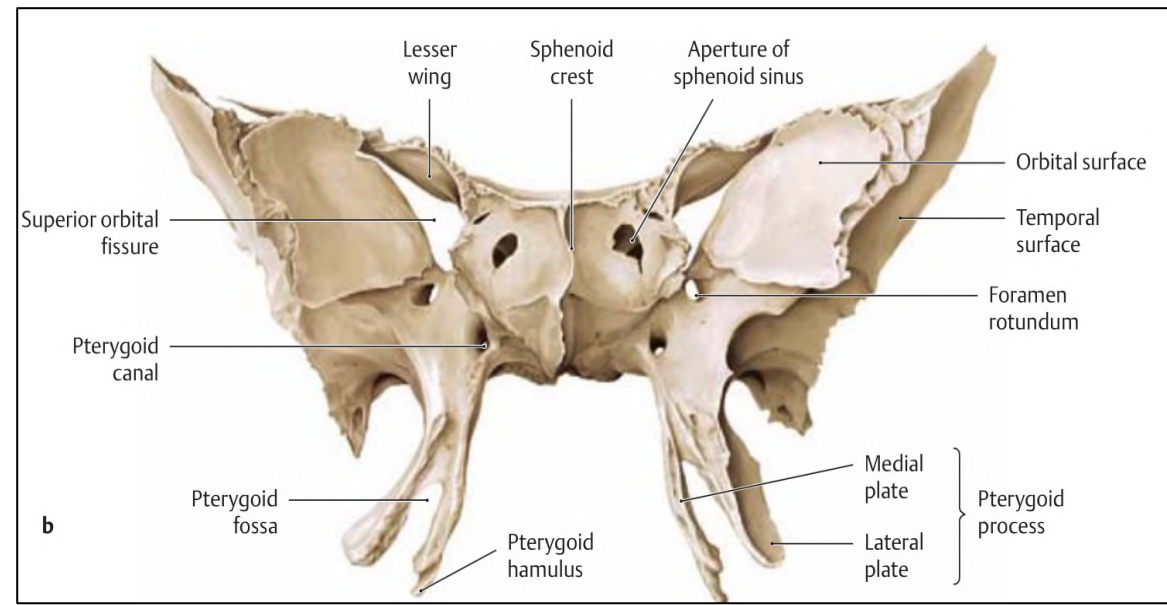
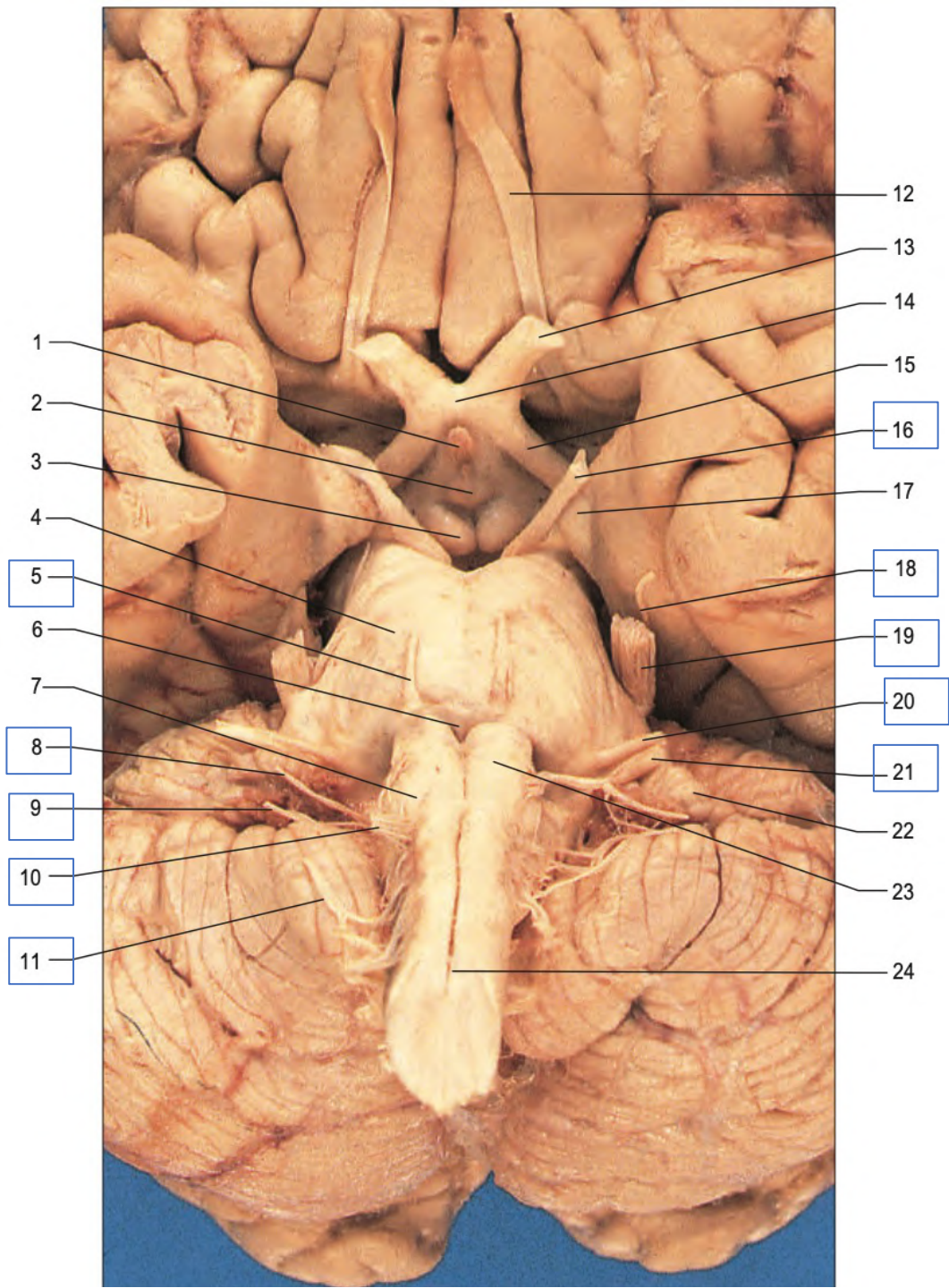
<b>Accommodation</b>	<b>AFFERENT</b>	<b>EFFERENT</b>
<b>Pupillary</b>		
<b>Corneal</b>		
<b>Lacrimation</b>		
<b>Cough</b>		
<b>Gag</b>		
<b>Jaw jerk</b>		

**GSA:**  
**Mesencephalic:**  
**Proprioception**

**Principal sensory:**  
**Touch, pressure**  
**Spinal: Pain, temp**

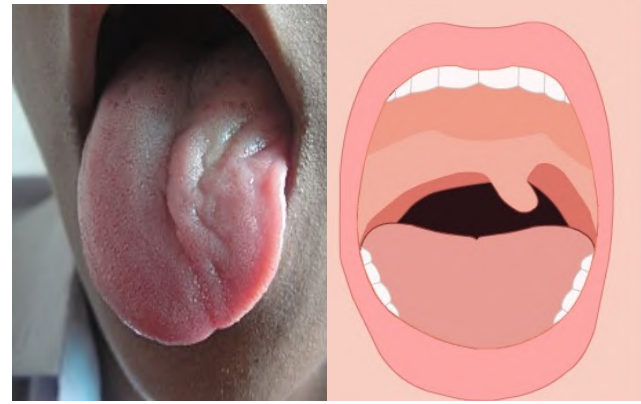# Cranial Nerves/ Foramina



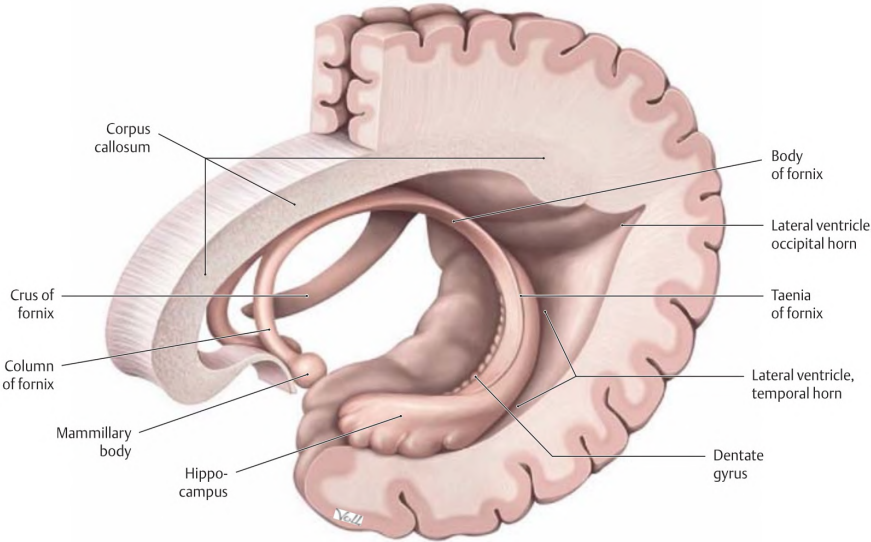
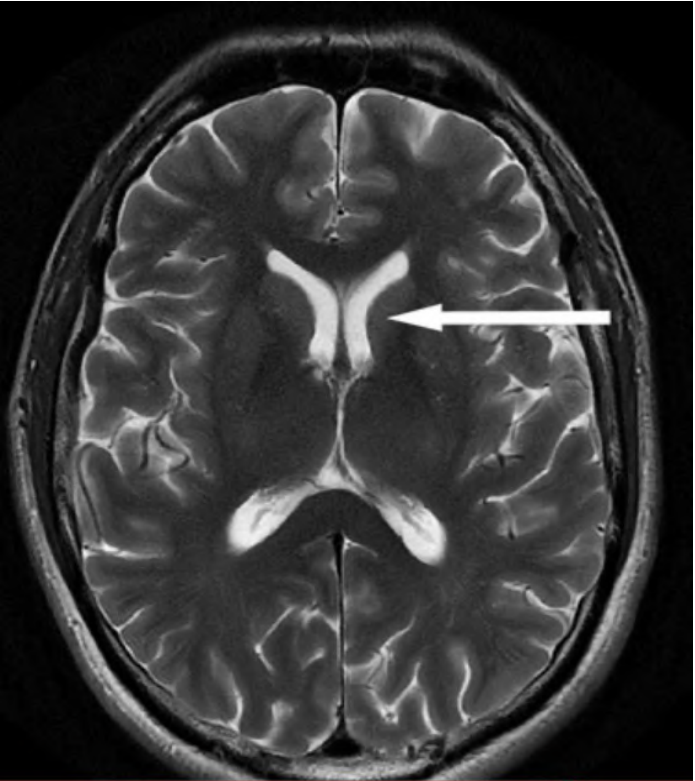
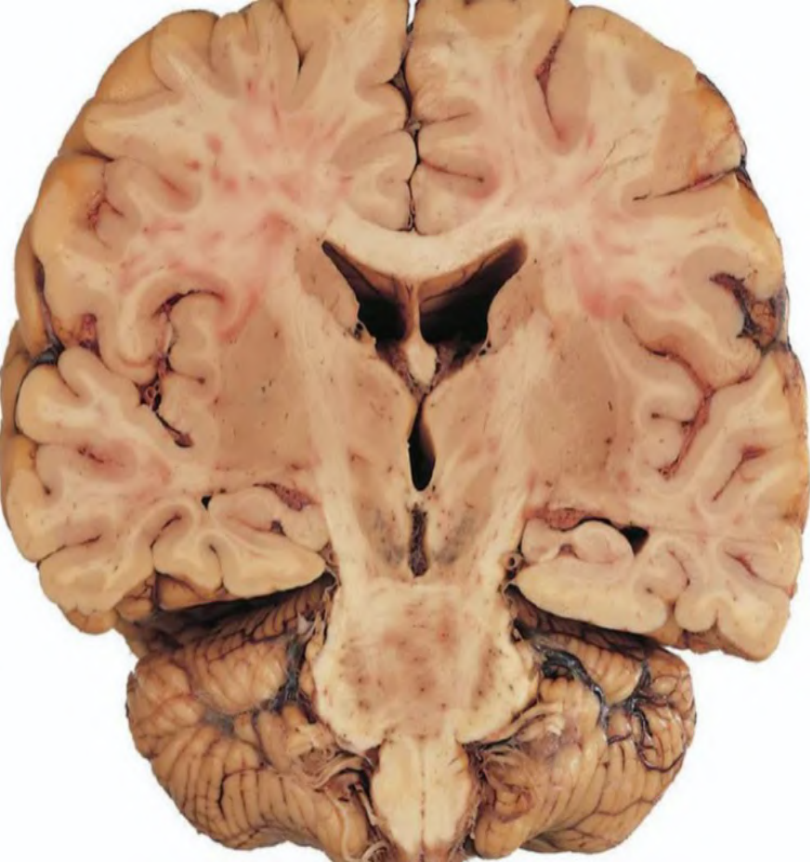


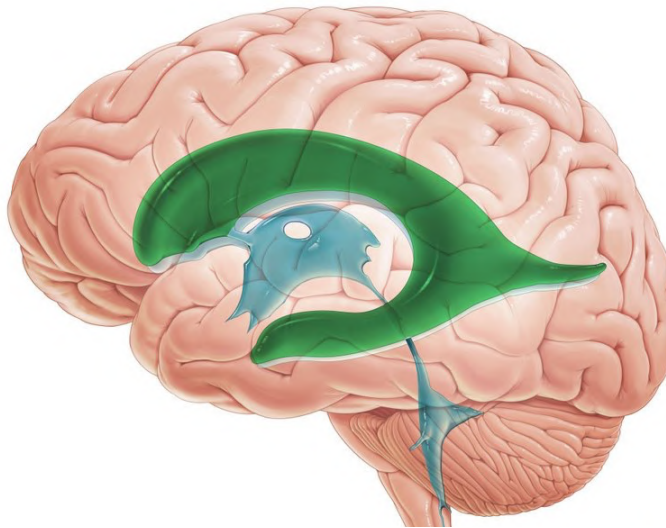
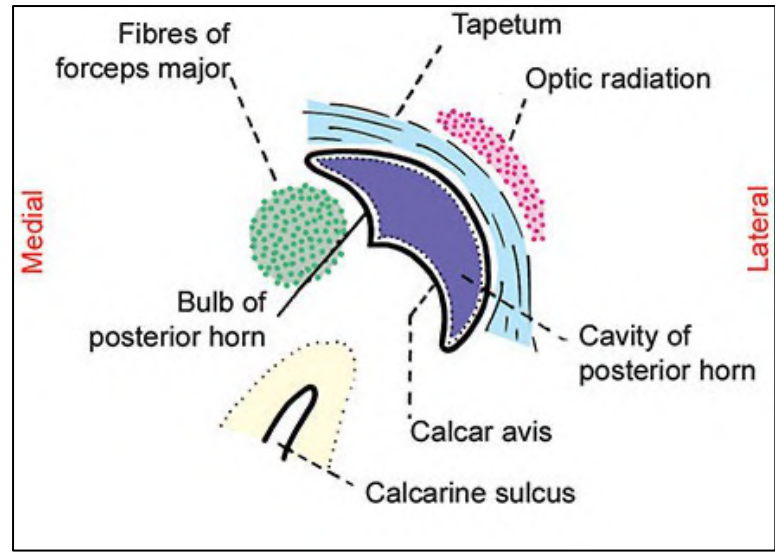
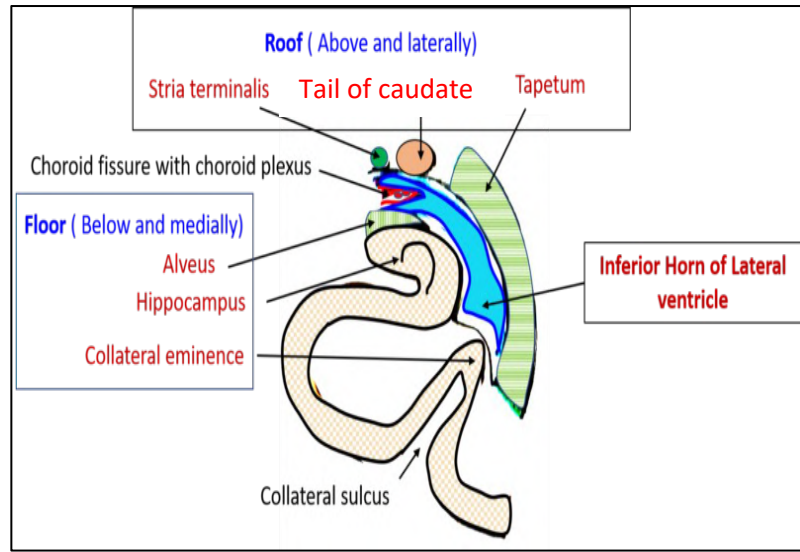
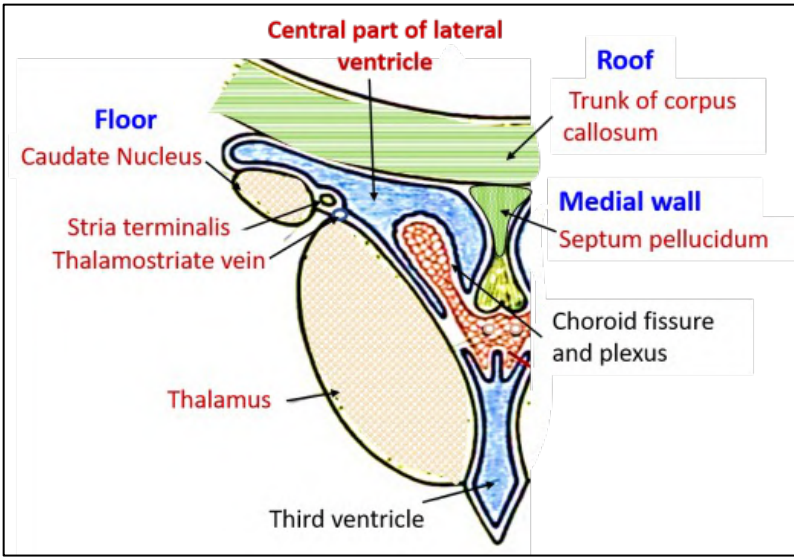
**Dorsal origin**  
**Internal decussation**  
**Longest intracranial course**  
**Thinnest, smallest**  
**Longest intradural course**  
**Longest intraosseous course**

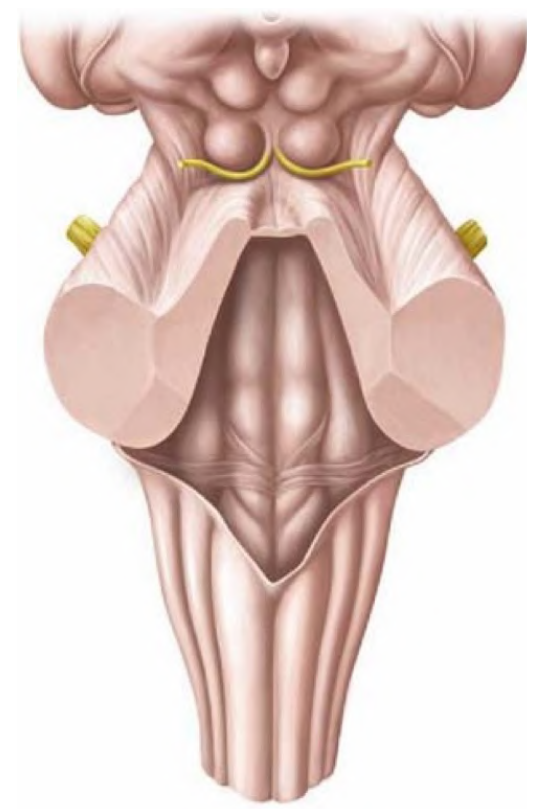
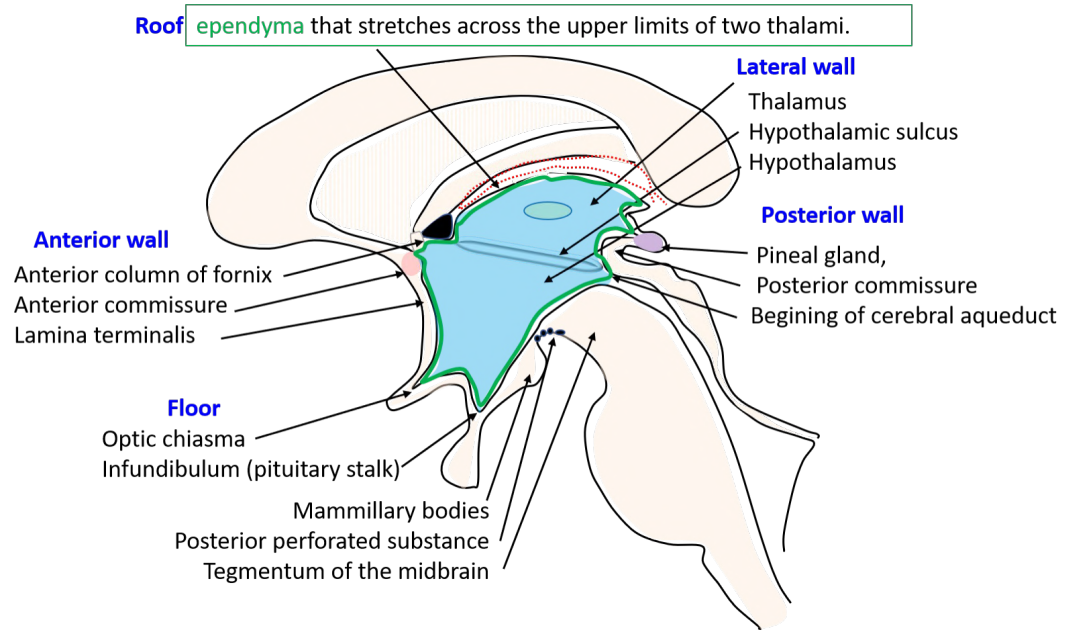
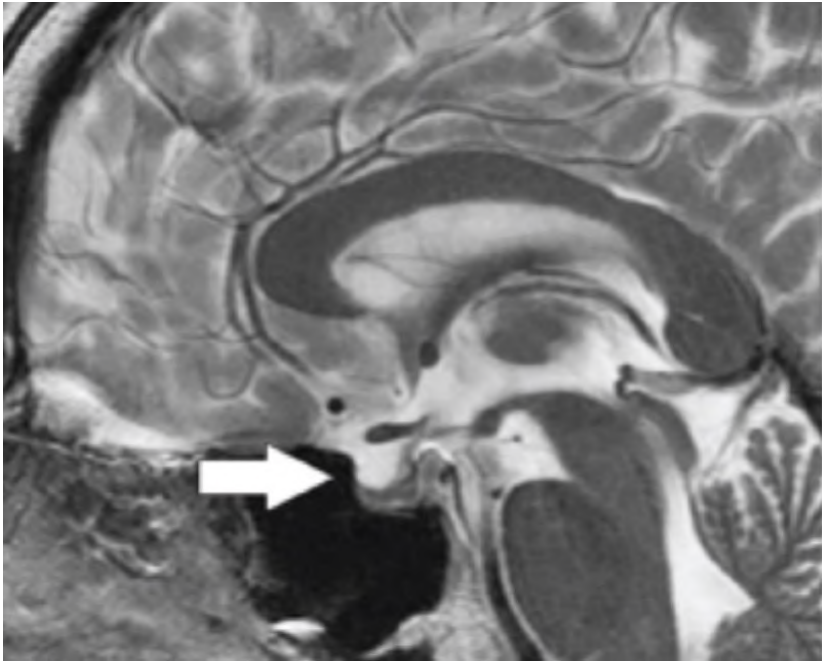
**RULE OF 17:**



# Neuroanatomy

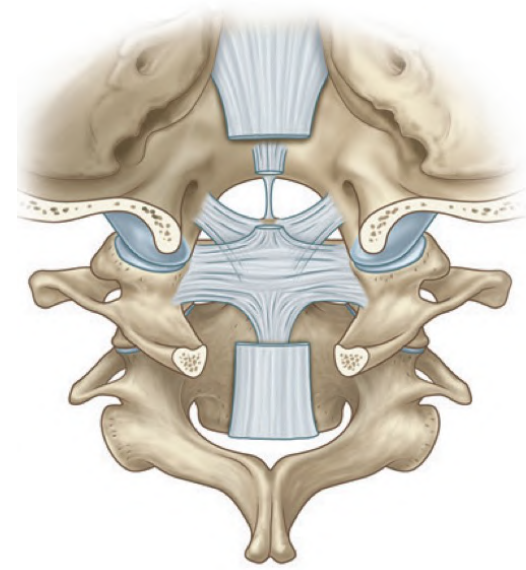
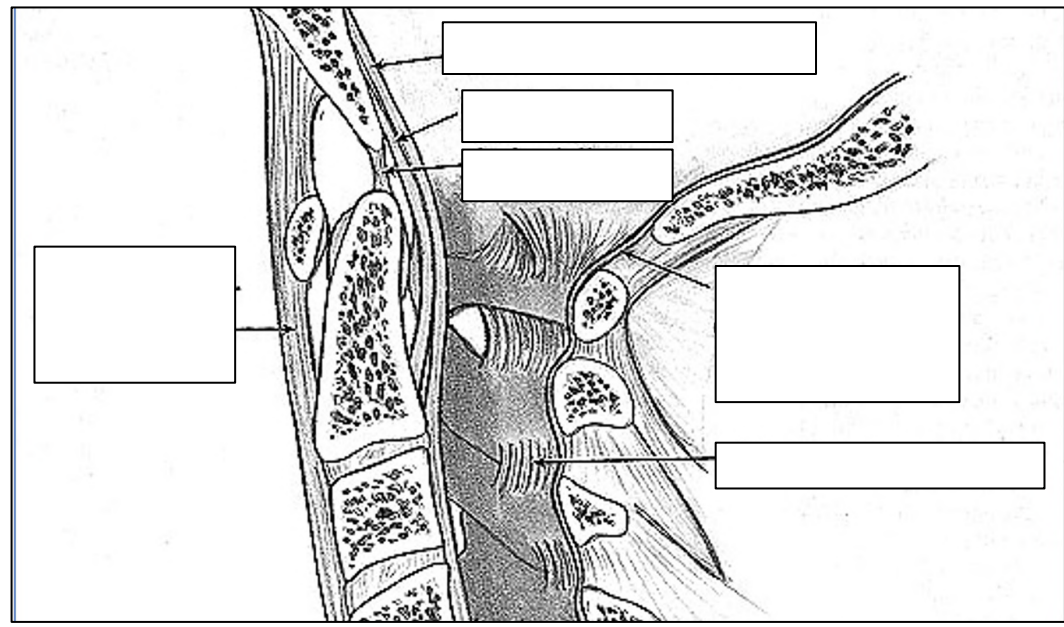
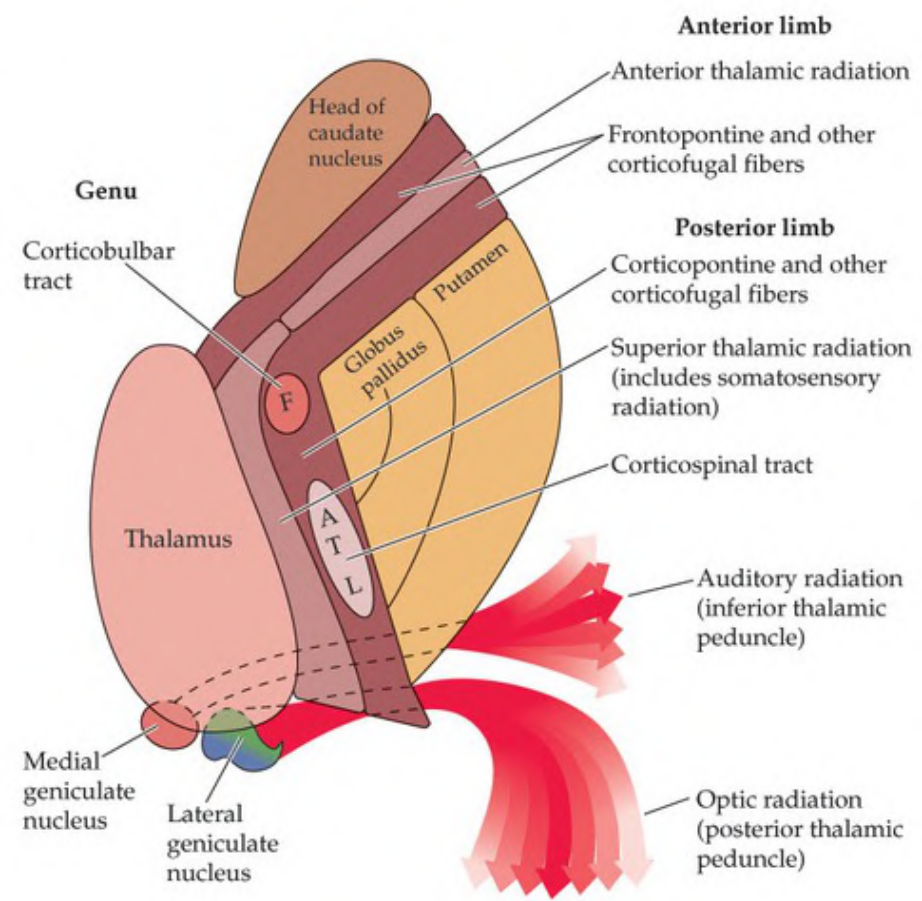






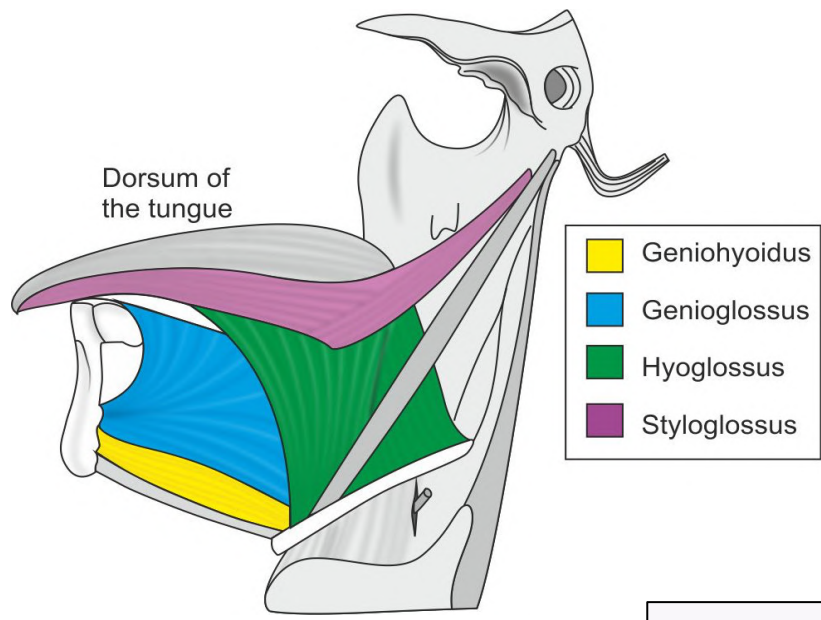
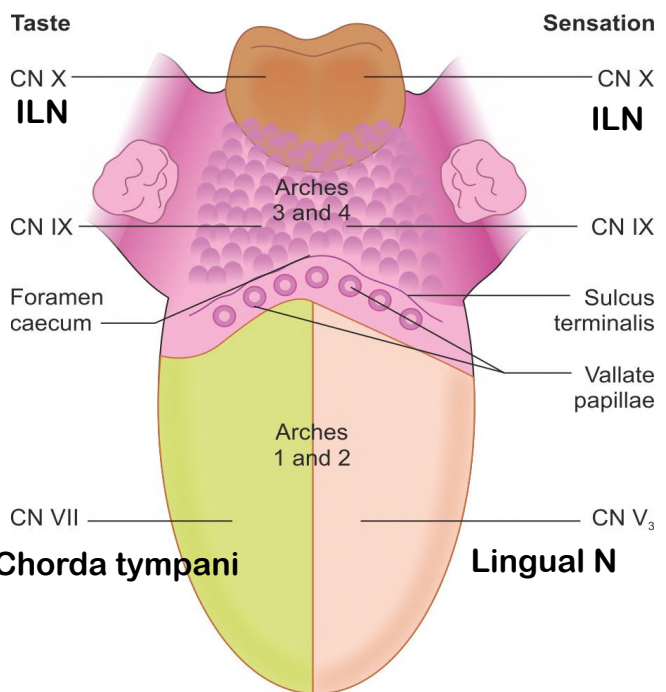
# White matter tracts

# Cranio-vertebral junction



**COMMISURAL:**  
**ASSOCIATION:**  
**PROJECTION:**  
**FORNIX:**

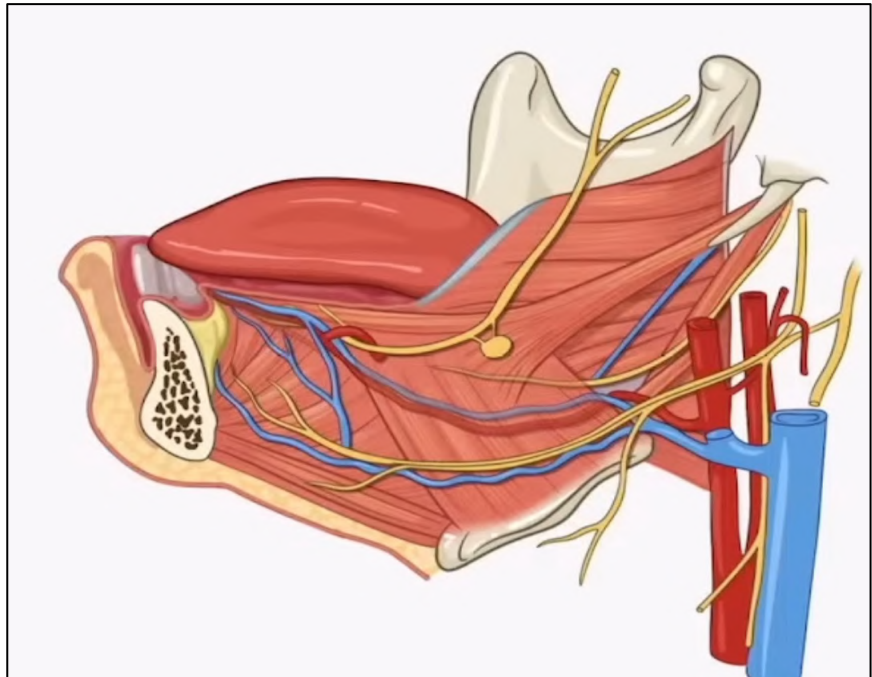
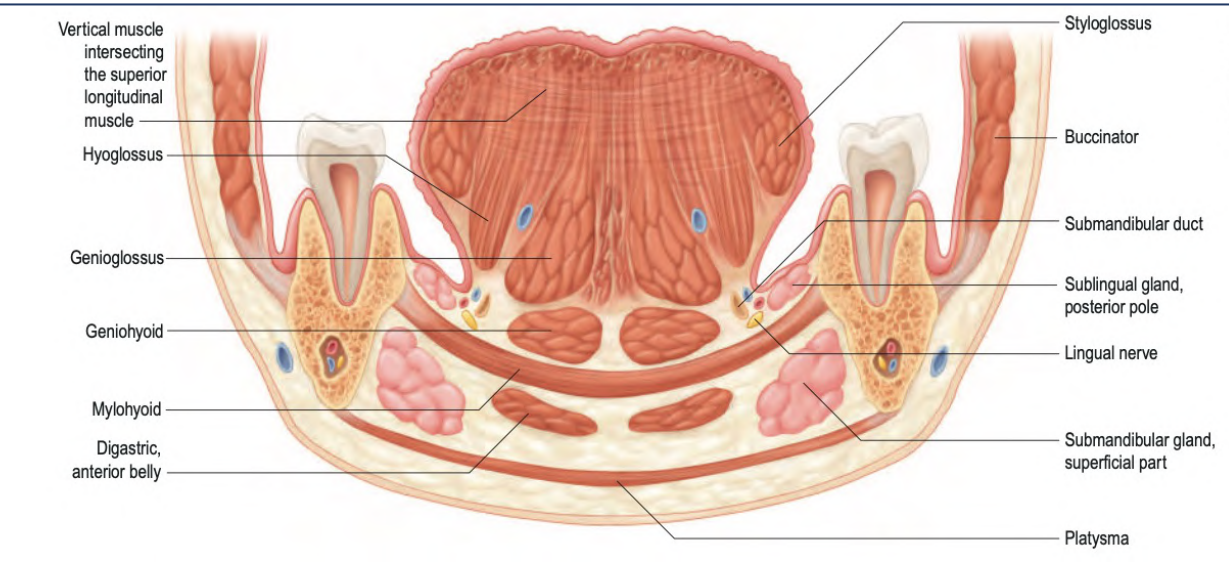
# Tongue and floor of mouth



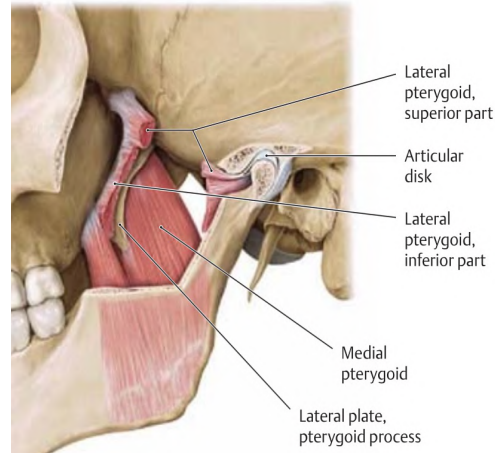
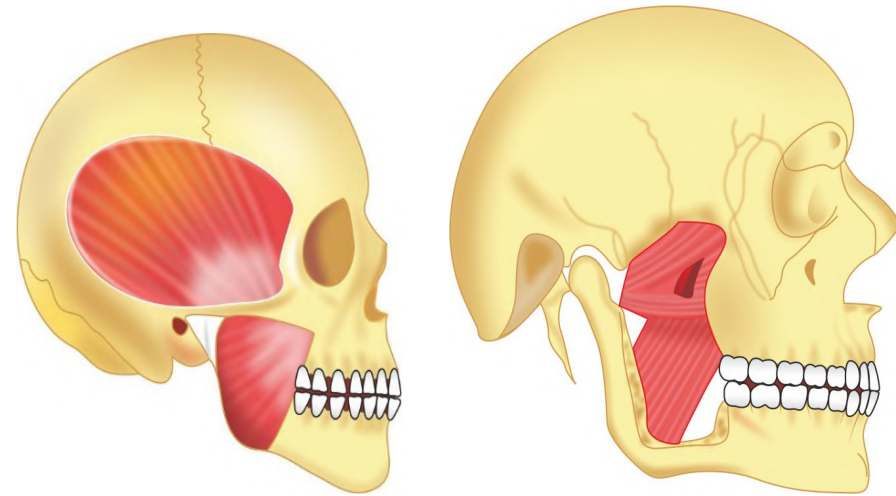
All muscles supplied by except

Safety muscle:

Depressor:



# Muscles of mastication



All muscles supplied by \_\_\_\_\_ except \_\_\_\_\_

All elevators except \_\_\_\_\_

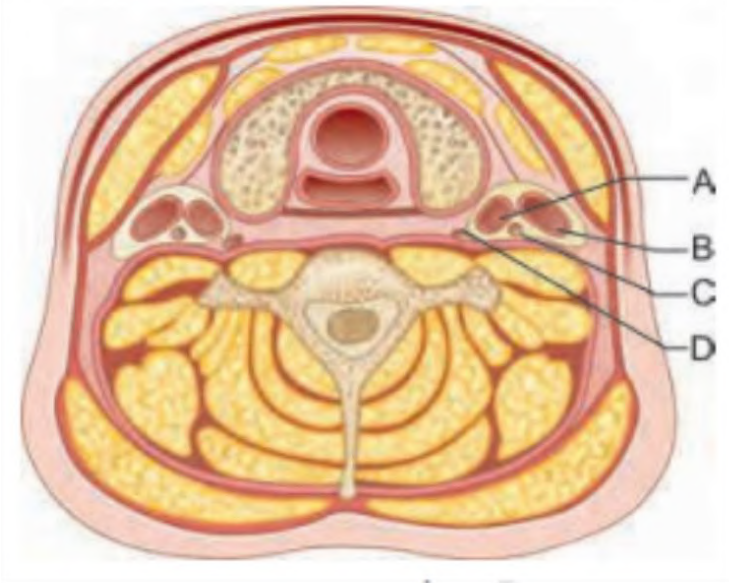
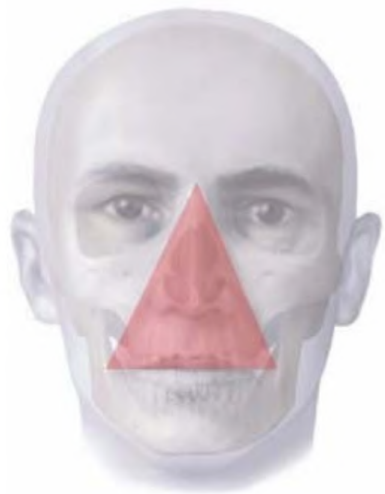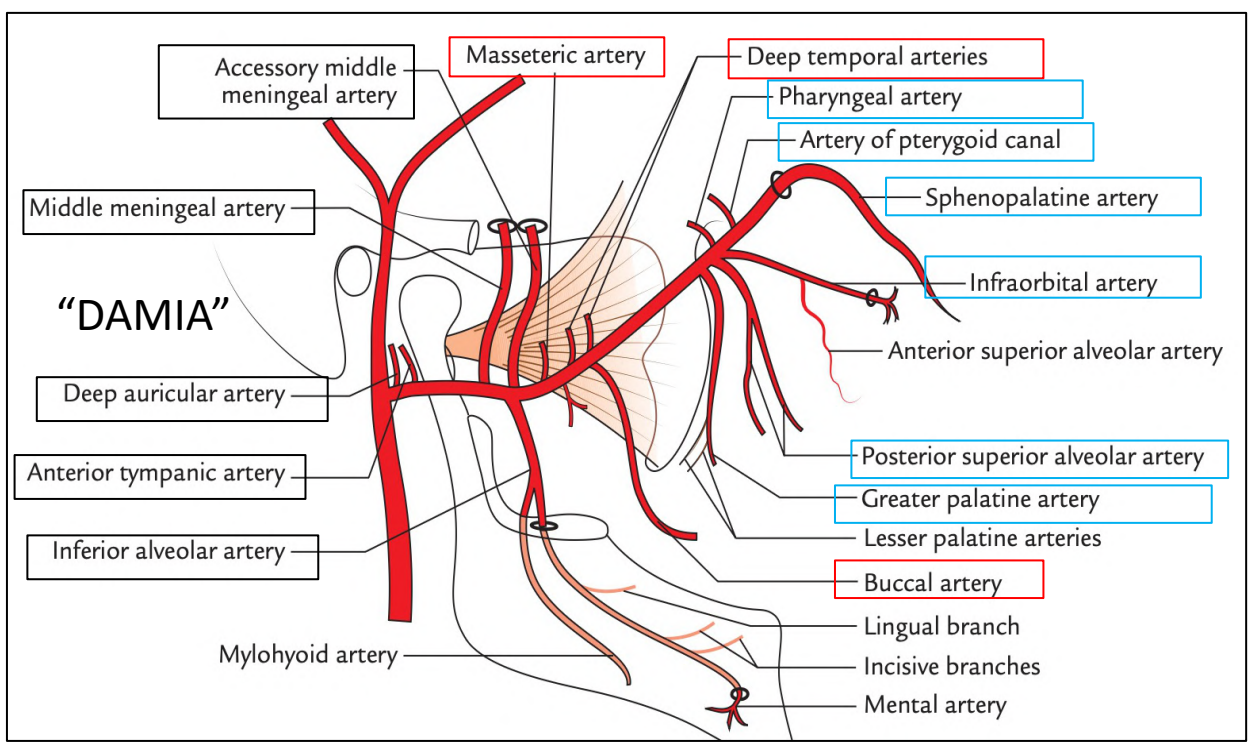
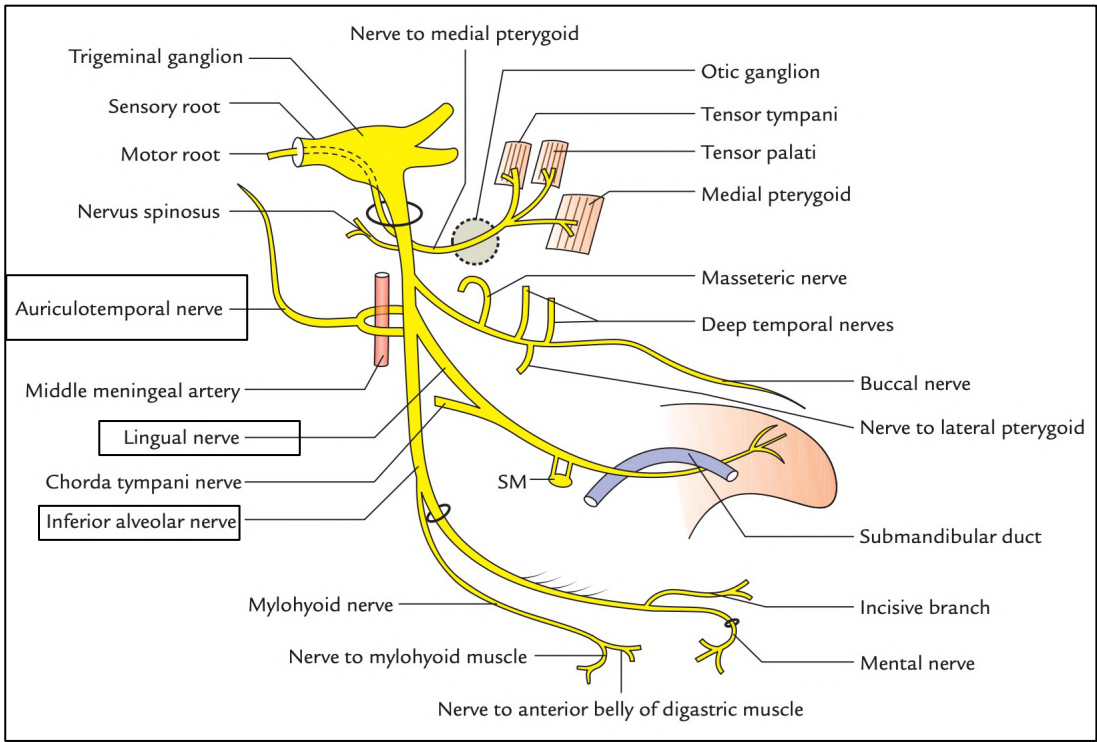
All protractors except \_\_\_\_\_  
Main protractor: \_\_\_\_\_

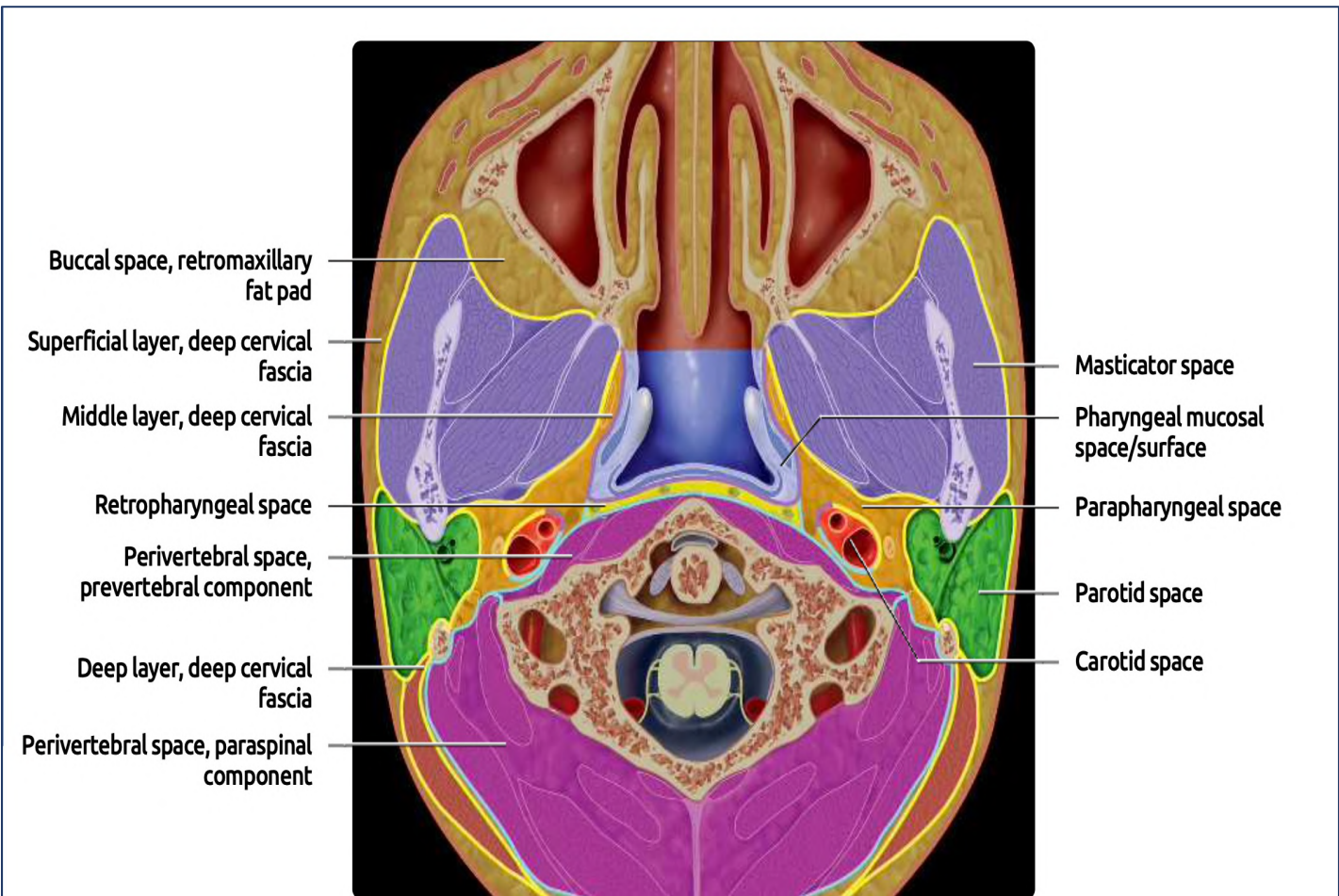
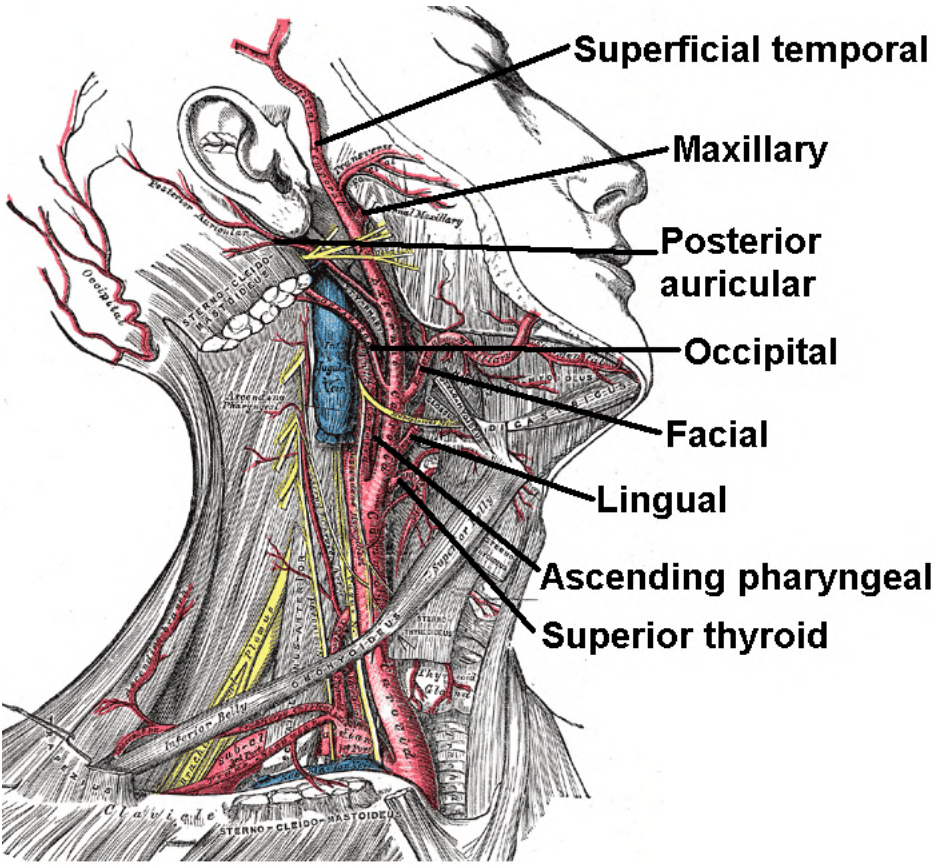
Attached to articular disc of TMJ: \_\_\_\_\_

Lock jaw: \_\_\_\_\_  
Lock jaw while yawning: \_\_\_\_\_

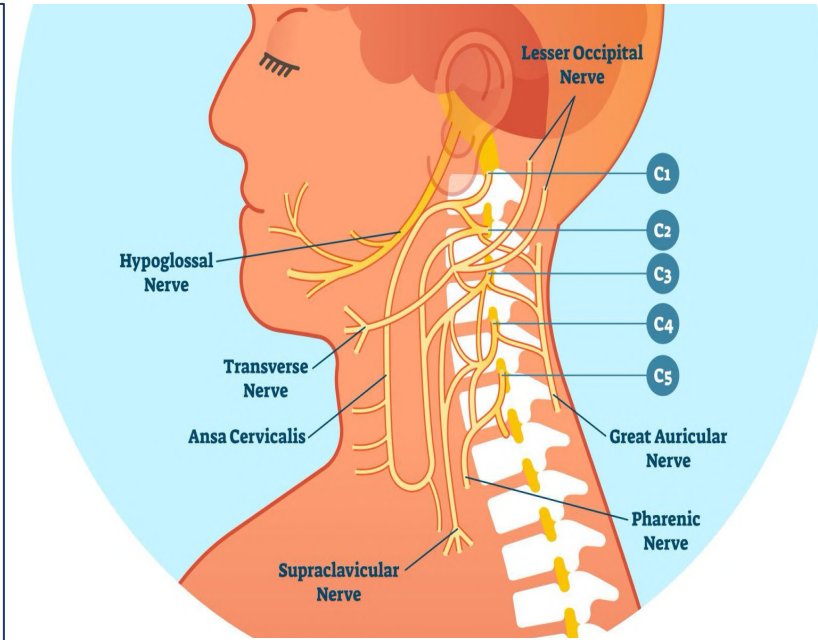
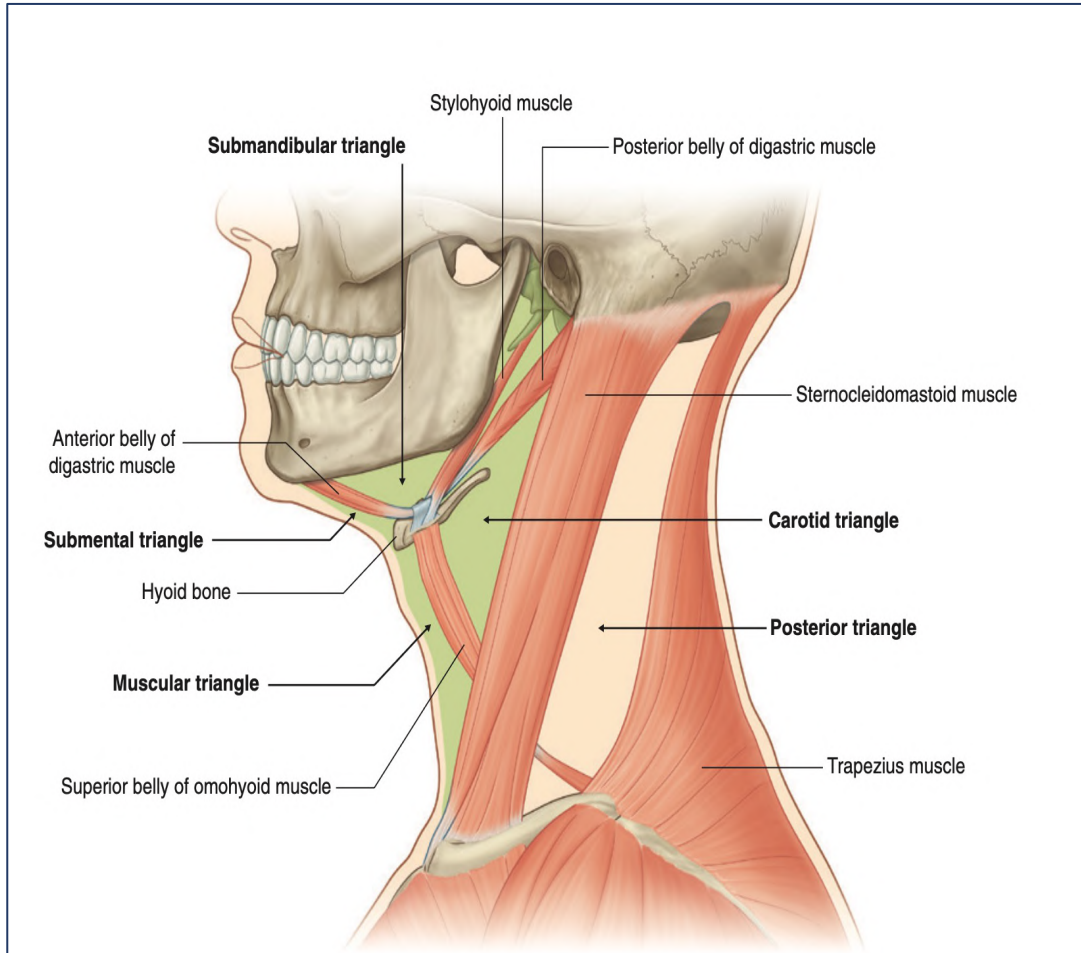
Accessory masticator muscle: \_\_\_\_\_

Structures piercing buccinator: \_\_\_\_\_

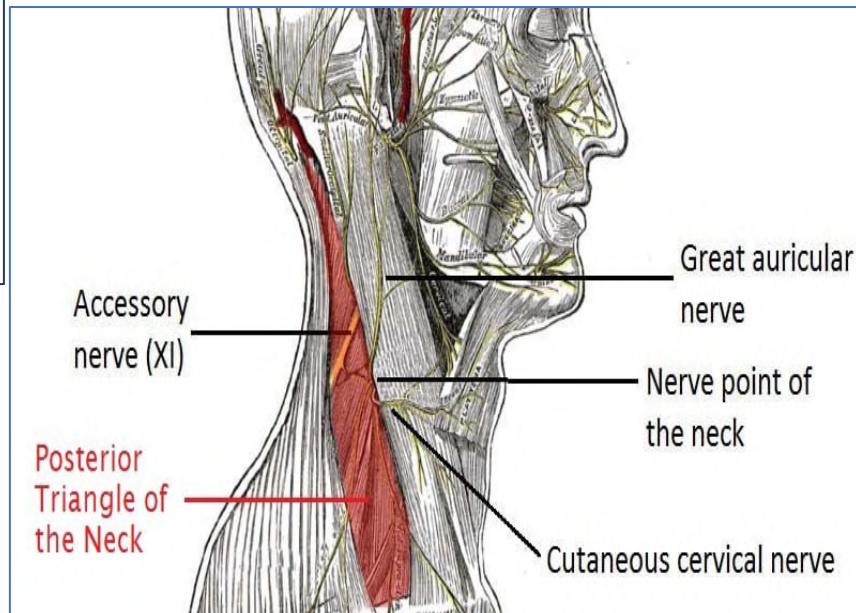
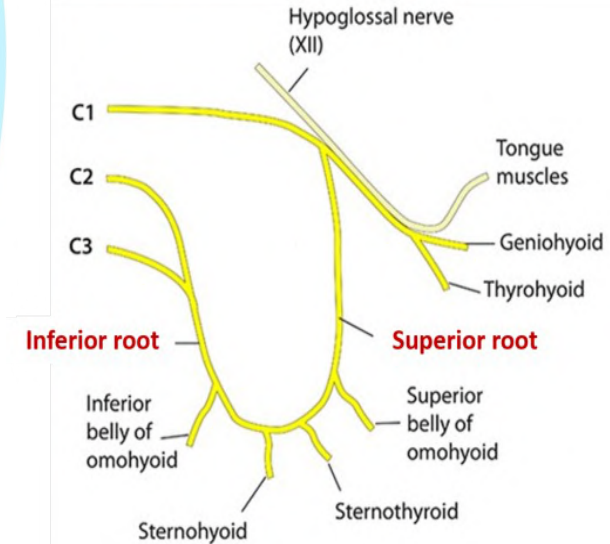




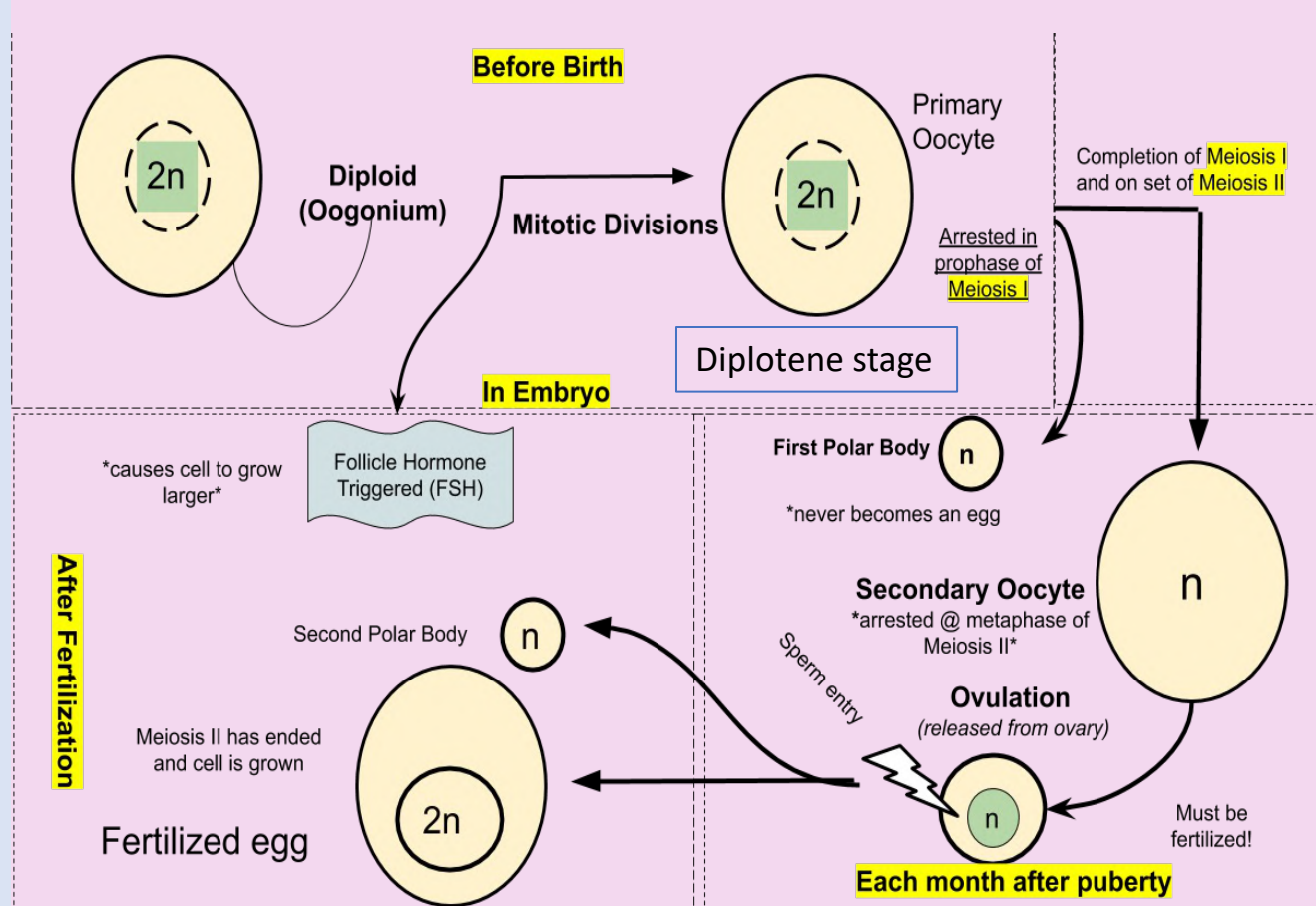
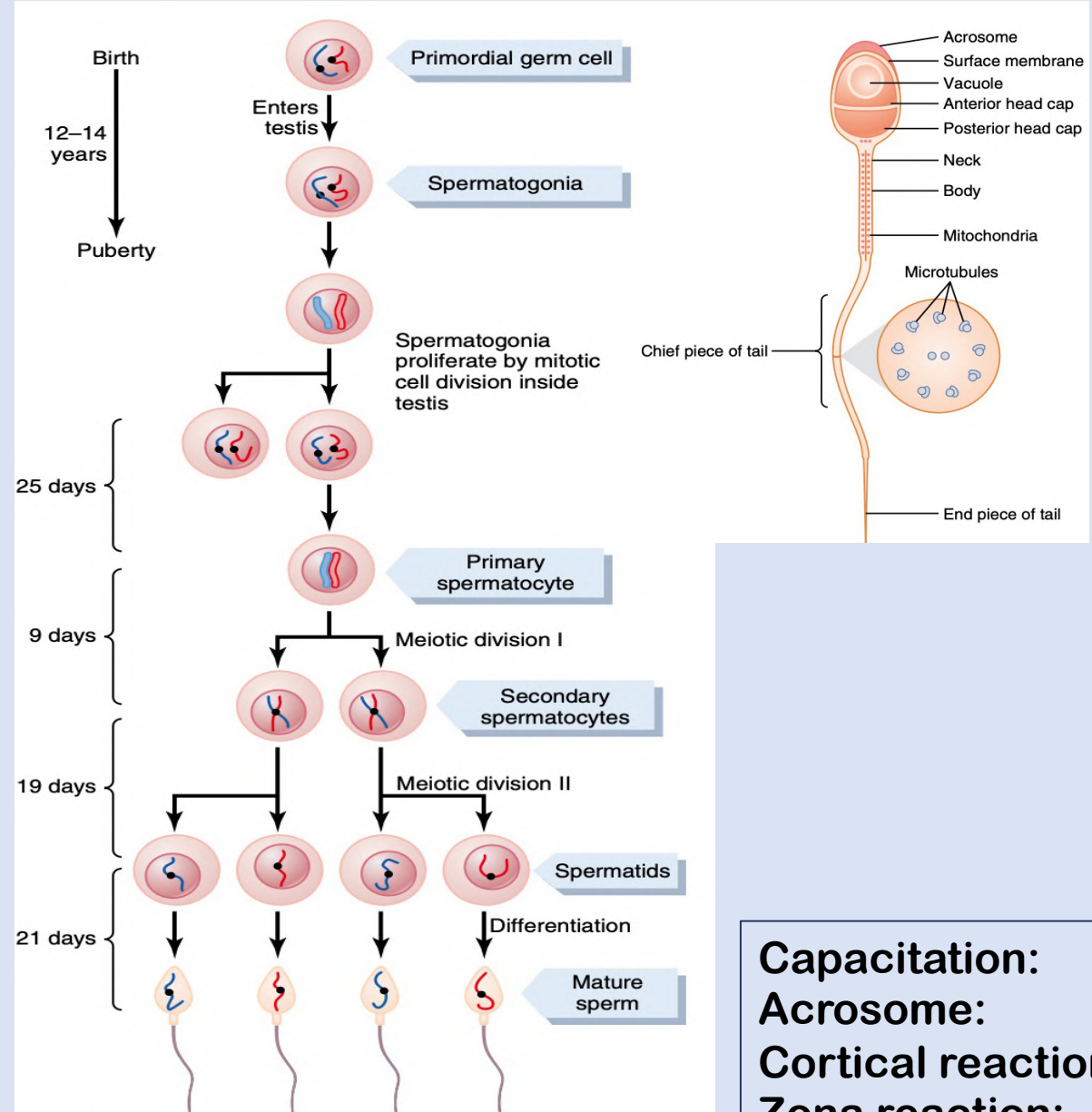
# Head and neck triangles



## Ansa cervicals

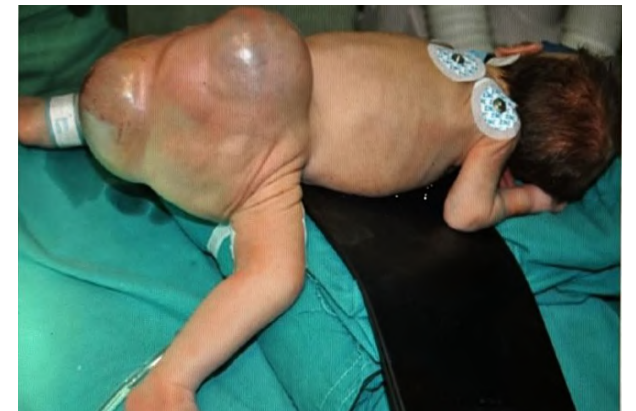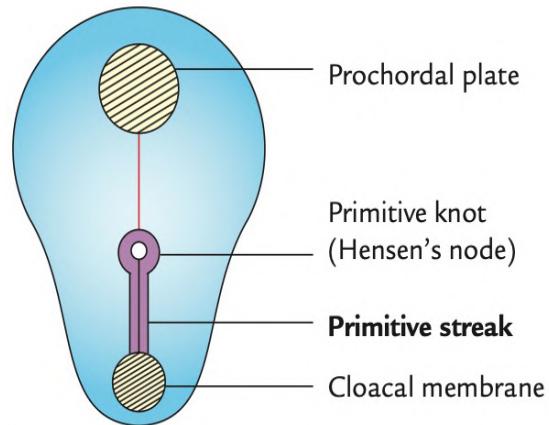
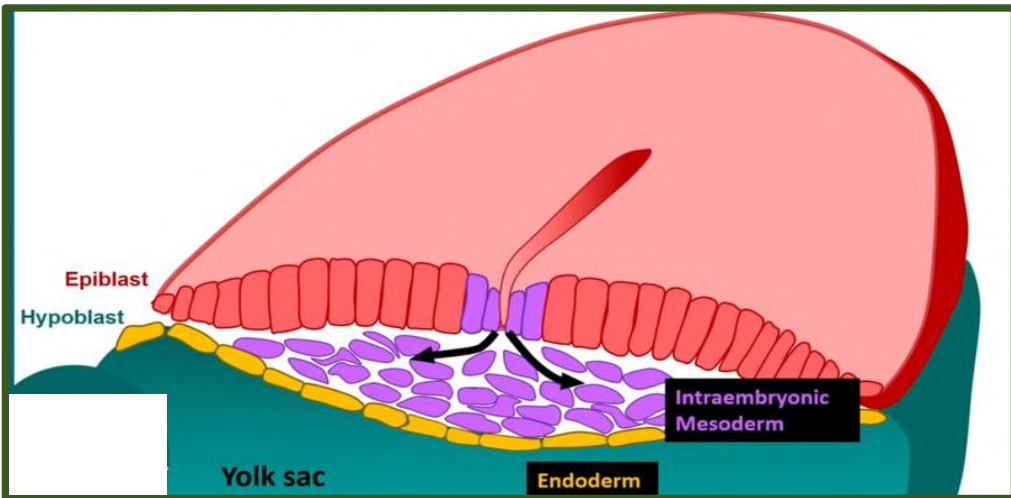
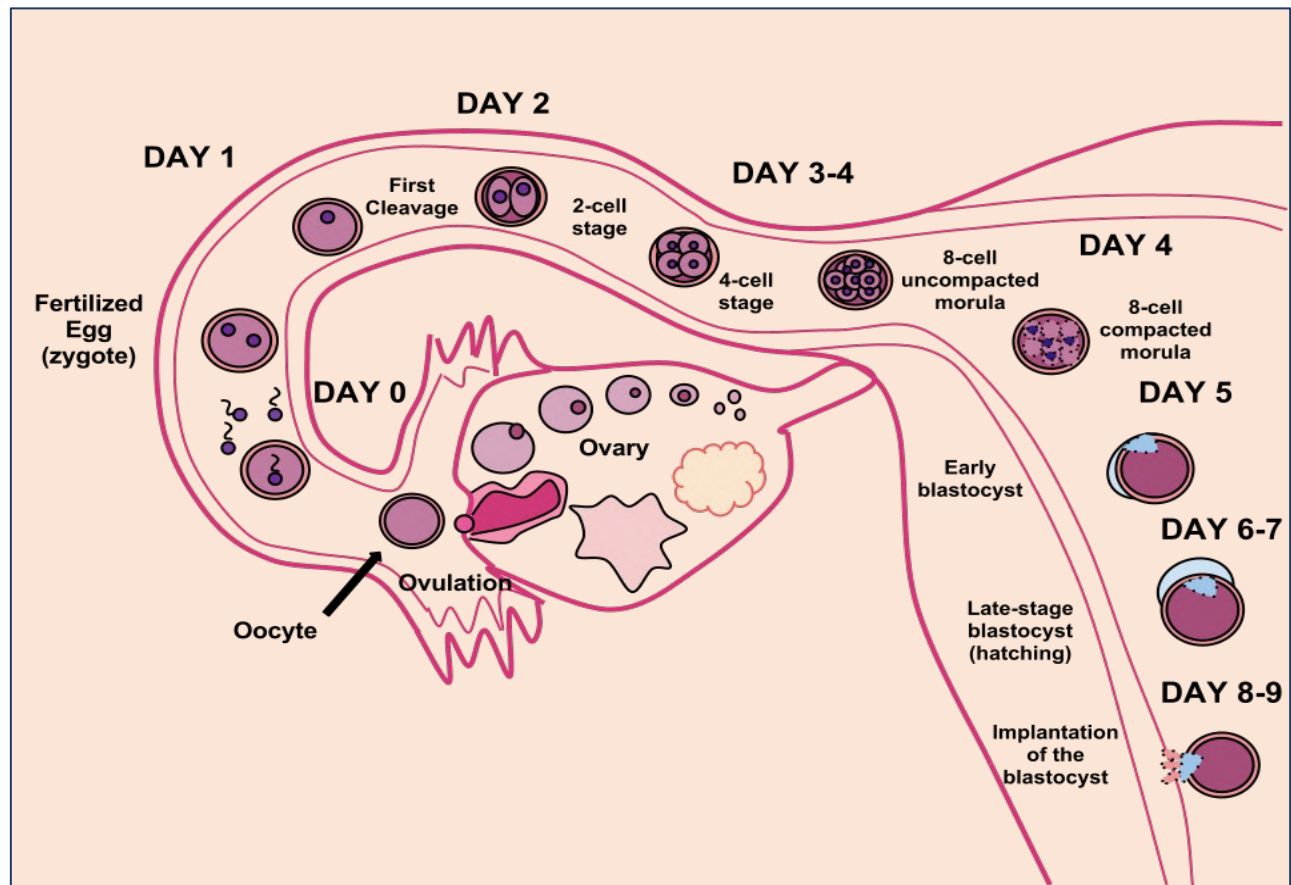


# Spermatogenesis-Oogenesis



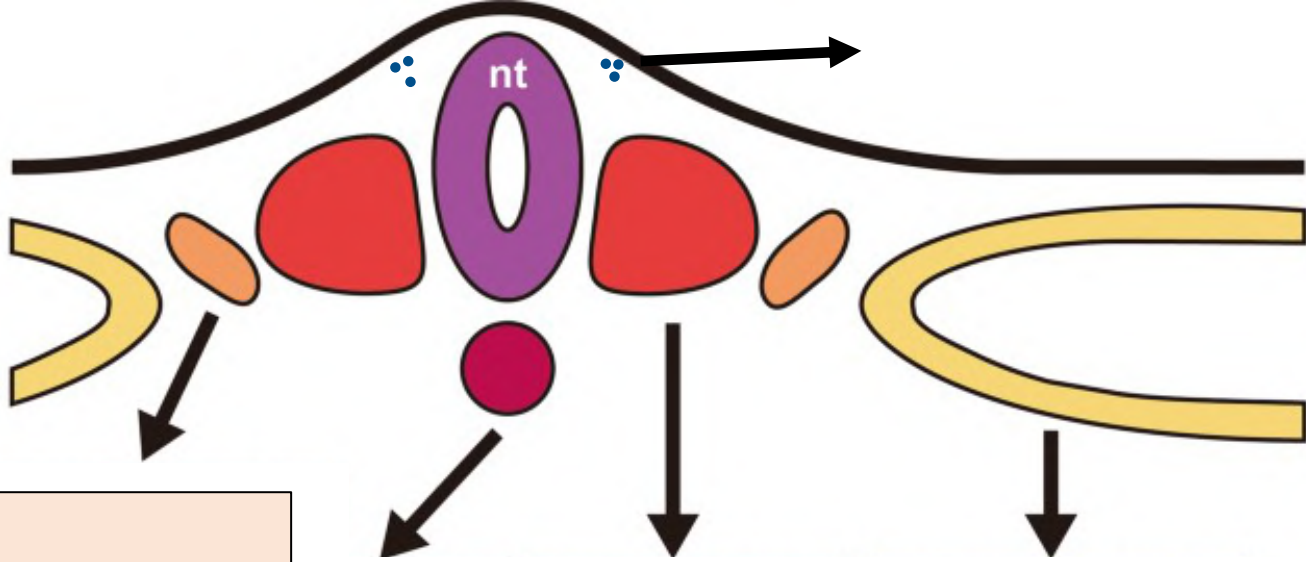
**Capacitation:**  
**Acrosome:**  
**Cortical reaction:**  
**Zona reaction:**

- Fertilisation
- Cleavage
- Compaction
- Differentiation
- Cavitation
- Hatching
- Implantation
- Bilaminar
- Gastrulation
- All layers from:



# Germ layer derivatives

NEURAL CREST  
MOTEL PASSES



GU system  
Adrenal cortex  
Gonads

Nucleus pulposus  
Tectorial membrane  
Apical ligament dens

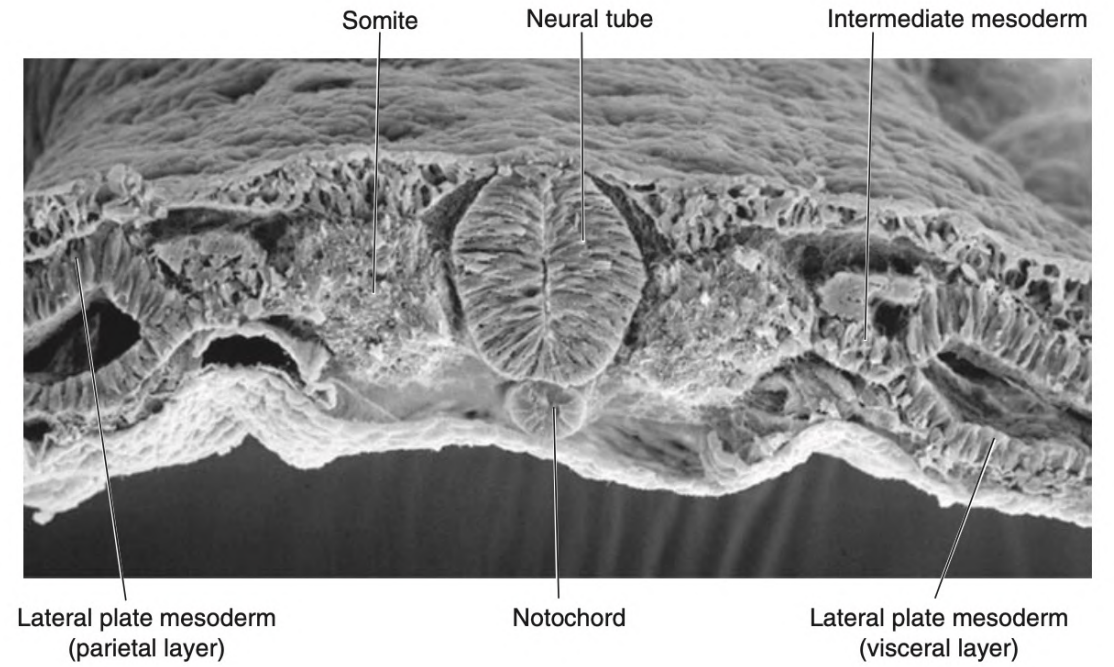
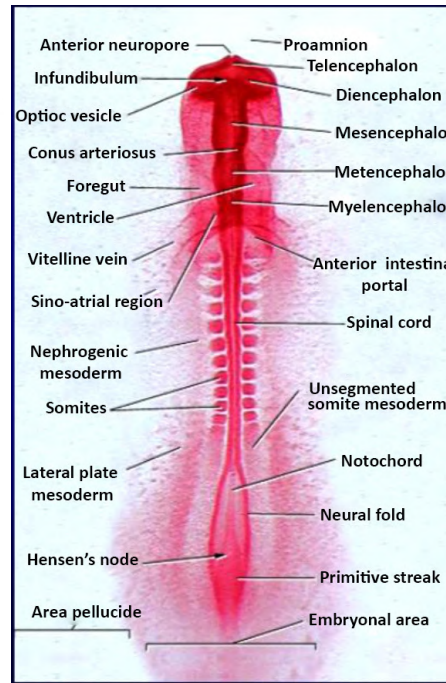
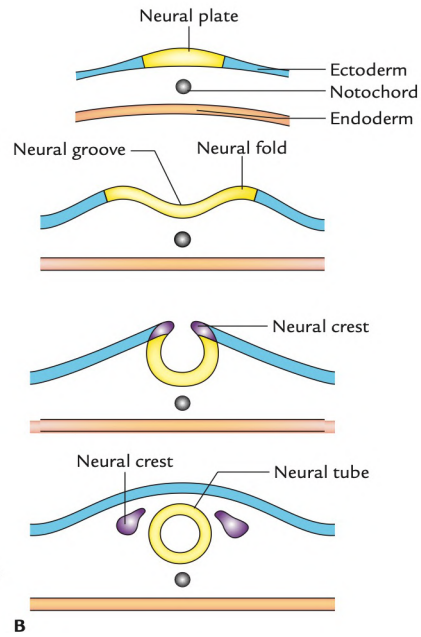
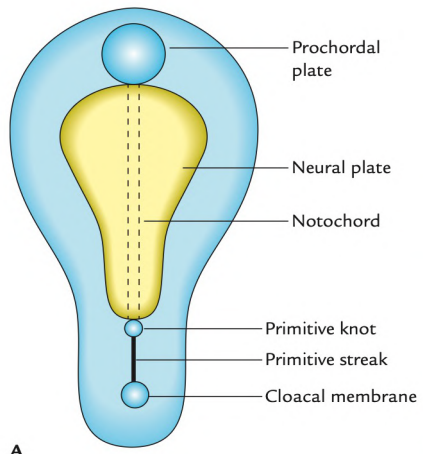
Dura  
SOMITES:  
Axial skeleton  
Dermis of back  
Skeletal muscles  
Tongue / EOM

SOMATOPLEURIC:  
Dermis of anterior torso, limbs  
Appendicular skeleton

SPLANCHNOPEURIC:  
Cardiac muscles  
Smooth Muscles  
RES-Spleen, Microglia  
Serosa, endothelium

Adrenal cortex-  
Adrenal medulla-

Dura-  
Leptomeninges-



# Surface ectoderm

**Enamel/ Ameloblast-  
Dentin/Odontoblast-**

Pituitary

EYE

EAR


GLANDS  
PSM

ANAL CANAL

EPIDERMIS,  
OLFACTORY  
EPITHELIUM,  
ENAMEL

# Neuroectoderm

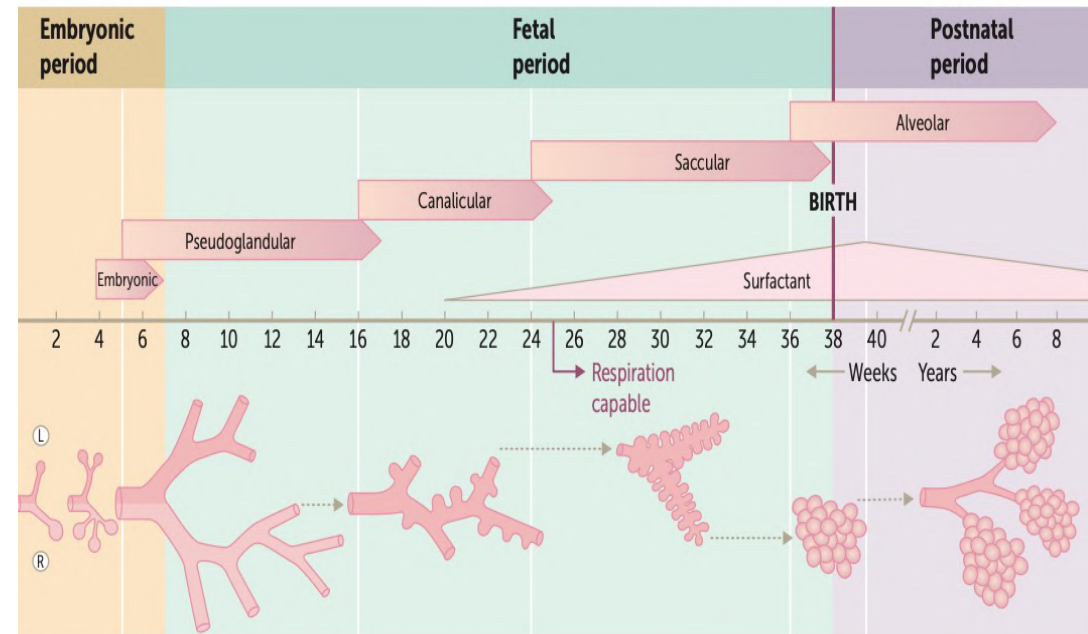
**Endoderm:  
Abdomen except spleen  
Urogenital sinus**



GLAND

Pituitary

EYE



# Urogenital system

## MESONEPHRIC DUCT=

Caudal end-Ureteric bud:

Males:

Females:

P  
E  
G

VS Gartner duct cyst-

## PARAMESONEPHRIC DUCT=

Males:

Females:

## Urinary system

Kidney (Till DCT)

Collecting system-

Trigone, post wall of urethra-

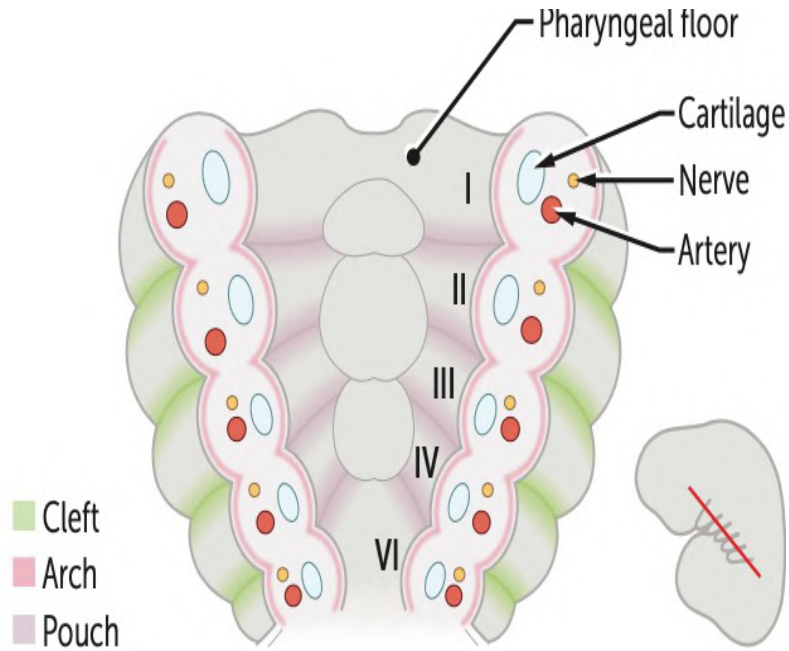
UB-

Urethra-

Prostate-

Structure	Male derivative	Female derivative
Genital tubercle	Glans Penis	Clitoris
Genital fold	Ventral shaft of penis	Labia minora
Genital swelling	Scrotum	Labia majora
Genital ridge	Testes	Ovary

# Pharyngeal cleft-pouch derivatives



Cleft	Adult derivatives
1 <sup>st</sup>	External auditory meatus, tympanic membrane
2 <sup>nd</sup> – 4 <sup>th</sup>	Cervical sinus- obliterates; Persist as Brachial cyst/sinus

Pouch	Adult derivatives
1 <sup>st</sup>	Middle ear cavity, Eustachian tube, Mastoid, Tympanic membrane
2 <sup>nd</sup>	Epithelial lining of crypts of palatine tonsil; including crypta magna
3 <sup>rd</sup>	Thymus, Inferior parathyroid glands
4 <sup>th</sup>	Superior parathyroid glands Ultimobranchial body (5 <sup>th</sup> remnant)

All tongue muscles supplied by  
 All palatal muscles supplied by  
 All pharyngeal muscles supplied by  
 All laryngeal muscles supplied by

except  
 except  
 except  
 except

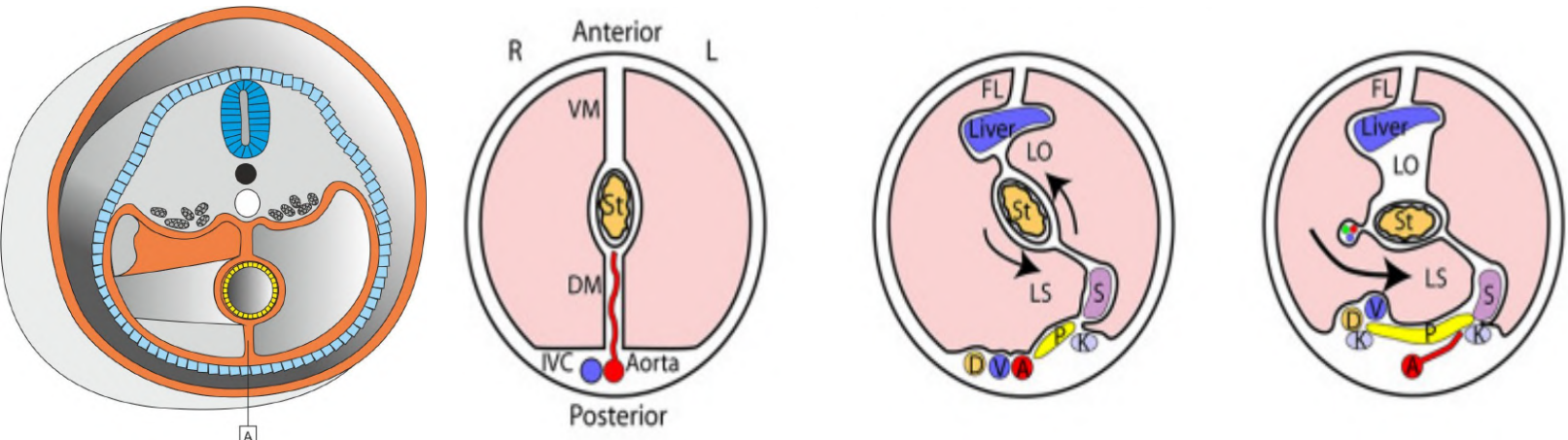
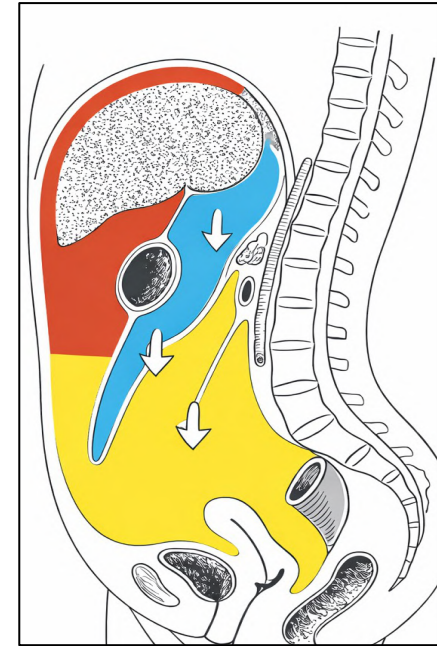
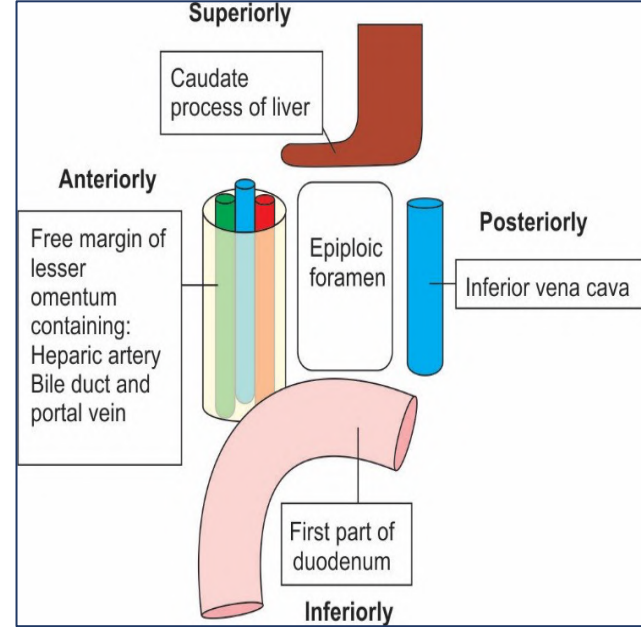
# Pharyngeal arch derivatives

Pharyngeal arch	Bones	Muscles	Nerve	Artery
1 <sup>st</sup>	Meckel's cartilage, Maxilla, Mandible, Malleus and incus, zygomatic bone, sphenomandibular ligament	Muscles of mastication, Mylohyoid, Anterior belly of digastric, Tensor veli palatini,	V3	Maxillary artery
2 <sup>nd</sup>	Reichert's cartilage Stapes ( <b>Except Footplate-Otic capsule</b> ), Styloid process, Lesser horn/ Sup body of hyoid bone, Stylohyoid ligament	Muscles of facial expression, Stylohyoid, Stapedius, Buccinator, Platysma, Posterior belly of digastric	VII	Stapedial artery
3 <sup>rd</sup>	Hyoid bone (Inferior Body and greater horn)	<b>Stylopharyngeus</b>	IX	Common carotid and internal carotid
4 <sup>th</sup>	Laryngeal cartilages (except epiglottis-hypobranchial eminence)	Cricothyroid, Levator palatini, Pharyngeal constrictors	Vagus nerve (X) Superior Laryngeal nerve	Left: Aortic arch Right: Proximal right subclavian artery (+ 7 <sup>TH</sup> intersegmental artery + Dorsal Aorta)
6 <sup>th</sup>		All intrinsic muscles of larynx (except cricothyroid) <b>Cricopharyngeus</b>	Vagus nerve (X) Recurrent laryngeal nerve	PA DA

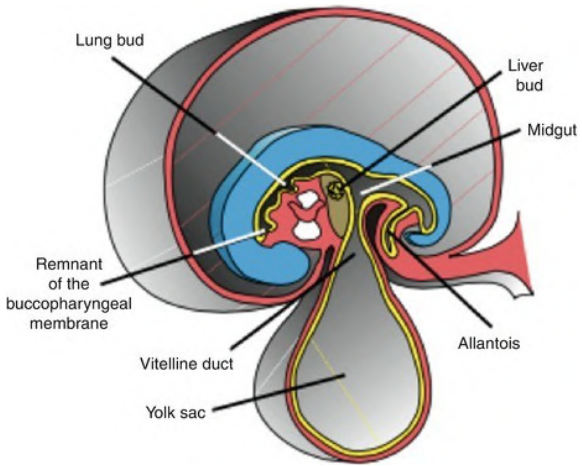
# Miscellaneous

Ventral mesentery derivatives	Dorsal mesentery derivatives
Lesser omentum Hepatogastric- Hepatoduodenal - Falciform ligament -	Greater omentum
Triangular ligament of liver	Gastrosplenic ligament-
Coronary ligament of liver	Lienorenal ligament-
	Gastrophrenic ligament
	Mesentery of SI, mesoappendix
	Transverse/ sigmoid mesocolon

Prevents descent of spleen:



- Lesser sac: Anterior Boundary: Lesser omentum, stomach, gastrocolic ligament (ant GO)
- Posterior Boundary: Post GO, Pancreas, upper left kidney, left adrenal gland, and the diaphragm



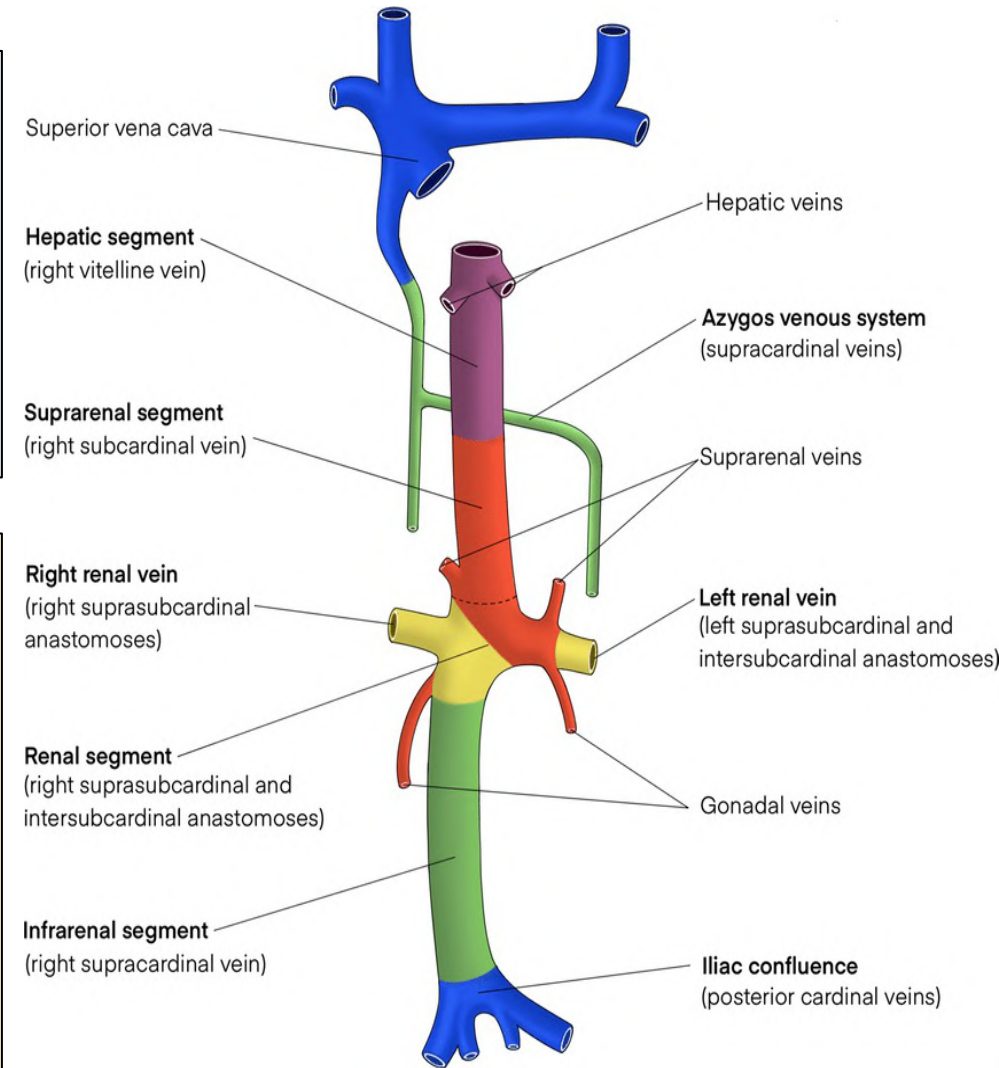
## UMBILICAL LIGAMENTS

**MEDIAN-  
Umbilical artery**

**Proximal:**

**Distal:**

**LATERAL-  
Left Umbilical vein-**



**Supracardinal Vein:**

**Subcardinal Vein:**

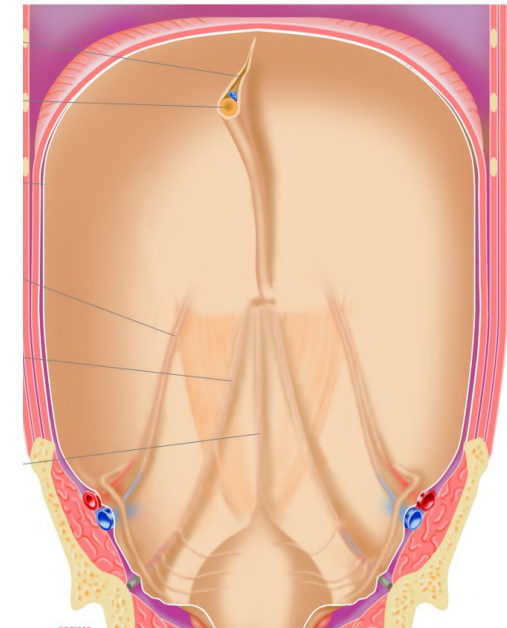
**Sub-Supracardinal Anastomosis:**

**Posterior cardinal veins:**

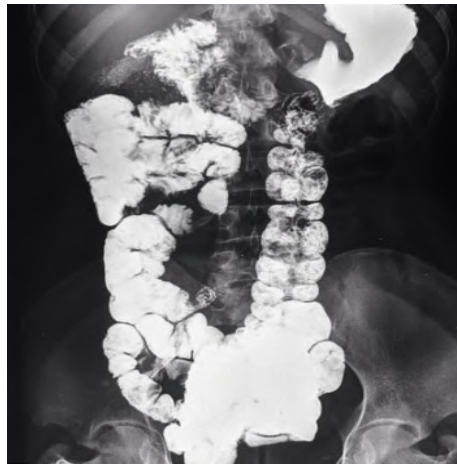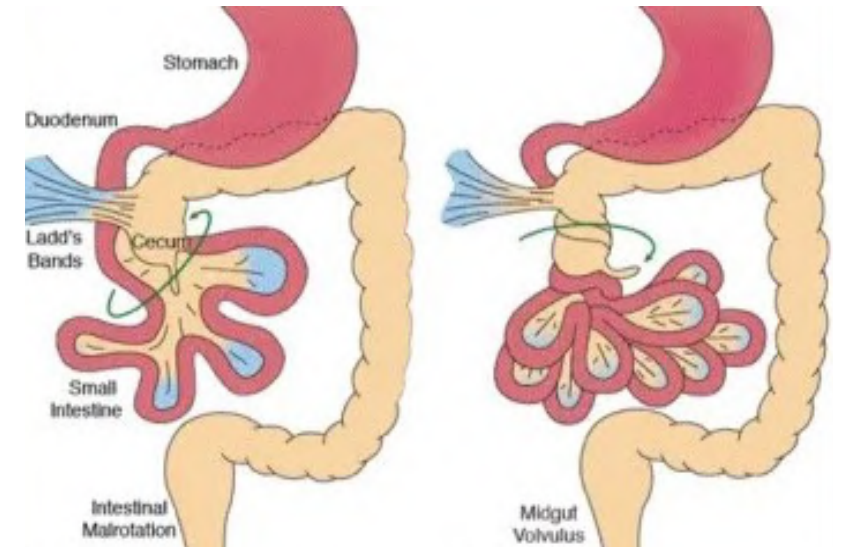
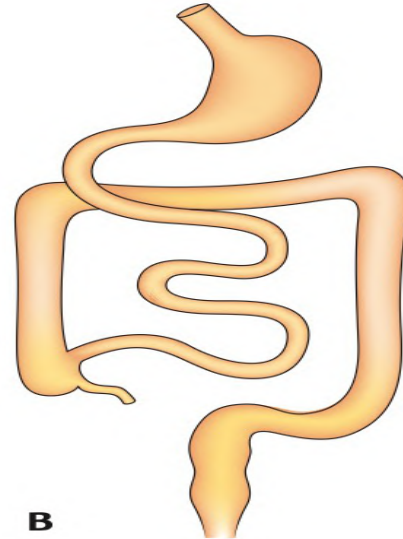
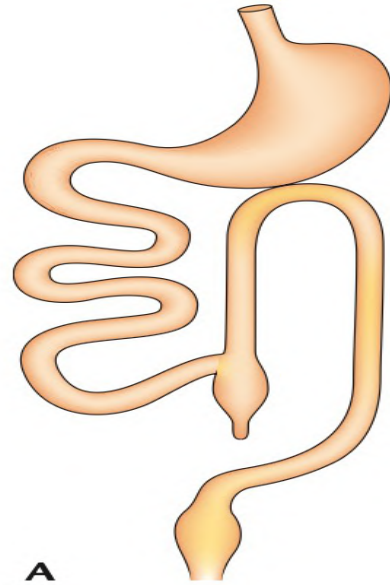
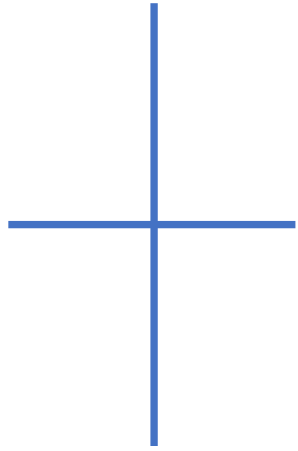
**Anterior cardinal veins:**

**Rt CCV + Rt ACV:**

**Vitelline vein:**

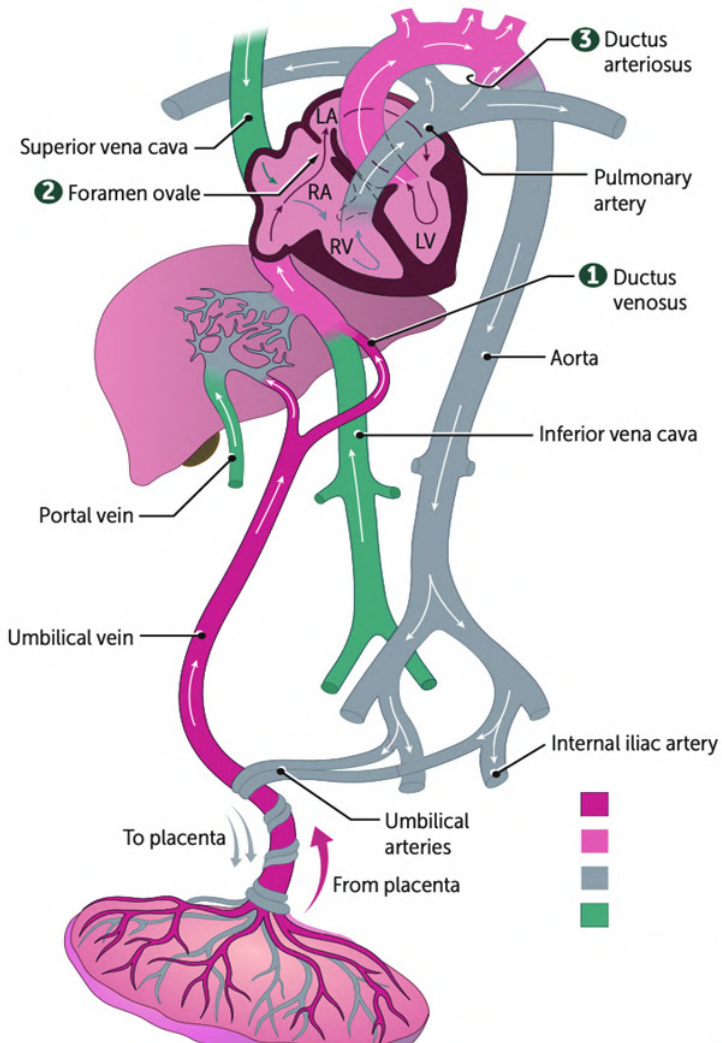


# Gut rotation - Malrotation

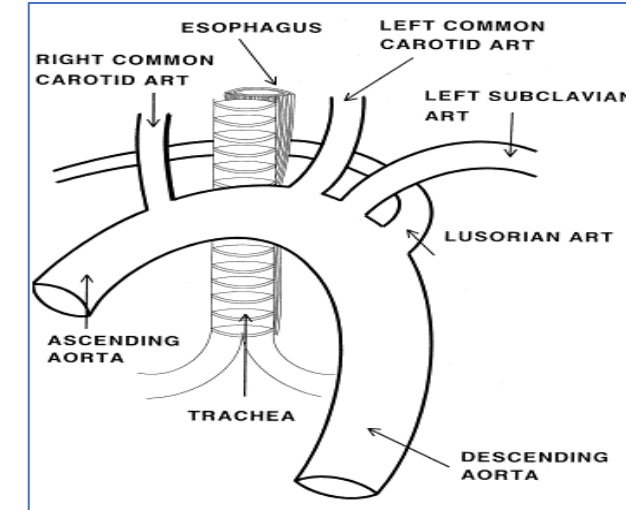


Incomplete rotation:

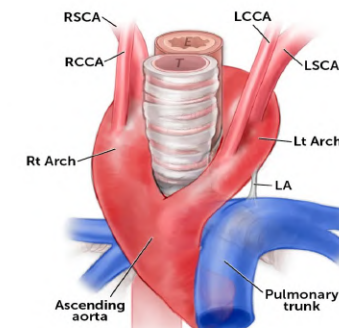
# Fetal circulation



Changes After Birth: Closing of Shunts		
Shunt	Functional closure	Anatomical closure
Ductus arteriosus	2-3d (10-15hrs)	2 – 3 wks
Foramen ovale	Within mins	One year
Ductus venosus	Within mins	3 – 7 days

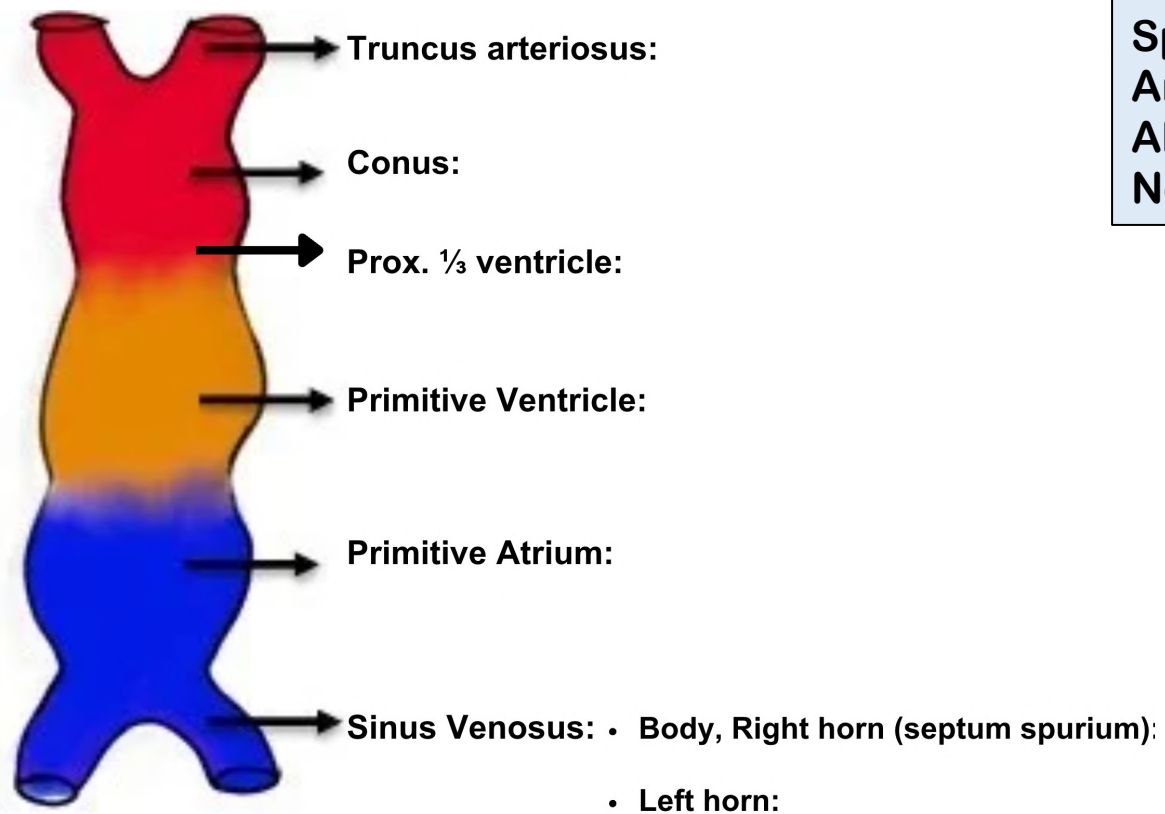


**Obliteration of R 4th arch A + Persistence of caudal part of R dorsal aorta**

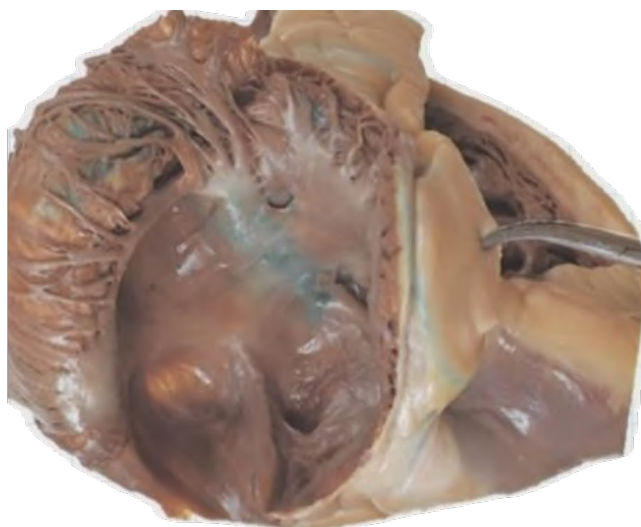


**Persistence of R 4th arch A + caudal part of R dorsal aorta**

# Heart-embryology

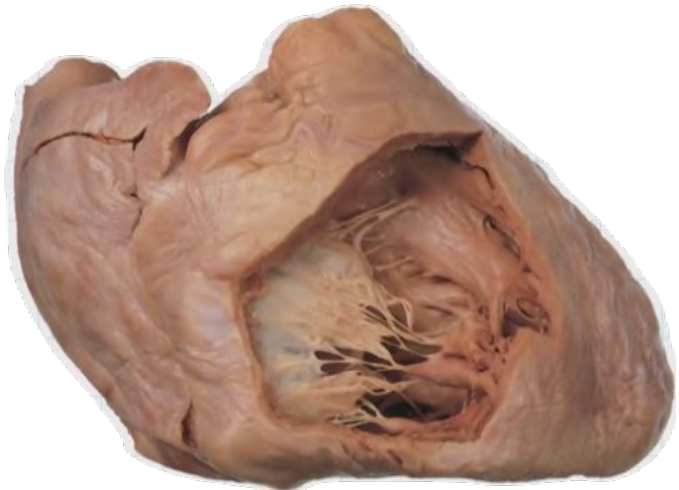



Spiral septum:  
 Anterior:  
 Absence:  
 Non-spiral:

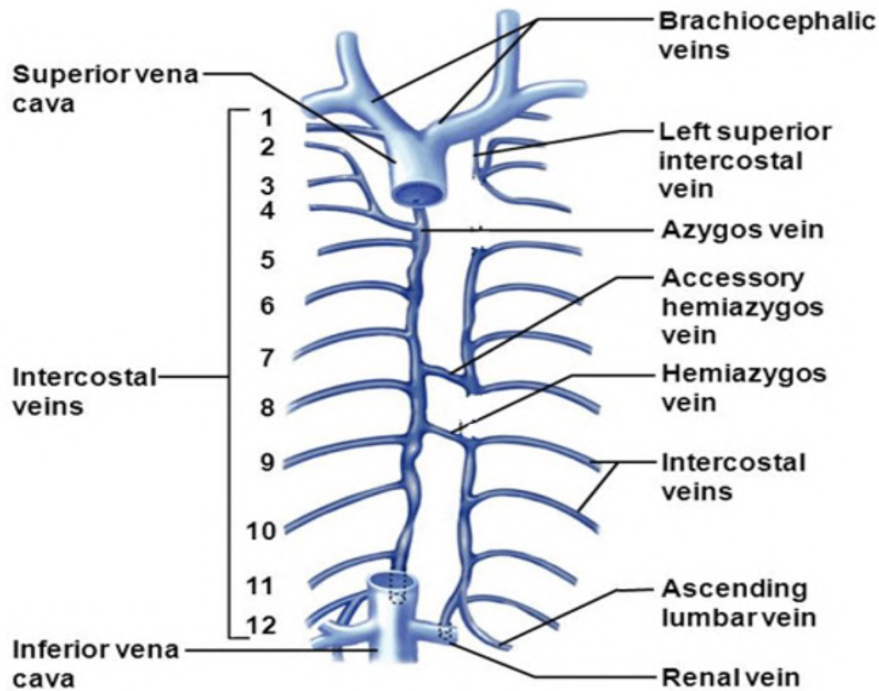


**Triangle of Koch**  
 1. Tricuspid Septal leaflet  
 2. Tendon of Todaro  
 3. Ostium of CS

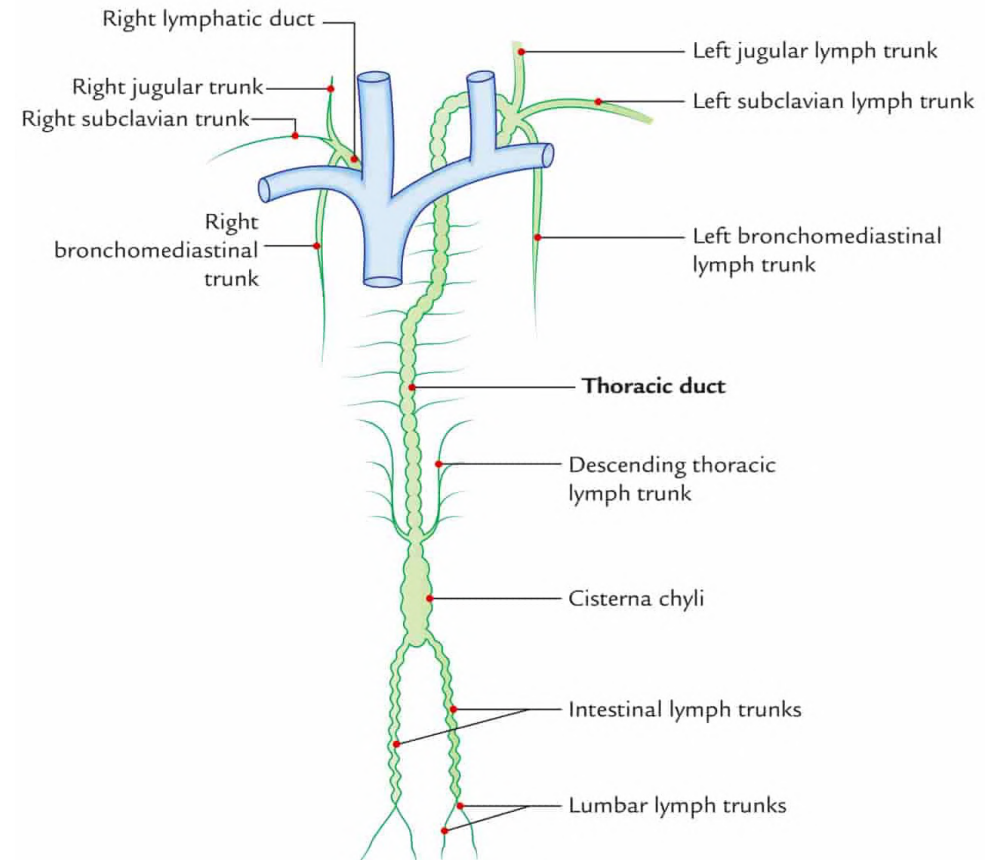
## Primitive pulmonary vein:



# Azygos vein



# Thoracic duct

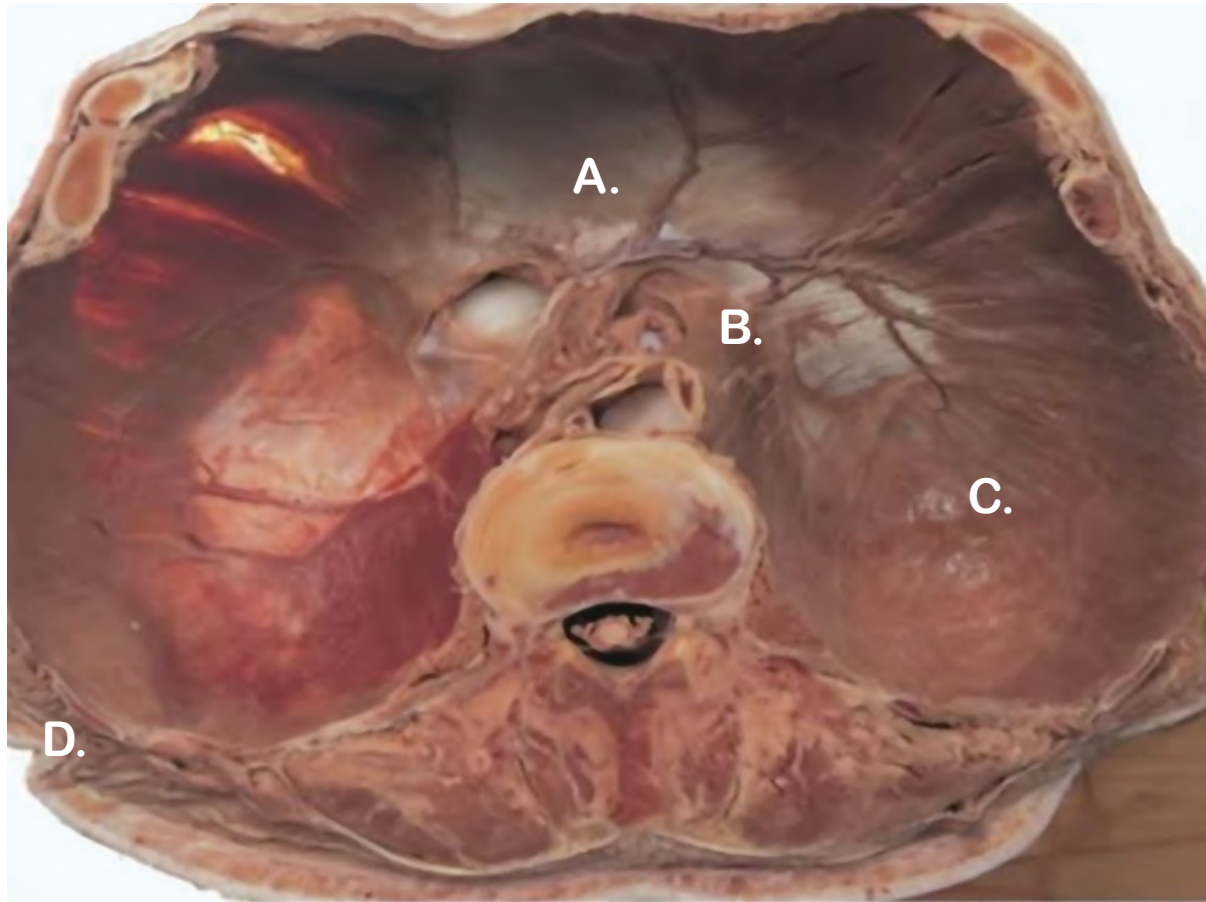


**Formed by:** Right Lumbar azygos, right subcostal, right ascending lumbar  
**Tributaries:**  
Right superior intercostal vein: 2,3,4 PICV  
Right 5-11<sup>th</sup> PICV  
Hemiazygos, Accessory hemiazygos-T8  
T4->SVC

**Formed by:** left Lumbar azygos, left subcostal, left ascending lumbar  
**Tributaries:** Left 9-11<sup>th</sup> PICV

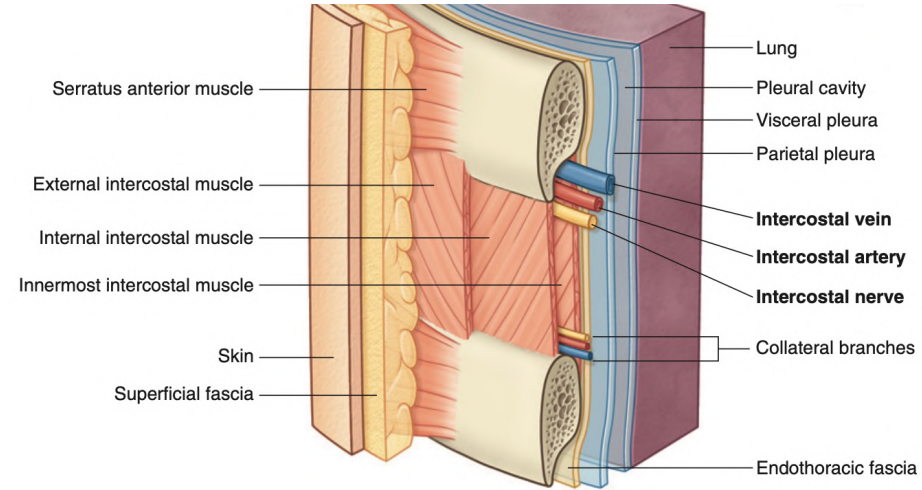
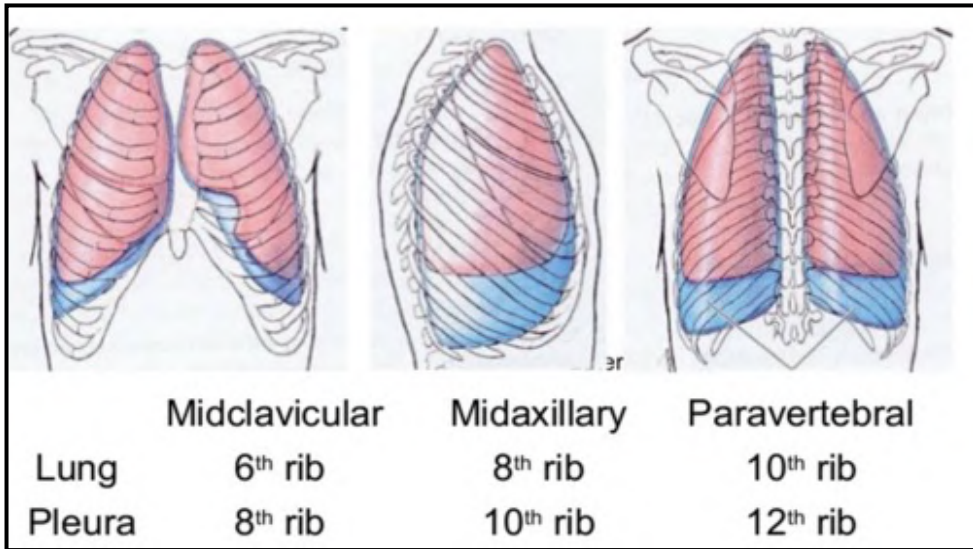
**Tributaries:** Left 5-8<sup>h</sup> PICV

# Diaphragm



Space of Larrey = Foramen of Morgagni	Superior epigastric vessels
Behind lateral arcuate ligament	Subcostal vessels and nerve
Behind medial arcuate ligament	Sympathetic nerve
Piercing each crus	Greater and lesser splanchnic nerves

# Thorax anatomy



**Intercostal space VAN except:**

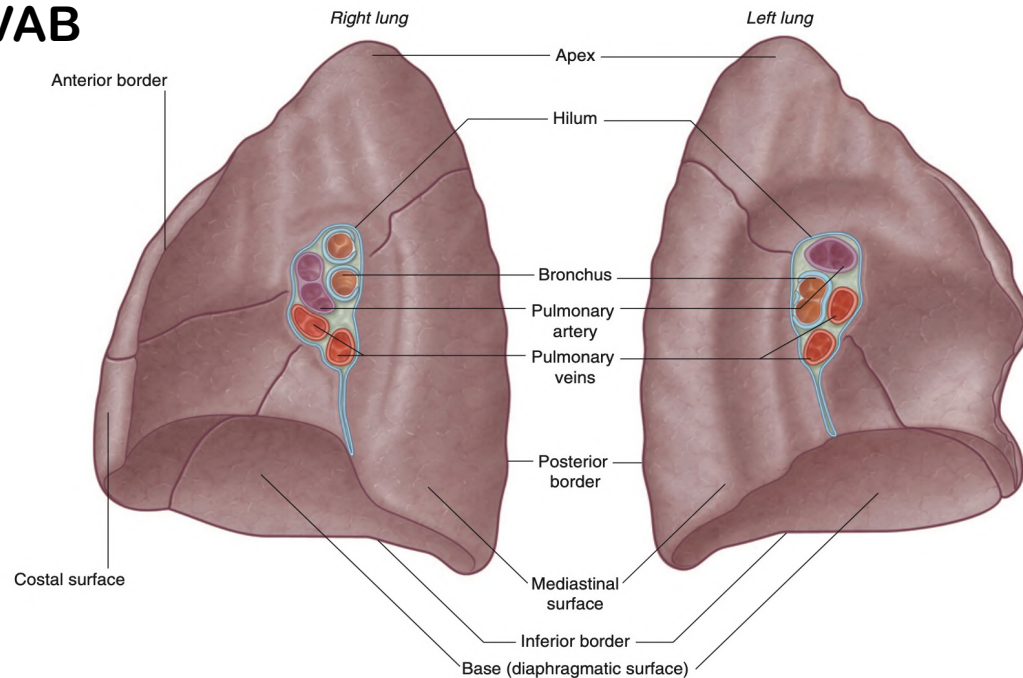
**Bronchopulmonary segments:**

**Pericardial sinuses:**

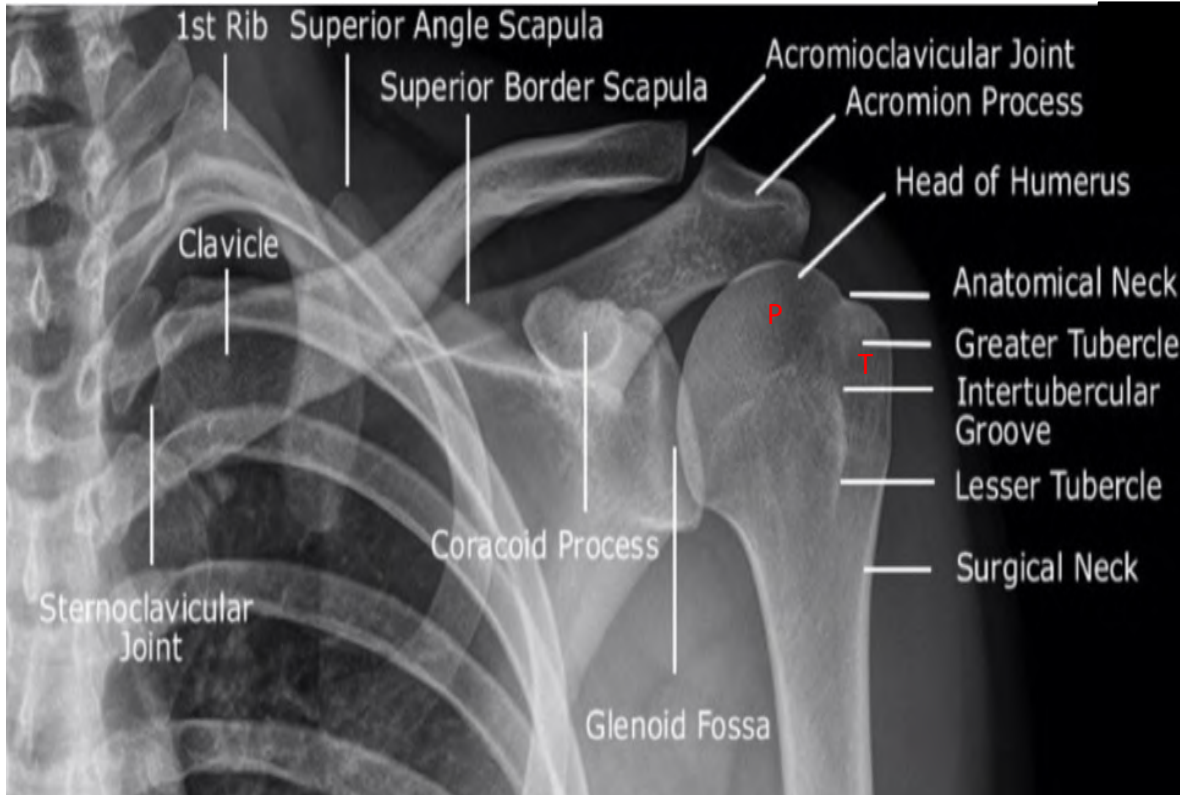
**Transverse:**

**Oblique:**

## VAB



# Upper Limb



## CORACOID

Type of epiphyses:

Origin: Short head of biceps, Coracobrachialis

Insertion: P.minor

GT:

S

I

T

LT:

Intertubercular groove:

Pmj

LD

Tmj

## Clavipectoral fascia

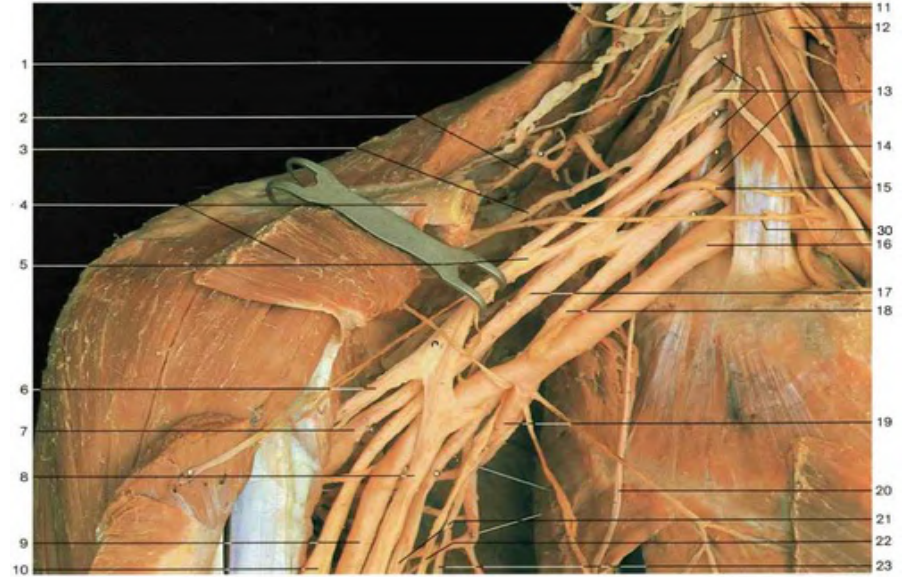
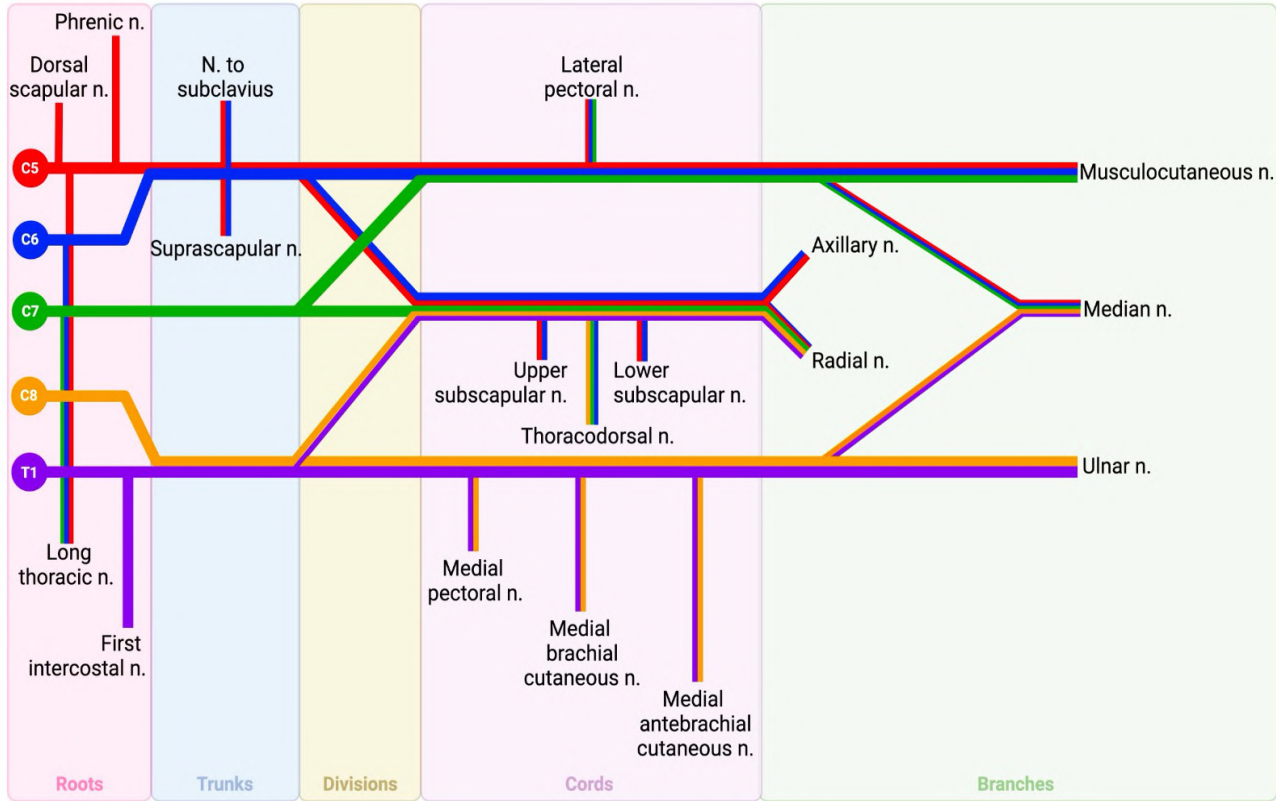
Encloses subclavius and P.minor

Peirce P.minor:

## Types of epiphysis

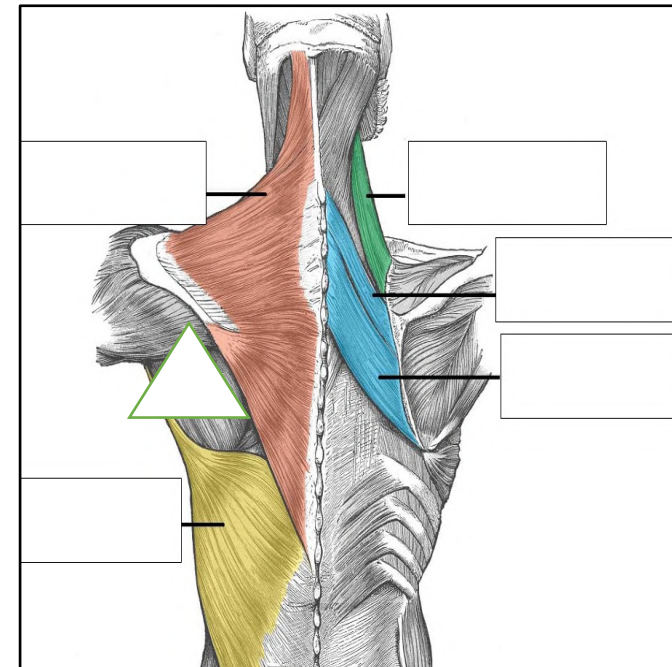
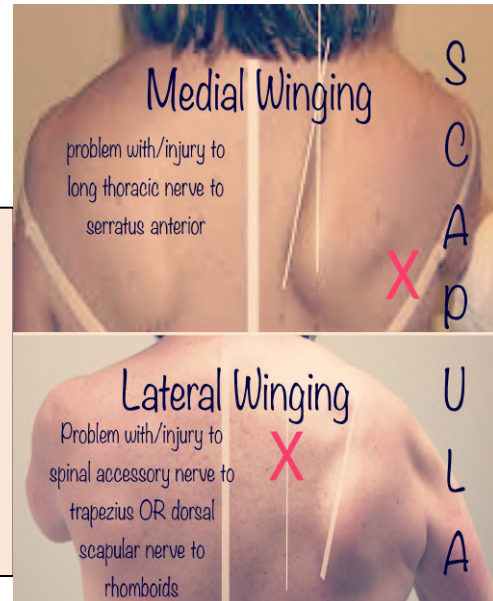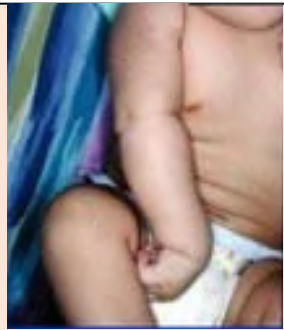Pressure	Head of femur / humerus, lower end of radius, tibial condyles
Traction	GT, LT of femur, mastoid process, GT and LT of humerus
Atavistic	Coracoid process, Os trigonum
Aberrant	Head of 1 <sup>st</sup> metacarpal, Base of other metacarpals

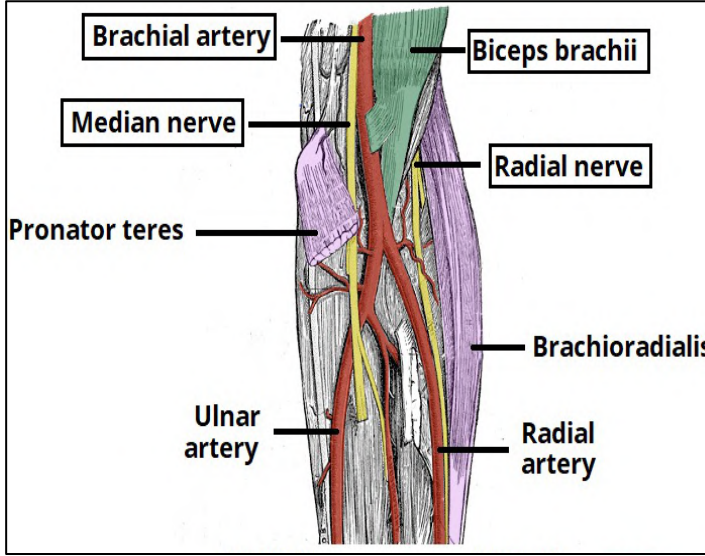
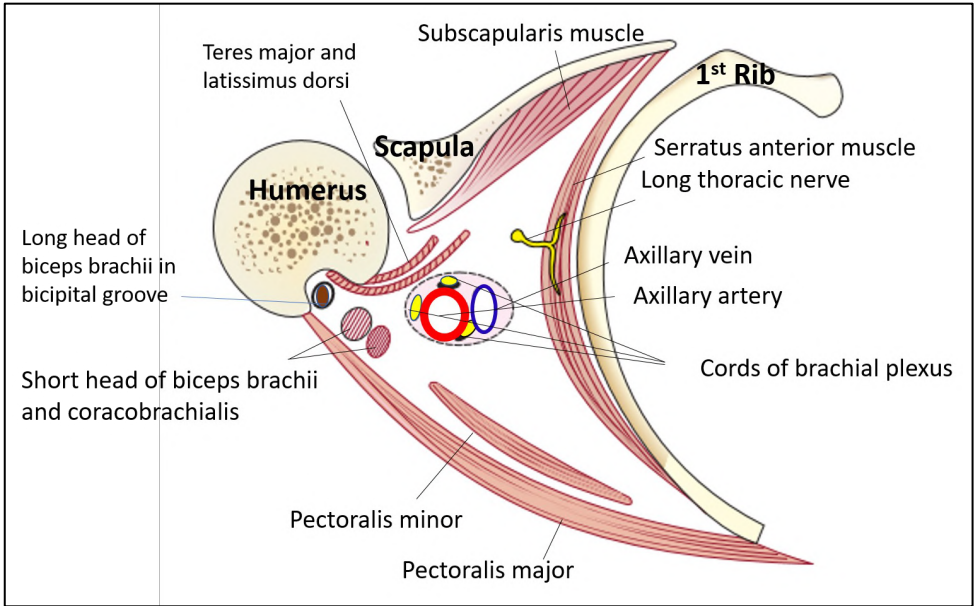
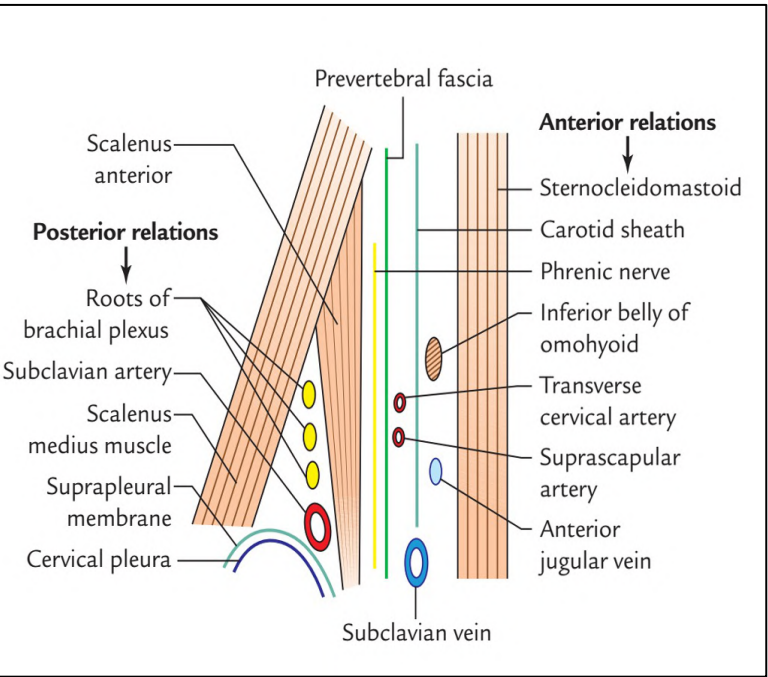
# Brachial plexus



Upper trunk:

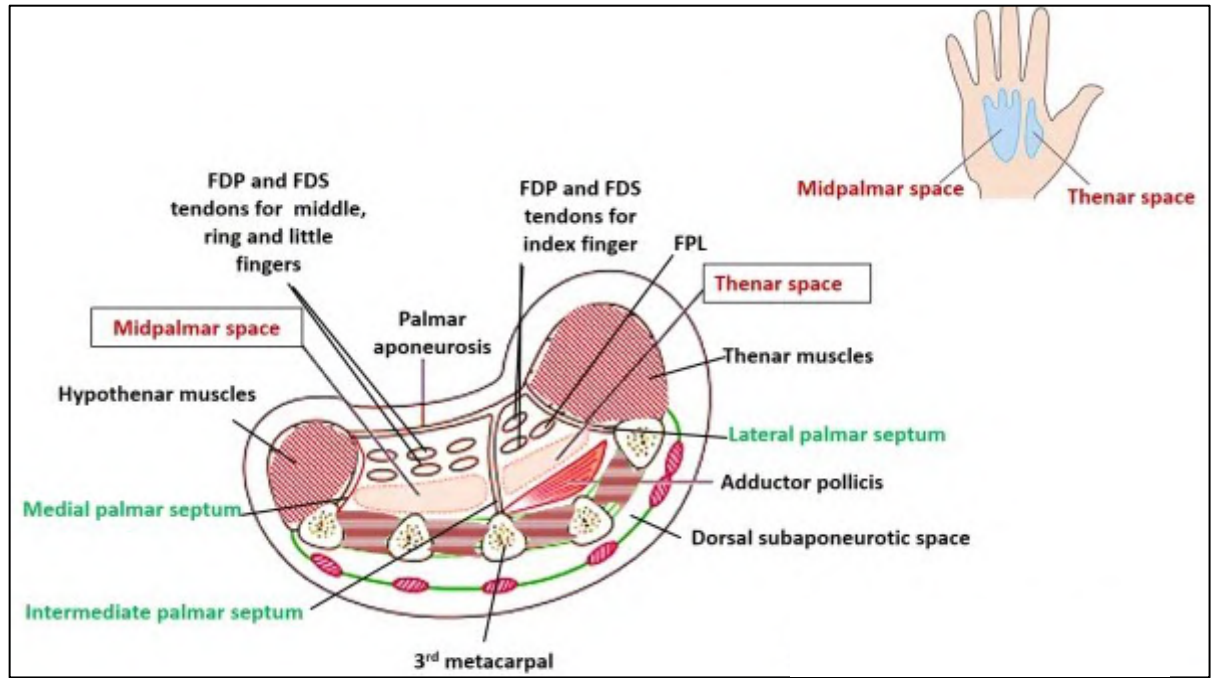
Lower trunk:

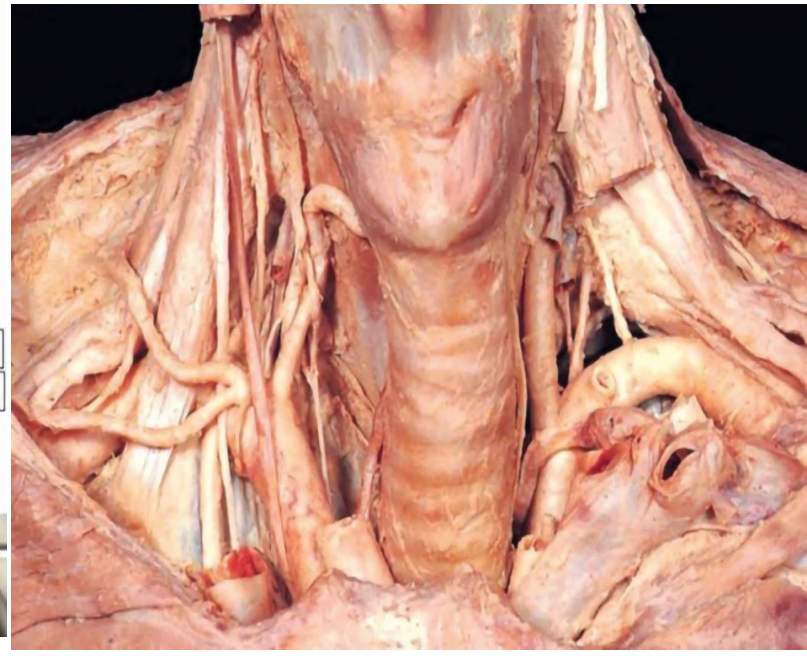
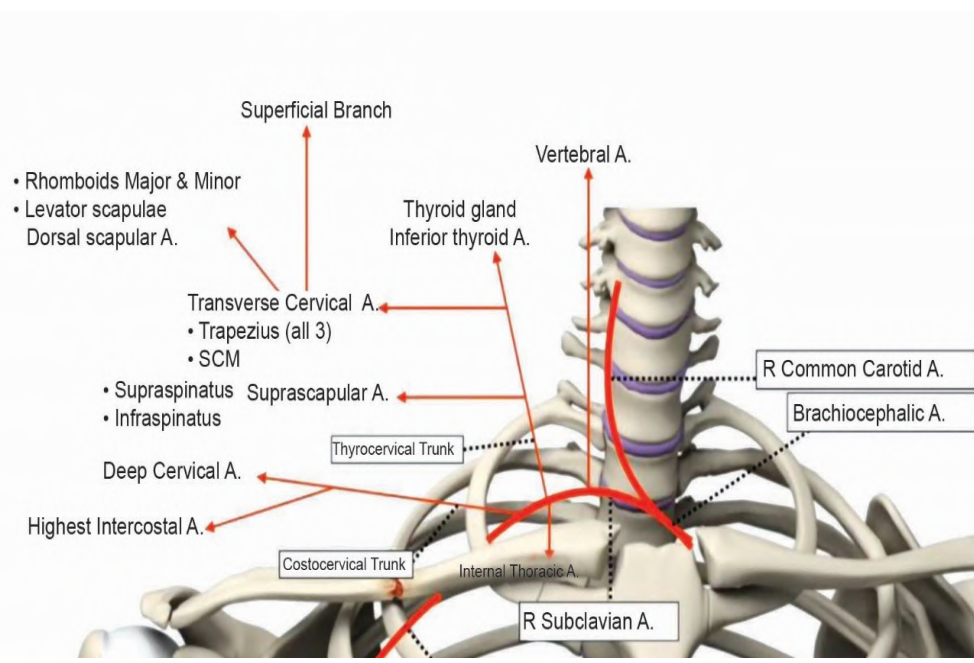
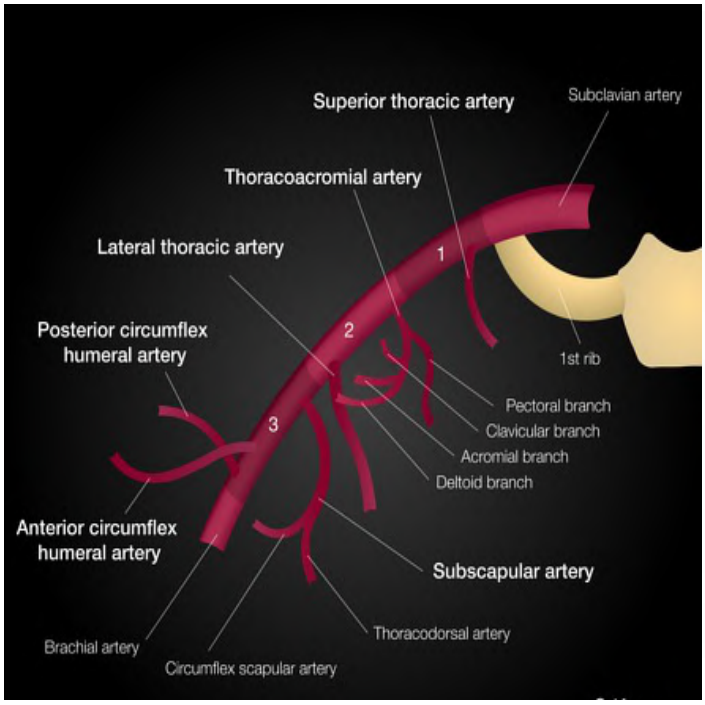




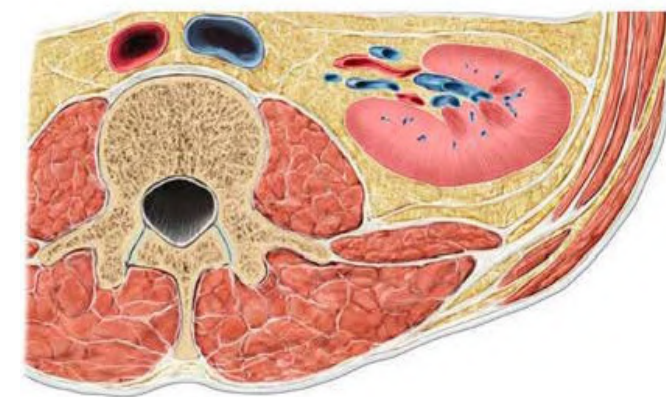
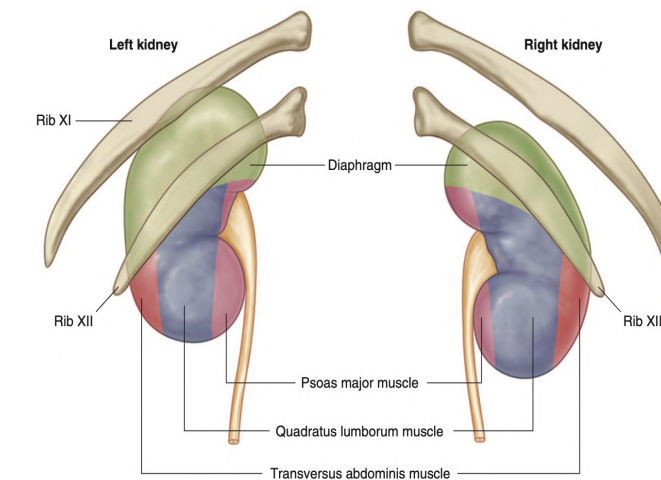
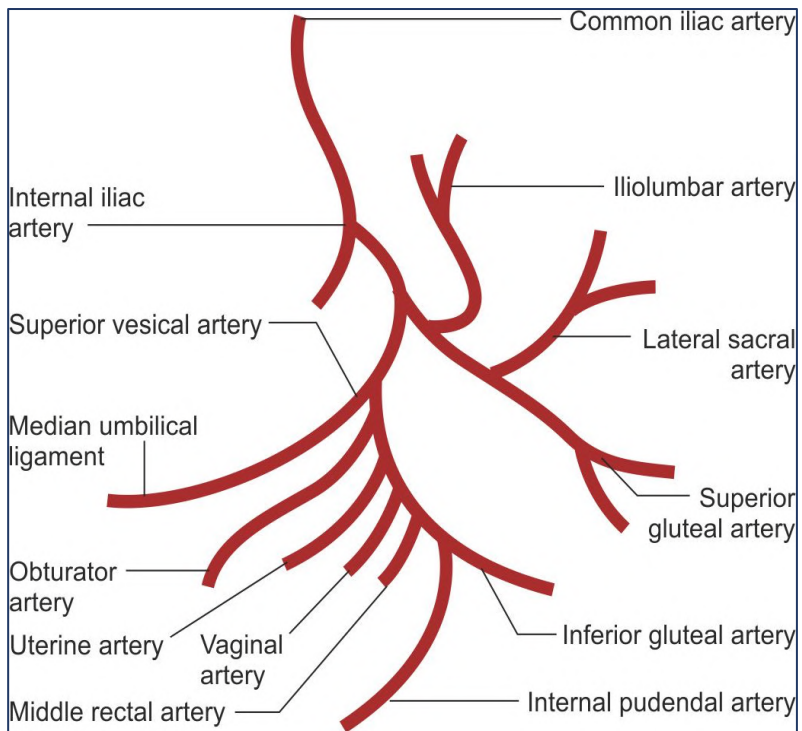
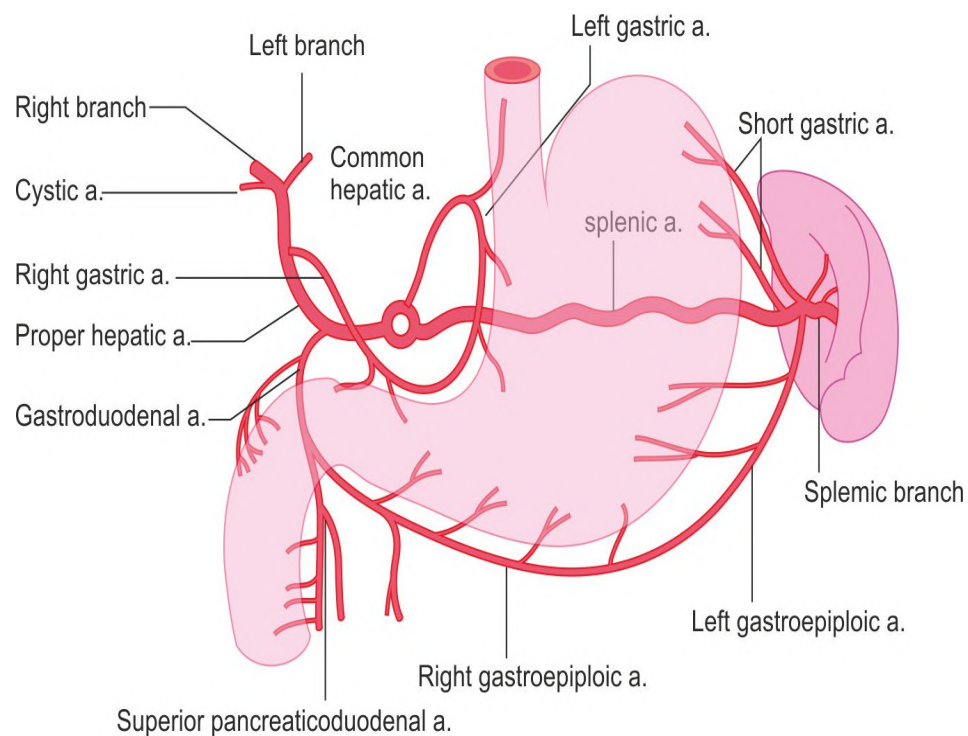
**Axillary sheath: Continuation of Ant to Scalenus anterior:**

**Inter-scalene triangle:**

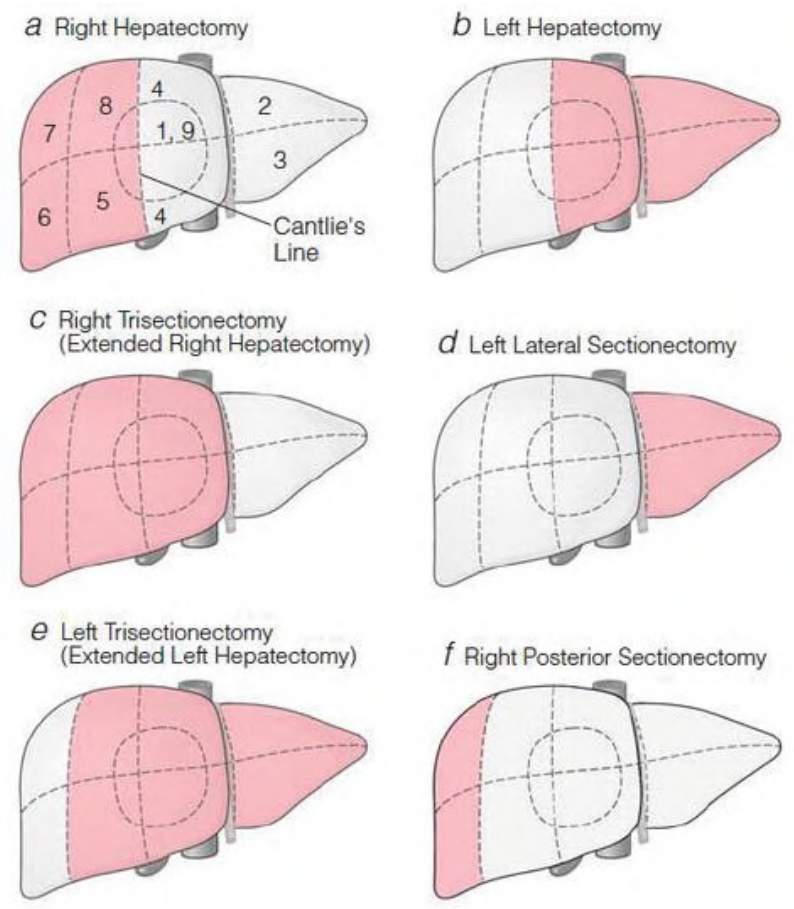
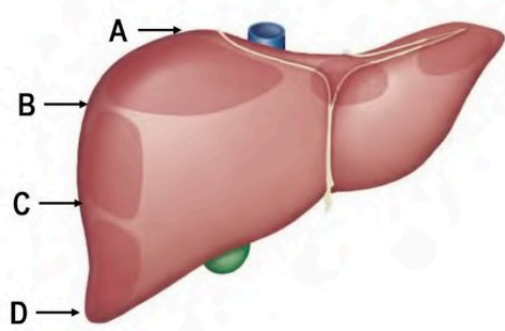
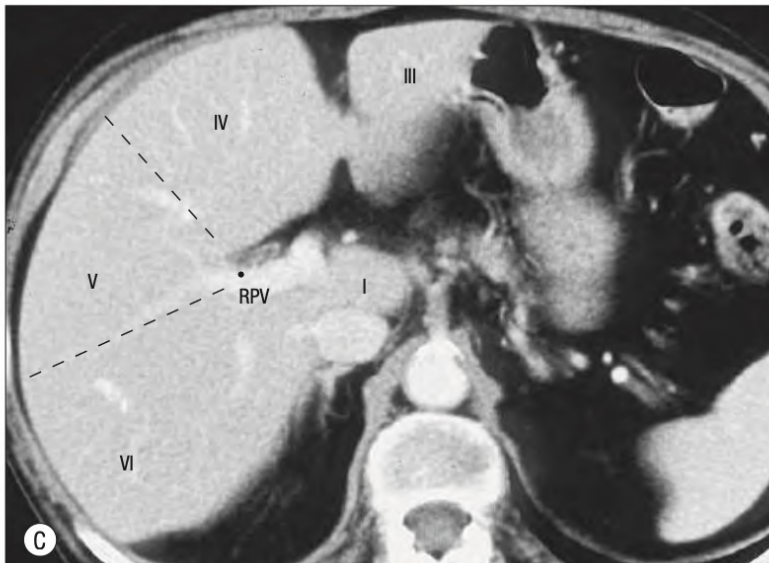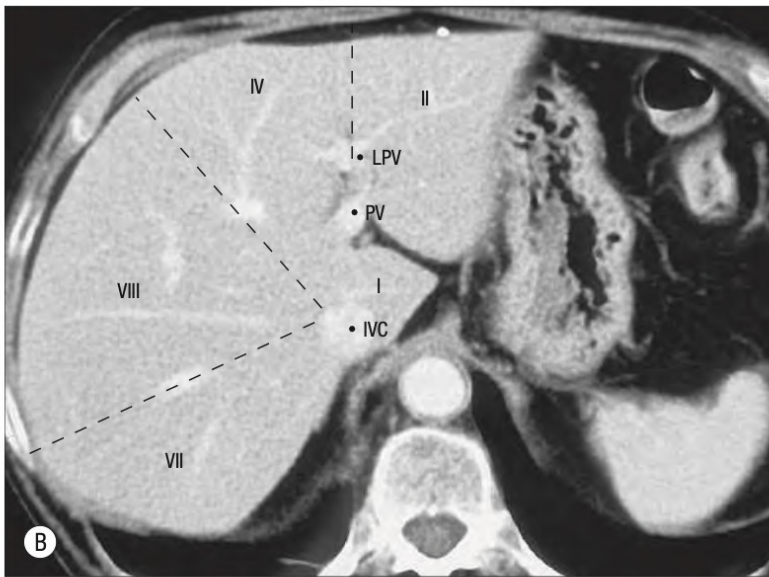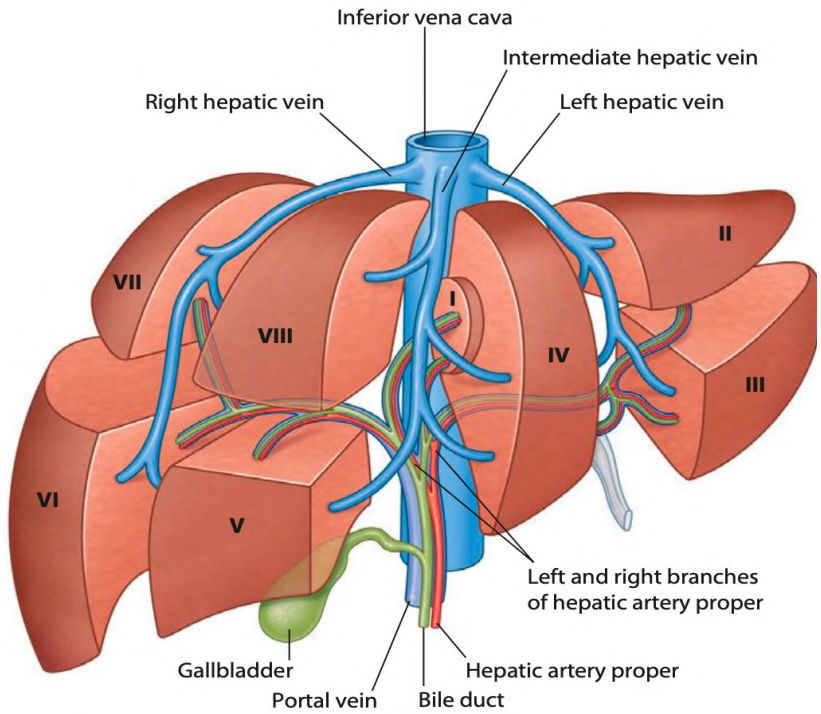




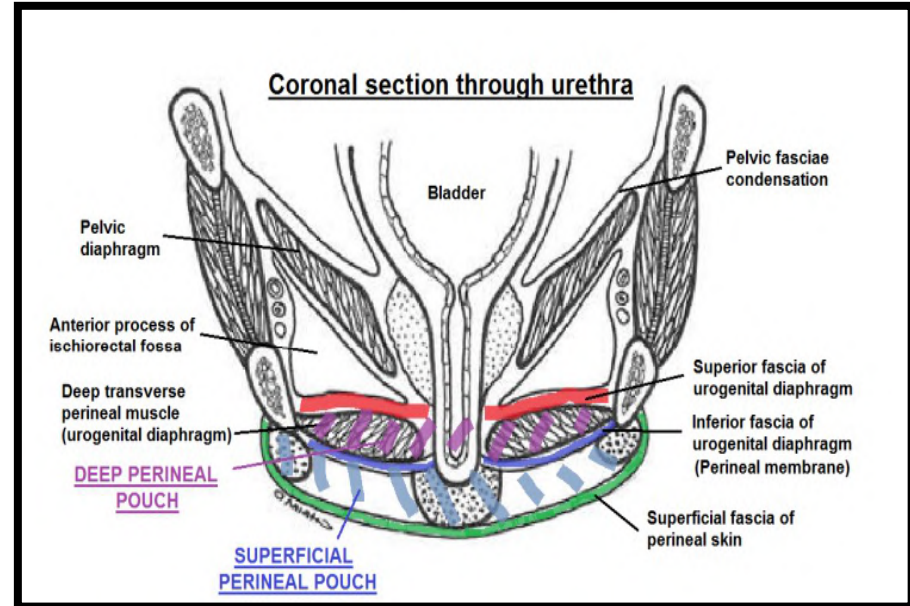
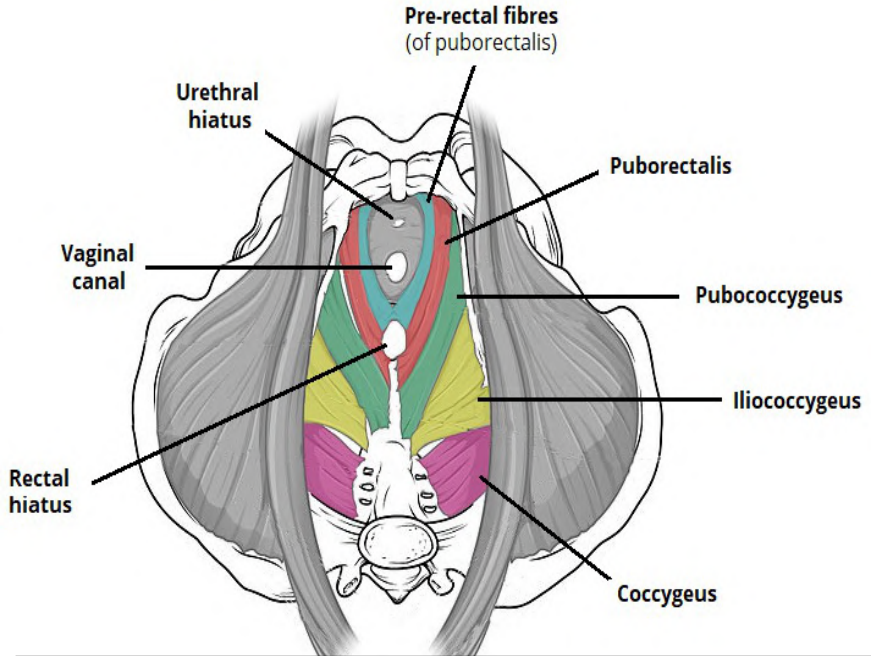
# Abdomen



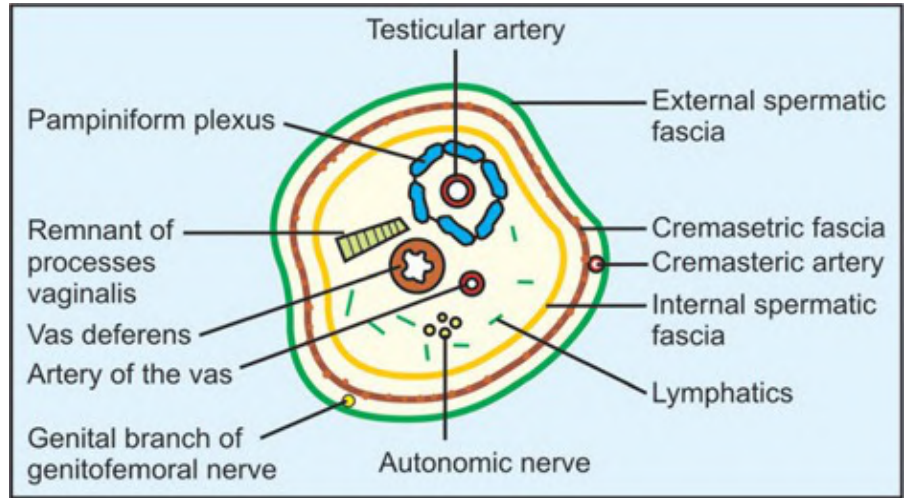
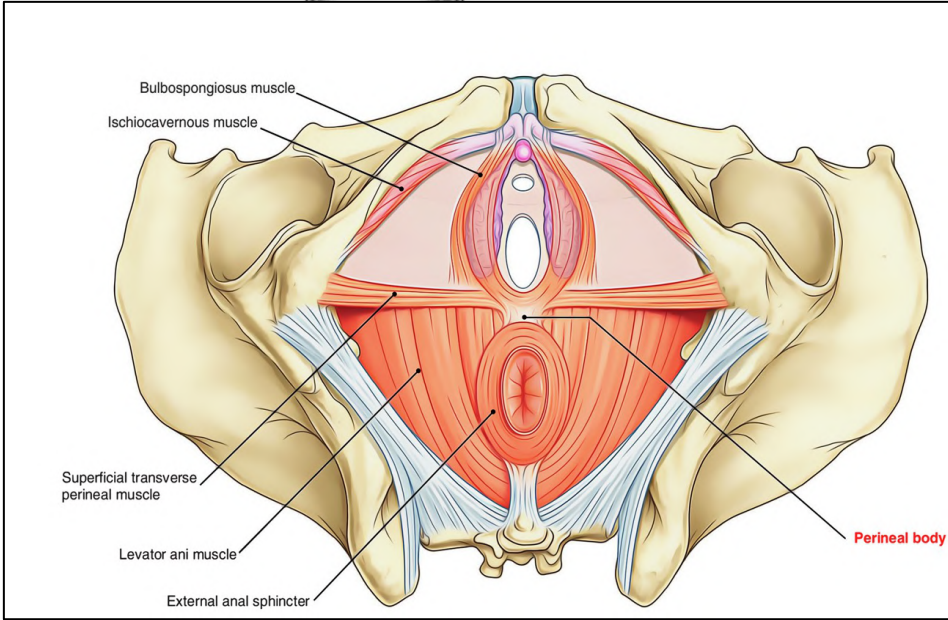
# Couinaud's liver segments



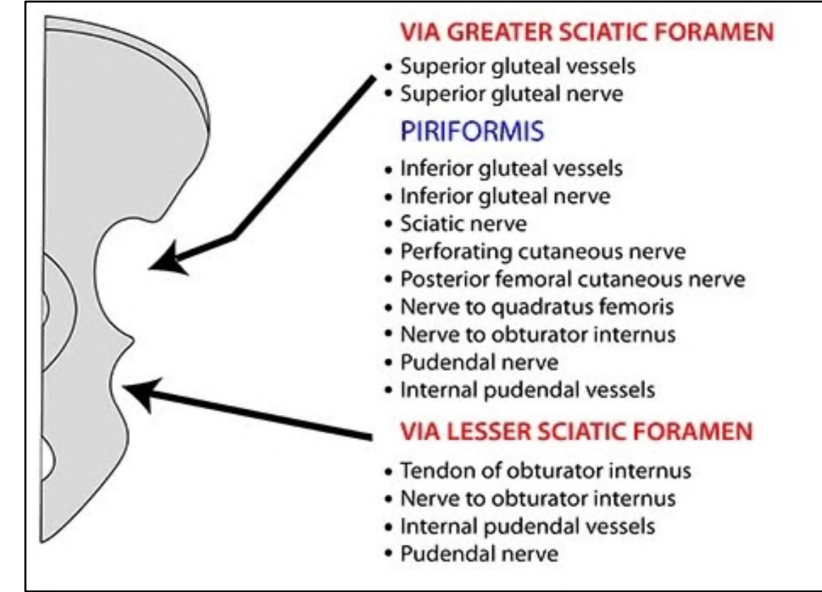
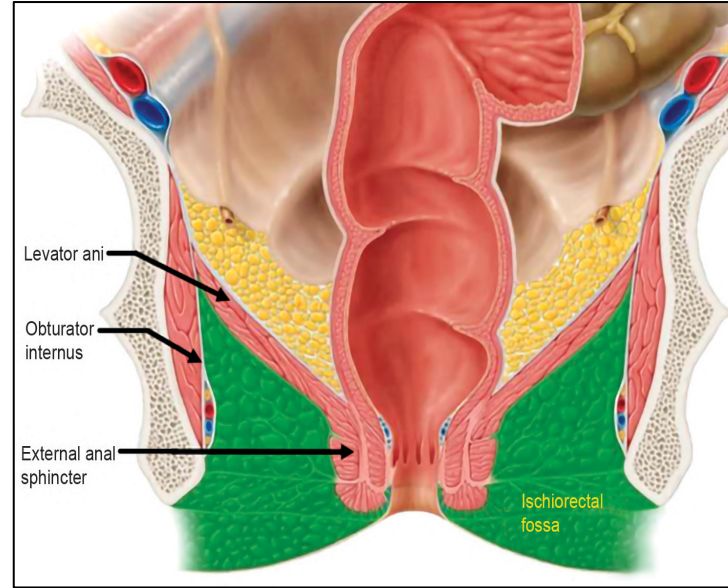
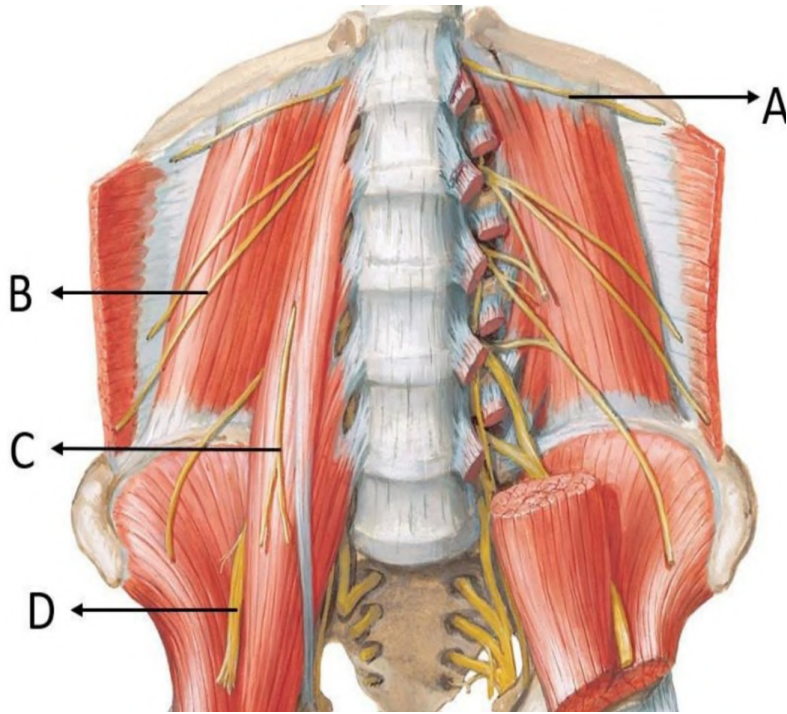
# Pelvis



- Deep perineal pouch:**
- Sphincter urethra
  - Deep transverse perinii
  - Membranous urethra
  - Bulbourethral (Cowper's) glands



# Miscellaneous



## Contents of Ischioanal fossa:

1. Pudendal nerve
2. Internal pudendal vessels
3. Inferior rectal nerve, vessels
4. Posterior scrotal nerves, vessels
5. Perforating cutaneous N. (S2, S3)

## Structures crossed by root of mesentery:

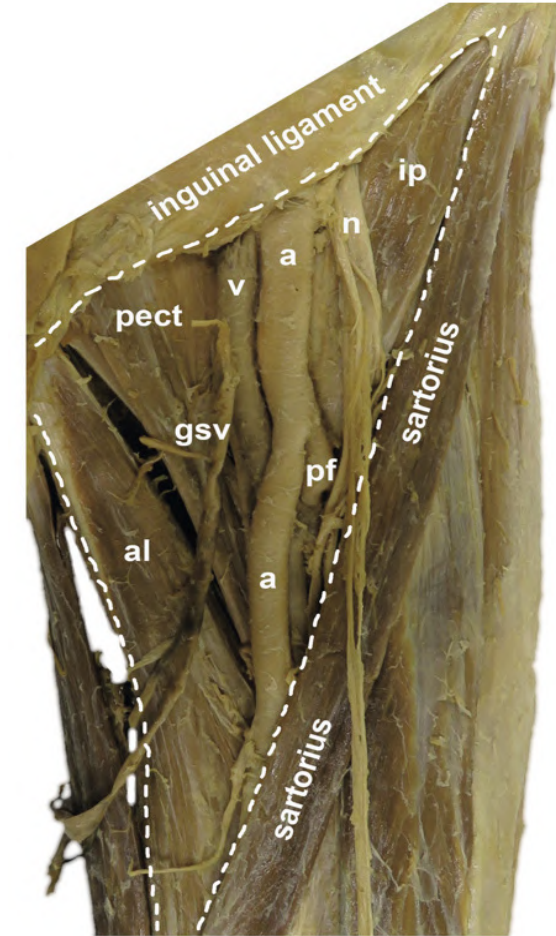
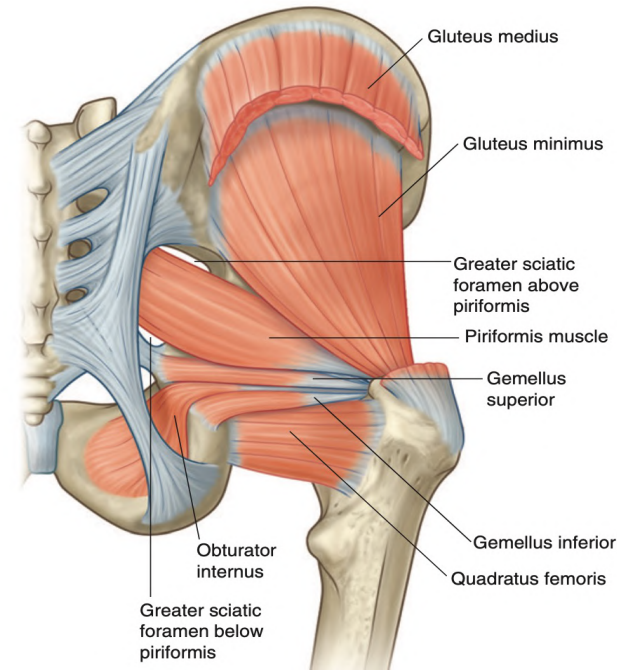
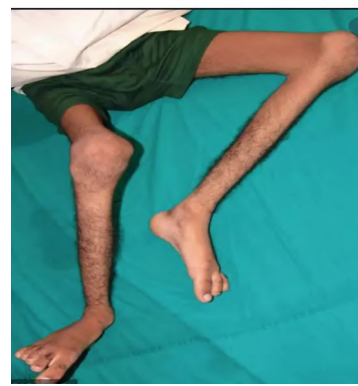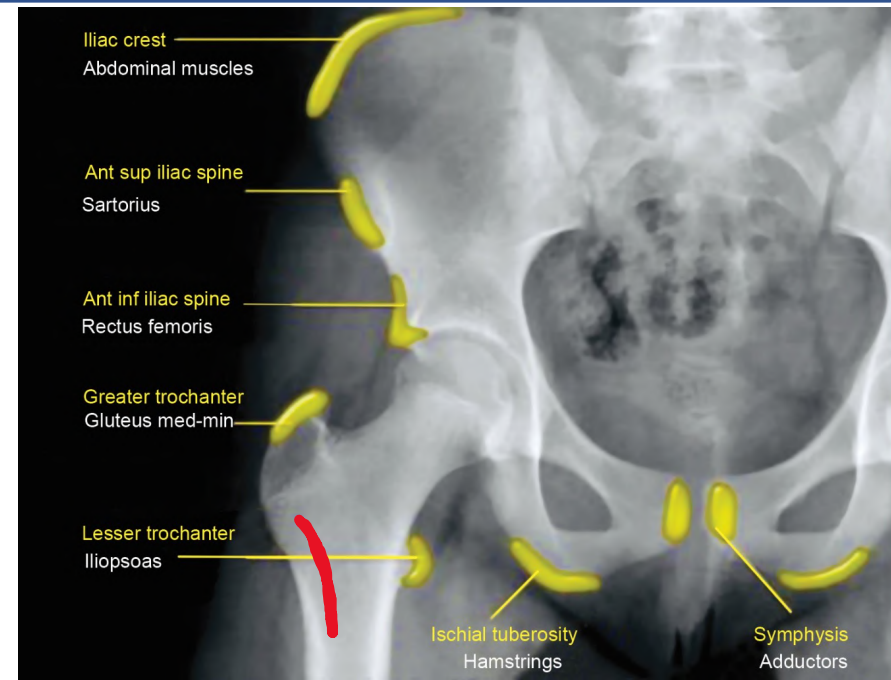
3<sup>rd</sup> part of duodenum

Aorta, IVC

Right gonadal vessels, ureter

Right psoas/ genitofemoral N

# Lower limb



**Gluteus minimus, medius:**

**Function:**

**Gluteus maximus:**

**Function:**

**Gover sign**

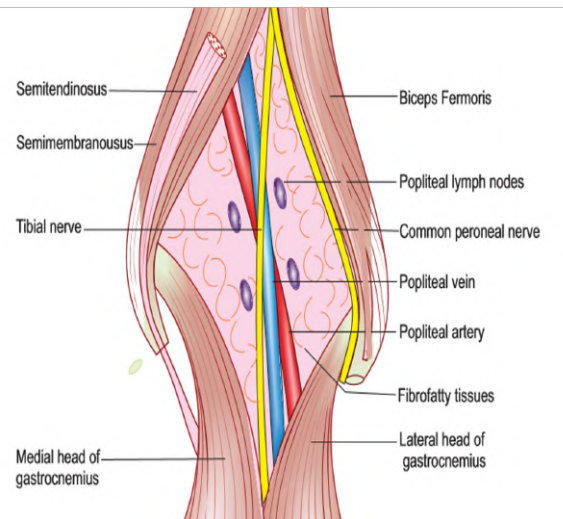
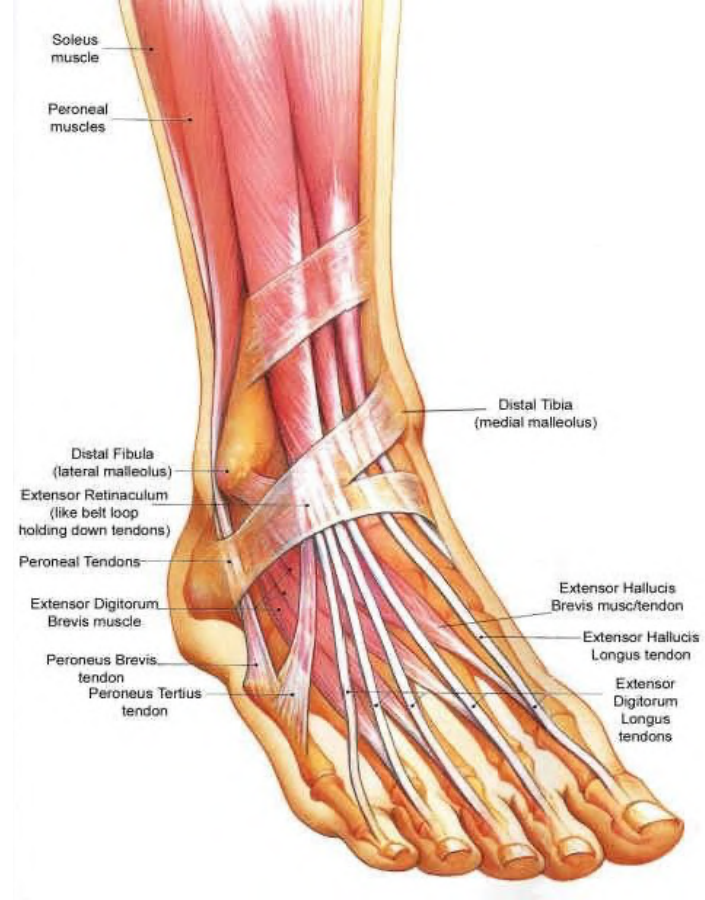
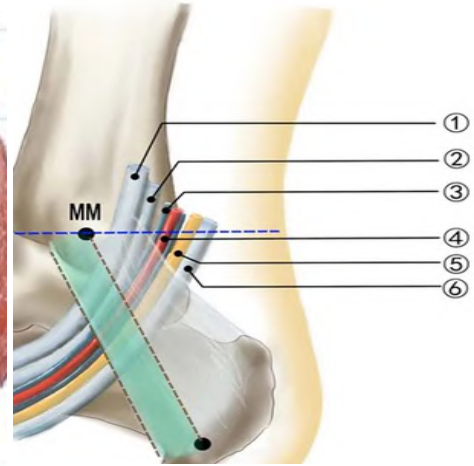
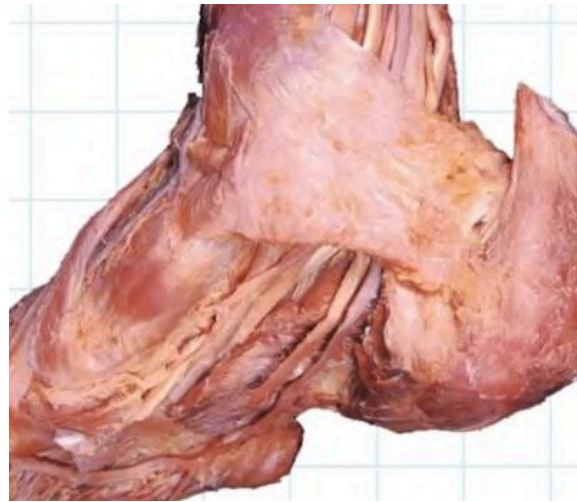
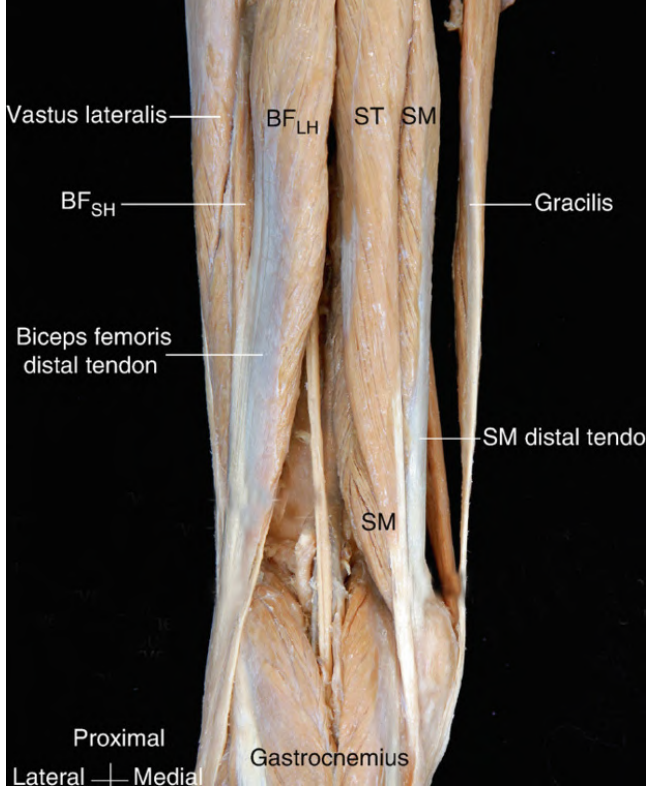
**Iliotibial tract:**

**Contracture:**

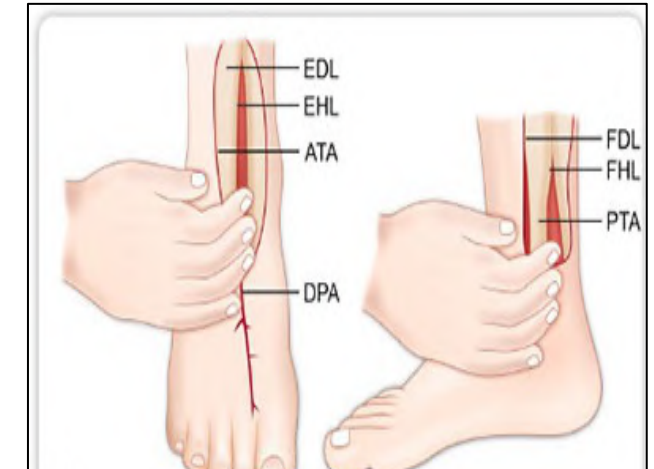
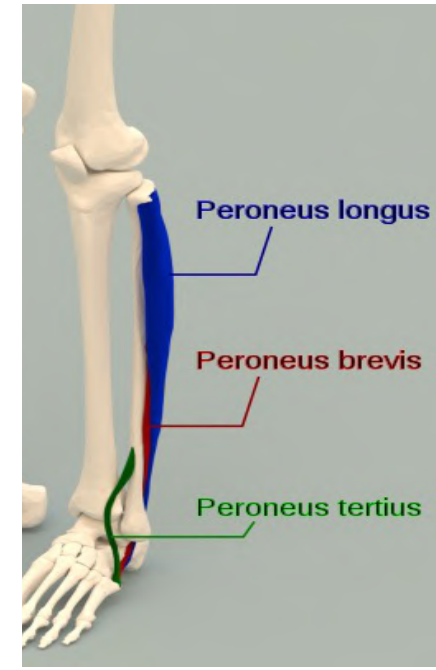
**Sartorius:**

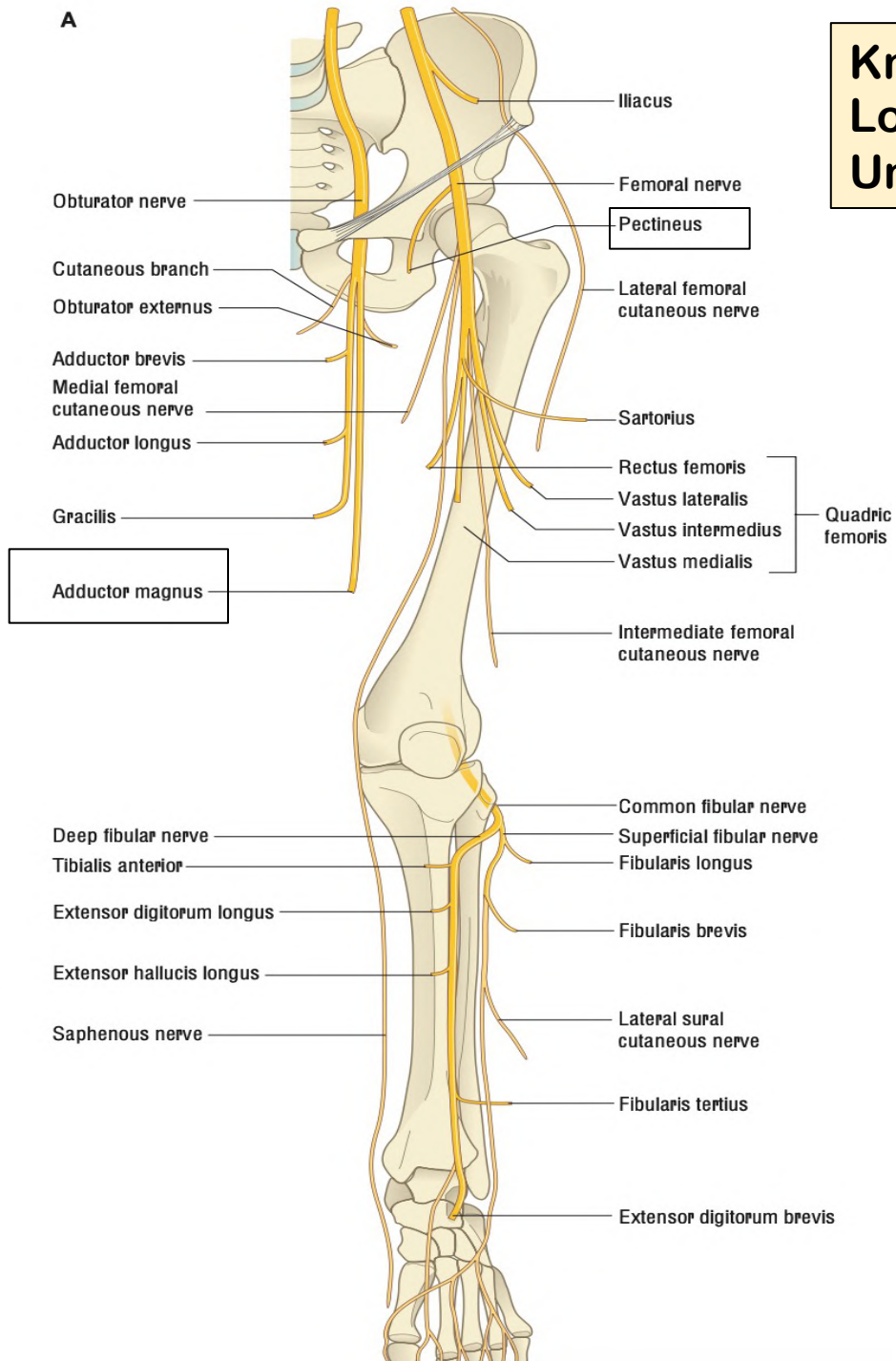
**Rectus femoris:**

**N to OI:**  
**N to QF:**  
**N to piriformis**

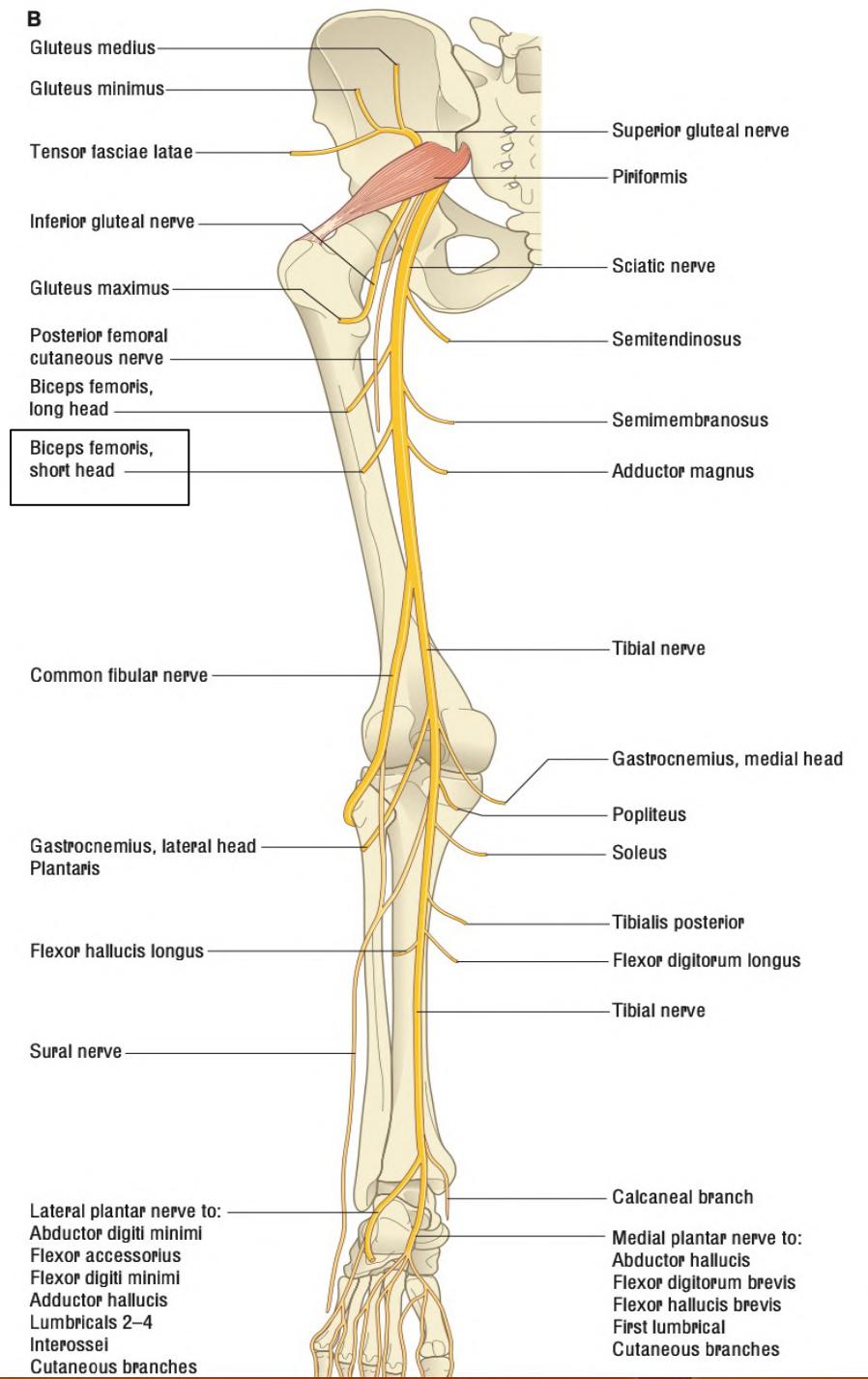


**NERVES of calf:**  
**Anterior (Dorsiflexion + invertor):**  
**Lateral (Evertor):**  
**Posterior (Plantar flexion + invertor):**

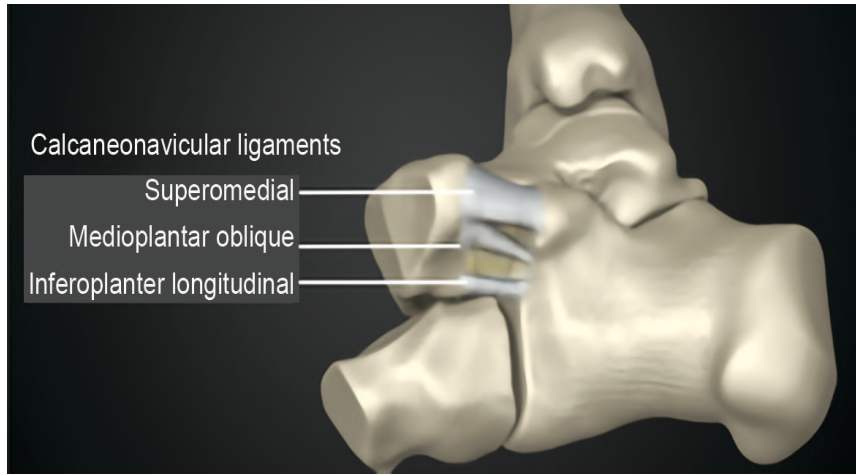
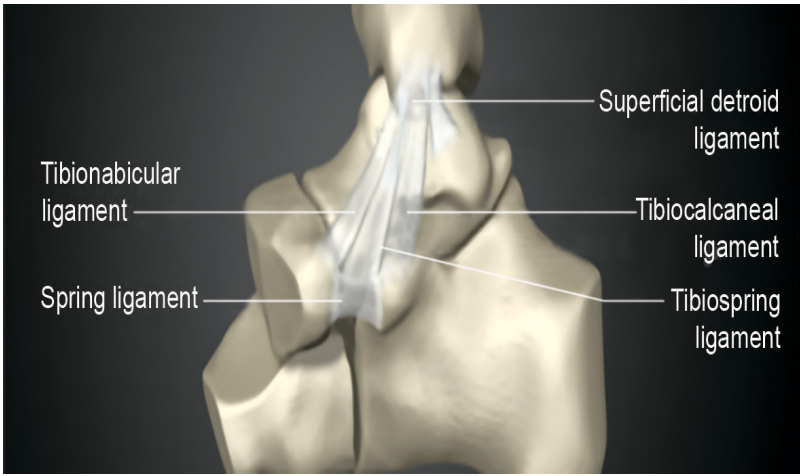
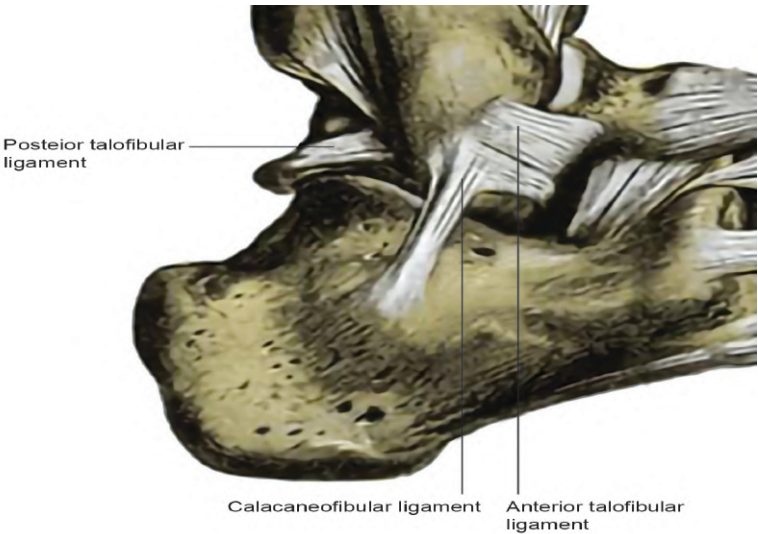


**A**

**Knee:  
Locking:  
Unlocking:**

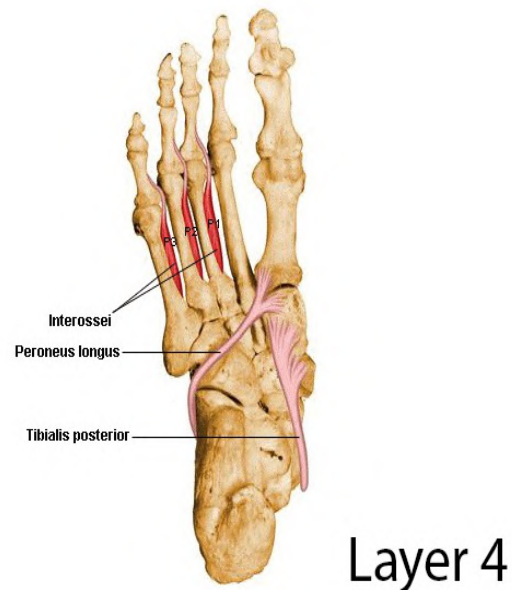
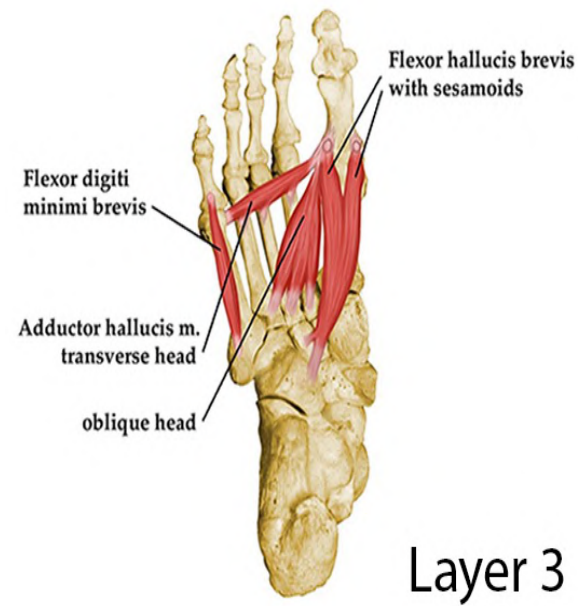
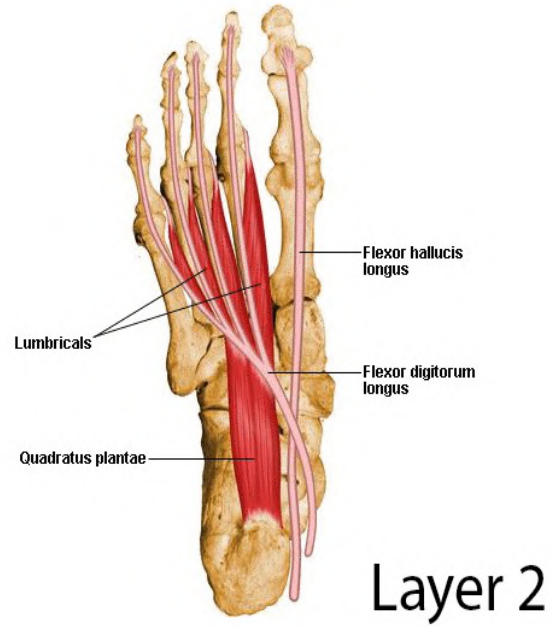
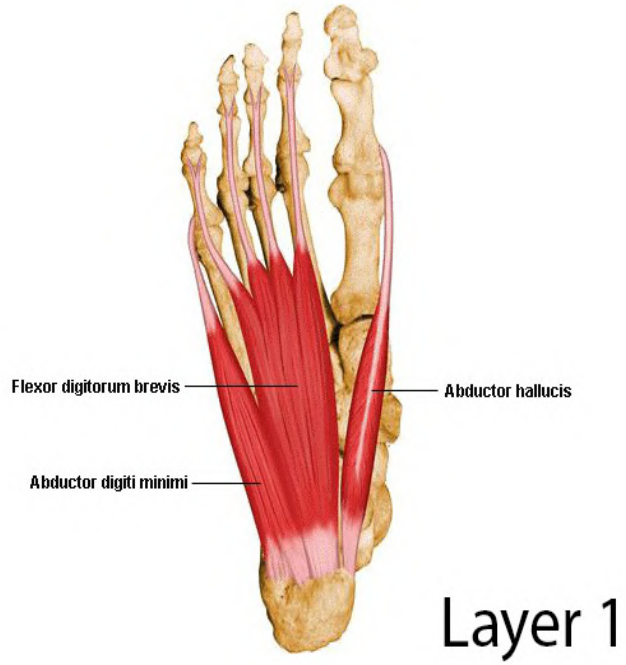
**B**

# Ankle/ Foot



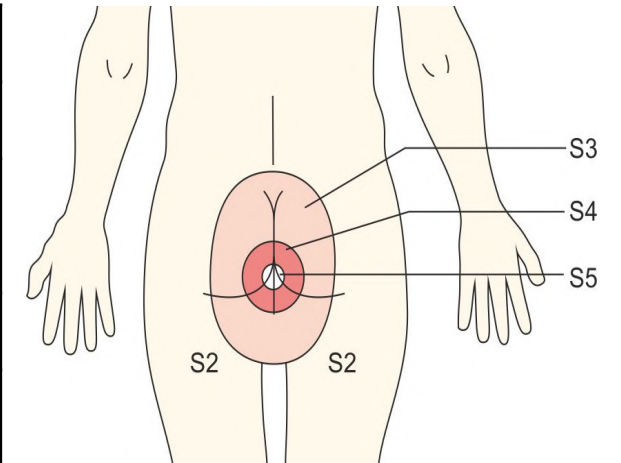
**Bifurcate ligament: Calcaneo-cuboid/ calcaneo-navicular**

**Plantar arterial arch between 3-4**

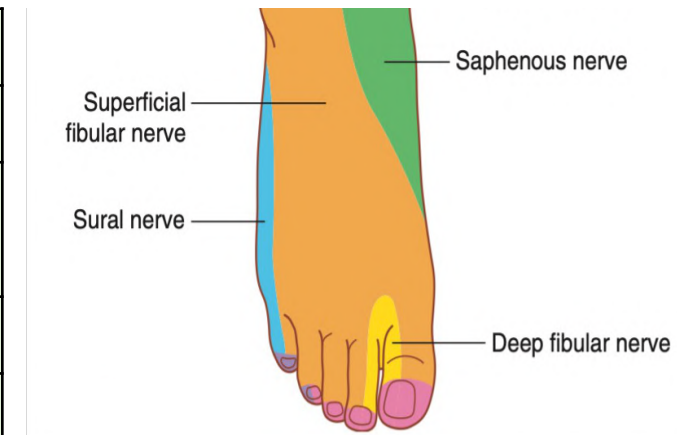


# NERVE ROOTS

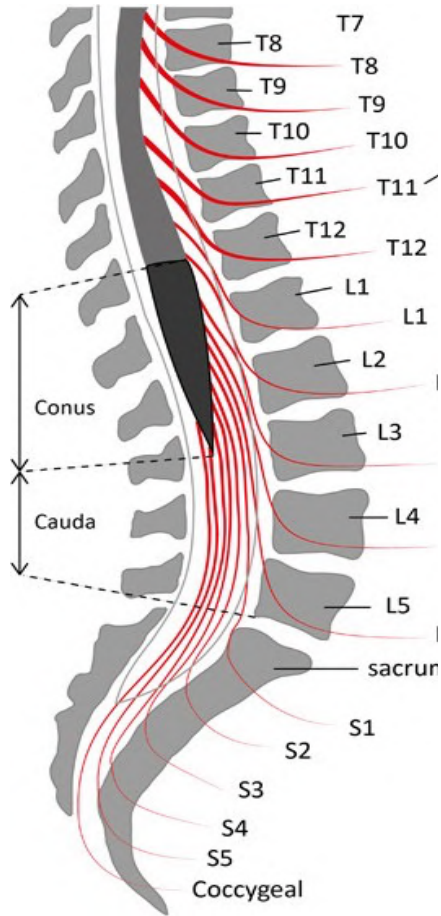
Nerve root	Motor	Sensation	Reflexes
<b>C5</b>	Deltoid	Lateral arm	Biceps (C5/6)
<b>C6</b>	Wrist extensors	Lateral forearm/ Thumb	Brachioradialis (C5/6)
<b>C7</b>	Triceps	Middle finger	Triceps (C6/7/8)
<b>C8</b>	Long finger flexors	Medial forearm/ Little finger	-
<b>T1</b>	Interossei muscles	Medial arm	-



Nerve root	Motor	Sensation	Reflexes
<b>L2</b>	Hip flexion	Anterior thigh, groin	Cremasteric (L1/L2)
<b>L3</b>	Knee extension	Anterior and lateral thigh	Patellar (L3/4)
<b>L4</b>	Ankle dorsiflexion	Medial leg and foot	Patellar (L3/4)
<b>L5</b>	Extensor hallucis longus	Lateral leg Dorsum of foot	-
<b>S1</b>	Ankle plantarflexion	Lateral foot Sole	Achilles (S1/2)

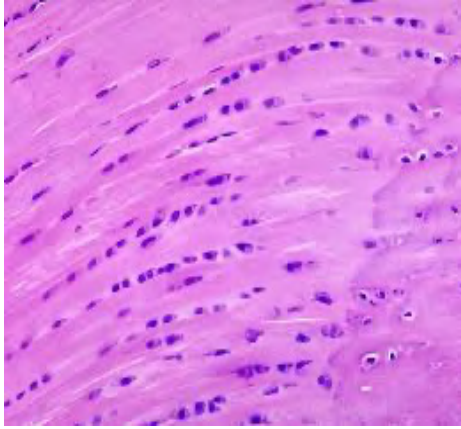


# CAUDA VS CONUS SYNDROME

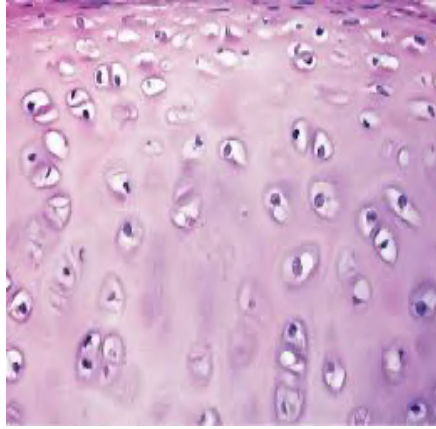


	Conus medullaris syndrome	Cauda equina syndrome
<b>Vertebral level</b>	L1 – L2	L2 – sacrum
<b>Spinal level</b>	Sacral cord segment and roots	Lumbosacral nerve roots
<b>Presentation</b>	<b>UMN + LMN</b> <b>Sudden and bilateral</b> <b>Symmetrical</b> <b>Early incontinence/ impotence</b>	<b>LMN</b> <b>Gradual and unilateral</b> <b>Asymmetric</b> <b>Saddle anesthesia</b>
<b>Radicular pain</b>	Less severe	More severe
<b>Reflexes</b>	Ankle jerks affected	Both knee and ankle jerks

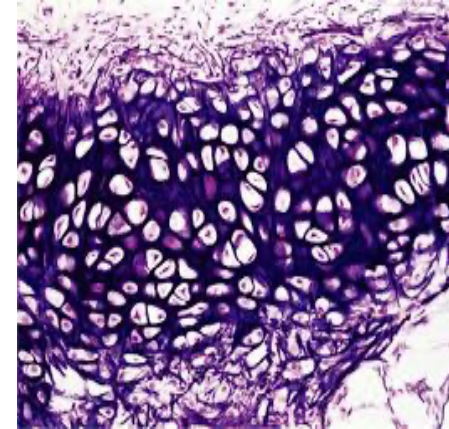
# HISTOLOGY



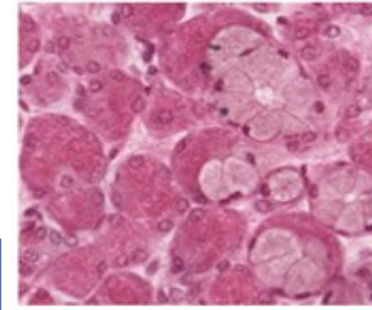
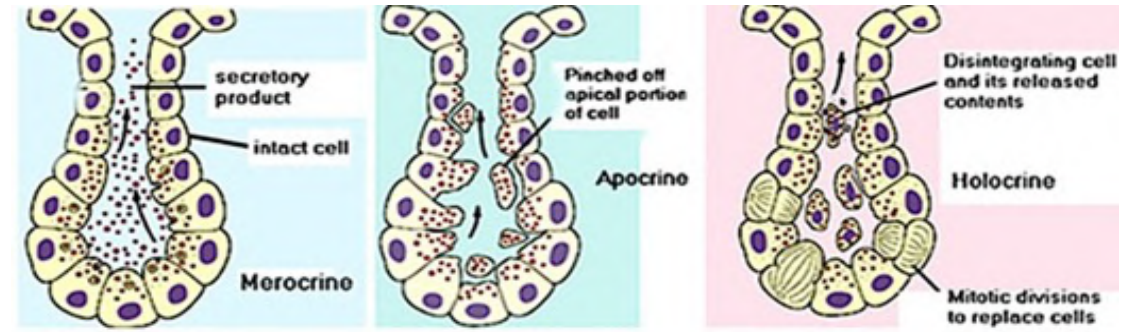
IVD, symphysis, Labrum, articular disc, menisci



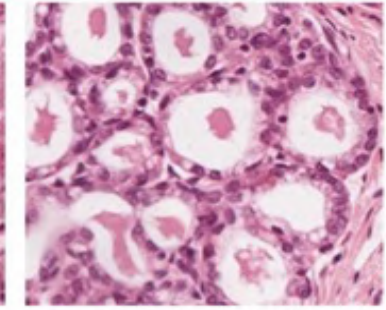
Cricoid, thyroid, arytenoid (except apex), trachea articular



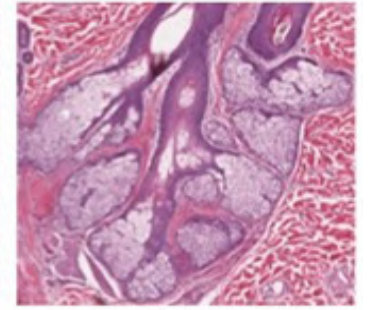
Epiglottis, Cuneiform, Corniculate, ET, Pinna, EAC



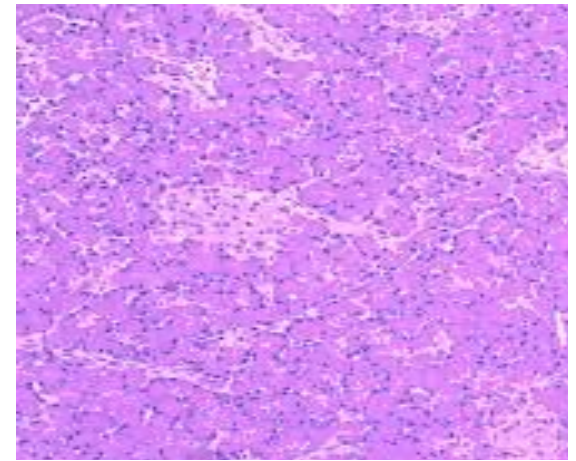
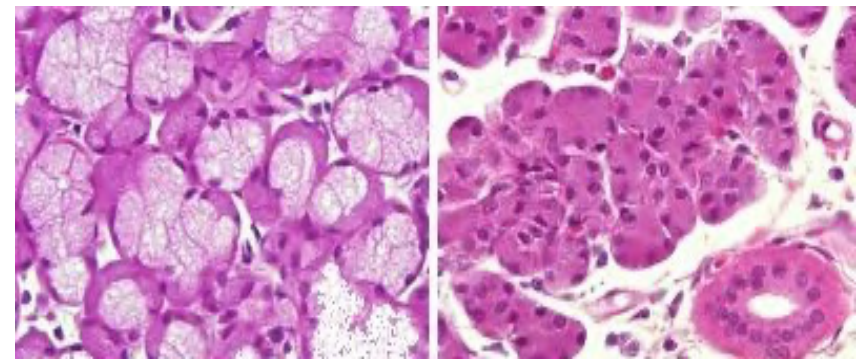
Submandibular gland

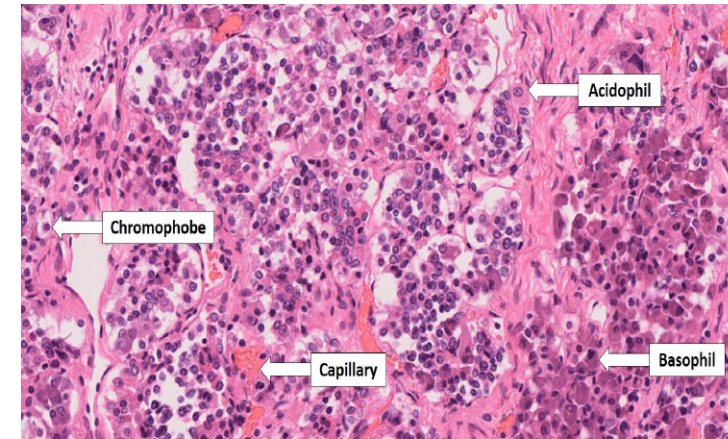
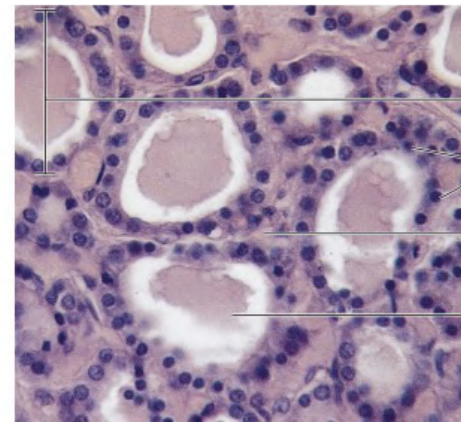
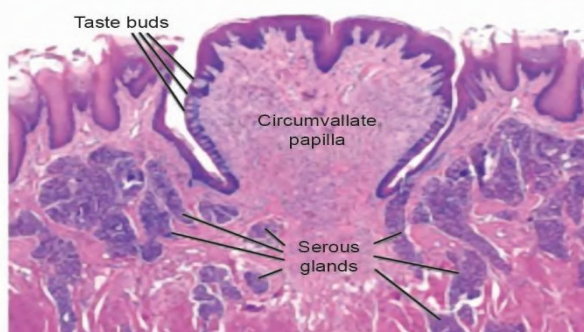
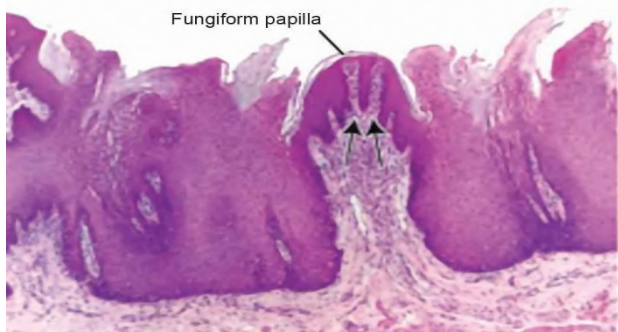
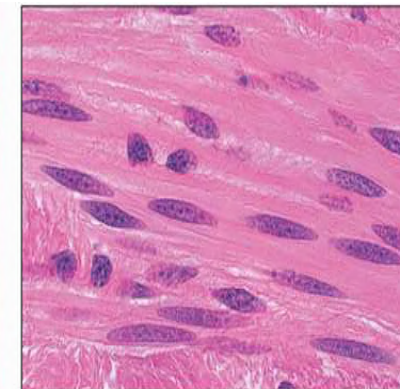
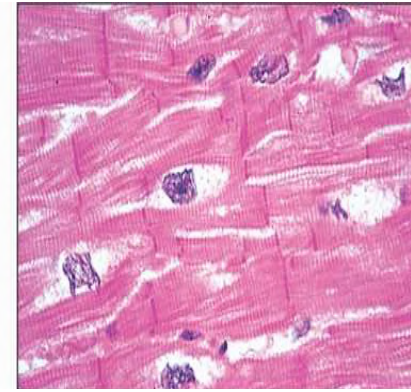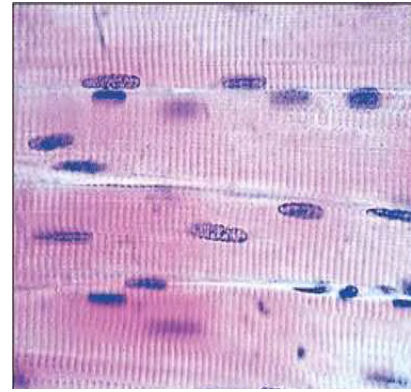
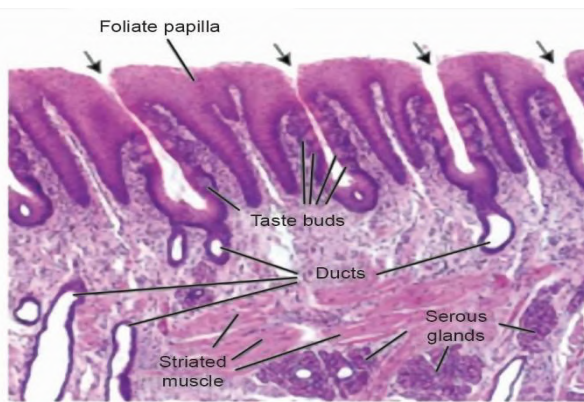
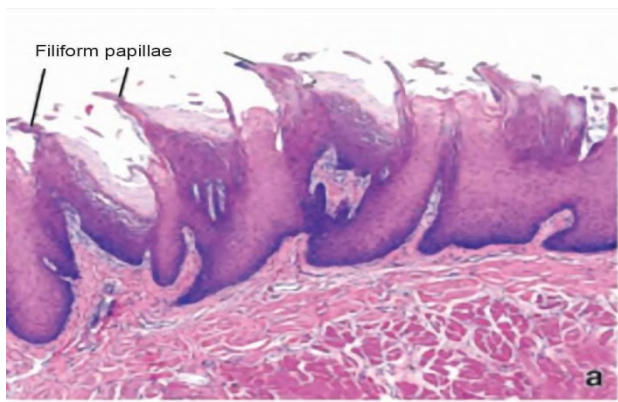


Mammary gland



Sebaceous gland





## GIT

-Mouth, Tongue, Tonsil, esophagus:

Filiform papilla:

-Stomach

-SI

Duodenum: Broad villi, Brunner gland

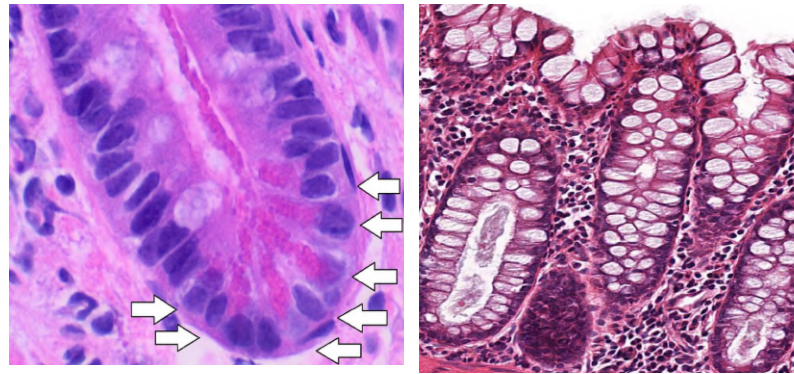
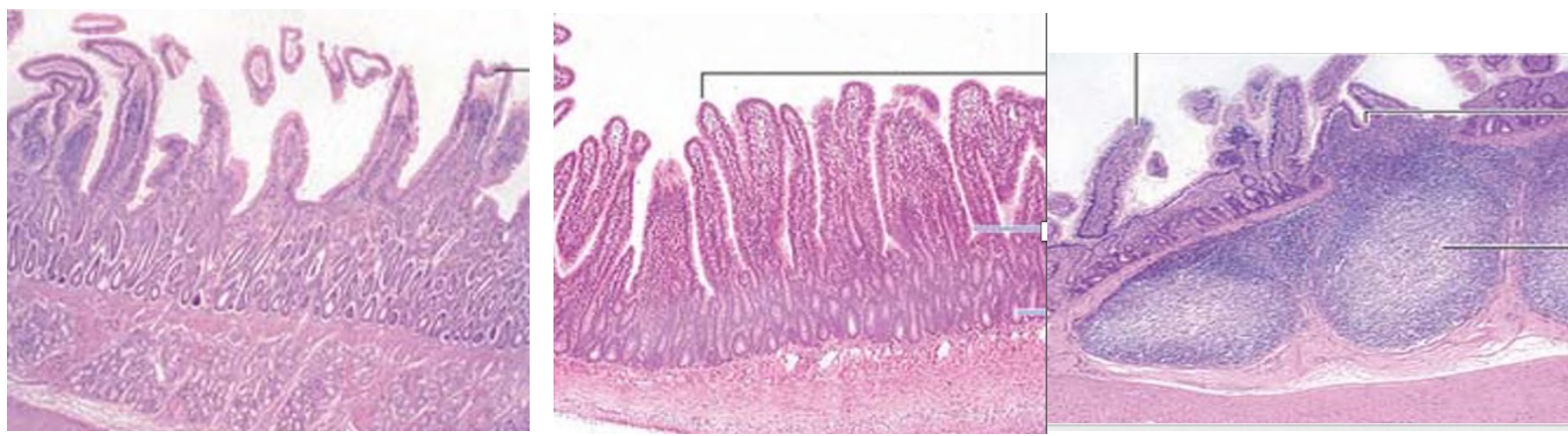Jejunum: Tongue shaped villi

Ileum: Flat vili, Peyer patches

-LI

-Anal canal : Above PL

Below PL



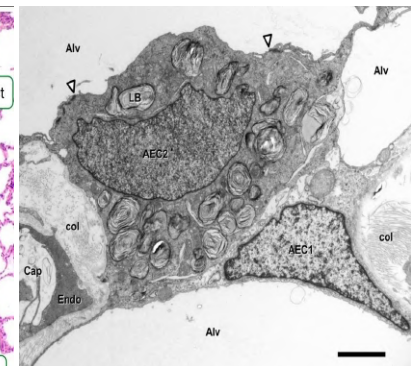
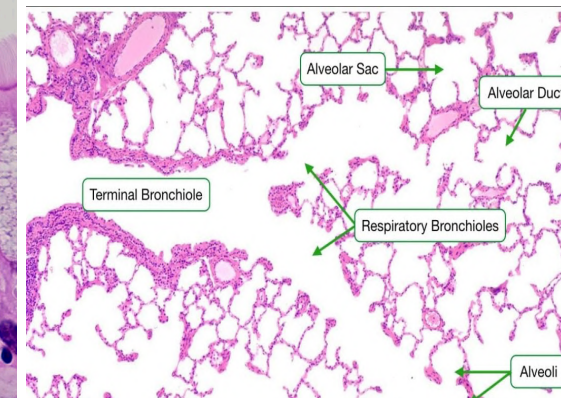
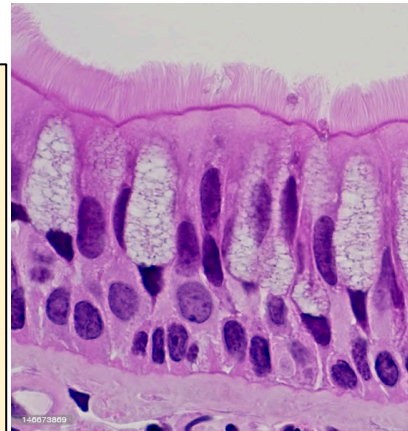
## Respiratory tract

-PNS, Trachea, Bronchus, Proximal bronchiole:

-Terminal bronchiole:

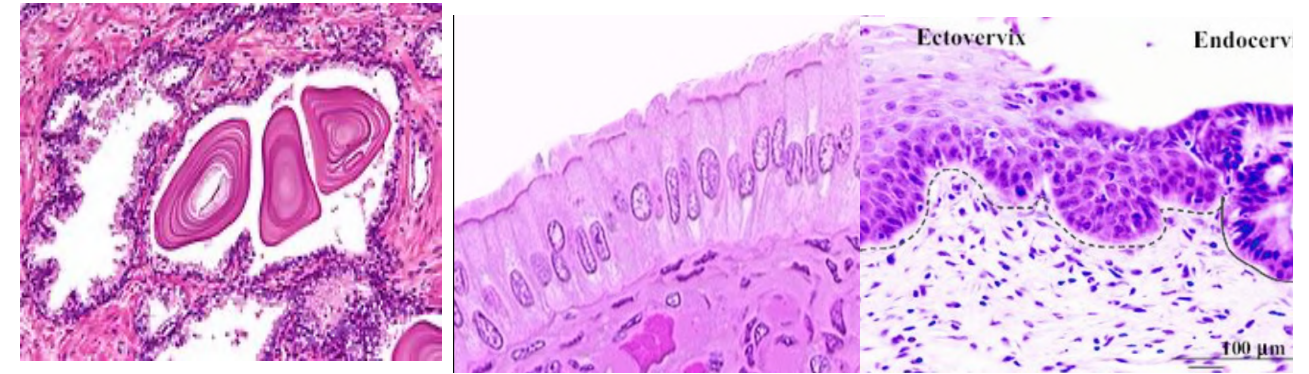
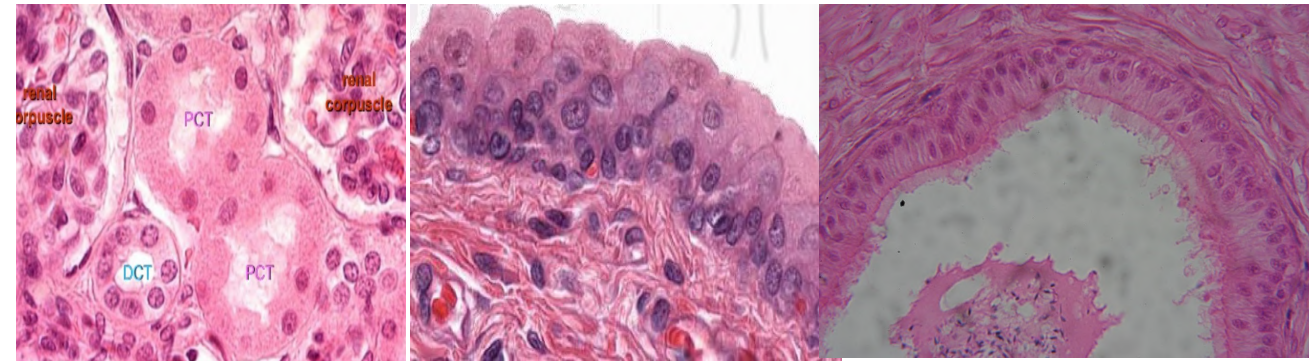
-Respiratory bronchiole

-Alveolus

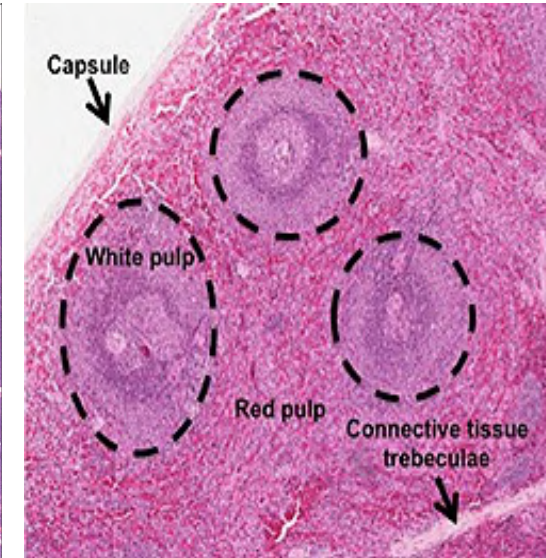
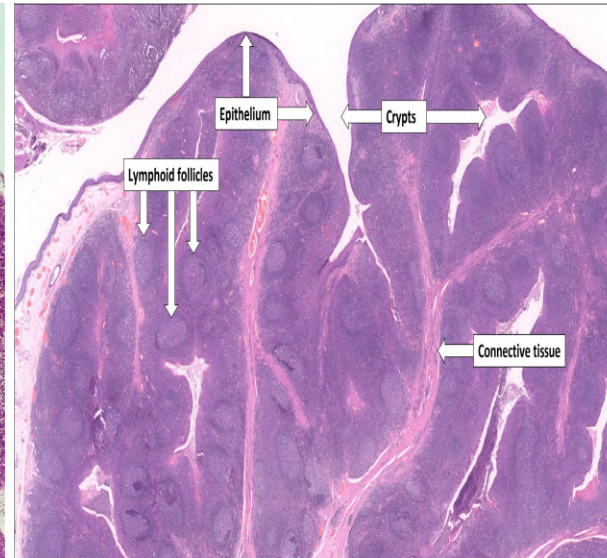
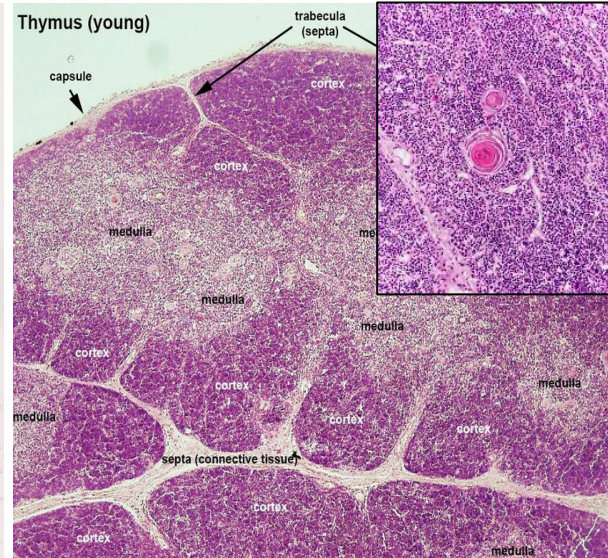
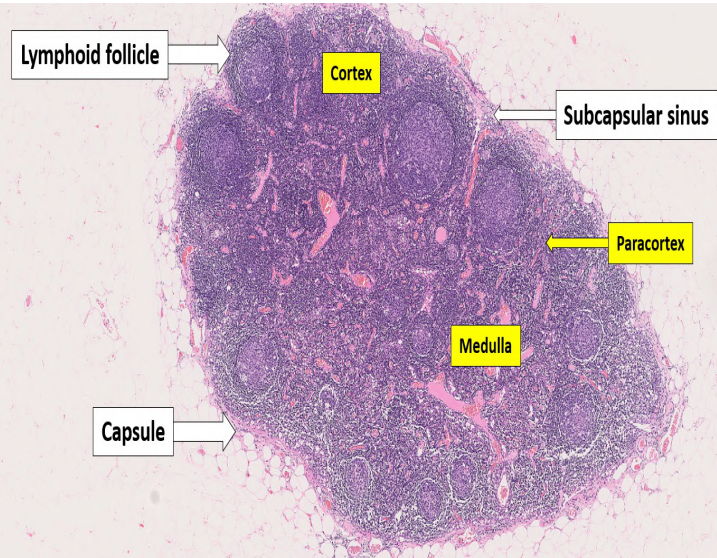


## Uro-genital tract

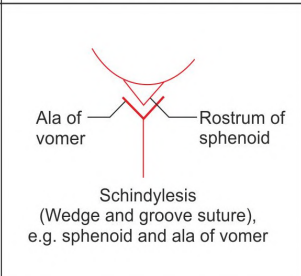
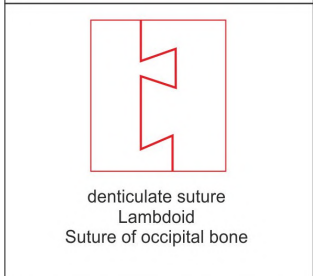
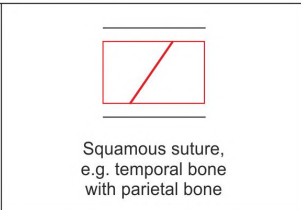
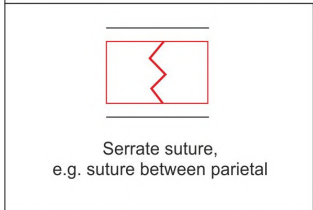
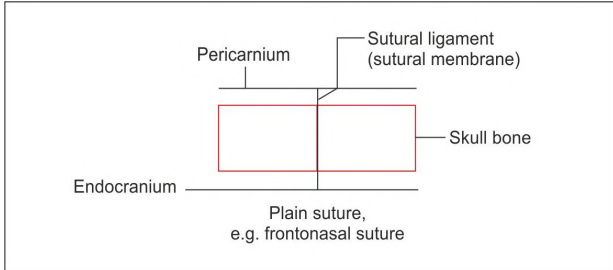
- PCT, DCT
- Calyces, Ureter, UB, Prostatic urethra:
- Membranous, penile Urethra:
- Epididymis, Vas deferens-
- Prostate-
  
- Ovary-
- Fallopian tube-
- Uterus, endocervix-
- Ectocervix, Vagina-



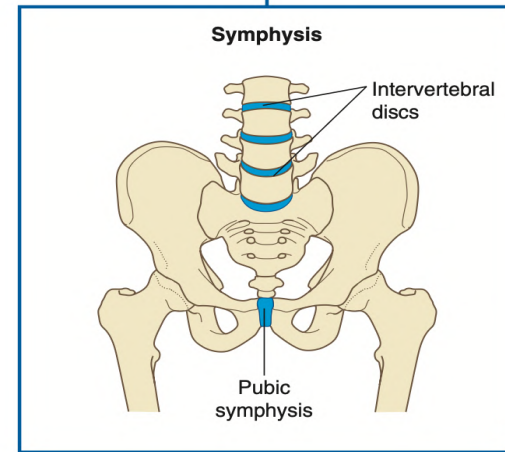
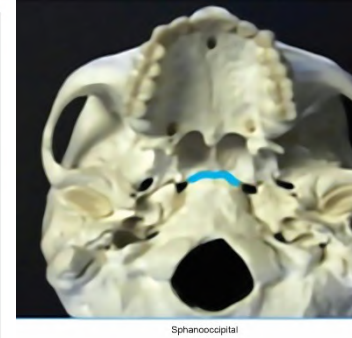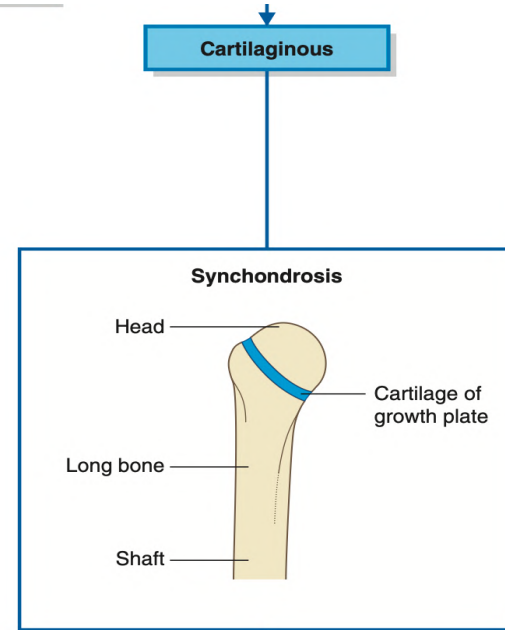
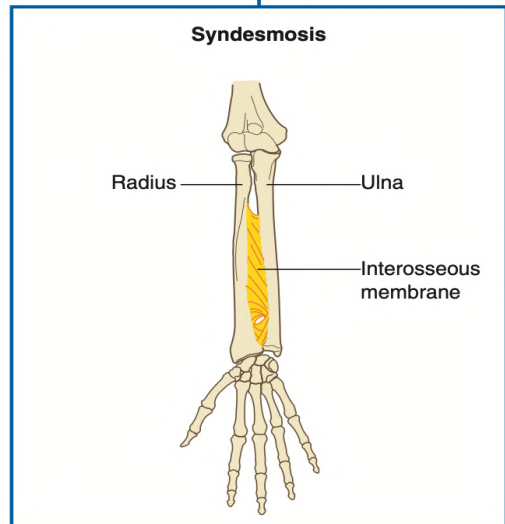
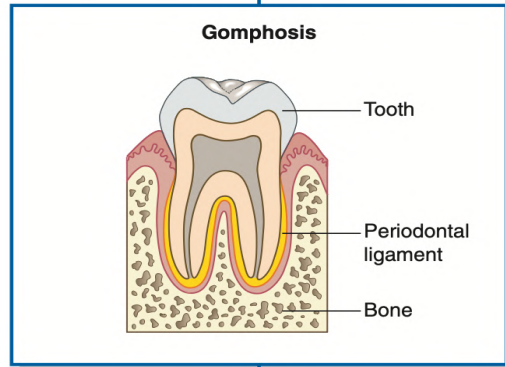
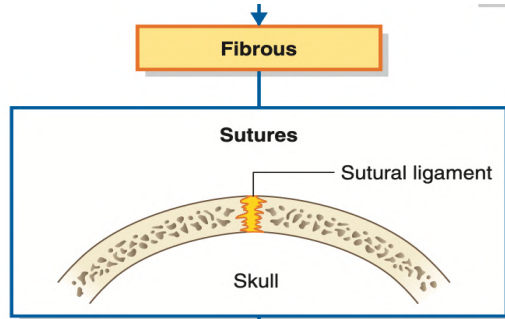
# Lymphoid organs:



# SOLID JOINTS



Middle radio-ulnar joint  
Inferior tibio-fibular joint  
Sacroiliac joint



- Manubriosternal joint
- Xiphisternal joint
- Intervertebral disc
- Pubic symphysis
- Sacro-coccygeal joint

# JOINTS-SYNOVIAL

---

- Incus-stapes
- Hip
- Shoulder
- Talo-calcaneo-navicular

- Malleus-incus
- 1<sup>st</sup> CMC
- Calcaneo-cuboid
- Sterno-clavicular
- Femur-patella

Atlanto-occipital  
  
Sup/inf radio-ulnar

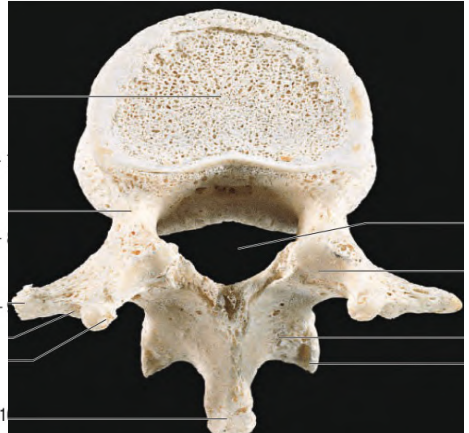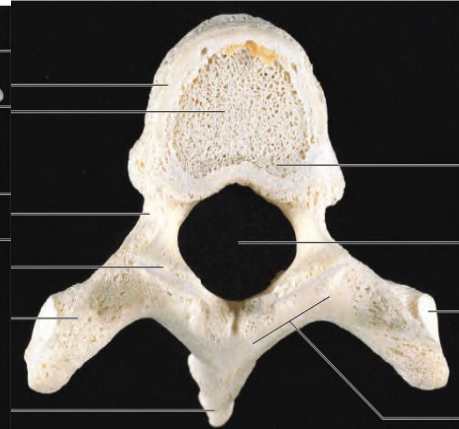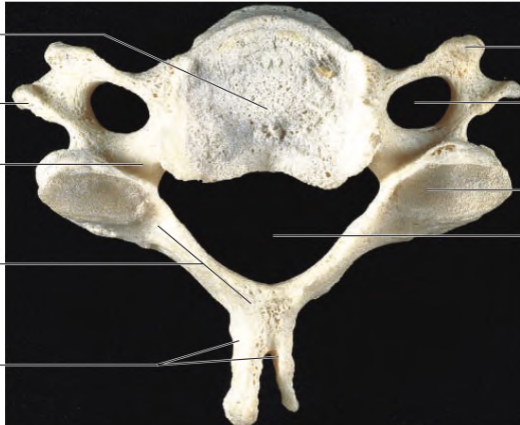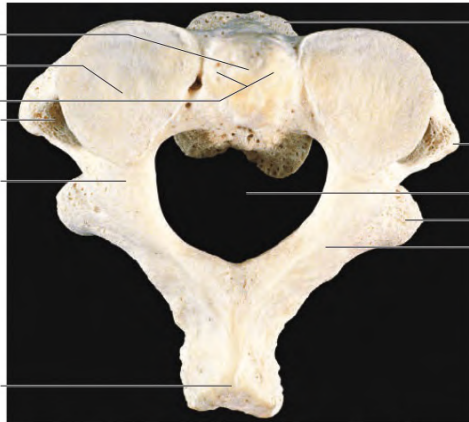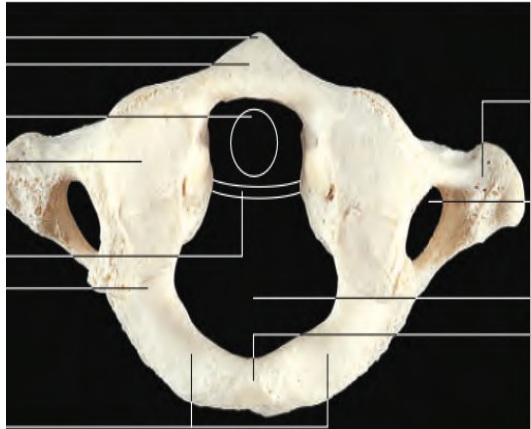Atlanto-axial  
  
Wrist  
MCP/MTP

TMJ  
Knee

Ankle  
Elbow  
IP

- Intercarpal
- Intertarsal
- Sup tibio-fibular
- Acromio-clavicular
- Costo-transverse
- Costo-vertebral
- Sterno-costal except 1st

# MISCELLANEOUS



Normal prostate volume:

Reticular fibres absent in:

Superficial posterior compartment of leg:

CCA division at the level of:

Transverse facial artery:

Primary ossification centres appear before birth and are single EXCEPT:

Only long bone with membranous ossification/ first to start ossification (5<sup>th</sup> week POG):

25 cm: Esophagus - Duodenum - Ureter - Descending colon

45 cm: Spinal cord - Thoracic duct - Vas deferens - Sartorius - Femur - Transverse colon

<b>Composite muscle</b>	<b>Nerve supply</b>
<b>Digastric</b>	Anterior belly: V3 Posterior belly: Facial nerve
<b><u>Flexor digitorum profundus</u></b>	Medial half: Ulnar nerve Lateral half: Anterior interosseous (branch of median nerve)
<b><u>Adductor magnus</u></b>	Adductor part: Obturator nerve Hamstring part: Tibial nerve
<b><u>Biceps femoris</u></b>	Long head: Tibial nerve Short head: Common peroneal nerve
<b><u>Pectineus</u></b>	Anterior fibres: Femoral nerve Posterior fibres: Obturator nerve
<b>Brachialis</b>	Proprioceptive: Radial nerve Motor: Musculocutaneous
<b><u>Flexor pollicis brevis</u></b>	Superficial head: Median nerve Deep head: Deep branch of ulnar nerve
<b>Pectoralis major and minor</b>	Medial and lateral pectoral nerves
<b>Subscapularis</b>	Upper and lower subscapsular nerves

**Parallel arrangement:** Thyrohyoid, Sternohyoid, Rectus abdominis, Fusiform:  
**Biceps brachii, digastric**

# Cadaveric sections

